

Neuroorthopaedics

Z. Rozkydal

Cerebral palsy

Obstetric paralysis

Stroke patients

Neuromuscular atrophies

Spinal dysraphism (spina bifida occulta
myelomeningocele, diastematomyelia)

Neurogenic arthropathies

Poliomyelitis

Peripheral nerve palsy

Cerebral palsy

Perinatal damage of CNS

1-5 /1000 new born babies

Causes: prenatal (rubeola, toxoplasmosis, cytomegalovirus,
drugs, alcohol)
perinatal (premature newborn, anoxia,
intracerebral bleeding)
postnatal (meningitis, encefalitis, injuries of the head)

Types

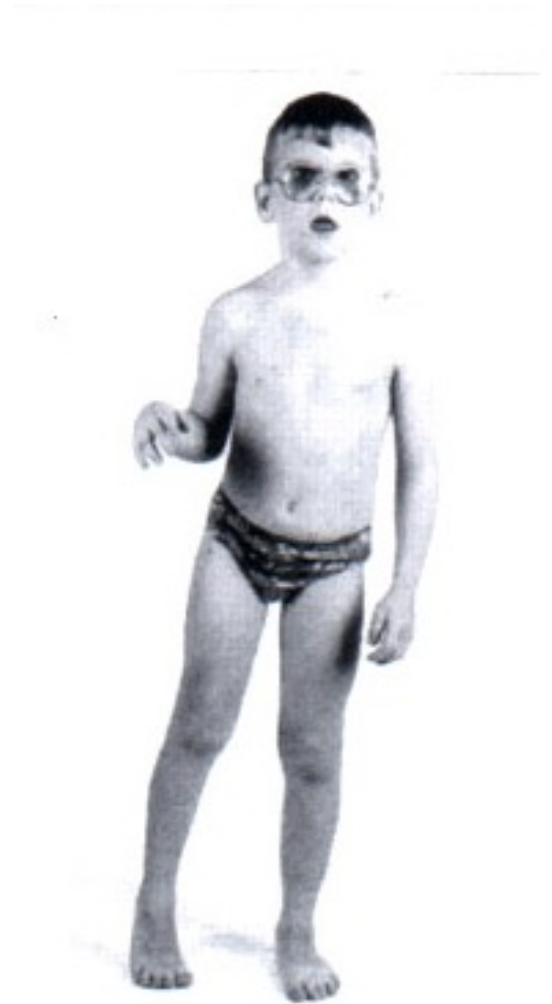Spastic paralysis	50 %
Athetosis	25 %
Ataxia	7 %
Tremor	1 %
Rigidity	7 %
Combinations	10 %

Hemiparesis

30 % of all cases

$\frac{1}{2}$ normal intelligence

Good walking ability



Diparesis

Both lower extremities are involved more than upper extremities

Retarded motoric and psychologic development

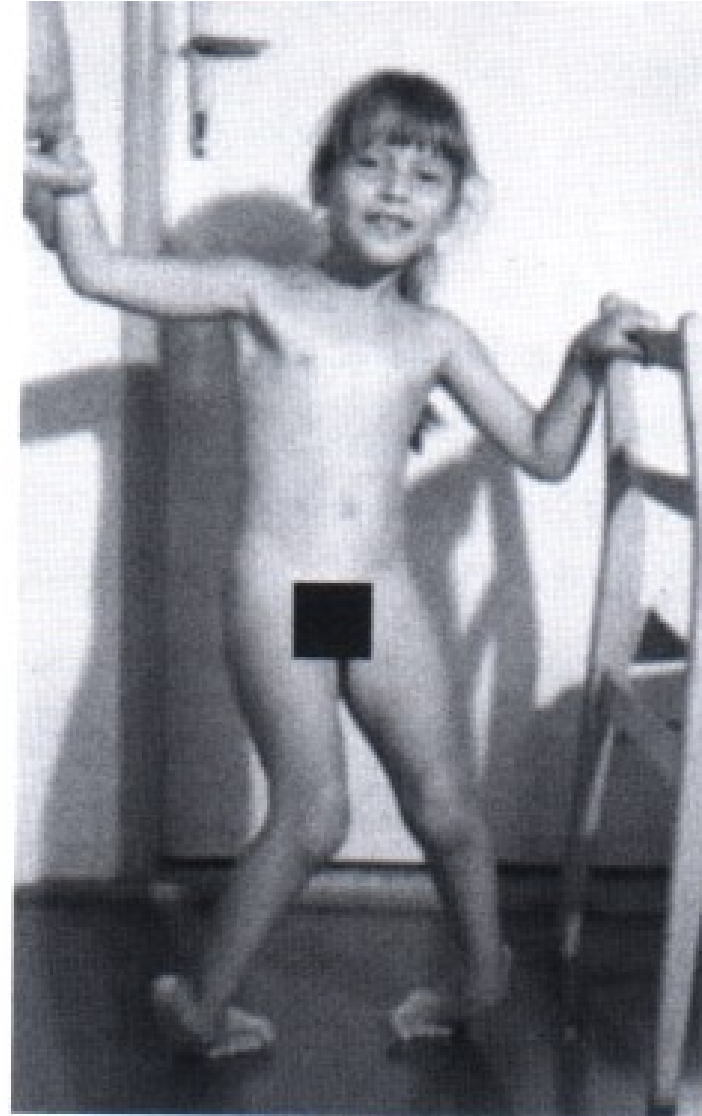Strabismus

Scissors gait

Flexion and adduction contracture in hip

Flexion contraction of the knee

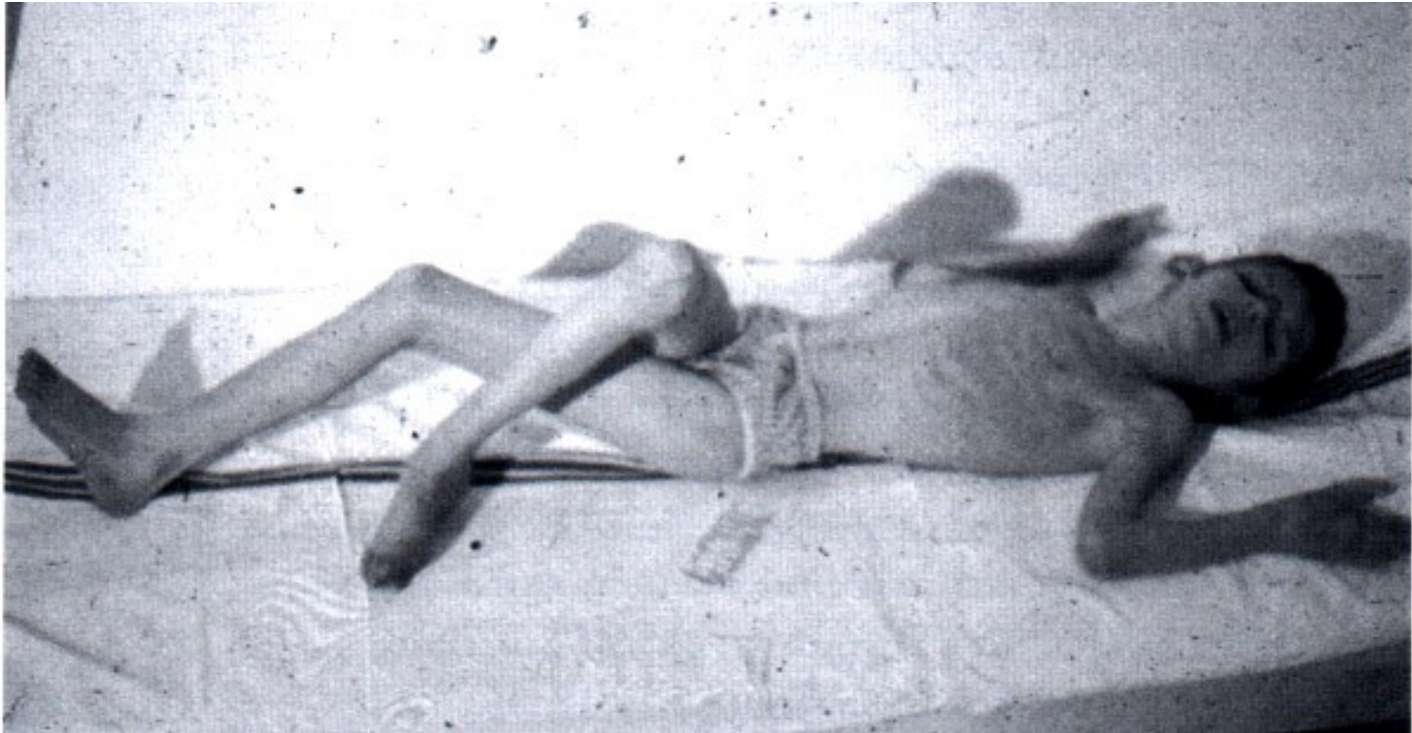
Equinosity of the feet, tip toe walking



Quadraparesis, tri paresis

Severe paralysis of both extremities

Head nerves involvement, debilitated patients



Management

Neonatology

Pediatrics

Neurology

Physiotherapy

Orthopaedic surgeon

Psychology

Social worker

Prosthetics

Orhopaedic procedures

Hip joint

Adductor tenotomy

Transposition of adductor of the hip

Iliopsoas recession

Open reduction of dislocated hip

Varus osteotomy of the femur

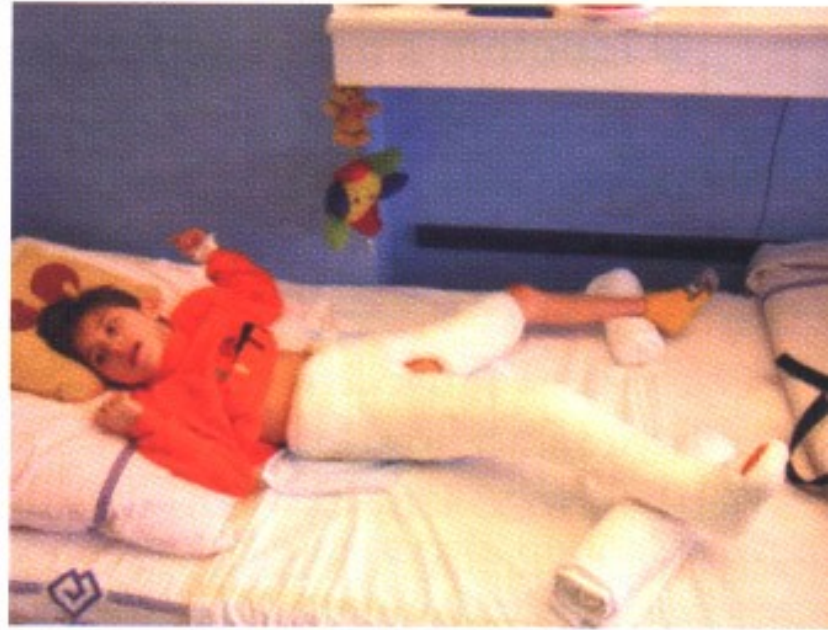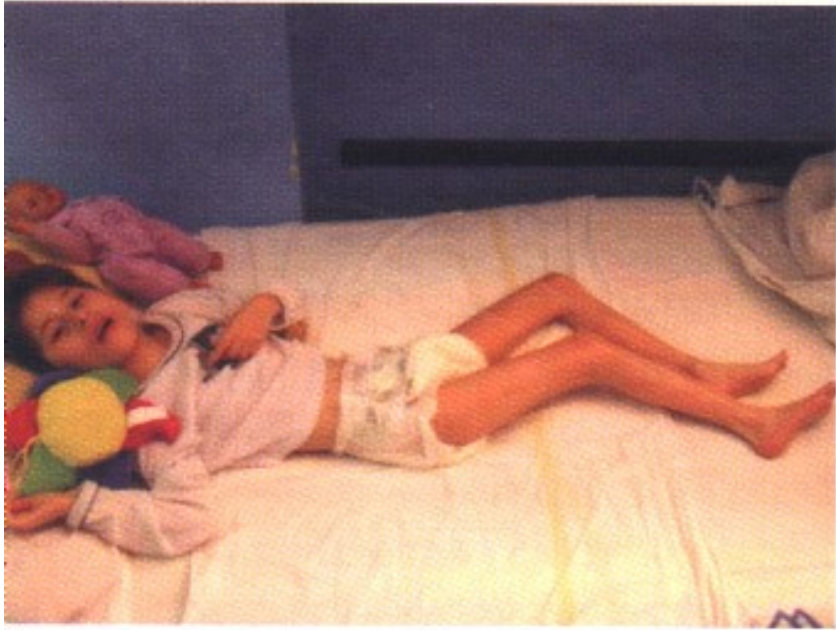Acetabuloplasty, shelf procedures

Osteotomy of the pelvis

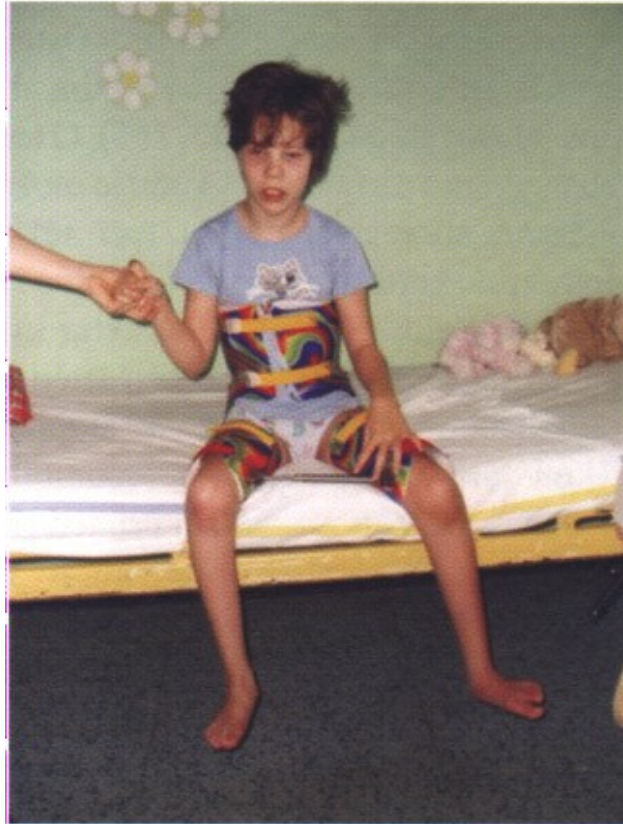Girdlestone

Schanz

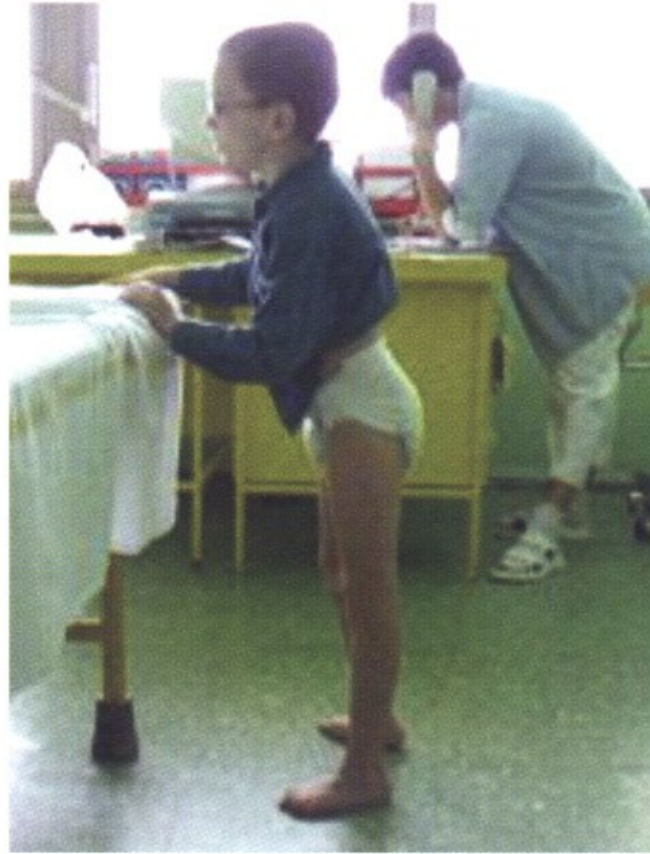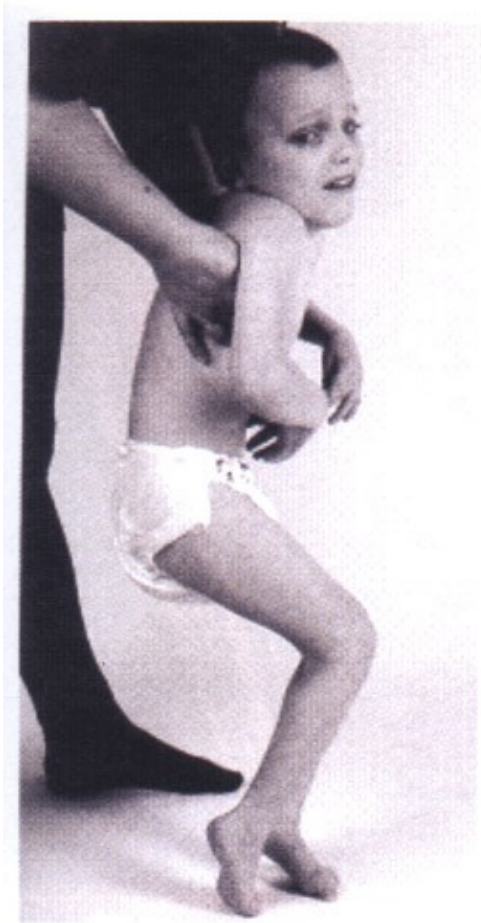THA



Adductor tenotomy



Atlanta orthosis



Flexion contracture of the hip and knee joints
Before surgery, after surgery

Procedures in the knee region

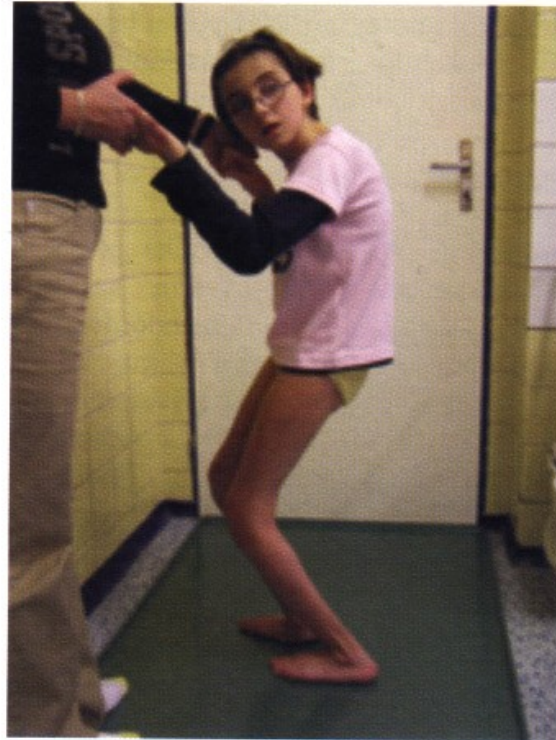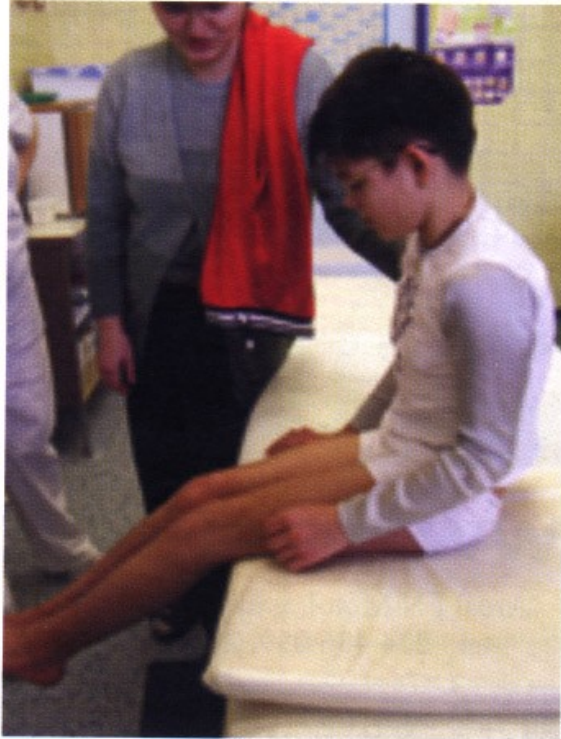
Prolongation of flexors

Transposition of distal insertion of rectus femoris muscle

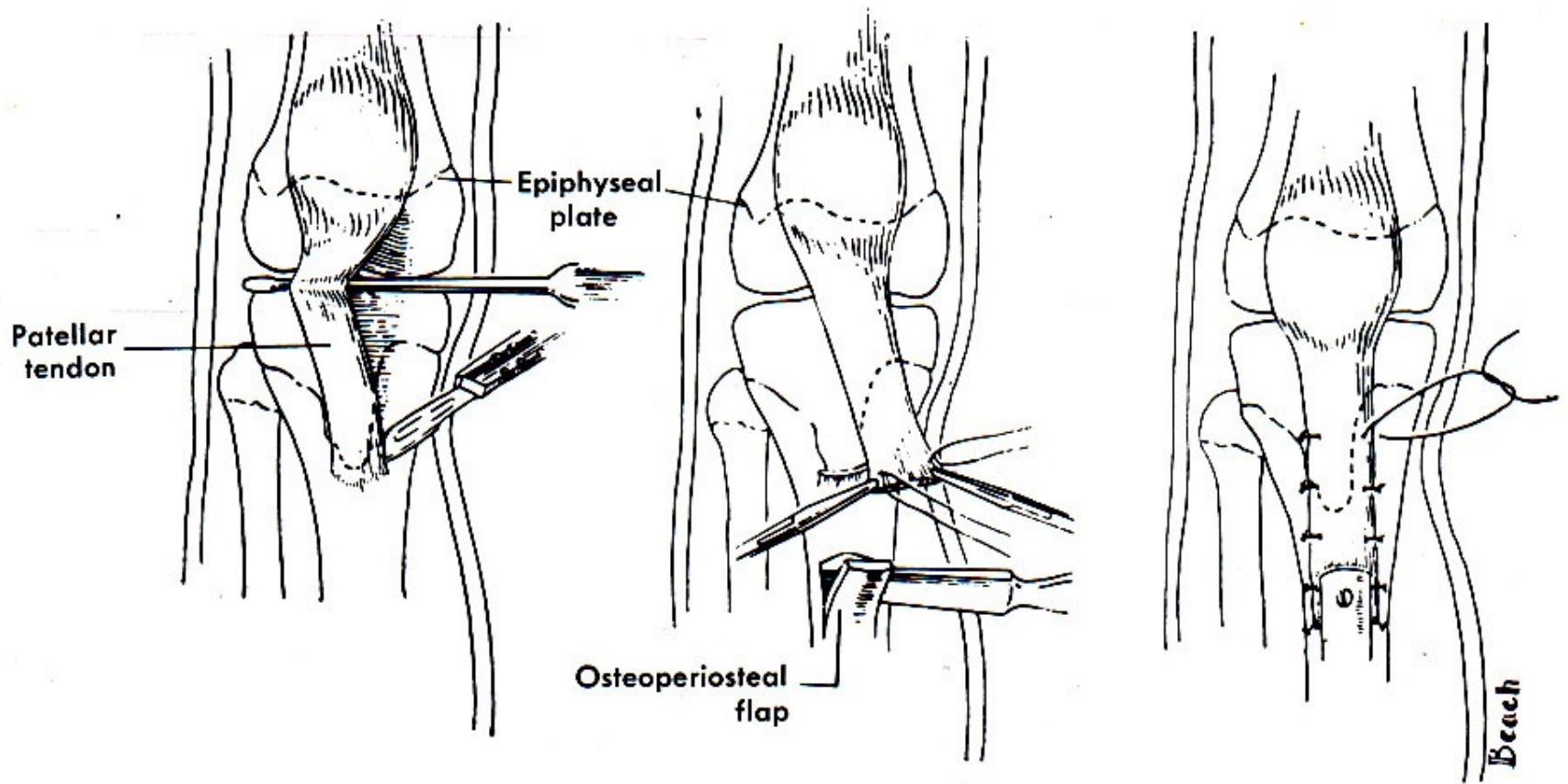
Eggers transposition of flexors

Plication of patellar tendon

Patellar advancement



Flexion contracture of the knee joints



Distalisation of patellar tendon- Baker procedure

Deformities of the foot

Pes varus

Pes valgus

Pes cavus

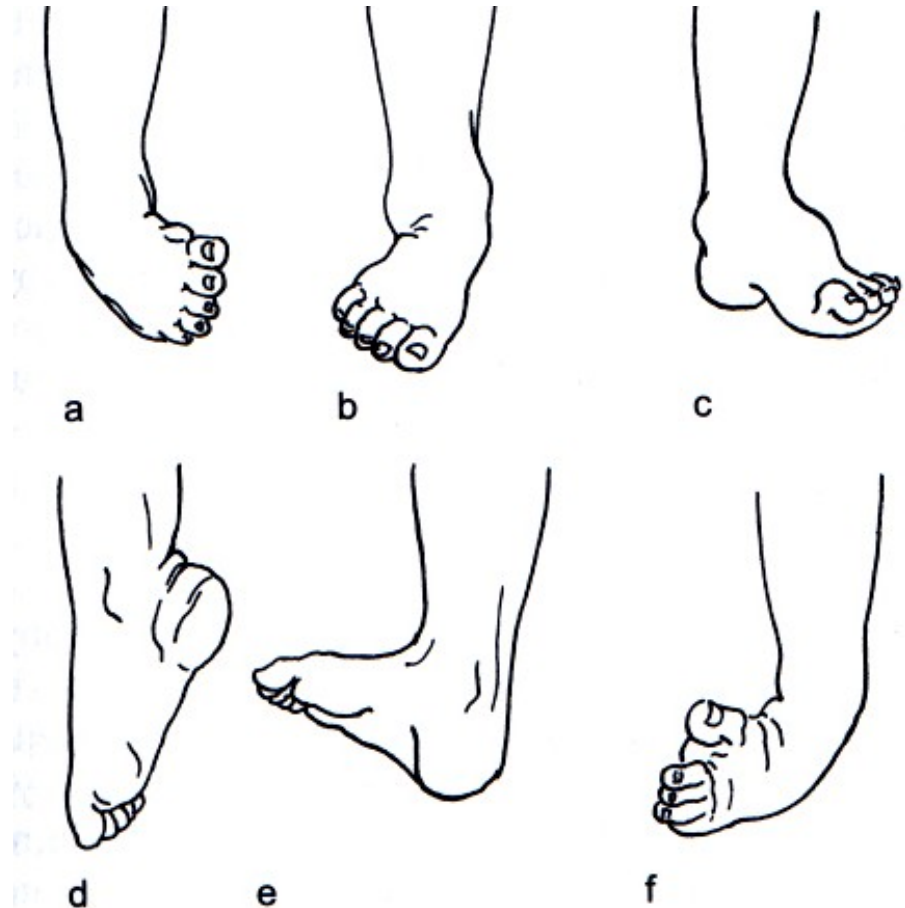
Pes equinus

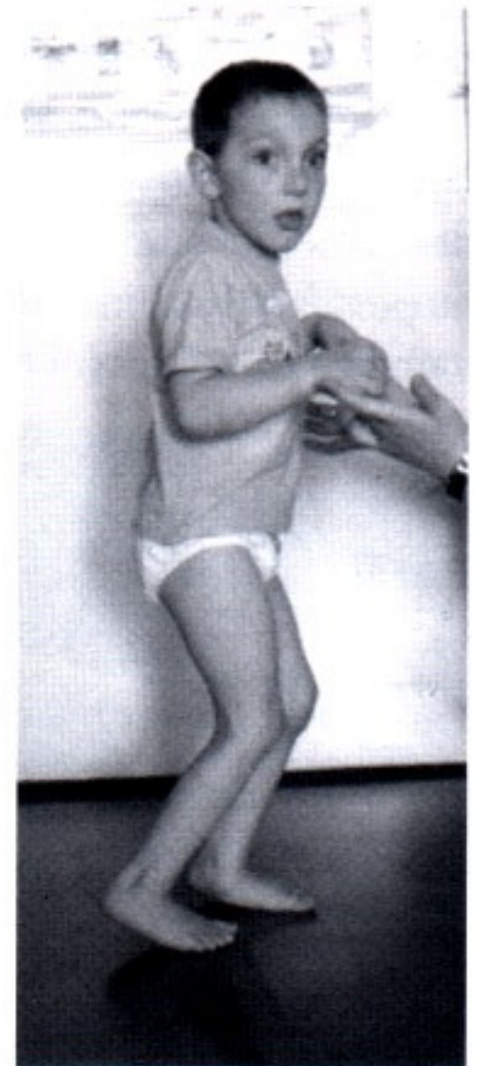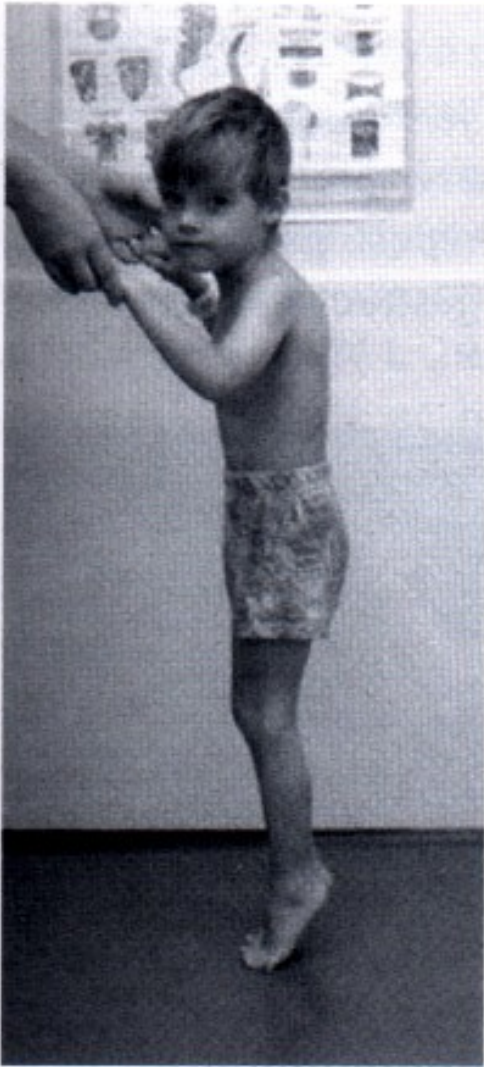Pes calcaneus

Pes equinovarus

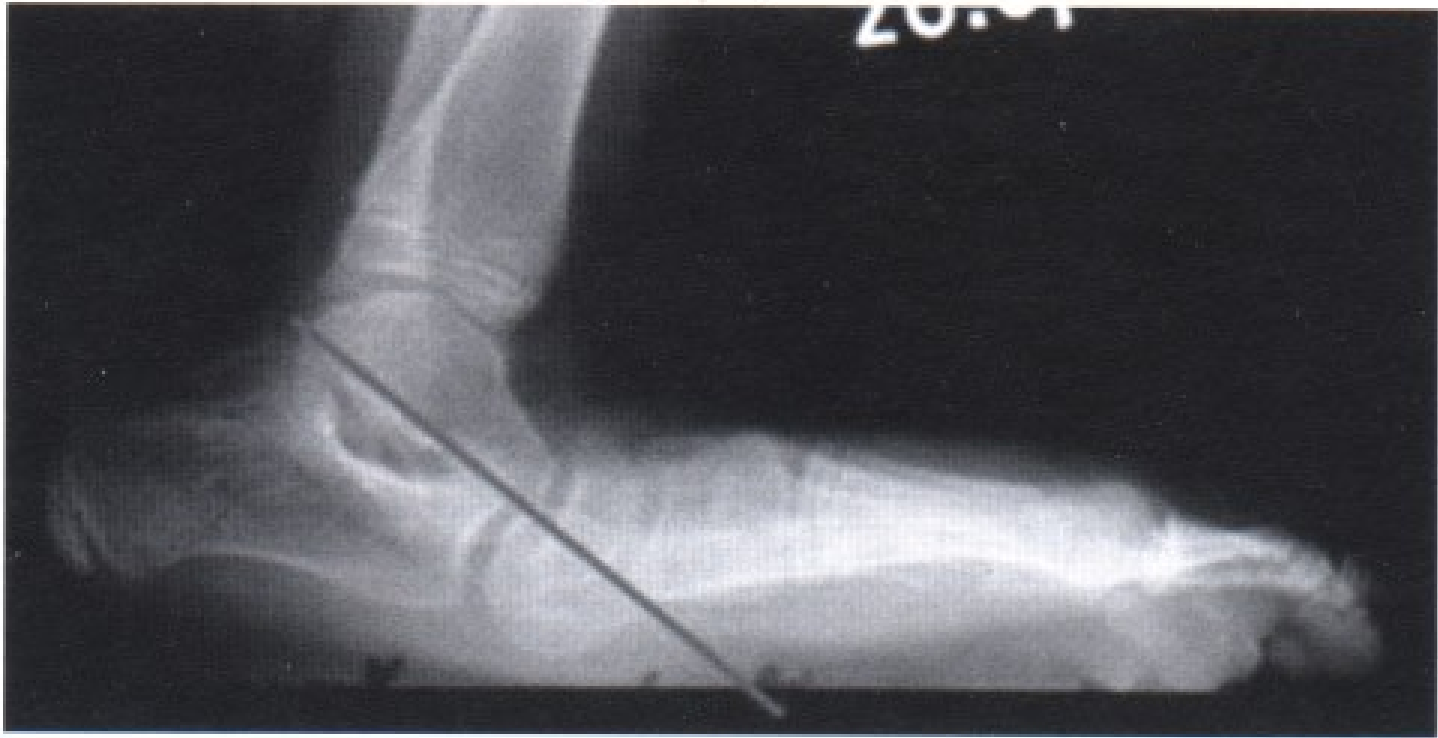Flail foot

Vertical talus





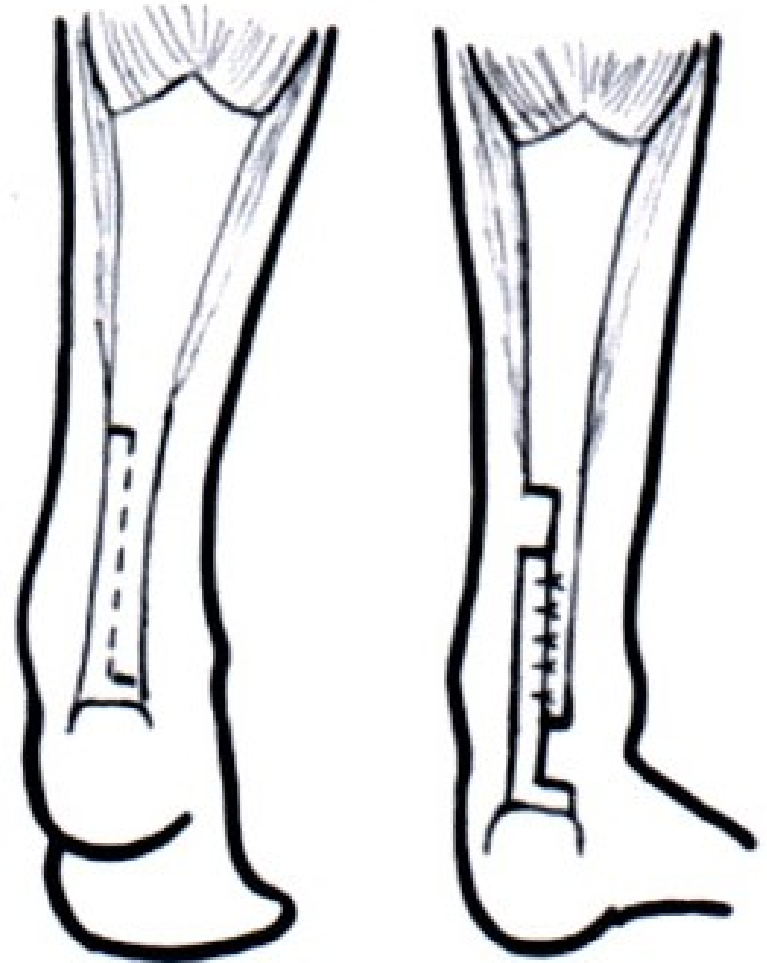
Deformities of the foot



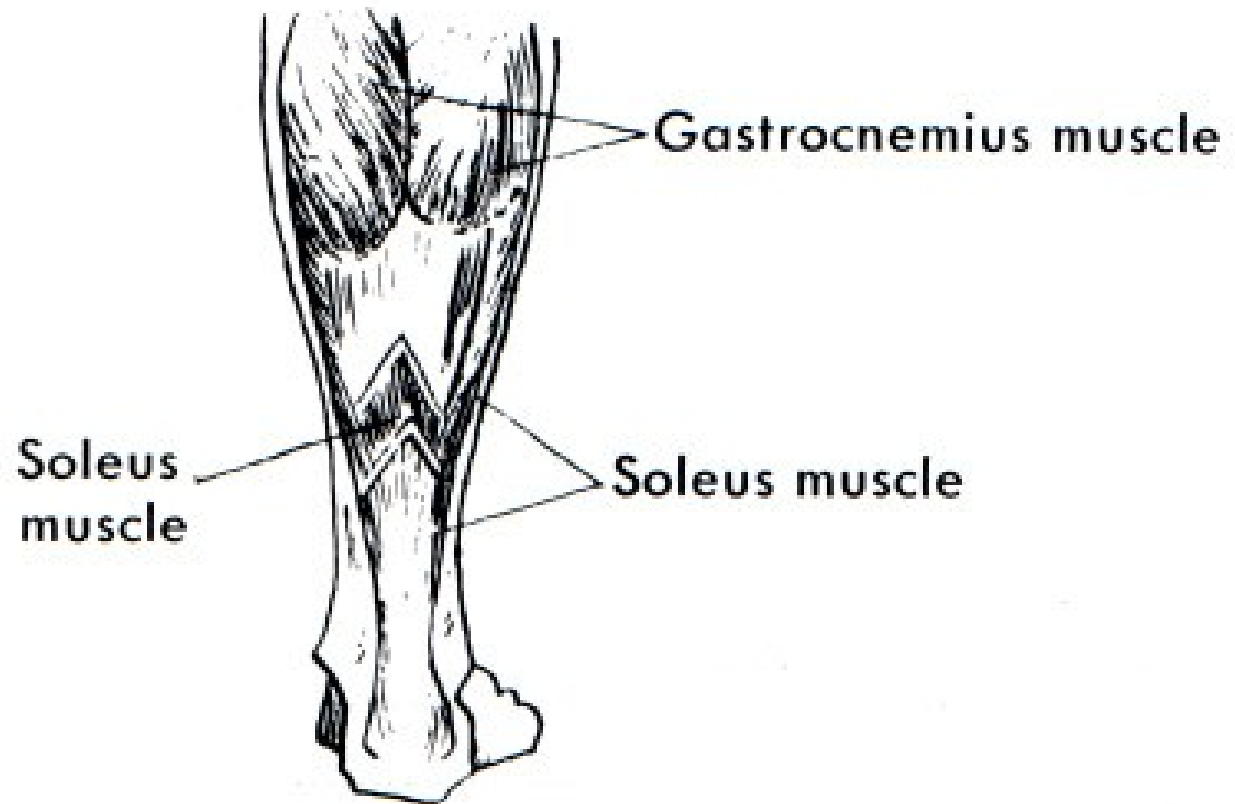
Paralytic flat foot

Procedures in the foot

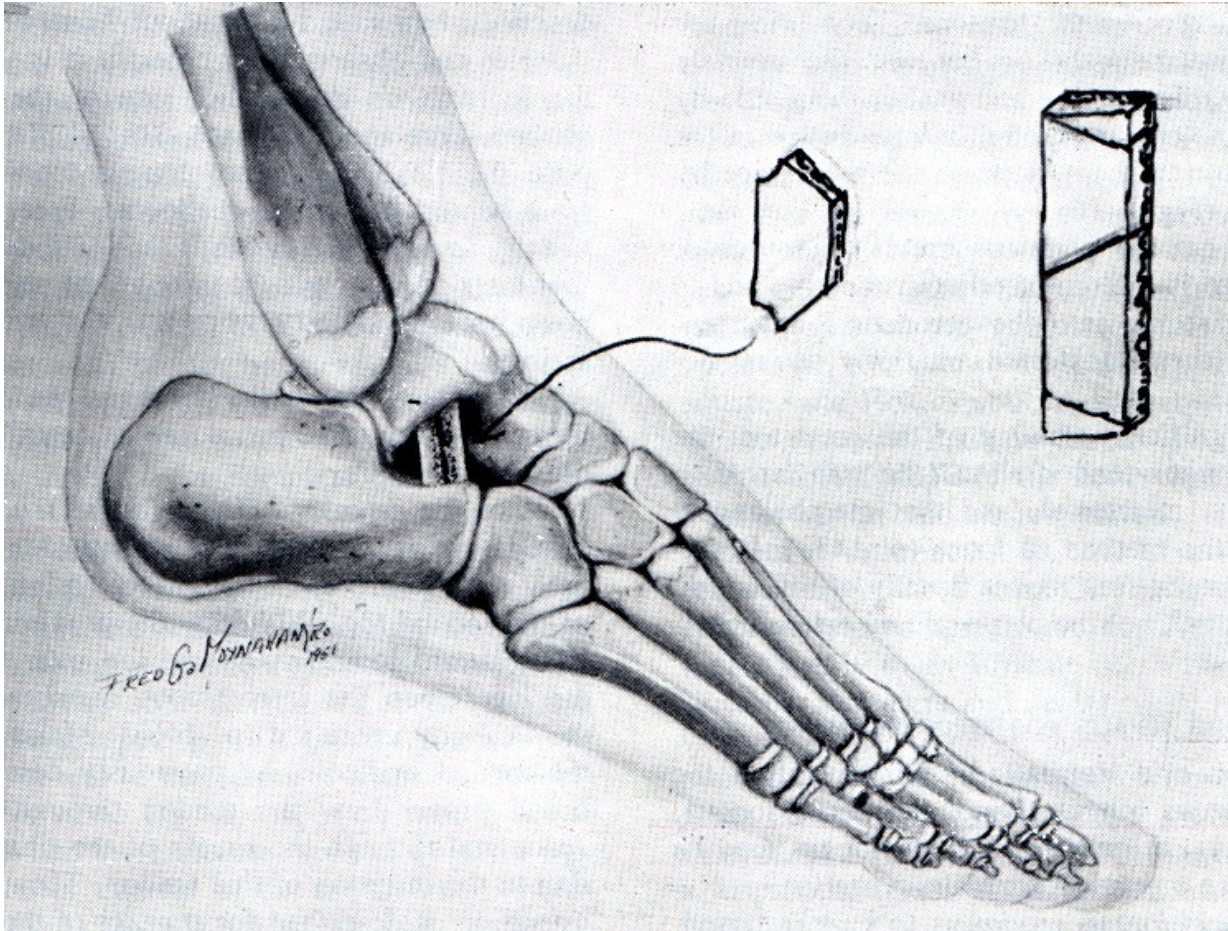
- Prolongation of Achillis tendon
- Vulpius
- Strayer
- Silverskiold
- Transposition of tibialis anterior
- Grice procedure
- Dwyer procedure
- Young procedure
- Triple arthrodesis
- Procedures for deformities of the toes
- Clawing of the toe



Prolongation of Achillis tendon

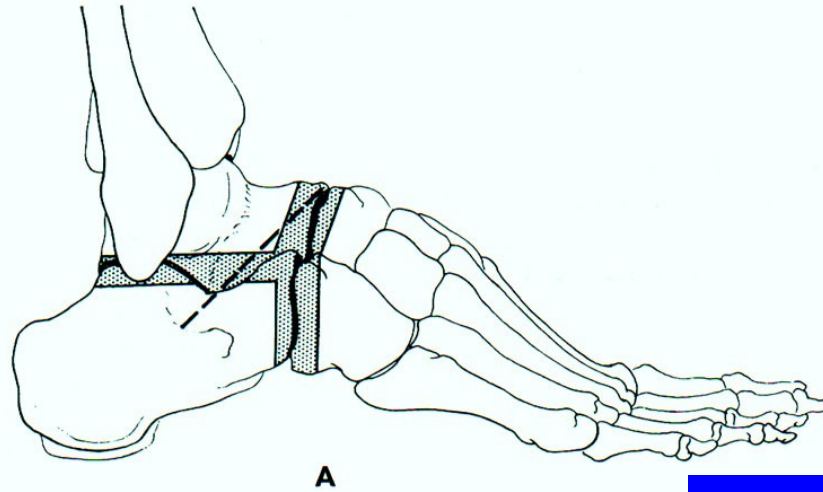


Vulpius procedure

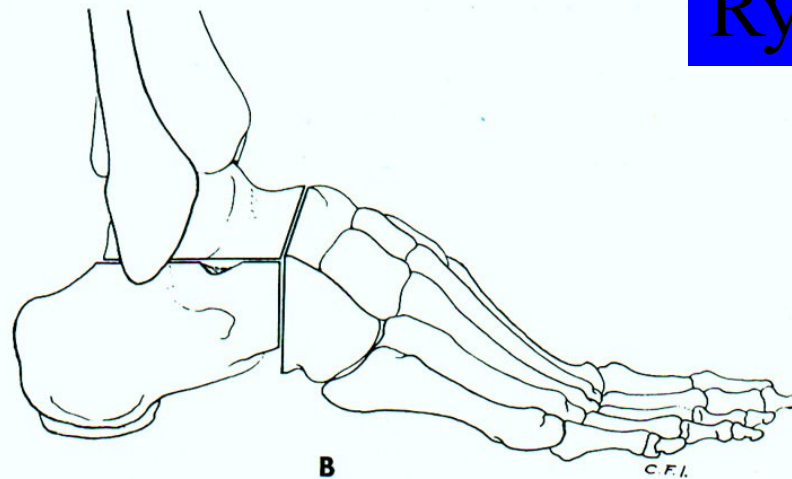


Grice procedure

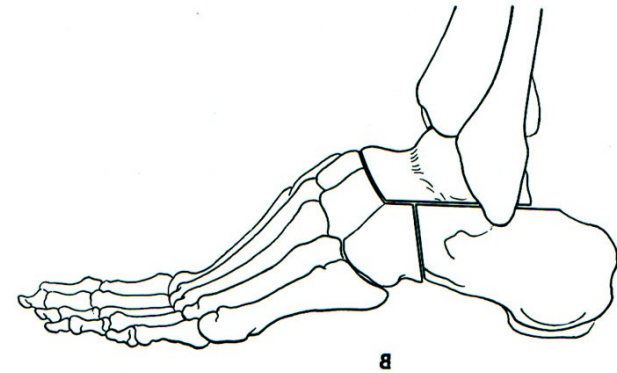
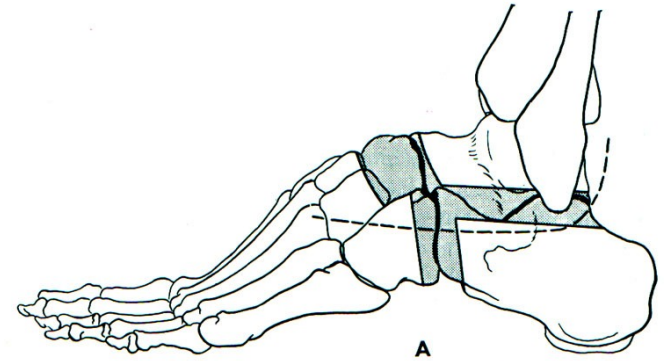
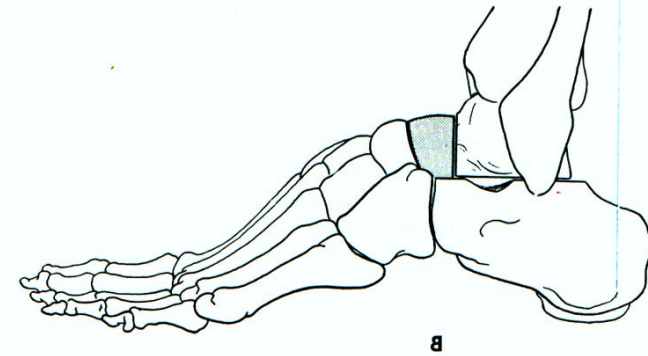
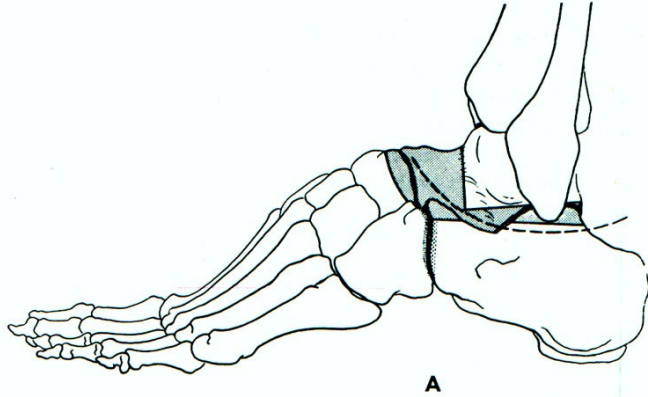
Triple arthrodesis



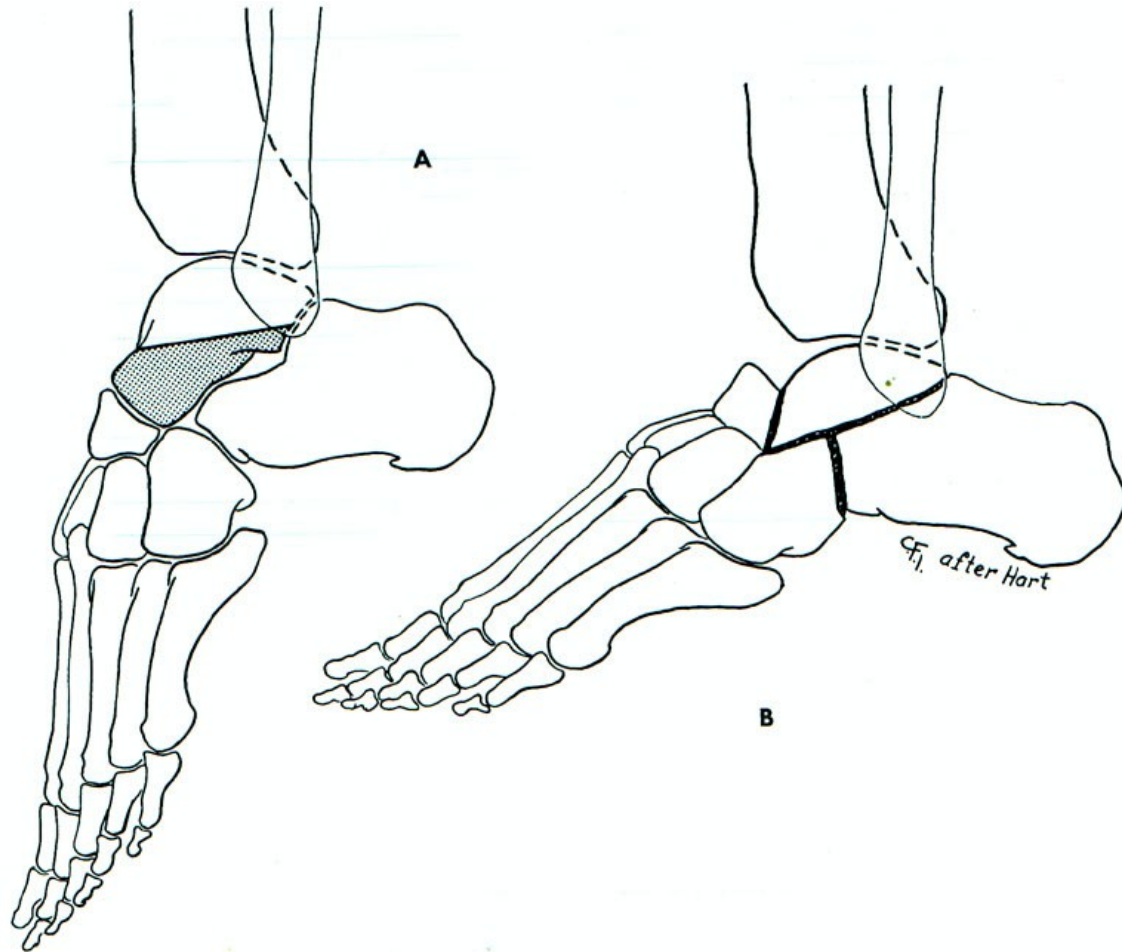
Ryerson



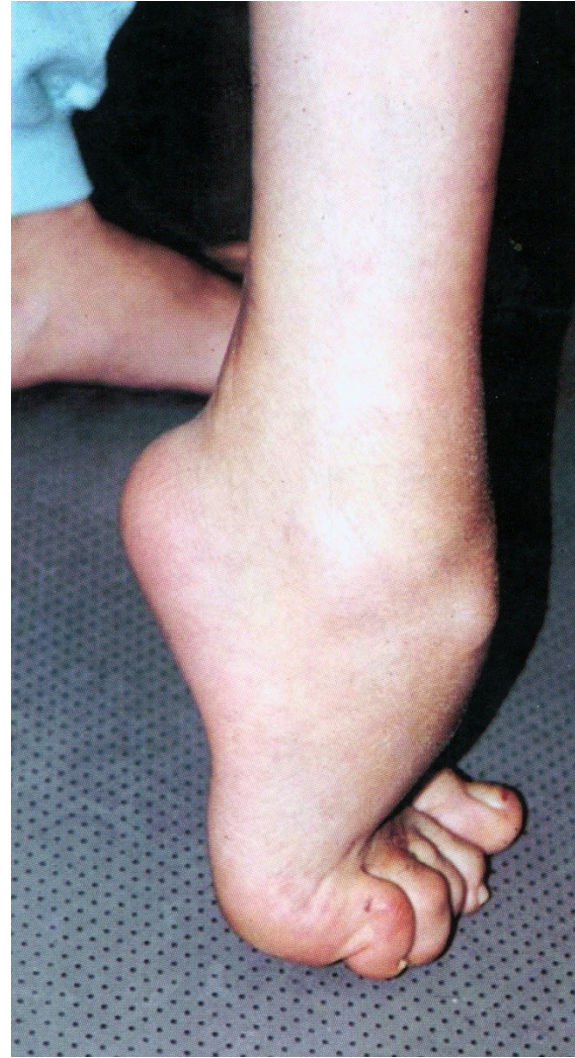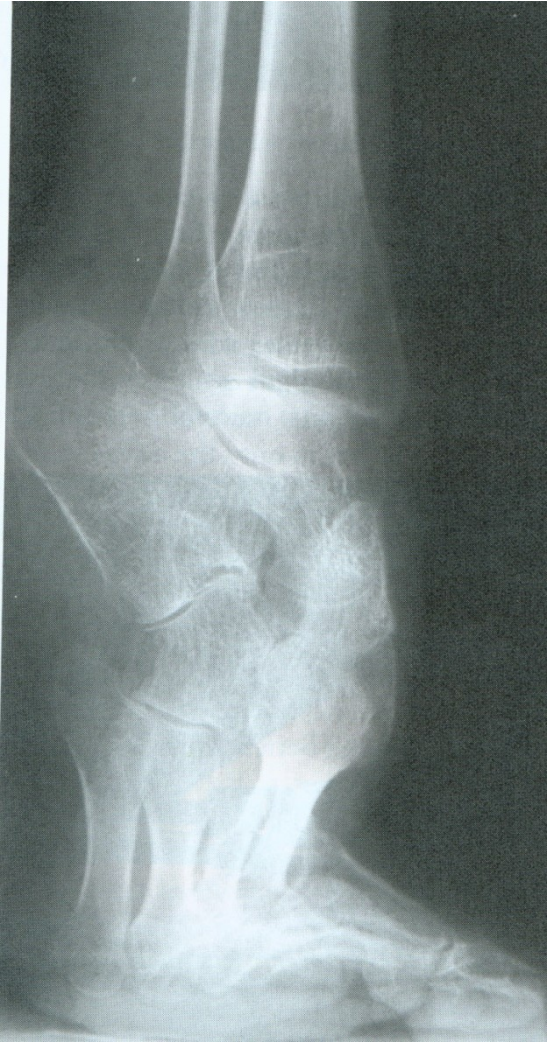Triple arthrodesis



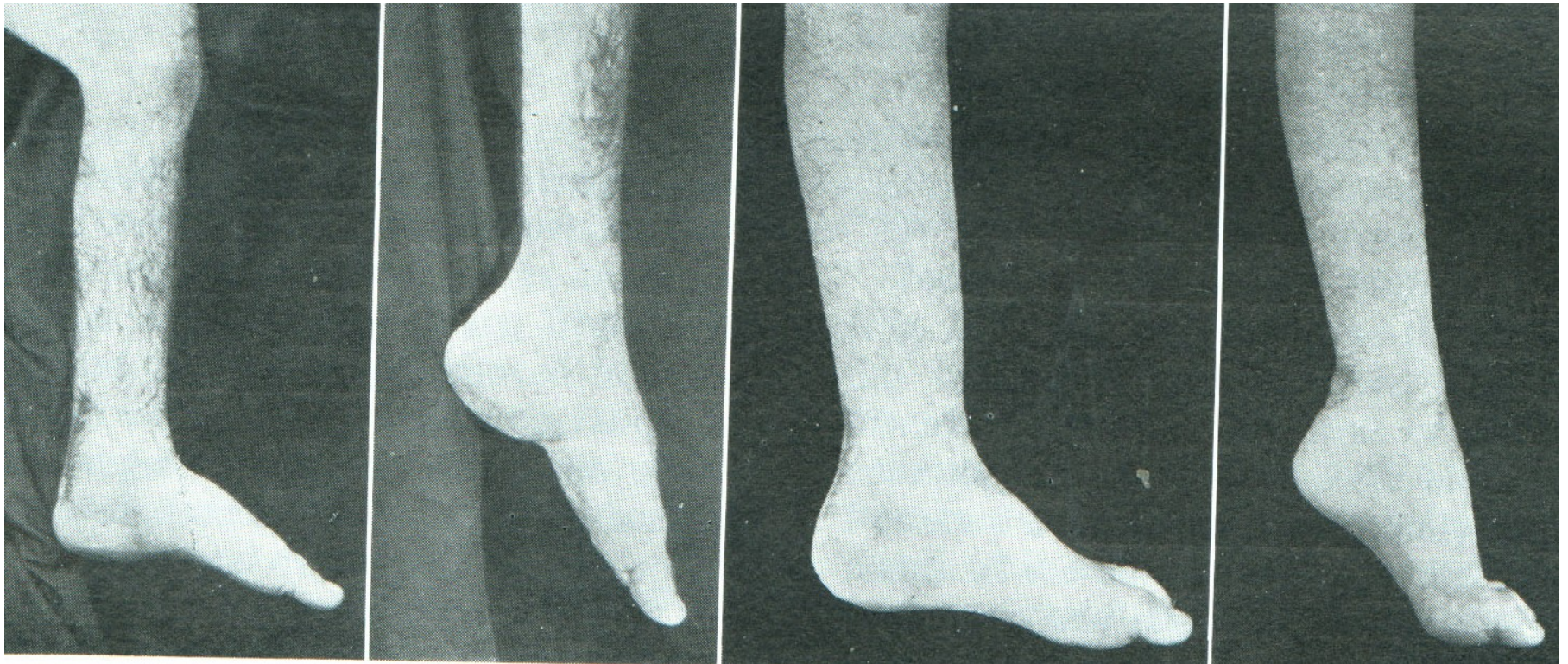
Triple arthrodesis



Equinus deformity



Correction for equinus deformity



Procedures in the hand

Release of adduction and flexion of the thumb

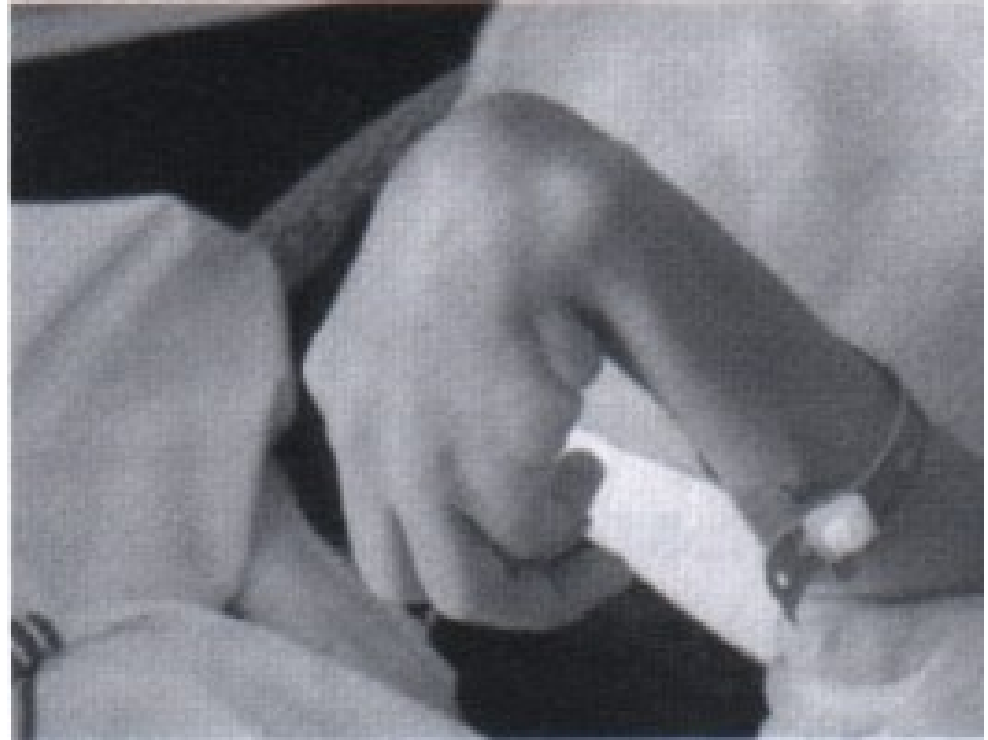Swan neck deformity correction

Release of flexion in the wrist joint

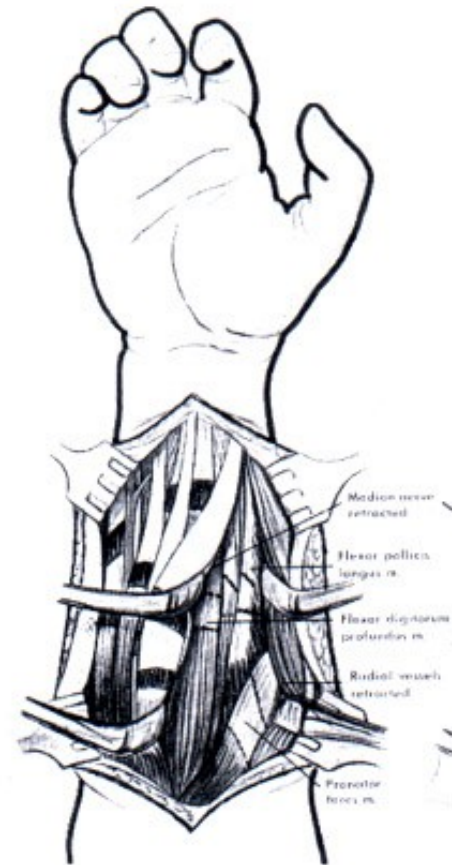
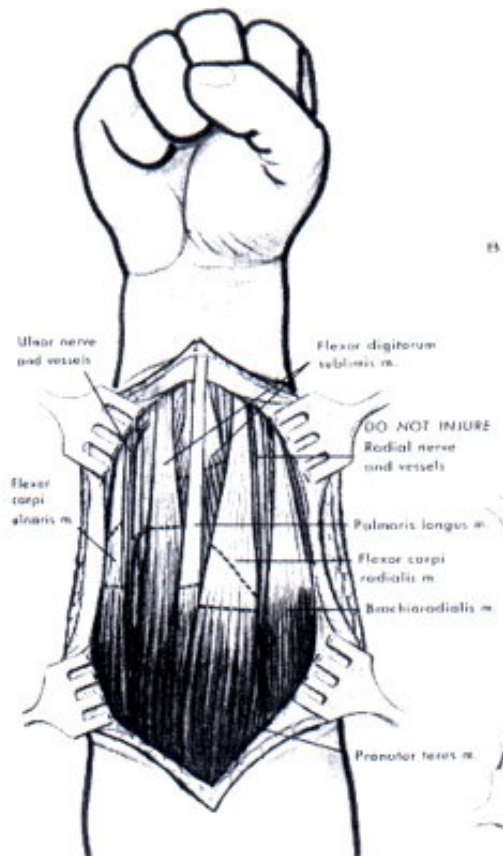
Arthrodesis of the wrist joint

Release of flexion contracture of the elbow

Z-plasty of biceps muscle



Spastic hand in cerebral palsy



Prolongation of flexors of the hand

Deformities of the spine in neurological diseases

Cerebral palsy

Friedreich ataxia

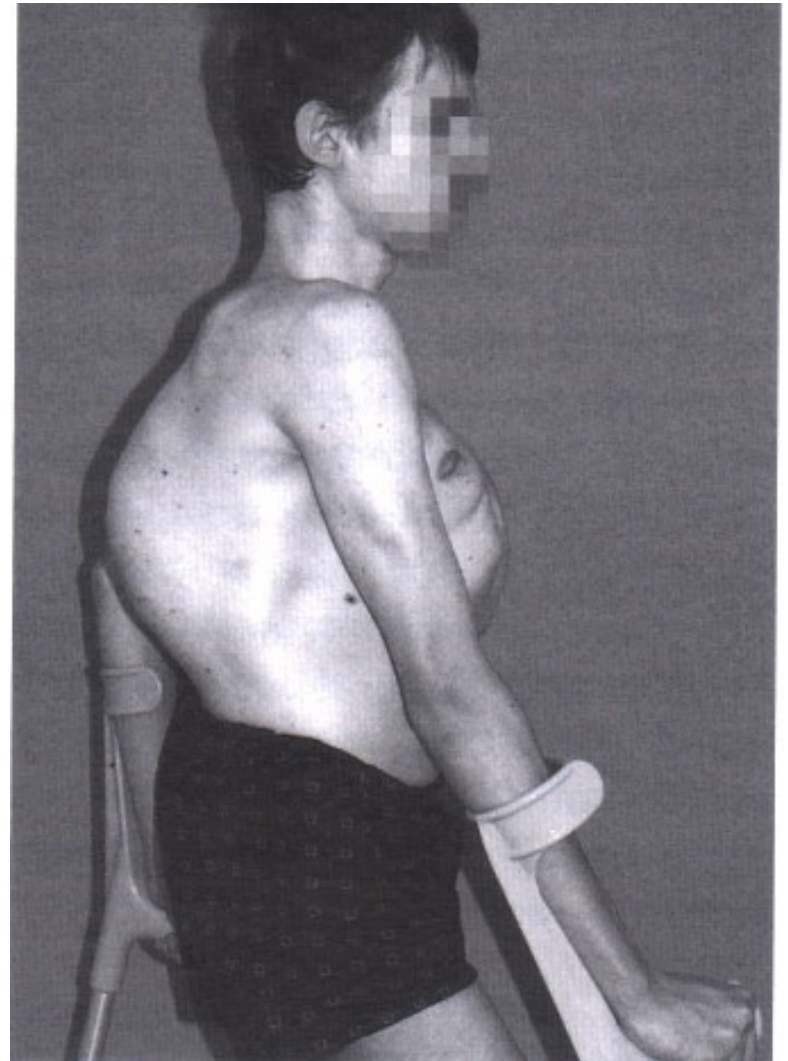
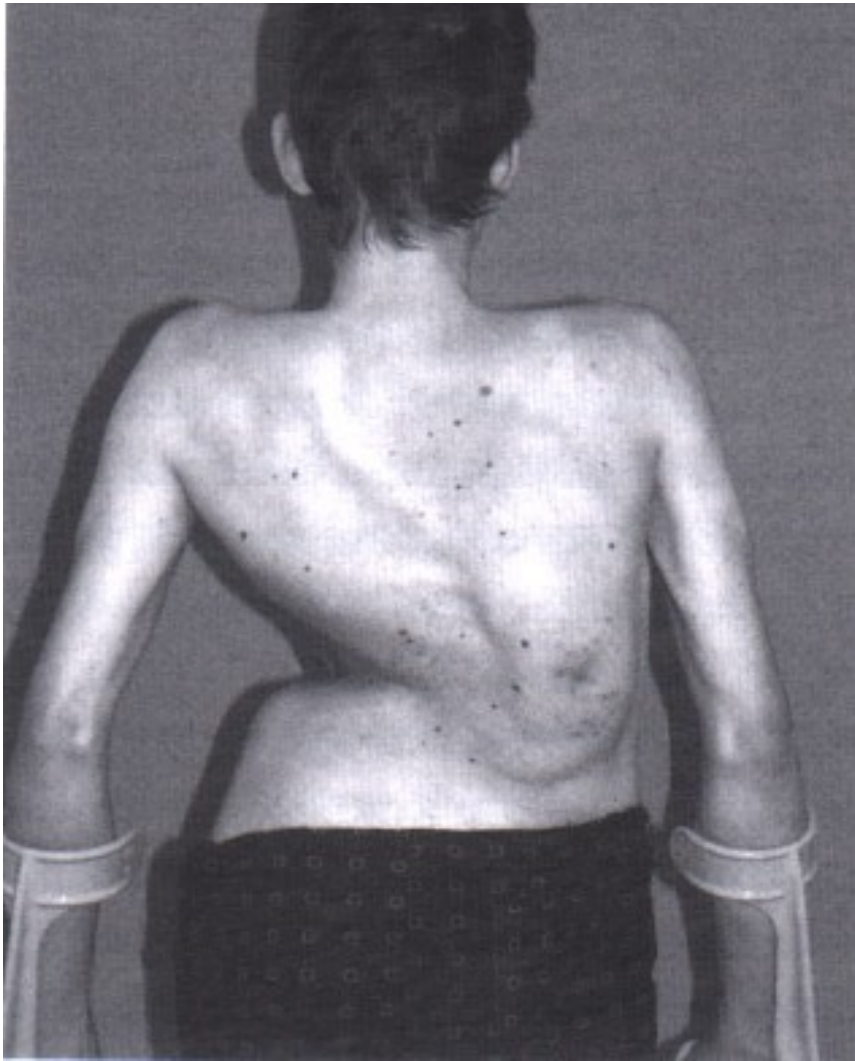Charcot- Marie- Tooth- Hoffmann

Poliomyelitis

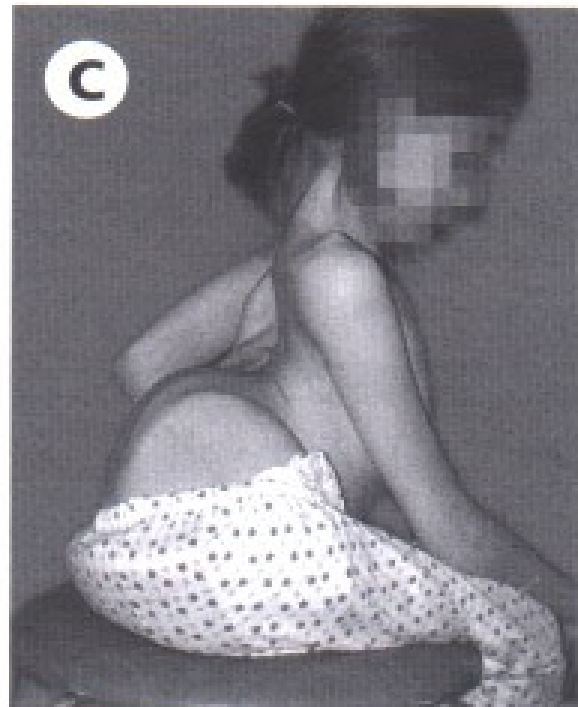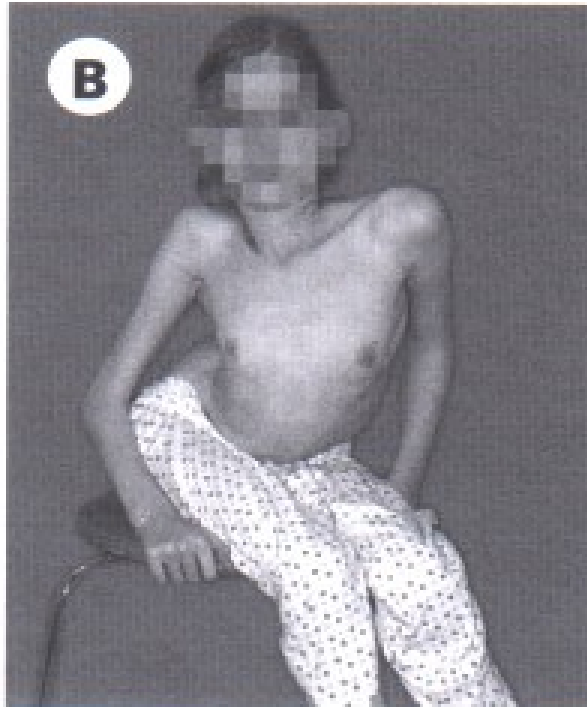
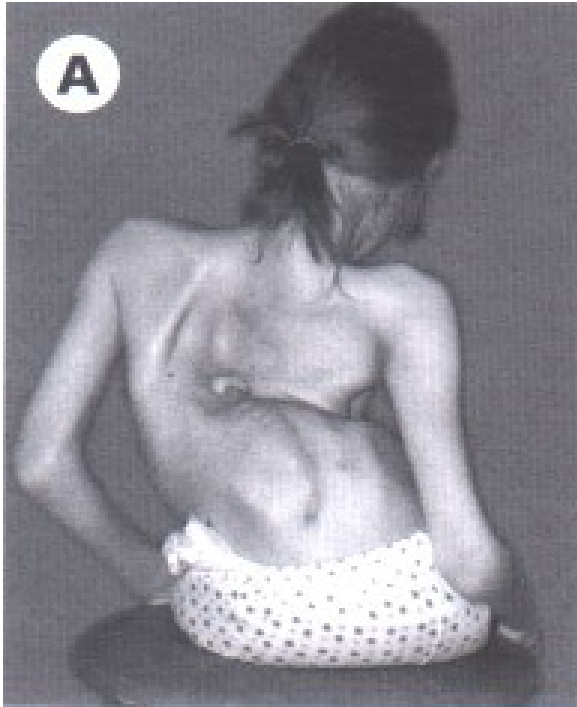
Spinal muscle atrophy

Arthrogryphosis multiplex congenita

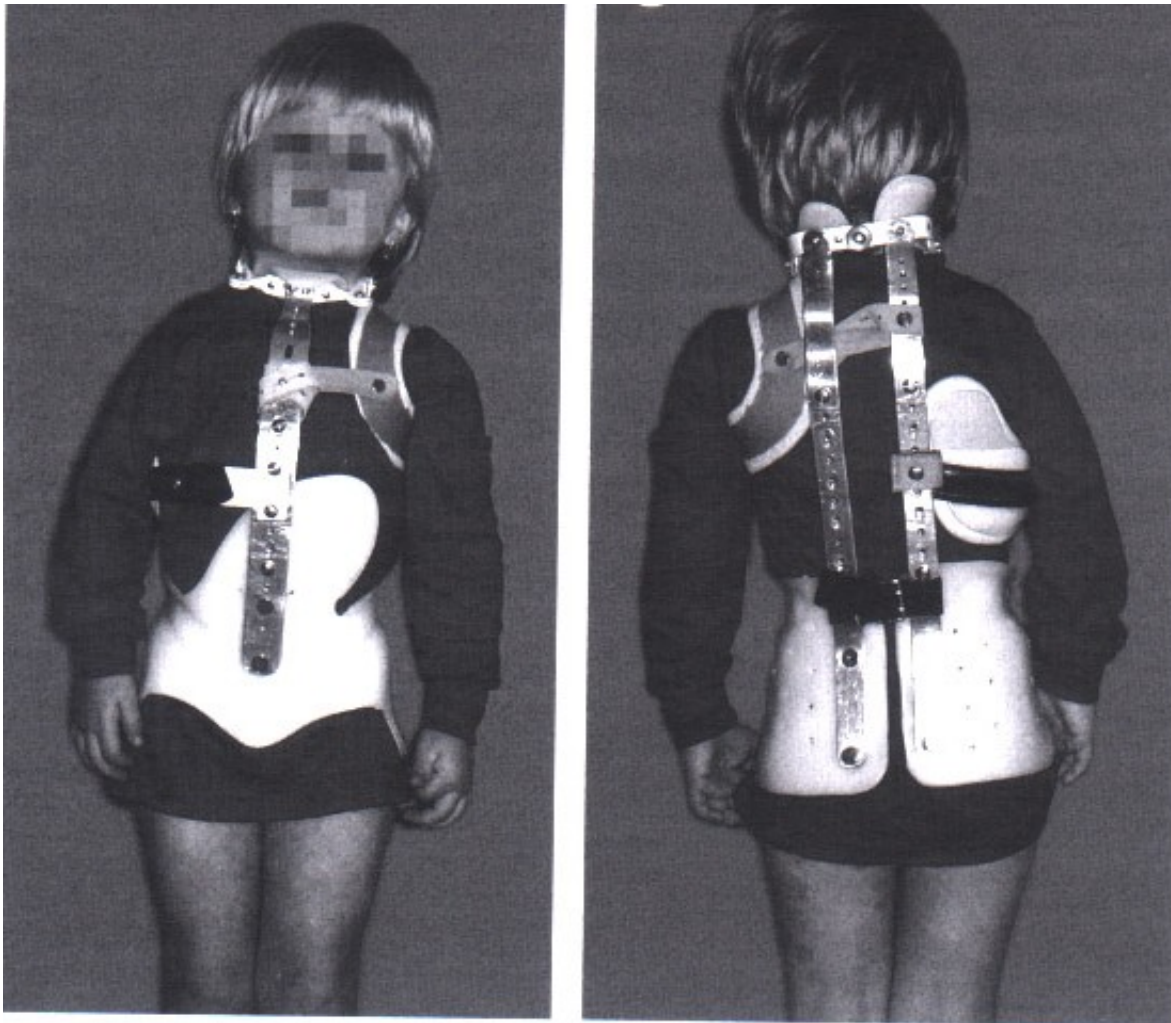
Duchenne muscle dystrophy



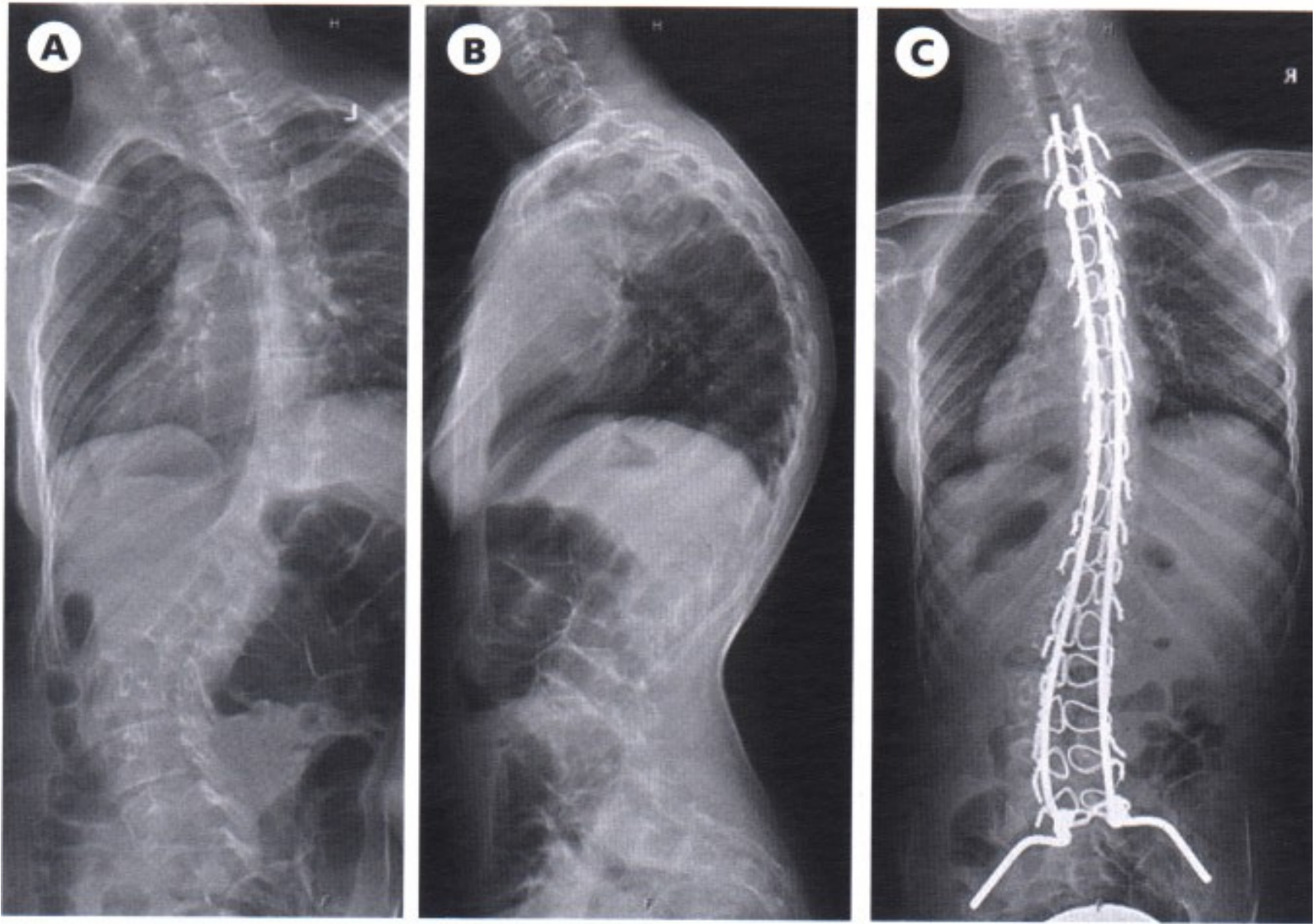
Kyphoscoliosis in cerebral palsy



Scoliosis in arthrogryphosis congenita



Millwaukee orthosis



Luque technique

Obstetric paralysis of brachial plexus

Injury of the brachial plexus during birth

Proximal type C4-C6 Erb- Duchenne

Distal type C7-T1- Klumpke

Total paralysis C4-T1

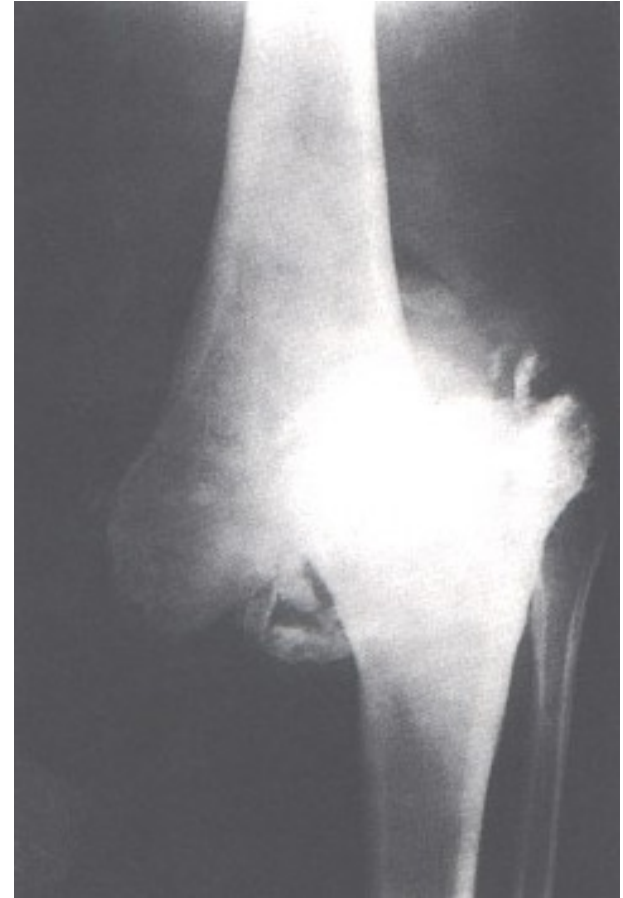
Therapy- physiotherapy

Neurogenic artropathy

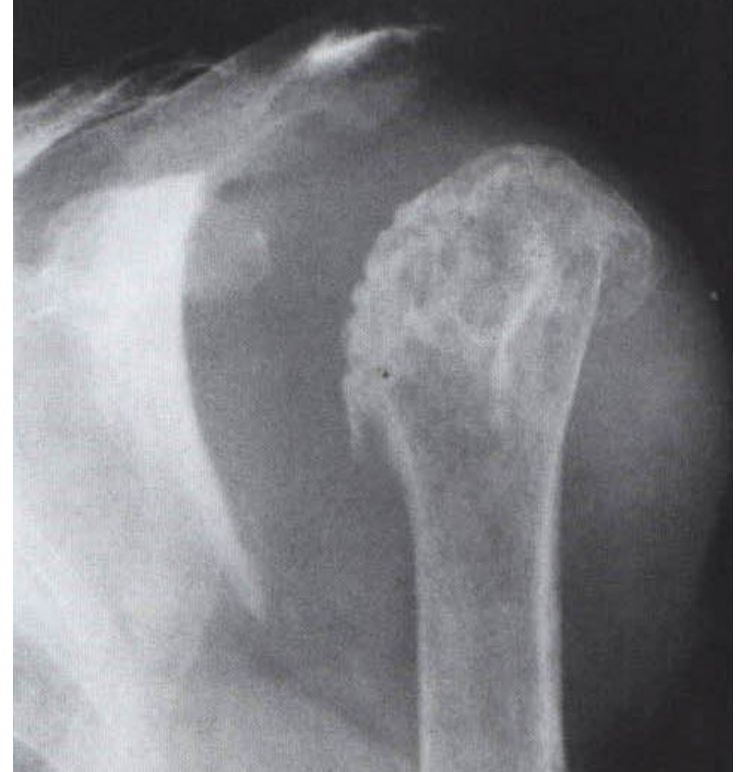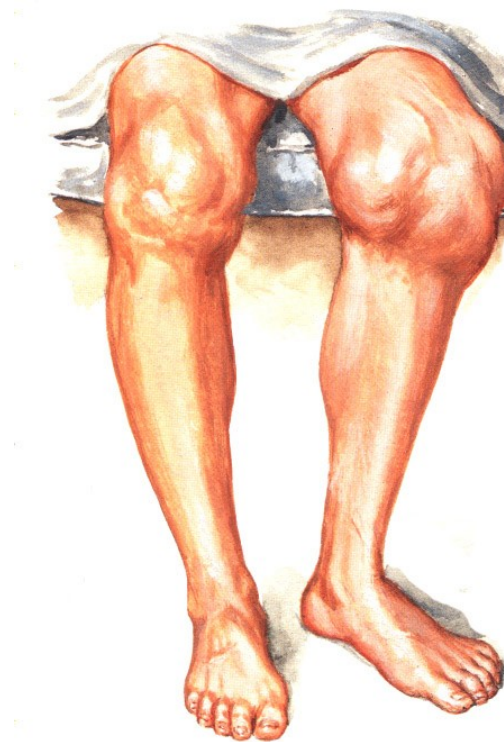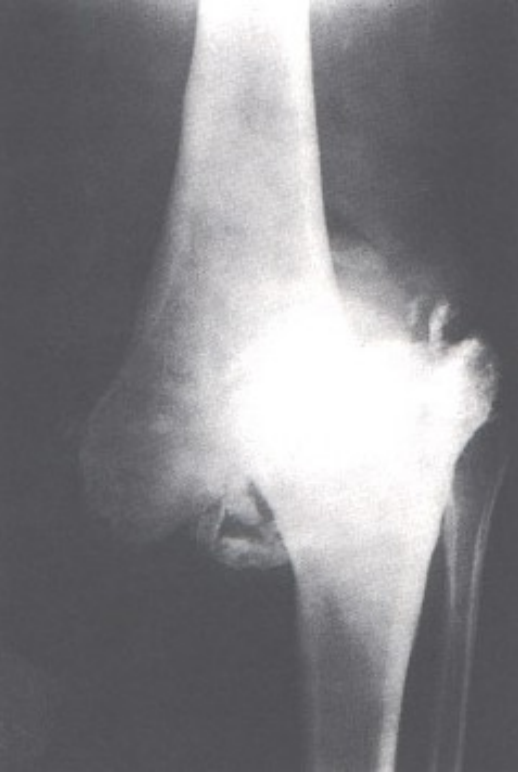Severe damage of the joints
Limited feeling of the pain
and limited deep sensation

Syndrom of posterior columns
Tabes dorsalis
Syringomyelia

Therapy- conservative



Neurogenic arthropathy



Peripheral nerve palsy

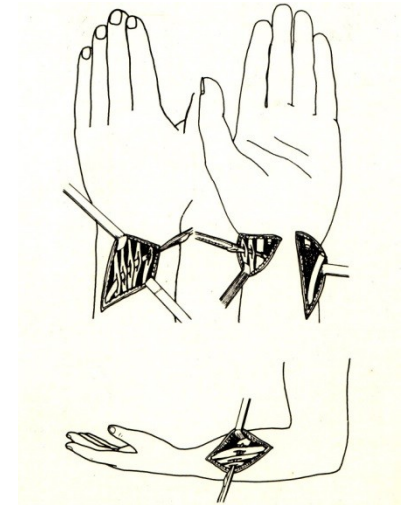
N. medianus

N. ulnaris

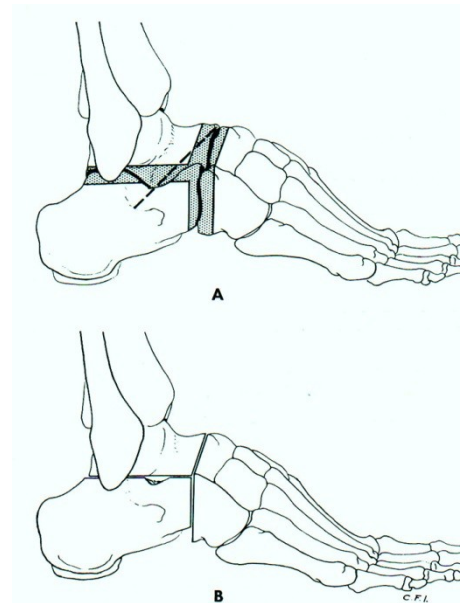
N. radialis

N. peroneus

Perthes procedure



Triplearthrodesis



Robophysiotherapy, robot-assisted rehabilitation

New therapeutical tool in neurorehabilitation, particularly for stroke patients and spinal cord lesions patients

Premise: repeating limb movements can help to recover motor control.

Initial trials of a robot-assisted arm and shoulder exercises were with sub-acute patients with a localised lesion.



Neuroplasticity is the basic mechanism underlying improvement in functional outcome after stroke and after spinal cord disease. These patients benefit from using robots.

Principles of stroke rehabilitation:

high-intensity practice

multidisciplinary team care

task-specific training

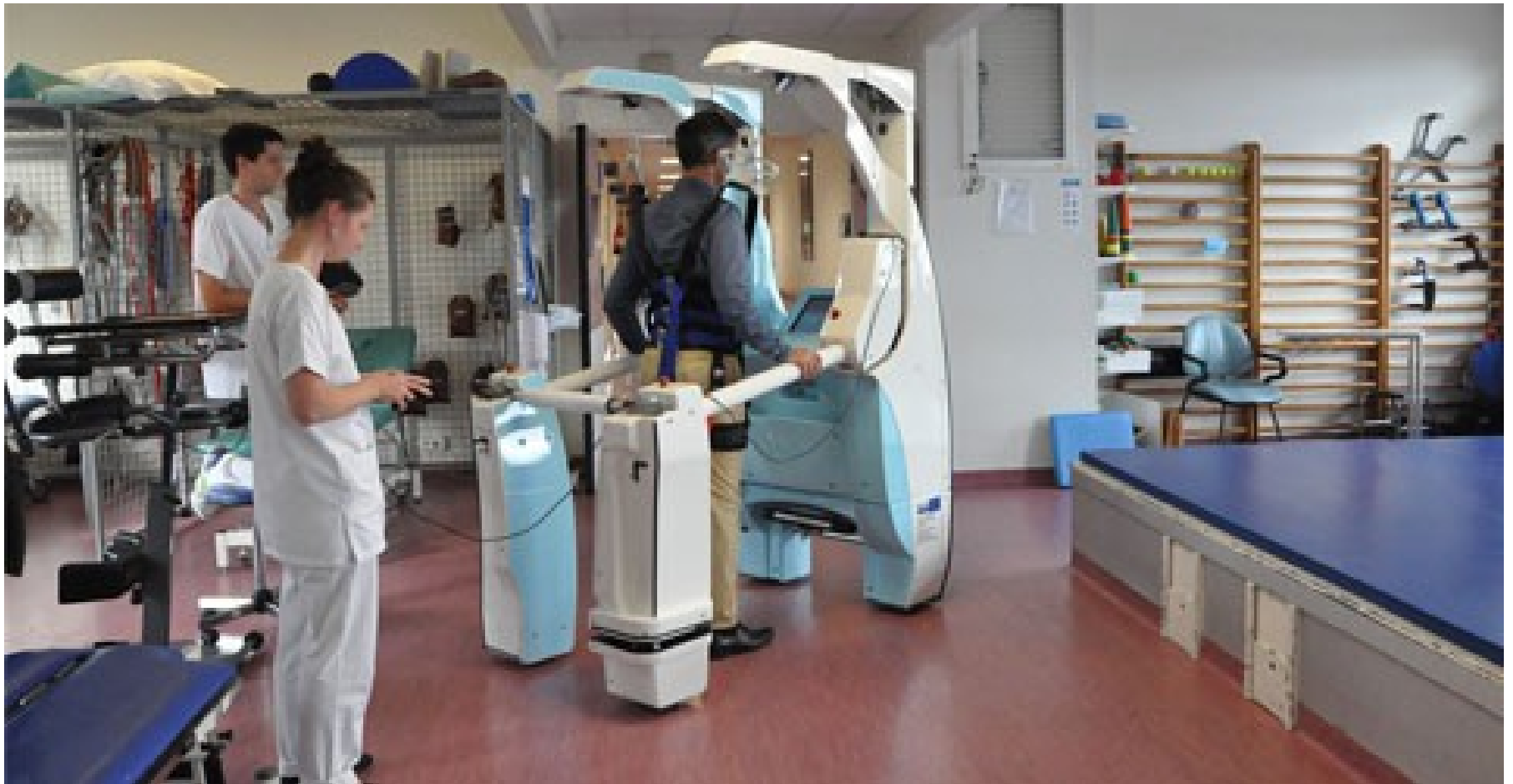repetitive practice of specific functional tasks

Robot-assisted therapy in combination with conventional physiotherapy produces greater improvement in gait function than conventional gait training alone.



Robotic rehabilitation therapy can deliver high-dosage and high-intensity training, making it useful for patients with motor disorders.

Robotic devices used for motor rehabilitation include end-effector and exoskeleton types.

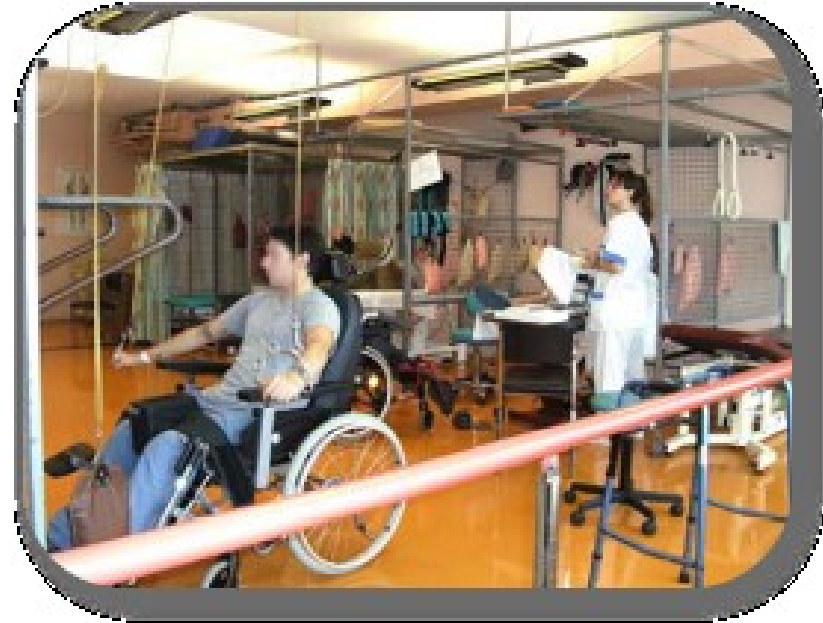


Upper arm

Recovery of upper arm function following stroke is a real problem.

A high proportion of people who had a stroke regain their ability to walk, but only 14 per cent of people with the upper arm problem.

Positive impact of robotics and the efficacy of electrical stimulation





Wheel chair case