

Musculoskeletal tumors

Janíček, P, Pazourek L.,
Ondrůšek Š., Rozkydal, Z.

Classification

- Malignant
- Benign
- Tumor like lesions
- Metastases

They are produced in mesenchym

Most of them are benign

Malignant tumors 1-2 % of all malignancies

Bone sarcomas

Soft tissue sarcomas

Symptoms

- Pain
- Swelling
- Impaired function
- Pathological fracture
- General symptoms (fever, weakness, cachexia ...)

Diagnostics

- History
- X-ray
- CT / MRI
- Scintigraphy of the skeleton
- Chest X-ray, CT of the lungs
- Ultrasonography of the abdomen
- Biopsy (histology)

- Other imaging methods (PET, angiography, laboratory tests. Genetic examination ...

Biopsy

- True cut biopsy
- Needle biopsy under CT
- Excisional biopsy
- Histology- experienced pathologist
- Biopsy – in special centres

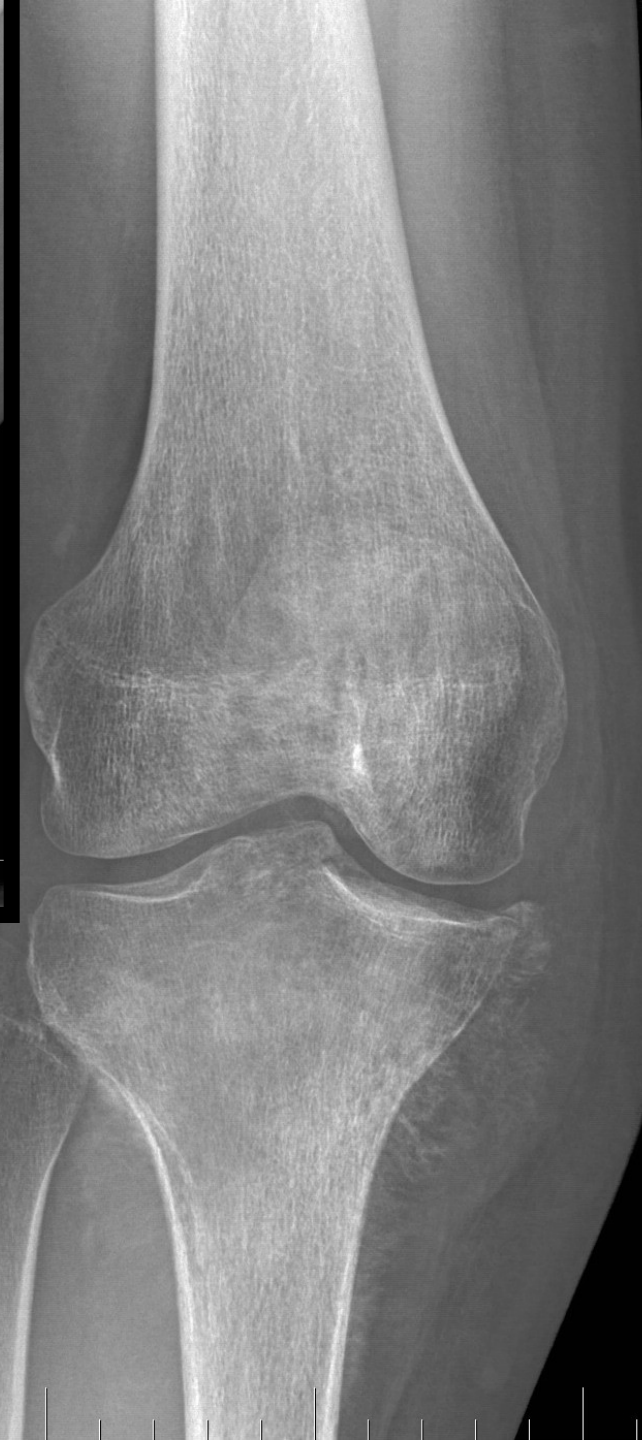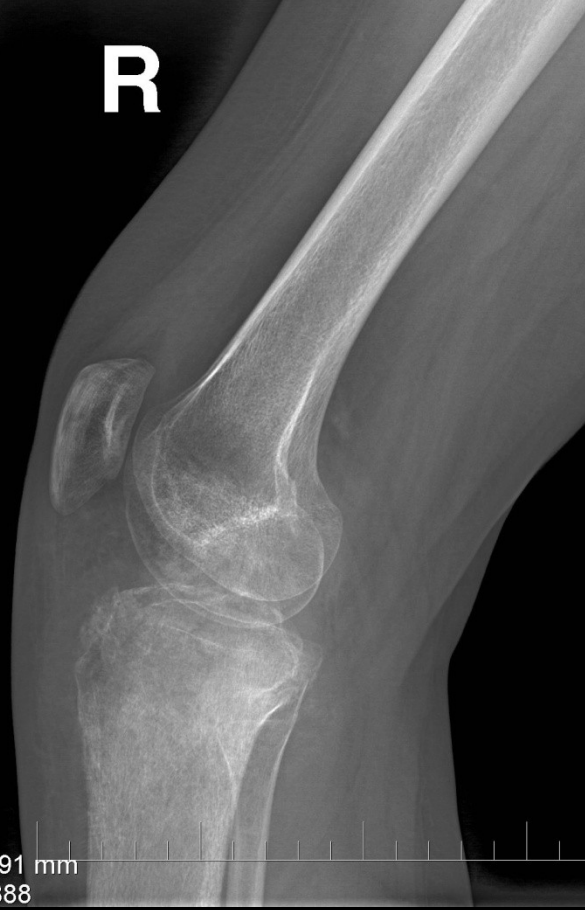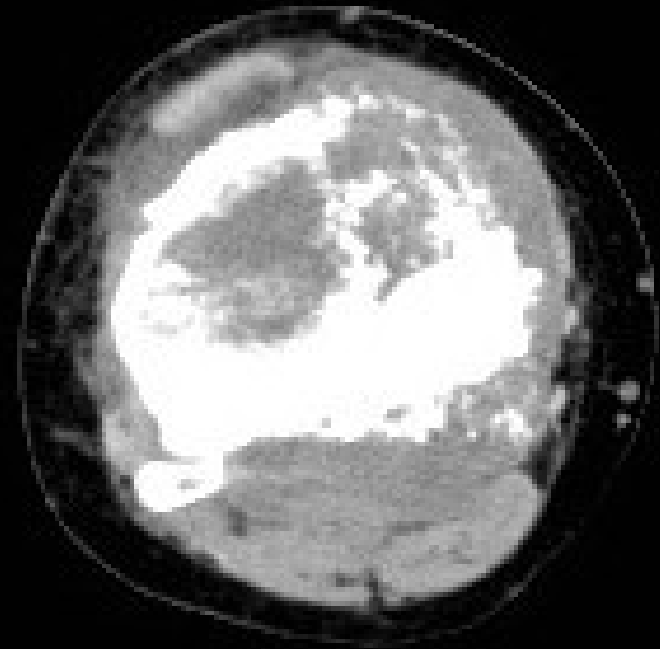
X-ray finding in malignant bone tumors

- Aggressive lesions
- Periosteal reaction
- Erosions of cortex
- Endostal irregularities

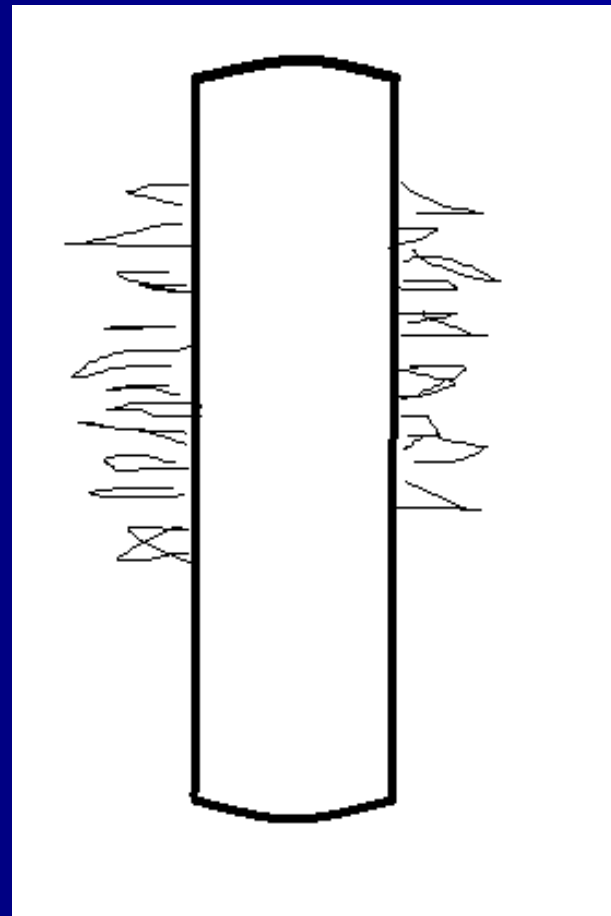
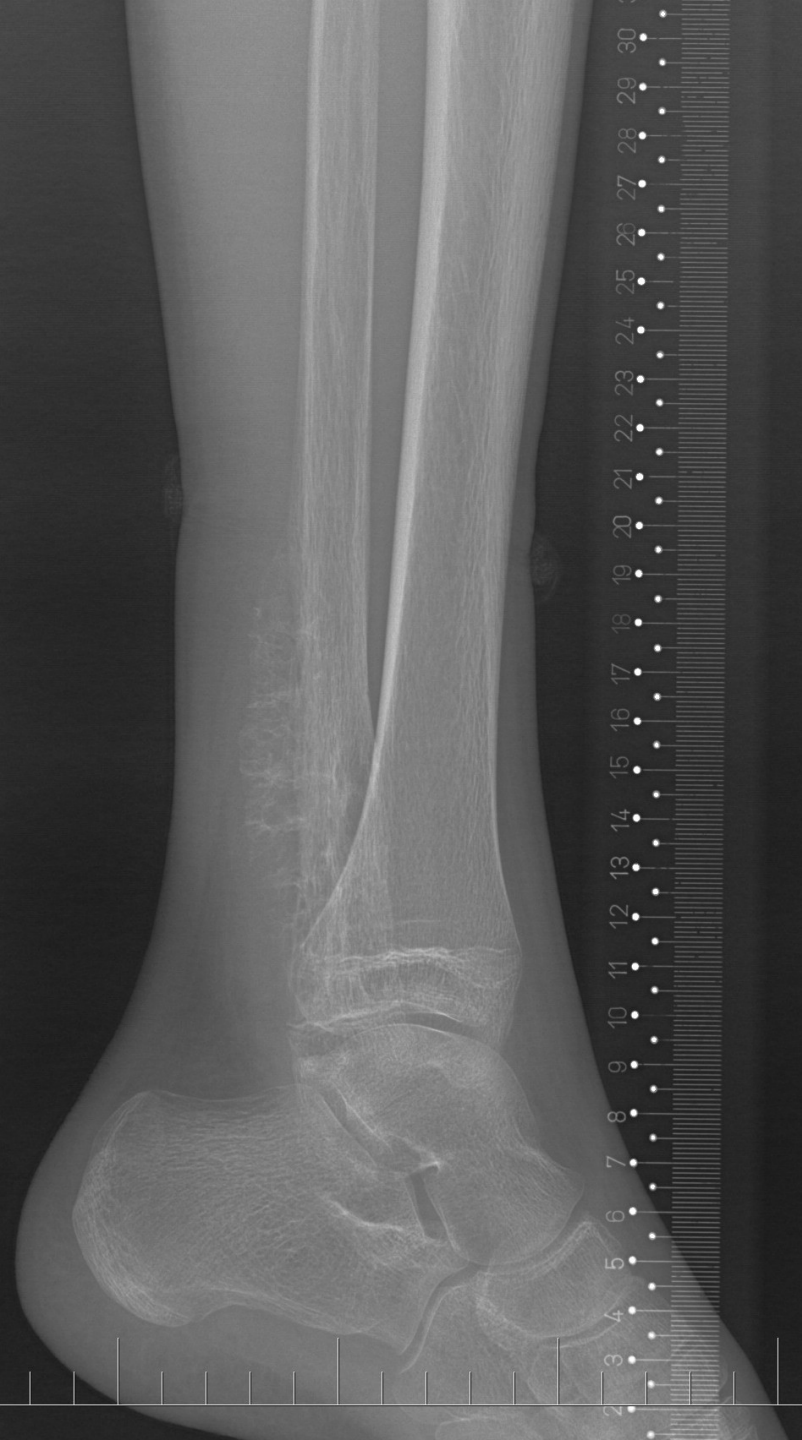Irregularities

R

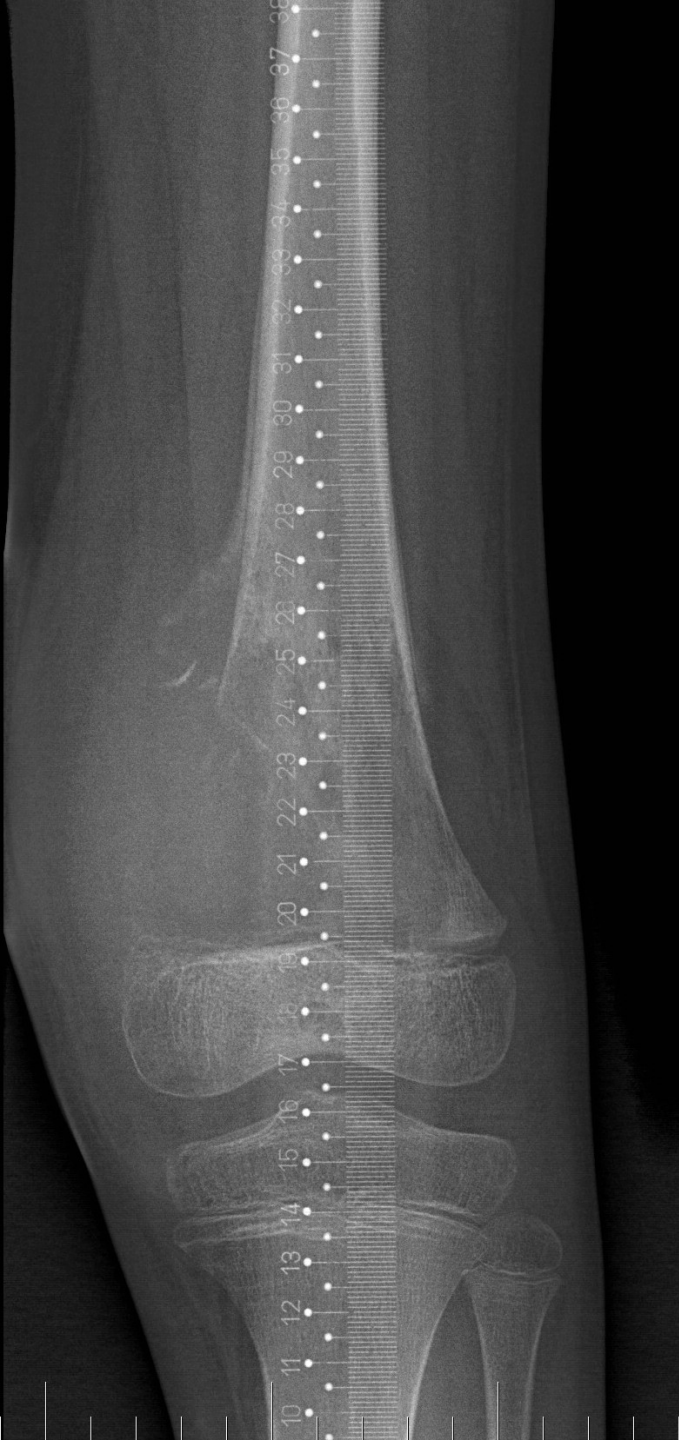
91 mm
388



Periosteal reaction (spikes)

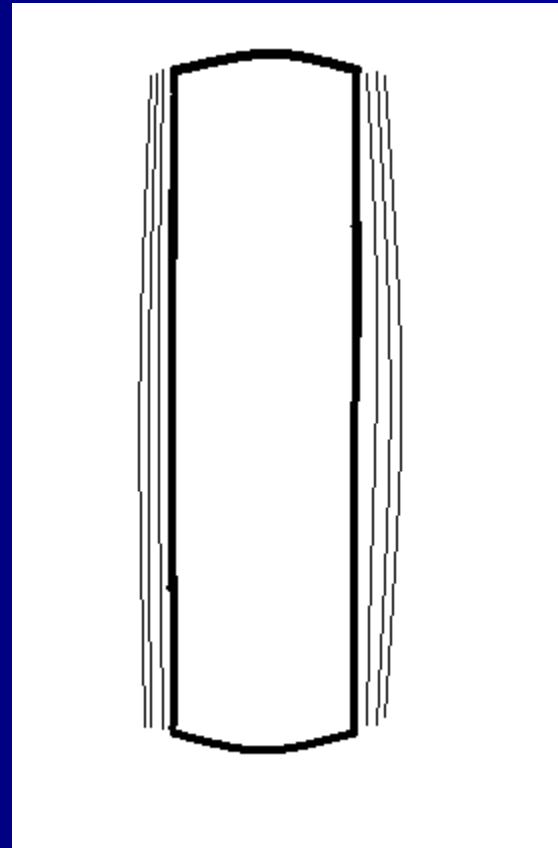


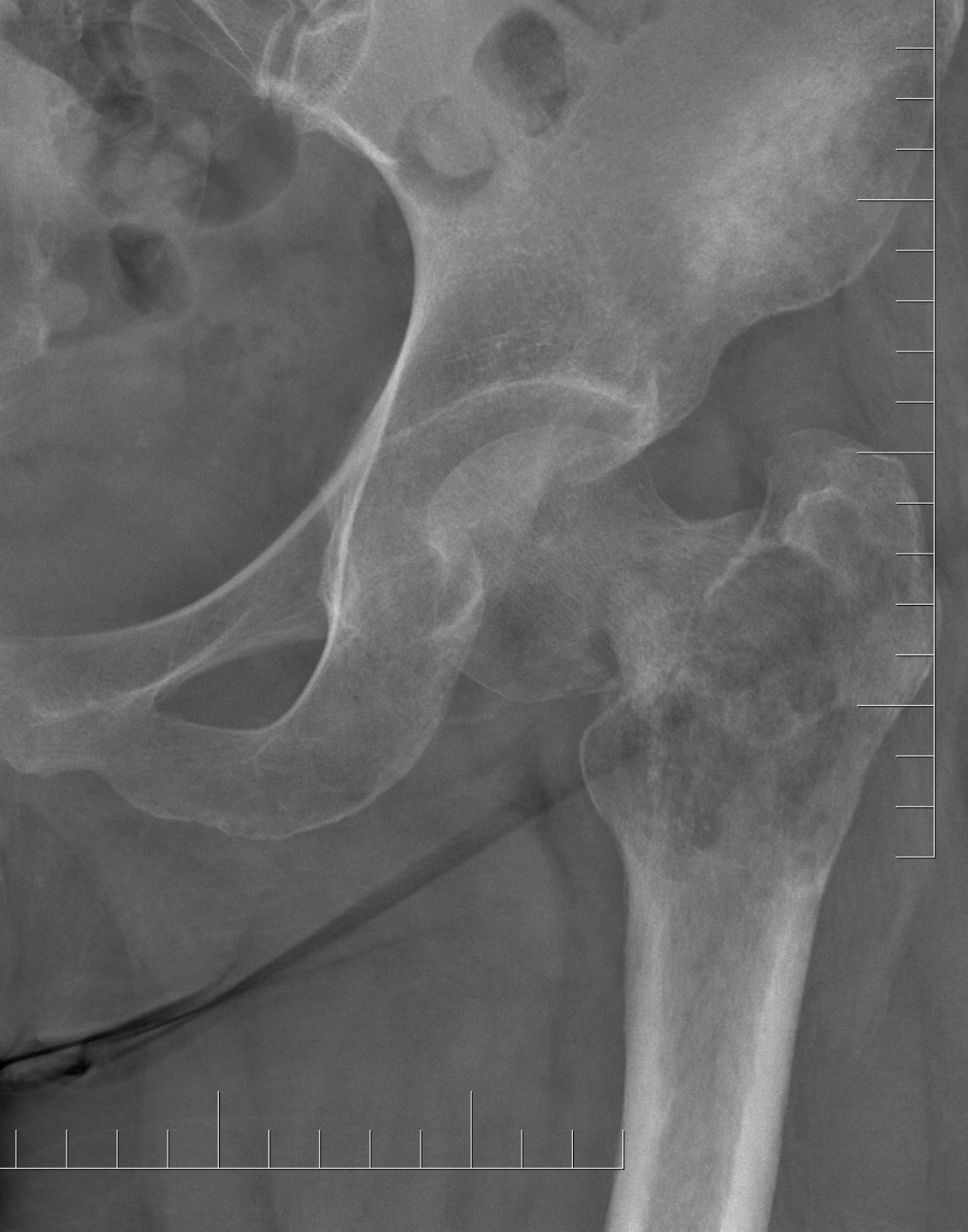Codman's triangle



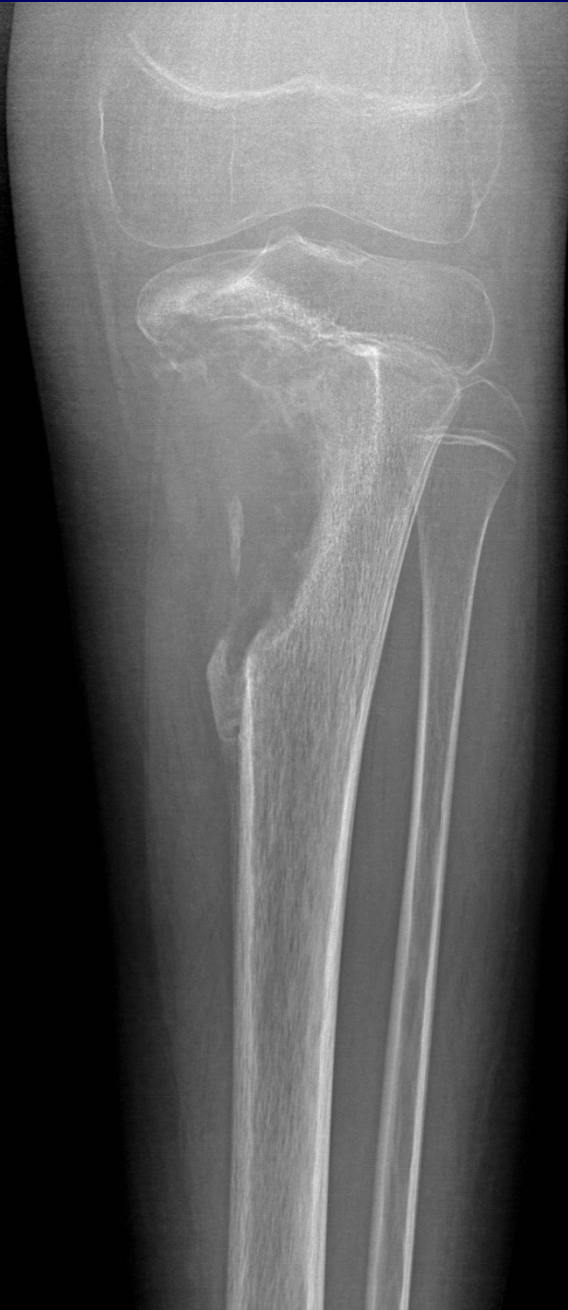R

Onion-like periostosis

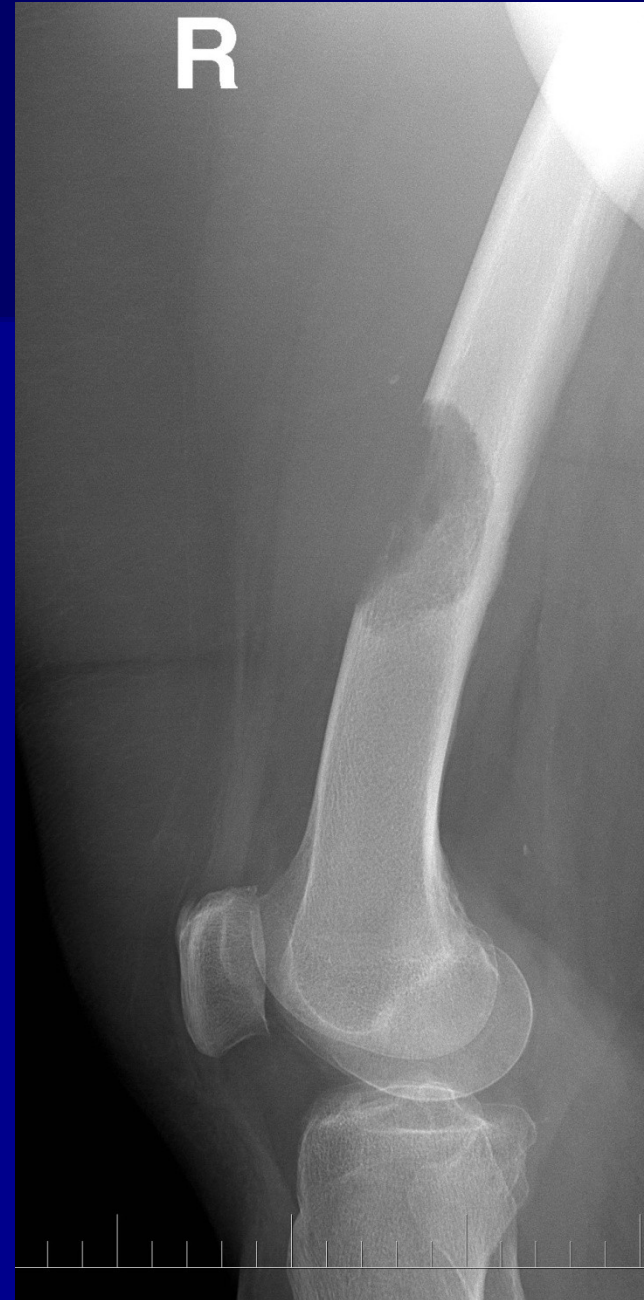



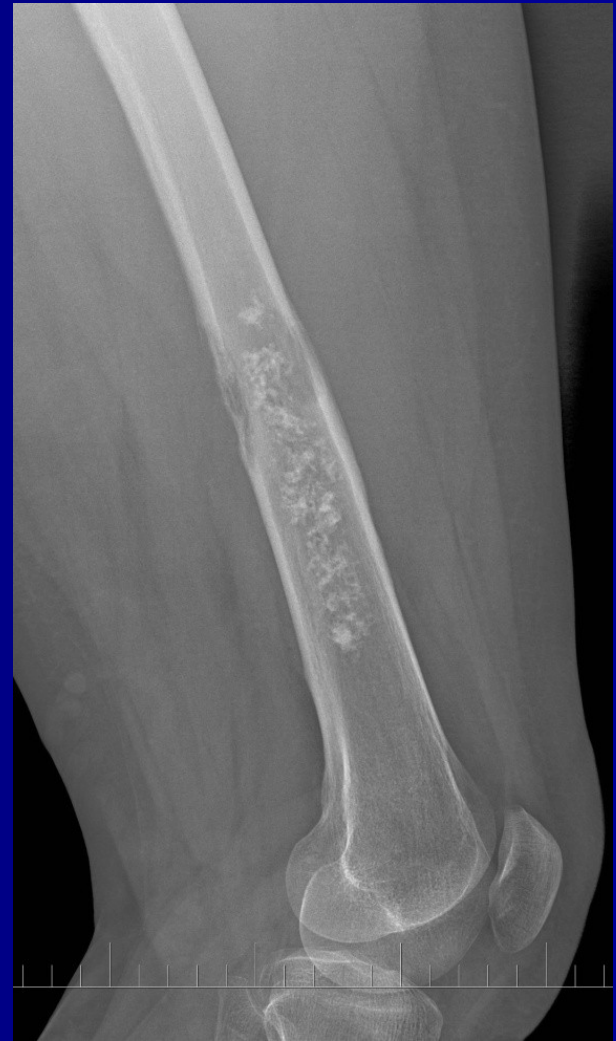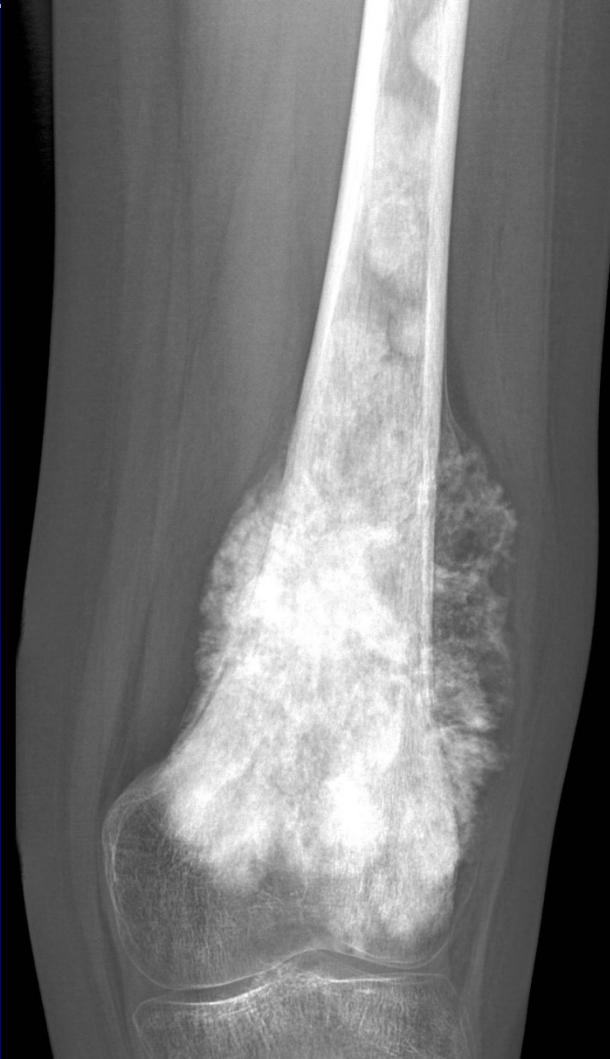**Osteolytic
patches**



Erosions of the cortex



Expansion of the tumor



Age

- 1. decade: EwingSA
- 2.-3. decade: OSA
- 3.-4. decade: osteoclastoma, parosteal OSA, chondrosarcoma ...
- 5. decade: Myeloma, secondary bone tumors, chondrosarcoma

Staging

TNM classification

T1- T4 (size and localisation)

N0-2 (lymphonodes)

M0, M1- lung, skeleton, liver, CNS

Staging of musculoskeletal tumors (Enneking)

- **Grade** – biological aggressivity
- **Local finding (T)**
- **N0-2**
- **M0-1**

Biological agresivity, Grade

Summary of
clinical, radiological and histological findings

G0 benign cytology

G1 invasive growth, mitoses, anaplastic cells

G2 infiltrative growth, no anatomical margins, high vascularity

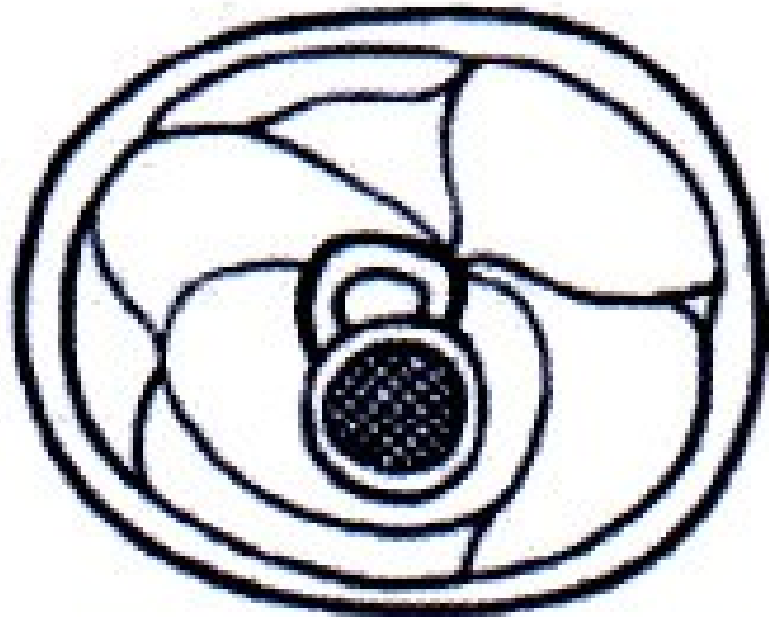
G3 fast growth, dediferencial tumor cells, distant metastases

Site of tumors

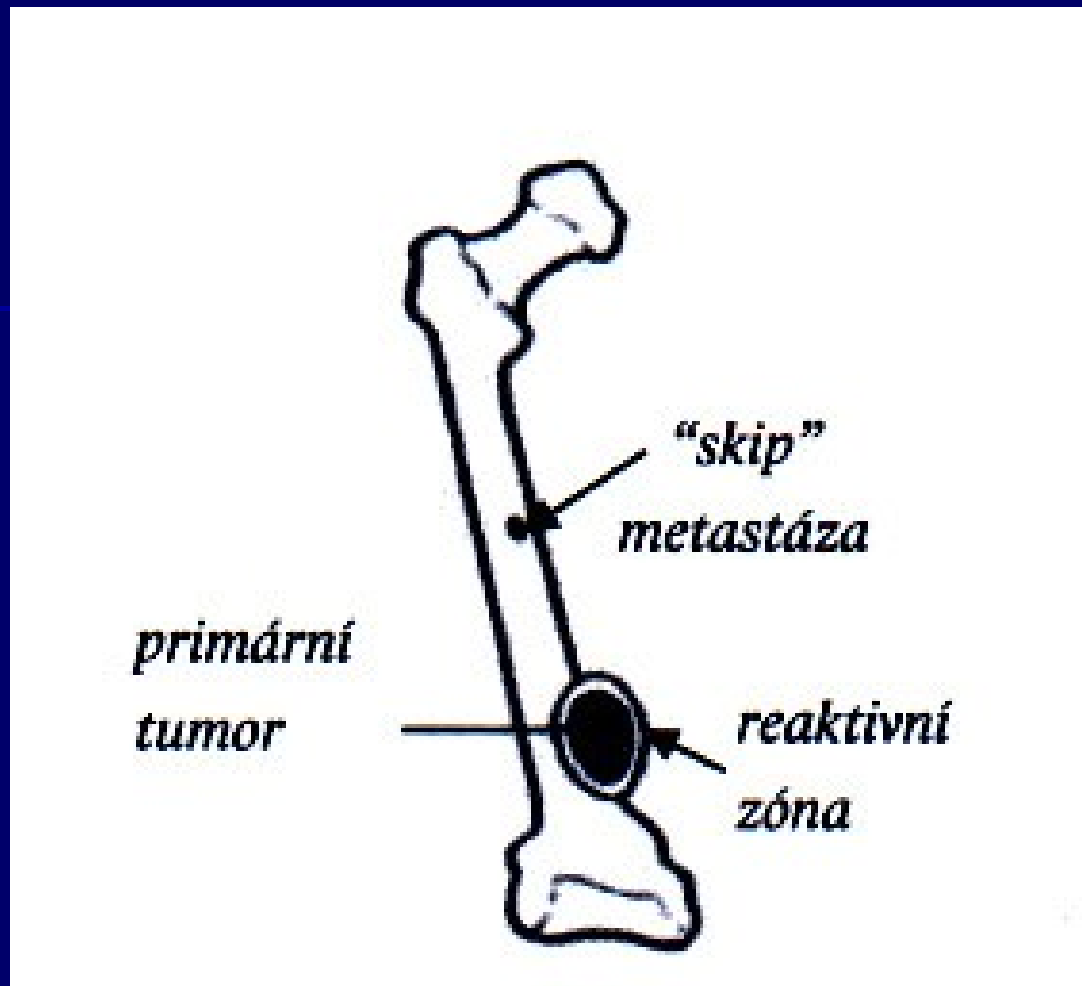
T0 tumor in capsule

T1 extracapsular growth, in compartment
Satelites in reactive zone

T2 extracompartamental growth



Extracompartmental growth



Reactive zone- satellite metastases
Skip metastases

Metastases

M0 no metastases

M1 metastases are present

regional lymphonodes

distant metastases- lung, skeleton, liver, CNS

Classification

- **I Low grade**

A Intracompartmental	G1-2	T1	M0
-----------------------------	------	----	----

B Extracompartmental	G1-2	T2	M0
-----------------------------	------	----	----

- **II High grade**

A Intracompartmental	G3	T1	M0
-----------------------------	----	----	----

B Extracompartmental	G3	T2	M0
-----------------------------	----	----	----

- **III Metastatic**

A Intracompartmental	G1-3	T1	M1
-----------------------------	------	----	----

B Extracompartmental	G1-3	T2	M1
-----------------------------	------	----	----

Clinical stage

I. Surgery

II. surgery + radiation + chemotherapy

III. Chemoinduction + radiation (or surgery + chemotherapy)

IV. Palliative management

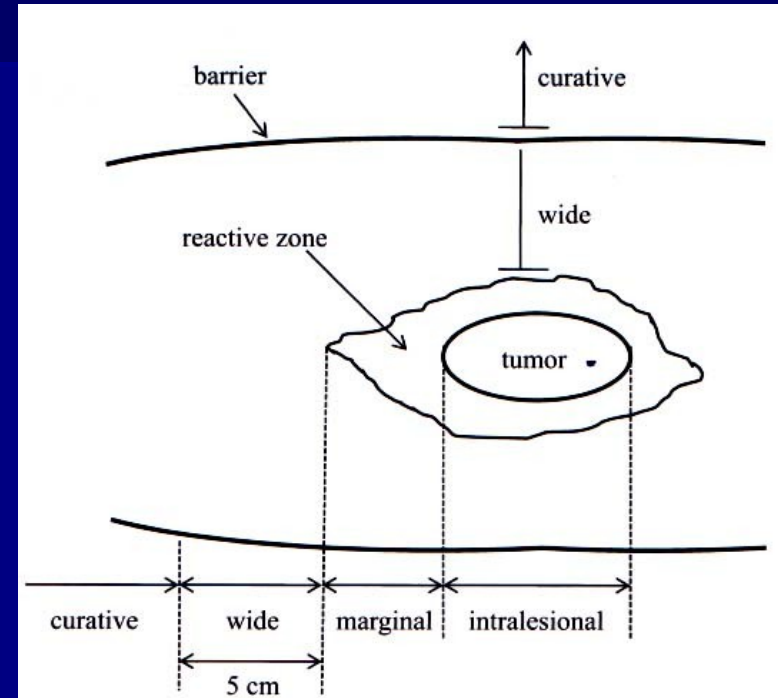
Therapy

- **Local therapy**
 - surgery
 - radiotherapy
 - others (embolisation, RFA ...)

- **Systemic therapy**
 - chemotherapy
 - hormonal therapy
 - bisphosphonates
 - biological treatment ...

Surgical radicality

- Radical
- Wide resection
- Marginal
- Intralesional



R0 margins of removed tumor - without tumor cells
R1 microscopic infiltration
R2 macroscopic infiltration

Oncological radicality

R0 surgery is curative

R1 surgery is not curative
adjuvant radiotherapy

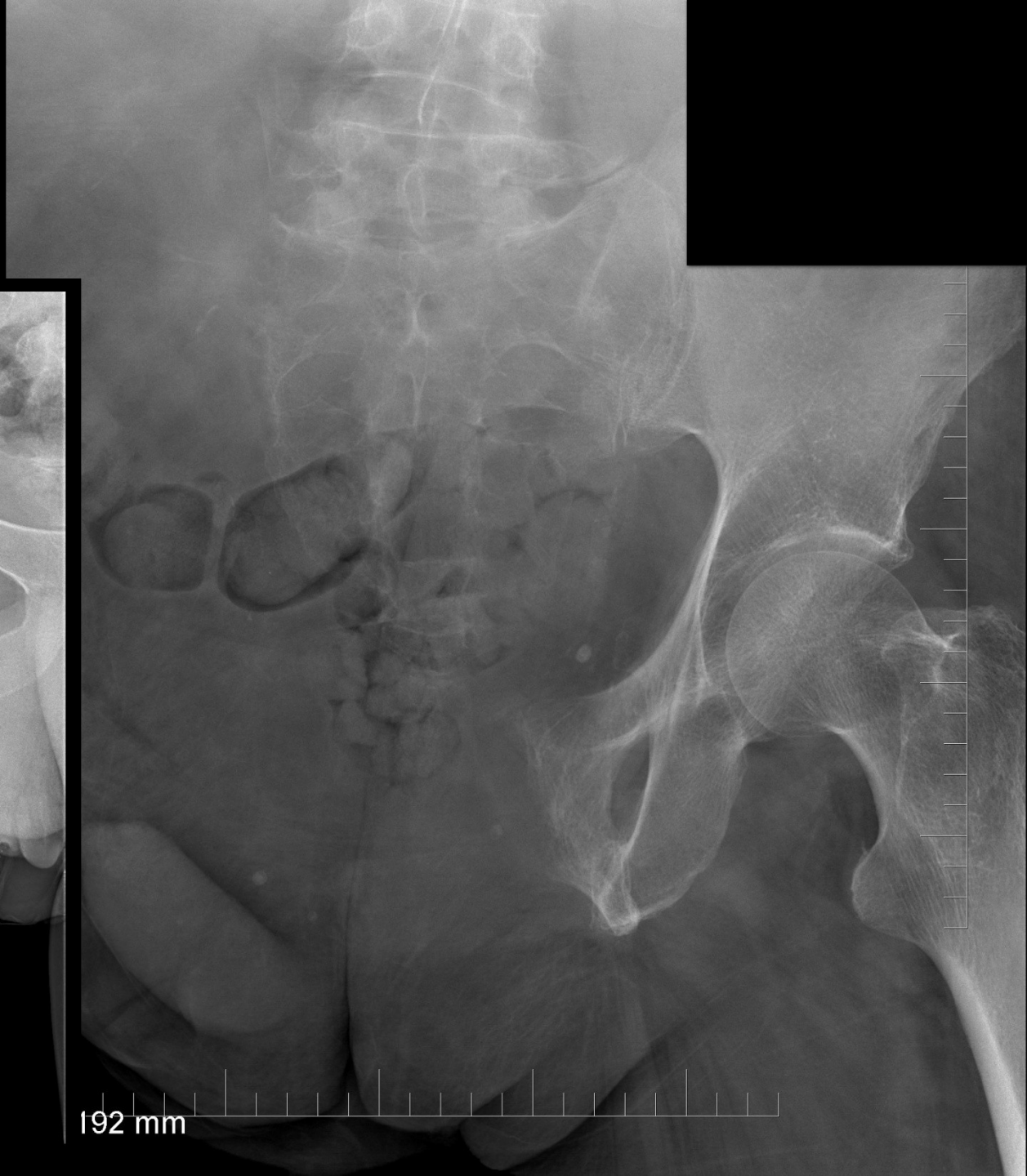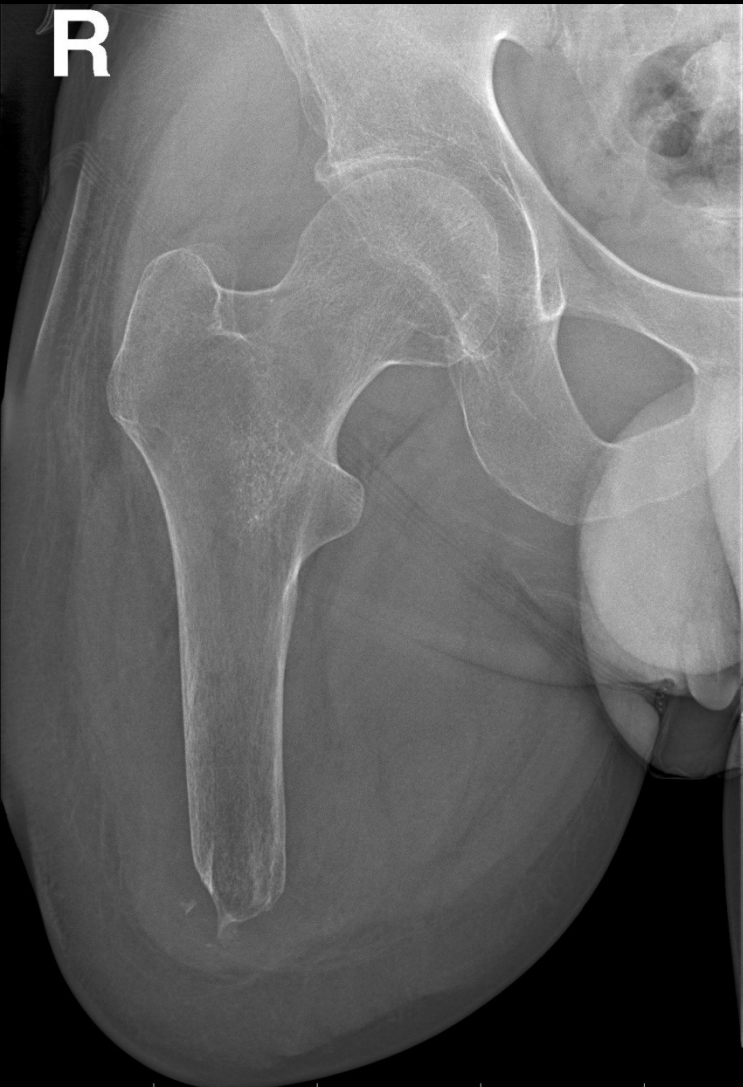R2 debulking
Surgery is not curative, only paliative
Adjuvant radiotherapy and chemotherapy

Surgery

- Ablative (amputation, disarticulation)
- Limb-salvage surgery

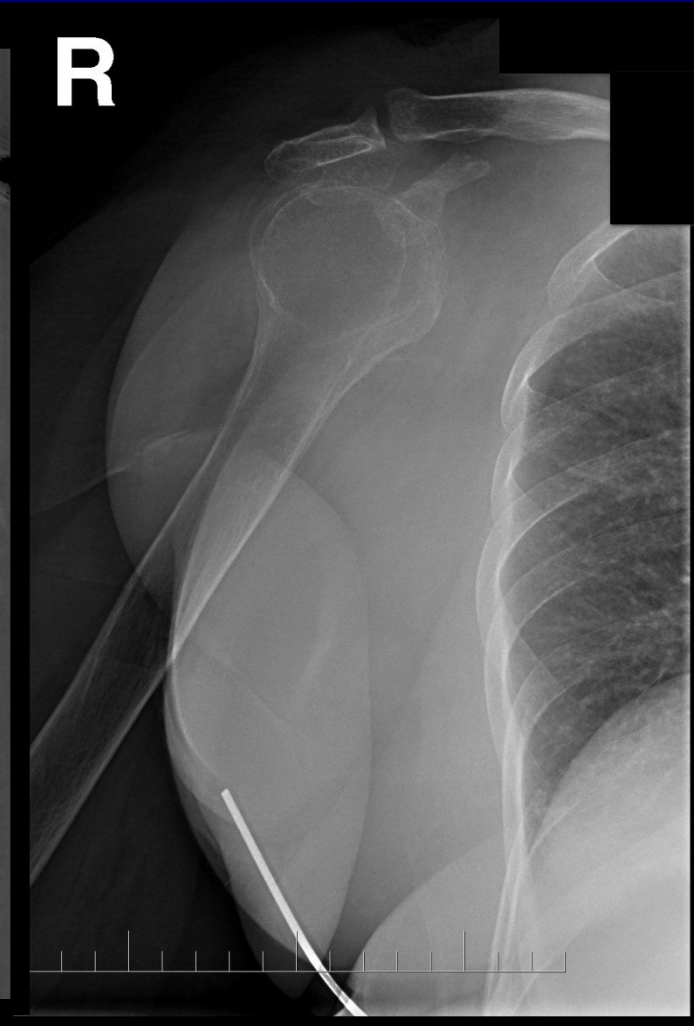
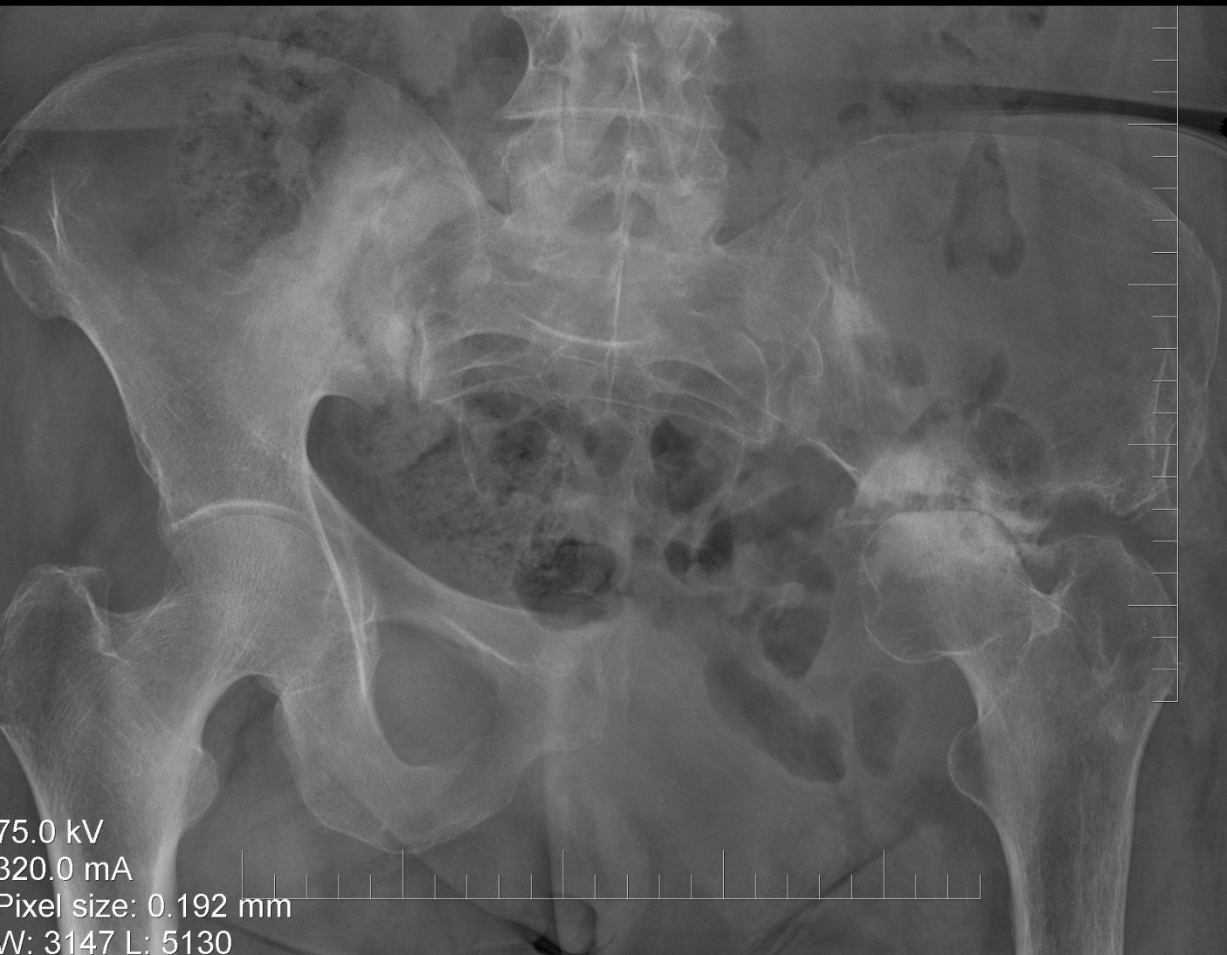Ablative

R

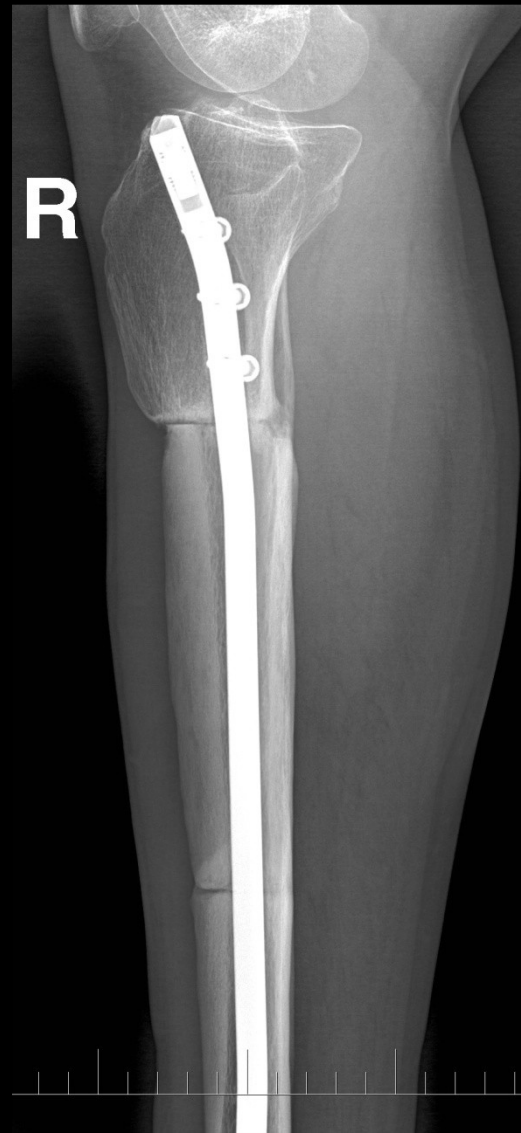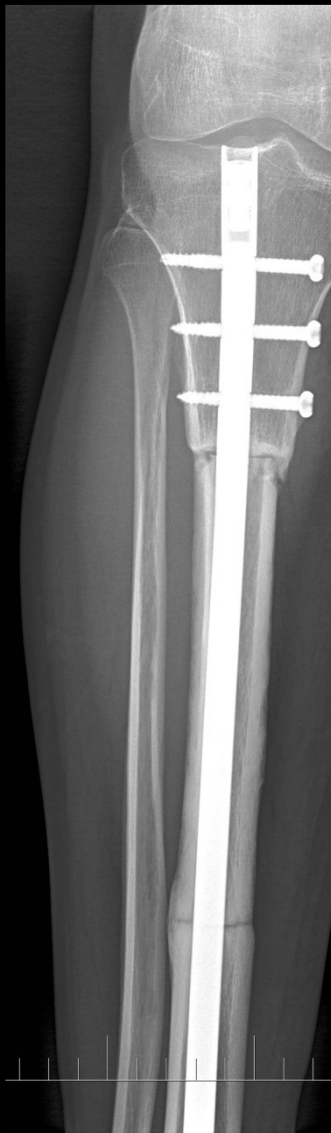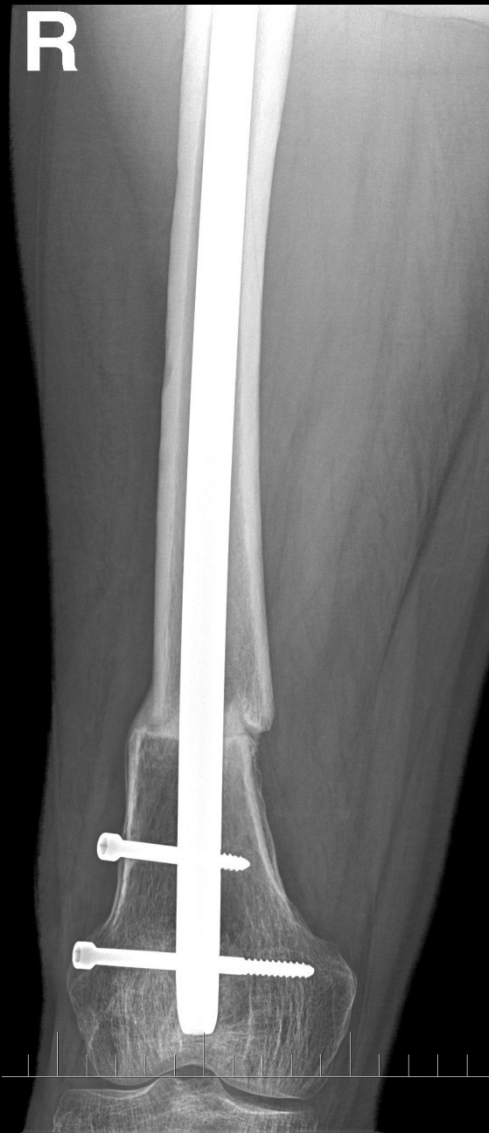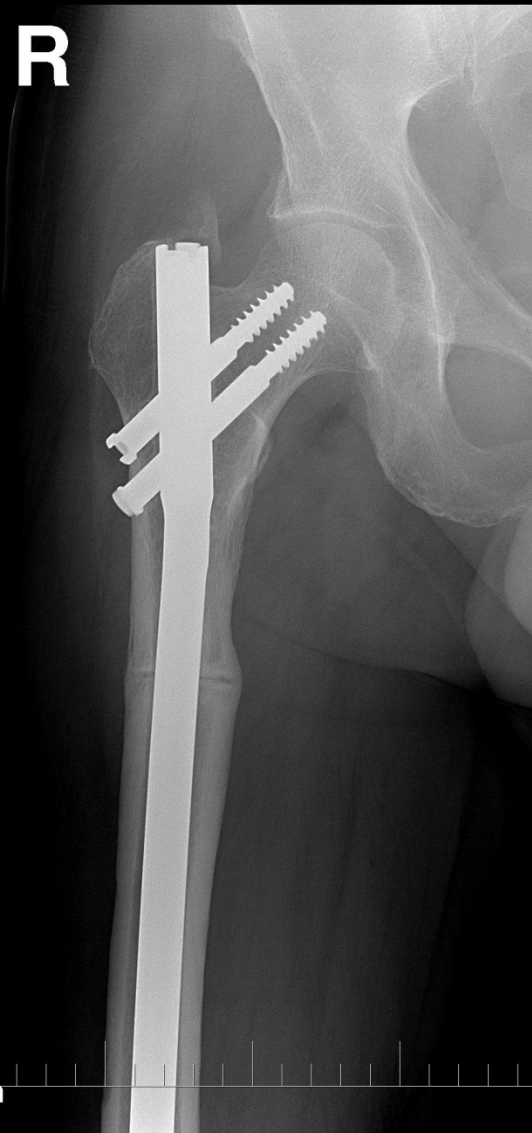


192 mm

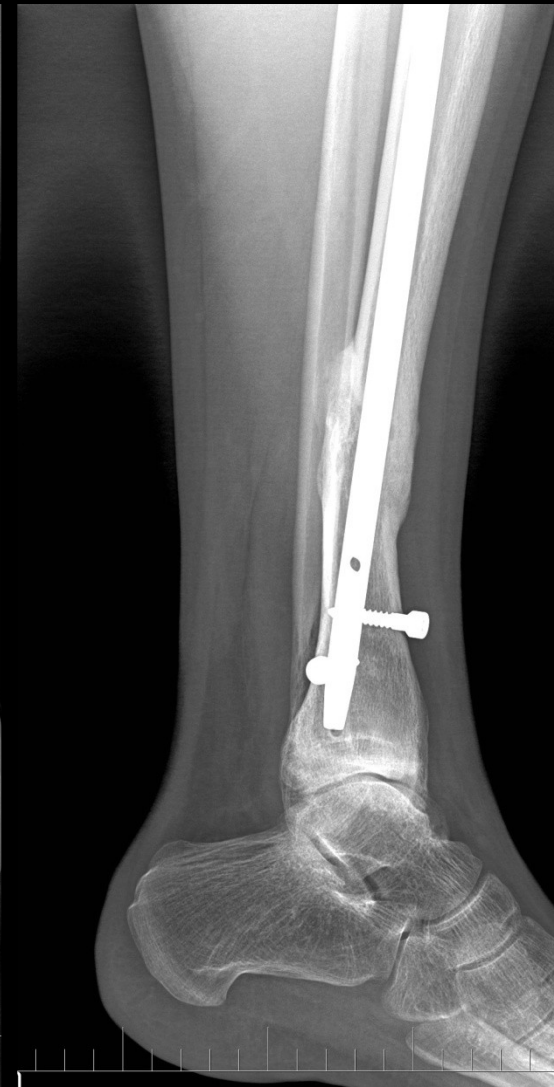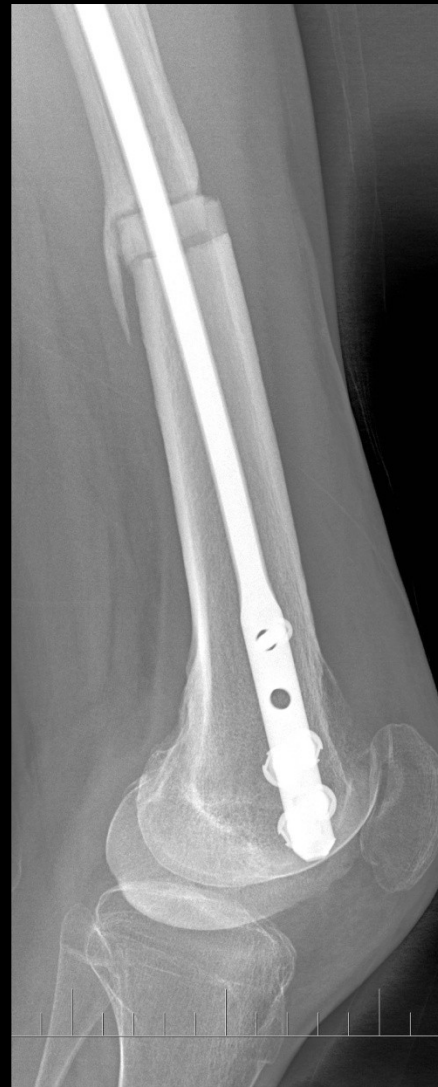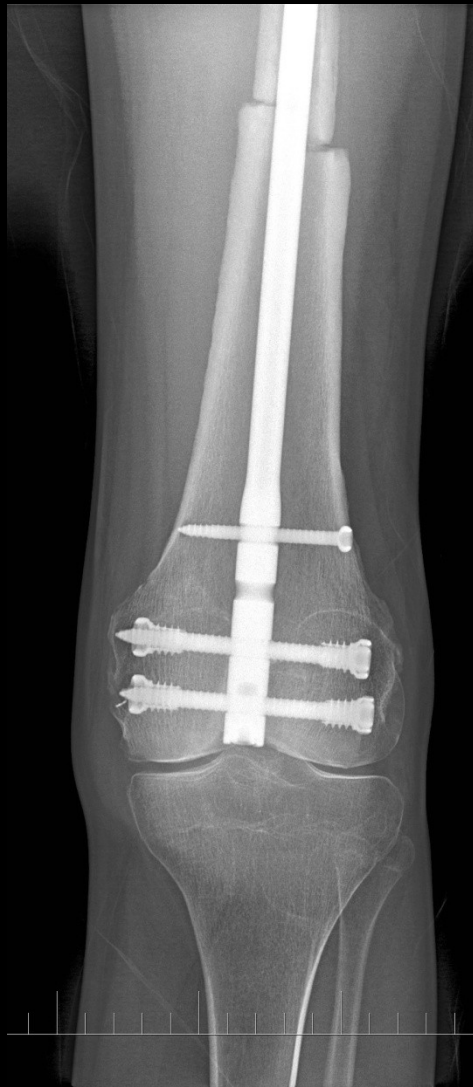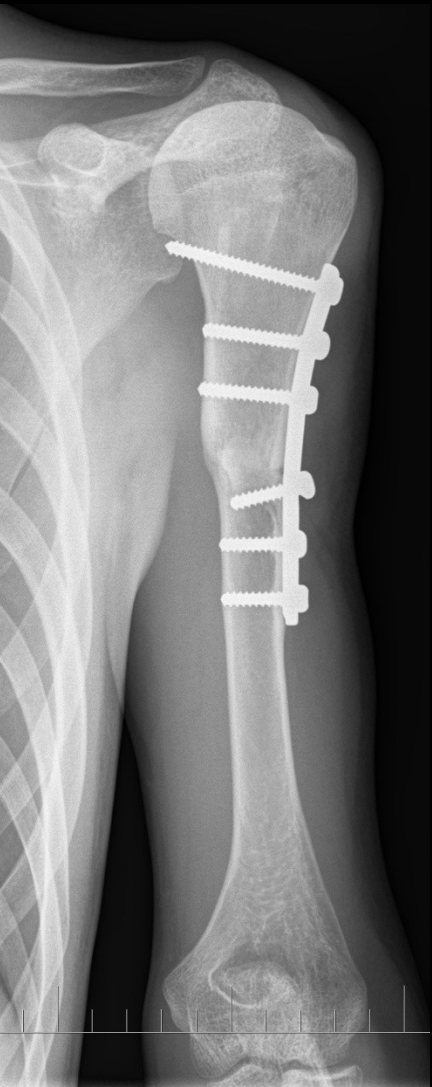
Conservative hemipelvectomy Scapulectomy



Intercalary bone graft

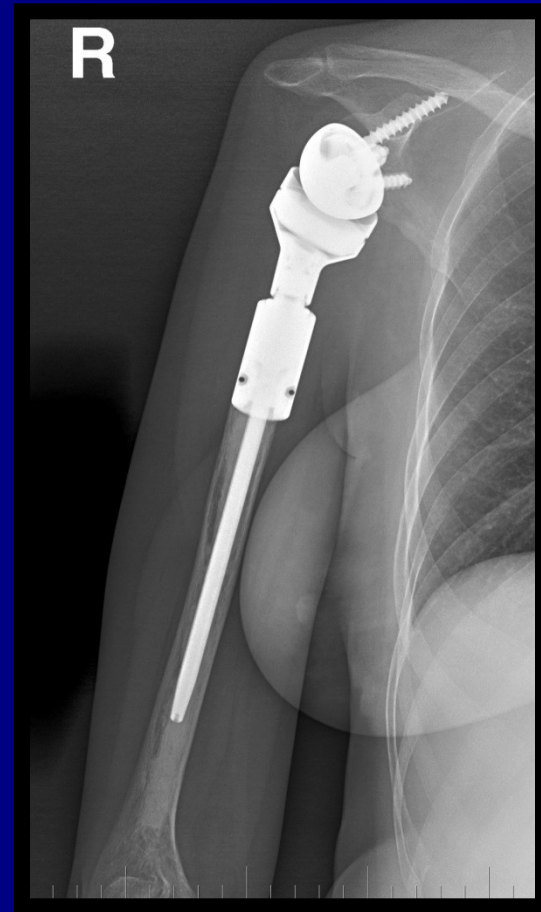
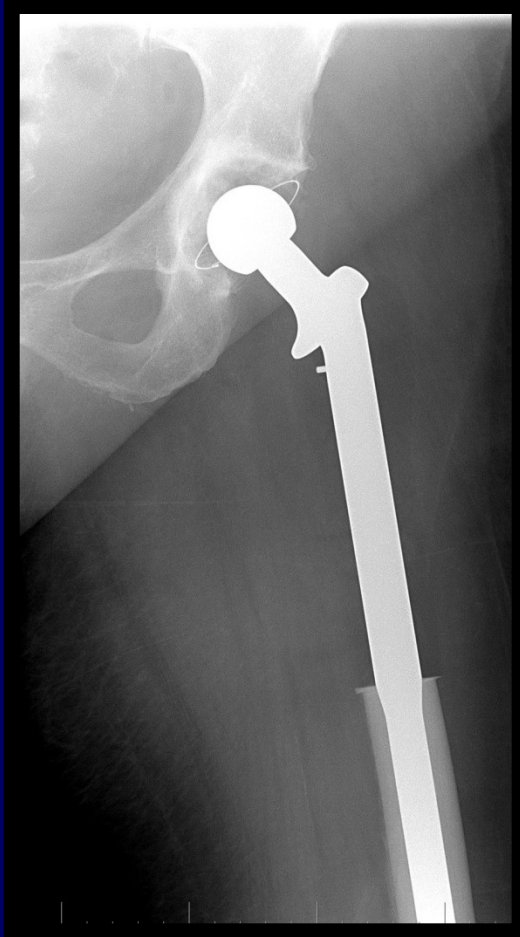
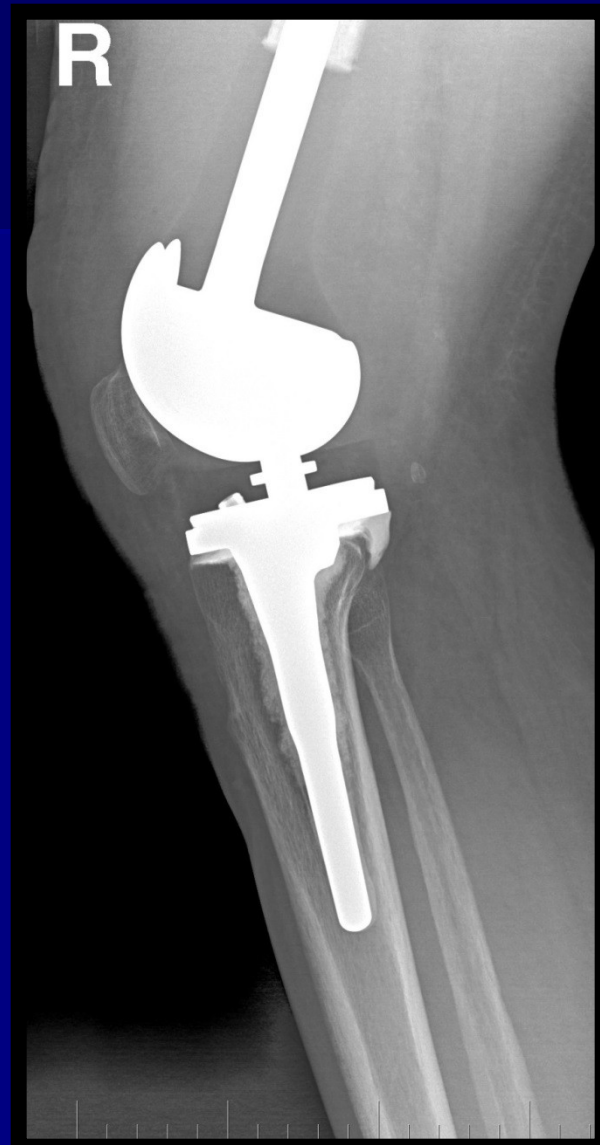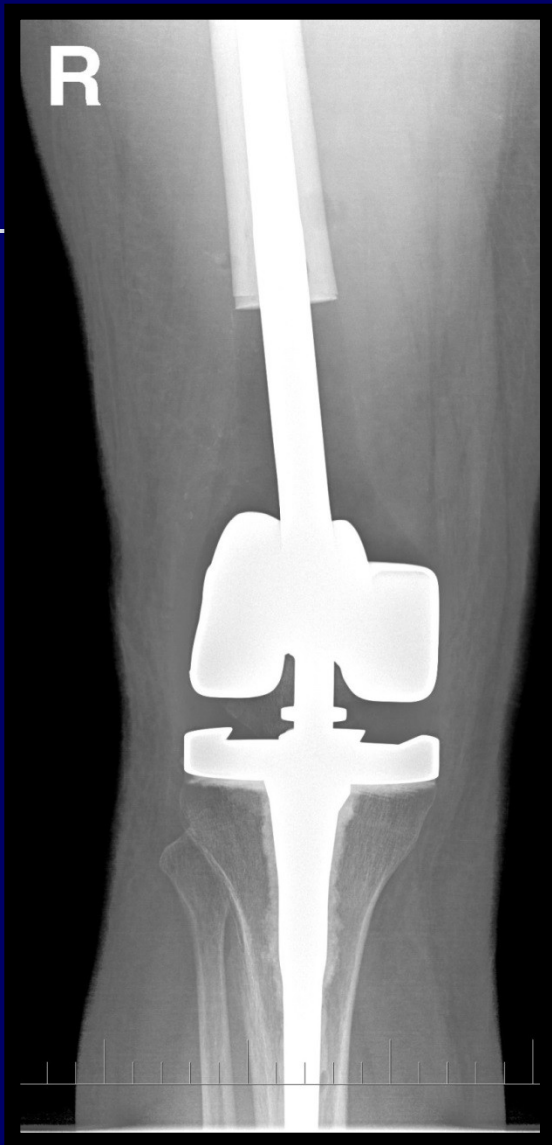Osteochondral grafts



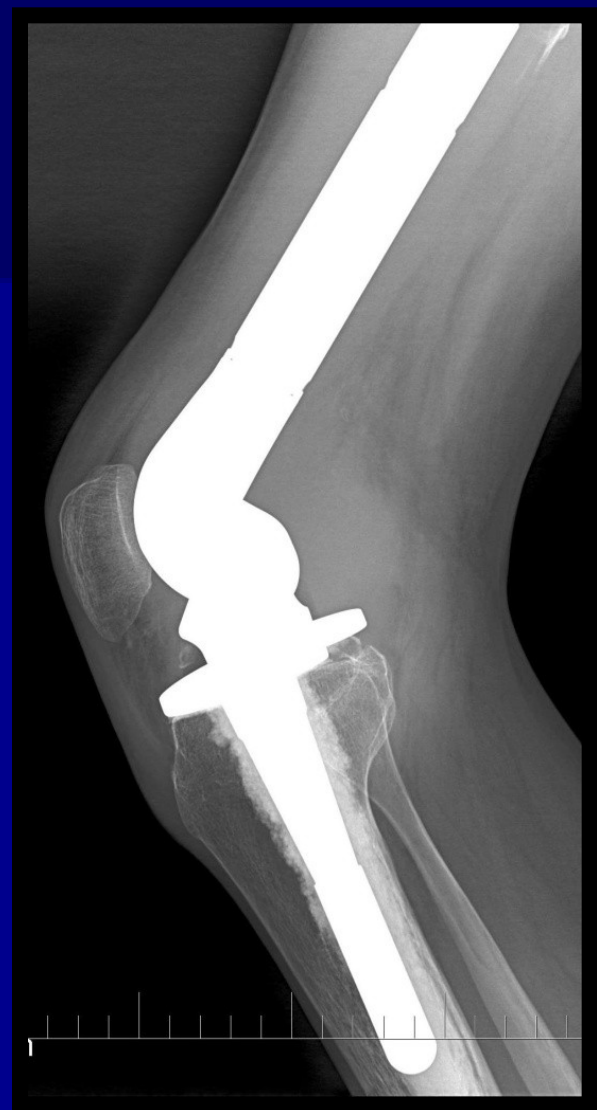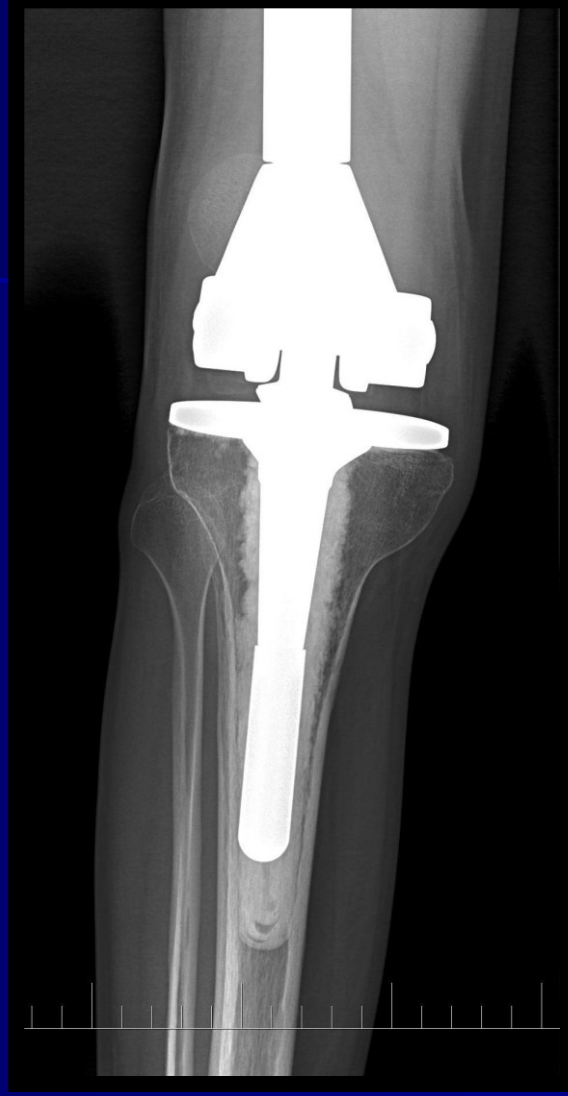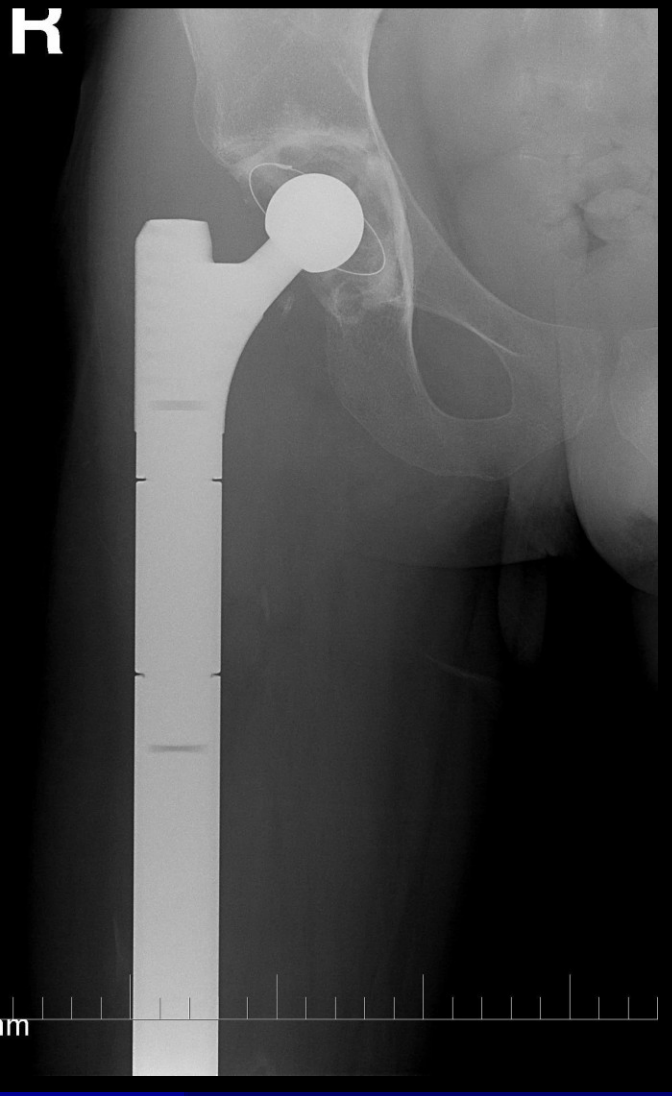Tumor endoprosthesis

- Resection and joint replacement





R



Composite endoprosthesis

