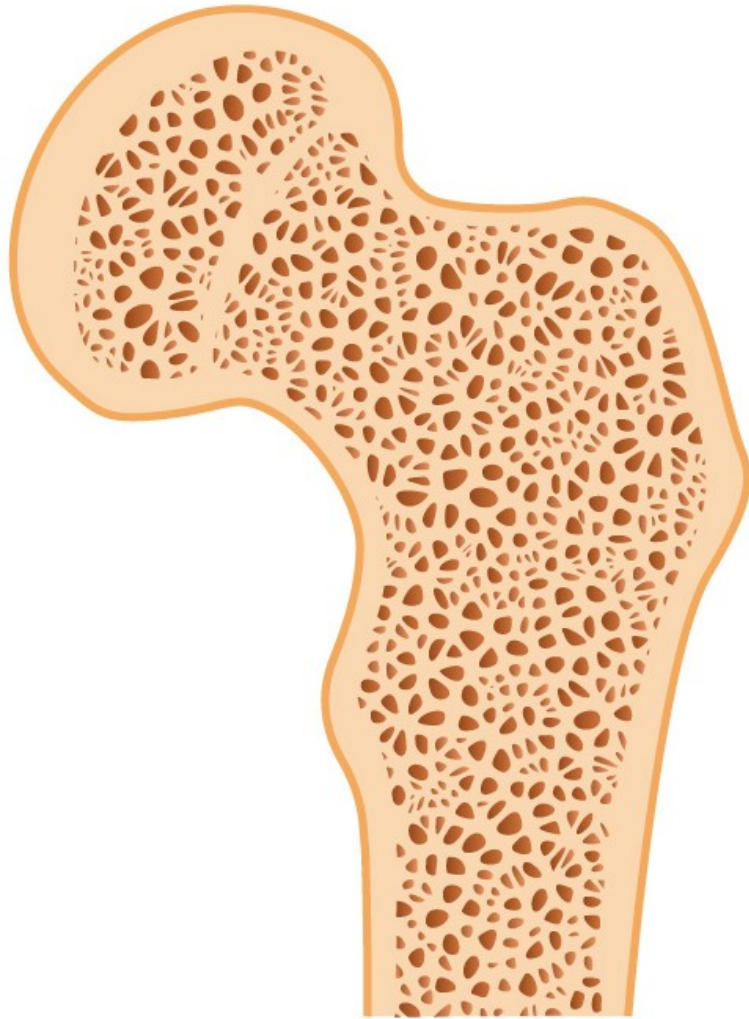


Pathology of the musculoskeletal system

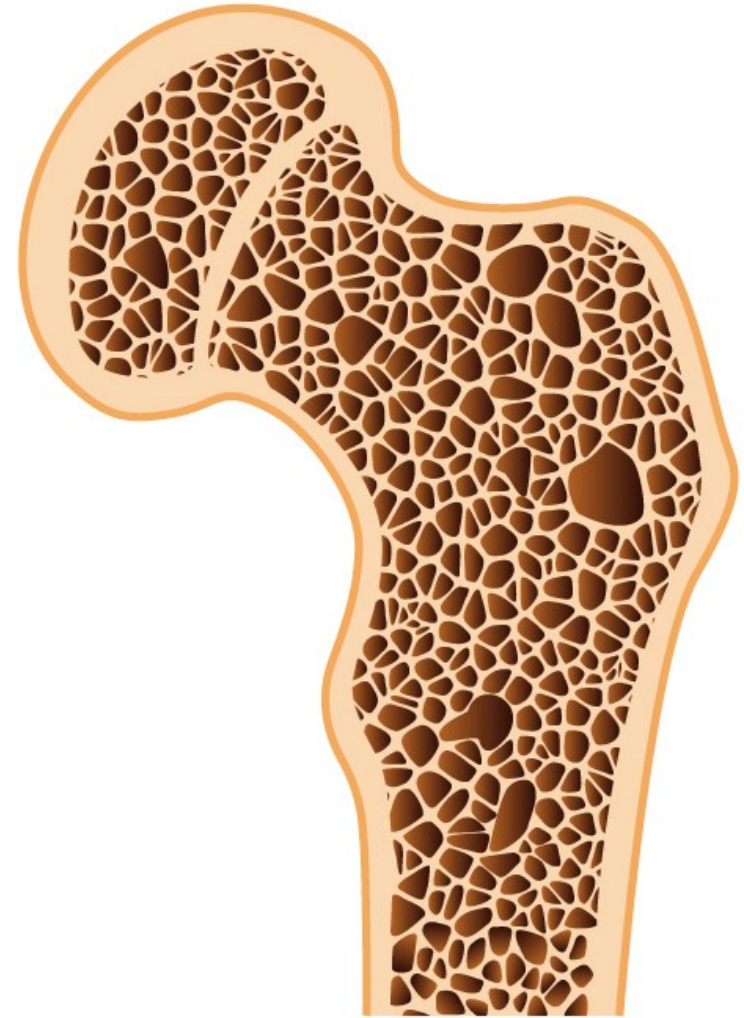
Markéta Hermanová

Osteoporosis

- Reduction of bone mass in the presence of normal mineralisation; due to increased bone resorption, decreased bone formation, or both
- Common in elderly, particularly in females, follows any form of immobility
- Complication of steroid therapy and Cushing's syndrome
- Associated with alcoholism, diabetes, liver disease and smoking
- Common predisposing factor of fractures, particularly neck of femur, causes skeletal deformities and bone pain (due to compression fractures)



Healthy bone



Osteoporosis

Osteoporosis:

increased porosity of the skeleton resulting from reduced bone mass

■ Primary

- postmenopausal
- Senile

■ Secondary

1. Endocrinopathies

- hyperparathyroidism
- hypo-hyperthyroidism
- hypogonadism
- pituitary tumors
- type I diabetes mellitus
- Addison disease

2. Neoplasia (multiple myeloma, carcinomatosis)

3. GIT disorders (malnutrition, malabsorption, hepatic insufficiency, vit. C,D deficiencies)

4. Rheumatologic diseases

5. Drugs (anticoagulans, chemotherapy, corticosteroids, alcohol, anticonvulsants)

6. Miscellaneous (osteogenesis imperfecta, immobilisation, pulmonary diseases, homocystinuria, anemia)

Regulation of calcium metabolism

■ Parathyroid hormone (PTH)

■ Vitamin D

- to stimulate bone calcium mobilisation (PTH)
- to increase renal reabsorption of calcium in the distal tubule (PTH, vitamin D)
- to stimulate intestinal calcium and phosphate absorption (vitamin D)

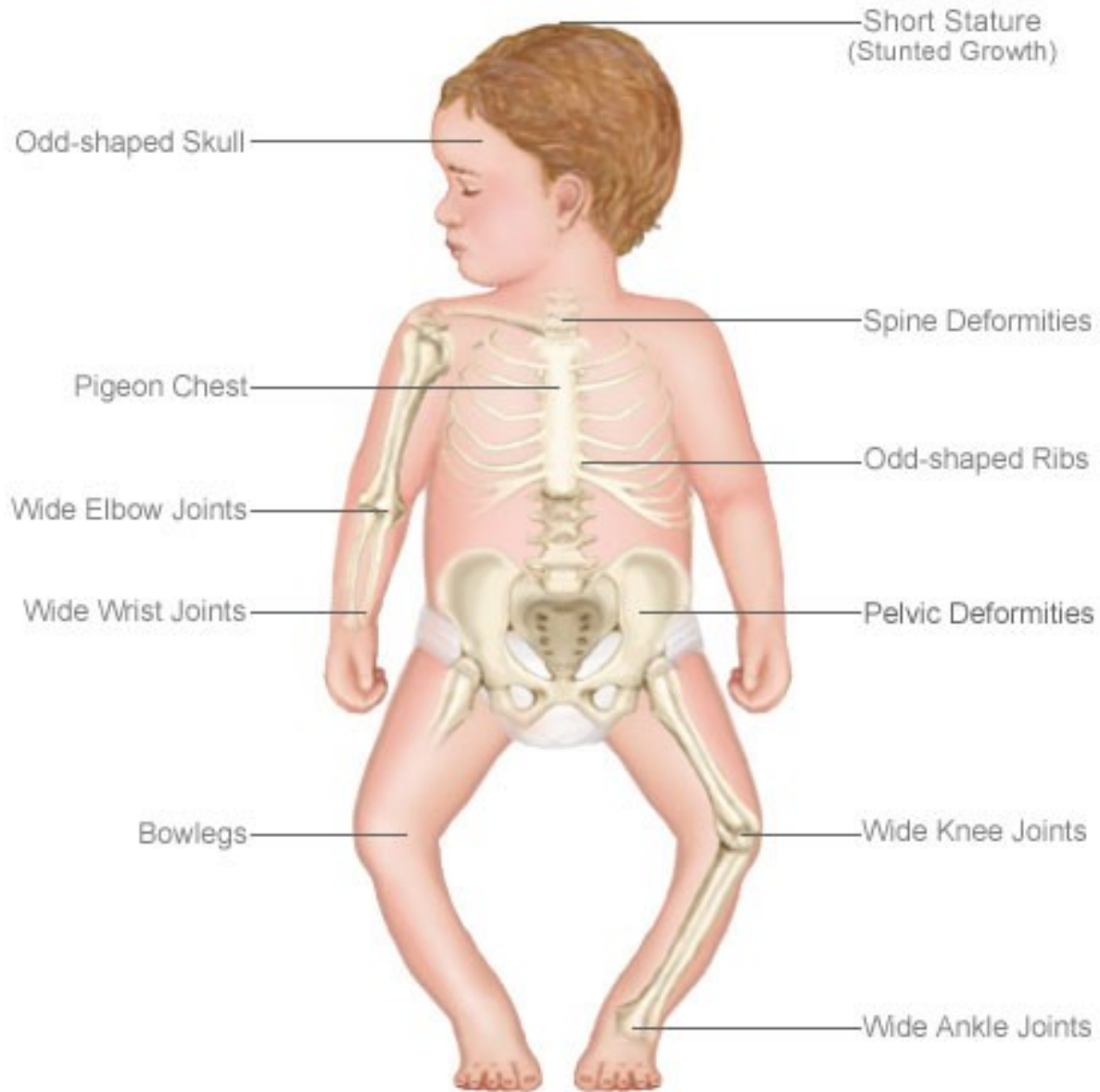
■ Calcitonin

- produced by parafollicular cells of the thyroid
- to lower serum calcium, if elevated

Rickets and osteomalacia

- Due to deficient mineralisation of organic bone matrix
- **Rickets** occurs in children and causes bone deformities
- **Osteomalacia** occurs in adults, causes susceptibility to fracture but few deformities
- Due to lack of active metabolites of vitamin D
- **Hypovitaminosis D** due to dietary deficiency of vitamin D, lack of sunlight, intestinal malabsorption, failure to metabolise vitamin D (in renal and liver diseases, in congenital enzyme deficiencies)

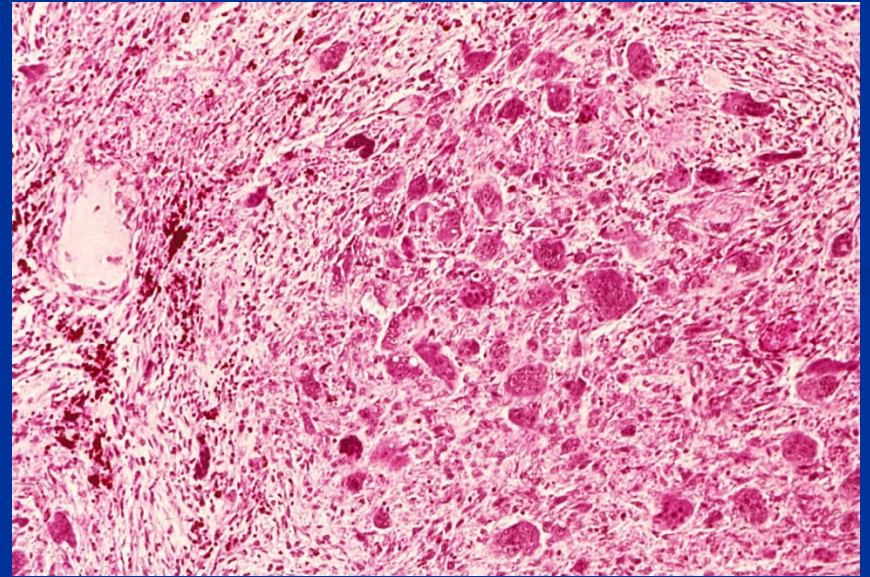
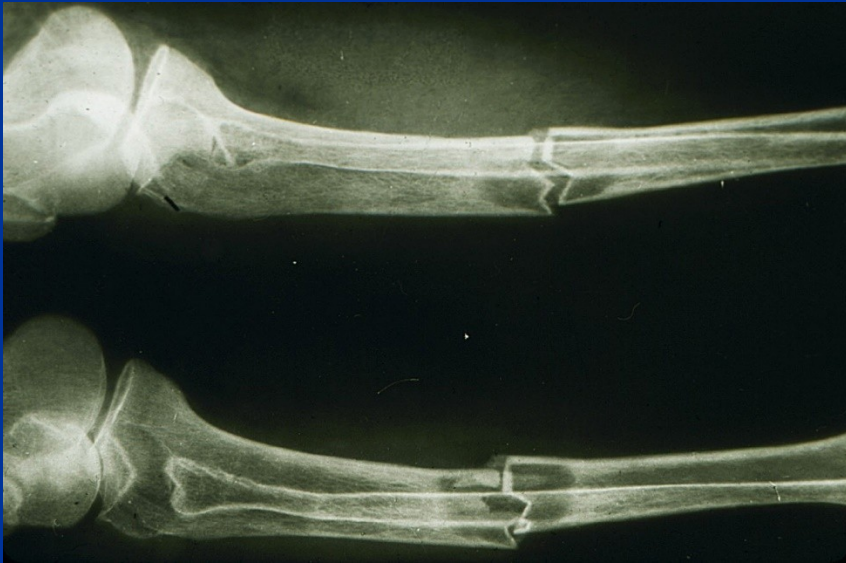The Effects of Rickets



Hyperparathyreoidism and hypercalcaemia

- **Hyperparathyreoidism (\uparrow PTH)** causes increased osteoclastic breakdown of bone
 - primary: hyperplasia, tumor (adenoma)
 - secondary: in hypocalcemia resulting in increased secretion of PTH (e.g. in renal failure: renal osteodystrophy (combination of osteomalacia and \uparrow PTH))
 - secretion of PTH related peptide by malignant tumor
- **Bone lesions:** thin cortex, osteopenia, fibrovascular tissue within bone marrow spaces, hemorrhages, organisation of hematomas, pseudocysts, brown tumors (mass of reactive tissue)

Pathologic fracture and brown tumor in hyperparathyreoidism



Moller-Barlow disease – avitaminosis C

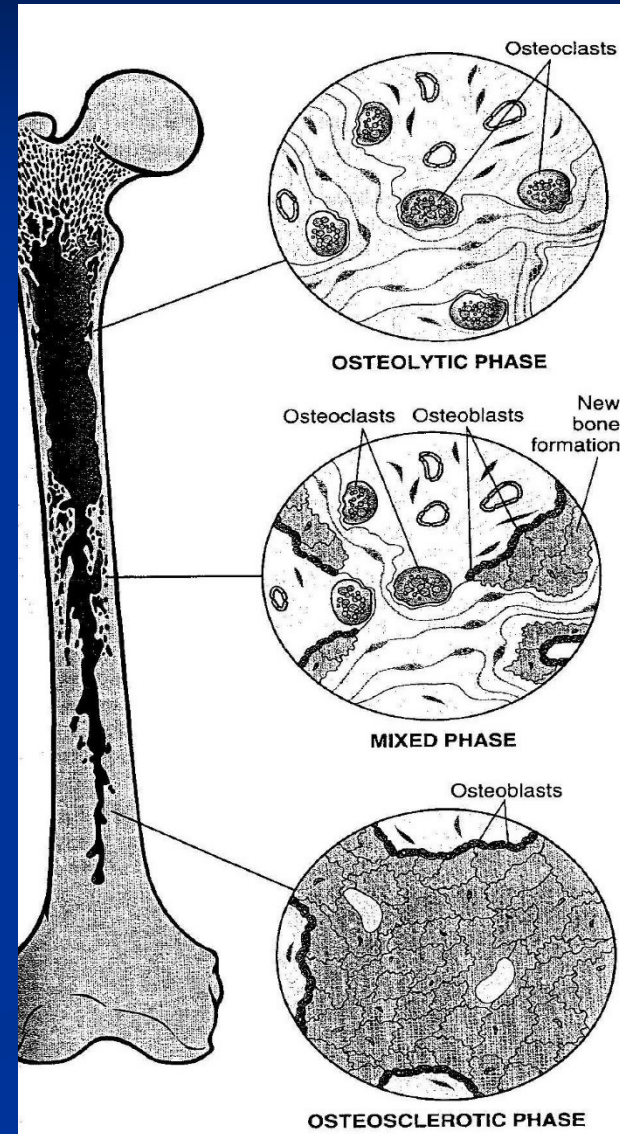
- vitamin C – hydroxylation of molecules of procollagen
- decreased secretion of collagen by fibroblasts and osteoblasts
- hemorrhages, subperiosteal hematomas, bleeding into joint spaces
- decreased production of osteoid and proliferation of cartilage (mineralization normal) – infractions, fractures, lysis epiphyseos, periostitis ossificans

Paget disease (osteitis deformans)

1. osteolytic stage
2. osteoclastic-osteoblastic stage
3. osteosclerotic stage

Etiology??

- slow virus infection (paramyxovirus) – viral particles seen in osteoclasts
- hereditary component (linked to locus on 18q)
- Pagetic bone enlarged with thick, coarsened cortices and cancellous bone
- Clinically pain, deformities, fractures, nerve compression
- Monoostotic – Polyostotic (15 %)
- Higher incidence of tumors and tumor-like lesions



Osteomyelitis

- Inflammatory lesion due to bacterial infection of bone
- Bacteria enter bone either from blood or directly through skin wound over a compound fracture
- Necrotic bone forms inner sequestrum
- Reactive new bone forms outer involucrum
- Most common in children (most usual *Staphylococcus aureus* infection)
- A complication of advanced tuberculosis
- May complicate the use of internal fracture fixation devices

Infections - osteomyelitis

■ Pyogenic osteomyelitis

- Staphylococcus a., E. coli, Pseudomonas, Klebsiella, Haemophilus i., Salmonella,...
- acute, subacute, chronic
- acute inflammatory reaction, subperiosteal abscess, necrosis (sequestrum), draining sinus
- chronic osteomyelitis: reactive periostitis ossificans (involcurum)

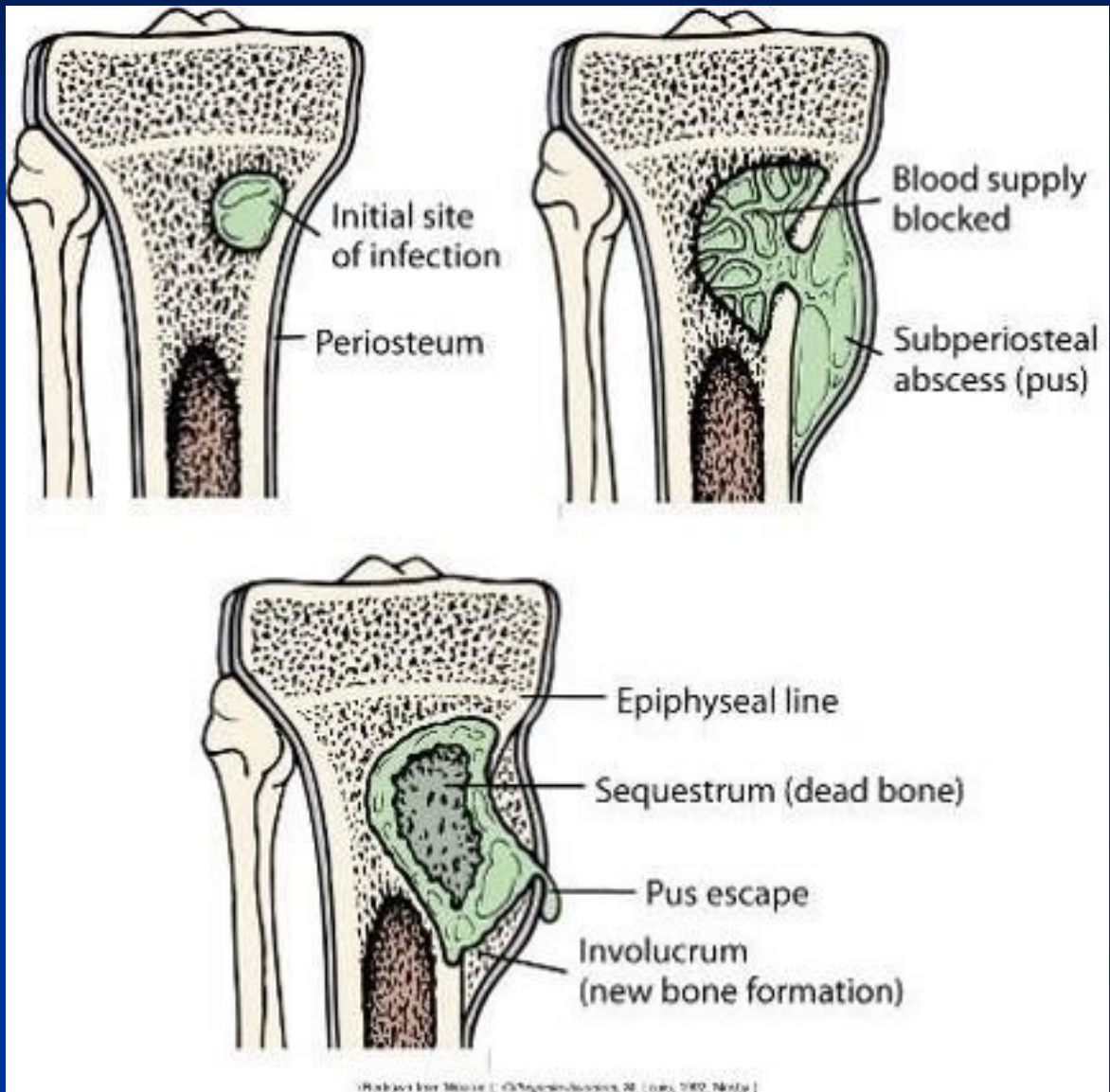
■ Tuberculous osteomyelitis

- hematogenous spread of BK into bones (rarely direct extension or lymphogenous spread)
- Pott disease in the spine

■ Skeletal syphilis

- STD, Treponema pallidum
- congenital syphilis (spirochetes localized in areas of active enchondral ossification (osteochondritis) and in the periosteum (periostitis))
- acquired syphilis (tertiary stage; reactive periostitis: nose, palate, skull, extremities – tibia – saber shin)

Osteomyelitis



Avascular necrosis: osteonecrosis

- Idiopathic (m. Perthes – femur, m. Kohler – os naviculare)
- Traumatic (mechanical vascular interruption, fracture)
- Corticosteroids
- Infections
- Dysbarism (nitrogen bubbles)
- Radiation therapy (vessel injury)
- Connective tissue disorders (vasculitis, vessel injury)
- Pregnancy
- Gaucher disease
- Sickle cells and other anemias
- Alcohol abuse
- Chronic pancreatitis
- Tumors
- Epiphyseal disorders

Inherited disease

■ Achondroplasia

- AD, single gene disorder (gene for fibroblast growth factor receptor)
- short stature, rhizomelic shortening of the limbs, frontal bossing, midface deficiency

■ Osteopetrosis

- reduced osteoclast bone resorption, diffuse symmetric skeletal sclerosis
- bones abnormally brittle (osteosclerosis fragilis generalisata)
- AR malignant type and AD benign type
- Anemia (reduced bone marrow space), extramedullar hemopoiesis – hepatosplenomegaly, repeated infections, fractures, cranial nerves problems – the result of nerve compression (optic atrophy, deafness, facial paralysis)

Inherited disease

■ mucopolysaccharidoses

- a group of metabolic disorders caused by the absence or malfunctioning of lysosomal enzymes needed to break down molecules called glycosaminoglycans. These long chains of sugar carbohydrates occur in each of our cells that help build bone, cartilage, tendons, corneas, skin and connective tissue.
- chondrocytes most severely affected
- abnormalities of hyaline cartilage result in short stature, chest wall abnormalities, malformed bones

■ osteogenesis imperfecta (collagen I disorder)

- phenotypically related disorders (types 1-4) ; variable severity of the disease within the types
- Clinically: bone fragility, hearing loss, blue sclerae, dentinogenesis imperfecta

■ type 2, 10, and 11 collagen diseases

- achondrogenesis (short trunk, severely shortened extremities, relatively enlarged cranium, flattened face)
- hypochondrogenesis (similar phenotype)

Malignant tumours of the bone						
Tumor	%	Usual age	M:F	Sites affected	Behaviour	Treatment, prognosis
Osteosarcoma	30	Adolescents	2:1	Long bones, distal femur, proximal tibia	Rapid growth, pain, swelling, lung metastases	Surgery and chemotherapy 40% + cure rate
Chondrosarcoma	15	35-60	2:1	Pelvis, ribs, spine, long bones	Slow enlargement, lung metastases	Surgery 75% cure rate
Fibrosarcoma	20	Any age, peak 30-40	3:2	Femur, tibia, humerus, pelvis	Local growth, vascular invasion	Surgery 40% cure rate
Ewing's sarcoma	7	Children and teenagers	2:1	Long bones, pelvis, ribs	Widespread metastases	Surgery and chemotherapy 50% + cure rate

+ secondary, metastatic tumors: breast, lung, prostate, kidney, thyroid cancer,.....
+ osteolytic lesions in myeloma (plasmocytoma)

Benign bone tumors

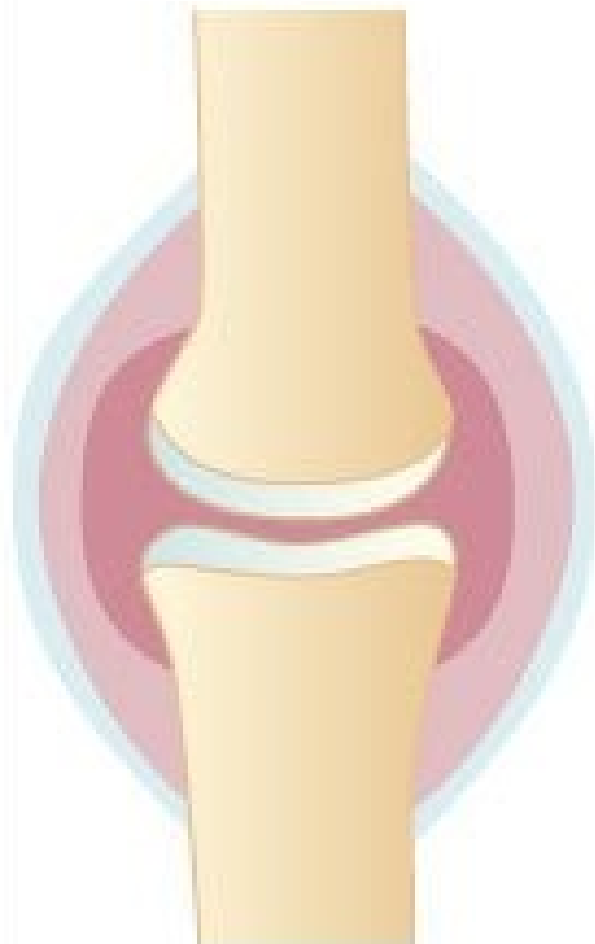- Osteochondroma (exostosis)
- Enchondroma
- Chondroblastoma
- Chondromyxoid fibroma
- Osteoma
- Osteoid osteoma

Locally aggressive or recurrent tumors

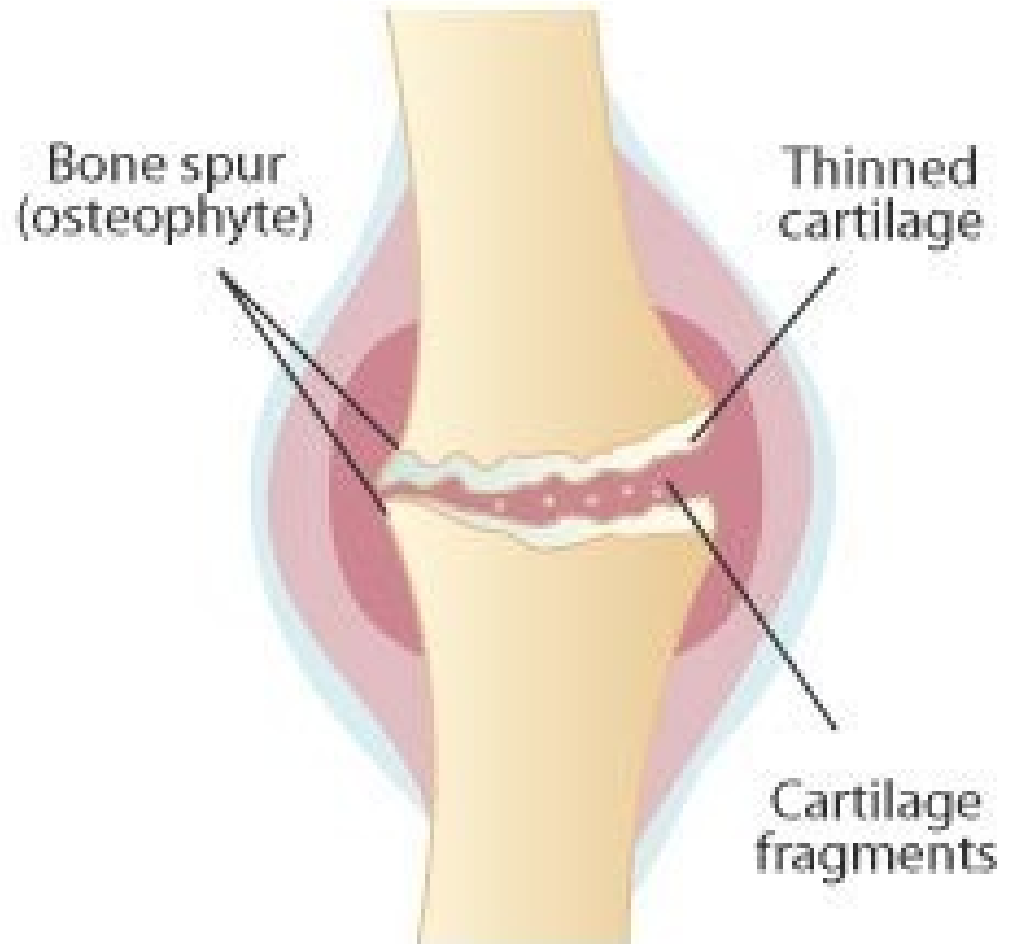
- Giant cell tumor (osteoclastoma)
- Osteoblastoma
- Chordoma
- Adamantinoma

Osteoarthritis (osteoarthrosis)

- Common painful, disabling degenerative joint disease
- Primarily affects cartilage of weight-bearing joints (e.g. hips, knees)
- Erosion of cartilage leads to secondary changes in underlying bone
- Only limited inflammatory changes in synovial membrane
- Osteoarthritis of hip and knee can be treated surgically by joint replacement



Normal joint



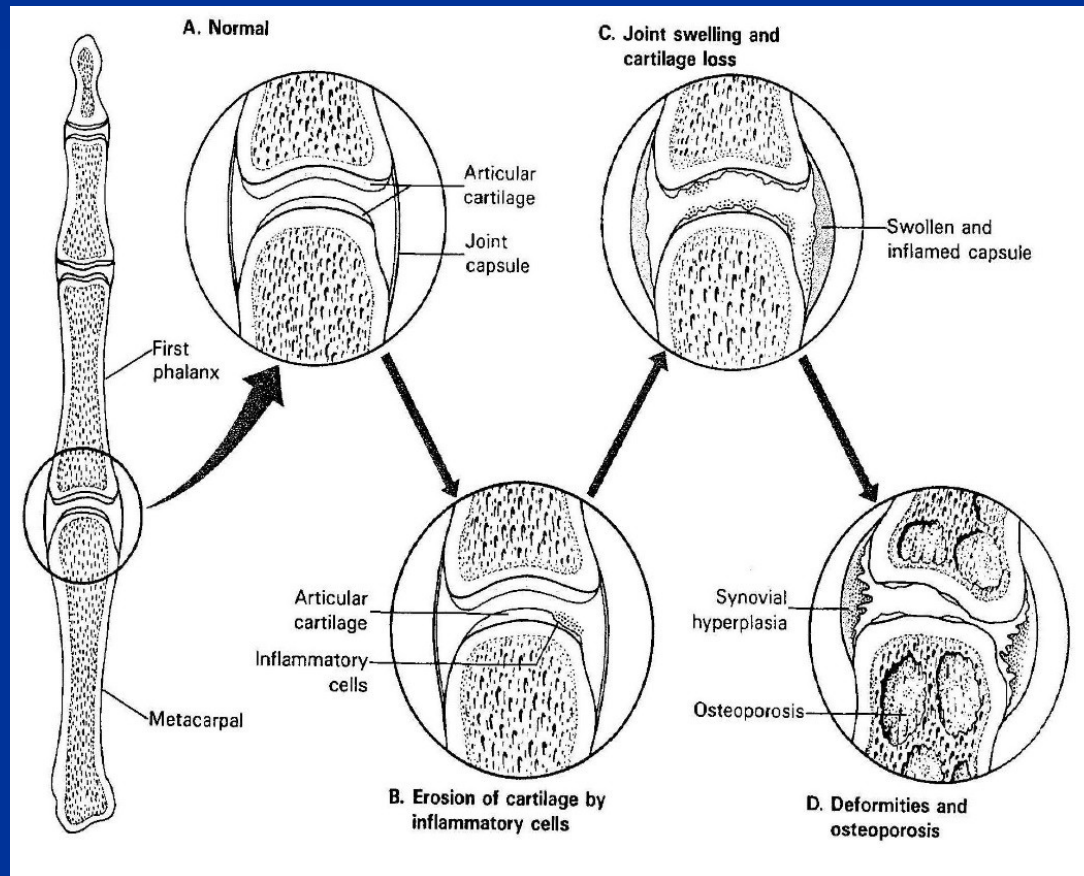
Joint affected by osteoarthritis

Rheumatoid arthritis

- a chronic systemic inflammatory disorder affecting also joints
- a nonsuppurative proliferative, inflammatory synovitis that often progresses to destruction of the articular cartilage and ankylosis of the joints
- autoimmune disease, in a genetically susceptible host; 95 % RA patients have positivity of rheumatoid factor (IgM against Fc fragment of IgG – immunocomplexes); F>M
- small bones of the hands, wrist, ankles, elbows, knees, cervical spine, hips affected; lumbosacral region spared

Rheumatoid arthritis

- systemic features include: subcutaneous rheumatoid nodules, anaemia, lymphadenopathy and splenomegaly, serositis (e.g. pericarditis), Sjögren syndrome, uveitis, vasculitis,....
- juvenile rheumatoid arthritis: children can be also affected



Seronegative spondylarthropathies: spondylarthropathies assoc. with HLA-B27 haplotype

■ Ankylosing spondylitis

- Inflammatory disorder of spinal joints
- Chronic synovitis, destruction of cartilage, bony ankylosis (sacroiliac and apophyseal joints), ossification of tendinoligamentous insertion
- Fusion of vertebral bodies inhibits flexion and rotation, especially in cervical segment, some patients develop fixed spinal deformities
- 90 % of cases have the HLA-B27 haplotype
- Systemic features include peripheral arthritis, uveitis, chronic inflammatory bowel disease

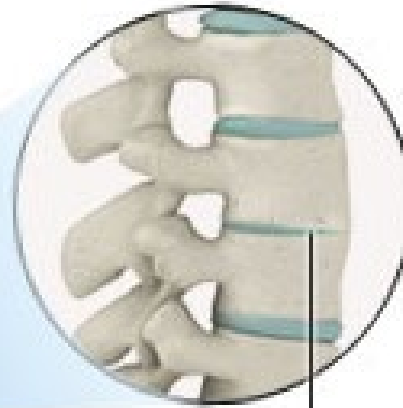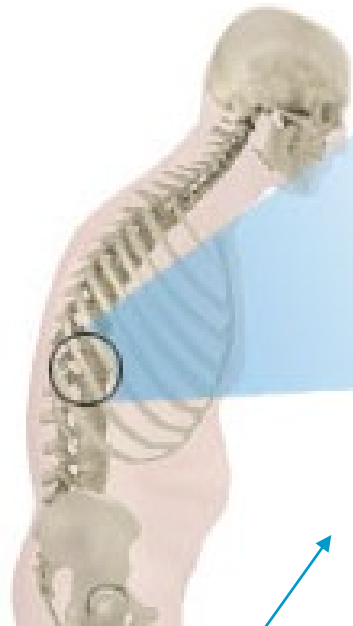
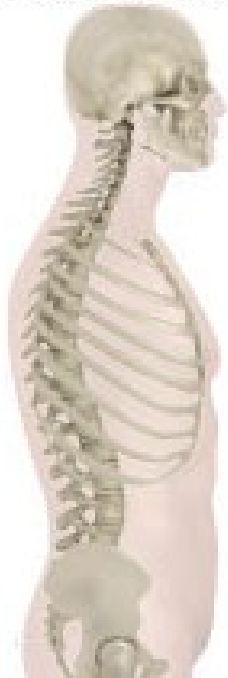■ Reiter's disease

- arthritis + conjunctivitis + urethritis
- 80 % HLA-B27+; autoimmune reaction initiated by prior infection
- infections of genitourinary (Chlamydia) and GIT (Shigella, Salmonella, Yersinia, Campylobacter)

+ **arthritis in psoriasis** (distal interphalangeal joints); in **IBD** (inflammatory bowel disease)

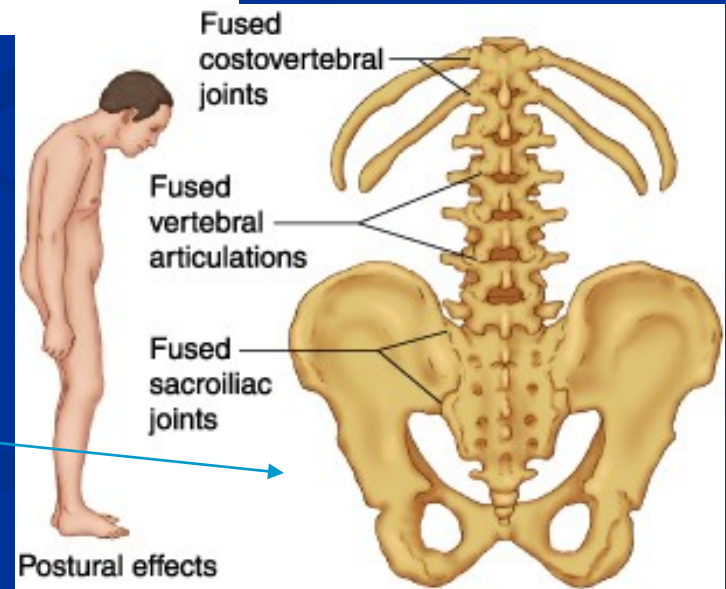
spine without
ankylosing spondylitis

spine with
ankylosing spondylitis



vertebrae
fused
together

Ankylosing spondylitis



Infective arthritis

■ Bacterial arthritis

- *Staphylococcus aureus*
- *Staphylococcus albus* (prosthetic joints)
- *Streptococcus pyogenes*
- *Haemophilus influenzae*
- *Diplococcus pneumoniae*
- *Neisseria gonorrhoeae*

■ tbc arthritis

- complication of tbc osteomyelitis or hematogenous dissemination from a visceral site of infection

■ Lyme arthritis

- *Borrelia burgdorferi* (transmitted by ticks)

■ Virus-associated arthritis

- parvovirus B19, rubella, HCV

■ Infective discitis

- *Staphylococcus aureus*, *Mycobacterium tuberculosis*, *Brucella abortus*

Rheumatic arthritis – rheumatic fever

- an acute immunologically mediated multisystem inflammatory disease occurring a few weeks after an episode of group A streptococcal pharyngitis
- migratory polyarthritits of large joints
- pancarditis

!!!

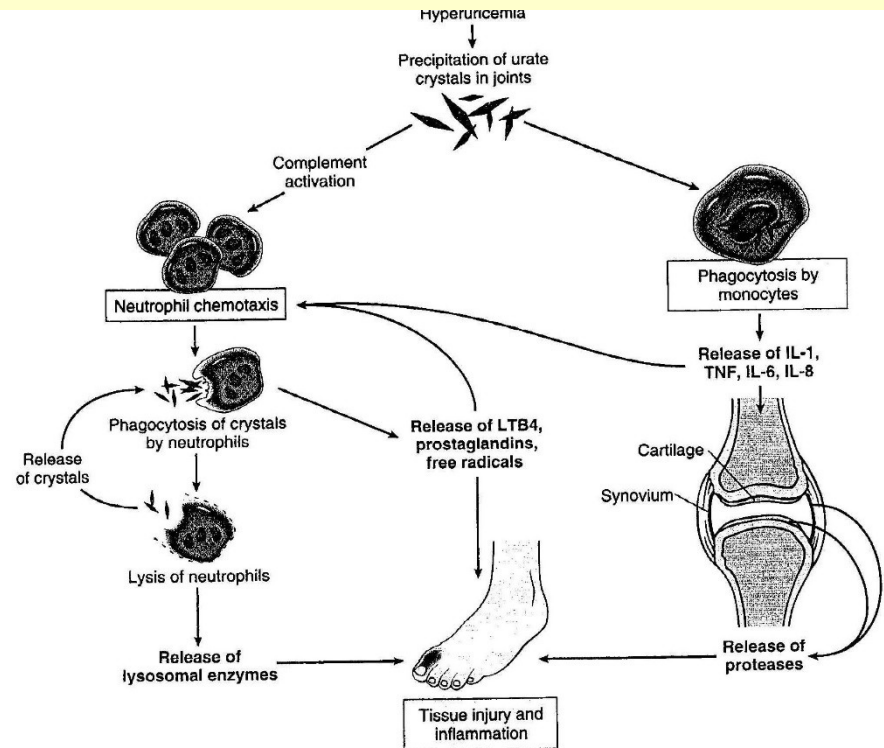
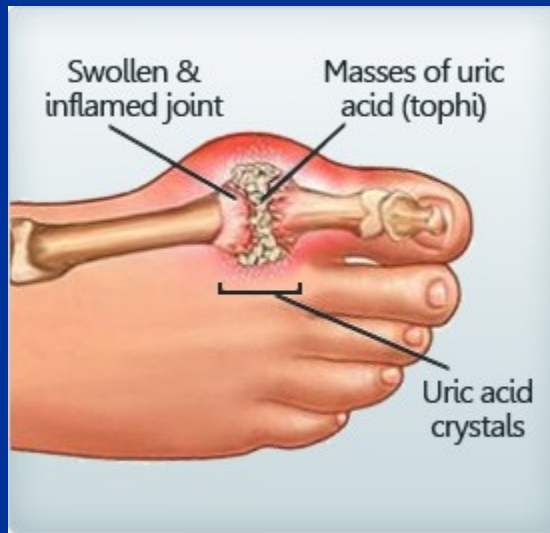Rheumatic fever: immunologically mediated post-streptococcal illness affecting heart and joints

Rheumatoid disease: autoimmune disorder causing arthritis, completely unrelated to rheumatic fever

Pathogenesis:

- Idiopathic
- Impaired uric acid excretion secondary to chronic renal failure, thiazide diuretics
- Increased uric acid production (in increased cell turnover, in specific enzyme defects)
- High dietary purine intake

Gout



- Painful acute inflammatory response to tissue deposition of urate crystals
- Most commonly affects metatarsophalangeal joint of first toe
- Much more common in males than females, onset 40-60 years, familial tendency
- Serum uric acid levels are raised
- May be associated with chronic renal disease

Connective tissue diseases, systemic

- Multisystem disorders, often affecting joints, skin, subcutaneous tissues
- Females preferentially affected (except polyarthritis nodosa and ankylosing spondylitis), weak genetic tendency
- Chronic clinical course, may respond to antiinflammatory drugs, immunosuppressive drugs (e.g. steroids)
- First presentation may be during adolescence or early adult life
- Immunological abnormalities often present (circulating auto-antibodies or evidence of immune complexes)

Clinical and pathological features of the major connective tissue diseases

Disease	F:M	Age (onset)	Clinical features	Immune abnormality	Pathology
Rheumatoid arthritis	3:1	Young and middle aged adults, also children	Chronic polyarthritis Subcutaneous nodules Splenomegaly	autoAb against native Ig (rheumatoid factor)	Chronic synovitis Granulomas in subcutaneous tissues Fibrinous pericarditis
Systemic lupus erythematosus	8:1	Young and middle aged adults	Erythematous (butterfly) skin rash Renal disease, glomerular damage Light sensitivity Arthritis, arthralgia. Anaemia, leukopenia	autoAb against nuclear and cytoplasmic proteins and other cellular component	Synovitis, glomerulonephritis, erythematous skin rashes
Polyarteritis nodosa	3:1	Any age, chiefly middle aged adults	Arthralgia Abdominal pain Ischaemic lesions in many organs, neuropathy, renal damage Fever, Leukocytosis, eosinophilia	Some antinuclear antibodies and rheumatoid factor	Necrotising vasculitis of medium-sized arteries
Ankylosing spondylitis	2:1	Young adults	Back pain Arthritis Uveitis	Most HLA-B27+	Spondylitis, bony fusion of spine and SI joints

Clinical and pathological features of the major connective tissue diseases

Disease	F:M	Age at onset	Clinical features	Immune abnormality	Pathology
Poly- and dermatomyositis	3:1	Adults (DM also in children)	Muscle weakness, pain, tenderness, skin rashes in DM	Myositis assoc. autoAb	Inflammatory myositis, in some cases paraneoplastic
Polymyalgia rheumatica	2:1	Elderly	Malaise, weakness, muscle aching, esp. shoulders, pelvis, hips	No consistent changes Raised ESR	Non specific muscle biopsy changes, some overlap with temporal arteritis
Temporal, giant cell arteriis	2:1	Elderly	Headache Visual loss Tender scalp	No consistent changes Raised ESR	Chornic granulomatous arteritis, head and neck arteries
Systemic sclerosis (scleroderma)	3:1	30-50 years	Raynaud's phenomenon Thick skin Polyarthritits Dysphagia. Dyspnoe. Hypertension	RF (25 %) Antinuclear Ab (50 %)	Fibrosis of subcutaneous and submucosal tissue, fibrosis of muscular arteries

Soft tissue tumors	
Benign	Malignant
Lipoma	Liposarcoma
Angioma	Angiosarcoma
Leiomyoma	Leiomyosarcoma
Rhabdomyoma	Rhabdomyosarcoma
Fibroma	Fibrosarcoma
	„Synovial“ sarcoma (=soft tissue sarcoma)

+ Tumor-like lesions of connective tissues:

- Fibromatoses (palmar, palntar, abdominal,...)
- Nodular fasciitis
- Myositis ossificans

Neuromuscular disorders

- **Neurogenic disorders – neurogenic atrophy**
- **Disorders of neuromuscular transmission**
- **Myogenic disorders**
 - Muscular dystrophies
 - Congenital structural myopathies
- **Inflammatory myopathies – myositis**
- **Myopathies associated with metabolic diseases**
 - Glycogenosis (glycogen storage diseases)
 - Carnitine deficiency
 - Mitochondrial disorders
- **Others**
 - myopathies in endocrinopathies (thyreotoxic and hypothyreoid myopathy, steroid myopathy,...)
 - drug induced myopathy (steroid myopathy, myopathy in patients treated with hydrochloroquine,...)
 - ethanol myopathy

Neurogenic disorders (denervation atrophy)

■ Motor neuron diseases

- Amyotrophic lateral sclerosis
- Spinal muscular atrophy

■ Radiculopathies

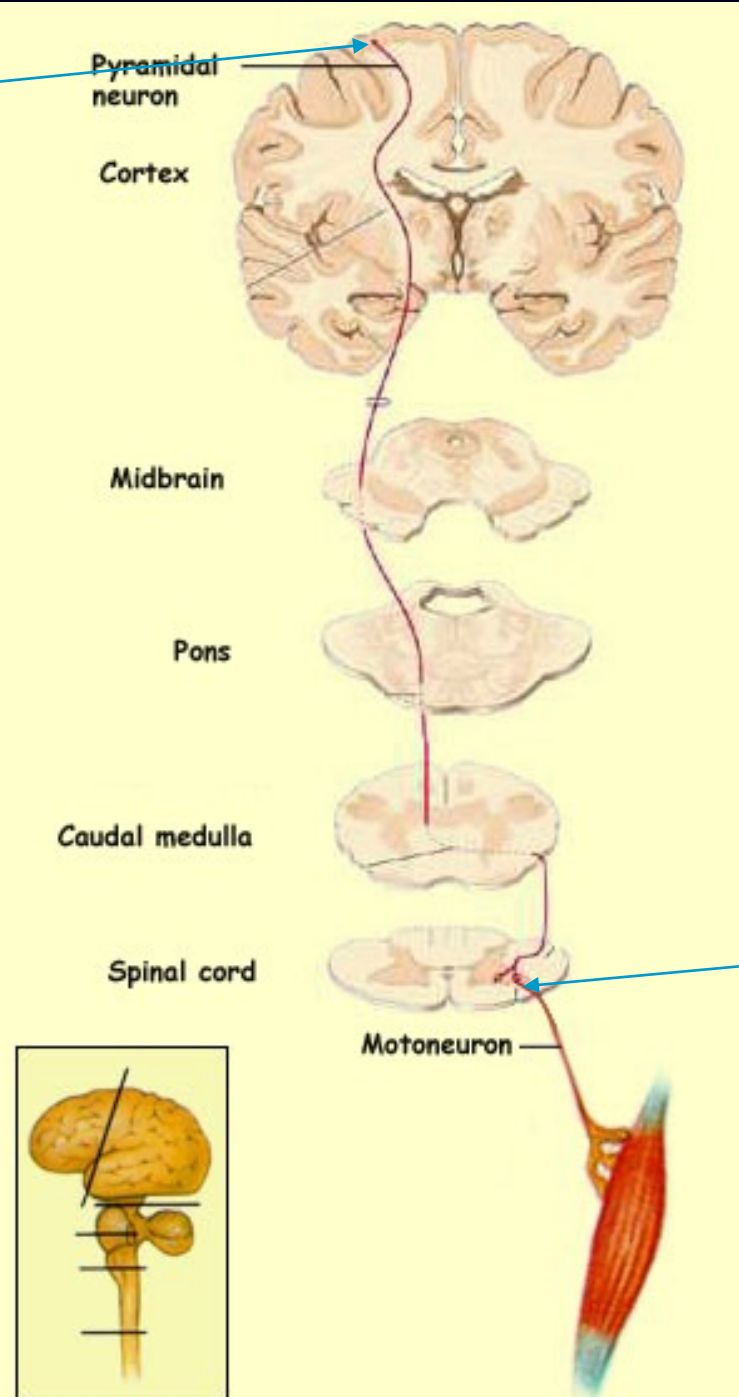
- discopathies
- extramedullar tumors
- polyradiculoneuropathy-immune mediated-Guillain-Barré syndrome – demyelinating disorder

■ Damage of peripheral nerves/peripheral neuropathies

inflammatory, traumatic, metabolic (diabetic), toxic, genetic (hereditary motor and sensory neuropathies), neoplastic

Upper motoneuron

Motor neuron tract



Lower motoneuron

Motor neuron diseases

- **Amyotrophic lateral sclerosis**

(both upper and lower motorneurons affected, distal and proximal muscle weakness and wasting spasticity)

- **Progressive muscular atrophy**

(lower motor neuron involvement, weakness and wasting of distal muscles, fasciculations and absent reflexes)

- **Progressive bulbar palsy**

(cranial nerves involvement results in weakness of the tongue, palate, pharyngeal muscles)

Amyotrophic lateral sclerosis

- **90 % sporadic ALS**

- F:M – 1,7:1

- older people, survival 3-4 years, first symptoms in 56-63 years, upper extremities preferentially affected, bulbar symptomatology

- **10 % hereditary ALS**

- 4th decade, juvenile forms, F:M – 1:1

Spinal muscular atrophy

- Inherited; AR; homozygous loss of SMN1 (survival motor neuron gene)
- occurring in 1/6000-10000 births; 2-3 % of populations are carriers
- 2nd most common inherited disorder after cystic fibrosis (mucoviscidosis)

Allelic variants of SMA

■ Type 1 (Werdnig-Hoffmann disease)

- Rapidly progressive, onset before 3 months of age, death before the age of 18 months

■ Type 2

- Onset between 6-12 months of age, more slowly progressive with variable life expectancy

■ Type 3 (Kugelberg-Welander disease)

- Onset between 2-15 years of age, slowly progressive

■ Type 4

- Affects adults, very slow course causing mild disability

Peripheral neuropathy: peripheral nerve disorders

■ **Mononeuropathy**

- a single nerve involved
- e.g. carpal tunnel syndrome

■ **Mononeuritis multiplex**

- several isolated nerves involved
- e.g. polyarteritis nodosa, sarcoidosis

■ **Polyneuropathy: multiple nerve involvement**

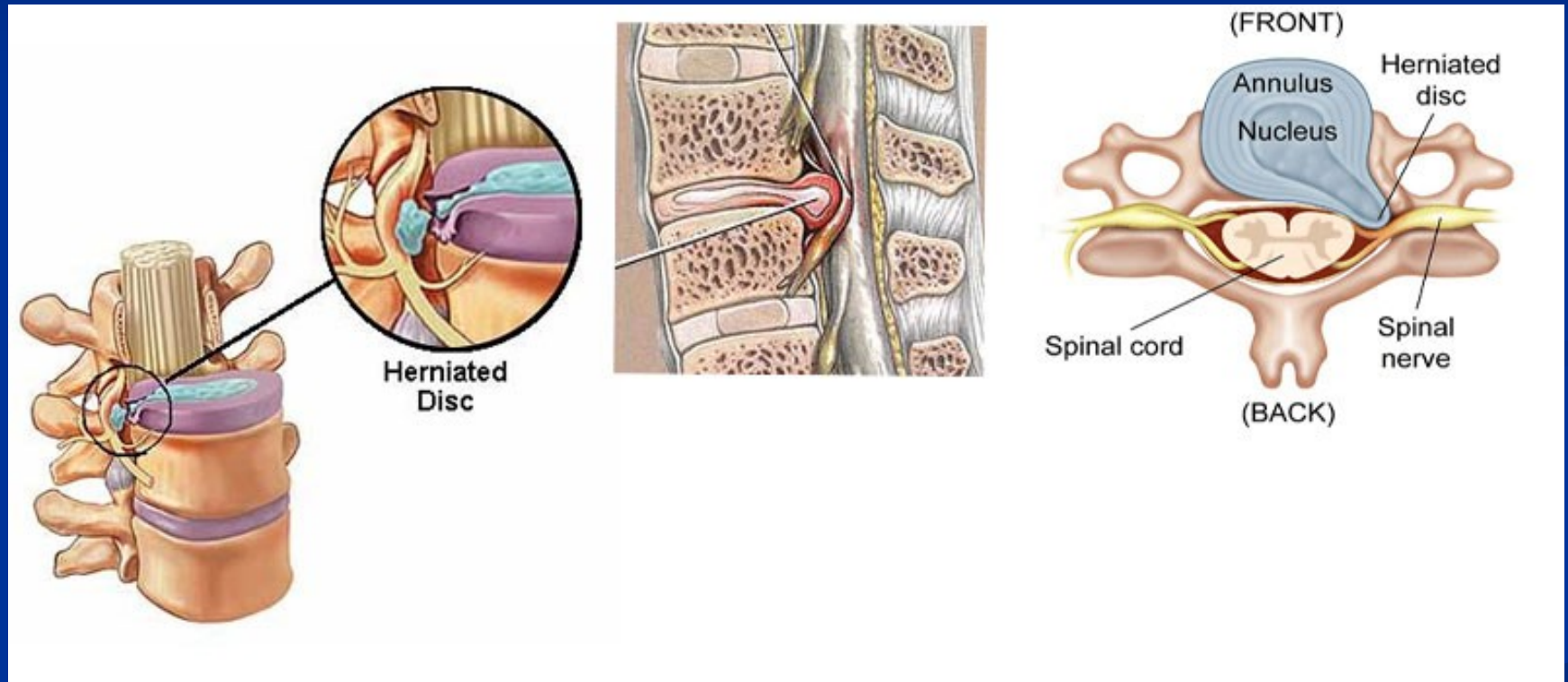
■ **Mainly motor:** e.g. Guillain-Barre sy (autoimmune polyradiculoneuritis)

■ **Mainly sensory:** carcinomatous neuropathy

■ **Sensorimotor:** e.g. alcoholism

■ **Autonomic:** e.g. diabetes

Intervertebral disc prolapse



Disorders of neuromuscular transmission

■ Myasthenia gravis

- autoimmune disease, loss of acetylcholine receptor due to production of autoAb
- fluctuating progressive muscle weakness (ocular, bulbar and proximal limb muscles preferentially affected)
- females more often affected
- thymic hyperplasia or thymoma in many patients
- immunosuppressive treatment and thymectomy

■ Lambert-Eaton myasthenia syndrome

- paraneoplastic, complication of malignancy (e.g. lung cancer – small cell carcinoma)
- limb girdle and proximal muscle weakness
- autoimmunity to calcium channels???

Muscular dystrophies

- heterogeneous group of inherited disorders of muscles
- progressive muscle weakness and wasting
- „dystrophic“ muscle biopsy changes and replacement of muscle by fibrofatty tissue
- defects in muscle proteins
- clinical and genetic heterogeneity
- some are associated with multisystem involvement (including cardiac (arrhythmias, both dilated and hypertrophic cardiomyopathies) and CNS)

Muscular dystrophies

- **Dystrophinopathies (X-linked)**
- **Limb-girdle muscular dystrophies; LGMDs (AR, AD)**
- **Emery-Dreifuss muscular dystrophy (X-linked, AD)**
- **Facioscapulohumeral muscular dystrophy (AD)**
- **Congenital muscular dystrophy (AR)**
- **Oculopharyngeal muscular dystrophy (AD)**
- **Distal myopathy (AR, AD)**
- **Bethlem's myopathy (AD)**
- **Barth's syndrome (X-linked)**
- **Myotonic dystrophy (AD)**

Diagnosis of muscular dystrophies

■ **Clinical assessment**

- general neurological examination
- serum creatine kinase (CK) level
- neurophysiology – electromyography (exclusion of neuropathy)
- muscle imaging (MRI, CT)

■ **Muscle biopsy (2/3 genetically defined LGMD are suggested by biopsy)**

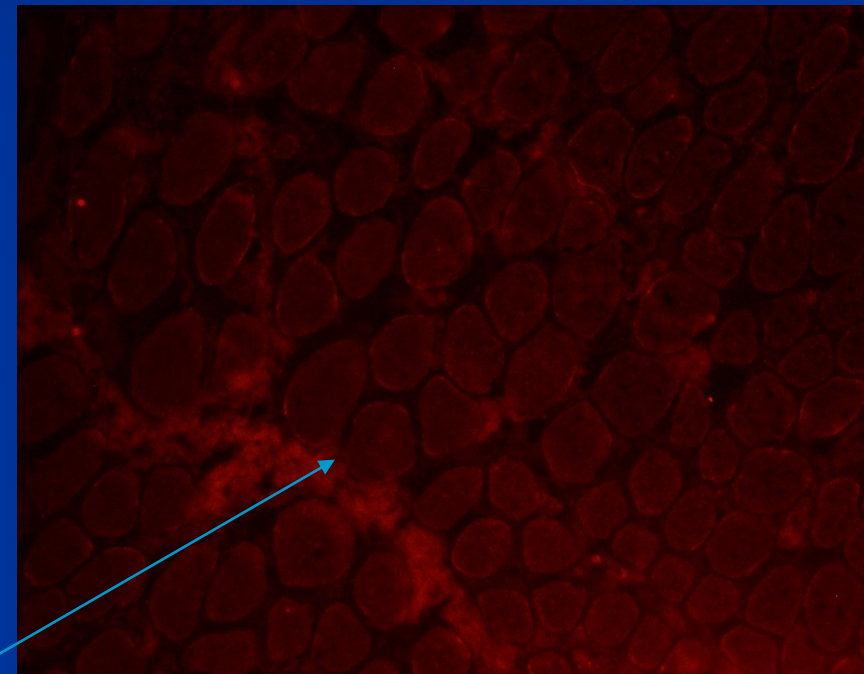
- histopathology
- immunohistochemistry (IH), immunofluorescence (IMF)
- immunoblotting

■ **Molecular genetic testing – mutational analysis (the gold standard for diagnosis)**

- DNA
- mRNA

Duchenne muscular dystrophy (DMD)

- Due to severe mutations in dystrophin gene
- X-linked; female carriers
- Median age of presentation: 3.5 years; progressive course; life expectancy 20 years; calf pseudohypertrophy
- Myogenic lesion in muscle biopsy, loss of dystrophin



immunofluorescence, loss of dystrophin in DMD

Becker muscular dystrophy (BMD)

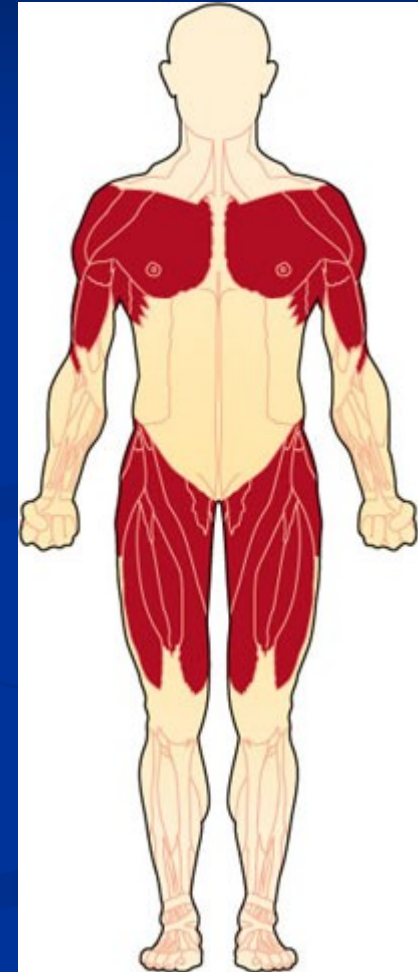- Due to in-frame deletion in dystrophin gene
- Milder allelic variant of DMD
- Truncated protein dystrophin is produced

Female carriers of DMD/BMD

- Symptomatic
- Asymptomatic

Limb-girdle muscular dystrophies

- Genetically and clinically heterogeneous group of progressive muscular dystrophies
- Muscles of the pelvic and shoulder girdle are preferentially affected
- 21 forms autosomal recessive
- 8 forms autosomal dominant
- + AR, AD and X-linked muscular dystrophies with LGMD phenotype



Congenital muscular dystrophies (CMD)

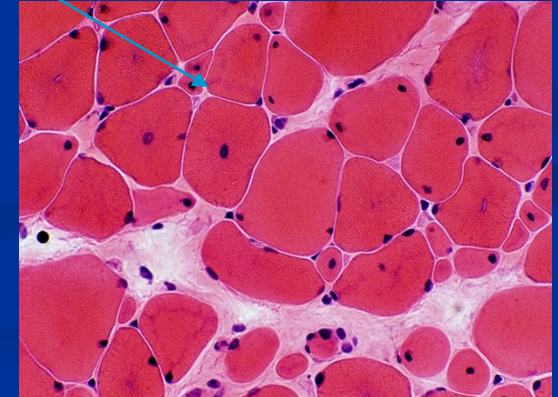
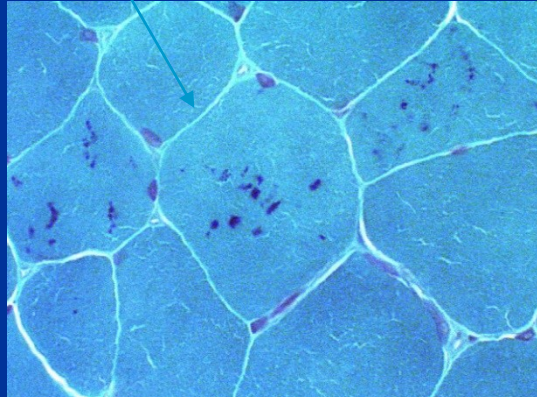
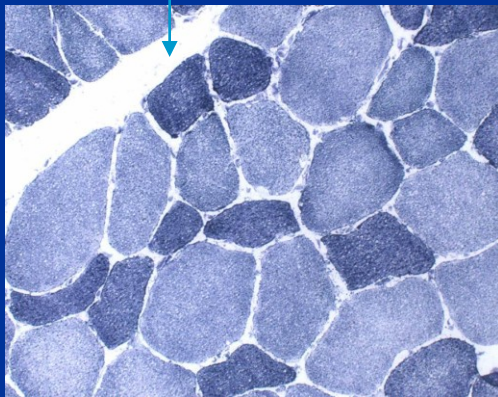
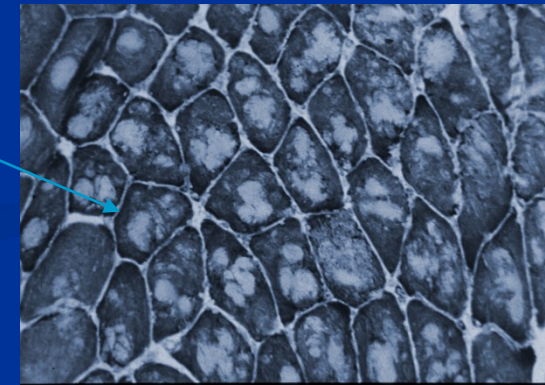
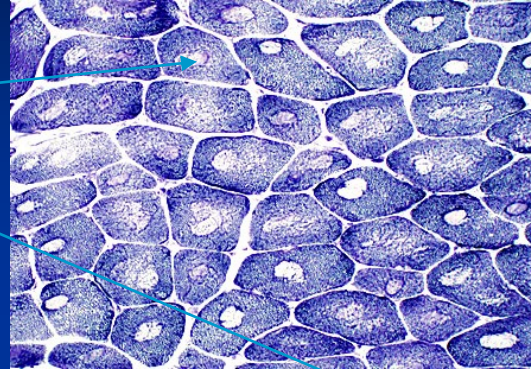
- Congenital, presented at birth, progressive
- Inherited, AR, genetically and phenotypically heterogeneous
- Muscle weakness, hypotonia, contractures; in some subtypes structural lesions of CNS and retina
- muscle biopsy: myogenic lesion, often degeneration, regeneration, and also inflammatory pattern in muscle biopsy

Congenital structural myopathies

- A distinctive abnormality in skeletal muscle fibres on the cellular level; observable via light microscope
- Symptoms of muscle weakness and hypotonia.
- Is a congenital disorder, meaning it occurs during development and symptoms present themselves at birth or in early life.
- Is a genetic disorder
- Clinically and genetically heterogeneous

Congenital structural myopathies

- Central core disease
- Multi and minicore disease
- Nemaline myopathy
- Centronuclear myopathy
- Congenital fibre type disproportion



Inflammatory myopathies -myositis

■ Polymyositis

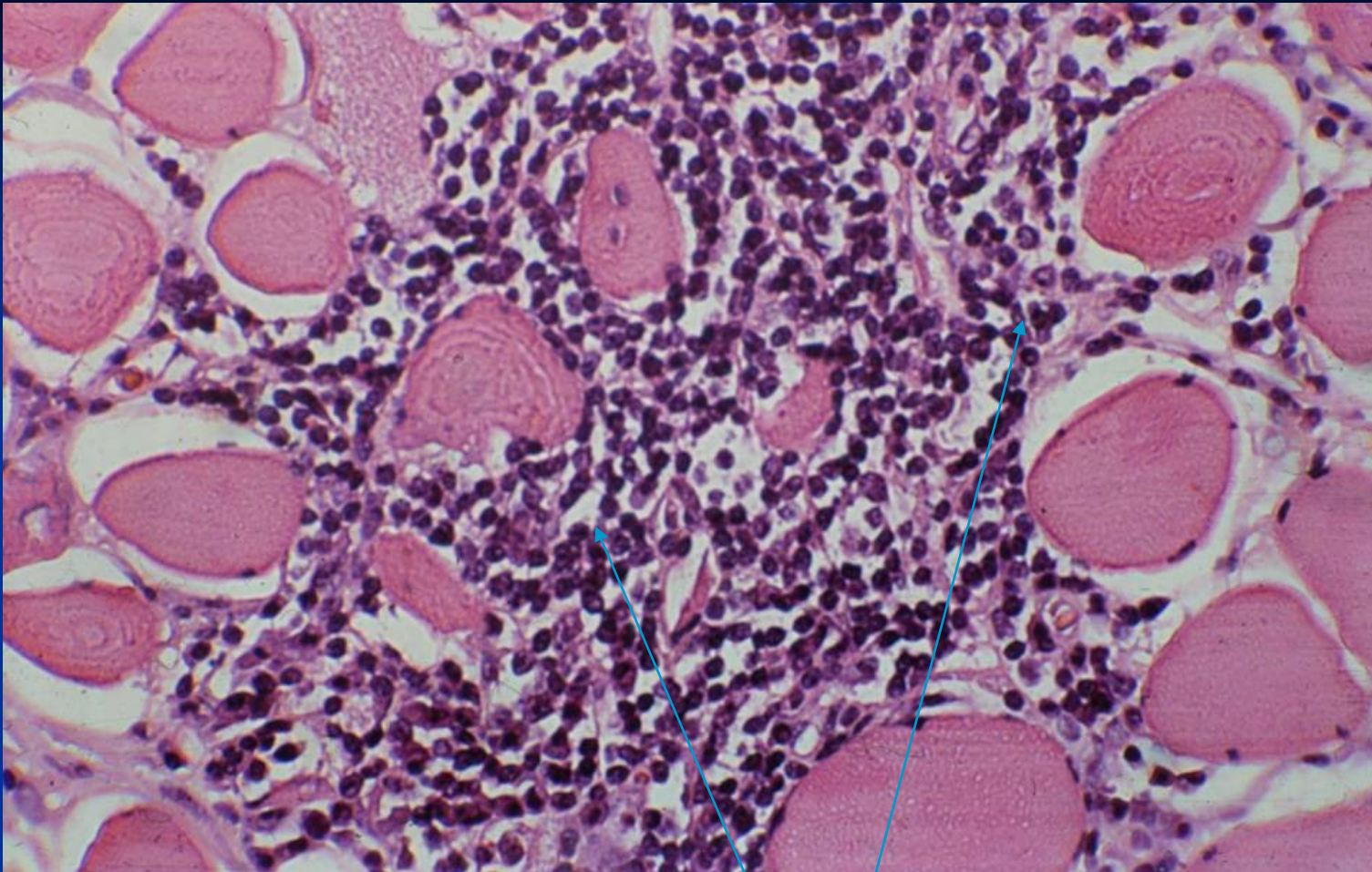
- females, autoimmune disease, oftend associated with other autoimmune diseases (anti-Jo-1 protilátky)
- Endomysial inflammatory infiltration

■ Dermatomyositis

- Juvenile and adult, more in females, dermatitis and myopathy
- Perivascular inflammatory infiltration (CD20+, CD4+, MAC+)
- Perifascicular atrophy

■ Myositis/myopathy with inclusion bodies

- Sporadic and hereditry
- Resistent to imunosupresive therapy



Polymyositis: endomysial lymphocytic inflammatory infiltration

Myotonia:

the sustained involuntary contraction of a group of muscles; patients complain of stiffness, difficulties in releasing their grip

1. Myotonia congenita (reduction of functional chloride channels)

- **Becker type (AR)**
- **Thomsen type (AD)**

2. Myotonic dystrophy

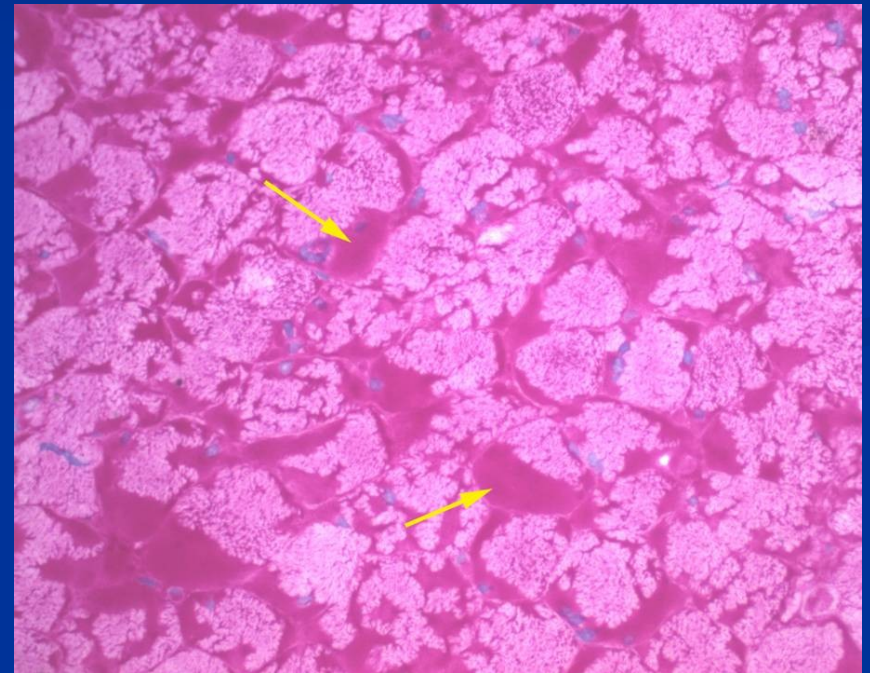
- **DM1 (AD; 19q13.3, myotonin proteinkinase)**
congenital (dementia, hypotonia), **classic** (myotonia, muscle weakness, atrophy, cataract, endocrinopathies), **milder form**
- **DM2 (AD; 3q21; zinc finger protein)- PROMM** – proximal myothonic dystrophy

Malignant hyperpyrexia

- Inherited disorder; AD; diagnostic *in vitro* contraction test
- Mutation in ryanodin receptor gene; association with central core disease
- Hypermetabolic state triggered by the induction of anesthesia, usually with halogenated inhalational agents and succinylcholine
- Tachycardia, tachypnoe, muscle spasms, hyperpyrexia; without intensive treatment fatal clinical outcome
- Channelopathy; increased levels of free calcium in sarcoplasm of myofibers

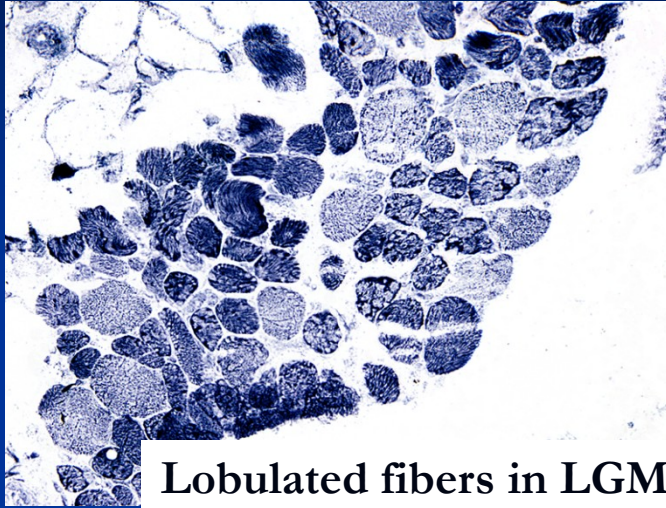
Storage of glycogen in muscles in glycogenosis (inherited; AR)

- PAS+ (glycogen)

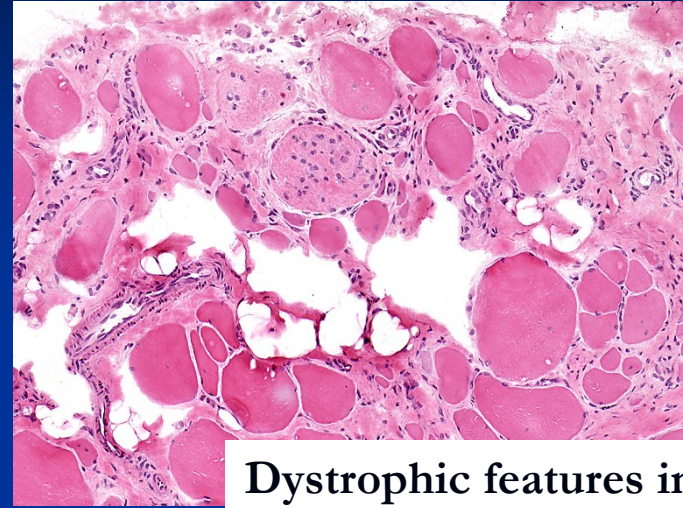


PAS

Muscle biopsy



Lobulated fibers in LGMD2A



Dystrophic features in biopsy

- Specialized laboratories in departments of pathology (FN Motol)
- Guided using imaging and results of clinical assessment
- Open versus needle biopsy
- Standard histological techniques, enzyme histochemistry
- Immunohistochemistry and immunoblotting
 - panel of antibodies
 - evaluation of primary and secondary changes on immunoanalysis
- Direction of reasonable mutational analysis

