

# Specific of pediatric surgery



III. Year - volume

# Anamnesis



- Family anamnesis
- Personal anamnesis
- Epidemiological anamnesis
- Farmacological anamnesis
- Allergic anamnesis
- Fyziological functions
- (*Gynecological anamnesis*)

# Anamnesis




- About birth
- Contact with infection
- DMO, PMR, obesity
- Psychical and social status
- Undirect anamnesis
- With child only supplementary questions
- Child abuse and neglect (CAN) – be careful

- Behaviour

- spontaneous
- Fear
- Change reactions without parents

- State of consciousness

- We can wake up it from the sleep
- Infants don't respond to verbal irritation
- We examine reflexes (mammilingus, defense,...)





- Hematoma - CAN
- Head - shape, size – congenital deformities
- Chest - pectus excavatum x carinatum
- Abdomen – ventral hernias, umbilicus

# Percussion

- Head – pain, impression
- Chest
  - Hypersonorous
    - pneumothorax
  - Hyposonorous
    - Hydrothorax, infiltration
  - Cardial shadow – change of index, location
    - Kardiomyopahia, big vessels transposition
- Abdomen
  - Hypersonorous
    - Pneumoperitoneum, ileus, enteral colic - tormina
  - Hyposonorous
    - Ascites, hemoperitoneum, infiltration

# Auscultation

- Neck – a. carotis communis - stenosis
- Chest
  - Pneumothorax
    - Diminished breathing or nothing
  - Hydrothorax
    - Damped breathing
  - Inflammatory or spastic phenomena
- Abdomen
  - Normal peristalsis
  - Intensive peristalsis
    - Ileus obstructive
  - Deadly silence
    - Ileus - paralysis

# Palpation

- Head
  - Big fontanella, impressions
- Chest
  - Ribs fracture, lymphatic nodes
- Abdomen
  - First we examine supposed painless region
  - Blumberg, Plenies, Murphy, Tapott
- Extremities



# Specialities of children

- Injuries
- Congenital defects
- Infections
- Tumours

# Head

- Hydrocephalus – head circumference
- Craniostenosis – premature closing of big fontanella, small head circumference
- Fissures – lip, palate, mandible, jaw bone

# Neck

- Persistent branchial arcus (cysts, fistulas)
- Congenital torticollis

# Chest

- Pectus excavatum x carinatum
- Peristalsis in chest cavity – diaphragmatic hernia
- Congenital heart defects
- CAN - multiple ribs fracture

# Abdomen

- Ventral hernias
- Omfalocele – persistent yolk sac
- Gastroschisis

# Limbs

- Luxatio perianularis (RU joint)
- Willow stick fracture
- Epiphyseolysis
  
- Good and fast healing
- Great ability of remodelation

# Gastrointestinal

- Atresia of oesophagus – salivation after the birth polyhydramnion, we can't establish NG tube
- Atresia of duodenum – double bubble on X ray vomiting, polyhydramnion
- Necrotic enterocolitis
- Meconious ileus – CF
- Atresia of anus
- Burn of GIT
- Foreign body of GIT

# Respiratory system

- Cystic fibrosis
- Bronchopulmonary dysplasia (33. w.g.)
- Laryngitis
- Foreign bodies



# Excretory system

- Hydronephrosis
- Wilms tumour
- VUR
- Hypospadias
- Stenosis of urethra
- Testicular retention

# Nervous system

- Hydrocephalus
- Meningomyelocele
- Tumours – gliomas
- Craniostenosis
- Child cerebral palsy
- Light cerebral dysfunction

# Musculoskeletal system

- Coxa vara
- Aseptic necrosis of femoral head
- Pes equinovarus
- Morbus Oosgod – Schlatter
- Spatic contractures
- Cysts and tumours (Ewing)

Diagnostic test

# Case 1

- Bend over
  - Subfebrilia
  - Emesis
  - Pain in right hypogastric region
  - Anamnesis cca 3 hours
  - Sonografic examination negative
  - CRP 12
  - WBC 6,4
- 
- Appendicitis acuta

# Case 2

- Age 3 years
  - Diarrhoea with blood
  - Abdoinal bloating
  - Emesis
  - Intensive peristalsis
  - Sonografic examination positive
- 
- Intususception

# Case 3

- Header
  - 4 s unconsciousness
  - Somnolence
  - Emesis
  - Headache
  - X ray negative
  - CT positive
- 
- Epidural hematoma

# Case 4

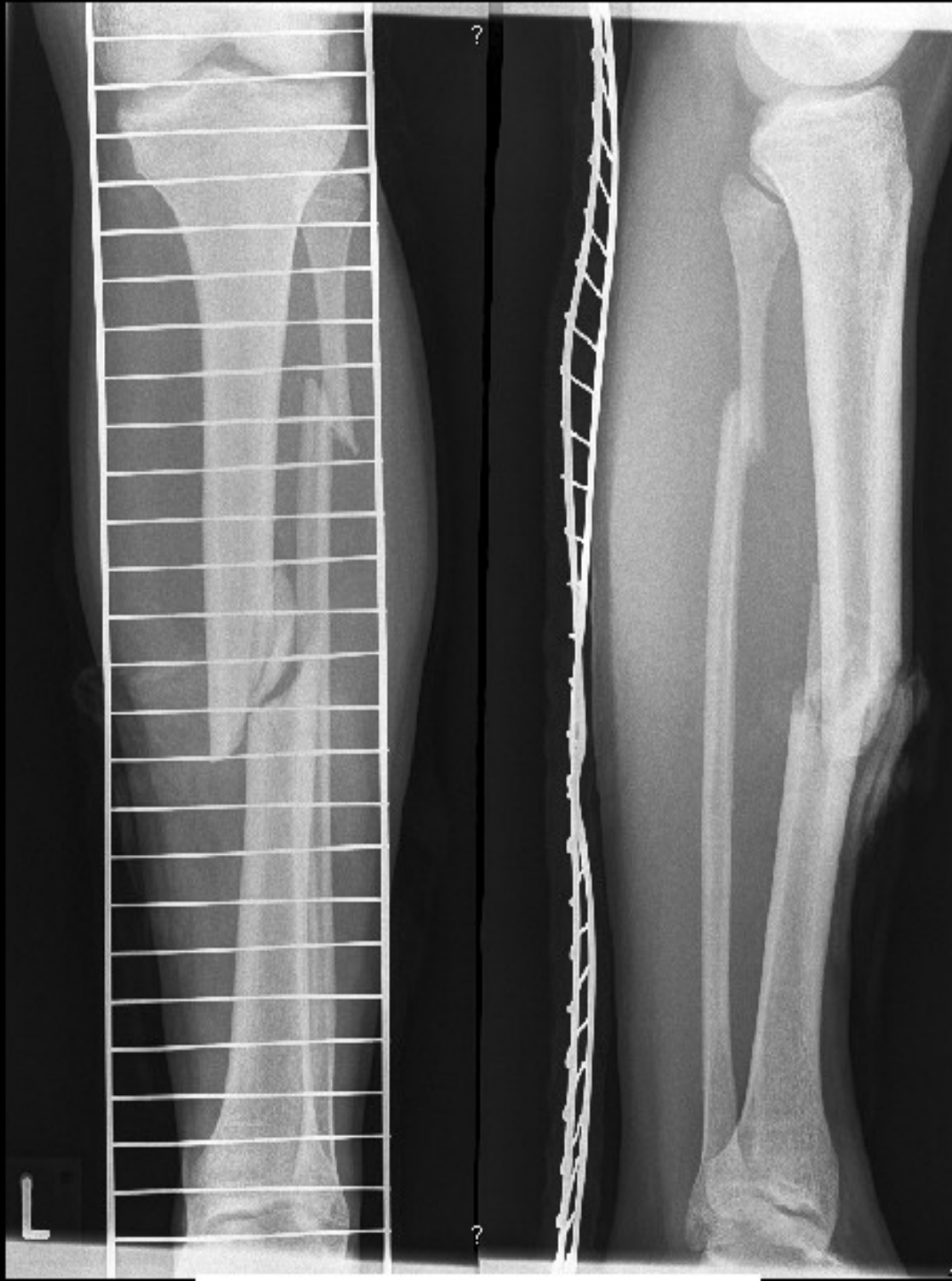- Fall from a tree
  - Left side of body impact
  - Urina without erythrocytes
  - Pallor
  - Pain of left shoulder
  - Ultrasonography positive
  - CT positive
  - RBC decline
- 
- Lienal rupture




# Radiodiagnostic test

ID:078500  
Kvas Michal  
Narozen:1989-03-24  
Datum:2005-01-02  
Cas:18.39.17  
No.1

1



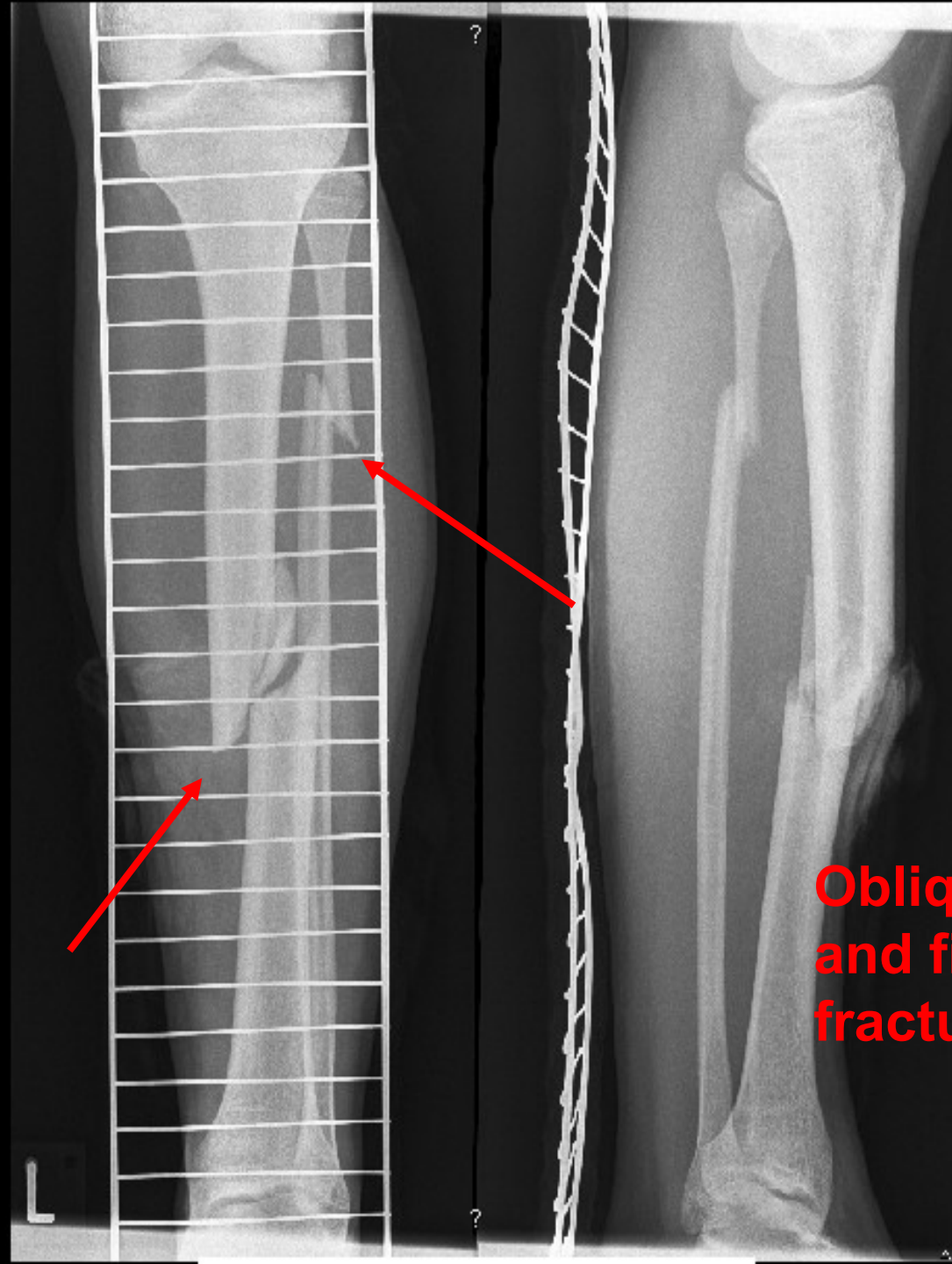
Q: 80%   
FN Brno -Detska nemocnice  
ADC\_5146

C: 2583  
W: 2635

ID:078500  
Kvas Michal  
Narozen:1989-03-24  
Datum:2005-01-02  
Cas:18:39:17  
No.1

Q: 80%   
FN Brno -Detska nemocnice  
ADC\_5146

1



**Oblique tibial  
and fibular  
fracture**

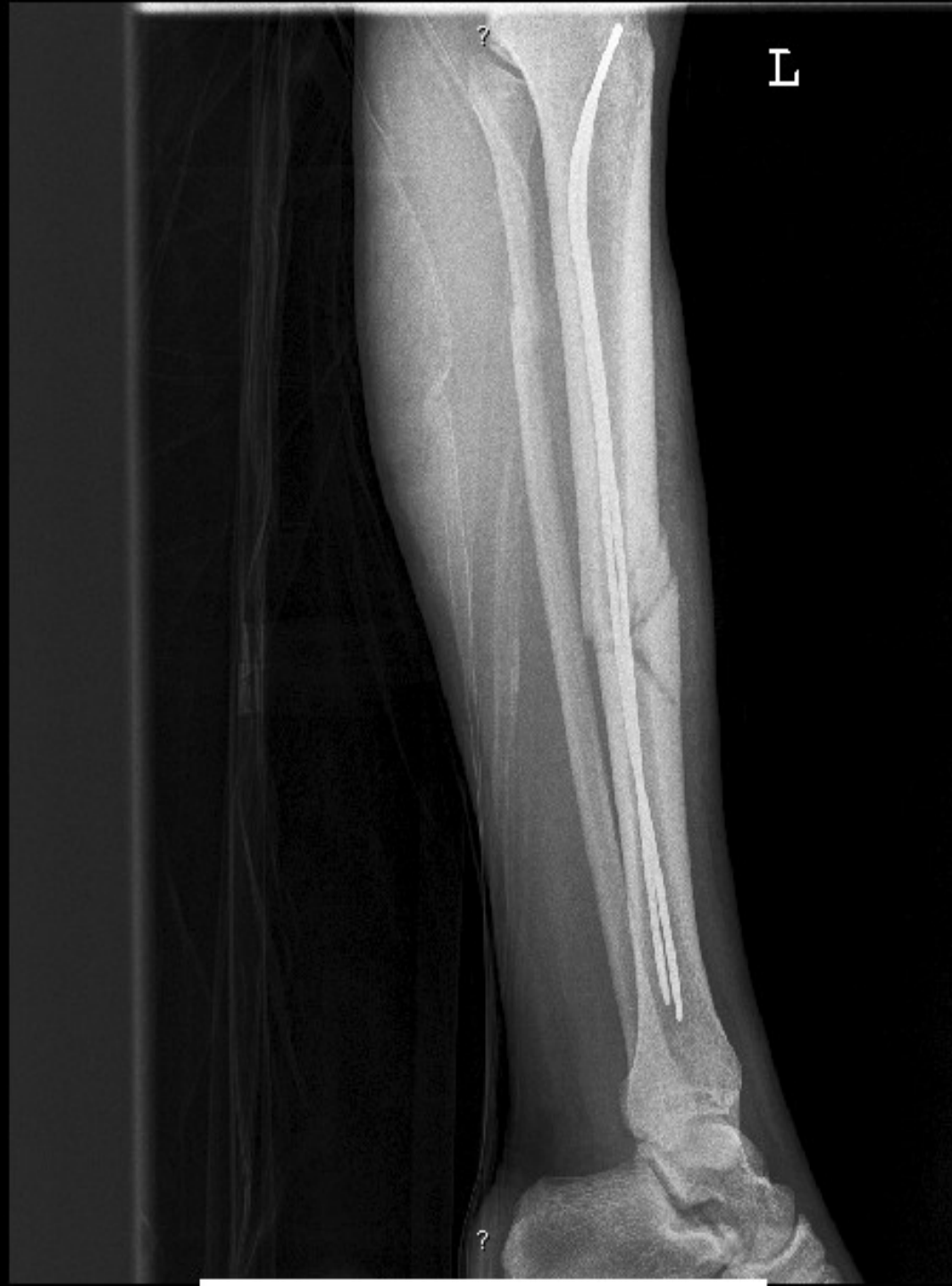C: 2583  
W: 2635

ID:078500  
Kvas Michal  
Narozen:1989-03-24  
Datum:2005-01-04  
Cas:08:51:47  
No.1

Q: 80%




FN Brno -Detska nemocnice  
ADC\_5146

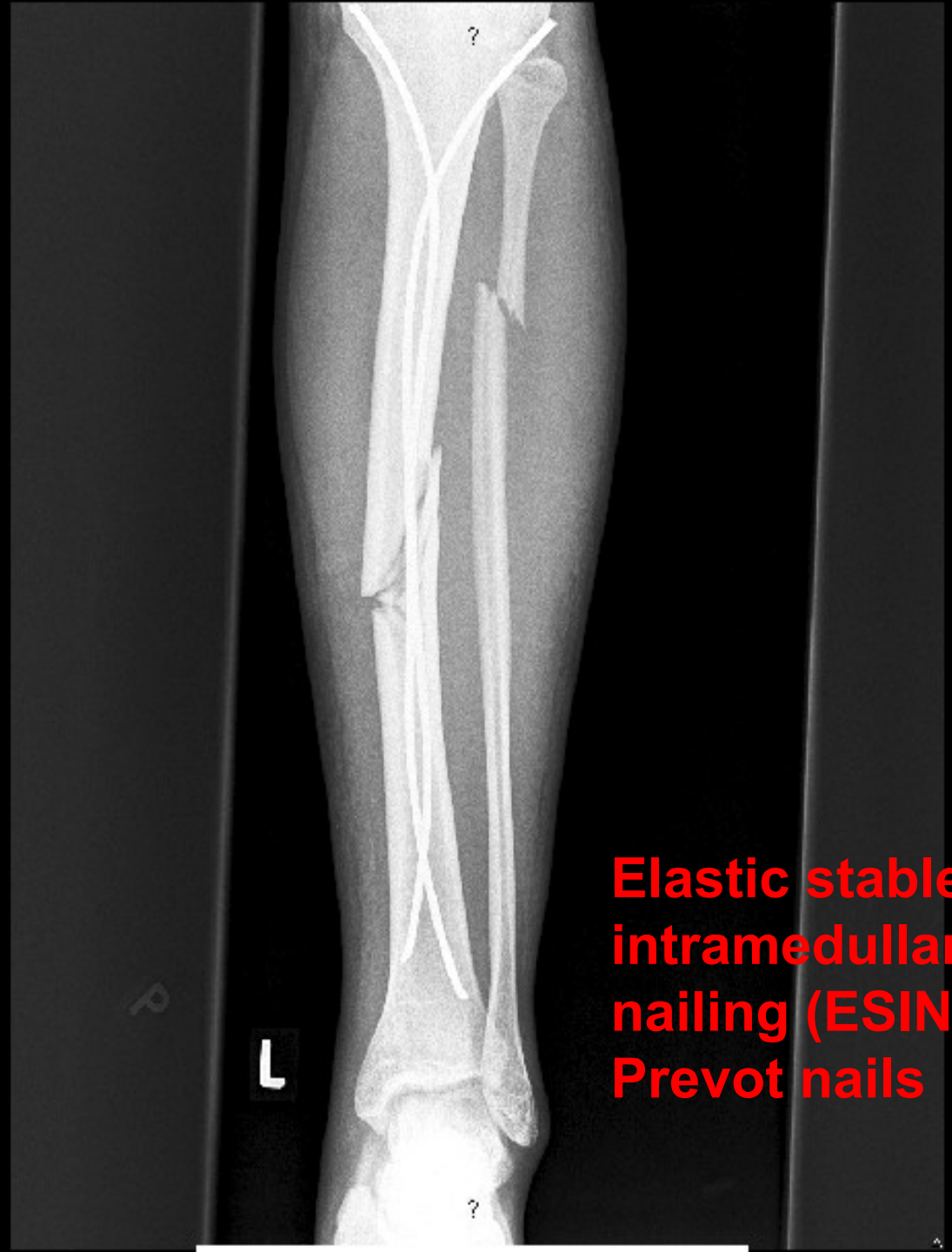

C: 2660  
W: 2061

ID:078500  
Kvas Michal  
Narozen:1989-03-24  
Datum:2005-01-04  
Cas:08:52:11  
No.1

Q: 80% 

FN Brno -Detska nemocnice  
ADC\_5146




**Elastic stable  
intramedullary  
nailing (ESIN)  
PrevoT nails**

C: 2745  
W: 1684

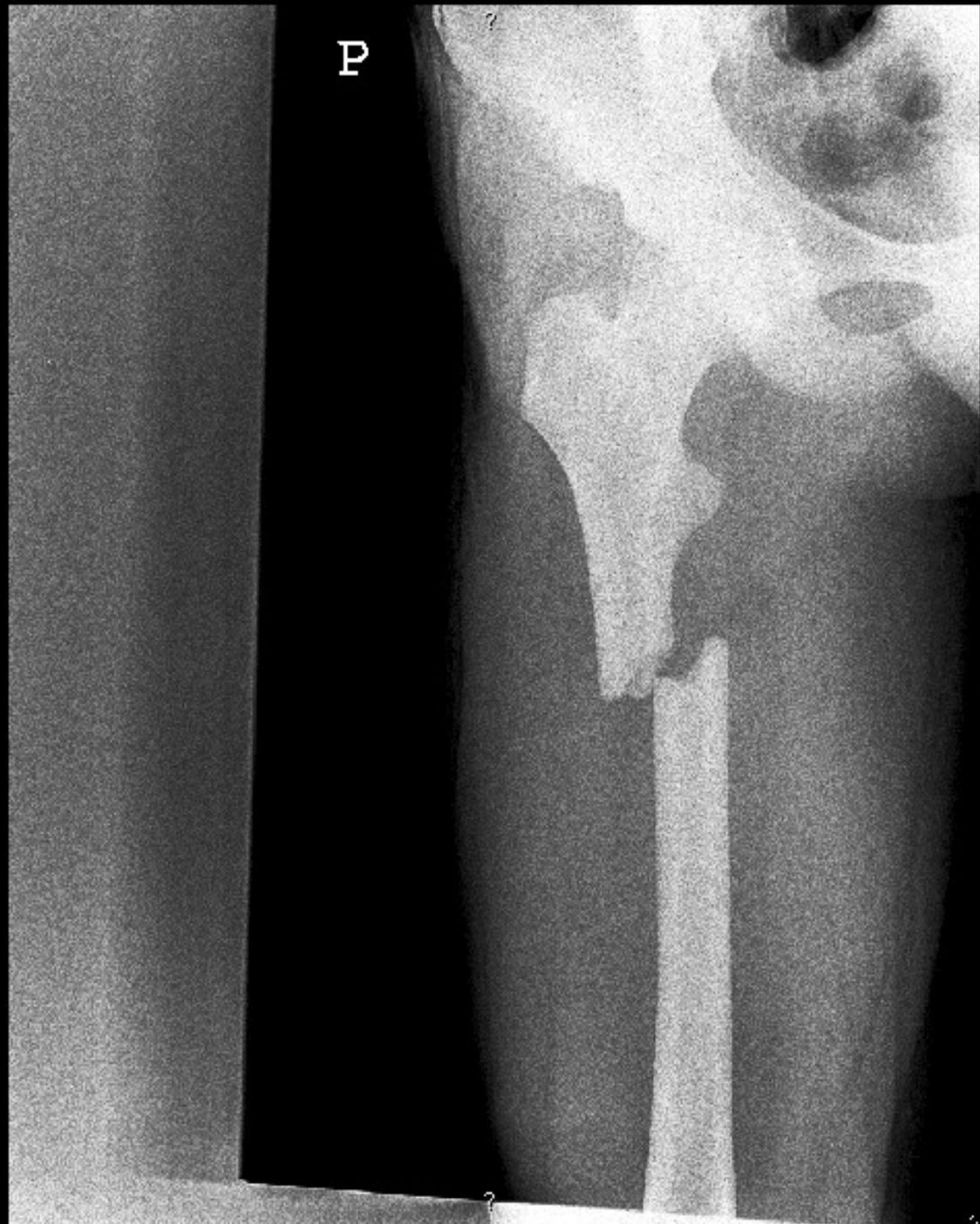ID:880310/4464  
Lechner Jan  
Narozen:1988-03-10  
Datum:2005-09-12  
Cas:08:48:22  
No.1

P

Q: 80% 

FN Brno -Detska nemocnice  
ADC\_5146

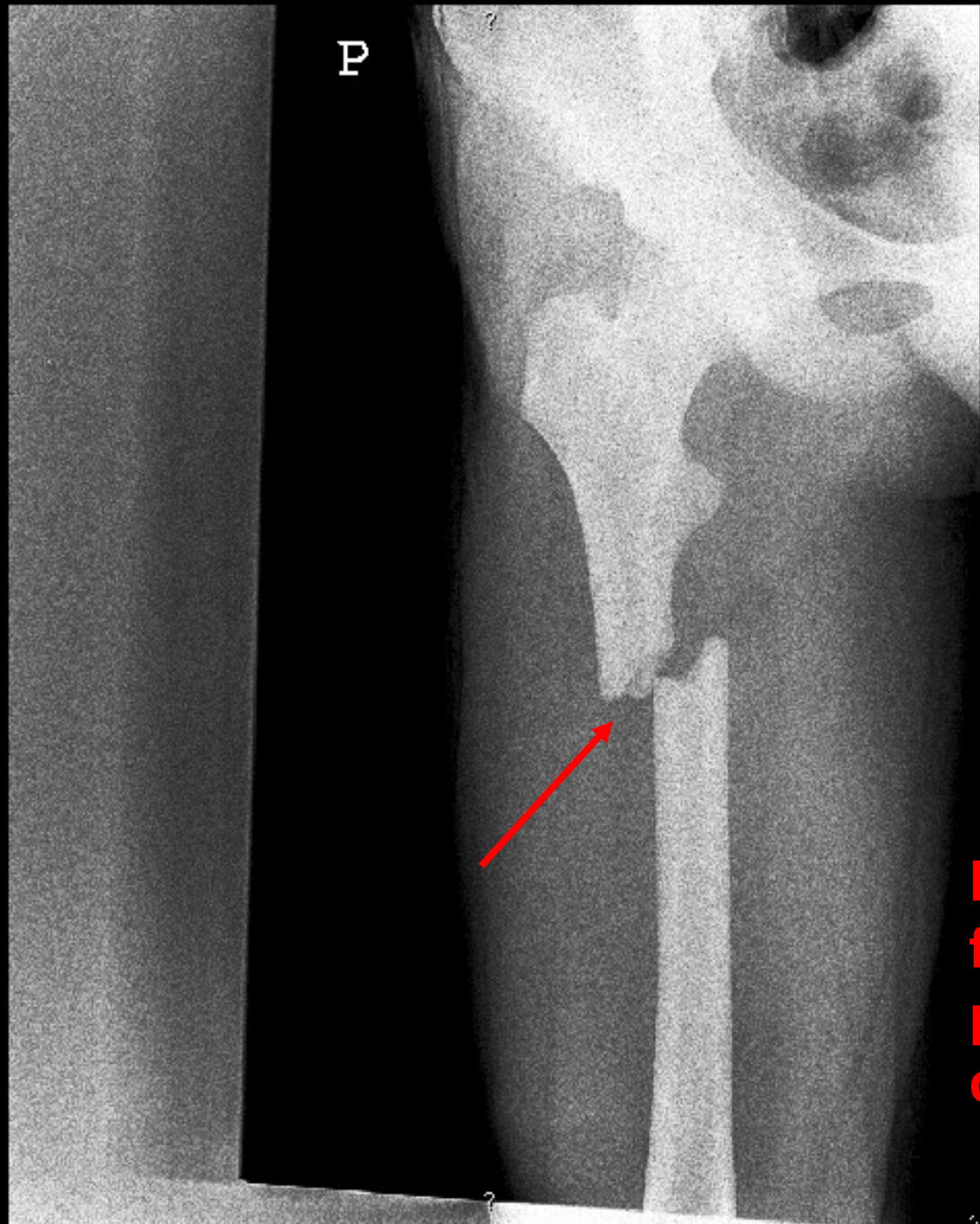
2



C: 1952  
W: 1206

P

2



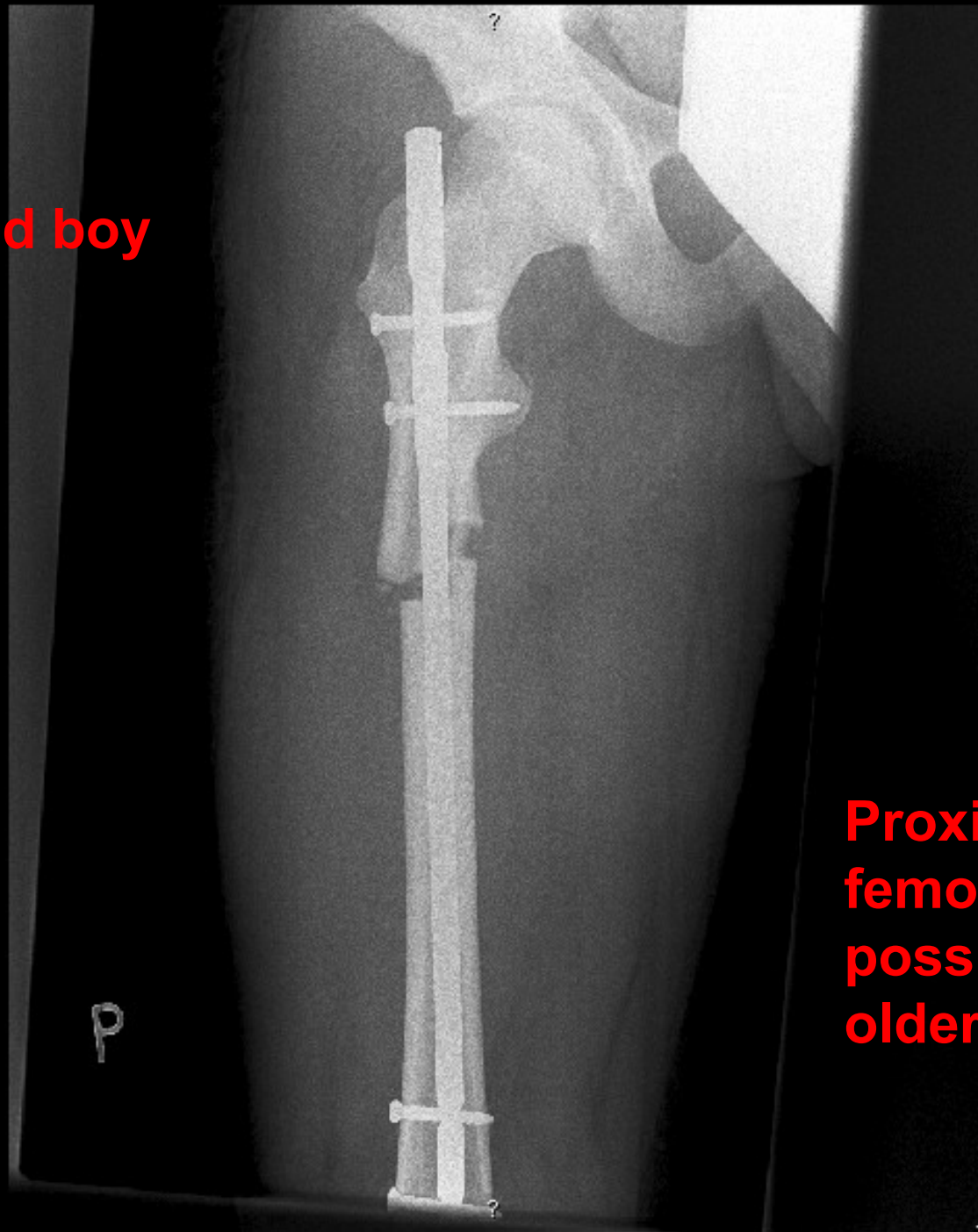
**Femoral  
fracture –  
proximal  
diaphysis**

ID:880310/4464  
Lechner Jan  
Narozen:1988-03-10  
Datum:2005-09-14  
Cas:08:11:16  
No.1

Q: 80% 

FN Brno -Detska nemocnice  
ADC\_5146

**17 years old boy**



**Proximal  
femoral nail –  
possible by  
older children**

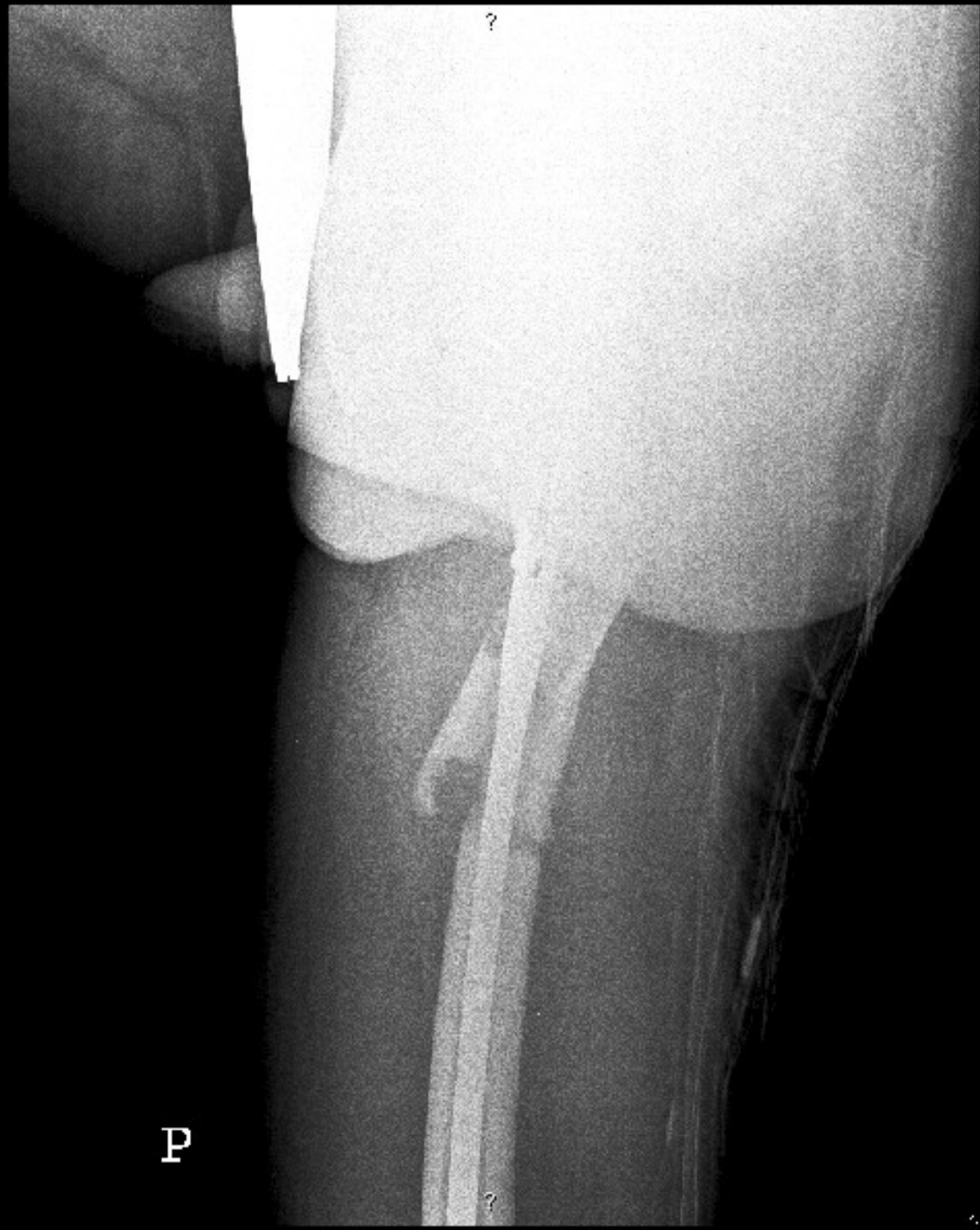C: 2450  
W: 1830



ID:880310/4464  
Lechner Jan  
Narozen:1988-03-10  
Datum:2005-09-14  
Cas:08:15:30  
No.1

Q: 80% 


FN Brno -Detska nemocnice  
ADC\_5146



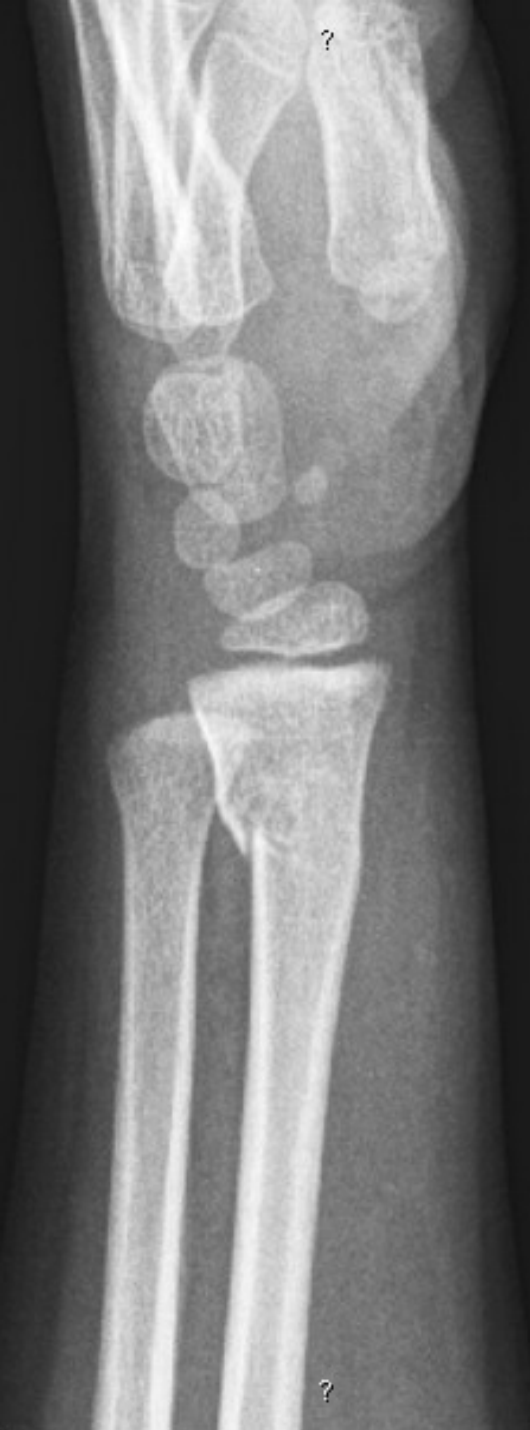P

C: 2375  
W: 1252

ID:007939  
Tenora Karel  
Narozen:1998-04-17  
Datum:2005-05-14  
Cas:17:25:20  
No.1


Co: 80%   
FN Brno -Detska nemocnice  
ADC\_5146

3



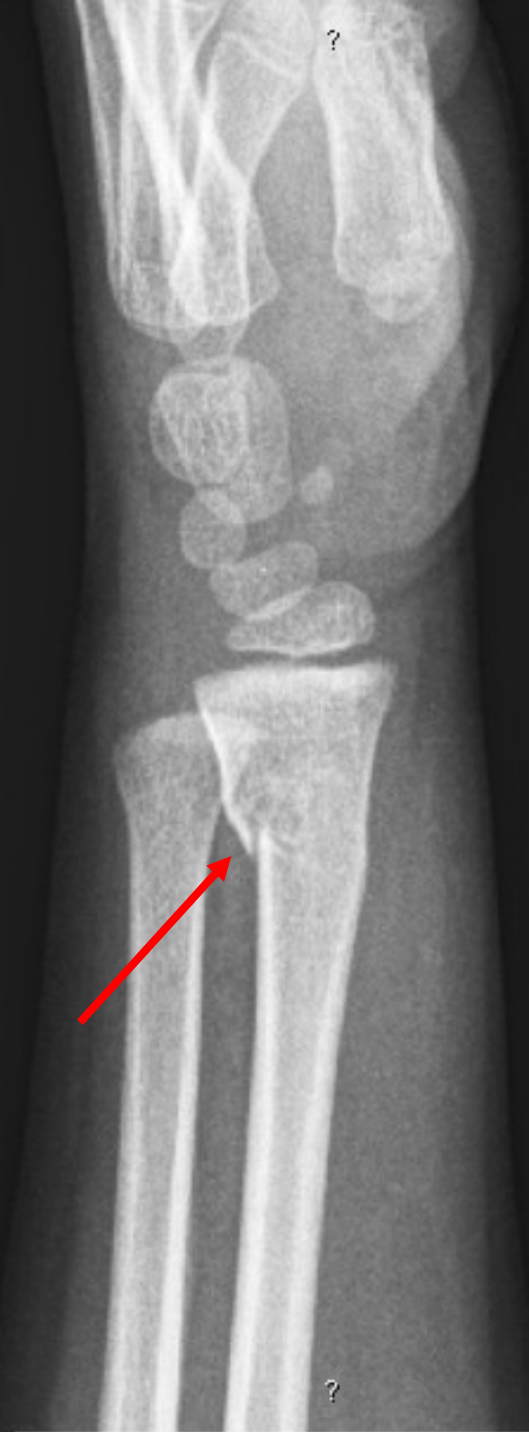C: 3572  
W: 1198

ID:007939  
Tenora Karel  
Narozen:1998-04-17  
Datum:2005-05-14  
Cas:17:25:20  
No.1

Co: 80% 


FN Brno -Detska nemocnice  
ADC\_5146

3



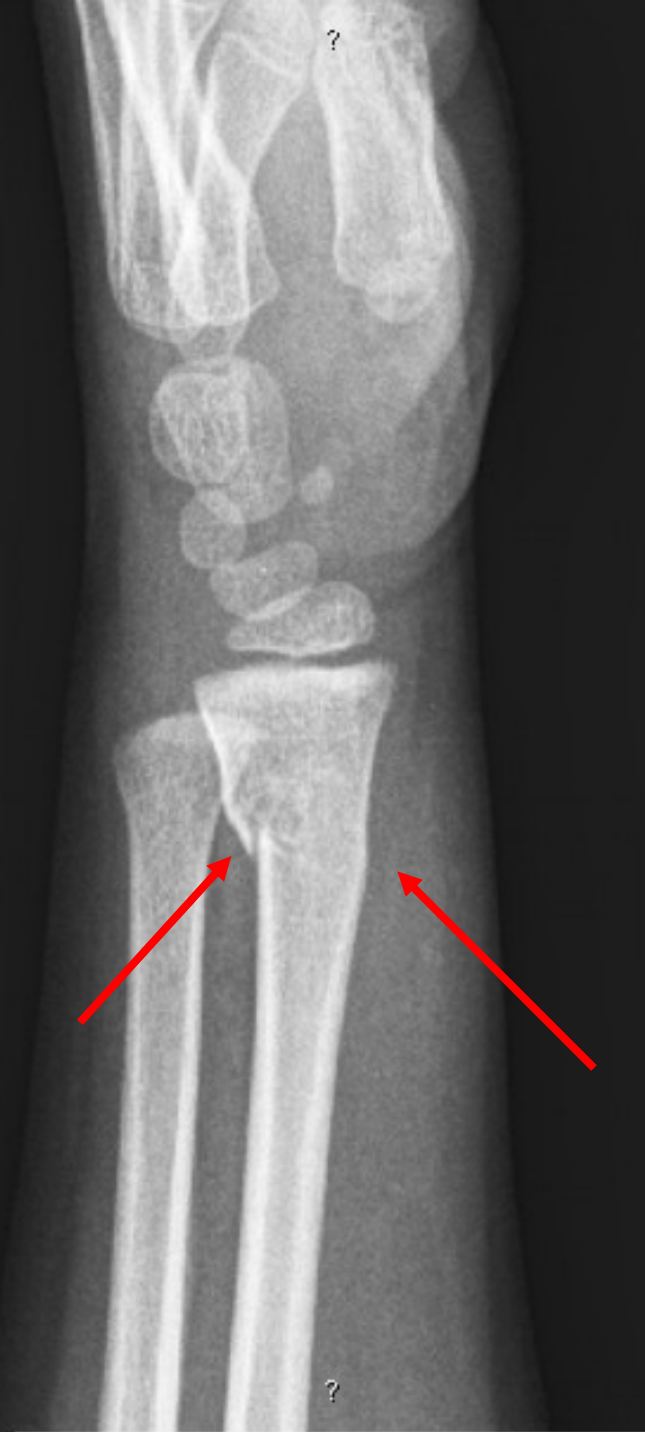C: 3572  
W: 1198

ID:007939  
Tenora Karel  
Narozen:1998-04-17  
Datum:2005-05-14  
Cas:17:25:20  
No.1

Co: 80% 

FN Brno -Detska nemocnice  
ADC\_5146

**Green stick  
fracture**



ID: 920504/4222  
Vodicka Jiri  
Narozen: 1992-05-04  
Datum: 2005-09-02  
Cas: 19:01:11  
No.1

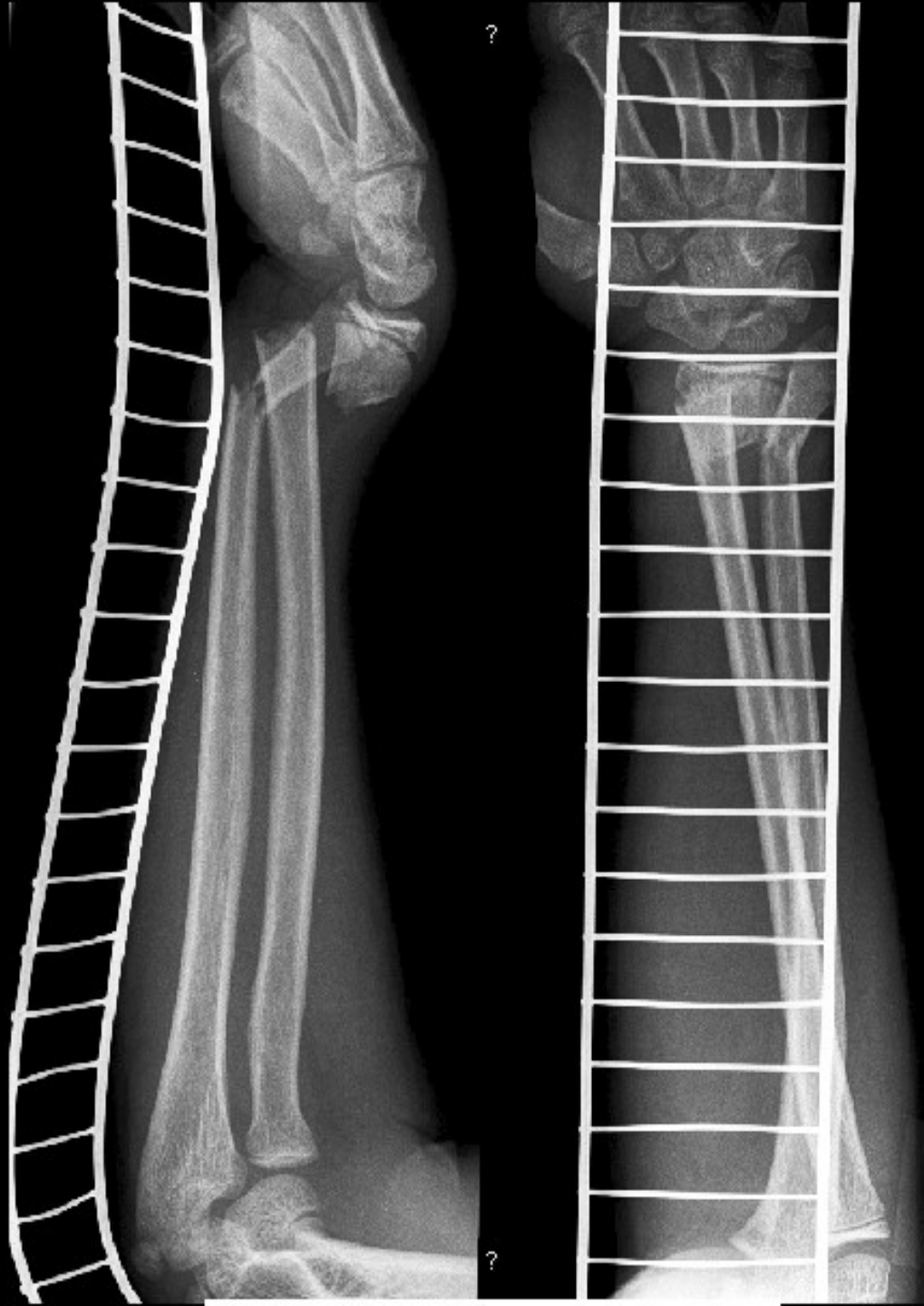

Q: 80%



FN Brno -Detska nemocnice  
ADC\_5146

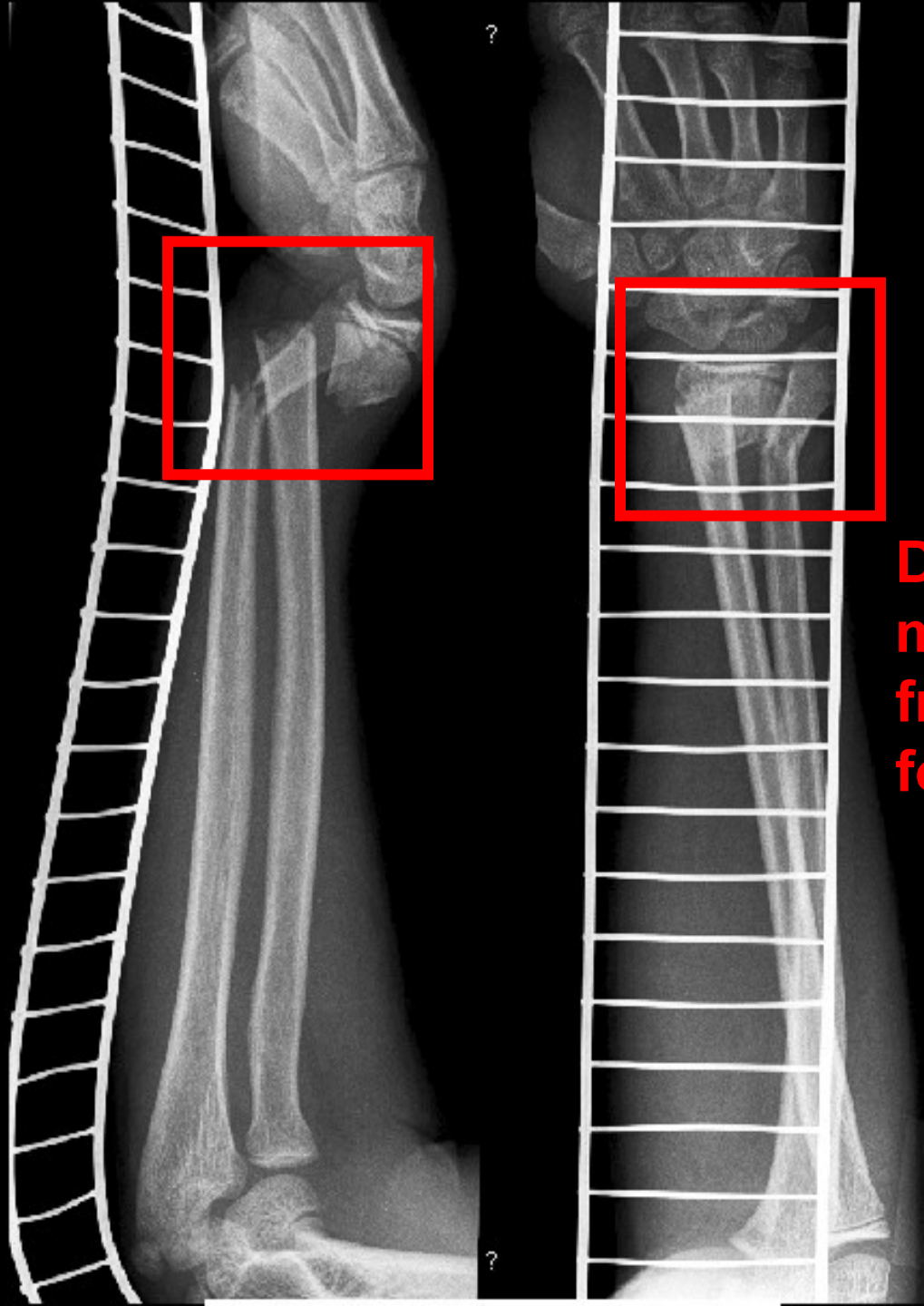
4



P

C: 3405  
W: 1047

4



**Distal metaphyseal fracture of forearm**

ID: 920504/4222  
Vodicka Jiri  
Narozen: 1992-05-04  
Datum: 2005-09-04  
Cas: 08:55:17  
No.1

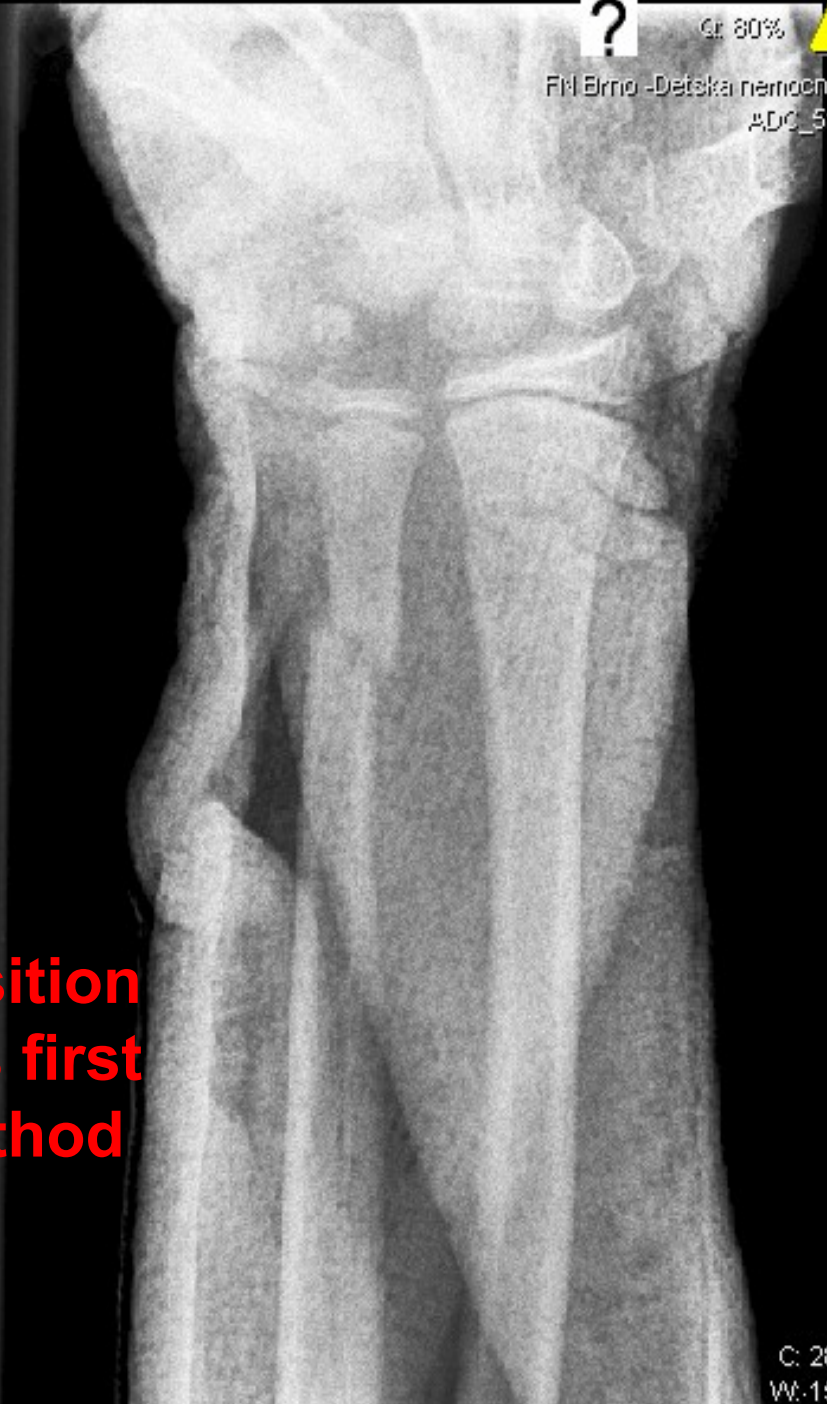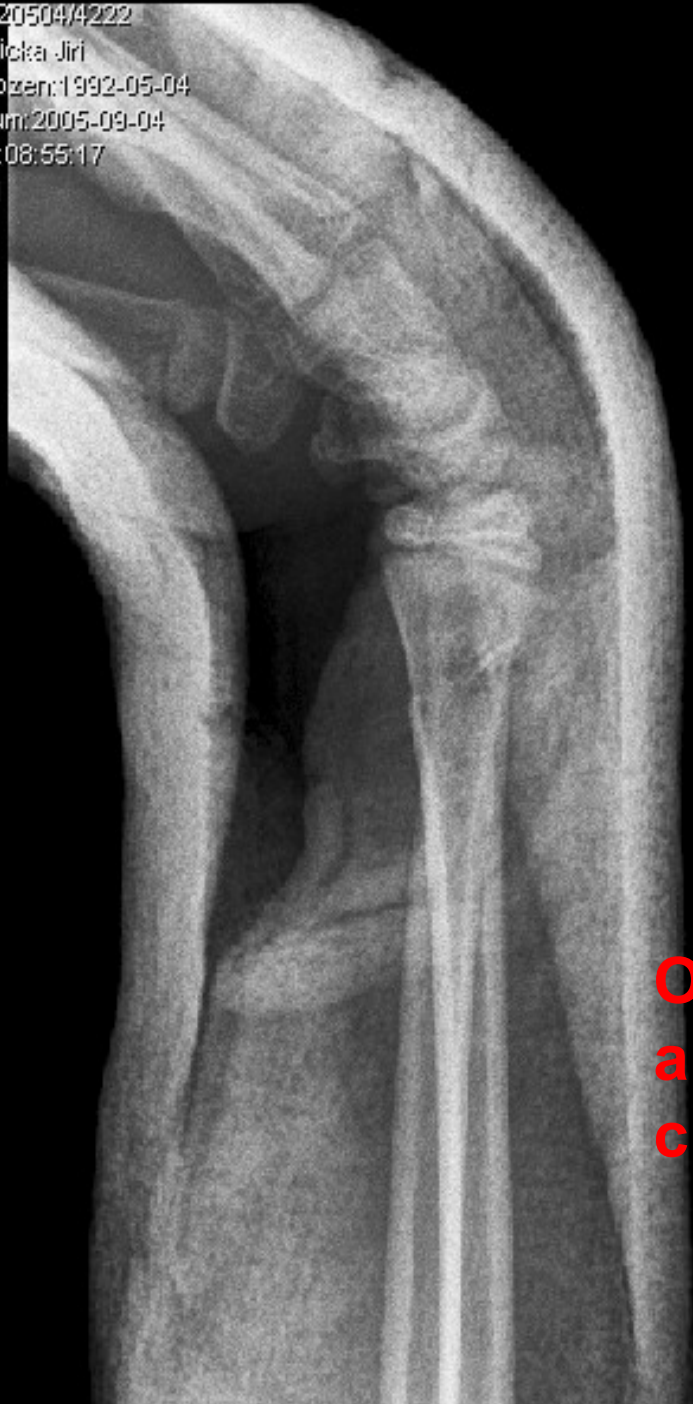P

?

Gr 80%



FN Brno - Detska nemocnice  
ADC\_5146

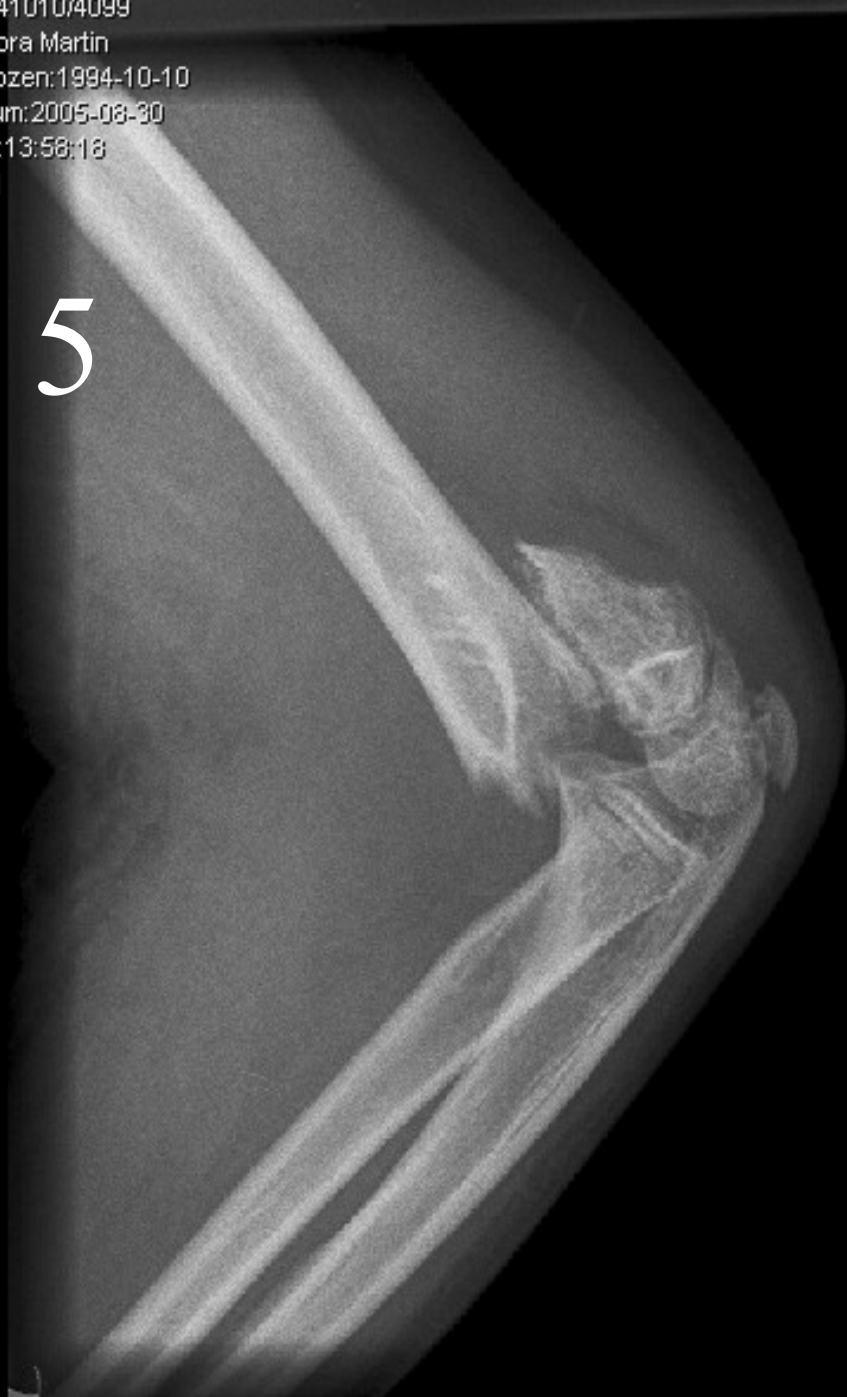


**Only reposition  
and část is first  
choice method**

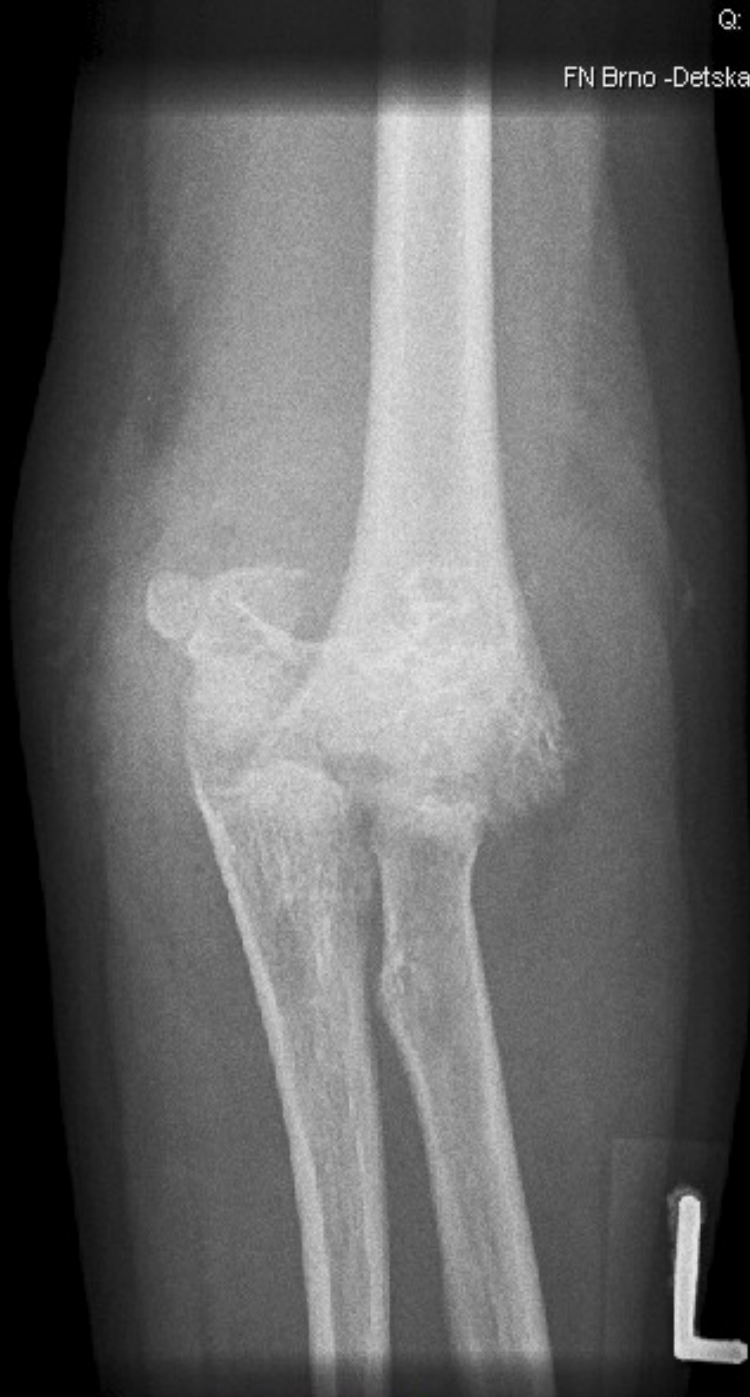C: 2800  
W: 1595

ID: 941010/4099  
Fasora Martin  
Narozen: 1994-10-10  
Datum: 2005-03-30  
Cas: 13:58:18  
No.1

5



Q: 80%   
FN Brno -Detska nemocnice  
ADC\_5146



L


C: 2887  
W: 1769




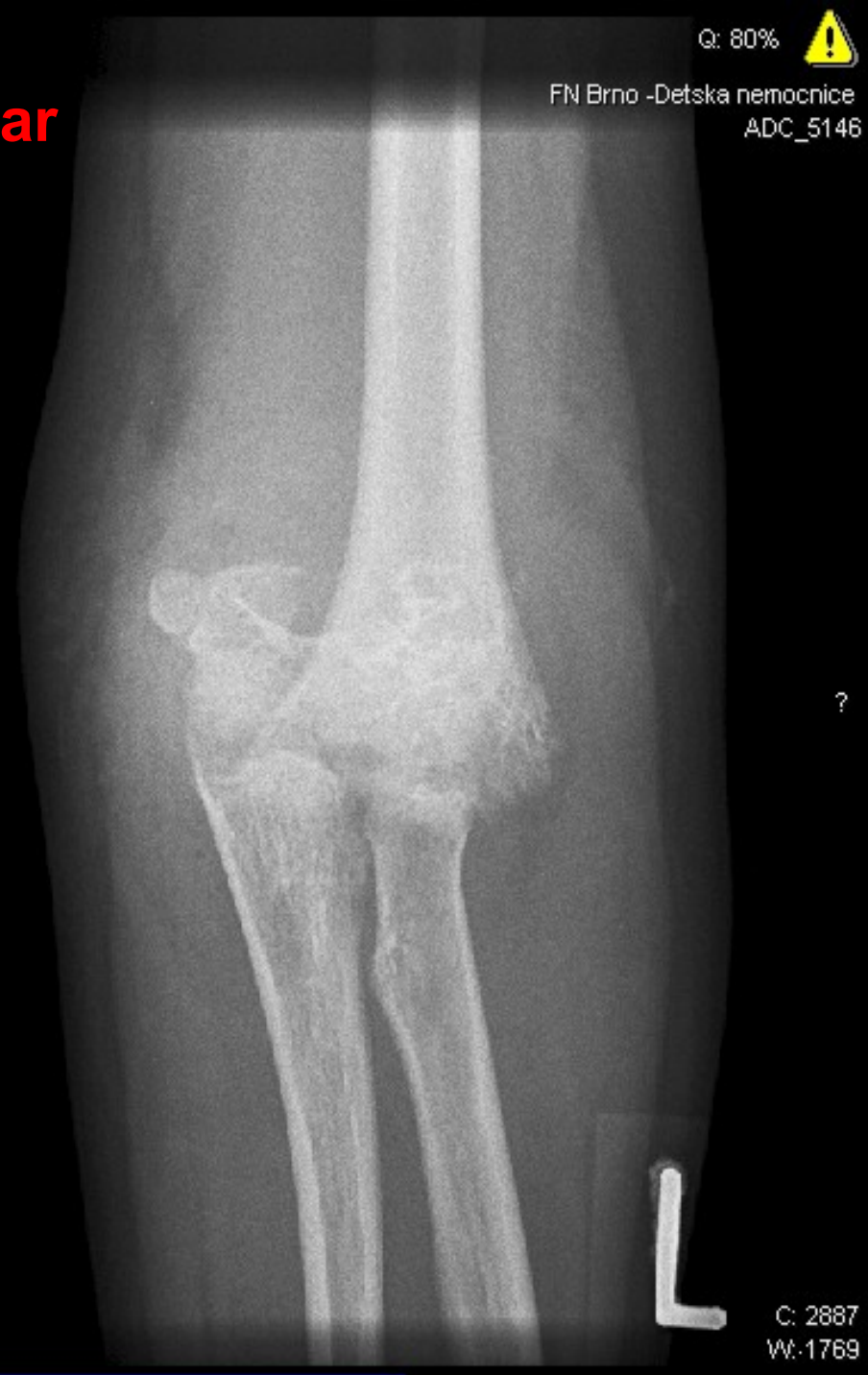ID:941010/4099  
Fasora Martin  
Narozen:1994-10-10  
Datum:2005-08-30  
Cas:13:58:18  
No.1

**Supracondylar  
fracture of  
humerus**

5



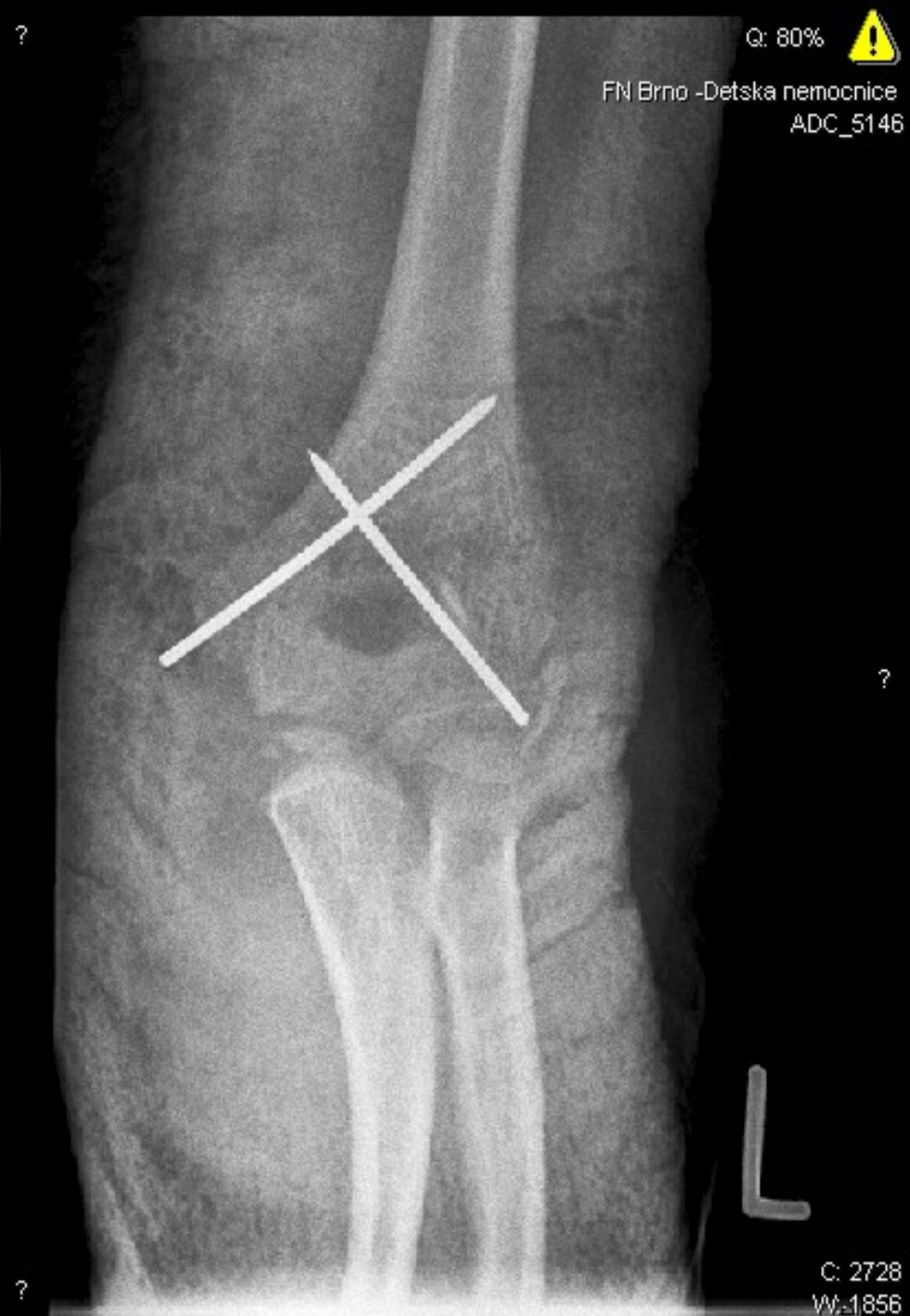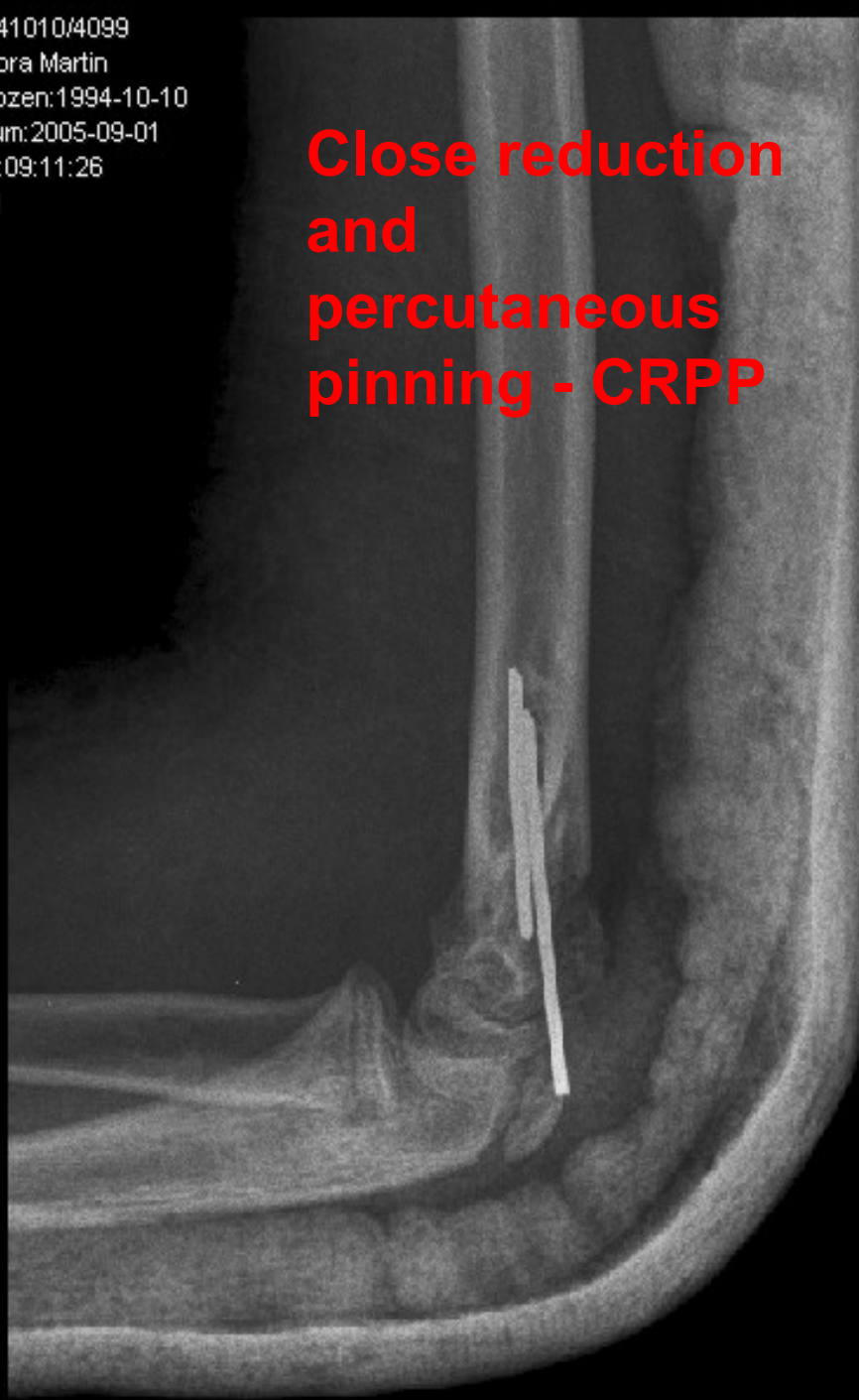Q: 80%   
FN Brno -Detska nemocnice  
ADC\_5146




C: 2887  
W: 1769

ID:941010/4099  
Fasora Martin  
Narozen:1994-10-10  
Datum:2005-09-01  
Cas:09:11:26  
No.1

**Close reduction  
and  
percutaneous  
pinning - CRPP**



Q: 80%   
FN Brno -Detska nemocnice  
ADC\_5146

C: 2728  
W:1856

ID:083849  
Zarychtova Simona  
Narozen:1999-12-23  
Datum:2005-03-07  
Cas:12:28:17  
No.1

6



?

Q: 80%

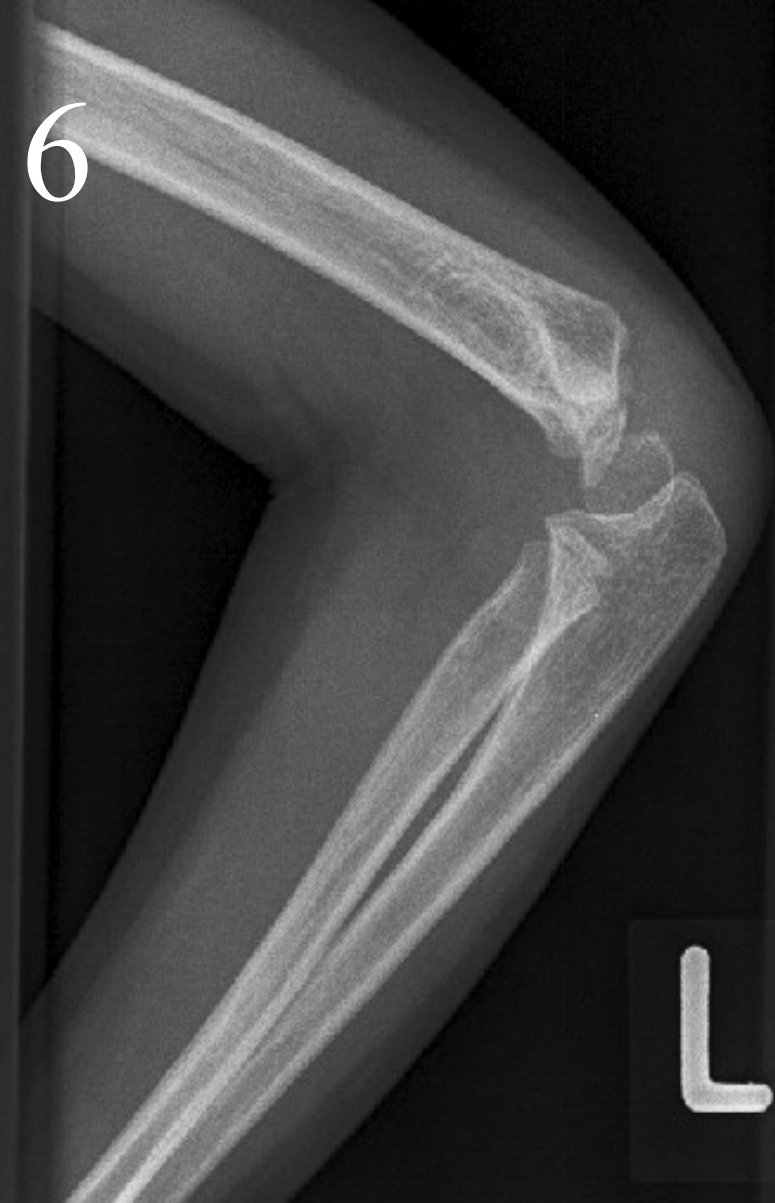

FH Brno -Detska nemocnice  
ADC\_51xx

C: 2780  
W: 1895

ID:083849  
Zarychtova Simona  
Narozen:1999-12-23  
Datum:2005-03-07  
Cas:12:28:17  
No.1

6

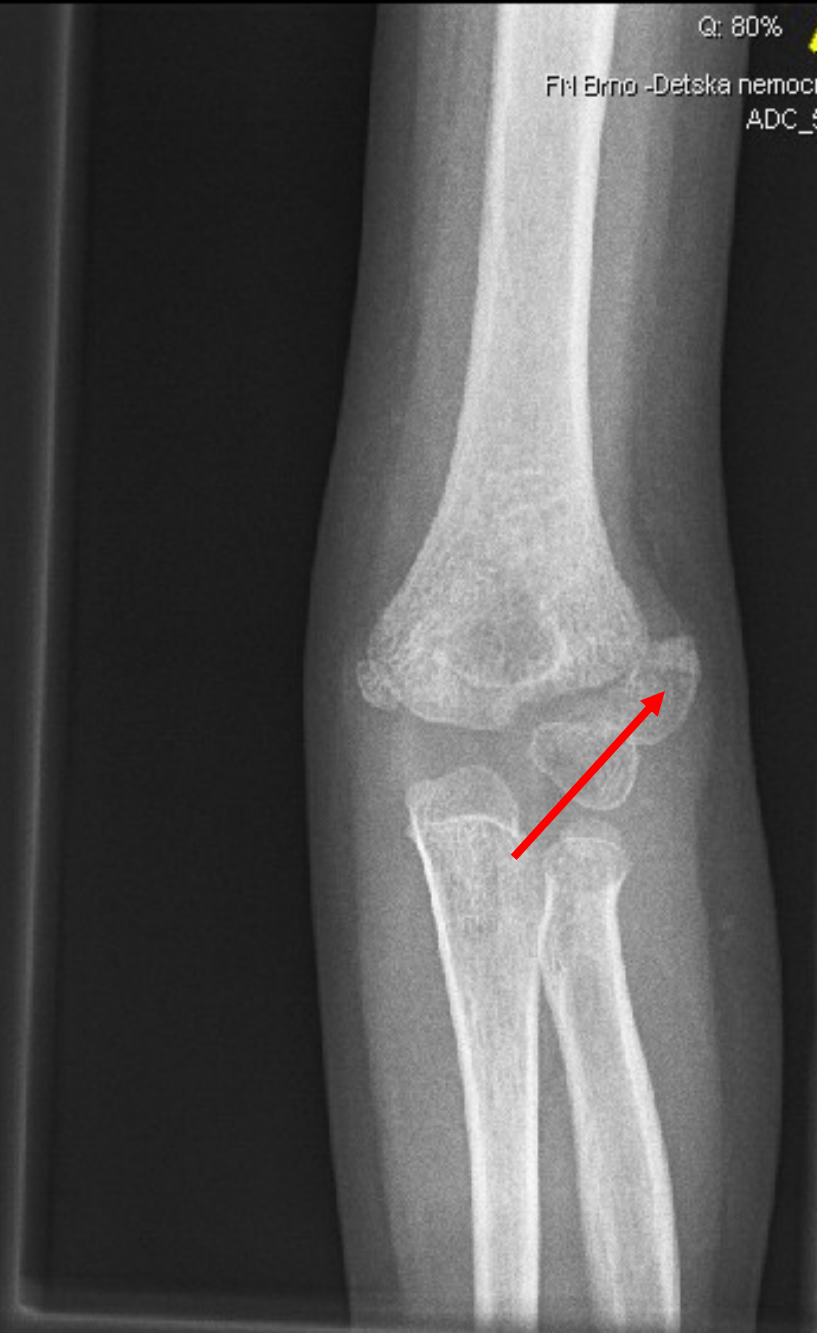

?

Q: 80%



FH Brno -Detska nemocnice  
ADC\_51xx



C: 2780  
W: 1895

?


Zarychtova Simona  
ID:083849  
DoB:1999-12-23  
2005-03-23  
09:25:28  
No. 66  
2005-03-23

Q: 95%



Fak. detska nemocnice  
SOMATOM PLUS 4

spin -18  
tilt +2



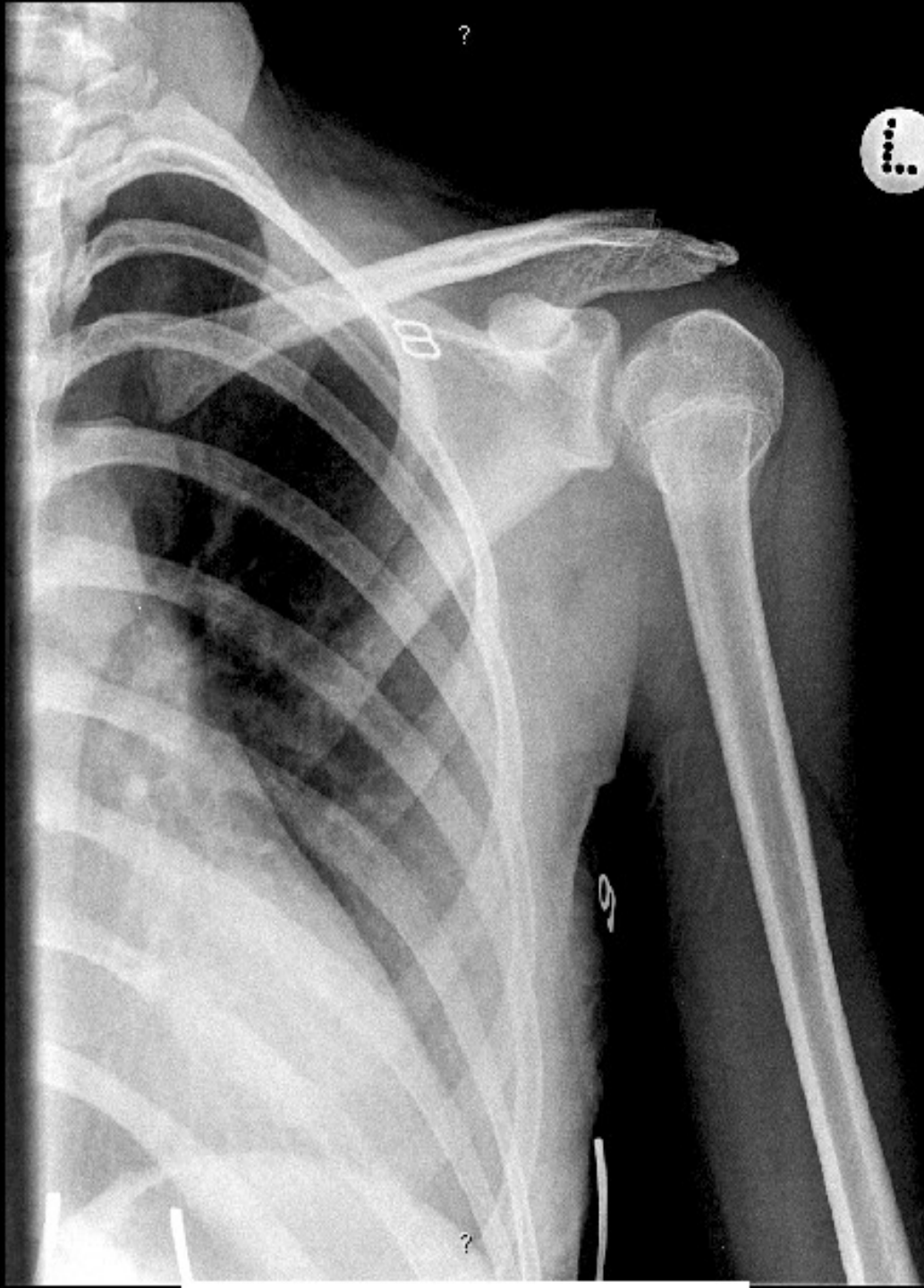**Radial condyle  
fracture of  
humerus**



C: 1100  
W: 3000

ID:094973  
Zemanova Veronika  
Narozen:1990-09-24  
Datum:2005-07-20  
Cas:21:56:01  
No.1

7



Q: 80%



FN Brno -Detska nemocnice  
ADC\_5146



C: 2890  
W: 1088

ID:094973  
Zemanova Veronika  
Narozen:1990-09-24  
Datum:2005-07-20  
Cas:21:56:01  
No.1

?



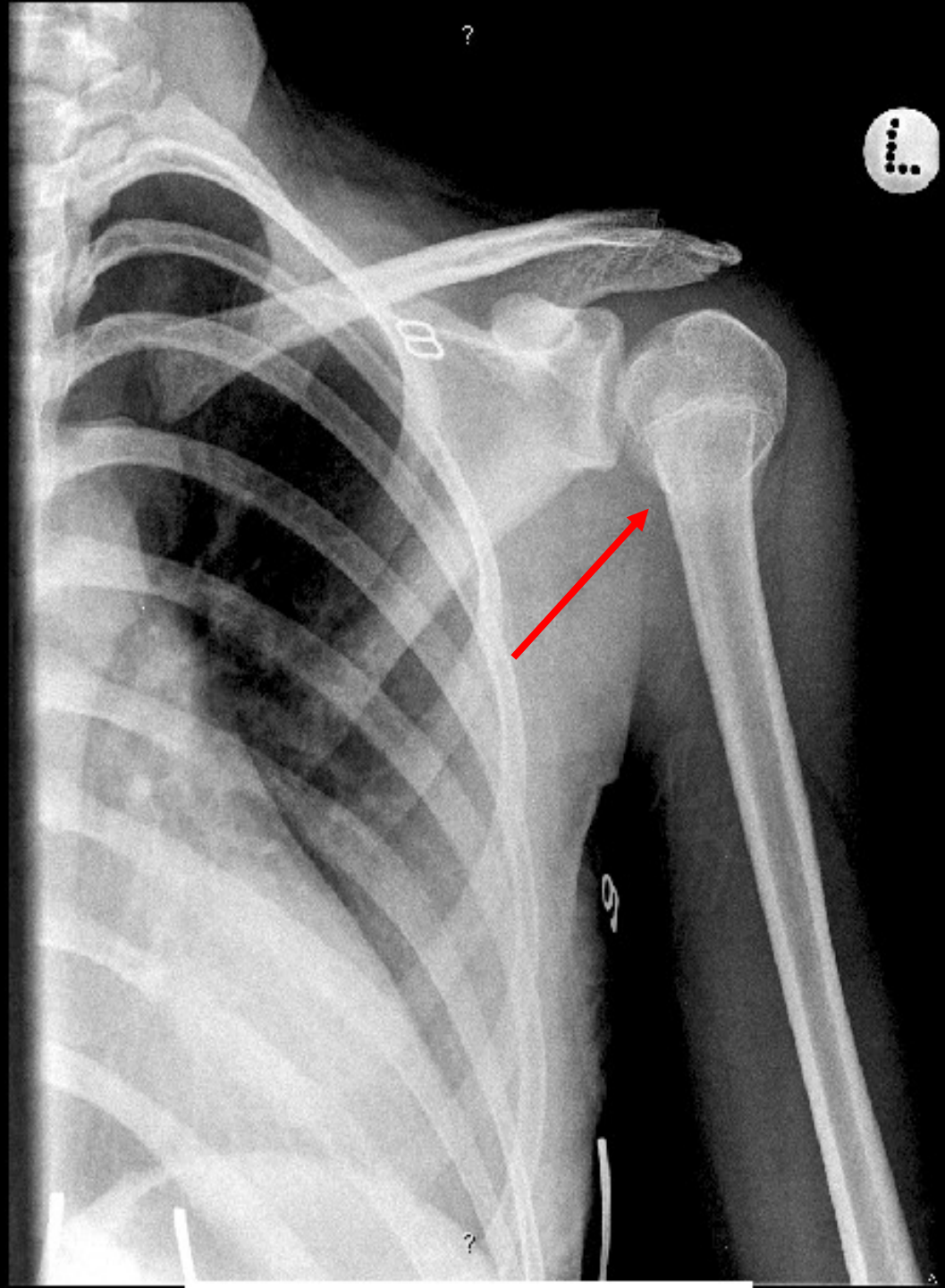
Q: 80%



FN Brno -Detska nemocnice  
ADC\_5146



7



C: 2890  
W: 1088

ID:094973

Zemanova Veronika

Narozen:1990-09-24

Datum:2005-07-20

Cas:22:09:59

No.1



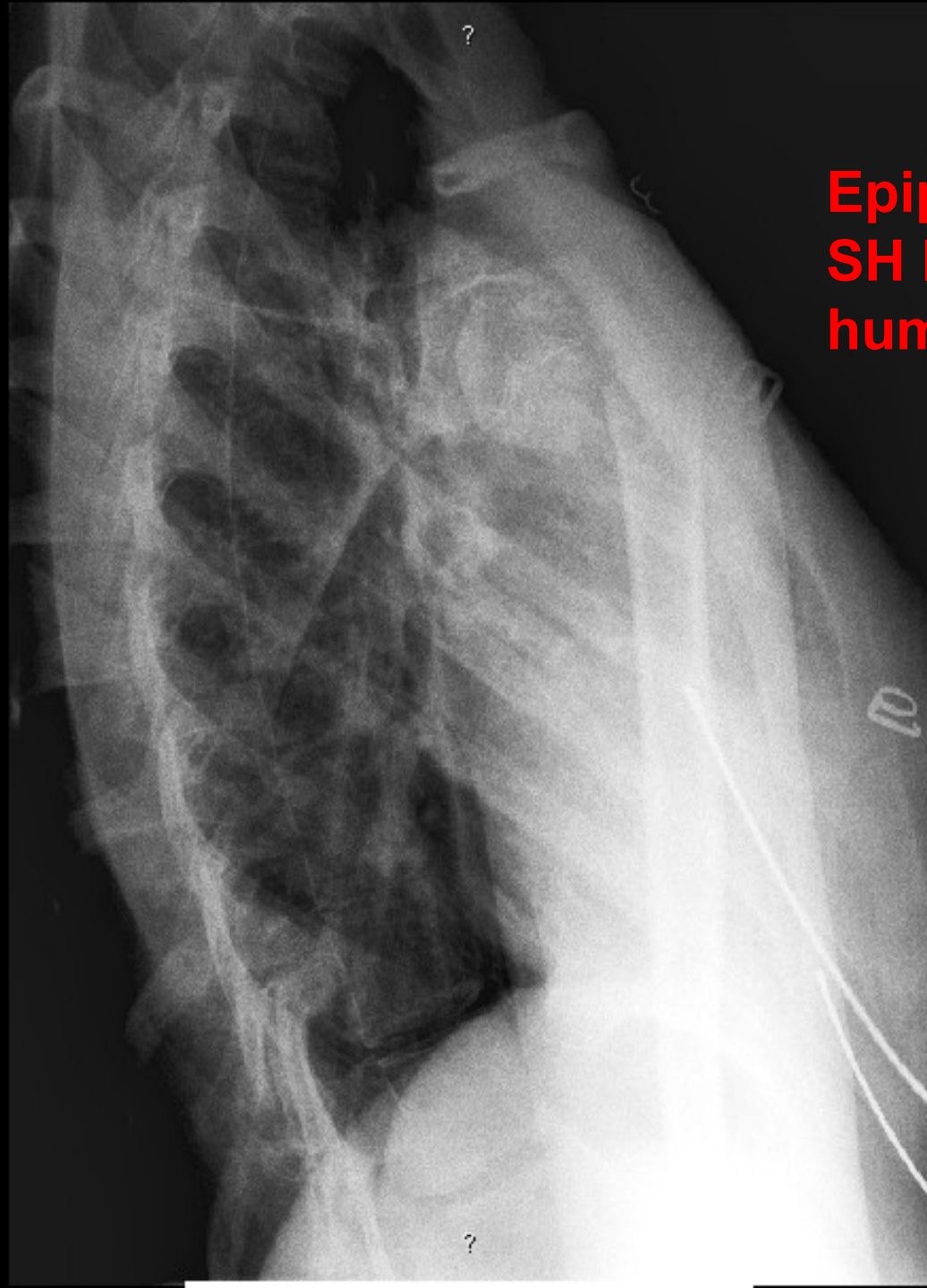
Q: 80%



FN Brno -Detska nemocnice

ADC\_5146

**Epiphyseolysis  
SH II of proximal  
humerus**

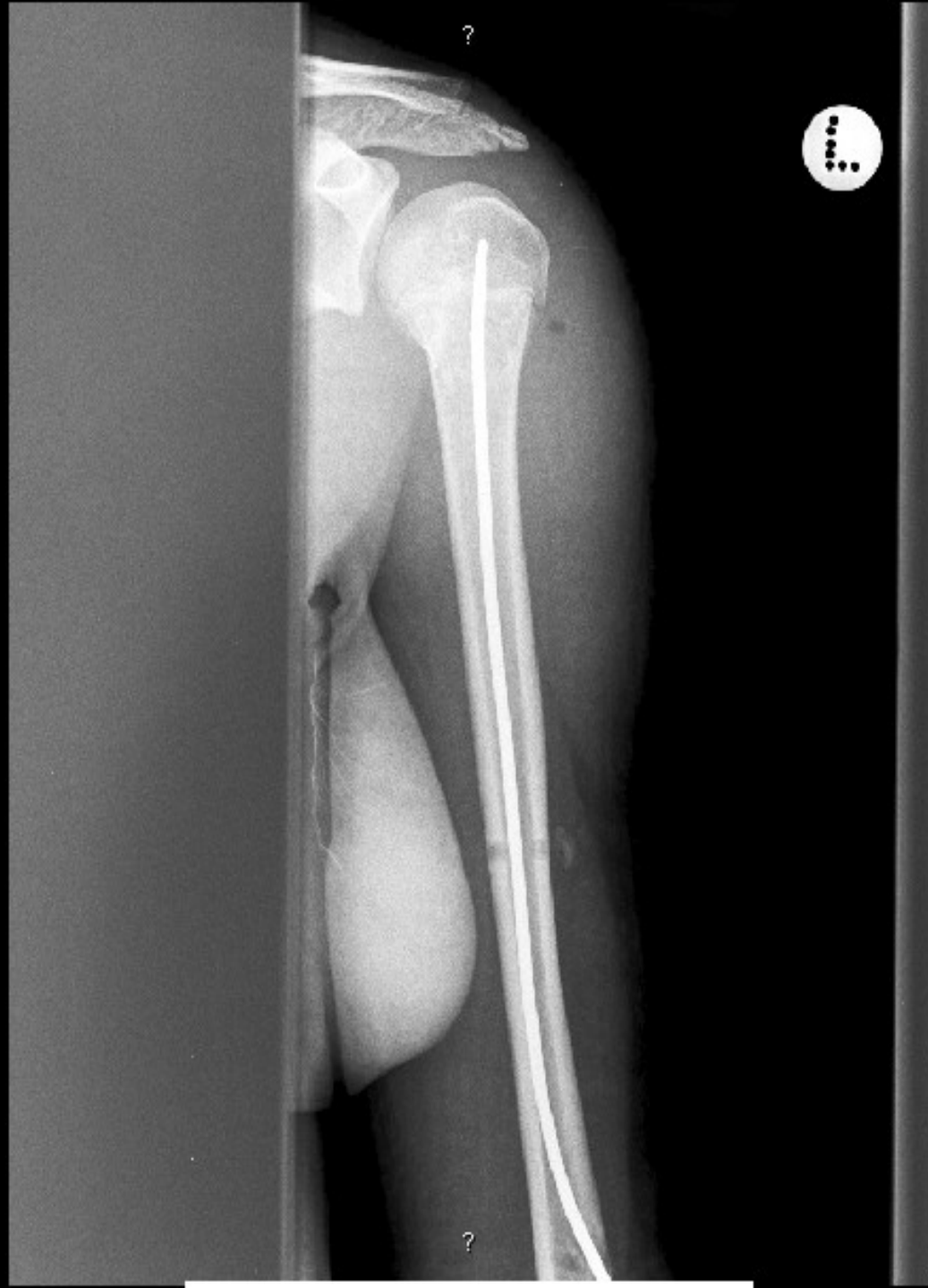

C: 3723

W: 807



ID:094973  
Zemanova Veronika  
Narozen:1990-09-24  
Datum:2005-07-27  
Cas:08:22:13  
No.1



Q: 80%

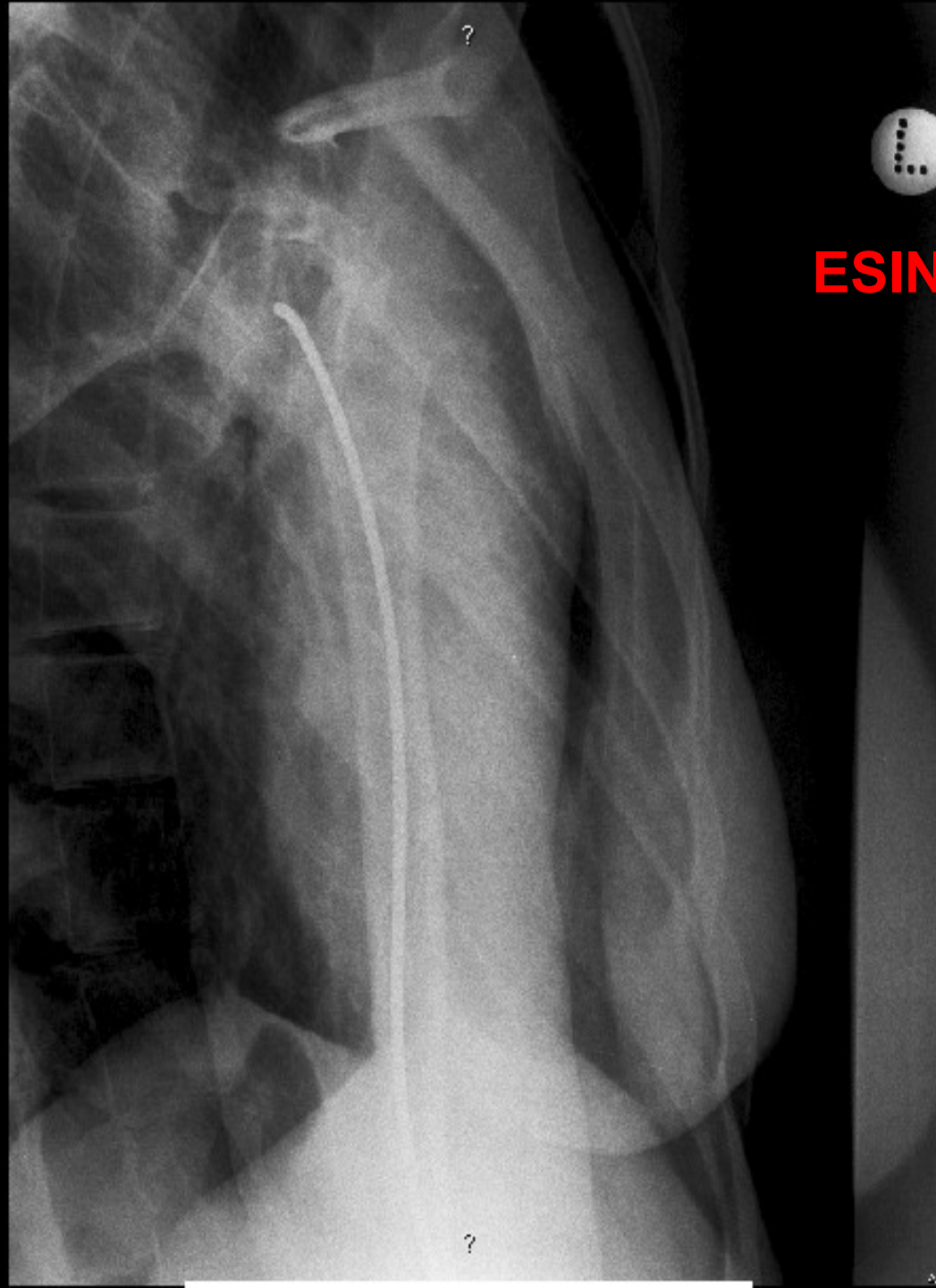


FN Brno -Detska nemocnice  
ADC\_5146



C: 3241  
W: 1475

ID:094973  
Zemanova Veronika  
Narozen:1990-09-24  
Datum:2005-07-27  
Cas:08:23:15  
No.1



Q: 80%



FN Brno -Detska nemocnice  
ADC\_5146



**ESIN**

C: 3138  
W: 1529

Thaisz Merlin  
ID:082185  
DoB:2004-04-01  
2005-02-14  
23:41:45  
No.15

AH

Q: 90%

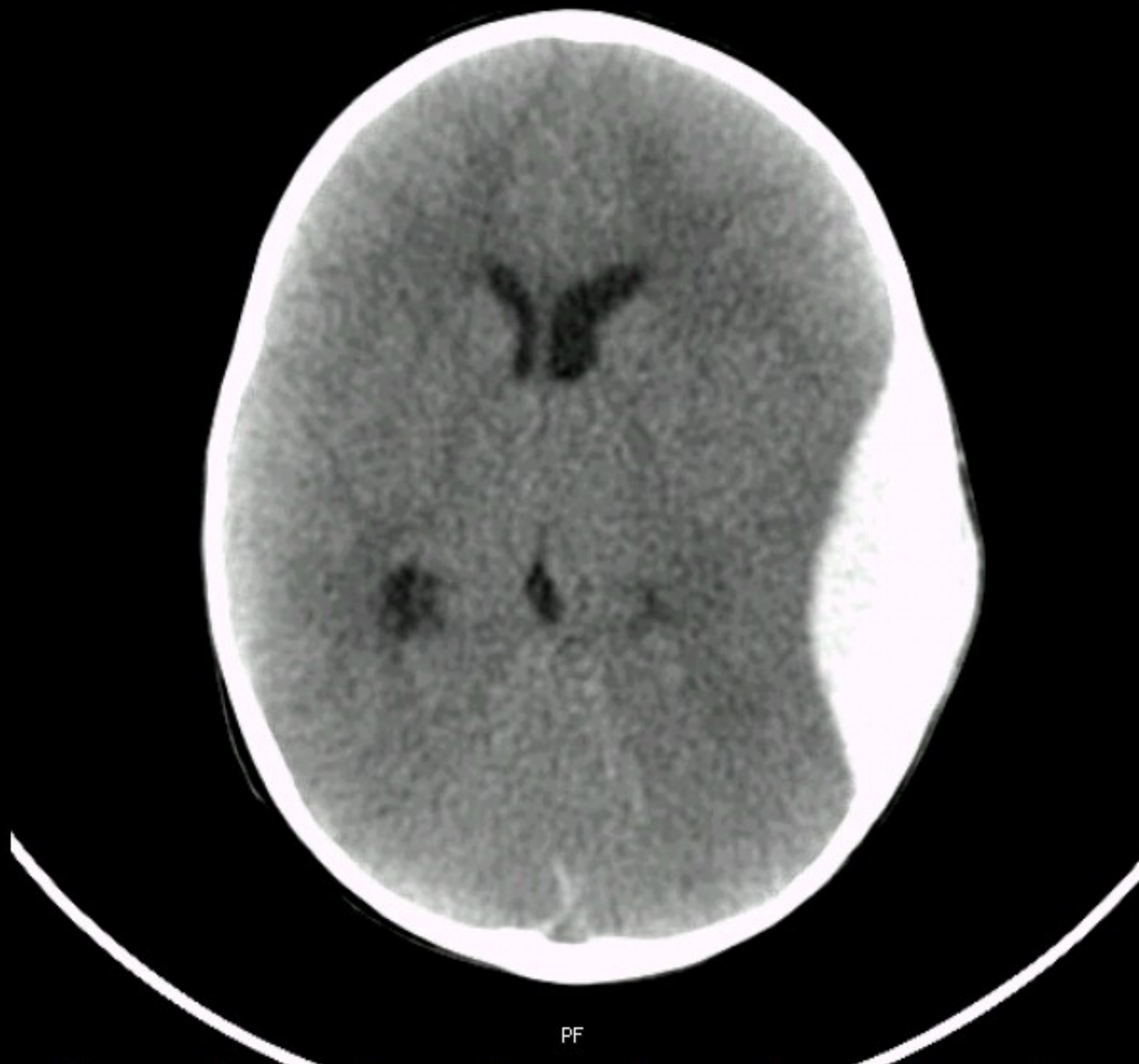

Fak. detska nemocnice  
SOMATOM PLUS 4

8

R

L



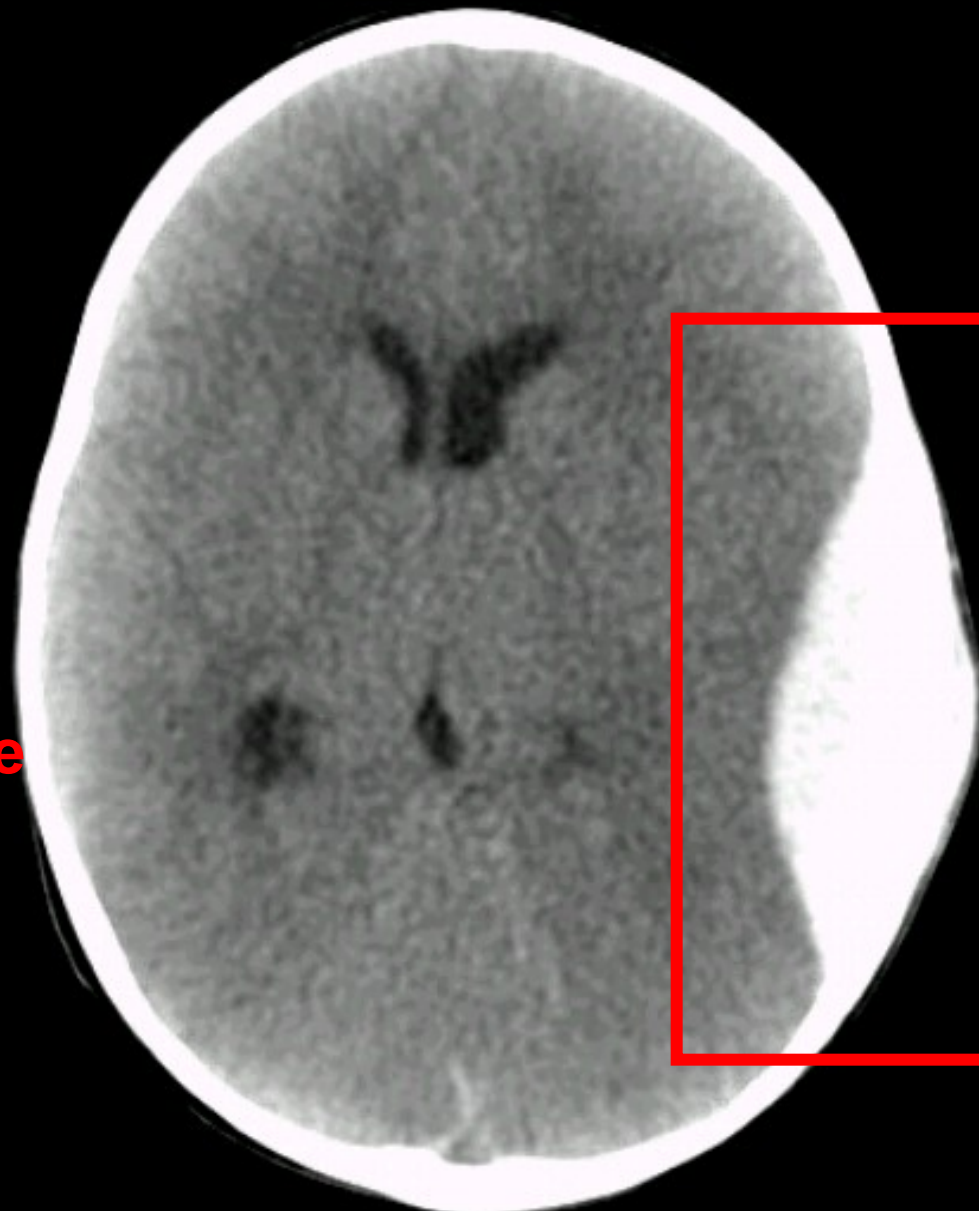RM  
GT:-2  
SP:350  
SL:5  
CM:

PF

C: 35  
W: 80

8

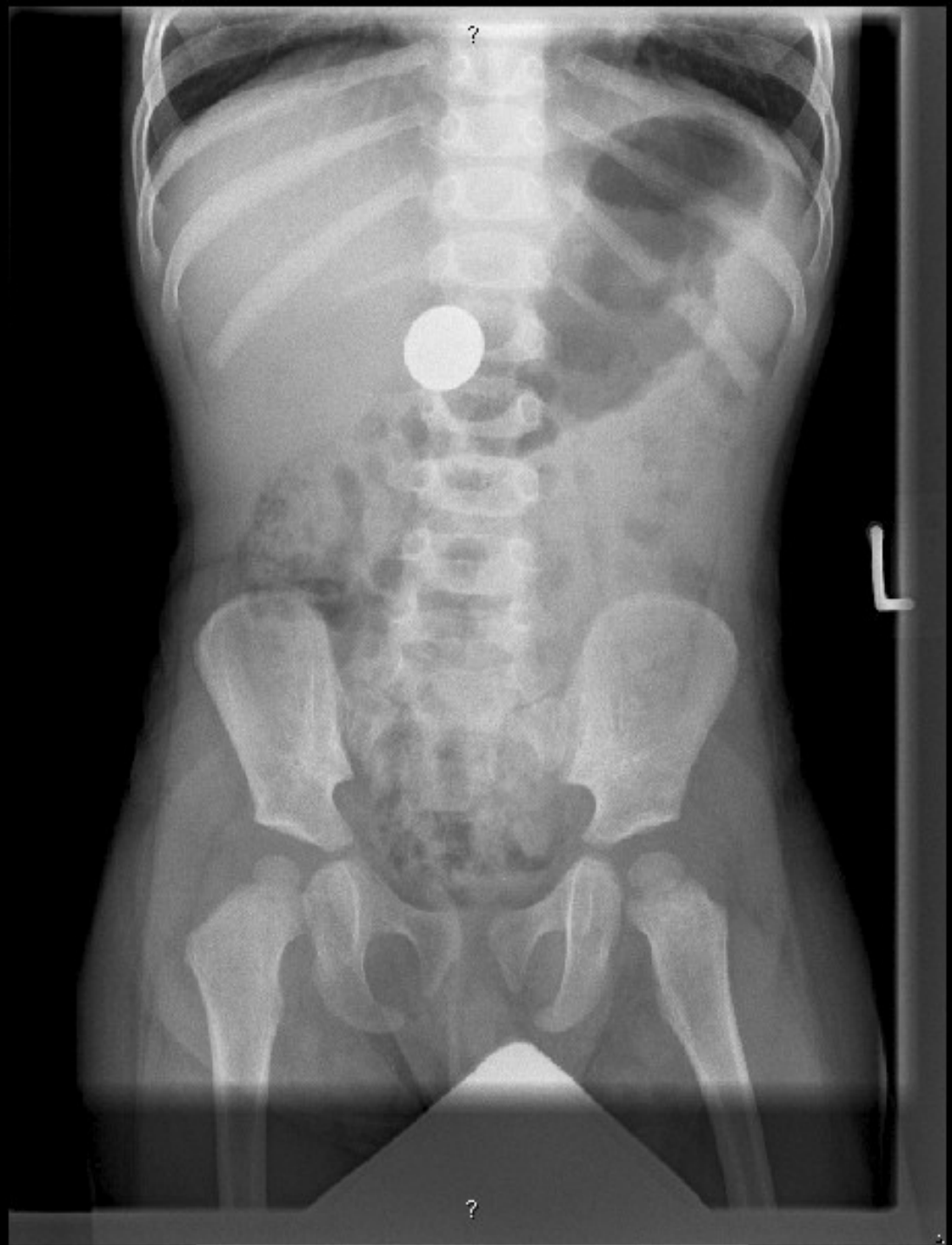
**Epidural  
hematoma  
typical  
lenticular shape**



ID:081582  
Huser Tomas  
Narozen:2003-06-03  
Datum:2005-02-11  
Cas:09:31:18  
No.1


Q: 80%   
FN Brno -Detska nemocnice  
ADC\_5146

9



C: 2968  
W: 1625

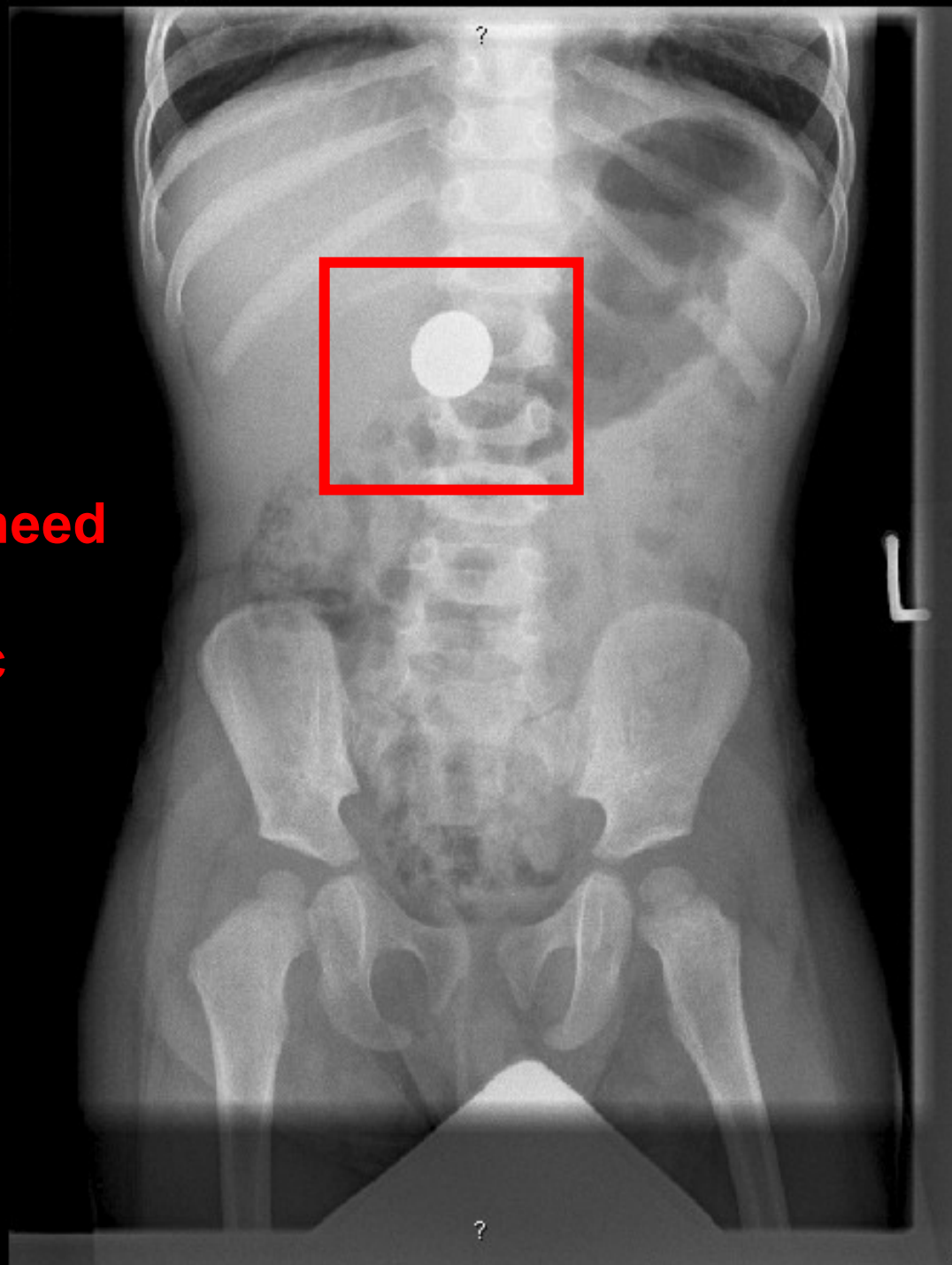
ID:081582  
Huser Tomas  
Narozen:2003-06-03  
Datum:2005-02-11  
Cas:09:31:18  
No.1

Q: 80% 

FN Brno -Detska nemocnice  
ADC\_5146

9

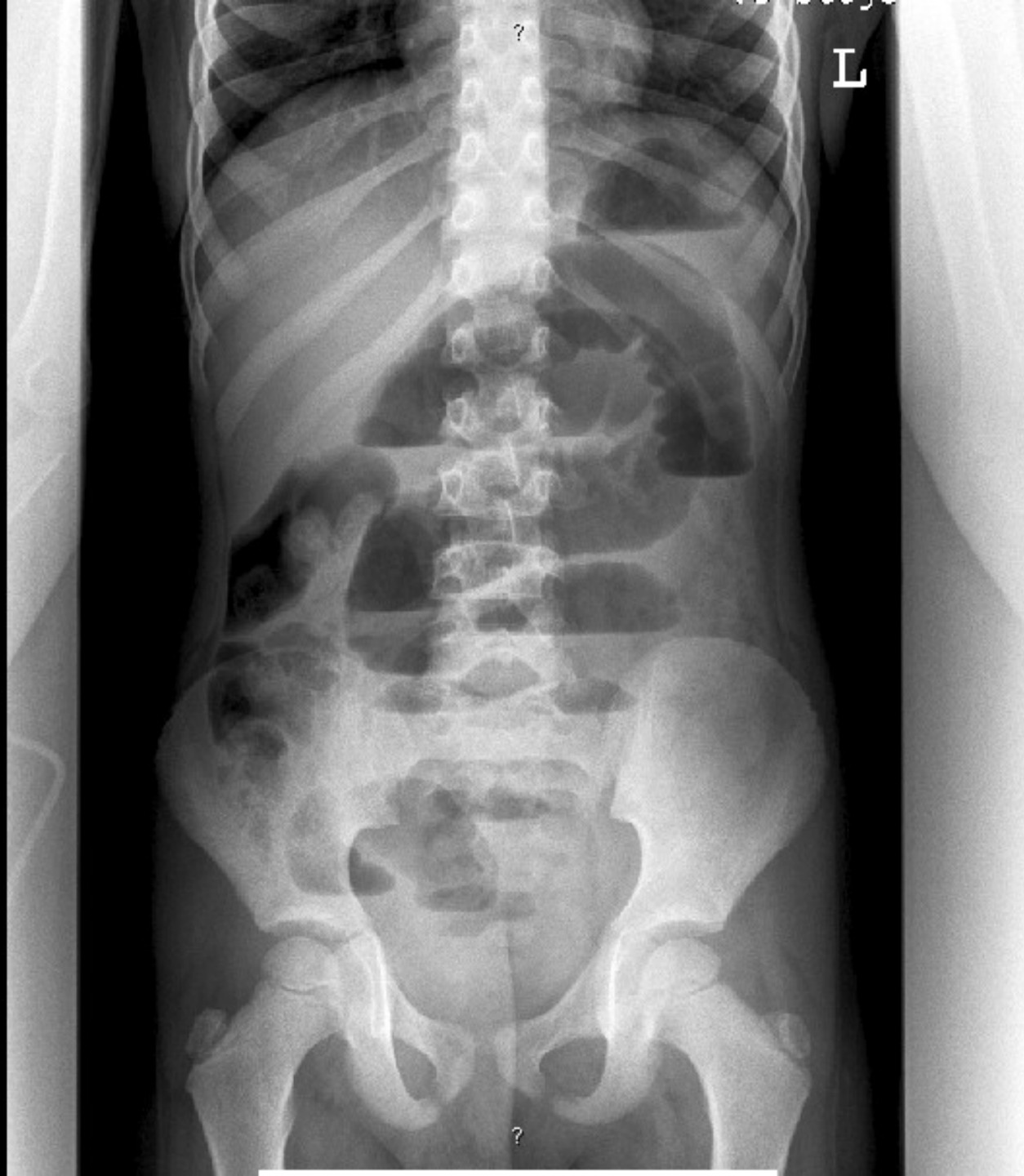
**Battery in  
stomach - need  
to early  
endoscopic  
extraction**



C: 2968  
W: 1625

ID:002433  
Vojta Jiri  
Narozen:1999-11-30  
Datum:2005-04-17  
Cas:08:59:46  
No.1

10




Q: 80% 

FN Brno -Detska nemocnice  
ADC\_5146

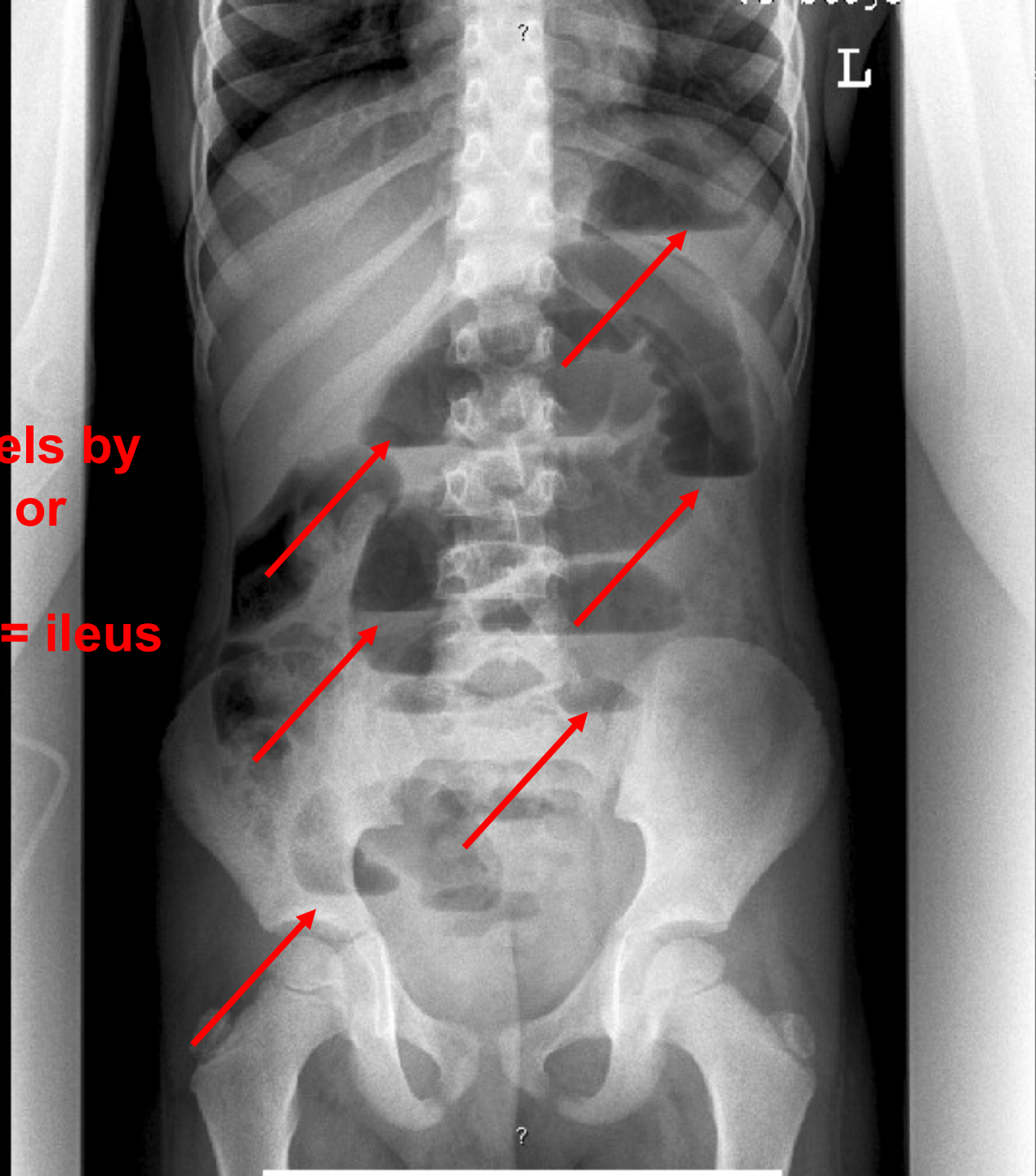
C: 2426  
W: 1865

ID:002433  
Vojta Jiri  
Narozen:1999-11-30  
Datum:2005-04-17  
Cas:08:59:46  
No.1

Q: 80%   
FN Brno -Detska nemocnice  
ADC\_5146

10


**Fluid levels by standing or hanging position = ileus**



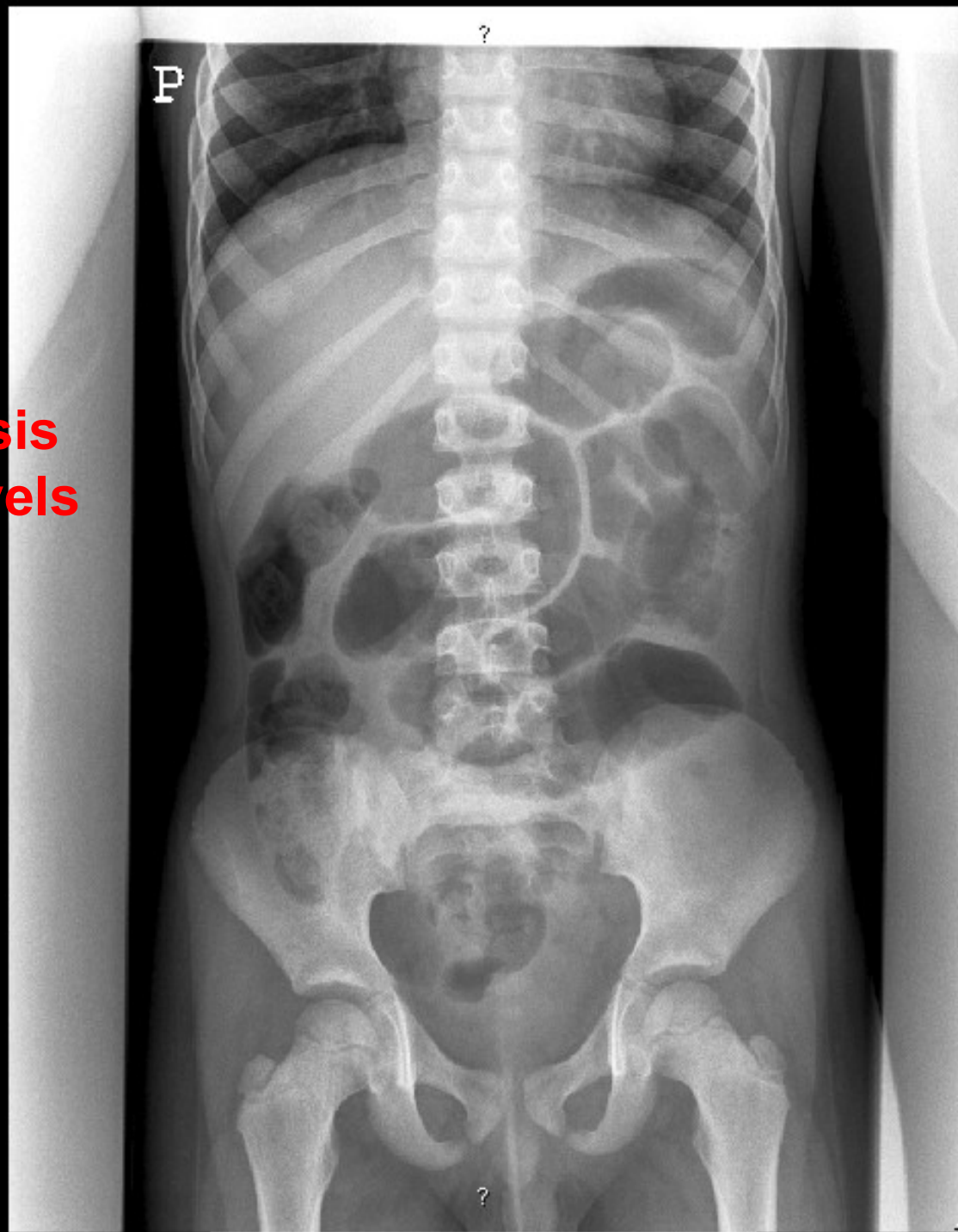
C: 2426  
W: 1865



ID:002433  
Vojta Jiri  
Narozen:1999-11-30  
Datum:2005-04-17  
Cas:08:55:08  
No.1

Q: 80% 

FN Brno -Detska nemocnice  
ADC\_5146



**Pneumatosis  
without levels**

C: 2546  
W: 2075

Thank you for your attention