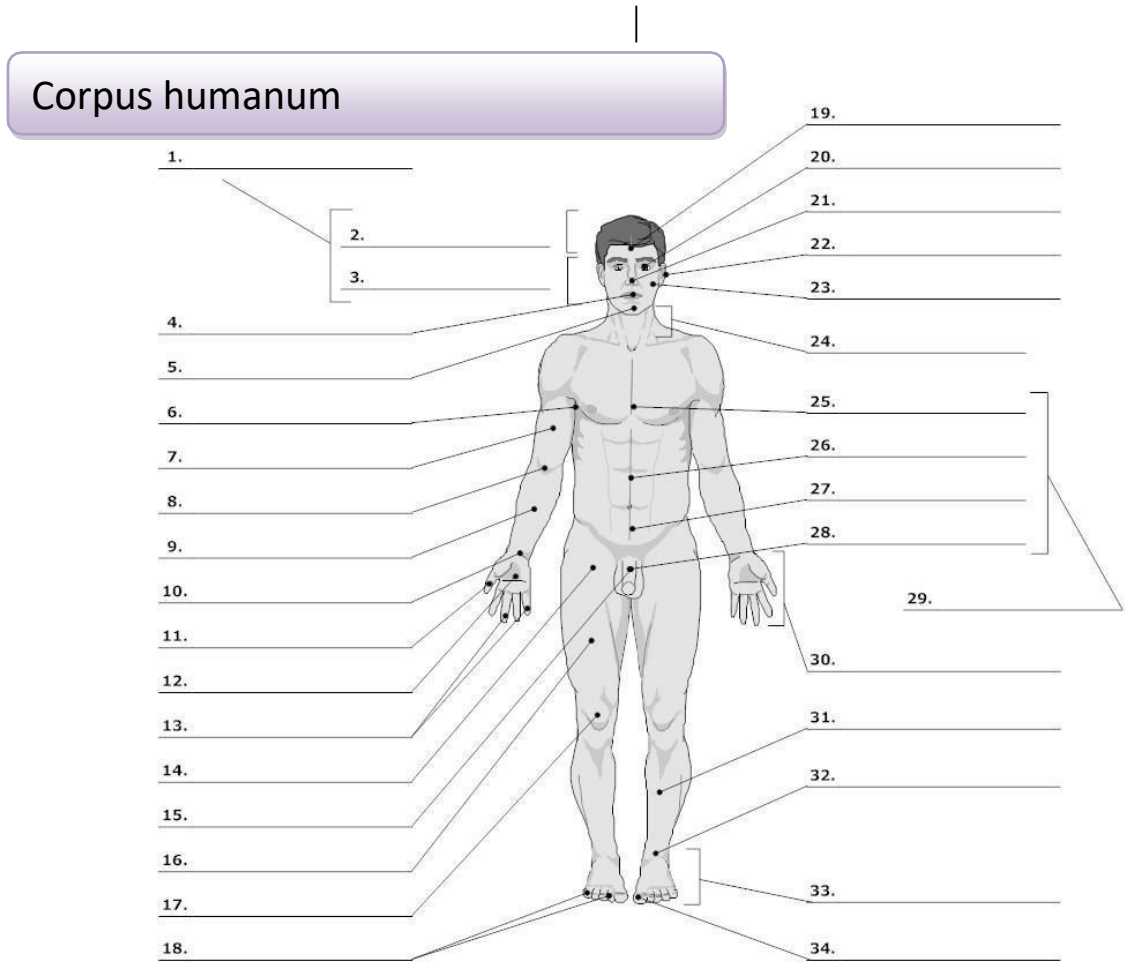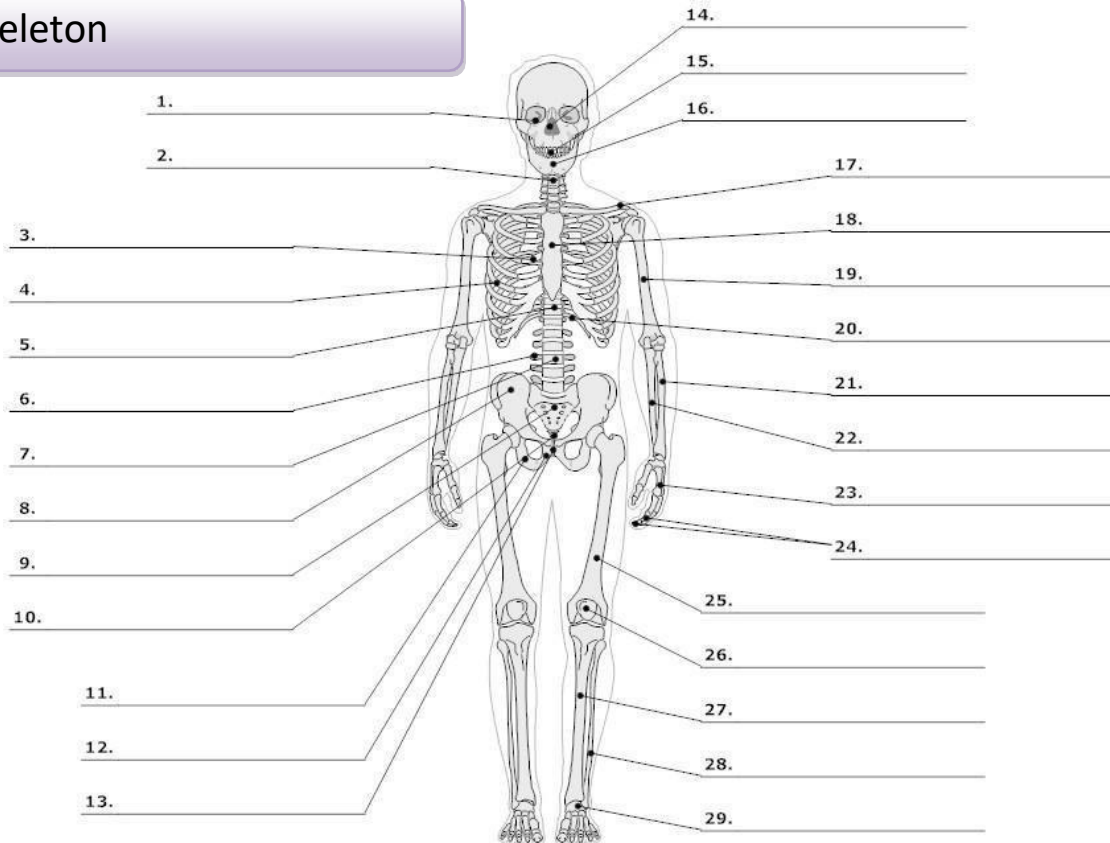


LIFEART Collection Images Copyright © 1999-2001 by Uppincott Williams & Wilkins, Baltimore, MD

0. corpus, oris, n.	body	16. femur, oris, n.	thigh, femur
cutis, is, f.	skin	17. genu, us, n.	knee
1. caput, itis, n.	head	19. frons, frontis, f.	forehead
2. capilli, orum, m.	hair	20. oculus, i, m.	eye
3. facies, ei, f.	face	21. nasus, i, m.	nose
4. os, oris, n.	mouth, opening	22. auris, is, f.	ear
lingua, ae, f.	tongue	23. bucca, ae, f.	cheek
5. mentum, i, n.	chin	24. collum, i, n.	neck (mostly with bones)
6. axilla, ae, f.	armpit, axilla	cervix, icis, f.	neck (with soft tissues)
7. brachium, ii, n.	upper arm, brachium	25. pectus, oris, n.	chest
8. cubitus, i, m.	elbow	26. abdomen, inis, n.	belly, abdomen
9. antebrachium, ii, n.	forearm	27. hypogastrium, ii, n.	hypogastrium
10. carpus, i, m.	wrist	29. truncus, i, m.	trunk
11. pollex, icis, m.	thumb	30. manus, us, f.	hand
12. palma, ae, f.	palm (of the hand)	31. crus, cruris, n.	lower leg, calf
13., 18. digitus, i, m.	finger	32. tarsus, i, m.	tarsus
14. sulcus, i, m. ¹	groove, furrow	talus, i, m.	anklebone, talus
15., 28. penis, is m.	penis	33. pes, pedis, m.	foot
		34. hallux, ucis, m.	big toe

¹ sulcus glutealis

Skeleton



LifeART Collection Images Copyright © 1989-2001 by Lippincott Williams & Wilkins, Baltimore, MD

0.	skeleton, i, n.	skeleton	scapula, ae, f.	shoulder blade
	os, ossis, n.	bone	18. sternum, i, n.	breastbone
	cranium, ii, n.	skull	19. humerus, i, m.	arm bone, humerus
1.	orbita, ae, f.	orbit	20. arcus, us, m.²	arch
2.	collum, i, n.	neck (mostly with bones)	21. radius, ii, m.	radial bone, radius
	cervix, icis, f.	neck, cervix (with soft tissues)	22. ulna, ae, f.	elbow bone
3.	thorax, acis, m.	thorax (chest with ribs)	23. metacarpus, i, m.	metacarpus
4.	costa, ae, f.	rib	24. phalanx, gis, f.	wrist
5.	discus, i, m.	(vertebral) disc	25. femur, oris, n.	finger bone
6.	processus, us, m.	process (protuberance)	26. patella, ae, f.	thighbone, femur
7.	vertebra, ae, f.	vertebra	27. tibia, ae, f.	kneecap
8.	pelvis, is, f.	pelvis	28. fibula, ae, f.	shinbone
	coxa, ae, f.	hip, hip joint	29. metatarsus, i, m.	calf bone
	ilium, ii, n.	ilium		metatarsus
9.	os sacrum*	sacral bone		
10.	coccyx, gis, f.	tailbone, coccyx		
11.	ischium, ii, n.	ischium		
12.	os pubis*	pubic bone		
13.	symphysis, is, f.	symphysis		
14.	nasus, i, m.	nose		
15.	dens, ntis, m.	tooth		
16.	mandibula, ae, f.	lower jaw		
17.	clavicula, ae, f.	collarbone, clavicle		

² arcus costalis