

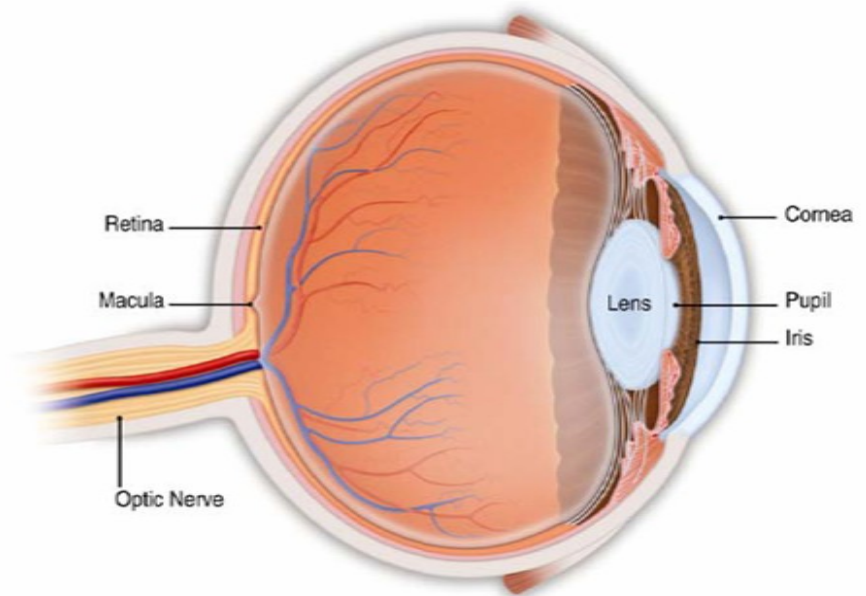
Glaucoma

Outline

- **Healthy eye**
- **What is glaucoma**
- **Anatomy of glaucoma**
- **Types of glaucoma**
- **Glaucoma risk factors**
- **Examination in glaucoma**
- **Treatment of glaucoma**

The healthy eye

- Light rays enter the eye the cornea, pupil and lens.
- These light rays are focused directly onto the retina, the light-sensitive tissue lining the back of the eye.
- The retina converts light rays into impulses; sent through the optic nerve to your brain, where they are recognized as images.



What is glaucoma?

- Disease of the optic nerve.
- When damage to the optic nerve fibers occurs, blind spots develop; blind spots usually go undetected until optic nerve is significantly damaged.
- One of leading cause of blindness in the world (especially in older people)
- Early detection and treatment are keys to prevent vision loss from glaucoma.



Normal vision



Vision as it might be affected by glaucoma

Glaucoma - definition

- Glaucoma is a multifactorial (there are more causes), irreversible and still progressive (without treatment) damage of the optic nerve, that is typical by acquired loss of ganglion retinal cells (=neurons) and by atrophy of optic nerve
- The newest theory describes glaucoma as illness of the brain, not only as disease of optic nerve (=neuropathy)

Types of glaucoma

Two main categories of glaucoma:

- **Open-angle glaucoma: the most common form of glaucoma.**
(chronic glaucoma)
- **Closed-angle glaucoma: a less common and more urgent form of glaucoma.**
(acute glaucoma)

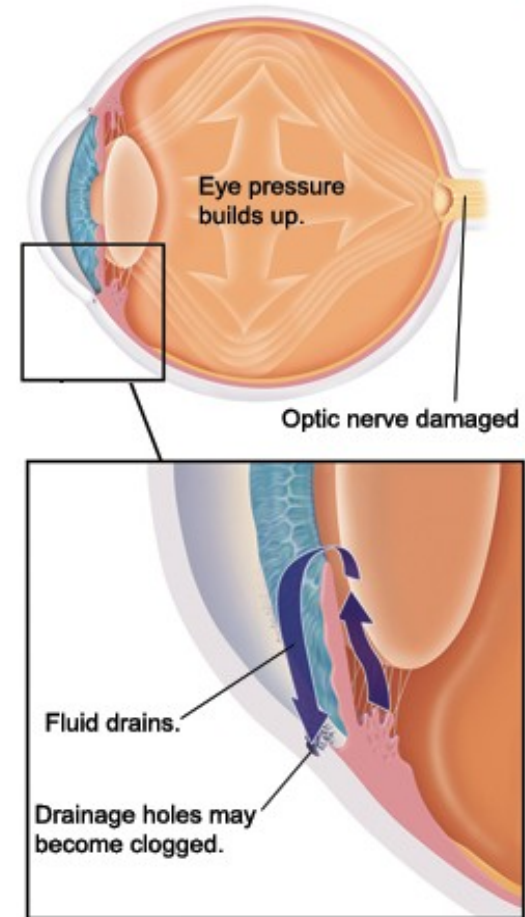
Glaucoma risk factors

Risk factors for glaucoma include:

- Age
- Family history
- Elevated eye pressure (IOP)
- Nearsightedness or farsightedness /myopia or hyperopia/
- African, Hispanic or Asian ancestry
- Diabetes
- Previous eye injury
- Thin cornea

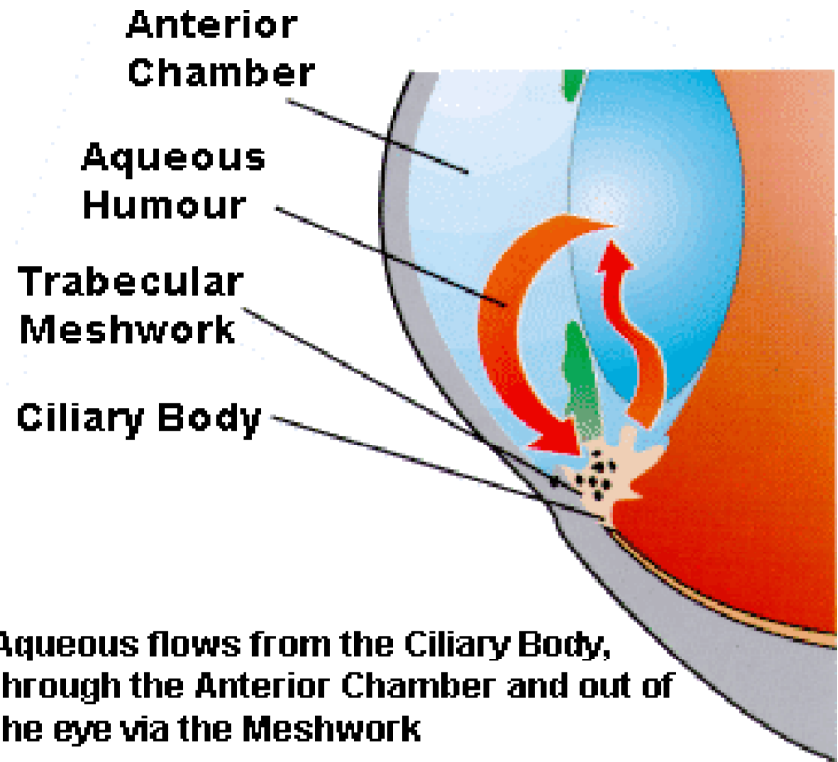
Anatomy of glaucoma

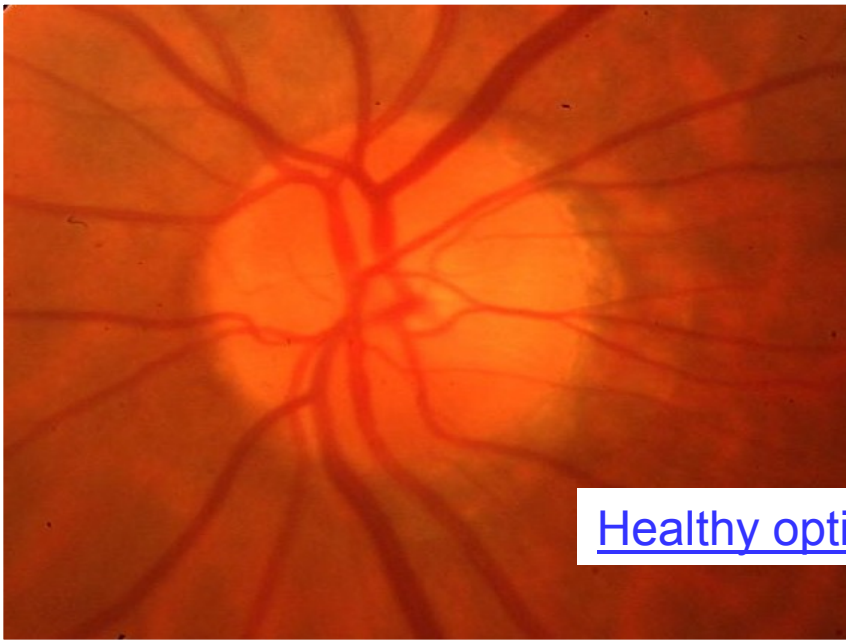
- In glaucoma, aqueous humor does not flow through the trabecular meshwork properly.
- Over time, eye pressure increases, damaging the optic nerve fibers.



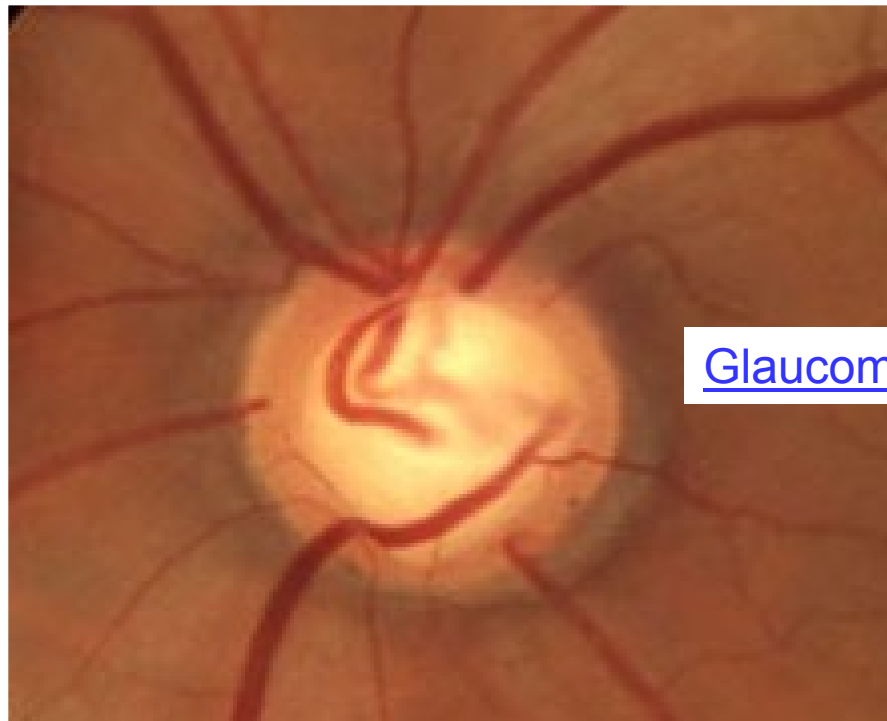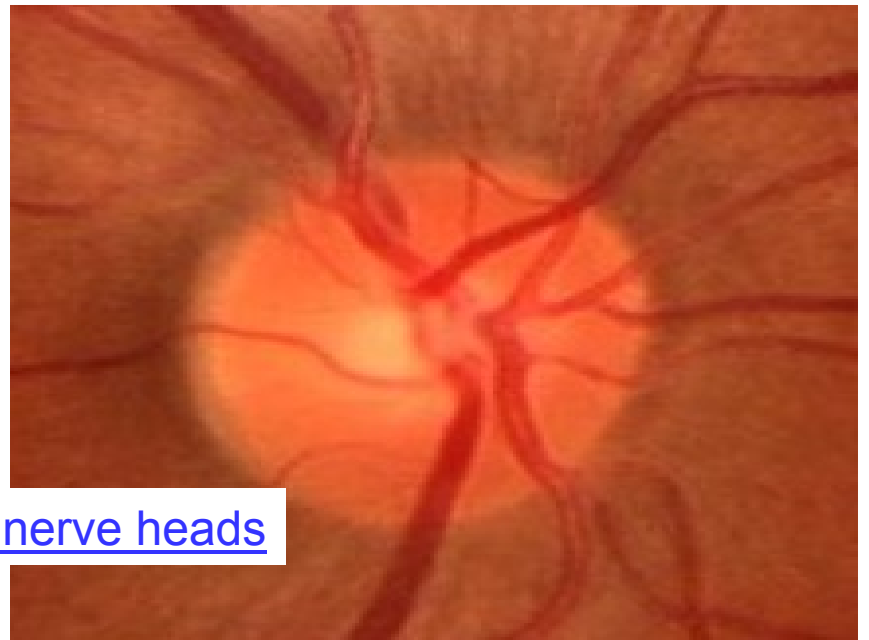Anatomy of glaucoma

- Clear liquid called *aqueous humor* circulates inside the front portion of the eye.
- To maintain a healthy level of pressure within the eye, a small amount of aqueous humor is produced constantly, while an equal amount flows out of the eye through a microscopic drainage system - the *trabecular meshwork*.





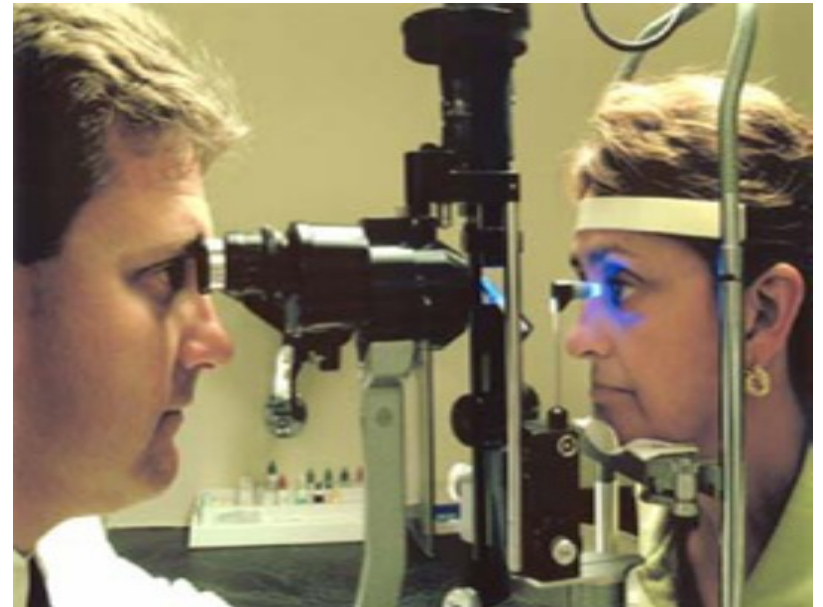Healthy optic nerve heads



Glaucoma damage of ONH

What happens during an exam

- **Tonometry measures eye pressure (IOP).**
- **High tonometry reading is often one of the first signs of glaucoma.**



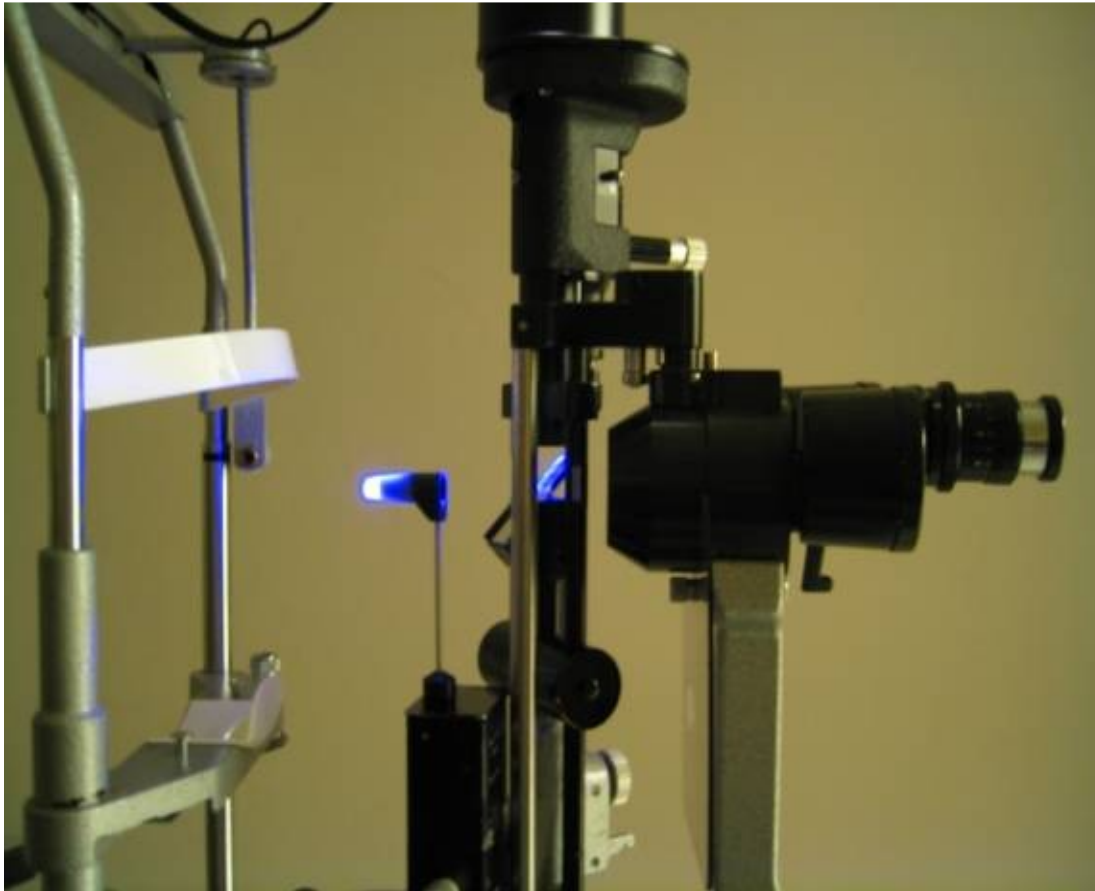


Tonometry examination

Non-contact tonometer

- IOP measured by air-flow
- Advantage:
 - no local (conjunctival) anesthesia
 - no transfer of infection
- Disadvantage:
 - less accurate (sensitive to corneal thickness)

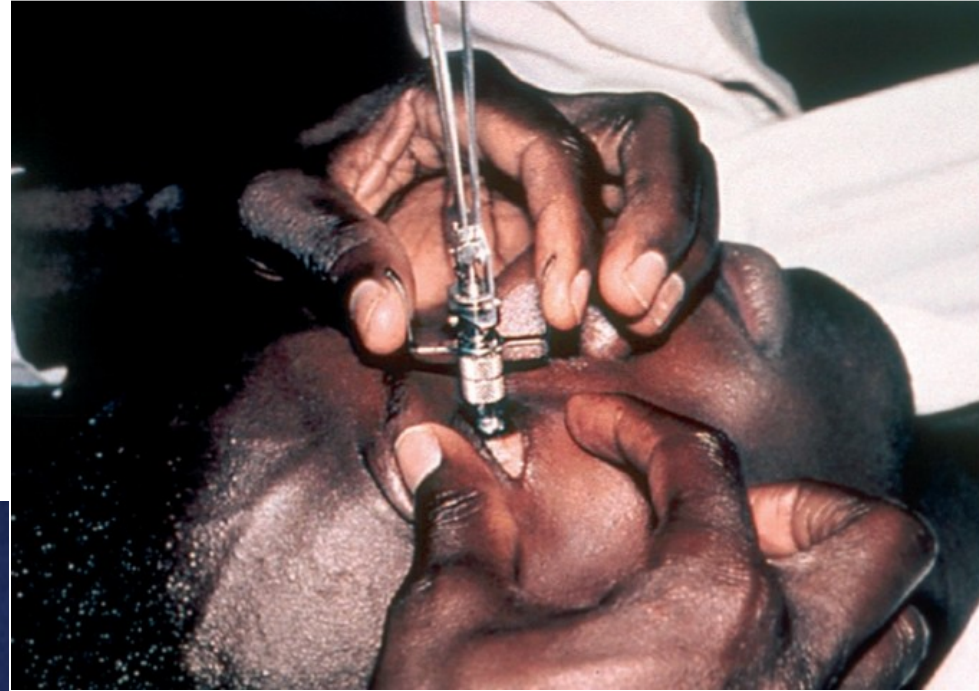
Goldmann's applanation tonometry



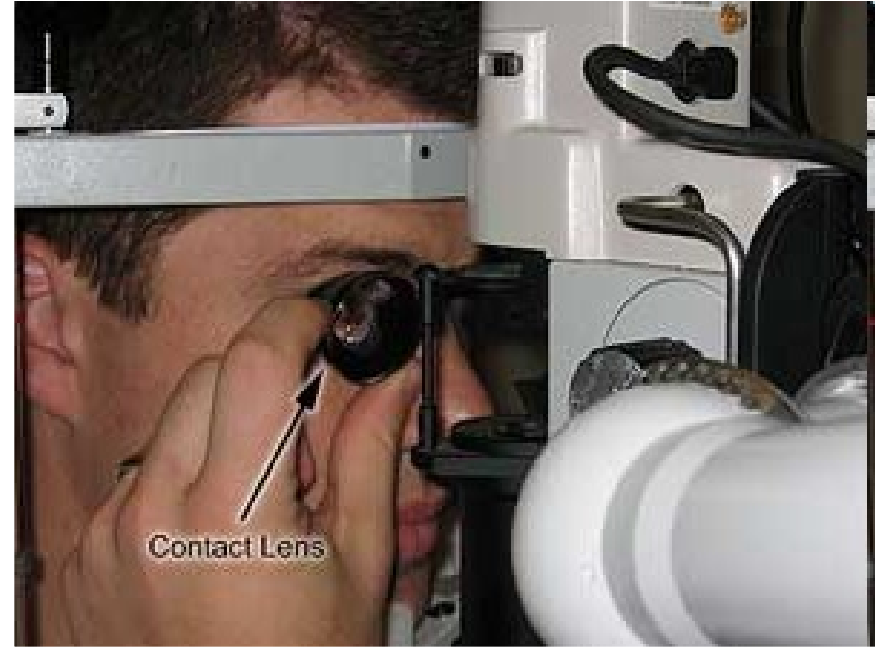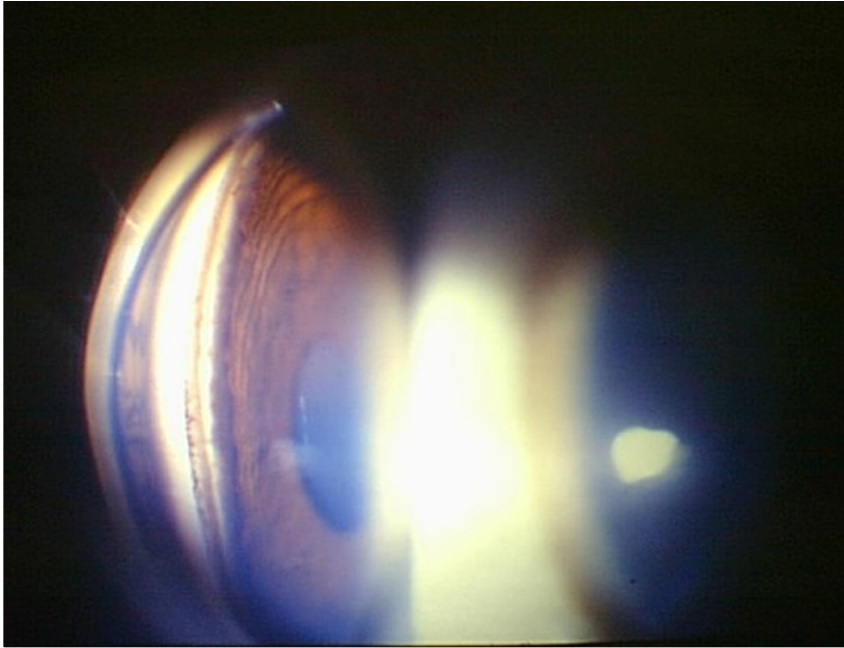
(the most precise method, benoxi, fluorescein, 2 curves must touch in the middle)

Schiötz tonometry

(not very precise, weight, contact method)

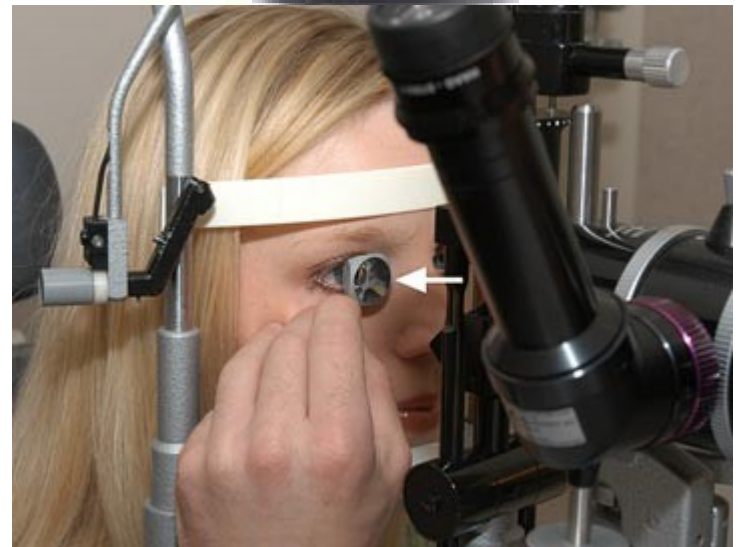

Gonioscopy



- local anesthesia required
- contact lens with a mirror
- examination of angle between cornea and iris
(place of aqueous humor outflow)

Gonioscopy



What happens during an exam

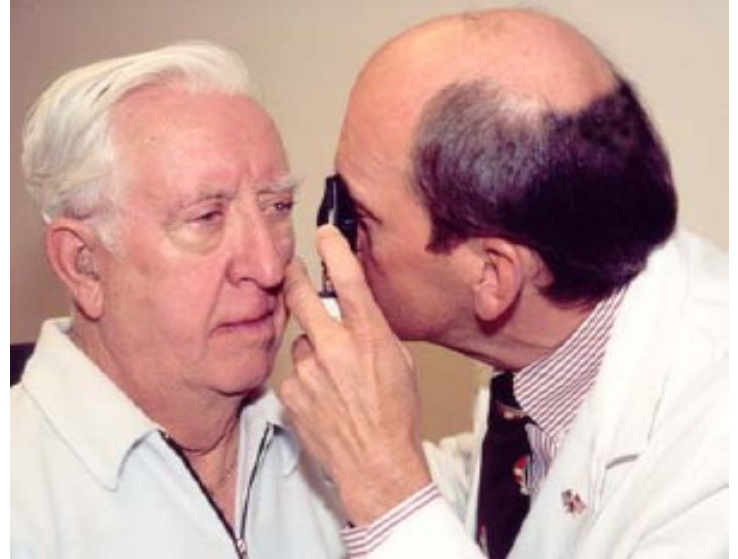- **Gonioscopy** inspects drainage angle of aqueous humor (anterior chamber angle)
- **Allows ophthalmologist to determine type of glaucoma (open- or closed-angle).**



Gonioscopic image of the eye

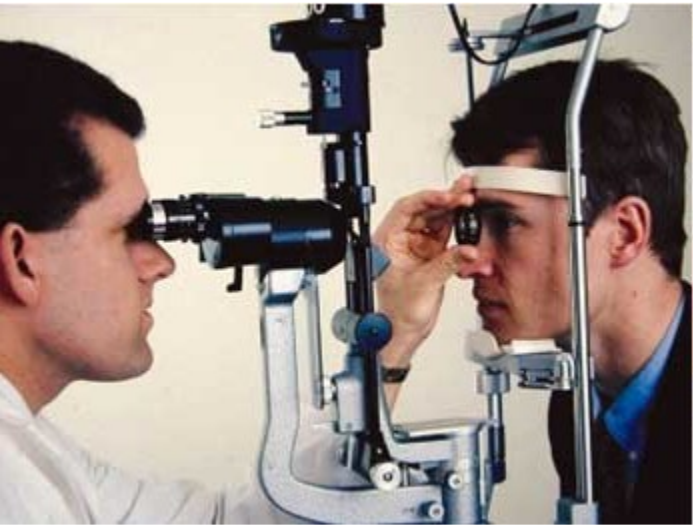Detecting glaucoma

- **Regular eye examinations by your ophthalmologist are the best way to detect glaucoma.**
- **Glaucoma screening that checks only eye pressure is *not* sufficient to detect glaucoma.**



Ophthalmoscope examination

Ophthalmoscopy - examination of ONH, mydriasis (dilatation of pupil) required

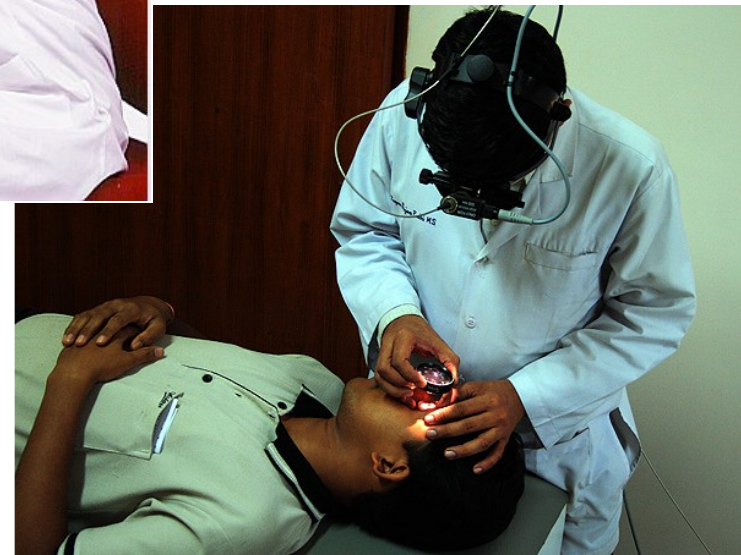

Biomicroscopy on a slit lamp



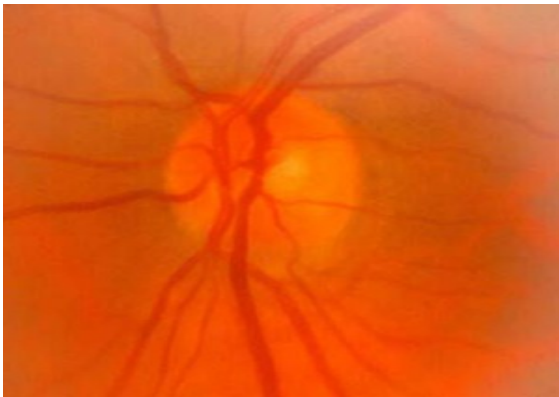
Direct ophthalmoscopy

Indirect ophthalmoscopy

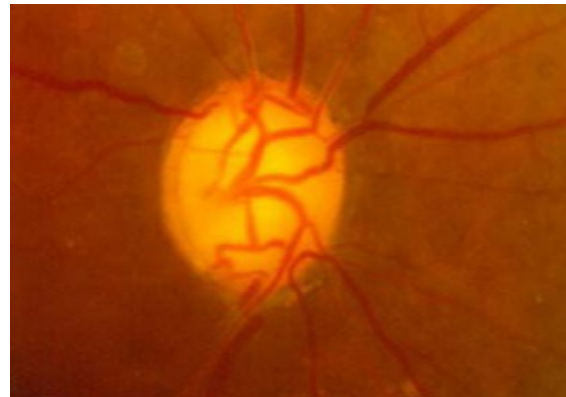


What happens during an exam

- Optic nerve exam, in which ophthalmologist dilates your pupils to detect optic nerve damage.
- Subtle changes of optic nerve reveal early signs of glaucoma (previous slides)



Normal optic nerve



Optic nerve damaged by glaucoma

Perimetry – visual field examination

Kinetic perimetry

- older method
- quantitative evaluation of VF
(provides detection just of absolute scotomas)

Static (computer) perimetry


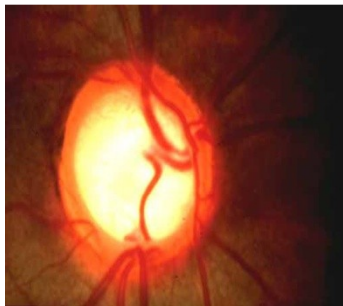
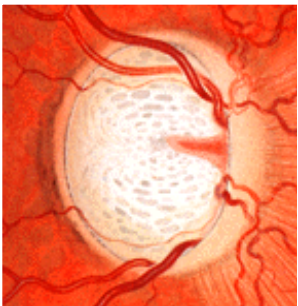
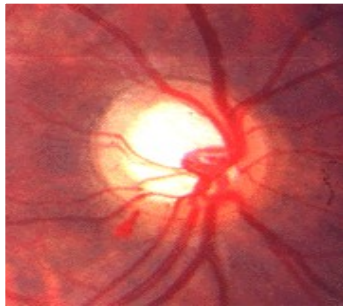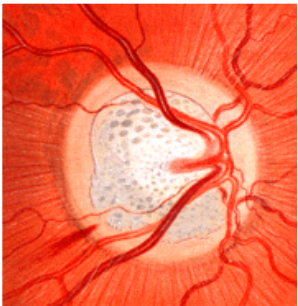
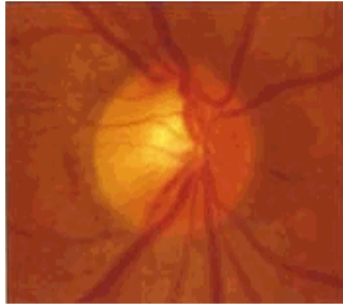
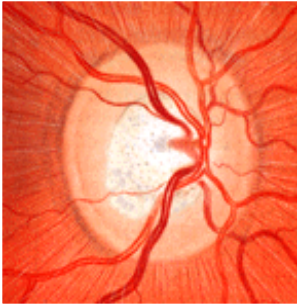
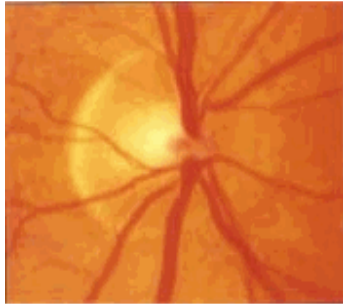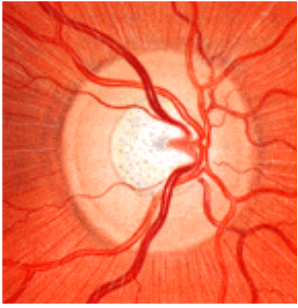- more modern method
- quantitative and qualitative evaluation of VF
(provides detection of absolute and also relative scotomas)

What happens during an exam

- **Visual field exam (perimetry), testing for blank spots in peripheral vision**
- **Scotomas – absolute or relative (decreased sensitivity).**



Visual field exam



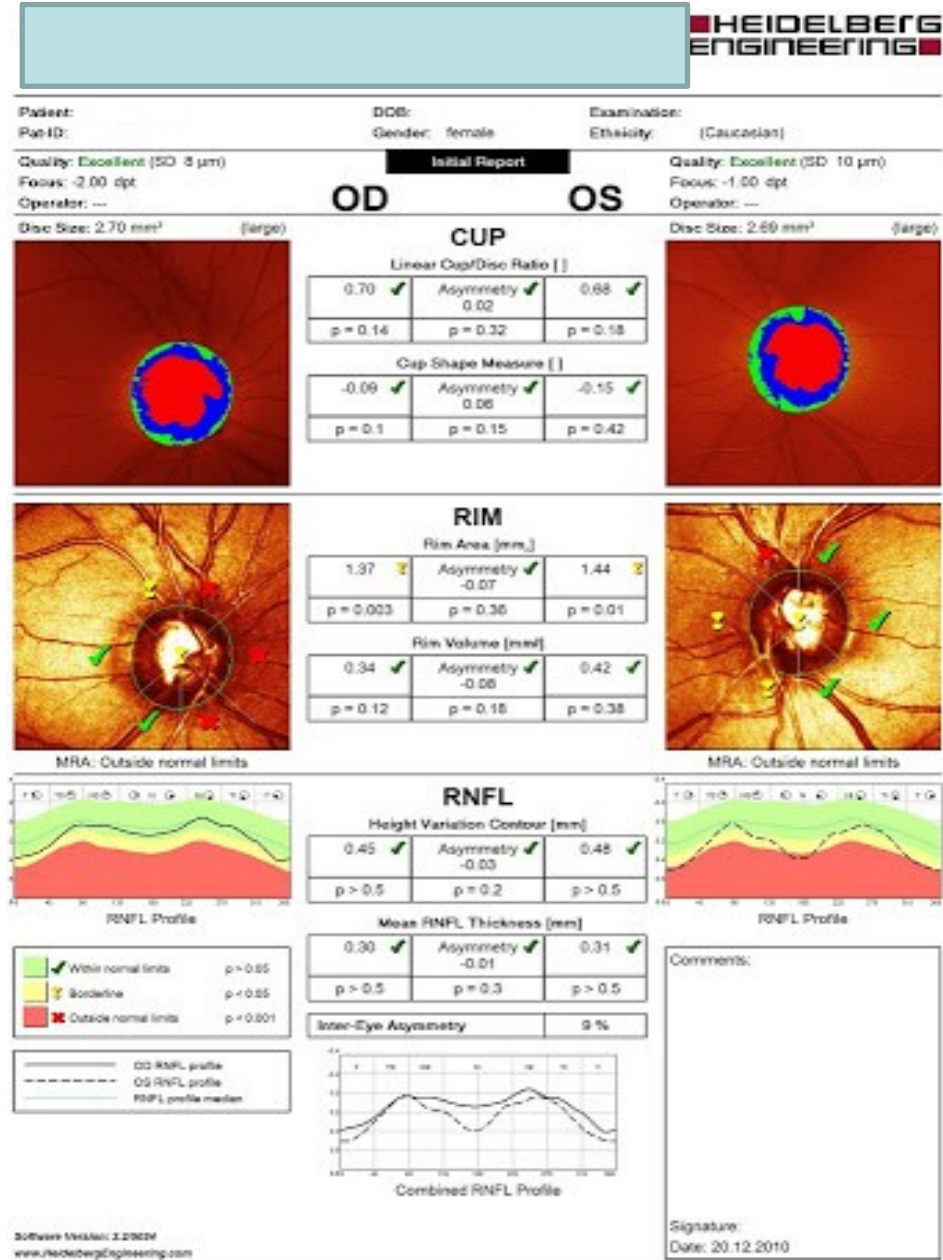
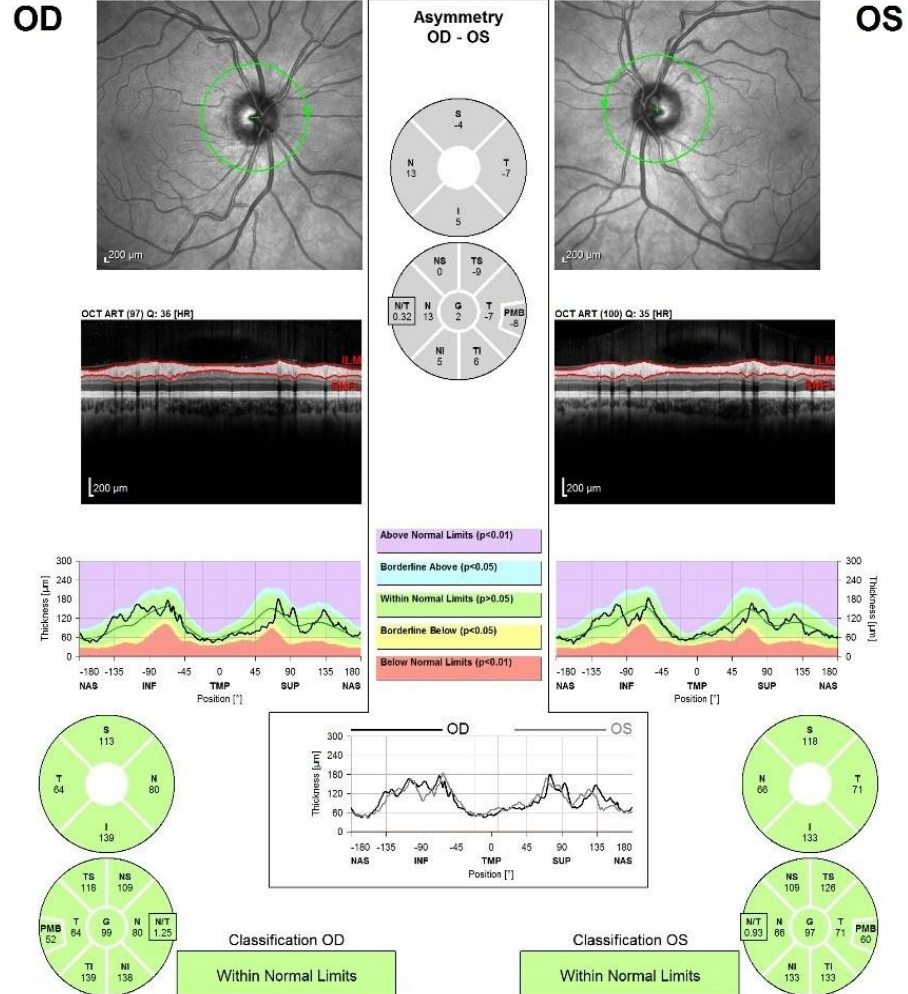


OCT RNFL

HRT

HEIDELBERG
ENGINEERING

Patient ID: --- Exam.: 24.10.2012
Diagnosis: --- Comment: ---



Notes: _____
 Date: 9.11.2015 Signature: _____
 Software Version: 5.8.3 www.HeidelbergEngineering.com Axonal Single Exam Report OU with FoDi™

Glaucoma damage

- **Anatomical loss of tissue**

Glaucoma atrophy of ONH – partial or total loss of nerve fibers, that create optic nerve

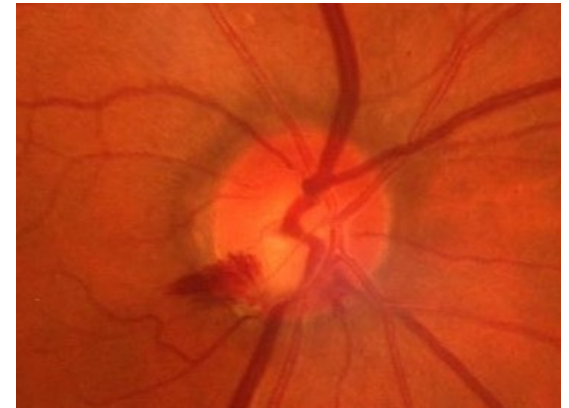
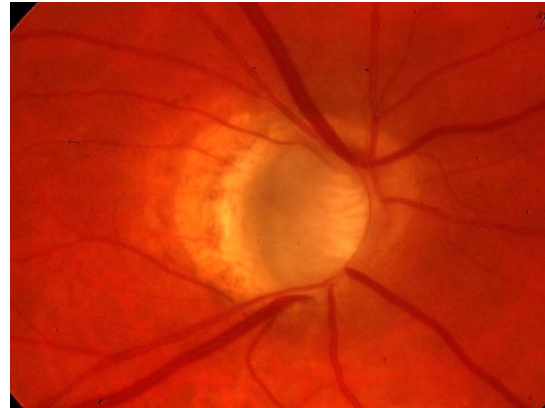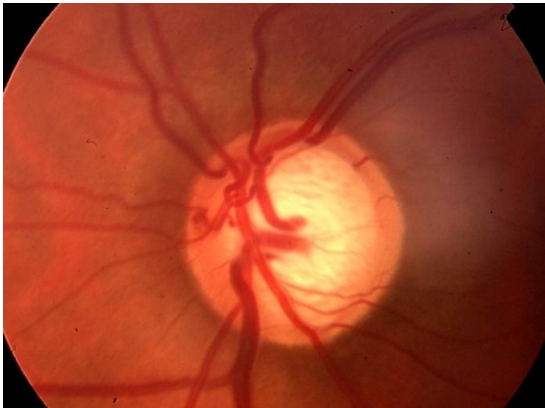
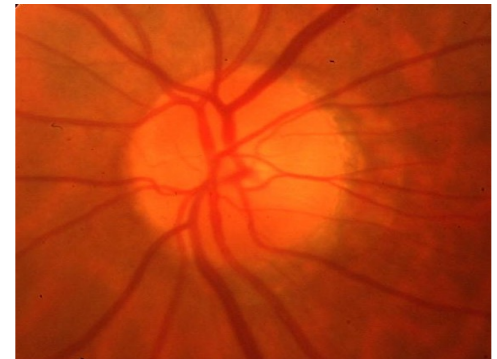
Signs of glaucoma atrophy of ONH:

Excavation of papilla of ONH

Nasalization (nasal shift of vessels)

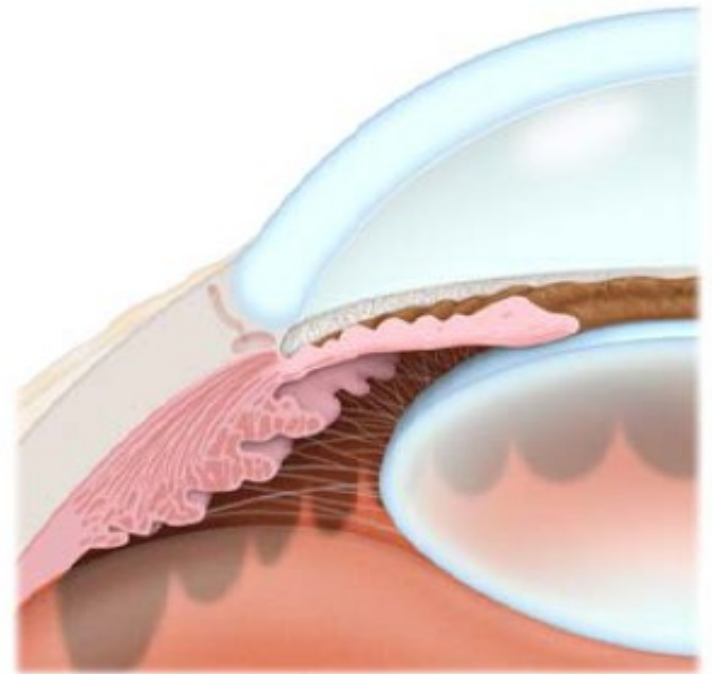
Peripapillary choroidal atrophy

Disc hemorrhage



Open angle glaucoma

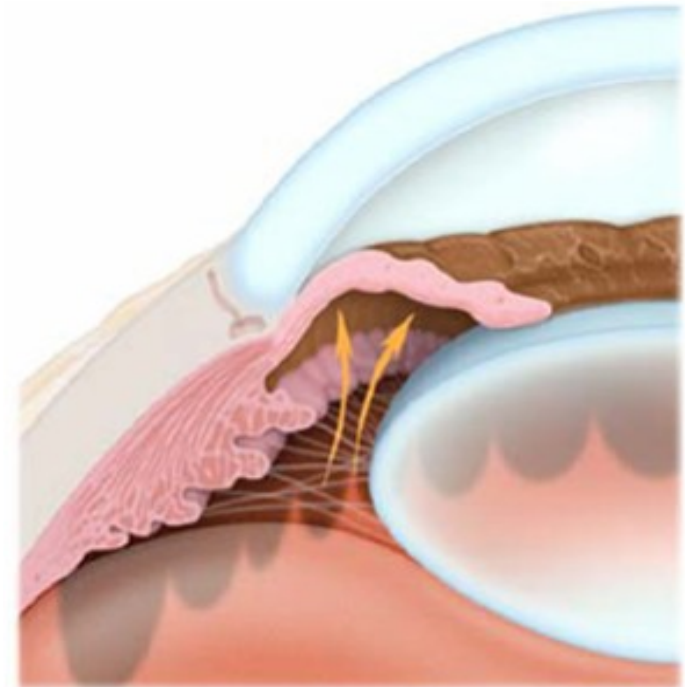
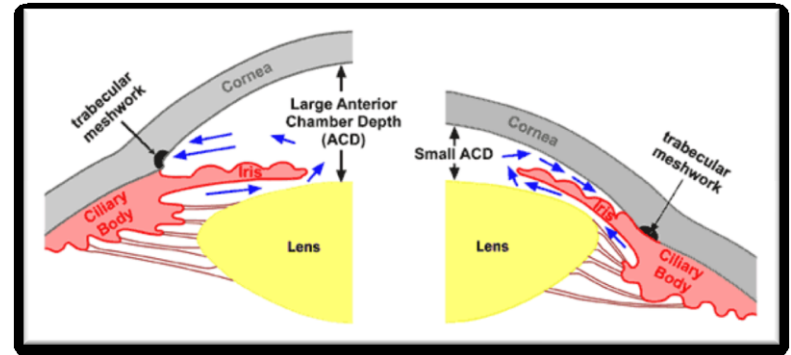
- Trabecular meshwork becomes less efficient at draining aqueous humor.
- Intraocular pressure (IOP) increases, which leads to damage of the optic nerve.
- Damage of the optic nerve occurs at different eye pressure among different patients.
- **Typically, glaucoma has no symptoms in its early stages**



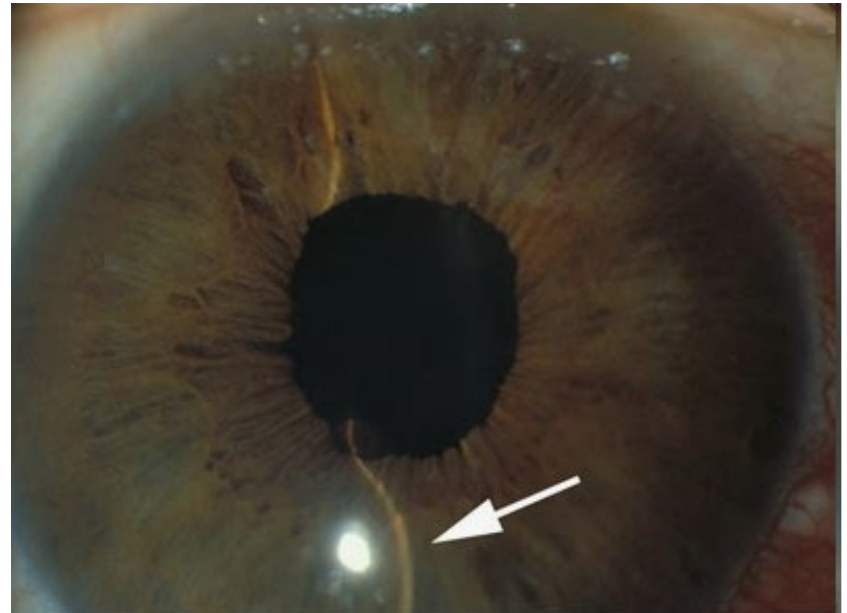
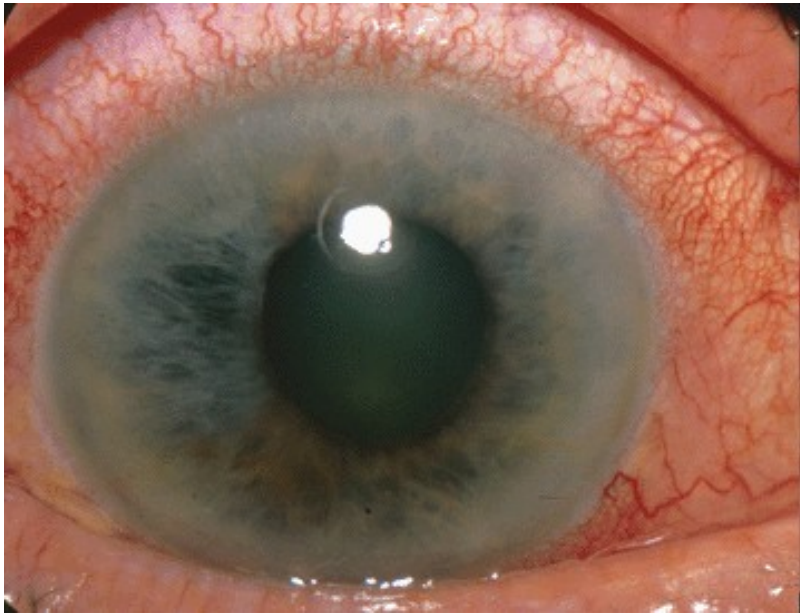
Open-angle glaucoma

Closed angle glaucoma

- often in hypermetropic eyes
- The drainage angle of trabecular meshwork becomes blocked by the iris.
- IOP increases very fast (very high IOP, painful)
- Symptoms include severe eye or brow pain, redness of the eye, decreased or blurred vision
- Must be treated as a medical Emergency - see your ophthalmologist immediately.



Signs of acute (narrow-angle) glaucoma

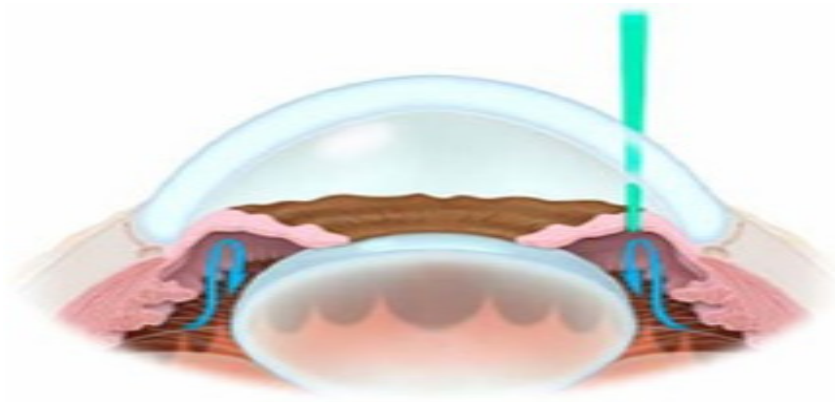


Red eye, pain of eye, corneal edema (semitransparent cornea), pain around the eye, headache, (sometimes nausea, vomiting), shallow anterior chamber, plegia of pupil (mid-dilated), very high IOP

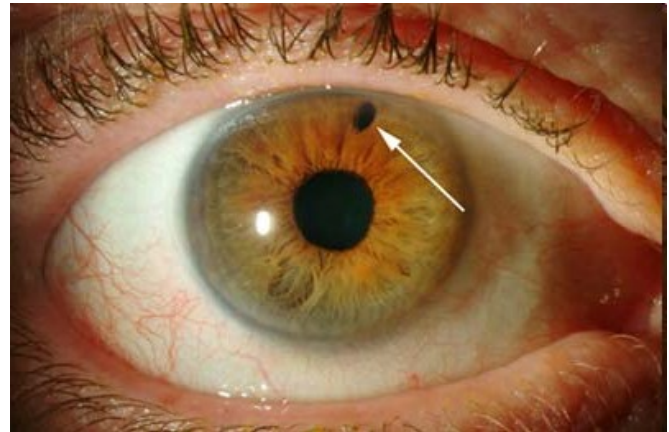
Treating glaucoma

Narrow-angle glaucoma (laser treatment)

- **Laser iridotomy:** creates a small hole in the iris to improve flow of aqueous humor into drainage angle.



Laser iridotomy



Treating glaucoma

- Treatment of glaucoma depends on:

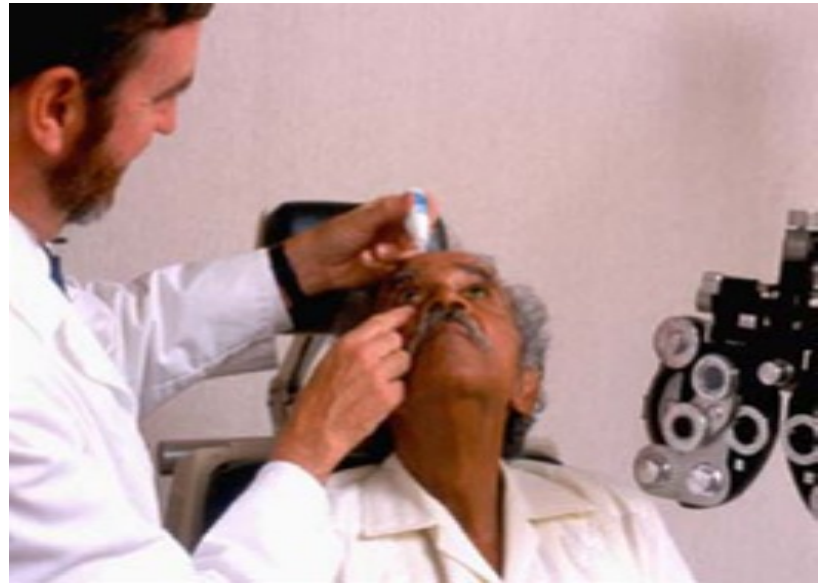Specific type of glaucoma

Severity of glaucoma

How glaucoma responds to treatment

Treating glaucoma

- Medication (see below)
- Eyedrops are the most common treatment



**Eyedrop application for
Open angle glaucoma**

Antiglaucomatics

- **Beta-blockers**
- Work by decreasing aqueous production in the eye and now are often prescribed as an adjunct to or in combination with prostaglandins.
- Medical history of patient is important. Beta-blockers have the potential to reduce heart rate and may cause adverse side effects in individuals with certain heart problems, lung problems (such as emphysema), diabetes, depression or other conditions.

Antiglaucomatics

- **Carbonic anhydrase inhibitors**
- Decreasing rate of aqueous humor production. They are usually used in combination with other anti-glaucoma eye drops and not alone. This classification of drug is also used in oral form (pills).
- Common side effects: include burning, a bitter taste, eyelid reactions and eye redness (ocular injection).
- The systemic (pill) form: Diluran (=acetazolamide): systemic side effects include fatigue, depression, loss of appetite, weight loss, loss of libido, kidney stones, metallic taste and tingling in fingers and toes (peripheral neuropathies). Not suitable for longterm therapy.

Antiglaucomatics

- **Prostaglandins**
- Often the best user compliance because they are required only once daily.
- Better outflow of fluids, thus reducing buildup of eye pressure.
- Possible side effects include stinging and burning, eye color change, and lengthening and curling of the eyelashes.

Antiglaucomatisc

- **Parasympathomimetics**
- Work by increasing the outflow of aqueous humor from the eye. Frequently used to control IOP in narrow-angle glaucoma. These eye drops cause the pupil to constrict, which assists in opening the narrowed or blocked angle where drainage occurs.
- Common side effects include brow ache, pupil constriction, burning, and reduced night vision.

Antiglaucomatics

- **Alpha-adrenergic agonists**
- Decrease rate of aqueous humor production and can be used alone or in combination with other anti-glaucoma eye drops
- Common side effects associated with this classification of eye drop include ocular injection, upper lid elevation, dilated pupils and itching.

Antiglaucomatics

- **Combination glaucoma drugs**
- Many individuals with glaucoma require more than one type of medication to control IOP. Pharmaceutical companies have produced "combination" eye drops that can include two different anti-glaucoma medicines in the same bottle.
- Combined medications have the additive effect of reducing IOP

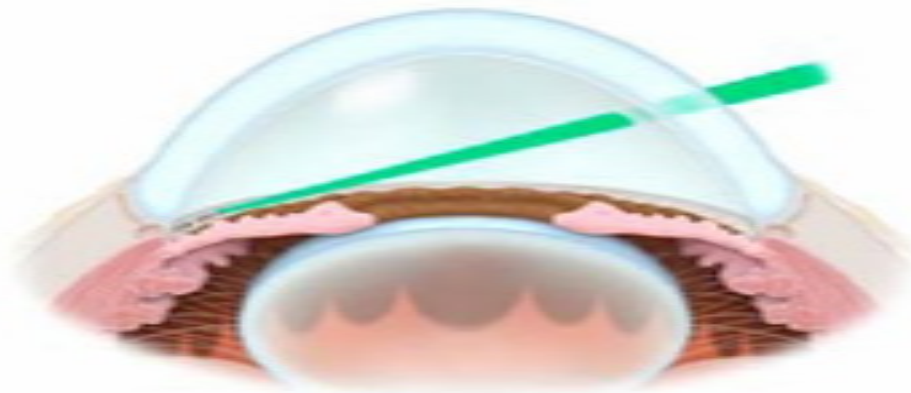
Antiglaucomatics

- **Hyperosmotic agents**
- For people with a severely high IOP that must be reduced immediately before permanent, irreversible damage occurs to the optic nerve. Hyperosmotic agents reduce IOP by lowering fluid volume in the eye.
- Usually given only on a one-time, emergency basis, these drugs include mannitol i.v. (20%, 100ml), (event. oral glycerin and isosorbide orally)

Treating glaucoma

Open angle glaucoma (laser treatment)

- **Laser trabeculoplasty: stimulates the trabecular meshwork (drainage angle) to function more efficiently (temporary effect).**

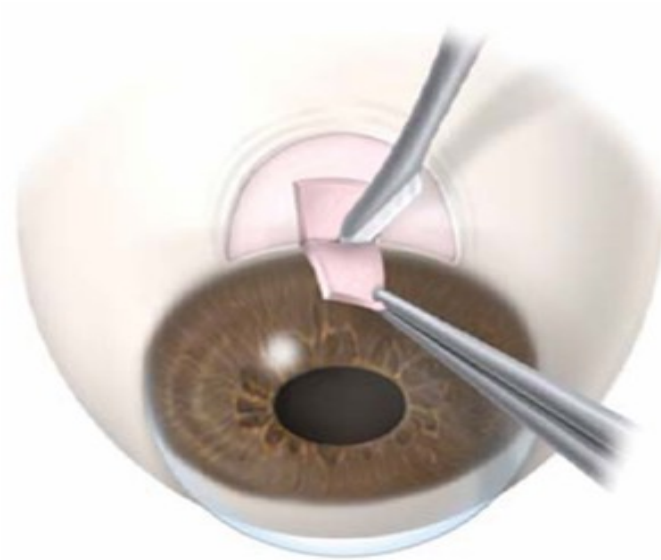


Laser trabeculoplasty

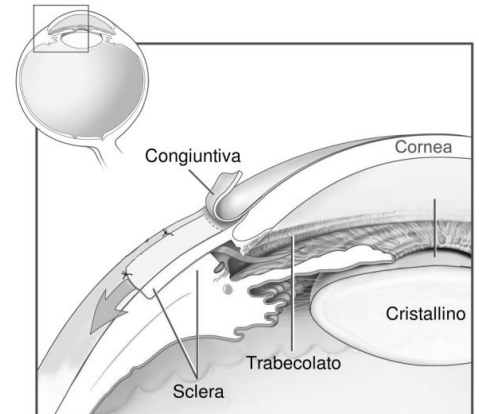
Treating glaucoma

Glaucoma surgery (all types of glaucomas)

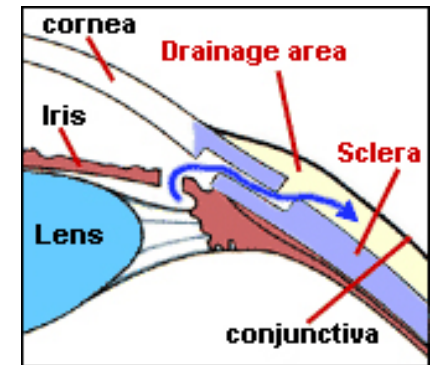

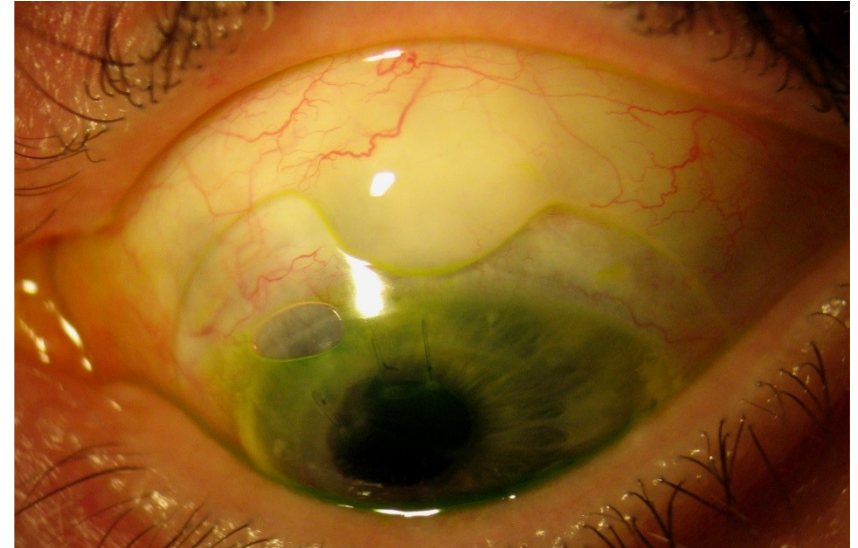
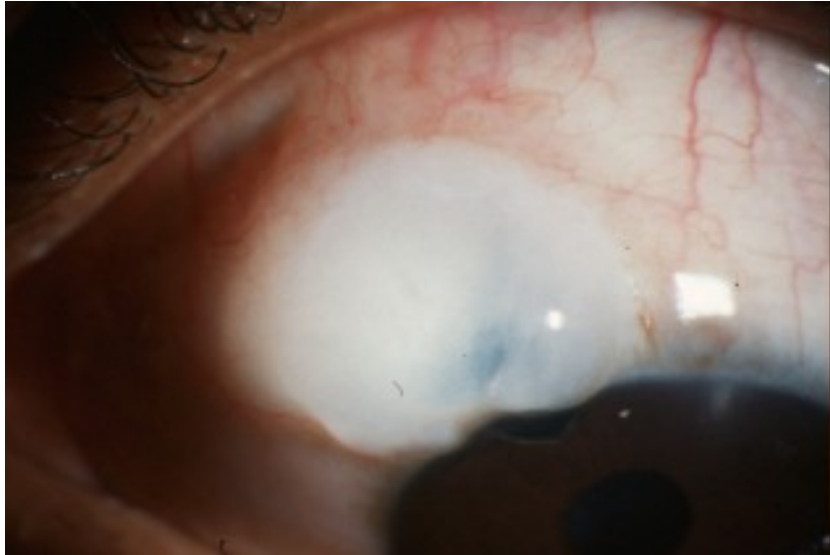
- **Trabeculectomy is a filtering surgery where a new drainage channel is created into the anterior chamber from underneath a partial thickness scleral flap to allow for aqueous flow out of the eye. The aqueous flows into the subconjunctival space, usually leading to an elevation of the conjunctiva, referred to as a filtering bleb**
- **Goal is to stabilize disease and prevent further damage/vision loss.**
- **Does not reverse damage to the optic nerve.**
- **Performed for treatment of glaucoma inadequately controlled by maximally tolerated medical therapy.**



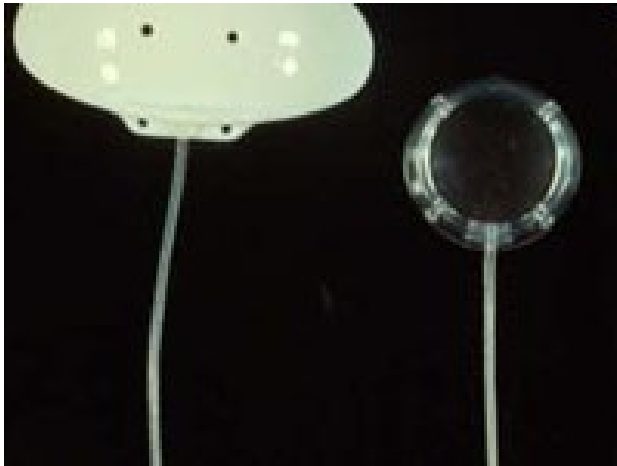
Trabeculectomy



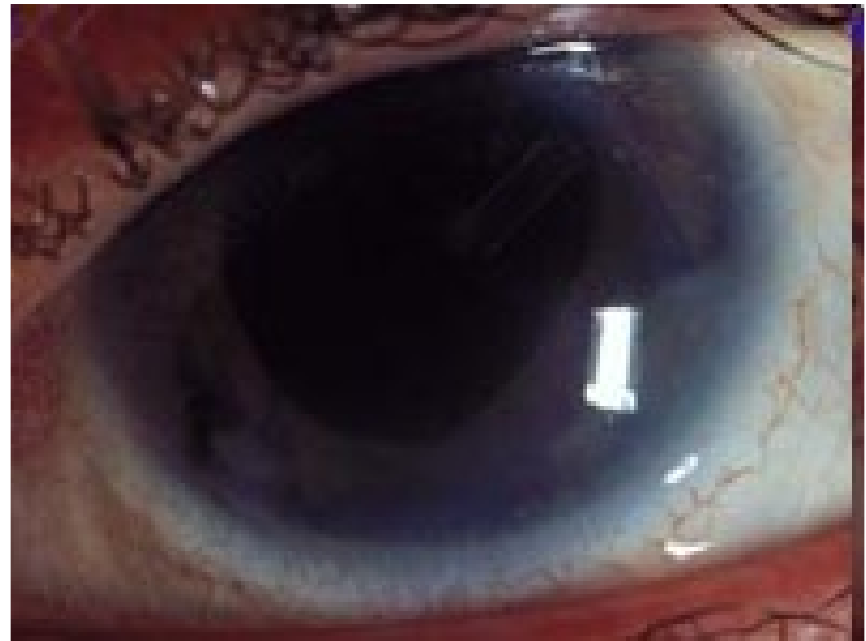
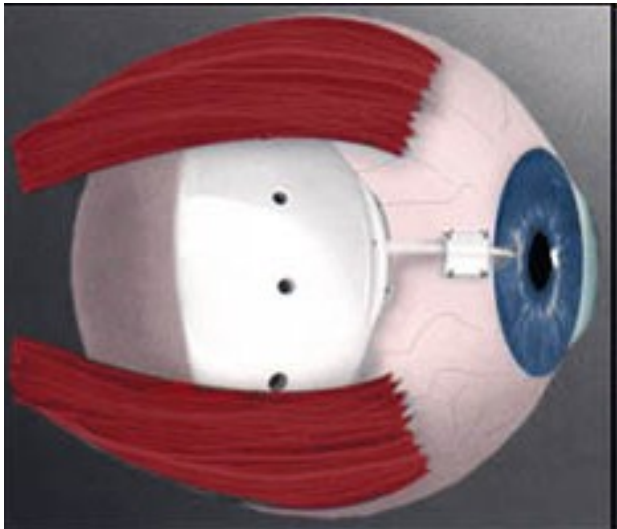
Trabeculectomy – filtering blebs

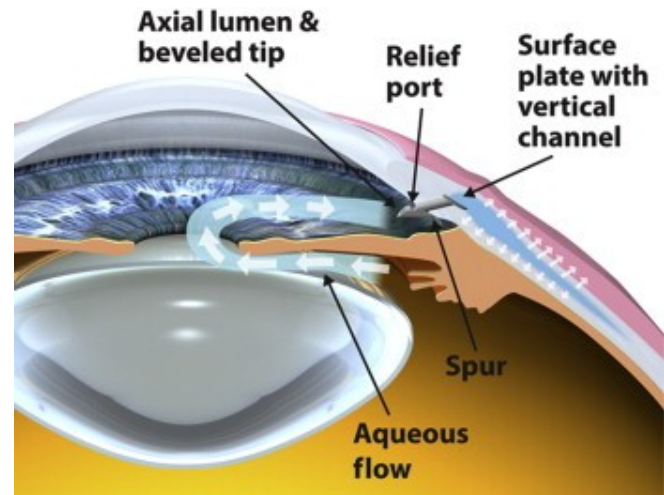
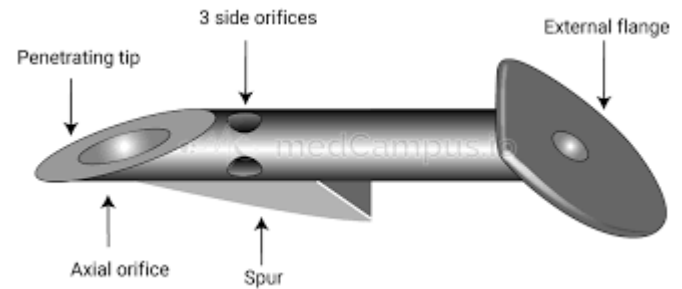
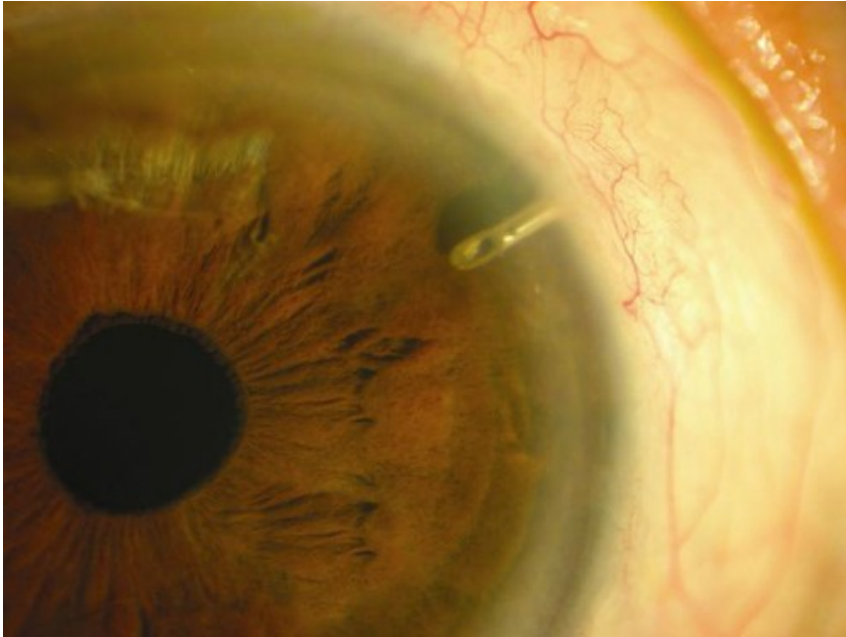


Aqueous shunts

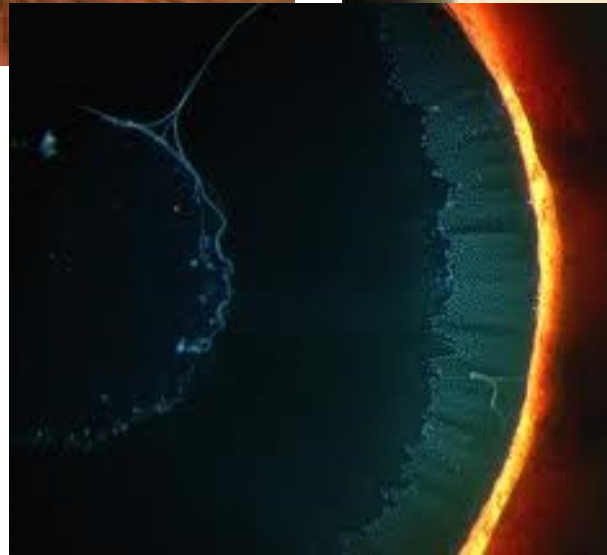
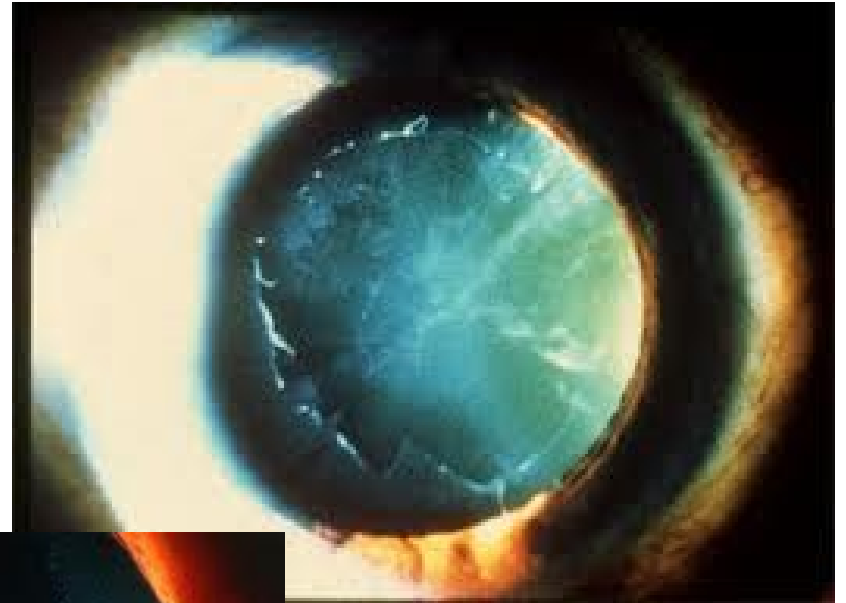
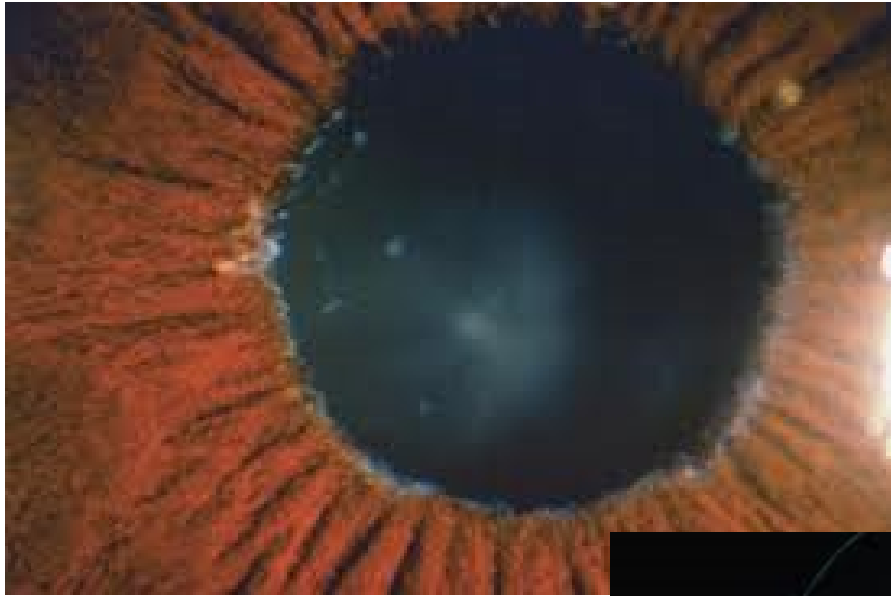- For managing complicated glaucoma
- When trabeculectomy has failed
- A silicone tube leads aqueous humor from anterior chamber or vitreous cavity to an extraocular fluid reservoir under conjunctiva


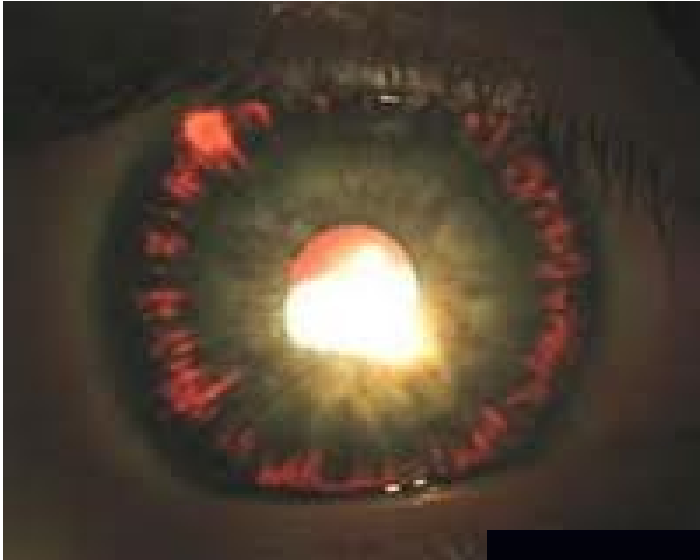




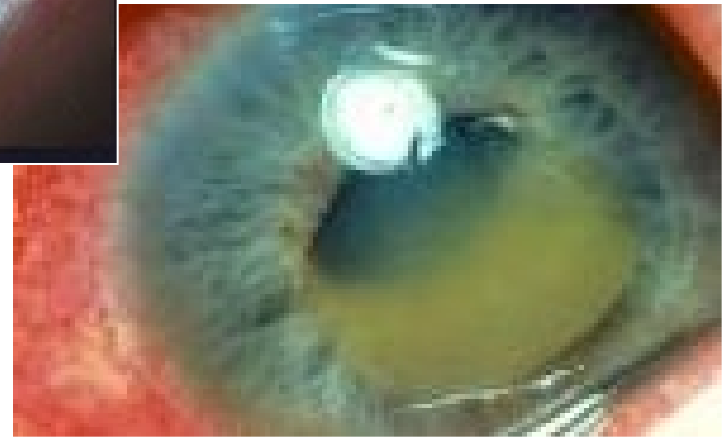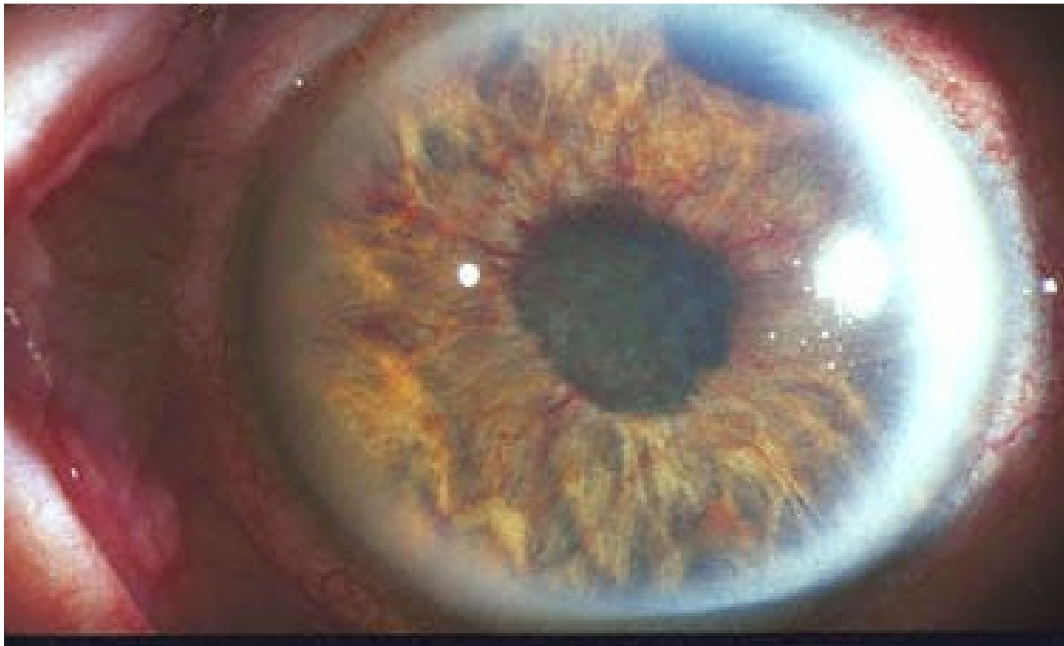
Glaucoma pseudoexfoliativum



Pigmentary glaucoma

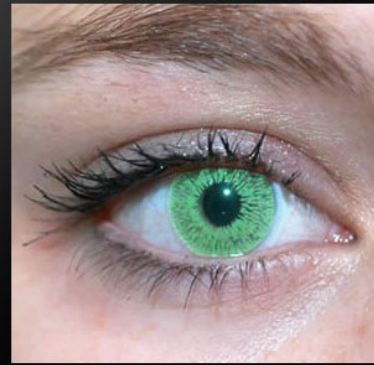
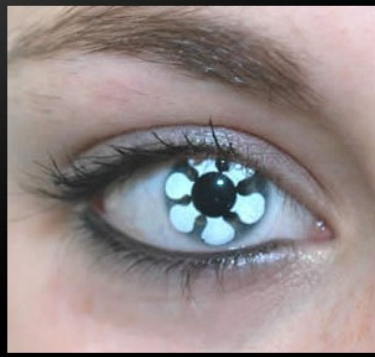
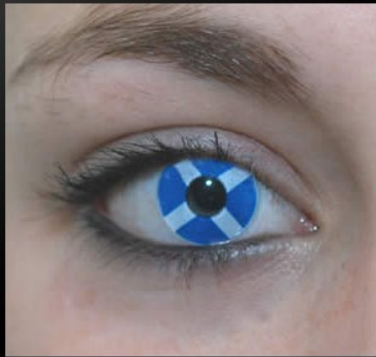

Neovascular glaucoma



Glaucoma is controllable

- **Glaucoma is a silent disease (usually)**
- **Glaucoma is a blinding disease**
- **Vision loss from glaucoma usually can be prevented if detected and treated early.**
- **If you are prescribed eyedrops for glaucoma, you must take them regularly.**
- **If you are at risk for glaucoma, visit your ophthalmologist regularly.**



**Thank you for
your attention !**

