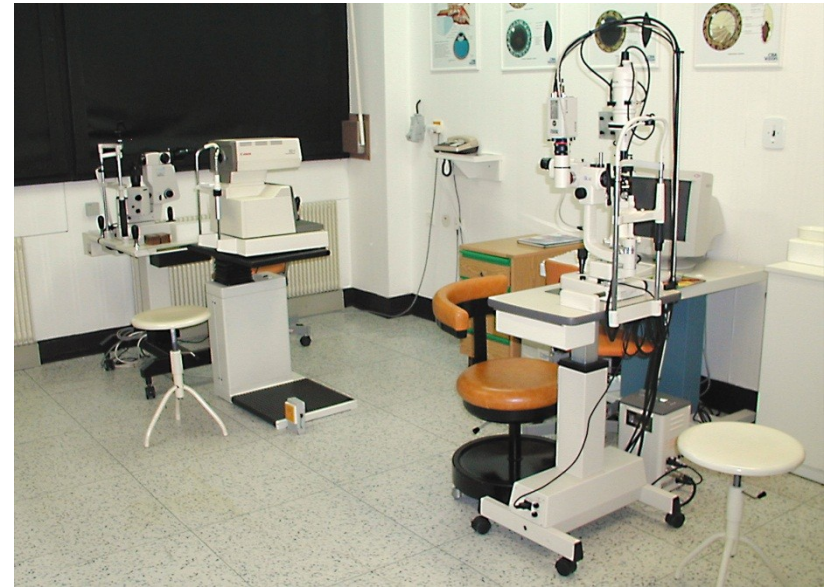

Examination techniques in ophthalmology

V. Matušková

Basic examination techniques

- Visual acuity (natural, best corrected)
- Measurement of intraocular pressure
- Slit lamp examination
- Fundus examination

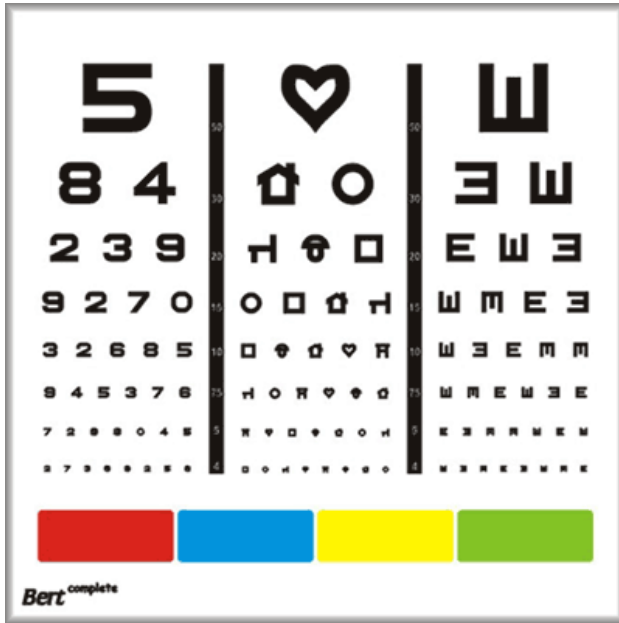


Visual acuity

- Visual acuity (natural, best corrected)
- Distance vision
- Near vision

- **Charts**
 - Snellen
 - Landolt ring
 - Pictures
 - ETDRS

Charts



VISUAL ACUITY CHARTS	
Standard Snellen chart	Bailey-Lovie chart
<p>E 1</p> <p>F P 2</p> <p>T O Z 3</p> <p>L P E D 4</p> <p>P P C F D 5</p> <p>K H F C E F 6</p> <p>VELOPED 7</p> <p>DEVELOPED 8</p> <p>XXXXXXXXXX 9</p> <p>XXXXXXXXXX 10</p>	<p>D S R K N</p> <p>C K Z O H</p> <p>O N R K D</p> <p>K Z V D C</p> <p>V S H Z O</p> <p>H D K C R</p> <p>O S N H N</p> <p>S Y Z D K</p> <p>XXXXXXXXXX</p> <p>XXXXXXXXXX</p>

Near vision

Jaeger chart



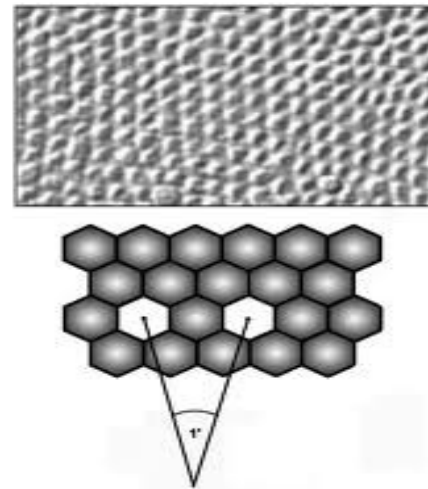
Visual acuity

- Counting finger (metres)
- Hand movement
- Light perception



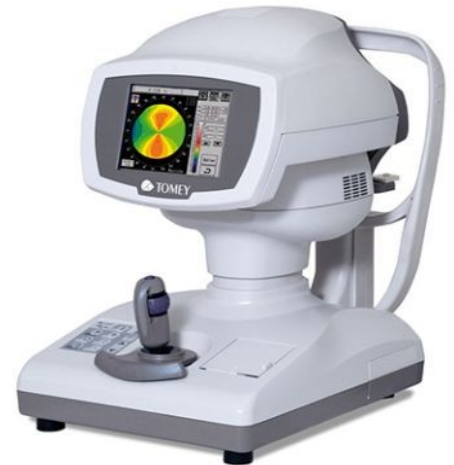Visual Acuity

- 5/50 (metres, feet 20/200)
- 0,1
- Minimum separabile – minimum angle of resolution



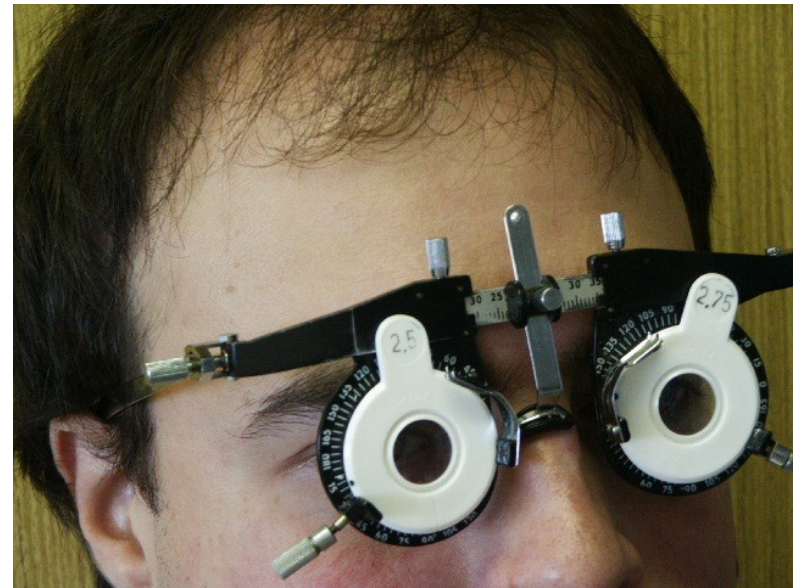
Refraction

- Refractive error is an optical abnormality in which the shape of the eye fails to bring light into sharp focus on the retina, resulting in blurred or distorted vision.
- In optometry, a "refraction" procedure is the measurement of refractive error
- **Autorefractor**



Visual acuity

- Frame
- Lenses



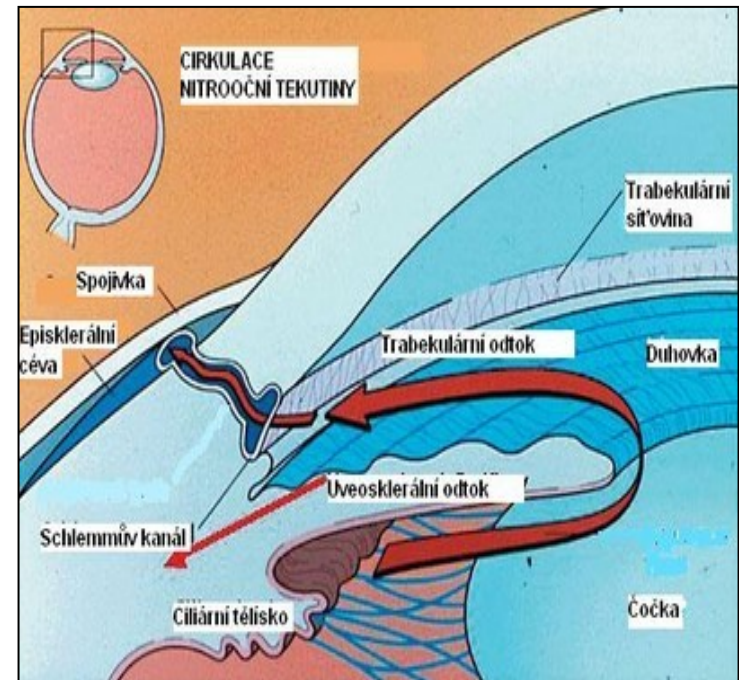
Tonometry

Contact techniques

- Schiötz tonometry
- Goldmann applanation tonometry


Non contact techniques

- Jet air (air puff)

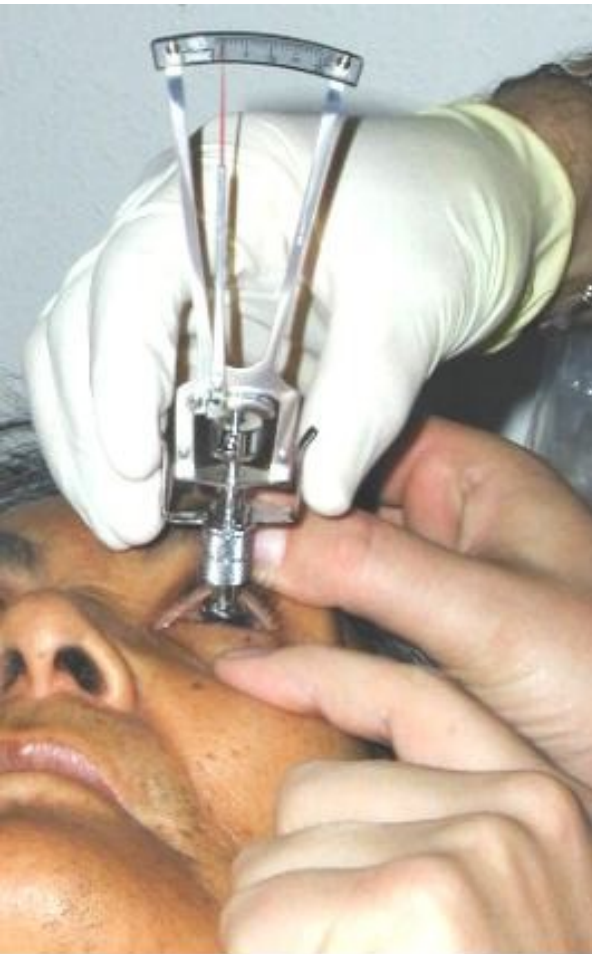

Schiötz tonometry

- 7/7,5
- Topical aneesthesia



Schiötz tonometry






Goldmann tonometry

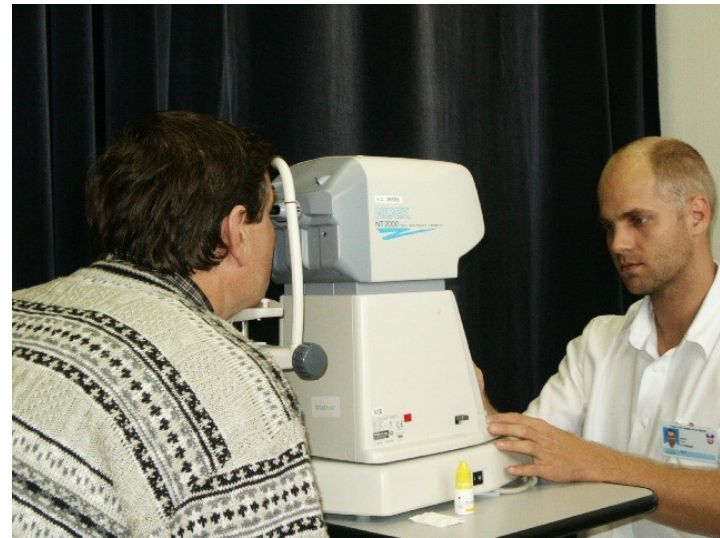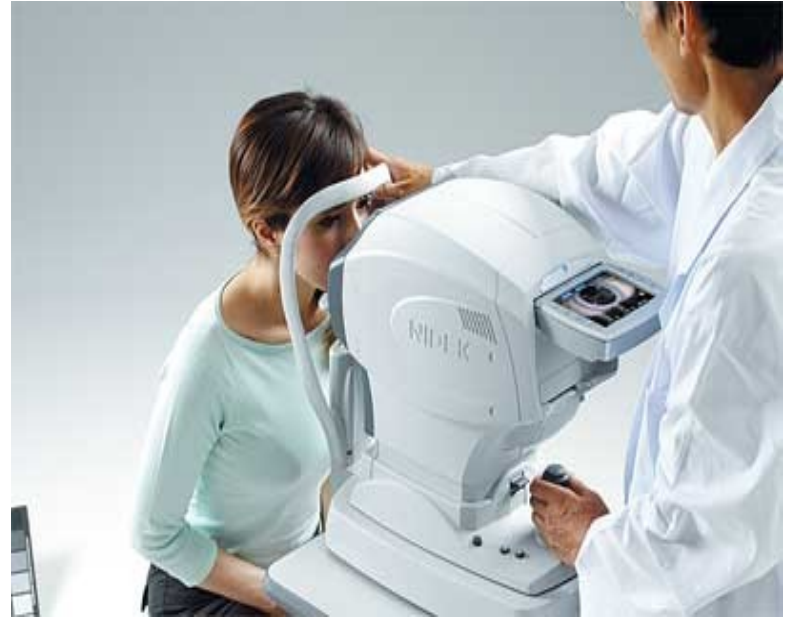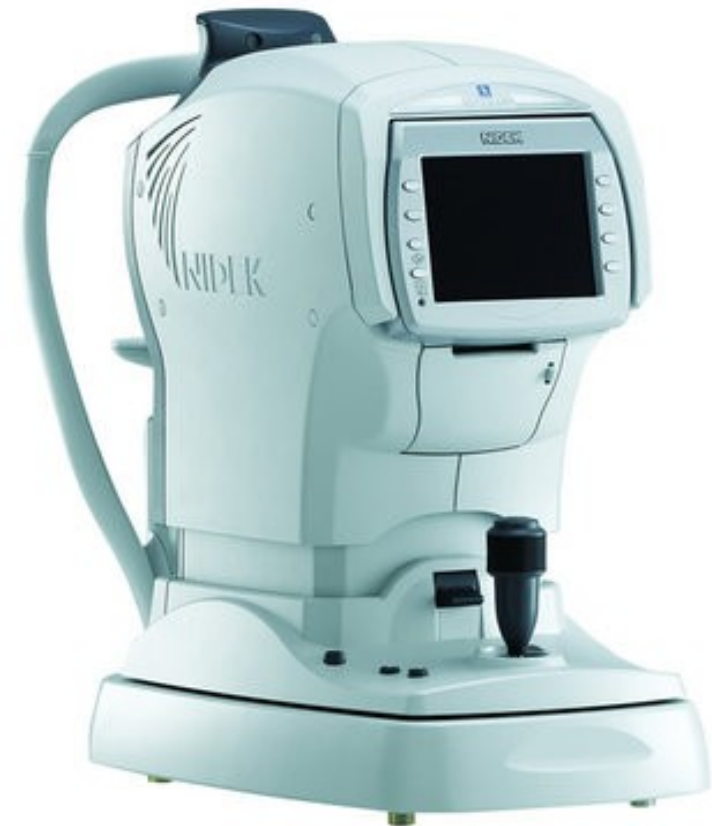- The normal range is 10-21 mmHg
- Topical anesthesia, fluorescein
- Force required to flatten the cornea



Goldmann tonometry

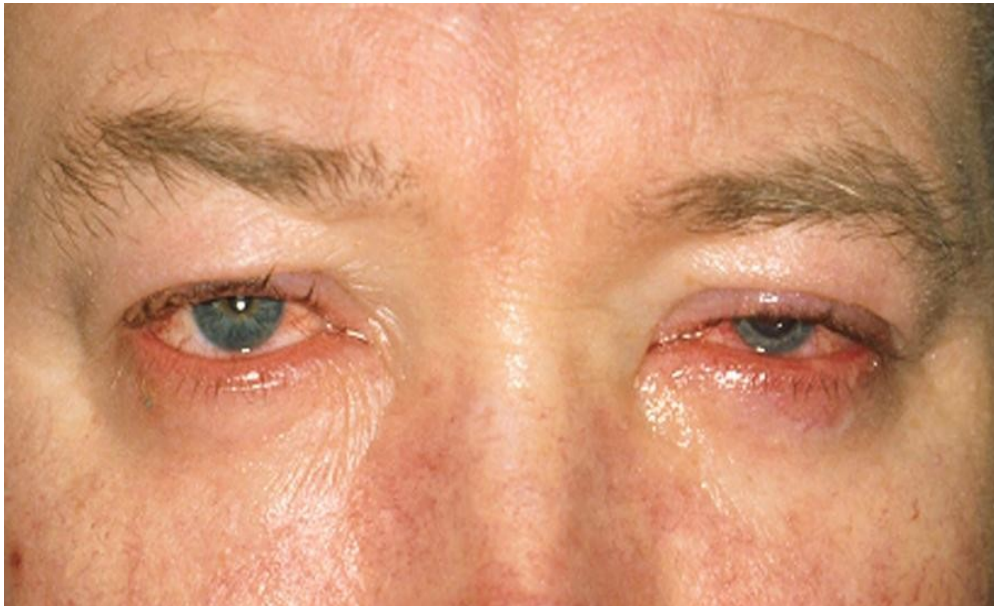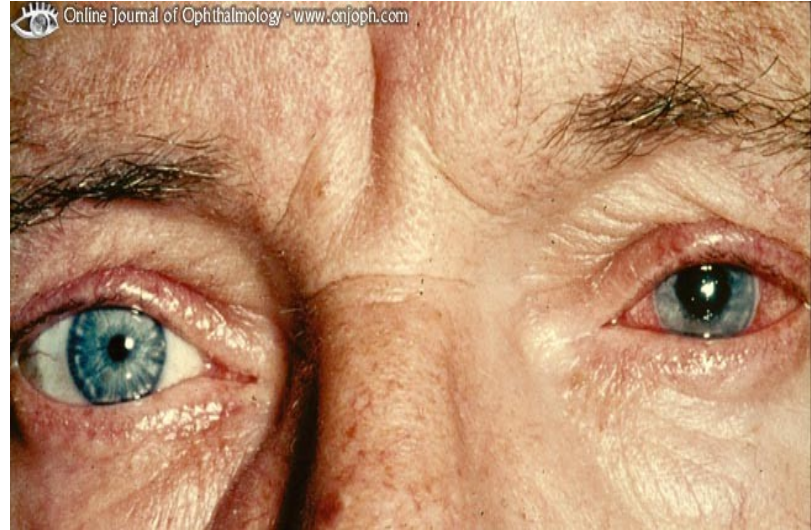


Non contact tonometry



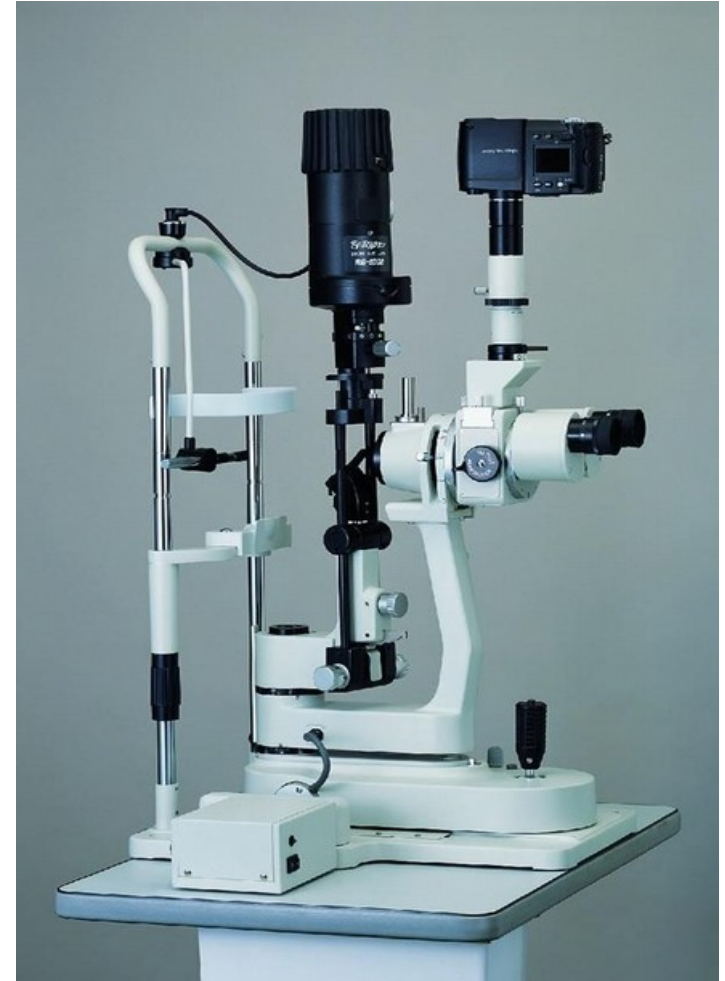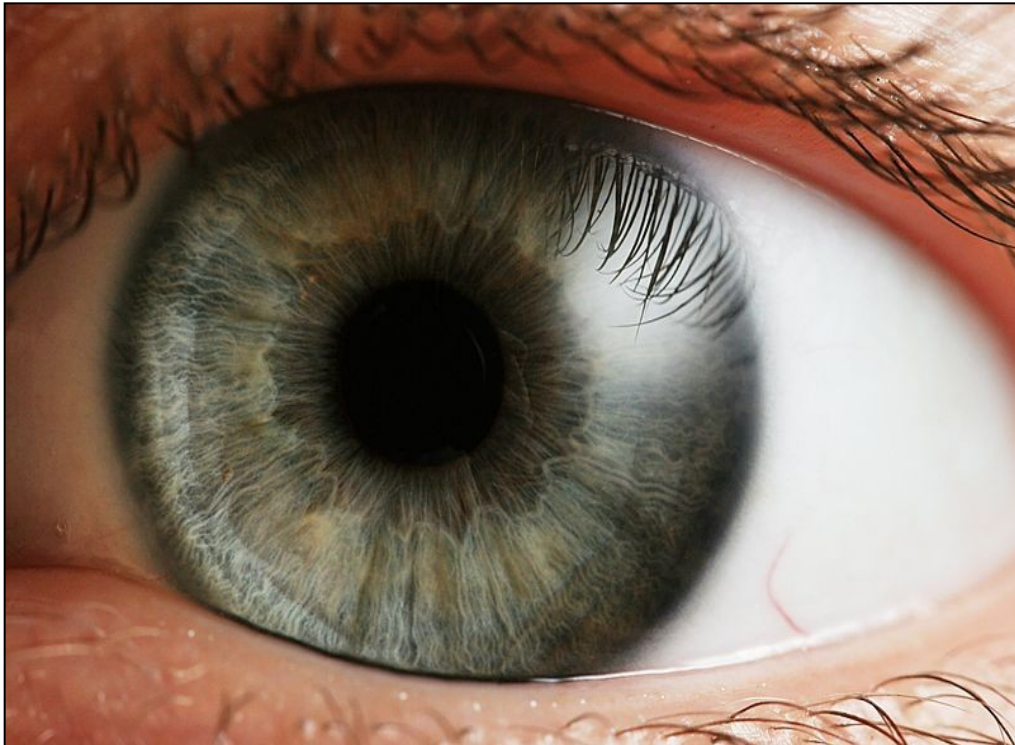
Examination of anterior segment

- Aspection

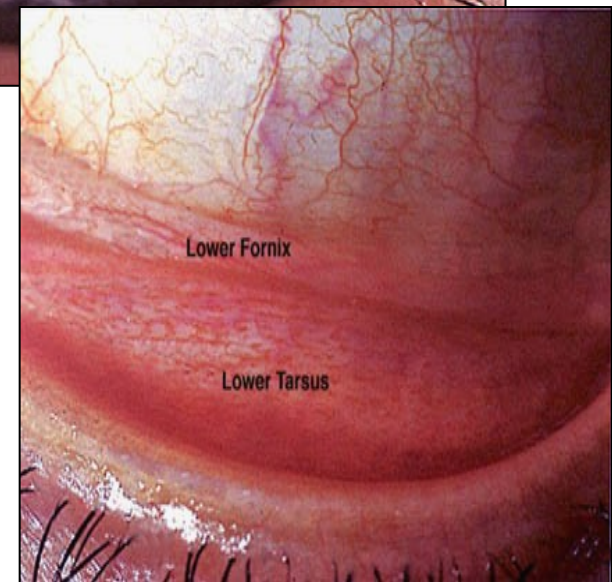
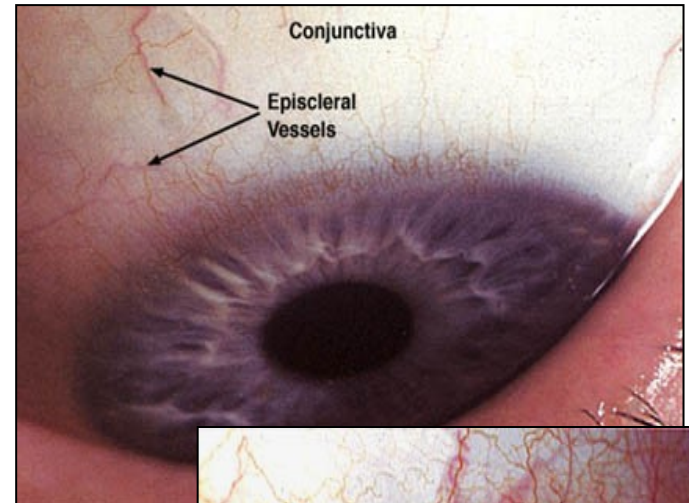
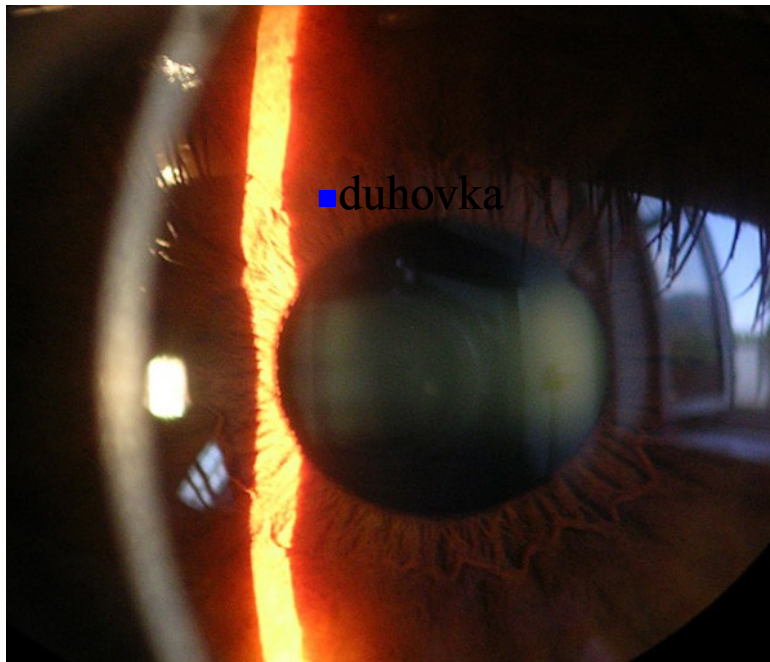


Slit lamp biomicroscopy

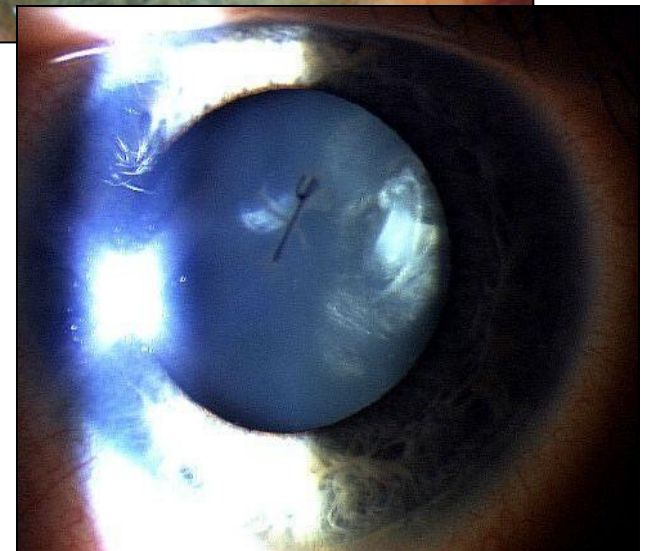
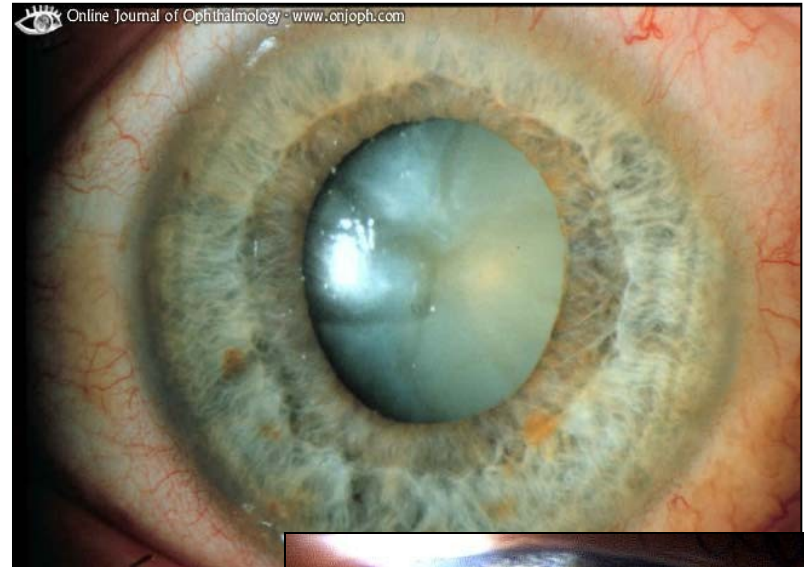
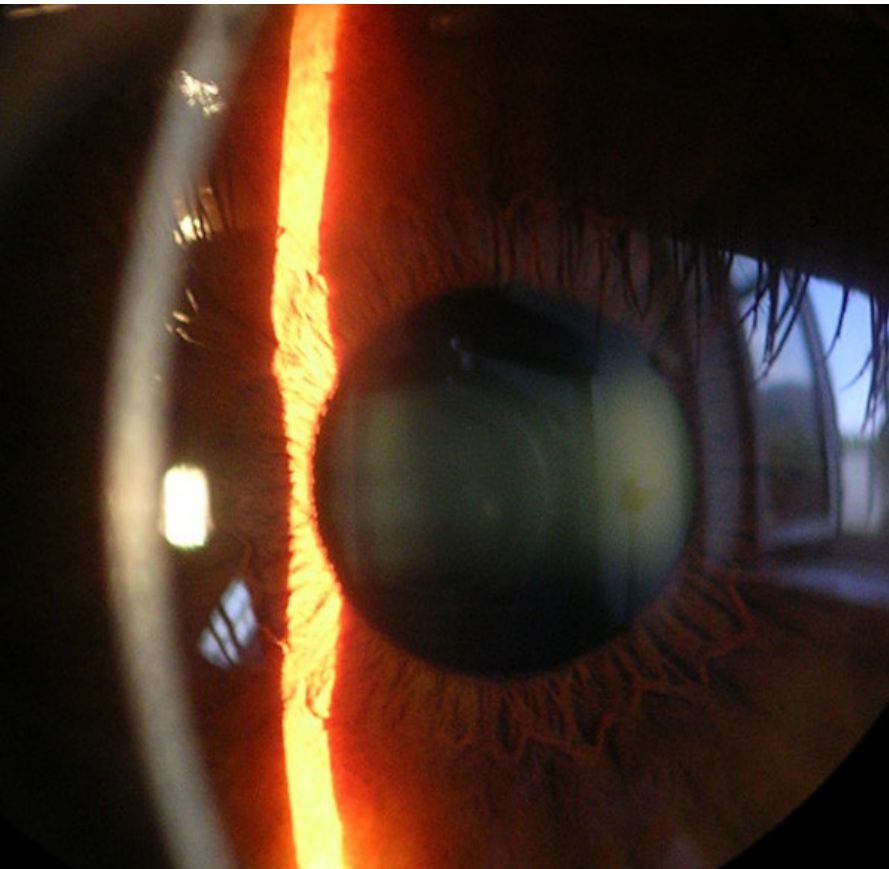
- table mounted microscope with a special adjustable illumination source attached



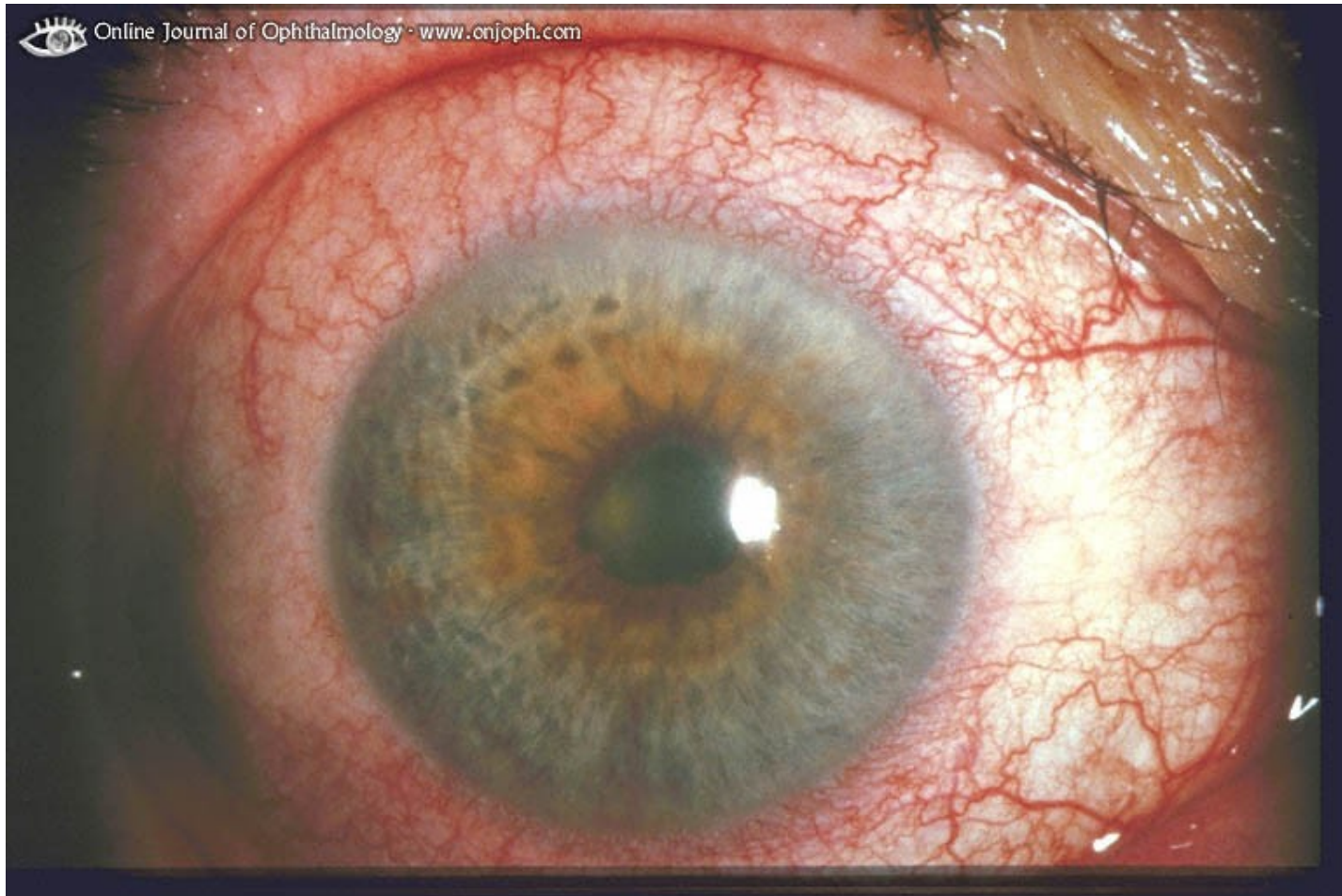Slit lamp biomicroscopy



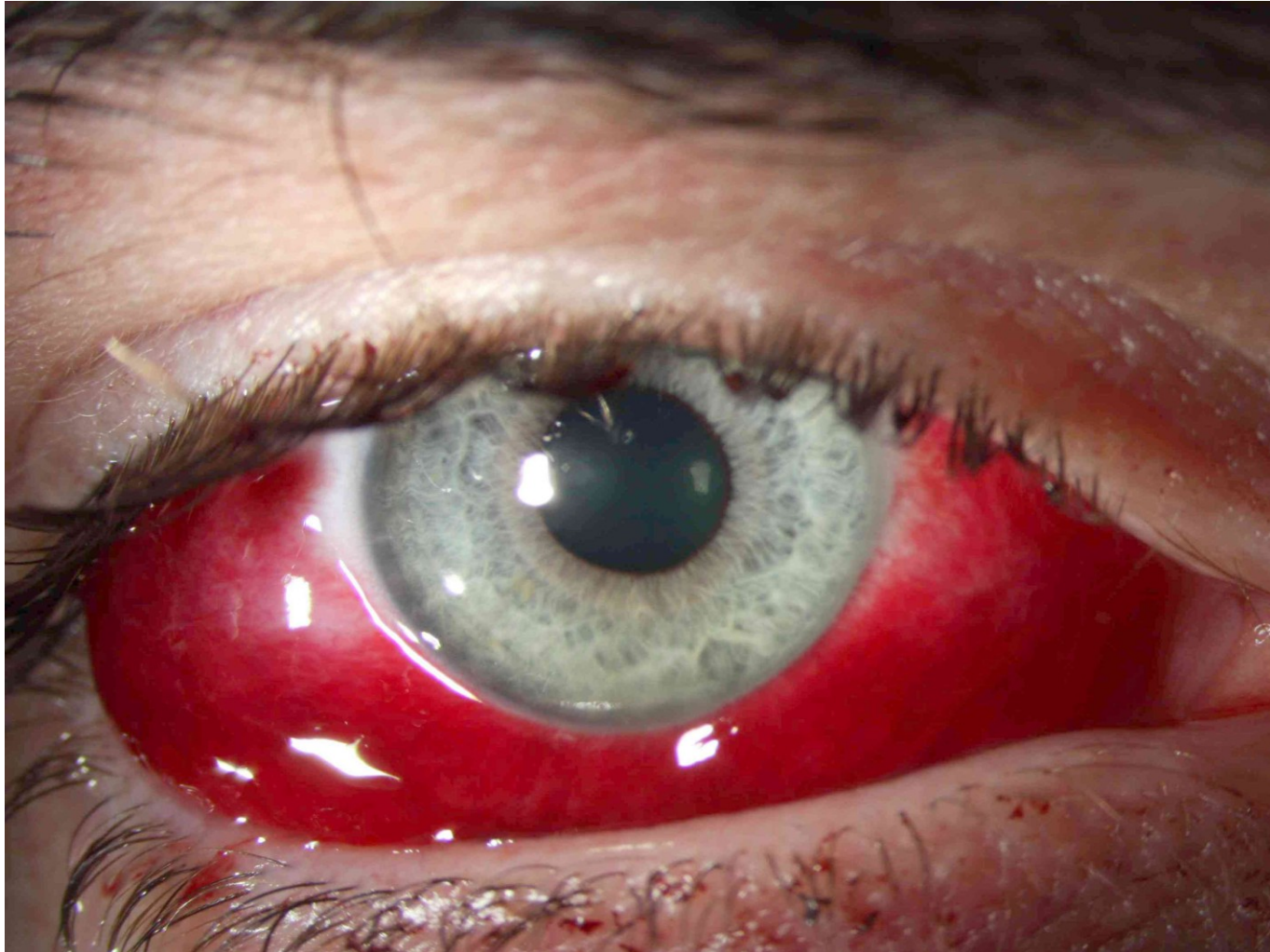
Slit lamp biomicroscopy



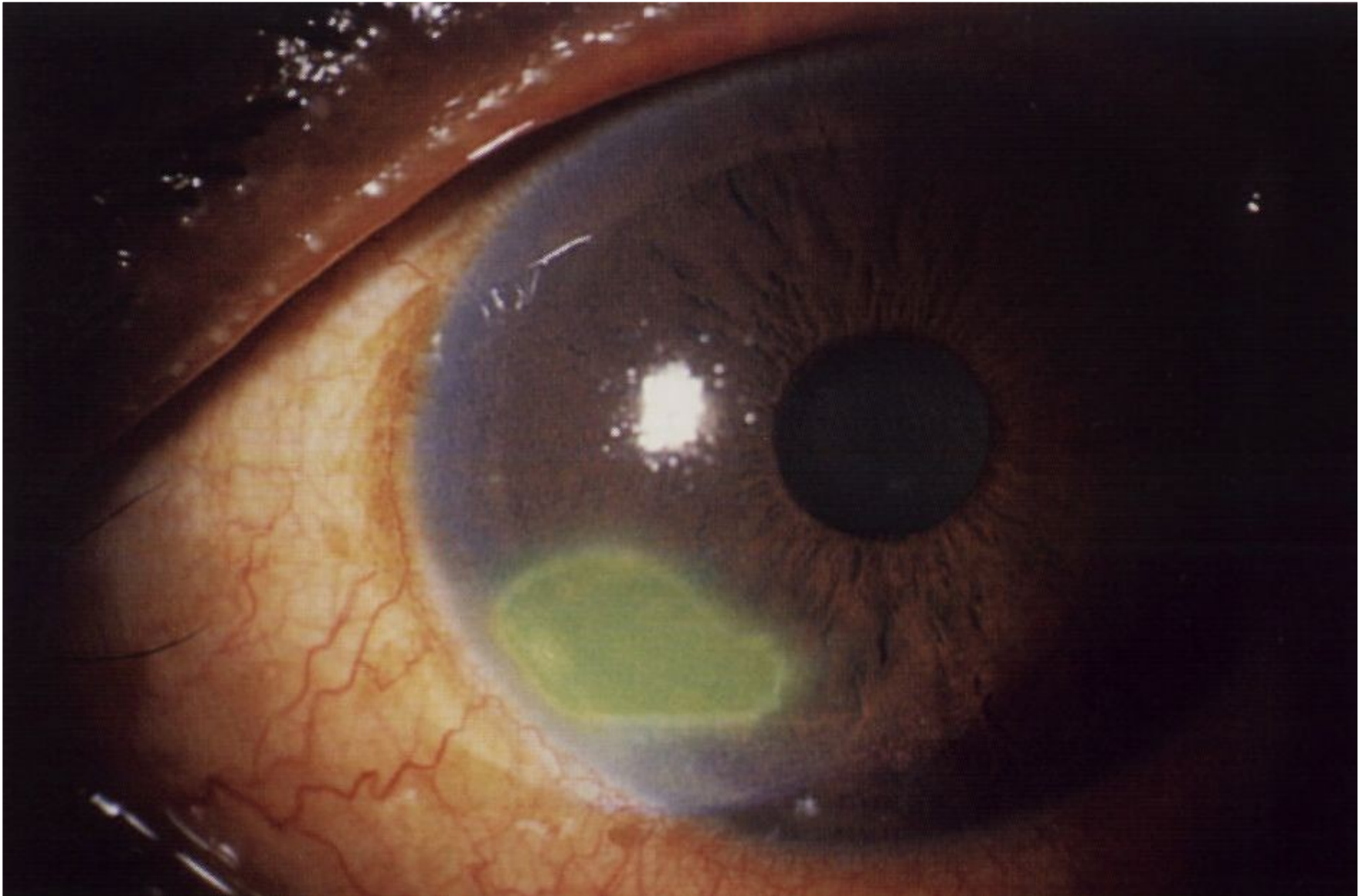
Synechia posterior



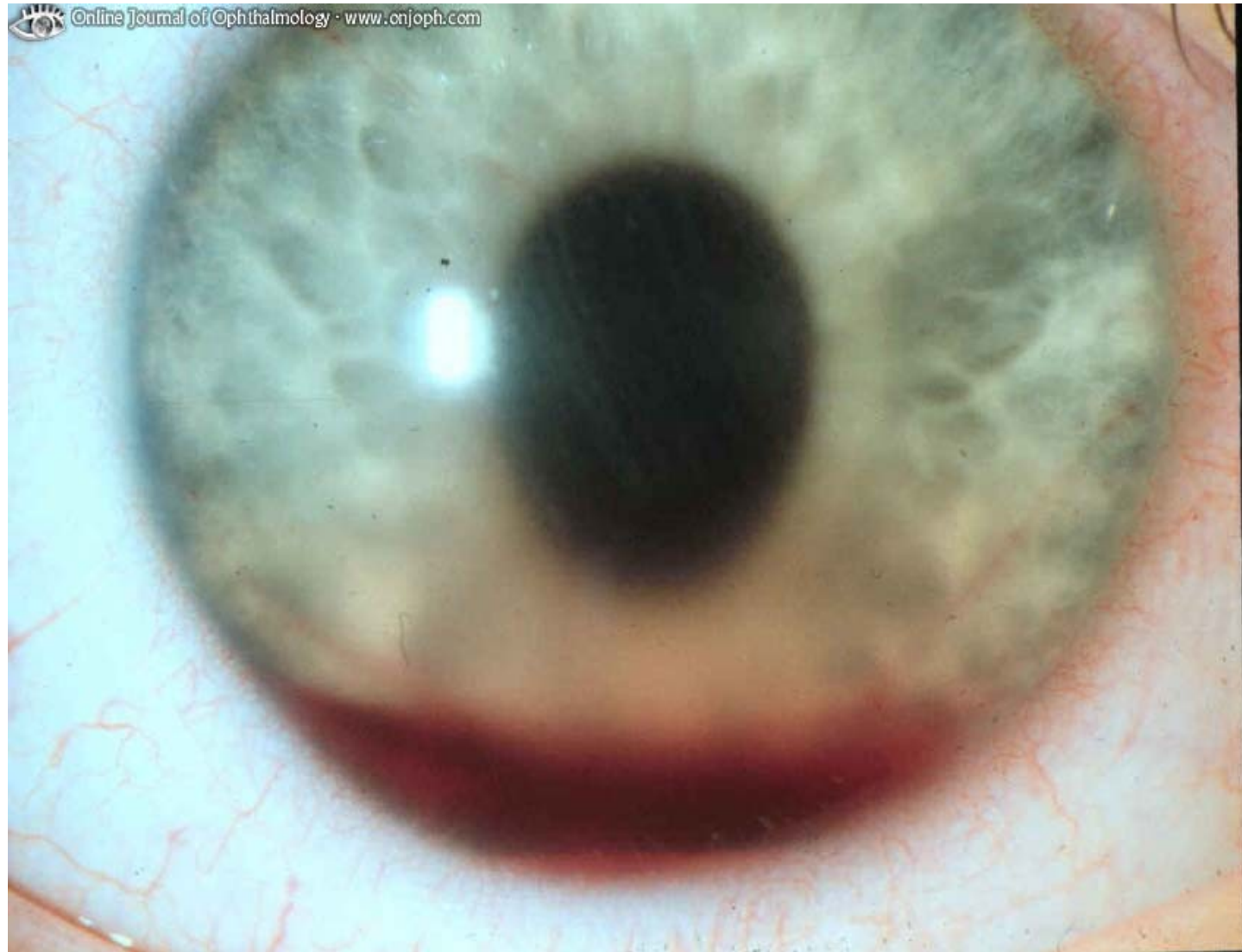
Sunconjunctival haemorrhage



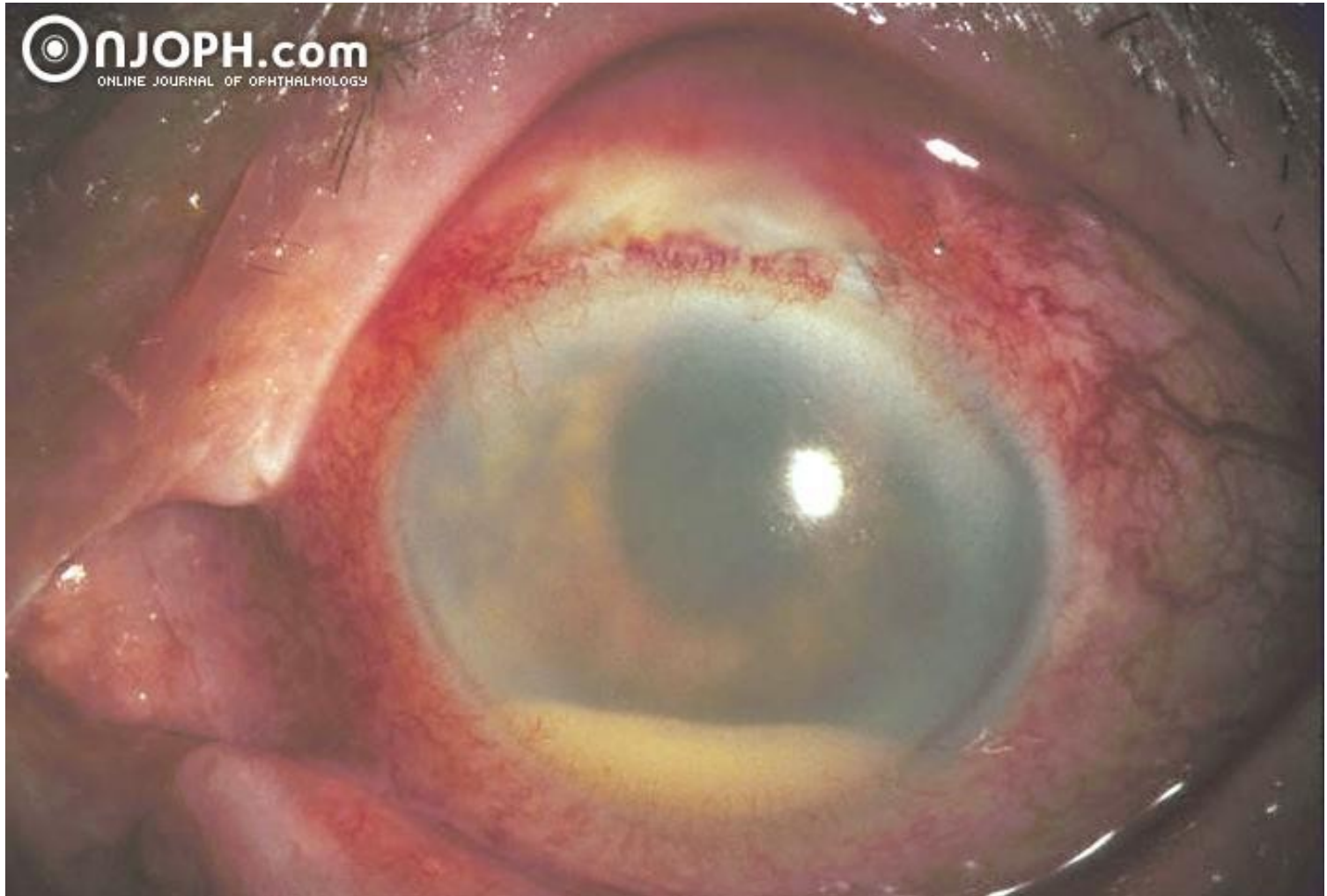Corneal abrasion



Hyphema

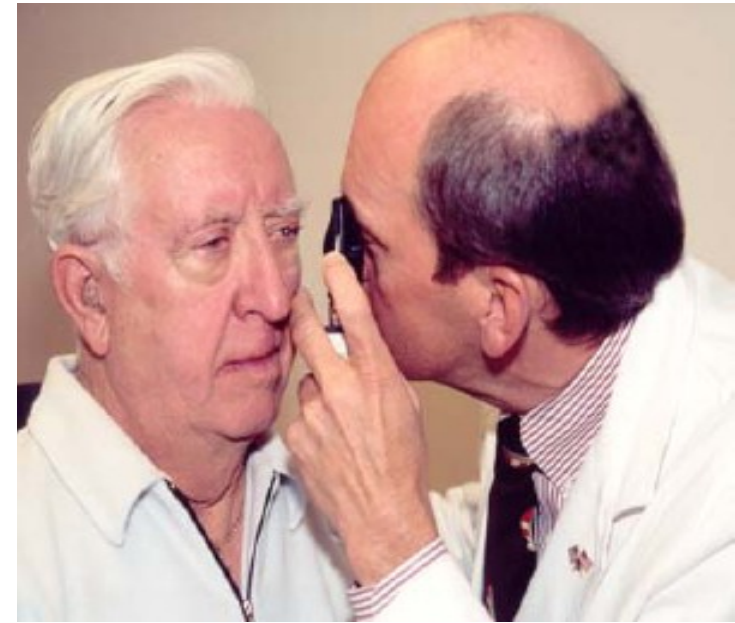
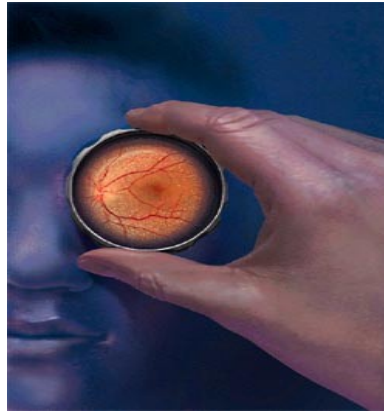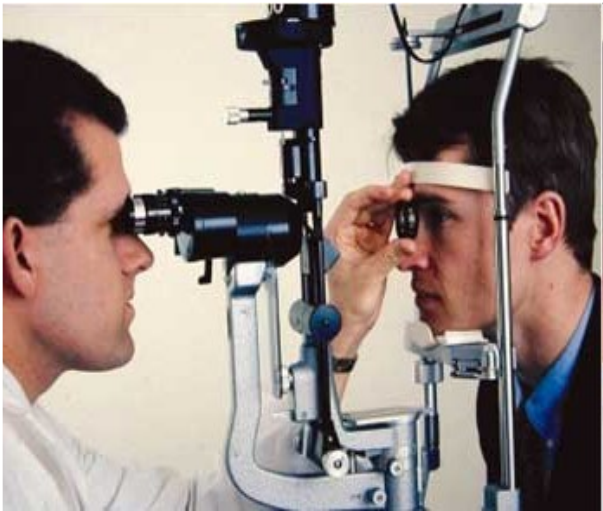


Hypopyon

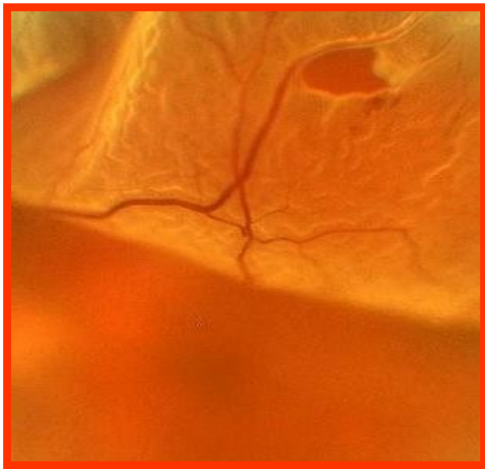
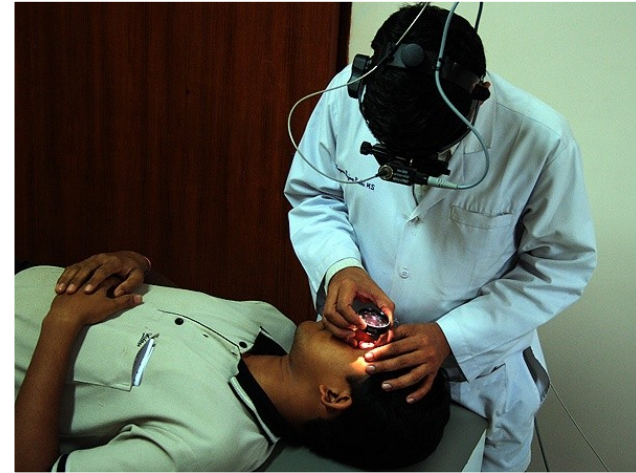
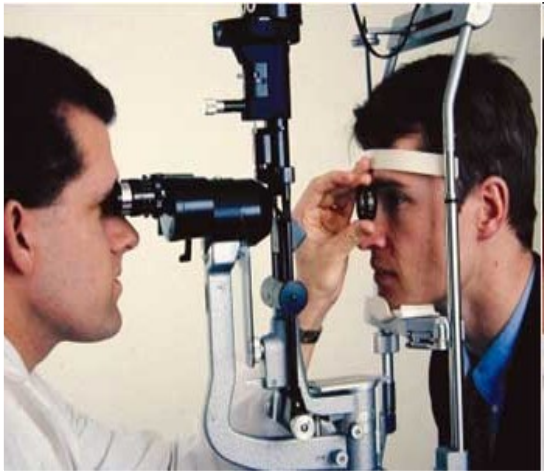Examination of fundus

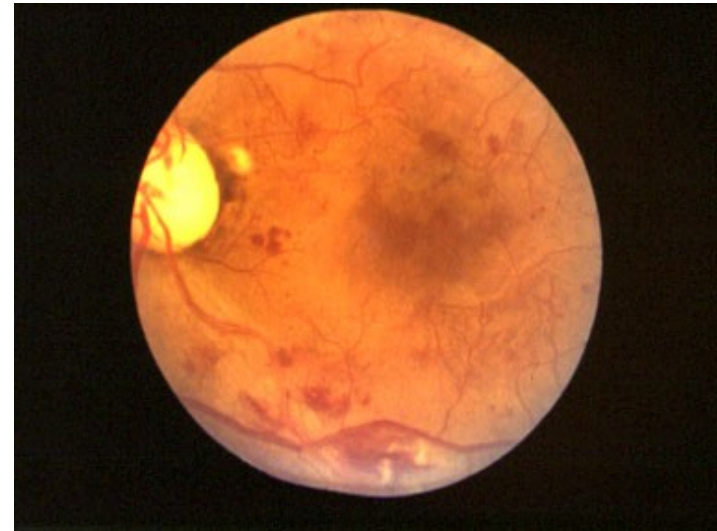
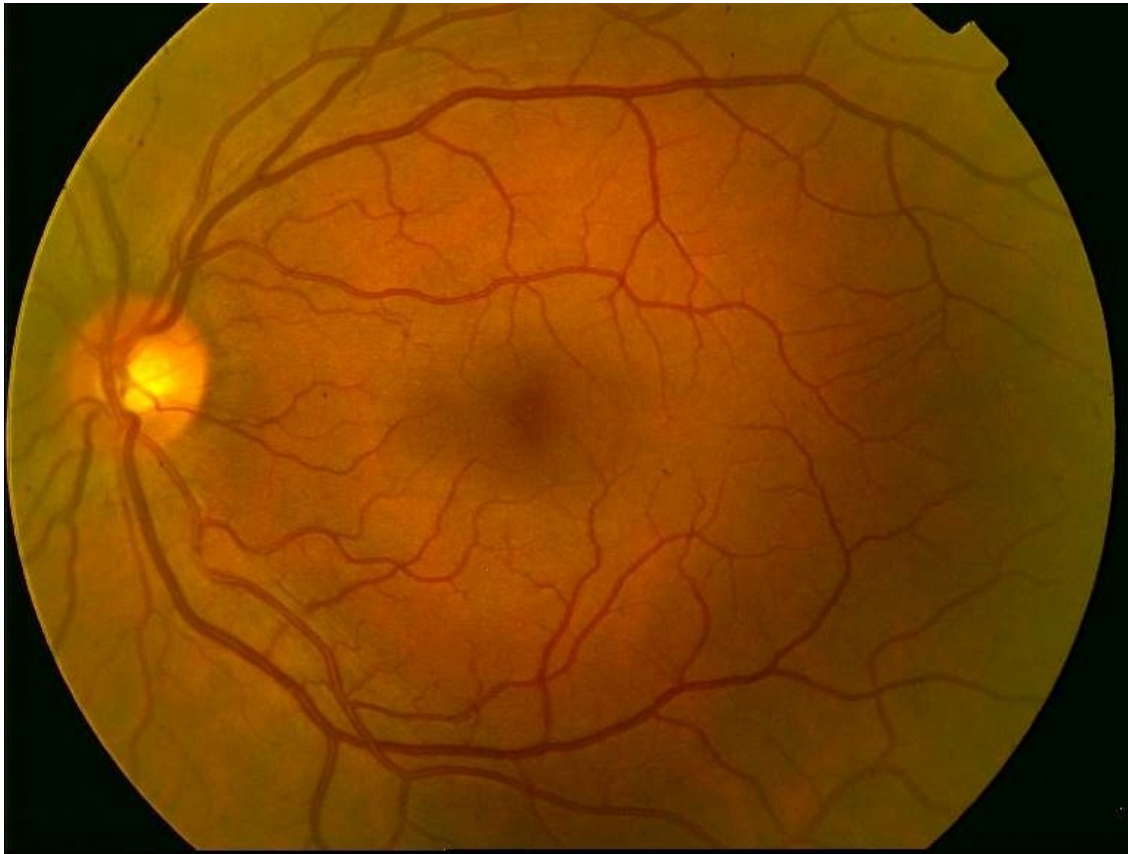
- **Ophthalmoscopy - direct**
- indirect
- **Slit lamp biomicroscopy**
(high power convex lens, the image is vertically inverted and laterally reversed)



	Angle	Angle	Angle
Examination distance (from patient)	constant and patient's eyes	60-90 degrees	30 degrees
Field of view	width of pupil	area length	area depth
Field of view	No	No	Yes
State of the	Examination	Optical	Image

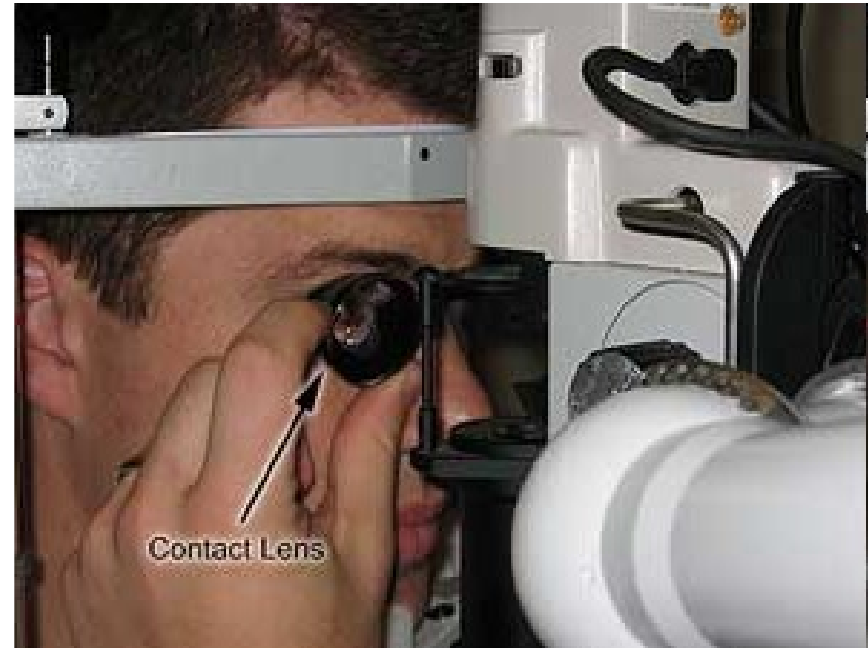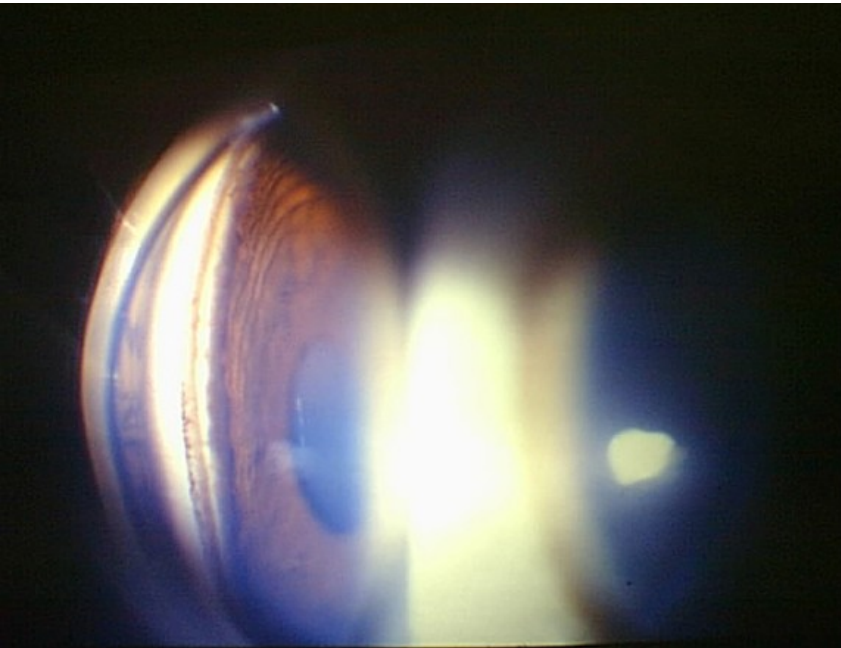


Ocular fundus

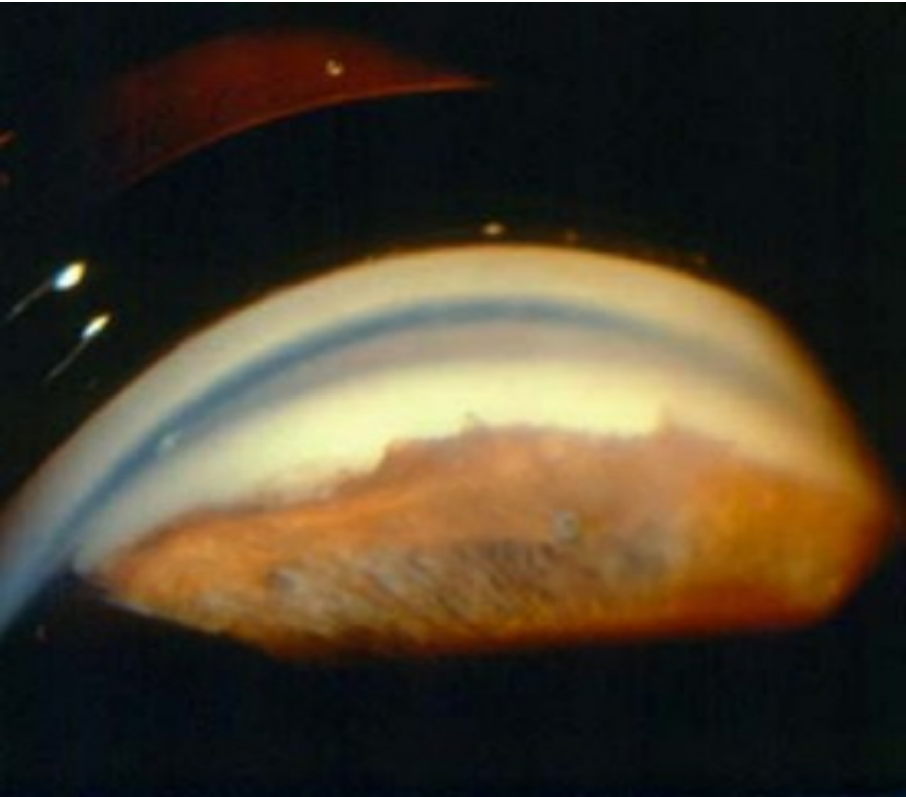

Special examination techniques

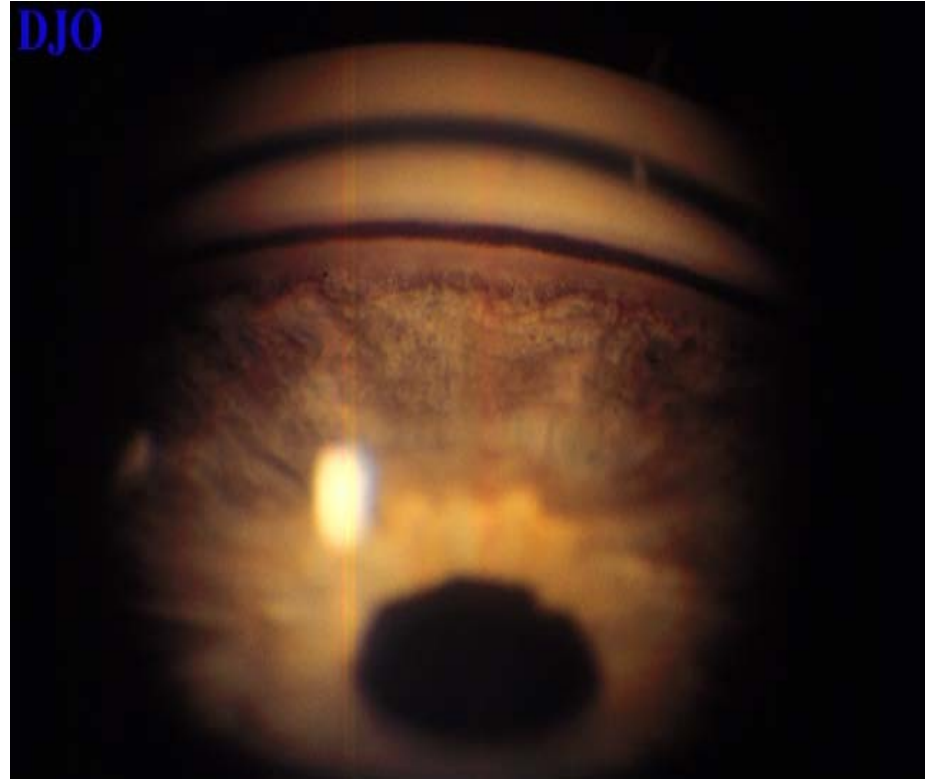
Gonioscopy

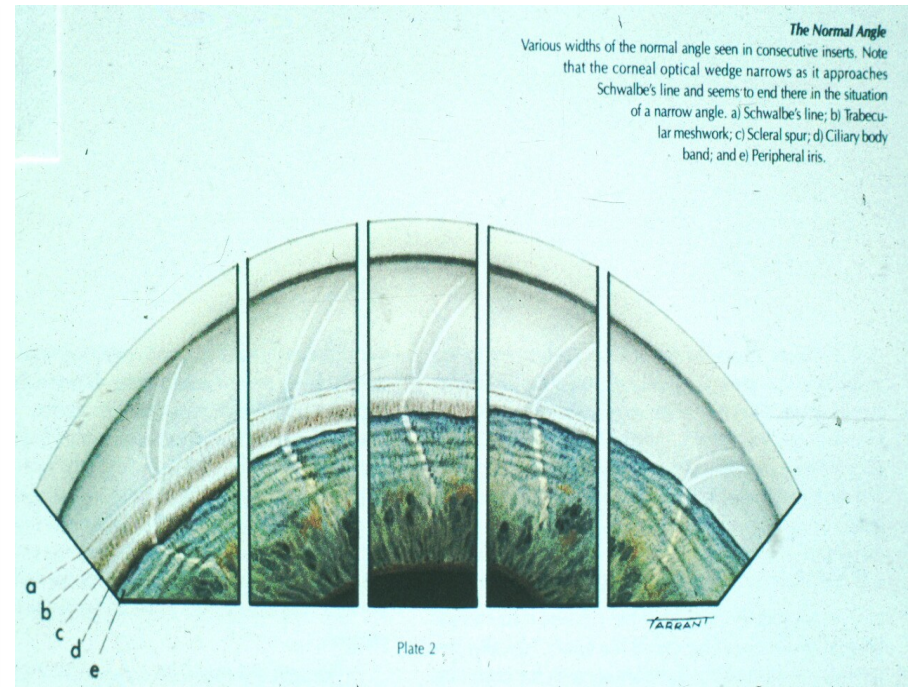
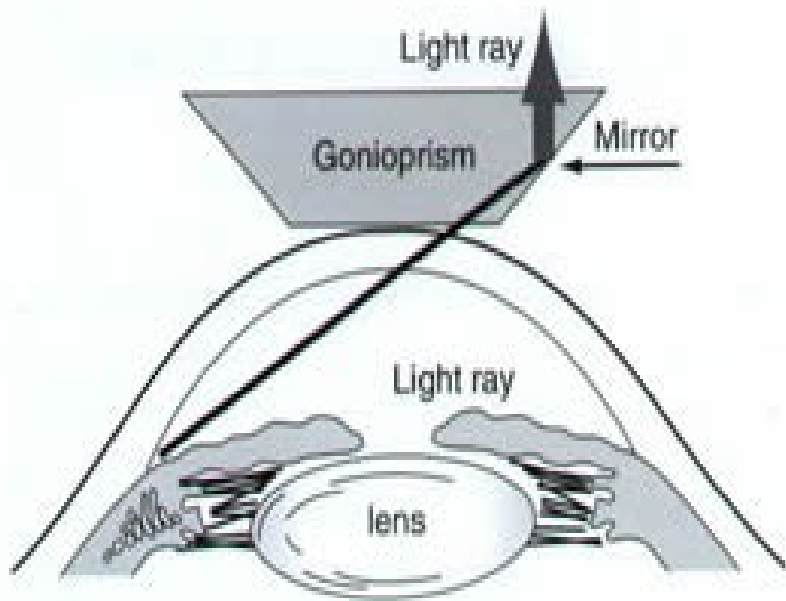


- Gonio lens (mirrors)
- Angle structures
- Fundus examination



DJO





Optical coherence tomography

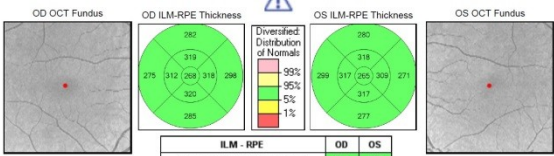
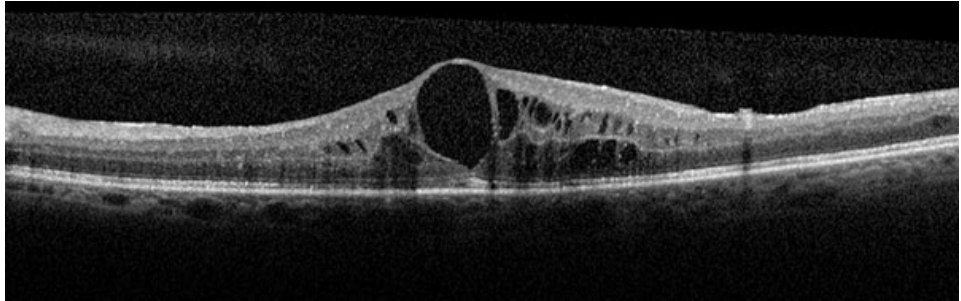
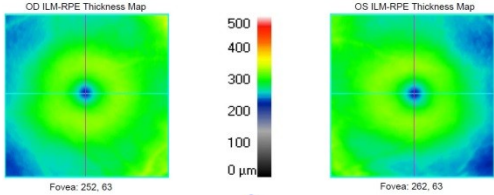
Name:
 ID:
 DOB:
 Gender: Unknown
 Technician: Operator, Cirrus

Exam Date:
 Exam Time:
 Serial Number: 4000-11302
 Signal Strength: 9/10

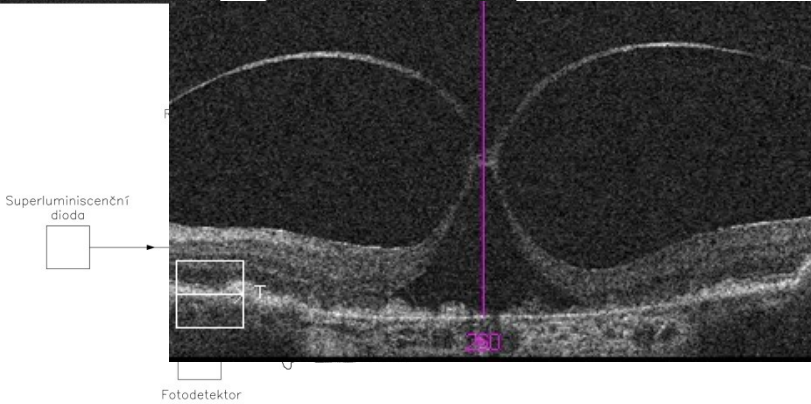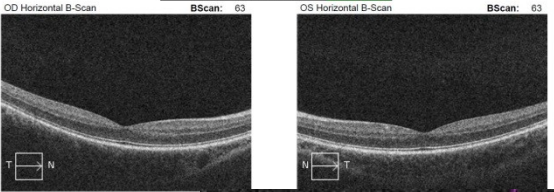
OD OS
 CZMI
 4000-11302
 9/10



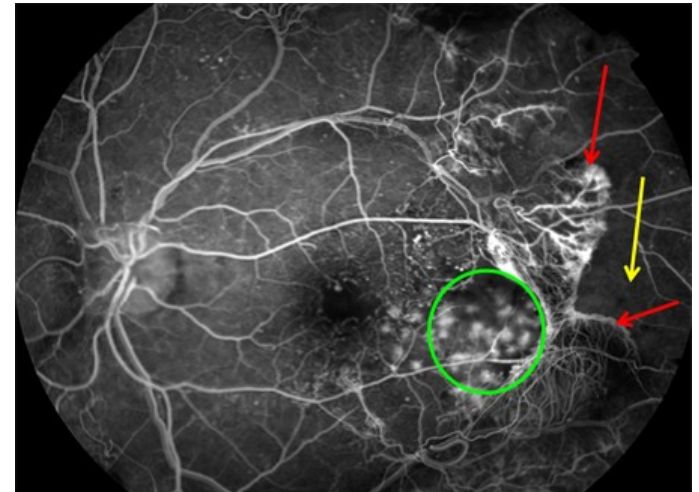
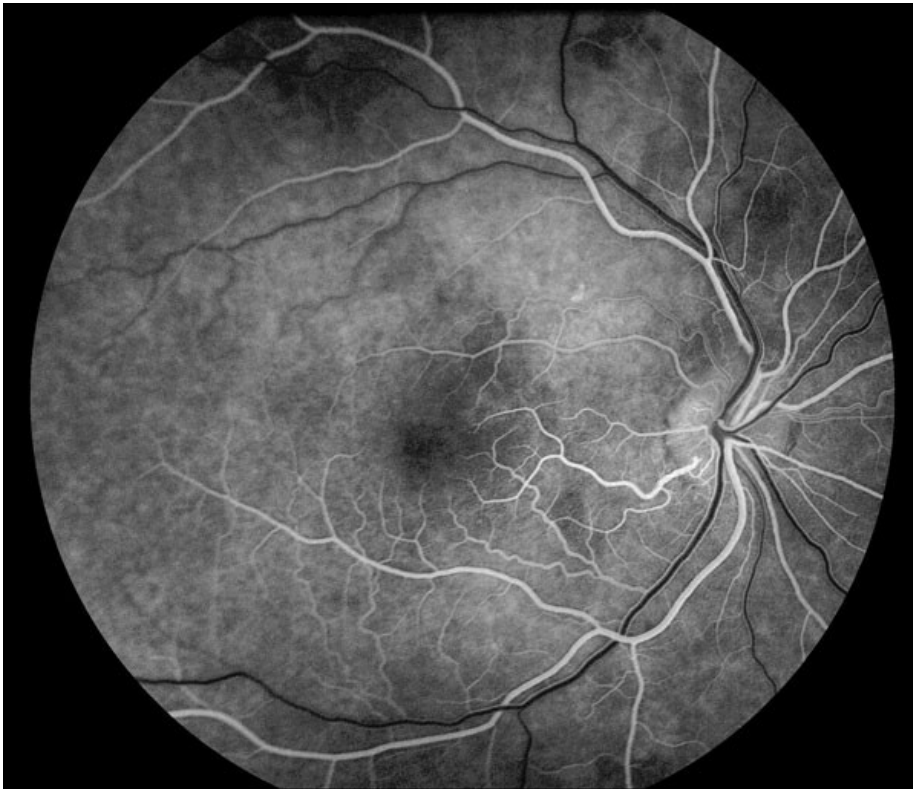
Macula Thickness OU: Macular Cube 512x128 OD ● OS



ILM - RPE		OD	OS
Thickness Central Subfield (μm)		268	265
Volume Cube (mm^3)		10.4	10.3
Thickness Avg Cube (μm)		289	296



Fluorescein angiography

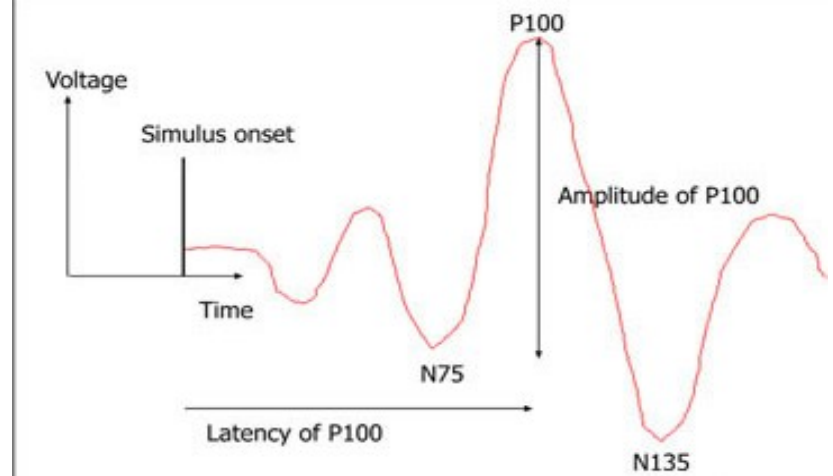
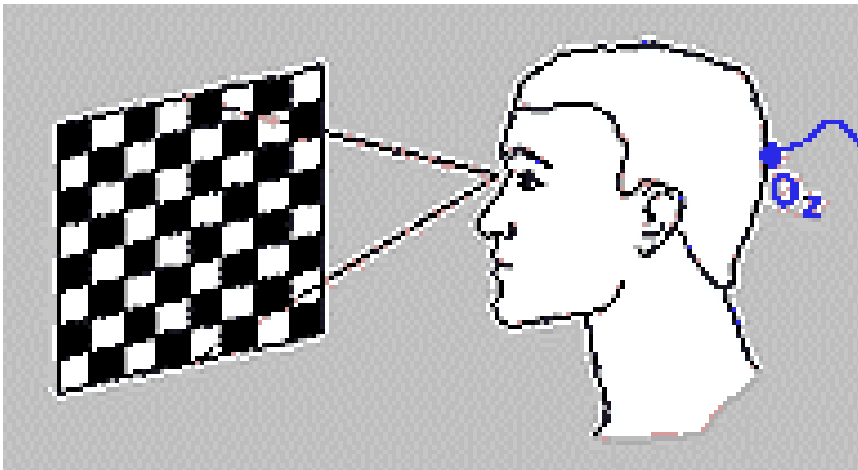


Electrophysical tests

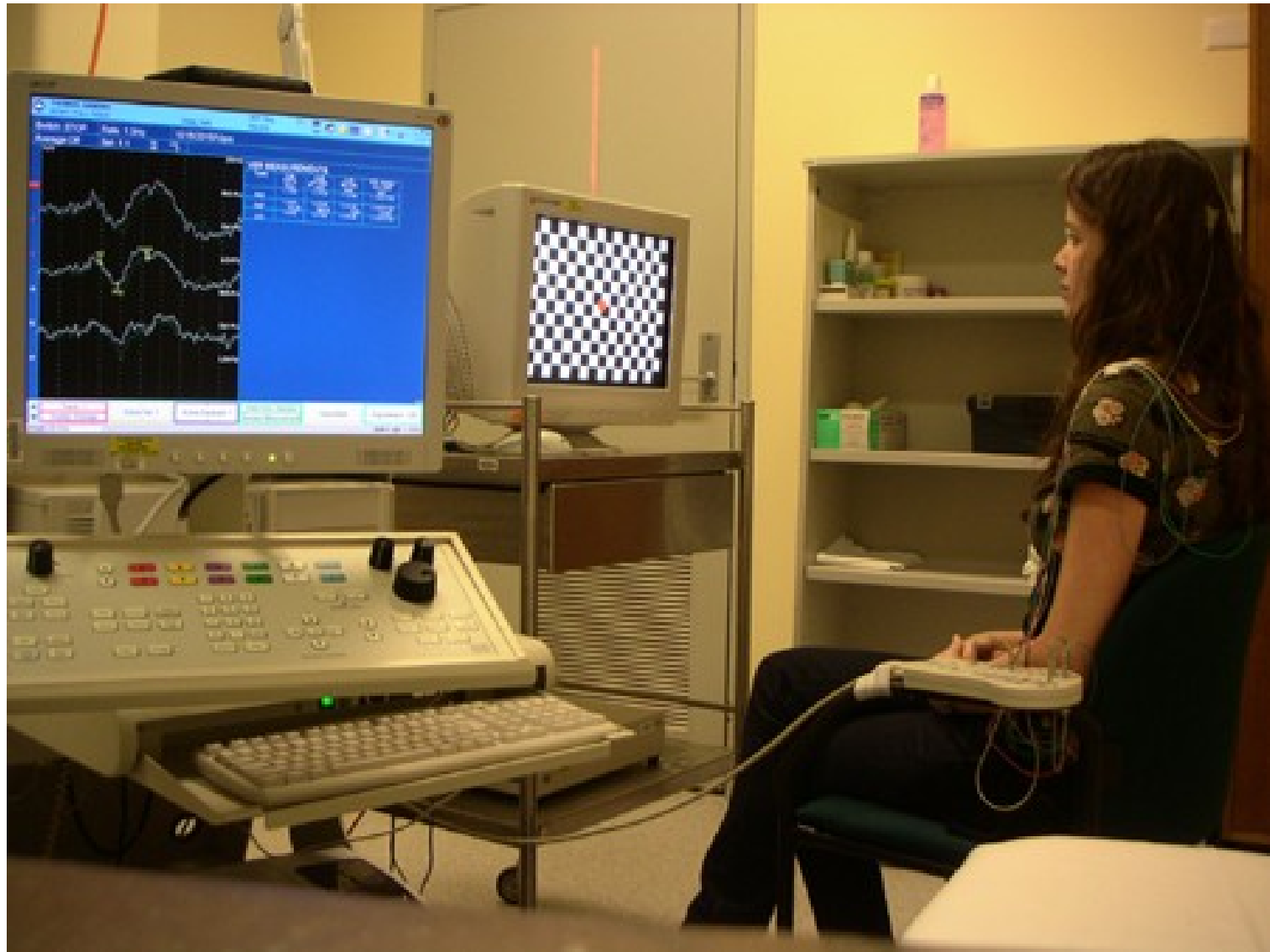
- **ERG (electroretinography)**
diagnosis of functional defects of retina
- Record of an action potential produced by the retina when it is stimulated by light

- **VEP (visual evoked potential)**
-diagnosis of functional defects of visual pathways
- Record of electrical activity of the visual cortex created by stimulation of the retina

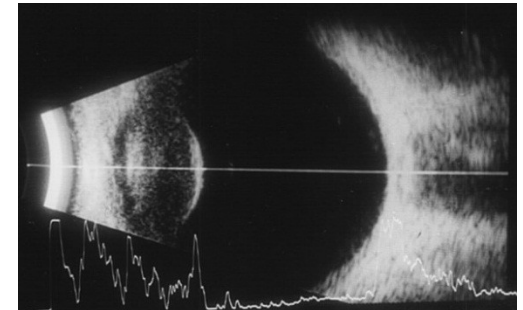
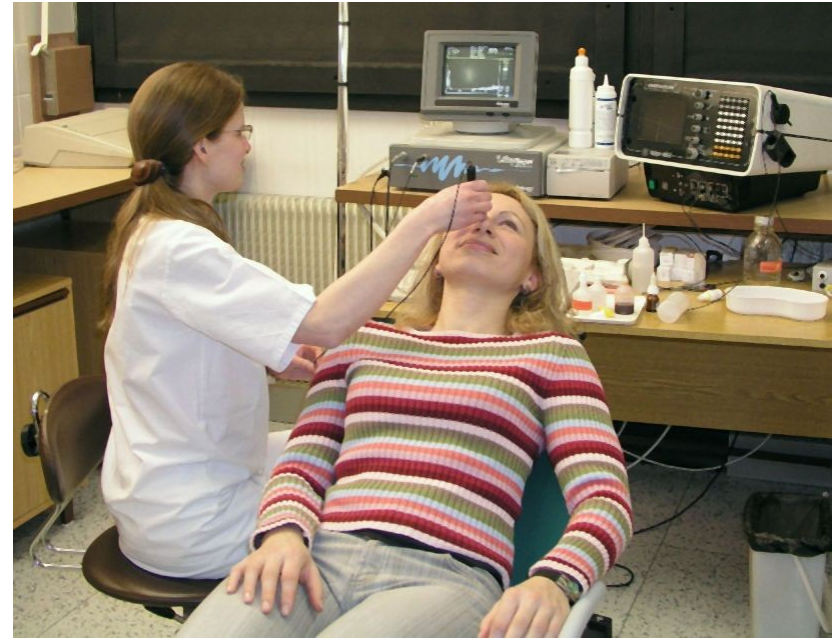Electrophysical tests



Electrophysiological tests

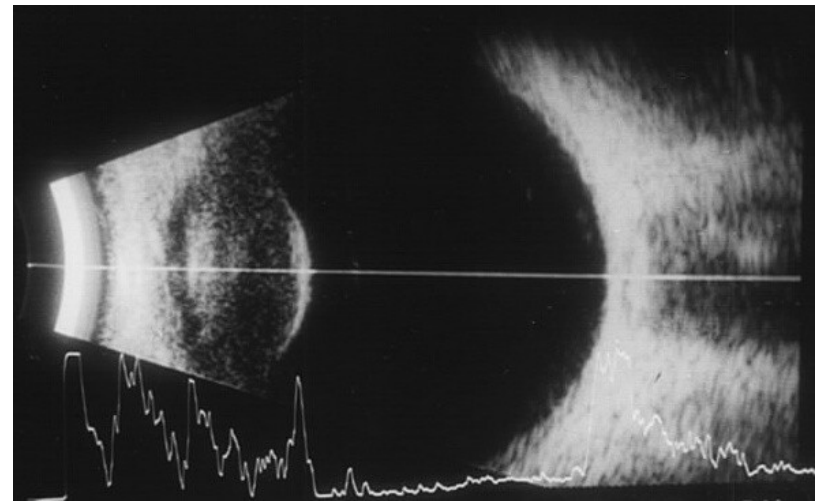
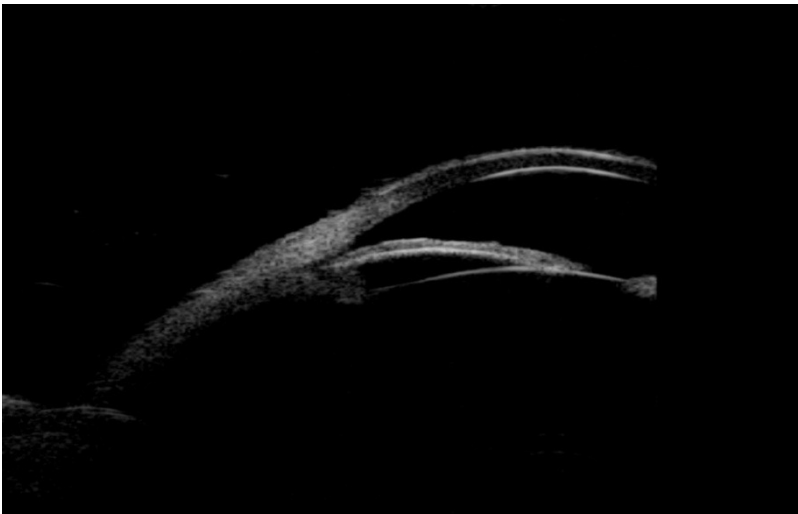


Ultrasound

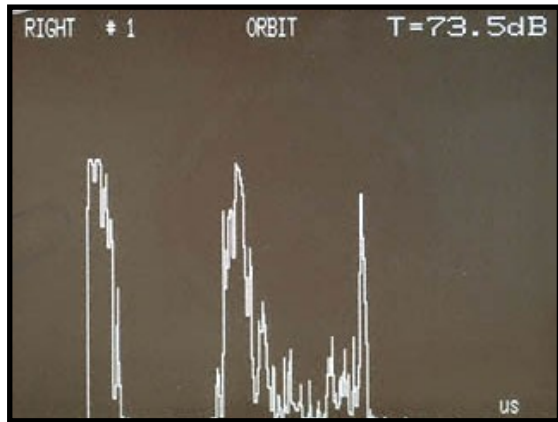


Ultrasound

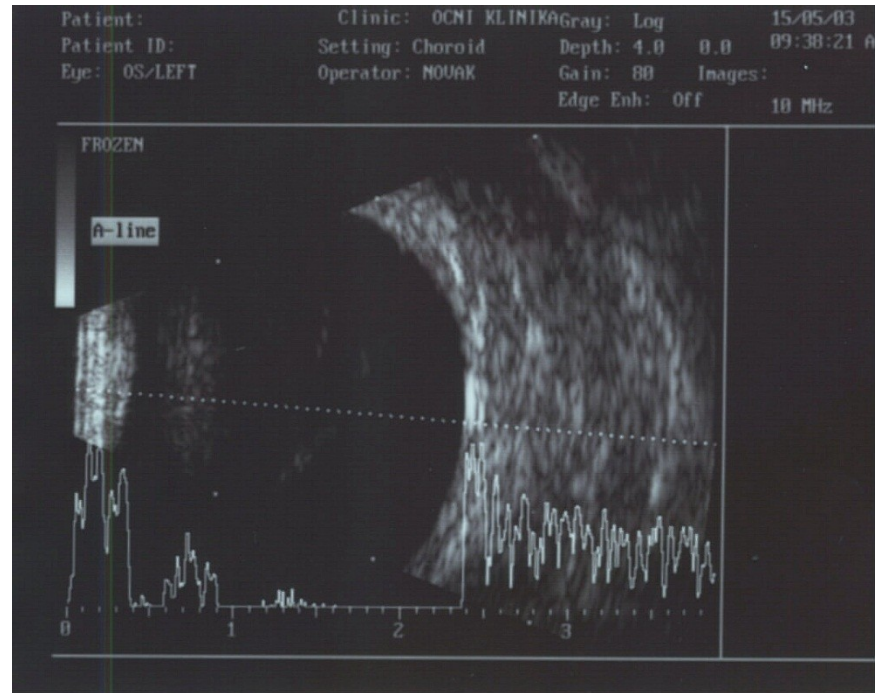
- Non transparent optical media
- UBM- high frequency ultrasound – imaging of anterior segment



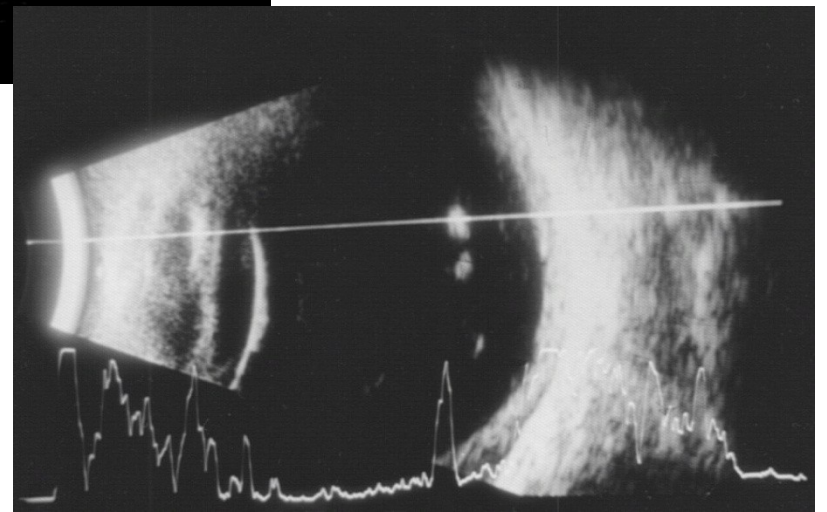
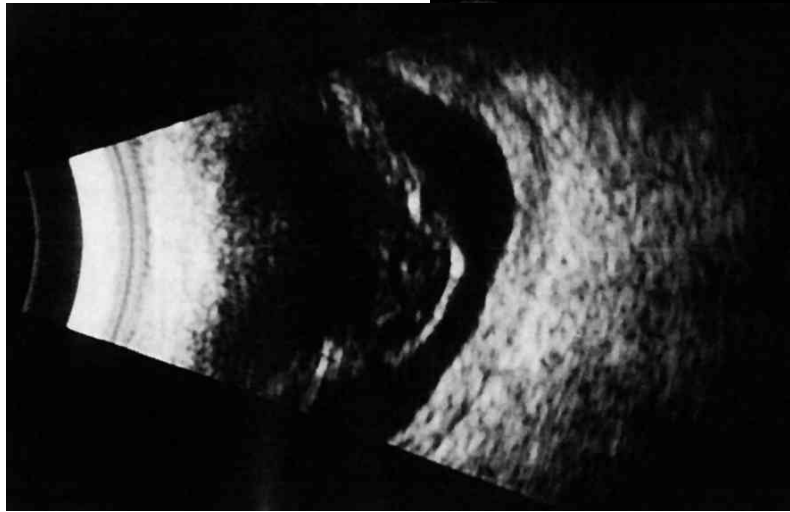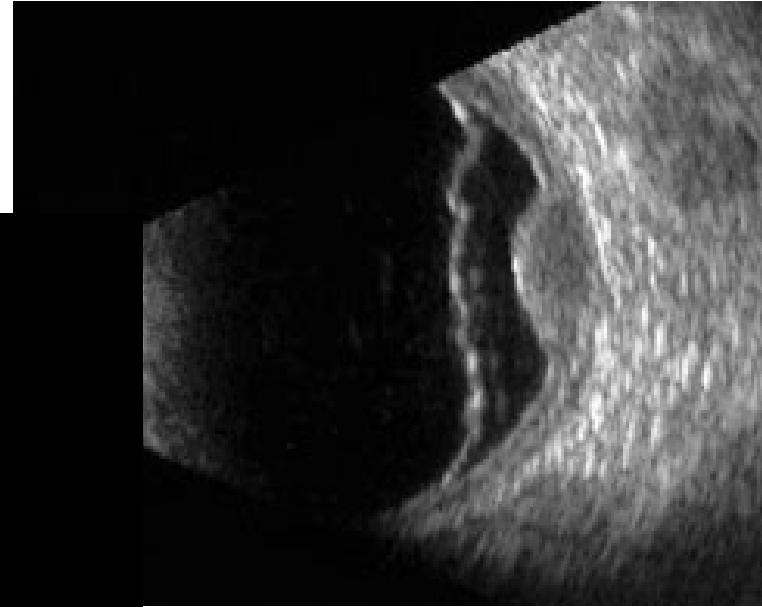
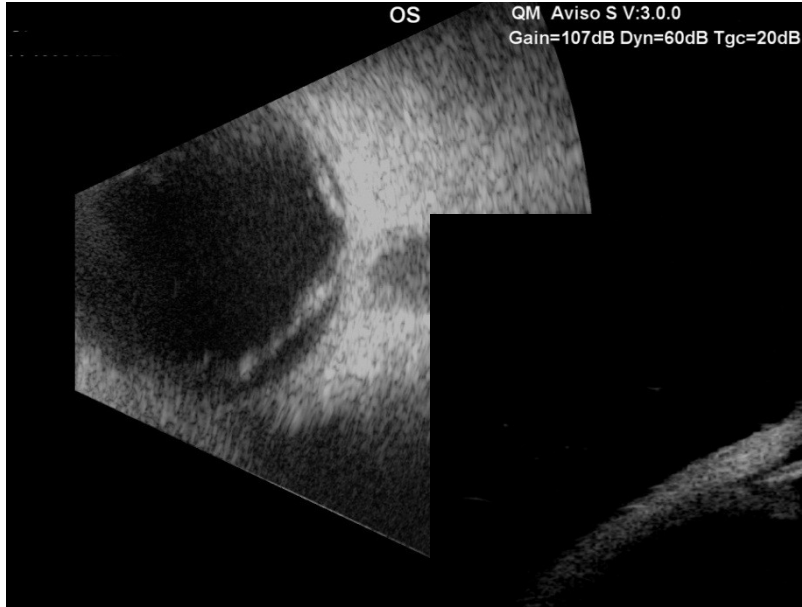
- **A scan (biometry)**




- **B scan**



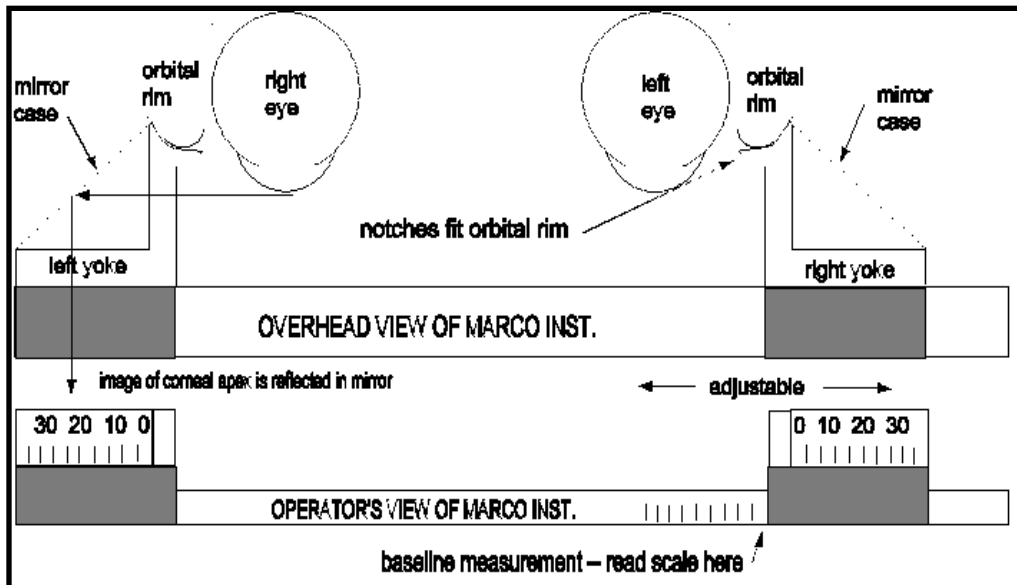


Ultrasound



Color vision – HUE test



Hertl exoftalmometry



Děkuji za pozornost!

