

FAKULTNÍ
NEMOCNICE
U SV. ANNY
V BRNĚ



Ear II

**ENT Clinic of Masaryk university, Brno
Faculty St. Ann Hospital**

Head: Ass.prof. Gál Břetislav, MD, Ph.D.

Pekařská 53, Brno , 656 91

Disorder of the ear

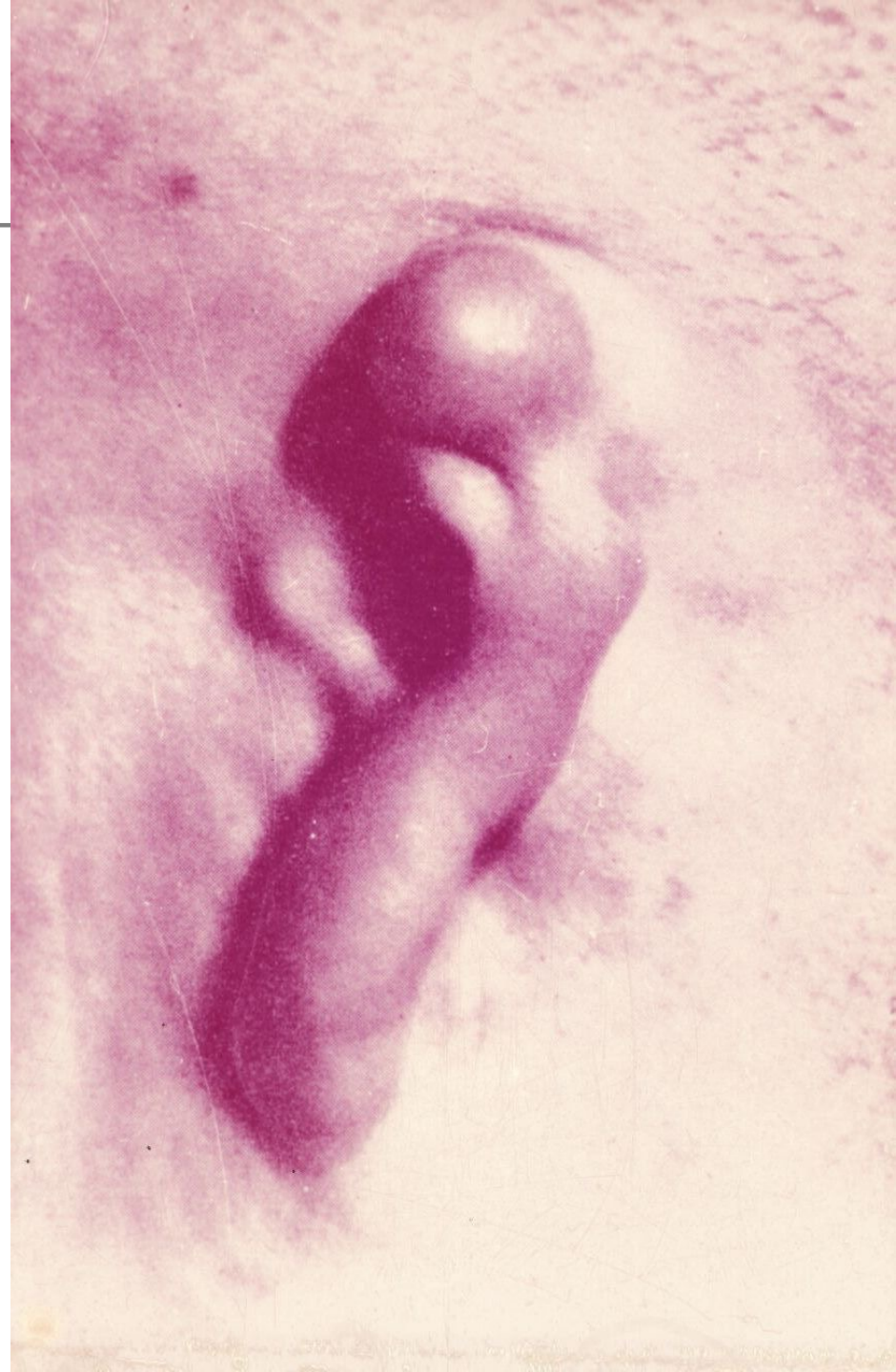congenital anomalies

inflammations

tumors

injuries

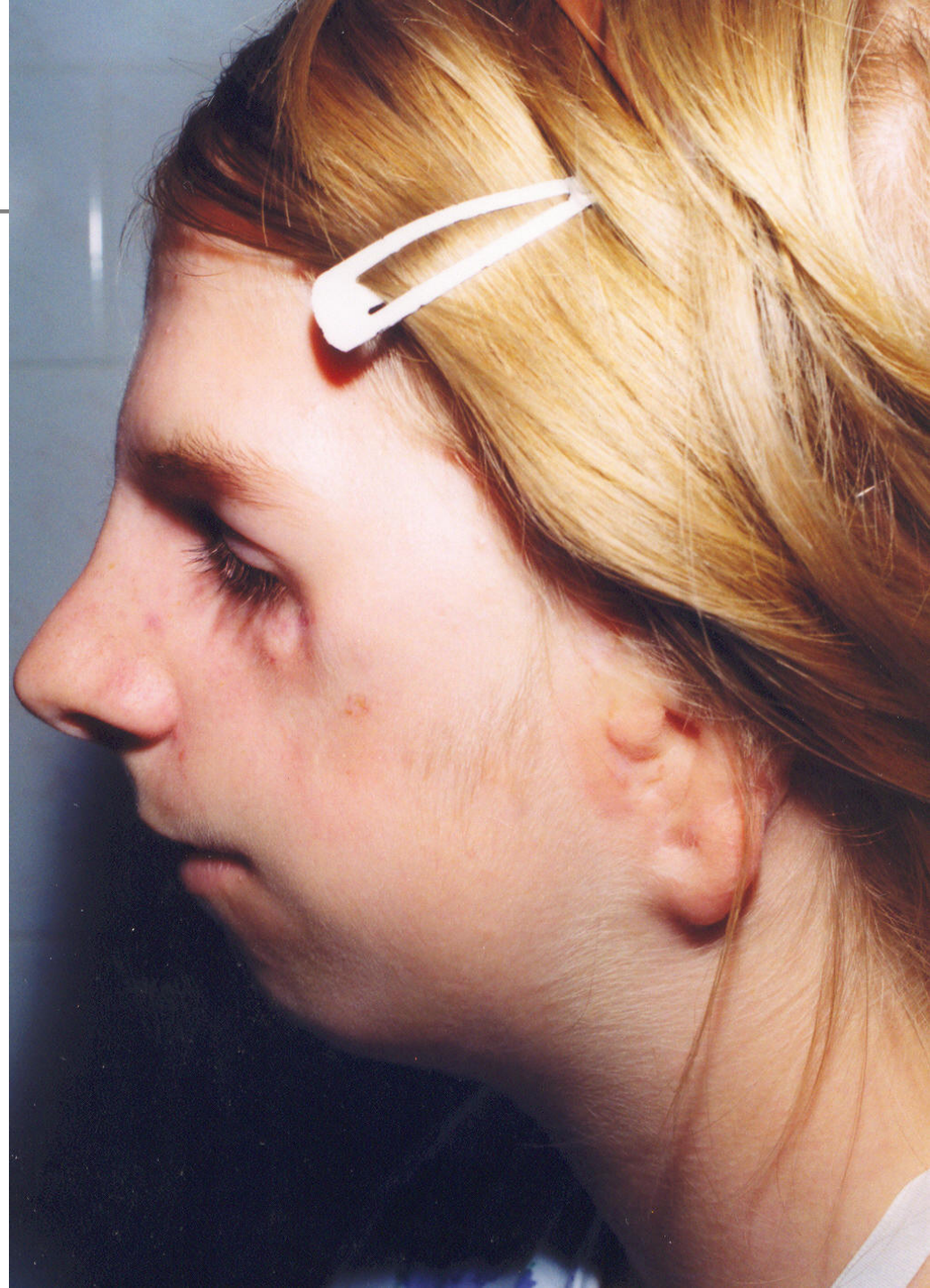Microotia III. St.



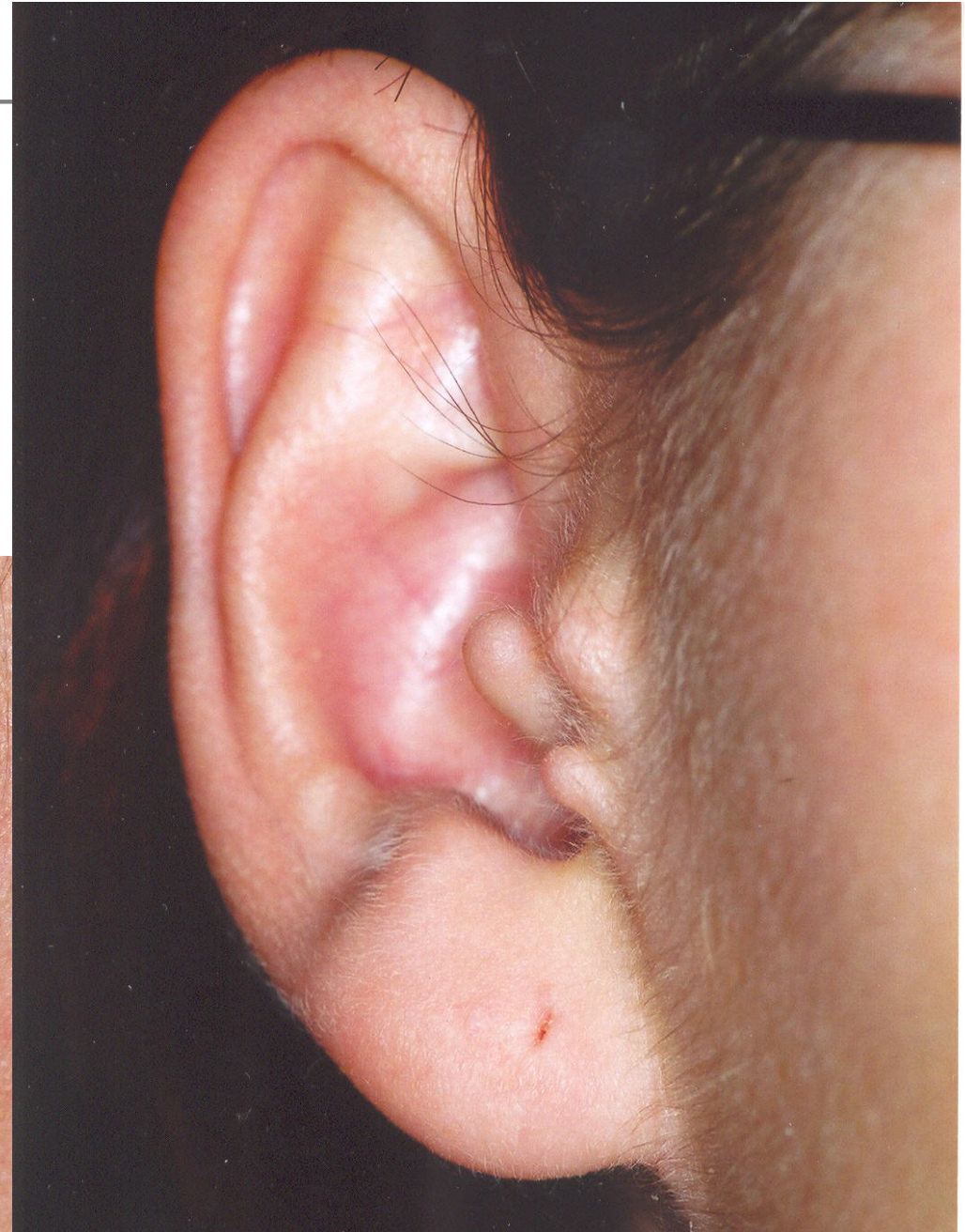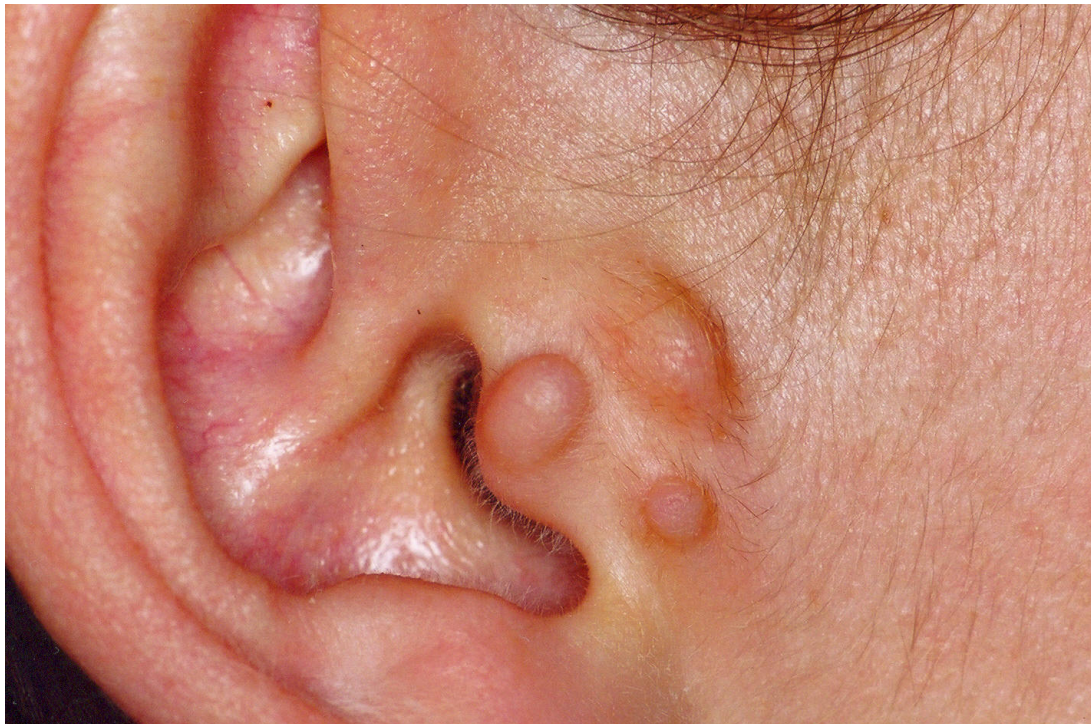Microotia Treacher-Collins syndrome

Most affected individuals have **underdeveloped facial bones**, particularly the cheek bones, and a very small jaw and chin (micrognathia). **Conductive Hearing loss** in about half of all affected individuals; - defects or by **underdevelopment of the external meatus**.

People with Treacher Collins syndrome usually have **normal intelligence**.

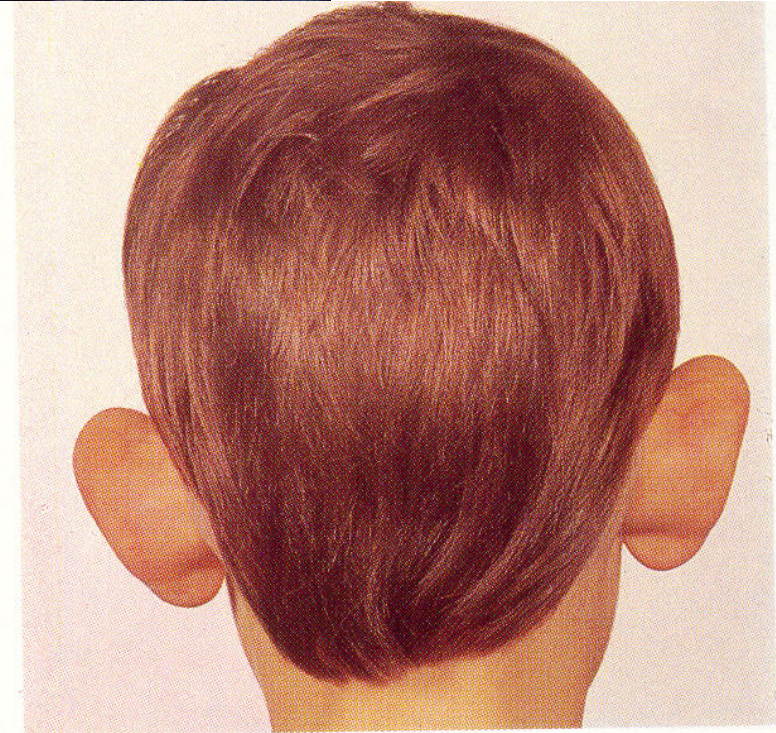
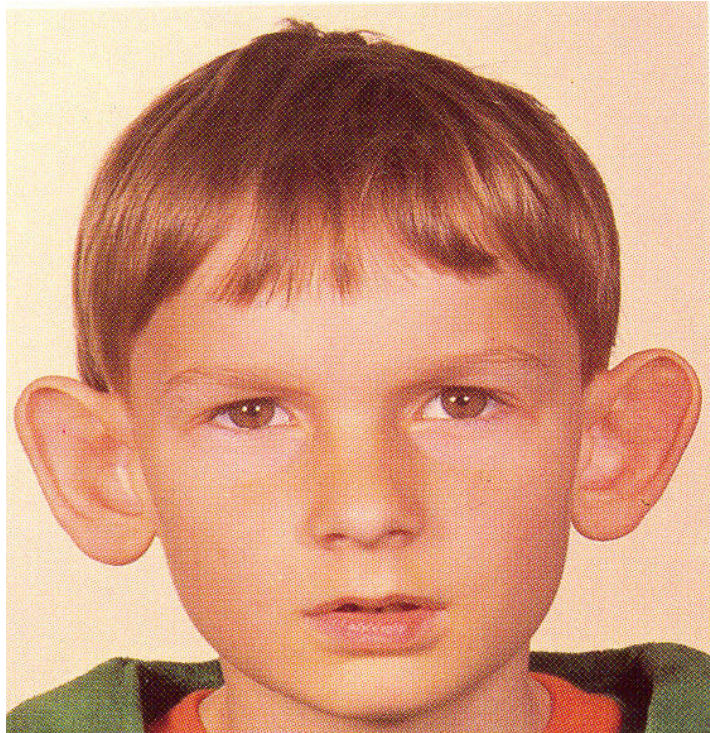
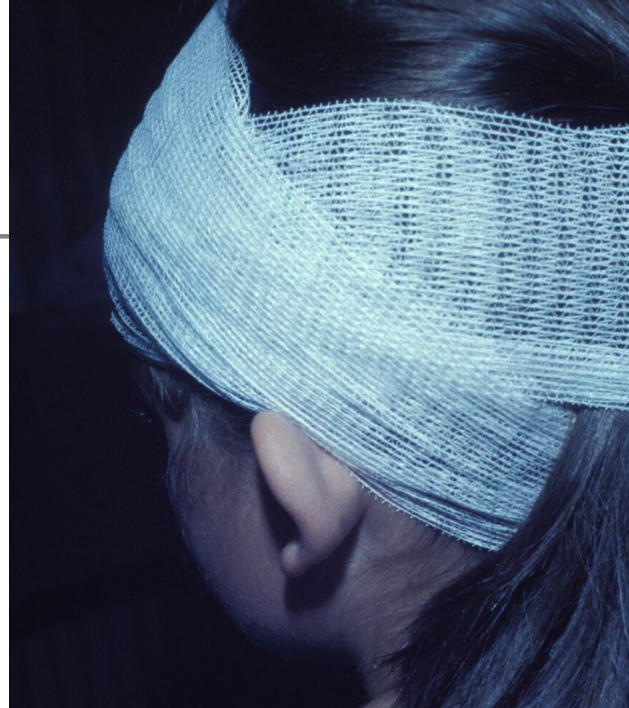Apendices praeauriculares



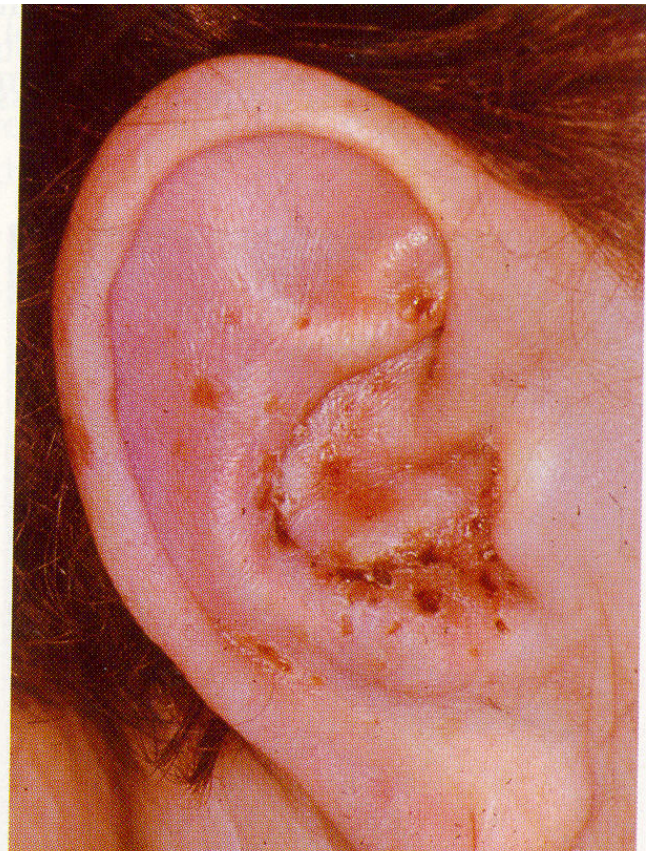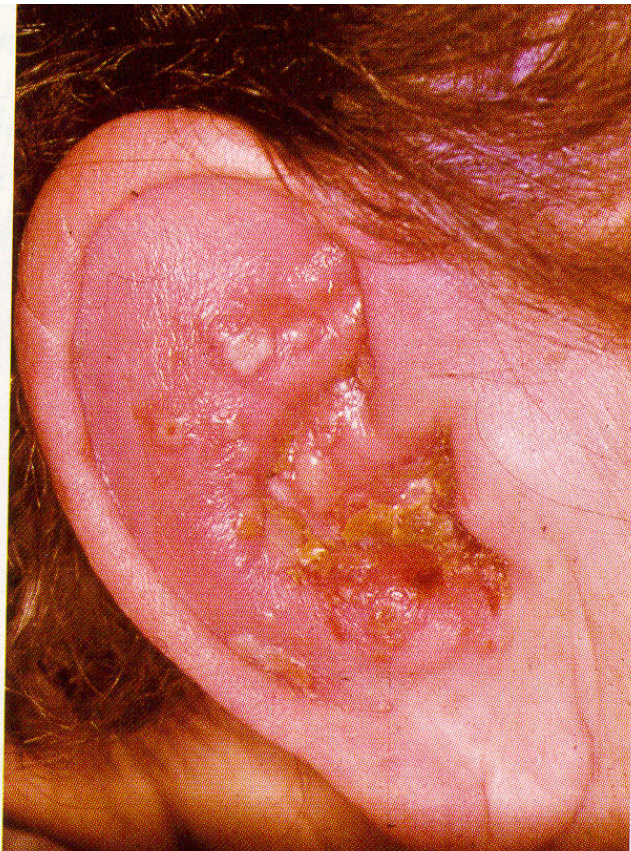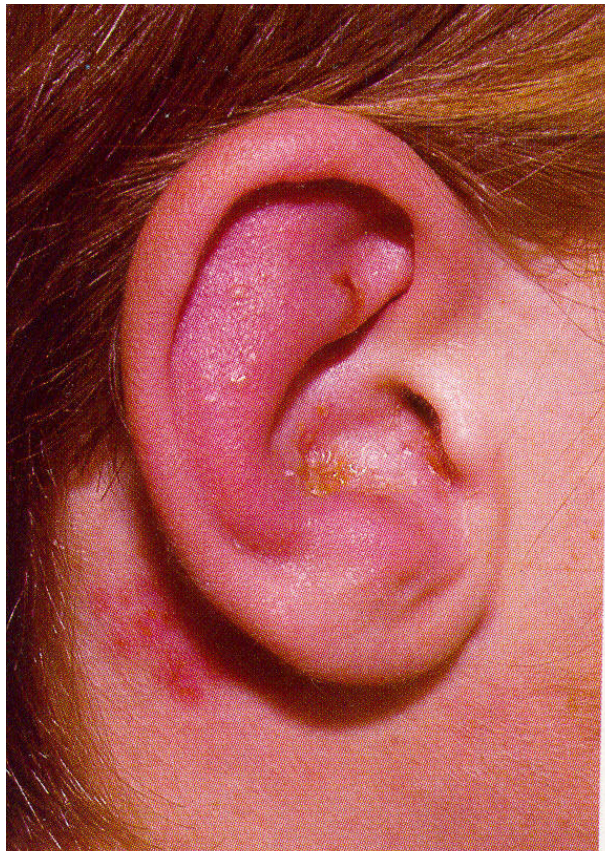Apostasis auriculae

Blunt attachment angle

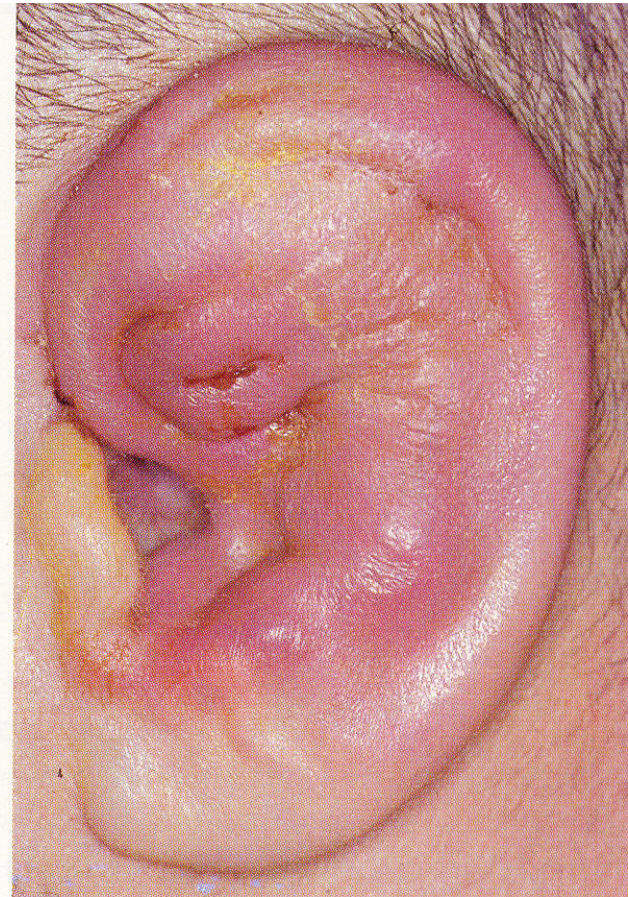
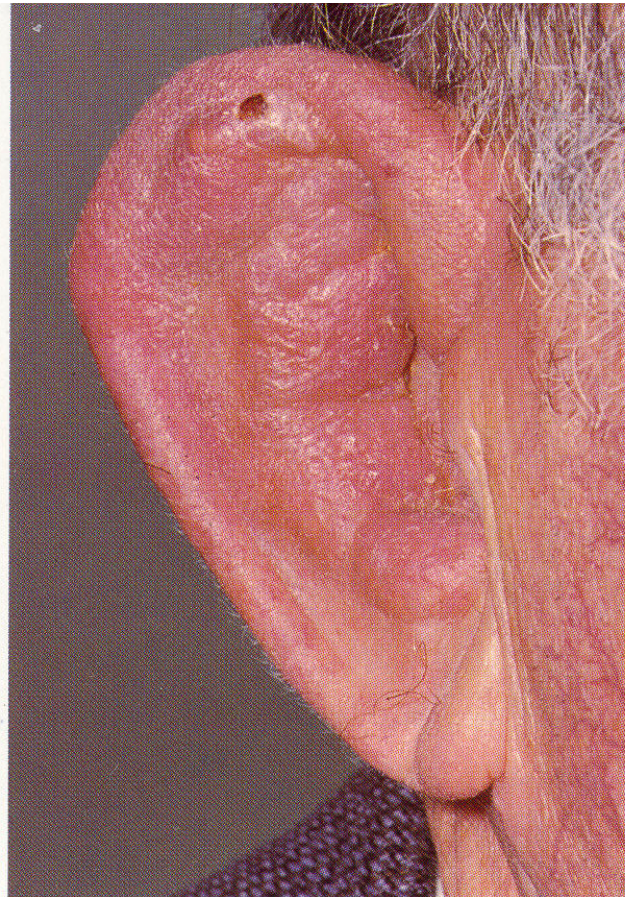
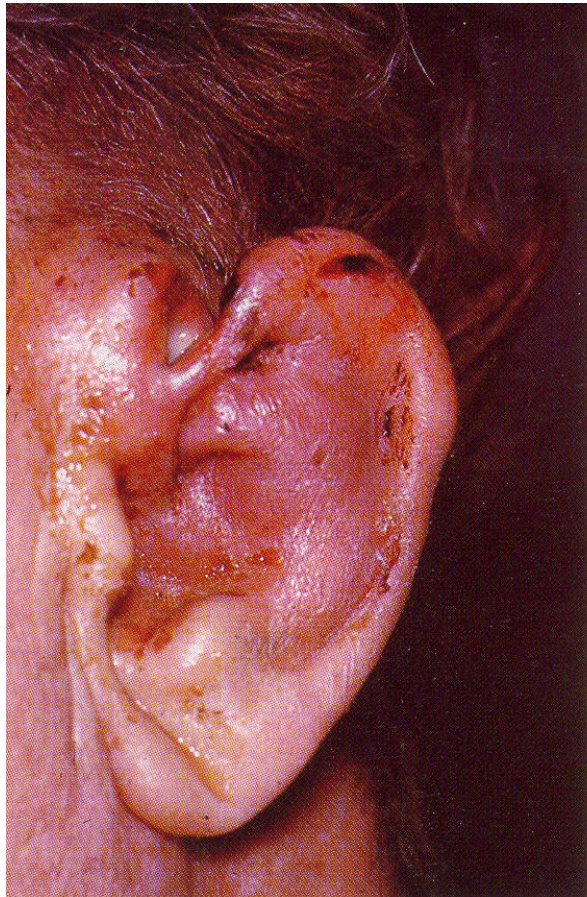Herpes zoster oticus (part of Ramsay-Hunt syndrome)

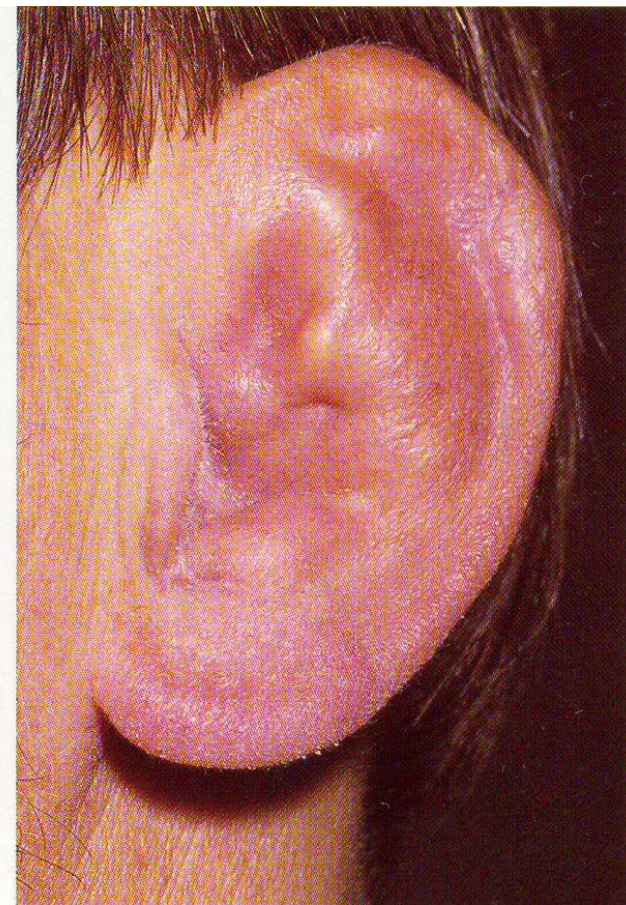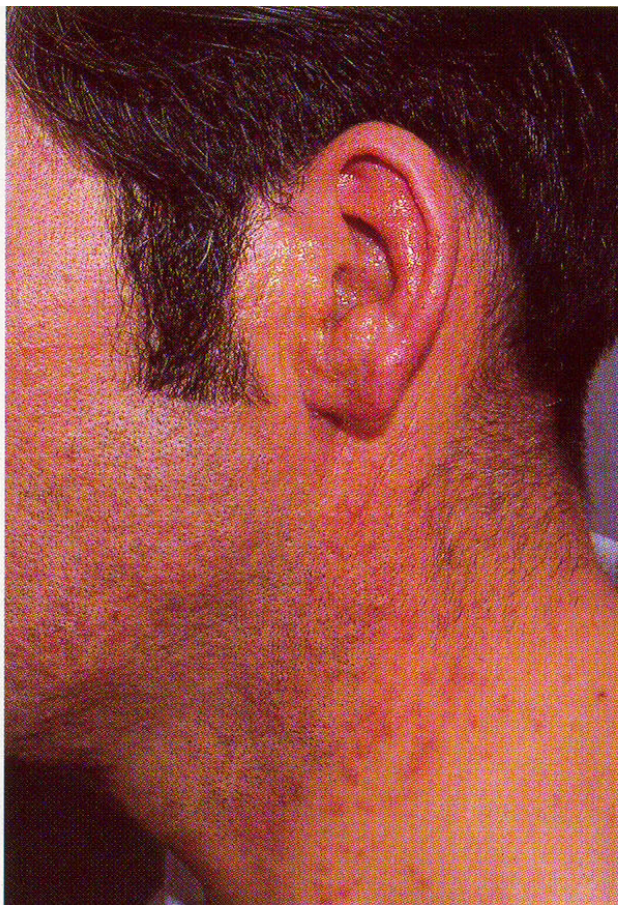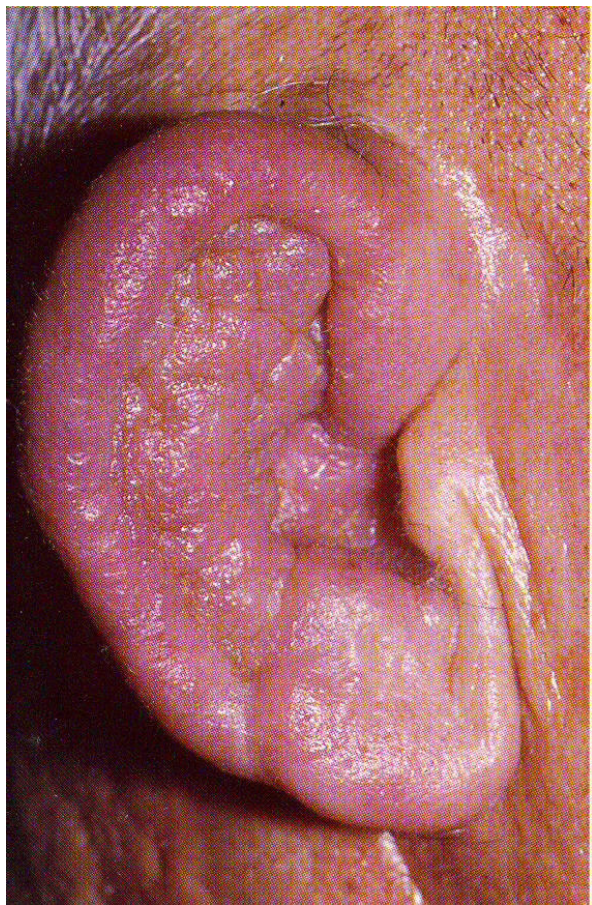
acute finding – after 3 days – after 10 days



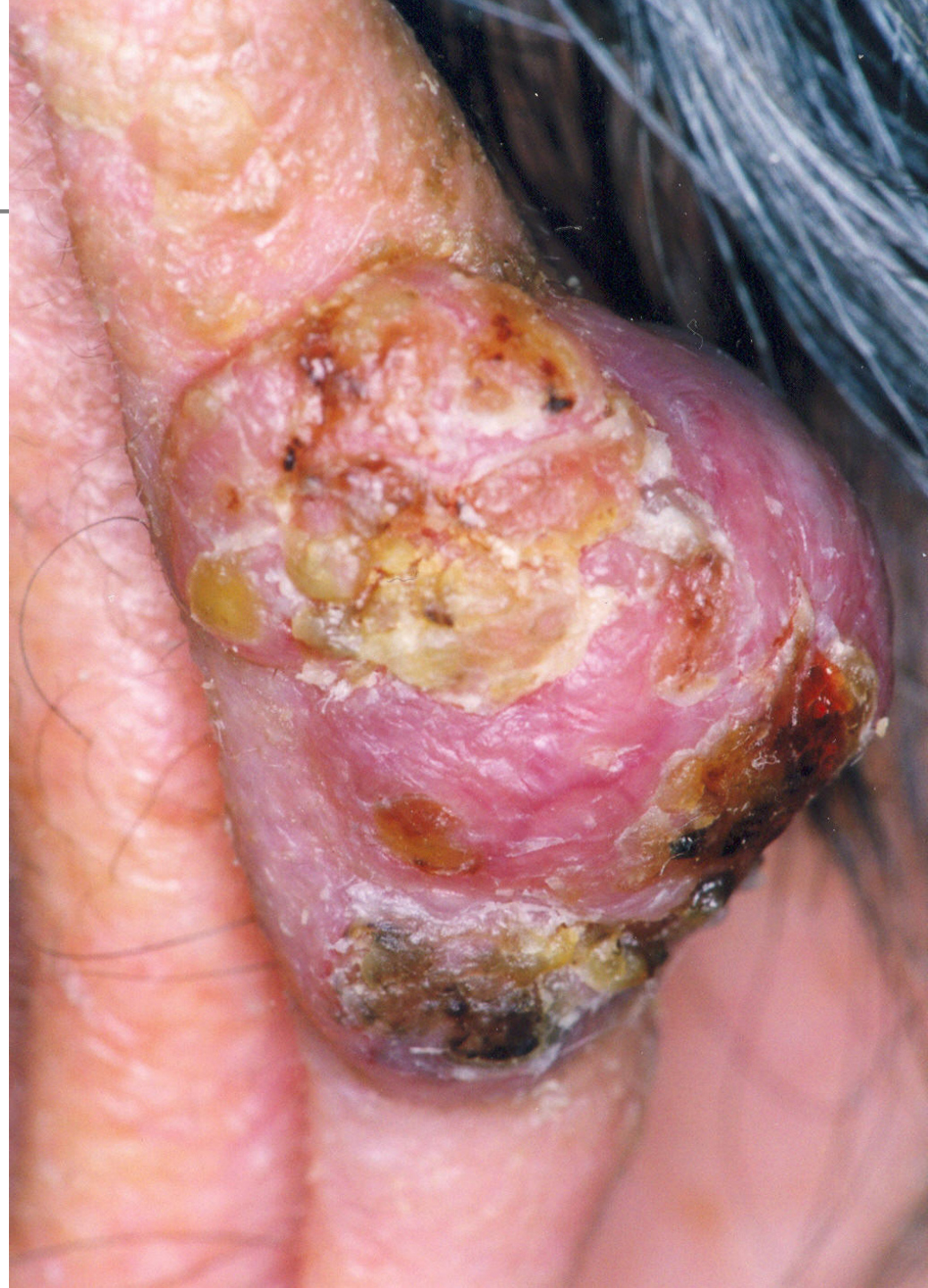Perichondritis



Chronic polychondritis – allergy- cauliflower ear

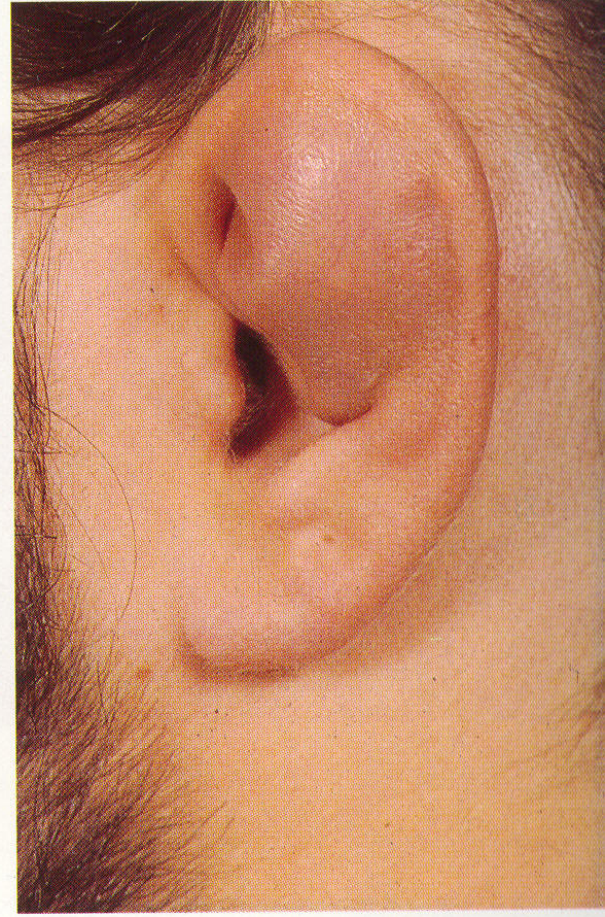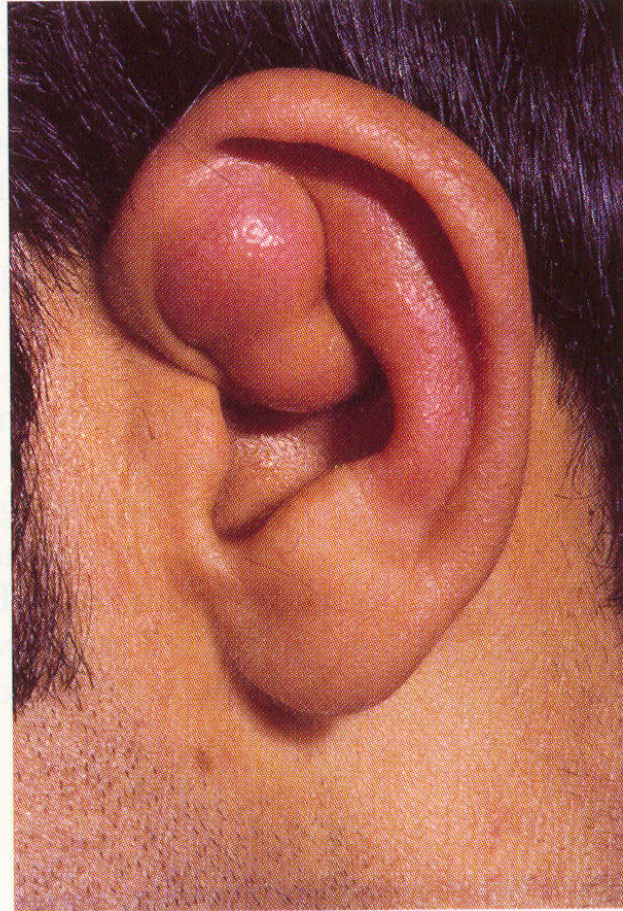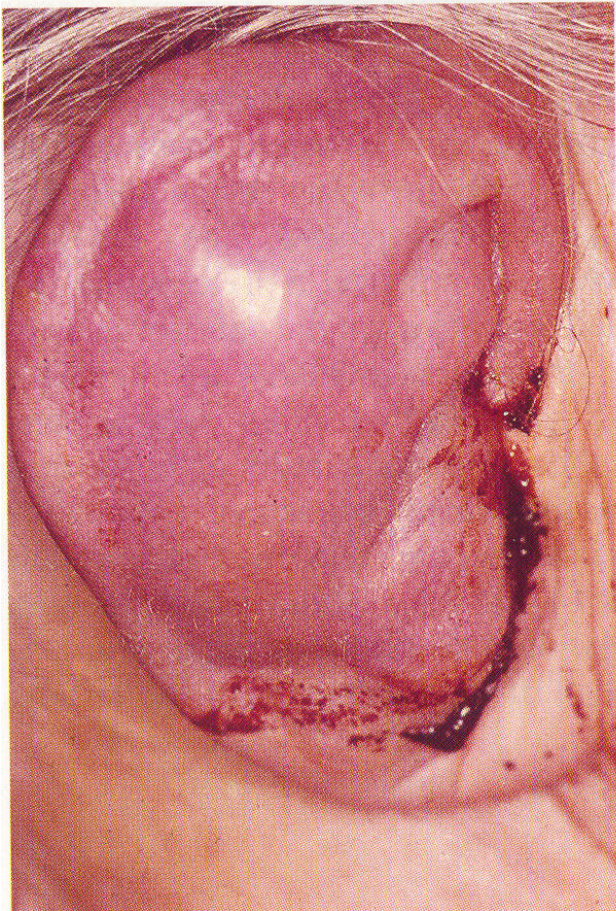


Spinocellular cancer of auricle

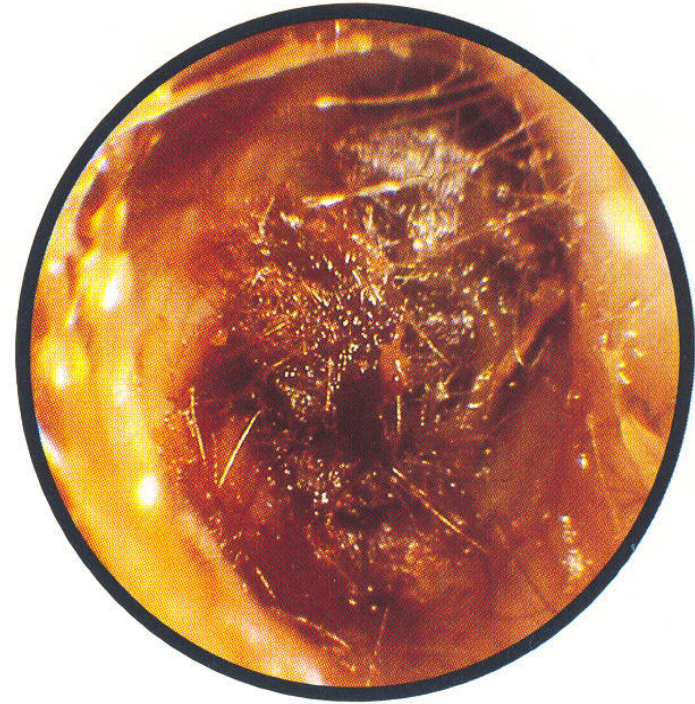
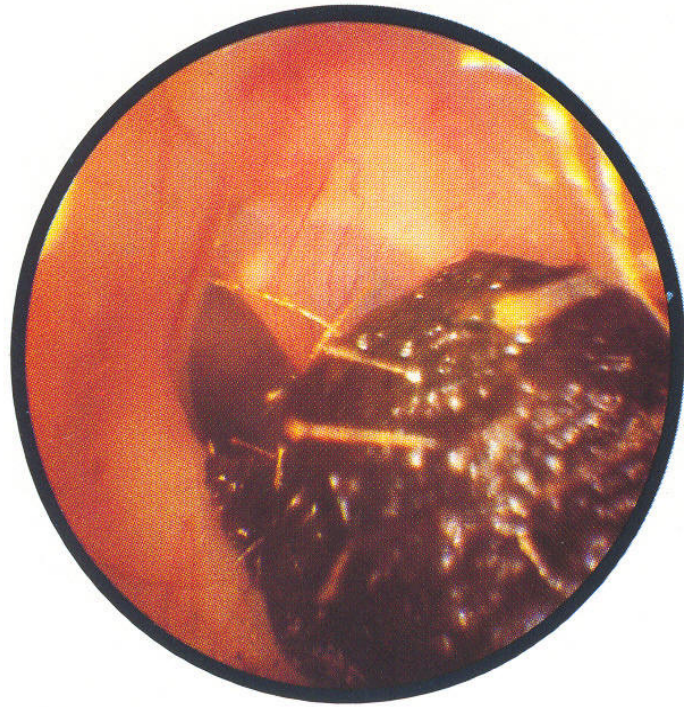


Othematoma

(fresh injury; after 14 days; after some months)

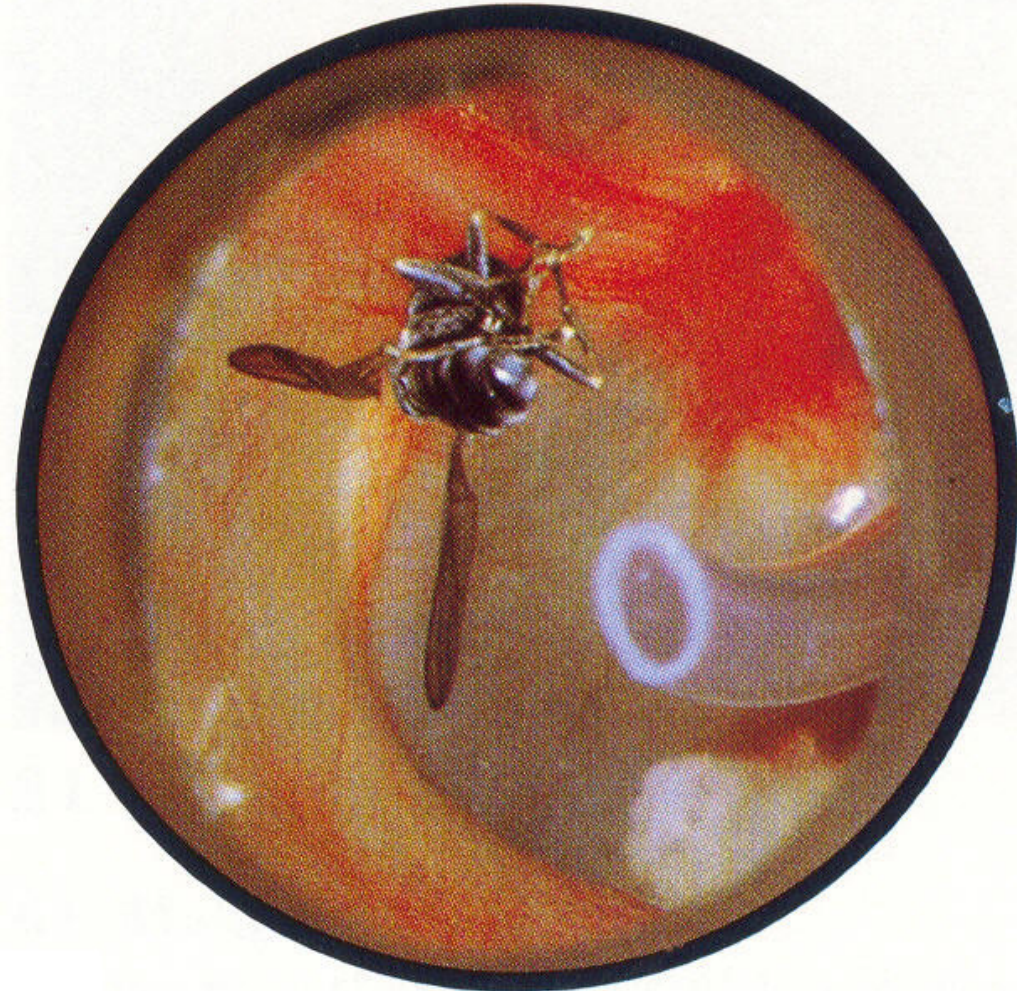

Earwax (Cerumen)

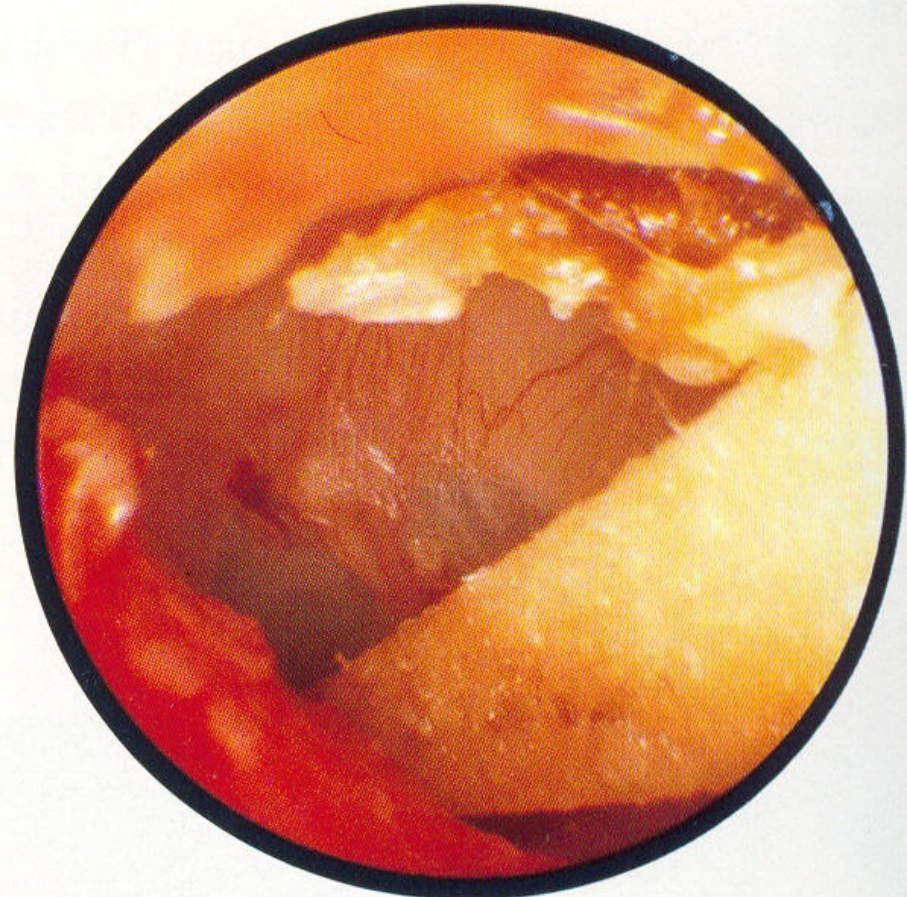
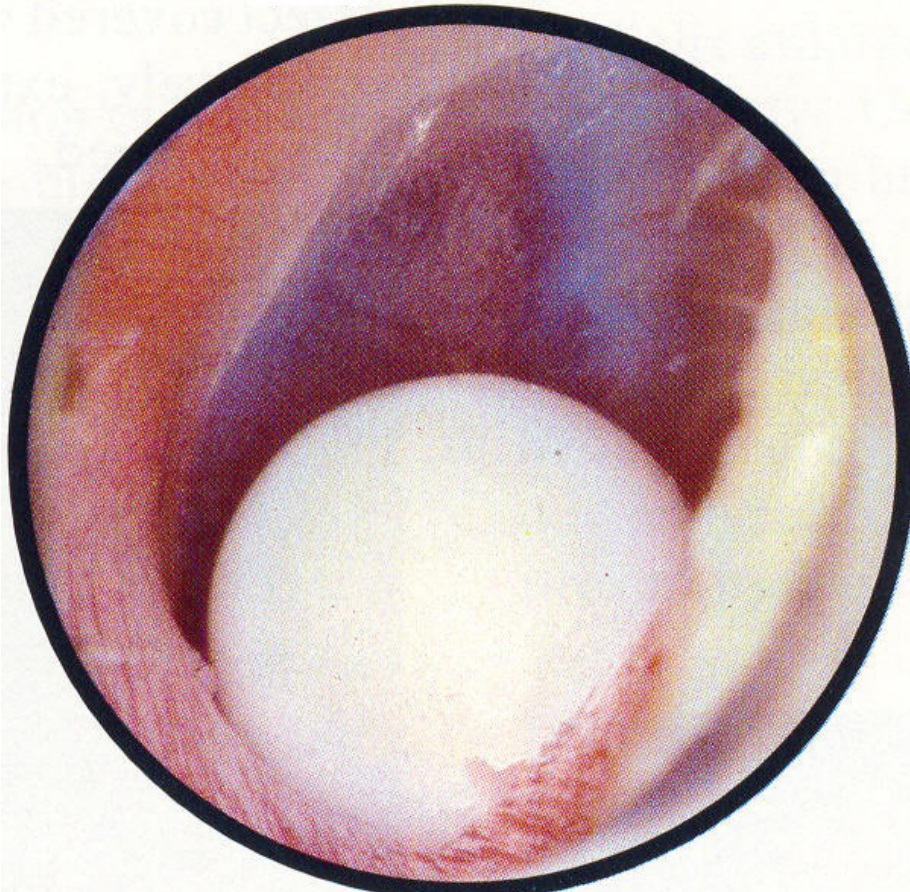


Foreign body in external meatus - insect

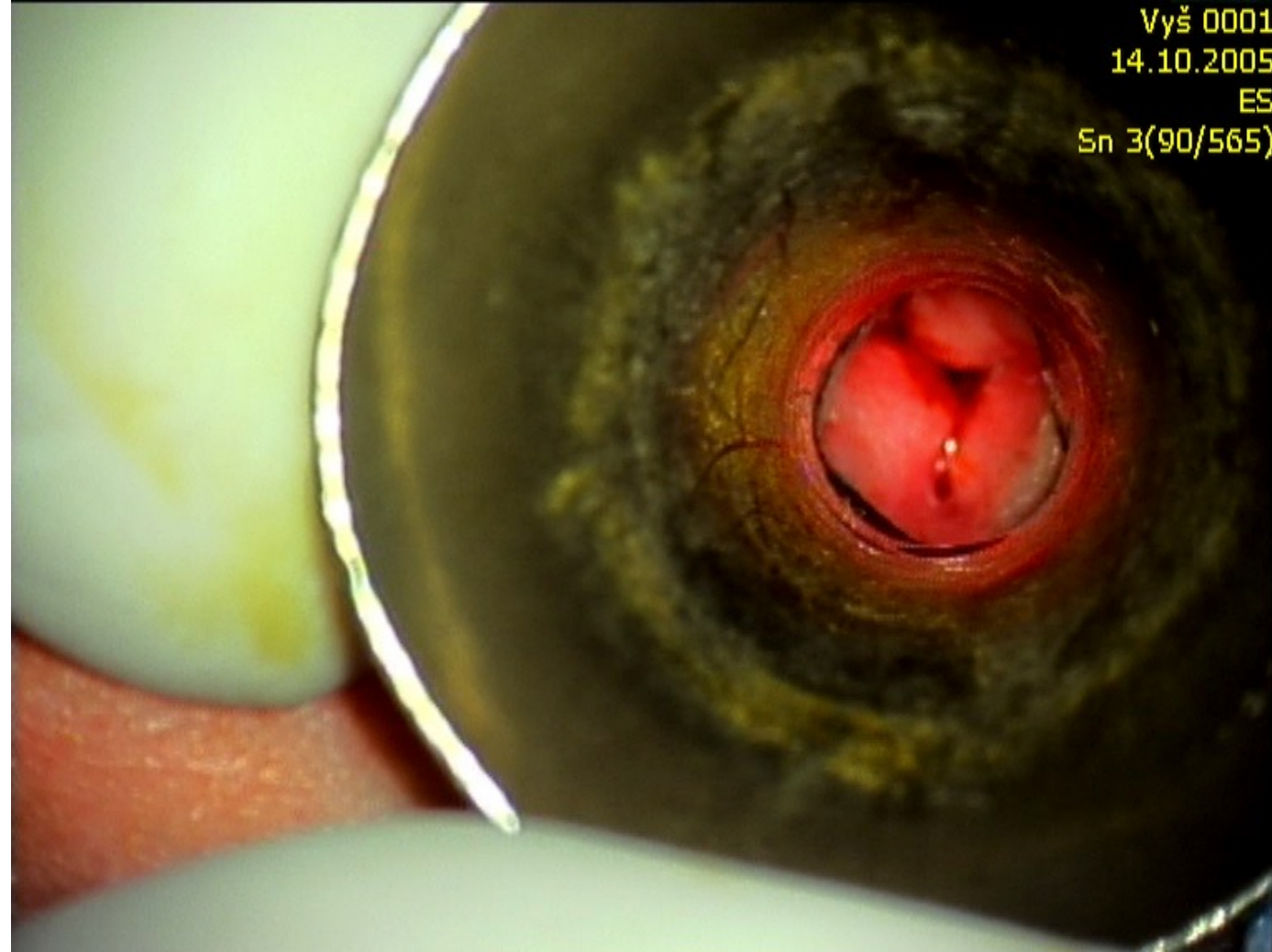
Insect, ventilation tube



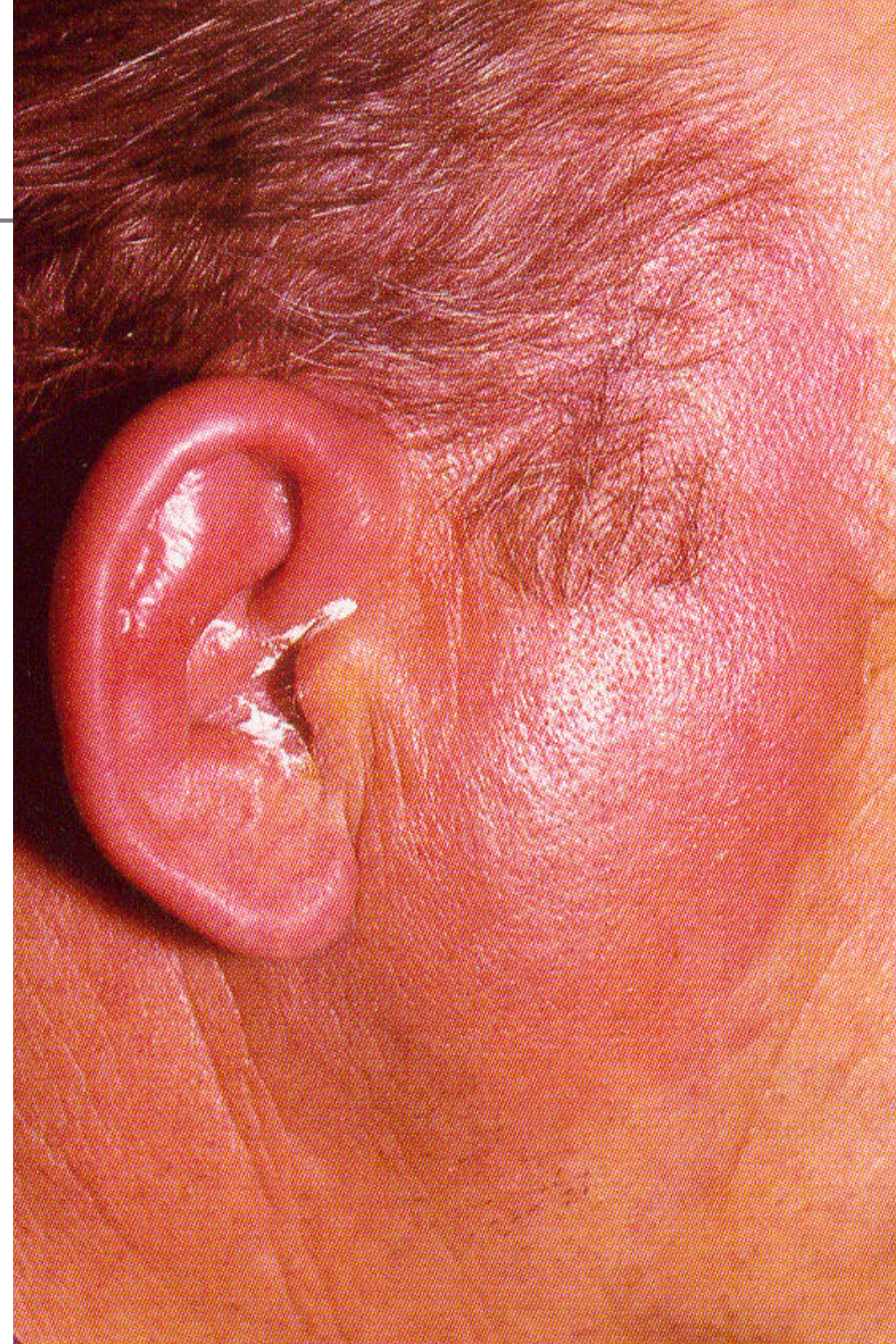Foreign body in external meatus bead, piece of wood, blood



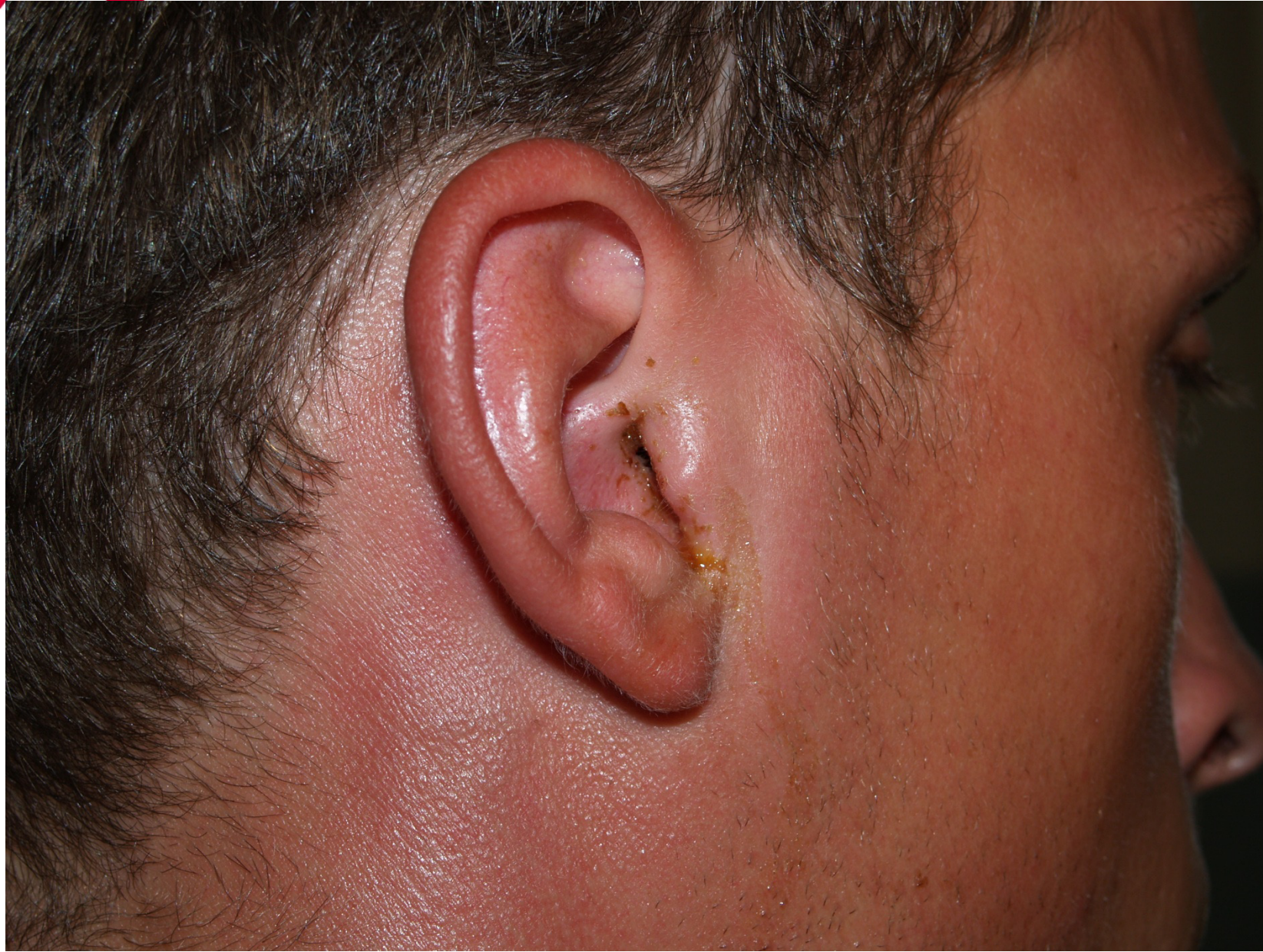Exostosis in ext. meatus right



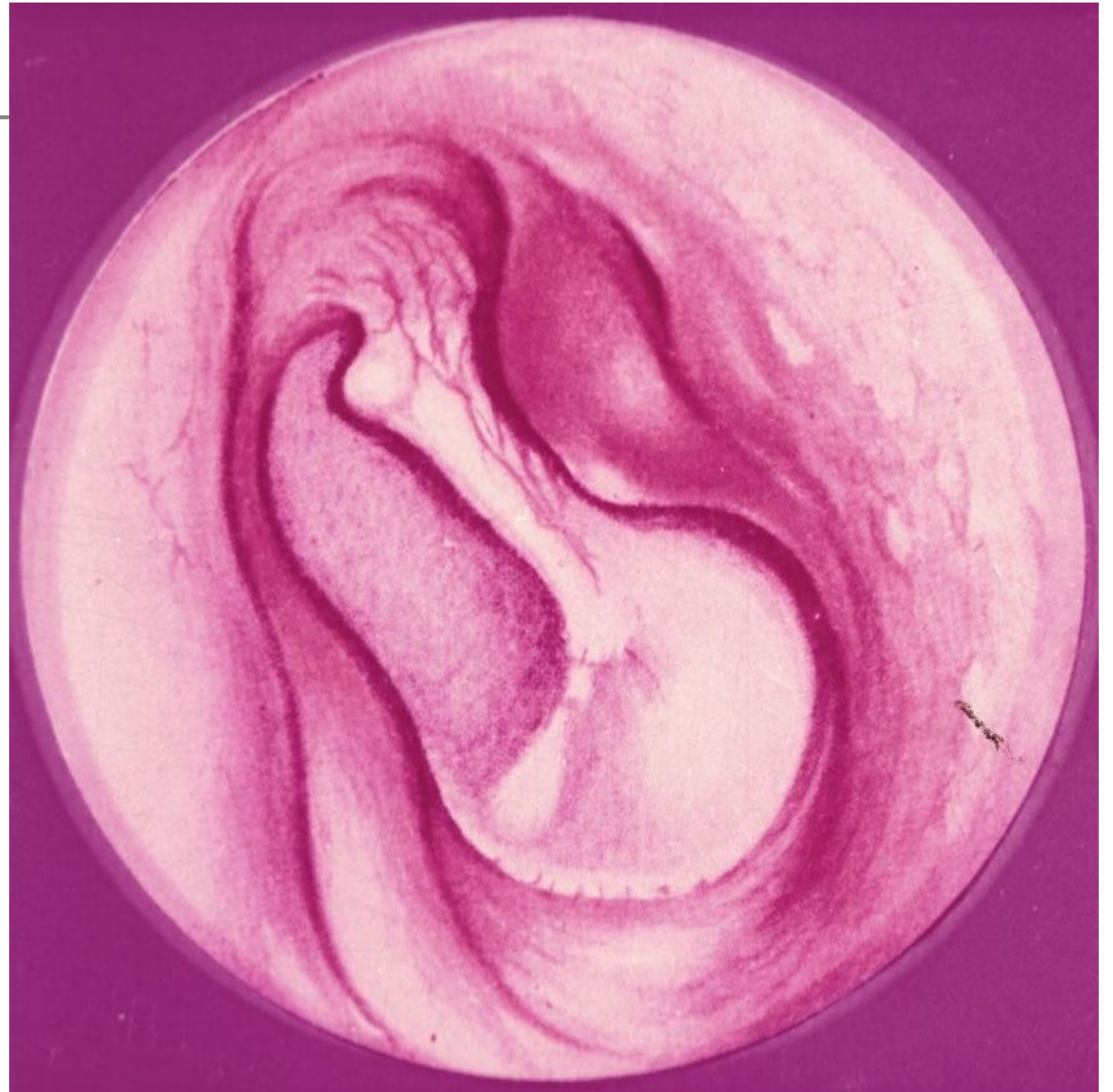Erysipelas bullosa auriculae



Inflammation of external meatus



Furunculus of external meatus





Middle ear cavity inflammations

According to course, extension, localization

Acute

- Catarrhus tubotympanalis acutus
- Otitis media acuta

Chronic

- **Non suppurative** – otitis media chronica secretorica (OMA, celistvý bubínek)
- **suppurative** (permanent perforation)
 - Otitis media chronica simplex – mostly mesotympanal
 - Otitis media chronica with polyps, granulations
 - Otitis media chronica cum ostitide
 - Otitis media chronica cum cholesteatomate

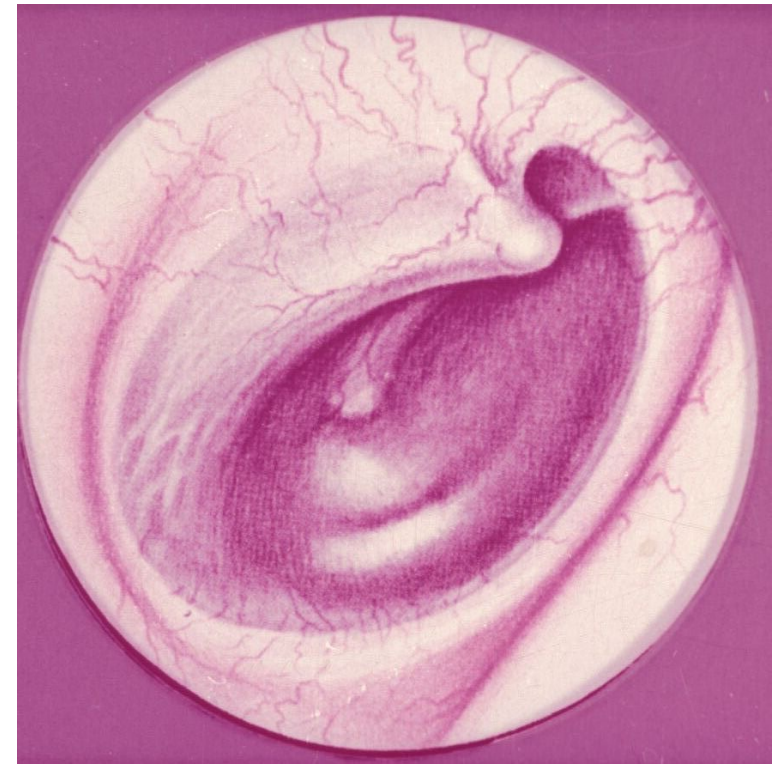
Catarrhus tubotympanalis acutus

Symptoms – feeling of fullness in the ear, pressure, hearing disorder.

Retracted ear drum, without perforation, tympanometry curve type C.

Th: treatment of upper airway inflammations, aeration of middle ear cavity.

retracted ear drum





Otitis media acuta

Infection - way: epipharyngeal, hematogenic, injury. Pneumococcus, haemophilus infl., Moraxella catarrhalis

1. Stage of tubal occlusion

- Blood vessel injection, without reflex, mild pressure, hearing disorder

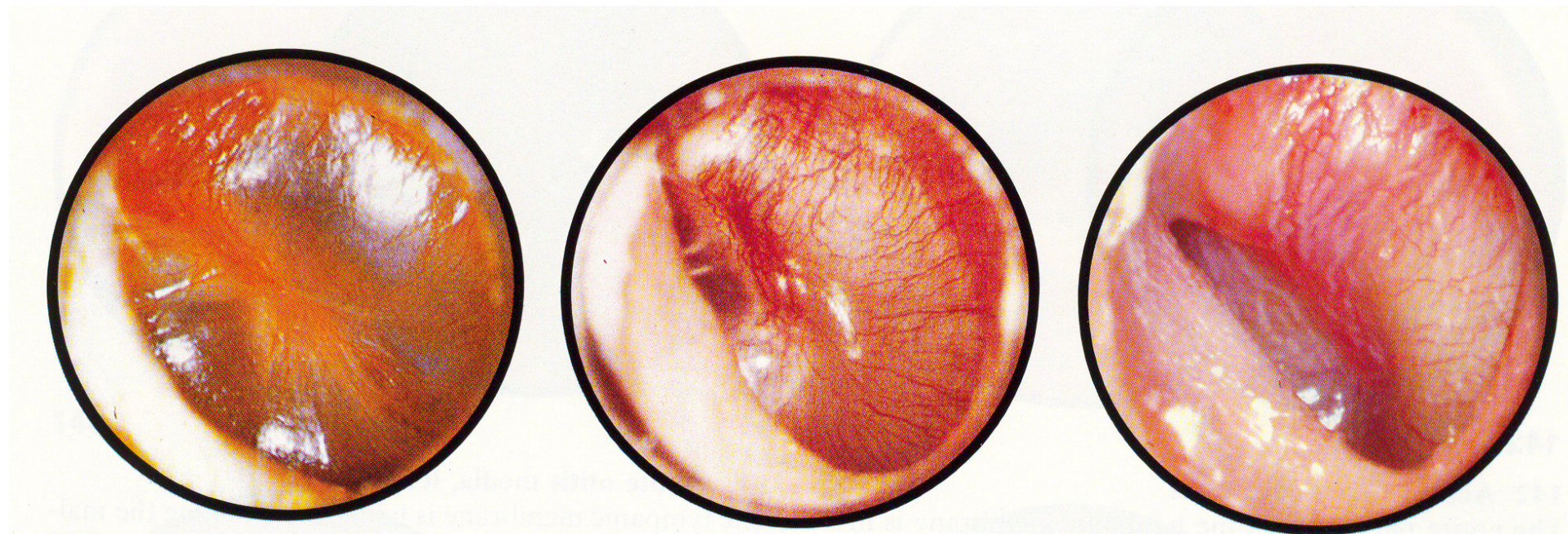
2. Stage of exudation

- Gradual bulging of ear drum, pain, fever, nausea, vomiting

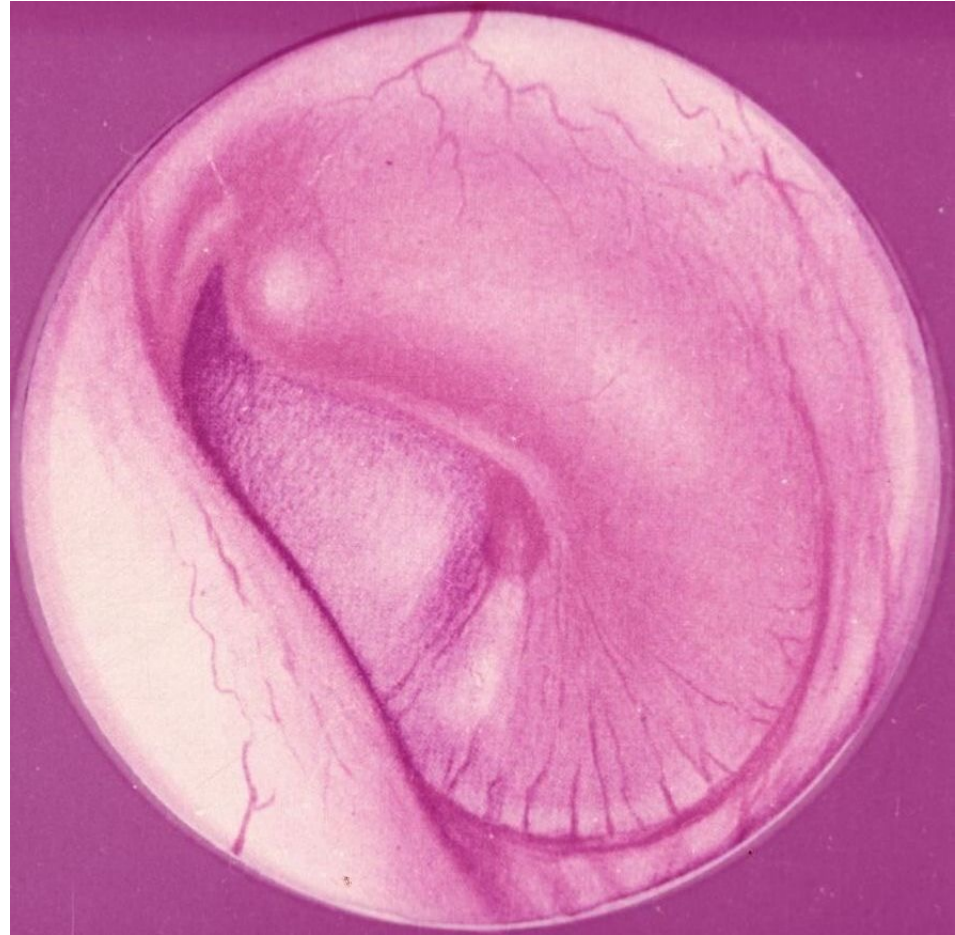
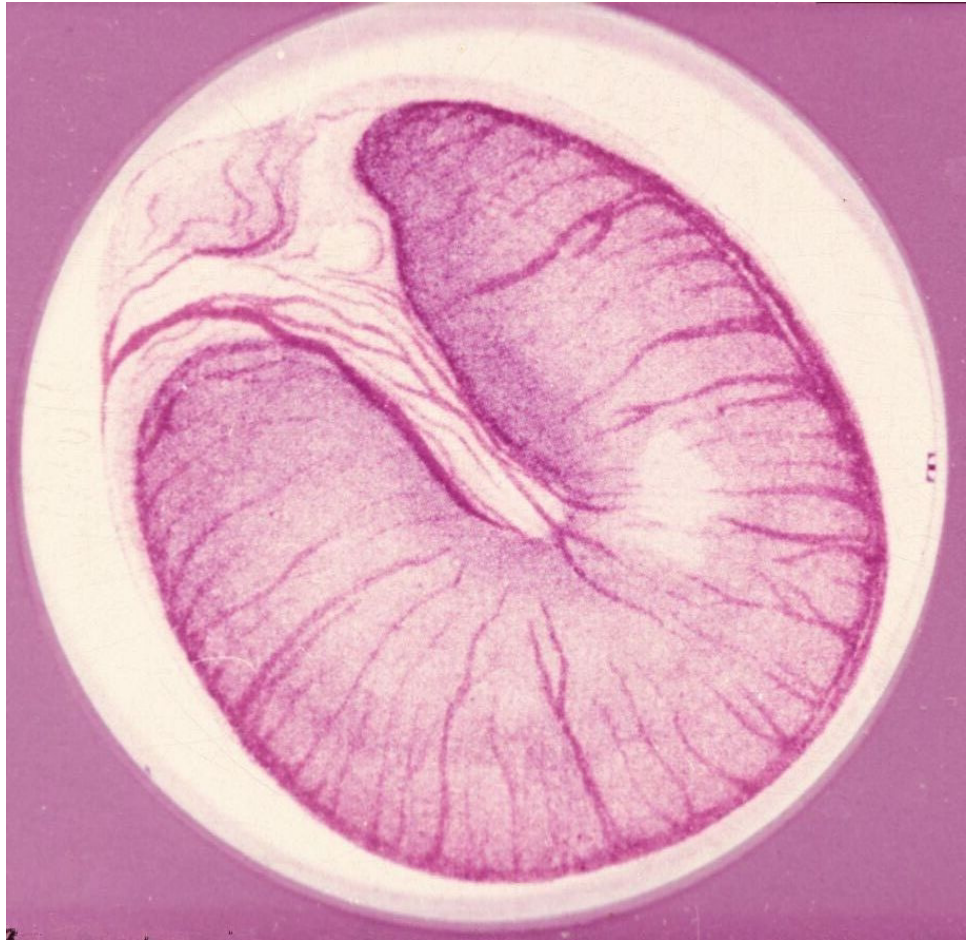3. Stage of suppuration – ear drum without contours, spontaneous perforation

4. Stage of reparation – small secretion, ear drum with contours, defect healing with scar

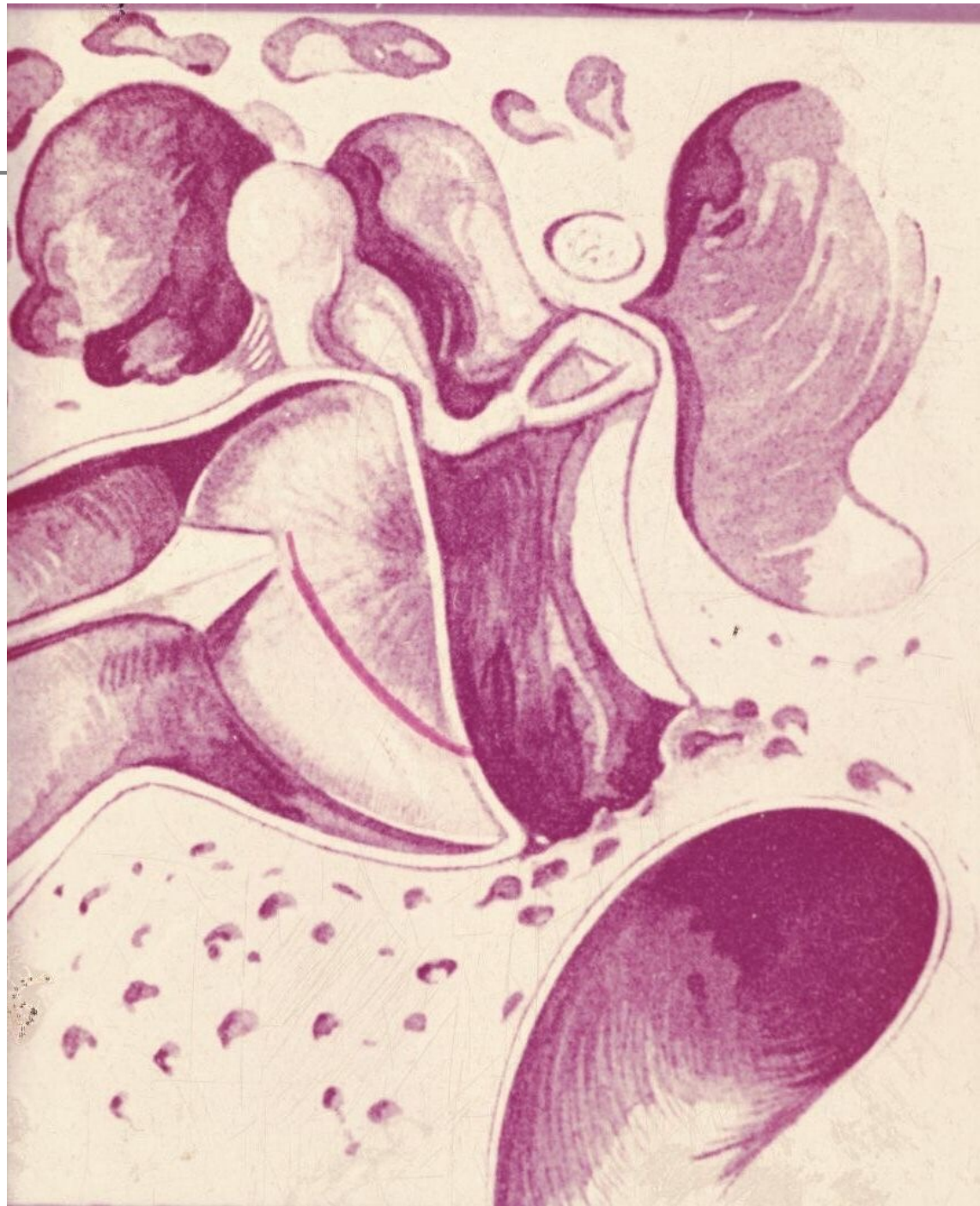Otitis med. ac. l. sin. – gradual changes on ear drum



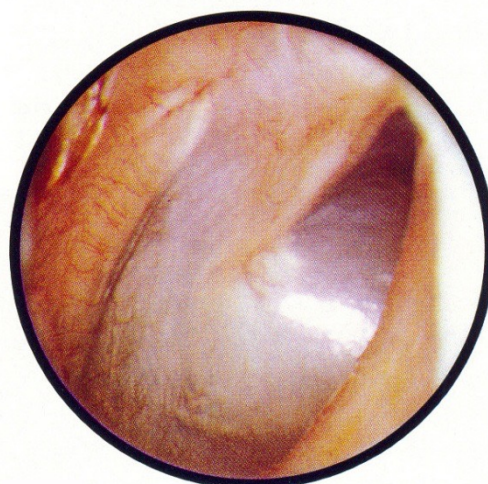
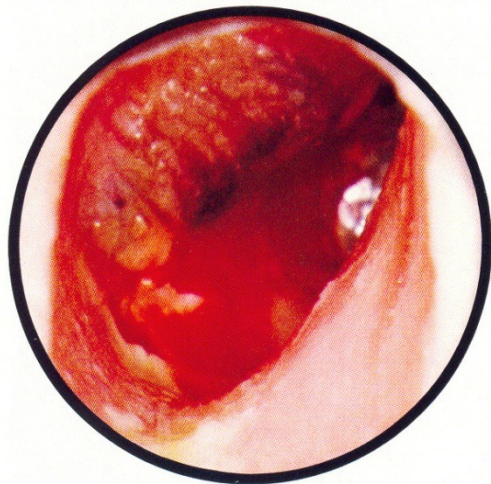
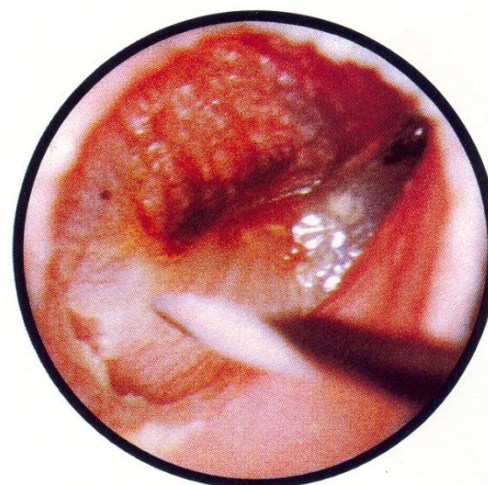
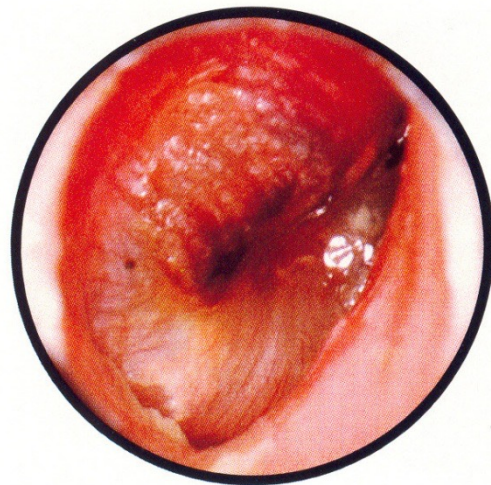
Otitis media acuta



Paracentesis (myringotomy)

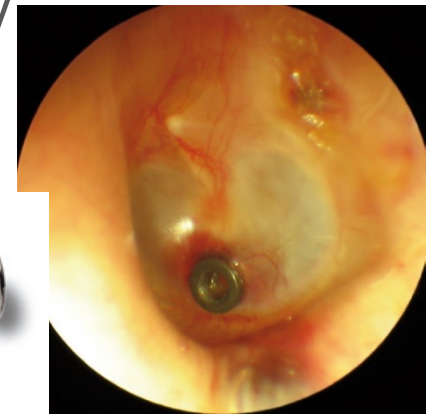


Otitis med. ac. sin. with myringotomy and following restitution



Otitis media chronica secretorica

- Presence of secretion behind whole ear drum without symptoms of acute inflammations. Time – longer as 3 months.
- Pathogenesis – dysfunction of eustachian tube - restructuring of epithelium middle ear cavity – secretion in middle ear cavity – risk of ear drum retraction.
- Dg – otoscopy, tympano B or C2 curve, conductive hearing loss
- Therapy
 - conservative – stimulation of palate muscles, aeration of middle ear cavity, antihistaminics, treatment of inflammations of upper airway
 - surgery. – adenotomy, myringotomy, TVT



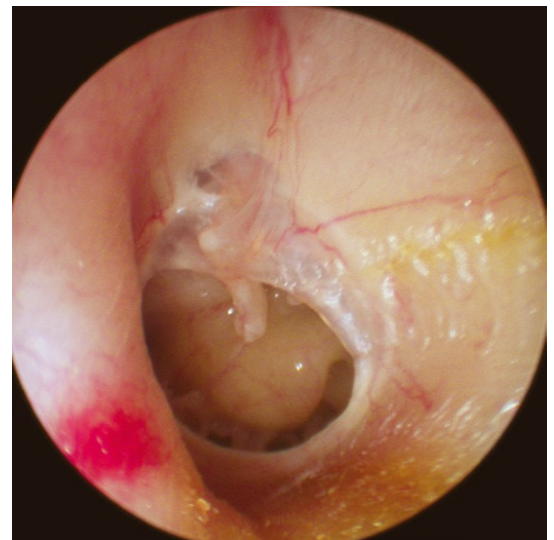
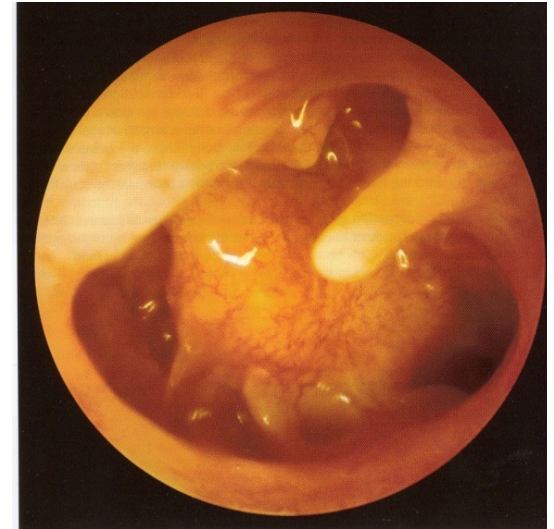
Otitis media chronica suppurativa

Form

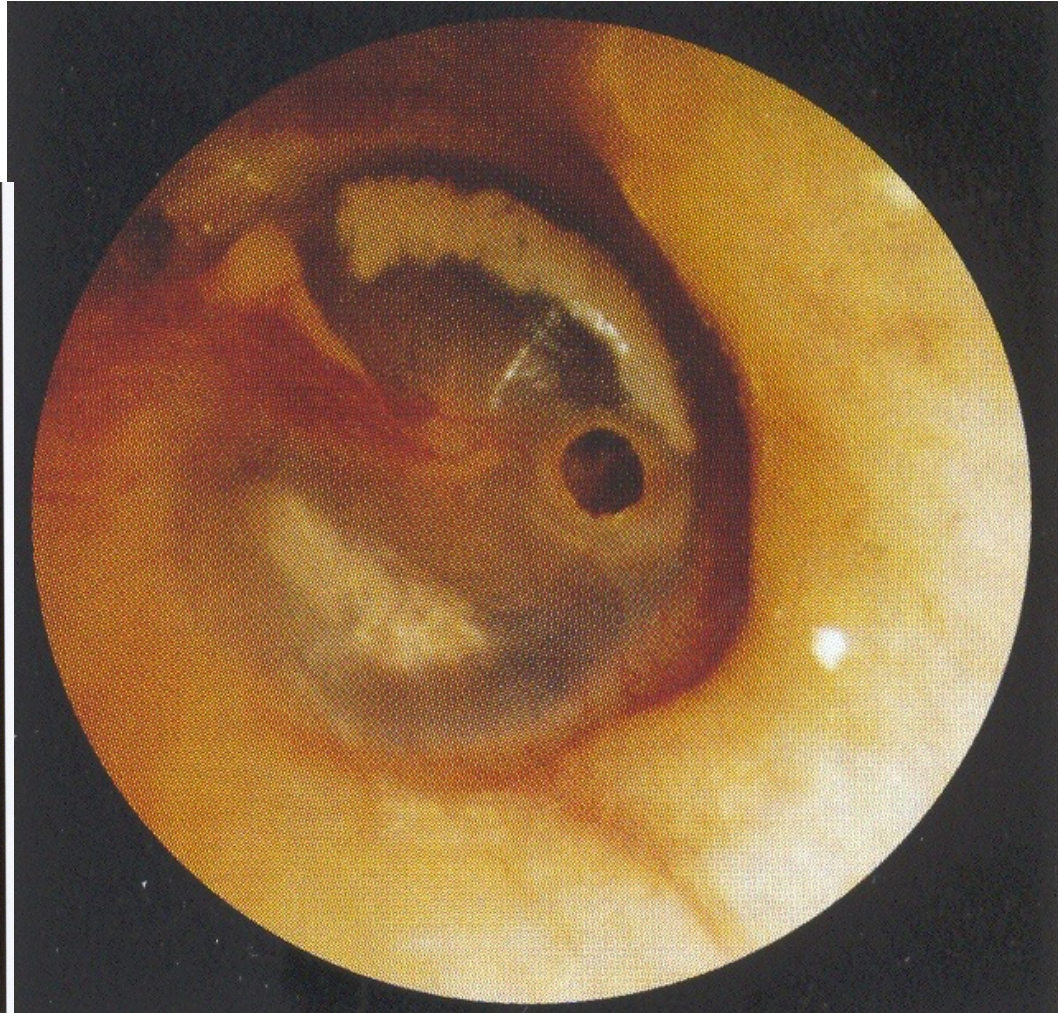
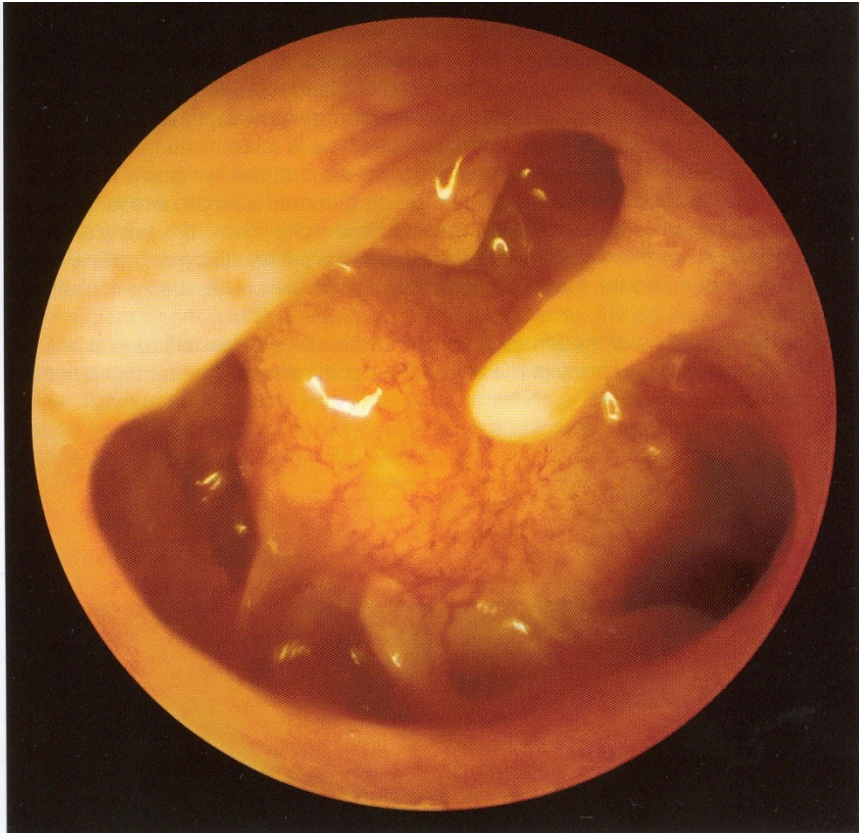
- Mesotympanal
- Epitympanal
- Mixed

Causes

- Recurrences of acuta inflamm. of middle ear cavity
- Eustachian tube dysfunction
- Chronic inflammation of upper airway



Central perforation





Otitis media chronica suppurativa mesotympanalis

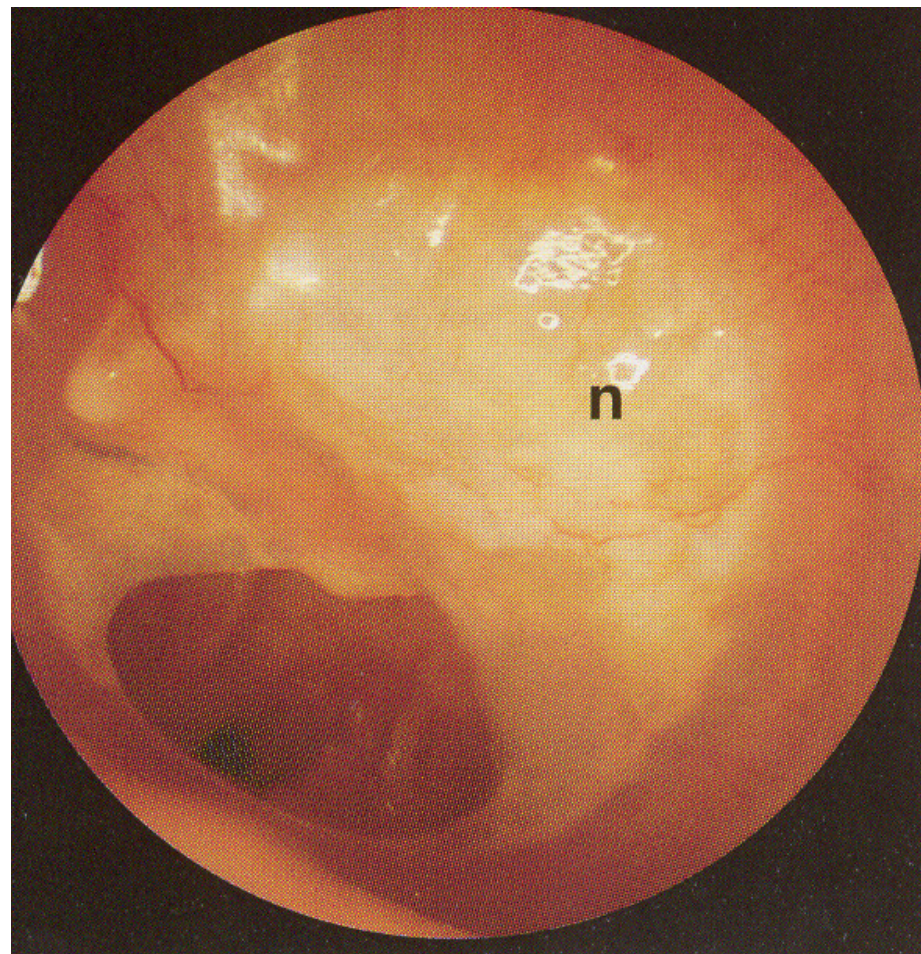
Depend of phasis of inflammation, exacerbation – symptoms as in acute inflammation:

- Conductive hearing loss,
- Ear drum perforation, in pars tensa, ear discharge – purulent, without smell,
- Without temperatures and pain.
- Microbiology – usually mixed microbes – Escherichia, Klebsiella, koky, pseudomonads and mycosis.

Otoscopy:

pars tensa - central perforation, changed middle ear epithelium, polyps, granulations.

Central perforation in antero-inferior quadrant





Otitis media chronica suppurativa mesotympanalis

Treatment

- Treatment of upper airway inflammation, improvement of nasal patency tube function.
- Local antibiotics , combination with s corticosteroids .
- Polyps and granulations removed surgically , ev. in 3-6 months myringoplasty, ev. Reconstruction of ossicle chain.

Prognosis

Favorite

Complications

rare

Otitis media chronica epitympanalis

- Localization in epitympanal cavity;
- Frequently connected with cholesteatoma and osteitides
- Possible destruction of ossicular chain, bone of middle ear cavity,

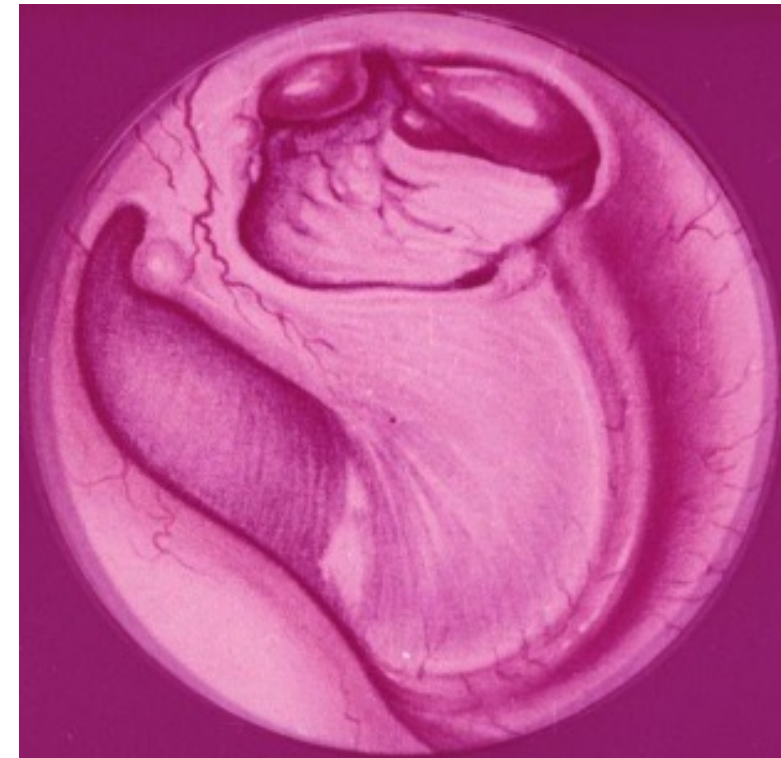Theory of genesis

1. Tube Dysfunction – pocket in Schrapnellově membrane – perforation –cholesteatoma
2. Direct growth of epithelium through defect of ear drum into middle ear
3. Embryogenetic theory – congenital cholesteatoma

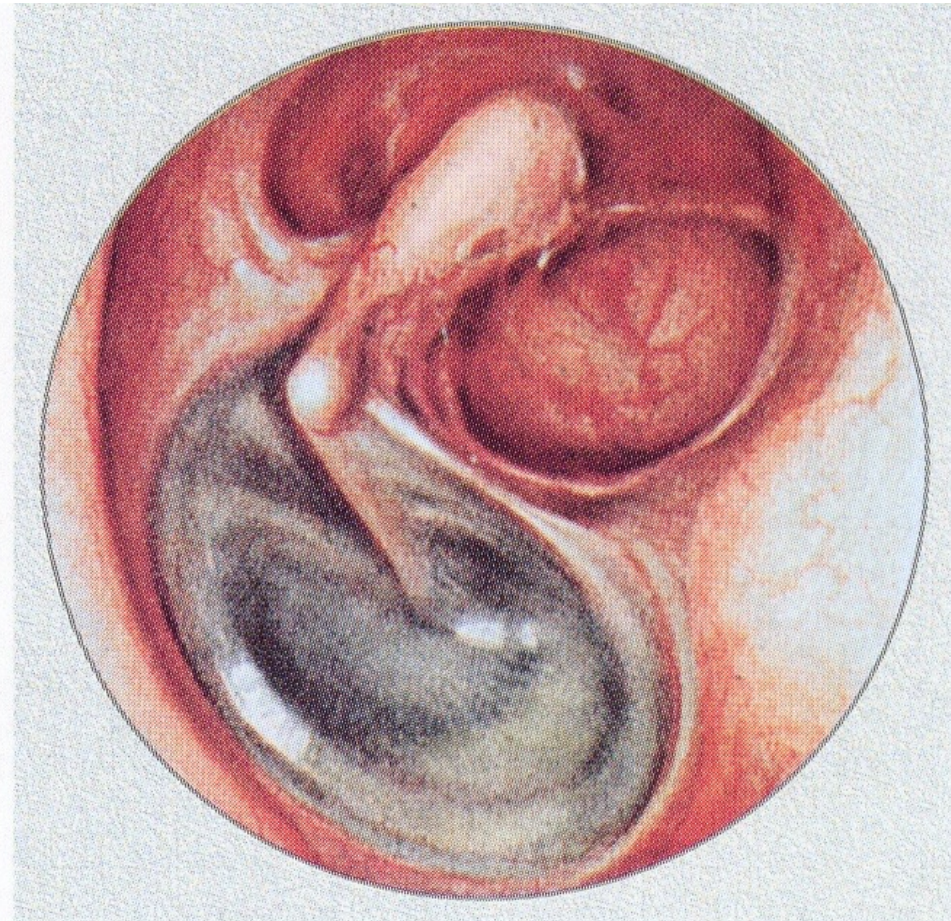
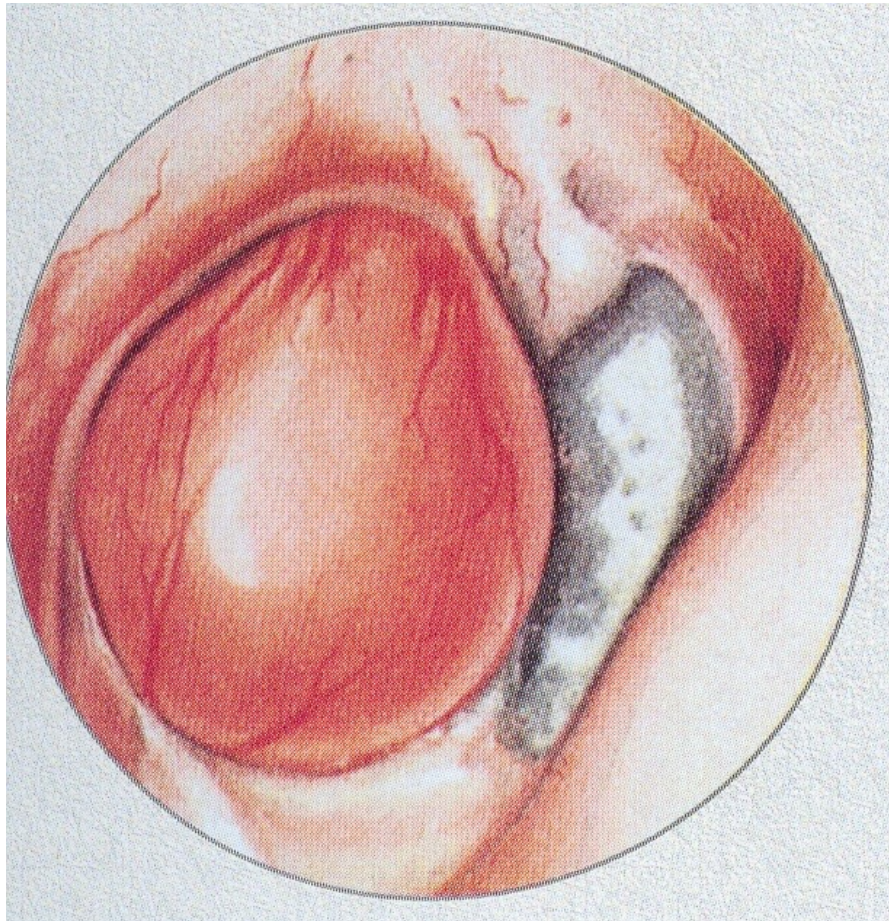
Symptoms: smelly discharge, hearing disorder, occasionally ear pain, ev. paresis n.VII

Otoscopy – perforation in pars flaccida

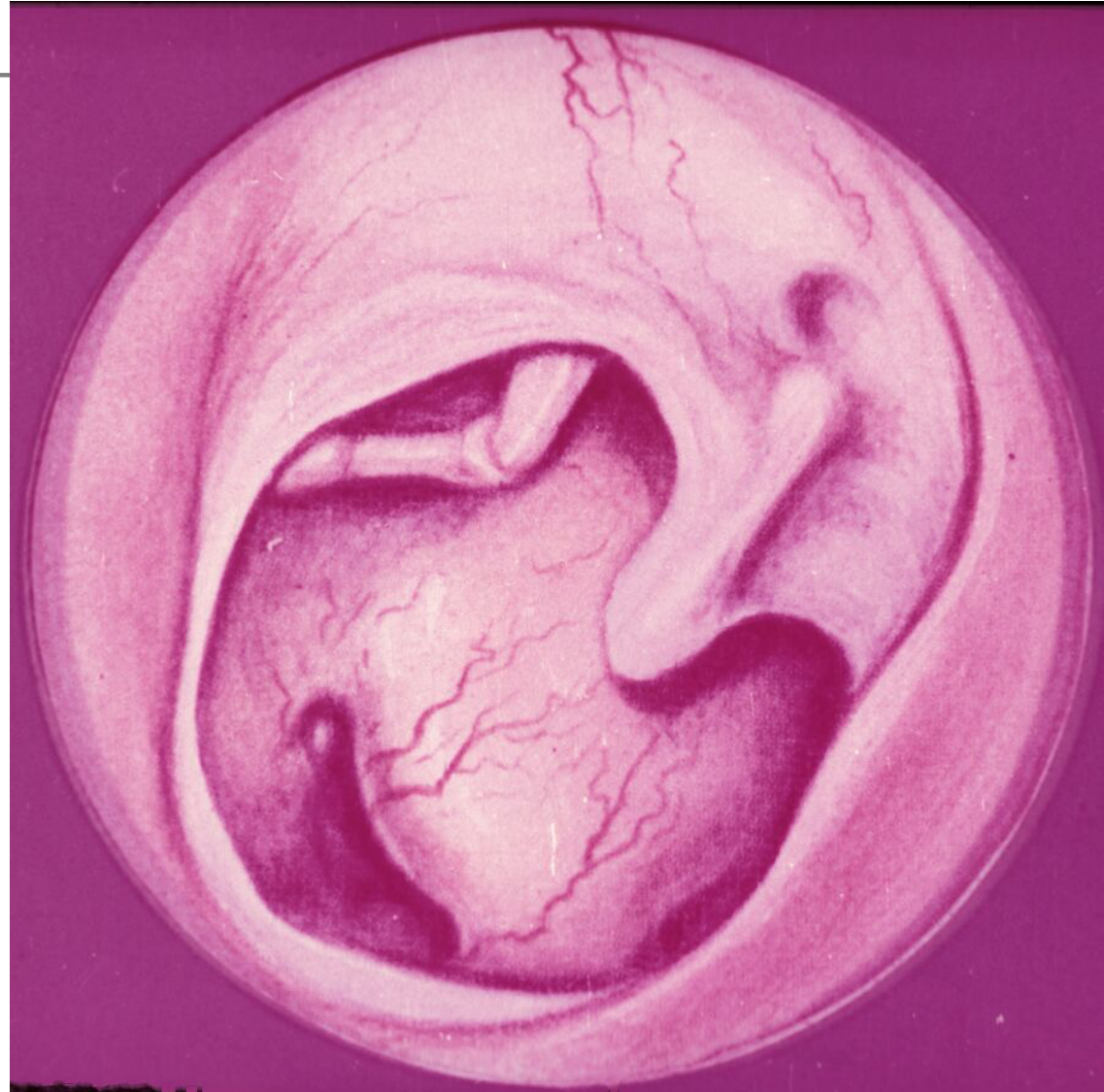
Therapy – surgery with removal of cholesteatoma



Polyp in otitis med. chronica, Defect of epitympani space after removal of cholesteatoma



Subtotal perforation of ear drum





Complications of middle ear inflammation

In antibiotic era rare

- **Otologic** – mastoiditis, petrositis, paresis , n. VII labyrinthitis
- **Intracranial** – abscessus epiduralis, subduralis, meningitis, brain and cerebellar abscess



Mastoiditis

Inflammation of processus mastoideus temporal bone.

Osseal septums are melted (radiologic diagnosis).

- Usually complication of middle earcavity inflam.
- Rarely hematologic spread or injury



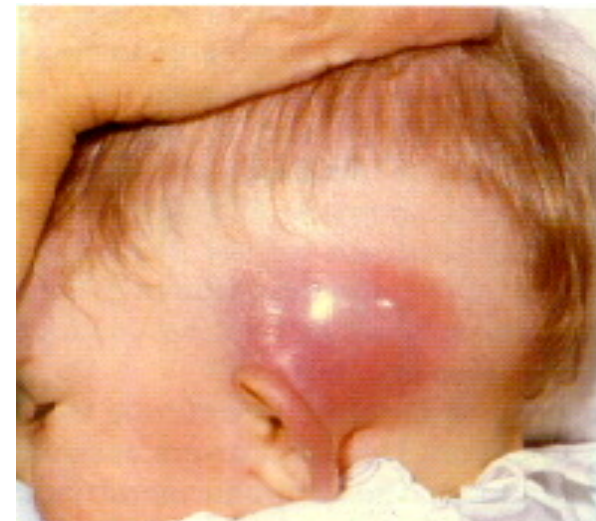Mastoiditis - forms

- **acute** (in 2–4 weeks after mediotitis, 50 % of all mastoiditis);
- **subacute**
- **latents**

Mastoiditis - symptoms

- **Acute mastoiditis:** fever, palpating pain, retroauricular infiltration, apostasis auriculae or antalgic head position, purulent discharge from ear chanal , worsening of hypacusis, tinnitus, worsening of general condition
- **Subacute and latent mastoiditis** (mild symptoms): some pain – feeling of pressure, hypacusis

Bezolds absces in child





Mastoiditis

Diagnosis:

- History of disease
- Otoscopy – posterior wall drop, signs of inflam. Middle ear
- Audiometry – decrease of both bone and air conduction
- **CT** – destruction of septums, cavity
- Increase of inflam. markers

Possible complications:

- Tromboflebits sinus sigmoideus
- Intracranial Nitrolební komplikace (epidurální, subdurální absces, meningitida, mozkový, mozečkový absces)

treatment:

- Broad spectrum antibiotics
- Mastoidectomy



Sanation and rekonstruction surgery inf chronic inflammation and its consequences

- **Sanation surgery** – aim – remove infection focus in temporal bone, potencial risk of life threatening intracranial complicatins
- **Rekonstructive surgery** – aim – reconstruction of hearing function



Surgery for otitis media – Sanation surgery

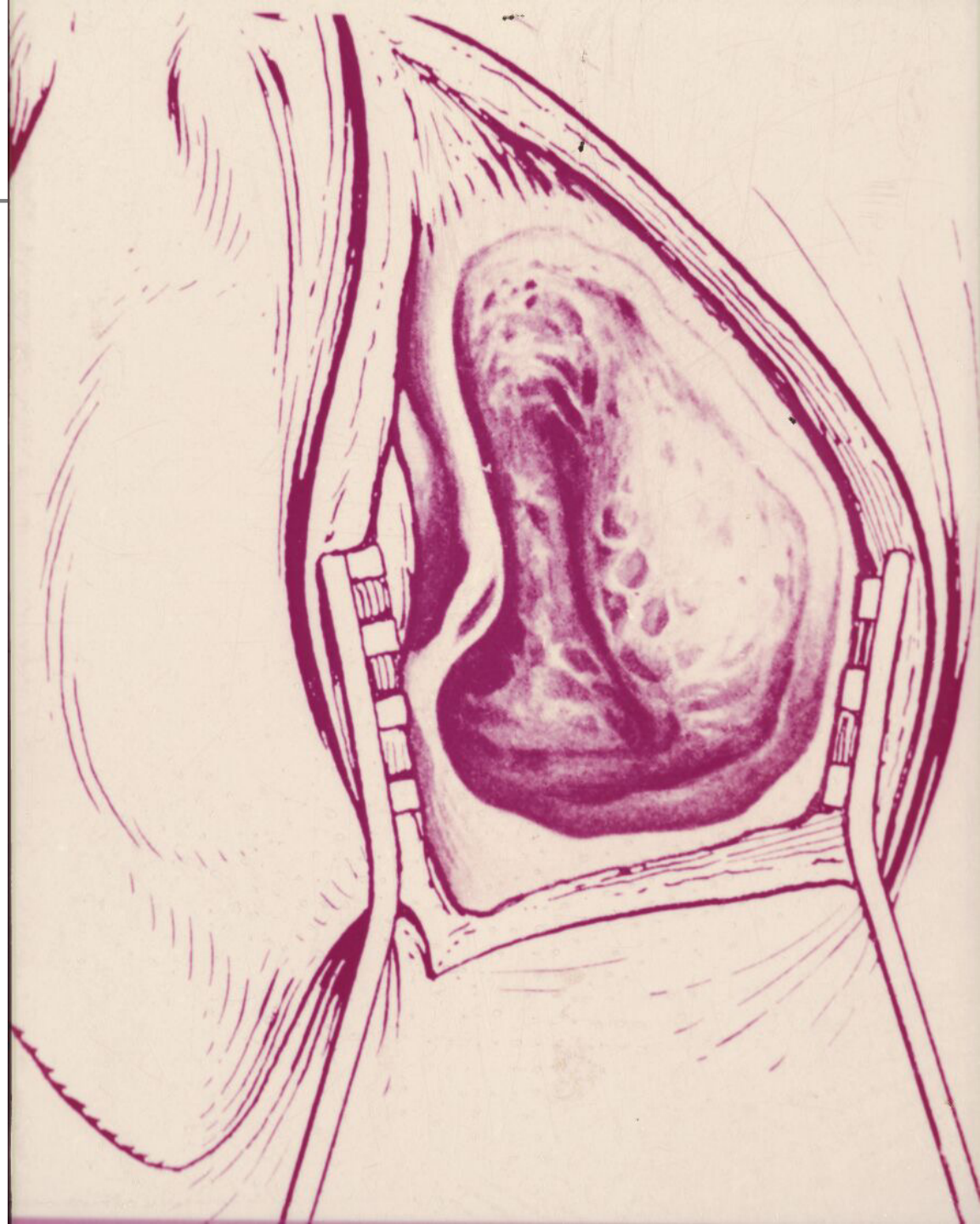
Approach

- Schwartz - via planum mastoideum into antrum
- Stake - via atticus into antrum
- Zaufal – via posterior wall into aditus ad antrum and from this anteriorly and posteriorly

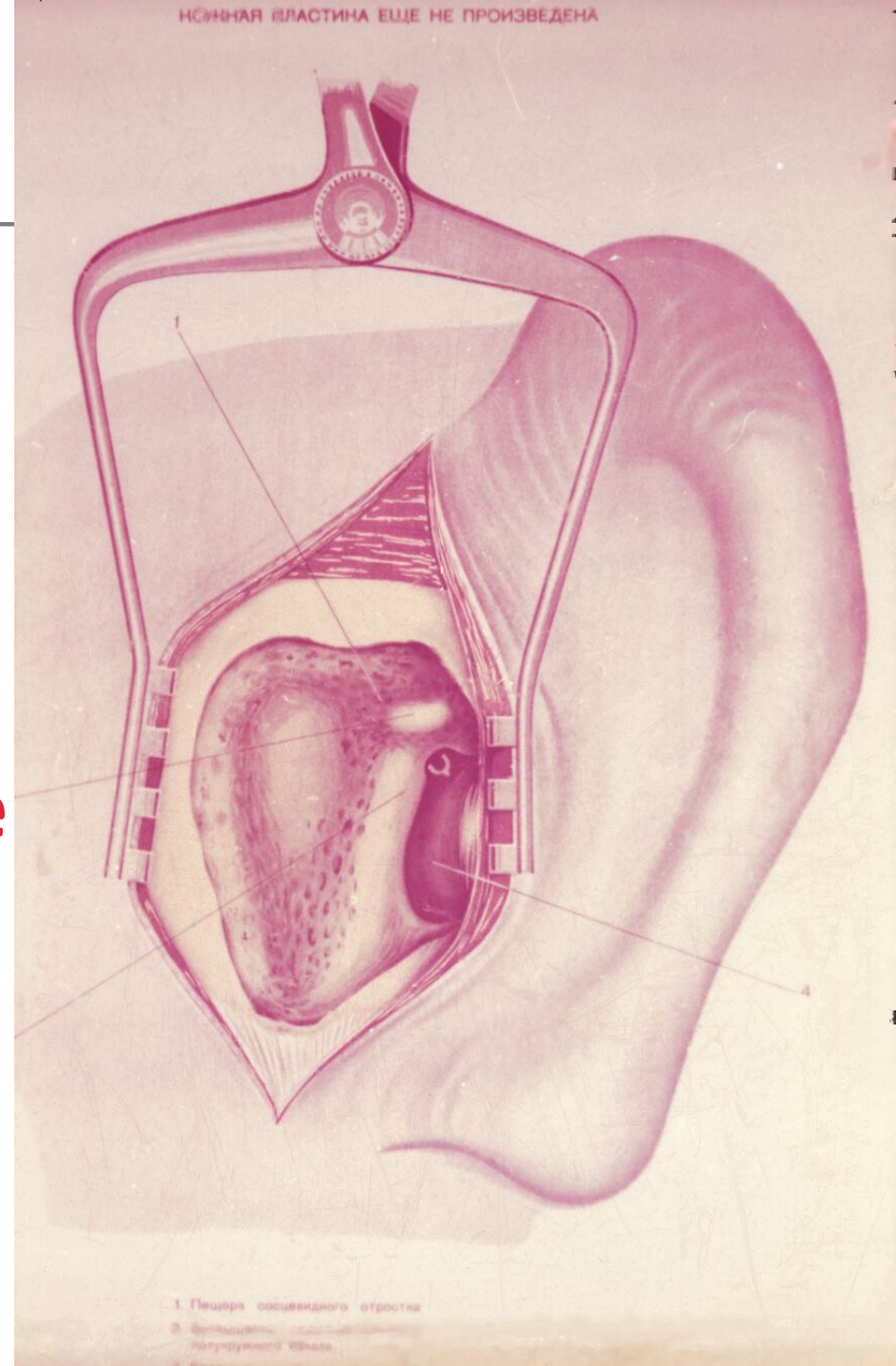
Sanation surgery

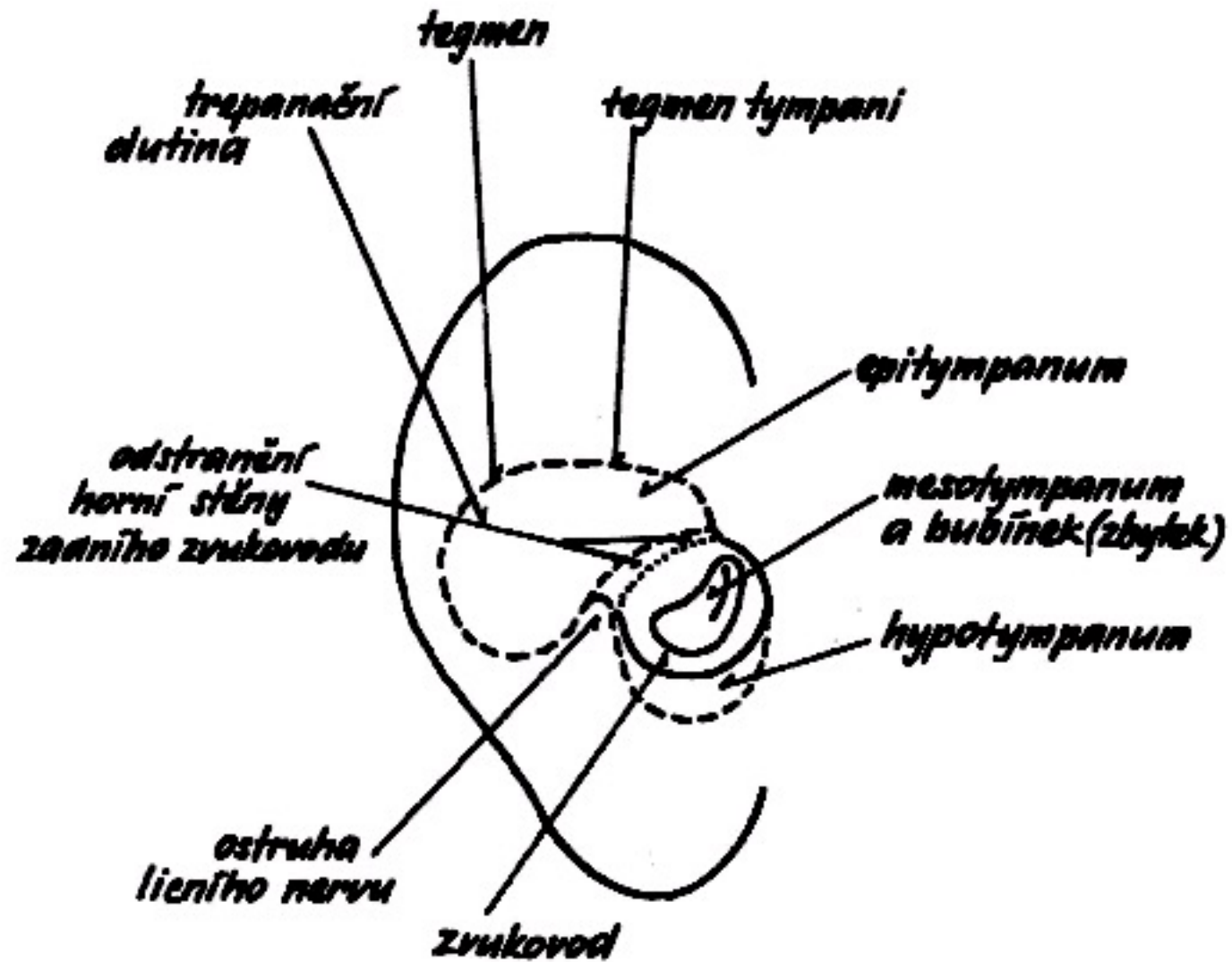
- **atticotomy**
- **meatoantrotomy**
- **atticoantrotomy**
- **tympanomastoidektomy**

Status post mastoid- ectomiam



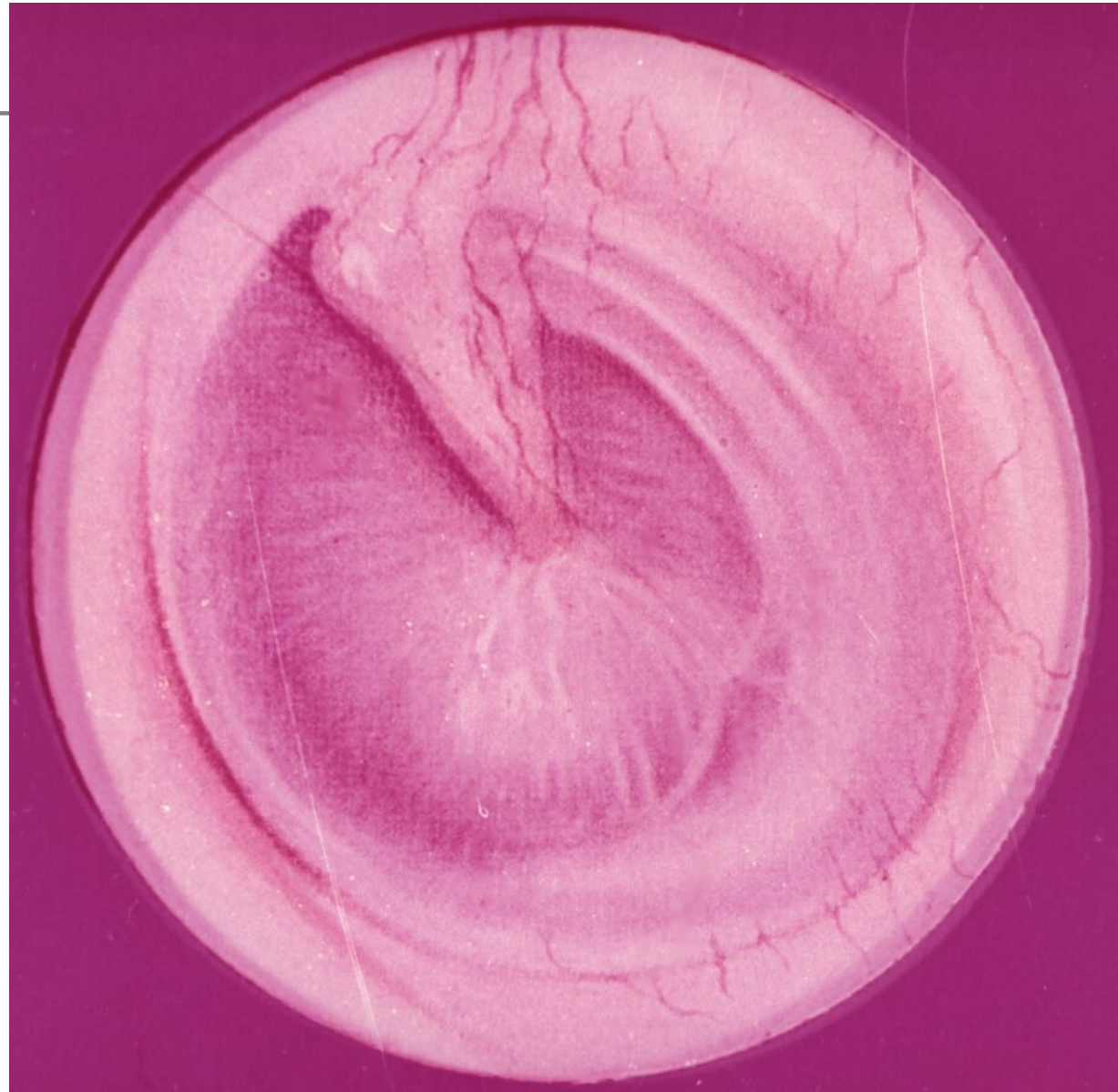
Status post atticoantrotomiam (radical- conservative surgery)



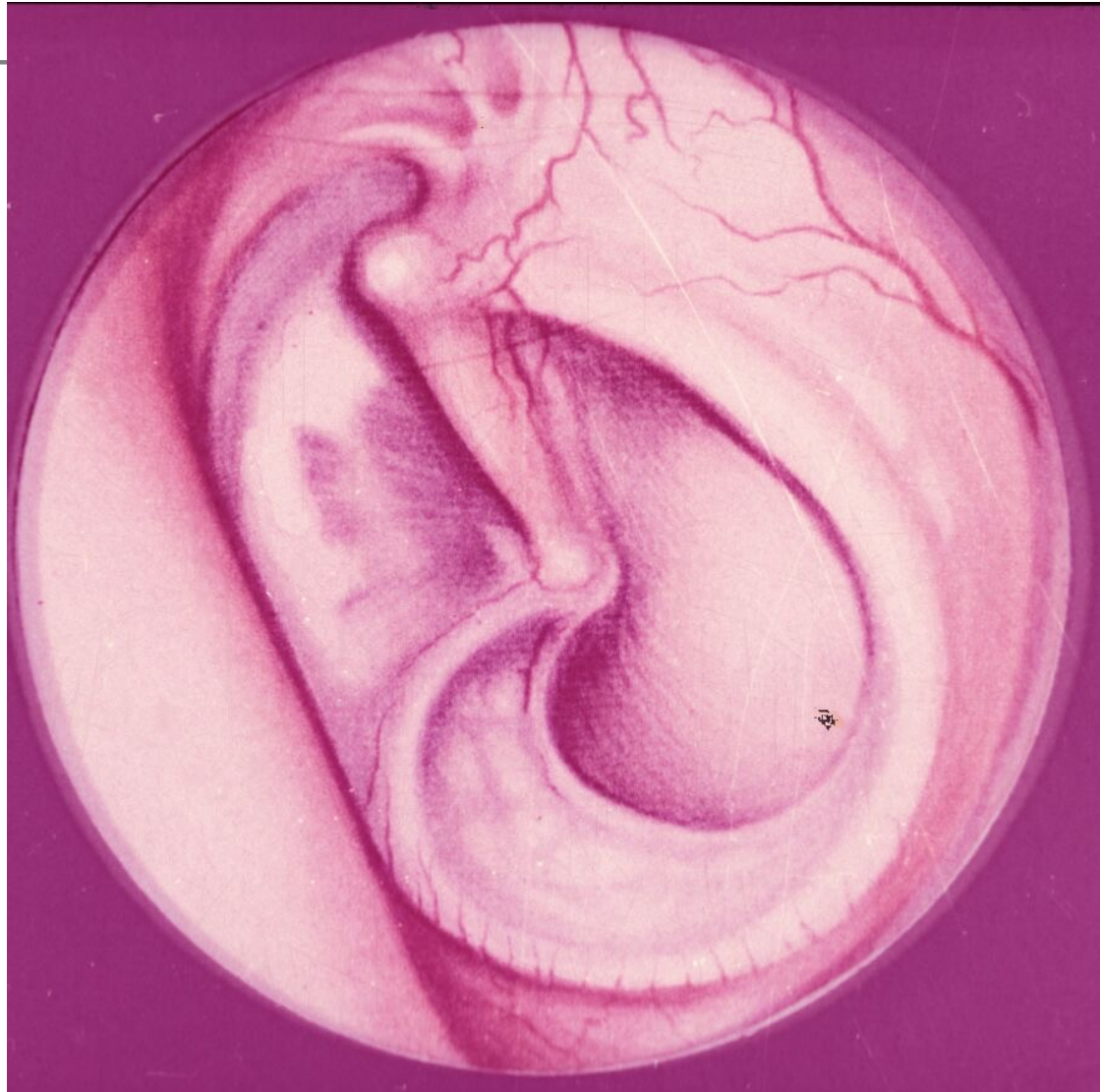

Relation between external meatus and trepanation cavity

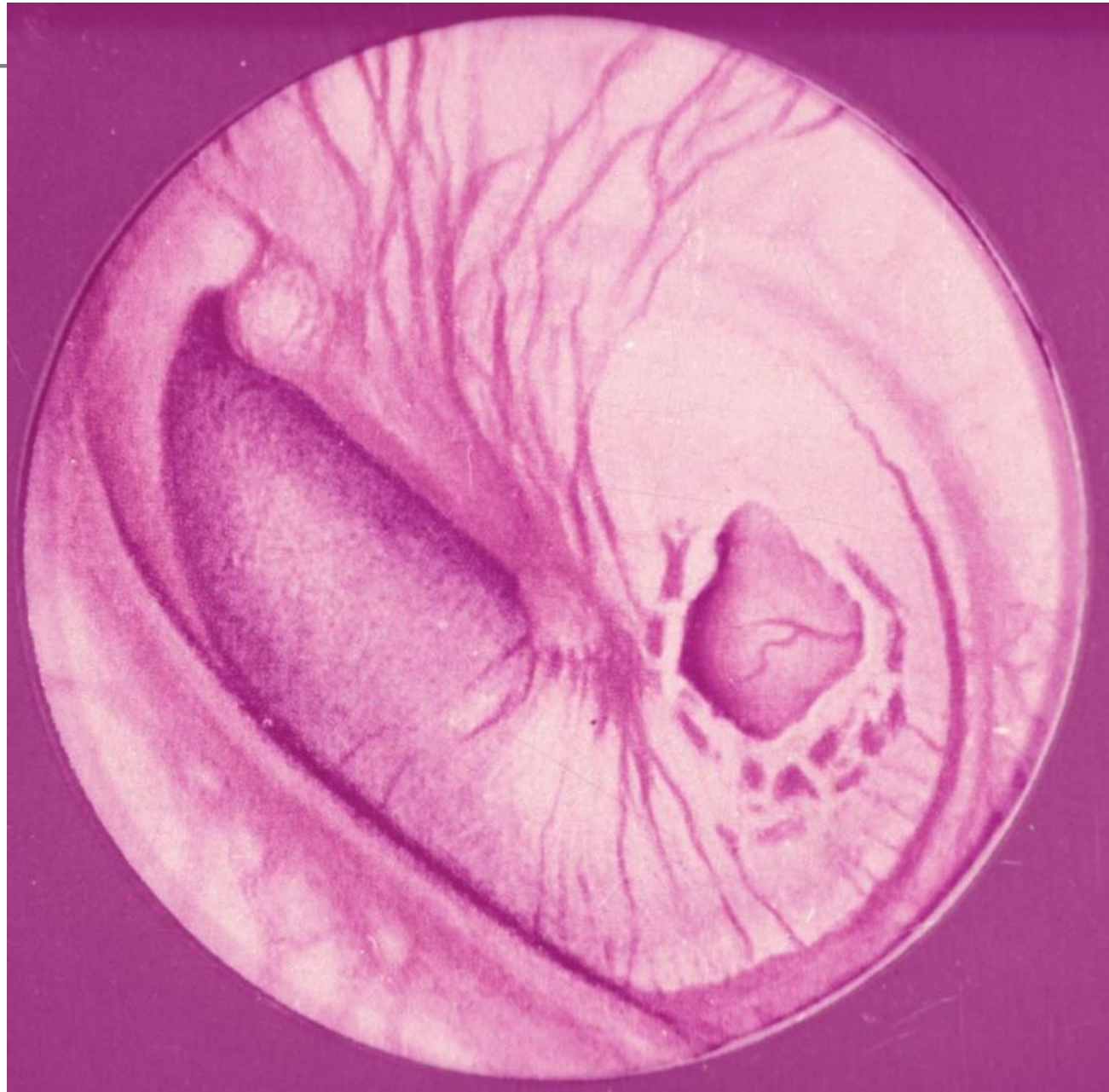Scared thickened ear drum after otitis



**Ear drum
with atrophic scar
and calcification
after otitis**



Injury perforation





Surgery treatment - reconstructive surgery (tympanoplasty)

Division according to Wulstein

I. Myringoplasty

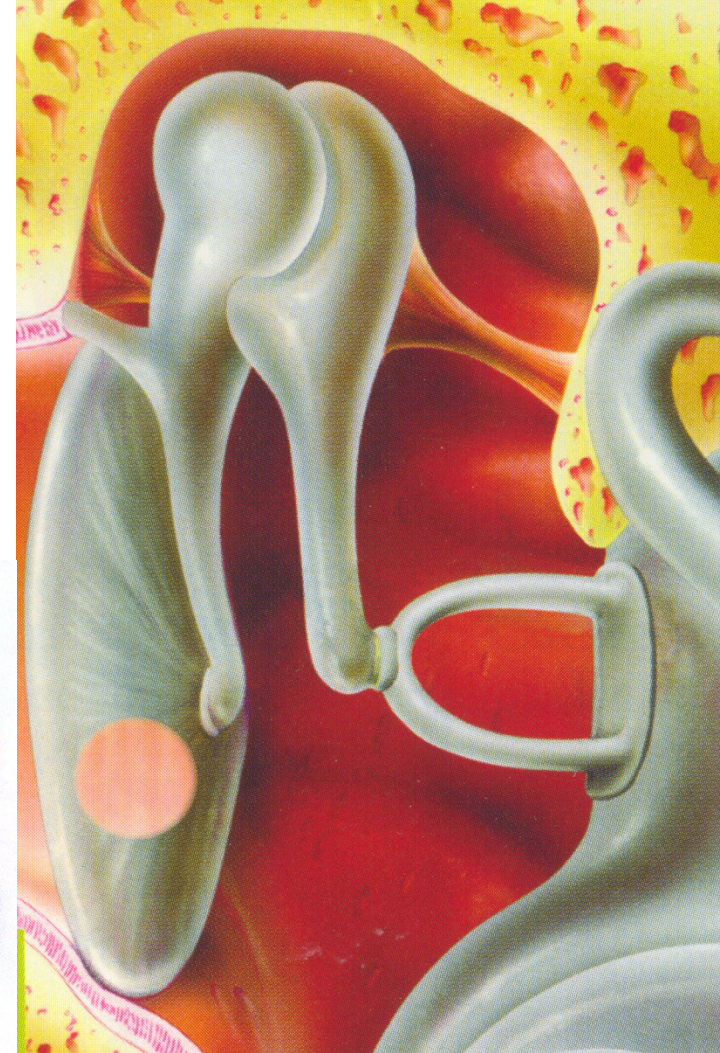
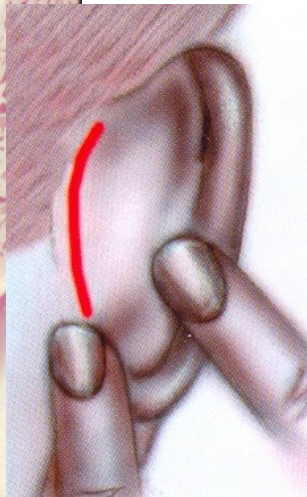
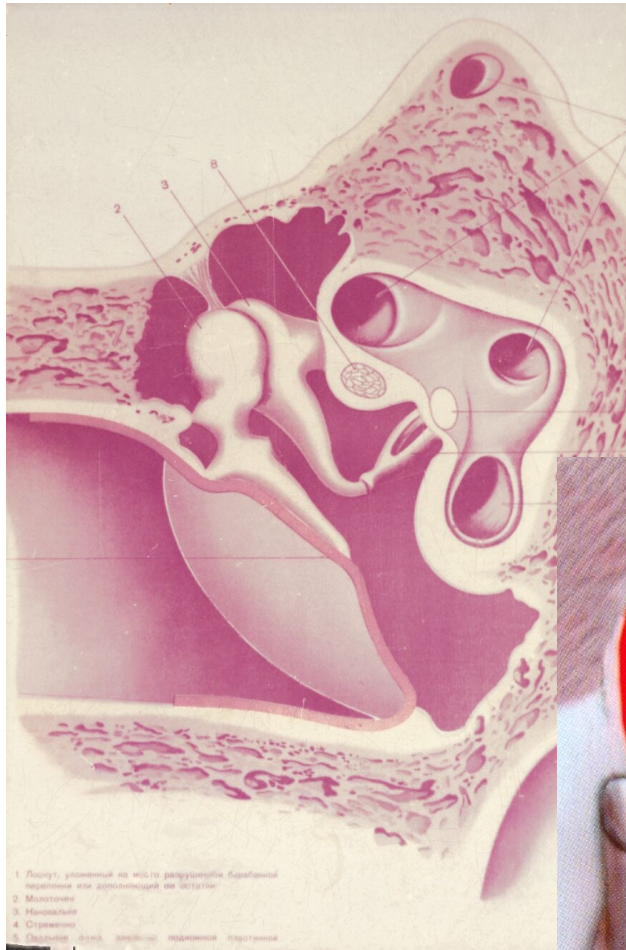II. Columelisation of incus

III. Columelisation (stapes)

IV. Ekranisation (shade of round window)

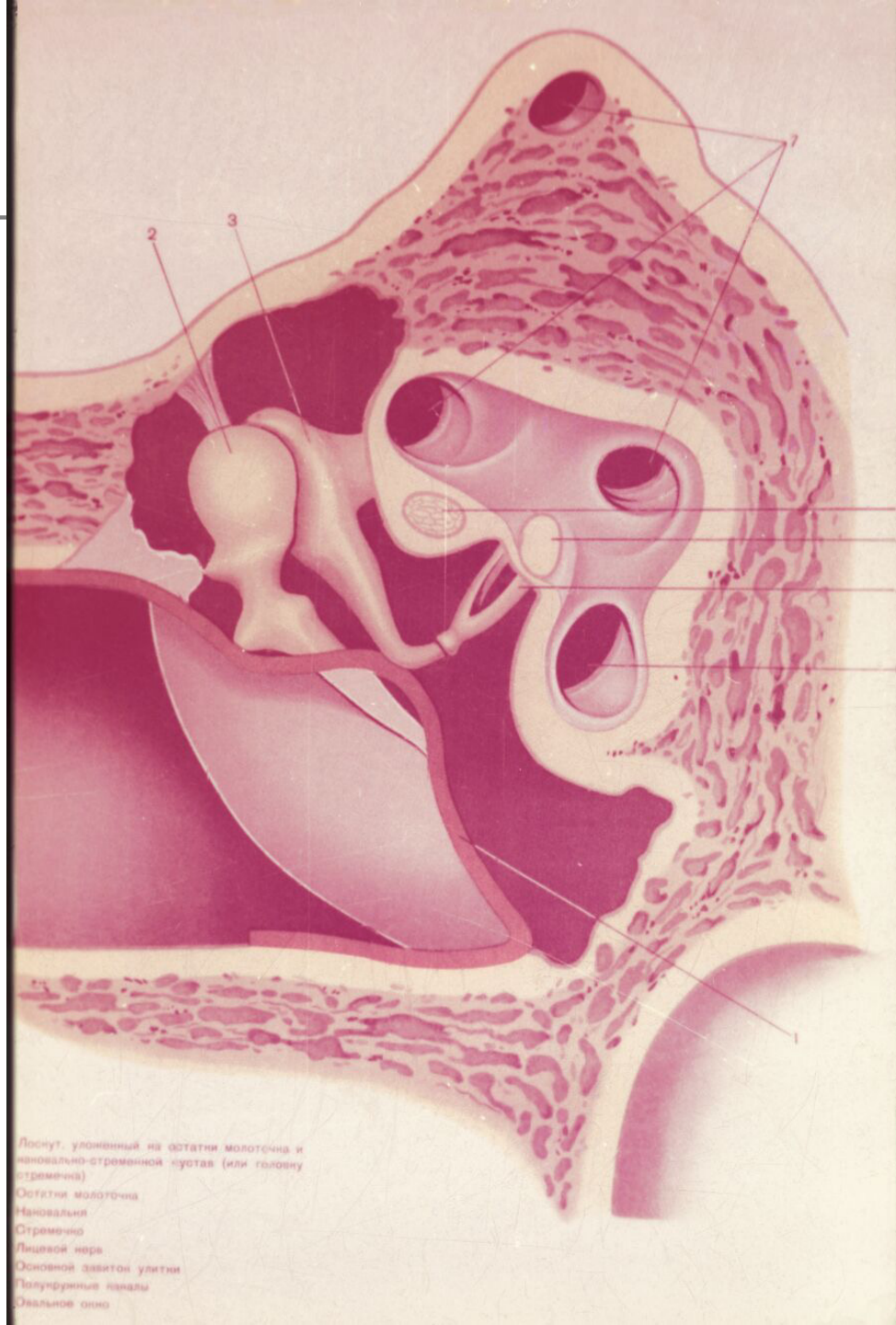
V. Fenestration of labyrinth

Tympanoplasty - type I. Myringoplasty



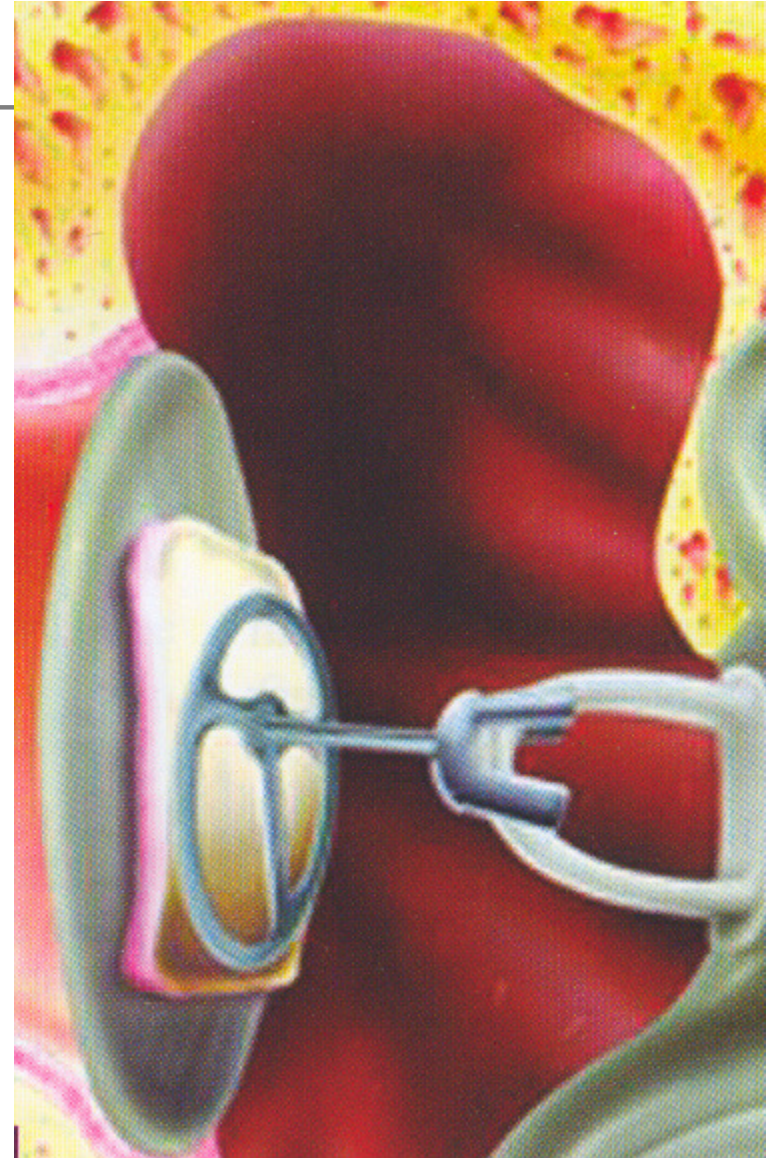
Tympanoplasty II.

Columalisation of incus



Tympanoplasty type III.a

damaged incus and malleus,
stapes intact, sound conducted
by prosthesis PORP, underlayed
by cartilage






PORP
partial
ossicular
replacement
prosthesis



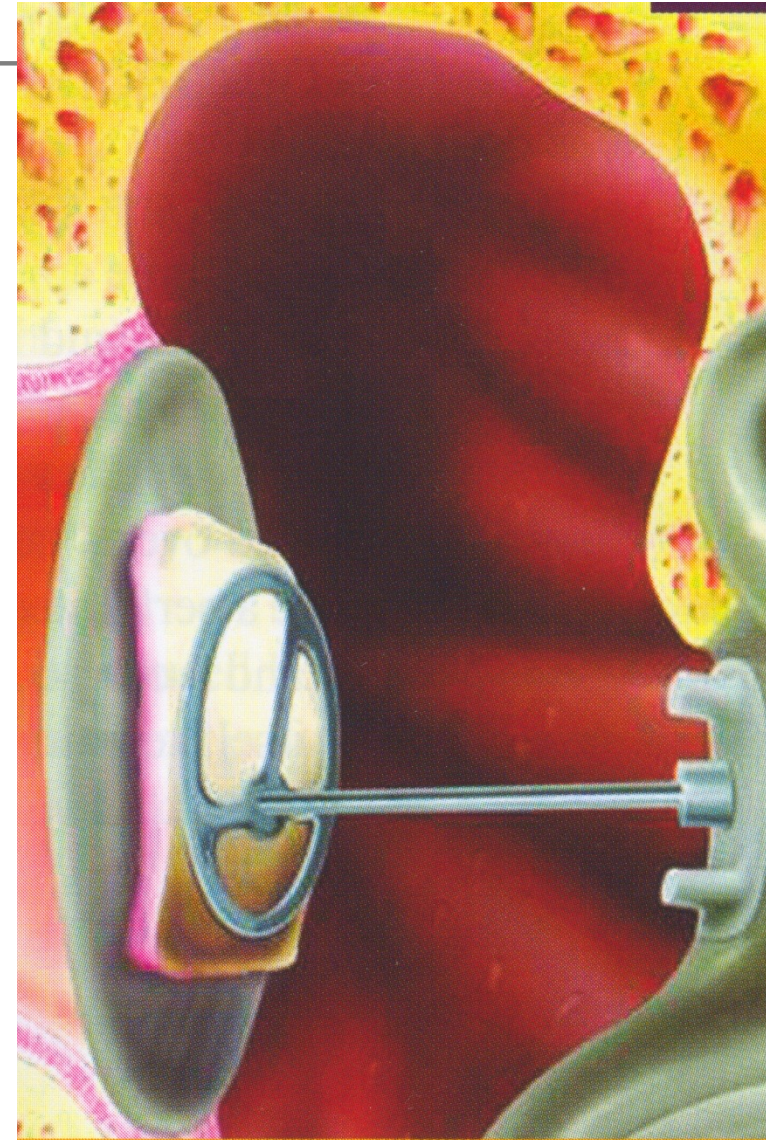
PORP





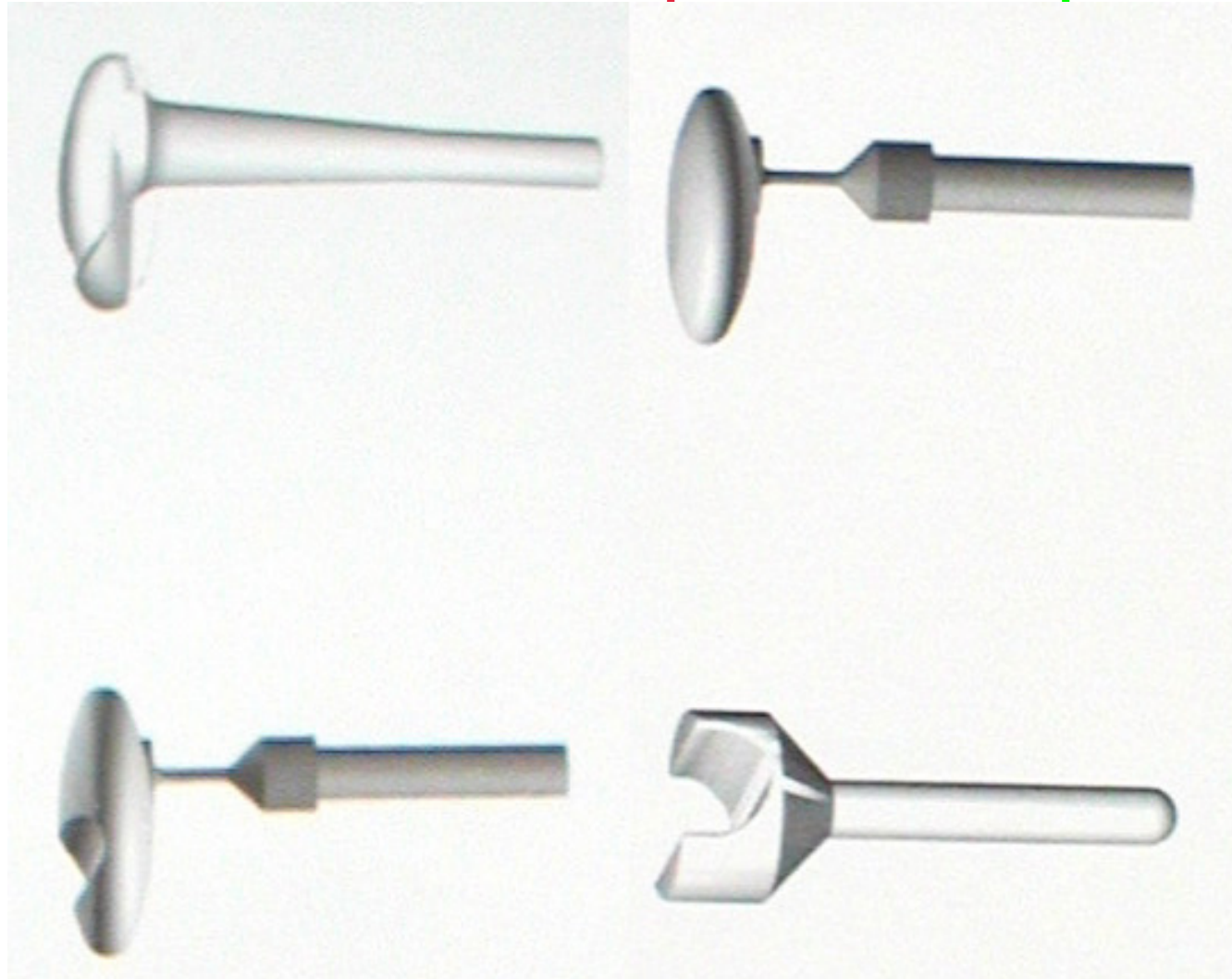
Tympanoplasty type III.b

**damaged incus and malleus,
stapes without suprastructures,
sound conducted by prosthesis
TORP, underlayed by cartilage.
Connection directly between basis
stapedis and ear drum.**



TORP

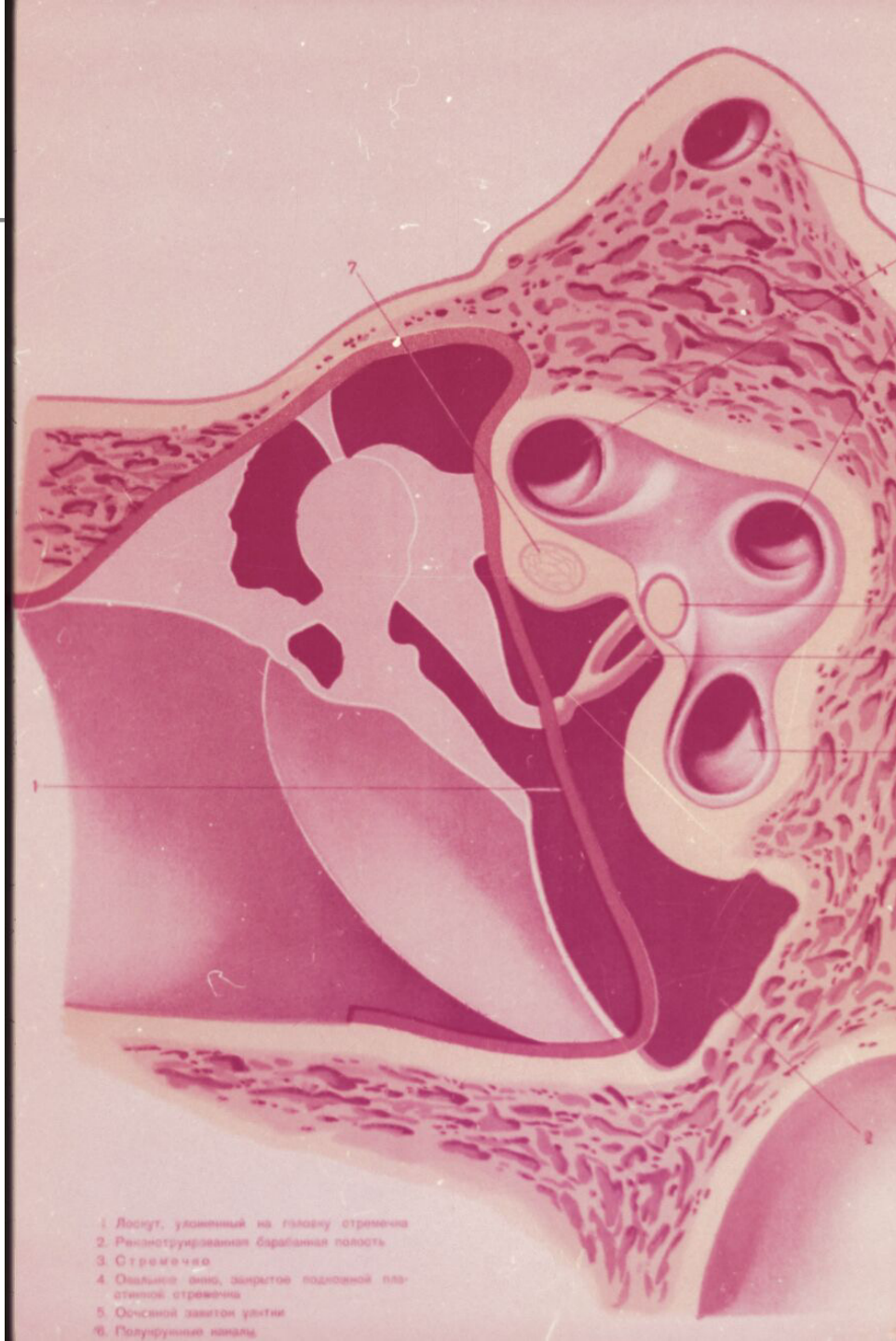Total ossicular replacement prosthesis



Tympanoplasty type III.c

Columelisation

damaged incus, malleus,
stapes intact, connected
directly to ear drum -
myringostapedopexis

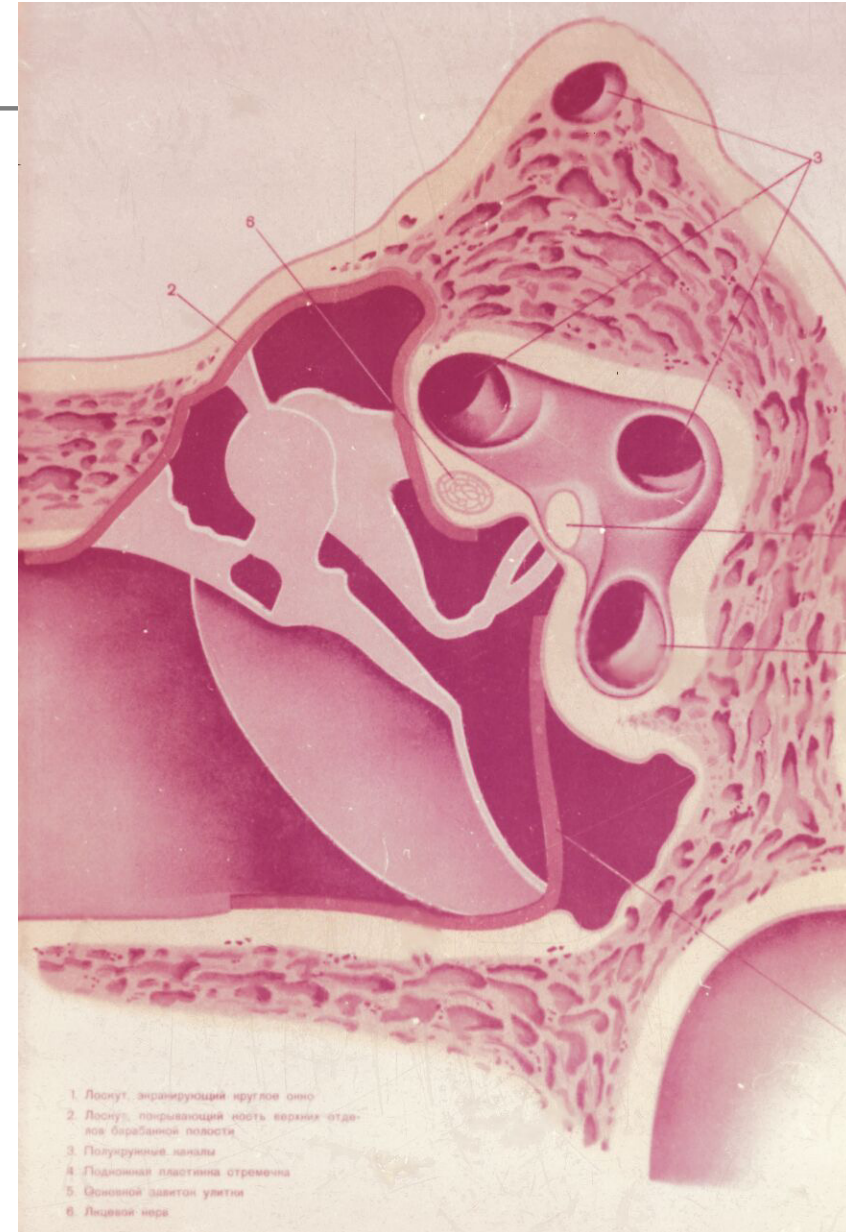


Tympanoplasty

typ IV.

Ecranisation

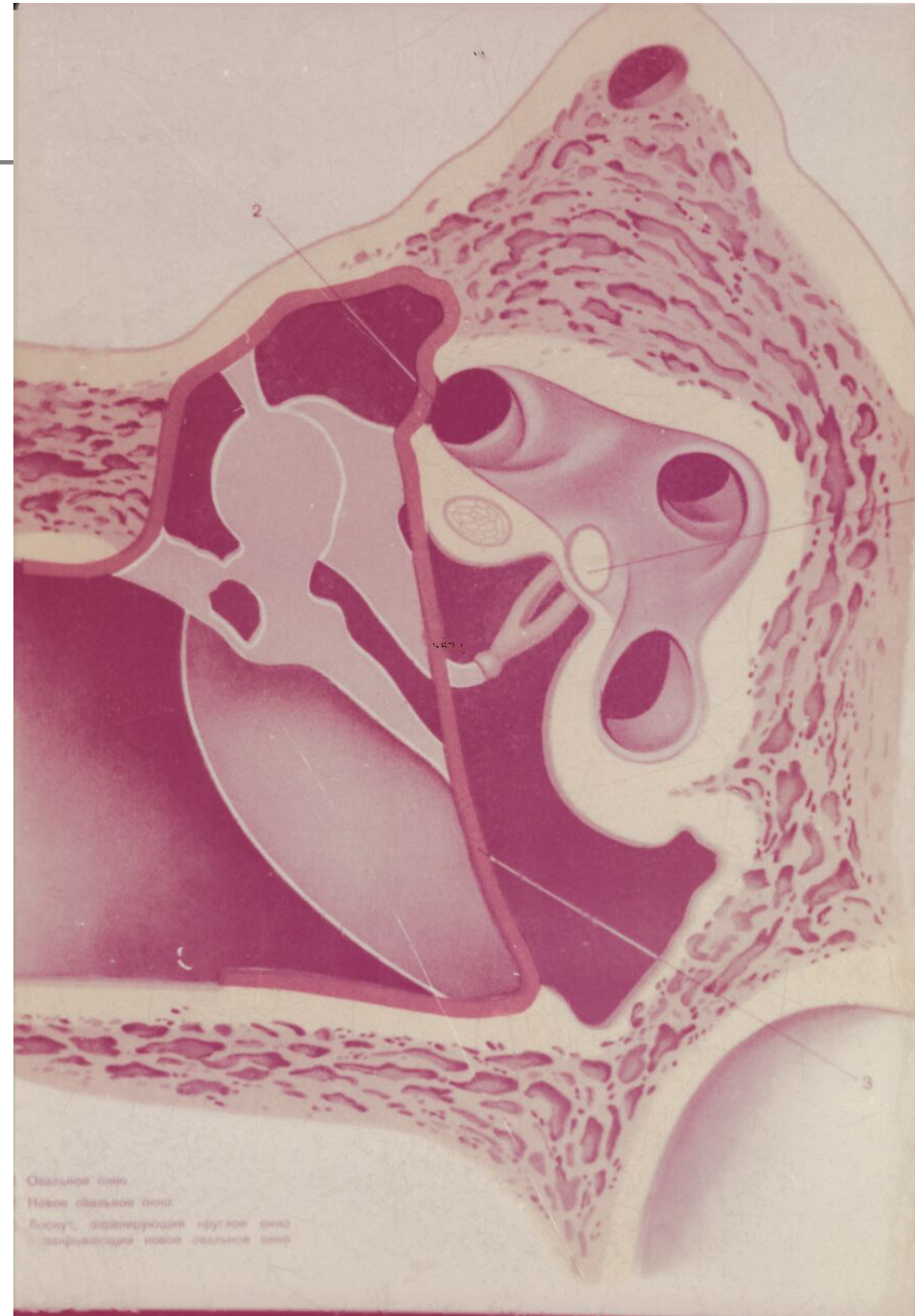
(round window shielded)



Tympanoplasty type V.

Fenestration

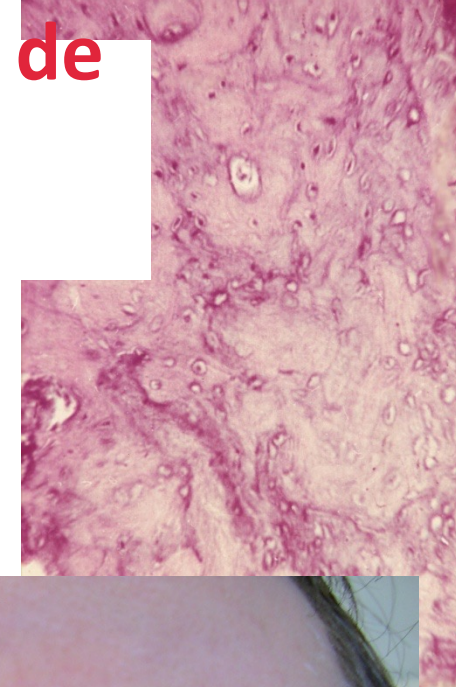
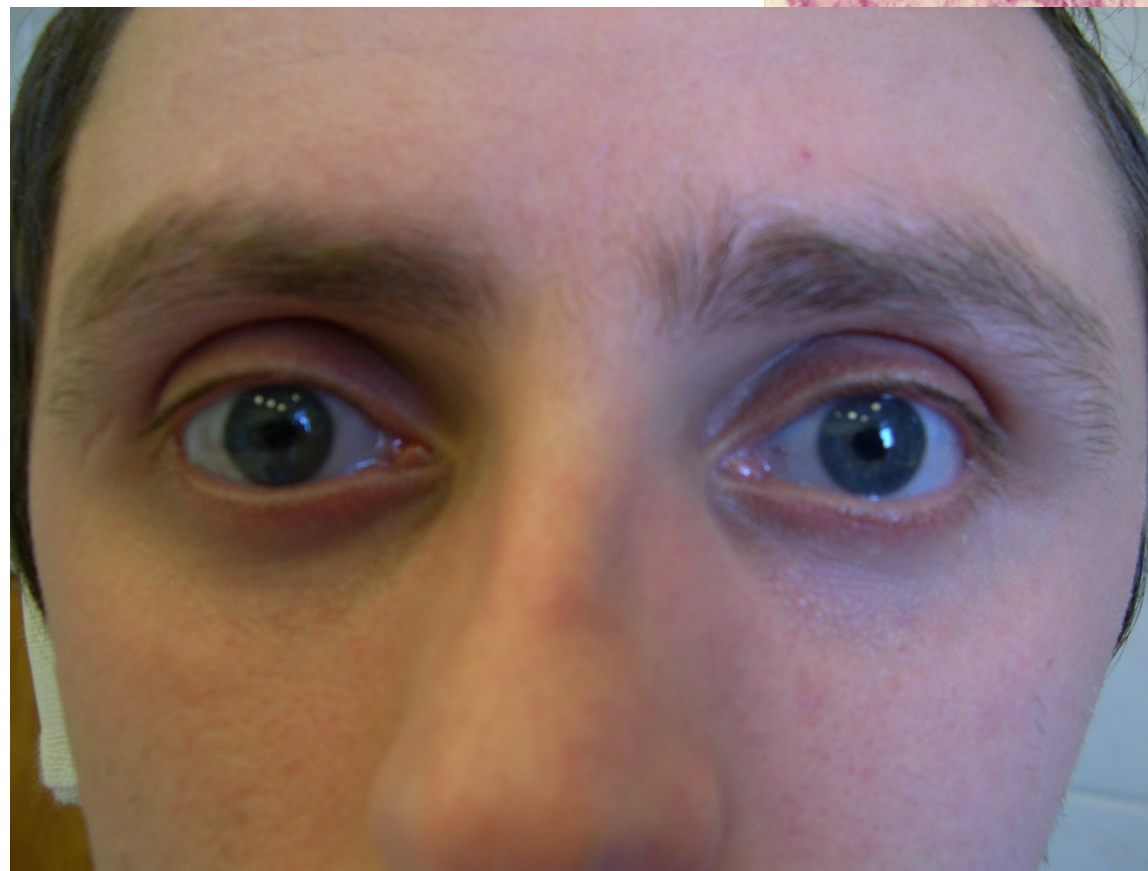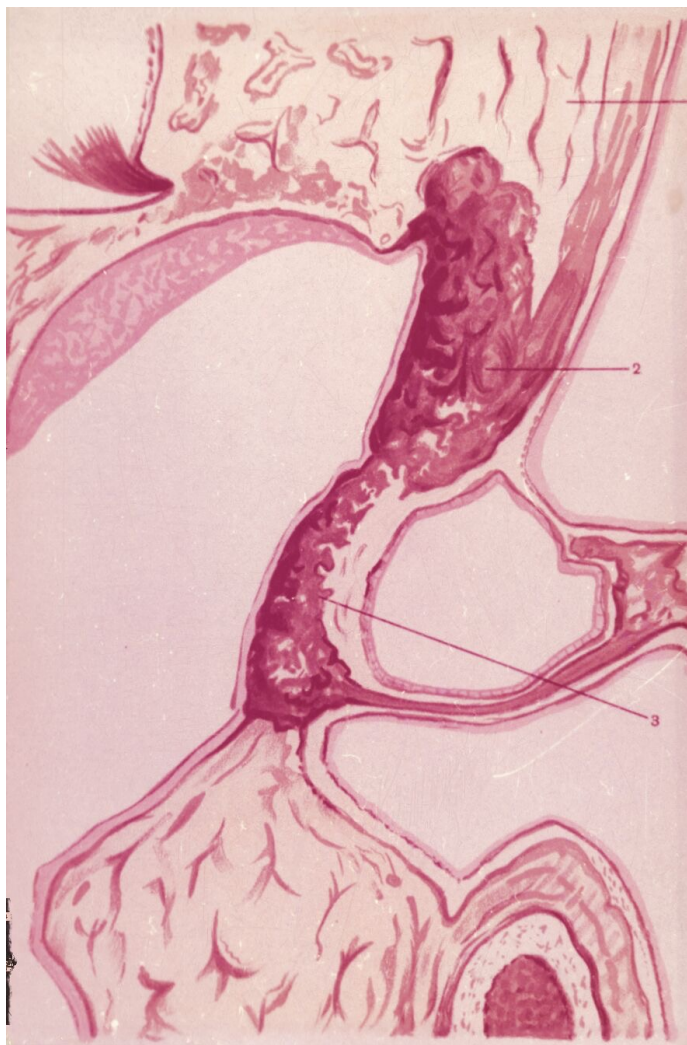(new window created into labyrinth)



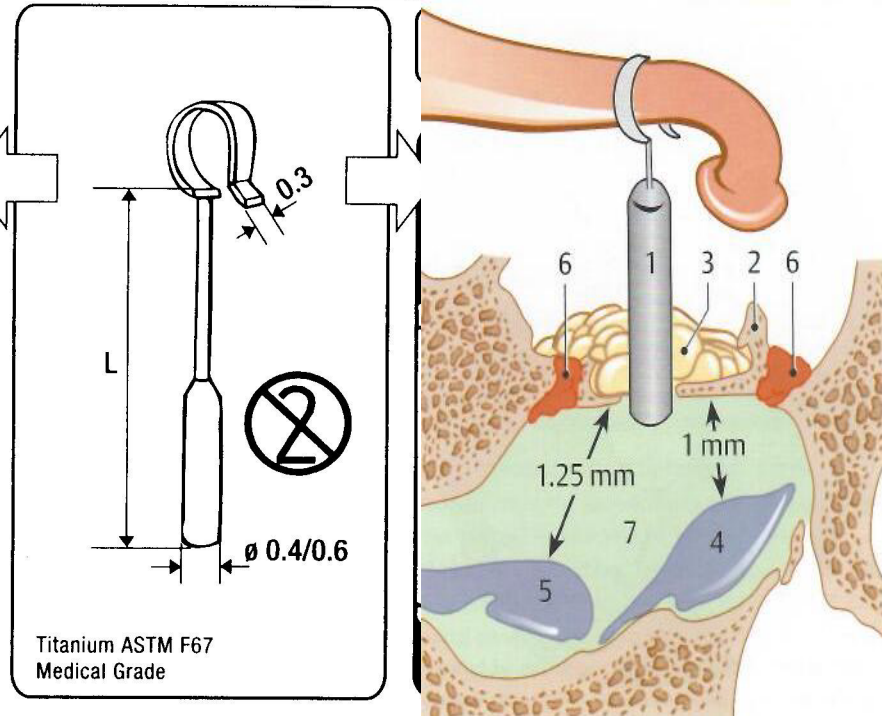
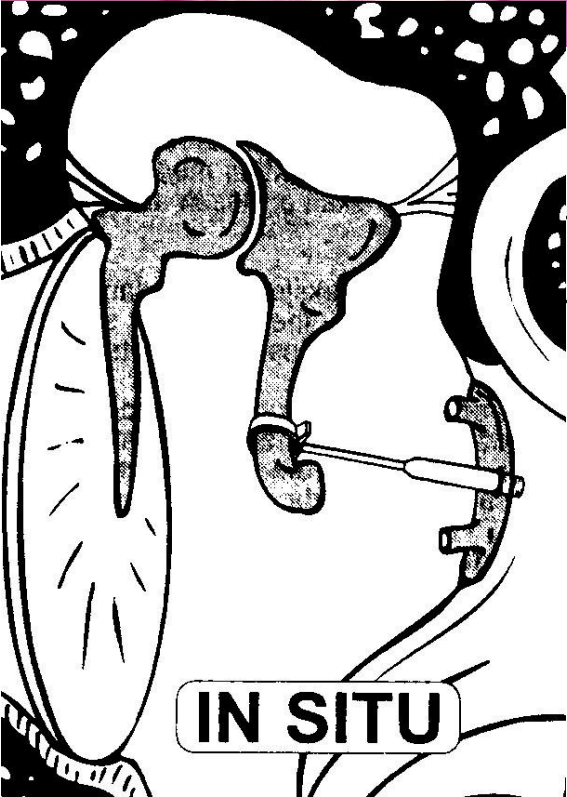
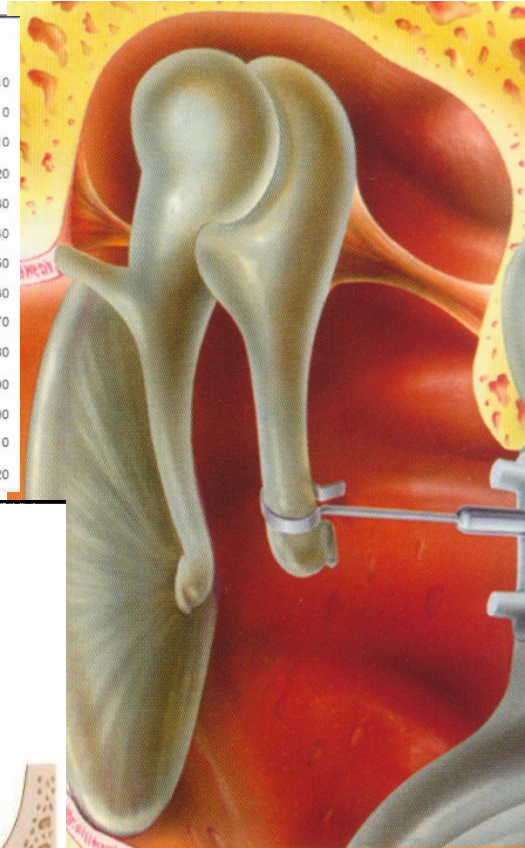
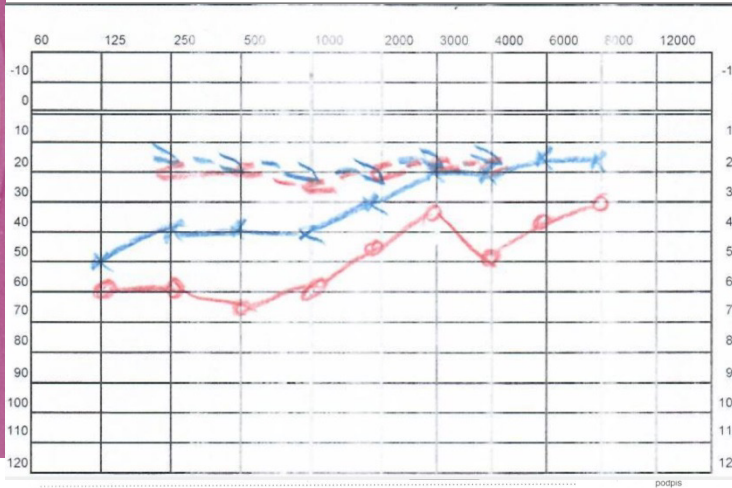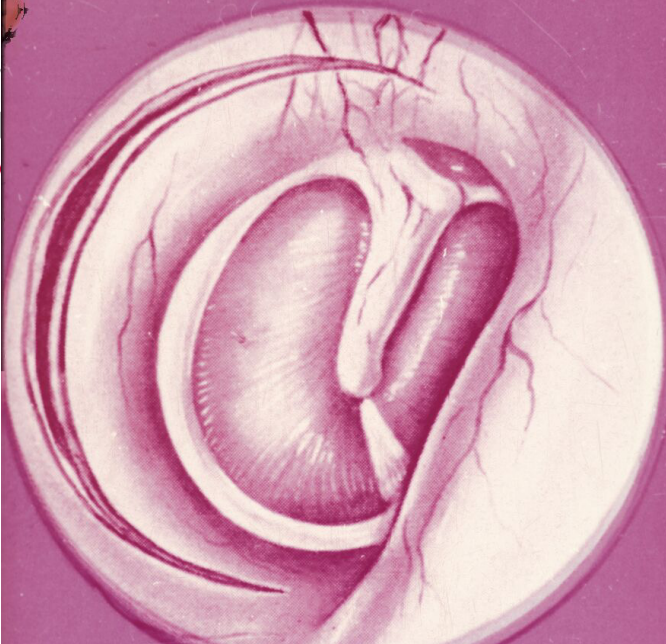
Syndrom Van den Hoeve de Klein

osteogenesis imperfecta
fixatio stapedis on both sides
blue sclera („the white of the eye“)

Otosclerosis vs. tympanosclerosis



Stapedotomy





K-PISTON STAPES PROSTHESIS

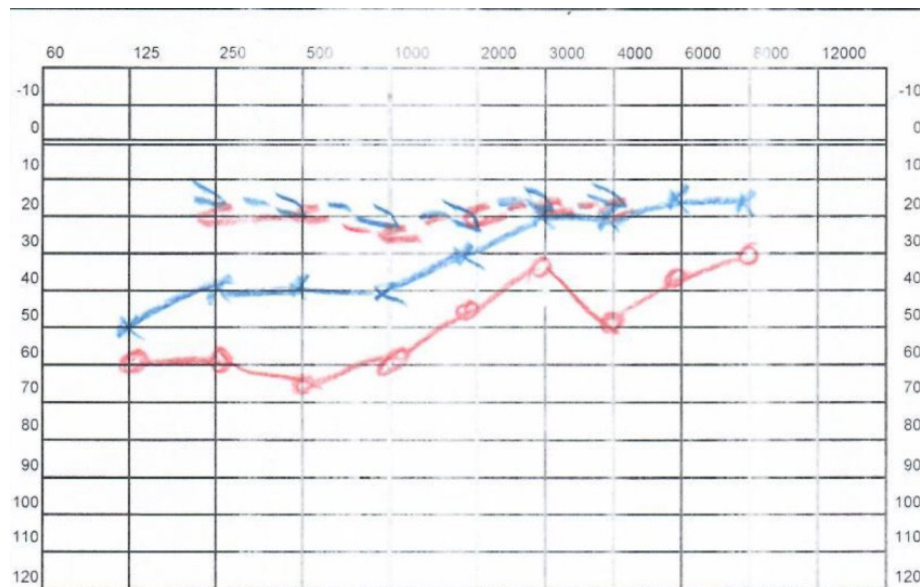

Clip piston maleovestibulopexis

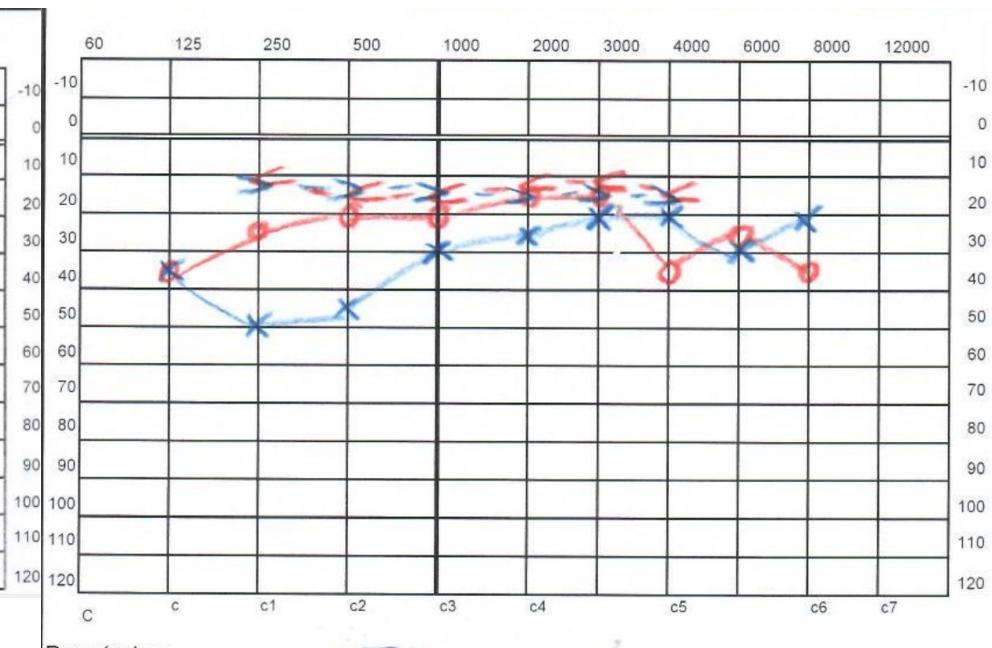


Stapedotomia

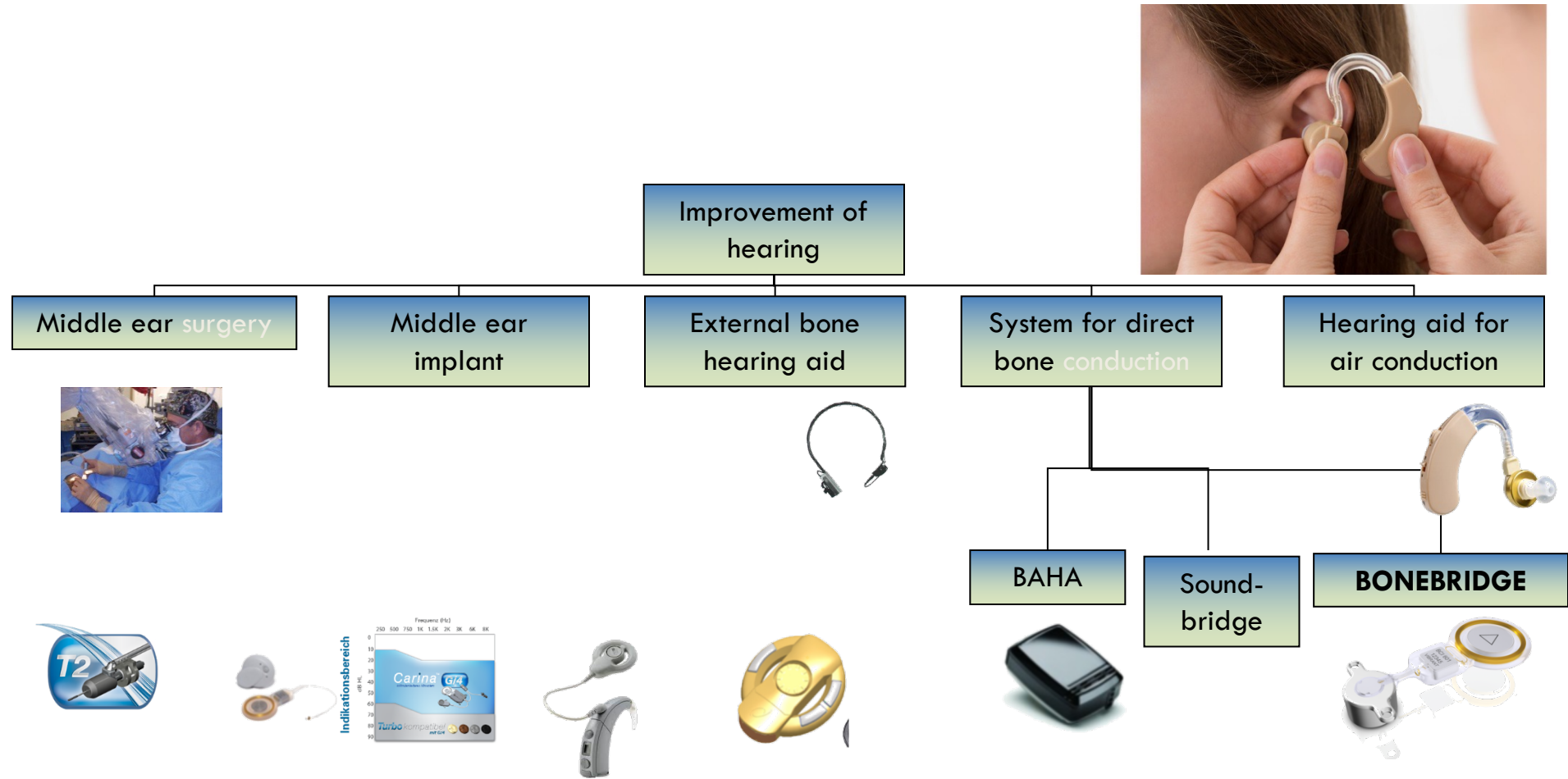
Hypacusis perc. I. utr.



St.p. stapedotomiam I.dx.

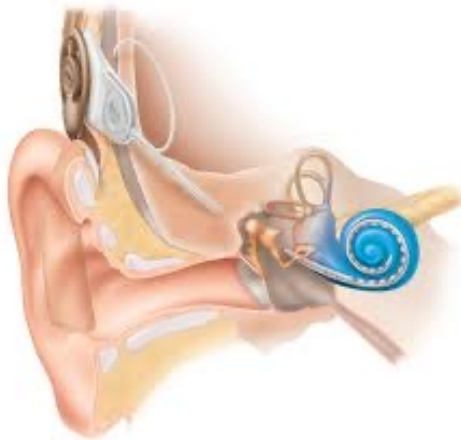

Possibility for improvement of hearing by surgery and prosthetics

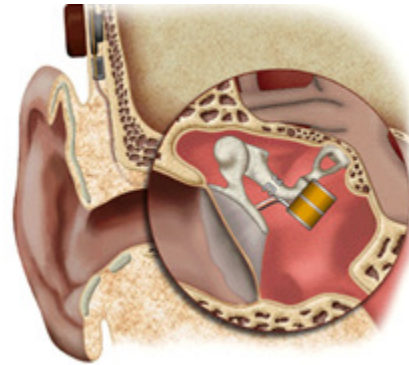


Implantable hearing aids

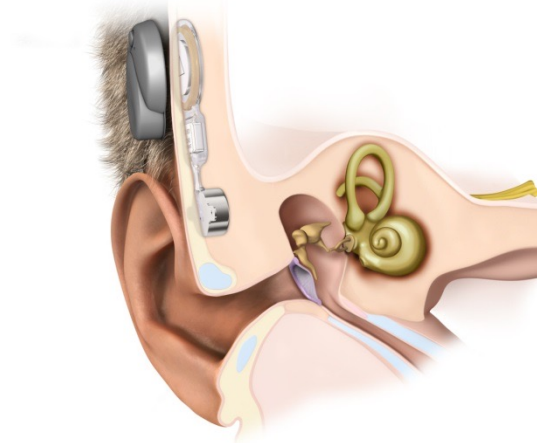
Cochlear
implants



Middle ear
implants (MEI)



Bone conduction
implants



BONEBRIDGE

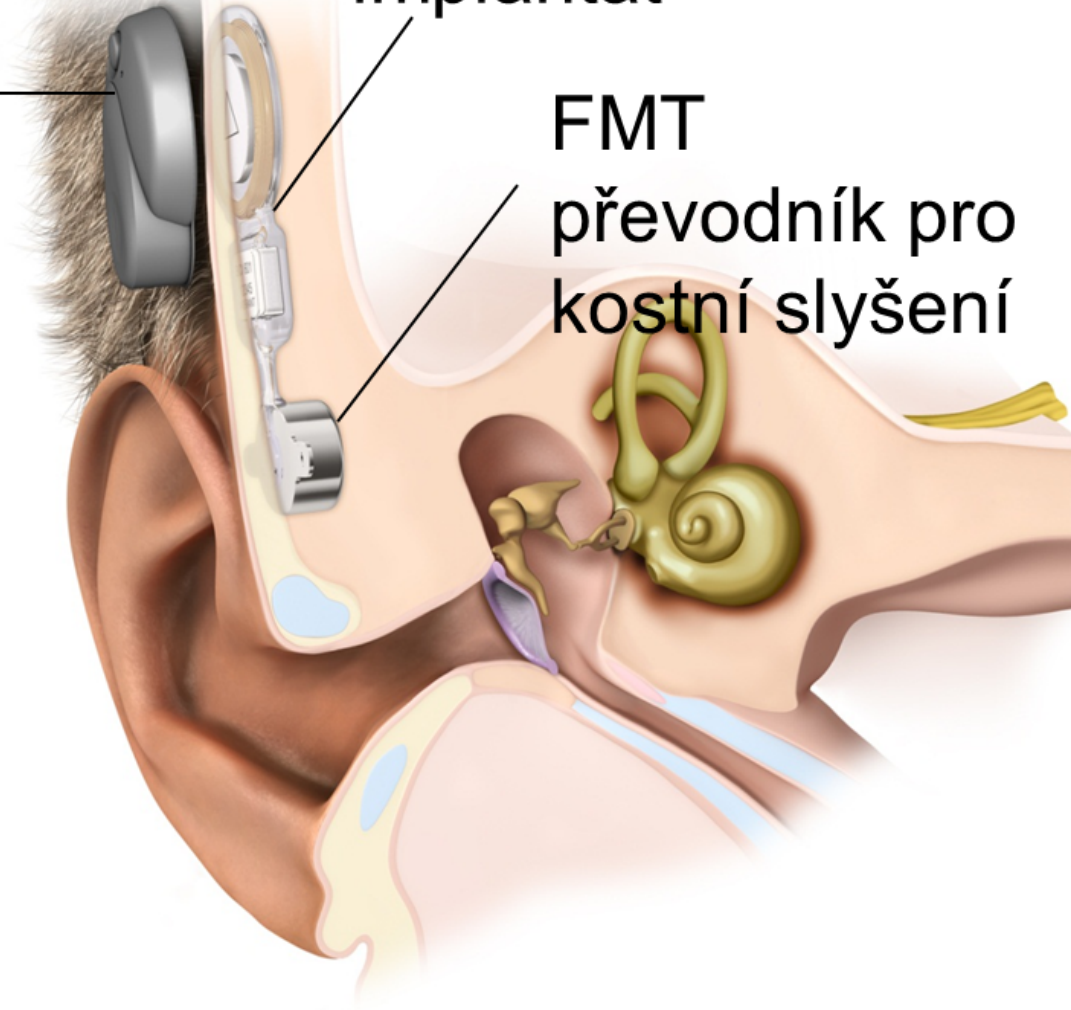




audioprocessor

implantát

FMT
převodník pro
kostní slyšení

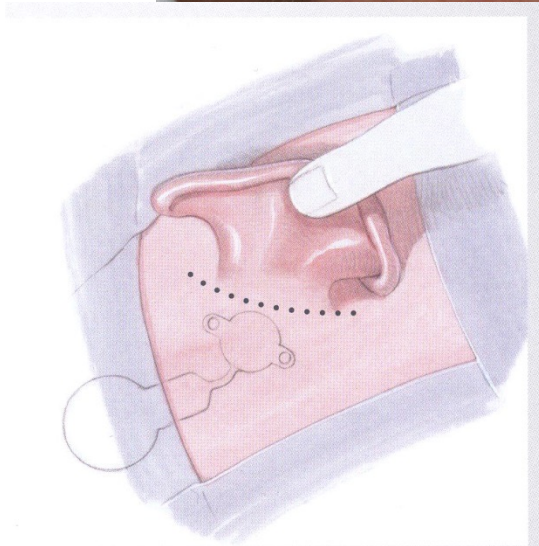
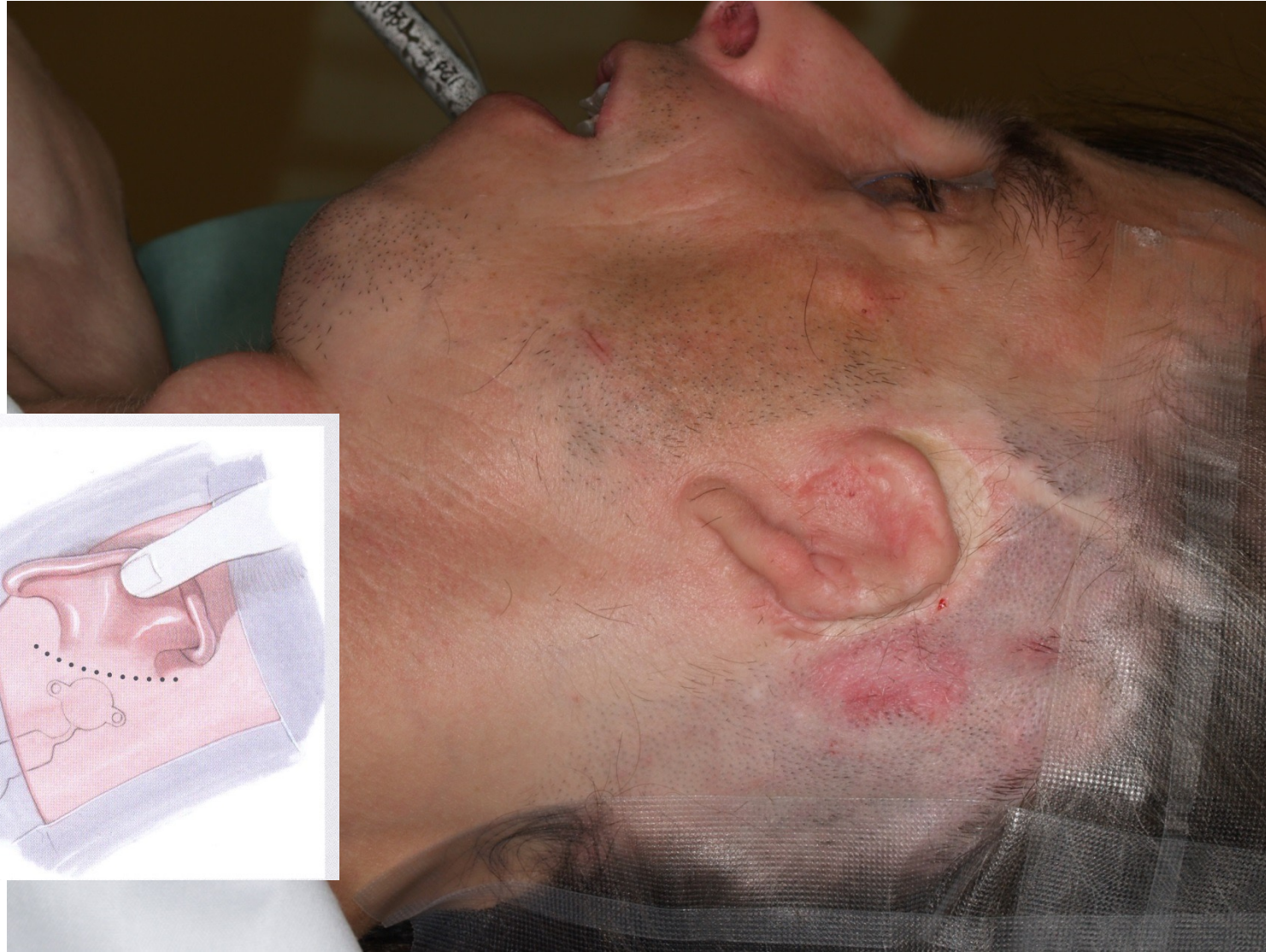

BC-FMT = Bone Conduction Floating Mass Transducer




First implantation of BONEBRIDGE in Czech rep.

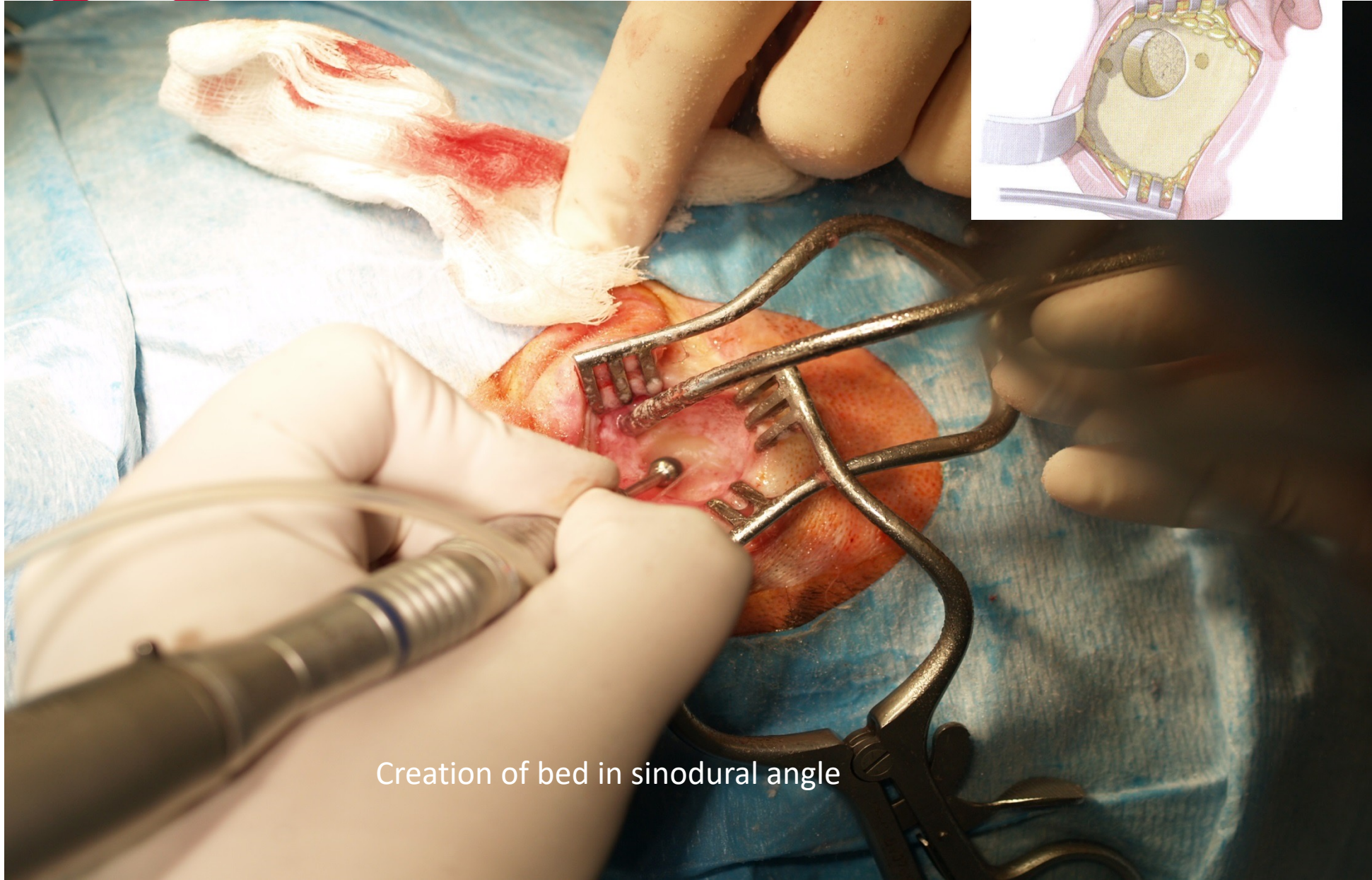
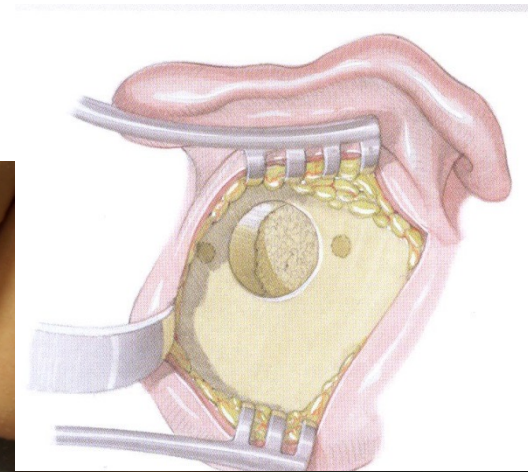
- Patient with Treacher-Collins syndrome and atresia meatus acust. ext.
- Normal bone conduction, full „cochlear reserve“ bothsided
- Surgery: ENT Clinic St. Ann Faculty hospital 29.8.2014



Incision

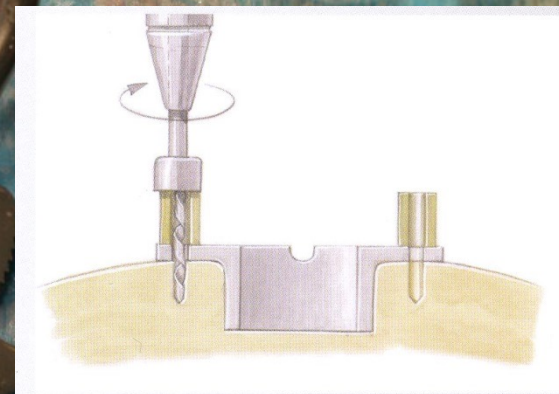
Estimation of cutaneous flap thickness (until 7 mm)



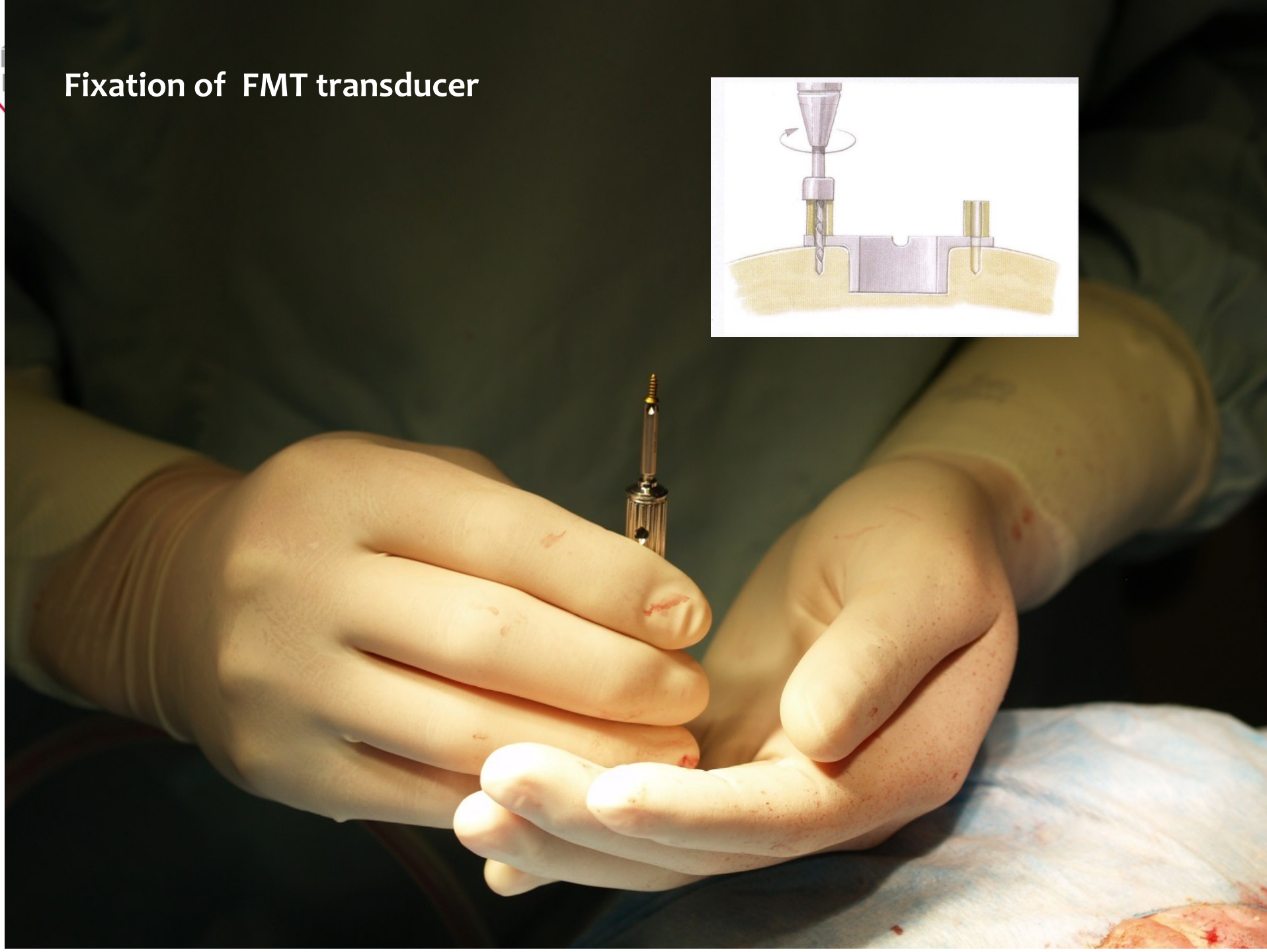
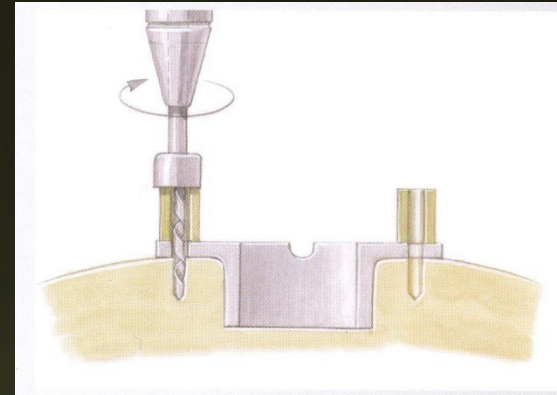


Creation of bed in sinusoidal angle

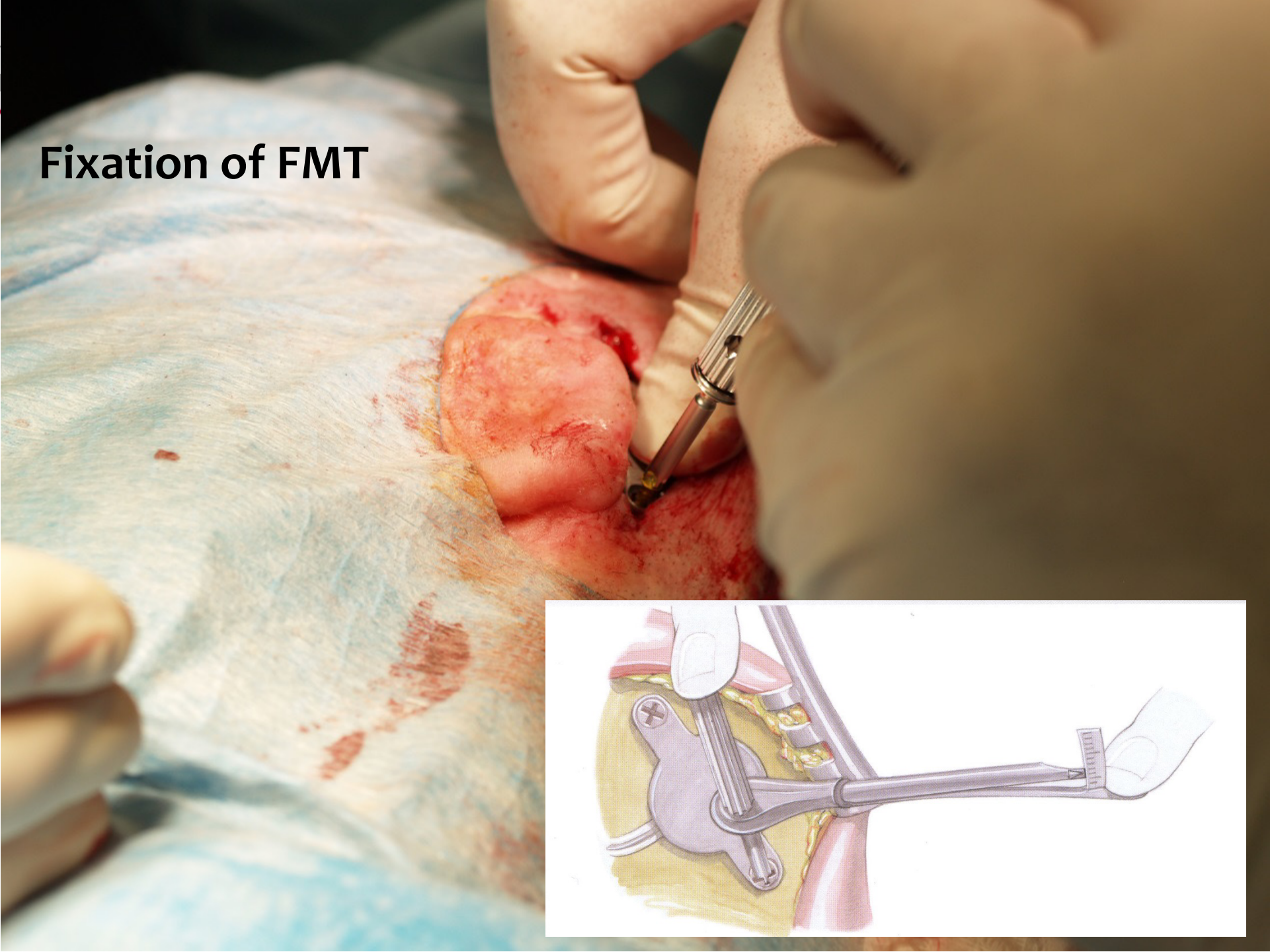
Gauge for FMT (T-sizer)



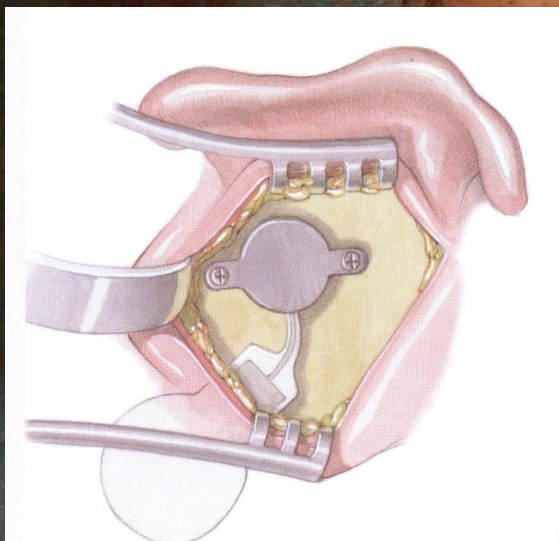
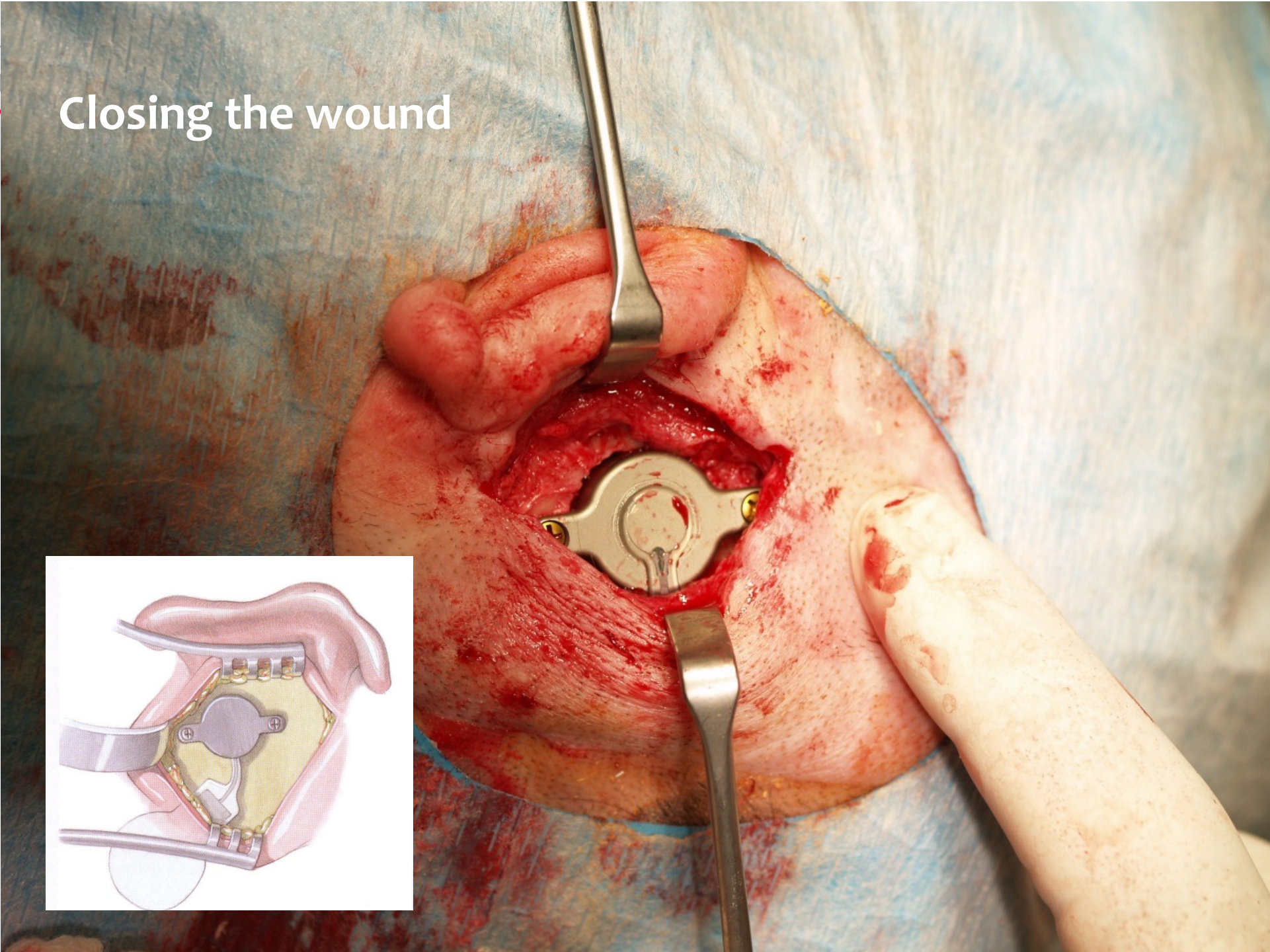
Fixation of FMT transducer



Fixation of FMT

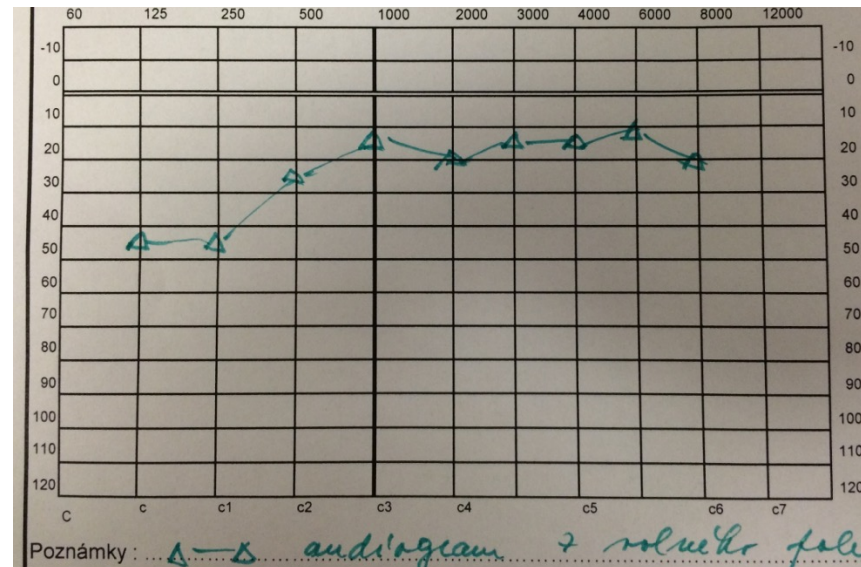
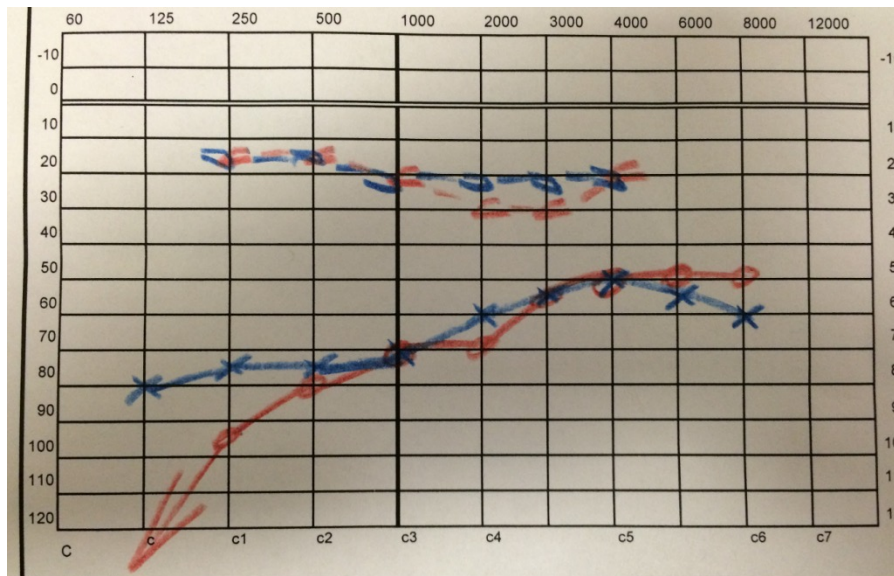


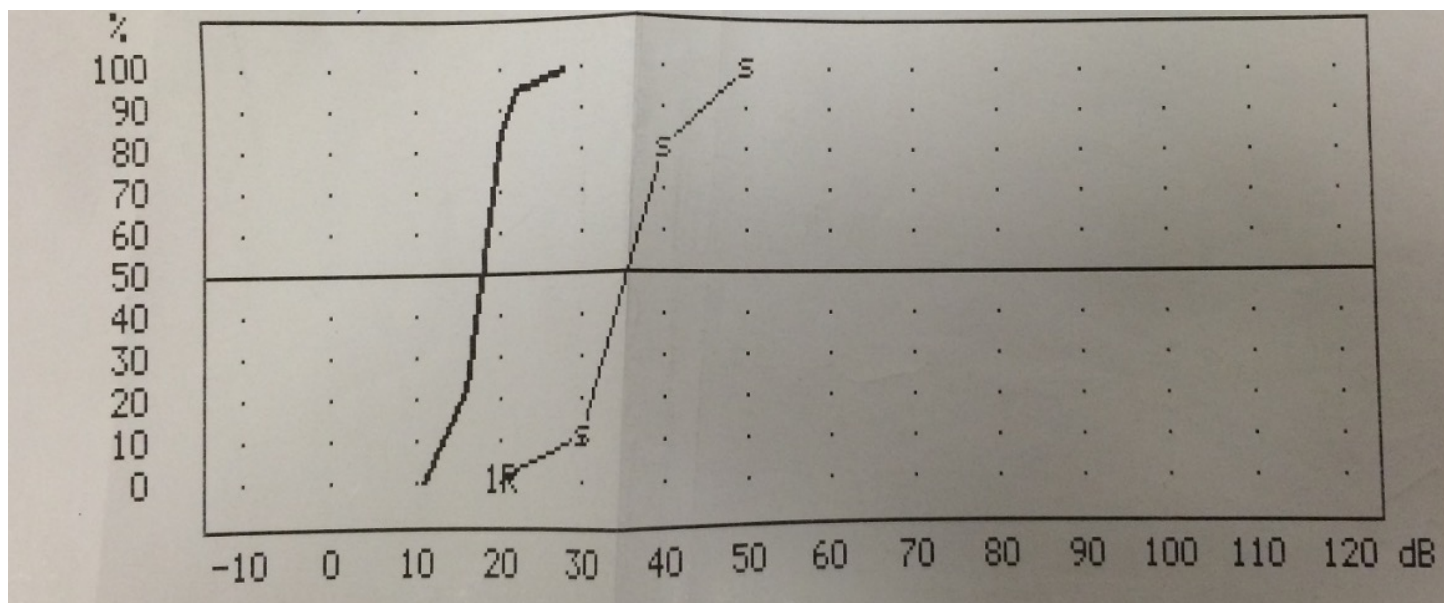
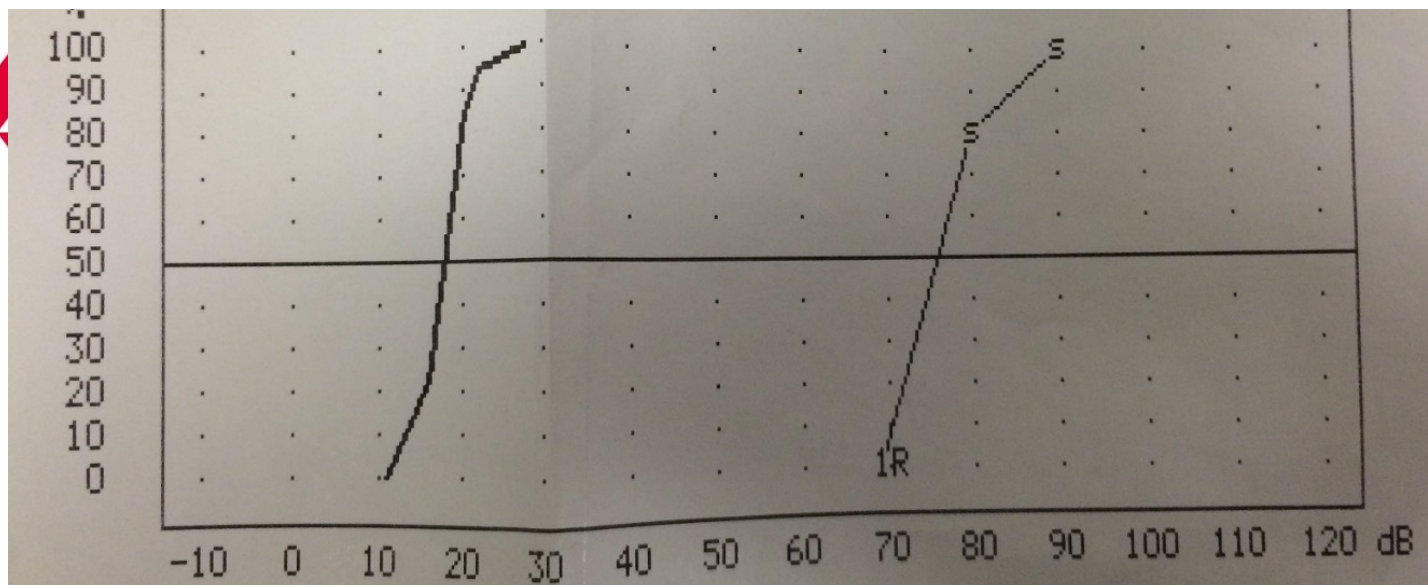
Closing the wound



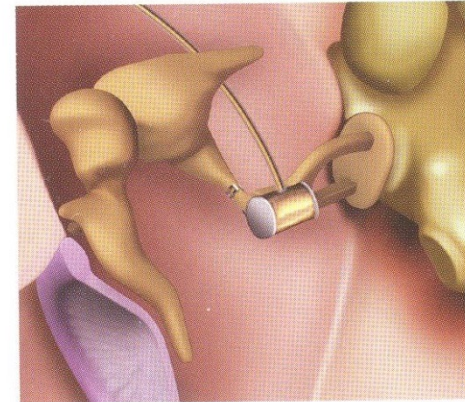
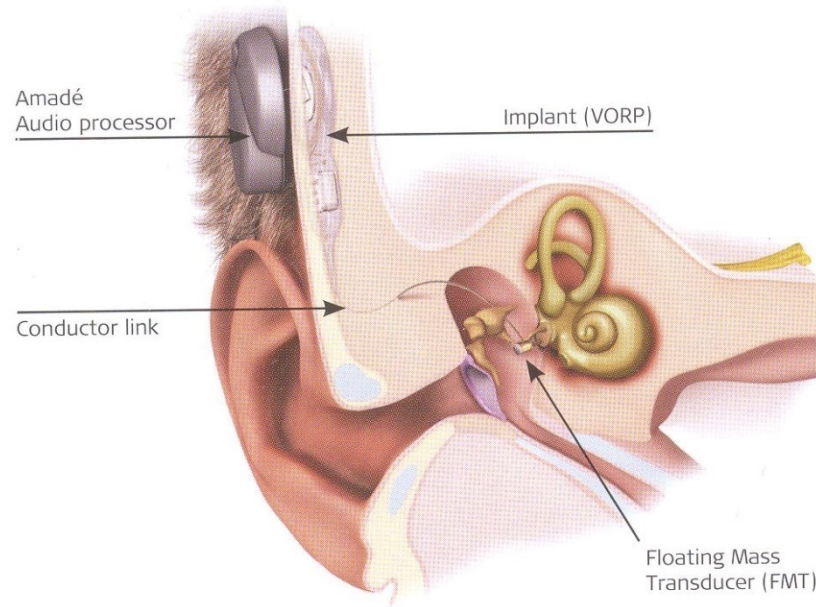


Hearing function before and after surgery

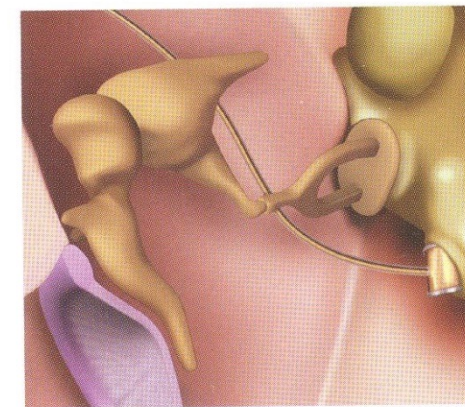




Vibroplasty - sound bridge



Incus Vibroplasty
used to treat
sensorineural hearing loss



Round Window
Vibroplasty
used to treat conductive
and mixed hearing loss

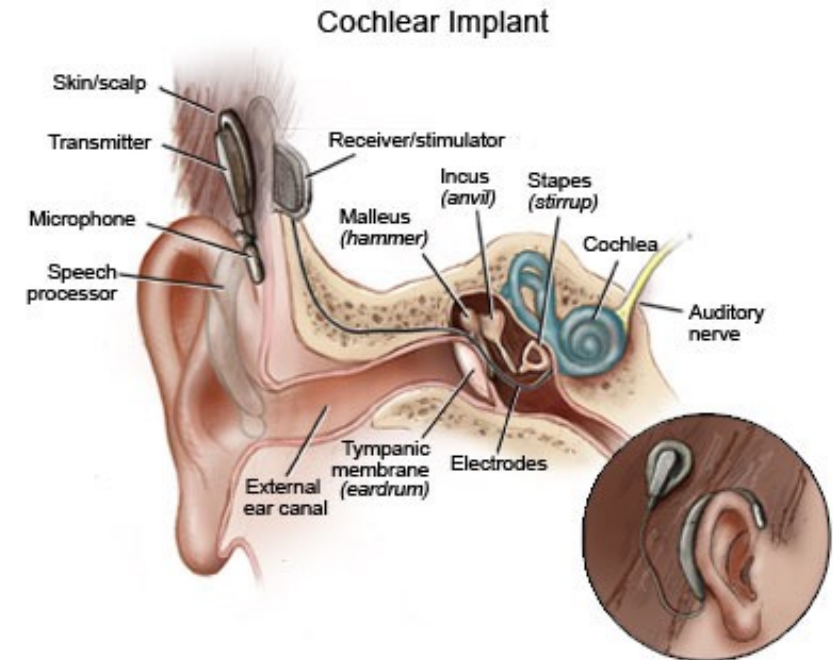
A cochlear implant system

two main components.

The externally worn **audio processor** detects sounds and sends them to the **internal implant**, which is placed just under the skin behind the ear.

The sound is encoded in processor, electric signal is sended into internal implant and through flexible electrode, which is introduced into the cochlea stimulates directly neurons of auditory nerve.

Electric signals are led into the brain, where they are interpreted as sound.



Vibrant soundbridge – middle ear implant hearing system. Vibroplasty

The externally worn **audio processor** receives and detects sounds and converts them into electrical signals, which are sent to the **internal implant**. Electrical signals are led into FMT, which change it into mechanical vibration and directly stimulate ossicles or round window niche or different vibratory structures.

