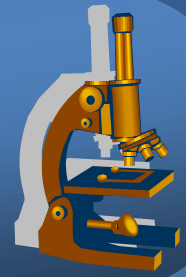
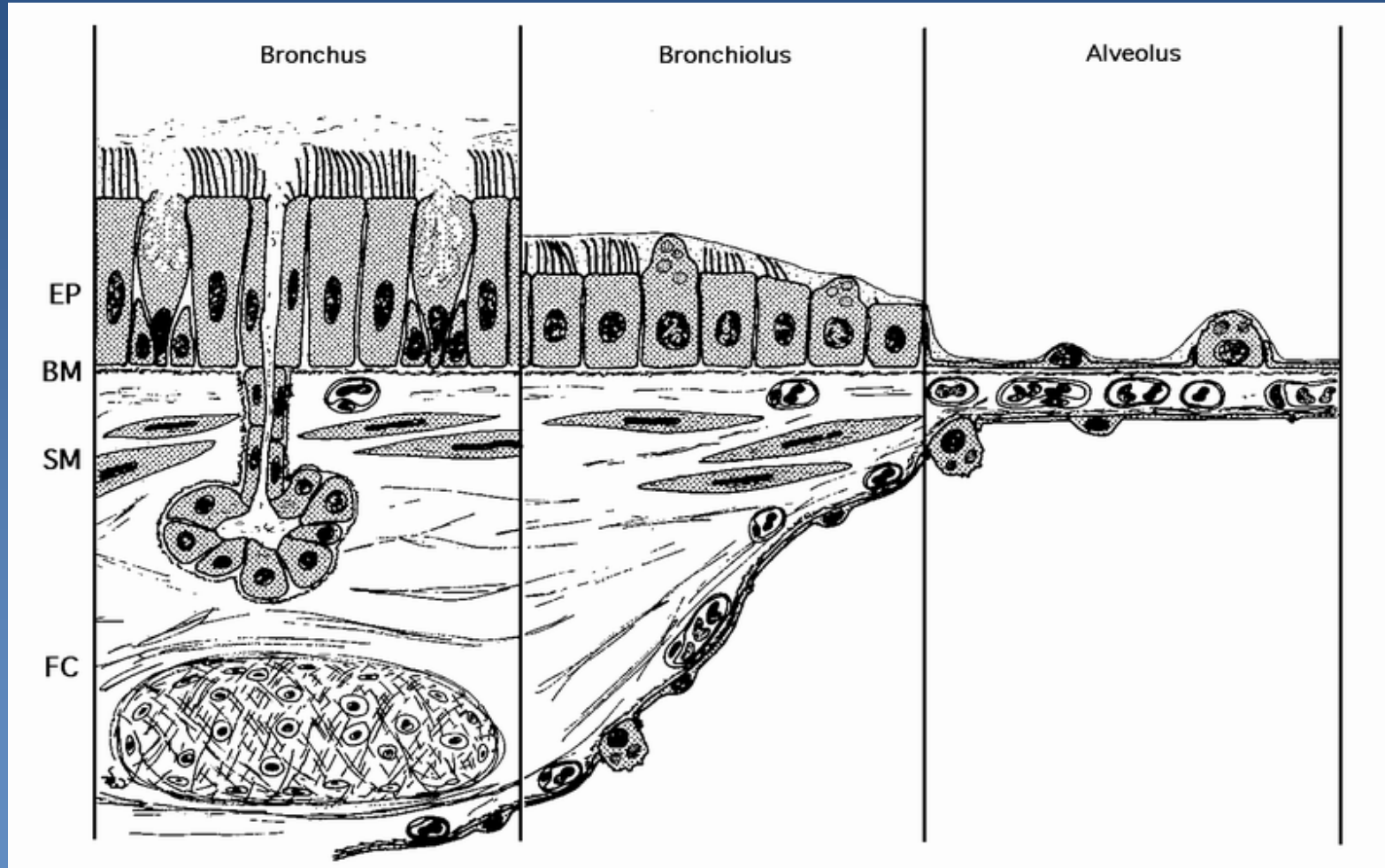
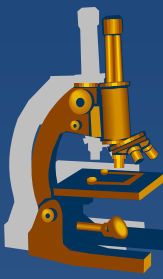


# *Systemic pathology*

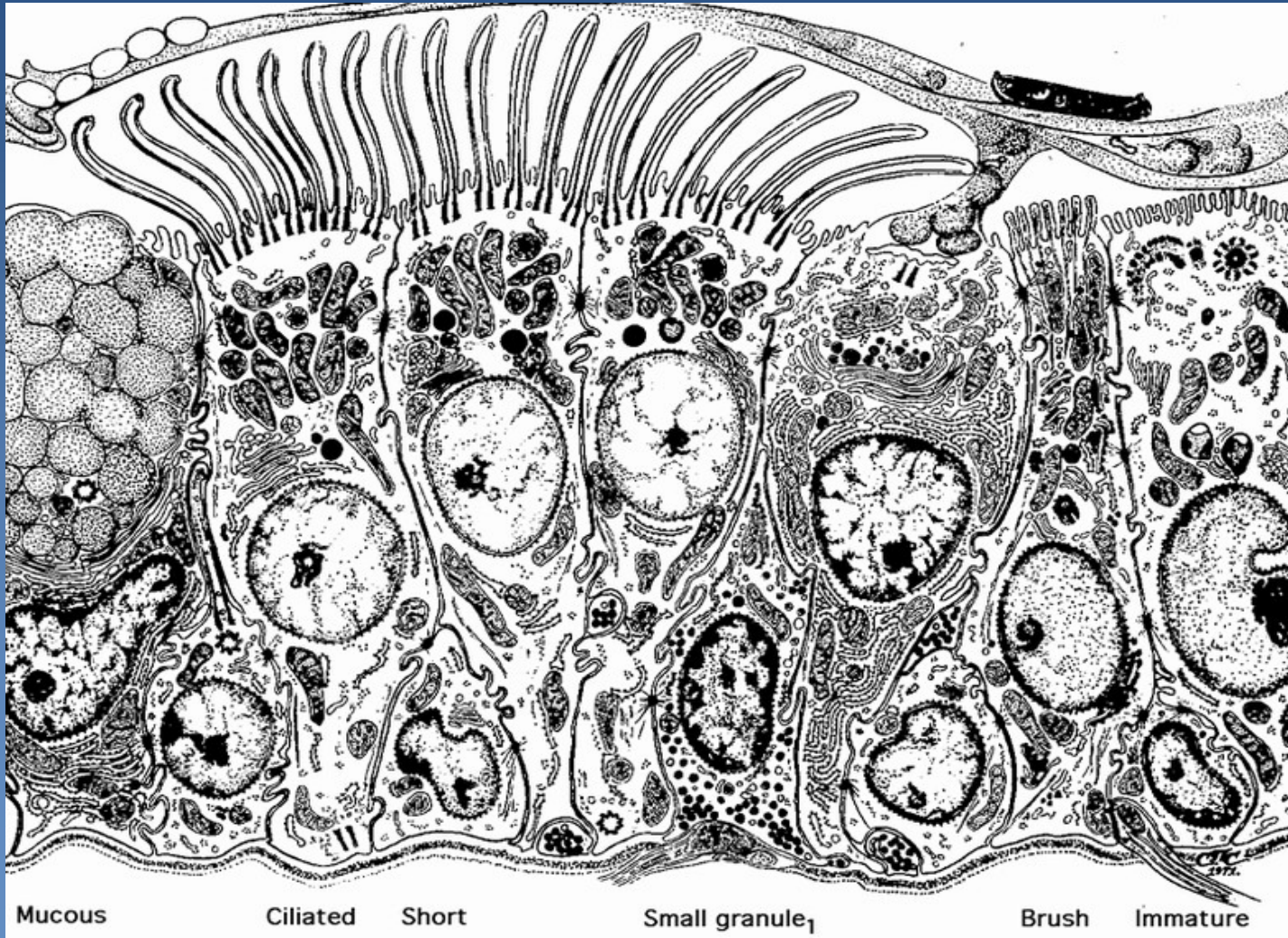
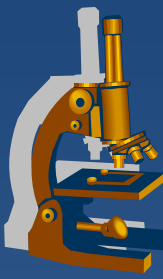


The respiratory tract

# *Histology of respiratory tract*



# Cellular components of bronchial mucosa



Mucous

Ciliated

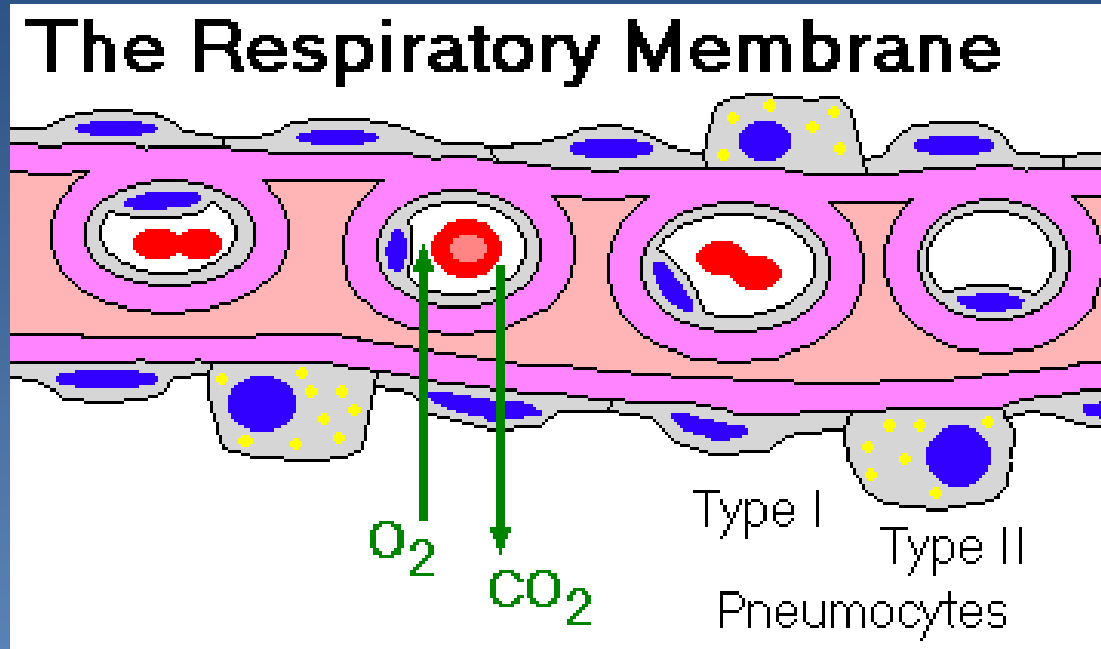
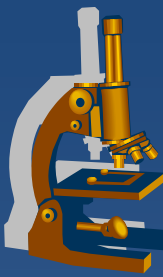
Short

Small granule<sub>1</sub>

Brush

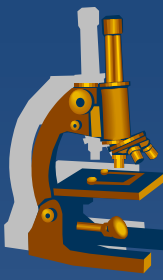
Immature

# The respiratory membrane



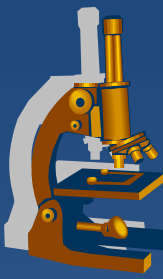
# *Chronic polypous rhinitis*

---



- ✗ chronic proliferative inflammation
- ✗ aetiology:
  - ⇒ *chronic irritation*
  - ⇒ *allergy*
  - ⇒ *repeated acute inflammations*

# Polypous chronic rhinitis



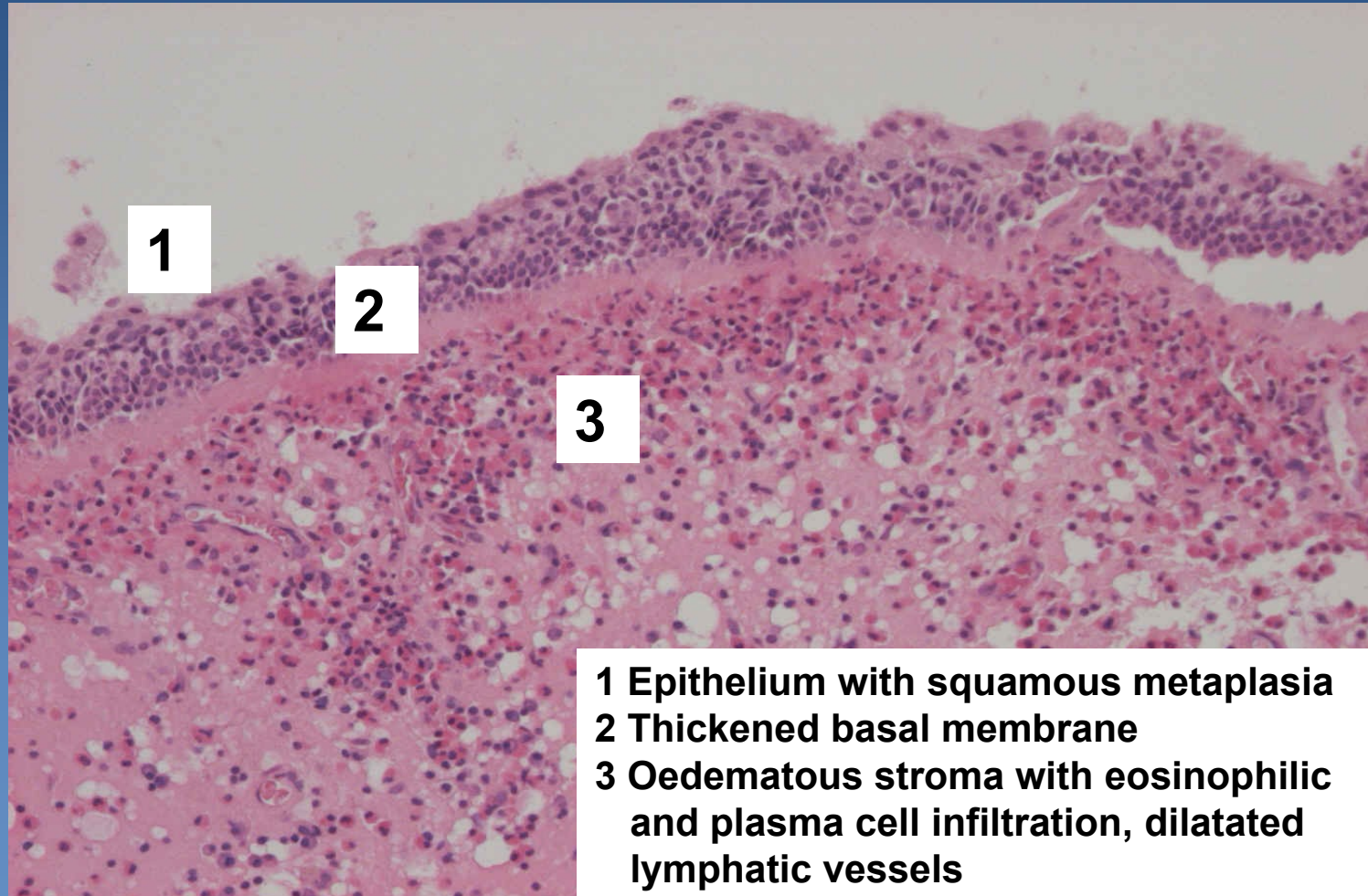
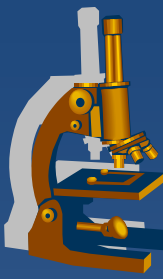
## x Gross:

- ⇒ *mucosal polyps, often multiple*
- ⇒ *variable size (mm – 2 cm)*

## x Micro:

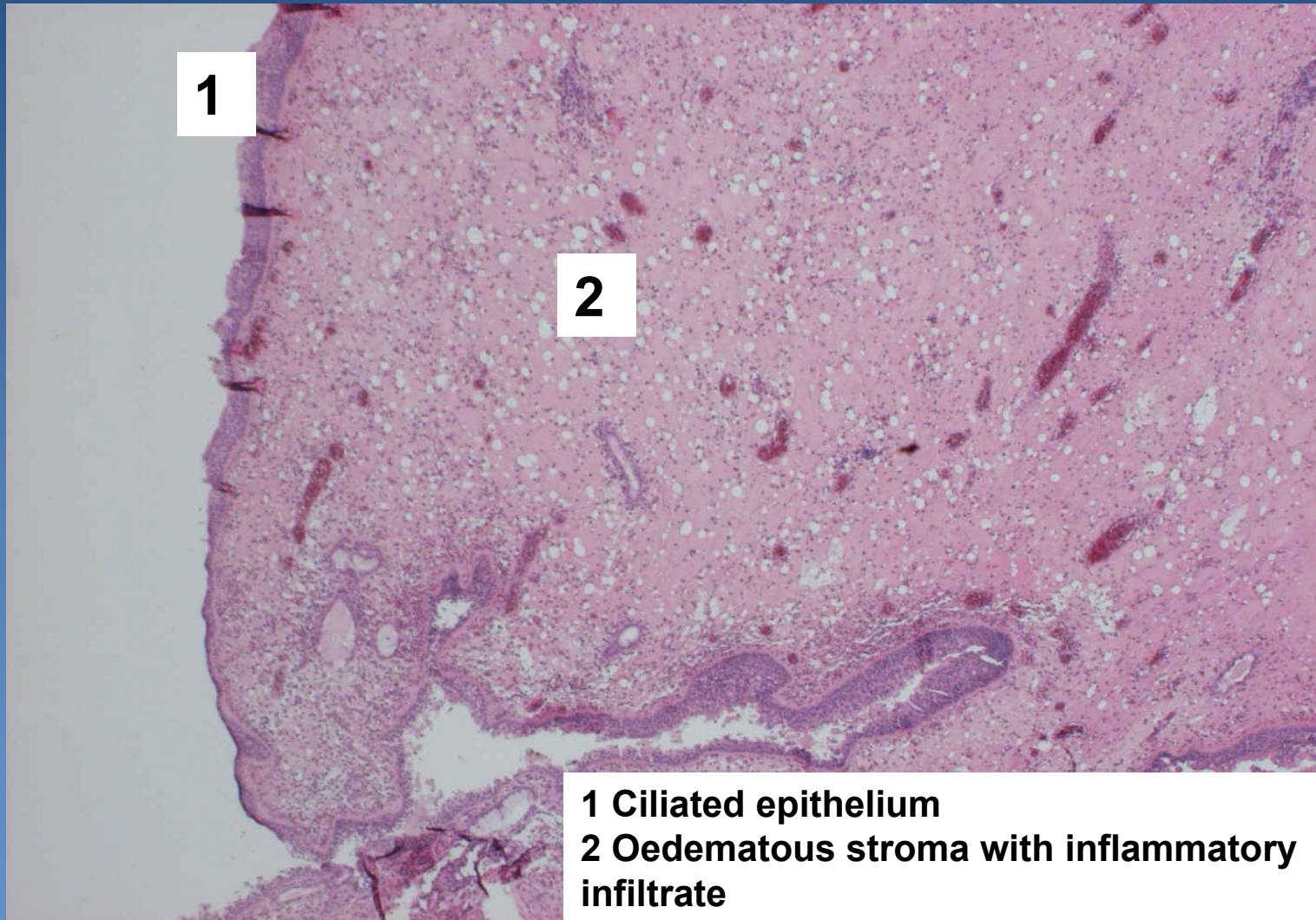
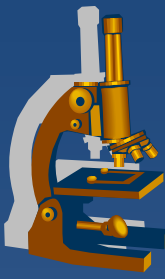
- ⇒ *oedematous mucosal connective tissue*
- ⇒ *lymphoplasmocytic reactive infiltration, admixture of eosinophils, event. neutrophils*
- ⇒ *mucinous hyperplasia*
- ⇒ *covered by hyperplastic respiratory epithelium, squamous metaplasia possible*

# *Polypous chronic rhinitis*



- 1 Epithelium with squamous metaplasia**
- 2 Thickened basal membrane**
- 3 Oedematous stroma with eosinophilic and plasma cell infiltration, dilatated lymphatic vessels**

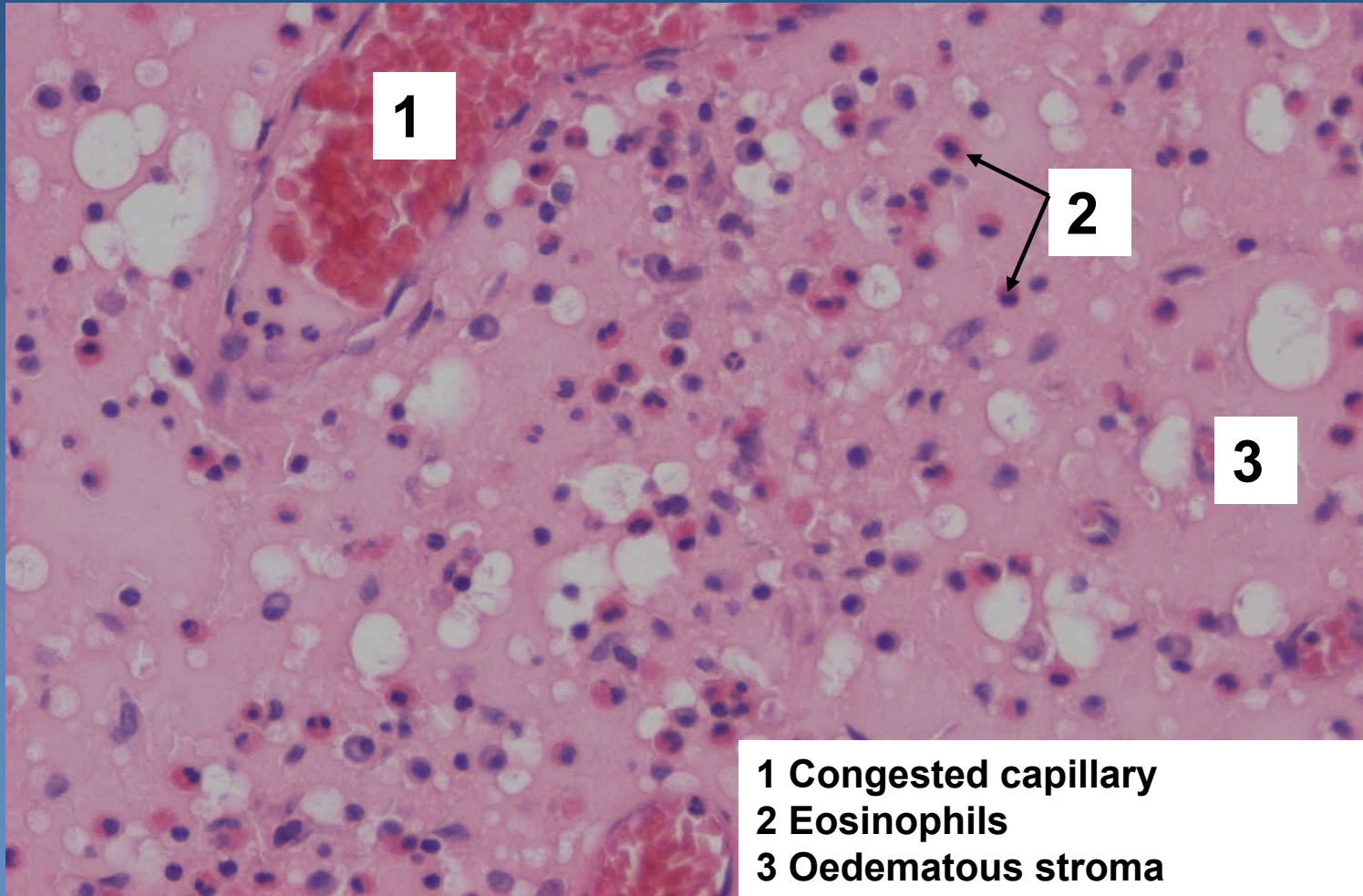
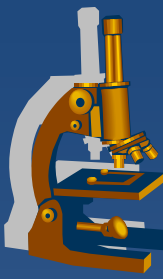
# *Polypous chronic rhinitis*



**1 Ciliated epithelium**  
**2 Oedematous stroma with inflammatory infiltrate**

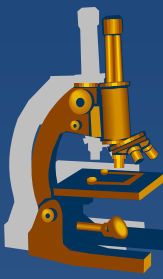


# *Polypous chronic rhinitis*



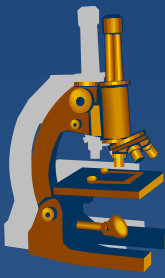
- 1 Congested capillary
- 2 Eosinophils
- 3 Oedematous stroma

# Asthma bronchiale



- ✗ recurrent attacks of bronchospasm with expiratory dyspnoea
- ✗ status asthmaticus:
  - ⇒ *increased frequency of attacks – permanent bronchospasm*
  - ⇒ *may be lethal*
- ✗ etiology:
  - ⇒ *Hypersensitivity I.type*
- ✗ variants:
  - ⇒ *Extrinsic (environmental factors):*
    - Atopic, IgE → mast cells degranulation..., bronchioconstriction, increased vascular permeability and mucus secretion + eosinophils activation
  - ⇒ *Intrinsic:*
    - hyperreactive URT, non-atopic

# Asthma bronchiale



× Gross (patients who died during status asthmaticus):

⇒ *acute emphysema*

⇒ *mucus plugs in peripheral bronchi and bronchioles*

× Micro:

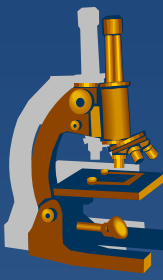
⇒ *intraluminal:*

- mucus, eosinophils, Charcot-Leyden crystals, cellular detritus

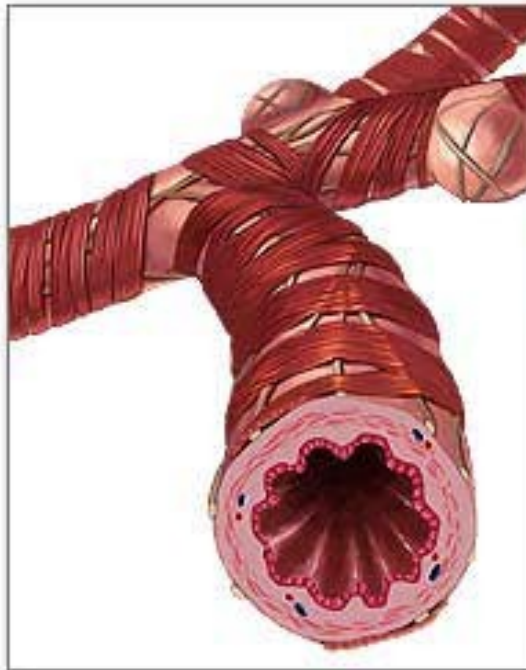
⇒ *bronchial wall:*

- oedema of the mucous membrane
- thickening (collagenisation) of the sub-basement membrane tissue
- mucous glands hypertrophy, eosinophil-rich inflammatory infiltrate

# *Asthma bronchiale*



Normal bronchiole

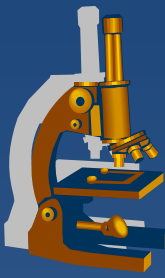


Asthmatic bronchiole



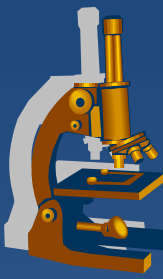
copy

# *Bronchiectasis*



- ✘ permanent abnormal dilatation of bronchi
- ✘ arising from the weakening of the walls or changes in air pressure
- ✘ morphology:
  - ⇒ *cylindrical*
  - ⇒ *saccular*
  - ⇒ *fusiform*

# Bronchiectasis



## x aetiology:

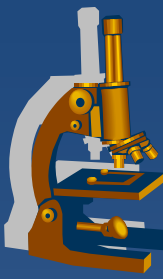
### ⇒ *congenital/hereditary conditions:*

- incomplete development of bronchial wall
- Kartagener syndrome
  - primary ciliary dysgenesis

### ⇒ *acquired:*

- chronic inflammations
- changes of the pressure
  - chronic pulmonary collapse

# Bronchiectasis



## x complications:

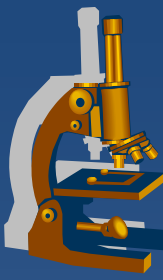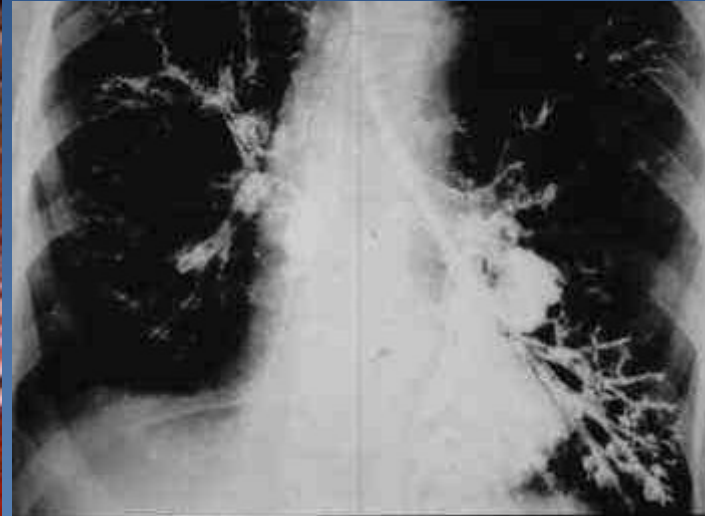
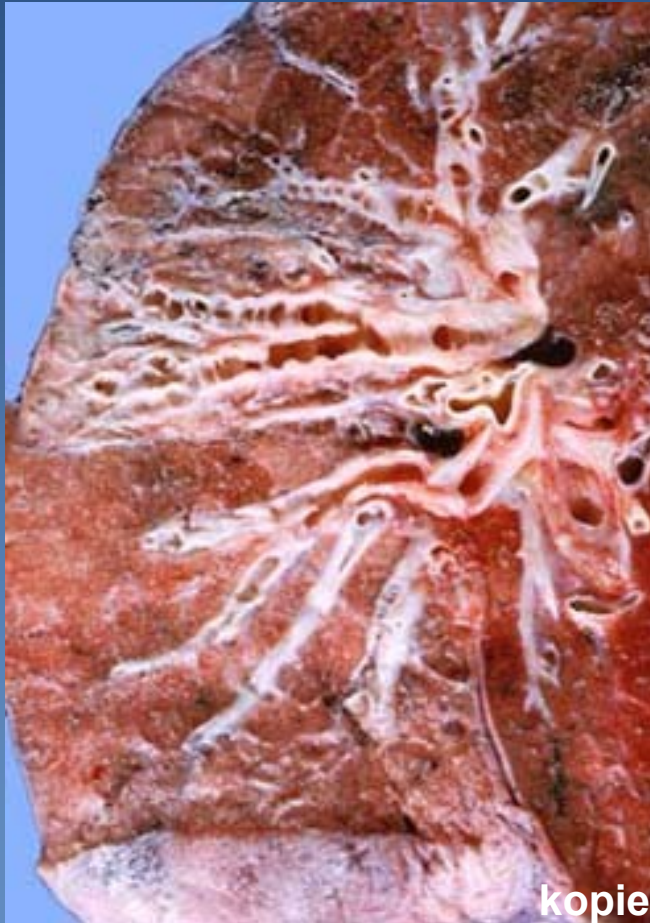### ⇒ *inflammations:*

- chronic purulent bronchitis
- bronchopneumonia including abscess formation

### ⇒ *fibrosis, pulmonary hypertension and cor pulmonale*

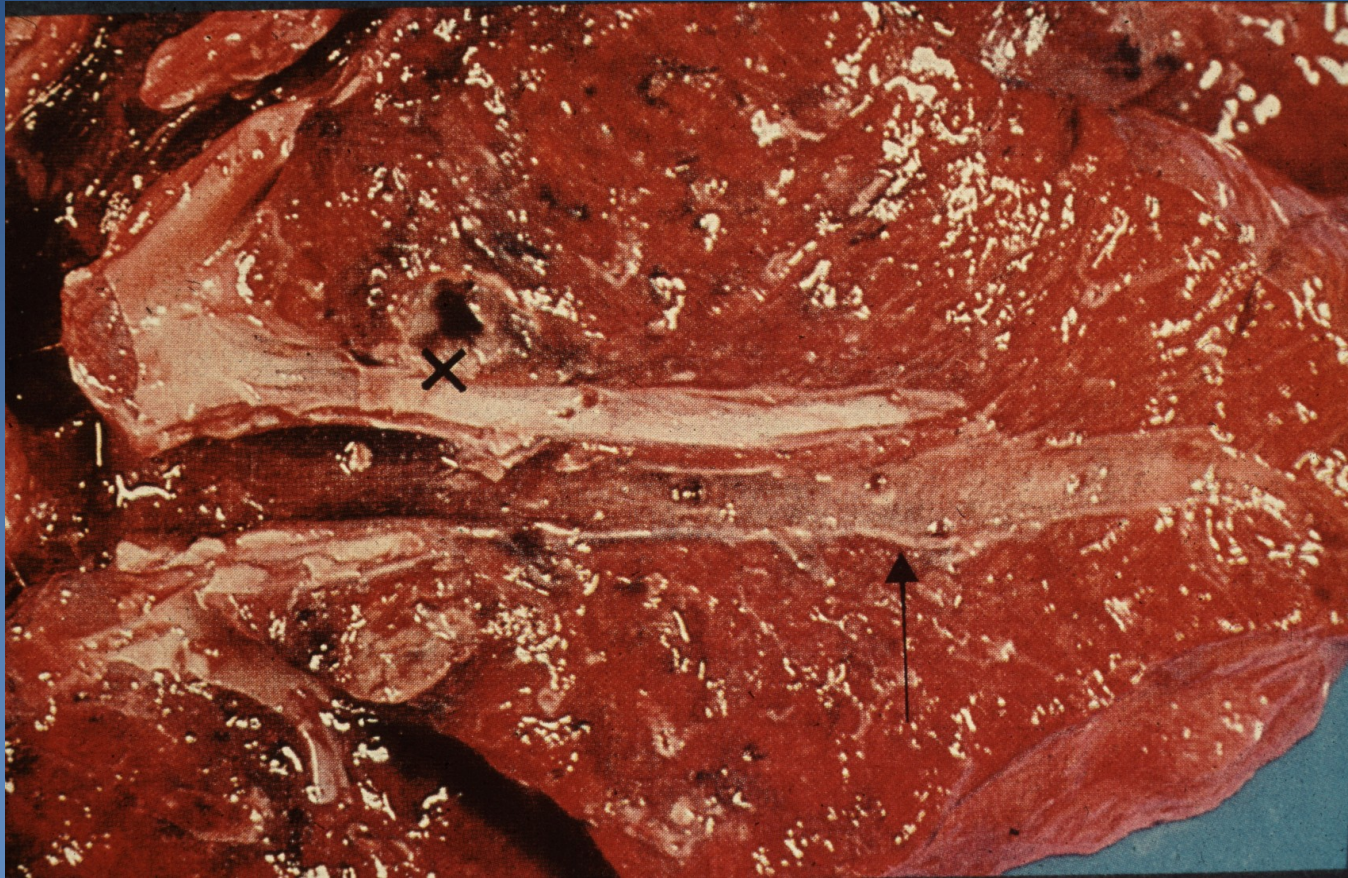
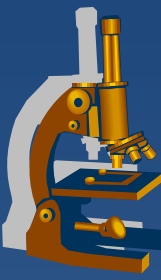
### ⇒ *secondary AA amyloidosis*

# *Bronchiectasis*

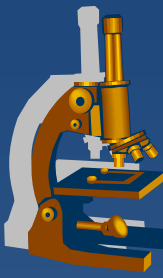




# *Bronchiectasis*

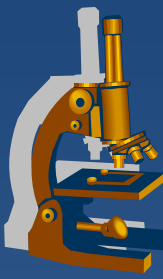


# *Pulmonary emphysema*



- × regressive change (atrophy)
- × abnormal permanent enlargement of the airspaces in pulmonary tissue
- × aetiology (combination of several factors):
  - ⇒ *smoking*
  - ⇒ *deficiency of  $\alpha$ 1-antitrypsin*
- × types:
  - ⇒ *alveolar:*
    - acute
    - chronic
  - ⇒ *interstitial – airway rupture (trauma)*

# *Alveolar emphysema*



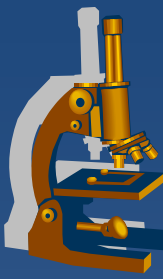
## **x** acute:

- ⇒ *alveolar septa are not destroyed*
- ⇒ *rather pulmonary hyperinflation or distention*

## **x** chronic:

- ⇒ *permanent enlargement of airspaces distal to terminal bronchioles*
- ⇒ *destruction of alveolar walls*
- ⇒ *part of COPD (chronic obstructive pulmonary disease)*
  - combination of chronic bronchitis and chronic emphysema

# Alveolar emphysema



## × types:

### ⇒ **centrilobular (centriacinar):**

- upper lobes – apex, more in males,
- most commonly seen in smokers without congenital ■-antitrypsin deficiency (but + chronic bronchitis), possible professional disease - dust

### ⇒ **panacinar:**

- often lower lung zones; significant microscopic changes; ■-antitrypsin deficiency, old age

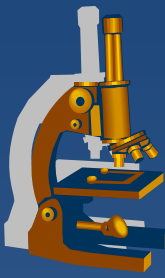
### ⇒ **distal acinar (paraseptal):**

- adjacent to pleura, upper lobes foci of fibrosis, formation of cystlike structures – **bullae** (pneumothorax risk)

### ⇒ **irregular:**

- associated with scarring, usually postinflammatory

# *Alveolar emphysema*



## **x** Gross:

⇒ *enlarged, voluminous lungs, light, pale, dry, emphysematous bullae*

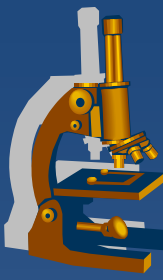
## **x** Micro:

⇒ *thinning and destruction of alveolar walls*

⇒ *deformation of bronchiolar walls*

⇒ *chronic inflammatory changes*

# Emphysema



## x pathogenesis and complications:

*thinning of alveolar walls and capillaries →*

*reduced blood supply →*

*complete destruction of alveolar walls →*

*difficult expiration + decreasing of lung capacity →*

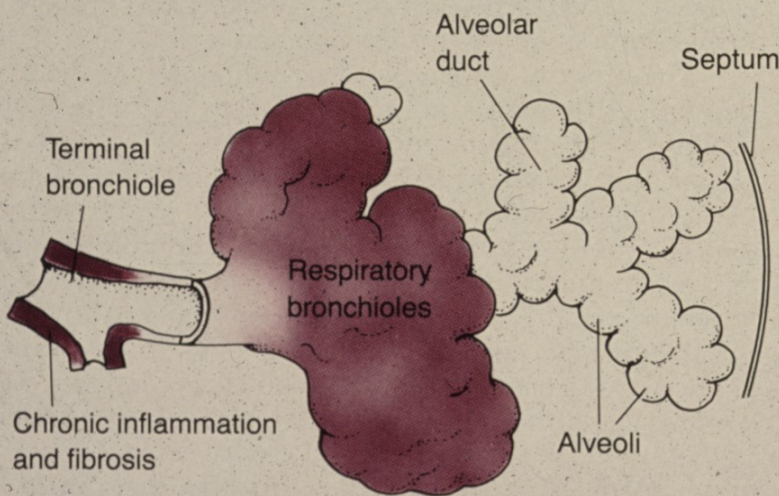
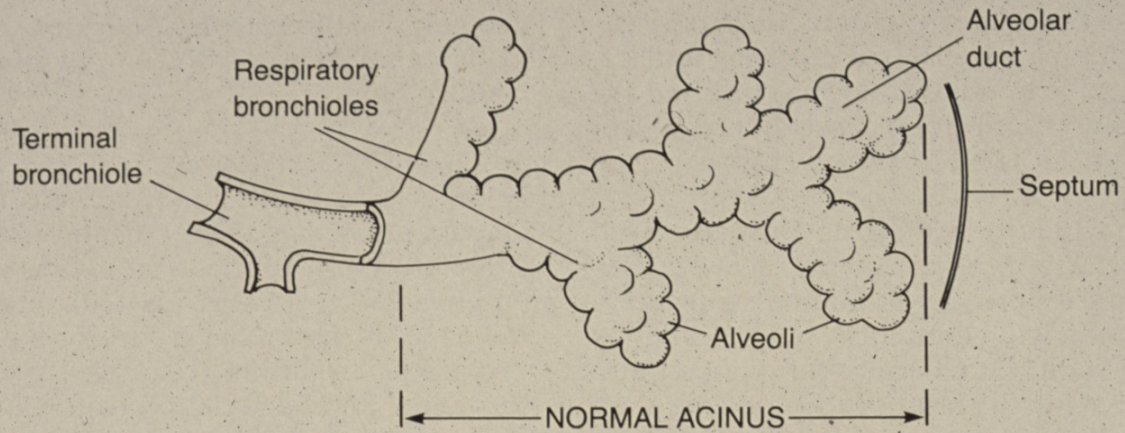
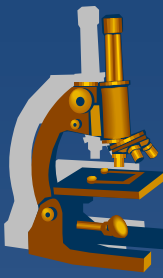
*hypoxemia →*

*vasoconstriction →*

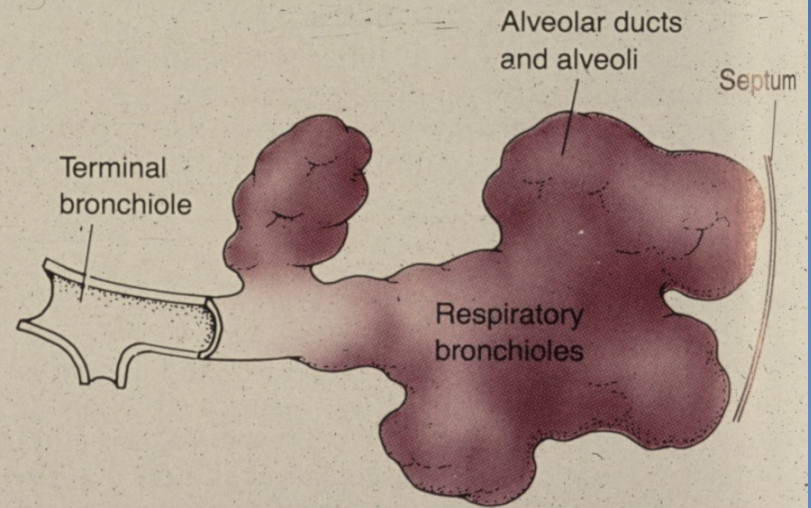
*secondary pulmonary hypertension → →*

*cor pulmonale*

# Emphysema



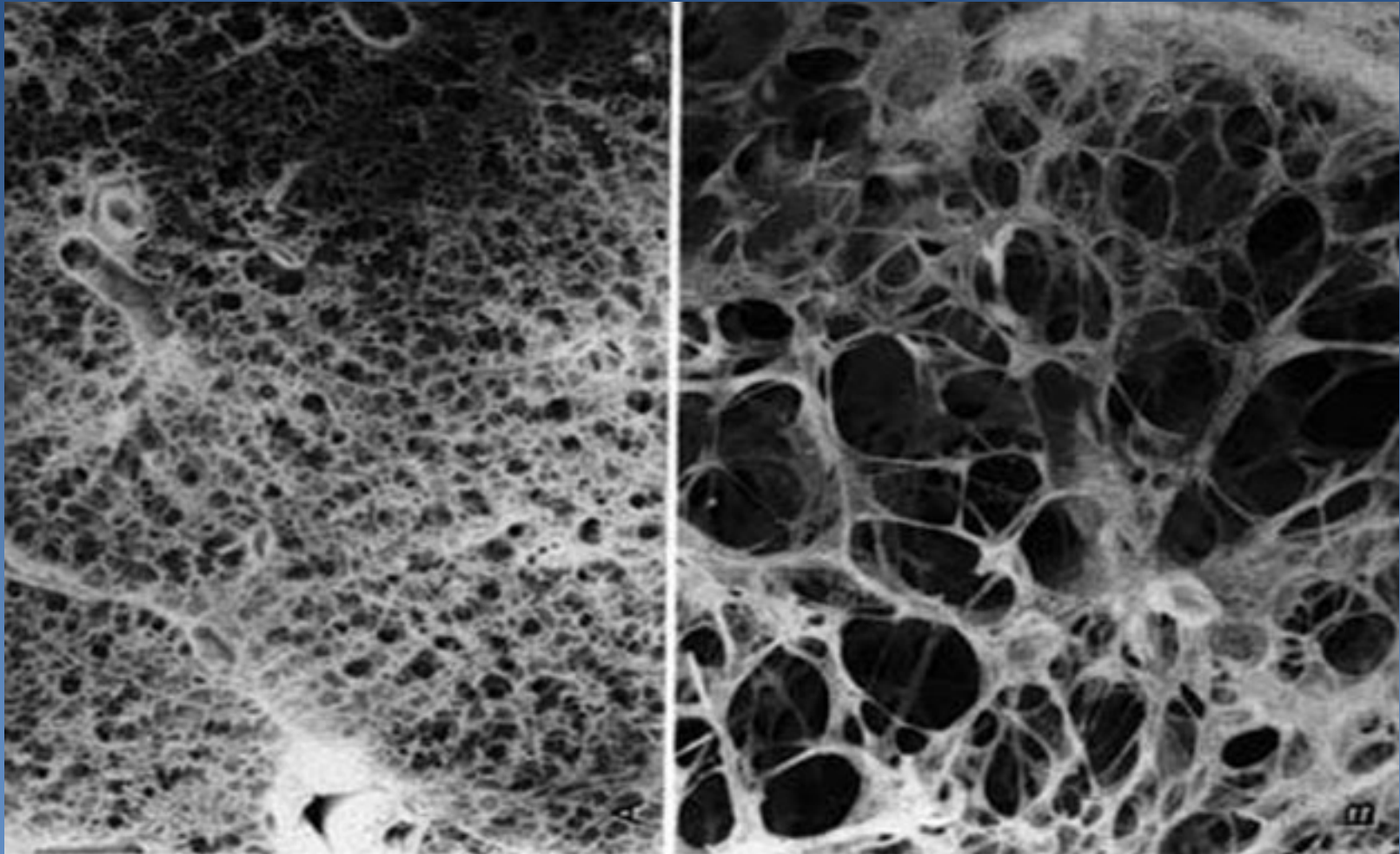
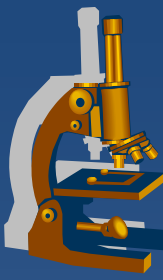
CENTRILOBULAR EMPHYSEMA



PANACINAR EMPHYSEMA

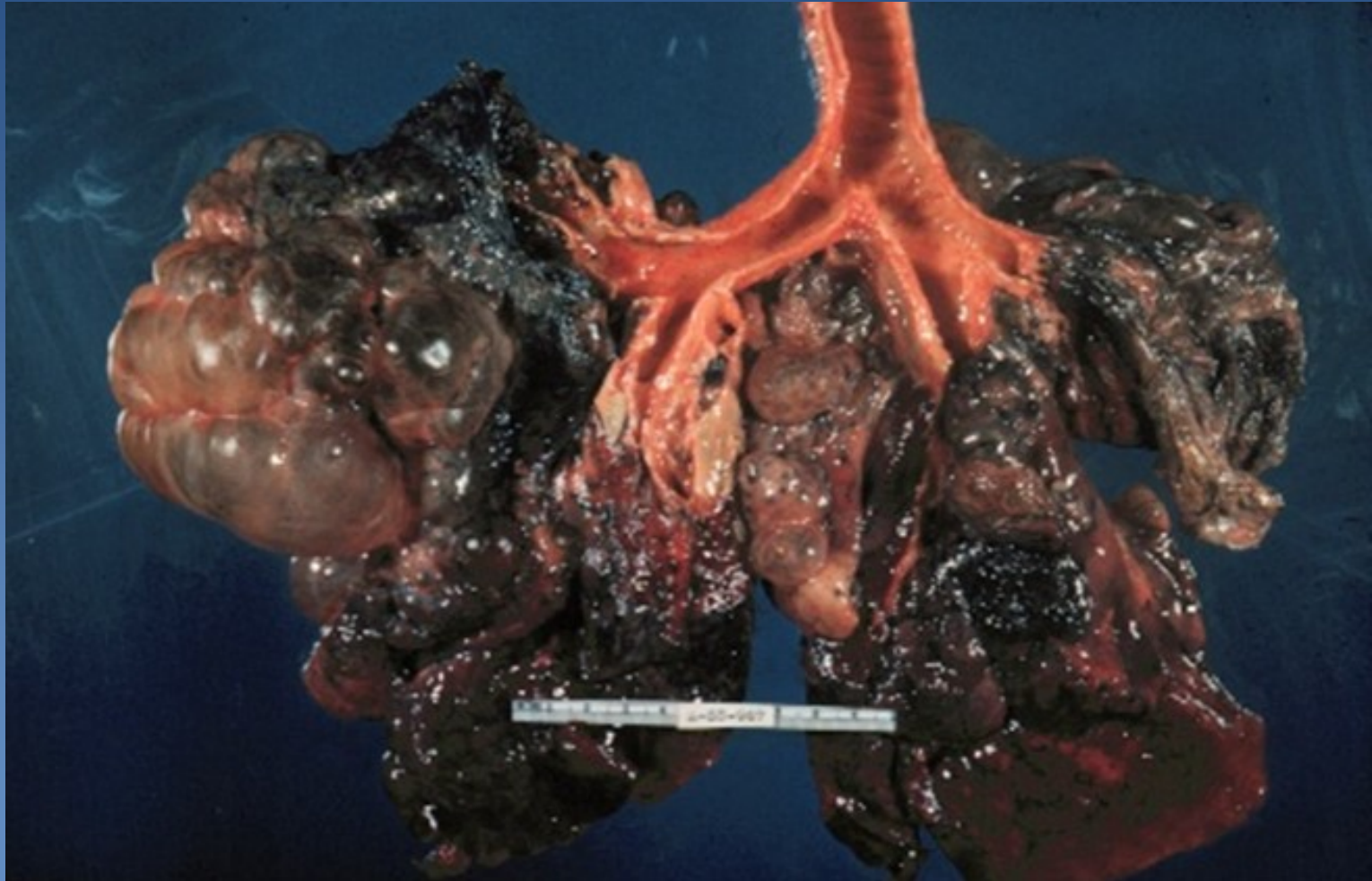
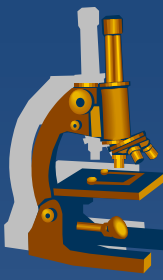
FIGURE 12-32

# *Normal lung and pulmonary emphysema*

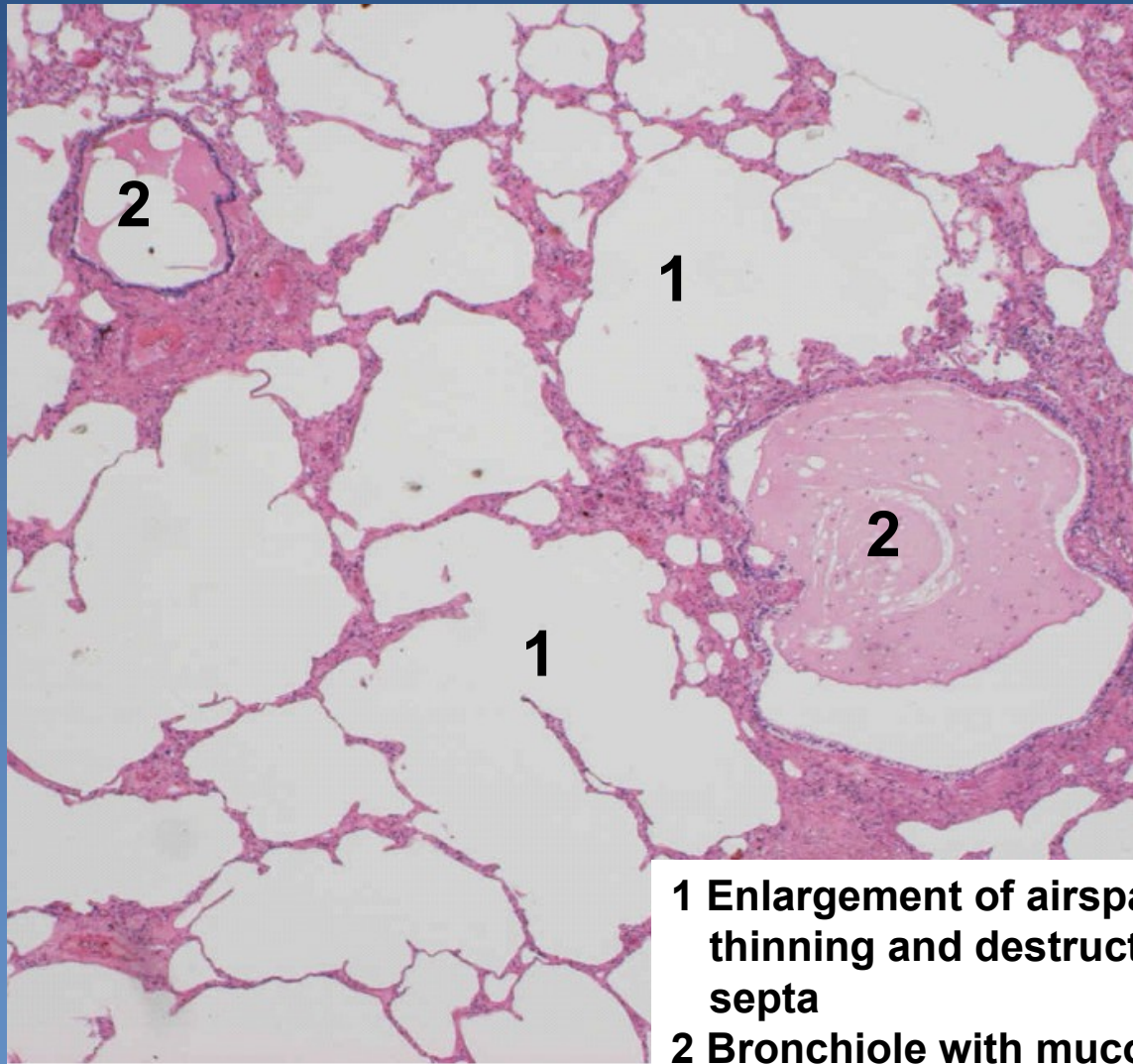
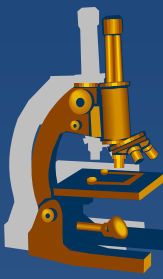




# ***Bullous emphysema***

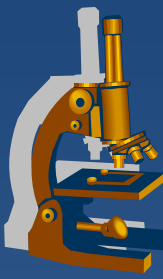


# *Panacinar emphysema*



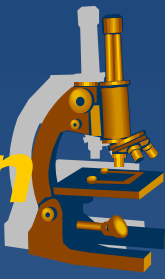- 1** Enlargement of airspaces with thinning and destruction of alveolar septa
- 2** Bronchiole with mucous secretions

# *Hemorrhagic pulmonary infarction*



- × aetiology:
  - ⇒ *thrombembolism of a. pulmonalis branches in the setting of compromised cardiovascular status (passive venous congestion)*
- × typically hemorrhagic
- × often in lower lung lobes adjacent to pleura
- × often multiple
- × healing:
  - ⇒ *granulation tissue, later formation of fibrous scar*

# ***Hemorrhagic pulmonary infarction***



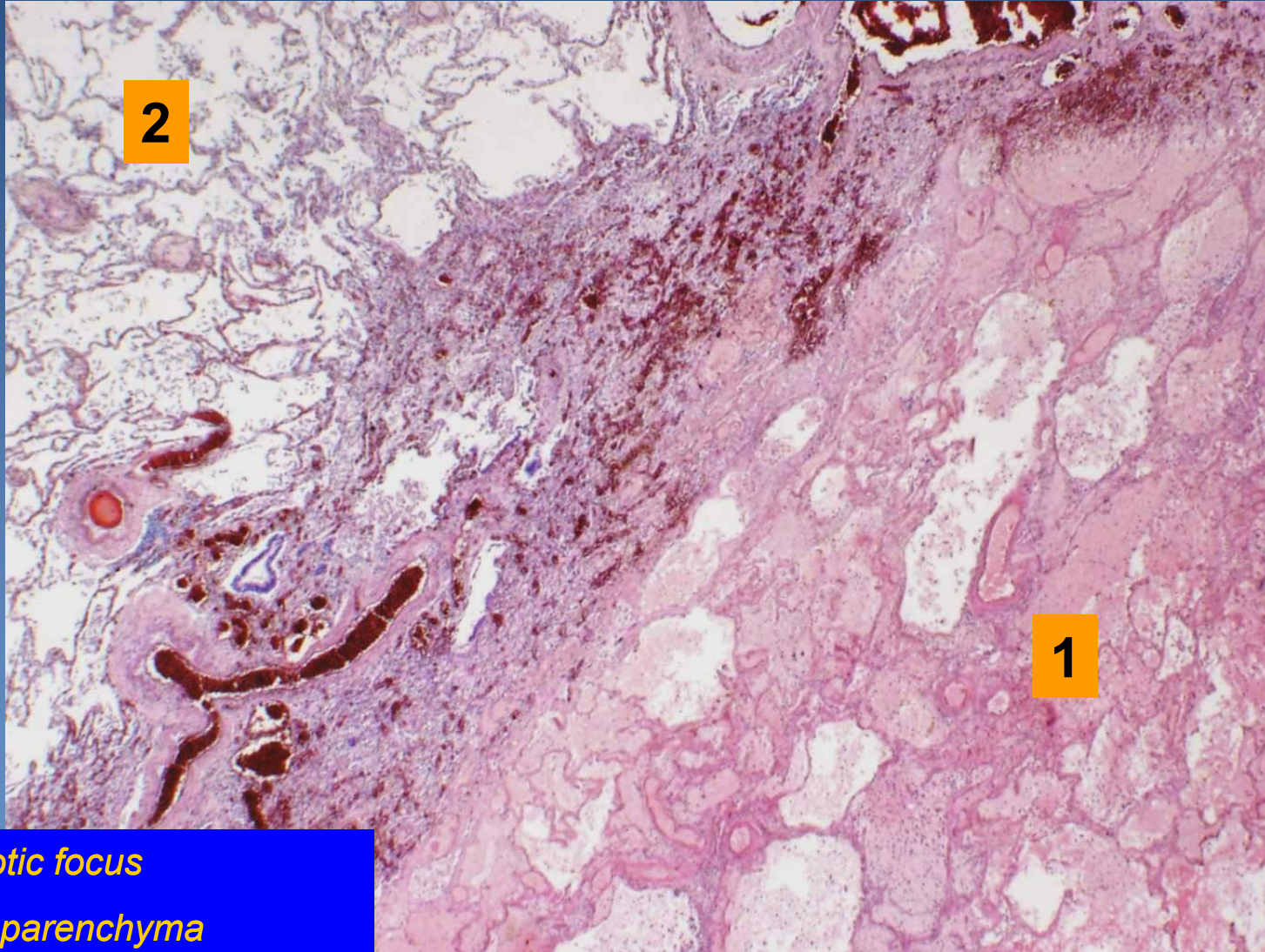
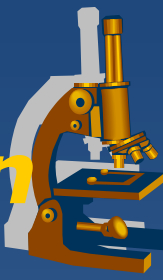
## **x Gross:**

- ⇒ *wedge-shaped focus of tissue with sharp borders*
- ⇒ *dark red-blue (new), yellowish-grey (older)*
- ⇒ *variable size*
- ⇒ *solid consistency*

## **x Micro:**

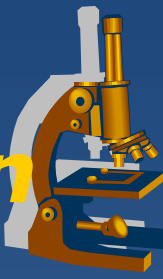- ⇒ *coagulative necrosis of lung parenchyma*
- ⇒ *large extravasations of erythrocytes*
- ⇒ *formation of abscess at secondary infection*
- ⇒ *reactive acute fibrinous pleuritis*
- ⇒ *healing – scarring + emphysema (diff.dg. x tumor)*

# Hemorrhagic pulmonary infarction

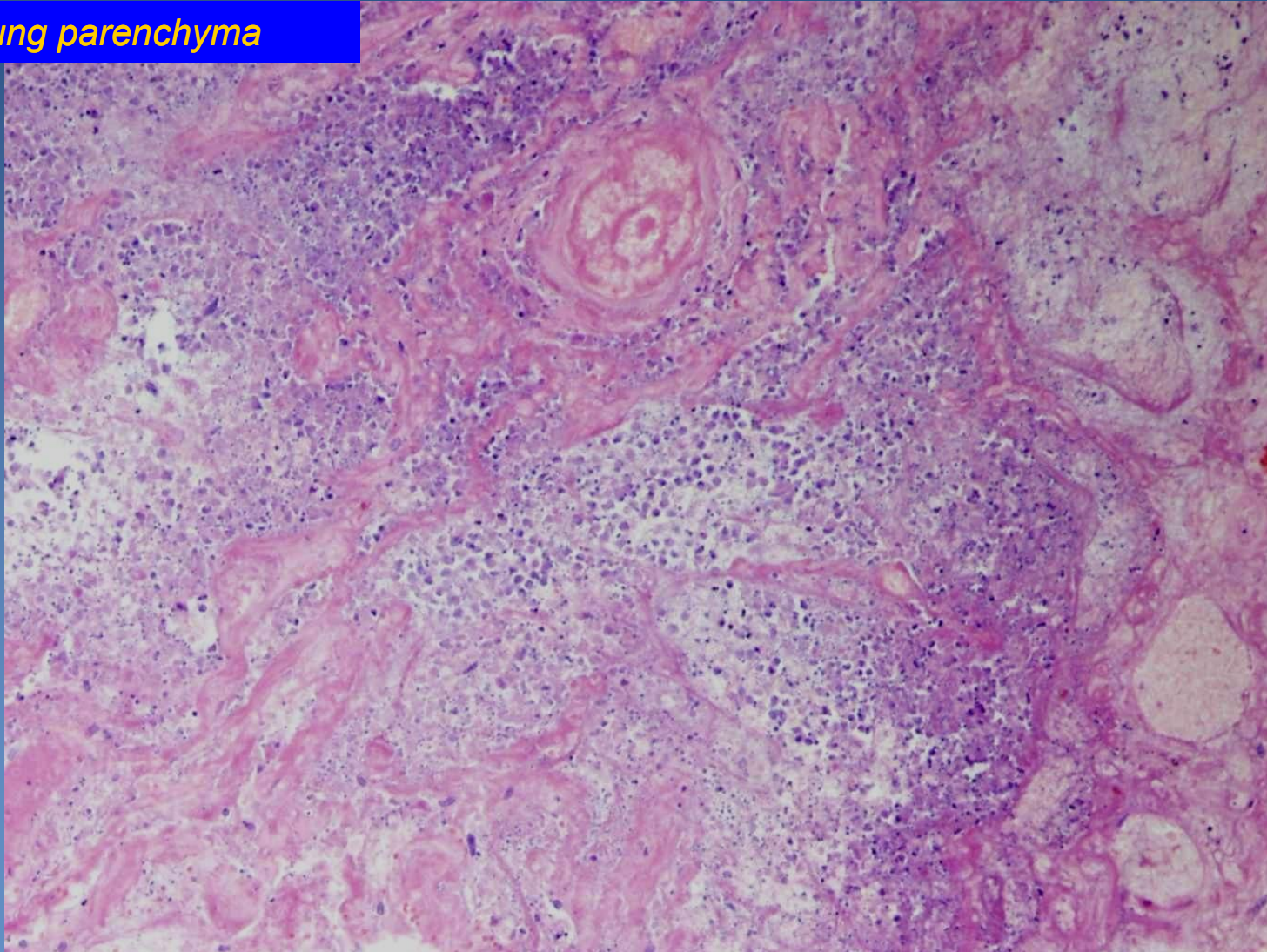


1. Necrotic focus
2. Lung parenchyma

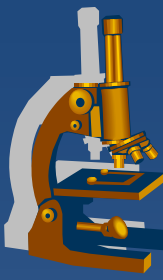
# *Hemorrhagic pulmonary infarction*



*Necrotic lung parenchyma*



# Chronic pulmonary venous congestion



✘ associated with chronic left-sided cardiac insufficiency

⇒ **etiology:**

- ischemic heart disease, systemic hypertension, valvular disorders, cardiomyopathy

✘ clinically („asthma cardiale“):

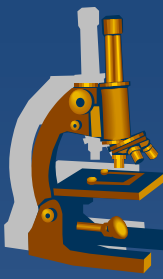
⇒ **cough**

- rusty sputum

⇒ **shortness of breath (dyspnoea)**

- ortopnoea
- paroxysmal nocturnal dyspnoea
  - relieved by sleeping with elevated head („additional pillows needed“)

# ***Chronic pulmonary venous congestion***



## **x Gross:**

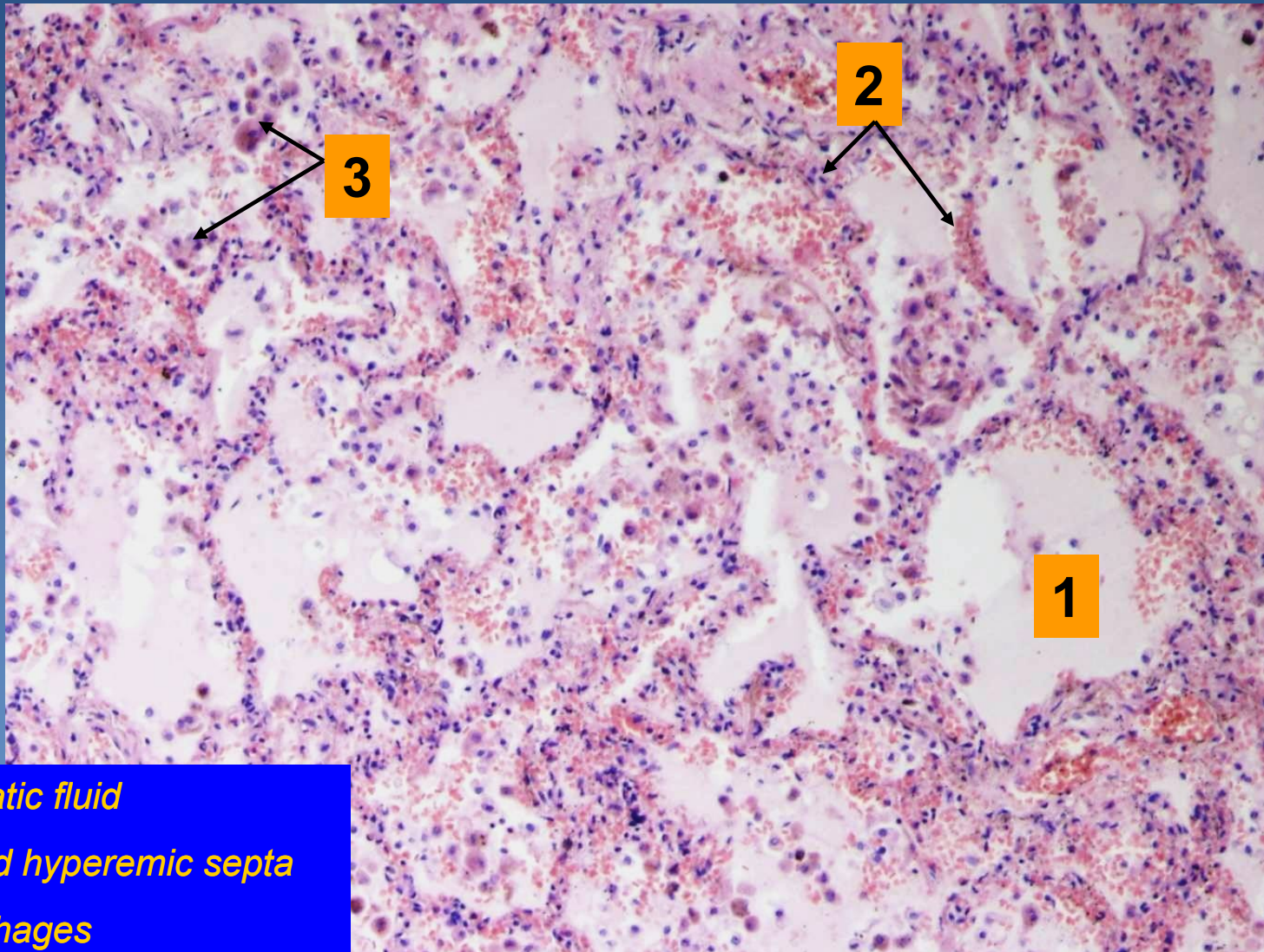
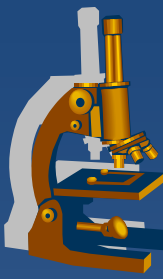
- ⇒ *slightly enlarged lungs*
- ⇒ *solid consistency*
- ⇒ *rusty-brown color*
  - rusty/cyanotic lung induration

## **x Micro:**

- ⇒ *congestion of alveolar capillaries*
- ⇒ *alveolar hemorrhage with siderophages:*
  - histiocytes with cytoplasmic granules of hemosiderin
- ⇒ *fibrotization of alveolar walls*

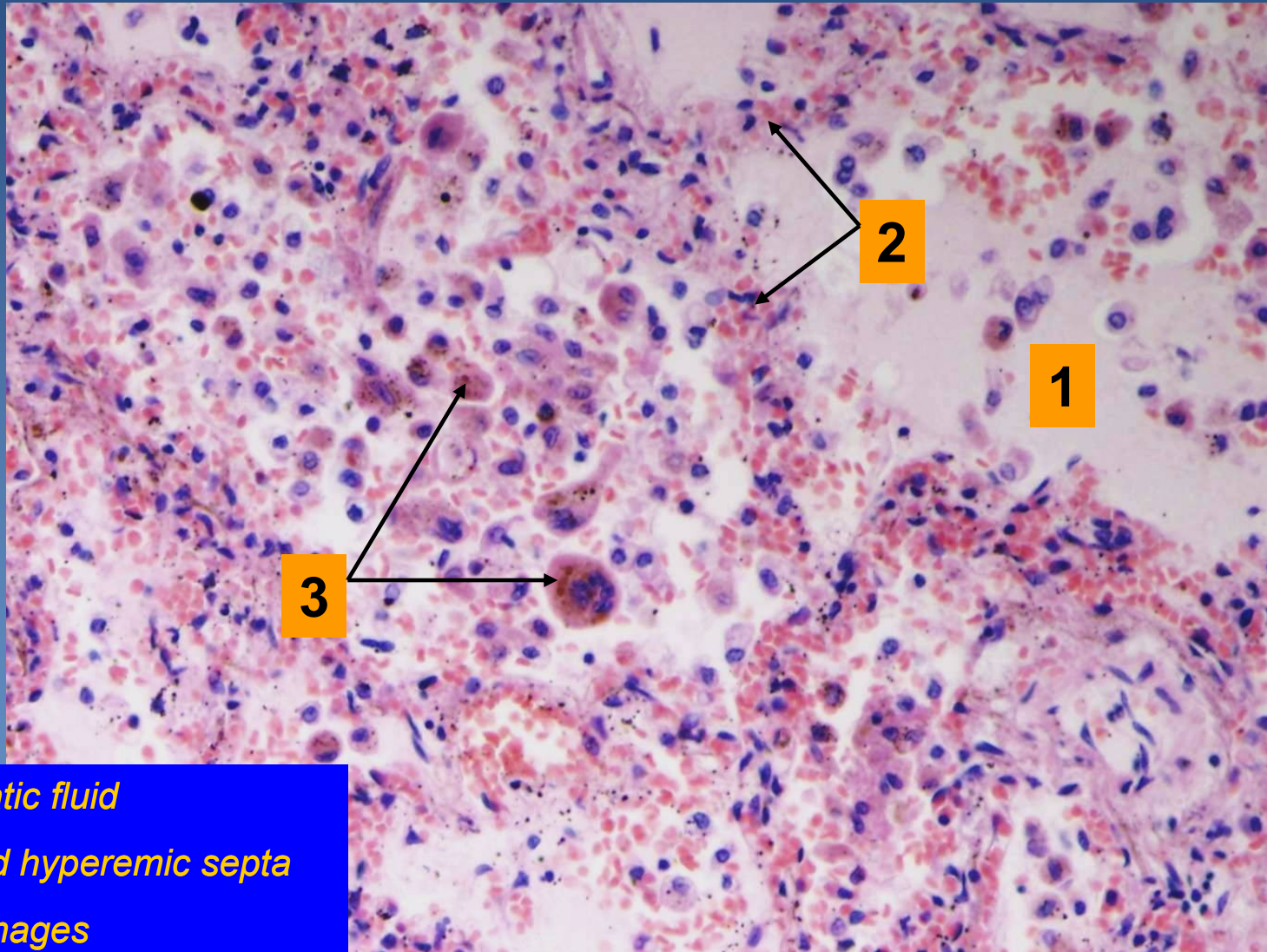
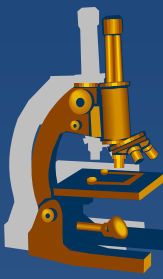


# *Chronic pulmonary venous congestion*



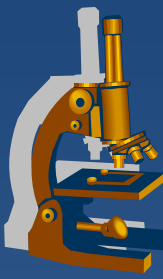
- 1. Oedematic fluid*
- 2. Enlarged hyperemic septa*
- 3. Siderophages*

# *Chronic pulmonary venous congestion*

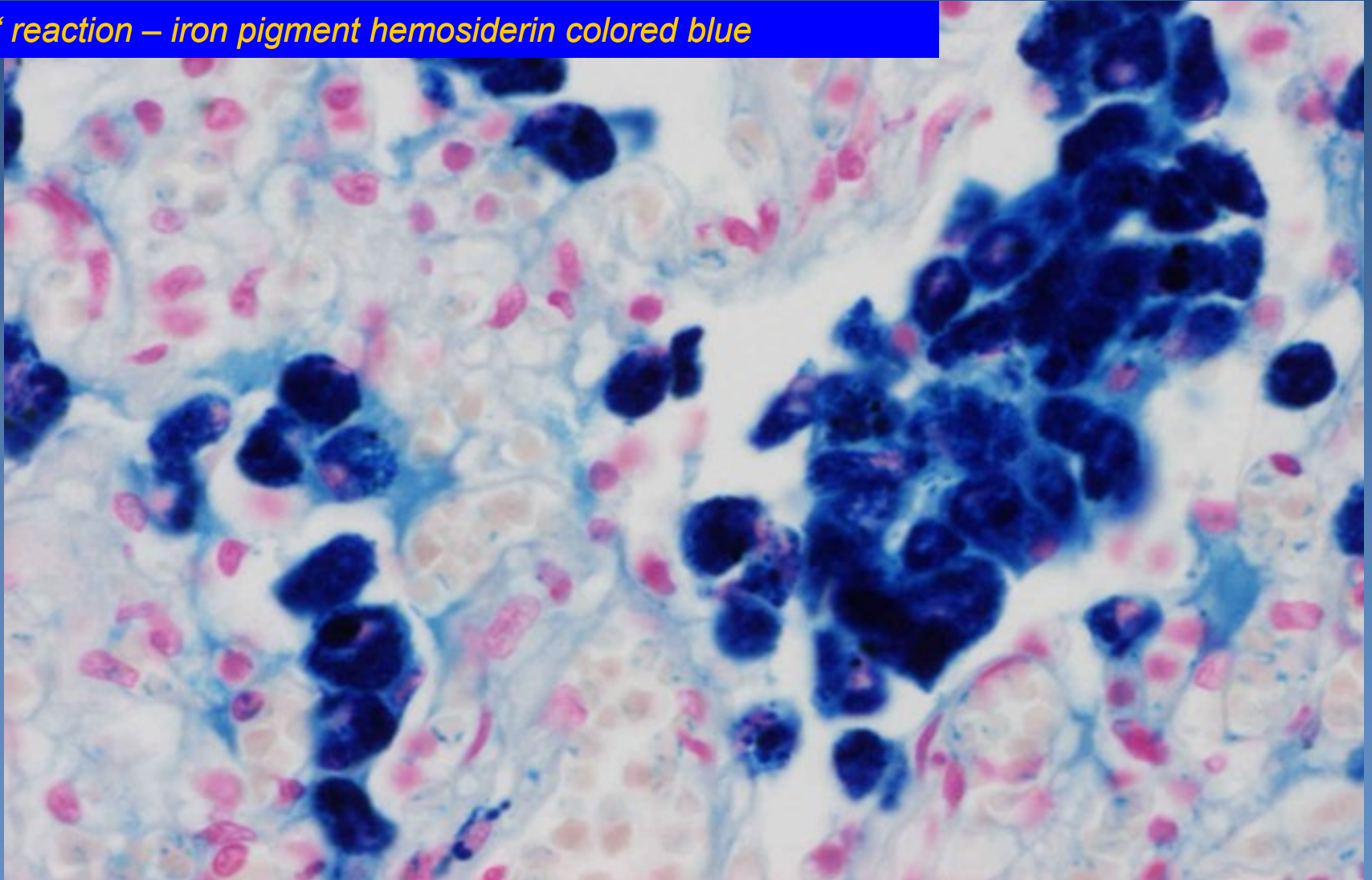


- 1. Oedematic fluid*
- 2. Enlarged hyperemic septa*
- 3. Siderophages*

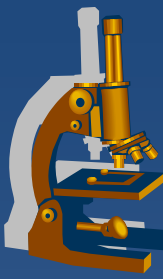
# *Chronic pulmonary venous congestion*



*Pertl's reaction – iron pigment hemosiderin colored blue*

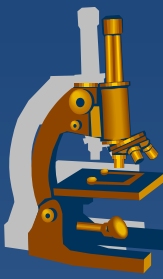


# Alveolar oedema



- ✗ fluid accumulation in alveoli
- ✗ clinically:
  - ⇒ *expectoration of bubbly watery pinkish sputum*
- ✗ pathogenesis:
  - ⇒ *↑ vascular permeability (injury to the alveolar-capillary wall)*
  - ⇒ *↑ vascular hydrostatic pressure*
  - ⇒ *↓ intravascular osmotic pressure*
  - ⇒ *lymphatic drainage obstruction*

# Alveolar oedema



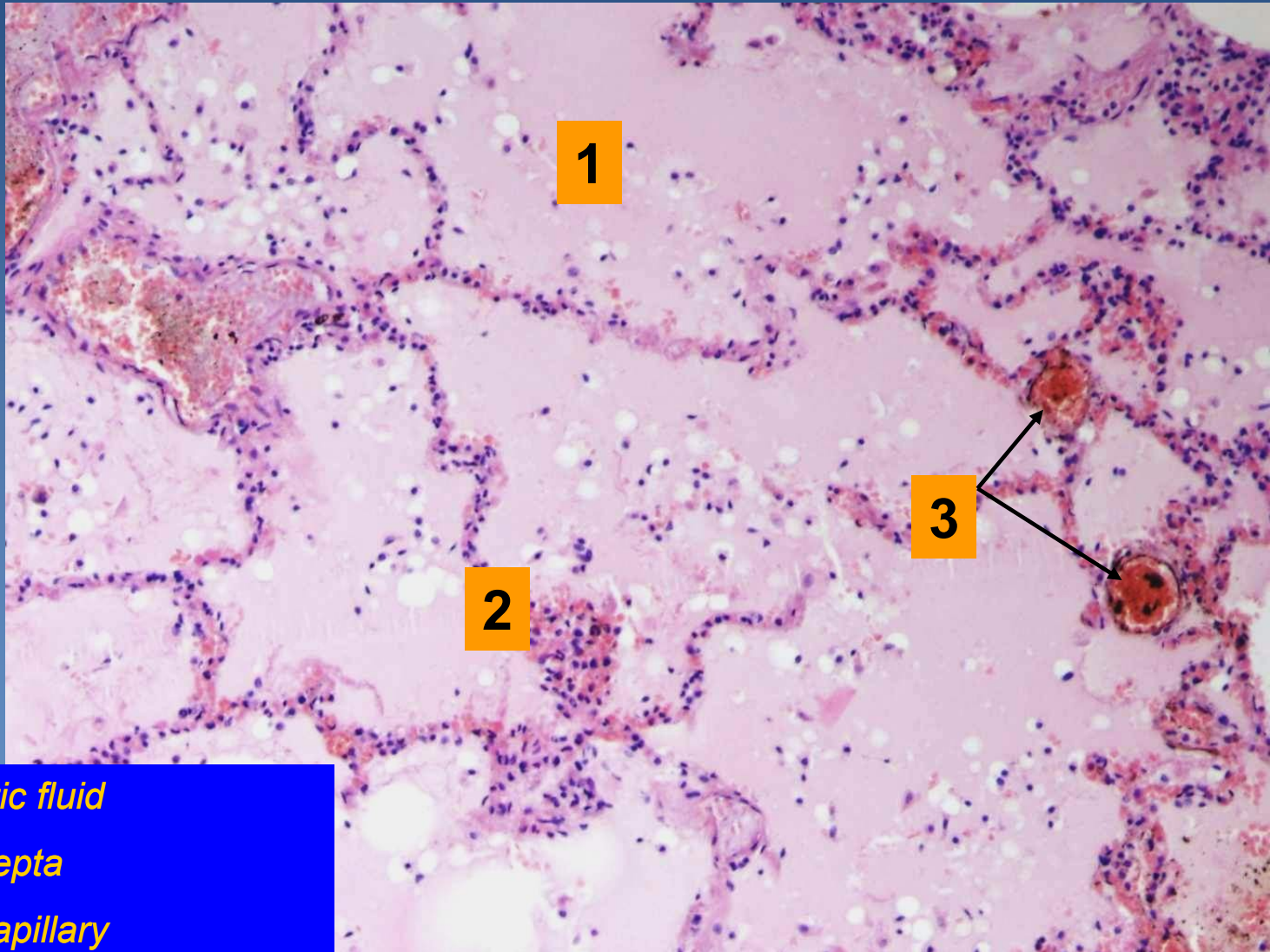
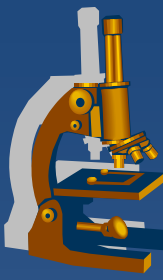
## x Gross:

- ⇒ *lungs enlarged, heavy, congested*
- ⇒ *bubbly fluid flowing out of the tissue +/- present in bronchi*

## x Micro:

- ⇒ *alveoli filled with pink, homogenous fluid + air bubbles*
- ⇒ *dilatation and hyperemia of alveolar wall capillaries*

# *Alveolar oedema*



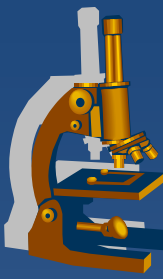
1

2

3

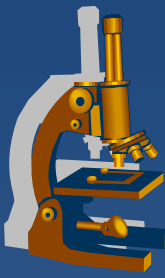
- 1. Oedematic fluid*
- 2. Dilated septa*
- 3. Dilated capillary*

# Amniotic fluid aspiration



- ✘ minor aspiration usual during birth
  - ⇒ *clinically insignificant*
- ✘ massive aspiration associated with fetus asphyxia
  - ⇒ *umbilical cord or placental disorders*
- ✘ clinic:
  - ⇒ *changes in fetal heart rate – immediate medical intervention necessary!*

# *Amniotic fluid aspiration*

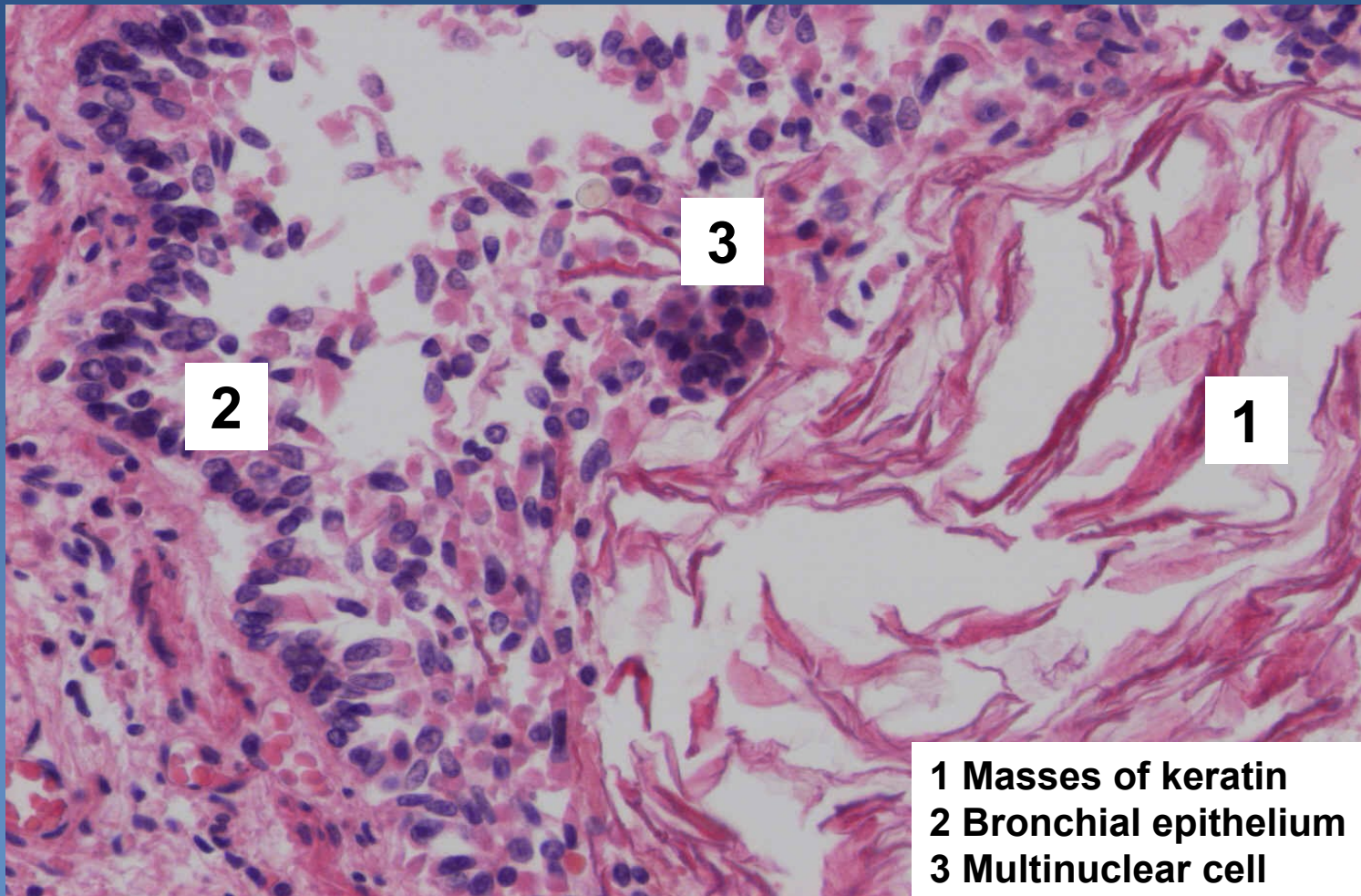
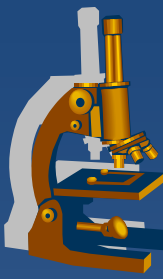


## **x** Micro:

- ⇒ *keratin masses in bronchi and alveoli*
- ⇒ *amniotic cells*
- ⇒ *lanugo (thin primary hairs)*
- ⇒ *meconium bodies (from fetus intestinal content)*
- ⇒ *infected amniotic fluid → fetal death, adnate **pneumonia***

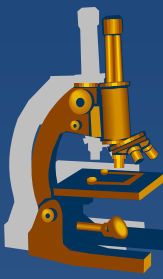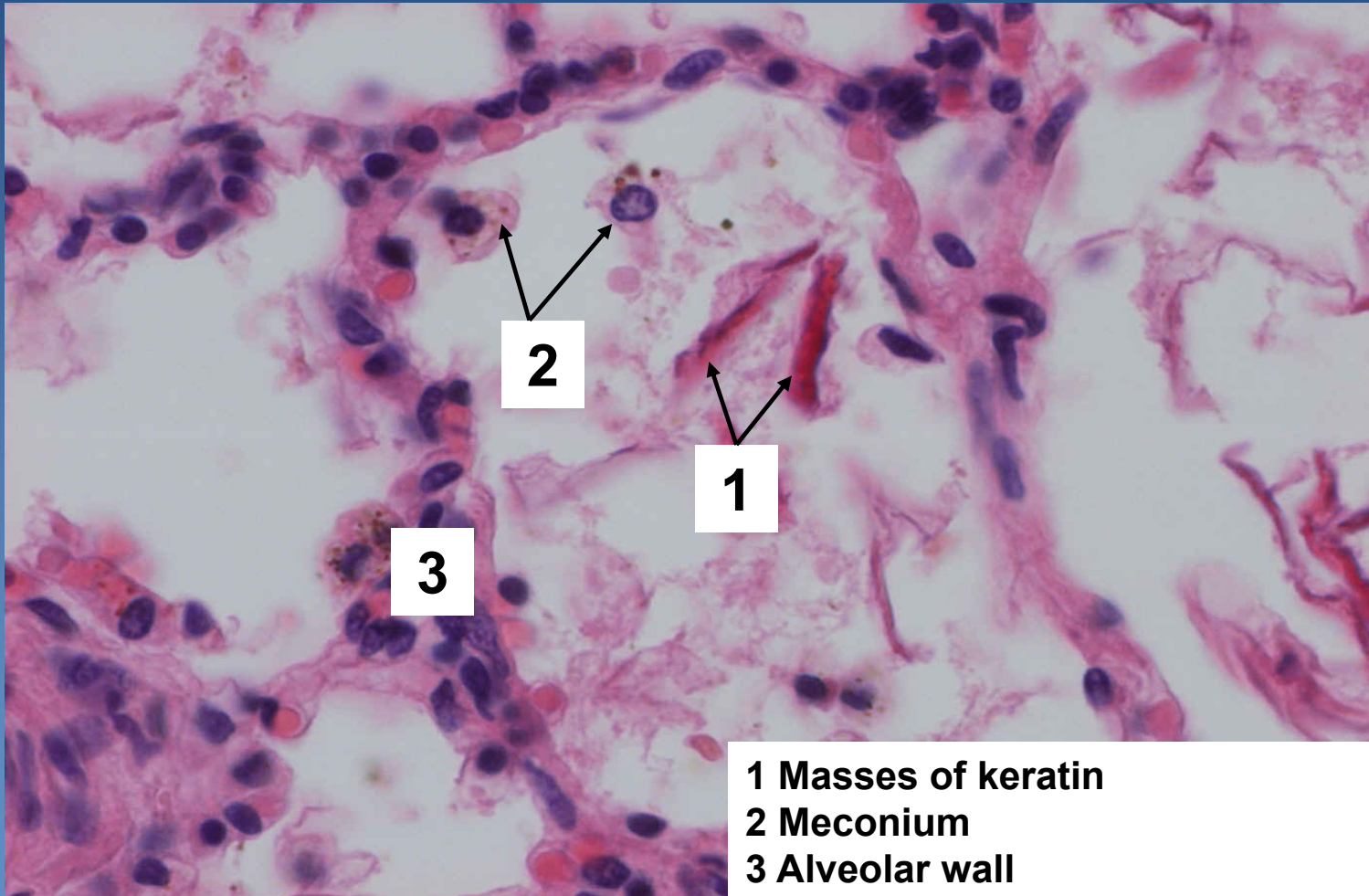


# *Amniotic fluid aspiration, keratin in bronchiole*

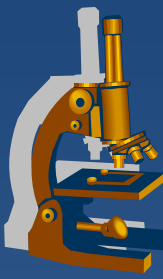


- 1** Masses of keratin
- 2** Bronchial epithelium
- 3** Multinuclear cell

# *Amniotic fluid aspiration, keratin in alveoli*



# ***Pulmonary inflammations - classification***



## **x superficial:**

⇒ *lobar pneumonia*

⇒ *bronchopneumonia*

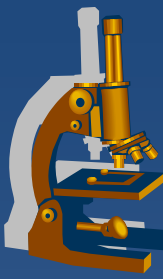
## **x interstitial**

⇒ *purulent (abscess, gangrene)*

⇒ *non-purulent*

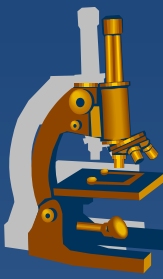
- infectious (acute) – atypical pneumonia
- non-infectious (chronic)

# *Lobar pneumonia*



- ✗ superficial diffuse **fibrinous** inflammation
- ✗ affecting major part / entire lobe of a lung
  - ⇒ *similar histological features in the same time*
  - ⇒ *older/immunocompromised patients → lethal without antibiotic therapy*
- ✗ untreated – 4 stages:
  - ⇒ *congestion (+ oedema)*
  - ⇒ *red hepatization (inflammatory infiltrate + congestion)*
  - ⇒ *grey hepatization (fibrin)*
  - ⇒ *resolution (resorption)*

# *Lobar pneumonia*



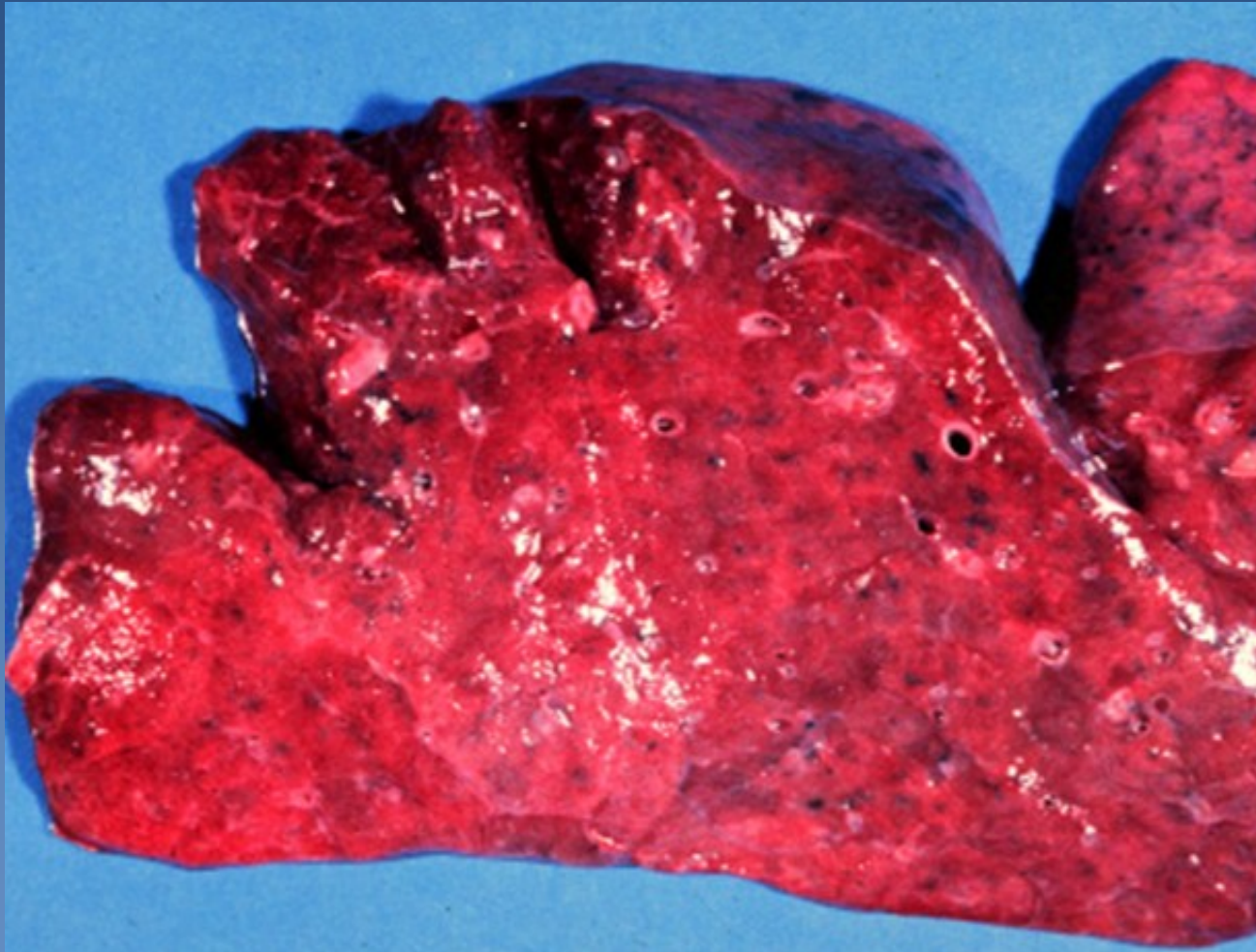
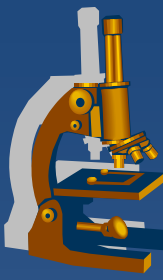
## **x** healing:

⇒ *ad integrum*

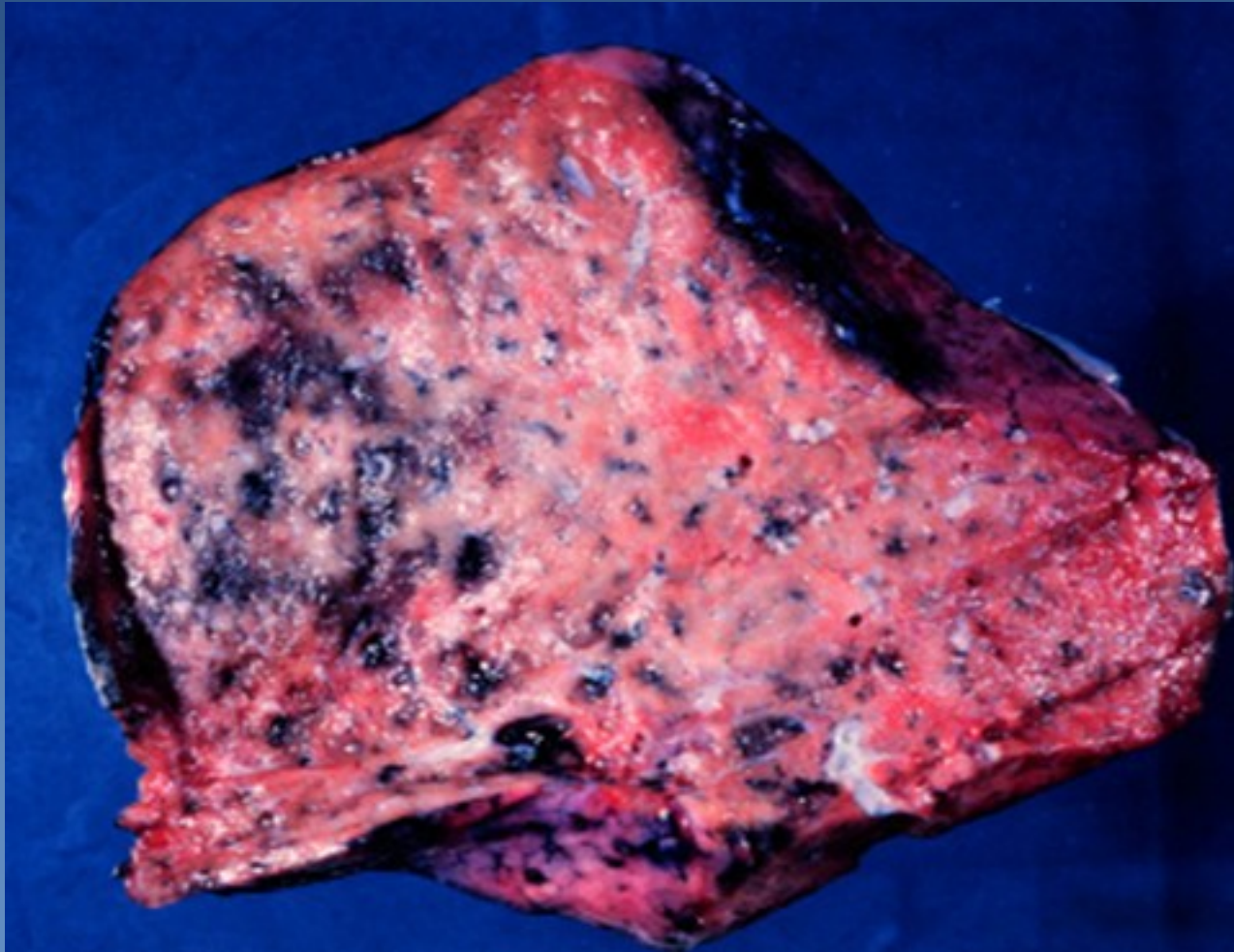
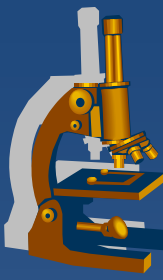
⇒ *complications:*

- empyema
- abscess
- carnification
- sepsis
- metastatic purulent inflammation
  - e.g. leptomeningitis, pericarditis, endocarditis...

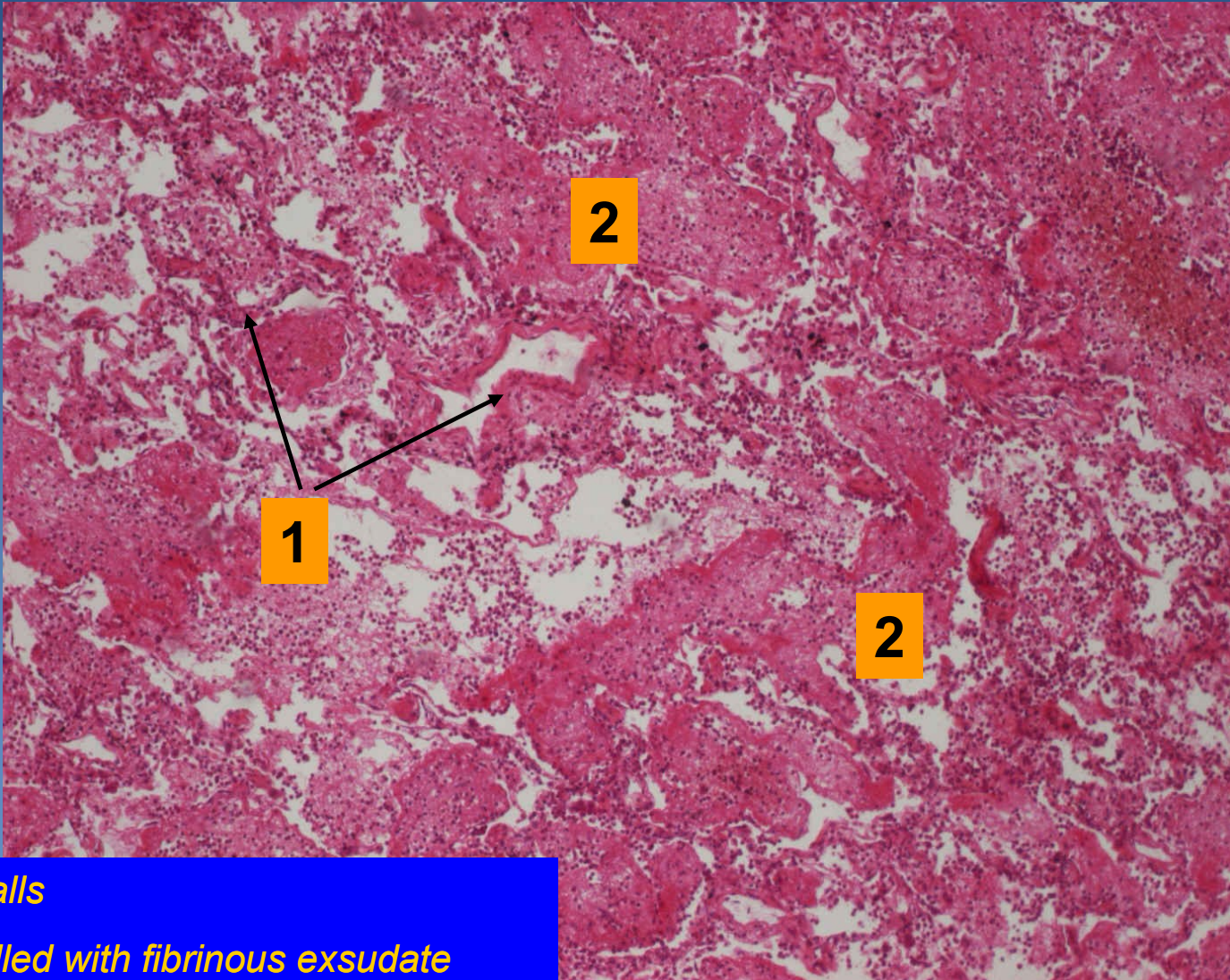
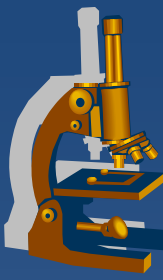
# ***Lobar pneumonia, red hepatization***



# *Lobar pneumonia, grey hepatization*



# *Lobar pneumonia*

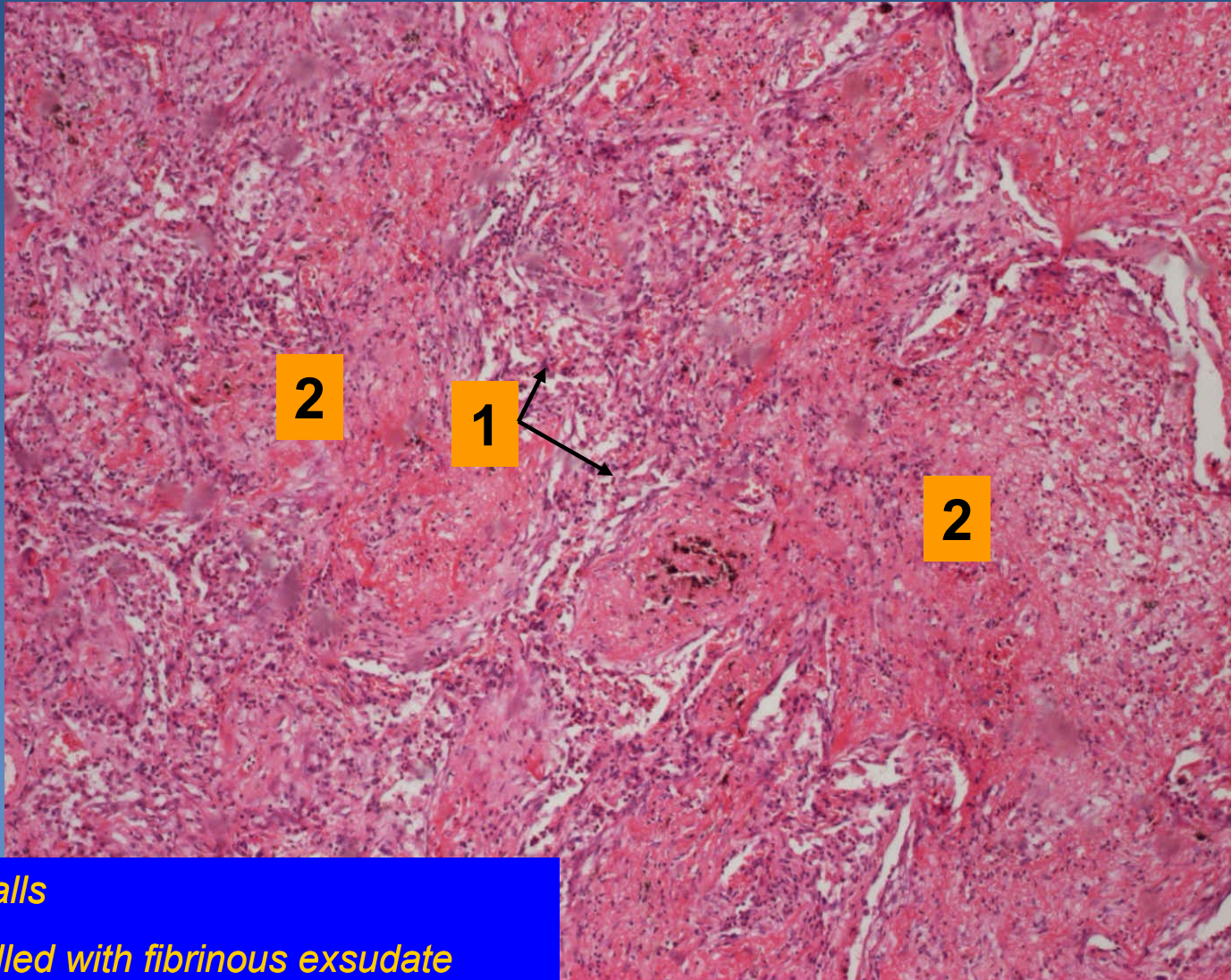
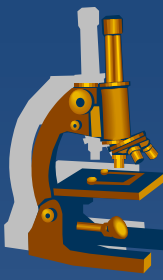


*1. Alveolar walls*

*2. Alveoli fulfilled with fibrinous exsudate*



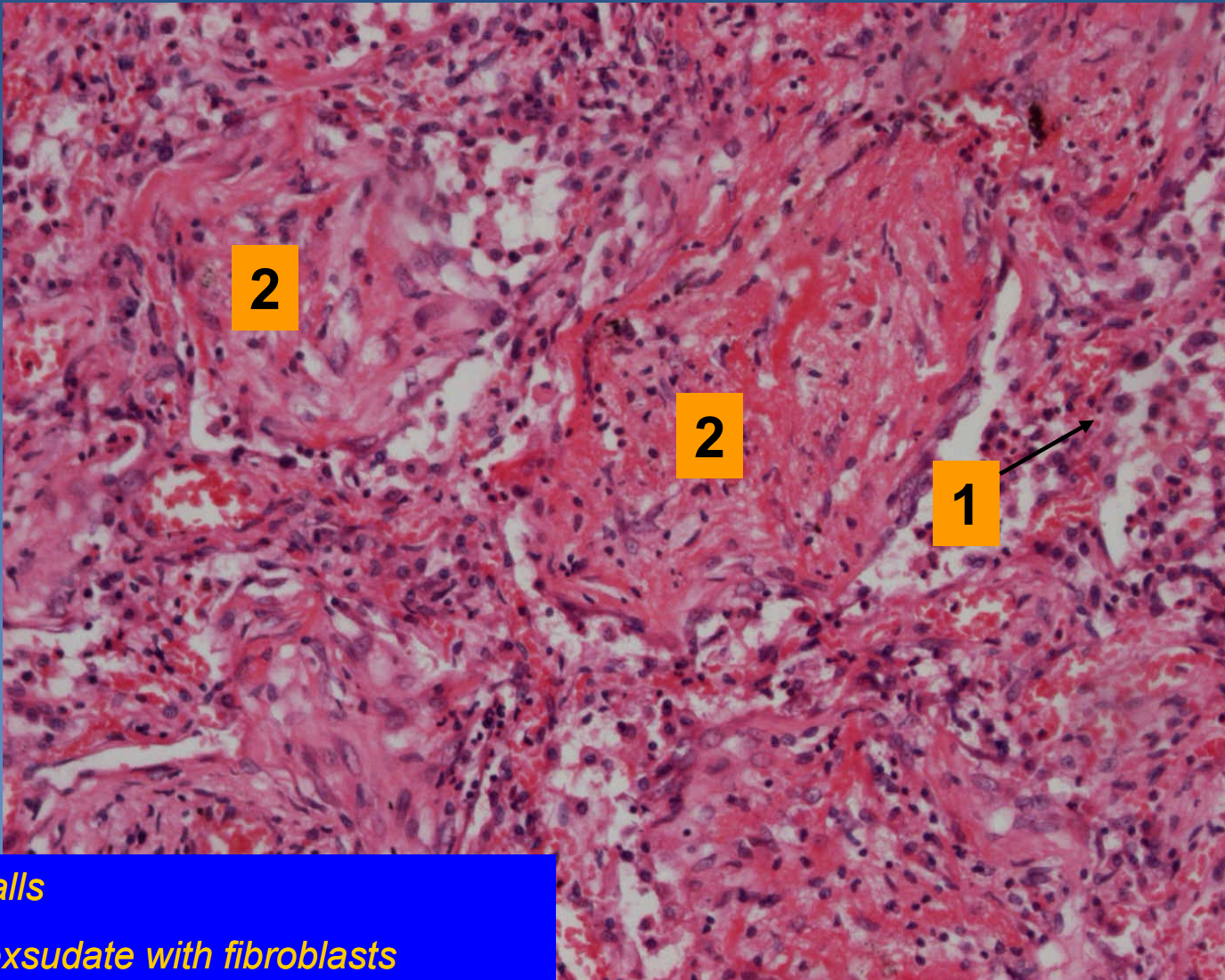
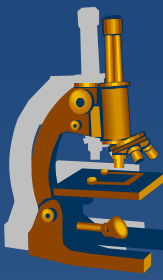
# *Lobar pneumonia*



*1. Alveolar walls*

*2. Alveoli fulfilled with fibrinous exudate*

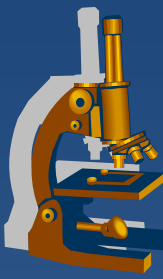
# *Lobar pneumonia*



*1. Alveolar walls*

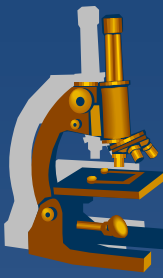
*2. Fibrinous exsudate with fibroblasts*

# Bronchopneumonia



- ✗ superficial type of pneumonia characterized by multiple foci of isolated, acute consolidation, affecting one or more pulmonary lobules
- ✗ inflammation spreads from bronchi
- ✗ aetiology:
  - ⇒ *streptococcus, staphylococcus, haemophilus, klebsiella*
  - ⇒ *legionella – micro:*
    - fibrinous purulent bronchopneumonia associated with fibrinous pleuritis
- ✗ possible secondary confluent inflammation, overlap patterns
- ✗ inflammatory complications:
  - ⇒ *pleuritis*
  - ⇒ *abscess*
  - ⇒ *sepsis*

# Bronchopneumonia



## × Gross:

⇒ *oedema, hyperemic tissue with small grey-yellow foci*

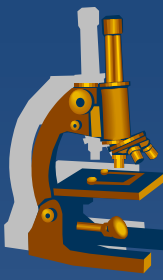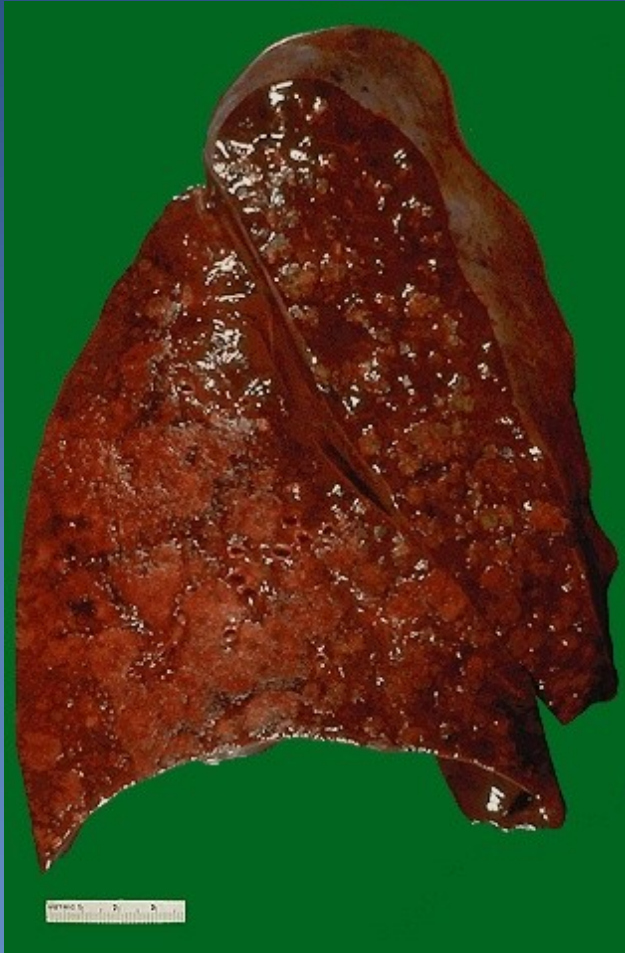
## × Micro:

⇒ *types of exsudate:*

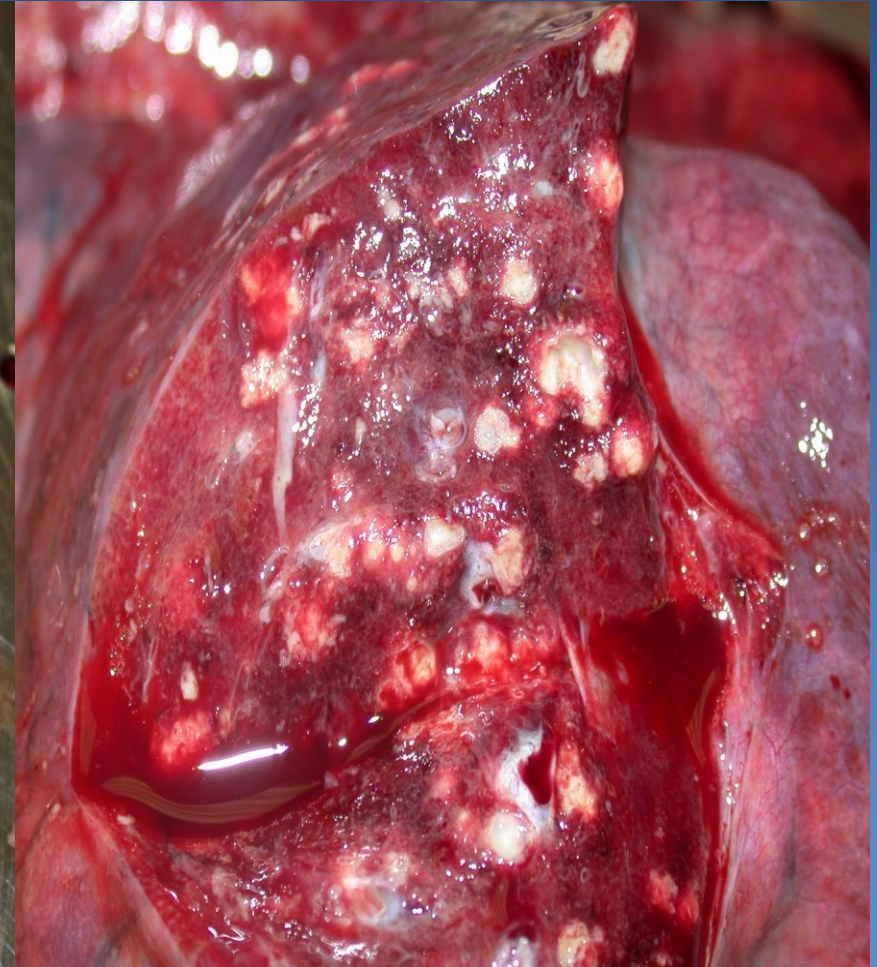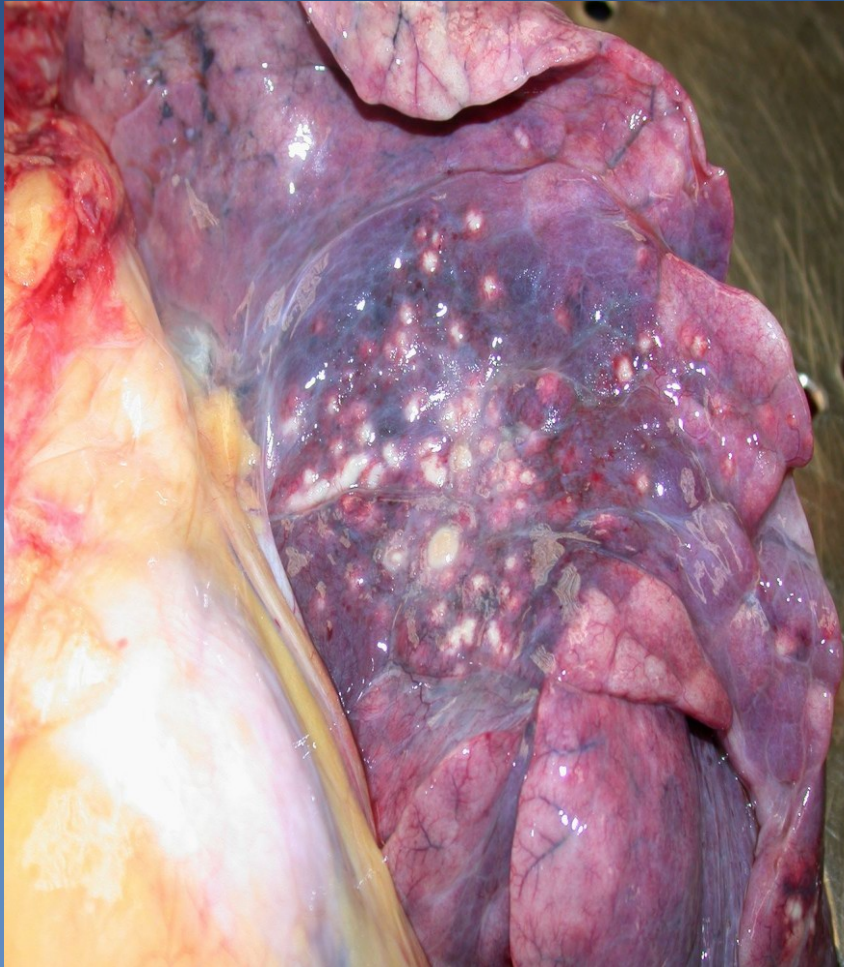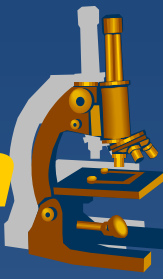- serous
- fibrinous
- suppurative (purulent)

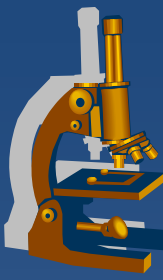
⇒ ***abscessing form*** – *suppurative destruction of alveolar walls*

# *Bronchopneumonia*

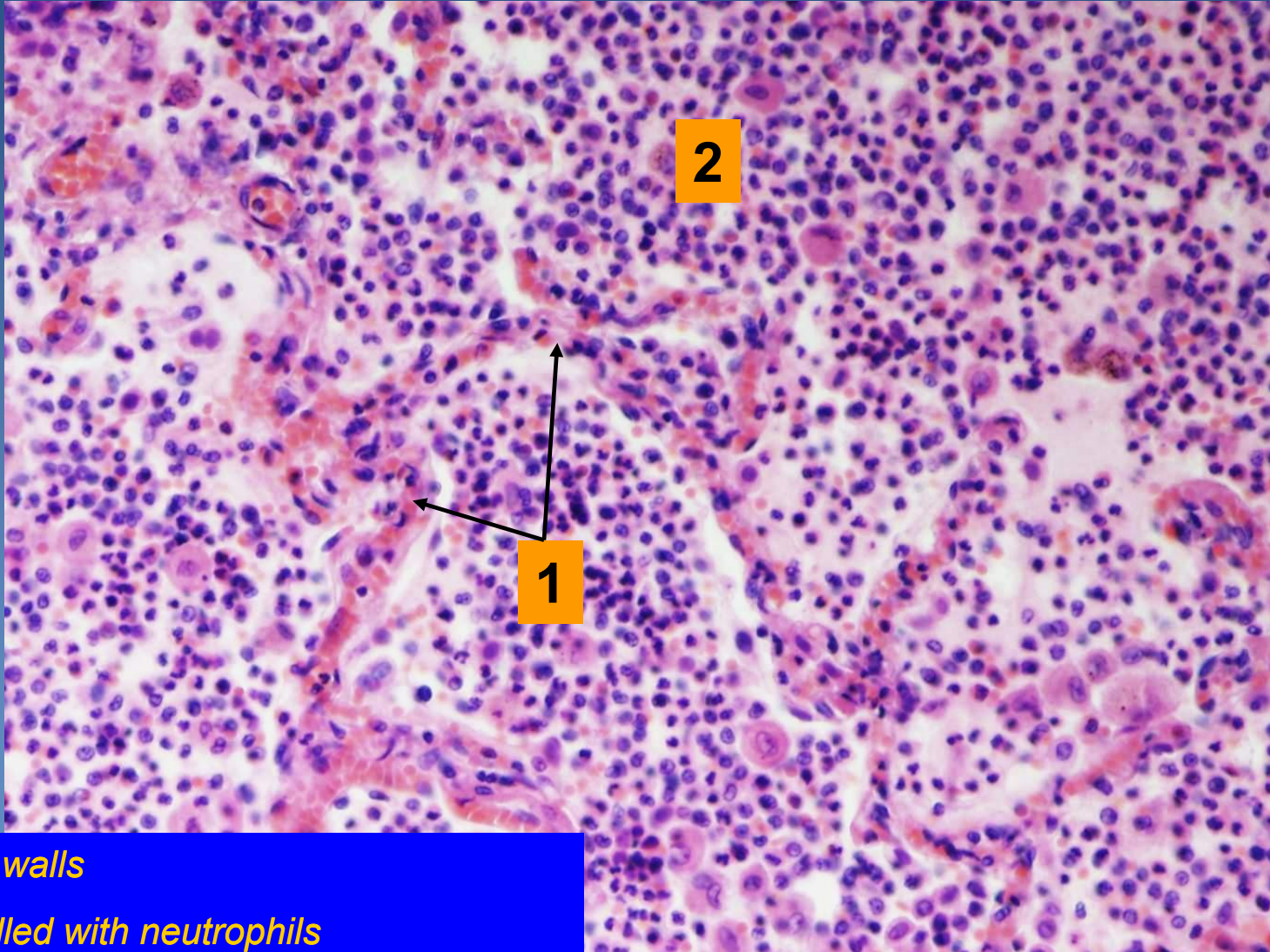


# ***Abscessing bronchopneumonia***





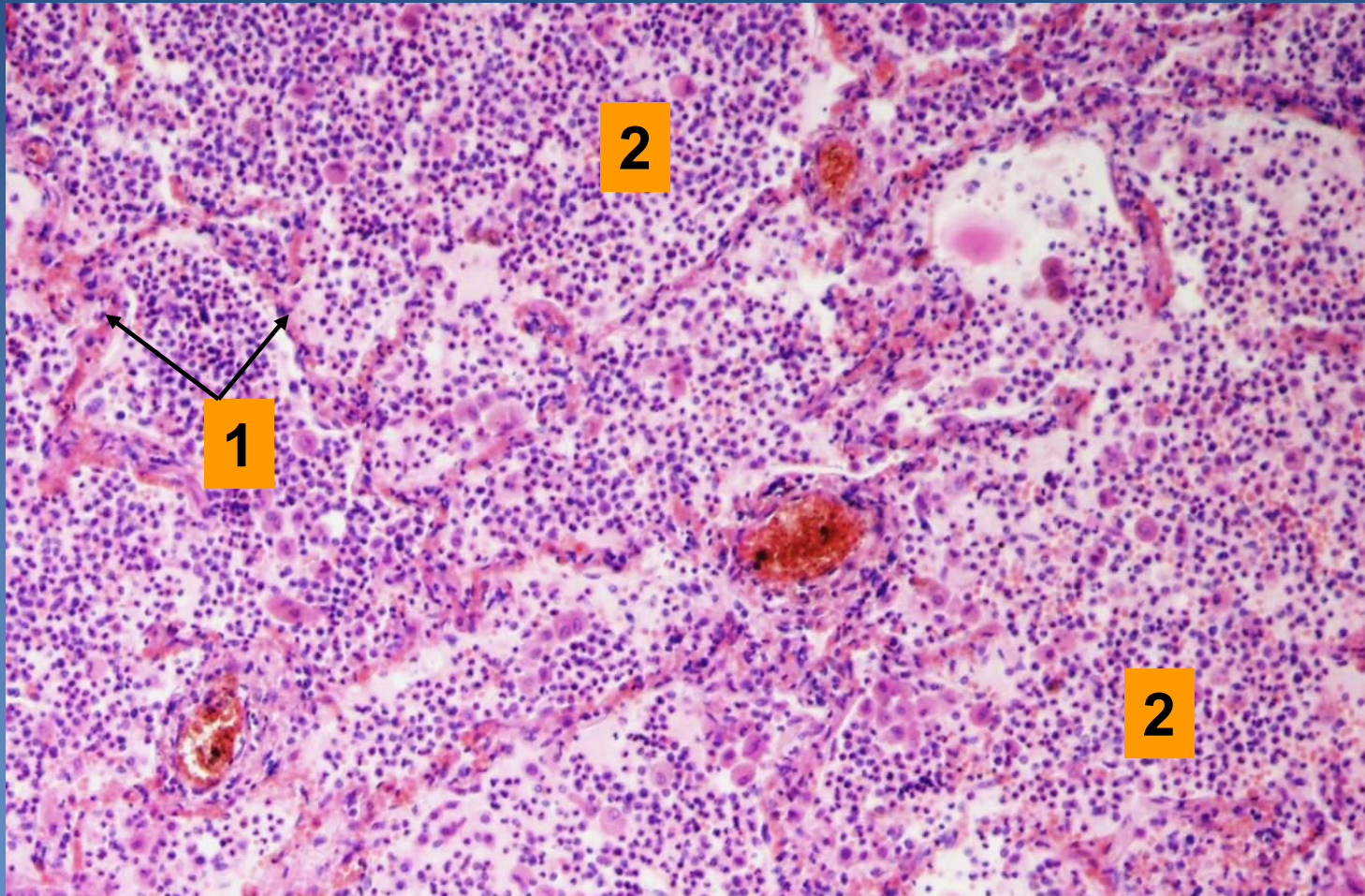
# *Purulent bronchopneumonia*



*1. Alveolar walls*

*2. Alveoli filled with neutrophils*

# *Abscessing bronchopneumonia*

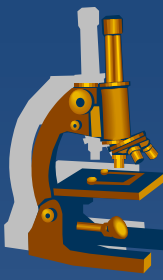


*1. Alveolar walls*

*2. Abscess with destruction of alveolar walls*



# ***Infectious interstitial pneumonia***



## **x Etiology:**

- ⇒ *viruses (incl. rubeola, varicella)*
- ⇒ *mycoplasma, chlamydia, coxiella, etc.*
- ⇒ *pneumocystis*

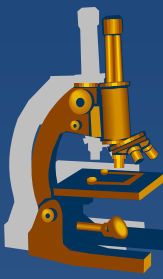
## **x Symptoms:**

- ⇒ *fever, dyspnoea, dry cough, auscultation may be normal (empty alveoli), x massive changes on X-ray*

## **x Healing:**

- ⇒ *ad integrum*
- ⇒ *secondary bacterial pneumonia*
- ⇒ *cryptogenic organizing pneumonia possible*

# ***Infectious interstitial pneumonia***

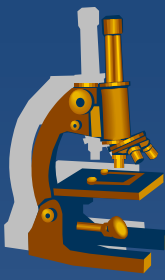


## **x Micro:**

### **⇒ 1) *common histological features:***

- oedema and dilatation of alveolar walls
- interstitium with mononuclear infiltrate (lymphocytes, macrophages, plasma cells)
- possible ARDS - „hyaline membranes“ formation
  - necrotic pneumocytes and fibrin
  - eosinophilic material lining the lumen of alveoli

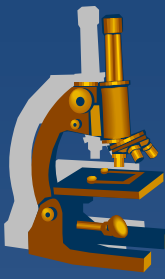
# *Infectious interstitial pneumonia*



## ⇒ 2) *inclusion pneumonia:*

- typical inclusions and cytopathologic changes of pneumocytes
- **CMV:**
  - large pneumocytes with basophilic intranuclear inclusions
- **Varicella, adenovirus:**
  - intranuclear inclusions
- **Measles:**
  - giant cell pneumonia
  - multinucleated cells in alveoli and bronchioli (Warthin-Finkeldey cells)
- **Pneumocystis pneumonia**

# *Pneumocystis pneumonia*



## x etiology:

⇒ *Pneumocystis jirovecii*

(opportunistic fungal infection, immunocompromised patients)

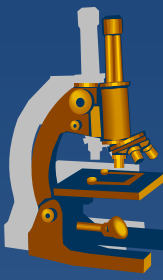
## x Micro:

⇒ *widened alveolar septa, intraalveolar bubbly eosinophilic material:*

- pneumocystis capsules

⇒ *special histological stains:*

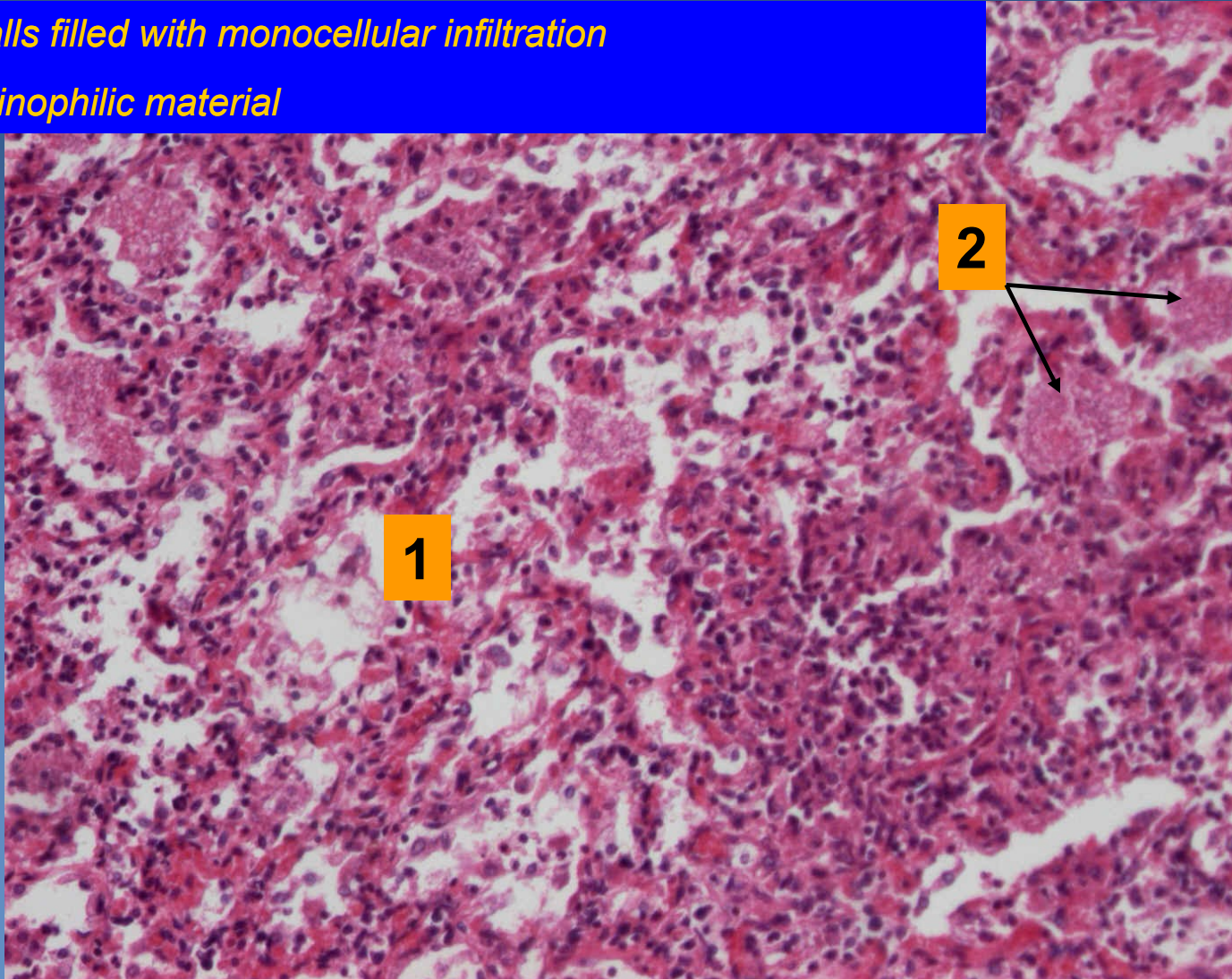
- Grocott silver impregnation (black)
- Giemsa (blue)
- PAS



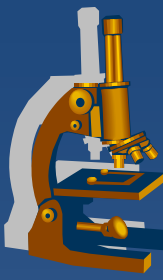
# *Pneumocystis pneumonia*

1. Alveolar walls filled with monocellular infiltration

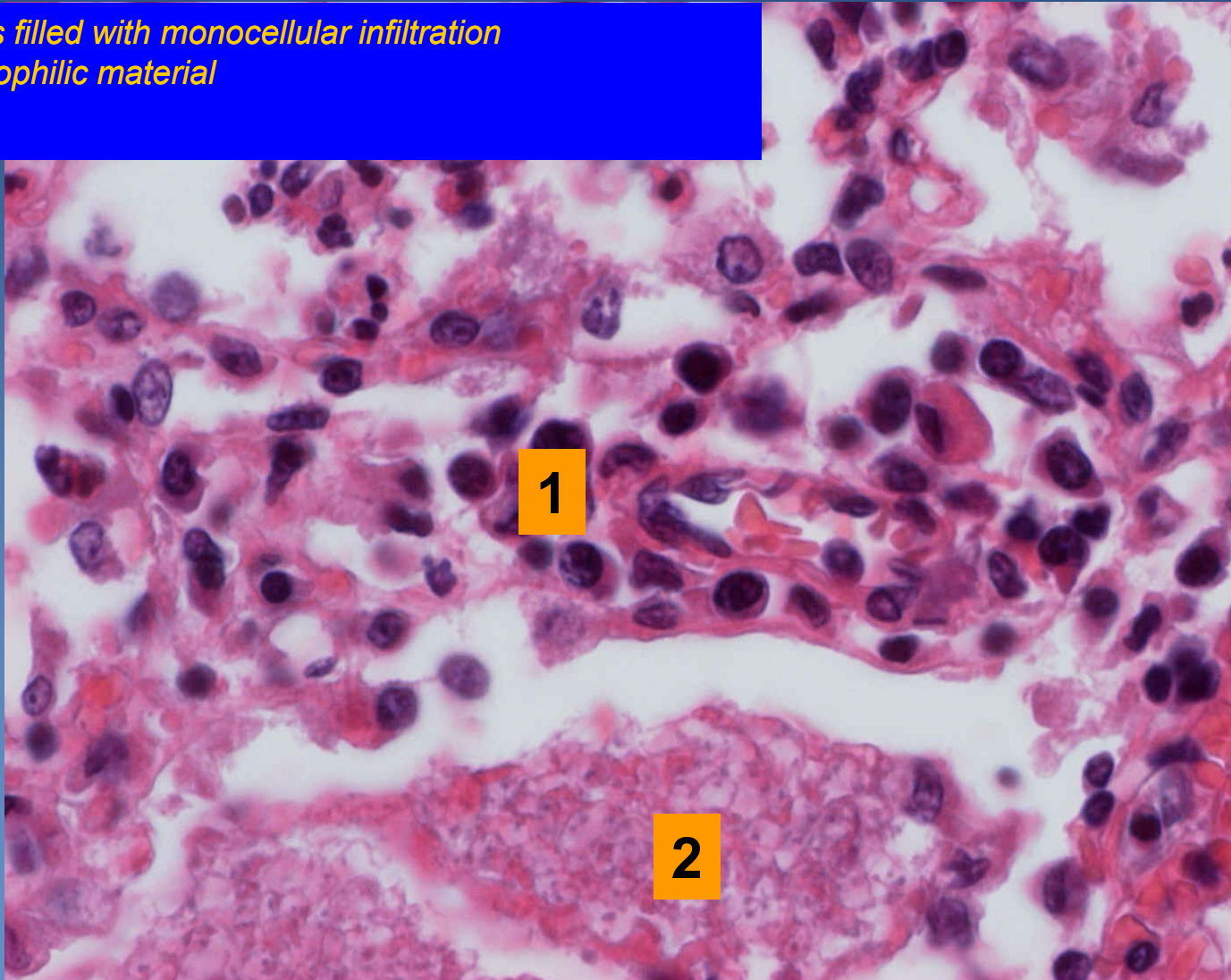
2. Bubbly eosinophilic material



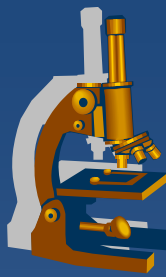
# *Pneumocystis pneumonia*



1. Alveolar walls filled with mononuclear infiltration
2. Bubbly eosinophilic material



# *Neinfekční intersticiální pneumonie*



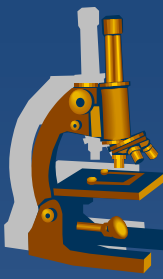
## **x** Klasifikace:

⇒ *Kryptogenní fibrotizující alveolitida (idiopatická intersticiální pneumonie)*

- Běžná
- Nespecifická
- Deskvamativní
- Obrovskobuněčná

⇒ *Extrinzická fibrotizující alveolitida (hypersenzitivní pneumonitida)*

# *Idiopathic pulmonary fibrosis*



✘ usual interstitial pneumonia“ (UIP):

⇒ **70% of all of idiopathic interstitial pneumonias**

⇒ **etiology:**

- in some collagenosis or in association with abnormalities of serum proteins
- smoking
- unclear

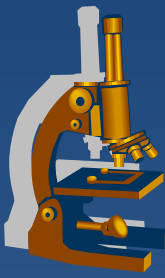
⇒ **dismal prognosis: lung transplantation**

⇒ **Mikro:**

- subpleural and a paraseptal foci of fibroblasts/fibrosis and chronic inflammatory infiltrate, cystic spaces - honeycombing
- irregular distribution of histological features – temporal heterogeneity



# *Idiopathic pulmonary fibrosis*



✗ non-specific interstitial pneumonia (NSIP):

⇒ *commonly women, without link with smoking*

⇒ *better prognosis*

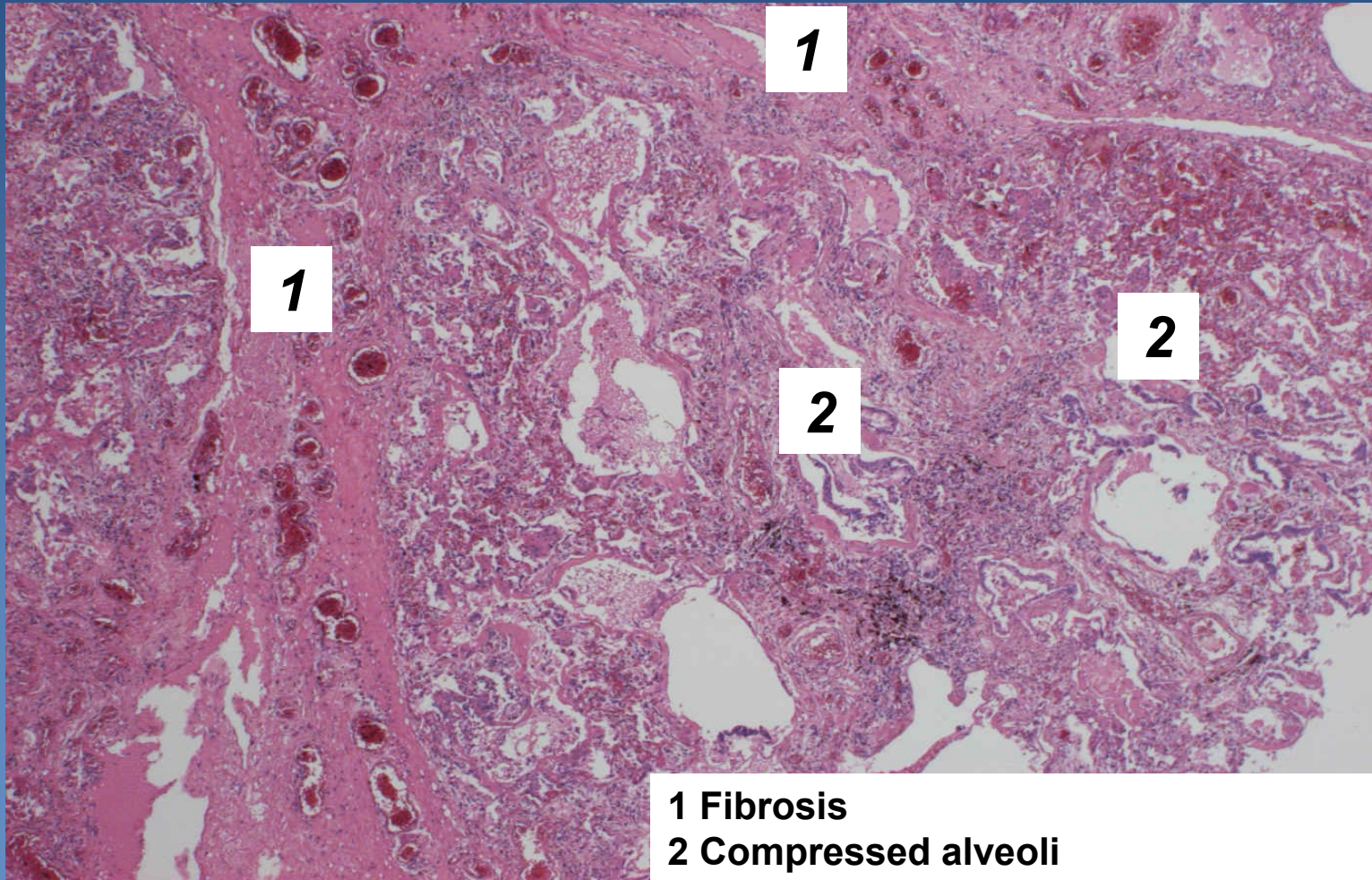
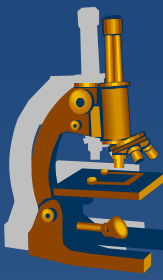
- treated with corticosteroids

⇒ **Micro:**

- chronic interstitial inflammation +/- fibrosis
- no honeycombing
- regular distribution of changes

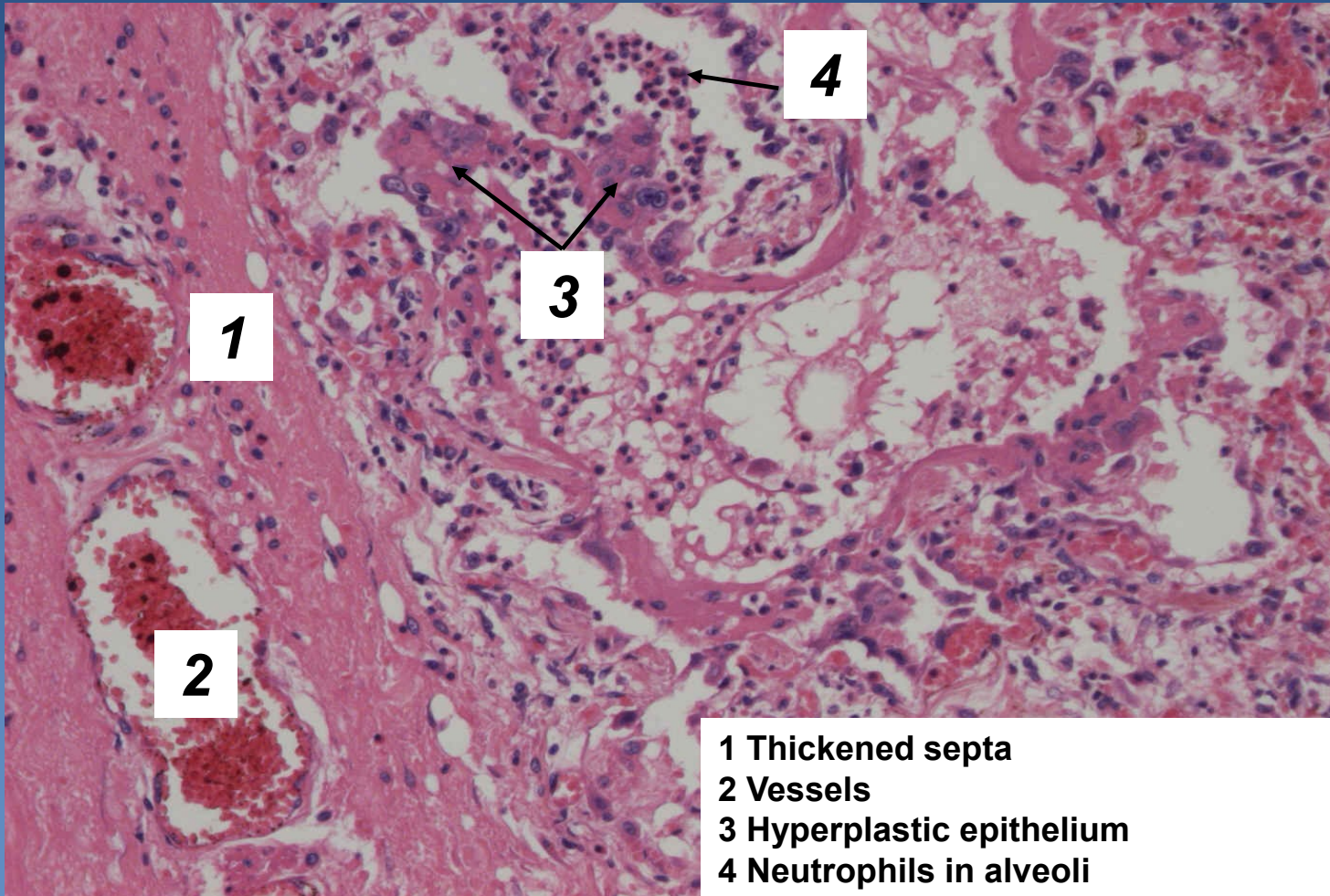
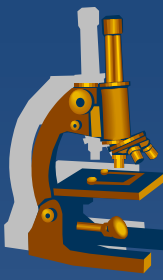
-

# *Usual interstitial pneumonia*



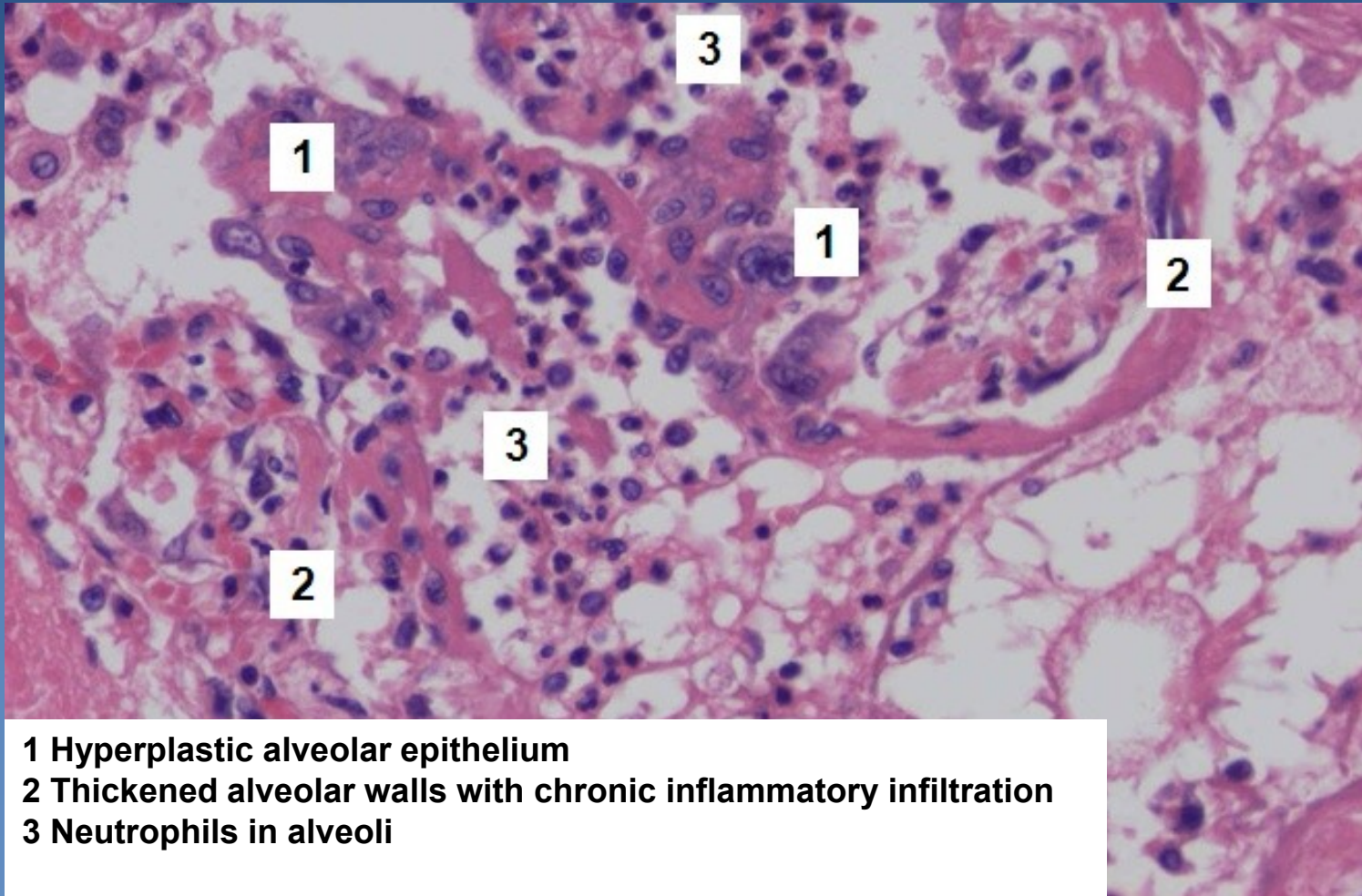
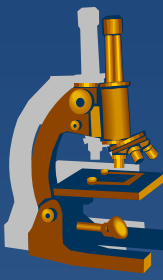
**1** Fibrosis  
**2** Compressed alveoli

# *Usual interstitial pneumonia*



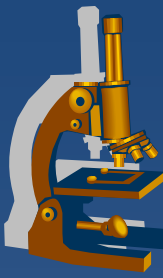
- 1 Thickened septa
- 2 Vessels
- 3 Hyperplastic epithelium
- 4 Neutrophils in alveoli

# *Usual interstitial pneumonia*



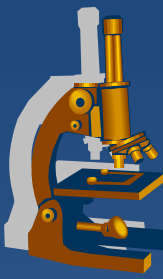
- 1 Hyperplastic alveolar epithelium
- 2 Thickened alveolar walls with chronic inflammatory infiltration
- 3 Neutrophils in alveoli

# Pneumoconiosis



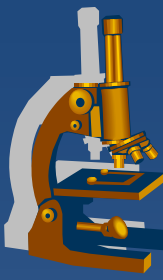
- ✗ an occupational and restrictive lung disease caused by the inhalation of specific dust
- ✗ sequels: inert (simple), fibrous, allergic, neoplastic
- ✗ high fibrogenicity of cristalline silica dust and asbestos
- ✗ 3 basic types:
  - *coal-worker`s pneumoconiosis*
  - ⇒ *silicosis*
  - ⇒ *asbestosis*

# *Silicosis*



- ✗ Chronic progressive pneumoconiosis
- ✗ Silicene dioxide particles (0,2-2 $\mu$ m) toxic to macrophages – focal necrosis + release of fibrogenic factors - fibrosis
- ✗ X-ray – reticular fibrosis, nodules, diffuse fibrosis
- ✗ lung insufficiency
- ✗ cor pulmonale

# Silicosis



- × Gross (stages):

- ⇒ *reticular fibrosis*

- ⇒ *silicotic nodules*

- ⇒ *progressive massive fibrosis*

- × Micro:

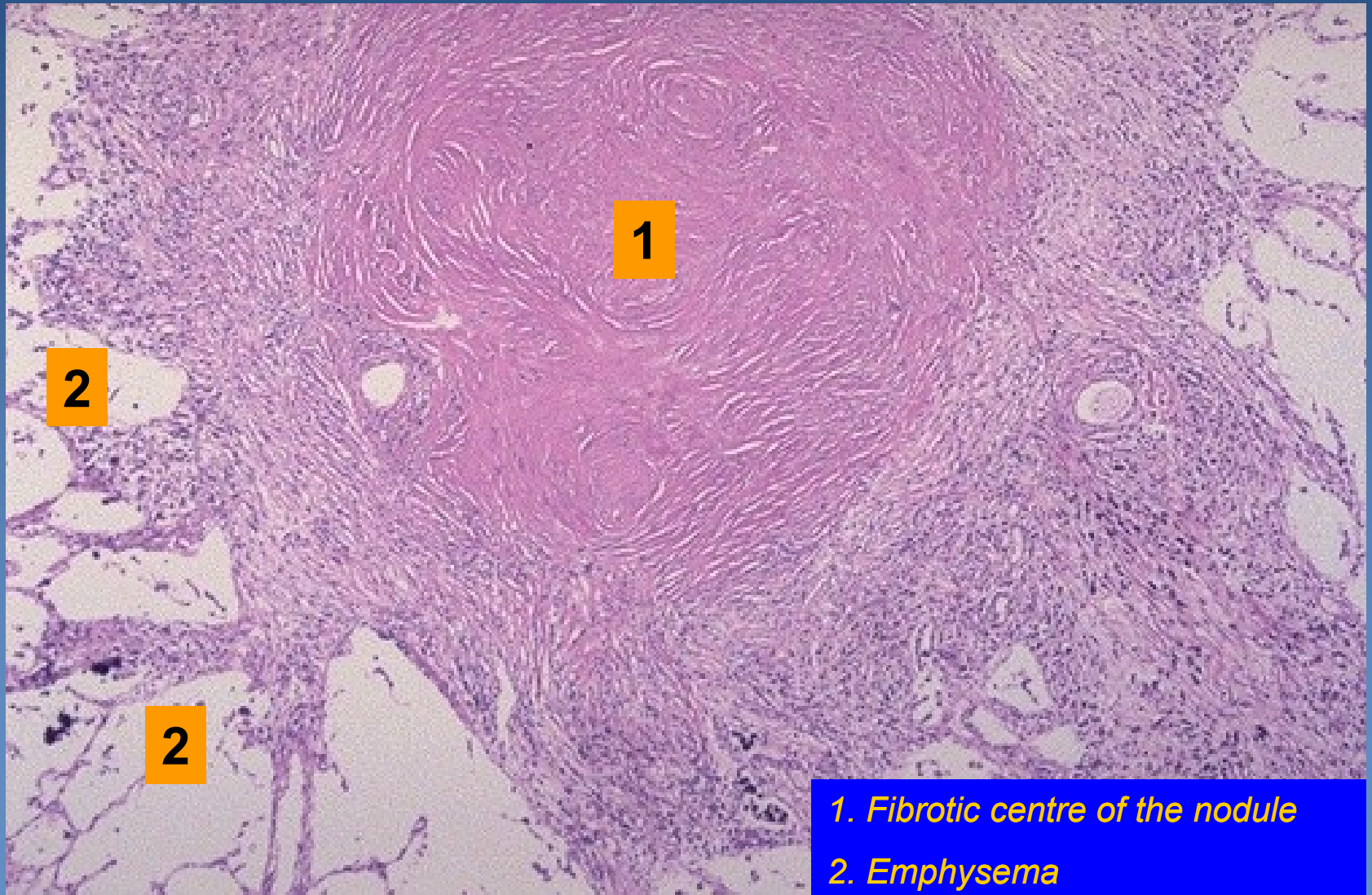
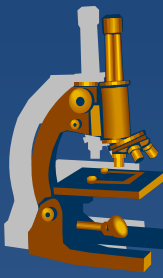
- ⇒ *nodules with concentric arrangement of hyalinized fibers and necrosis*

- ⇒ *anthracophages in the periphery of the nodule*

- ⇒ *emphysema in adjacent pulmonary tissue*

- ⇒ *particles seen under polarized light*

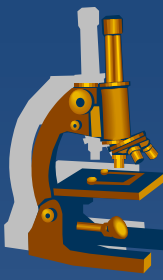
# *Silicotic nodule - lung*



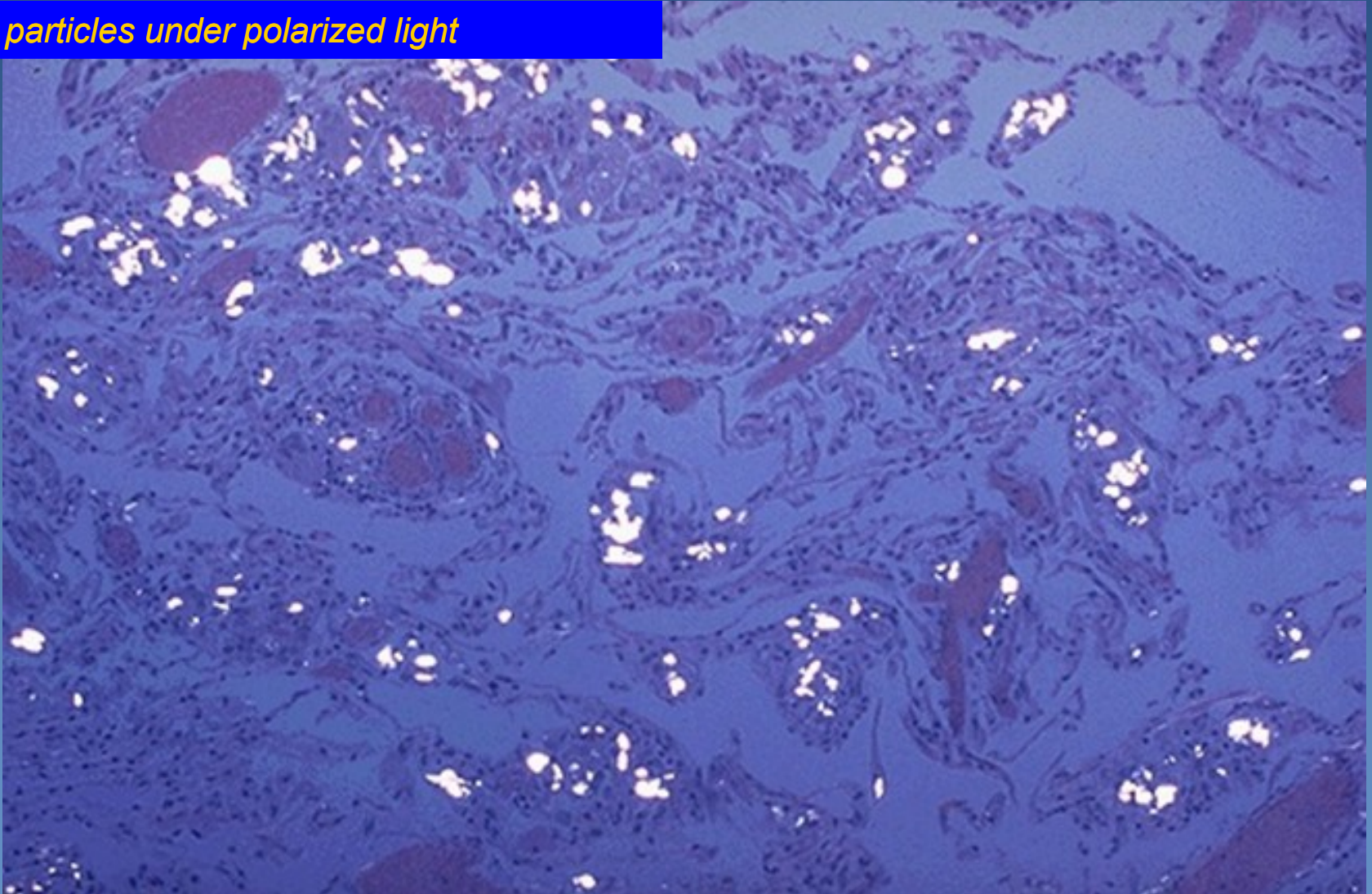
- 1. Fibrotic centre of the nodule*
- 2. Emphysema*



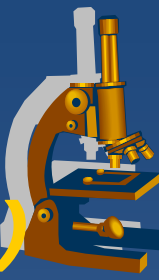
# *Pulmonary silicosis*



*Silica particles under polarized light*



# ***Diffuse alveolar damage (Acute Respiratory Distress Syndrome)***



× DAD (ARDS, RDS)

× clinical:

⇒ *progressive respiratory insufficiency associated with shortness of breath and hypoxia, high mortality*

× Etiology:

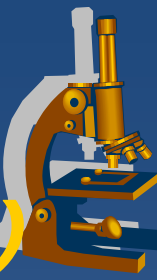
⇒ **Primary ARDS:**

- lung inflammation/infection, aspiration of gastric content, mechanical trauma incl. chest contusion, fat embolism, near-drowning, ionizing radiation, inhaled irritants (smoke, chemicals),

⇒ **Secondary ARDS:**

- trauma (head) or sepsis
- acute pancreatitis
- renal insufficiency (uremia)
- burns
- hematologic conditions – DIC, multiple transfusions
- chemical injury (heroin overdose, acetylsalicylates, ...)

# ***Diffuse alveolar damage (Acute Respiratory Distress Syndrome)***



## **x Gross:**

- ⇒ *heavy lung*
- ⇒ *dark red color*
- ⇒ *boggy*

## **x Micro:**

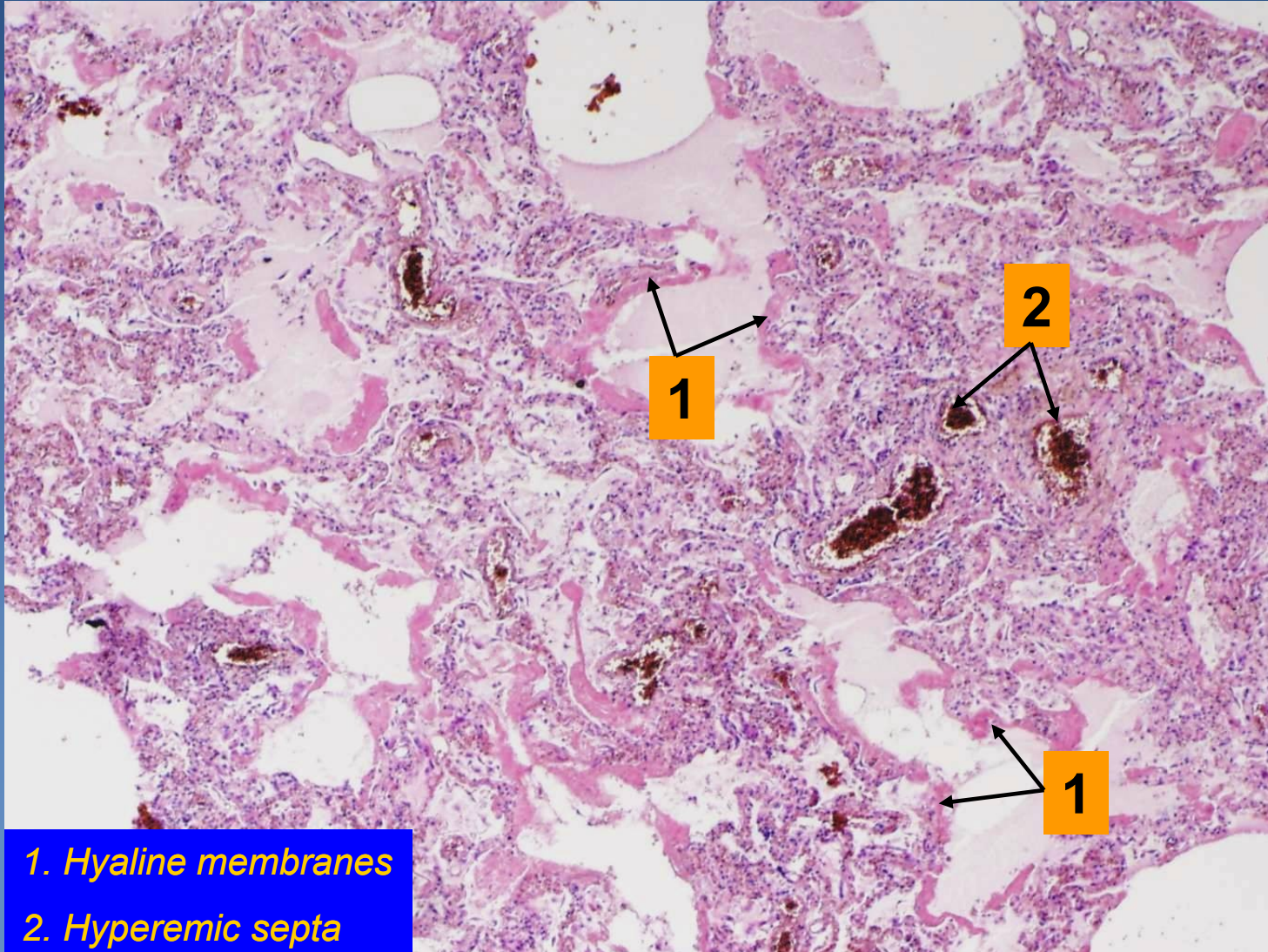
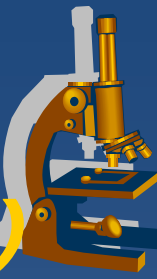
### ⇒ *exsudative phase:*

- capillary congestion, oedema, hyaline membranes formation within 48 hours

### ⇒ *proliferative phase:*

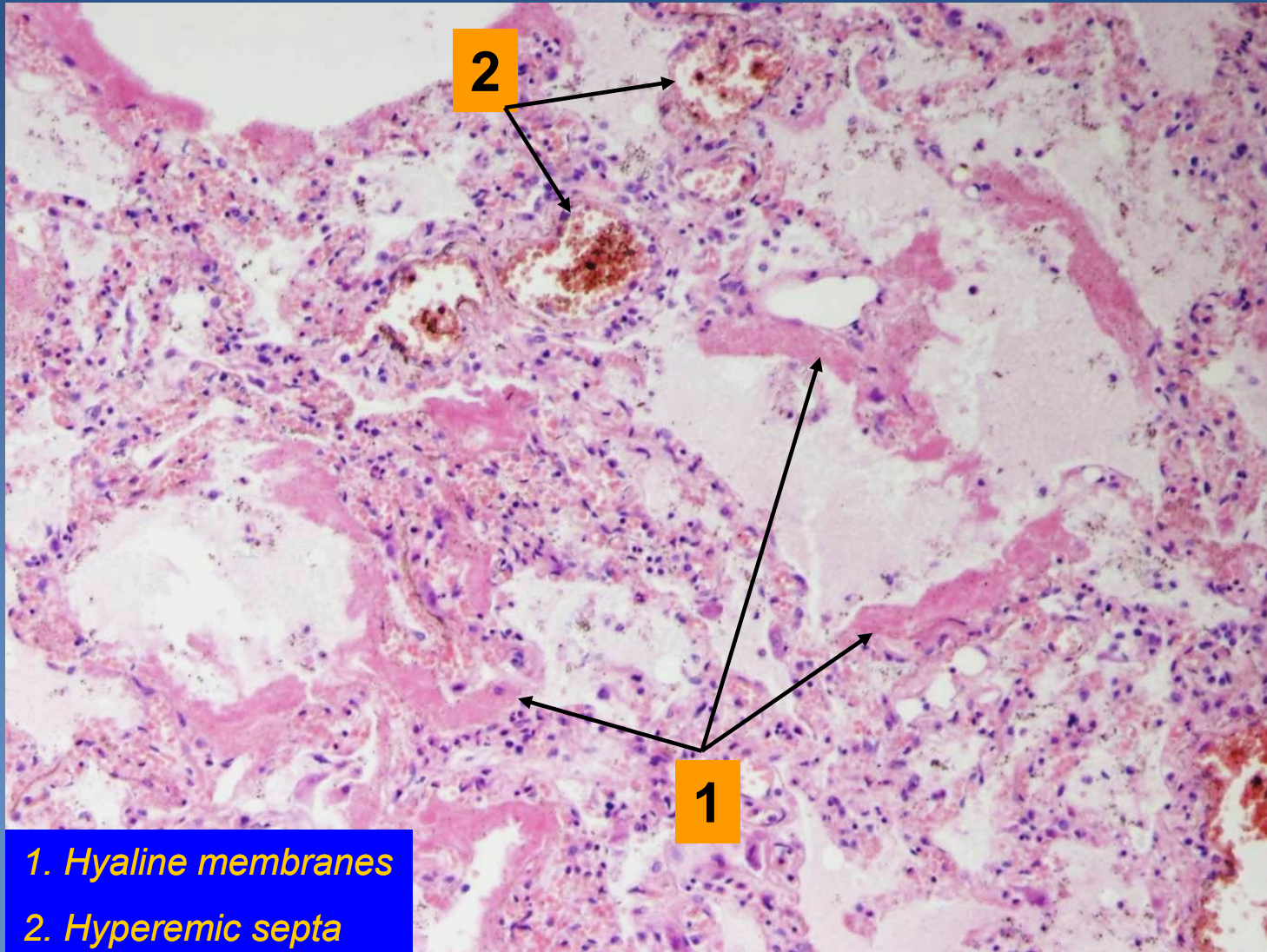
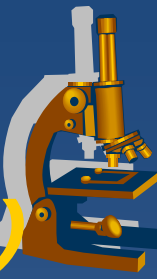
- epithelium regeneration (type II. pneumocytes)
- hyaline membranes ingested by macrophages
- proliferation of fibroblasts in alveolar walls -> pulmonary fibrosis possible

# *Diffuse alveolar damage (Acute Respiratory Distress Syndrome)*




1. Hyaline membranes
2. Hyperemic septa

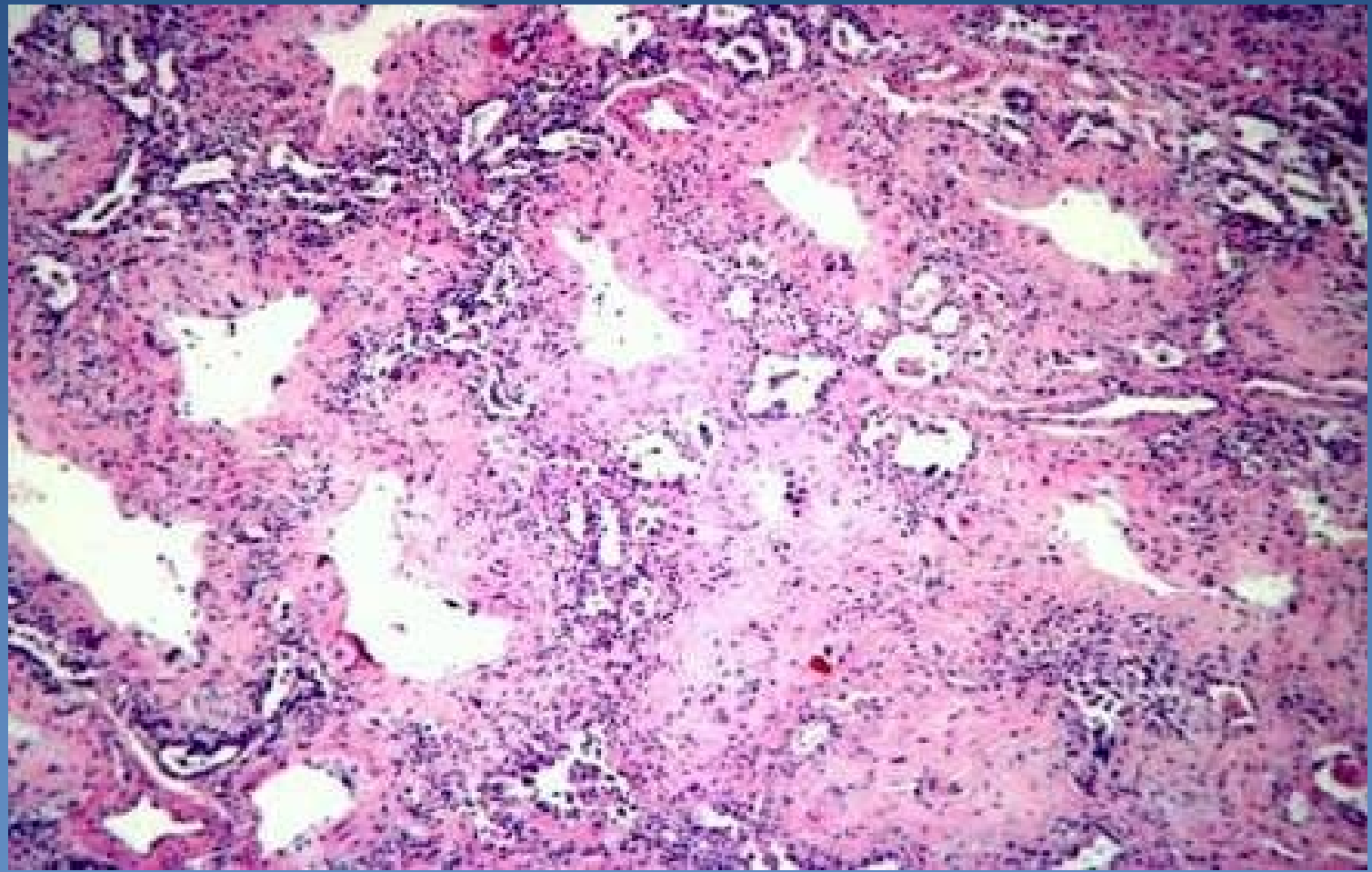
# *Diffuse alveolar damage (Acute Respiratory Distress Syndrome)*



- 1. Hyaline membranes
- 2. Hyperemic septa



**6.3 DAD, proliferative phase - fibrotic stage – distinctly thickened interalveolar septa with a chronic inflammatory infiltrate.**



# Granulomatous inflammations - Tuberculosis



## x aetiology

⇒ *Mycobacterium tuberculosis*, *M. bovis*

⇒ special *Ziehl-Neelsen stain*

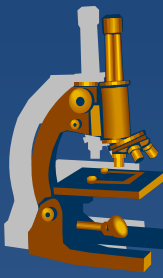
- PCR more sensitive

## x delayed-type hypersensitivity

(type IV. hypersensitivity)

⇒ *T cells-mediated immune memory response to TBC antigens (granulomas)*

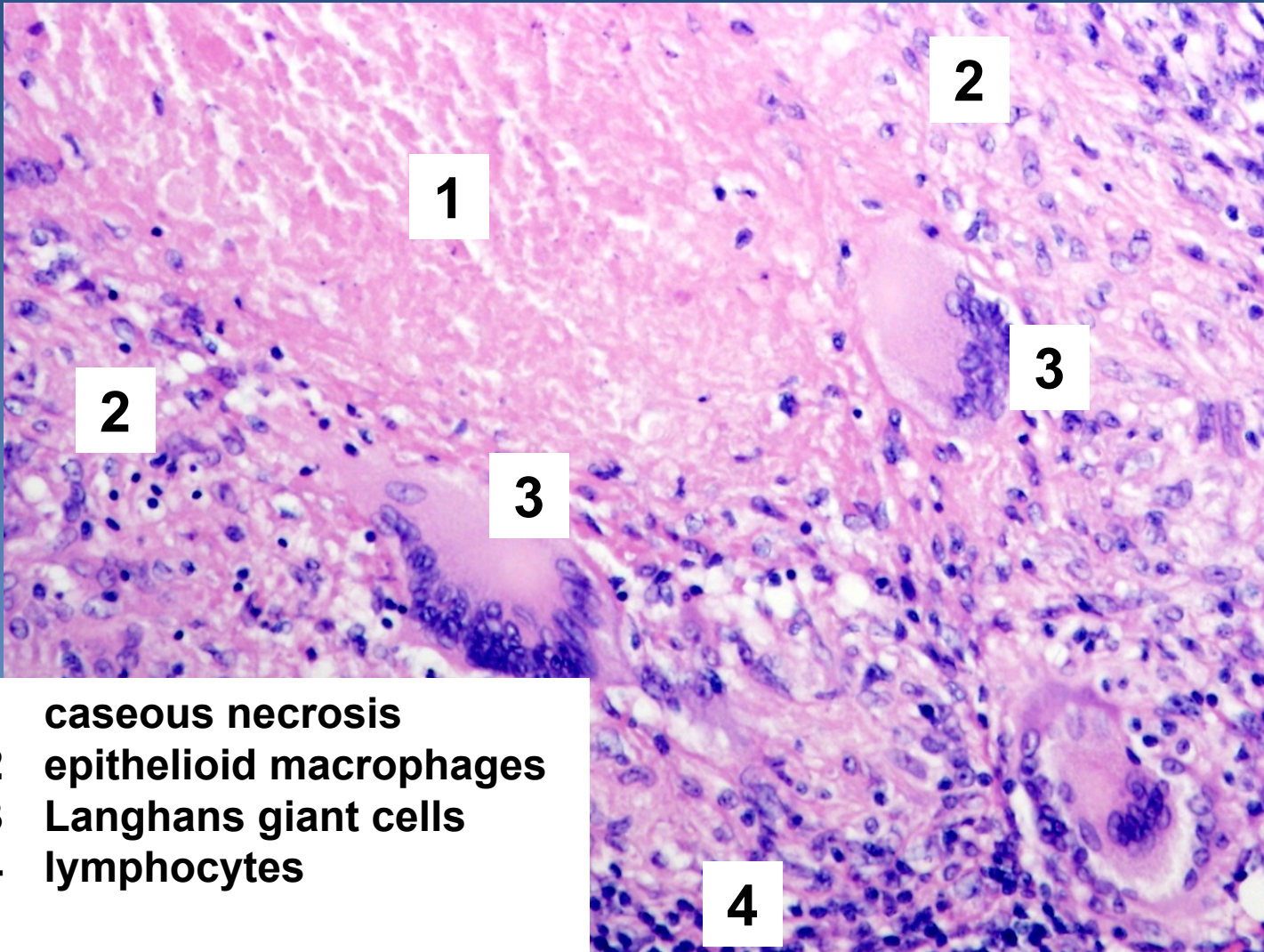
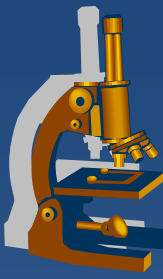
# Tuberculosis – morphological features



- × **tbc granuloma** – *proliferative form*
  - ⇒ *host resistance*
  - ⇒ *specific granulation tissue: epithelioid macrophages + Langhans giant cells*
  
- × **tbc exsudate** – *exsudative form (meningitis)*
  - ⇒ *allergy*
  - ⇒ *serofibrinous exsudate + Orth cells (macrophages)*
  
- + **caseification**
  - ⇒ *cheese-like, caseous necrosis – sensitization?*
  
- + **colliquation (liquefaction)**
  - ⇒ *after release of proteolytic enzymes by neutrophils*
  
- + **calcification**

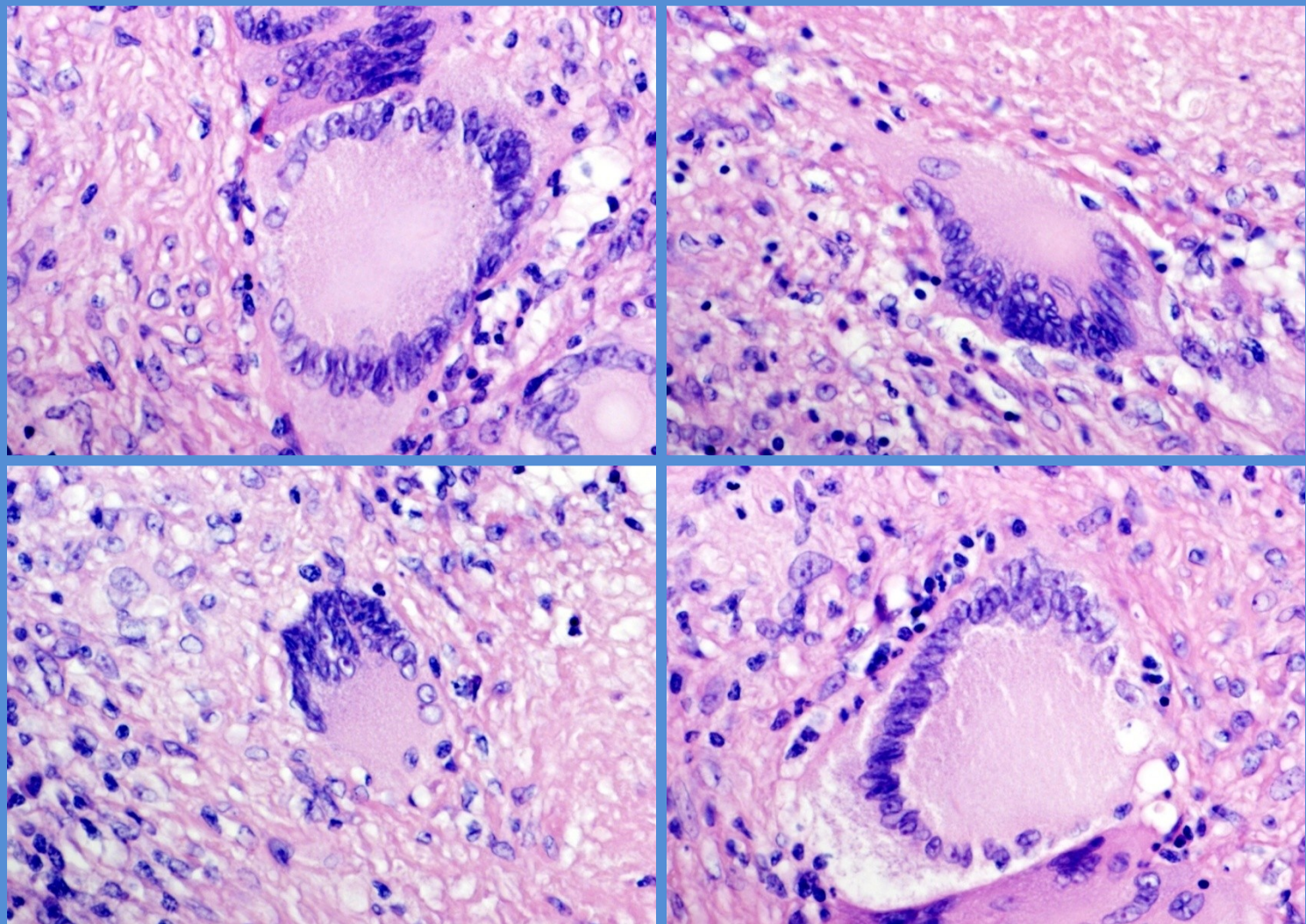
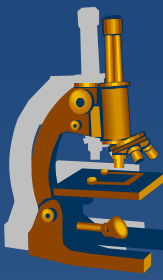


# *Tbc granuloma*

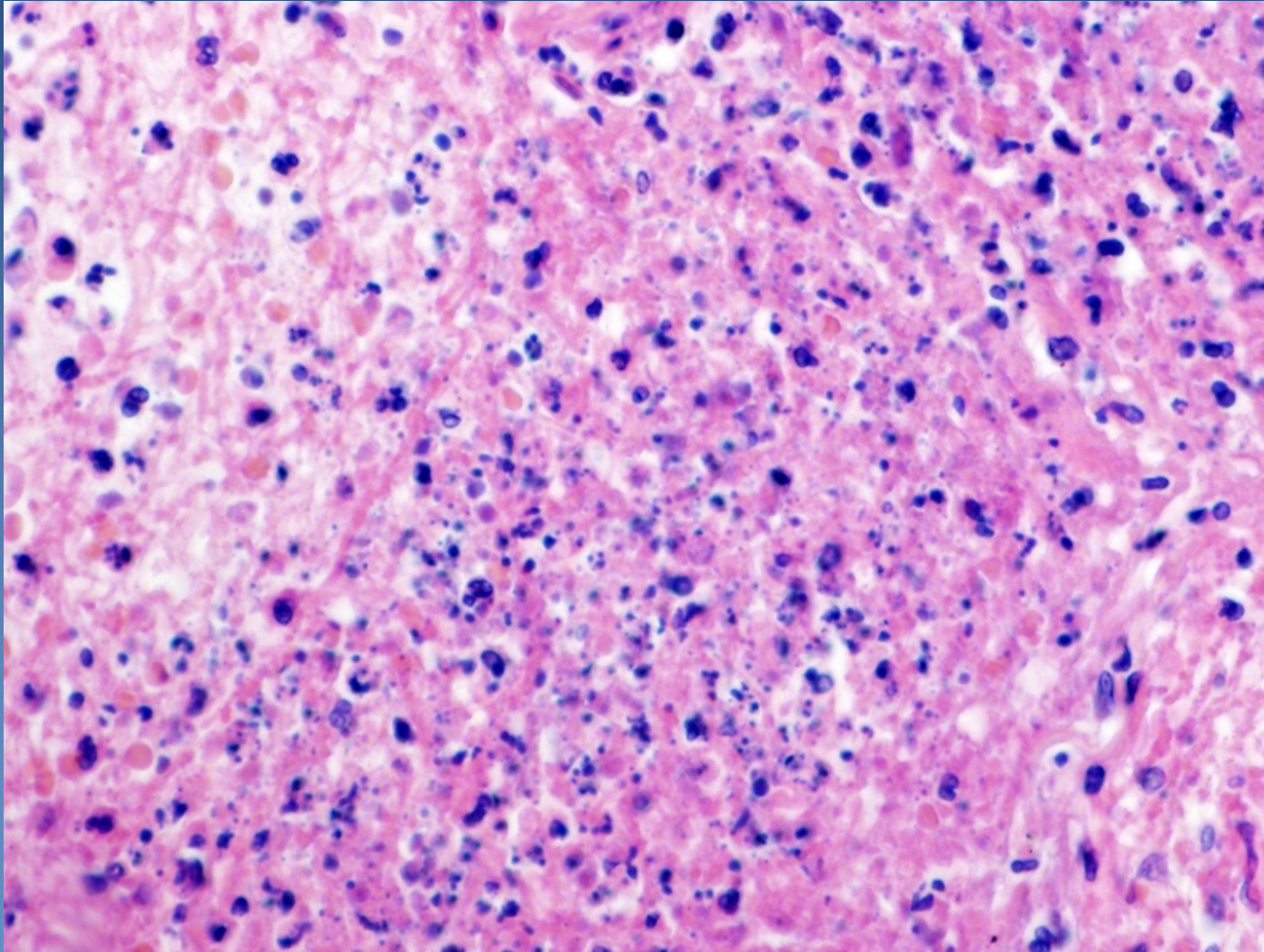
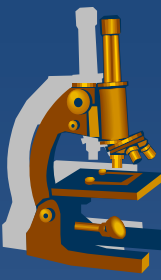


- 1 caseous necrosis
- 2 epithelioid macrophages
- 3 Langhans giant cells
- 4 lymphocytes

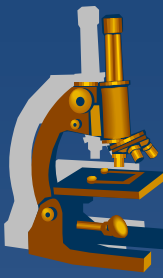
# *Langhans giant cells*



# *Caseous necrosis*

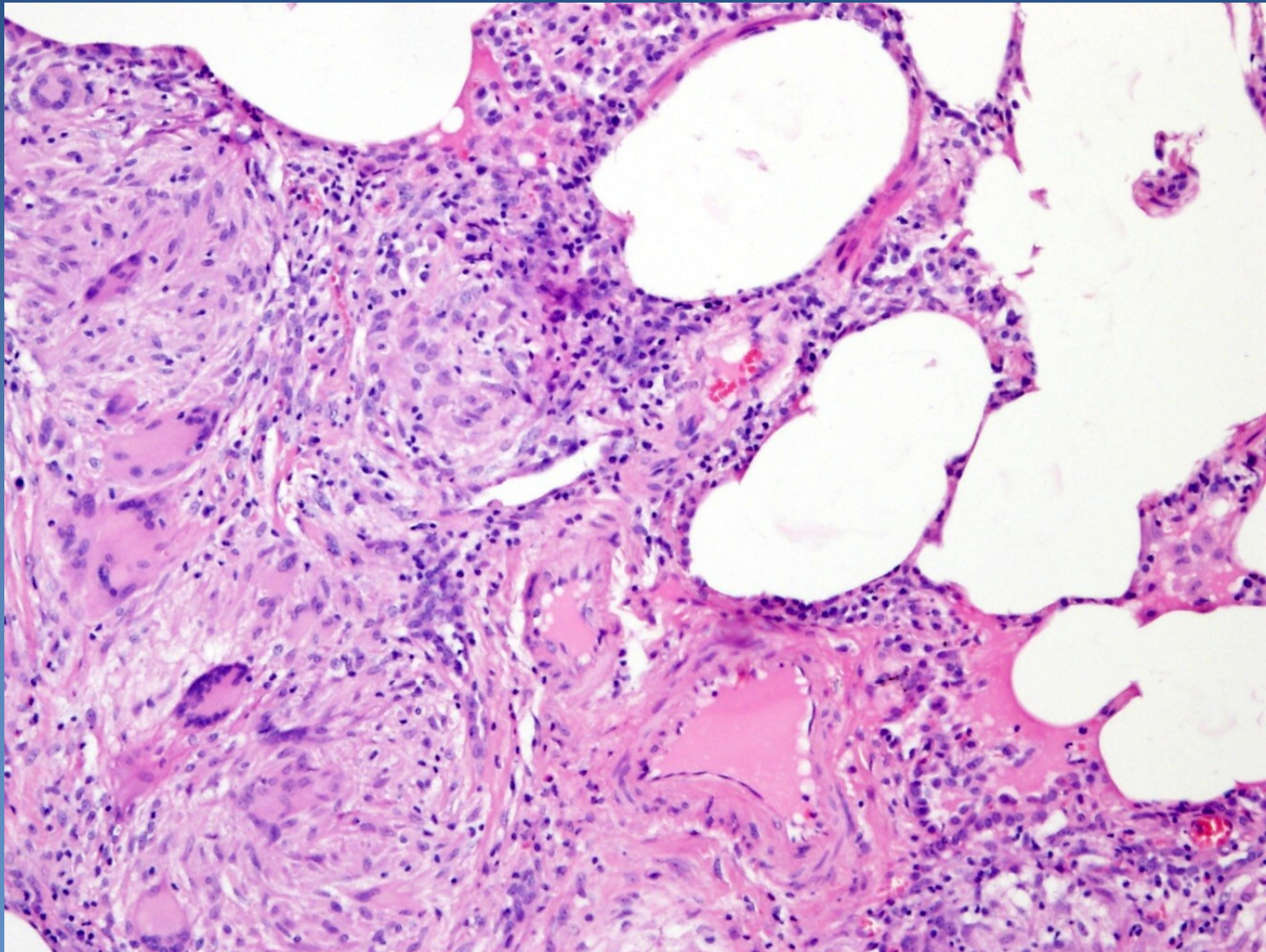
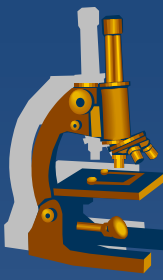


# Sarcoidosis



- ✗ chronic granulomatous inflammatory disease of unknown aetiology
  
- ✗ affected tissue:
  - ⇒ *mediastinal lymph nodes, lungs, skin, eye*
  - ⇒ *granulomas can affect any organ*
  
- ✗ small regular granulomas similar to TBC granulomas, but without caseous necrosis, fibrosis usually more pronounced
- ✗ cytoplasmic bodies of Langhans giant cells, not specific:
  - ⇒ *asteroid inclusions*
  - ⇒ *Schaumann bodies*
  
- ✗ dg. *per exclusionem* – necessary elimination of TBC, fungal infection etc.

# *Sarcoidosis*



# *Pulmonary chondrohamartoma*

---



- ✘ hamartoma? benign tumor?
- ✘ incidental X-ray finding
- ✘ differential diagnosis x malignant tumors important!

# *Pulmonary chondrohamartoma*



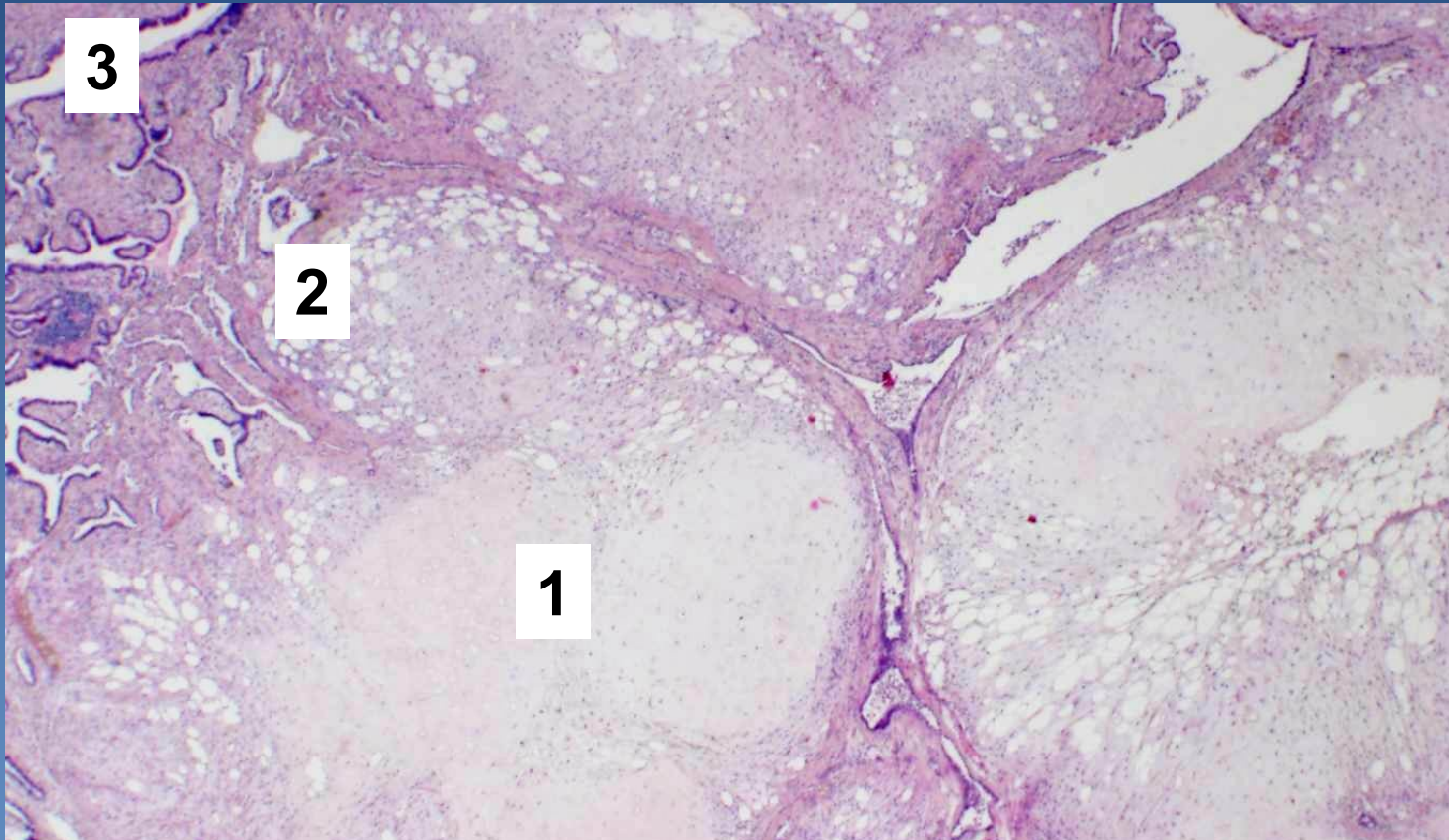
## *x Gross:*

- ⇒ whitish yellow*
- ⇒ well demarcated*
- ⇒ lobular structure*

## *x Generally formed of mixture of homologous non-organised afunctional tissues :*

- ⇒ cartilage*
- ⇒ connective tissue*
- ⇒ fat*
- ⇒ tubular structures with epithelium*

# *Pulmonary chondrohamartoma*



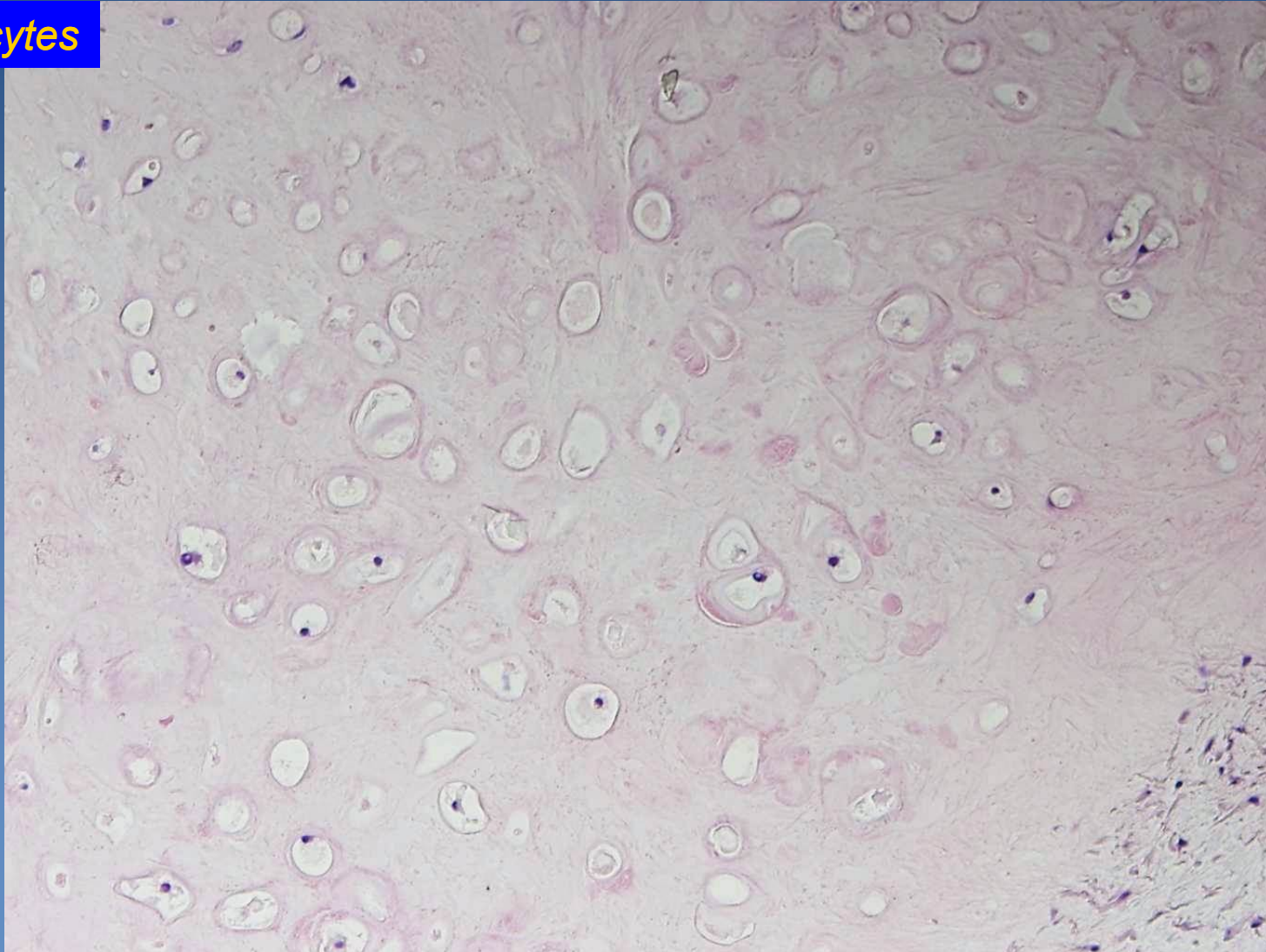
- 1. Cartilage*
- 2. Fat tissue*
- 3. Tubular structures with respiratory epithelium*



# *Pulmonary chondrohamartoma*



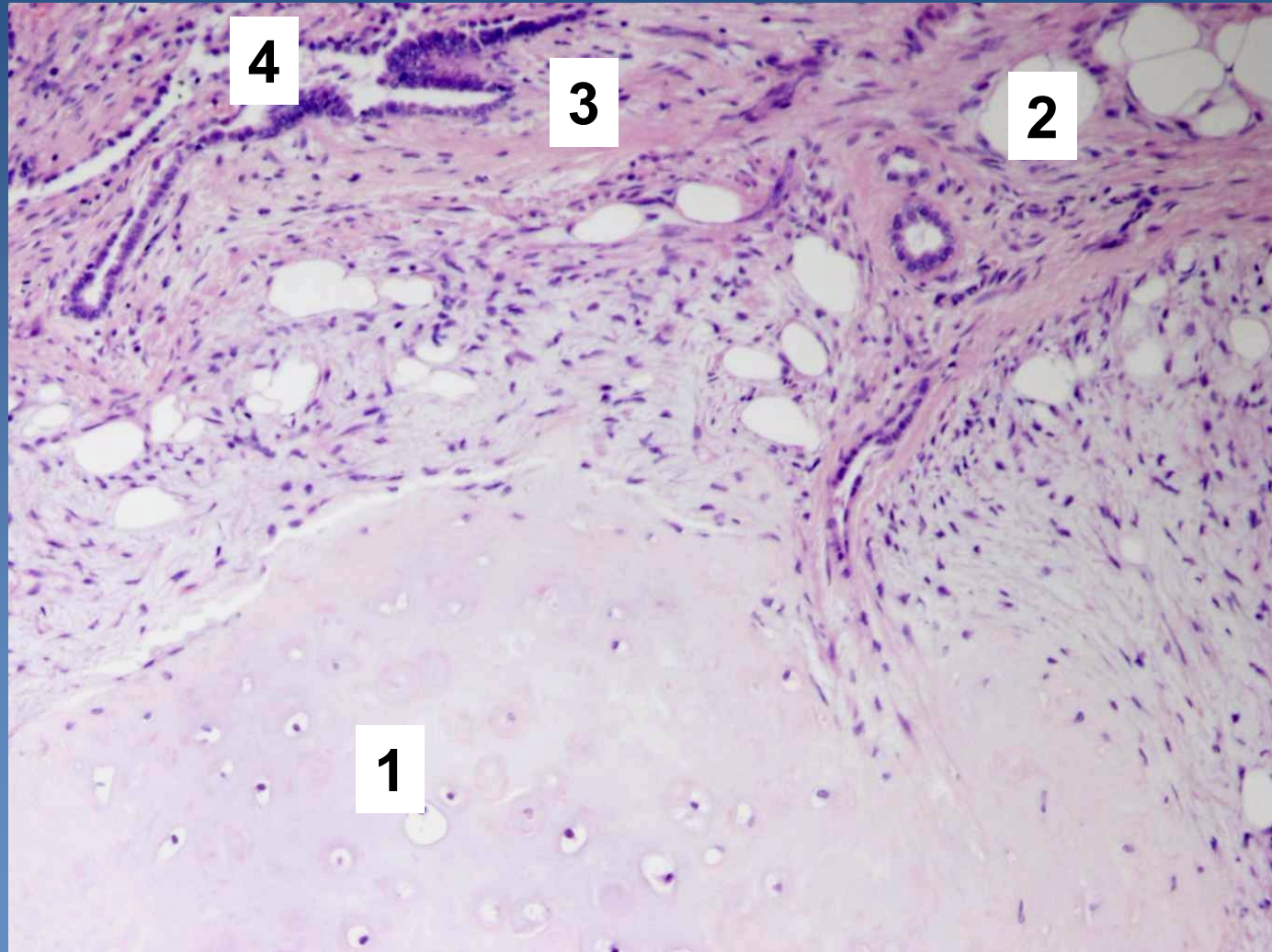
*Chondrocytes*



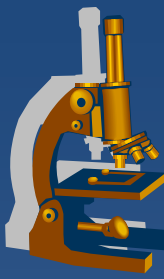
# *Pulmonary chondrohamartoma*



1. Cartilage
2. Fat tissue
3. Connective tissue
4. Tubular structures



# Bronchogenic carcinoma



## x incidence:

- ⇒ *in CZE males 100/100 000 (the most common malignancy of men),*
- ⇒ *females 25/100 000 (the 3rd most common malignancy of women, ↑ tendency)*

## x aetiology:

### ⇒ *smoking*

- generally 20X higher risk in smokers
- 20 cigarettes/day = 20 years, 40 cigarettes/day = 10 years...
- magic threshold 200000 cigarettes

### ⇒ *asbestos, Hg, Ni, As*

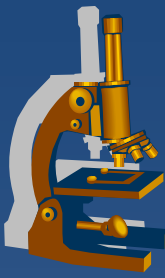
### ⇒ *ionization*

### ⇒ *radioactive radon*

### ⇒ *dust particles*

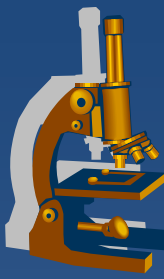
### ⇒ *familial predisposition*

# ***Bronchogenic carcinoma***



- x** Most common primary malignancy
- x** 5 year survival 5 – 7 %
- x** 4 – 7 decenium, more commonly males
- x** Clinical symptoms:
  - ⇒ *weight loss, chronic cough, haemoptysis, dyspnoea, chest pain, paraneoplastic syndromes (ACTH, ADH, PTH)*

# Bronchogenic carcinoma



## ✘ local complications:

⇒ *depends on the localization of the tumor:*

- lung collapse, bronchiectasis, bronchopneumonia, gangrene
- Jeros cavern
  - destruction of vascular wall by necrotic mass of tumor
  - fatal bleeding

⇒ *paraneoplastic syndromes*

- Aberrant production of peptide hormones (ACTH,ADH,PTH,..)

## ✘ clinical types:

⇒ *small cell lung carcinoma (SCLC)*

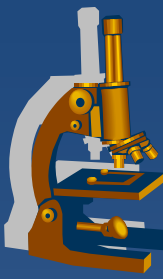
⇒ *non-small cell lung carcinoma (NSCLC)*

# *Small cell lung carcinoma*



- × undifferentiated (high grade) neuroendocrine tumor
- × 20 % of all bronchogenic carcinomas
- × associated with **smoking**
- × localized in **lung hilus**
- × early metastatic spread, widespread dissemination
  - ⇒ *lymphatic and hematogenous (LN, liver, brain, bones, kidney, adrenals, ...)*

# Small-cell lung carcinoma



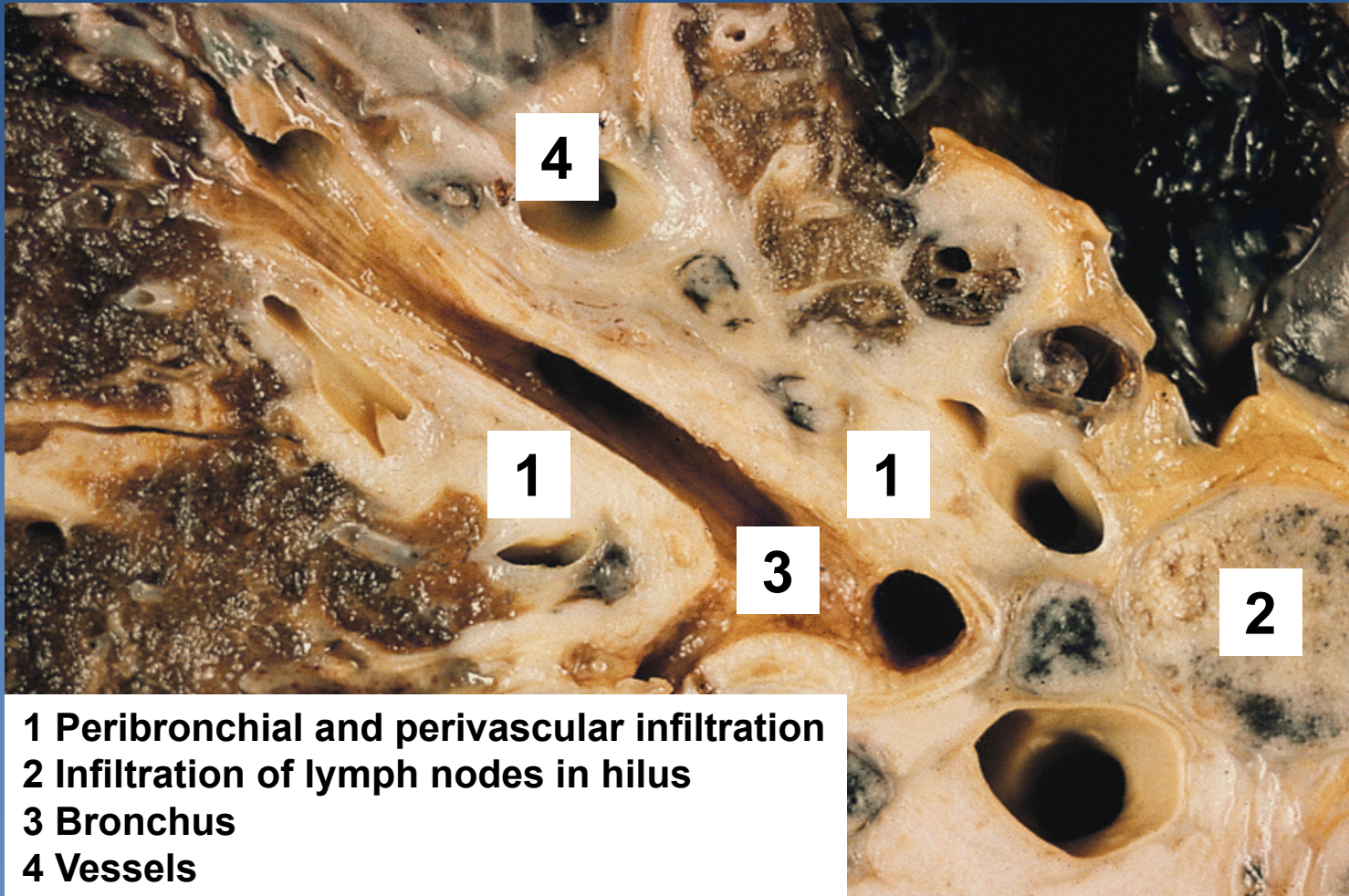
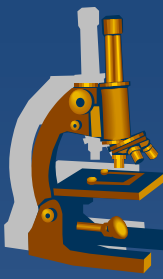
## × histologic types:

- ⇒ *small cell („oat cell carcinoma“)*
- ⇒ *intermediate (now included into small cell type)*
- ⇒ *combined*

## × Micro:

- ⇒ *small cells with scant cytoplasm (size < 3 lymphocytes)*
- ⇒ *small round - elongated dark blue nuclei without obvious nucleoli (oat cell carcinoma)*
- ⇒ *solid growth*
- ⇒ *neurosecretory granules in cytoplasm*
  - chromogranin, synaptophysin

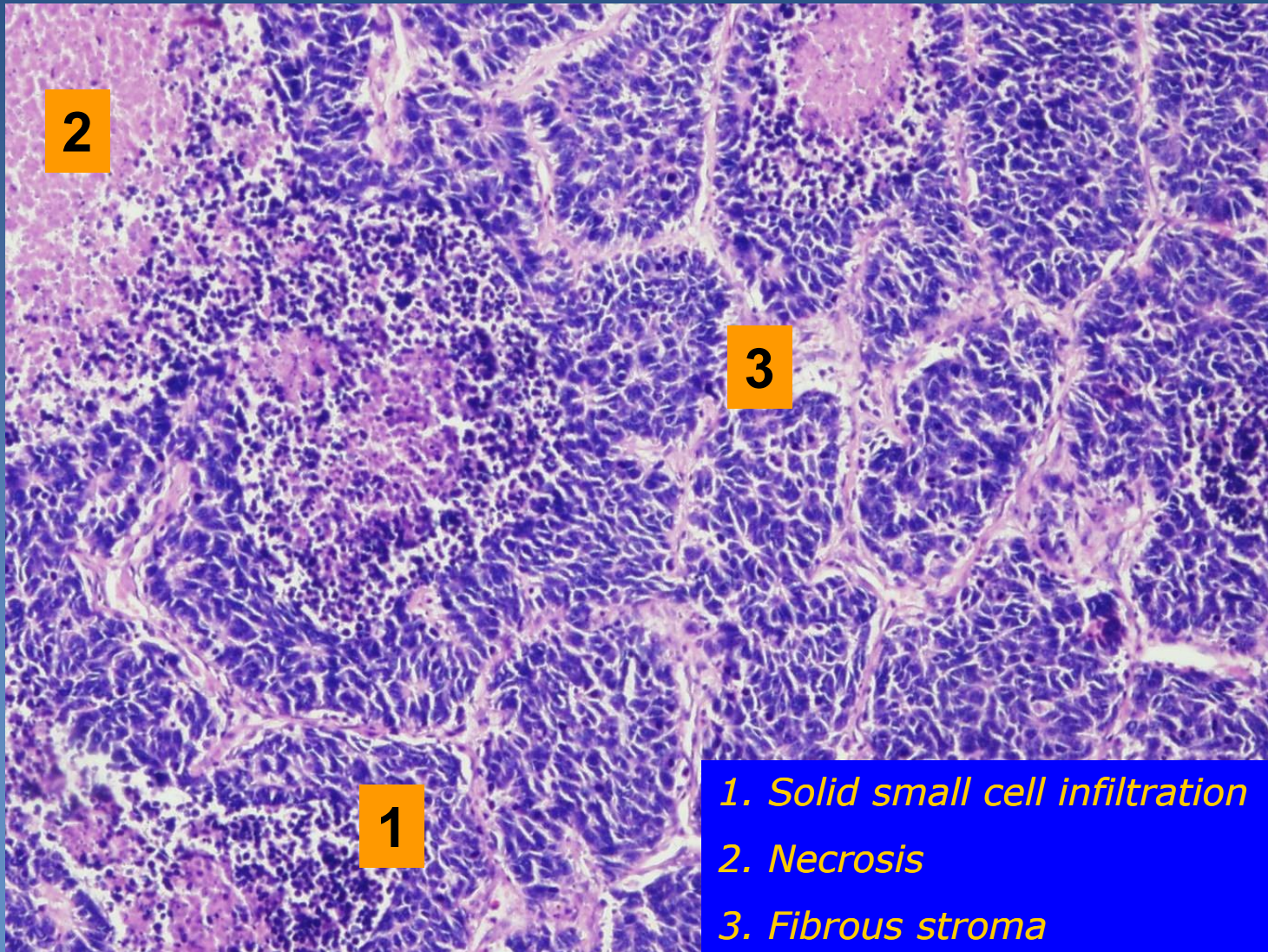
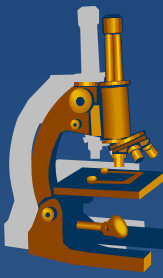
# *Small-cell lung carcinoma*



- 1 Peribronchial and perivascular infiltration**
- 2 Infiltration of lymph nodes in hilus**
- 3 Bronchus**
- 4 Vessels**

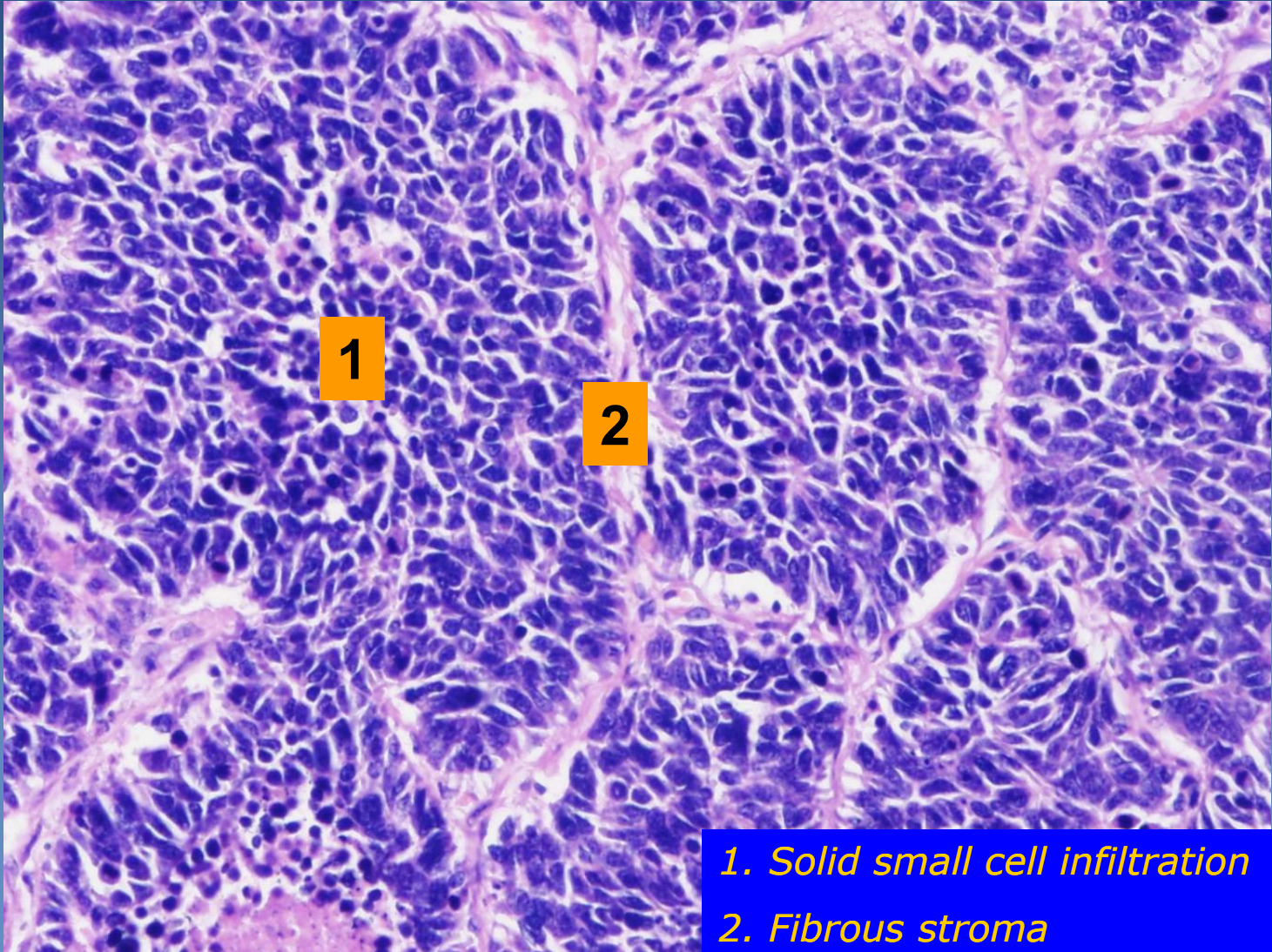
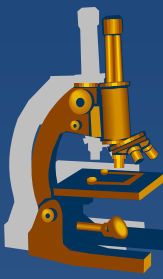


# *Small-cell lung carcinoma*



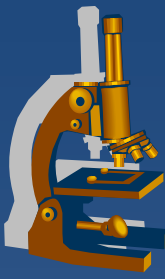
- 1. Solid small cell infiltration*
- 2. Necrosis*
- 3. Fibrous stroma*

# *Small-cell lung carcinoma*



- 1. Solid small cell infiltration*
- 2. Fibrous stroma*

# Non-small cell lung carcinoma



× squamous cell carcinoma

× adenocarcinoma

⇒ *adenocarcinoma in situ*

⇒ *minimally invasive:*

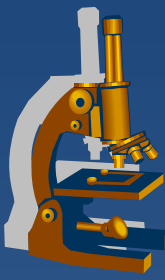
- non-mucinous
- mucinous
- mixed

⇒ *invasive:*

- lepidic
- acinar
- papillary
- micropapillary
- solid

× large cell lung carcinoma

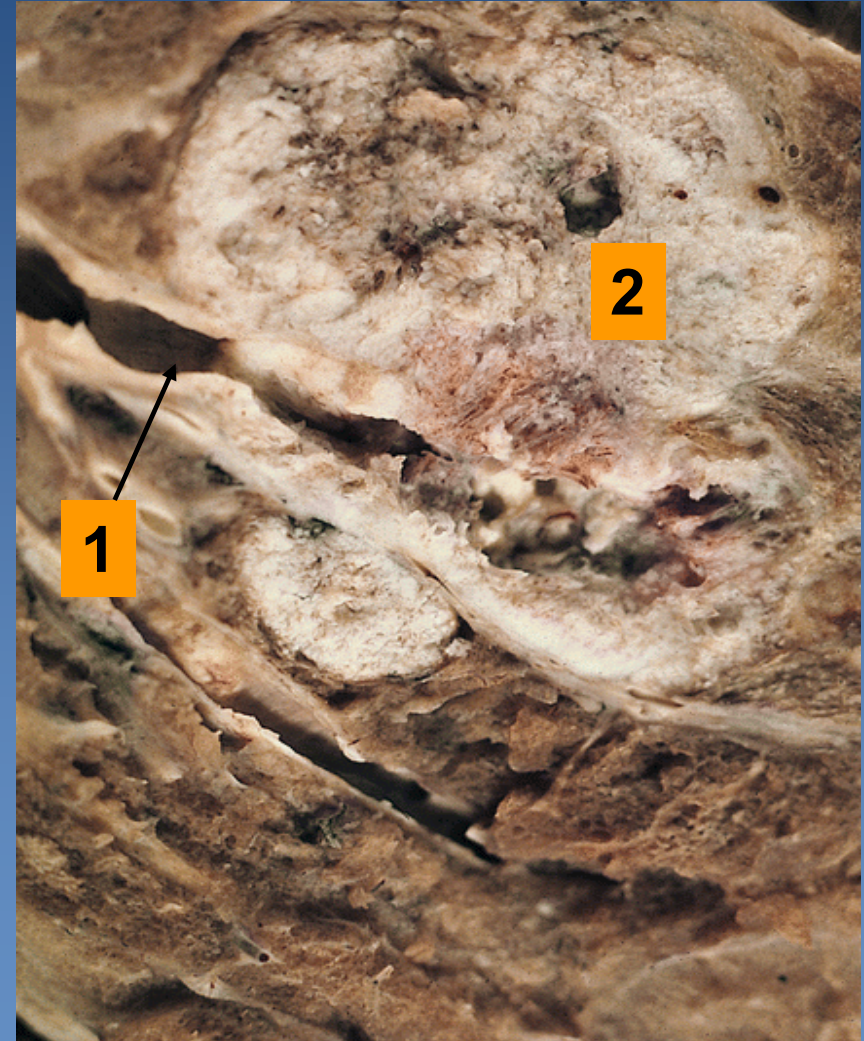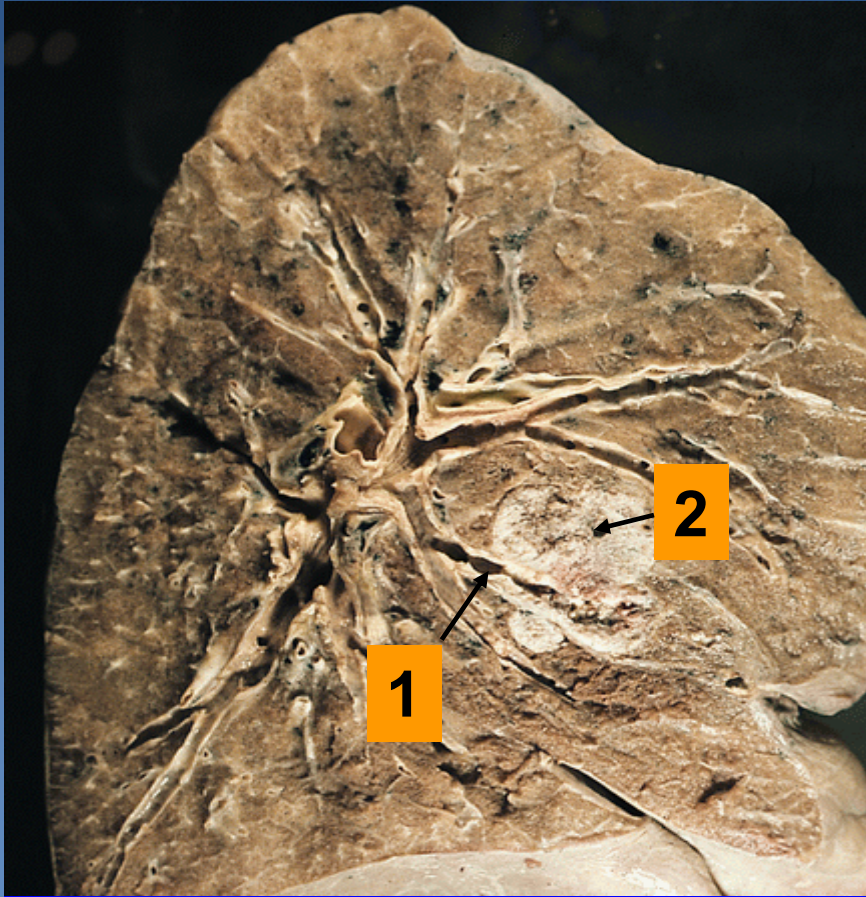
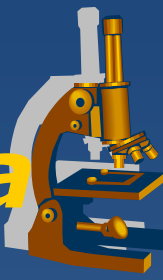× other, incl. mixed



# *Squamous cell carcinoma*

- ✗ male 40%, female 20%
- ✗ strongly associated with smoking
- ✗ typical perihilar localisation (central > peripheral)
- ✗ commonly slow progression from squamous metaplasia – dysplasia – ca in situ
  - ⇒ *late metastases*
- ✗ Micro:
  - ⇒ *squamous cell carcinoma of common type*
    - polygonal shaped cells in solid nests, keratin pearls, cell junctions
  - ⇒ *variable differentiation*

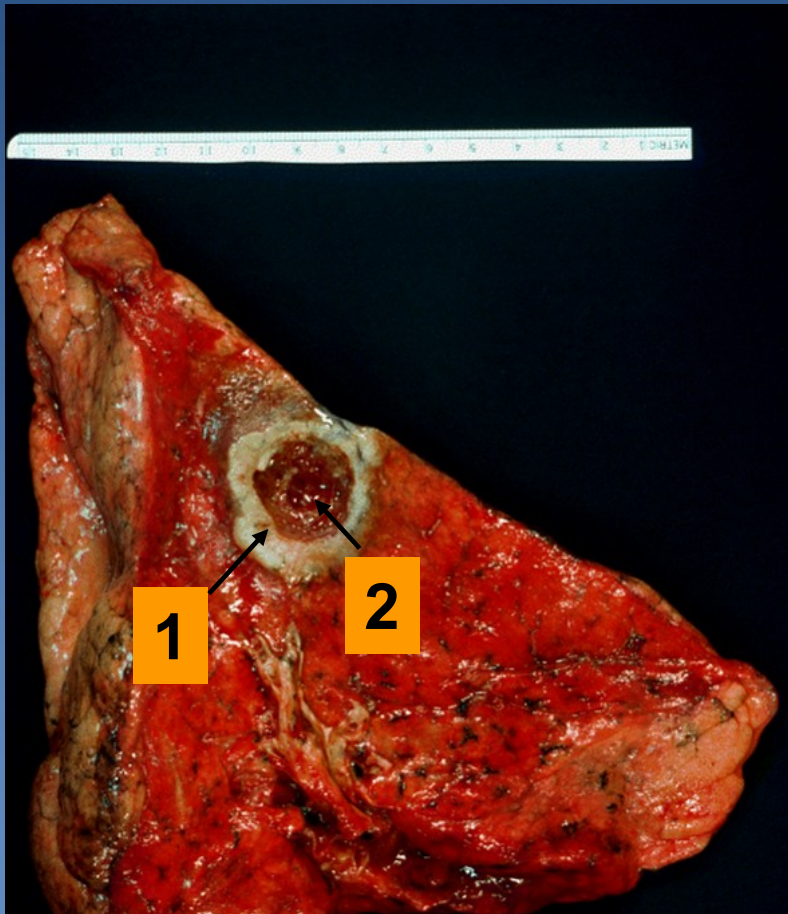
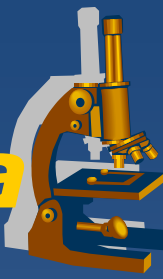# Squamous-cell lung carcinoma



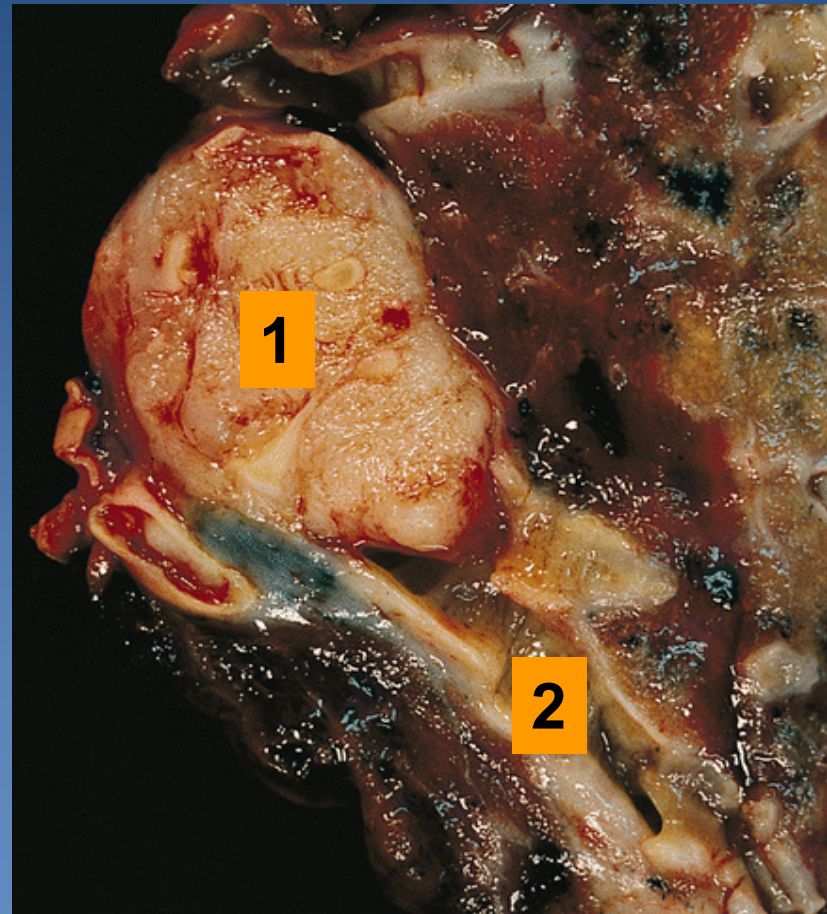
1. Segmental bronchus

2. Tumor

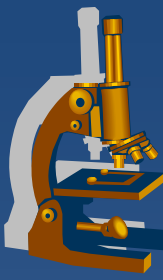
# Squamous cell lung carcinoma



1. Tumor localized in the periphery
2. Central necrosis

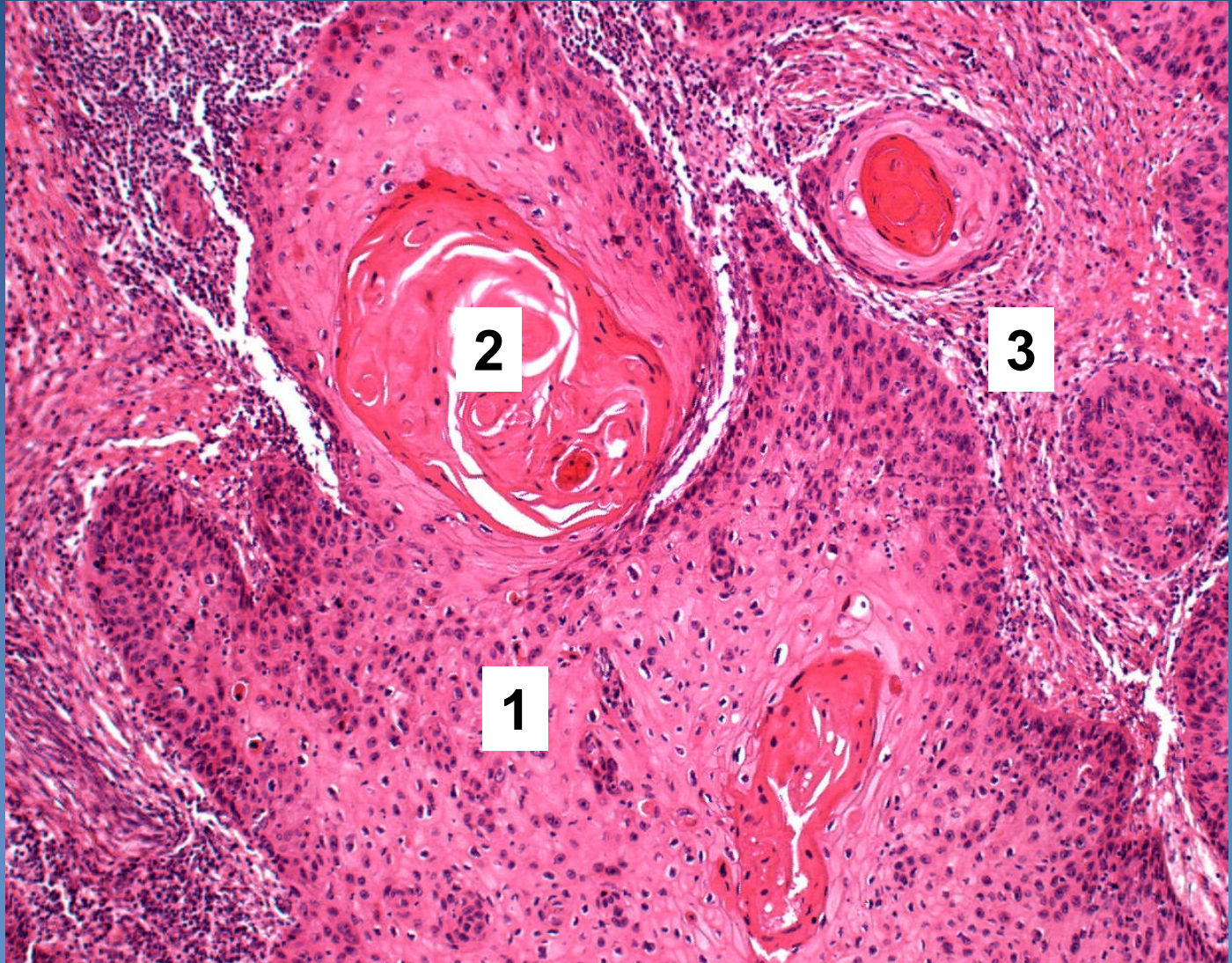


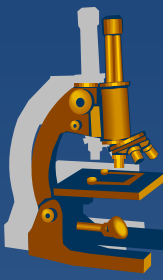
1. Tumor in bronchus
2. Segmental bronchus



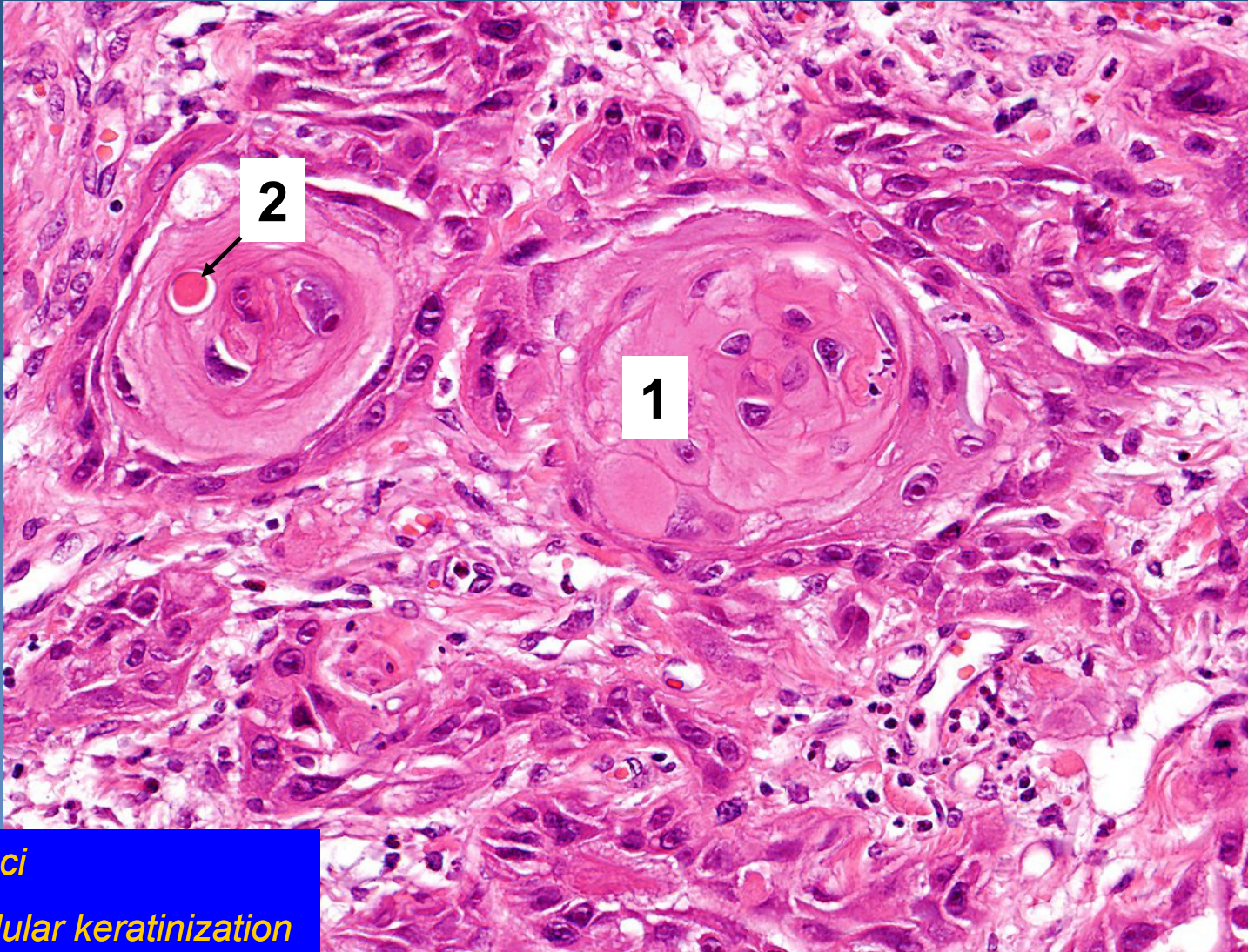
# *Squamous cell carcinoma*

1. *Solid nests of malignant keratinocytes*
2. *Keratin pearls*
3. *Stroma of the tumor*



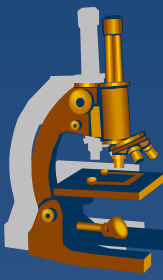


# *Squamous cell carcinoma*



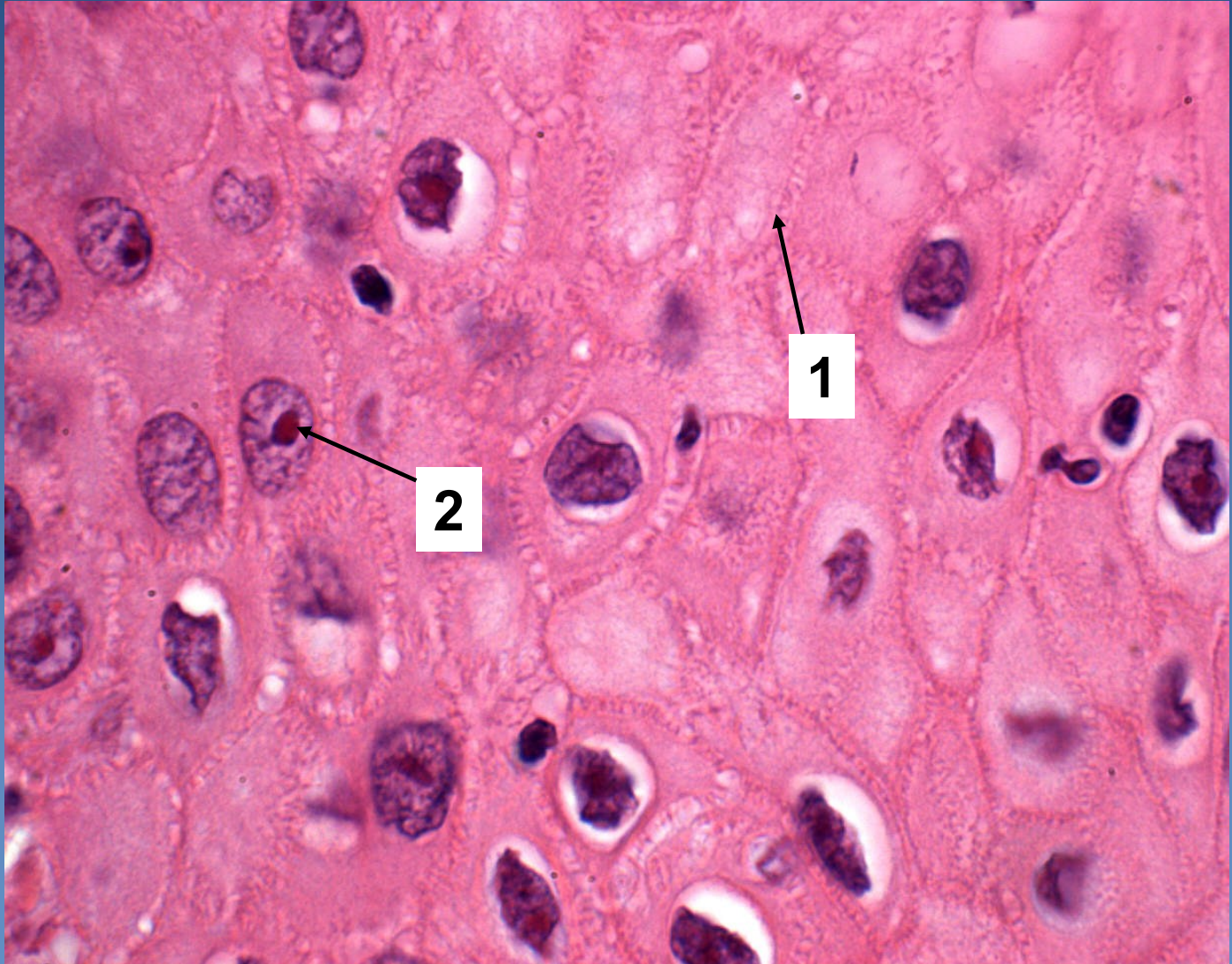
- 1. *Tumor foci*
- 2. *Monocellular keratinization*



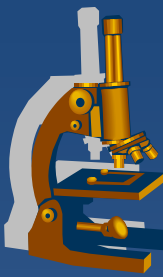


# *Squamous-cell carcinoma*

1. *Cell junctions*
2. *Nucleus with prominent nucleoli*

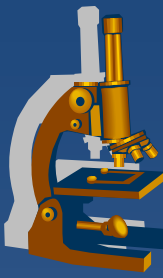


# Adenocarcinoma



- ✗ male 20%, female 40%;
- ✗ most cases in smokers, but the most common type in non-smokers
- ✗ typically localized in the periphery, subpleural
  - ⇒ *late symptoms !!!*      *Commonly accidental finding on X-ray/CT*
- ✗ formerly used term:
  - ⇒ *bronchioloalveolar adenocarcinoma (BAC) no more in use (but still present in WHO classification of lung tumors)*

# Adenocarcinoma



## × classification:

### ⇒ *Adenocarcinoma in situ - AIS (size $\leq 3$ cm):*

- non/mucinous (earlier BAC),
- mucinous
- mixed
- no stromal/vascular/pleural invasion present

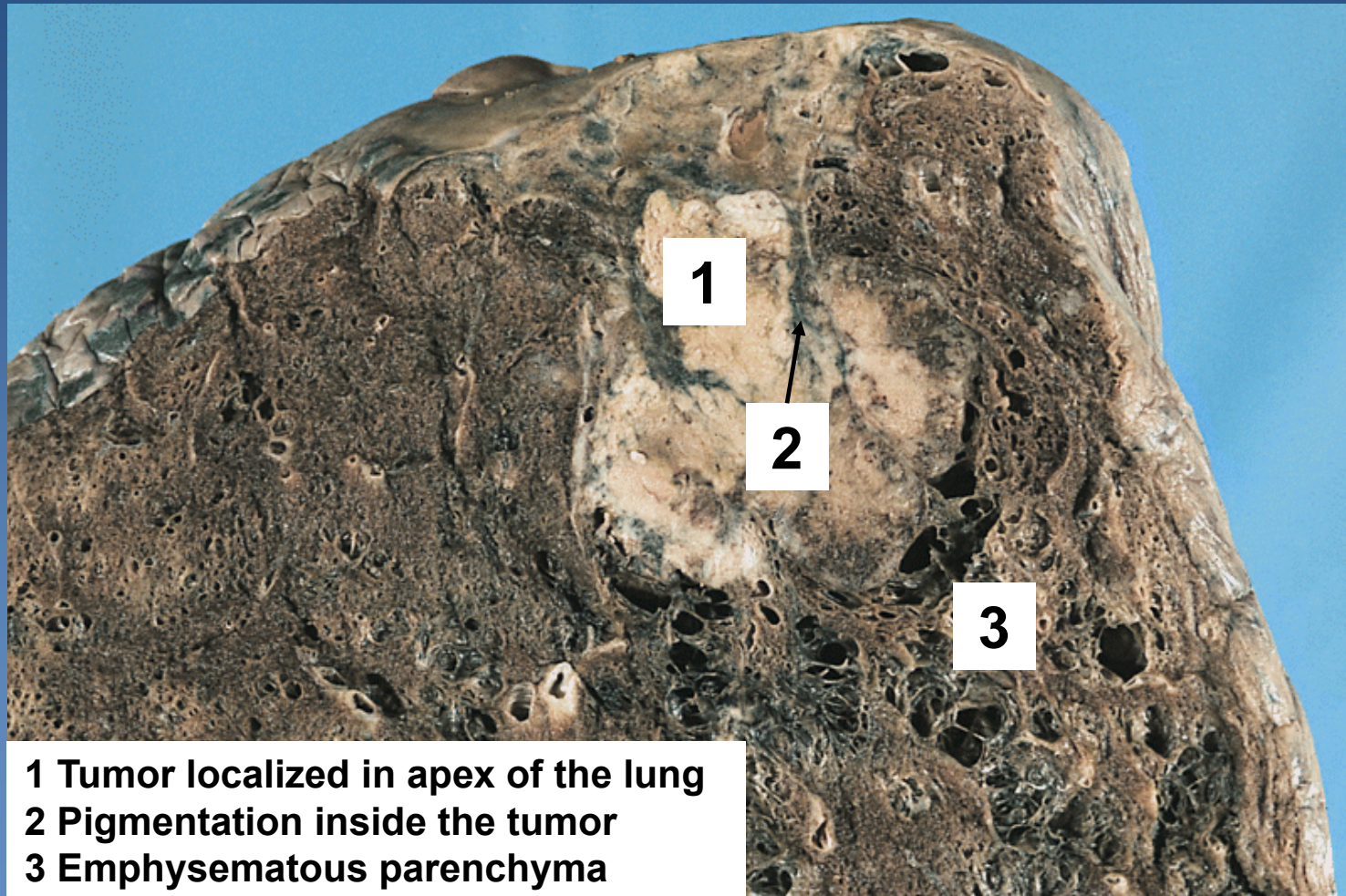
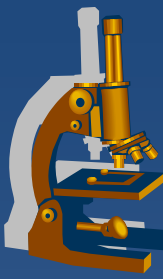
### ⇒ *Minimally invasive ACA (size $\leq 3$ cm and $\leq 5$ mm invasion): idem*

- apart of lepidic growth other types of spread (papillary, solid....) or stromal invasion present
- no vascular/pleural invasion present

### ⇒ *Invasive ACA:*

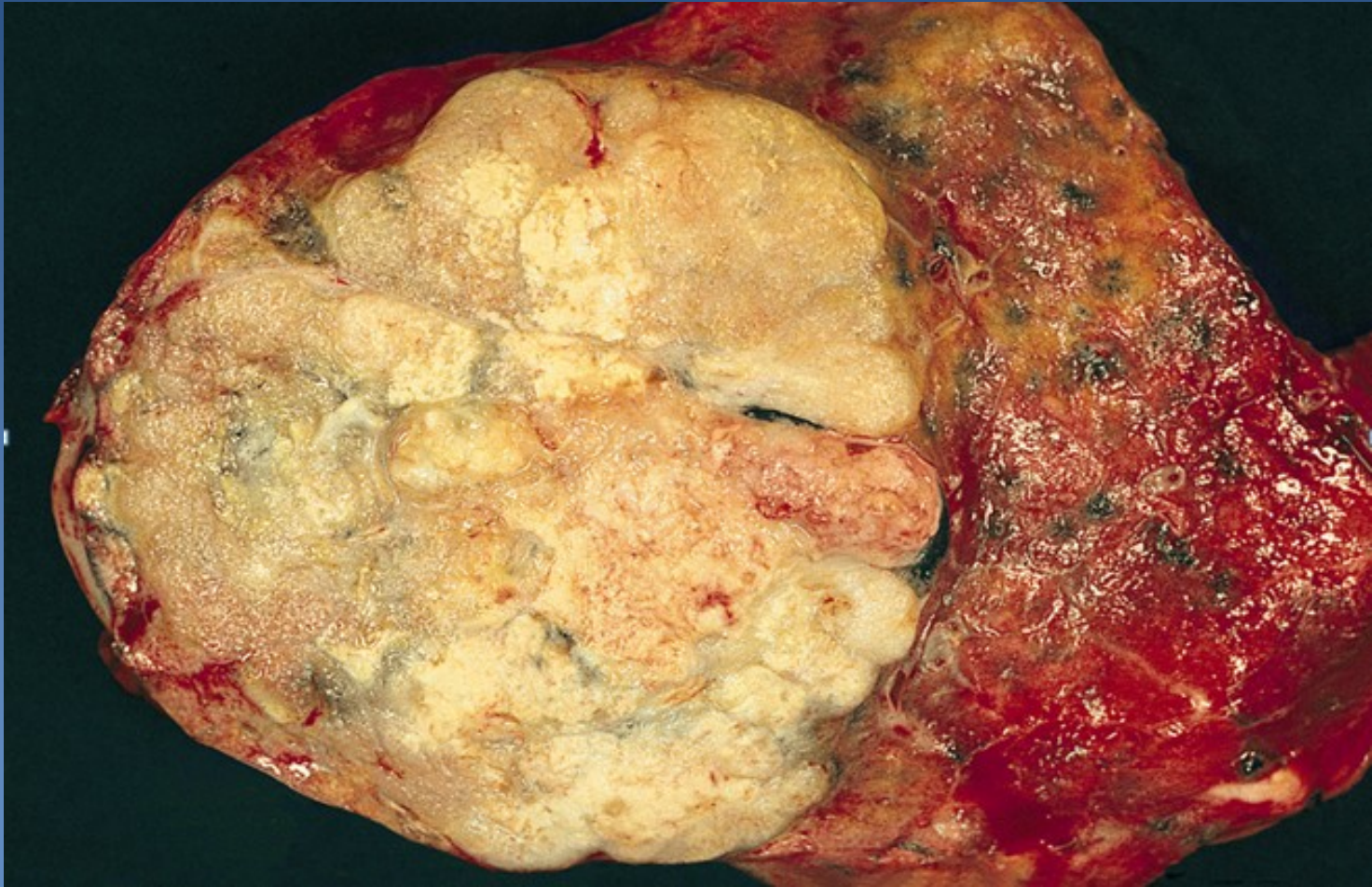
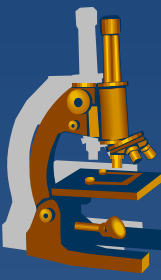
- Lepidic
- Acinar
- Papillary
- Micropapillary
- Solid

# Adenocarcinoma

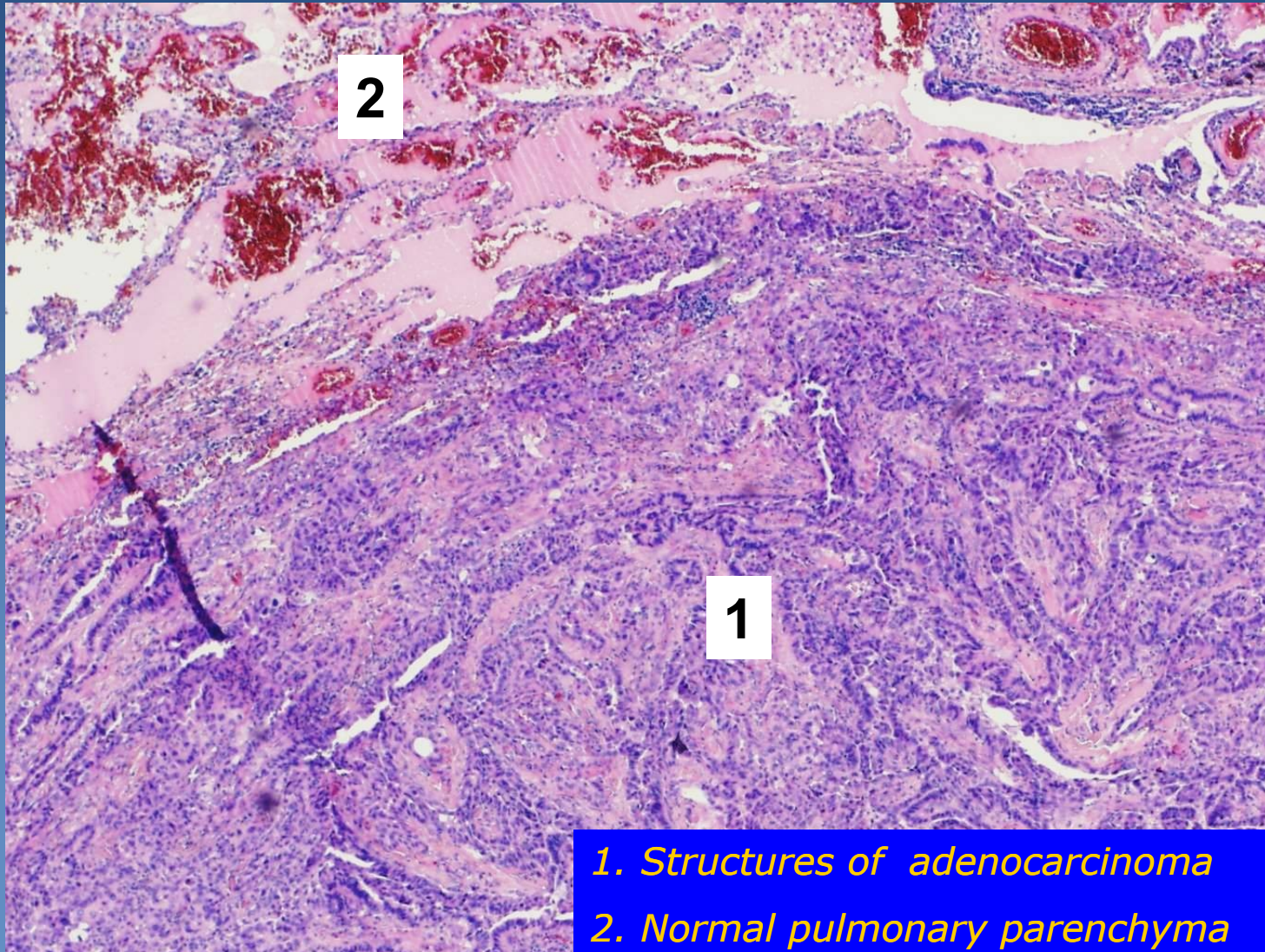
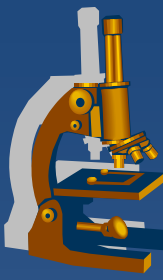


- 1 Tumor localized in apex of the lung
- 2 Pigmentation inside the tumor
- 3 Emphysematous parenchyma

# *Adenocarcinoma*

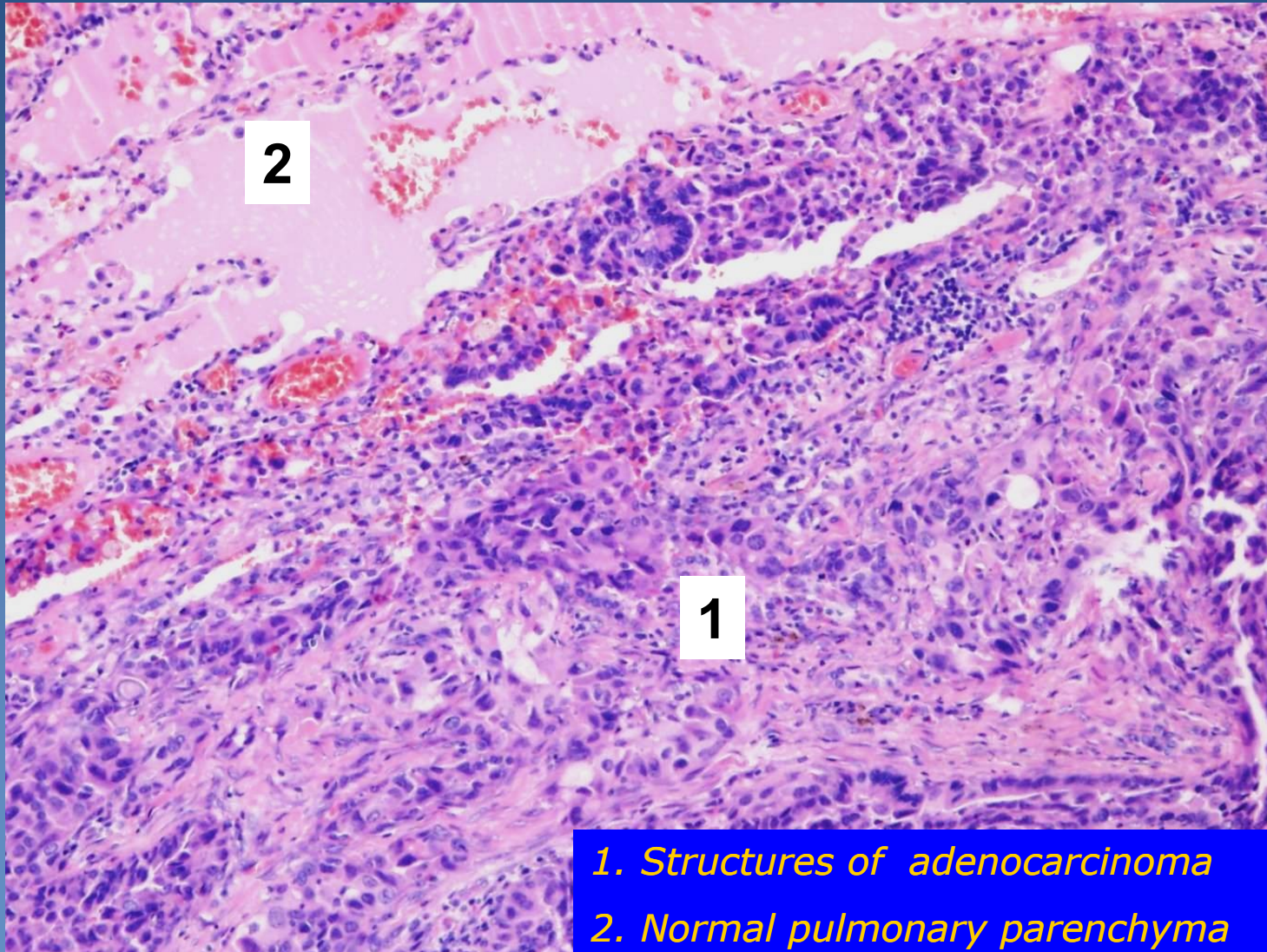
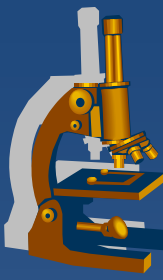


# Adenocarcinoma



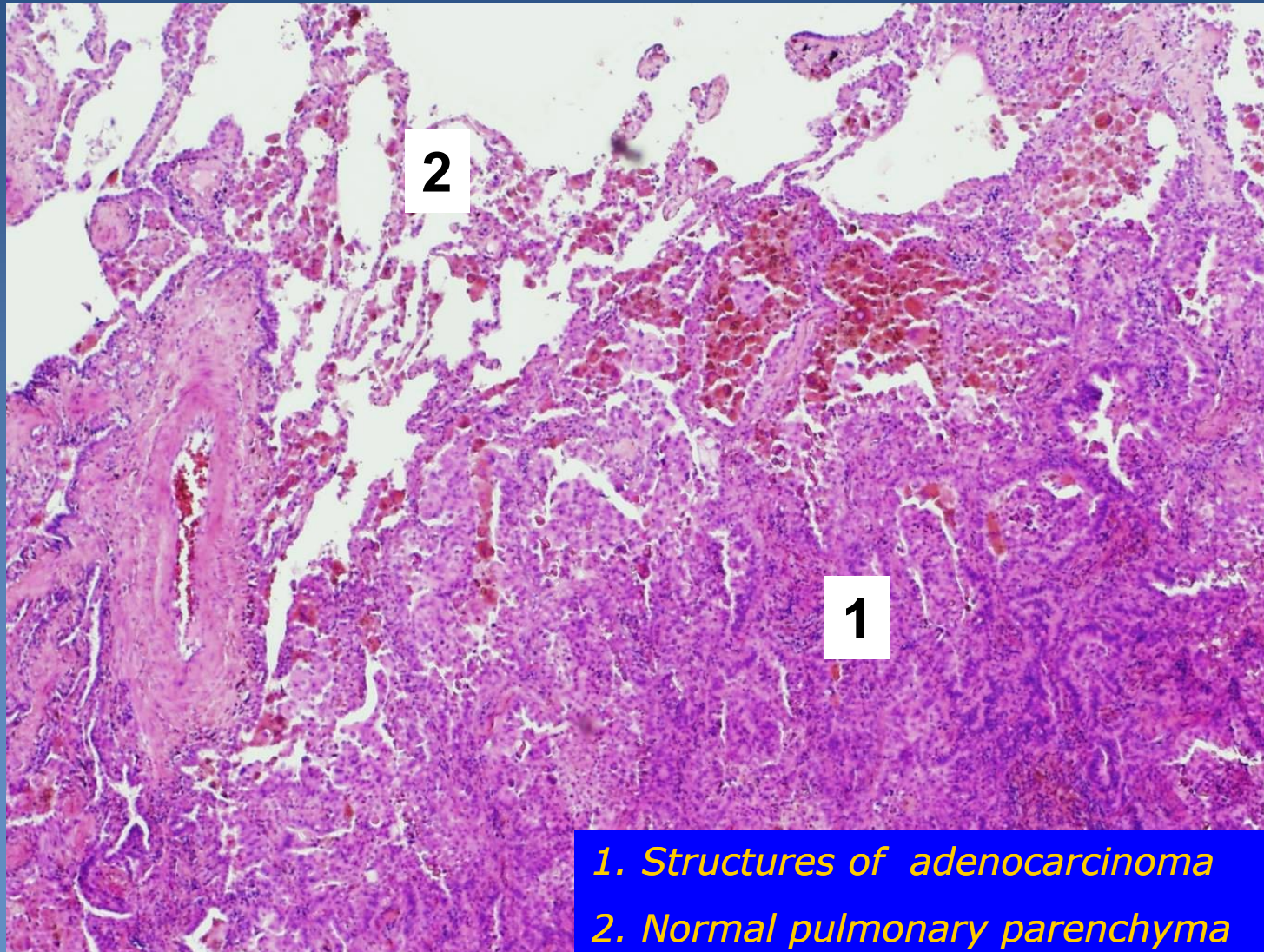
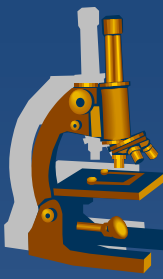
1. Structures of adenocarcinoma
2. Normal pulmonary parenchyma

# Adenocarcinoma



1. Structures of adenocarcinoma  
2. Normal pulmonary parenchyma

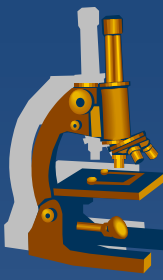
# Adenocarcinoma



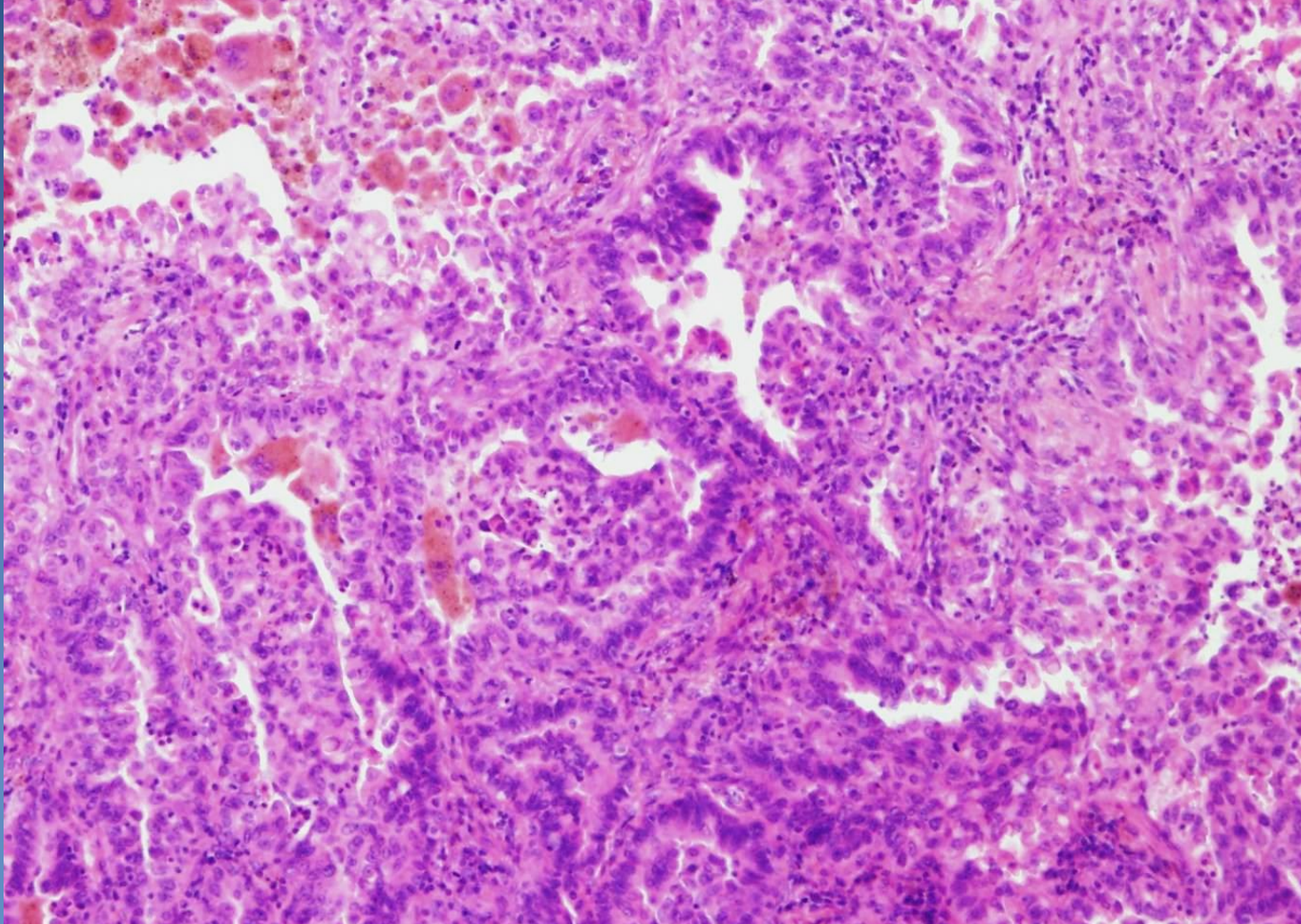
1. Structures of adenocarcinoma
2. Normal pulmonary parenchyma



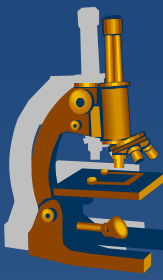
# Adenocarcinoma



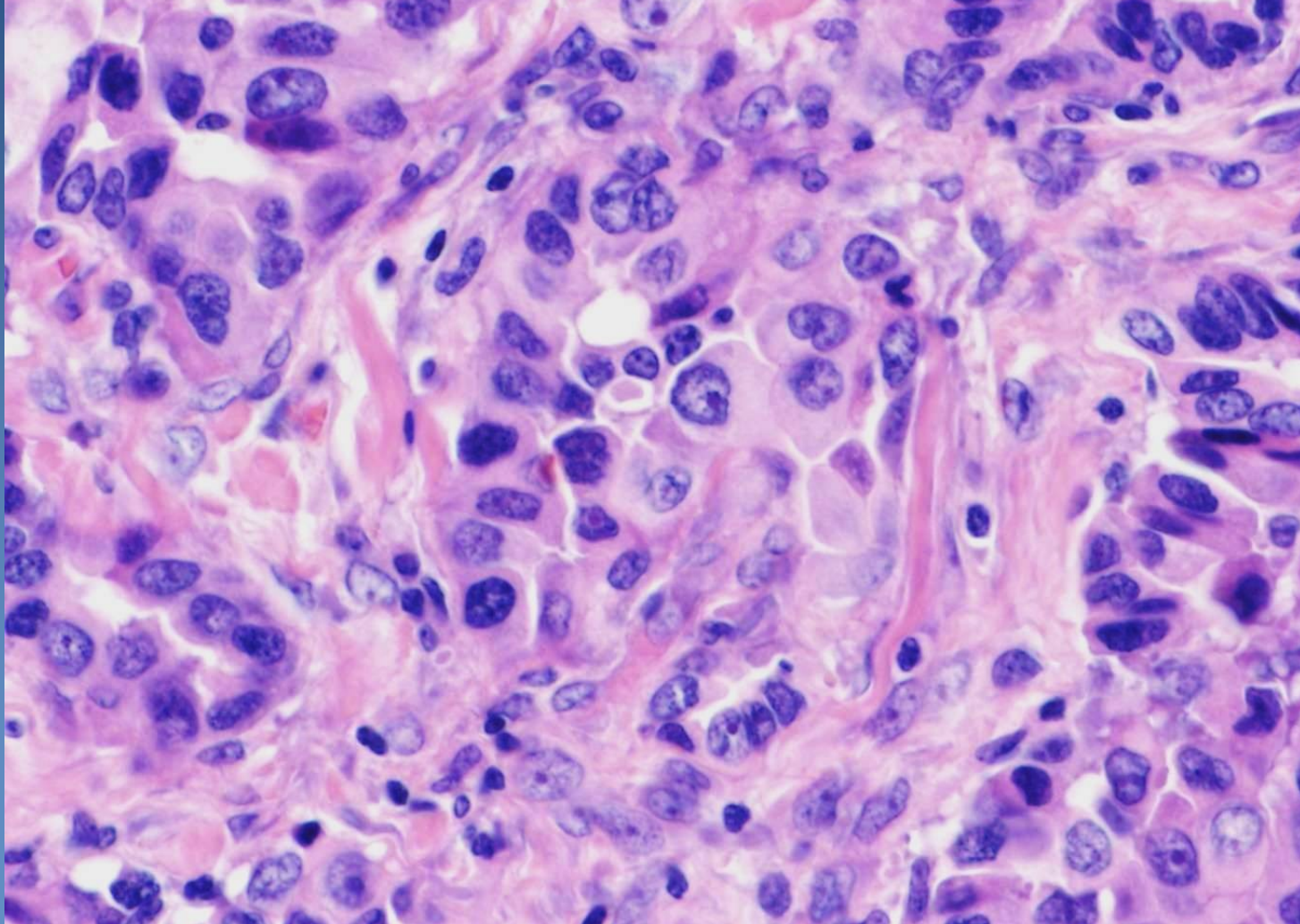
*Structures of an acinary and papillary formed adenocarcinoma*



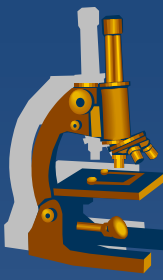
# Adenocarcinoma



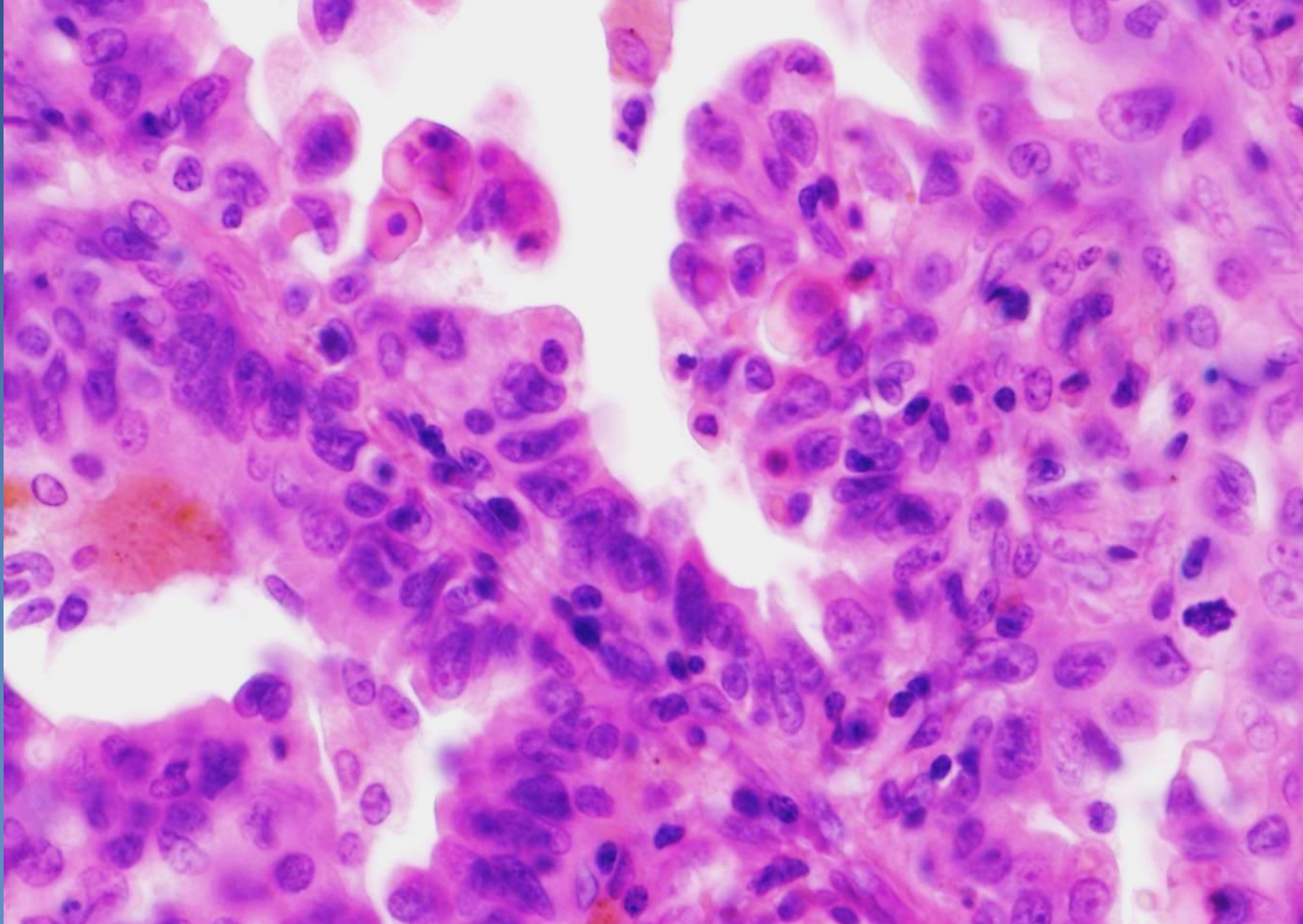
*Cytology of malignant cells - anisocytosis and anisokaryosis*

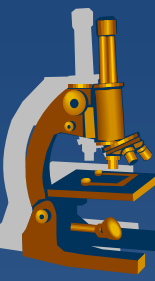


# Adenocarcinoma

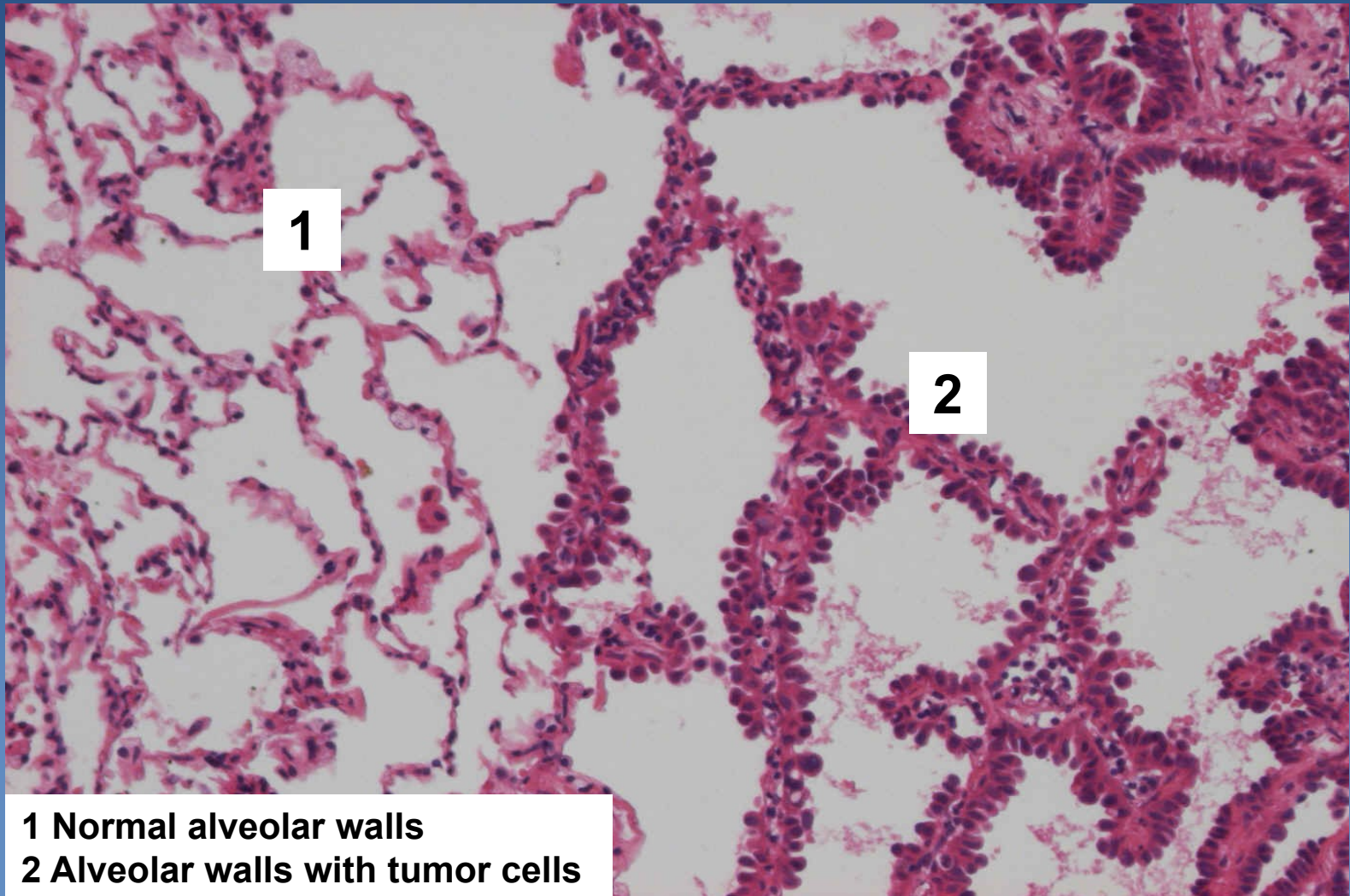


*Cytology of malignant cells - anisocytosis and anisokaryosis*





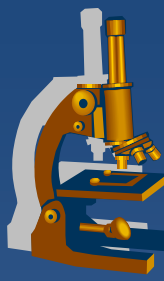
# ***AIS/minimally invasive ACA non/mucinous (earlier BAC)***



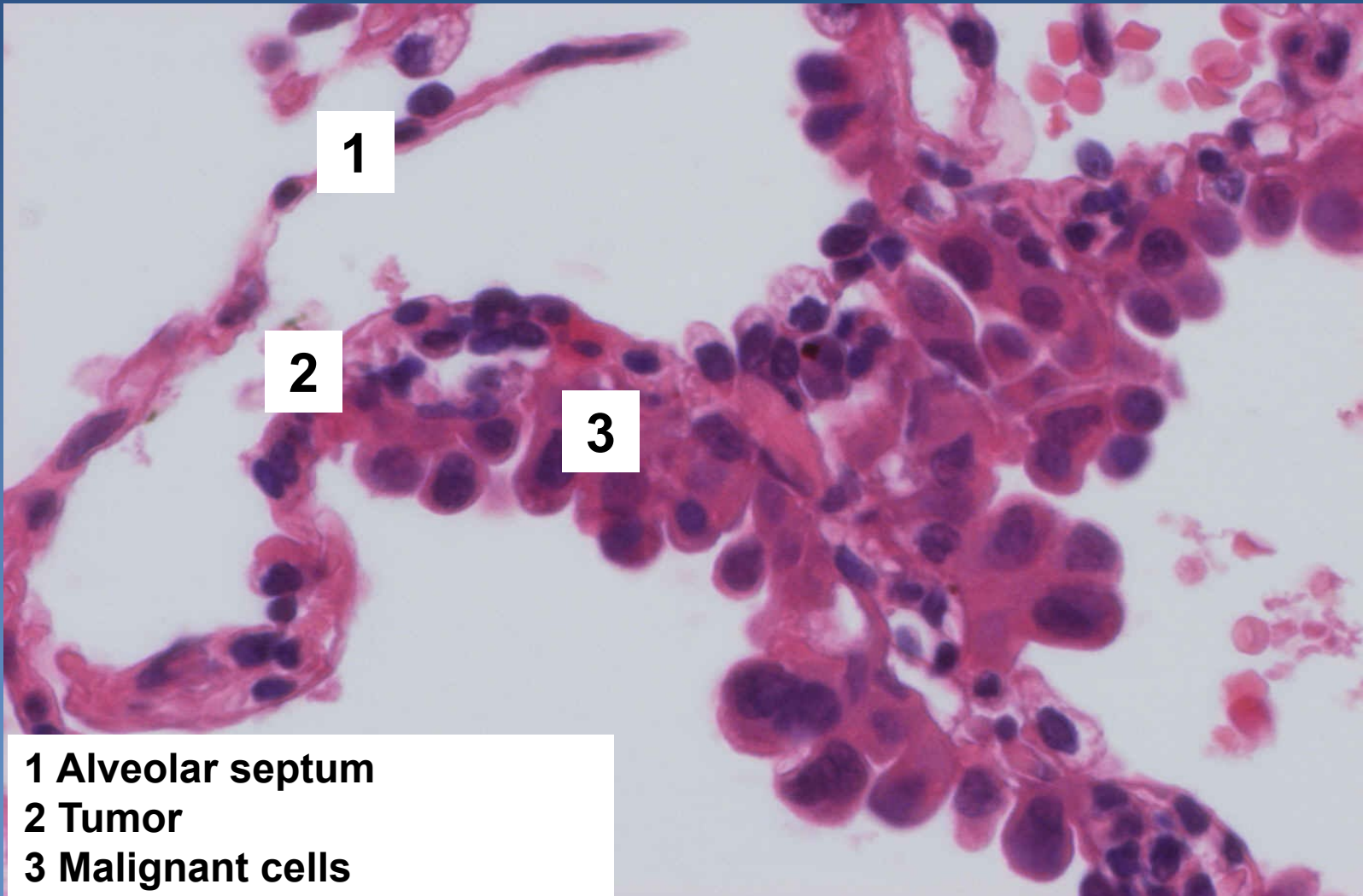
**1**

**2**

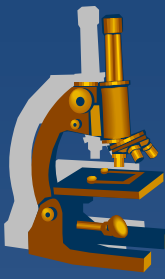
**1 Normal alveolar walls  
2 Alveolar walls with tumor cells**



# ***AIS/minimally invasive ACA non/mucinous (earlier BAC)***



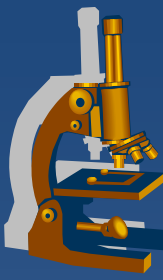
- 1 Alveolar septum
- 2 Tumor
- 3 Malignant cells



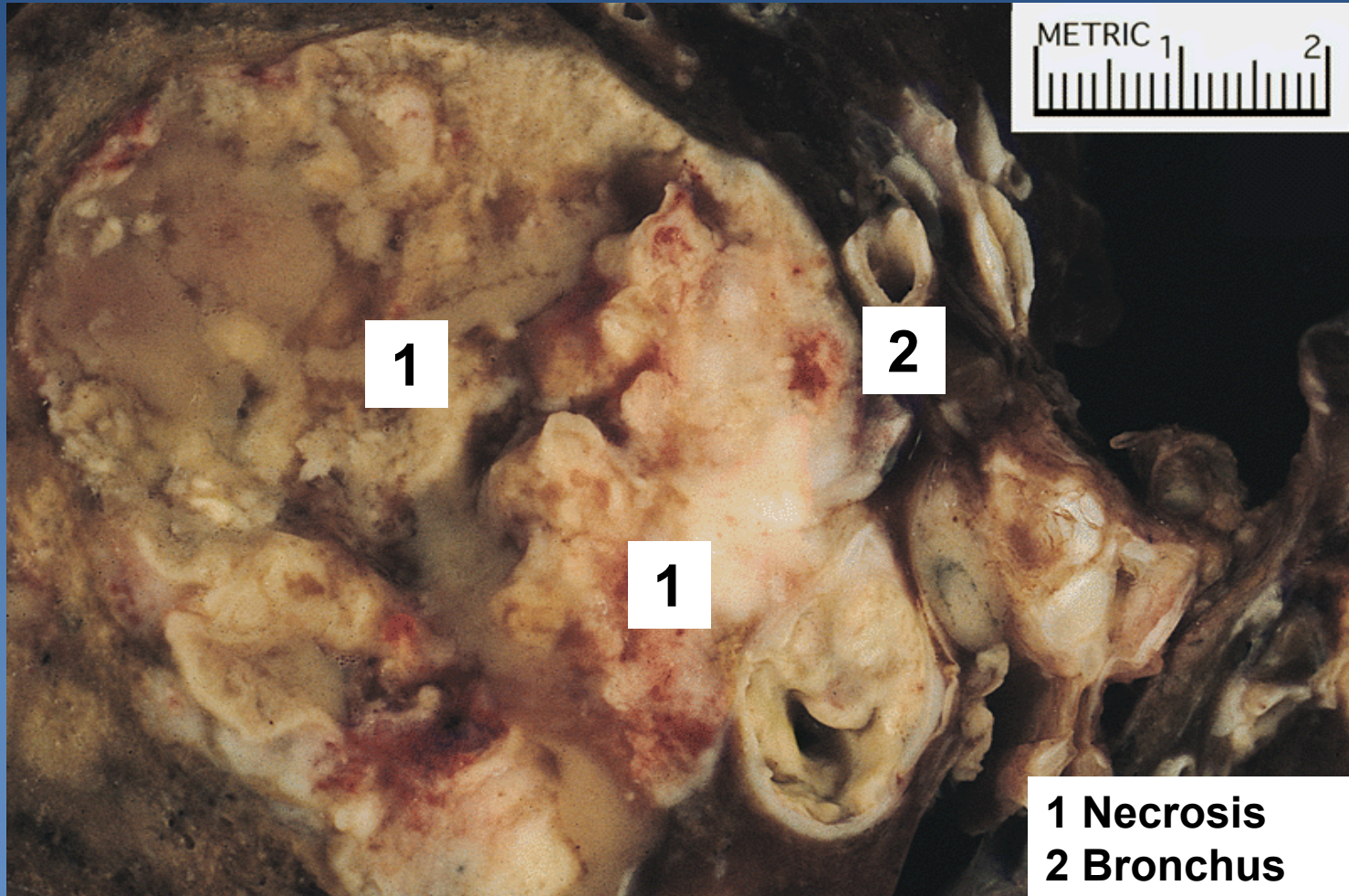
# *Large cell lung carcinoma*

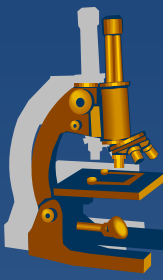
---

- x undifferentiated non-small cell carcinoma*
- x Micro:*
  - ⇒ atypical pleomorphic cells*
  - ⇒ absent features of small cell carcinoma, adenocarcinoma or squamous cell carcinoma*

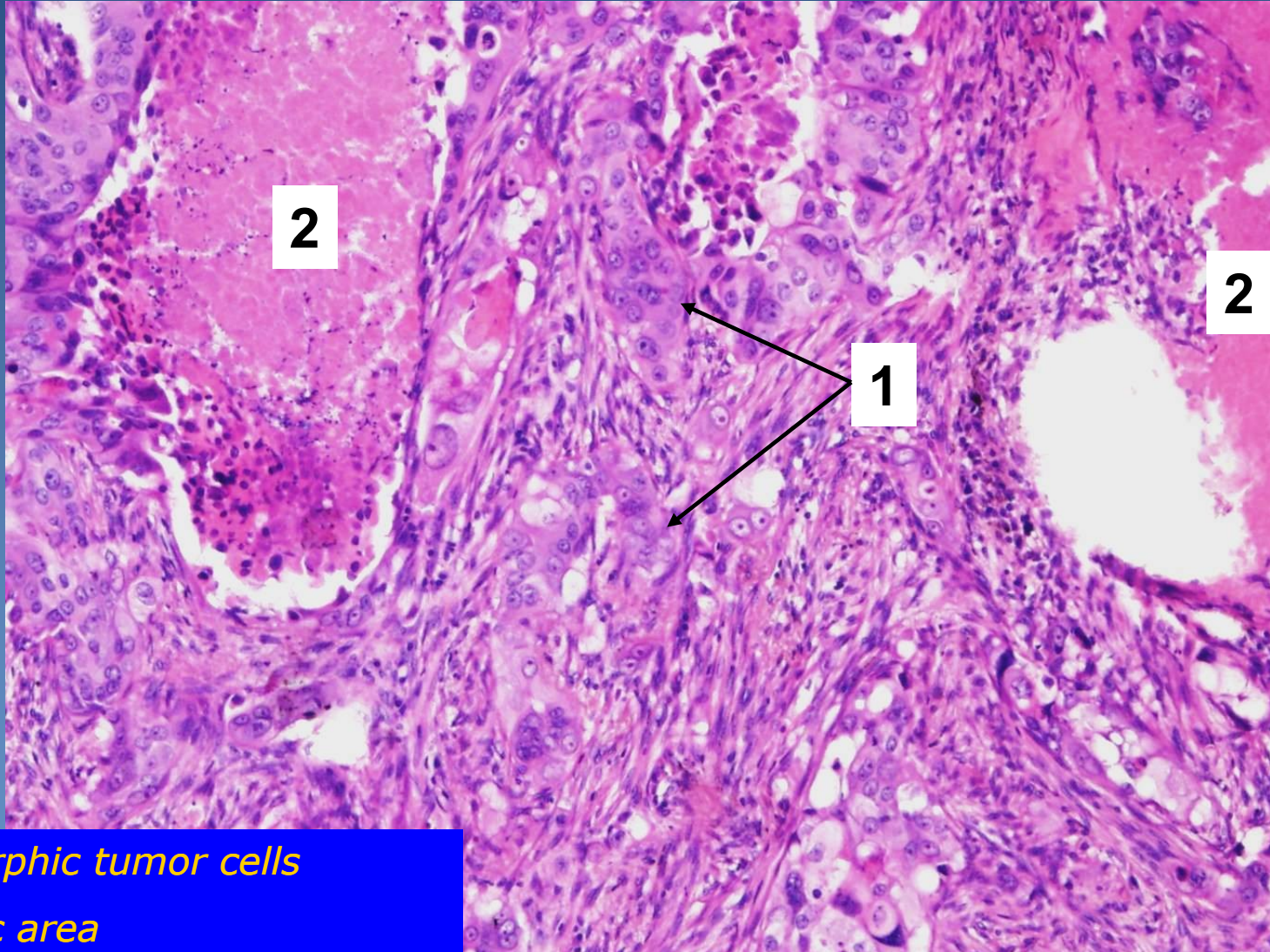


# *Large cell lung carcinoma*



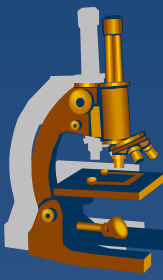


# *Large cell lung carcinoma*

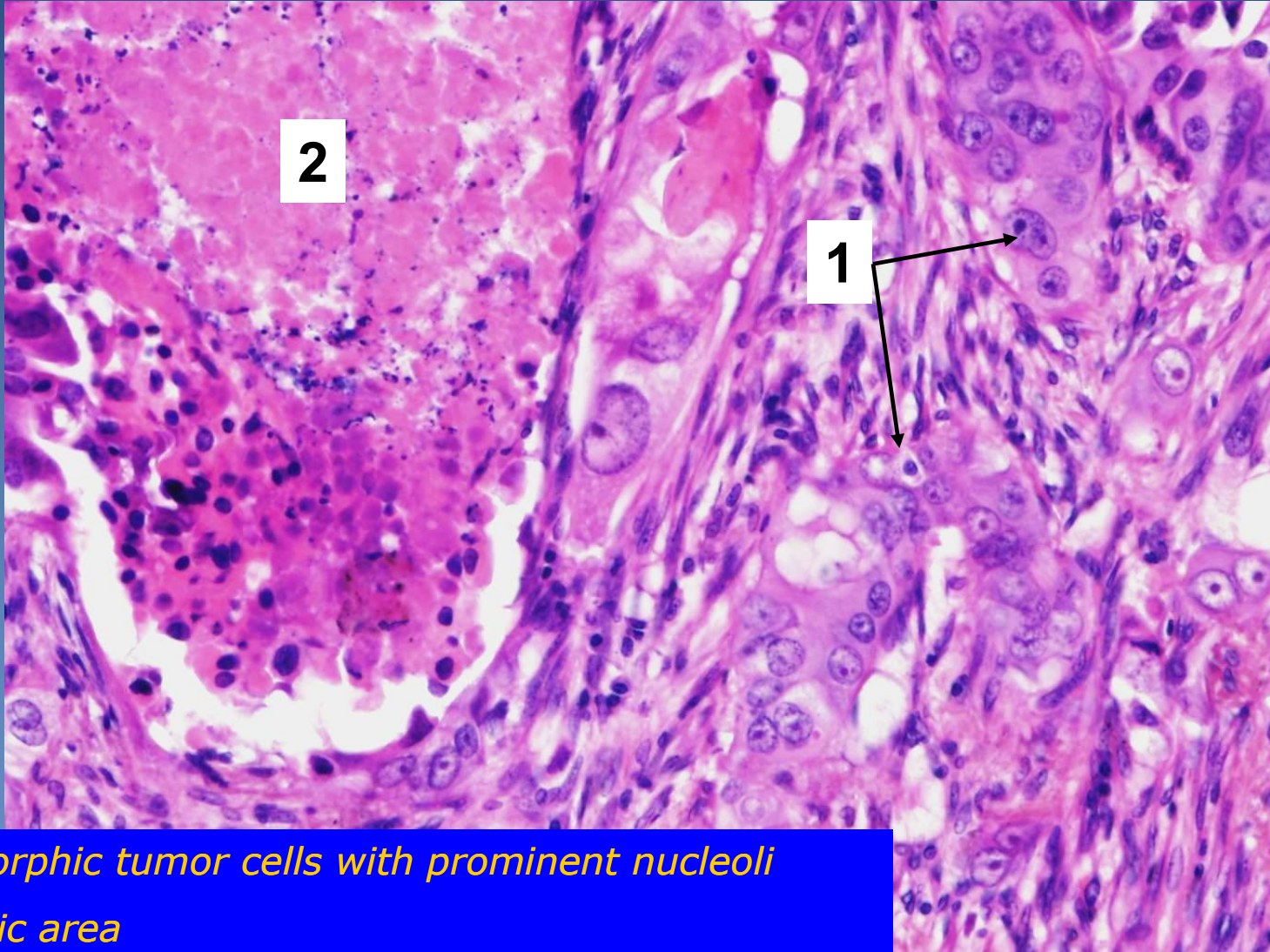


- 1. Pleomorphic tumor cells*
- 2. Necrotic area*





# *Large cell lung carcinoma*



- 1. Pleomorphic tumor cells with prominent nucleoli*
- 2. Necrotic area*