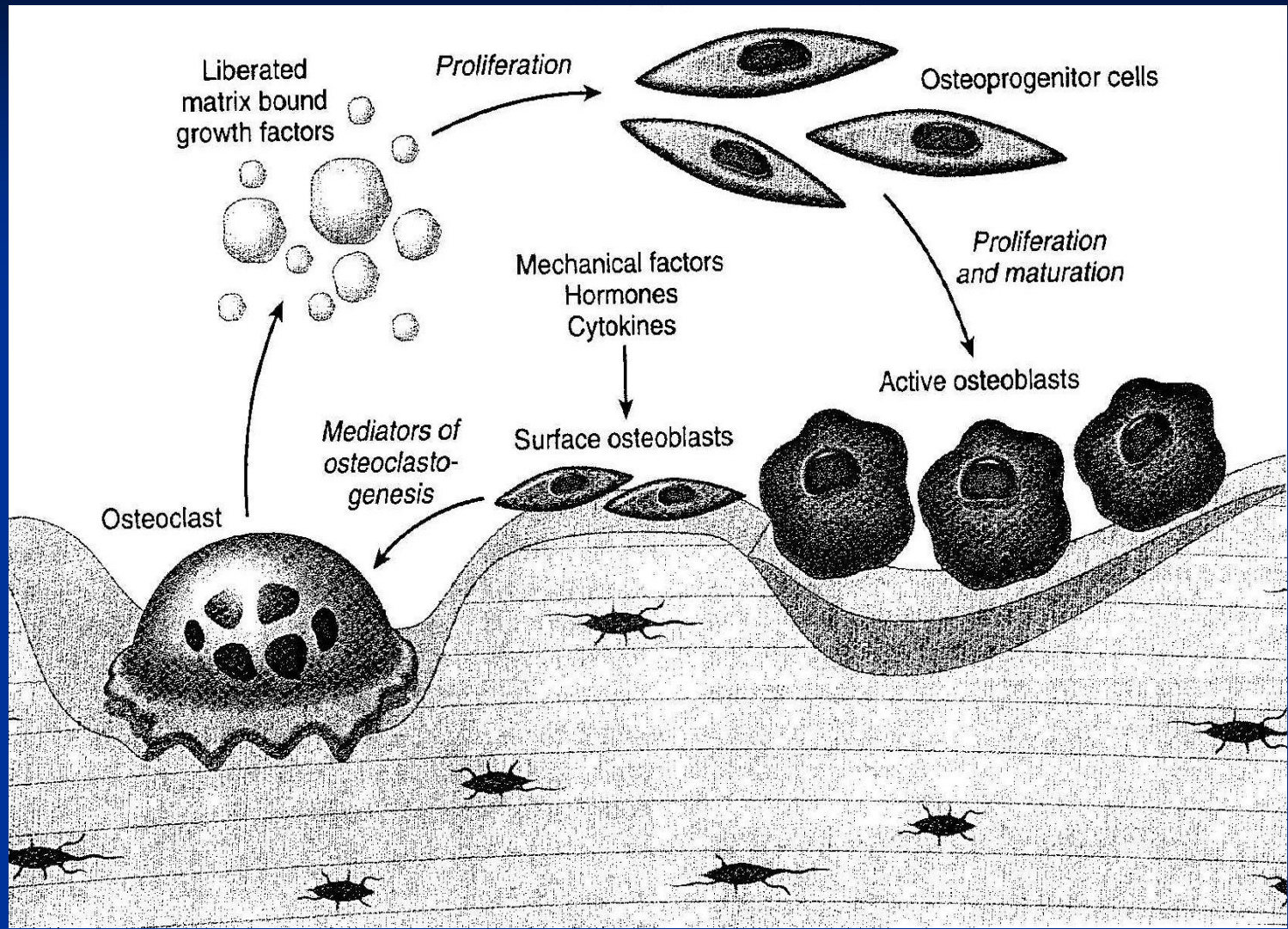


Bones and joints.

Markéta Hermanová



Inherited diseases

■ Achondroplasia

- AD, single gene disorder (gene for fibroblast growth factor receptor)
- short stature, rhizomelic shortening of the limbs, frontal bossing, midface deficiency

■ Osteopetrosis

- reduced osteoclast bone resorption, diffuse symmetric skeletal sclerosis
- bones abnormally brittle (osteosclerosis fragilis generalisata)
- AR malignant type and AD benign type
- Anemia (reduced bone marrow space), extramedullary hemopoiesis – hepatosplenomegaly, repeated infections, fractures, cranial nerve problems – the result of nerve compression (optic atrophy, deafness, facial paralysis)

■ Mucopolysaccharidoses

- enzymes (acid hydrolases) degrading dermatan, heparan, and keratan sulphates deficiencies
- chondrocytes (playing a role in the metabolism of extracellular matrix mucopolysaccharides) most severely affected; also bones, skin, connective tissues and corneas affected
- abnormalities of hyaline cartilage result in short stature, chest wall abnormalities, malformed bones
- type I (Hurler disease) and IV

Inherited diseases

■ type 1 collagen disease (osteogenesis imperfecta types 1-4)

- phenotypically related disorders; variable severity of the disease within the types
- clinically: bone fragility, hearing loss, blue sclerae, dentinogenesis imperfecta; variable severity of the disease within the types

■ type 2, 10, and 11 collagen diseases

- **achondrogenesis** (short trunk, severely shortened extremities, relatively enlarged cranium, flattened face)
- **hypochondrogenesis** (similar phenotype)
- **multiple epiphyseal dysplasia** (short or normal stature, small epiphyses, early onset osteoarthritis)
- **metaphyseal chondrodysplasia** (coxa vara, bowing of lower extremities, metaphyseal flaring)

Regulation of calcium metabolism

■ Parathyroid hormone (PTH)

■ Vitamin D

- to stimulate bone calcium mobilisation (PTH)
- to increase renal reabsorption of calcium in the distal tubule (PTH, vitamin D)
- to stimulate intestinal calcium and phosphate absorption (vitamin D)

■ Calcitonin

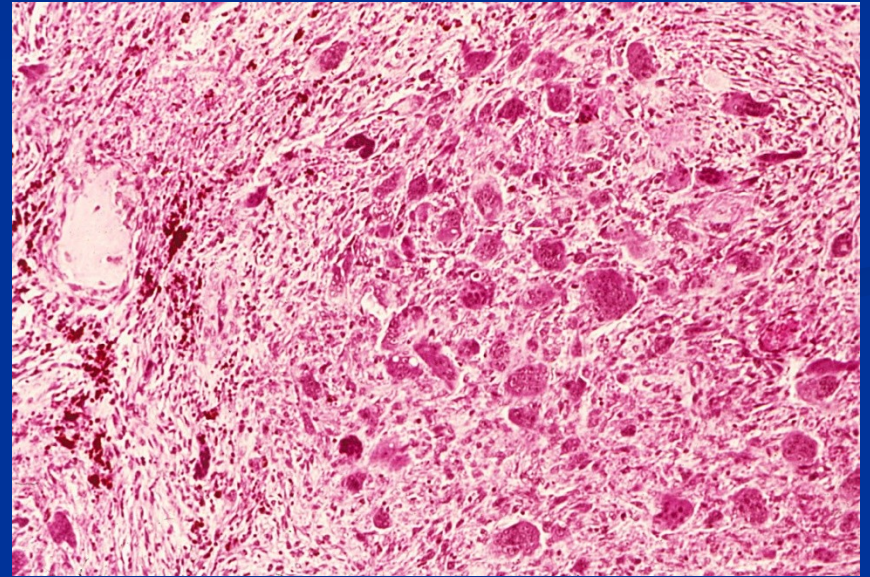
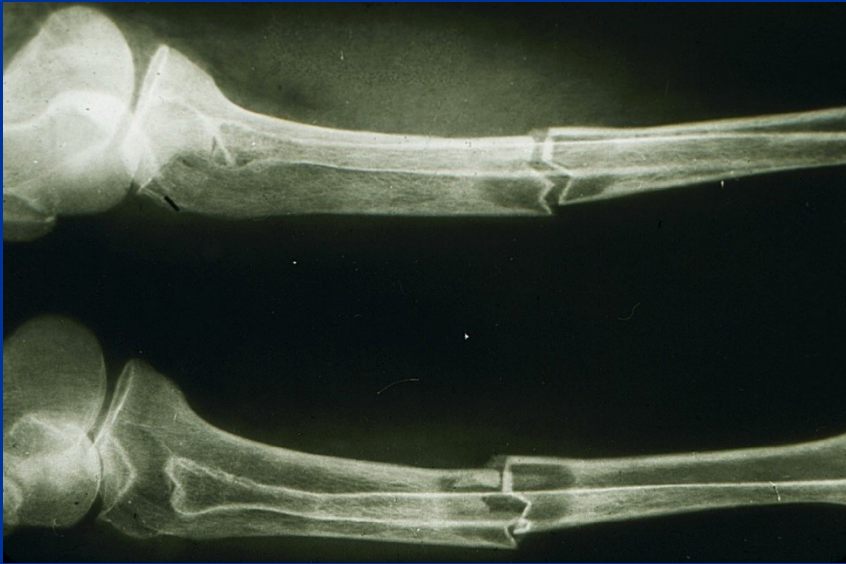- produced by parafollicular cells of the thyroid
- to lower serum calcium, if elevated

Hyperparathyreoidism:

fibrous osteodystrophy, osteitis cystica fibrosa, von Recklinghausen disease of bones

- **Hyperparathyreoidism (↑PTH):** causes increased osteoclastic breakdown of bone
 - **primary:** hyperplasia, tumor (adenoma)
 - **secondary:** in hypocalcemia resulting in increased secretion of PTH (e.g. in renal failure: renal osteodystrophy (combination of osteomalacia and ↑PTH))
 - secretion of PTH related peptide by malignant tumor
- entire skeleton affected, osteitis fibrosa cystica now very rare
- thin cortex, osteopenia, fibrovascular tissue within bone marrow spaces, hemorrhages, organisation of hematomas, pseudocysts, brown tumors (mass of reactive tissue)

Pathologic fracture and brown tumor



Renal osteodystrophy

- **high turnover osteodystrophy (high osteoclastic and osteoblastic activity)**
- **low turnover osteodystrophy (low activity; adynamic, aplastic disease)**
- **osteomalacia**
- **mixed picture of the renal osteodystrophy**

- **chronic renal diseases:**
 - phosphate retention and hyperphosphatemia
 - hypocalcemia (avitaminosis D)
 - secondary hyperparathyroidism
 - metabolic acidosis stimulating also bone resorption
 - aluminium deposition at the site of mineralization (dialysis solution); Al interferes with the deposition of calcium hydroxyapatite promoting osteomalacia
 - amyloid deposition in bones and periarticular structures (β_2 mikroglobulin) in patients on long-term dialysis

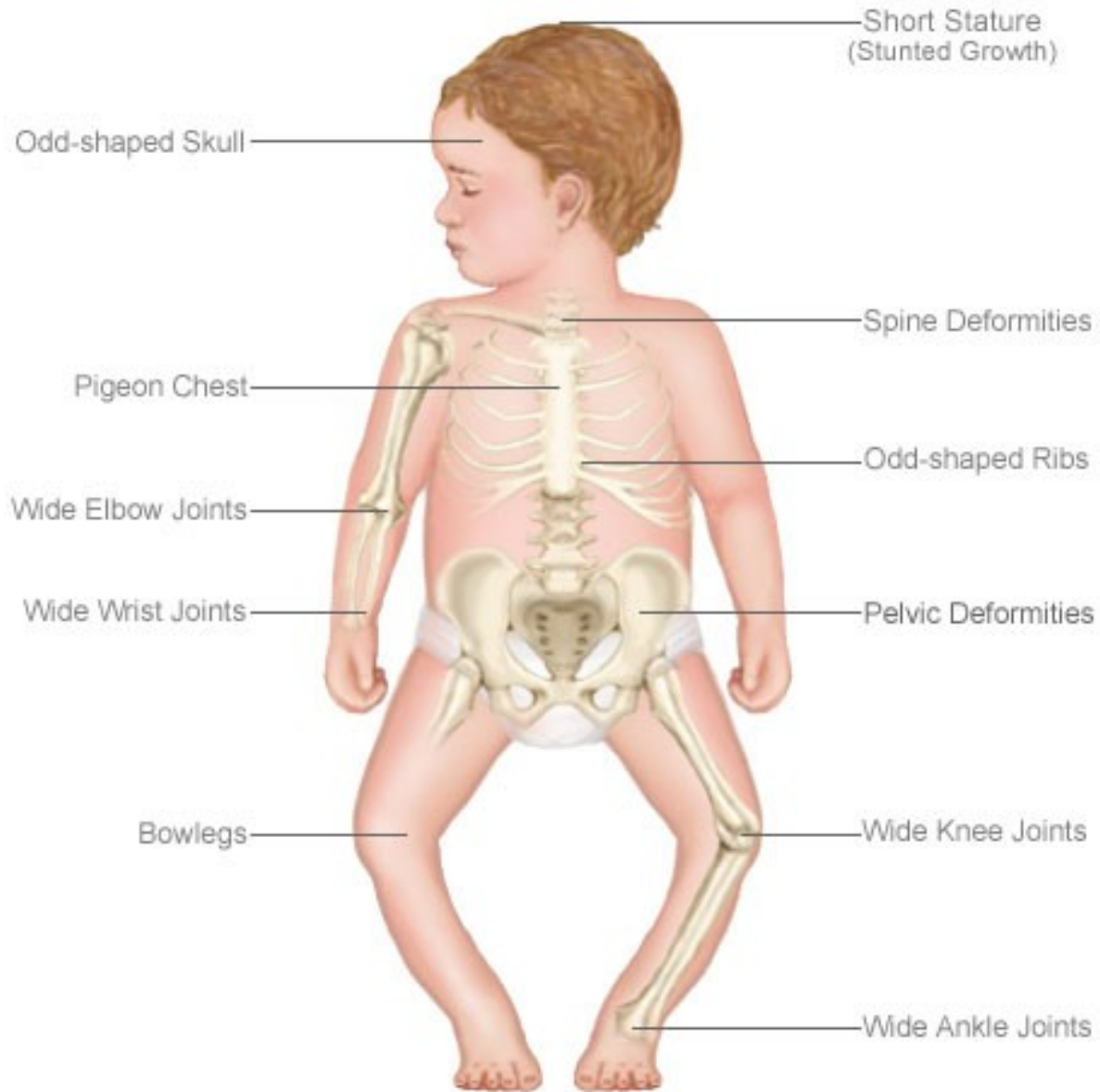
Rickets and osteomalacia

- Due to deficient mineralisation of organic bone matrix
- In sites of enchondral, endostal and periostal ossification; results in excess of unmineralized matrix
- Due to lack of active metabolites of vitamin D
- **Hypovitaminosis D** due to dietary deficiency of vitamin D, lack of sunlight, intestinal malabsorption, failure to metabolise vitamin D (in renal and liver diseases, in congenital enzyme deficiencies)

Rickets and osteomalacia

- **Rickets** occurs in growing children and causes bone deformities; inadequate provisional calcification of epiphyseal cartilage, persisted masses of cartilage, osteoid matrix on inadequately mineralized cartilaginous remnants, abnormal overgrowth of capillaries and fibroblasts in the disorganized zones because of microfractures, deformation of skeleton (caput quadratum, pigeon breast deformity, rachitic rosary, lumbar lordosis, bowing of the legs,...)
- **Osteomalacia** occurs in adults, causes susceptibility to fracture but few deformities; inadequate mineralization of newly formed osteoid matrix – weak and vulnerable bones (bone trabecules rimmed by unmineralized osteoid)
- **Vitamin D resistant rickets and osteomalacia**
 - hypophosphatemic osteomalacia
 - inhibition of mineralization by fluor, aluminium, diphosphonates
 - oncogenic osteomalacia (small cell carcinoma produces phosphaturic substance)

The Effects of Rickets



Moller-Barlow disease – avitaminosis C

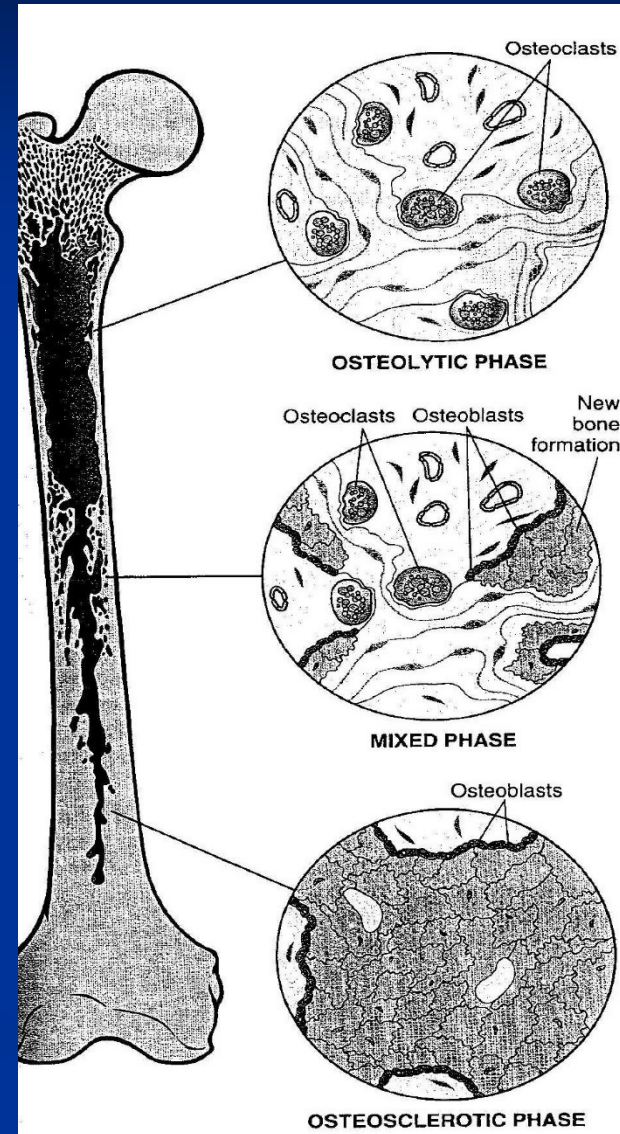
- vitamin C – hydroxylation of molecules of procollagen
- decreased secretion of collagen by fibroblasts and osteoblasts
- hemorrhages, subperiosteal hematomas, bleeding into joint spaces
- decreased production of osteoid and proliferation of cartilage (mineralization normal) – infractions, fractures, lysis epiphyseos, periostitis ossificans

Paget disease (osteitis deformans)

1. osteolytic stage
2. osteoclastic-osteoblastic stage
3. osteosclerotic stage

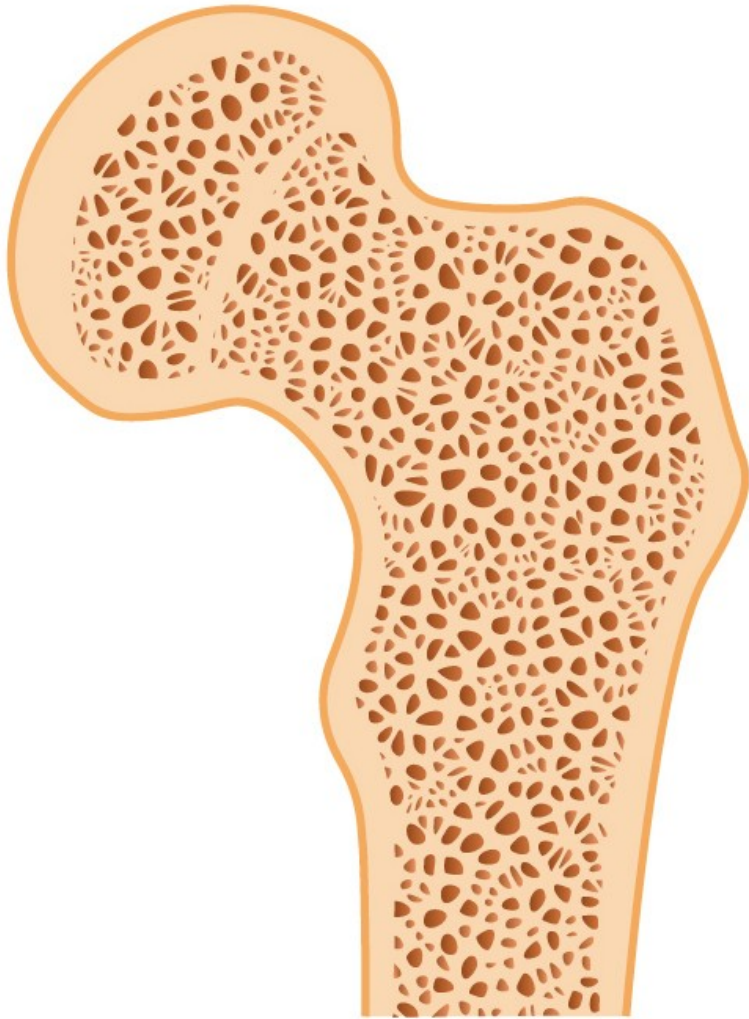
Etiology??

- slow virus infection (paramyxovirus) – viral particles seen in osteoclasts
- hereditary component (linked to locus on 18q)
- Pagetic bone enlarged with thick, coarsened cortices and cancellous bone
- Clinically pain, deformities, fractures, nerve compression
- Monoostotic – Polyostotic (15 %)
- Higher incidence of tumors and tumor-like lesions

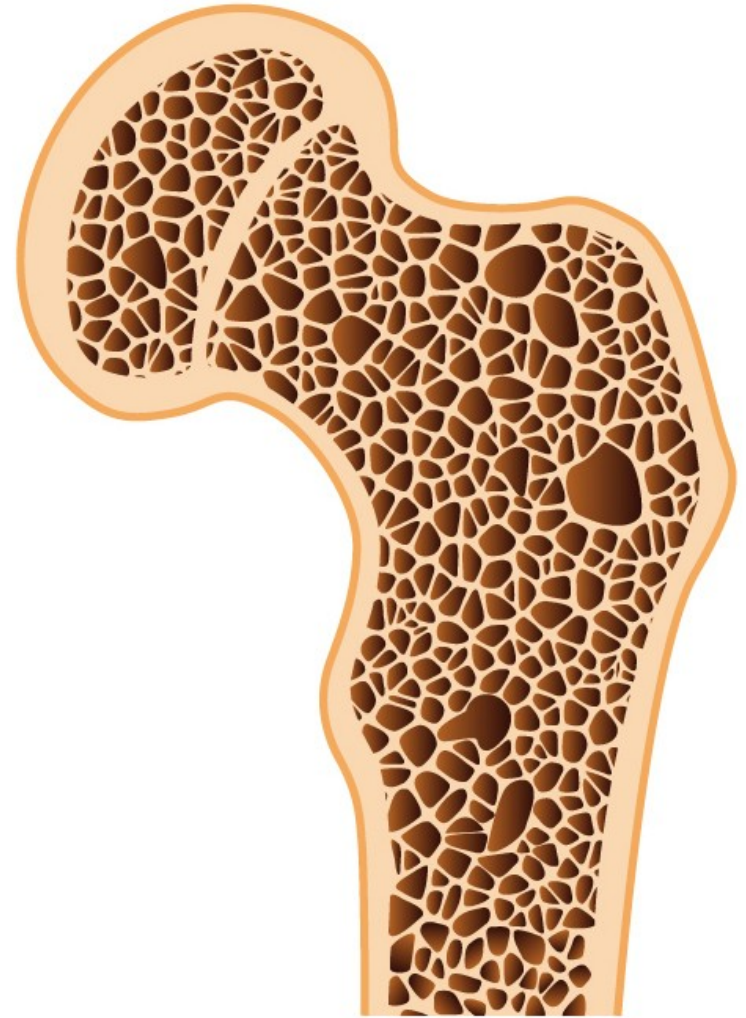


Osteoporosis

- Reduction of bone mass in the presence of normal mineralisation; due to increased bone resorption, decreased bone formation, or both
- Common in elderly, particularly in females, follows any form of immobility
- Complication of steroid therapy and Cushing's syndrome
- Associated with alcoholism, diabetes, liver's disease and smoking
- Common predisposing factor of fractures, particularly neck of femur, causes skeletal deformities and bone pain (due to compression fractures)



Healthy bone



Osteoporosis

Osteoporosis:

increased porosity of the skeleton resulting from reduced bone mass

■ Primary

- postmenopausal
- Senile

■ Secondary

1. Endocrinopathies

- hyperparathyroidism
- hypo-hyperthyroidism
- hypogonadism
- pituitary tumors
- type I diabetes mellitus
- Addison disease

2. Neoplasia (multiple myeloma, carcinomatosis)

3. GIT disorders (malnutrition, malabsorption, hepatic insufficiency, vit. C,D deficiencies)

4. Rheumatologic diseases

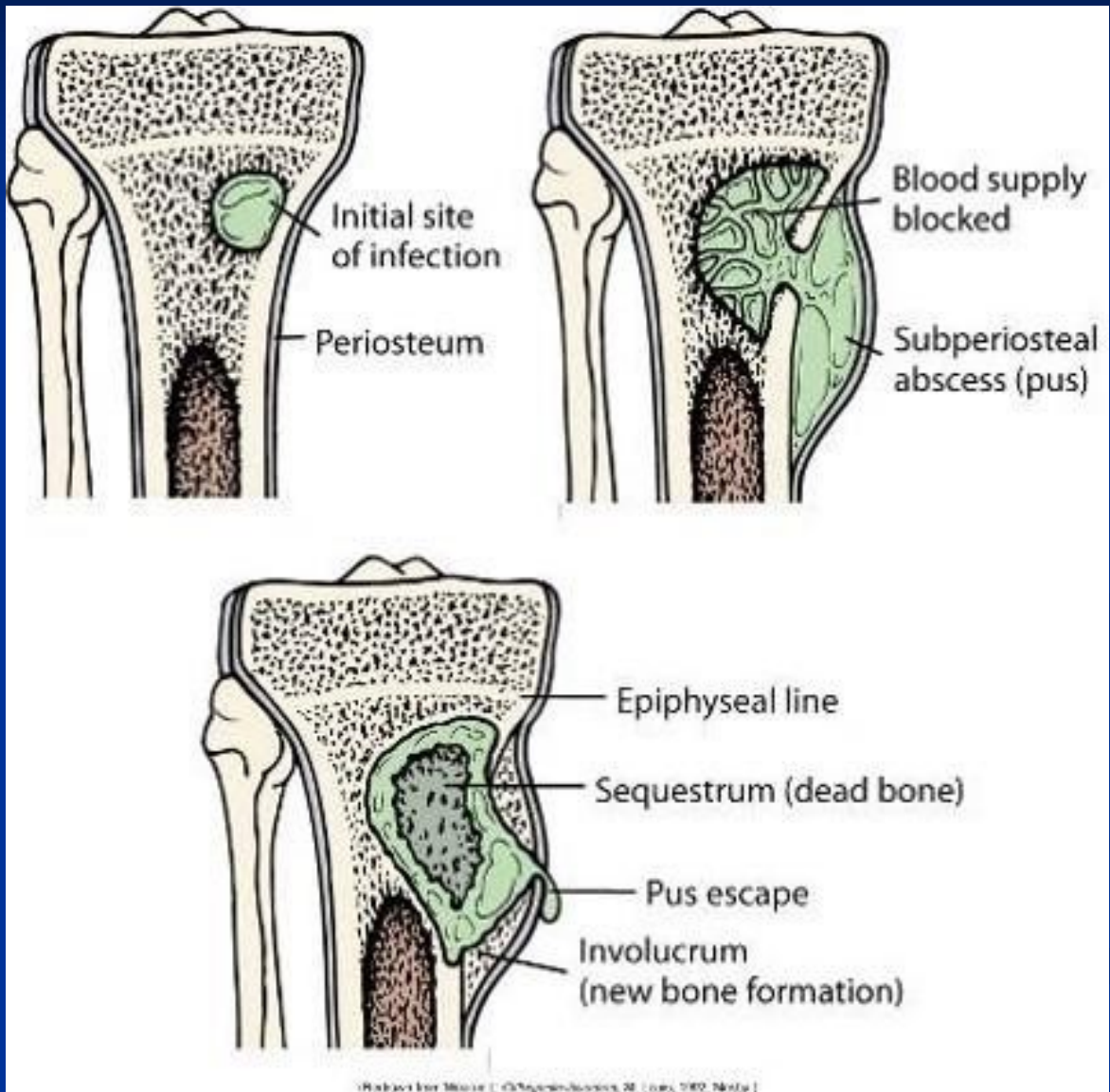
5. Drugs (anticoagulans, chemotherapy, corticosteroids, alcohol, anticonvulsants)

6. Miscellaneous (osteogenesis imperfecta, immobilisation, pulmonary diseases, homocystinuria, anemia)

Osteomyelitis

- Inflammatory lesion due to bacterial infection of bone
- Bacteria enter bone either from blood or directly through skin wound over a compound fracture
- Necrotic bone forms inner sequestrum
- Reactive new bone forms outer involucrum
- Most common in children (most usual *Staphylococcus aureus* infection)
- A complication of advanced tuberculosis
- May complicate the use of internal fracture fixation devices

Osteomyelitis



Infections - osteomyelitis

■ Pyogenic osteomyelitis

- Staphylococcus a., E. coli, Pseudomonas, Klebsiella, Haemophilus i., Salmonella,...
- acute, subacute, chronic
- acute inflammatory reaction, subperiosteal abscess, necrosis (sequestrum), draining sinus
- chronic osteomyelitis: reactive periostitis ossificans (involcurum)

■ Tuberculous osteomyelitis

- hematogenous spread of BK into bones (rarely direct extension or lymphogenous spread)
- Pott disease in the spine

■ Skeletal syphilis

- STD, Treponema pallidum
- congenital syphilis (spirochetes localized in areas of active enchondral ossification (osteochondritis) and in the periosteum (periostitis))
- acquired syphilis (tertiary stage; reactive periostitis: nose, palate, skull, extremities – tibia – saber shin)

Avascular necrosis: osteonecrosis

- Idiopathic (m. Perthes – femur, m. Kohler – os naviculare)
- Traumatic (mechanical vascular interruption, fracture)
- Corticosteroids
- Infections
- Dysbarism (nitrogen bubbles)
- Radiation therapy (vessel injury)
- Connective tissue disorders (vasculitis, vessel injury)
- Pregnancy
- Gaucher disease
- Sickle cells and other anemias
- Alcohol abuse
- Chronic pancreatitis
- Tumors
- Epiphyseal disorders

Bone tumors and tumor-like lesions

- Bone-forming tumors
- Cartilage-forming tumors
- Fibrous and fibro-osseous tumors
- Ewing sarcoma and primitive neuroectodermal tumor (PNET)
- Giant cell tumor (osteoclastoma)

Secondary – metastatic tumours

■ Metastases in adults:

- carcinomas of prostate, breast, kidney, lung,....

■ Metastases in children:

- neuroblastoma, Wilms tumor, osteosarcoma, Ewing sarcoma, rhabdomyosarcoma,...

■ Metastases:

- **lytic** – secretes (PG, IL, PTHRP,...) stimulating osteoclastic bone resorption (e.g. carcinomas of kidney, lung, GIT, melanoma,...)
- **osteoblastic** (prostatic cancer)
- **mixed lytic and osteoblastic**

Bone forming tumors - benign

■ Osteoma

- facial and skull bones
- solitary or multiple (Gardner syndrome: osteomas, intestinal polyps, benign STT)
- bosselated round to oval sessile tumors
- waven and lamelar bone in a cortical patterns with haverian-like systém

■ Osteoid osteoma

- < 2 cm, painful (excess of PG E₂ produced by proliferating osteoblasts)
- teenagers
- appendicular skeleton (femur, tibia,...), cortex>medulla; M:F=2:1
- centrally nidus (trabeculae of woven bone rimmed by osteoblasts); rimmed by reactive sclerotic bone

■ Osteoblastoma

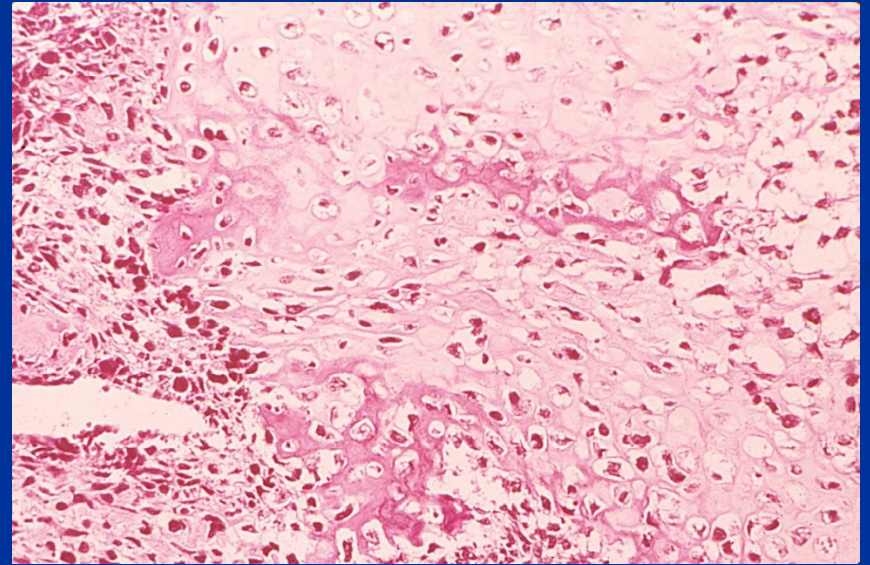
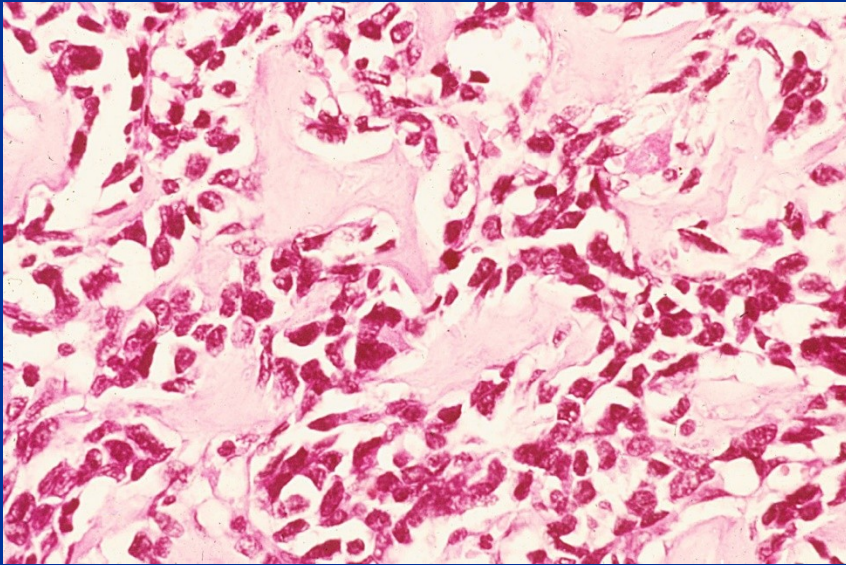
- > 2 cm
- no rim of sclerotic bone
- locally aggressive
- spine and long bones
- pain no responsive to salicylates

Bone forming tumors – malignant

■ Osteosarcoma

- malignant mesenchymal tumors with neoplastic cells producing bone matrix
- 75 % in patients under 20
- in older patients often associated with Paget's disease, bone infarcts and prior irradiation (secondary tumors)
- metaphyses of long bones (60 % knee)
- intramedullary, intracortical or surface
- abnormalities of RB gene, p16, p53, p21, cyclinD1, mdm2, CDK4,...
- osteoblastic, chondroblastic, fibroblastic, teleangiectatic, small cell, giant cell
- clinically painful, enlarging mass, pathologic fracture
- destruction of cortex, soft tissue masses, periosteal bone formation (Codman triangle)
- hematogeneous spreading (metastases in lungs, bones, brain,...)

Osteosarcoma



Cartilage-forming tumors

■ Osteochondroma (exostosis osteocartilaginea)

- metaphysis of long bones (knee) near the growth plate
- solitary or multiple (hereditary exostosis-AD)
- mushroom shaped covered by benign hyaline cartilage and perichondrium, 1-20 cm, growth based on enchondral ossification
- rarely giving rise to chondrosarcoma

■ Chondroma

- enchondroma (within medullar cavity) or juxtacortical chondromas (subperiostal)
- Ollier disease - multiple enchondromas with a risk of malignization
- Maffucci syndrome – multiple enchondromas with a risk of malignization + soft tissue hemangiomas
- Nodules of hyaline cartilage surrounded by a thin layer of reactive bone

■ **Chondroblastoma**

- young patients, teens, M:F=2:1
- epiphyses (knee), pelvis, ribs
- sheets of compact polygonal chondroblast, hyaline matrix (if calcified – chicken-wire pattern of hyalinization) , nodules of hyaline cartilage, osteoclast-type giant cells, hemorrhagic cystic degeneration

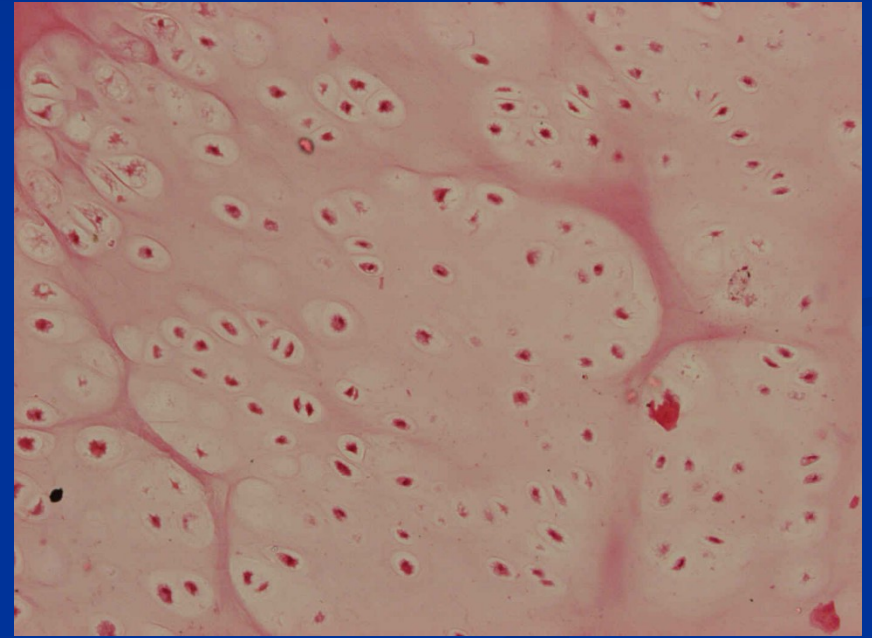
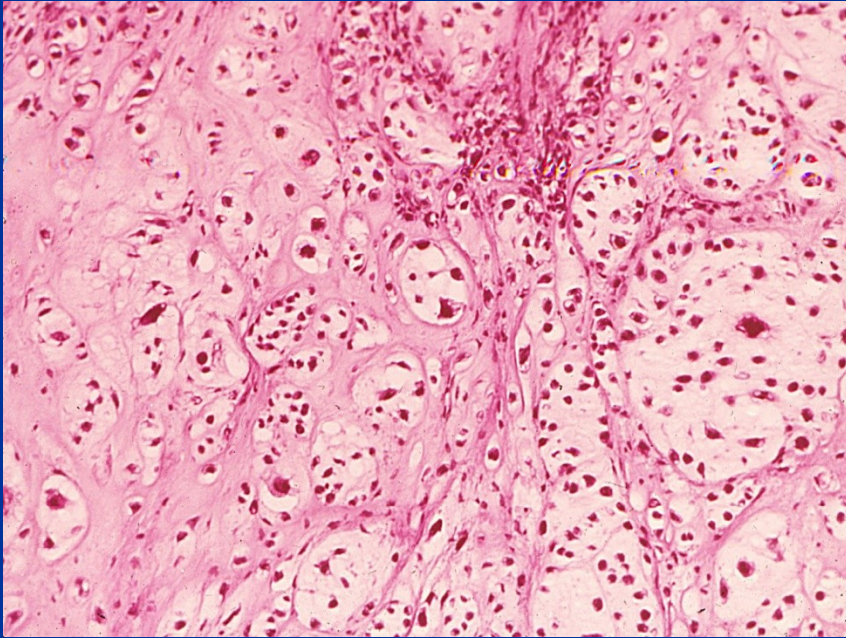
■ **Chondromyxoid fibroma**

- teens and twenties, M>F
- metaphysis of long tubular bones, 3-8 cm, lobular, chondromyxoid tissue with spindle or stellate cells; more cellular at the periphery of lobules, often with osteoclast-type cells

■ **Chondrosarcoma**

- patients more than 20, usually more than 40
- pelvis, shoulder, ribs
- de novo or malignization of enchondromas, osteochondromas, chondroblastomas, fibrous dysplasia, or setting in Paget's disease
- painful, progressively enlarging mass, thickening of the cortex, destruction of the cortex and soft tissue mass; metastatic spread into lungs and skeleton (often late metastatic spread)
- malignant hyaline and myxoid cartilage, nodular arrangement; variants: juxtacortical, dedifferentiated, clear cell

Chondrosarcoma and chondroma



Fibrous and fibro-osseous tumors

- **Fibrous cortical defect and non-ossifying fibroma (metaphysal fibrous defect)**
 - distal femur and proximal tibia, also bilateral and multiple
 - lytic lesions
 - self-limited FCD; progressively growing NOF
 - proliferation of fibroblasts (often storiform pattern), histiocytes (multinucleated giant cells, clusters of foamy macrophages)
- **Fibrous dysplasia**
 - monoostotic, polyostotic, McCune-Albright syndrome (polyostotic FD, café au lait skin pigmentation, endocrinopathies)
 - circumscribed, intramedullary
 - curvilinear trabeculae of woven bone and moderately cellular fibroblastic proliferation, sometimes nodules of hyaline cartilage; cystic degeneration, hemorrhages, foamy macrophages
- **Fibrosarcoma**
 - older people, long bones
 - malignant fibroblast in a herringbone pattern
- **Malignant fibrous histiocytoma**
 - older patients, long bones
 - spindle fibroblasts, storiform pattern admixed with bizarre, large, multinucleated tumor giant cells

Miscellaneous tumors

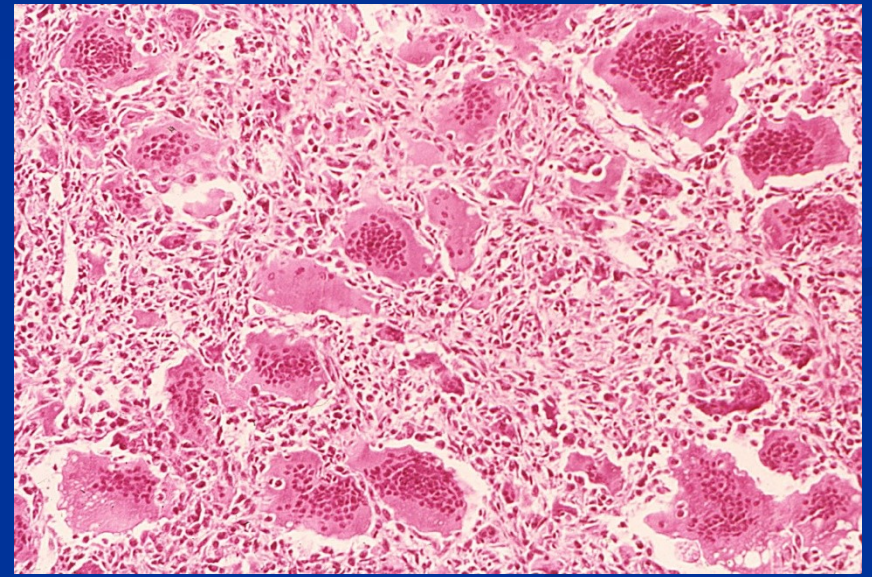
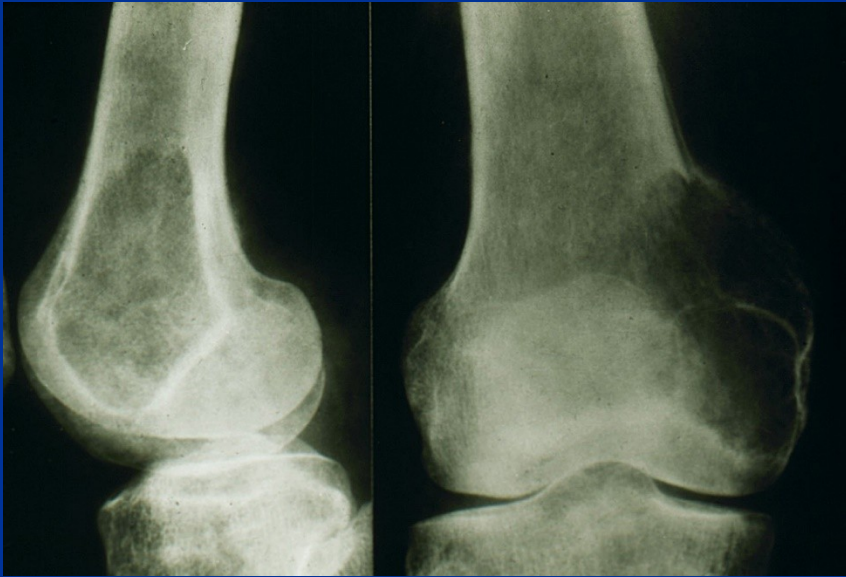
■ Ewing sarcoma and primitive neuroectodermal tumor (PNET)

- small round cell tumors of the bones and soft tissues
- 6-10 % of primary bone tumors
- 80 % patients under 20, M>F
- translocations (t(11;22), t(7;22), t(21;22)); fusion of EWS gene with a member of ETS family of transcription factor; result in chimeric protein which acts as a constitutively active transcription factor stimulating cell proliferation
- diaphyses of long tubulary bones and pelvis; arising in medullary cavity invading the cortex, periosteum and soft tissues
- lytic lesion, periosteal reaction – reactive bone in an onion-like fashion
- neural differentiation, Homer-Wright rosettes

■ Giant cell tumor (osteoclastoma)

- locally aggressive, osteolytic, large, red brown, often cystically degenerated; high recurrence rate, potentially malignant (5 %)
- proliferating mononuclear cells, osteoclast-type giant cells, necrosis, hemorrhage, hemosiderin deposits, reactive bone formation
- epiphyses of long bones
- between 20 and 40
- differential diagnosis: brown tumor in hyperparathyreoidism, giant cell reparative granuloma, pigmented villonodular synovitis, chondroblastoma

Giant cell tumor - osteoclastoma

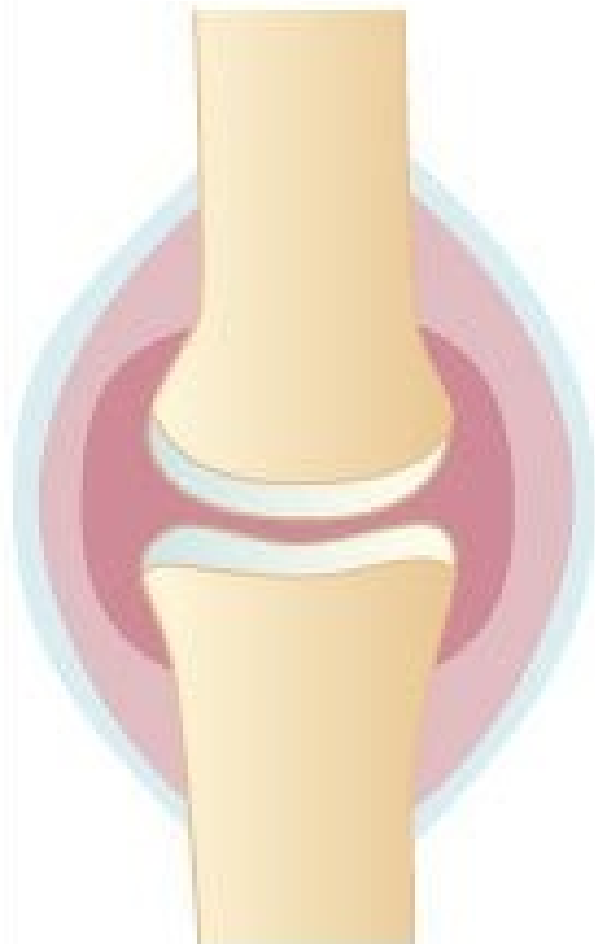

Malignant tumours of the bone						
Tumor	%	Usual age	M:F	Sites affected	Behaviour	Treatment, prognosis
Osteosarcoma	30	Adolescents	2:1	Long bones, distal femur, proximal tibia	Rapid growth, pain, swelling, lung metastases	Surgery and chemotherapy 40% + cure rate
Chondrosarcoma	15	35-60	2:1	Pelvis, ribs, spine, long bones	Slow enlargement, lung metastases	Surgery 75% cure rate
Fibrosarcoma	20	Any age, peak 30-40	3:2	Femur, tibia, humerus, pelvis	Local growth, vascular invasion	Surgery 40% cure rate
Ewing's sarcoma	7	Children and teenagers	2:1	Long bones, pelvis, ribs	Widespread metastases	Surgery and chemotherapy 50% + cure rate

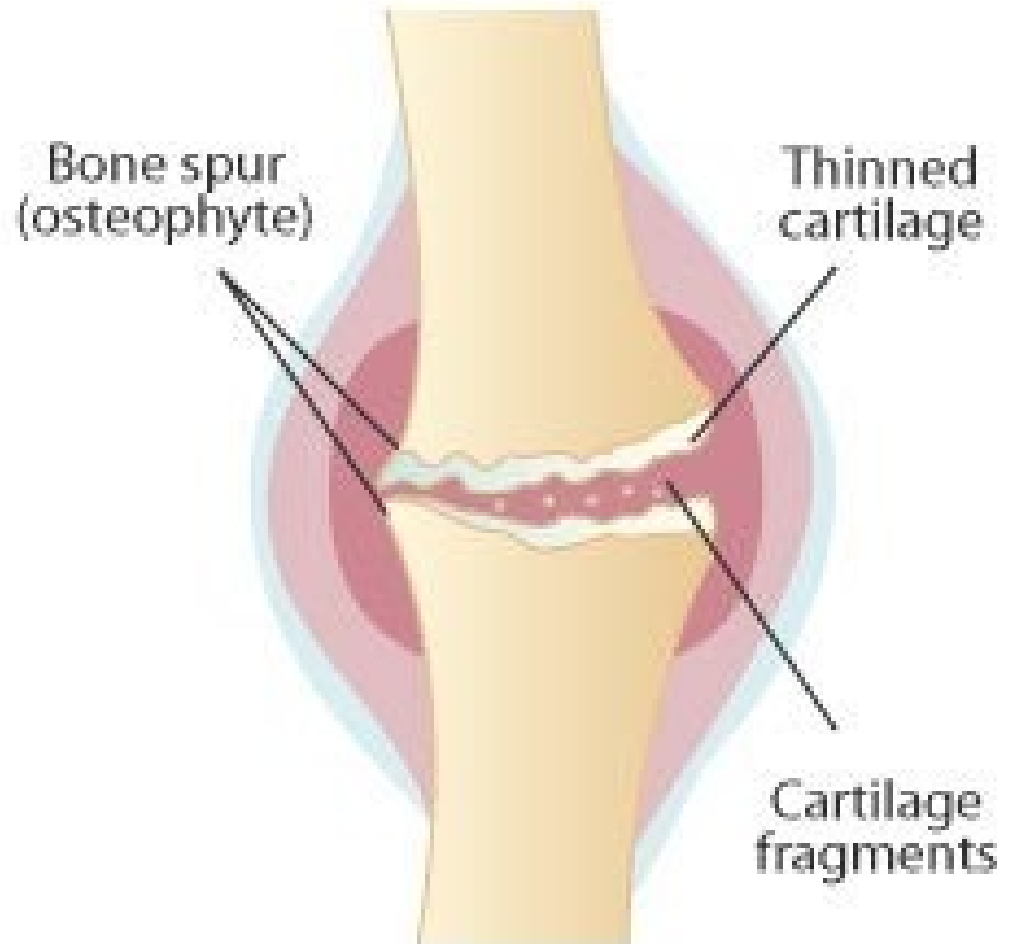
+ secondary, metastatic tumors: breast, lung, prostate, kidney, thyroid cancer,.....
+ osteolytic lesions in myeloma (plasmocytoma)

Osteoarthritis (osteoarthrosis)

- Common painful, disabling degenerative joint disease
- Primarily affects cartilage of weight-bearing joints (e.g. hips, knees)
- Erosion of cartilage leads to secondary changes in underlying bone
- Only limited inflammatory changes in synovial membrane
- Osteoarthritis of hip and knee can be treated surgically by joint replacement



Normal joint



Joint affected by osteoarthritis

Osteoarthritis (degenerative joint disease)

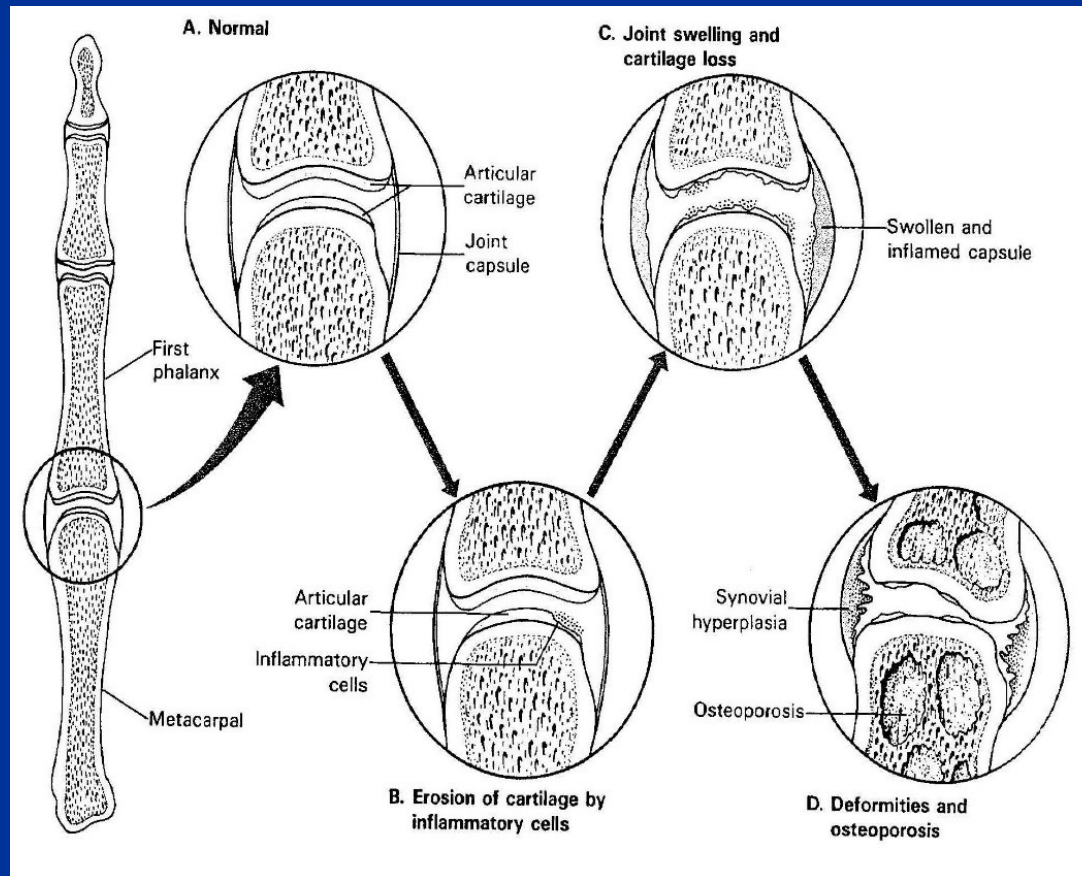
- non-inflammatory degenerative disease; progressive erosion of cartilage; secondary changes: inflammatory and reactive changes in synovial membranes and the adjacent bones
- aging and mechanical defects, genetic factors
- deep achy pain, morning stiffness, crepitus and limitation of range of movement
- proliferation of chondrocytes, biochemical changes of matrix, vertical and horizontal fibrillation and cracking of the matrix, degradation of superficial layers of cartilage, bone eburnation, sclerosis of underlying bone, formation of loose bodies, synovial fluid in subchondral regions – pseudocysts, osteophytes at the margins of the articular surface

Rheumatoid arthritis

- a chronic systemic inflammatory disorder affecting also joints
- a nonsuppurative proliferative, inflammatory synovitis that often progresses to destruction of the articular cartilage and ankylosis of the joints
- autoimmune disease, in a genetically susceptible host; 95 % RA patients have positivity of rheumatoid factor (IgM against Fc fragment of IgG – immunocomplexes); F>M
- small bones of the hands, wrist, ankles, elbows, knees, cervical spine, hips affected; lumbosacral region spared

Rheumatoid arthritis

- systemic features include: subcutaneous rheumatoid nodules, anaemia, lymphadenopathy and splenomegaly, serositis (e.g. pericarditis), Sjögren syndrome, uveitis, vasculitis,....
- juvenile rheumatoid arthritis: children can be also affected



Seronegative spondylarthropathies: spondylarthropathies assoc. with HLA-B27 haplotype

■ Ankylosing spondylitis

- Inflammatory disorder of spinal joints
- Chronic synovitis, destruction of cartilage, bony ankylosis (sacroiliac and apophyseal joints), ossification of tendinoligamentous insertion
- Fusion of vertebral bodies inhibits flexion and rotation, especially in cervical segment, some patients develop fixed spinal deformities
- 90 % of cases have the HLA-B27 haplotype
- Systemic features include peripheral arthritis, uveitis, chronic inflammatory bowel disease

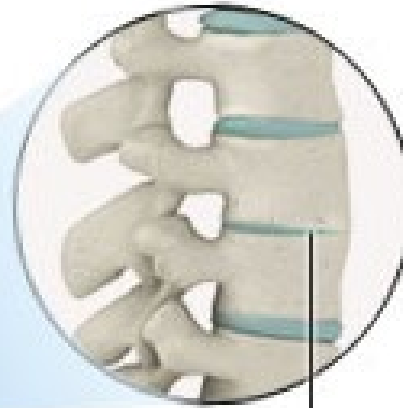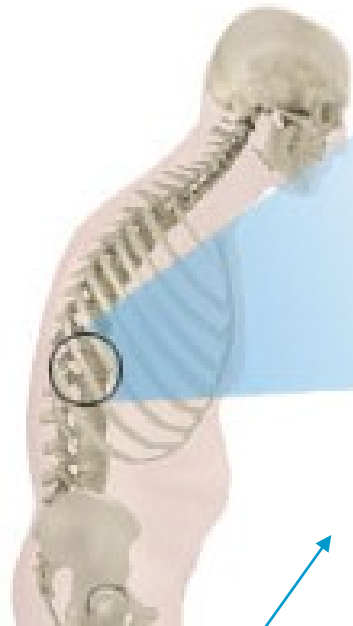
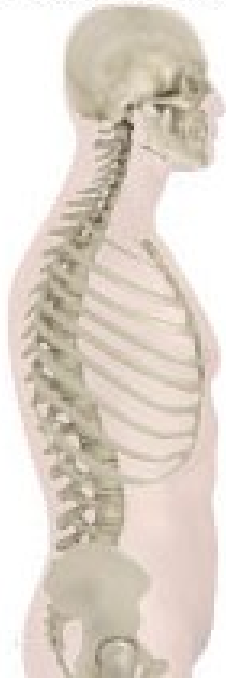■ Reiter's disease

- arthritis + conjunctivitis + urethritis
- 80 % HLA-B27+; autoimmune reaction initiated by prior infection
- infections of genitourinary (Chlamydia) and GIT (Shigella, Salmonella, Yersinia, Campylobacter)

+ **arthritis in psoriasis** (distal interphalangeal joints); in **IBD** (inflammatory bowel disease)

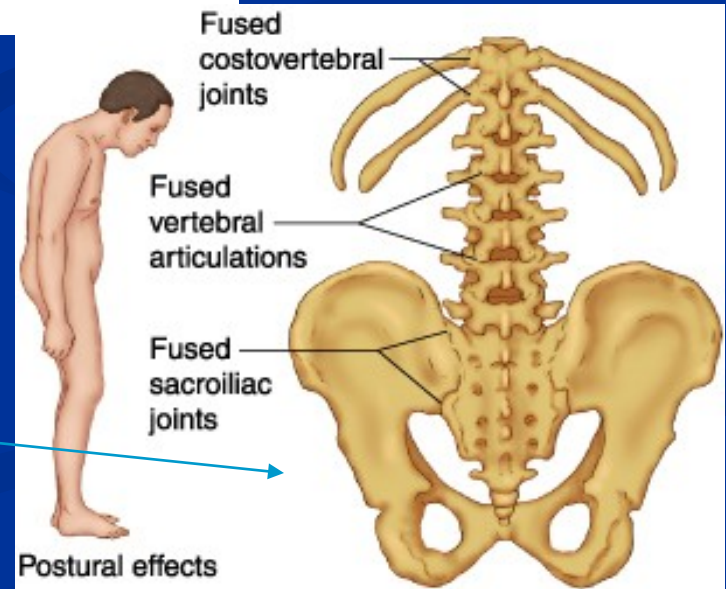
spine without
ankylosing spondylitis

spine with
ankylosing spondylitis



vertebrae
fused
together

Ankylosing spondylitis



Infective arthritis

■ Bacterial arthritis

- *Staphylococcus aureus*
- *Staphylococcus albus* (prosthetic joints)
- *Streptococcus pyogenes*
- *Haemophilus influenzae*
- *Diplococcus pneumoniae*
- *Neisseria gonorrhoeae*

■ tbc arthritis

- complication of tbc osteomyelitis or hematogenous dissemination from a visceral site of infection

■ Lyme arthritis

- *Borrelia burgdorferi* (transmitted by ticks)

■ Virus-associated arthritis

- parvovirus B19, rubella, HCV

■ Infective discitis

- *Staphylococcus aureus*, *Mycobacterium tuberculosis*, *Brucella abortus*

Rheumatic arthritis – rheumatic fever

- an acute immunologically mediated multisystem inflammatory disease occurring a few weeks after an episode of group A streptococcal pharyngitis
- migratory polyarthritits of large joints
- pancarditis

!!!

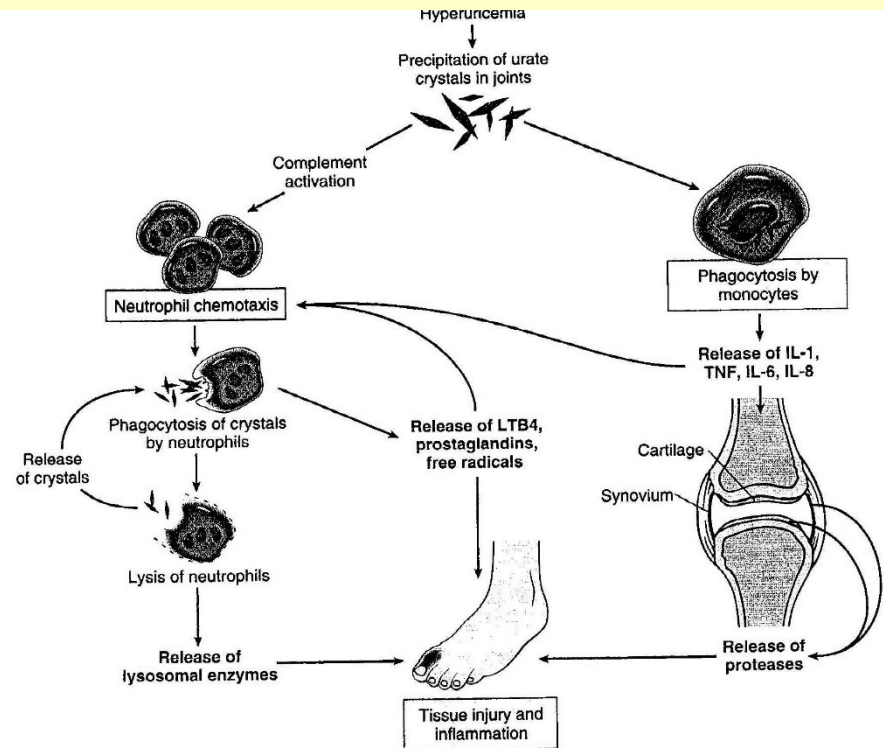
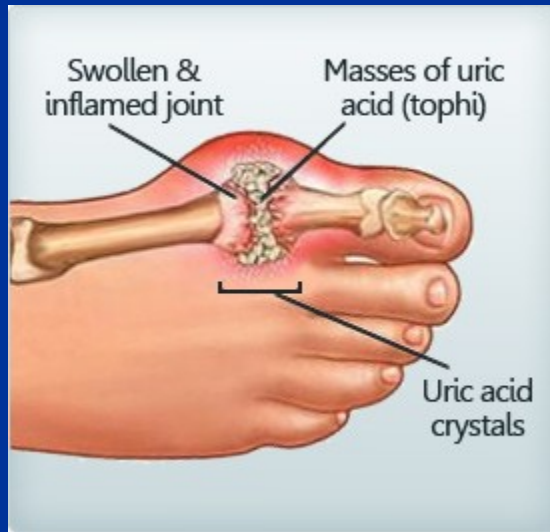Rheumatic fever: immunologically mediated post-streptococcal illness affecting heart and joints

Rheumatoid disease: autoimmune disorder causing arthritis, completely unrelated to rheumatic fever

Pathogenesis:

- Idiopathic
- Impaired uric acid excretion secondary to chronic renal failure, thiazide diuretics
- Increased uric acid production (in increased cell turnover, in specific enzyme defects)
- High dietary purine intake

Gout



- Painful acute inflammatory response to tissue deposition of urate crystals
- Most commonly affects metatarsophalangeal joint of first toe
- Much more common in males than females, onset 40-60 years, familial tendency
- Serum uric acid levels are raised
- May be associated with chronic renal disease

Tumor-like lesions of the joints

■ Ganglion

- near a joint capsule, wrist, pea-sized nodule
- result of cystic and myxoid degeneration of connective tissue

■ Synovial cysts

- herniation of synovium or enlargement of a bursa
- popliteal space – Baker cyst

■ Osteochondral loose bodies

- in degenerative joint disease

Tumors of the joints

■ Pigmented villonodular synovitis

- benign neoplasm
- one or more joints, diffusely involved (knee)
- red brown folds, finger-like projections, nodules, synovialocytes, hemosiderin deposits, foamy macrophages, multinucleated giant cells, zones of sclerosis; erosion of the bone

■ Giant cell tumor of tendon sheath

- localised nodular tendosynovitis, discrete nodule on a tendon sheath

■ Synovial chondromatosis

- multiple intrasynovial chondromas or ossifying chondromas

■ Synovial sarcoma

- soft tissue tumor
- dual line of differentiation (epithelial-like and spindle cells); rarely monophasic
- t(X;18)
- metastases into lungs

Connective tissue diseases, systemic

- Multisystem disorders, often affecting joints, skin, subcutaneous tissues
- Females preferentially affected (except polyarthritis nodosa and ankylosing spondylitis), weak genetic tendency
- Chronic clinical course, may respond to antiinflammatory drugs, immunosuppressive drugs (e.g. steroids)
- First presentation may be during adolescence or early adult life
- Immunological abnormalities often present (circulating auto-antibodies or evidence of immune complexes)

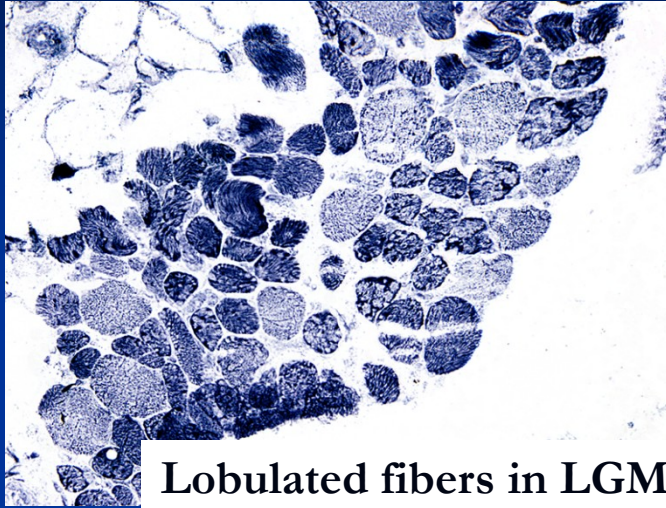
Clinical and pathological features of the major connective tissue diseases

Disease	F:M	Age (onset)	Clinical features	Immune abnormality	Pathology
Rheumatoid arthritis	3:1	Young and middle aged adults, also children	Chronic polyarthritis Subcutaneous nodules Splenomegaly	autoAb against native Ig (rheumatoid factor)	Chronic synovitis Granulomas in subcutaneous tissues Fibrinous pericarditis
Systemic lupus erythematosus	8:1	Young and middle aged adults	Erythematous (butterfly) skin rash Renal disease, glomerular damage Light sensitivity Arthritis, arthralgia. Anaemia, leukopenia	autoAb against nuclear and cytoplasmic proteins and other cellular component	Synovitis, glomerulonephritis, erythematous skin rashes
Polyarteritis nodosa	3:1	Any age, chiefly middle aged adults	Arthralgia Abdominal pain Ischaemic lesions in many organs, neuropathy, renal damage Fever, Leukocytosis, eosinophilia	Some antinuclear antibodies and rheumatoid factor	Necrotising vasculitis of medium-sized arteries
Ankylosing spondylitis	2:1	Young adults	Back pain Arthritis Uveitis	Most HLA-B27+	Spondylitis, bony fusion of spine and SI joints

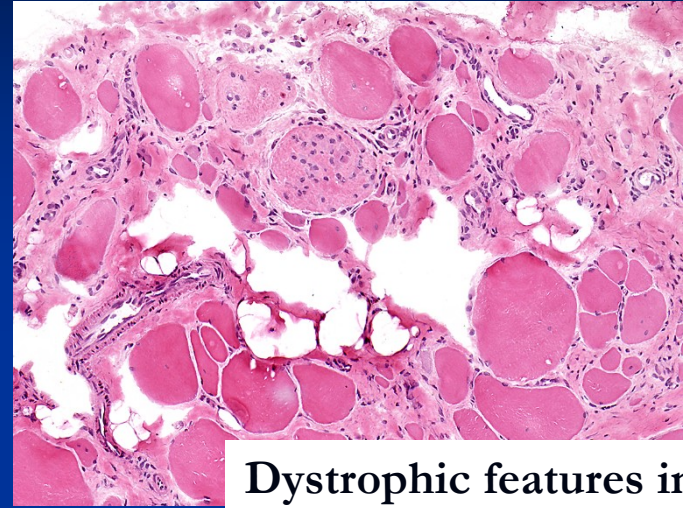
Clinical and pathological features of the major connective tissue diseases

Disease	F:M	Age at onset	Clinical features	Immune abnormality	Pathology
Poly- and dermatomyositis	3:1	Adults (DM also in children)	Muscle weakness, pain, tenderness, skin rashes in DM	Myositis assoc. autoAb	Inflammatory myositis, in some cases paraneoplastic
Polymyalgia rheumatica	2:1	Elderly	Malaise, weakness, muscle aching, esp. shoulders, pelvis, hips	No consistent changes Raised ESR	Non specific muscle biopsy changes, some overlap with temporal arteritis
Temporal, giant cell arteriis	2:1	Elderly	Headache Visual loss Tender scalp	No consistent changes Raised ESR	Chornic granulomatous arteritis, head and neck arteries
Systemic sclerosis (scleroderma)	3:1	30-50 years	Raynaud's phenomenon Thick skin Polyarthritits Dysphagia. Dyspnoe. Hypertension	RF (25 %) Antinuclear Ab (50 %)	Fibrosis of subcutaneous and submucosal tissue, fibrosis of muscular arteries

Muscle biopsy



Lobulated fibers in LGMD2A



Dystrophic features in biopsy

- Specialized laboratories in departments of pathology (FN Motol)
- Guided using imaging and results of clinical assessment
- Open versus needle biopsy
- Standard histological techniques, enzyme histochemistry
- Immunohistochemistry and immunoblotting
 - panel of antibodies
 - evaluation of primary and secondary changes on immunoanalysis
- Direction of reasonable mutational analysis

Neuromuscular disorders

- **Neurogenic disorders – neurogenic atrophy**
- **Disorders of neuromuscular transmission**
- **Myogenic disorders**
 - Muscular dystrophies
 - Congenital structural myopathies
- **Inflammatory myopathies – myositis**
- **Myopathies associated with metabolic diseases**
 - Glycogenosis (glycogen storage diseases)
 - Carnitine deficiency
 - Mitochondrial disorders
- **Others**
 - myopathies in endocrinopathies (thyreotoxic and hypothyreoid myopathy, steroid myopathy,...)
 - drug induced myopathy (steroid myopathy, myopathy in patients treated with hydrochloroquine,...)
 - ethanol myopathy

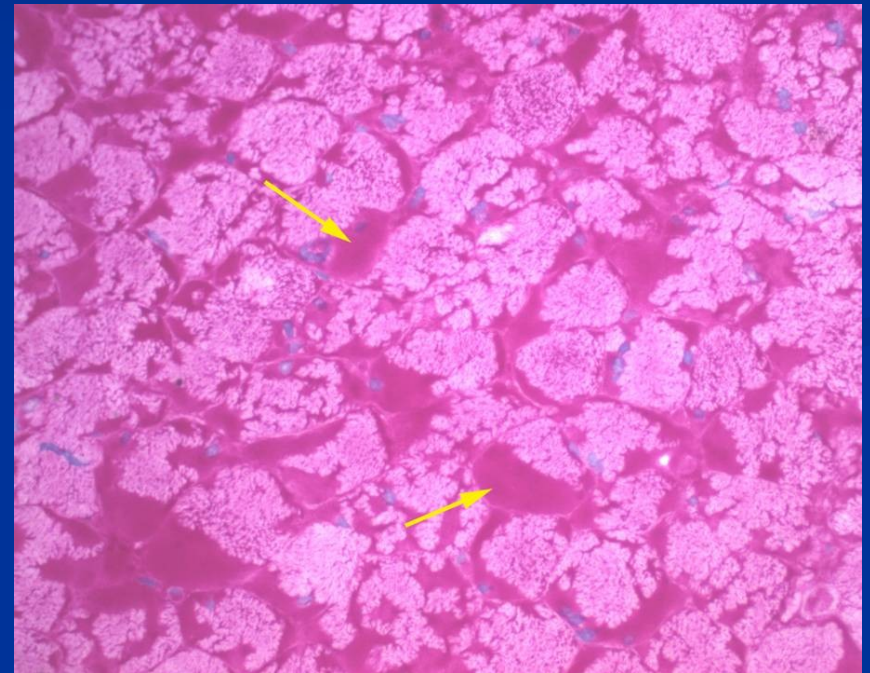
Myopathies associated with inborn errors of metabolism (1)

Glycogen storage disease

- Type IIa ; AR, Pompe´s disease; acid maltase deficiency
- Typ IIb; XR, X linked vacuolar cardiomyopathy and myopathy ; Danon´s disease, LAMP 2 deficiency (lysosome associated membrane protein)
- Typ IV; AR, Andersen´s disease; brancher enzyme deficiency
- Typ V; AR, McArdle´s disease; muscle phosphorylase deficiency
- Typ III (debrancher deficiency), Typ VII (phosphofruktokinase deficiency)

Storage of glycogen in muscles in glycogenosis (inherited; AR)

- PAS+ (glycogen)



PAS

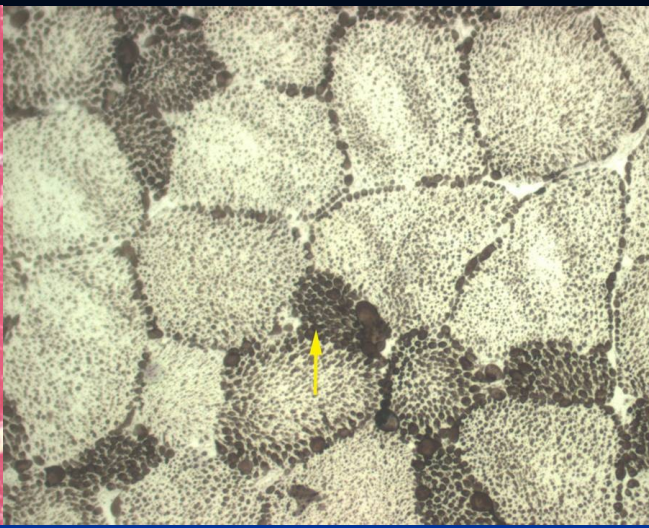
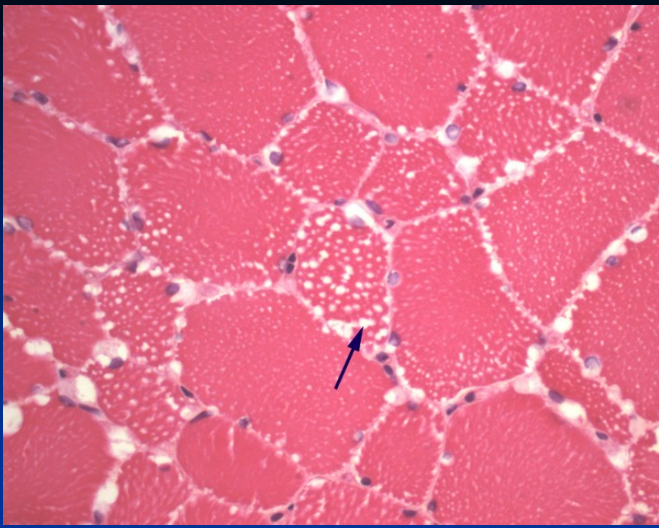
Myopathies associated with inborn errors of metabolism (2)

■ Lipid myopathies

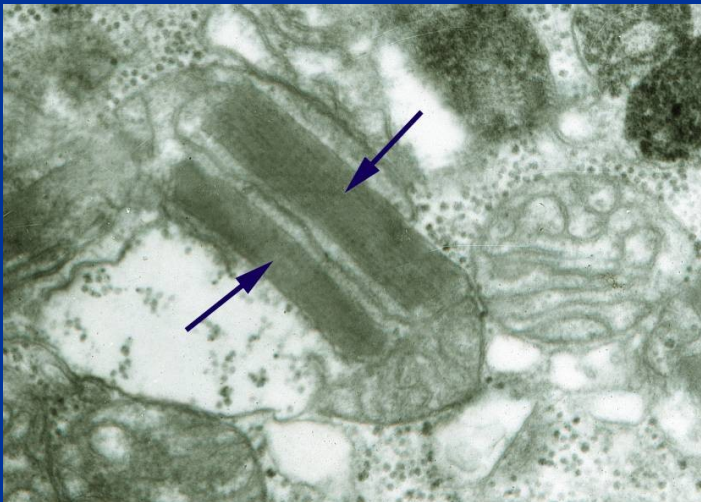
- carnitine palmitoyl-transferase deficiency
- carnitine deficiency

■ Mitochondrial myopathies (oxidative phosphorylation diseases)

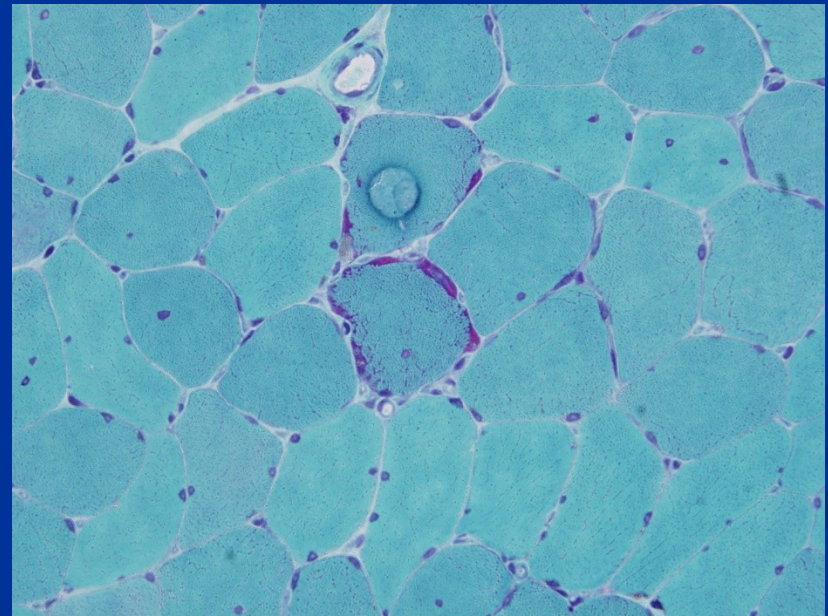
(mt DNA, nuclear DNA)



Carnitine palmitoyl-transferase deficiency: accumulation of neutral lipids



Mitochondrial myopathy:
lamellar mitochondrial inclusion



Ragged red fiber in mitochondrial myopathy

Neurogenic disorders (denervation atrophy)

■ Motor neuron diseases

- Amyotrophic lateral sclerosis
- Spinal muscular atrophy

■ Radiculopathies

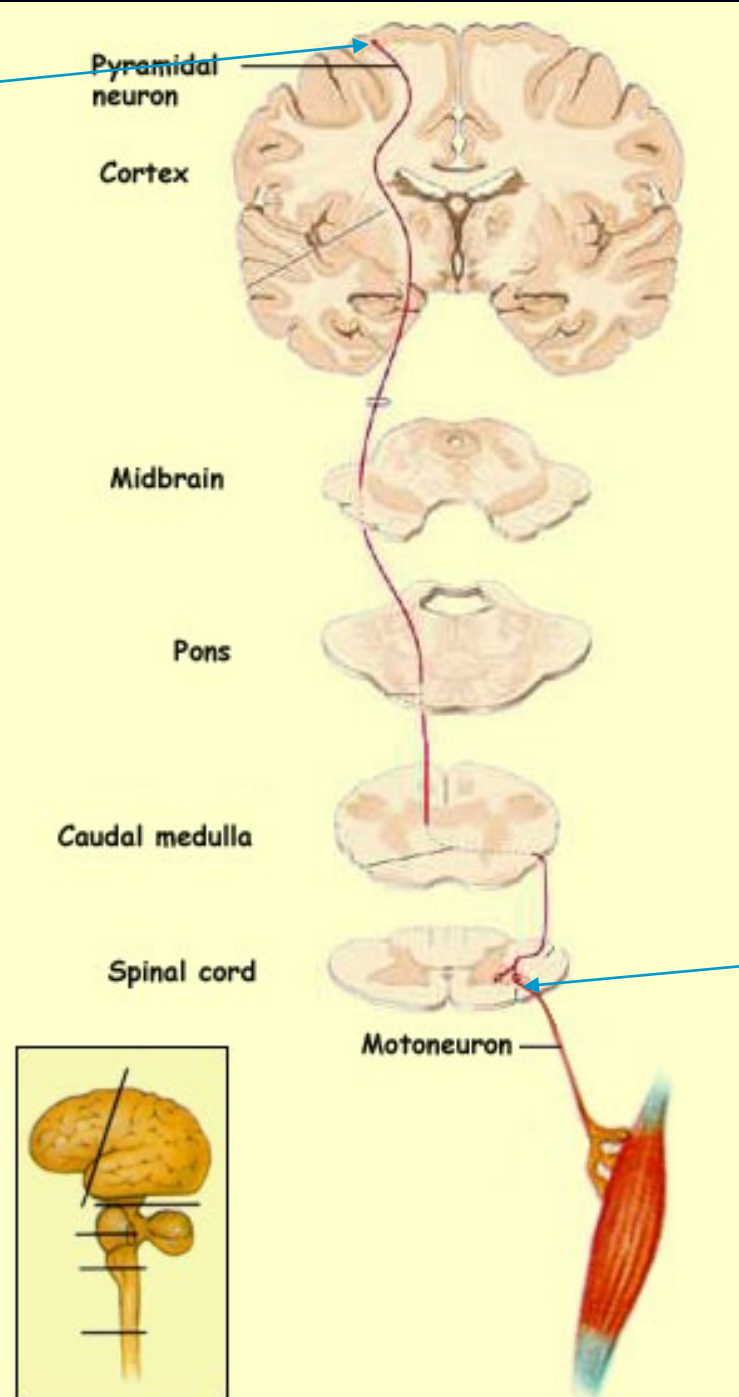
- discopathies
- extramedullar tumors
- polyradiculoneuropathy-immune mediated-Guillain-Barré syndrome – demyelinating disorder

■ Damage of peripheral nerves/peripheral neuropathies

inflammatory, traumatic, metabolic (diabetic), toxic, genetic (hereditary motor and sensory neuropathies), neoplastic

Upper motoneuron

Motor neuron tract

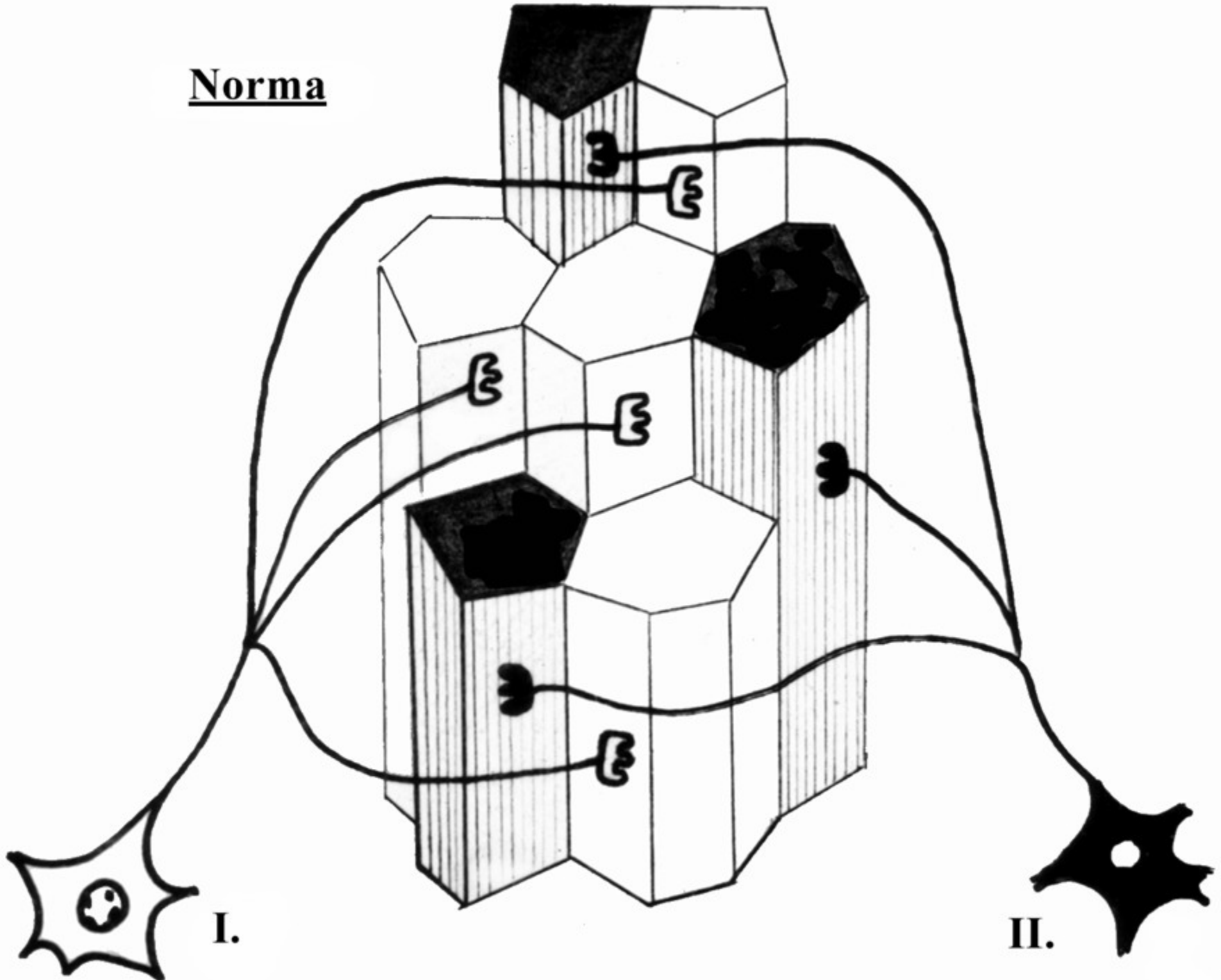


Lower motoneuron

Types of muscle fibers

reaction	1 (SO) Slow oxidative	2A (FOG) Fast oxidative glycolytic	2B (FG) Fast glycolytic
mATPasa (pH 9,4)	-	+	+
mATPasa (pH 4,6)	+	-	+
mATPasa (pH 4,3)	+	+/-	-
NADH-TR and SDH	+	+/-	-

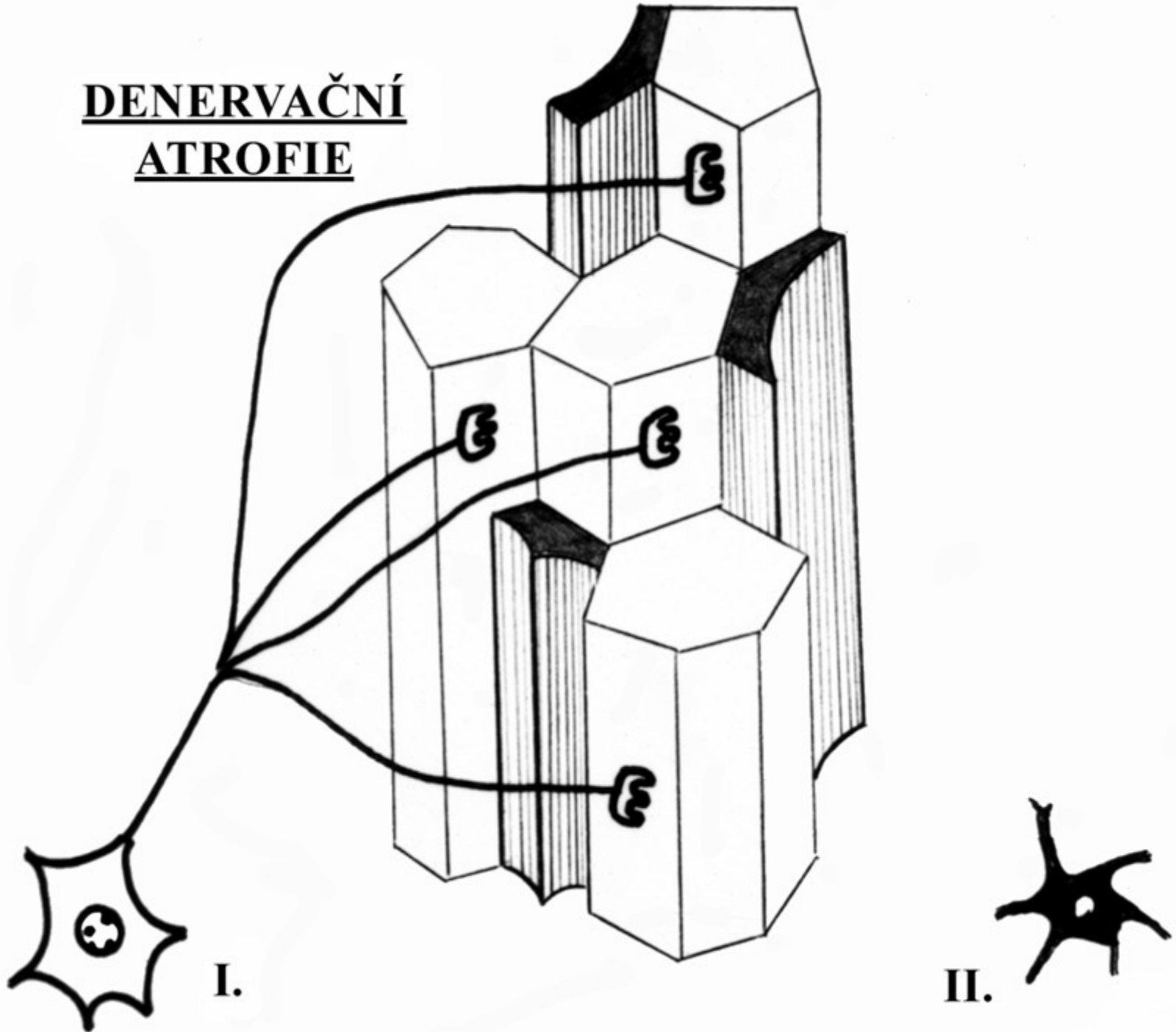
Norma



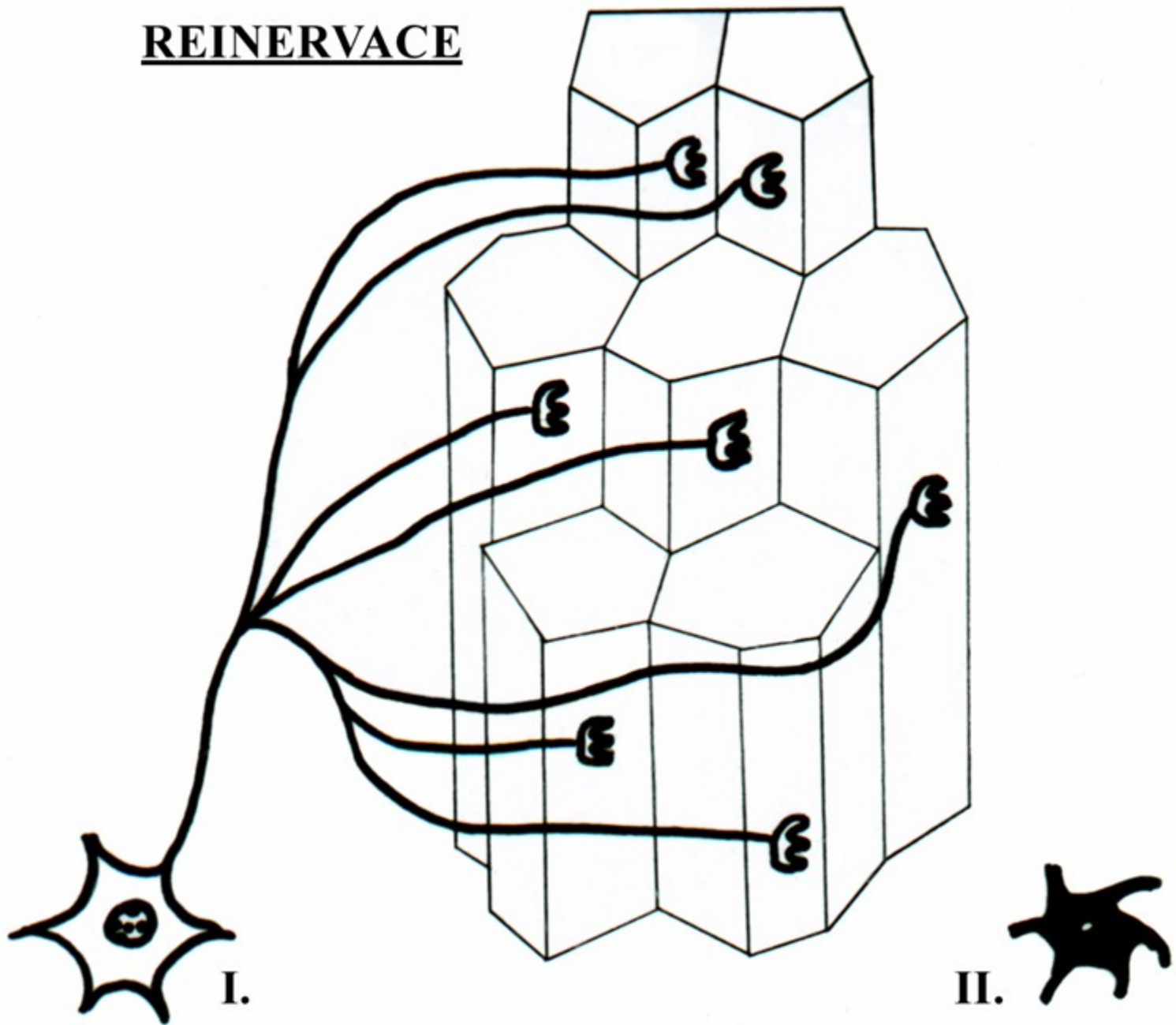
I.

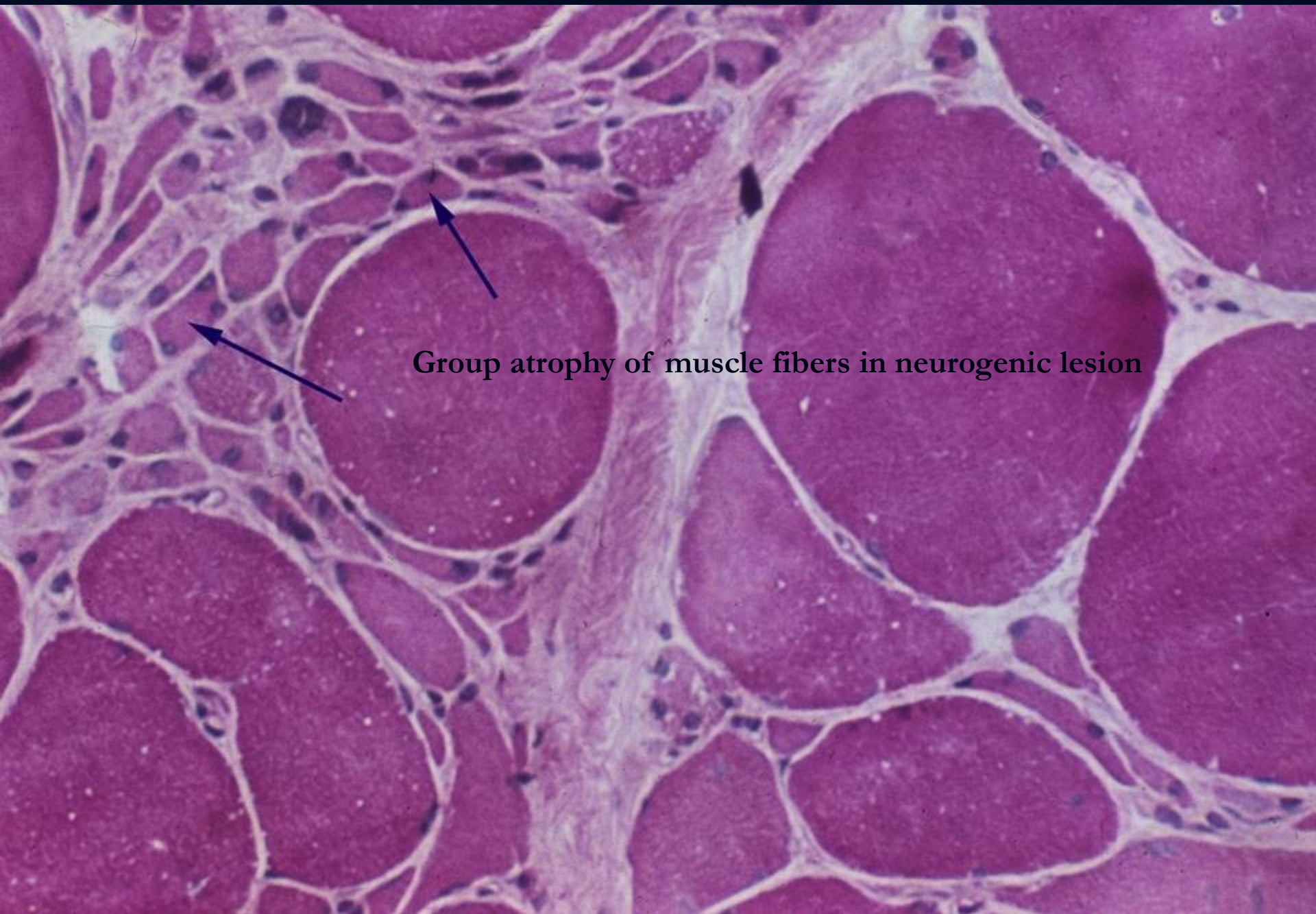
II.

DENERVAČNÍ ATROFIE

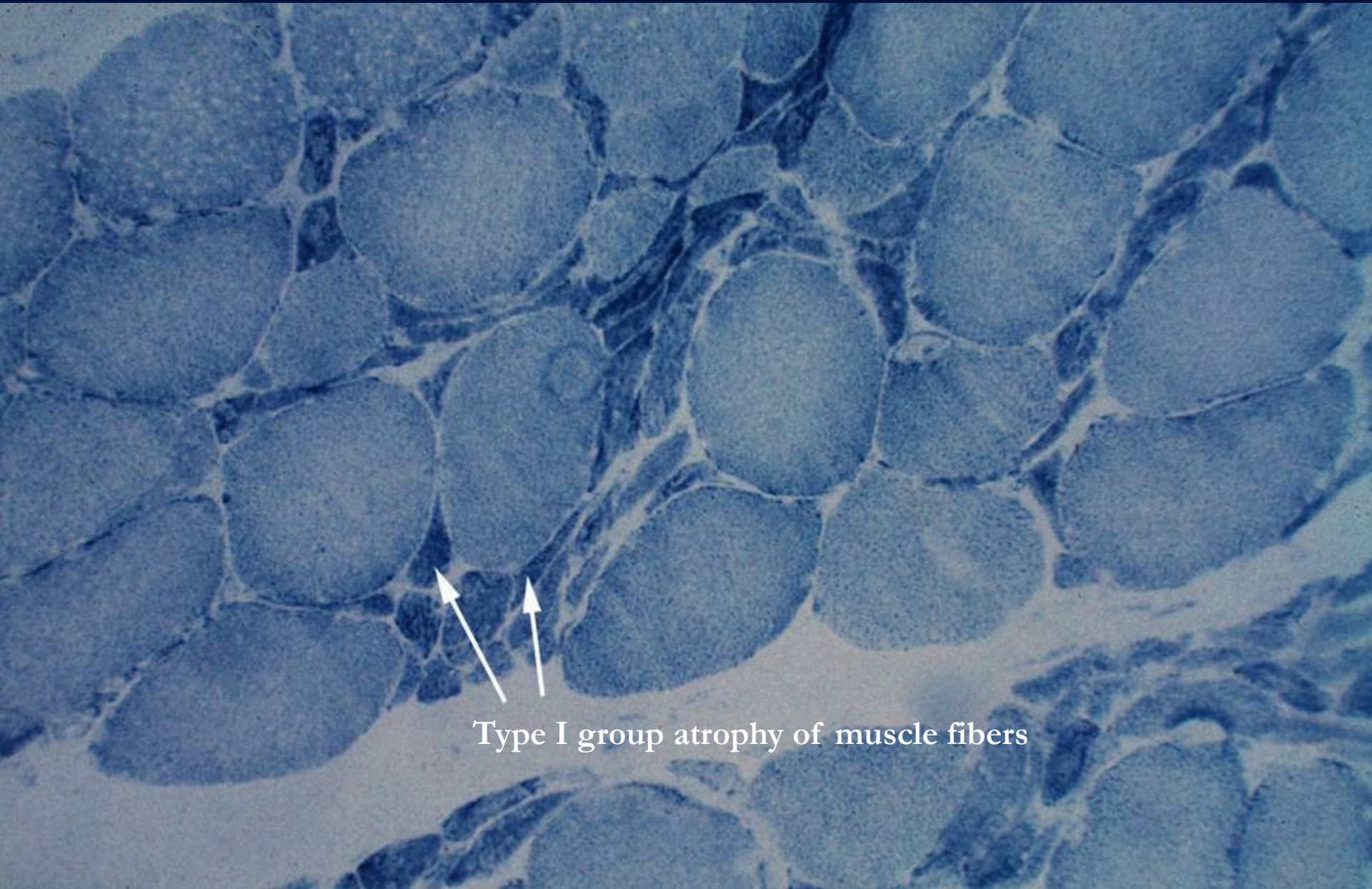

REINERVACE





Group atrophy of muscle fibers in neurogenic lesion



Type I group atrophy of muscle fibers

Motor neuron diseases

- **Amyotrophic lateral sclerosis**

(both upper and lower motorneurons affected, distal and proximal muscle weakness and wasting spasticity)

- **Progressive muscular atrophy**

(lower motor neuron involvement, weakness and wasting of distal muscles, fasciculations and absent reflexes)

- **Progressive bulbar palsy**

(cranial nerves involvement results in weakness of the tongue, palate, pharyngeal muscles)

Amyotrophic lateral sclerosis

- **90 % sporadic ALS**

- M:F – 1,7:1

- older people, survival 3-4 years, first symptoms in 56-63 years, upper extremities preferentially affected, bulbar symptomatology

- **10 % hereditary ALS**

- 4th decade, juvenile forms, F:M – 1:1

Spinal muscular atrophy

- Inherited; AR; homozygous loss of SMN1 (survival motor neuron gene)
- occurring in 1/6000-10000 births; 2-3 % of populations are carriers
- 2nd most common inherited disorder after cystic fibrosis (mucoviscidosis)

Allelic variants of SMA

■ Type 1 (Werdnig-Hoffmann disease)

- Rapidly progressive, onset before 3 months of age, death before the age of 18 months

■ Type 2

- Onset between 6-12 months of age, more slowly progressive with variable life expectancy

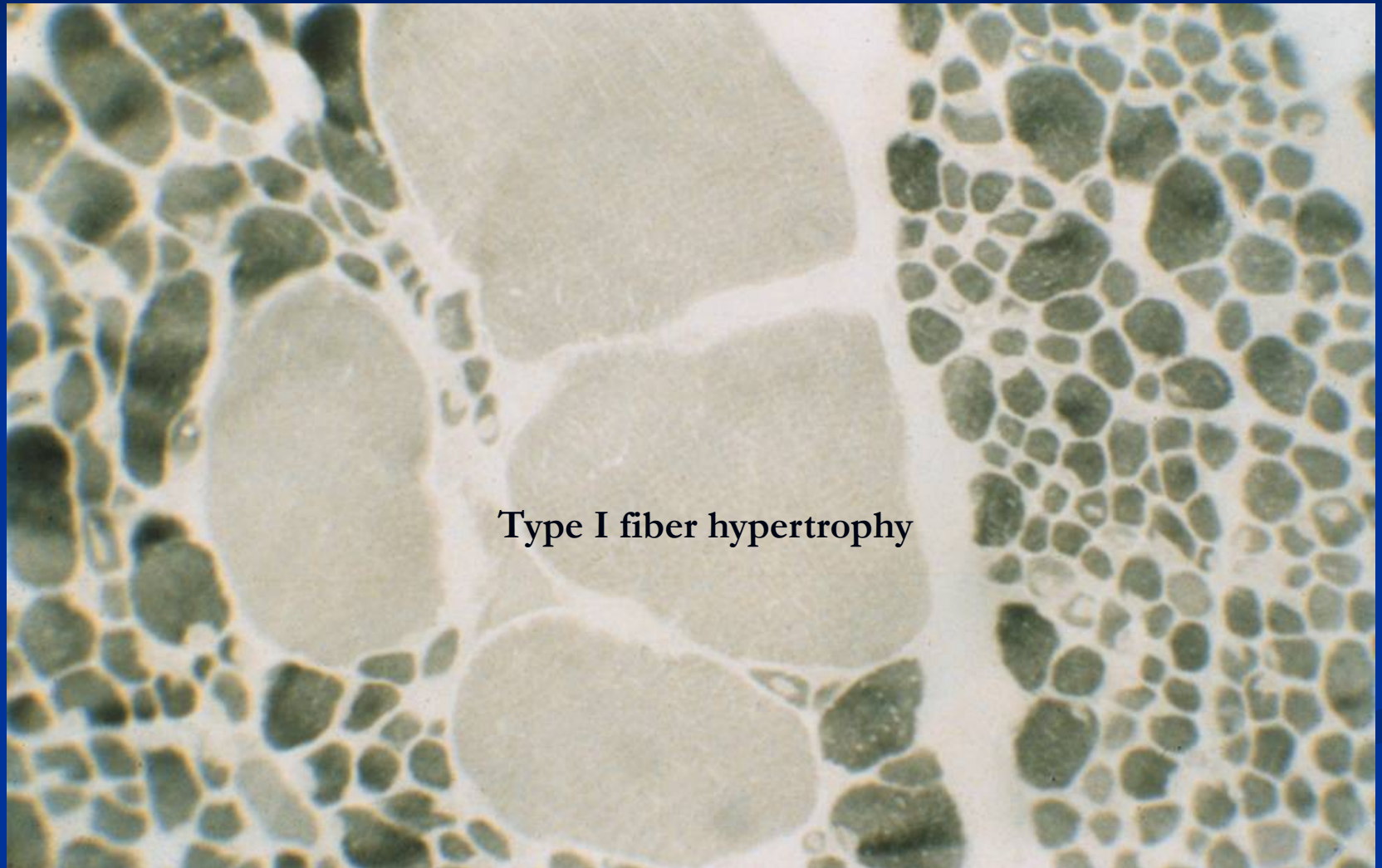
■ Type 3 (Kugelberg-Welander disease)

- Onset between 2-15 years of age, slowly progressive

■ Type 4

- Affects adults, very slow course causing mild disability

Spinal muscular atrophy



Peripheral neuropathy: peripheral nerve disorders

■ **Mononeuropathy**

- a single nerve involved
- e.g. carpal tunnel syndrome

■ **Mononeuritis multiplex**

- several isolated nerves involved
- e.g. polyarteritis nodosa, sarcoidosis

■ **Polyneuropathy: multiple nerve involvement**

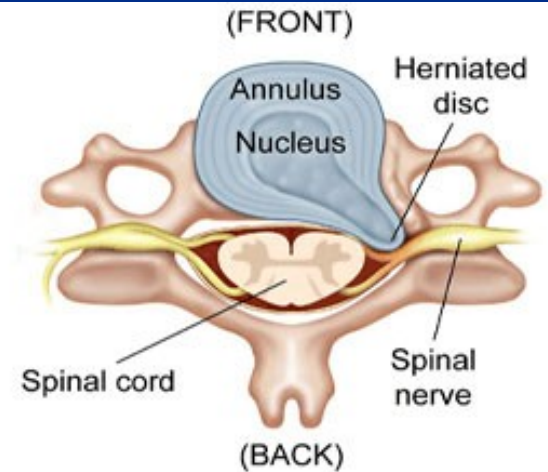
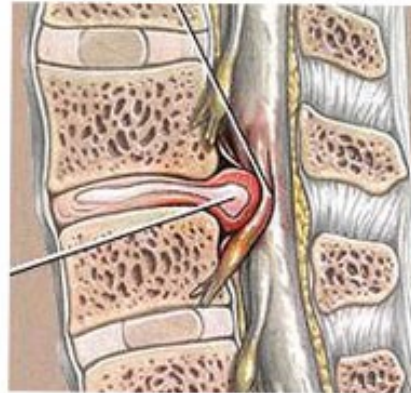
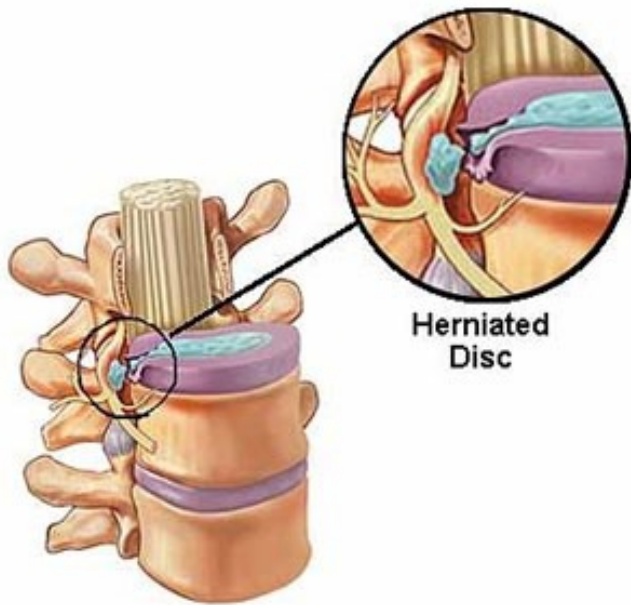
■ **Mainly motor:** e.g. Guillain-Barre sy (autoimmune polyradiculoneuritis)

■ **Mainly sensory:** carcinomatous neuropathy

■ **Sensorimotor:** e.g. alcoholism

■ **Autonomic:** e.g. diabetes

Intervertebral disc prolapse



Disorders of neuromuscular transmission

■ Myasthenia gravis

- autoimmune disease, loss of acetylcholine receptor due to production of autoAb
- fluctuating progressive muscle weakness (ocular, bulbar and proximal limb muscles preferentially affected)
- females more often affected
- thymic hyperplasia or thymoma in many patients
- immunosuppressive treatment and thymectomy

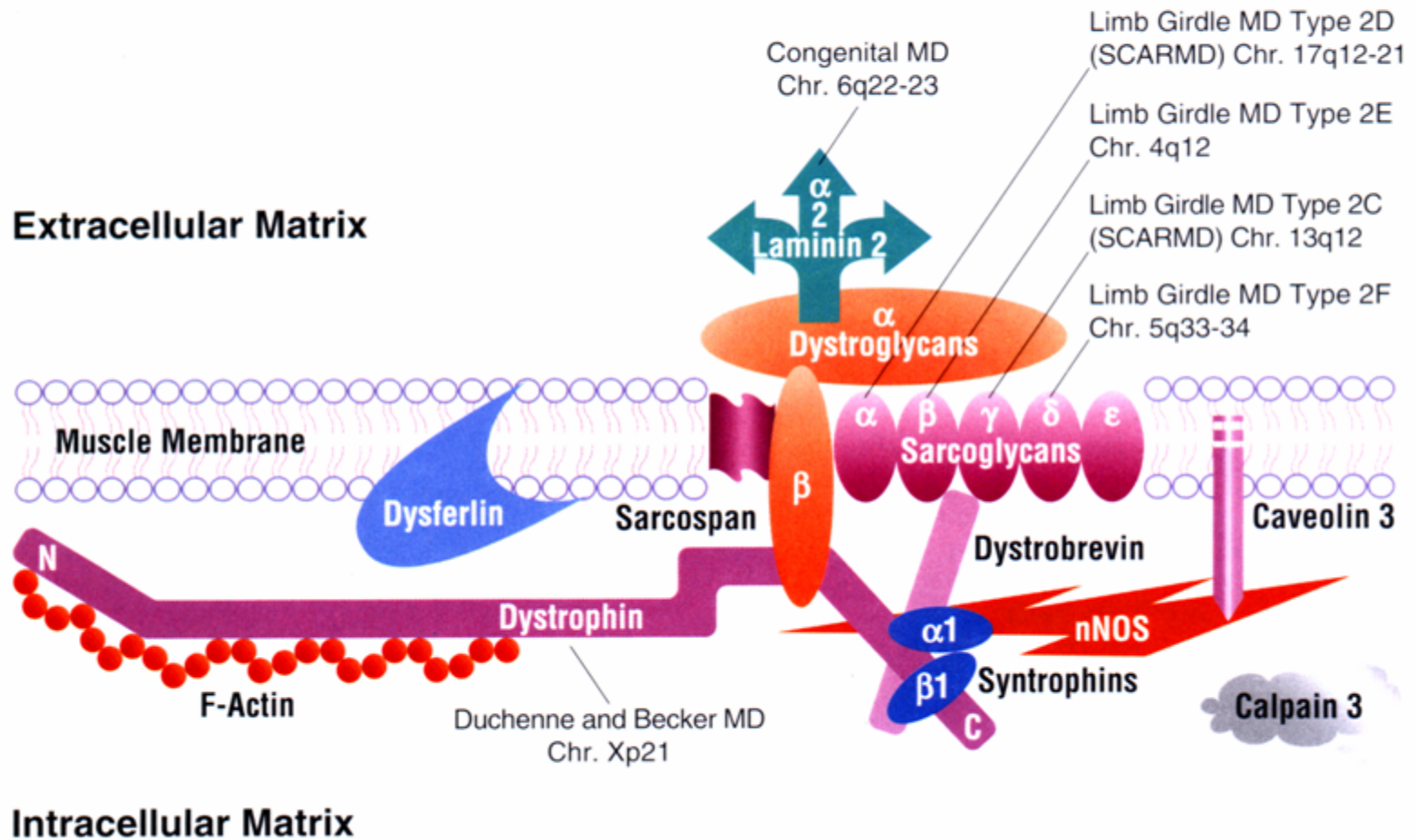
■ Lambert-Eaton myasthenia syndrome

- paraneoplastic, complication of malignancy (e.g. lung cancer – small cell carcinoma)
- limb girdle and proximal muscle weakness
- autoimmunity to calcium channels???

Muscular dystrophies

- heterogeneous group of inherited disorders of muscles
- progressive muscle weakness and wasting
- „dystrophic“ muscle biopsy changes and replacement of muscle by fibrofatty tissue
- defects in muscle proteins
- clinical and genetic heterogeneity
- some are associated with multisystem involvement (including cardiac (arrhythmias, both dilated and hypertrophic cardiomyopathies) and CNS)

Dystrophin Associated Proteins and their Involvement in Muscular Dystrophy



A schematic diagram illustrating the arrangement of dystrophin, dystrophin associated proteins and their link to different muscular dystrophies.

Muscular dystrophies

- **Dystrophinopathies (X-linked)**
- **Limb-girdle muscular dystrophies; LGMDs (AR, AD)**
- **Emery-Dreifuss muscular dystrophy (X-linked, AD)**
- **Facioscapulohumeral muscular dystrophy (AD)**
- **Congenital muscular dystrophy (AR)**
- **Oculopharyngeal muscular dystrophy (AD)**
- **Distal myopathy (AR, AD)**
- **Bethlem's myopathy (AD)**
- **Barth's syndrome (X-linked)**
- **Myotonic dystrophy (AD)**

Diagnosis of muscular dystrophies

■ **Clinical assessment**

- general neurological examination
- serum creatine kinase (CK) level
- neurophysiology – electromyography (exclusion of neuropathy)
- muscle imaging (MRI, CT)

■ **Muscle biopsy (2/3 genetically defined LGMD are suggested by biopsy)**

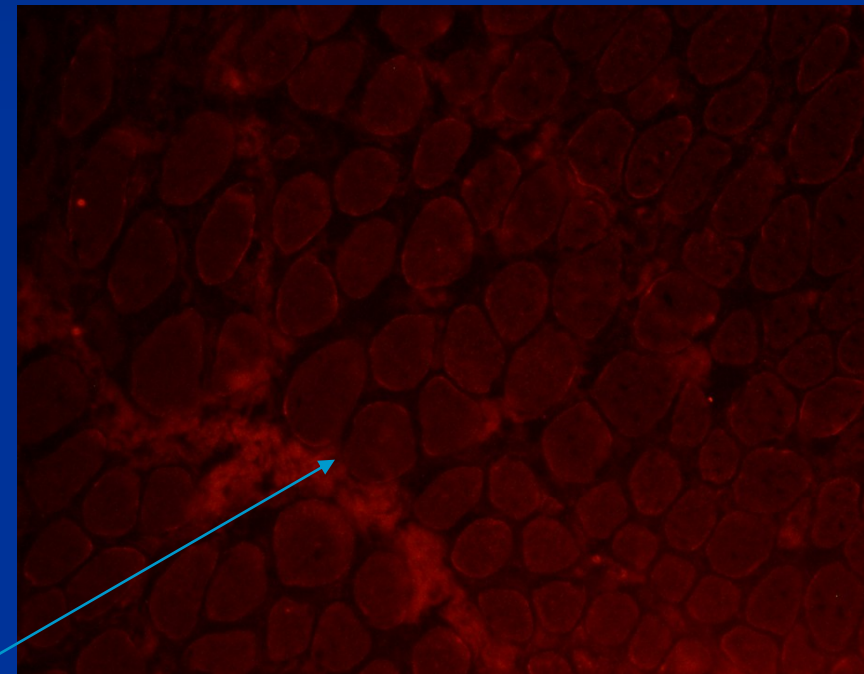
- histopathology
- immunohistochemistry (IH), immunofluorescence (IMF)
- immunoblotting

■ **Molecular genetic testing – mutational analysis (the gold standard for diagnosis)**

- DNA
- mRNA

Duchenne muscular dystrophy (DMD)

- Due to severe mutations in dystrophin gene
- X-linked; female carriers
- Median age of presentation: 3.5 years; progressive course; life expectancy 20 years; calf pseudohypertrophy
- Myogenic lesion in muscle biopsy, loss of dystrophin



immunofluorescence, loss of dystrophin in DMD

Becker muscular dystrophy (BMD)

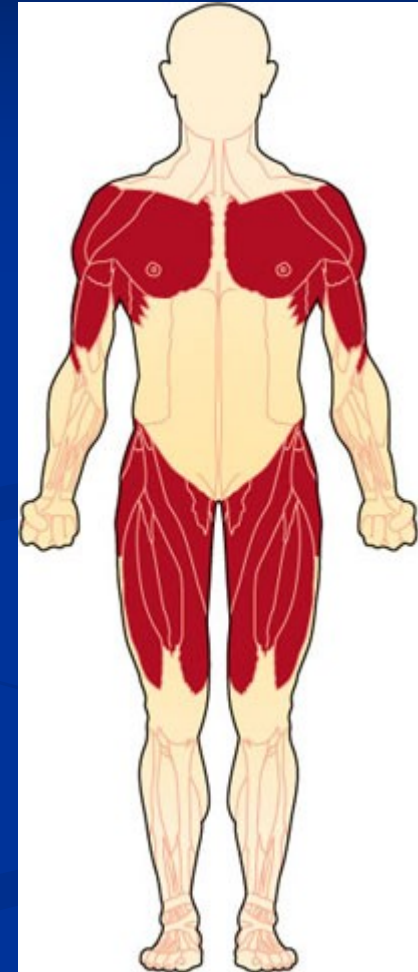- Due to in-frame deletion in dystrophin gene
- Milder allelic variant of DMD
- Truncated protein dystrophin is produced

Female carriers of DMD/BMD

- Symptomatic
- Asymptomatic

Limb-girdle muscular dystrophies

- Genetically and clinically heterogeneous group of progressive muscular dystrophies
- Muscles of the pelvic and shoulder girdle are preferentially affected
- 25 forms autosomal recessive (at least)
- 8 forms autosomal dominant
- + AR, AD and X-linked muscular dystrophies with LGMD phenotype



Classification of autosomal recessive LGMD (14)

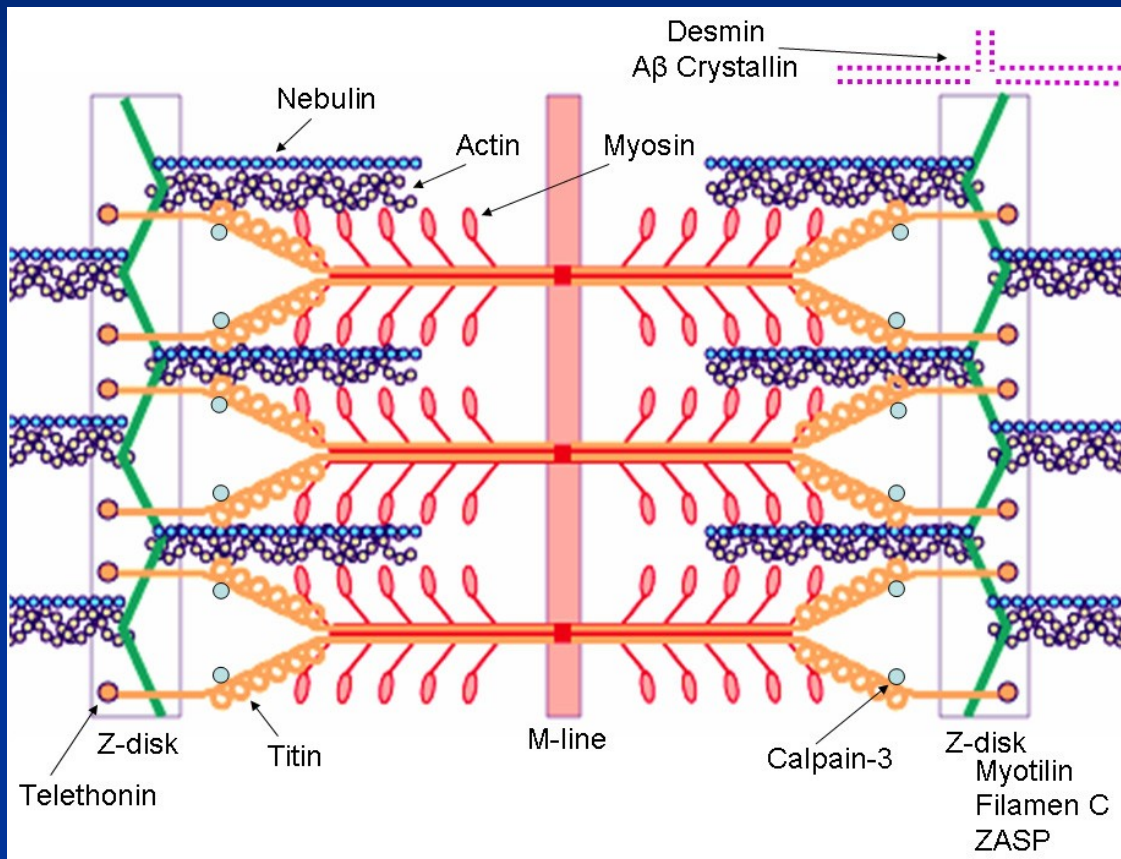
Disease	Protein	Gene	Relative prevalence
LGMD2A	Calpain 3	<i>CAPN3</i>	worldwide (WW); eastern Europeans
LGMD2B	Dysferlin	<i>DYSF</i>	southern>northern Europe; Australia
LGMD2C	γ -Sarcoglycan	<i>SGCG</i>	WW, most frequent in Tunisia
LGMD2D	α -Sarcoglycan	<i>SGCA</i>	WW; most frequent sarcoglycanopathy
LGMD2E	β -Sarcoglycan	<i>SGCB</i>	northern and southern Indiana Amish
LGMD2F	δ -Sarcoglycan	<i>SGCD</i>	common in African-Brazilian
LGMD2G	Telethonin	<i>TCAP</i>	rarely outside Brasil
LGMD2H	TRIM32	<i>TRIM32</i>	Hutterite population of Canada
LGMD2I	Fukutin-related protein	<i>FKRP</i>	Northern Europe (826C>A)
LGMD2J	Titin	<i>TTN</i>	Only in Finland
LGMD2K	O-Mannosyl transferase-1	<i>POMT1</i>	Few cases in Turkey and England
LGMD2L	Anoctamin 5	<i>ANO5</i>	French-Canadian family
LGMD2M	Fukutin	<i>FKTN</i>	5 families
LGMD2N	O-Mannosyl transferase-2	<i>POMT2</i>	Few reported

+ 11 recently described AR LGMD.....

Classification of autosomal dominant LGMD (8)

Disease	Protein	Gene	Relative prevalence
LGMD1A	Myotilin	<i>MYOT</i> 5q22-q34	> 15 families described
LGMD1B	LaminA/C	<i>LMNA</i> 1q11-q21	Clinical syndromes: Emery-Dreifuss MD, LGMD1B, CMD with rigid spine, neuropathy (AR-CMT2A), quadriceps myopathy with dilated cardiomyopathy, Familial partial lipodystrophy, Mandibuloacral dysplasia, premature aging, lethal phenotype.
LGMD1C	Caveolin-3	<i>CAV3</i> 3p25	Clinical syndromes: LGMD1C, rippling muscle disease, idiopathic hyperCKaemia, distal myopathy
LGMD1D	?	7q	2 families described
LGMD1E	?	6q23	1 large family described: French Canadian descent
LGMD1F	?	7q32	1 large family described: Spanish
LGMD1G	?	4p21	1 family described: Brazilian-Caucasian
LGMD1H	?	3p23	1 family described: Southern Italian family

Sarcomere associated proteins



Telethonin: LGMD2G

Myotilin: LGMD1A

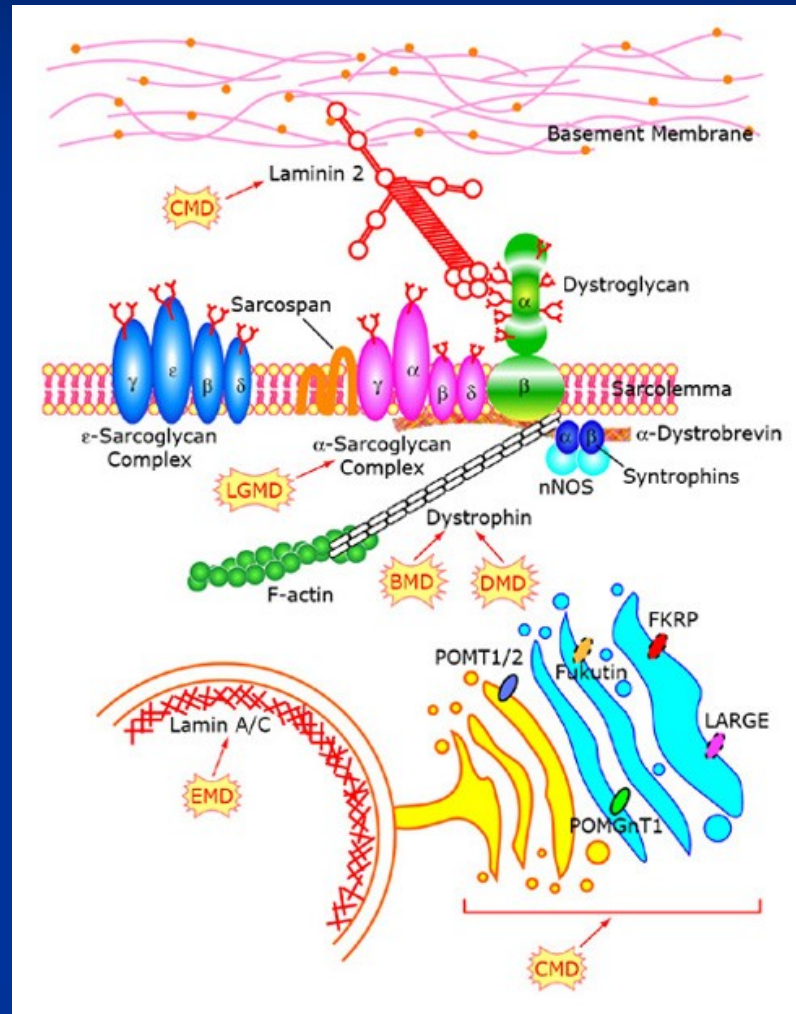
Titin: LGMD2J

Sarcolemmal proteins.

Nuclear lamina structural complex.

Glycosyltransferases.

Sarcoglycans: LGMD2C-2F
Caveolin-3: LGMD1C
Dysferlin: LGMD2B
Lamin A/C: LGMD1B
FKRP: LGMD2I
POMT1: LGMD2K
POMT2: LGMD2N
Fukutin: LGMD2M

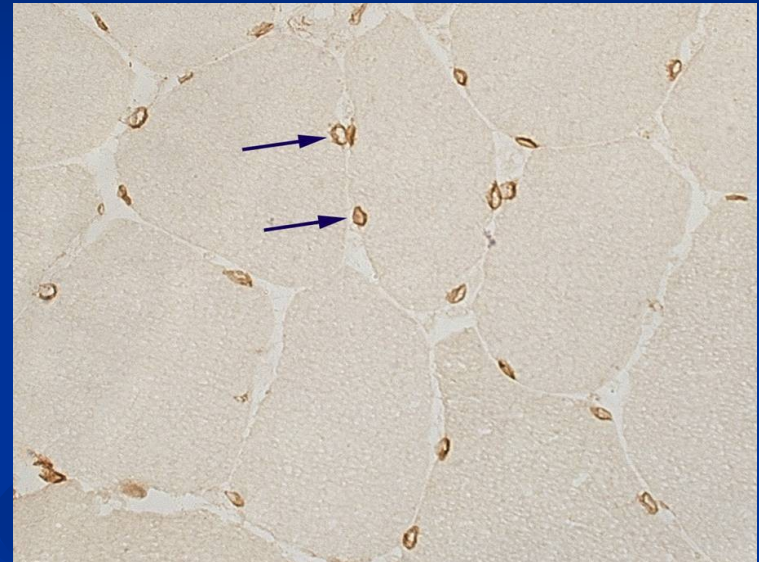


Emery-Dreifuss muscular dystrophy

- contractures
- slight progressive myopathy preferentially in humeroperoneal localisation
- arrhythmias
- mild myogenic lesion in muscle biopsy

X-EDMD (Xq28): emerin

AD (resp. AR)-EDMD (11q11-23): lamin A a C



IHC, normální exprese emerinu na jaderné membráně

Congenital muscular dystrophies (CMD)

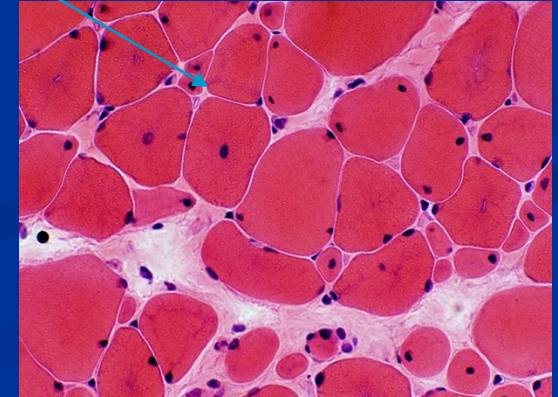
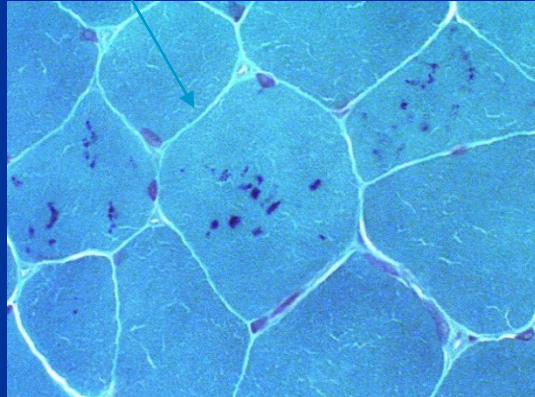
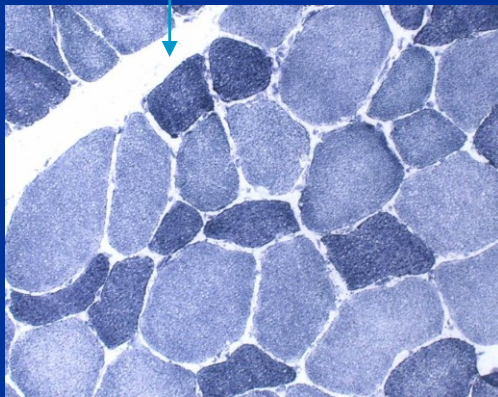
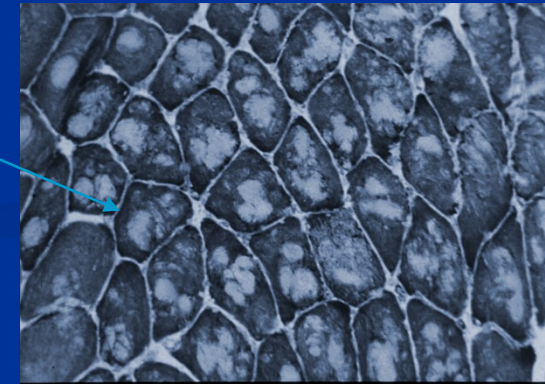
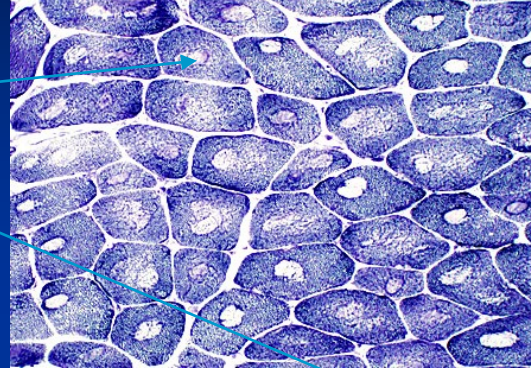
- Congenital, presented at birth, progressive
- Inherited, AR, genetically and phenotypically heterogeneous
- Muscle weakness, hypotonia, contractures; in some subtypes structural lesions of CNS and retina
- 40% of CMD: merosin deficient form (MDC1A); mutations in LAMA2 gene (α2 chain of merosin)
- Glycylglycanopathies – mutations in genes encoding glycosyltransferases of α-dystroglycan (FCMD, MDC1C, MEB, WWS, MDC1D)
- muscle biopsy: myogenic lesion, often degeneration, regeneration, and also inflammatory pattern in muscle biopsy

Congenital structural myopathies

- A distinctive abnormality in skeletal muscle fibres on the cellular level; observable via light microscope
- Symptoms of muscle weakness and hypotonia.
- Is a congenital disorder, meaning it occurs during development and symptoms present themselves at birth or in early life.
- Is a genetic disorder
- Clinically and genetically heterogeneous

Congenital structural myopathies

- Central core disease
- Multi and minicore disease
- Nemaline myopathy
- Centronuclear myopathy
- Congenital fibre type disproportion



Inflammatory myopathies -myositis

■ Polymyositis

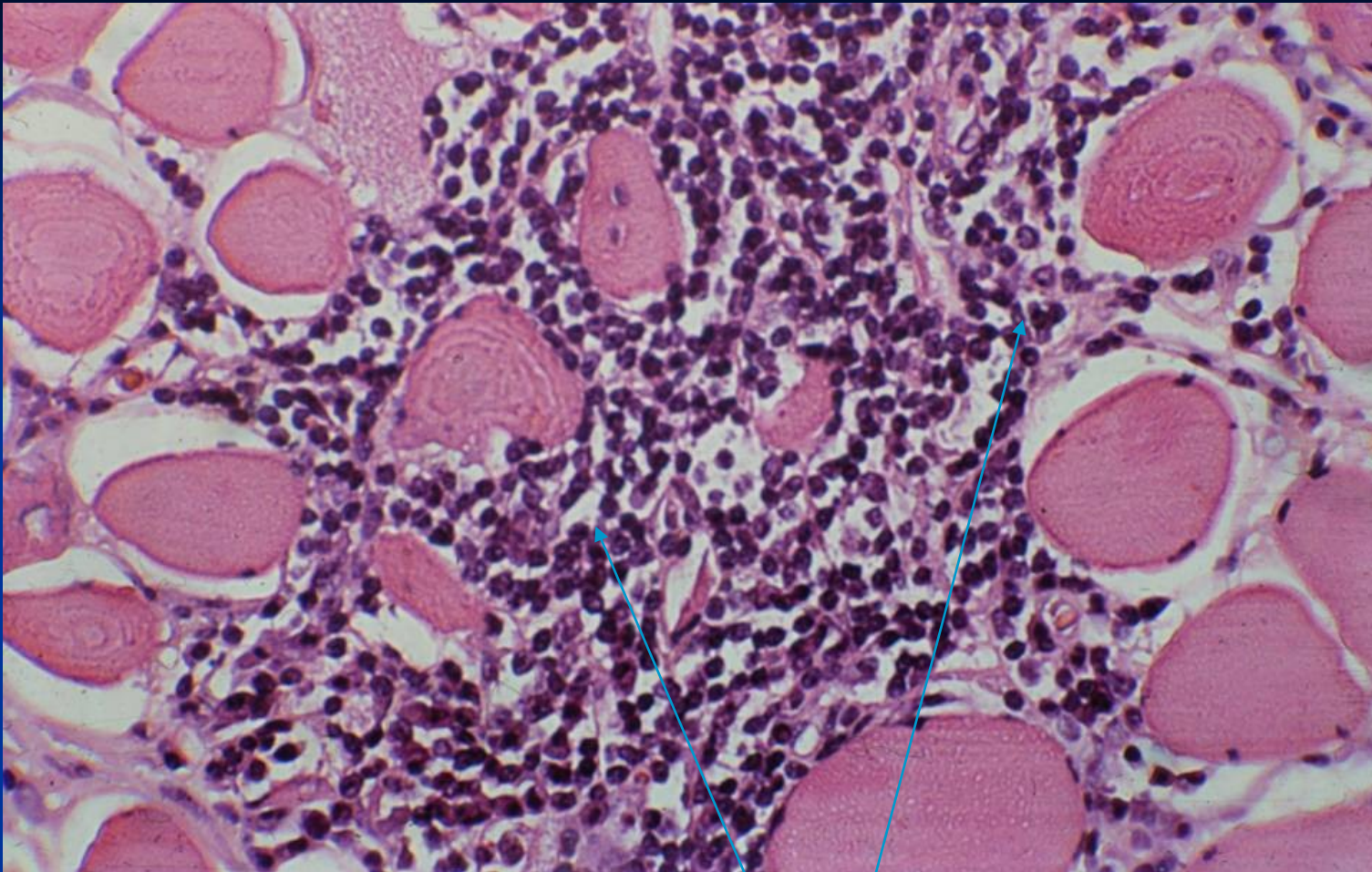
- females, autoimmune disease, ofted associated with other autoimmune diseases (anti-Jo-1 protilátky)
- Endomysial inflammatory infiltration

■ Dermatomyositis

- Juvenile and adult, more in females, dermatitis and myopathy
- Perivascular inflammatory infiltration (CD20+, CD4+, MAC+)
- Perifascicular atrophy

■ Myositis/myopathy with inclusion bodies

- Sporadic and hereditry
- Resistent to imunosupresive therapy



Polymyositis: endomysial lymphocytic inflammatory infiltration

Myotonia:

the sustained involuntary contraction of a group of muscles; patients complain of stiffness, difficulties in releasing their grip

1. Myotonia congenita (reduction of functional chloride channels)

- **Becker type (AR)**
- **Thomsen type (AD)**

2. Myotonic dystrophy

- **DM1 (AD; 19q13.3, myotonin proteinkinase)**
congenital (dementia, hypotonia), **classic** (myotonia, muscle weakness, atrophy, cataract, endocrinopathies), **milder form**
- **DM2 (AD; 3q21; zinc finger protein)- PROMM** – proximal myothonic dystrophy

Malignant hyperpyrexia

- Inherited disorder; AD; diagnostic *in vitro* contraction test
- Mutation in ryanodin receptor gene; association with central core disease
- Hypermetabolic state triggered by the induction of anesthesia, usually with halogenated inhalational agents and succinylcholine
- Tachycardia, tachypnoe, muscle spasms, hyperpyrexia; without intensive treatment fatal clinical outcome
- Channelopathy; increased levels of free calcium in sarcoplasm of myofibers

