

Nephropathology

V. Žampachová

I. ÚP

Anatomical remarks

- **Vessels** - 90% of blood flow through the cortex
- Afferent arteriole → glomerular capillaries → efferent arteriole → peritubular capillary plexus (from superficial glomeruli) or vasa recta for medulla (from juxtamedullary glomeruli)
- terminal arteries
- glomerular damage commonly leads to damage of peritubular blood flow – risk of ischemia

Possible clinical signs

- Weight gain, edema – fluid retention
- Thirst – chronic renal failure, DM
- Fatigue – acute/chronic renal failure (RF)
- Fever – urinary tract infection (UTI)
- Headache – hypertension, RF
- Hematuria – UTI, glomerulonephritis, tumor, stone
- Polyuria – DM, tubular disorders

Renal diseases commonly clinically silent!

Clinical features

- Diminished renal reserve – GFR \sim 50% of normal
- Renal insufficiency - GFR 20-50% of normal
- Azotemia – increase of blood urea and creatinine due to decreased glomerular filtration (20-30%), or extrarenal cause
- Uraemia - azotemia together with several clinical and biochemical abnormalities: metabolic, endocrine, ...
 - uremic gastroenteritis/colitis + IS dysregulation, malnutrition;
 - hypertension, fibrinous pericarditis, AS acceleration
 - pneumonia, pleuritis
 - dermatitis, itching
 - renal osteodystrophy, osteoporosis, muscle loss
 - peripheral neuropathy,

Clinical features

- Renal failure - GFR less than 20-25%, oedema, uraemia; causes: *prerenal, postrenal, renal (vascular, glomerular, tubulointerstitial)*; acute r.f. (oliguria→anuria) chronic r.f.
- End-stage renal disease - GFR less than 5% of norm
- Anuria <100ml/24hrs

Clinical features

- **Nephritic syndrome** due to acute glomerular disease; hematuria + mild proteinuria + hypertension; oliguria + azotemia + mineral dysbalance
- **Rapidly progressive glomerulonephritis** – very rapid (days - a few weeks) nephritic syndrome
- **Nephrotic syndrome**: usually chronic gl. dis., severe proteinuria (>3,5 g/d) + hypoalbuminemia/oedema + hyperlipidemia + lipiduria; possible ↑ infections (IgG loss)

Clinical features

- Asymptomatic hematuria and/or proteinuria – commonly mild glomerular lesion
- Polyuria + nocturia + electrolyte disorders – renal tubular defects
- Bacteriuria + pyuria – urinary tract infection (UTI)
- Renal colic + hematuria - nephrolithiasis

Renal diseases

- congenital anomalies
- glomerular diseases
- vascular diseases
- tubulointerstitial diseases
- tumors

Congenital anomalies

- 10% of all people
- hereditary or acquired developmental defect
- decreased volume of renal tissue (e.g. agenesis)
- disorders of differentiation (dysplasia)
- anatomical abnormalities (ectopy)
- metabolic disorders (cystinuria)

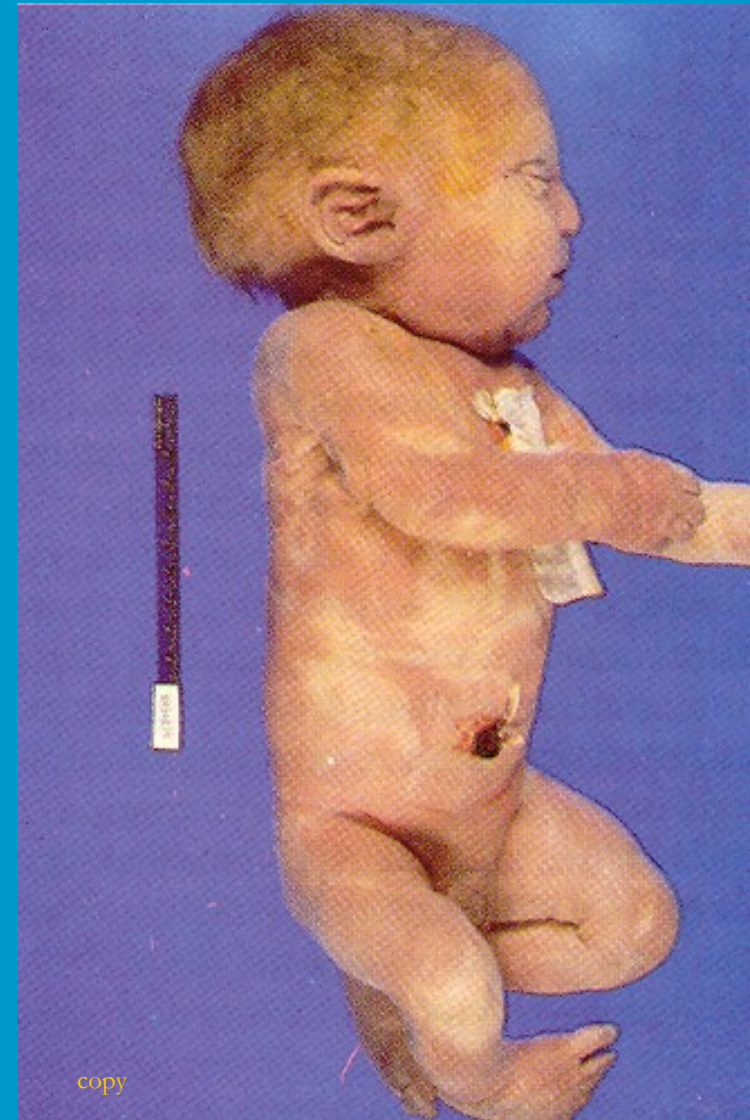Agenesis

- Bilateral agenesis – 1:6000, incompatible with independent life, usually stillborn, accompanied by characteristic appearance (Potter's syndrome), commonly associated with other congenital defects
- Unilateral agenesis – infrequent, the opposite kidney enlarged by compensatory hypertrophy

Oligohydramnion (Potter's syndrome)

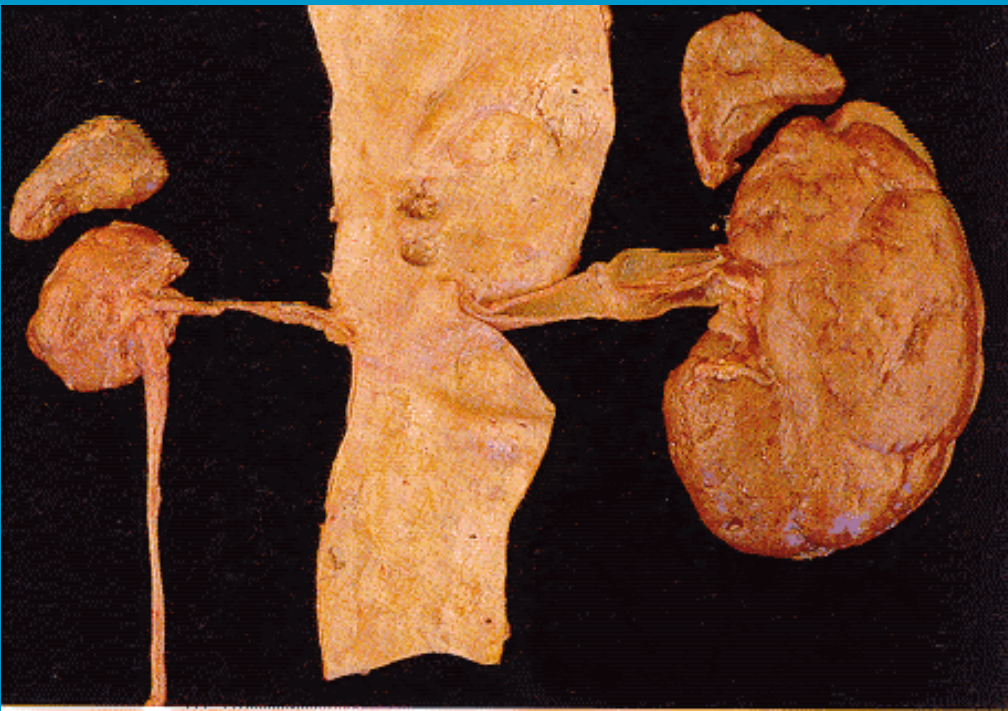
decreased amount of amniotic fluid (placental abnormalities, renal agenesis or malformation)

flat face, lung hypoplasia, limb deformities, ...



Hypoplasia

- Abnormally small kidneys (x atrophy)
- reduced number of lobes and pyramids



Renal ectopy

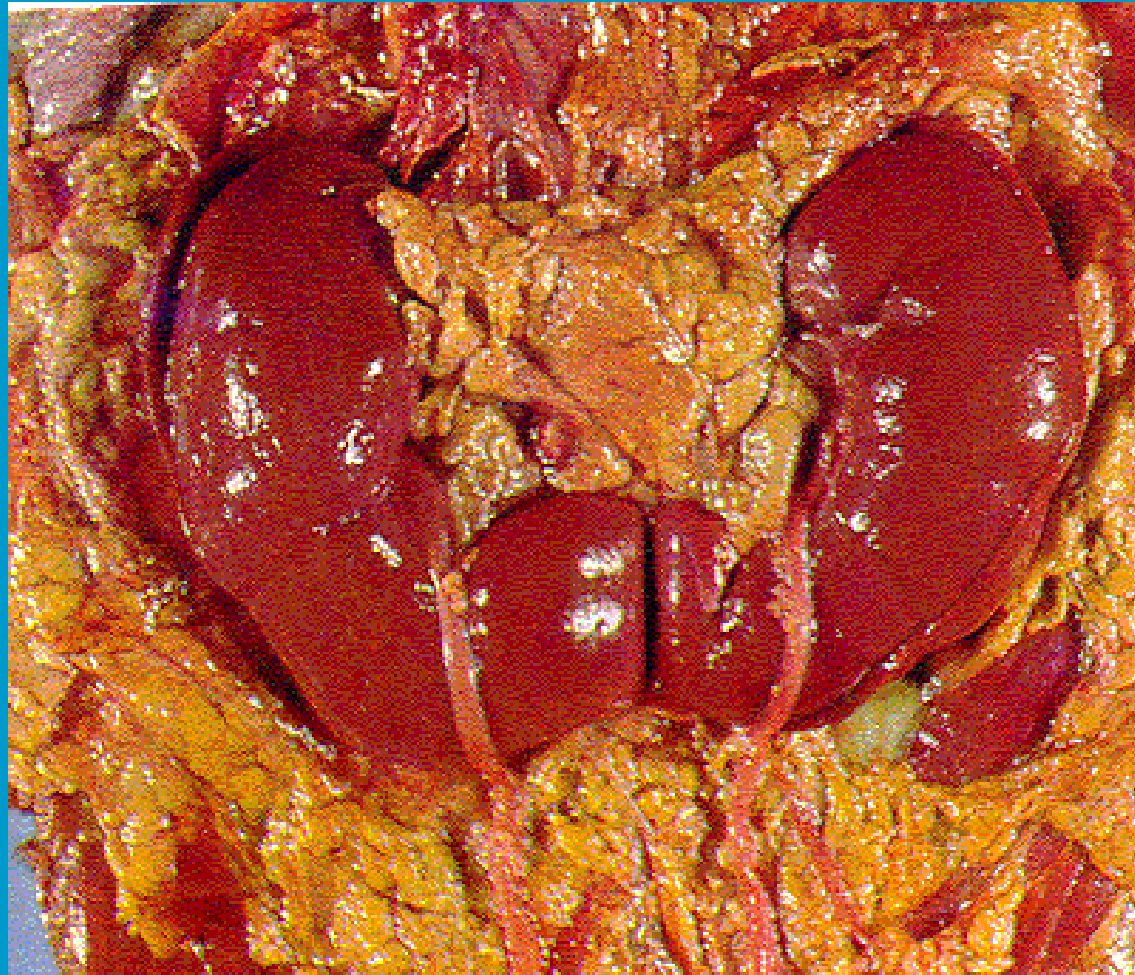
- Abnormal site, usually in pelvis, due to migration stop of the *metanephros*
- *A. renalis* - from lower aorta or *a. ilica communis*
- Short ureter

Ren migrans, ren mobilis

- Not a malformation, normal *a. renalis*
- Secondary renal descensus, usually due to loss of adipous capsule
- Long ureter, risk of obstruction and infection

Horseshoe kidney

- Renal pole fusion
- Ureteral obstruction

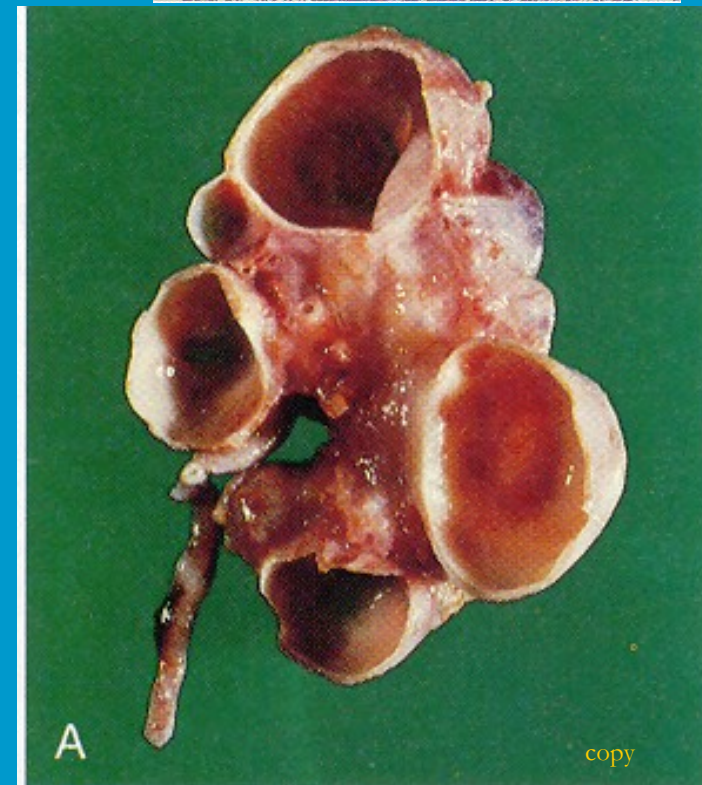
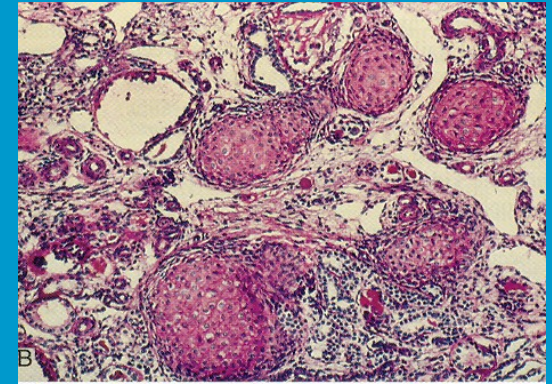


Cystic renal disease

- Hereditary, congenital nonhereditary, acquired
- Pathogenesis: primary defect of tubular epithelial cells and their growth, resulting in tubular dilatation
- Secondary tubular obstruction (oxalate crystals etc.)
- Multiple or solitary
- Affects the whole kidney, or mostly cortex or medulla

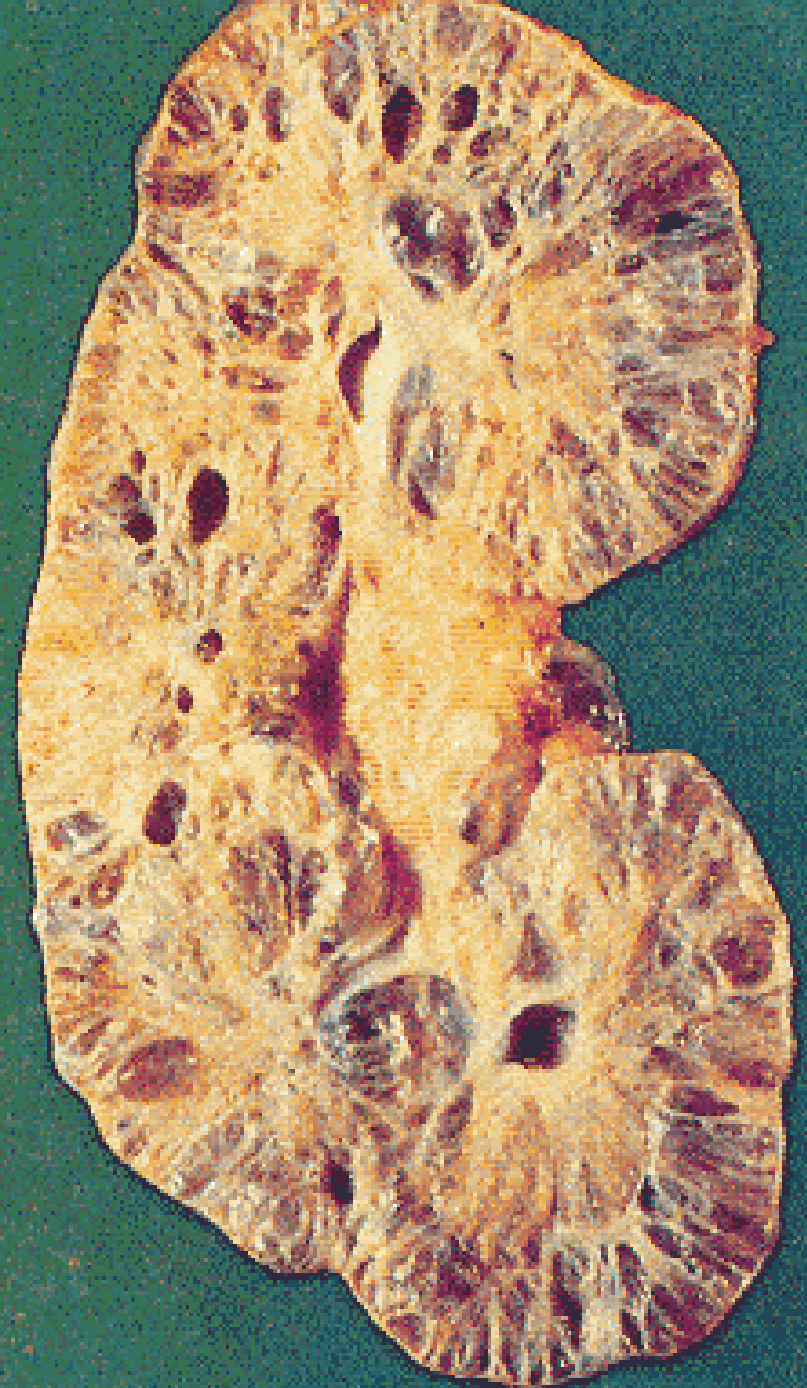Cystic dysplasia

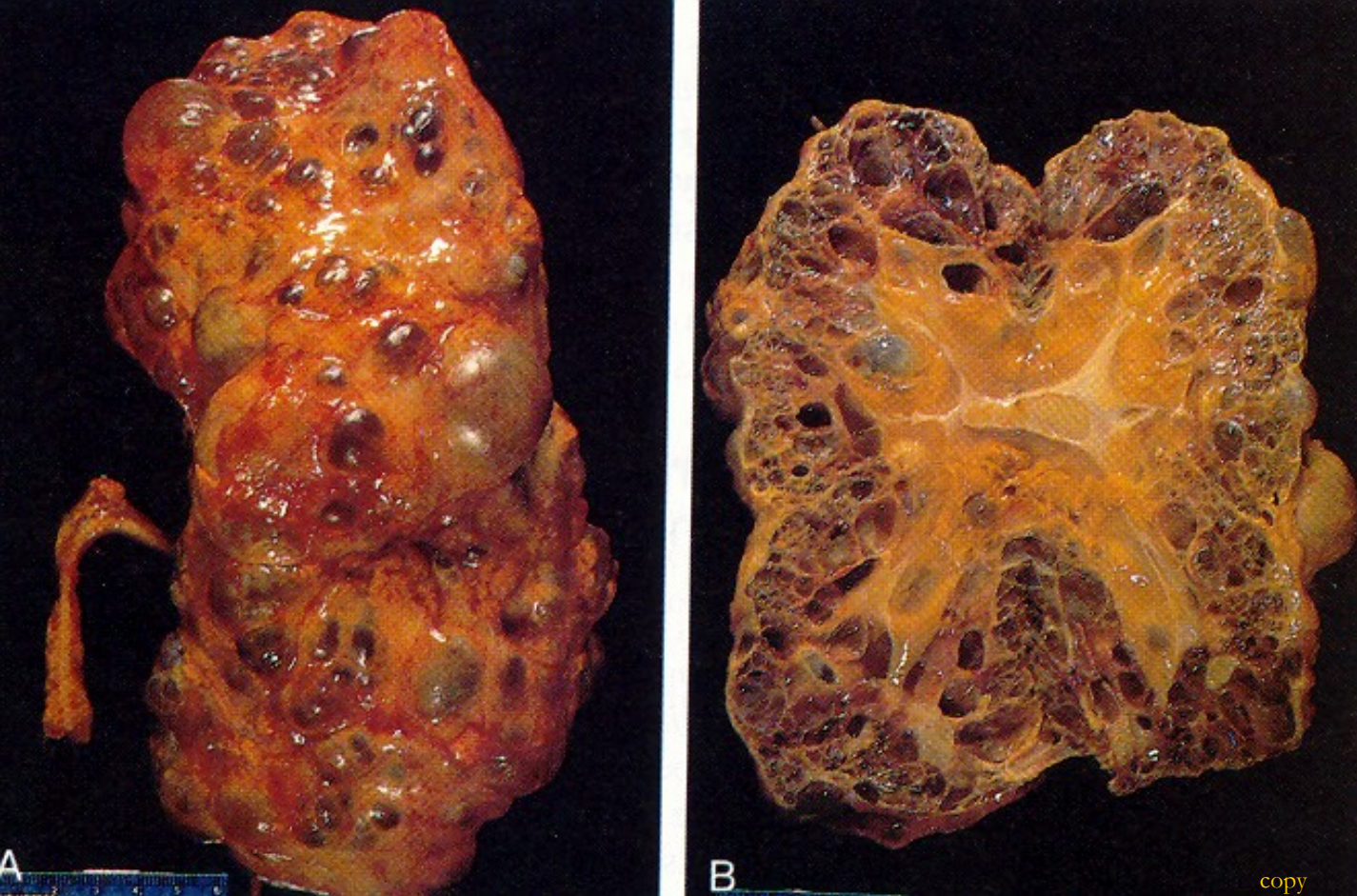
- Uni- or bilateral
- Enlarged multicystic kidney
- Cysts mm-cm.
- Islands of undifferentiated mesenchyme, immature tubules
- Commonly cartilage
- Bilateral - renal insufficiency



Polycystic kidney - autosomal recessive

- Infants
- Enlarged kidney at birth, smooth surface, microcystic
- Radial elongated cysts and channels
- Congenital hepatic fibrosis
- RF in childhood

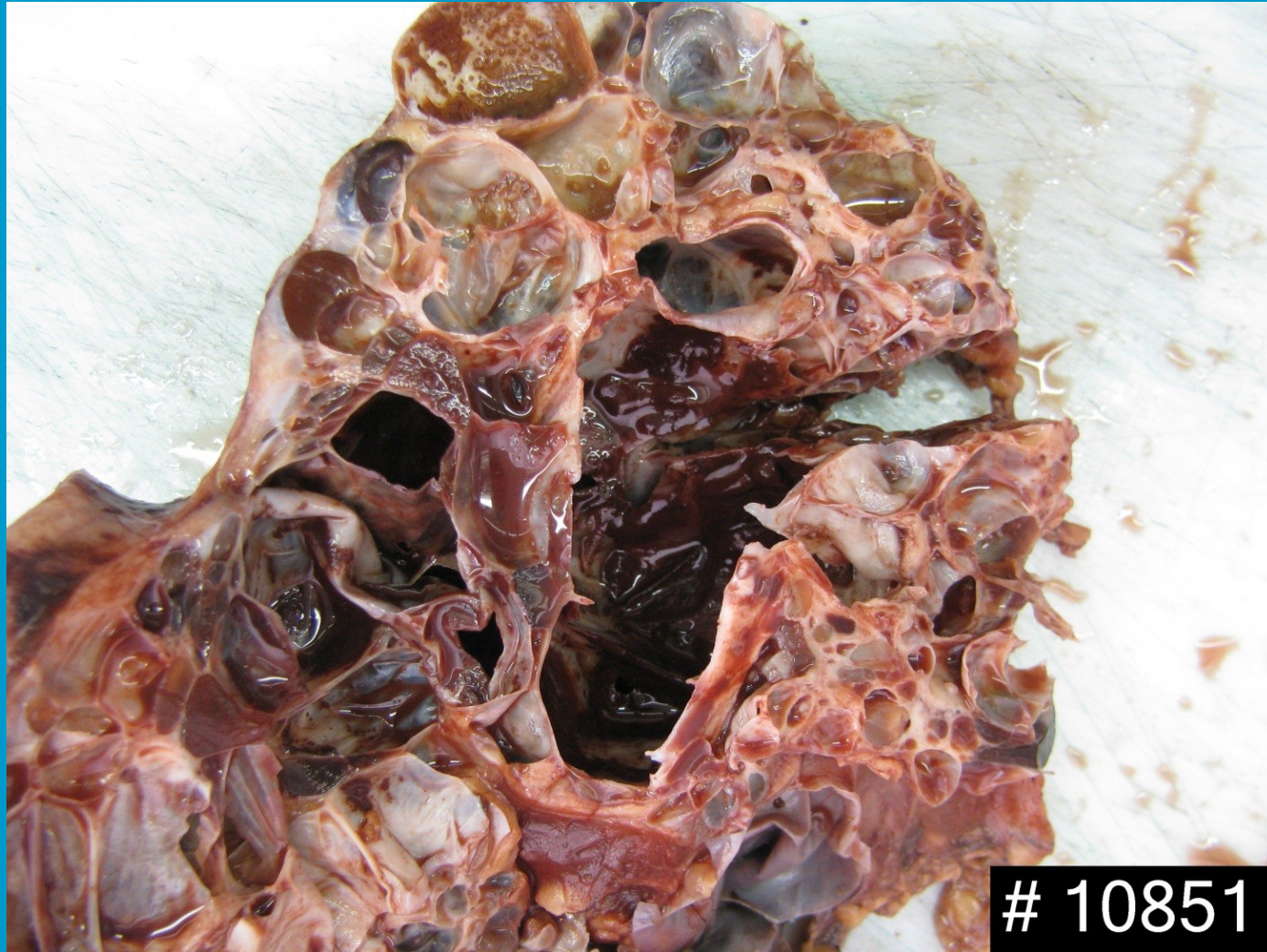



Adult polycystic kidney disease (APKD)

Autosomal-dominant, liver cysts, berry aneurysms. 1:500-1:1000. Pain, hematuria, UTI, stones, hypertension, slow progression, chronic RF at 40-60 yrs. ↑risk of ca

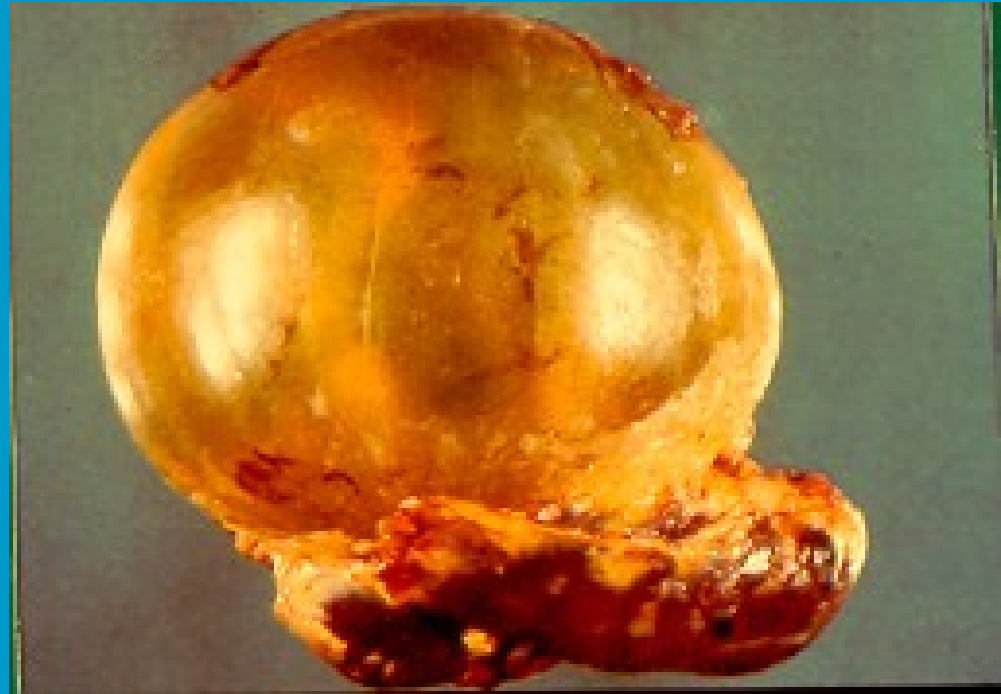Adult polycystic kidney



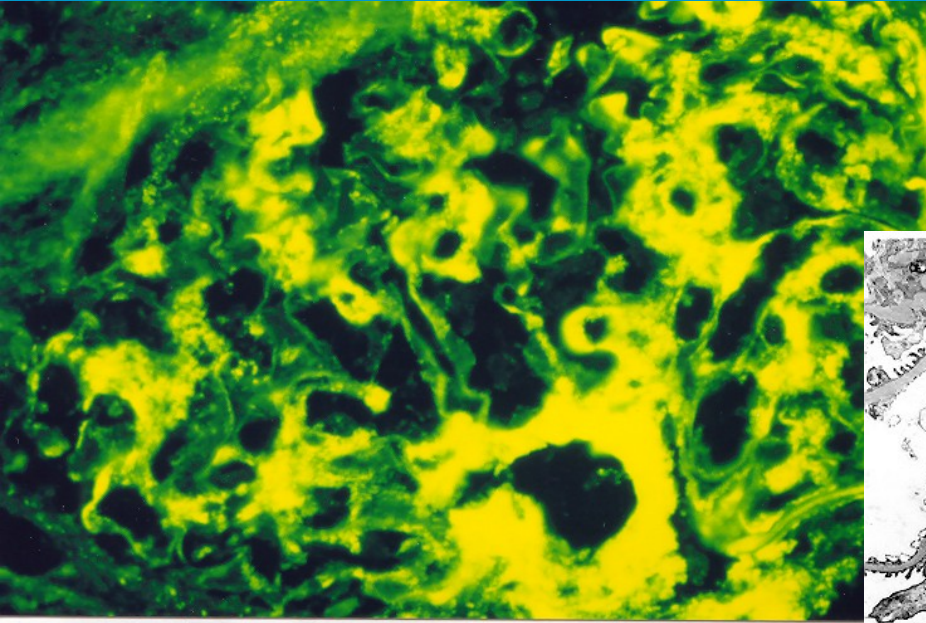
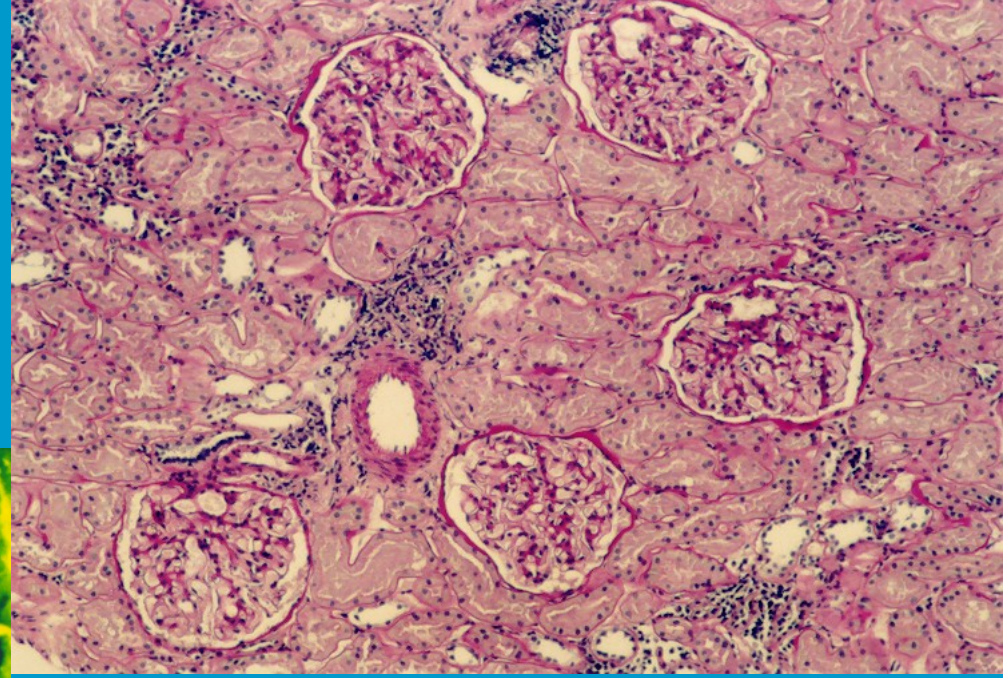
10851

Simple cyst

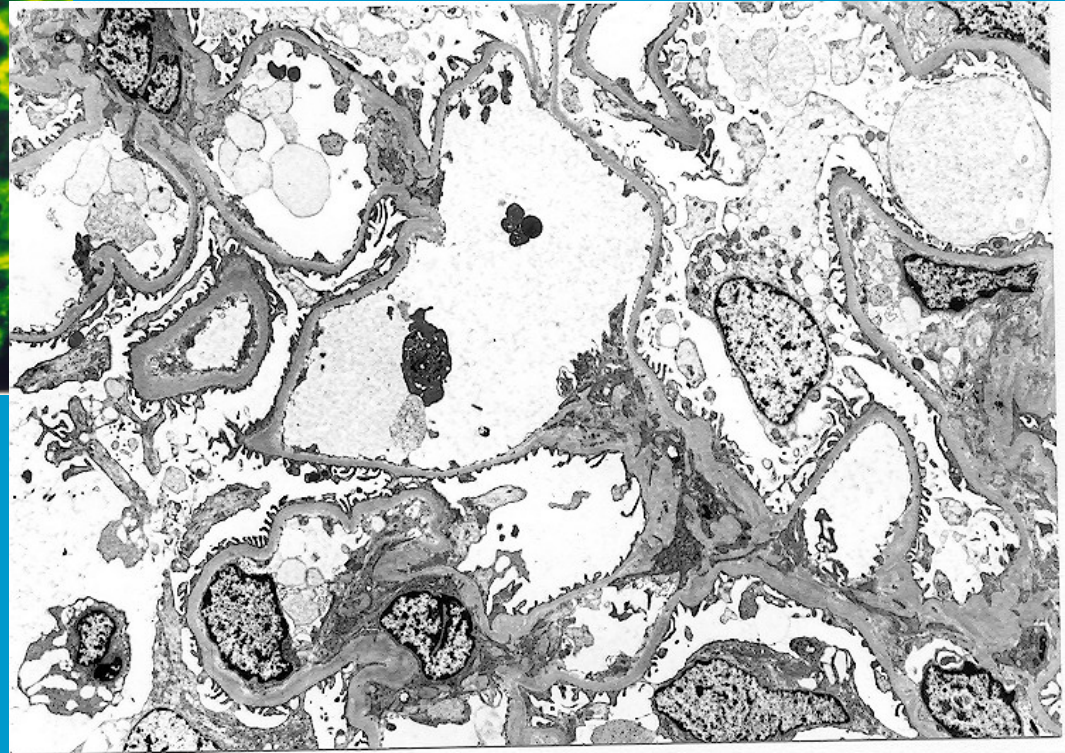
- Single or multiple
- Up to 10 cm
- Haemorrhage possible
- Differential diagnosis x cystic tumors
- „Complicated“ cyst – with regressive changes, diff. dg. x ca



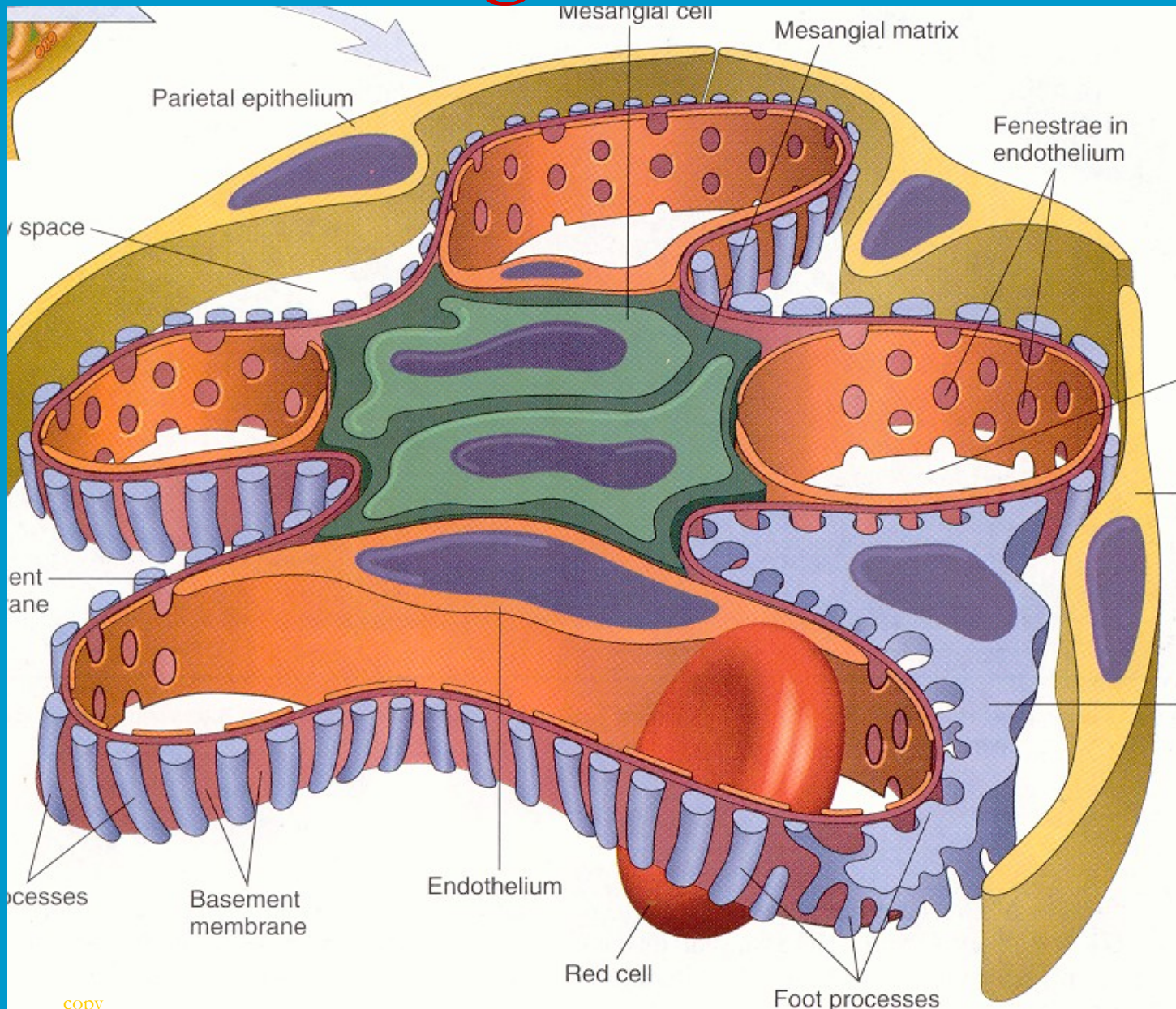
Renal biopsy



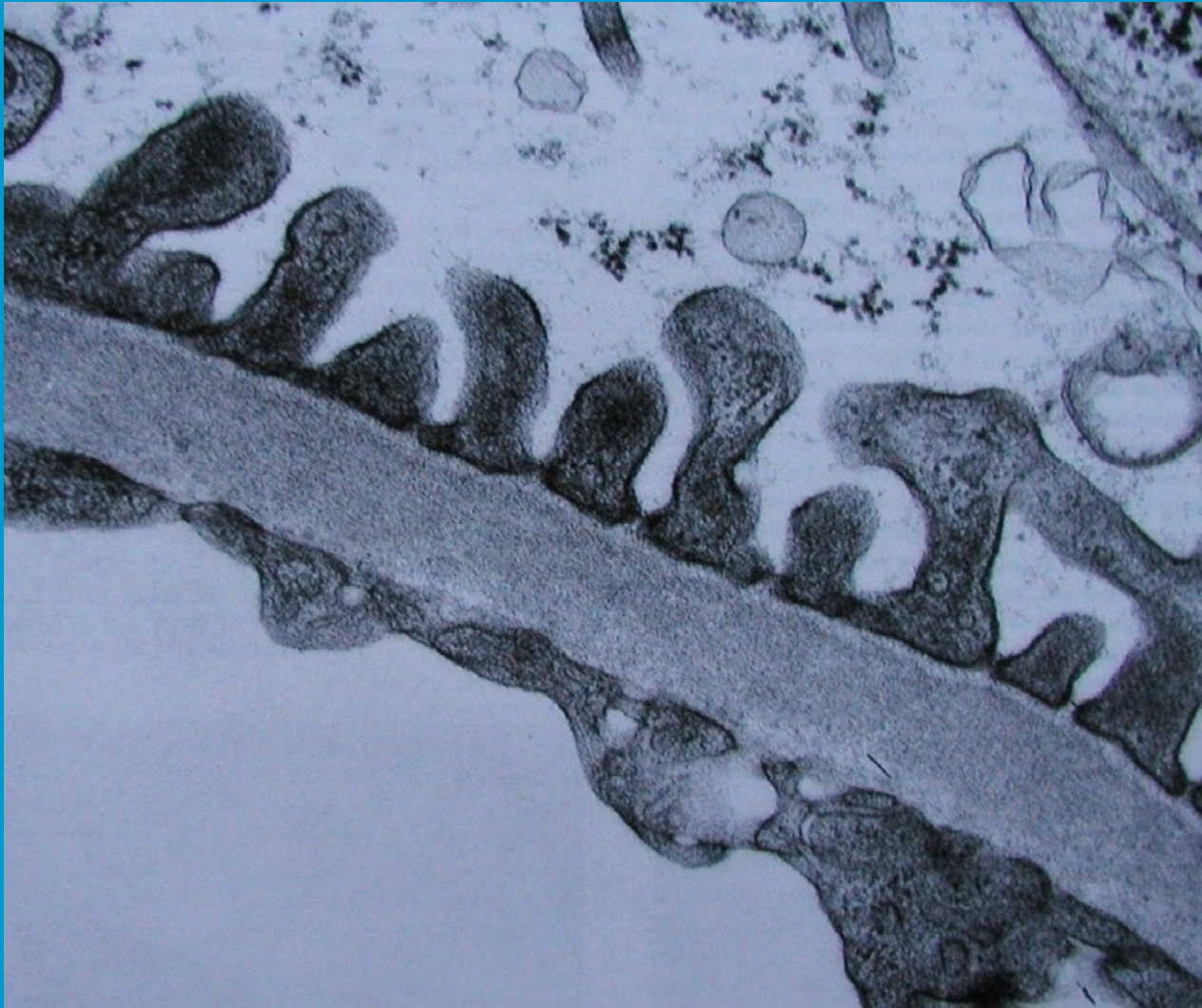Direct
immunofluorescence
Electron
microscopy



Normal glomerulus



Glomerular filtration barrier



Glomerular diseases

- Classification by aetiology and mechanisms of injury (primary x secondary; immunological x non-immunological)
- Histological classification (patterns of injury – proliferative, membranous change, membranoproliferative, crescentic, hyalinisation + sclerosis)
- One disease may have variable morphology/pattern (SLE)
- One pattern may be seen in variable disorders

Glomerular diseases

- Nephritic syndrome, rapidly progressive GN: inflammation +/- endothelial damage;
- usually immune mediated
 - Immune complex deposition (acute proliferative GN, SLE)
 - Antibodies x glomerular basement membrane (Goodpasture sy)
 - Systemic noninfectious vasculitis: autoantibodies p-ANCA, c-ANCA; (polyangiitis with granuloma)

Glomerular diseases

- **Nephrotic syndrome:** malfunction/leakage of barrier-filtration system - ↑ increased permeability

Capillary wall: thickening by in situ IC deposits (membranous glomerulopathy; primary, sec.), abnormal substances (DM, amyloid)

Epithelial cells: loss of normal structure (foot processes in minimal change disease; disruption in focal segmental glomerulosclerosis)

Glomerular diseases

Non-immune mediated lesions

vascular

- hemodynamic factors
- hypertension
- ischemia

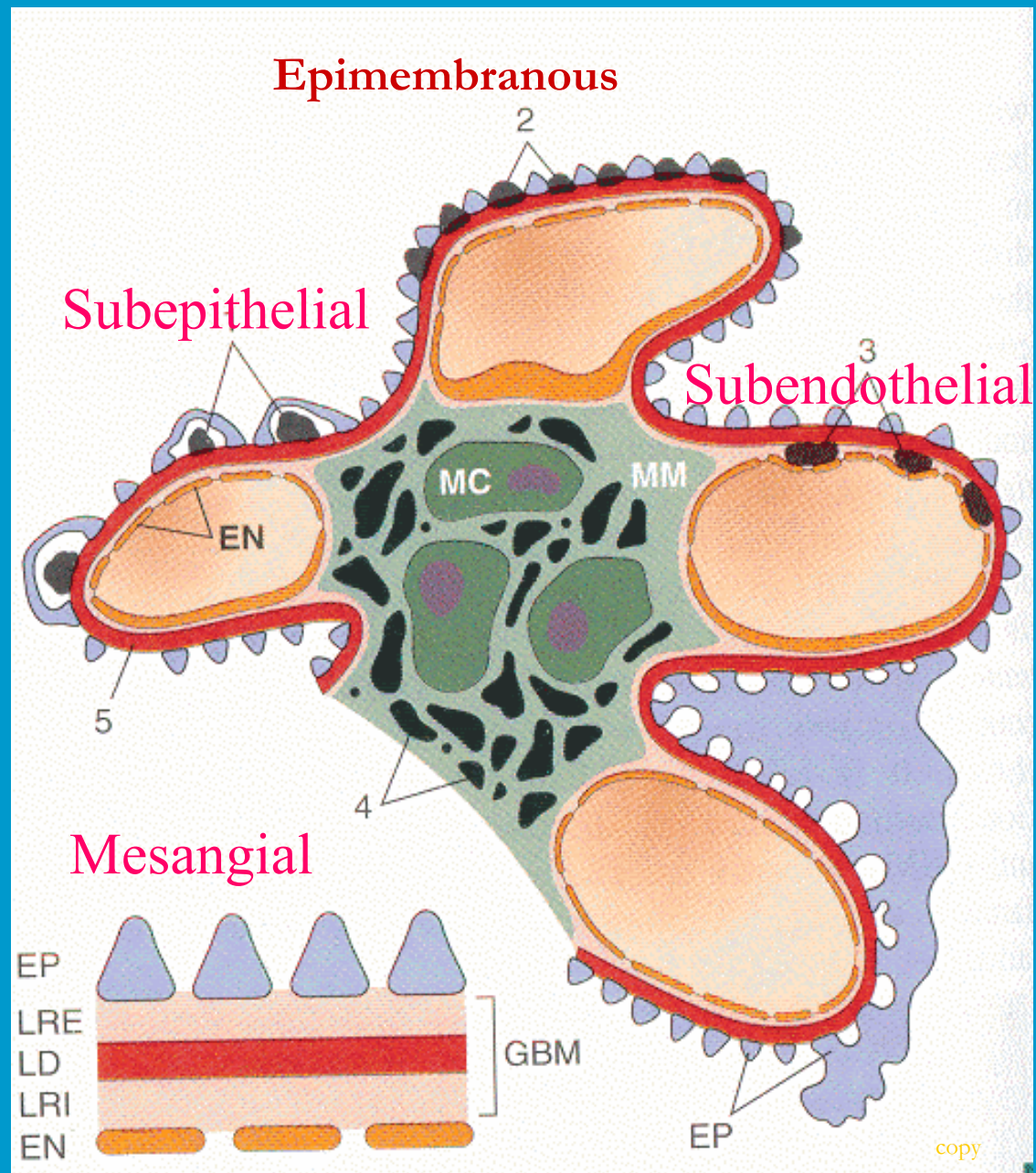
Patterns of glomerular injury

- **Proliferative** – increased glomerular cellularity, combination of endogenous proliferation and exogen. infiltration
- **Membranous change** – thickening of loops due to BM expansion + IC deposition
- **Membrano-proliferative**
- **Crescentic** – florid prolif. of cells in Bowman's capsule + infiltration, later fibrotic changes
- **Hyalinisation** – extracellular/intramural amorphous material w. plasmatic proteins + lipids, PAS+, silver impregnation -
- **Sclerosis** – extracellular collagenous matrix, membranes, PAS+, impregn. -

Glomerular injury distribution

- **Diffuse** – almost all glomeruli affected (> 50-80%)
- **Focal** – only some glomeruli
- **Global** – affecting the whole glomerulus
- **Segmental** – affecting only part of the glomerulus

IC localisation



Progression in glomerular disease

- ↓ GFR (30-50% of normal) → independent progression to RF – ablation nephropathy
- Focal segmental glomerulosclerosis – adaptation – compensatory glomerular hypertrophy (glomerular + systemic hypertension → proteinuria → mesangial proliferation + matrix accumulation → sclerosis)
- Tubulointerstitial fibrosis – proteinuria + ischemia → tubular damage + interstitial inflammation

Clinical presentations

■ Isolated proteinuria

- sometimes asymptomatic
- glomerular – damage to filtration membrane
 - selective – proteins w. low-middle molecular weight (albumin)
 - nonselective – high weight proteins – Ig
- tubular
 - problem in tubular resorption of LMW proteins

■ Isolated hematuria

- microscopic x macroscopic

Clinical presentations

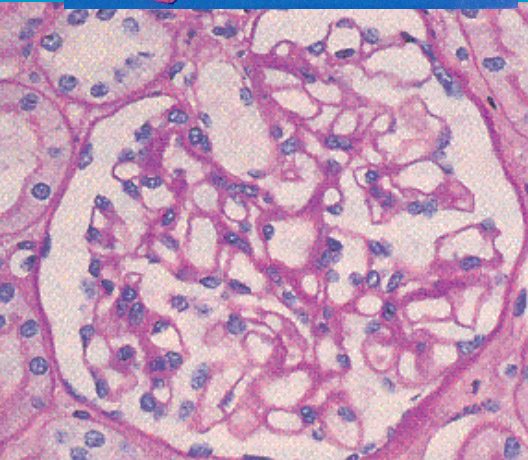
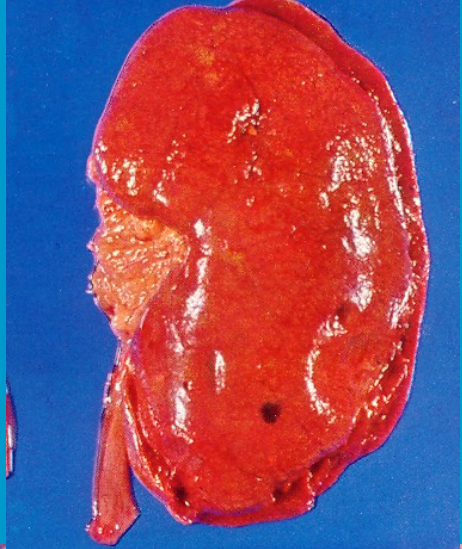
- Nephritic syndrome – acute gl. damage, rapid start, hematuria, variable proteinuria, oliguria, edema, hypertension, azotemia, mineral dysbalance
- Nephrotic syndrome - heavy proteinuria $> 3,5$ g/daily, generalised edema, hypoalbuminemia, hyperlipidemia, lipiduria; hypercoagulative state (loss of coagulation proteins, increase in blood viscosity)

Clinical presentations


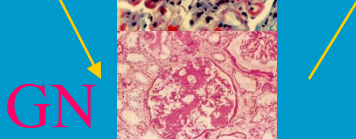
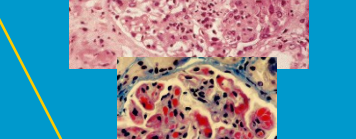
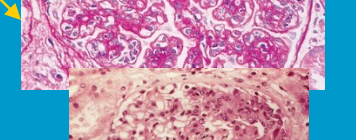
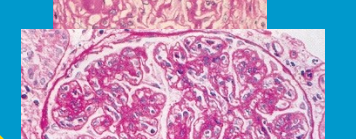
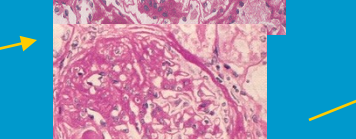
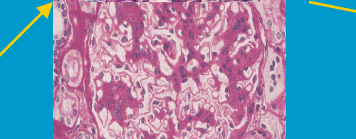
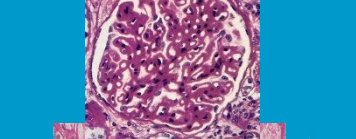
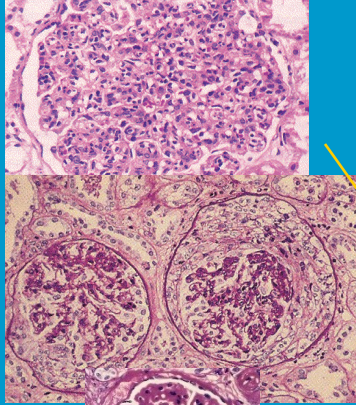
- Acute renal failure – progressive oliguria to anuria, azotemia, metabolic acidosis;
 - prerenal – renal – postrenal
 - with according therapy usually return to function
- Chronic renal failure - prolonged symptoms of uremia, anemia, nausea
 - chronic uremia in irreversible damage
 - most commonly due to DM, hypertension, AS

GLOMERULAR DISEASES

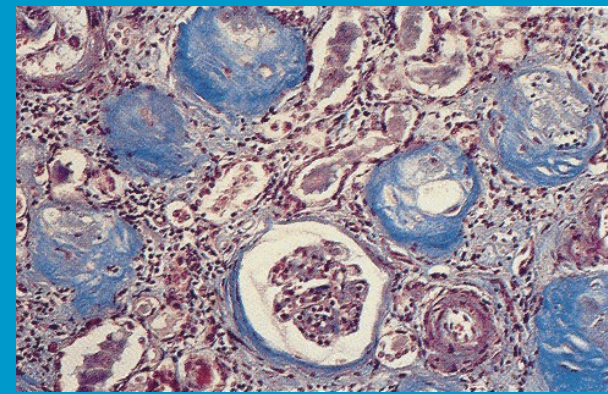
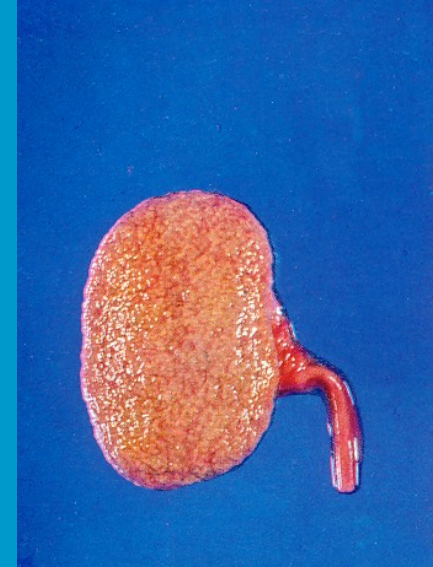
- **PRIMARY GLOMERULAR DISEASE:** kidney as a main affected organ, other clinical signs due to impaired renal function (i.e. minimal change disease)
- **SECONDARY GLOMERULAR DISEASE:** renal injury only a part of systemic disease affecting multiple organs (lung, joints, skin), i.e. SLE



Normal kidney



GN



Chronic sclerosing GN

Glomerulopathy

- One histological type may have variable clinical presentation, i.e. membranoproliferative lesion may present as glomerulonephritis with nephritic sy, glomerulopathy with nephrotic sy, or isolated hematuria

Glomerulopathy with:

- Proteinuria or nephrotic syndrome
- Isolated or predominant hematuria
- Hematuria + proteinuria combined w. renal failure
- Glomerulopathy due to vascular diseases
- Glomerulopathy in systemic lupus
- Chronic glomerulopathy

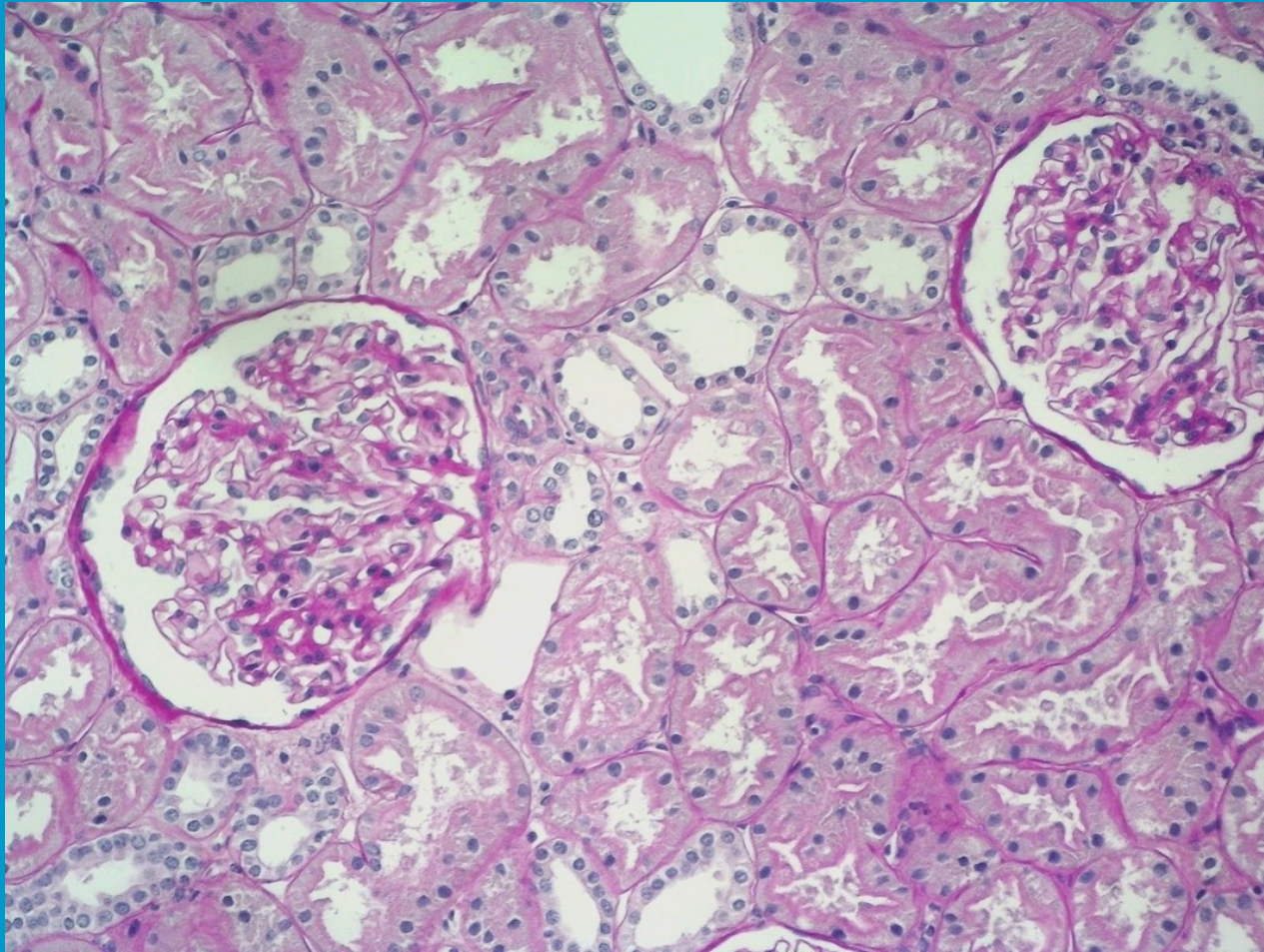
Glomerulopathy with proteinuria or nephrotic syndrome

- Minimal glomerular change disease
- Focal segmental glomerulosclerosis
- Membranous glomerulopathy
- Other immune complex GN
- Amyloidosis
- Diabetic nephropathy

Minimal change disease

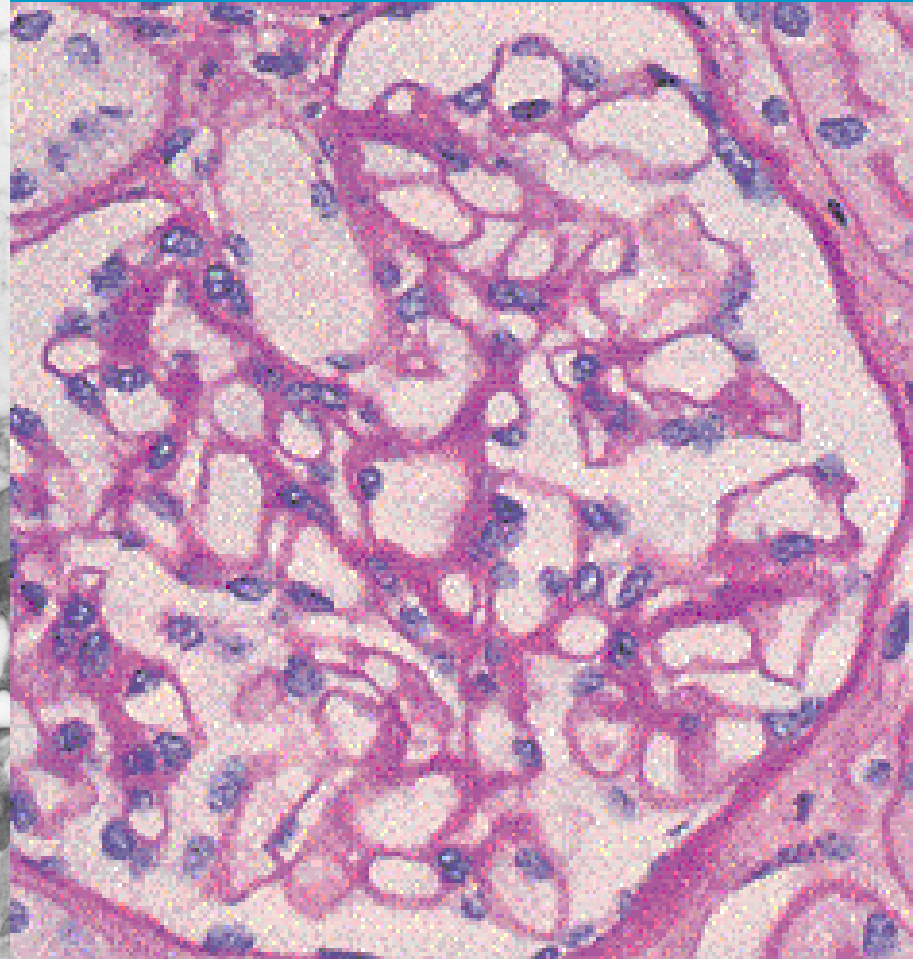
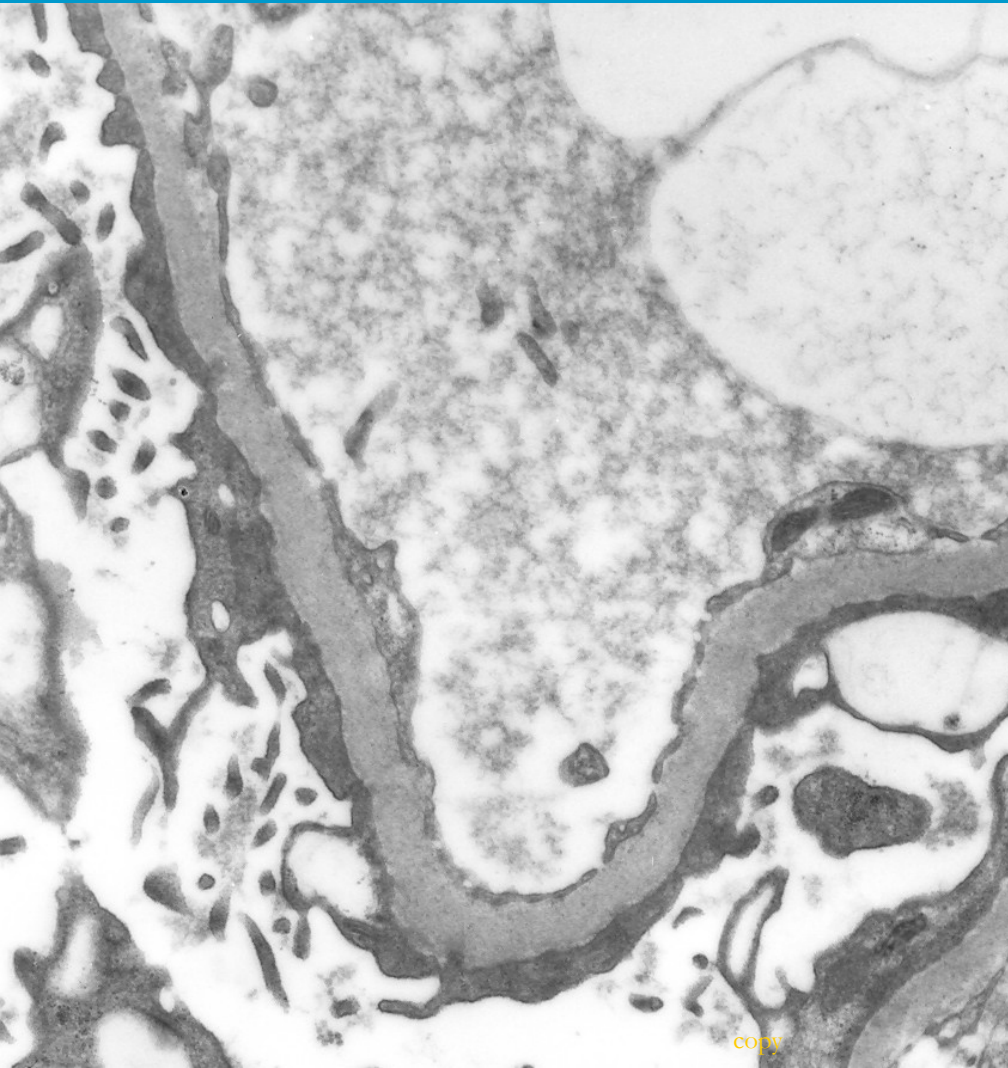
- Most common cause of nephrotic sy in children
- heavy selective proteinuria - albuminuria
- mostly in children ≤ 5 yrs
- Light microscopy + IMF normal
- Genetic predisposition + immunological basis
(association with respiratory infection, atopy, Hodgkin lymphoma)
- Epithelial cell injury – effaced foot processes
- steroid therapy, good prognosis in children

Minimal change disease



Minimal change disease

Loss of epithelial foot processes in elmi, fat in tubular epithelia
(„lipoid nephrosis“)



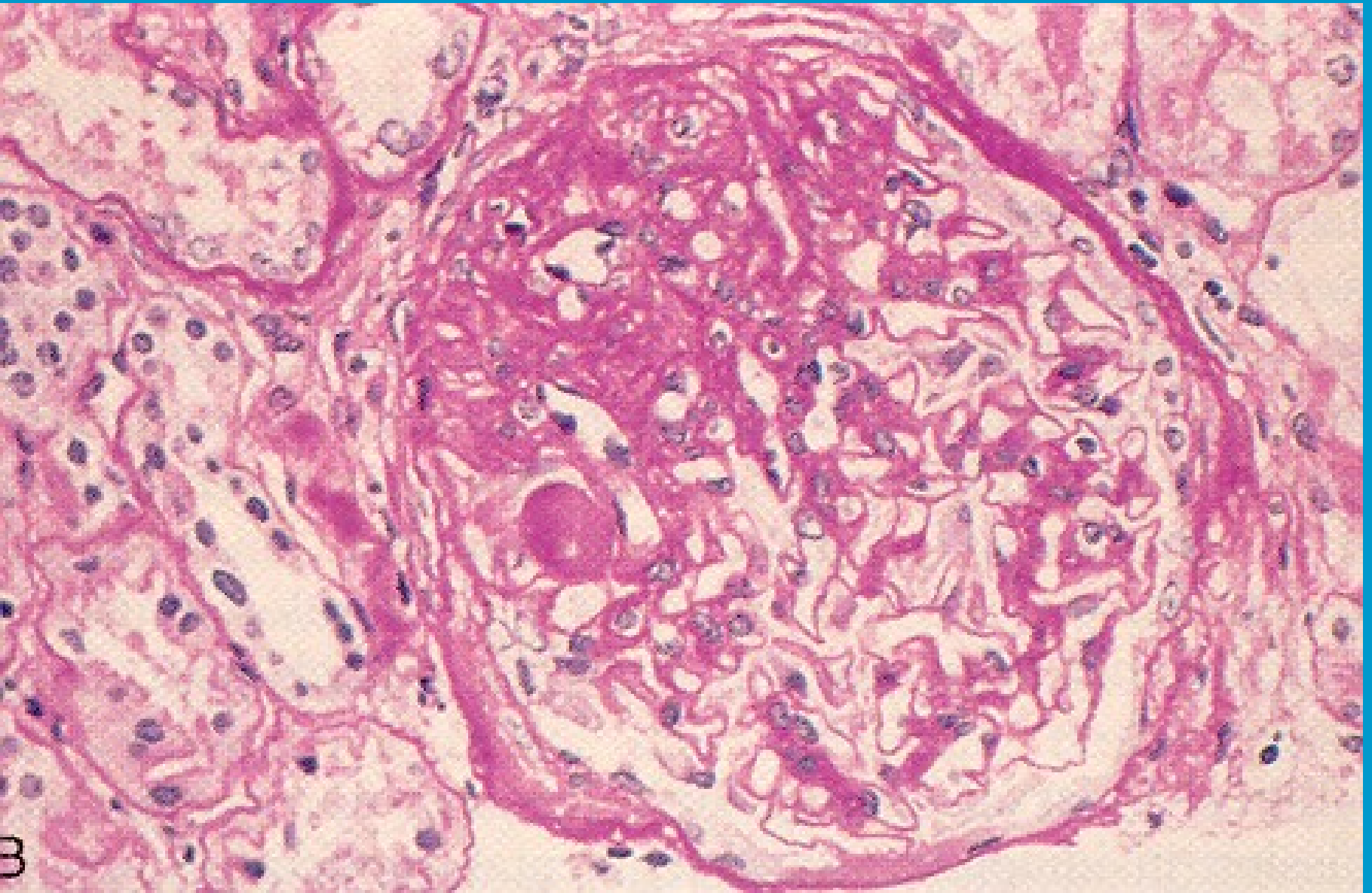
Focal segmental glomerulosclerosis

- Nephrotic sy, ↑ incidence, any age
- Hematuria, ↓ GFR, proteinuria
- Progression usual – 50% → RF in 7 years, steroid-resistant
- Primary – idiopathic, variable podocyte protein mutations, plasma factor ↑ permeability
- Secondary: late part of adaptive response to preexisting renal disease (renal ablation - reflux nephropathy, hypertension, glomerulopathies – IgA, SLE,...)
- Association with other diseases (HIV, obesity, toxins – heroin, drugs)

FSGS

- epithelial damage
- hyalinosis (plasma protein leakage), foamy macrophages
- segmental sclerosis (mesangial matrix production, capillary loops collapse)
- No immune deposits on IF
- Podocyte injury on EM

Focal segmental glomerulosclerosis



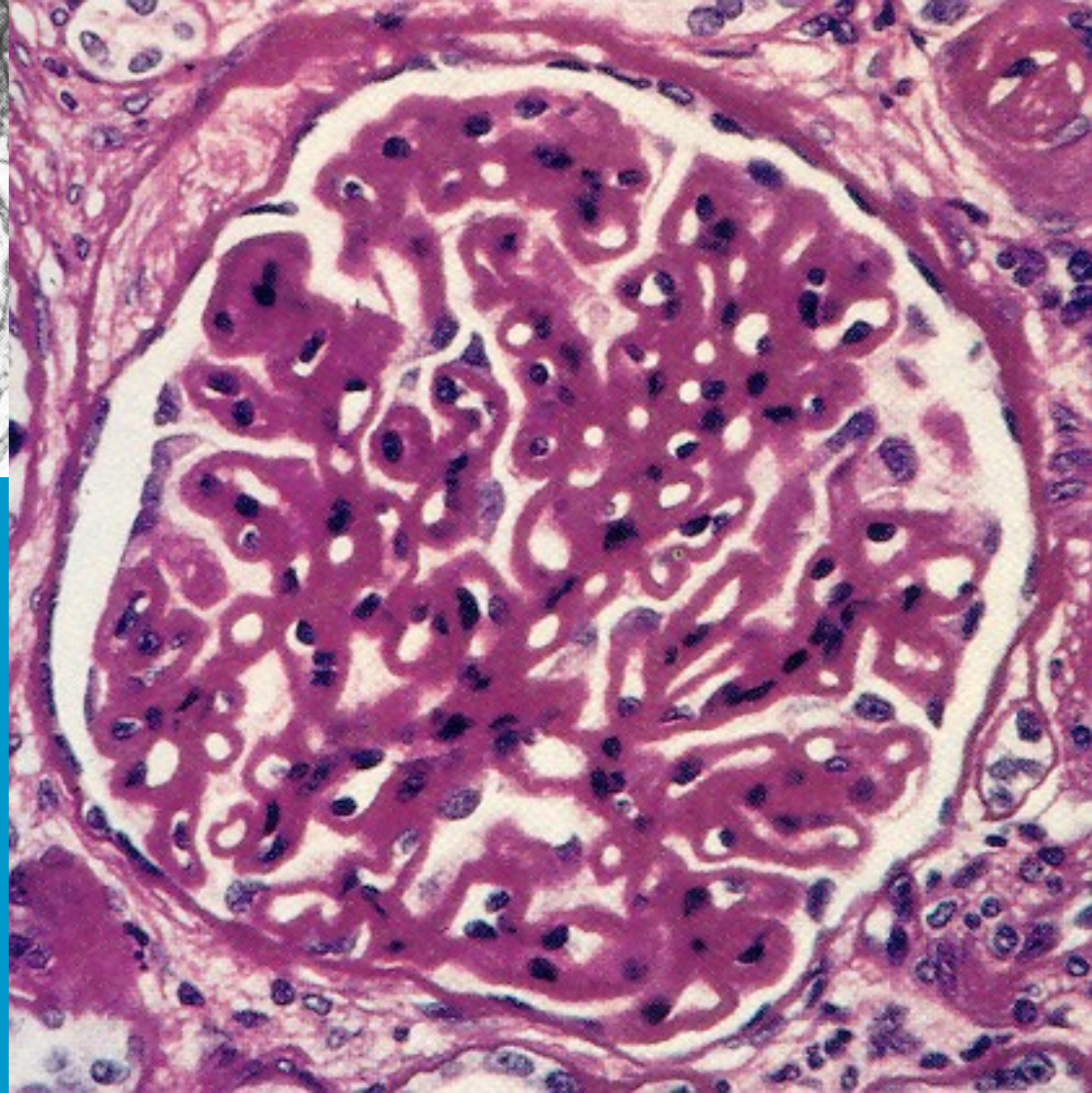
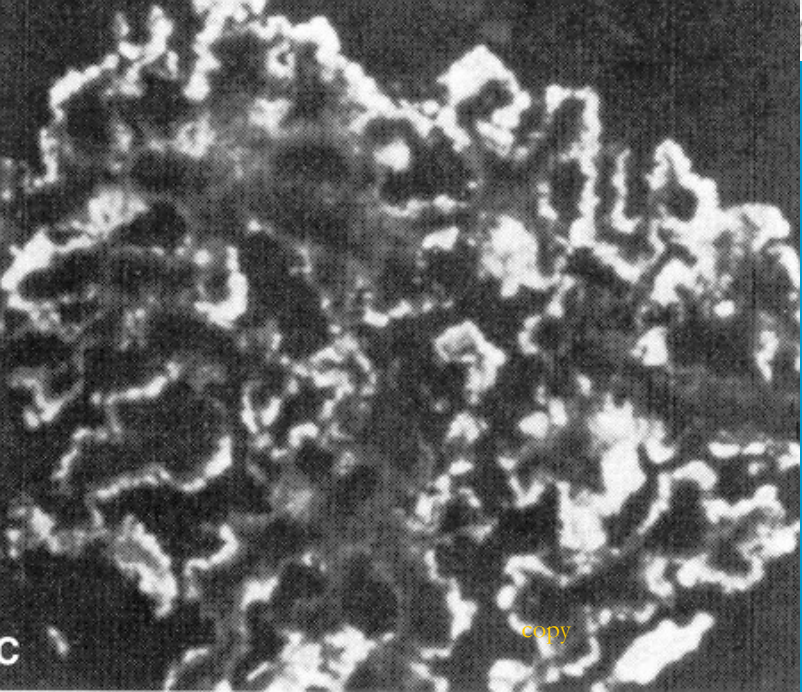
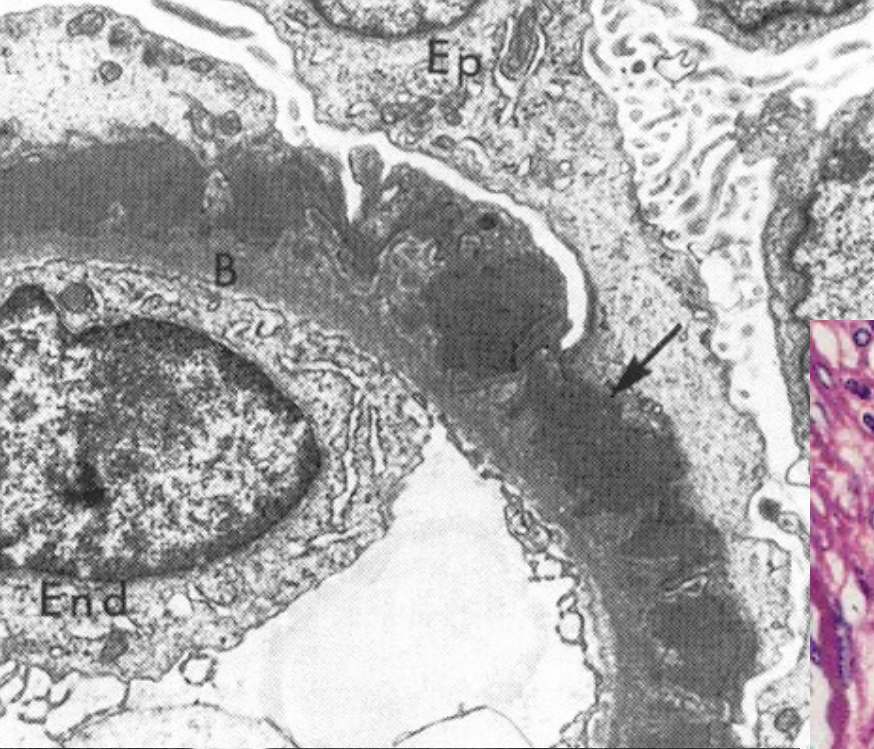
Membranous glomerulopathy

- primary autoimmune,
- mostly older adults – most common nephrotic sy in this age group
- Ab x specific receptor in podocytic membrane antigen,
- proteinuria or nephrotic sy, variable course, 1/3 RI
- diffuse global glomerulopathy
- thickening of capillary wall, subepithelial IC deposits, „spikes“ - BM material in impregnation
- no increased glomerulus cellularity

Membranous glomerulopathy

- secondary – infections (HBV, HCV, syphilis, malaria)
tumors (lung ca, colorectal ca, melanoma), drugs (NSAID),
autoimmune diseases (SLE, thyroiditis)

Membranous glomerulopathy



Diabetes mellitus and kidneys

- **Nonenzymatic glycosylation** of proteins – accumulation of irreversible glycosylation products in BM of vessel walls, **metabolic defect** – increased collagen synthesis, **hemodynamic changes**
- **Diabetic microangiopathy** in kidney (glomerulosclerosis) and retina (diabetic retinopathy). Diffuse thickening of capillary BM leads to ischemic changes, simultaneously increased plasmatic proteins permeability

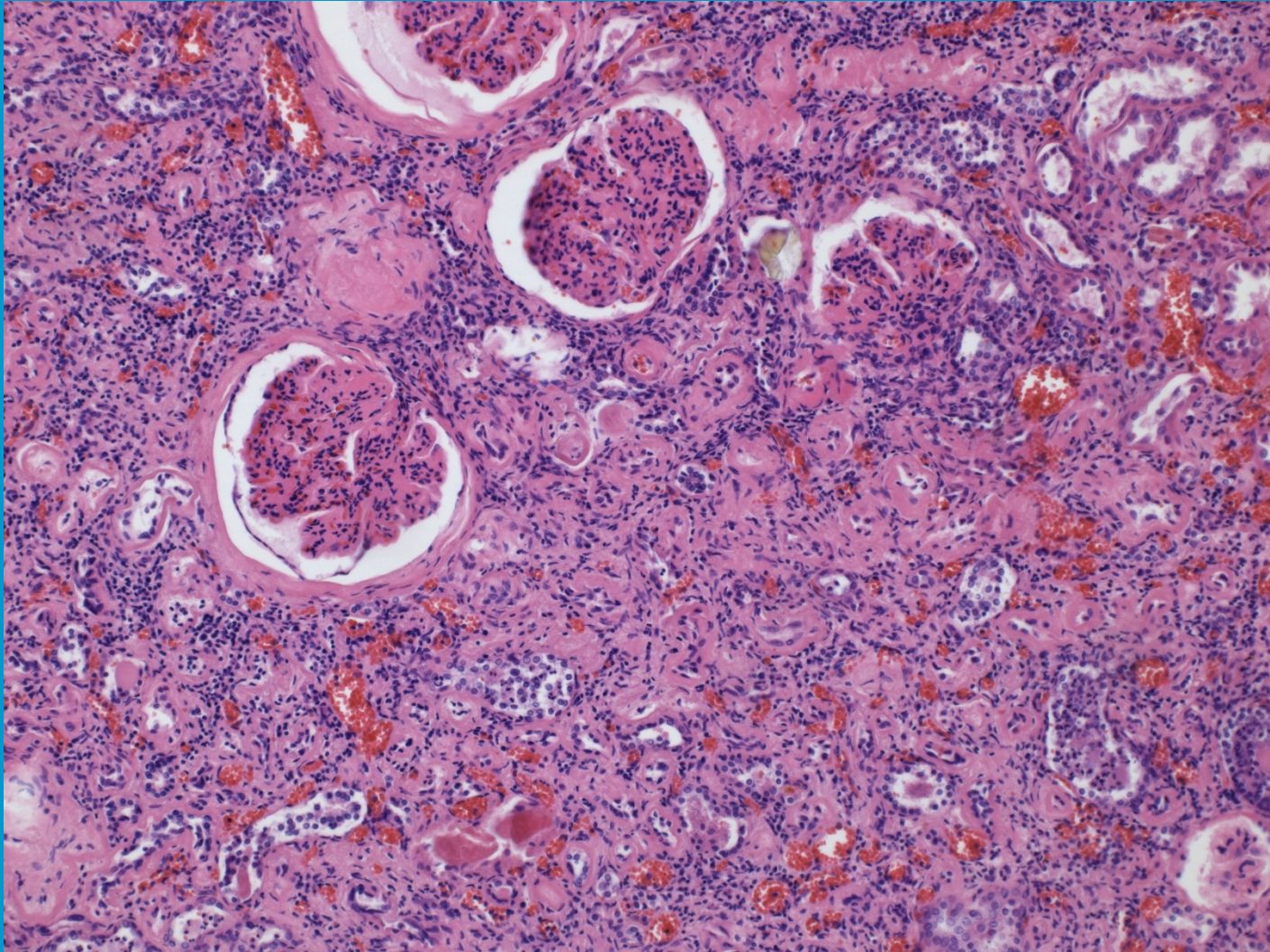
Diabetic nephropathy

- **Diabetic microvascular disease**
- **Clinically:** non-nephrotic proteinuria, nephrotic syndrome, chronic renal failure
- **Morphology:** glomerulosclerosis (diffuse mesangial, nodular), hyalinizing arteriolar sclerosis, tubulointerstitial lesions (steatosis and glycogenation of tubular epithelium, pyelonephritis, papillary necrosis)
- one of the most common causes of RF

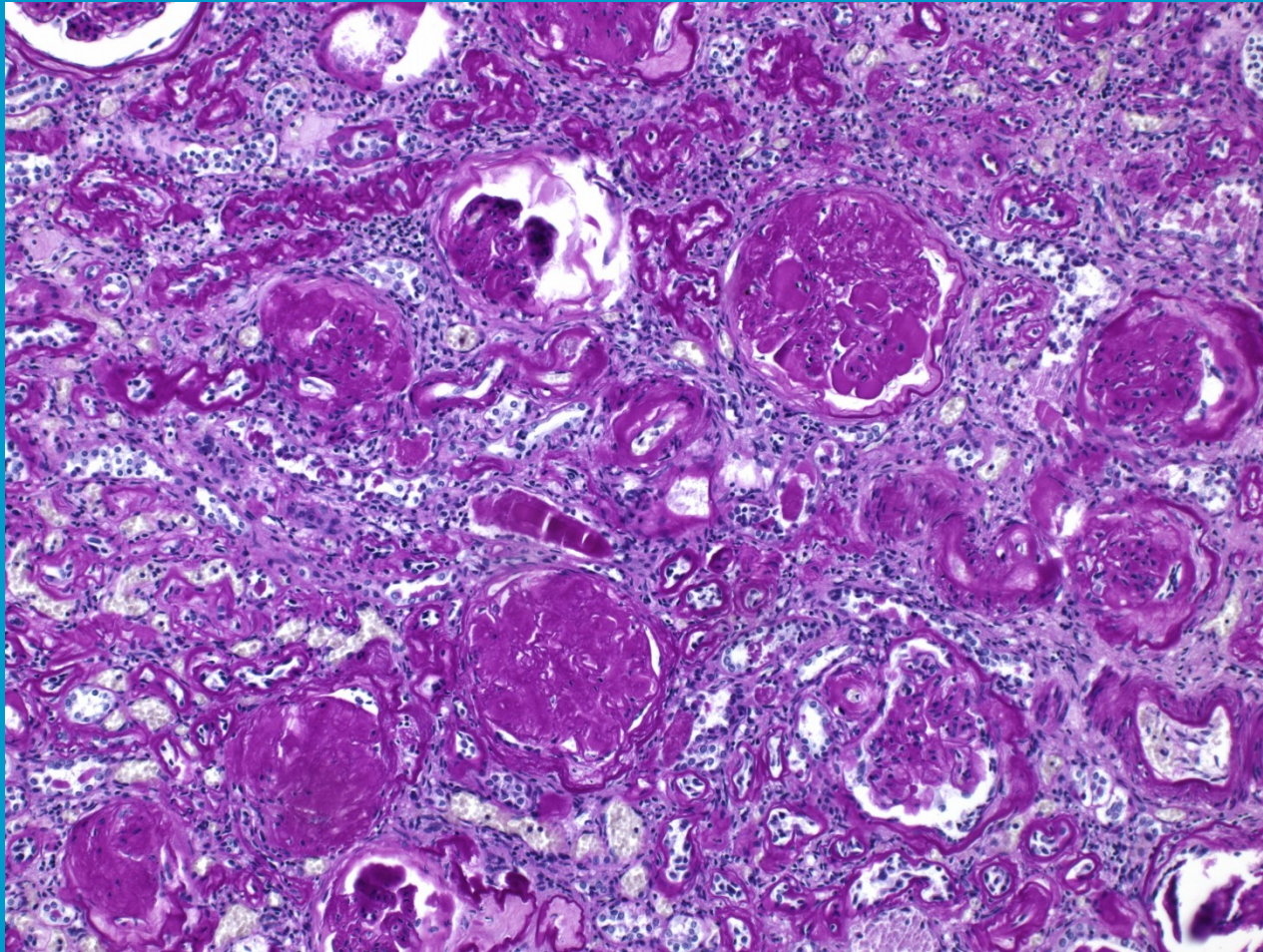
Diabetic glomerulosclerosis

- **Diffuse glomerulosclerosis** – GBM thickening, increase in mesangial matrix + cellularity
- **Nodular glomerulosclerosis** - (Kimmelstiel-Wilson) after 10-15 yrs; PAS+ nodular acellular material deposits at the tips of capillary loops; leads to chronic renal insufficiency
- no immune deposits in IMF

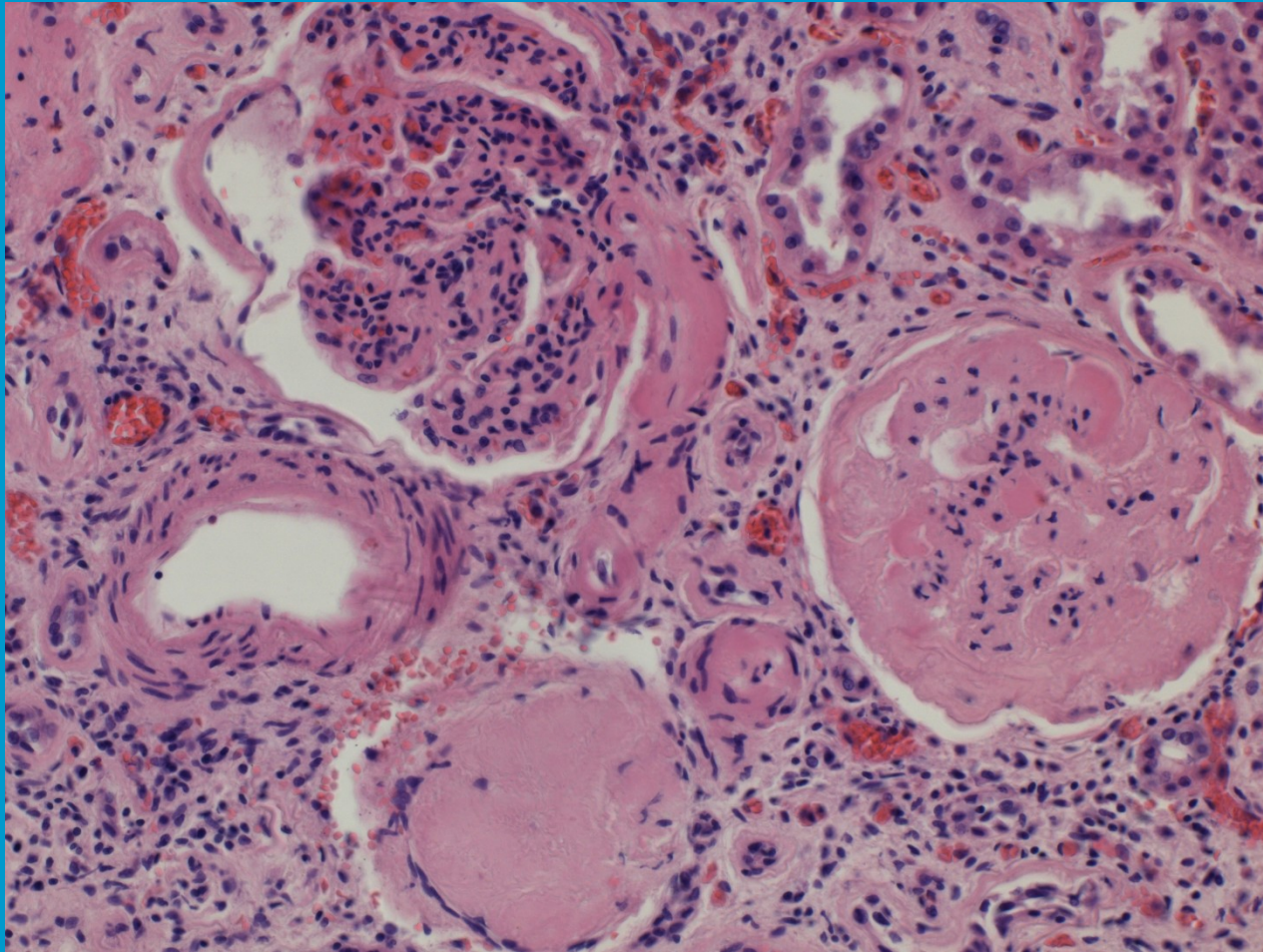
Diabetic glomerulosclerosis

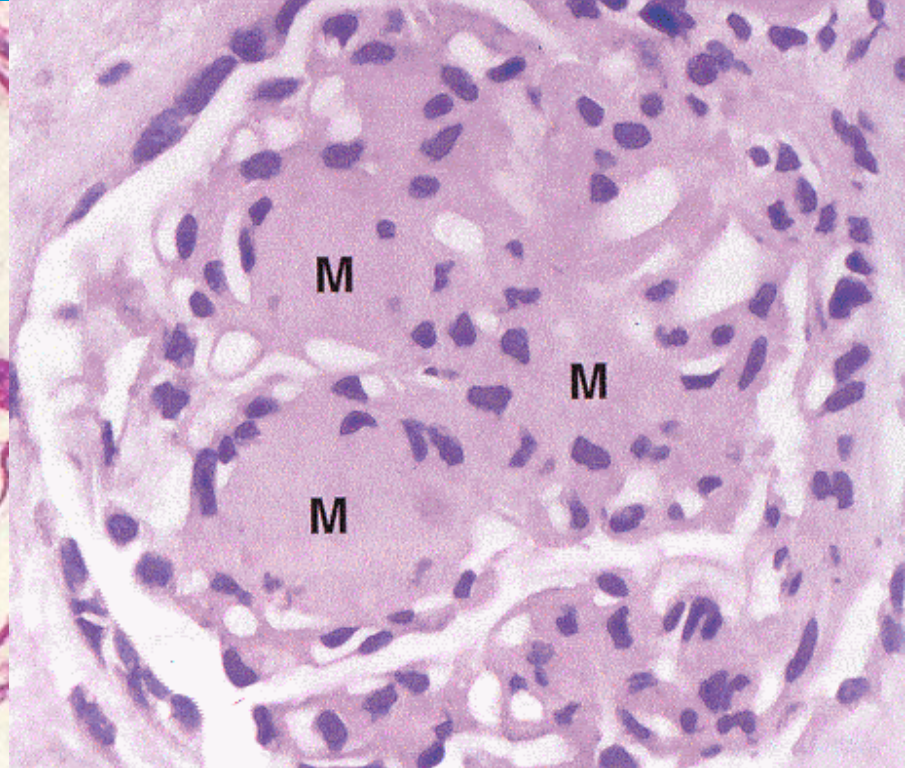
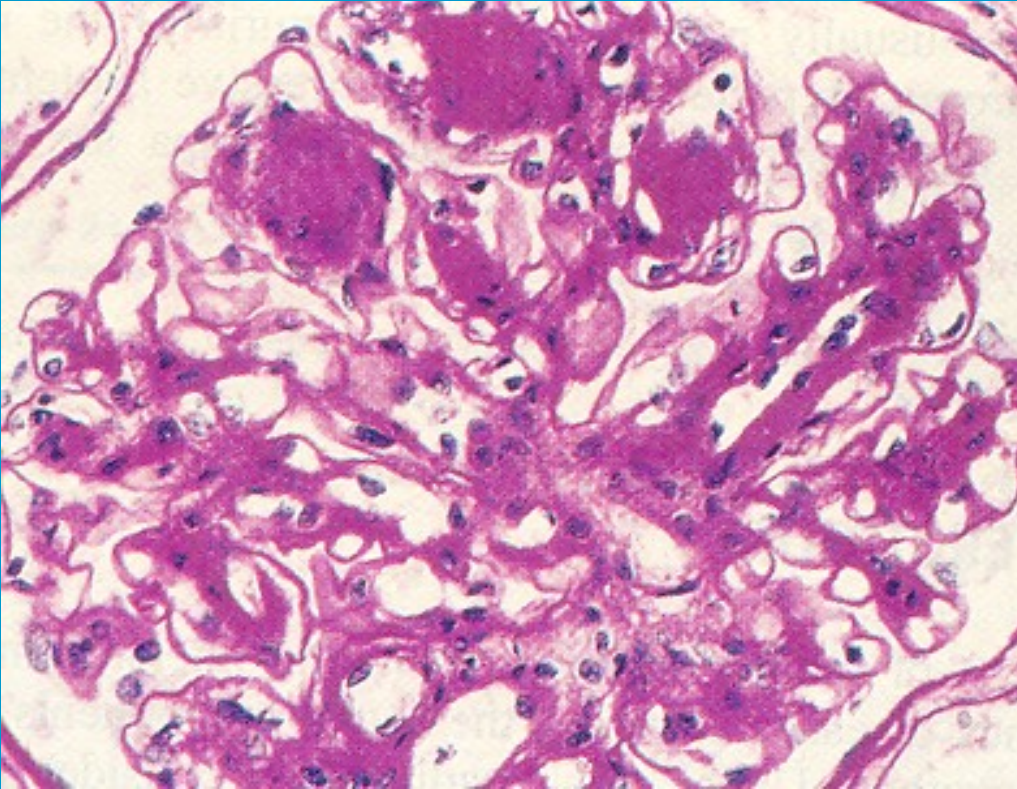


Diabetic glomerulosclerosis



Diabetic glomerulosclerosis





Diabetic glomerulosclerosis

Further renal complications in diabetics

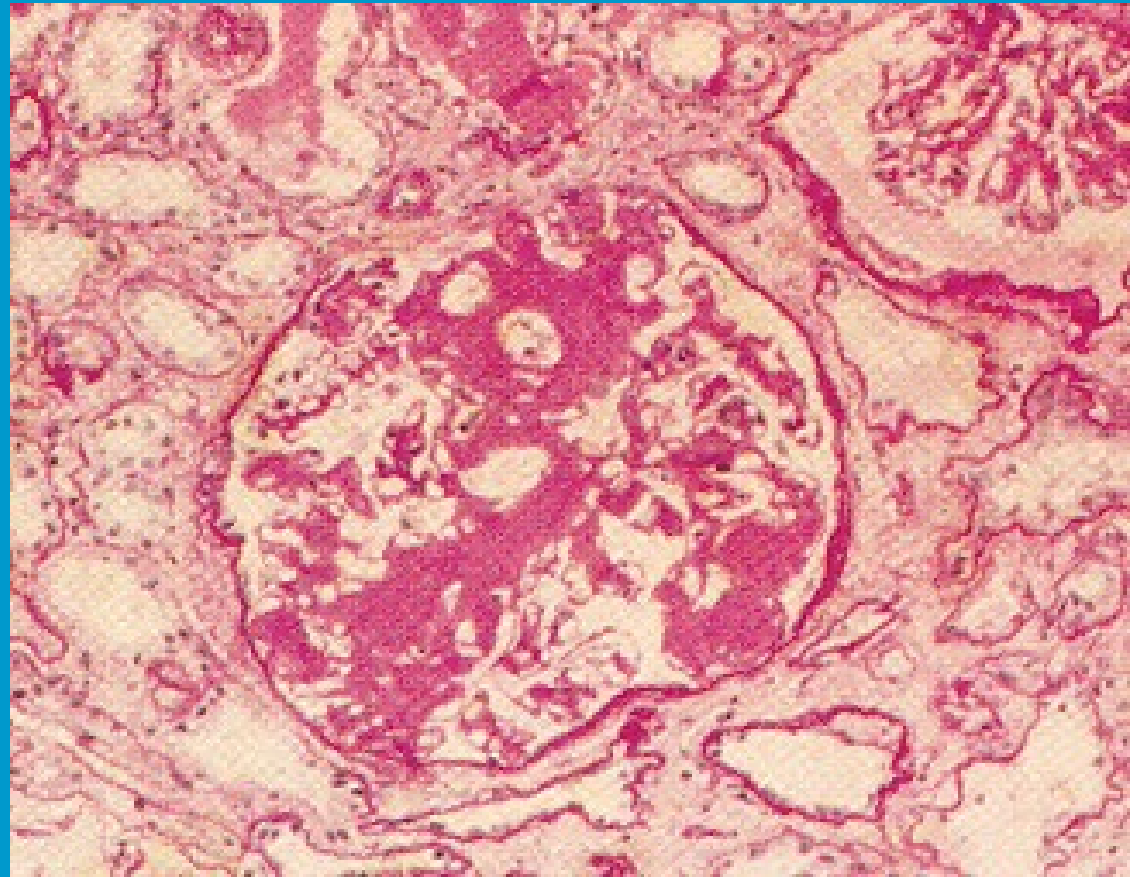
- accelerated arteriolosclerosis and arteriosclerosis, hypertension
- Pyelonephritis
- Renal papillary necrosis in acute PN

Renal amyloidosis

- Amyloidosis – pathologic deposits of abnormal microfibrillary (8-10nm) proteinaceous acellular material
- Eosinophilic in HE, Kongo red +, green dichroism in polarised light
- Firm pale enlarged kidney in macroscopy

Renal amyloidosis

- Amyloid deposits in glomerular mesangial matrix and capillary walls; glomerular obliteration
- Peritubular and blood vessel walls
- Proteinuria
- Nephrotic syndrome
- CHRI

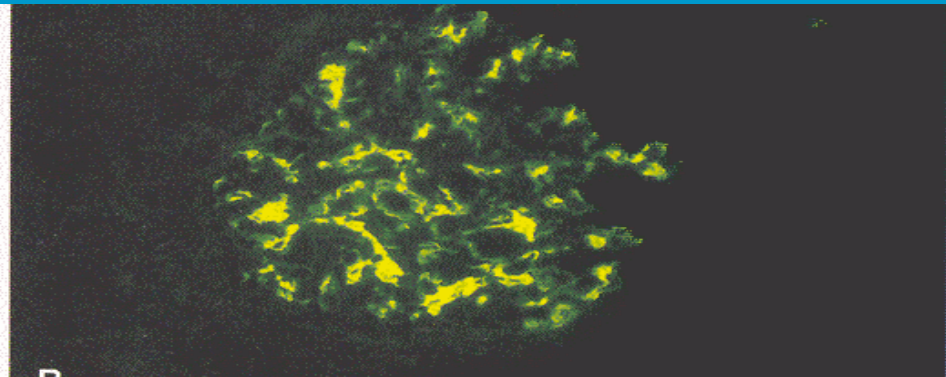
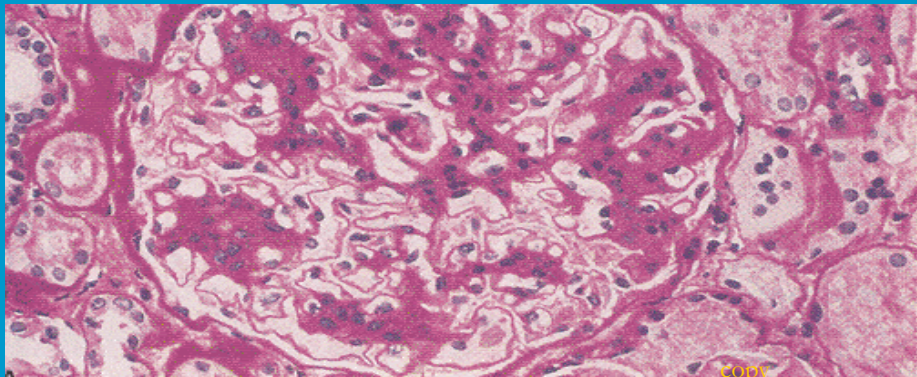


Glomerulopathy with hematuria

- **Primary:** IgA nephropathy (Berger's disease)
 - Alport syndrome / thin basement membranes sy
- **Secondary (systemic):** SLE
 - Henoch-Schönlein purpura
 - polyarteritis

IgA nephropathy

- Recurrent hematuria, children and young adults w. genetic predisposition, after GIT, respiratory tract, urinary tract infections, may → RF; most common cause of RF in primary glomerulopathies
- IgA and C3 mesangial deposition, mesang. cells and matrix proliferation, segmental glomerulosclerosis
- Abnormal increase/pathologic form of IgA production, AAxIgA – IC; ↓ clearance of IC in cirrhosis



IgA nephropathy

- changes of IgA nephropathy present in Henoch-Schönlein purpura
- preexisting respiratory infection
- purpura due to vasculitis (+ skin rash, GIT hemorrhage, arthritis)

Alport syndrome

- Part of collagen IV glomerulopathies
- genetic disorder, 90% X-linked, AR or AD
- abnormal basement membranes (lamina densa), later FSGS, tubular atrophy, interstitial fibrosis
- manifestation mostly in kidney (hematuria – nephritis, proteinuria), RF;
- HD, transplantation
- ear – deafness
- eye – lens + cornea disorders, cataract

Thin basement membrane

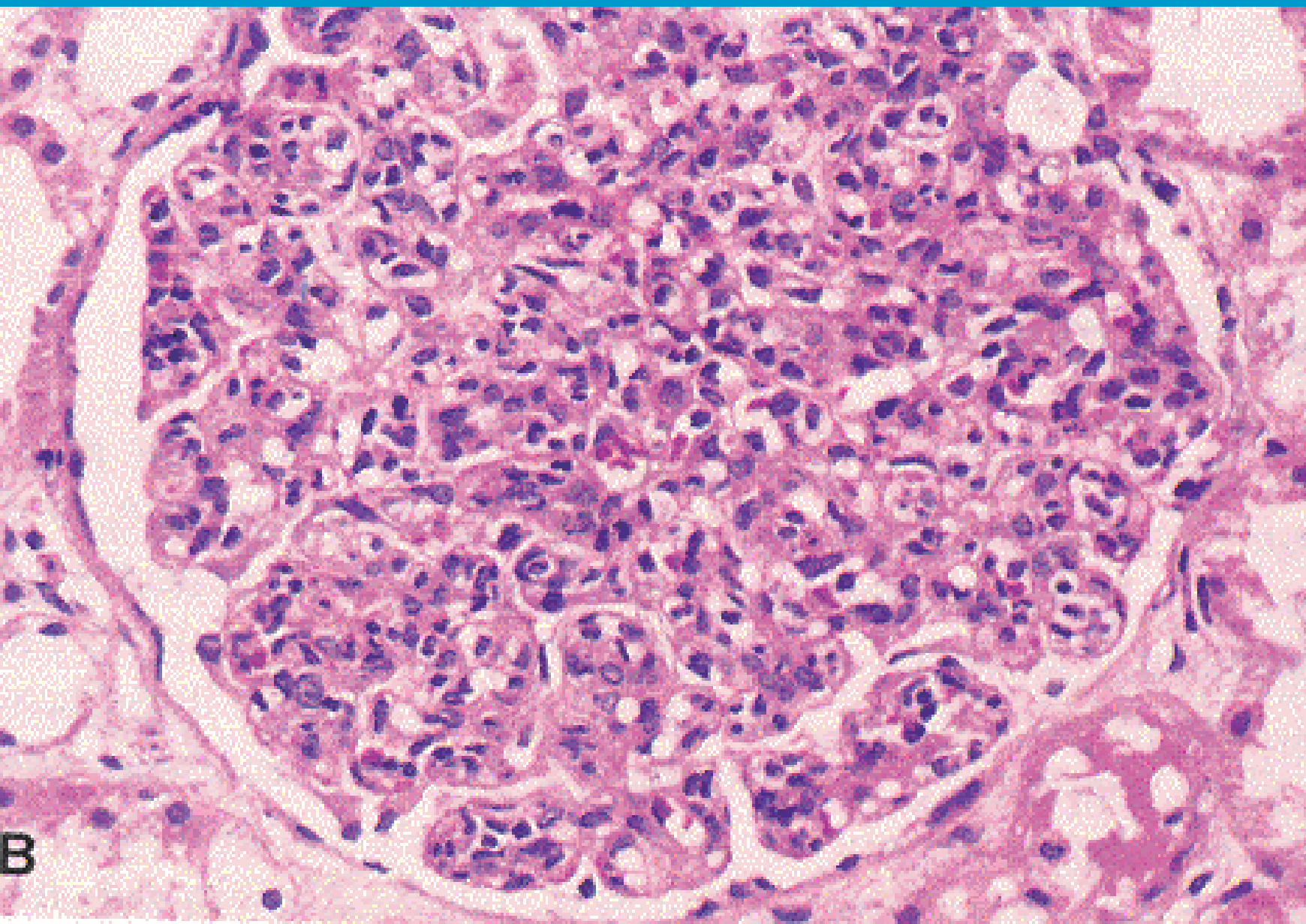
- benign familial hematuria, no progression to RF
- common inherited lesion – hereditary nephropathy
- heterozygous carriers of collagen IV mutations
- without other problems (ocular, ...)
- differential diagnosis

Glomerulopathy w. acute nephritic sy

proliferative GN w. increased mesangial/ endocapillary cellularity, commonly crescentic

- acute (diffuse endocapillary) proliferative GN
- membranoproliferative GN (C3, prim. IC),
- rapidly progressive GN
- secondary mostly in vasculitis – SLE, polyarteritis granulomatosis with polyangiitis (Wegener)

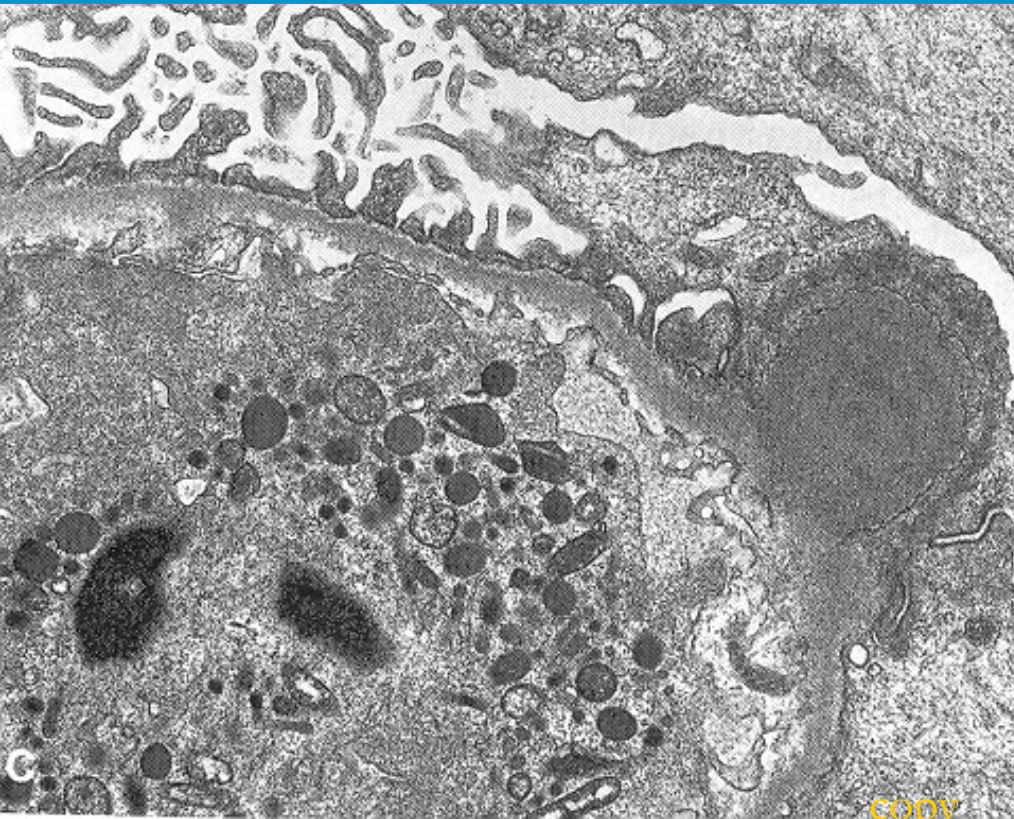
Diffuse proliferative GN



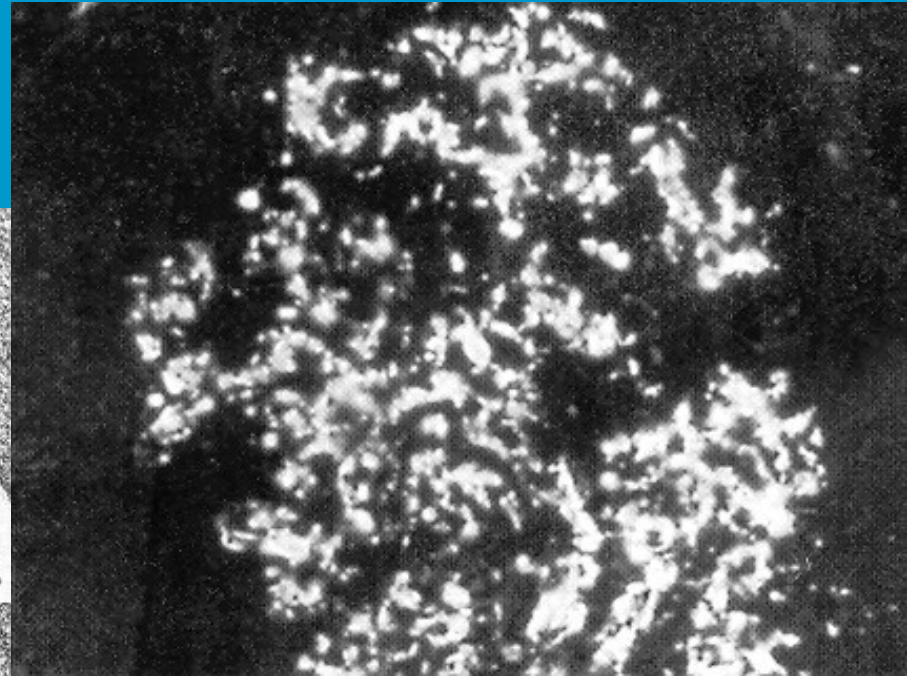
Diffuse proliferative GN

subepithelial immune complex deposition,
postinfective

Elmi
„humps“



Immunofluorescence



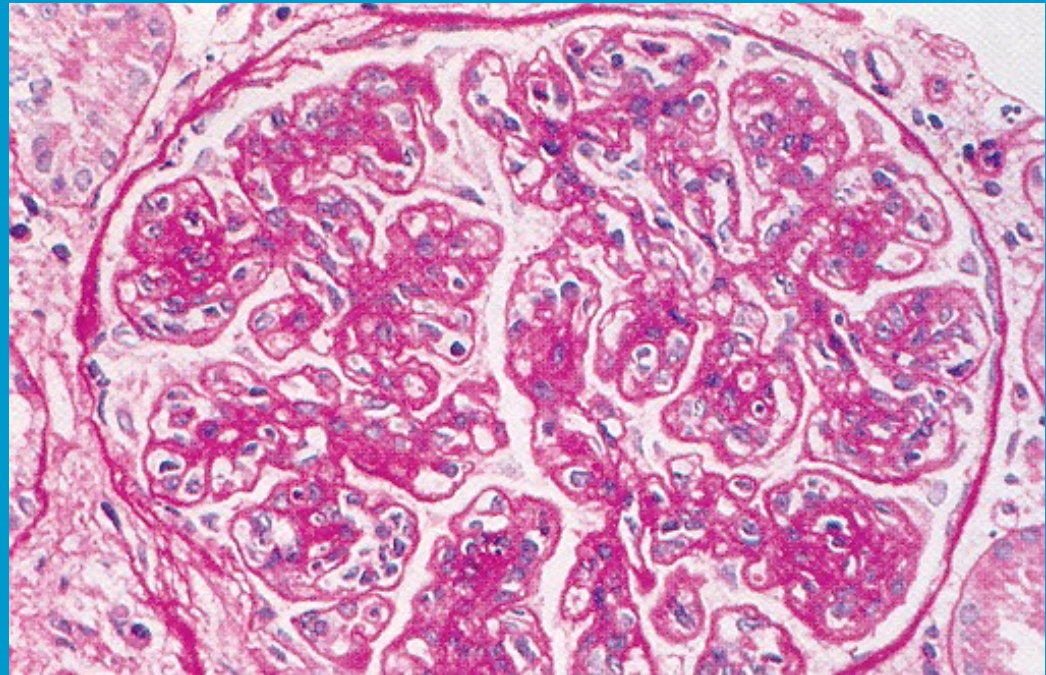
granular deposits

Membranoproliferative GN

- formerly type I-III MPGN
- **Now:** a group of disorders w. complement abnormalities
 - C3 part of complement present in biopsy
- Immune complexes GN
 - inflammatory diseases w. proliferative GN, IMF IgG+, C3+
 - IC: cryoglobulinemia (80% due to HCV); SLE, HIV; malignancy (CLL, ML), alpha1- AT deficiency),
- C3 nephropathy (C3 GN and dense deposit disease)
- young, poor progn., CHRI, recurrent in graft

Membranoproliferative GN

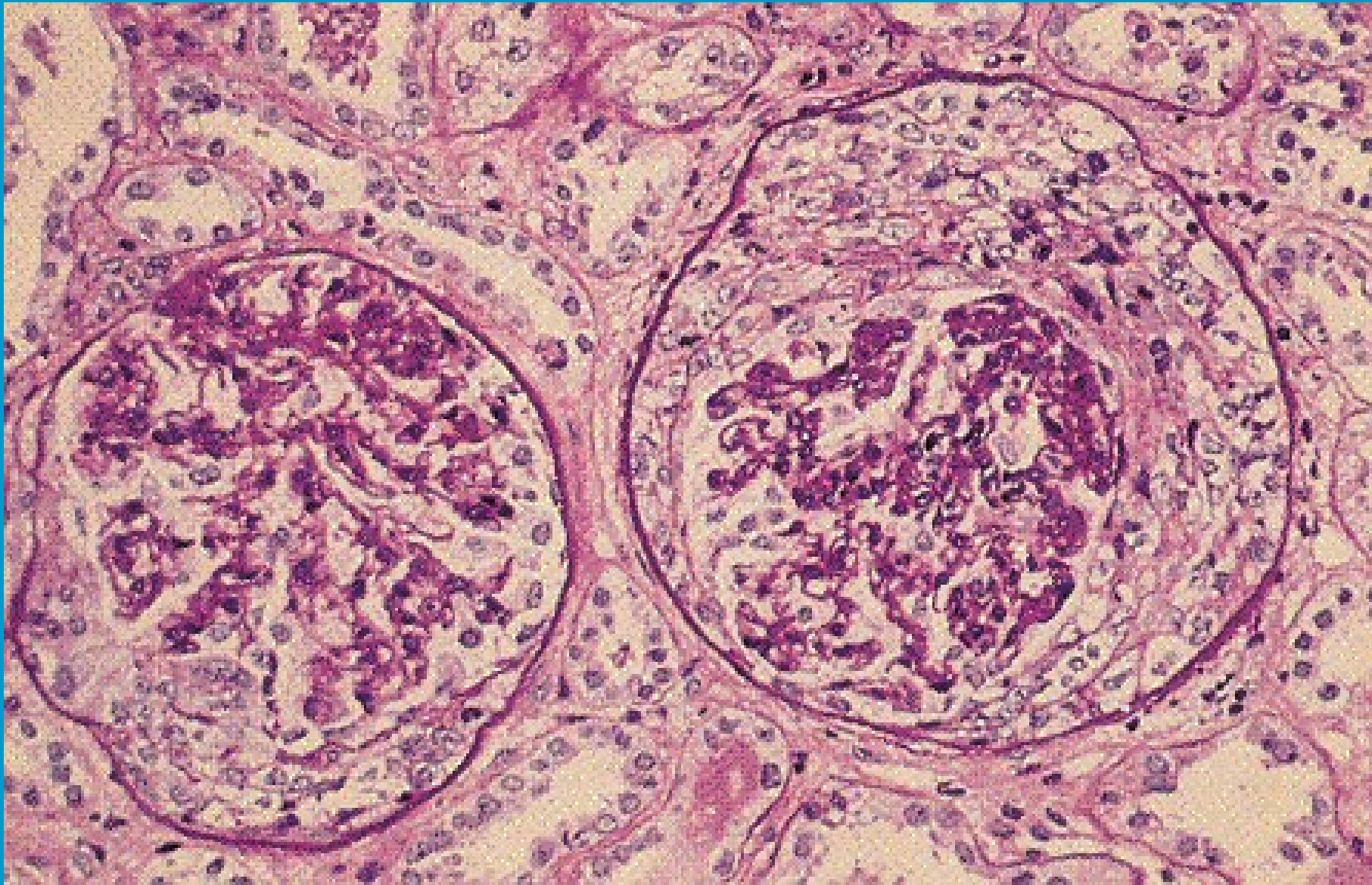
- diffuse mesangial + endothelial cells activation and proliferation (mesangiocapillary GN), mesangial matrix expansion, BM thickening – „duplication – tram-track“



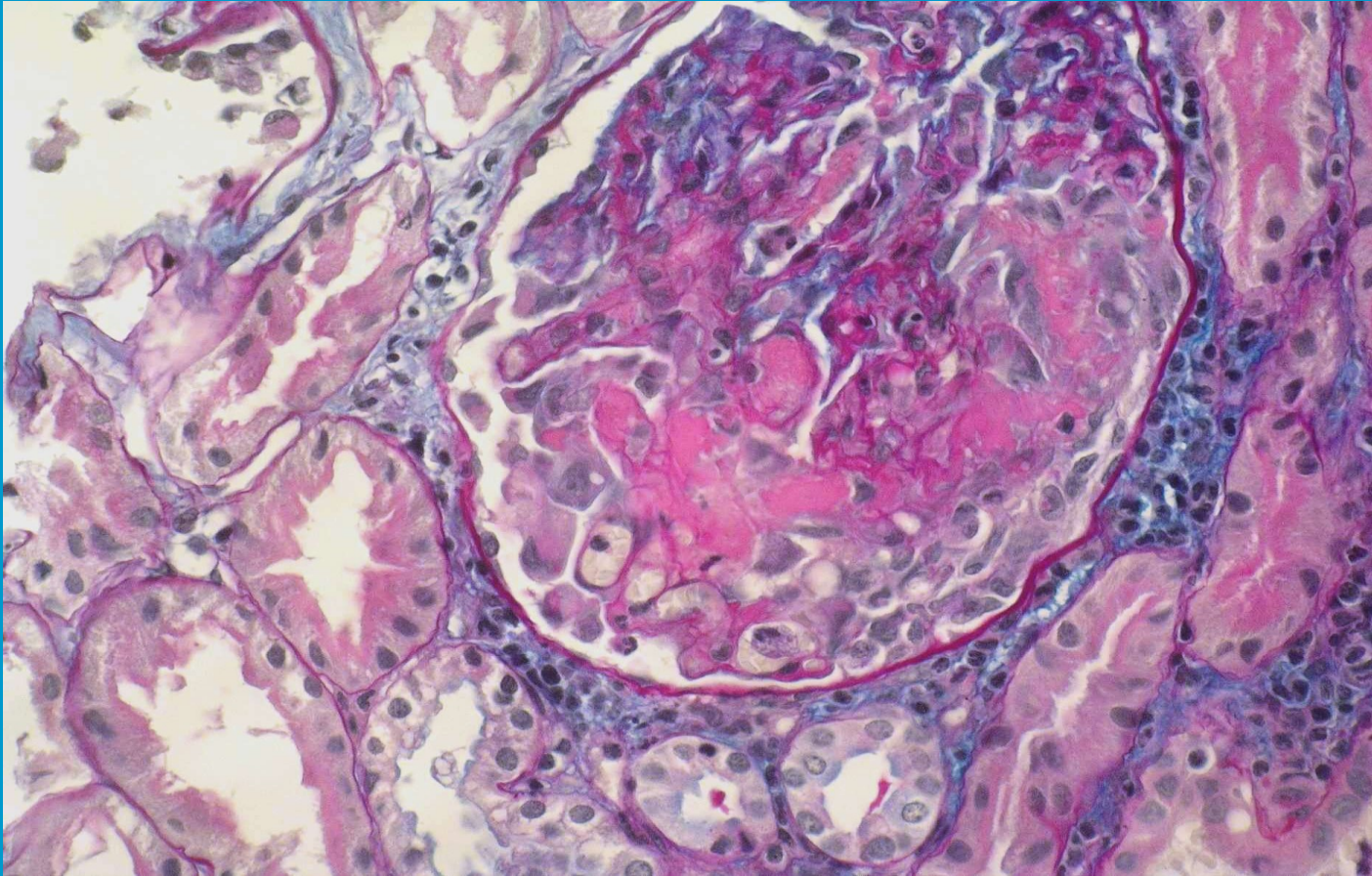
Rapidly progressive (crescentic) GN

- clinically rapidly progressive GN,
- various etiology (immune-complex mediated incl. IgA, pauci-immune + ANCA, anti-GBM)
- small vessel vasculitis, SLE,...
- necrotising GN – capillary rupture, exudation – extracapillary proliferation - crescentic
- Immunosuppression in active lesion + plasma exchange in known circulating AB (anti-GBM)
- No direct therapy in fibrosing lesion

Rapidly progressive (crescentic) GN



Rapidly progressive (crescentic) GN



Anti-GBM disease

- uncommon
- rapidly progressive renal failure +/- hemoptysis (Goodpasture sy)
- linear deposits of IgG

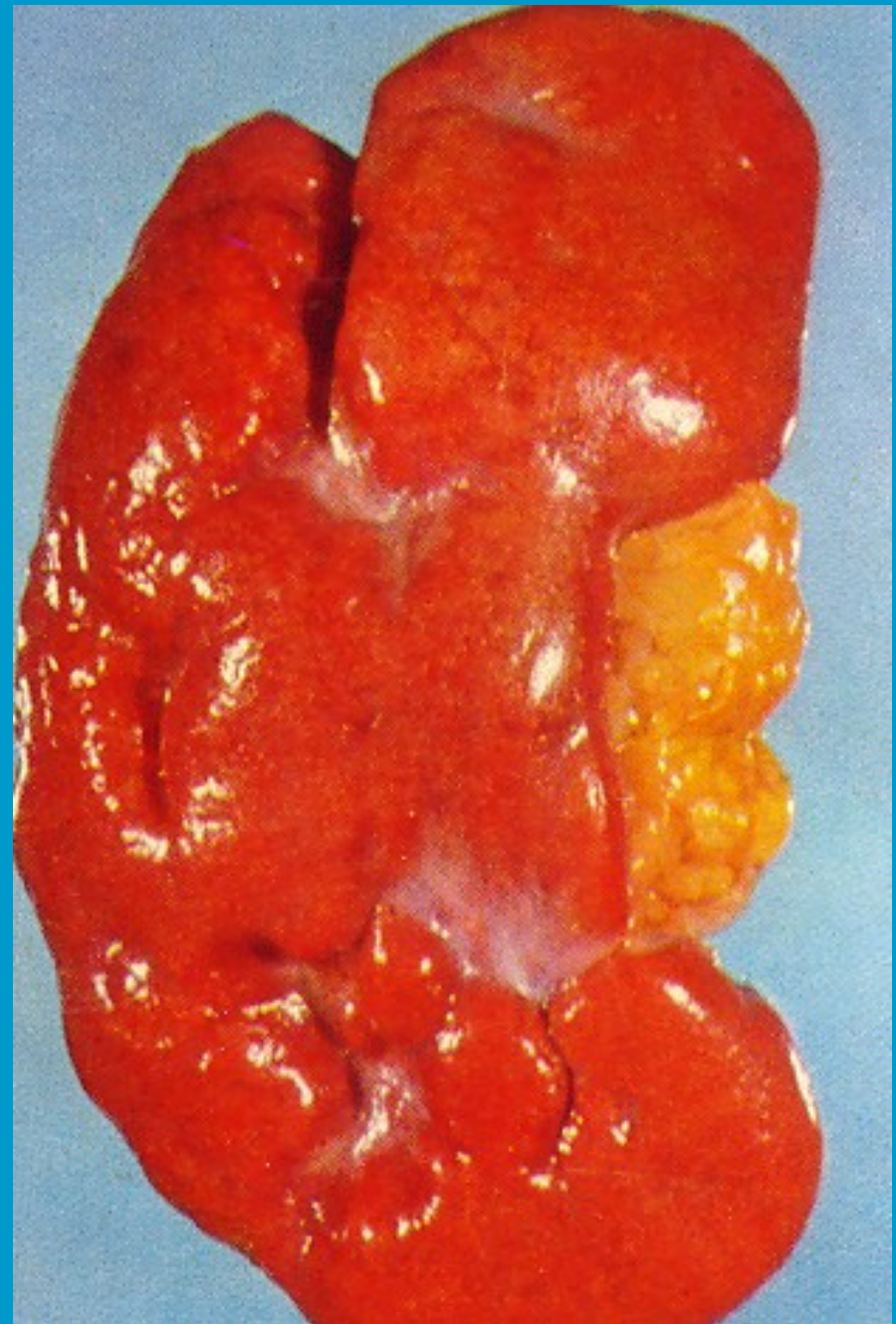
Glomerulopathy due to vascular disorders

- in hypertension
- renal infarction
- renal artery stenosis
- thrombotic microangiopathy (HUS, thrombotic thrombocytopenic purpura)
- systemic vasculitis (ANCA+, microscopic polyangiitis, anti-GBM GN)

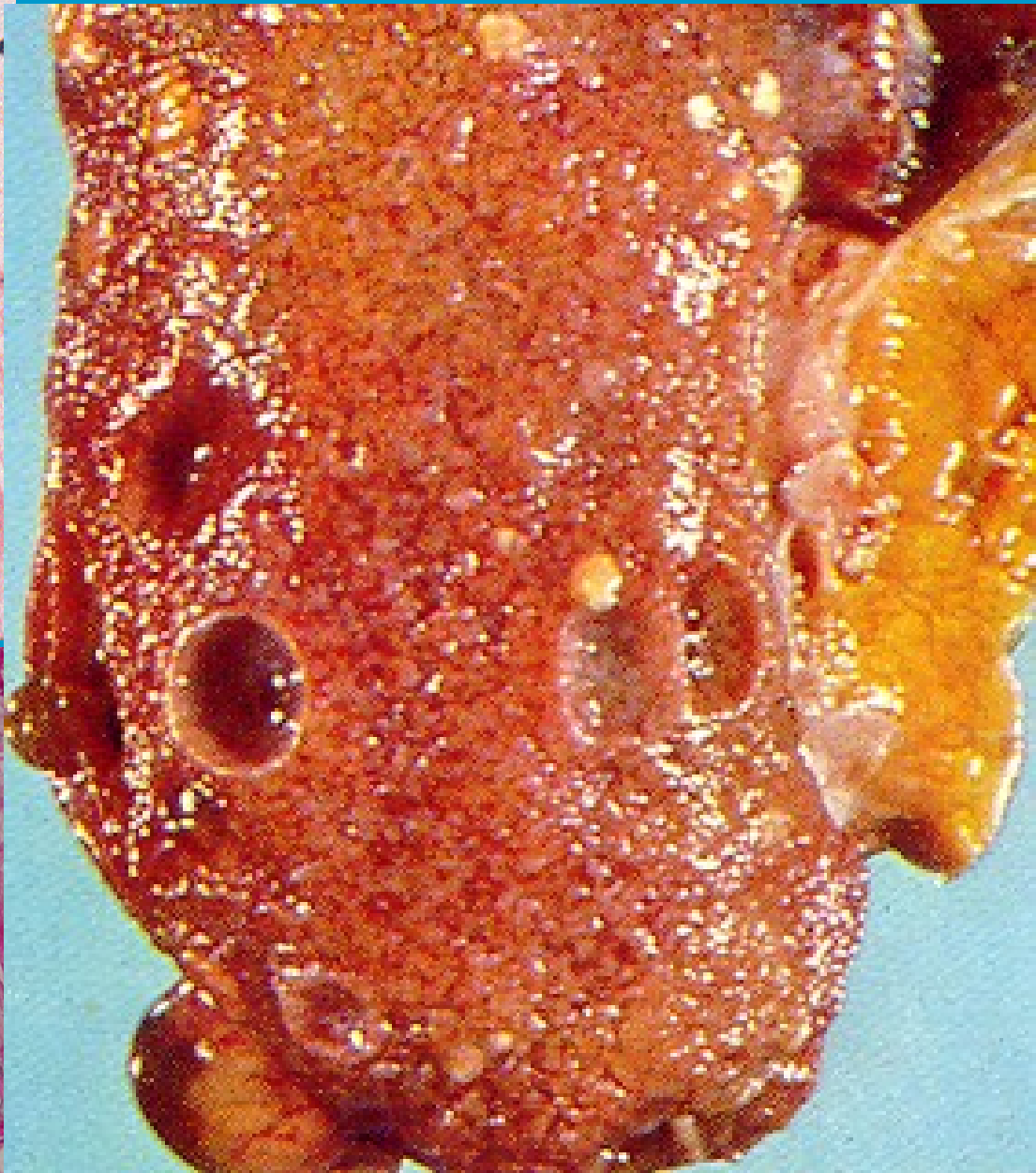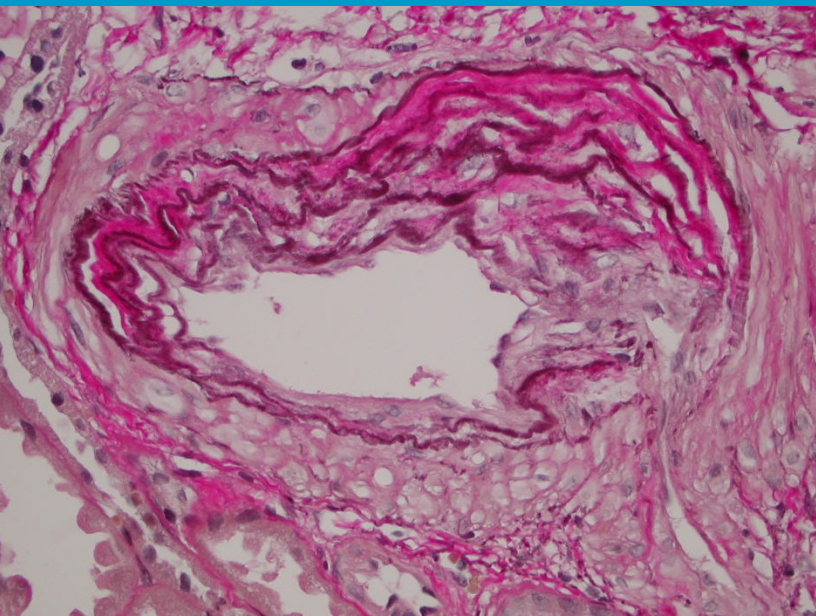
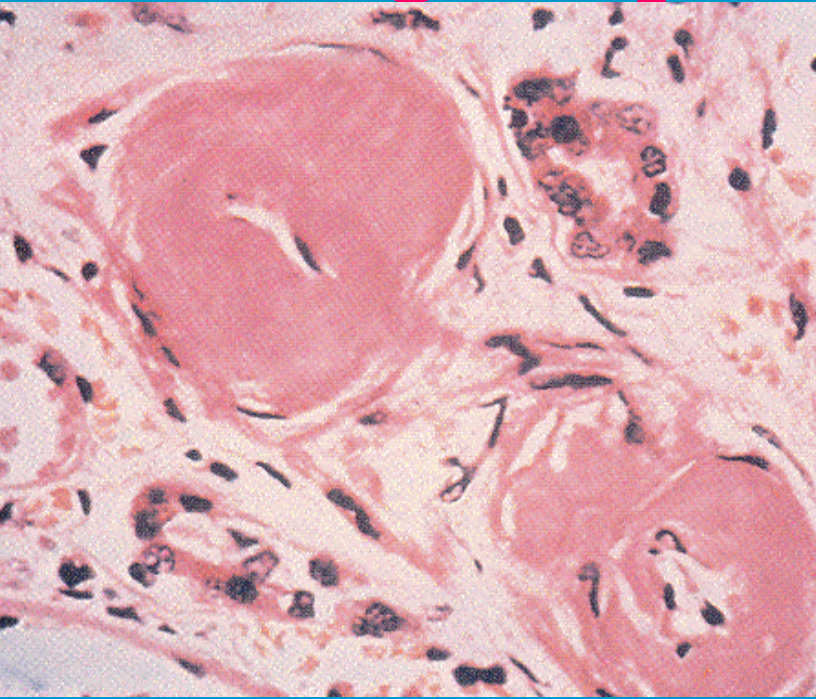
Nephropathy in hypertension

- Benign nephrosclerosis= compensated hypertension
 - macro: decreased size, granulated surface, atrophic cortex 2-3 mm
 - micro: hyaline insudation on arteriolar wall, arteries w. hypertrophic media, intimal sclerosis, glomerular ischemic changes + loss, tubular atrophy, interstitial fibrosis
 - wrinkling GBM

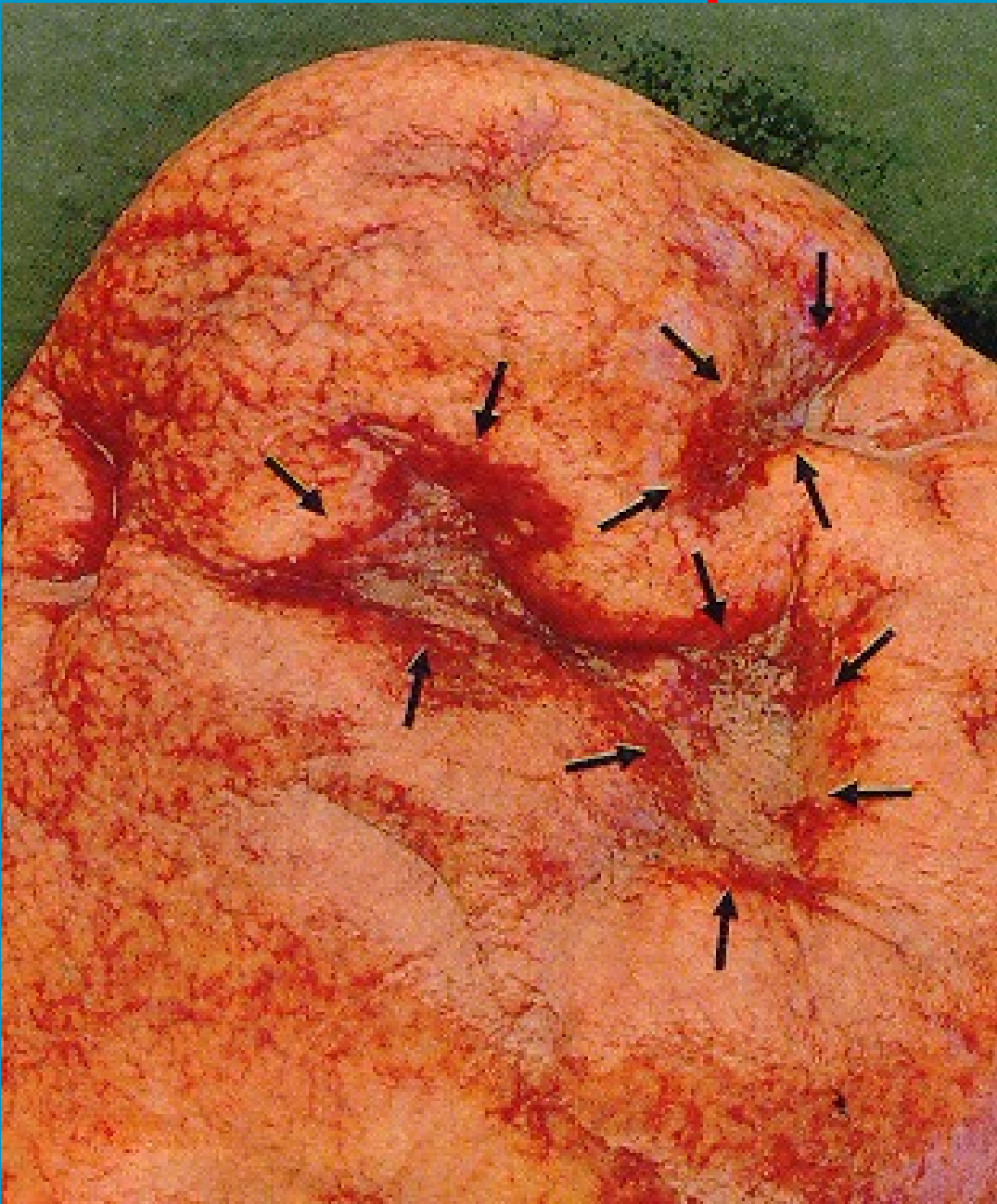
Benign nephrosclerosis



Benign nephrosclerosis arteriolosclerotic

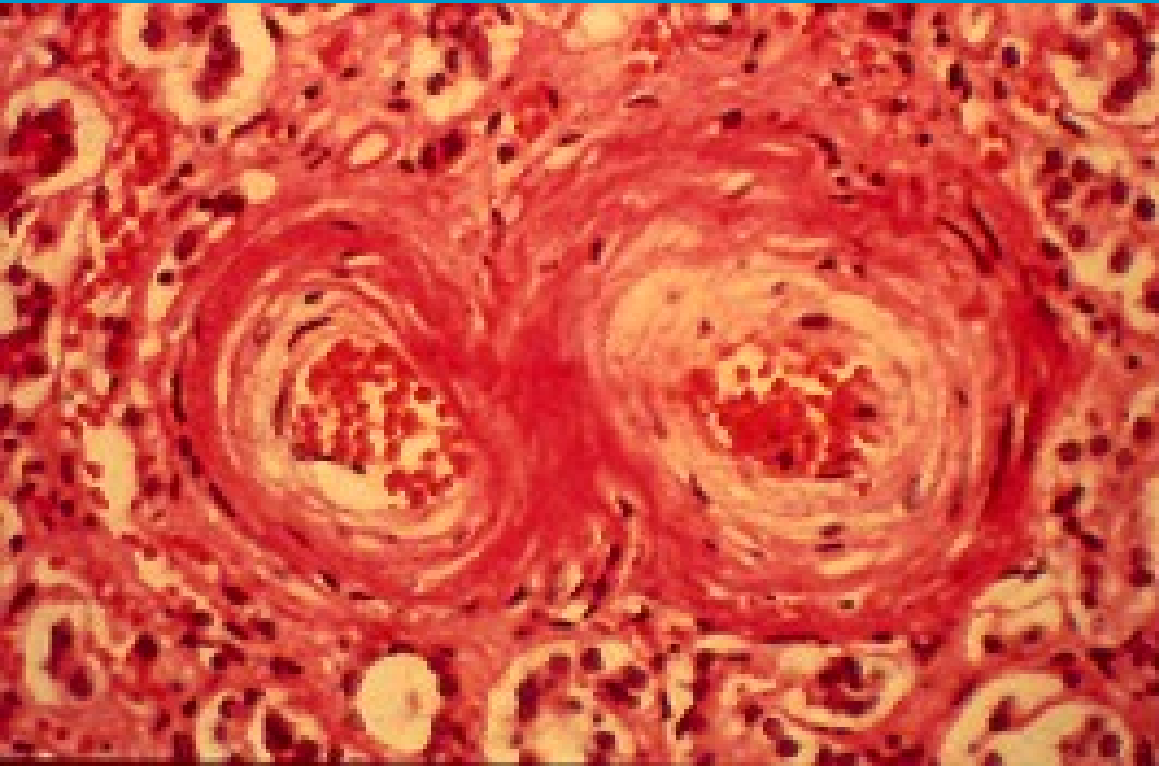
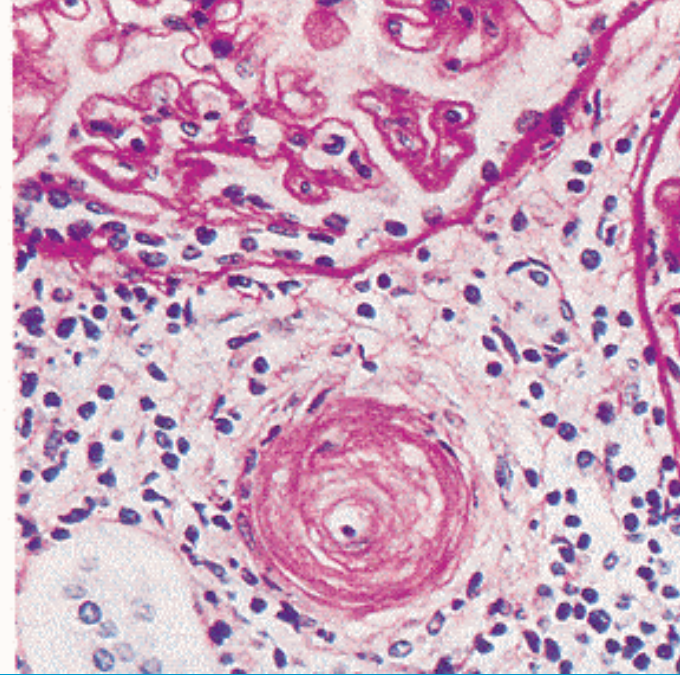
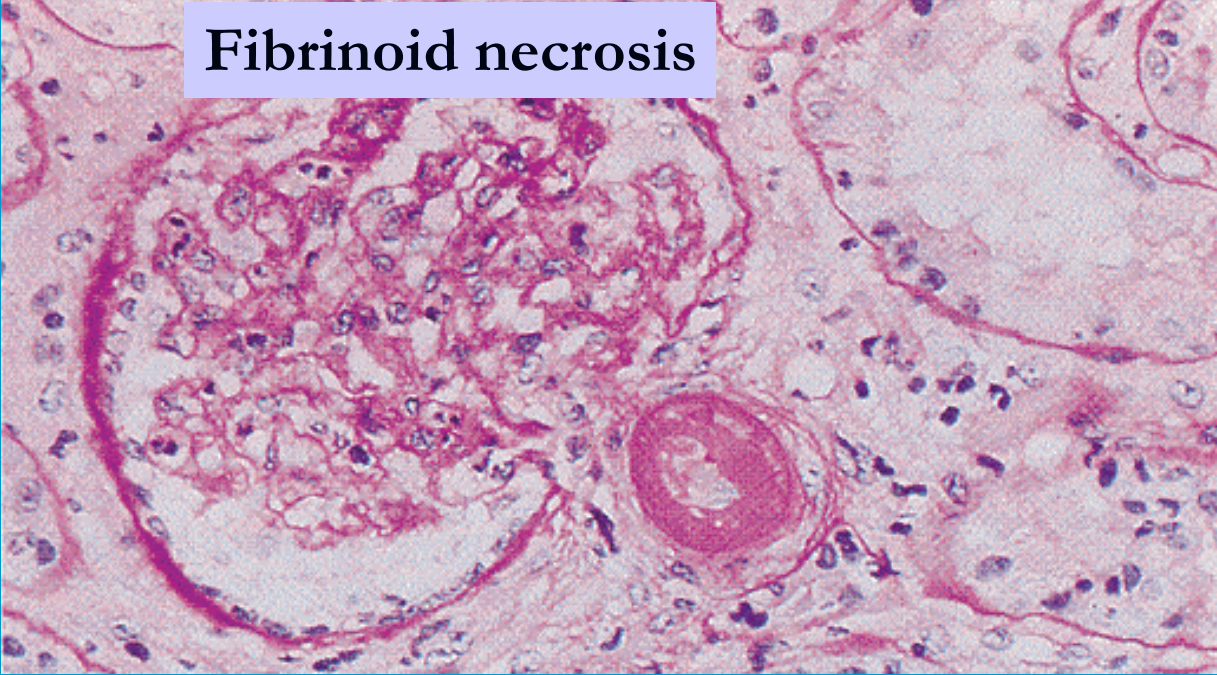


Nephrosclerosis



granulations
and post-infarct
scars

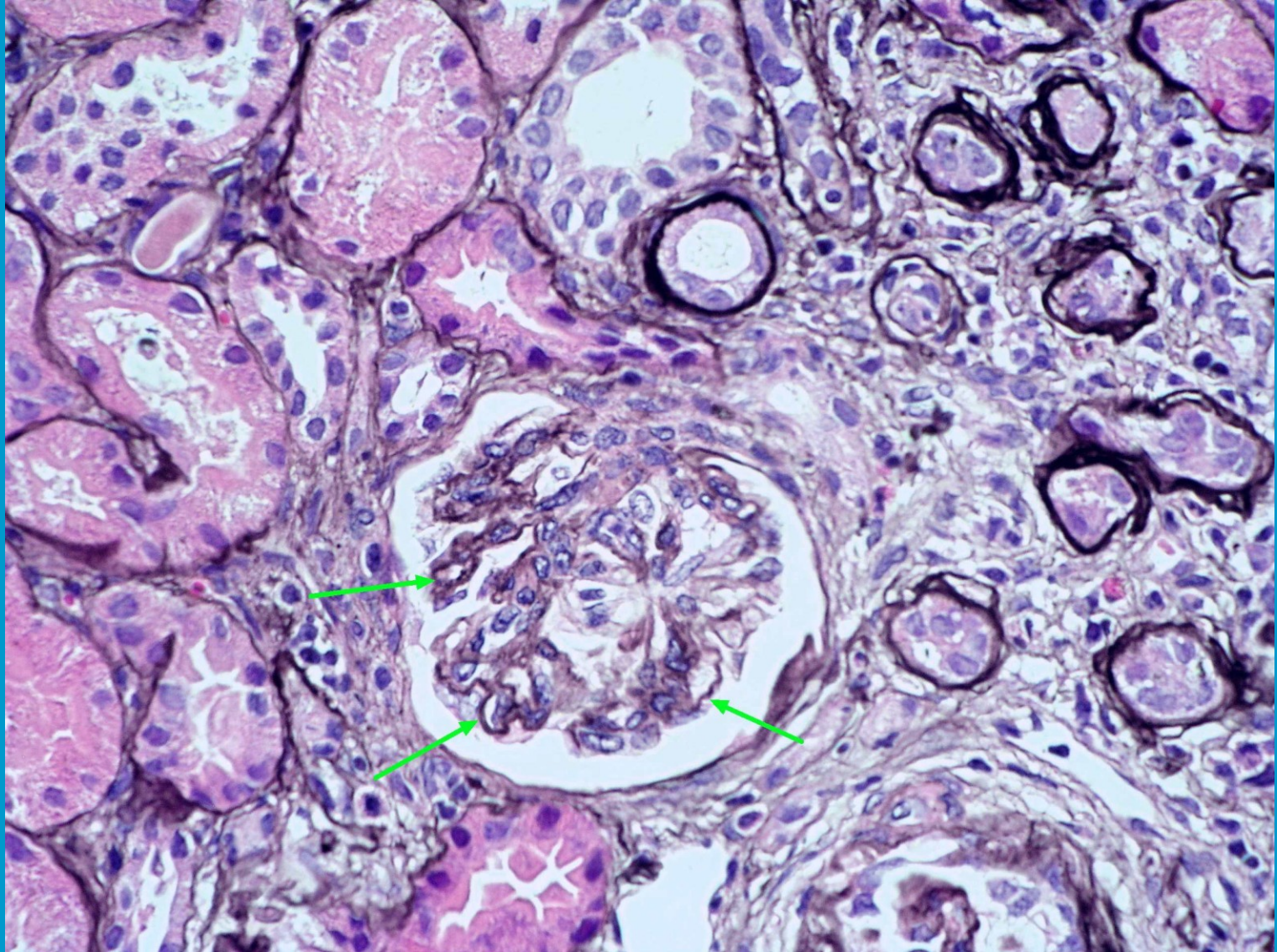
Fibrinoid necrosis



Onion-skin

formations – hyperplastic arteriosclerosis +/- arteriolonecrosis; hyaline arteriosclerosis hypertension

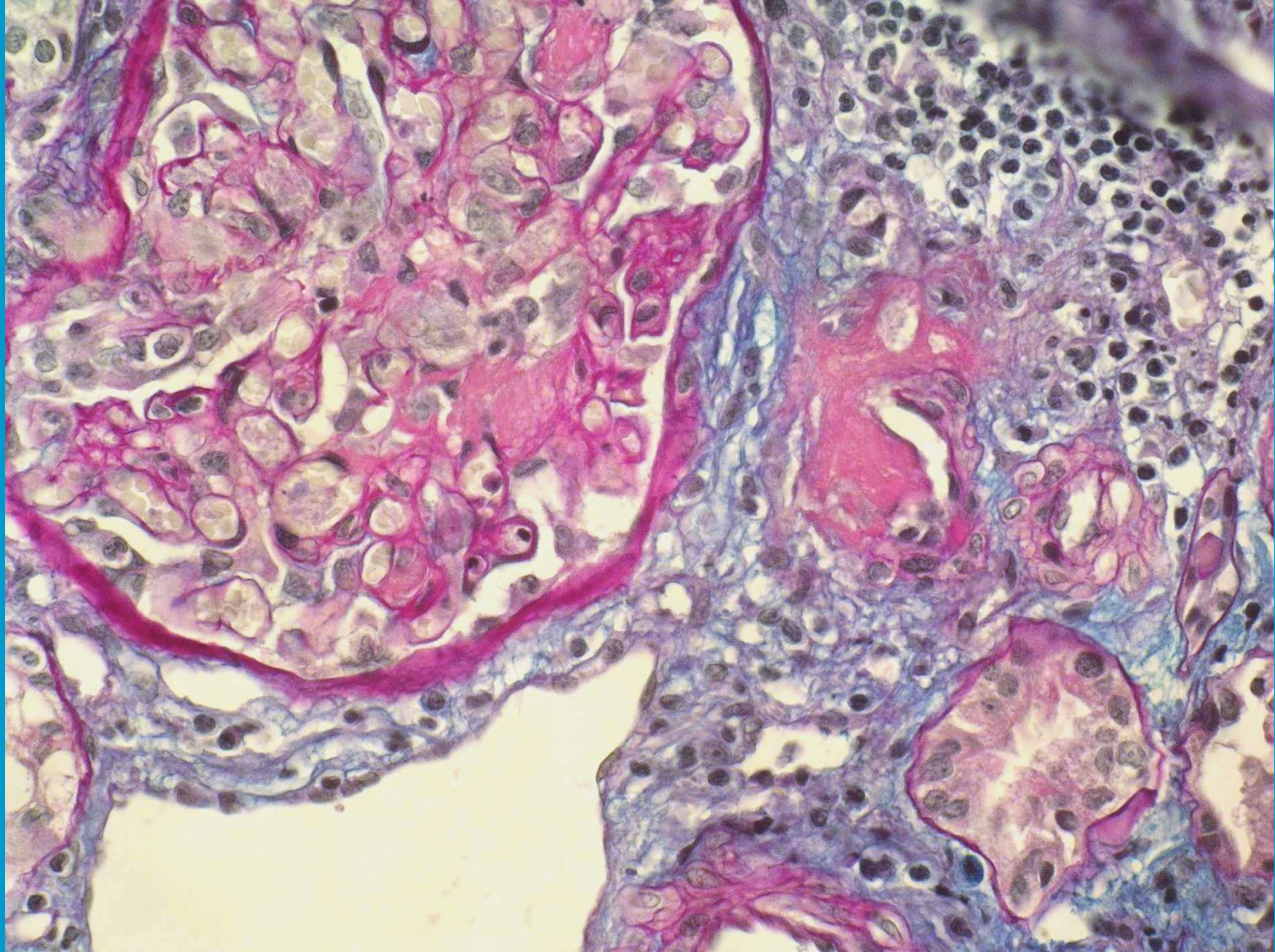
Nephrosclerosis



Nephropathy in hypertension

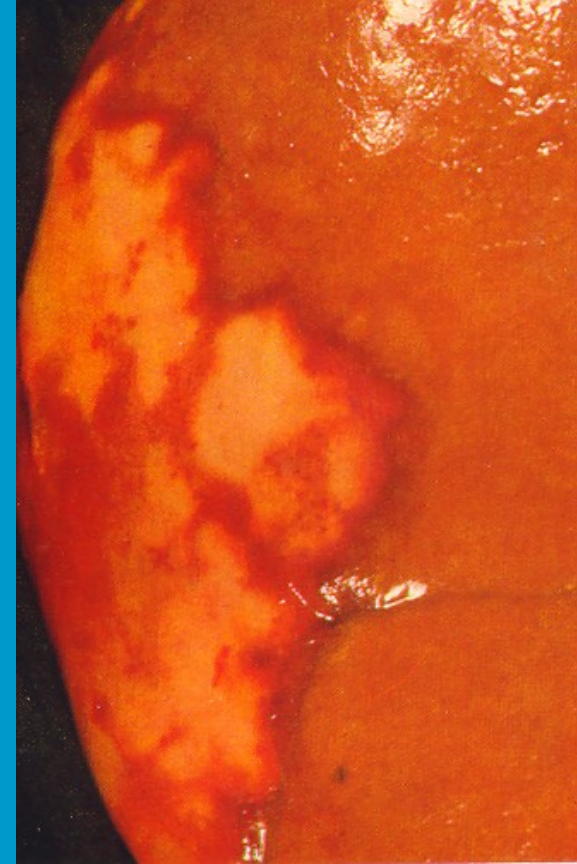
- Malignant nephrosclerosis = accelerated hypertension (190/130 mm Hg)
 - approx. 5 % HT
 - emergency, radical antihypertensive th. necessary
 - high risk of RF, heart failure, brain haemorrhage
 - endothelial damage
 - macro edema, pinpoint bleeding, infarctions
 - micro edema, fibrinoid necrosis, possible thrombi, haemorrhagic necrosis or oschemic collapse of glomeruli

Nephropathy in hypertension



Renal infarction

- Causes of renal artery branches obstruction
 - thrombembolia;
 - thrombosis
 - vasculitis
 - aneurysm of abdominal aorta

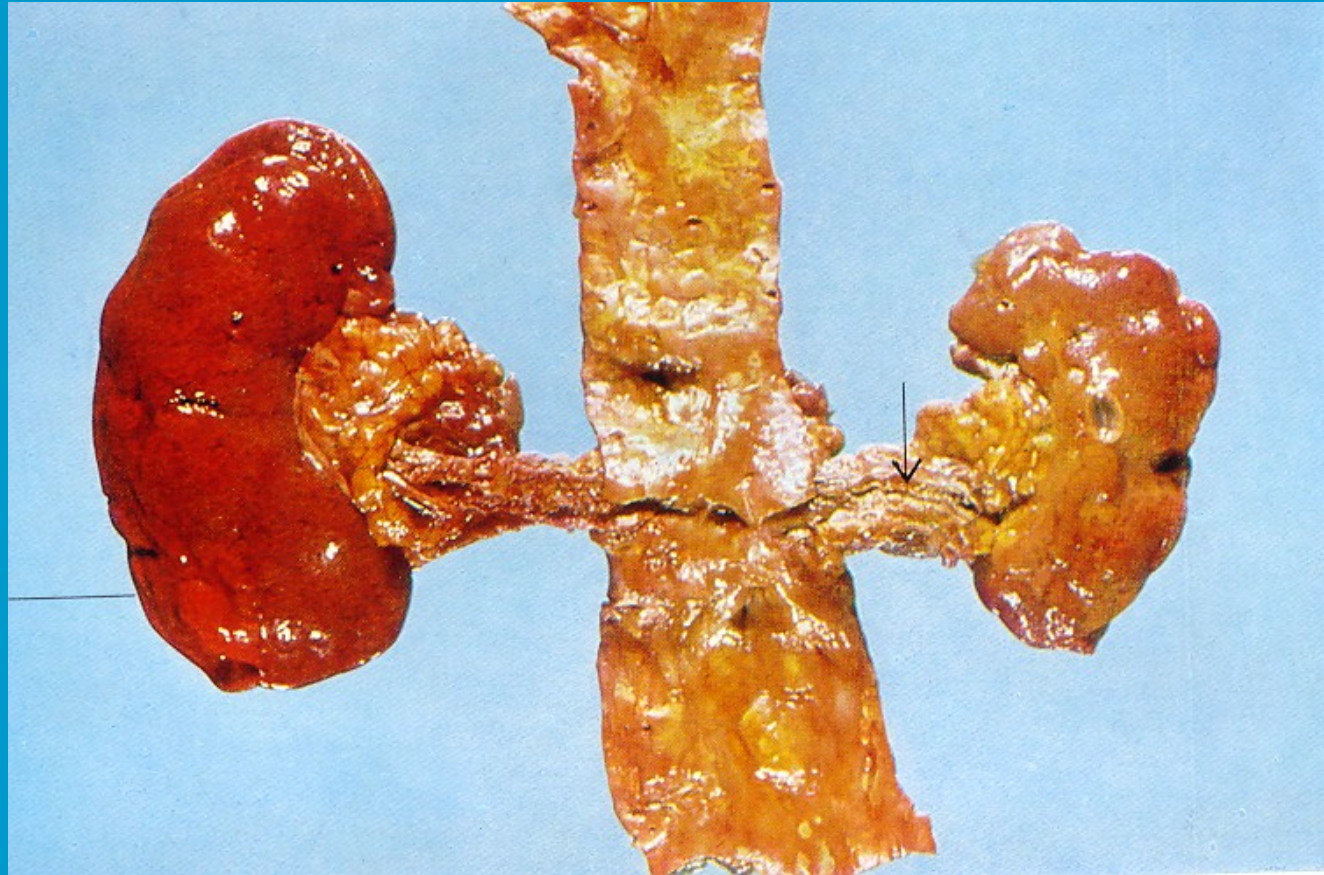

Renal artery stenosis

- cause of renovascular hypertension
 - ↓ of blood pressure in afferent arteriole
 - activation of renin-angiotensin system →
 - ↑ BP, atrophy in longer duration
 - hypertension in contralateral kidney

Benign nephrosclerosis – hypertensive nephropathy

- a. renalis stenosis, renal atrophy and hypertension (Goldblatt)



Thrombotic microangiopathy

- Endothelial damage → microthrombi → damage of erythrocytes + platelets → hemolytic anaemia
 - fibrinoid necrosis without vasculitis
- Hemolytic-uremic sy (typical – epidemic – Shiga toxin; atypical – antiphospholipid antibodies, malignant hypertension, pregnancy, drugs, irradiation, ...)
- Thrombotic thrombocytopenic purpura
 - genetic deficiency in von Willebrand-cleaving factor)
 - acquired (AI, therapy) sudden, CNS, heart damage
- Pregnancy complications: pre- eclampsia

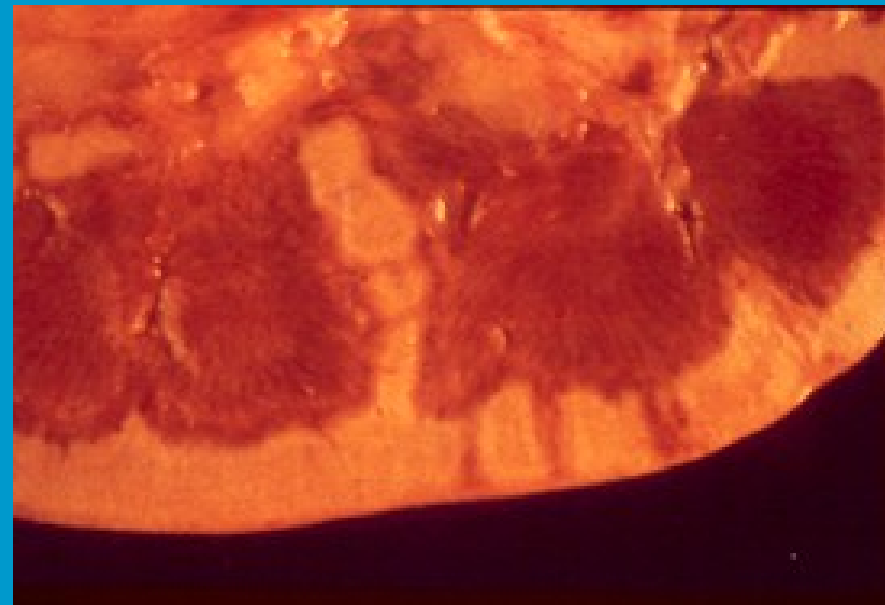
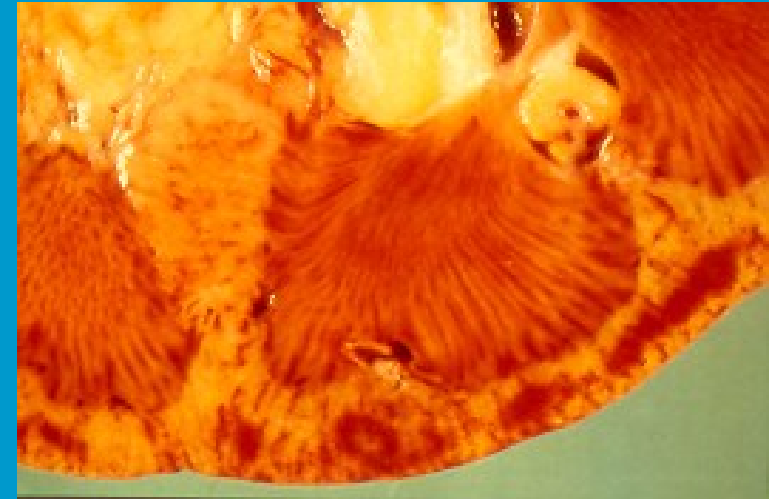
Hemolytic-uremic syndrome

1) Ischemic cortical changes with tubular dilatation
2) Disperse focal hemorrhages,
necroses

3) Diffuse cortical
Acute nephropathy
+ haemolysis
thrombocytopenia

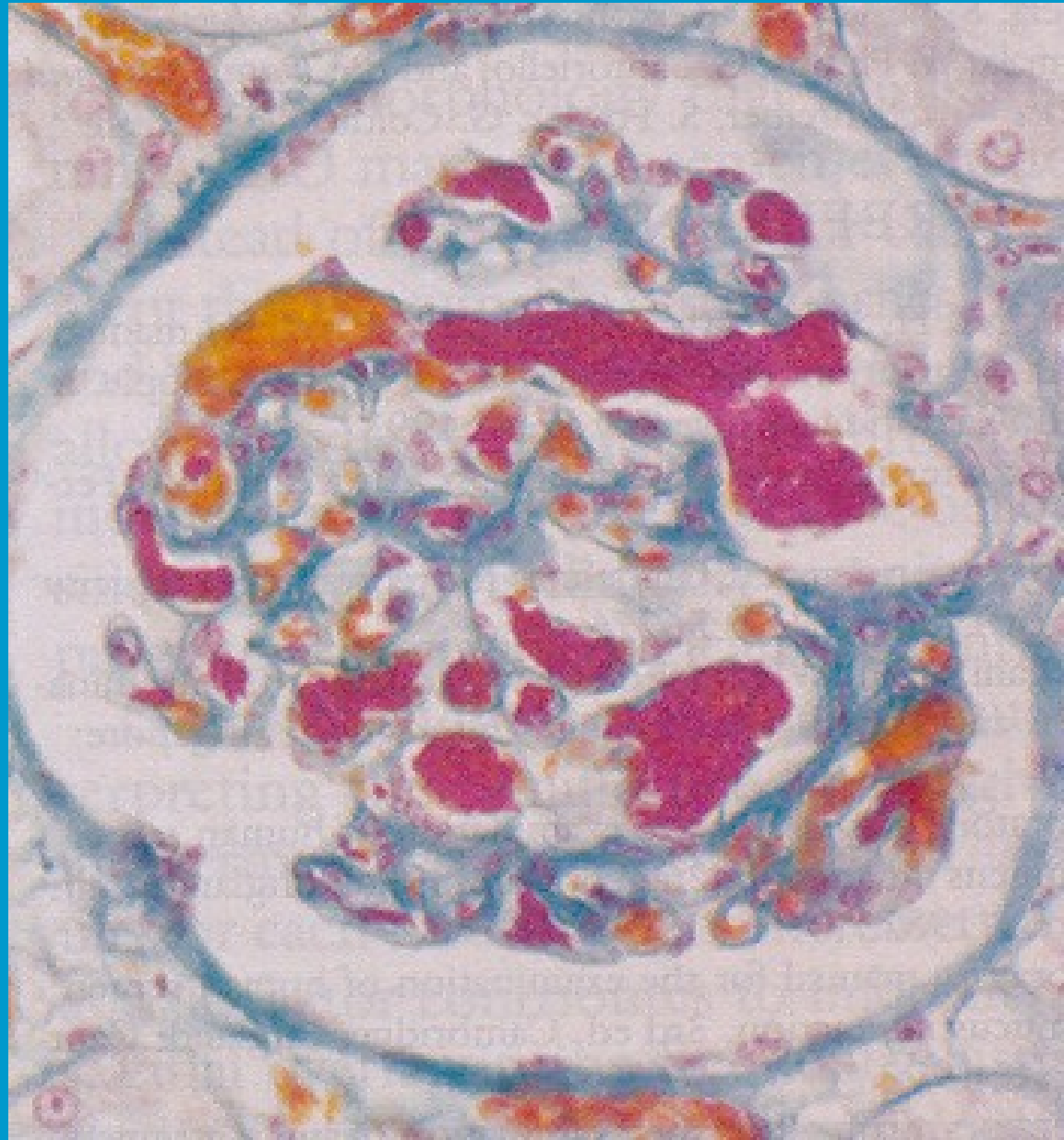
diarrhea

E.coli verotoxin,
other toxins, AI



Hemolytic-uremic syndrome

- Microtrombi in glomerular capillaries (endothelial injury + platelet activation)
- Thickening of capillary walls
- Necrosis and intimal hyperplasia of small arteries



Systemic vasculitis

■ 3 main types

■ vasculitis directly caused by autoantibodies

- anti-GBM glomerulonephritis – Goodpasture sy

■ immune complex vasculitis

- Henoch-Schönlein purpura

■ ANCA vasculitis

- granulomatosis w. polyangiitis (Wegener v.) c-ANCA
- microscopic polyangiitis p-ANCA
- Churg-Strauss eosinophilic granulomatosis w. polyangiitis

Systemic vasculitis c-ANCA

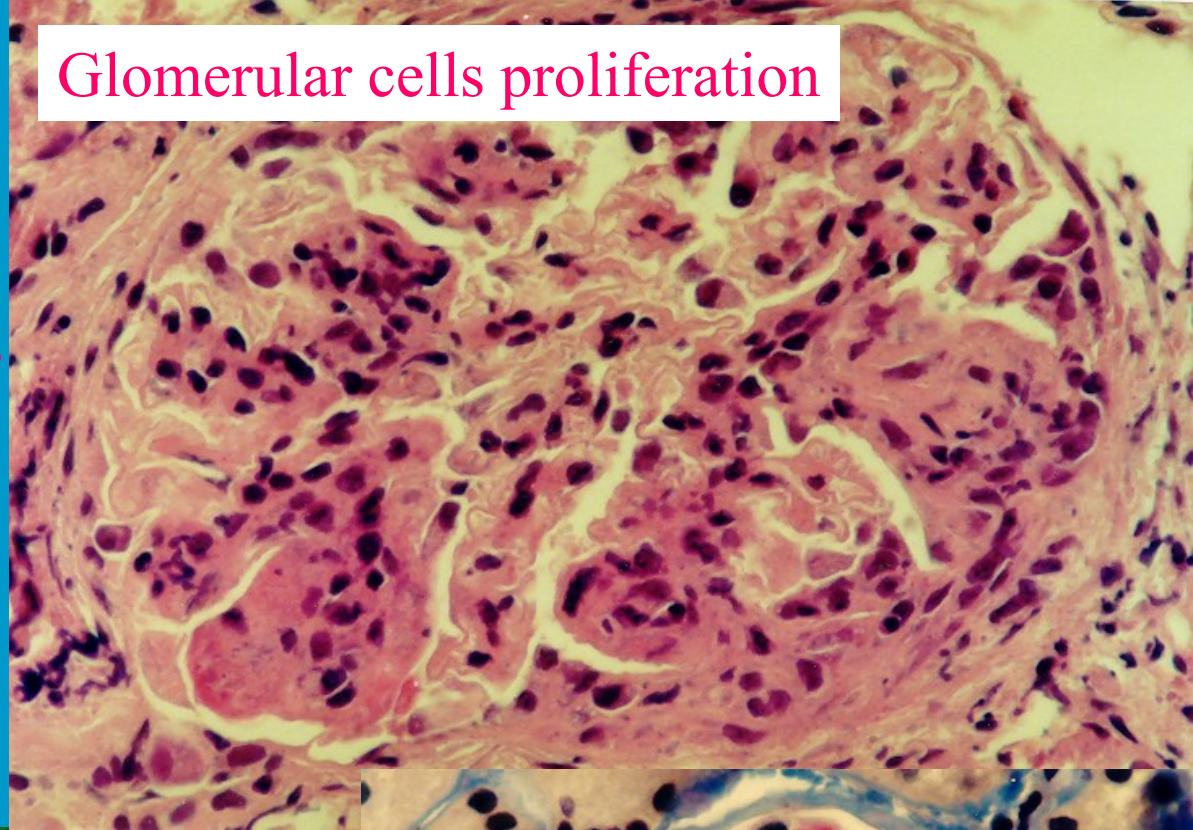
- Small vessel vasculitis
- Incidence ↑ with age
- High mortality
- Renal or multiorgan
- Rapidly progressive GN, hematuria, proteinuria, red cell casts

Glomerulopathy in SLE

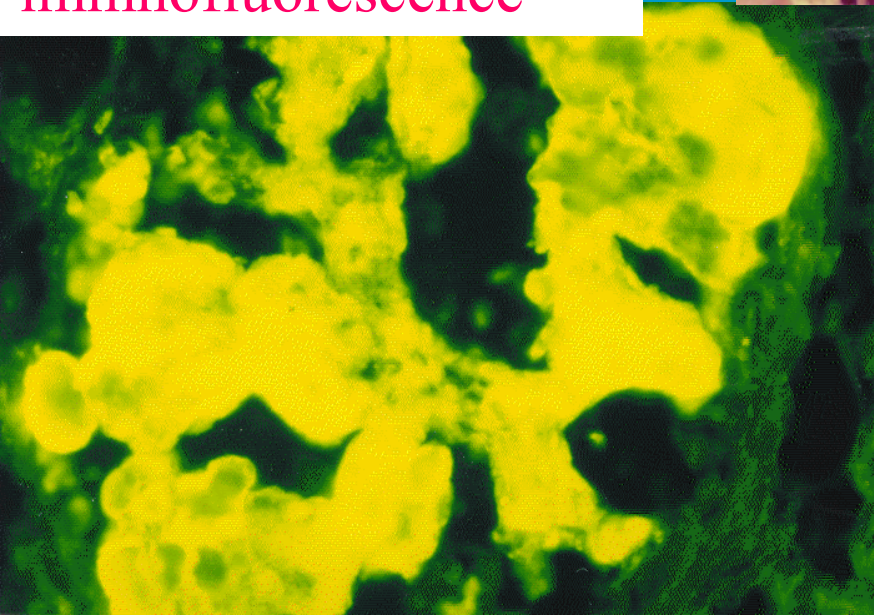
- Multiorgan AI disease
- Variable autoantibodies
- Kidney damage in 80 %
- Variable presentation and/or type of kidney damage
 - asymptomatic hematuria + proteinuria
 - nephrotic sy
 - RPGN
- 6 classes of lupus nephritis

Lupus nephritis

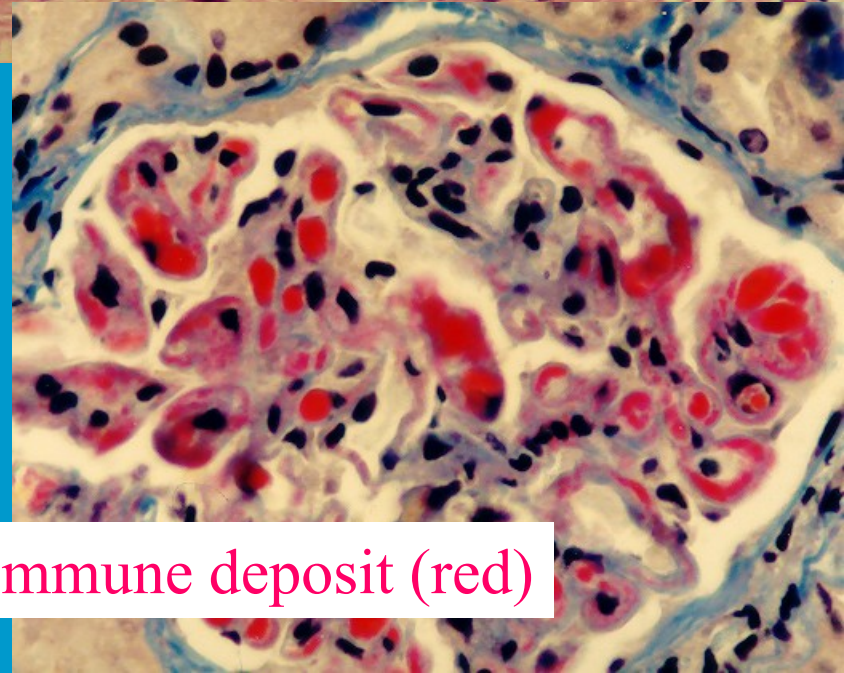
Glomerular cells proliferation



Deposits in direct immunofluorescence



Immune deposit (red)



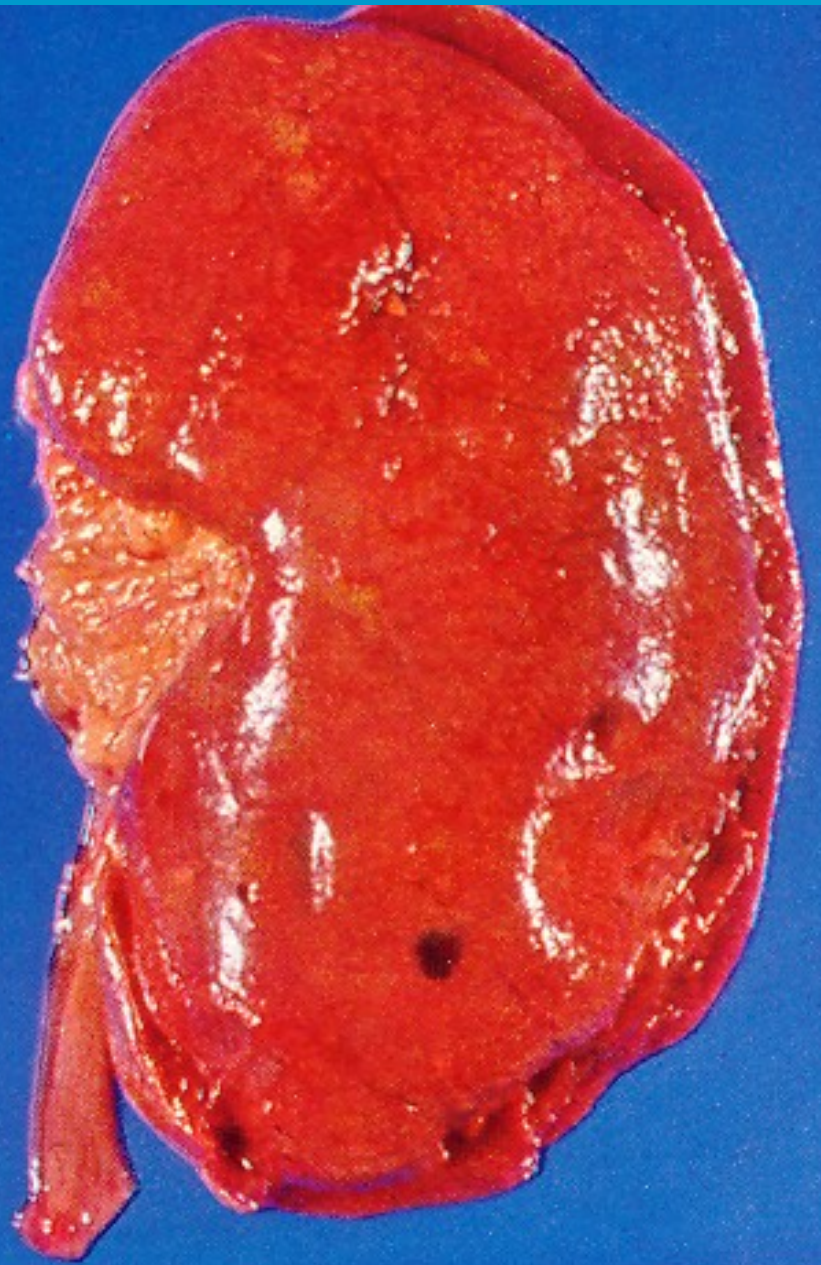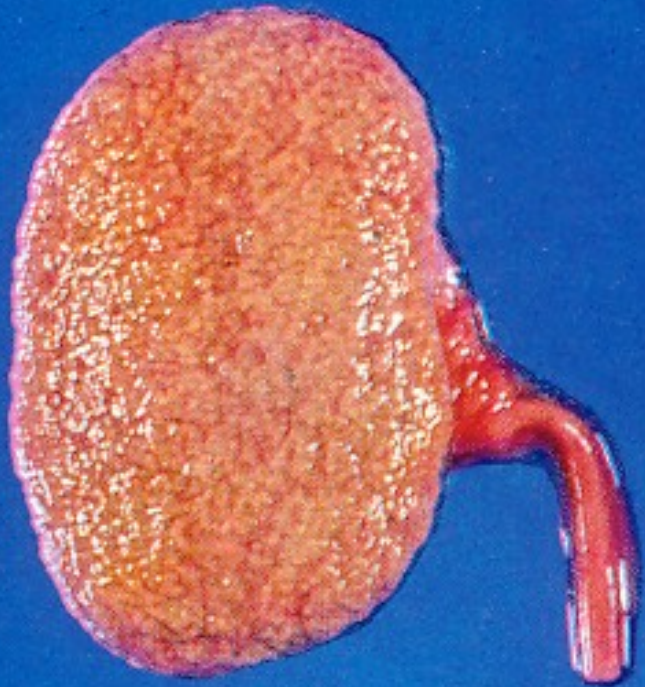Chronic glomerulonephritis

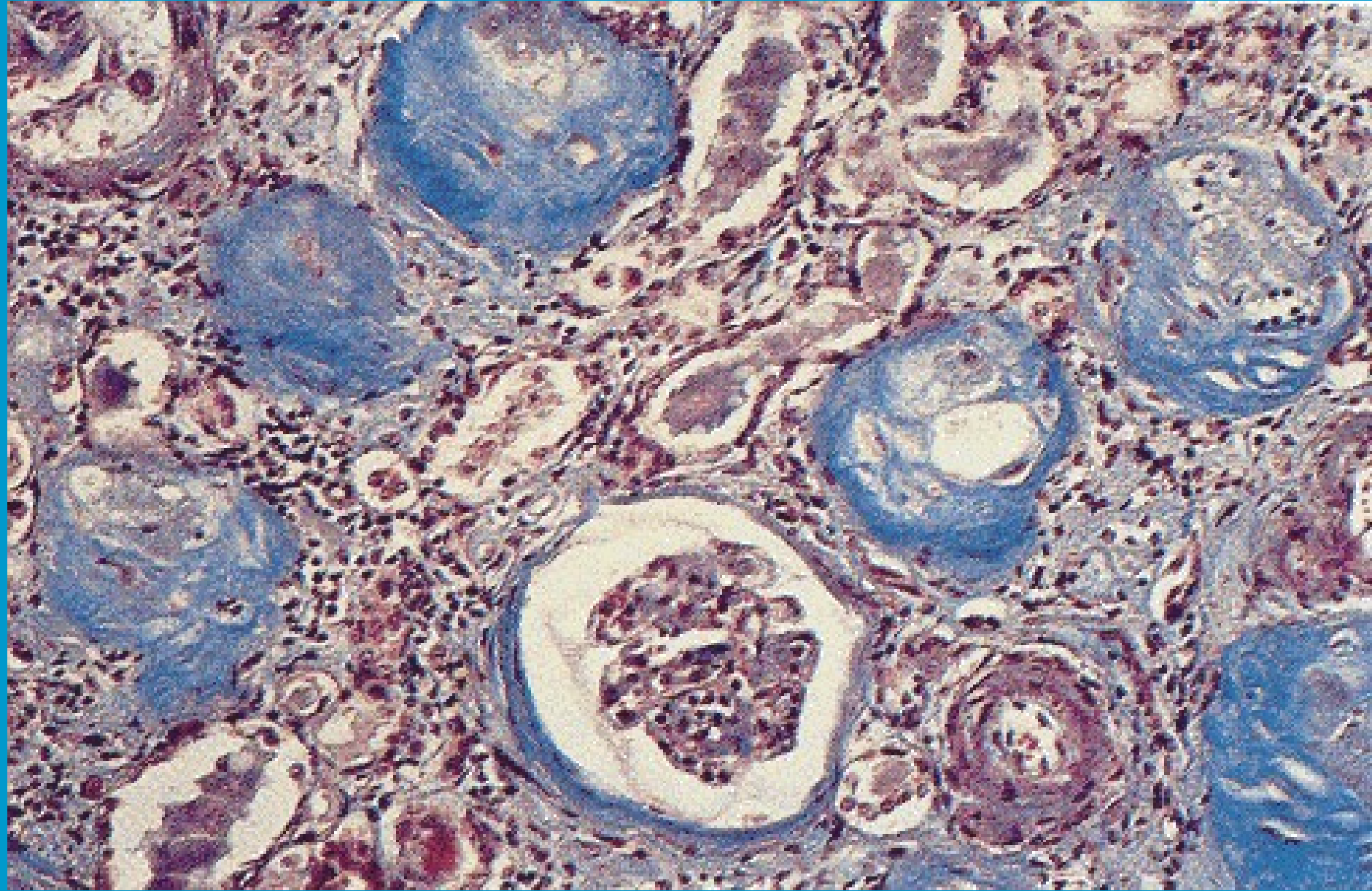
- end stage of variable glomerular disease
- commonly no more identifiable
- different rate of progression in different diseases
- FSGS 50-80%
- RPGN, membranous, membranoproliferative ~ 50%
- poststreptococcal 1-2%

Chronic glomerulonephritis

- granular surface (!x chronic interstitial nephritis, nephrosclerosis, diabetic nephropathy,...)
- thin cortex
- obliterated glomeruli, arterio- and arteriolosclerosis (hypertension), tubular atrophy

Chronic GN – end-stage kidney





Tubulo-interstitial disorders

- Concurrent damage to the tubular epithelium and interstitium
- Usually no glomerular damage, or only secondary (e.g. glomerulosclerosis)

Tubulo-interstitial disorders - groups

TUBULOINTERSTITIAL NEPHRITIS (TIN)

Acute pyelonephritis

Chronic pyelonephritis, reflux nephropathy

Abacterial interstitial nephritis (drugs, etc.)

ISCHEMIC AND TOXIC INJURY

Acute tubular necrosis

OTHERS (e.g. obstructive uropathy, tbc, myeloma, urate nephropathy, immunologic reaction AI, posttransplant)

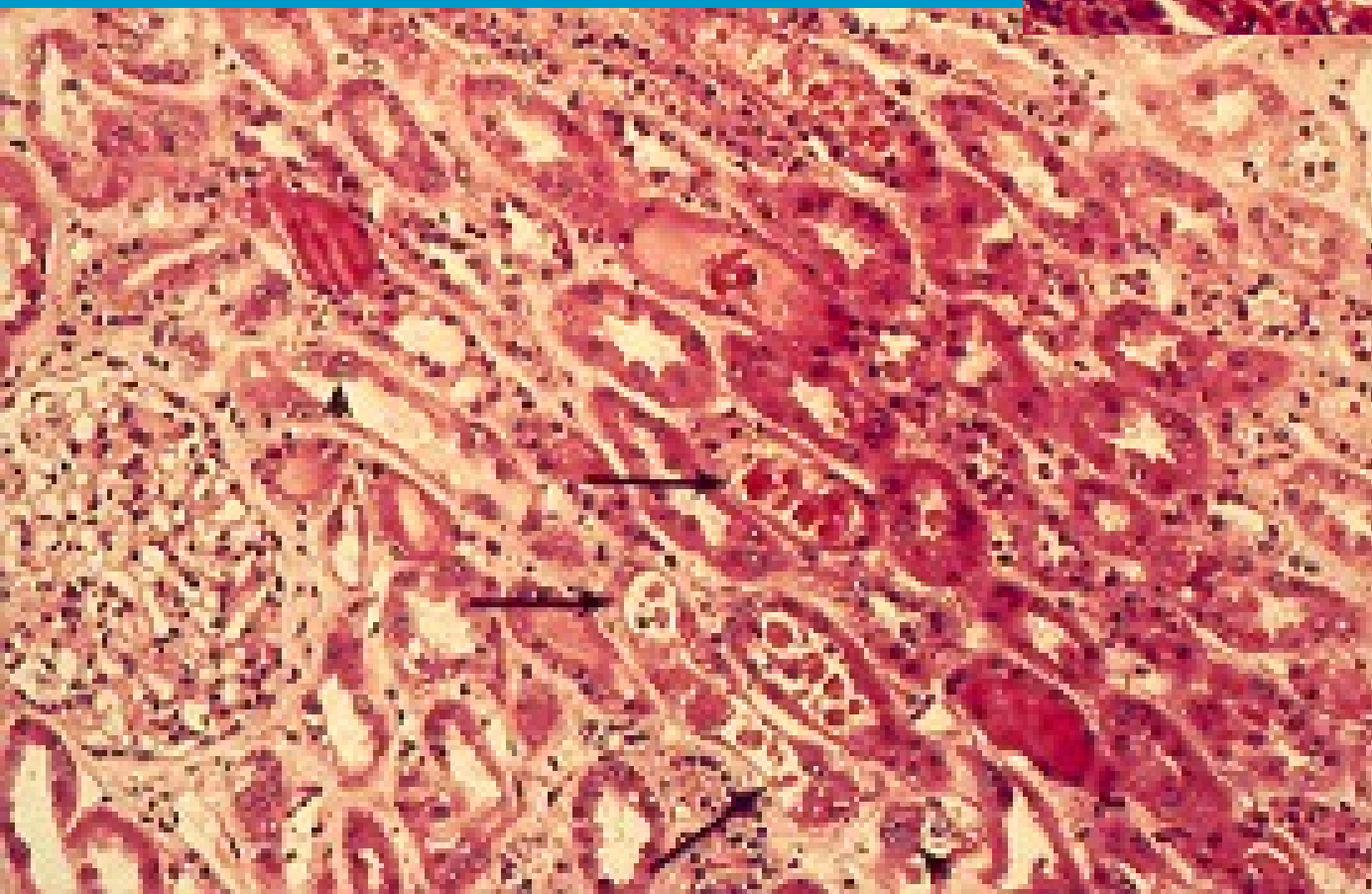
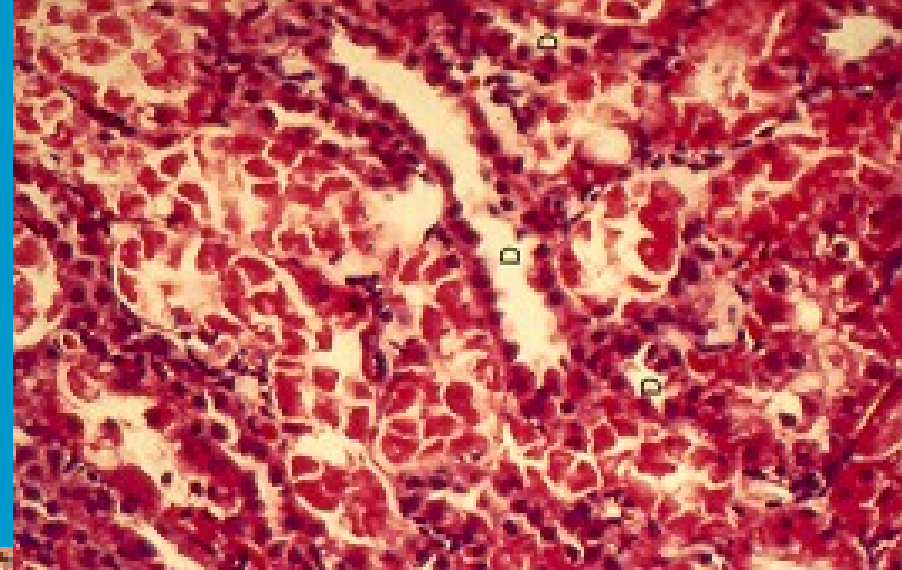
Acute tubular necrosis (ATN)

- Destruction/injury of tubular epithelium, leading to acute diminution or loss of renal function
- **Ischemic ATN** – due to decreased or interrupted blood flow, e.g. in shock, trauma, acute pancreatitis, polyarteritis nodosa, haemoglobinuria (haemolysis), myoglobinuria (crush), etc.
- **Nephrotoxic ATN** – direct toxic injury to the tubules by drugs, heavy metals (mercury), organic solvents (carbon tetrachloride), ethylene glycol

Acute tubular necrosis (ATN)

- Morphology: **ischemic ATN** with loss of proximal epithelial brush border, cell flattening, focal tubular epithelial necrosis along the whole nephron, BM rupture, occlusion by casts; interstitial oedema, inflammatory infiltrate
- Later epithelial regeneration starting from uninjured parts
- **Toxic ATN**: extensive tubular necrosis/cytotoxic changes along the proximal tubules

Acute tubular necrosis (ATN)



Tubulointerstitial nephritis induced by drugs and toxins (hypersensitivity nephritis)

- Sulfonamids, synthetic penicilins, some diuretics, NSAIDs
- 7-15 days after exposure fever, eosinophilia, rash, hematuria, proteinuria, leukocyturia, cca 50% acute renal failure with oliguria
- Late-phase reaction of an IgE-mediated hypersensitivity (type I)
- Oedema and mononuclear **interstitial infiltration**, commonly with **eosinophils**, giant cell **granulomas** may be present. Tubulitis and tubular regressive changes.

Analgesic nephropathy

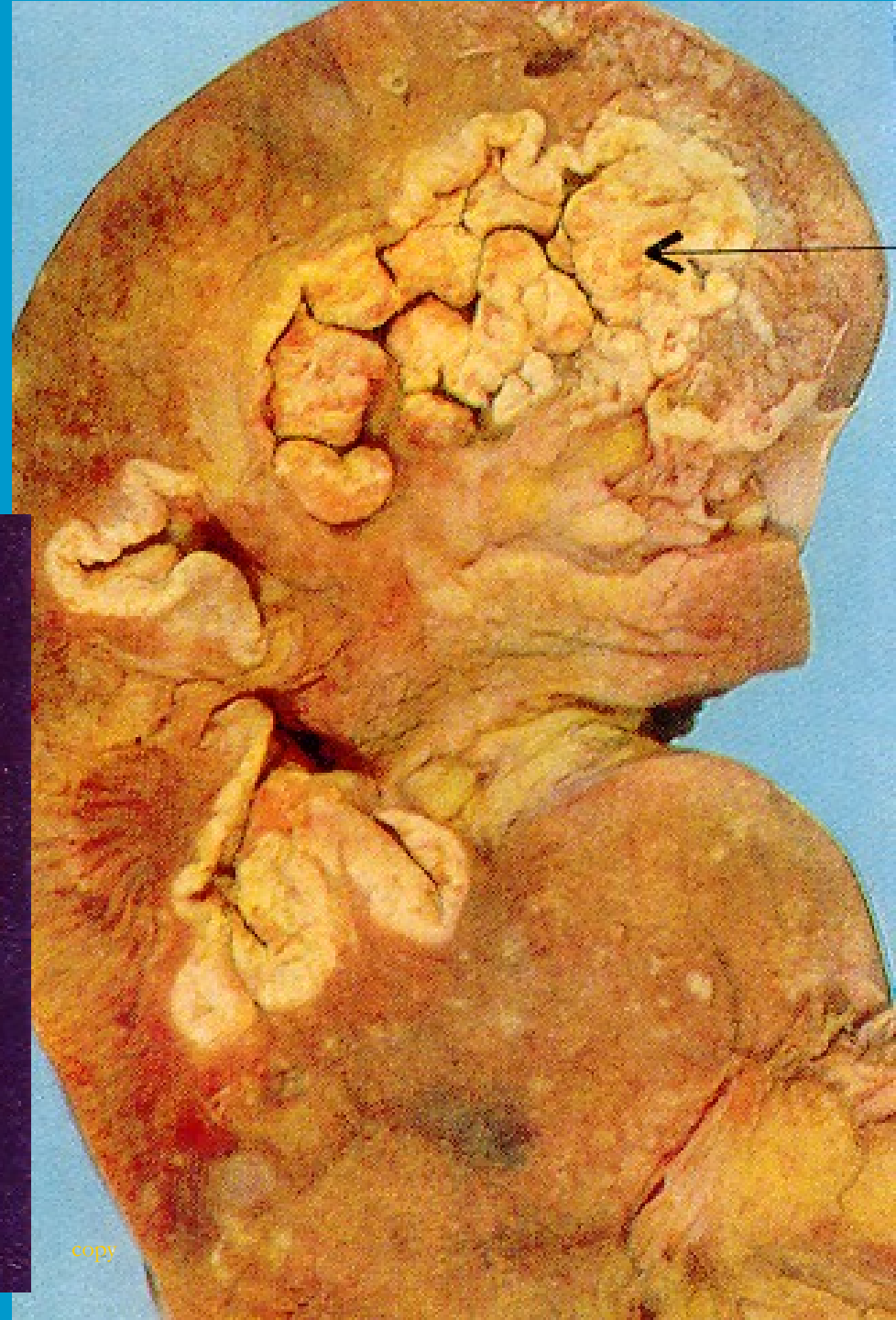
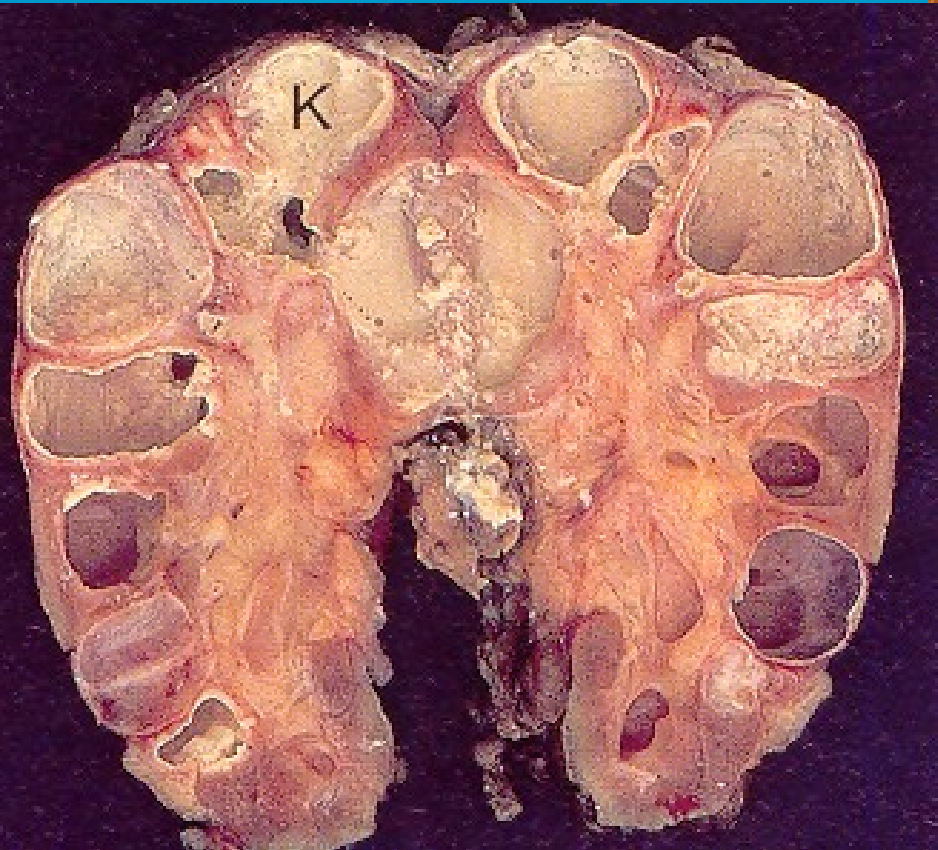
- Chronic renal disease due to excessive use of analgesic mixtures
- Form of chronic tubulointerstitial nephritis with renal papillary necrosis
- Combination effects of aspirin (papillary ischaemia), phenacetin (toxic metabolites)

Renal TBC

- Part of miliary spread
- Solitary postprimary tbc lesion
- Gross: caseous-cavernous mass with fibrous capsule (closed tbc) or rupture and drain into pelvis (open tbc), possible infection of urinary tract.

Renal TBC

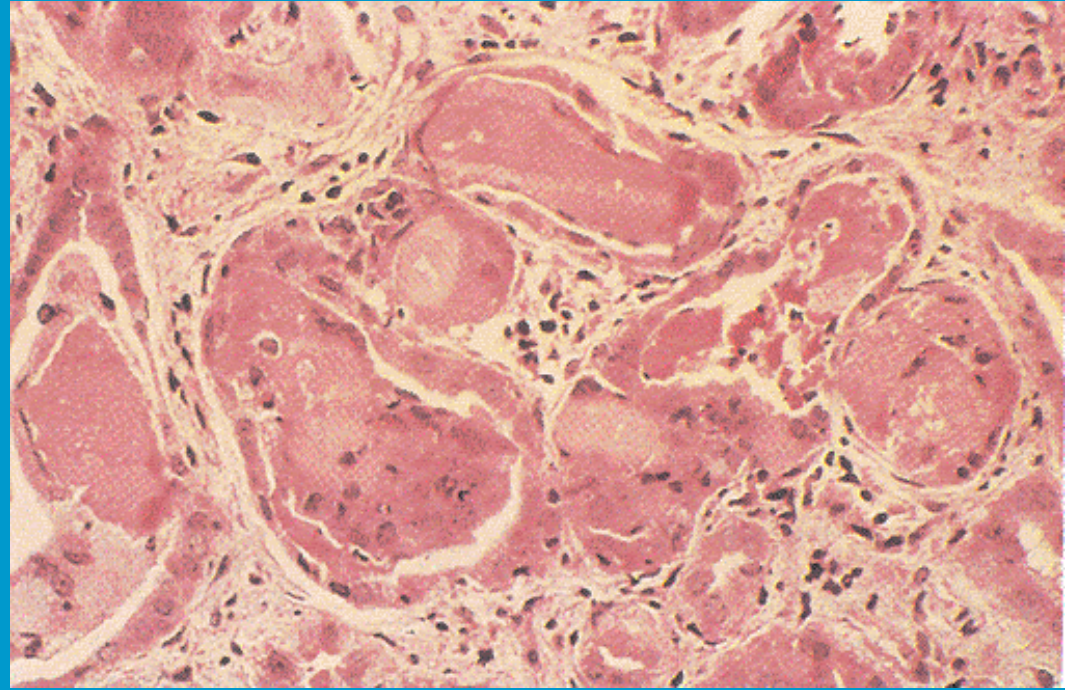
Caseation



Urate nephropathy

- Hyperuricemic disorders (urate crystals formation) may lead to 3 forms of injury:
- **Acute urate nephropathy** in patients with haematologic malignancies, commonly during chemotherapy (extensive cell breakdown – release of nucleic acids – urate crystals in tubules – acute renal failure
- **Chronic urate nephropathy** – in gout. Urate crystals surrounded by foreign body giant cells, tubulo-interstitial nephritis
- **Urate stones**

Multiple myeloma



- Amyloidosis
- Myeloma nephrosis: tubular casts formed by precipitated Bence-Jones protein, nephrohydrophrosis
giant cell reaction

Renal tumors

WHO histological classification of renal tumors

- Renal cell tumours
- Metanephric tumours
- Nephroblastic tumours
- Mesenchymal tumours
- Mixed mesenchymal and epithelial tumours
- Neuroendocrine tumours
- Haematopoietic and lymphoid tumours
- Germ cell tumours
- Metastatic tumours

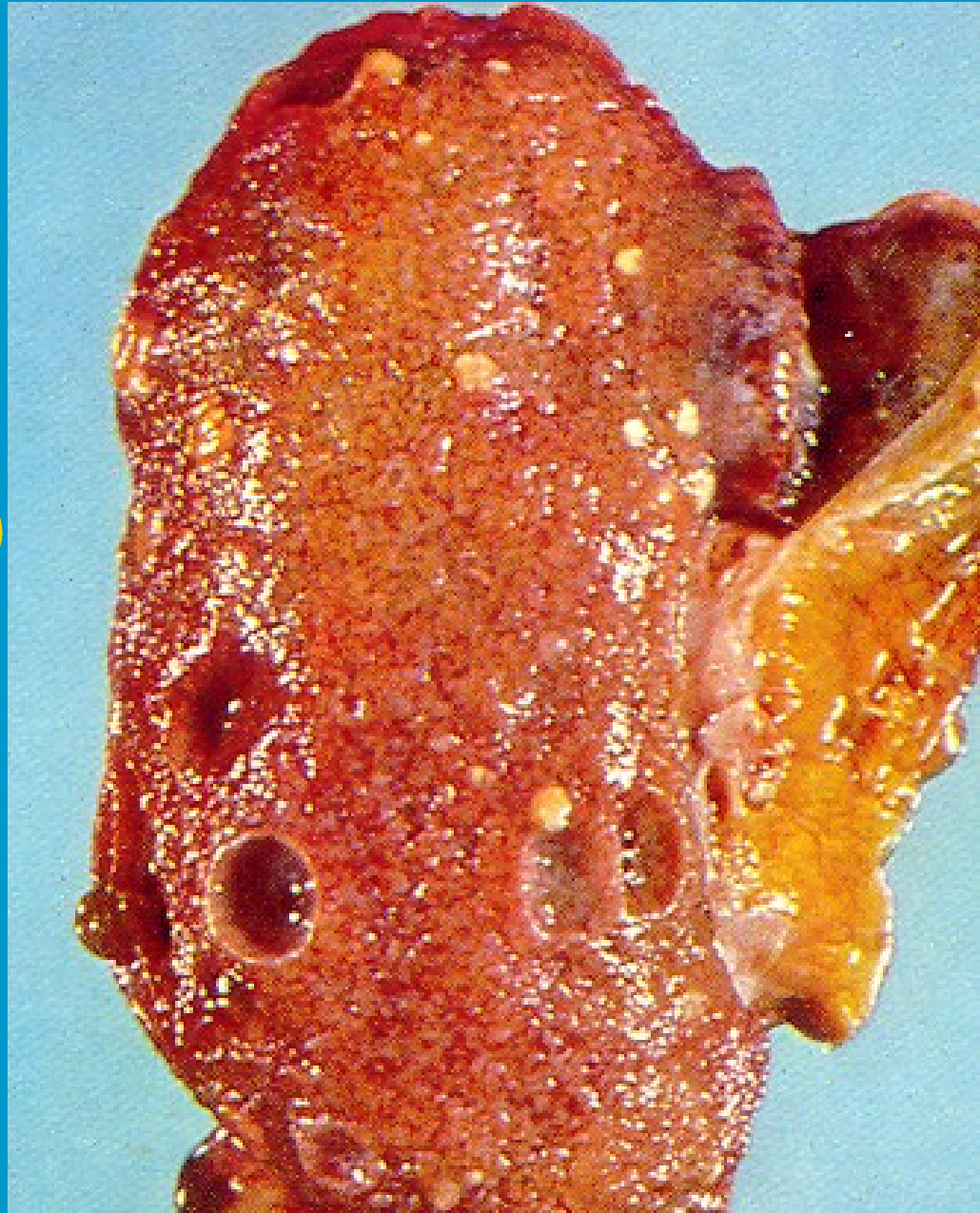
WHO classification of renal cell tumors

- Clear cell renal cell carcinoma
- Multilocular cystic renal neoplasm of low malignant potential
- Papillary renal cell carcinoma
- Hereditary leiomyomatosis and renal cell carcinoma (HLRCC)-associated renal cell carcinoma
- Chromophobe renal cell carcinoma
- Collecting duct carcinoma
- Renal medullary carcinoma
- MiT Family translocation carcinomas
- Succinate dehydrogenase (SDH)-deficient renal carcinoma
- Mucinous tubular and spindle cell carcinoma
- Tubulocystic renal cell carcinoma
- Acquired cystic disease associated renal cell carcinoma
- Clear cell papillary renal cell carcinoma
- Renal cell carcinoma, unclassified
- Papillary adenoma
- Oncocytoma

Benign renal tumors

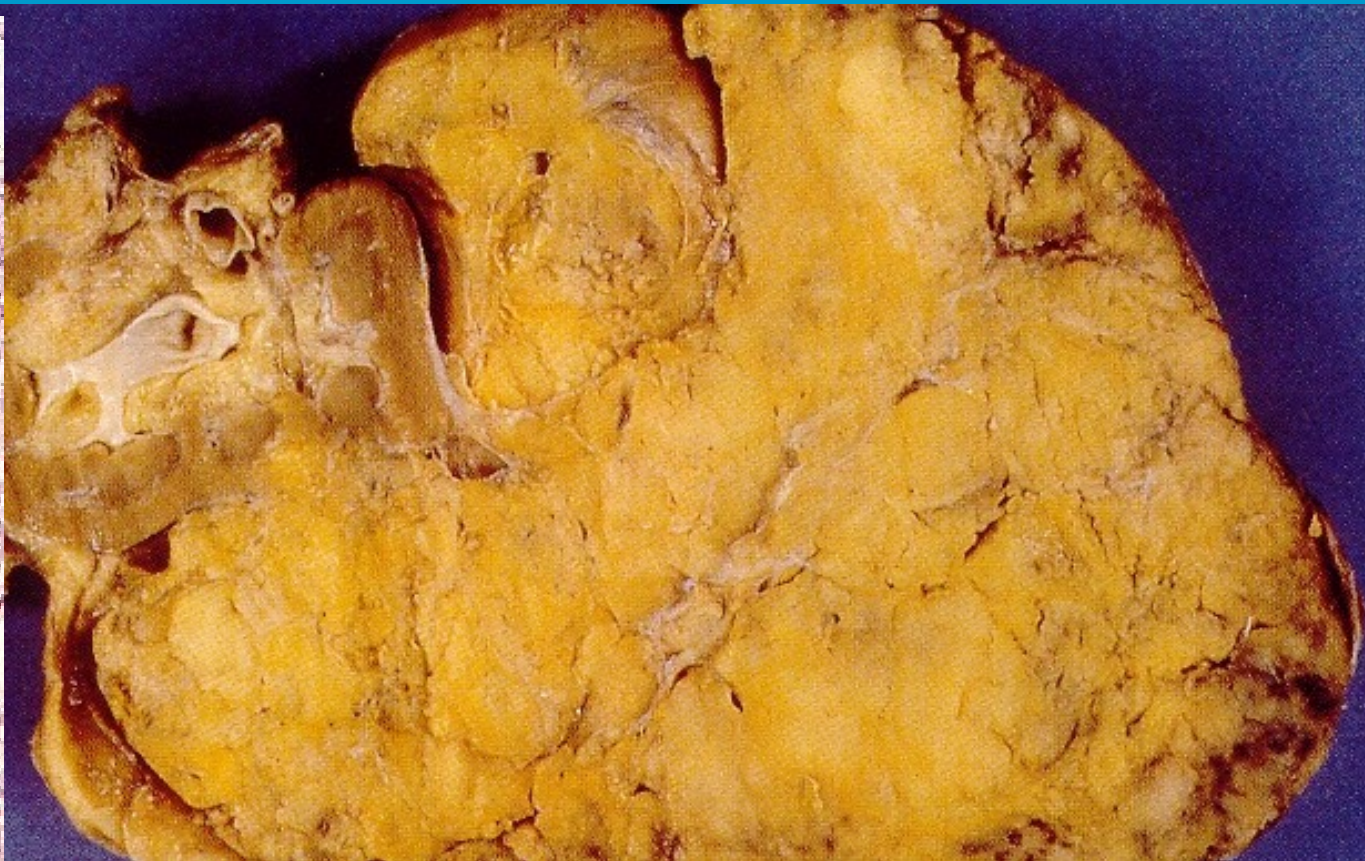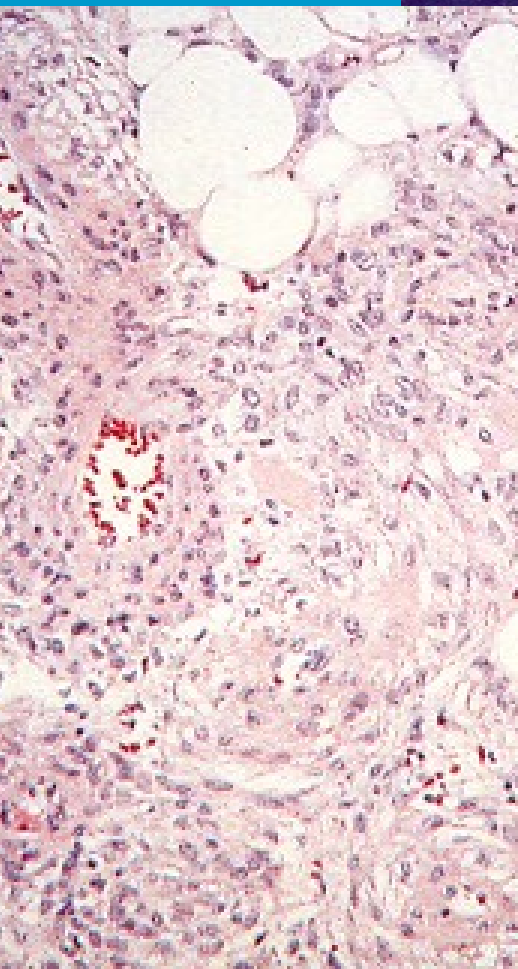
Cortical papillary adenoma

- Small tumors (1-15 mm)
- May be multiple
- Papillary structure



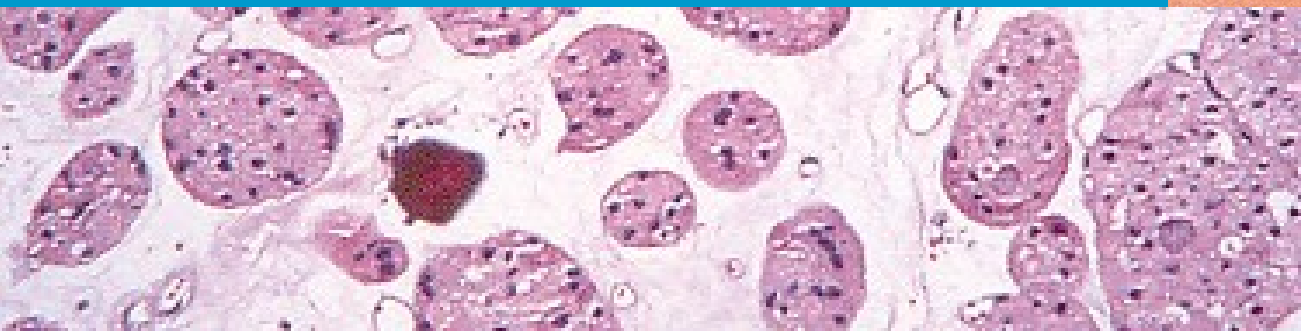
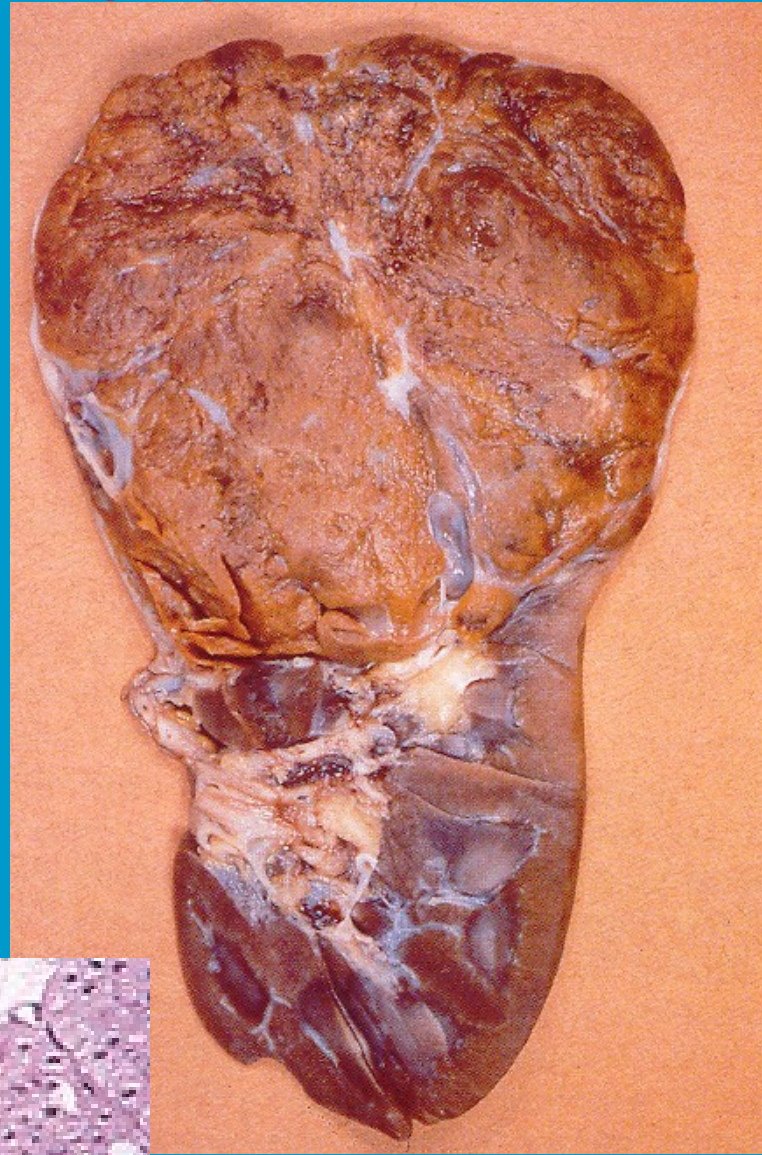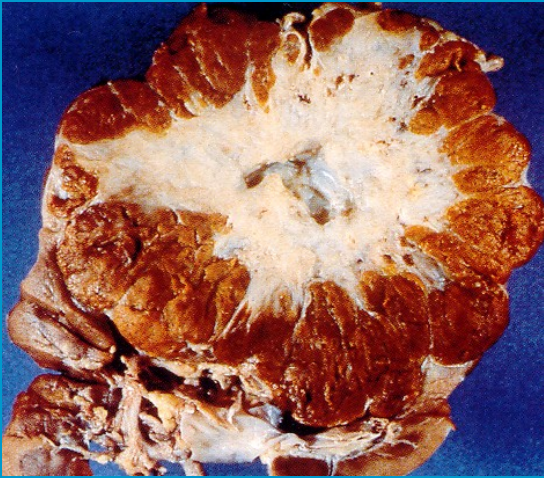Benign renal tumors

- **Angiomyolipoma (PEComa), mesenchymal**



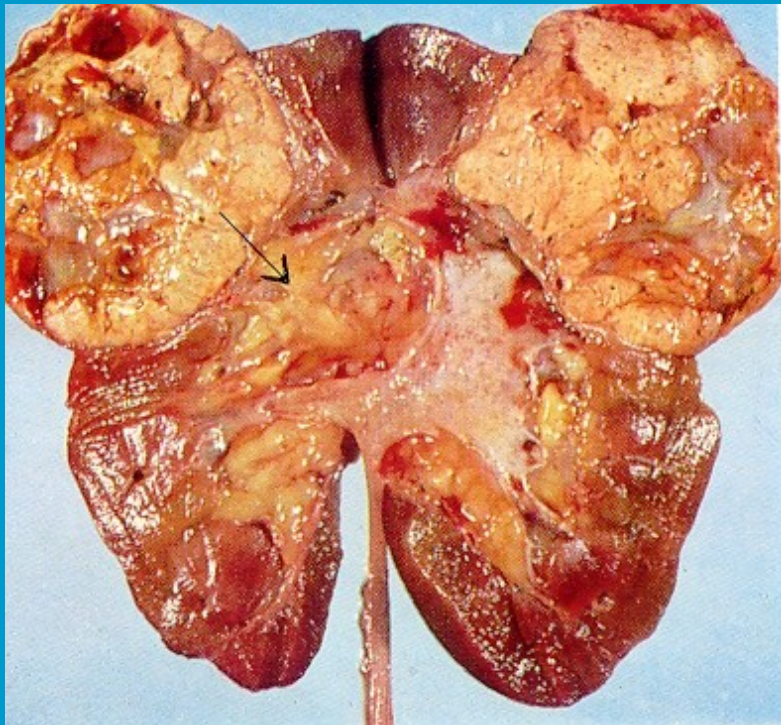
Benign renal tumors

- Oncocytoma epithelial, asymptomatic



Renal cell carcinoma

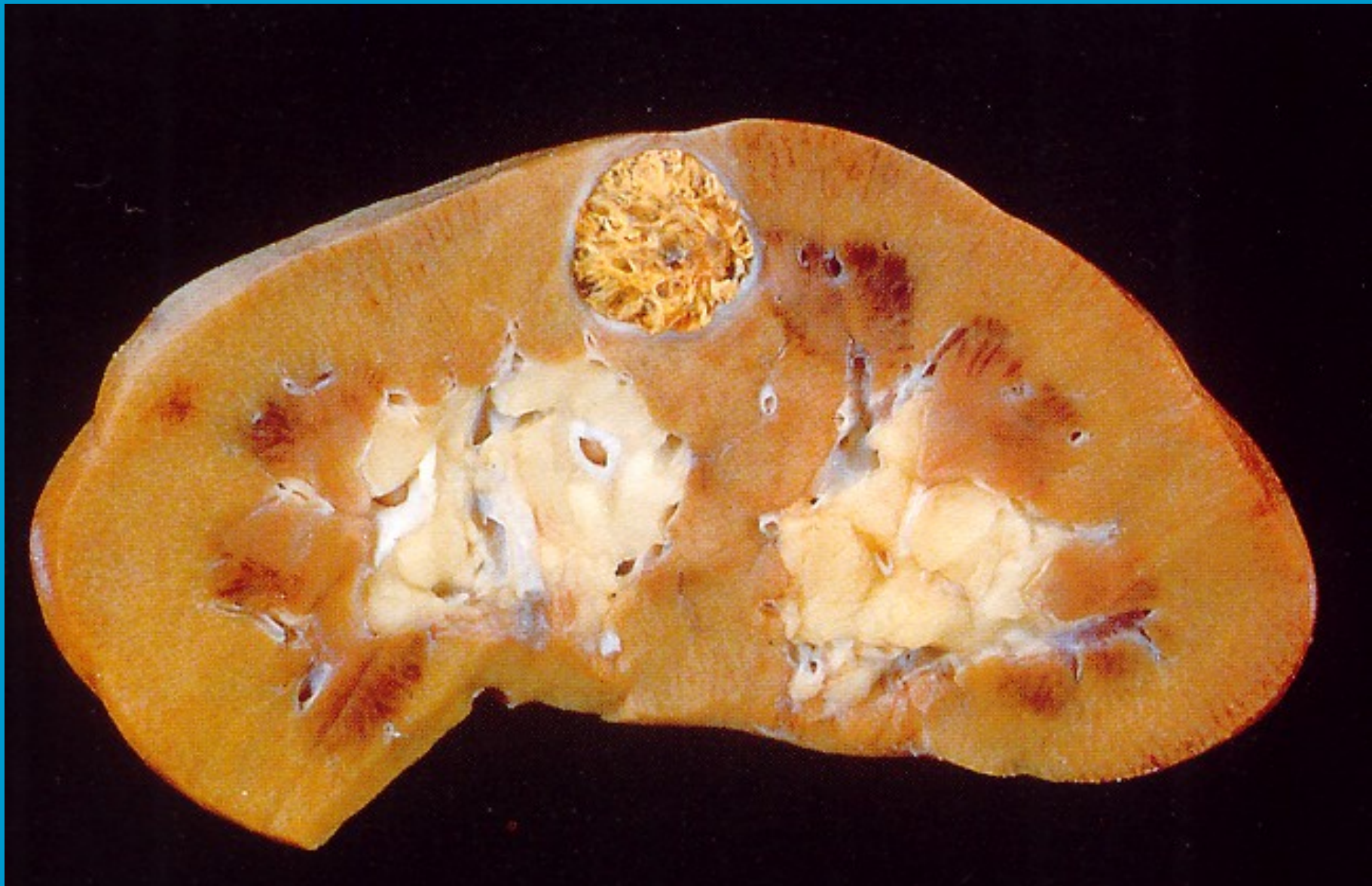
- Adenocarcinoma from tubular epithelium (clear cell - Grawitz)
- 85% of renal malignancies



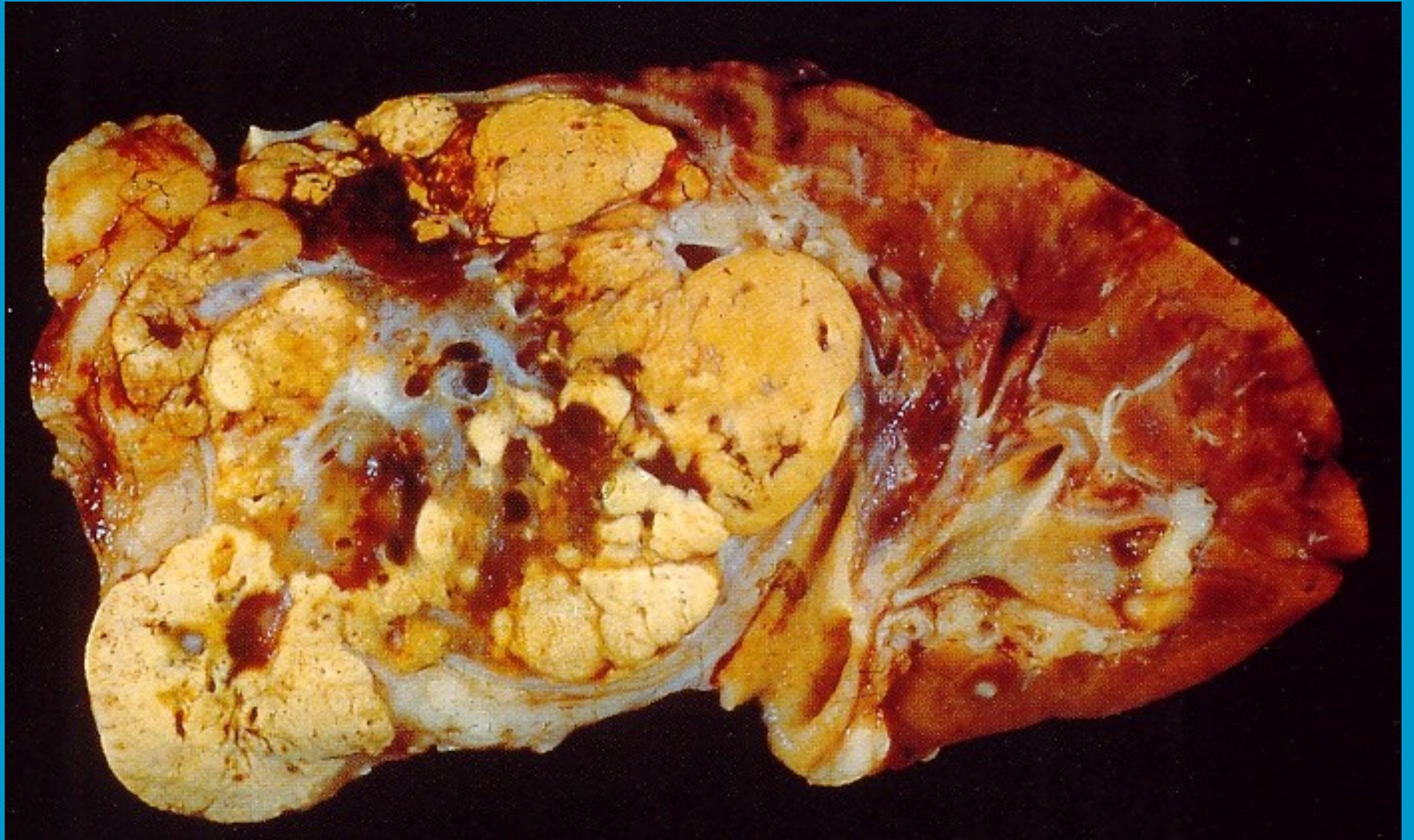RCC

- Clear cell (conventional) RCC (80%)
 - Chromophobe RCC
 - Papillary RCC
-
- Risk f.: smoking, obesity, HT, genetic factors, industrial pollution, chemicals (asbestos, arsenic, organic diluents, ...)
 - Incidental finding, hematuria, metastasis

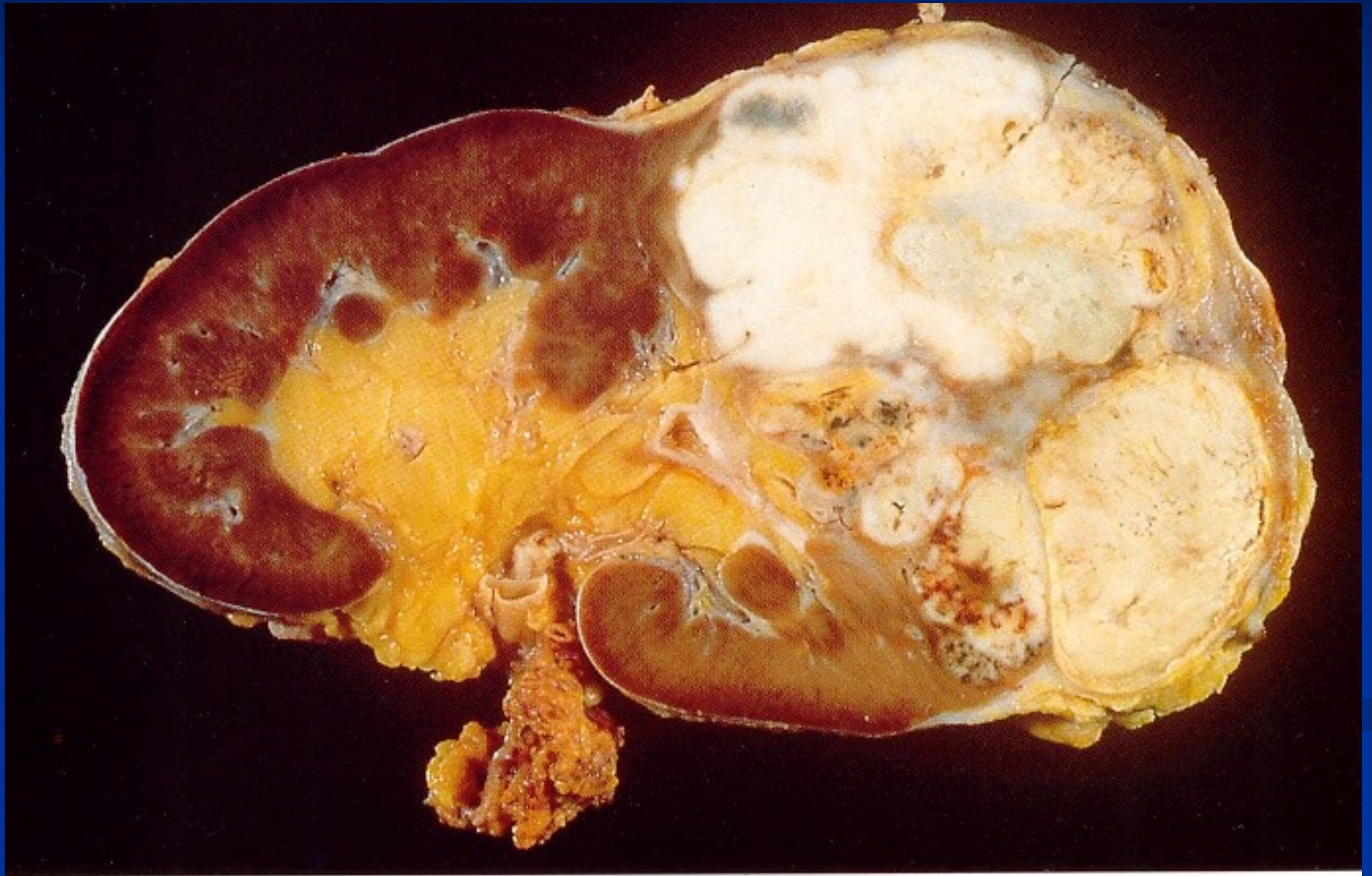
Renal cell carcinoma



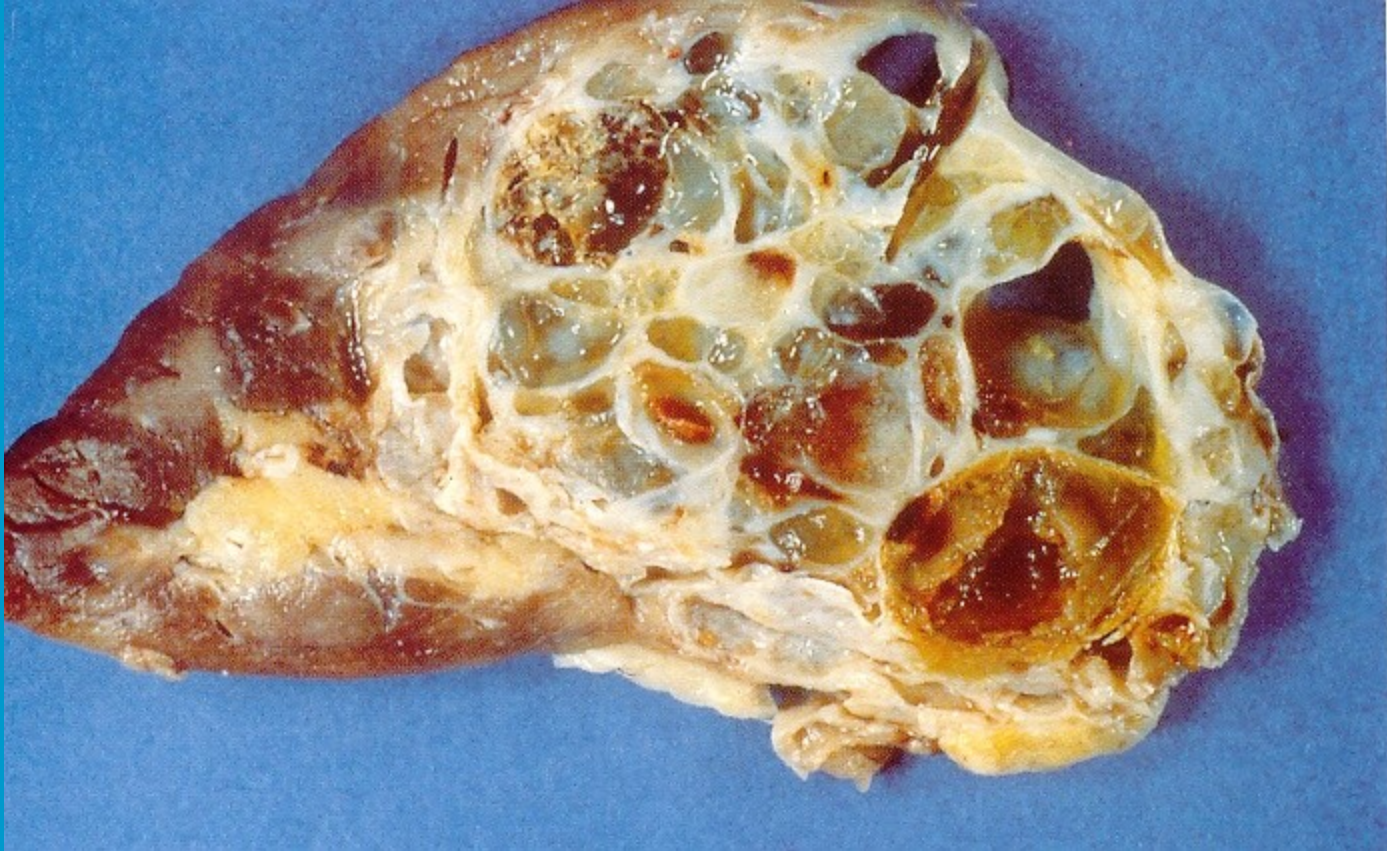Renal cell carcinoma



Renal cell carcinoma



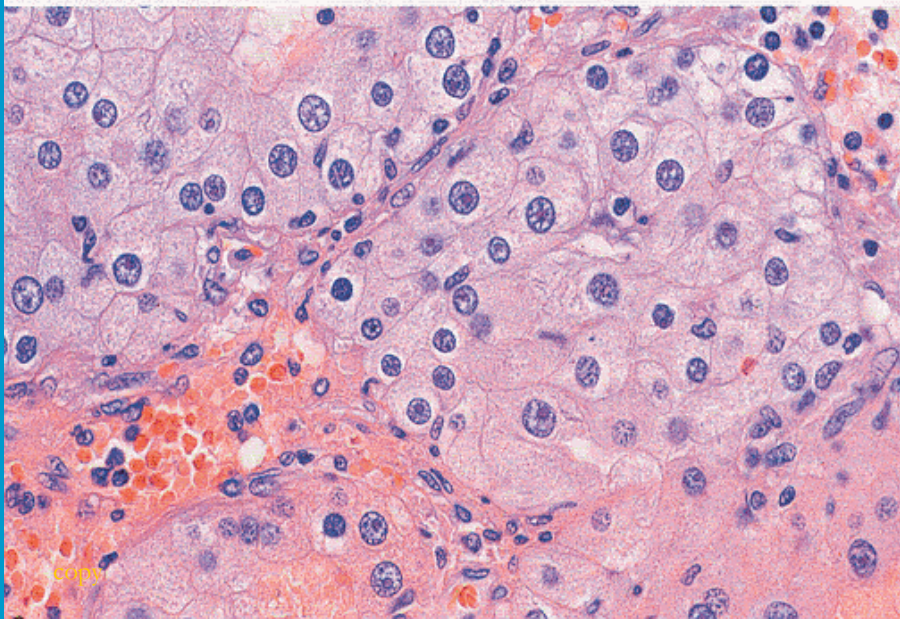
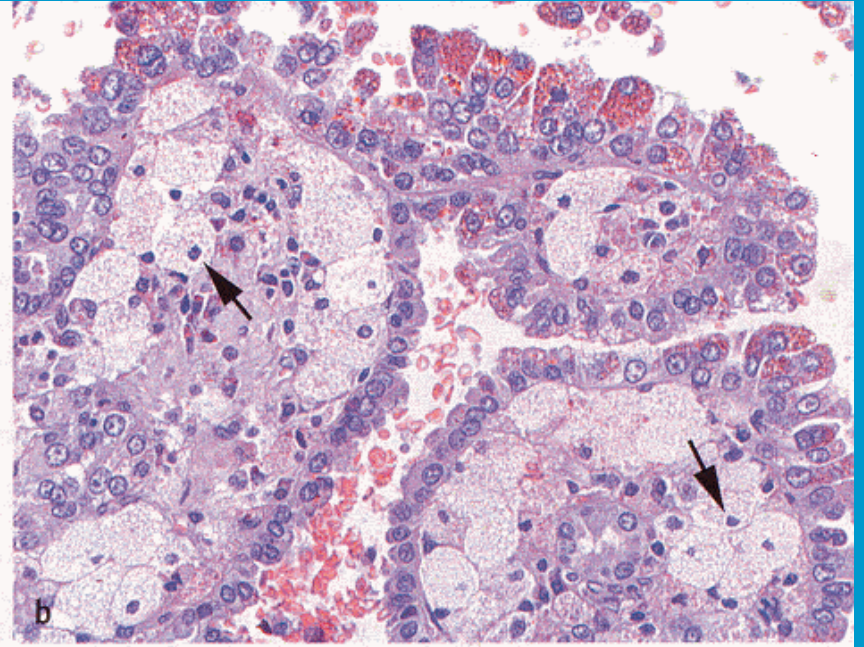
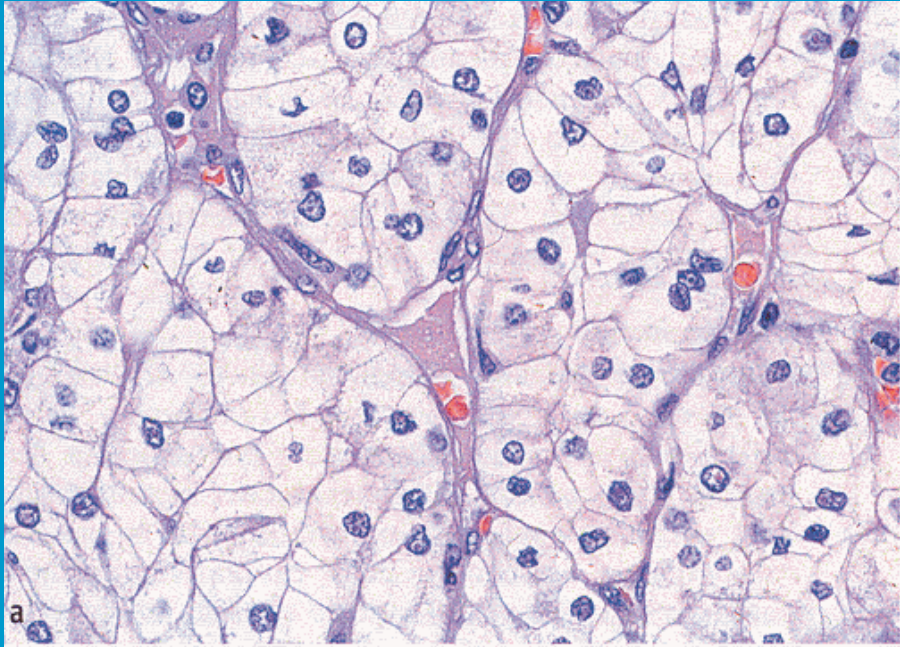
Renal cell carcinoma



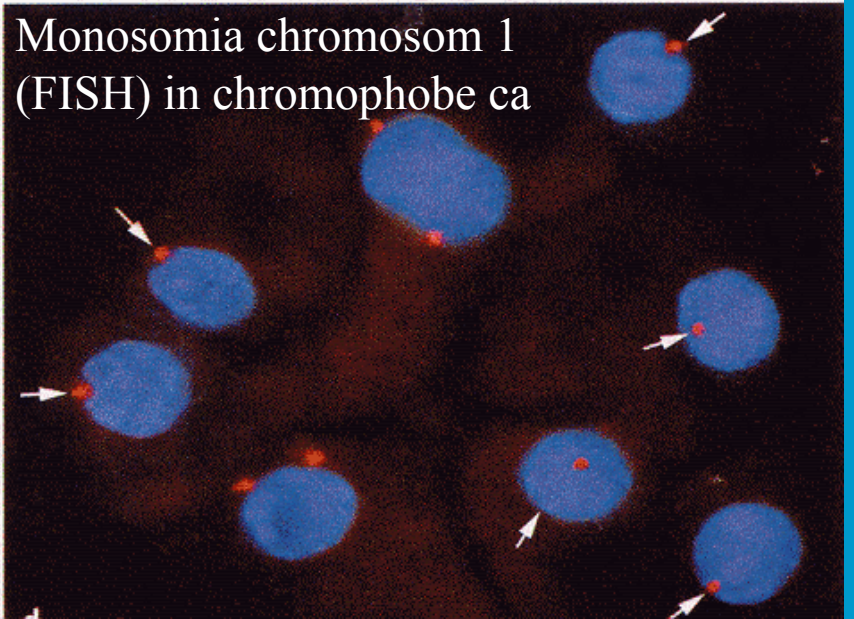
RCC

- Clear cell (conventional) RCC (80%)
 - glycogene + lipids in cytoplasm, common regressive changes, venous invasion, may have late metastasis
 - nuclear grading
- Chromophobe RCC 5 %
 - very good prognosis, eosinophilic granular cytoplasm
- Papillary RCC: 15 %,
 - commonly multifocal / bilateral, stromal foam macrophages

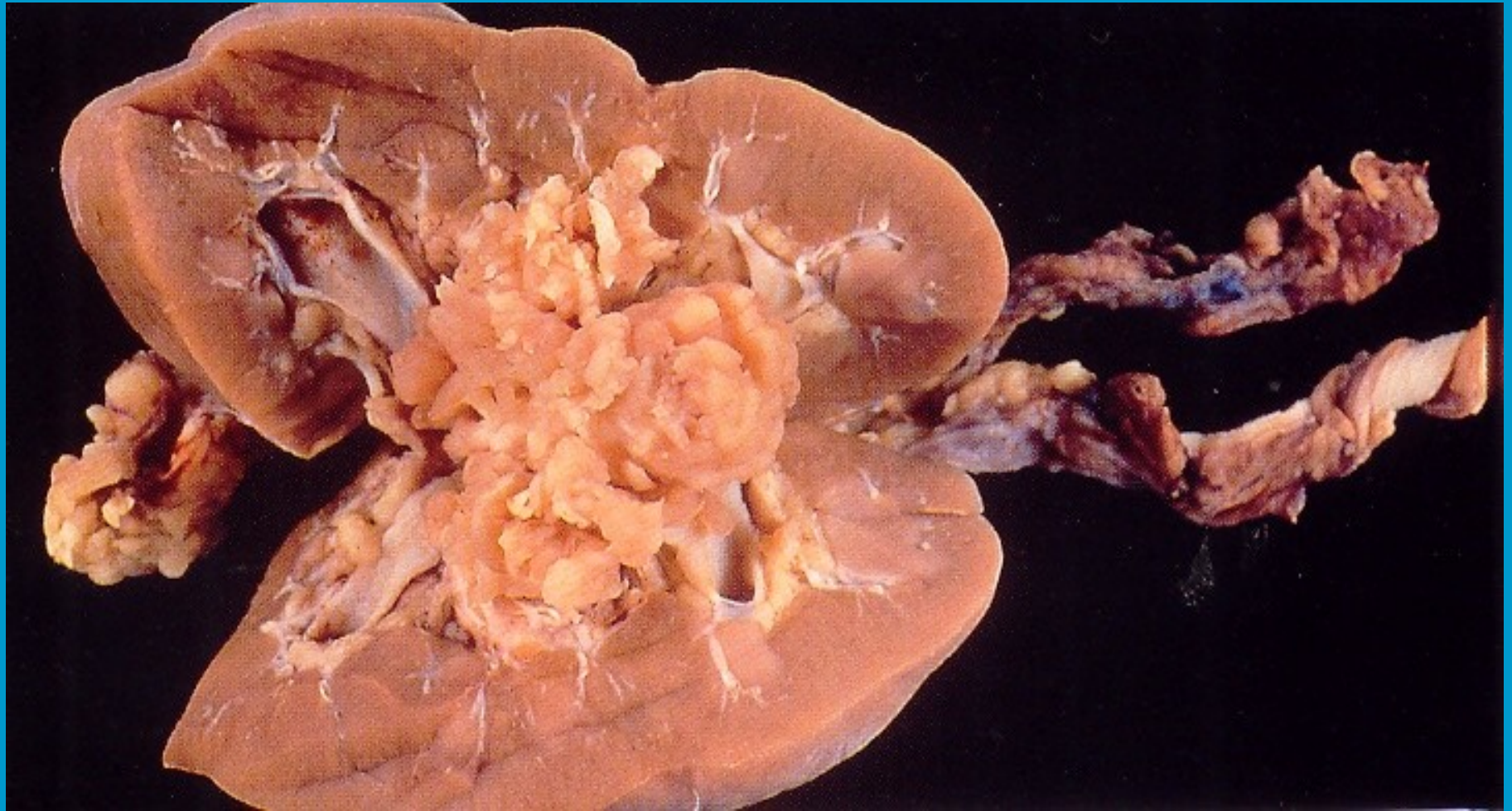
Renal cell carcinoma



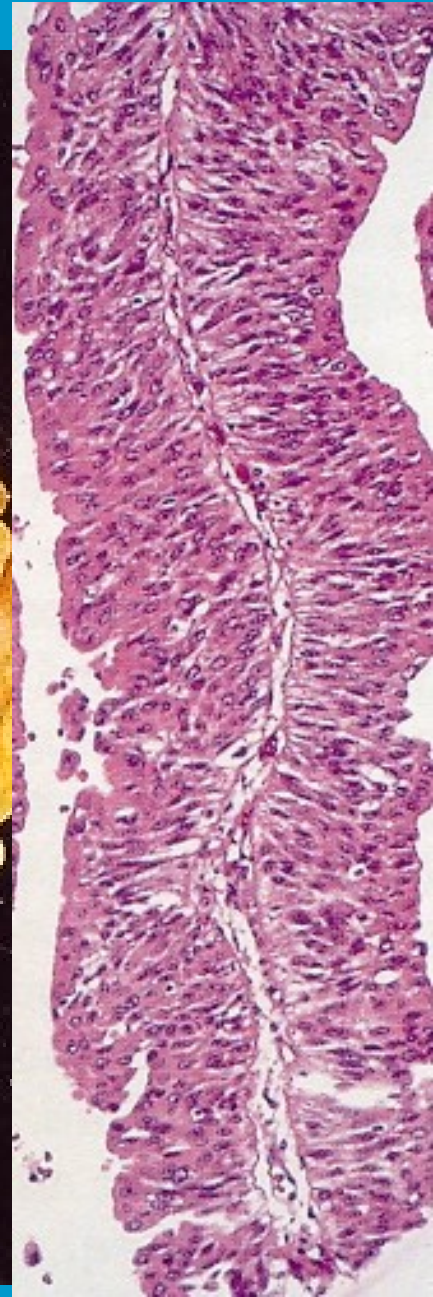
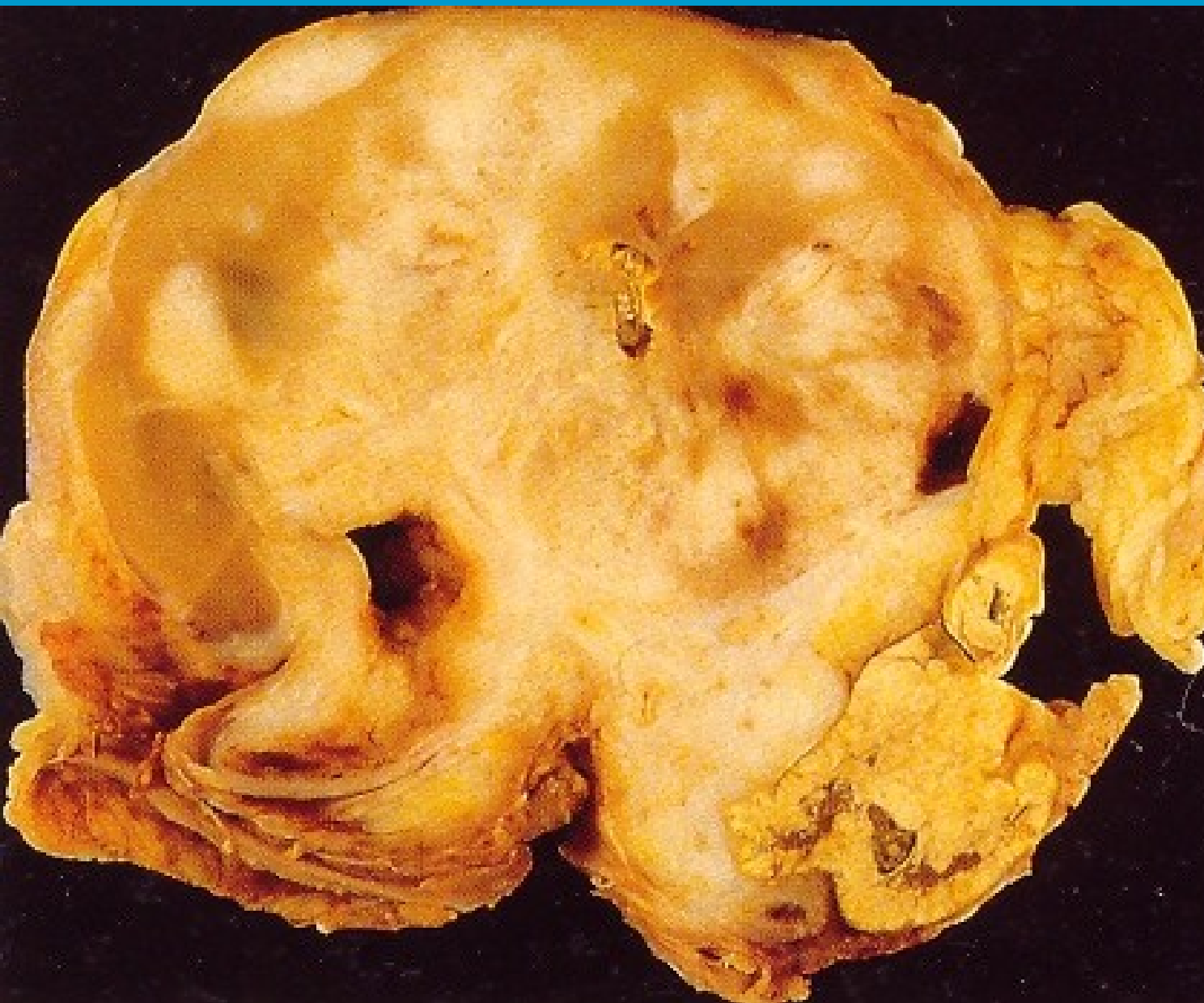
Monosomia chromosom 1
(FISH) in chromophobe ca



Transitional cell ca of the renal pelvis

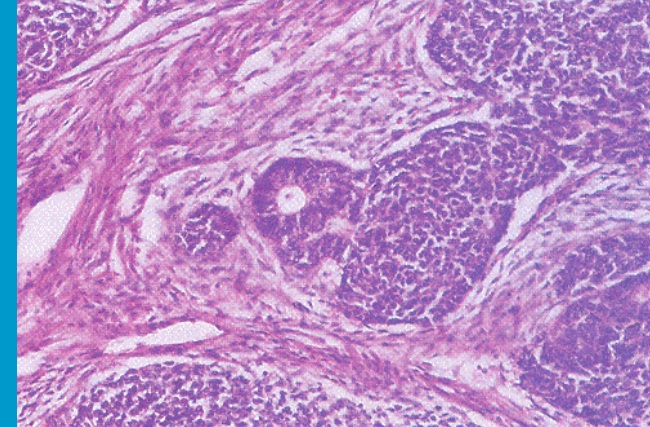
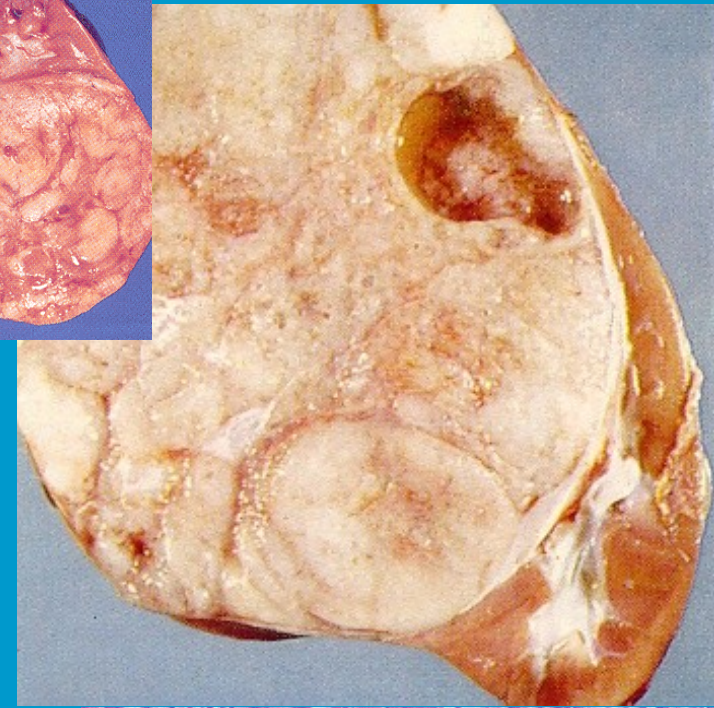
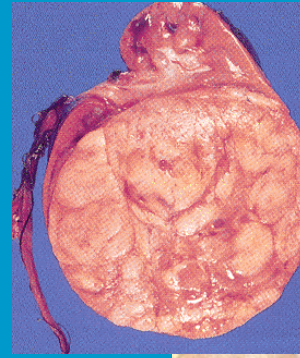


Transitional cell ca of the renal pelvis

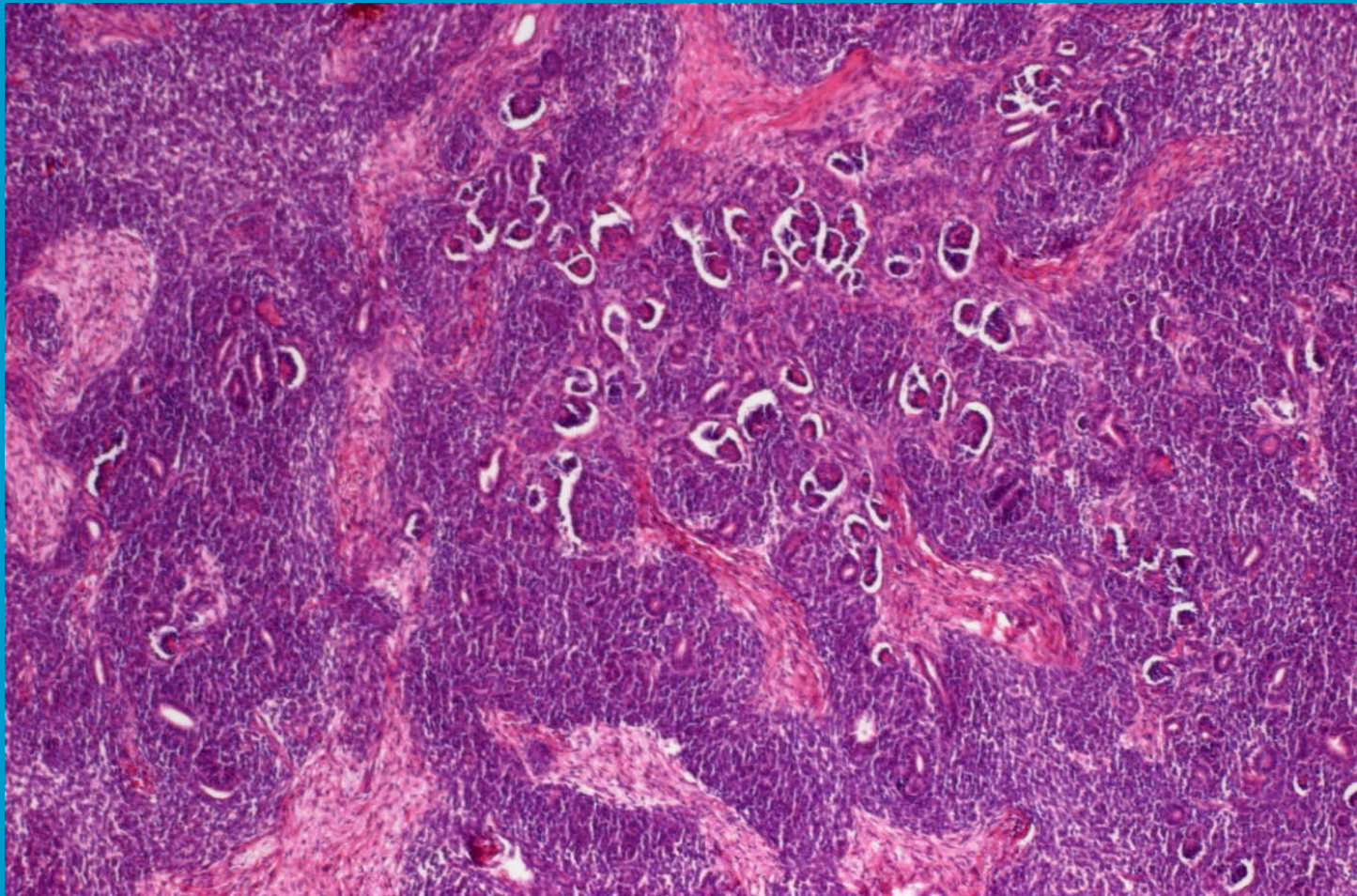


Wilms' tumor - nephroblastoma

- Malignant embryonal tumor arising from metanephrogenous blastema
- Peak incidence 1-4 yrs
- 3rd most common ch. malignancy, treatable
- hematuria, local compression
- Suppressor gene WT1 (11p13), WT2 (11p15)
- MACRO: large, soft
- MICRO blastic cells, immature **epithelial, mesenchymal** differentiation



Wilms' tumor - nephroblastoma



Secondary tumors

- Local spread (adrenals, pancreas, liver)
- Lung carcinoma
- Malignant lymphoma
- Others

