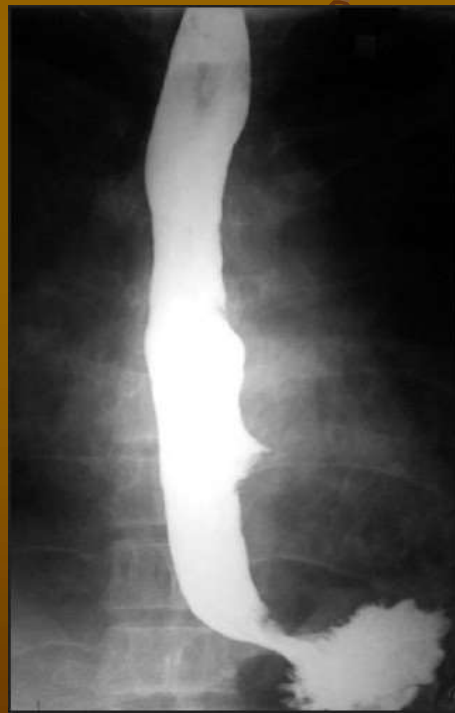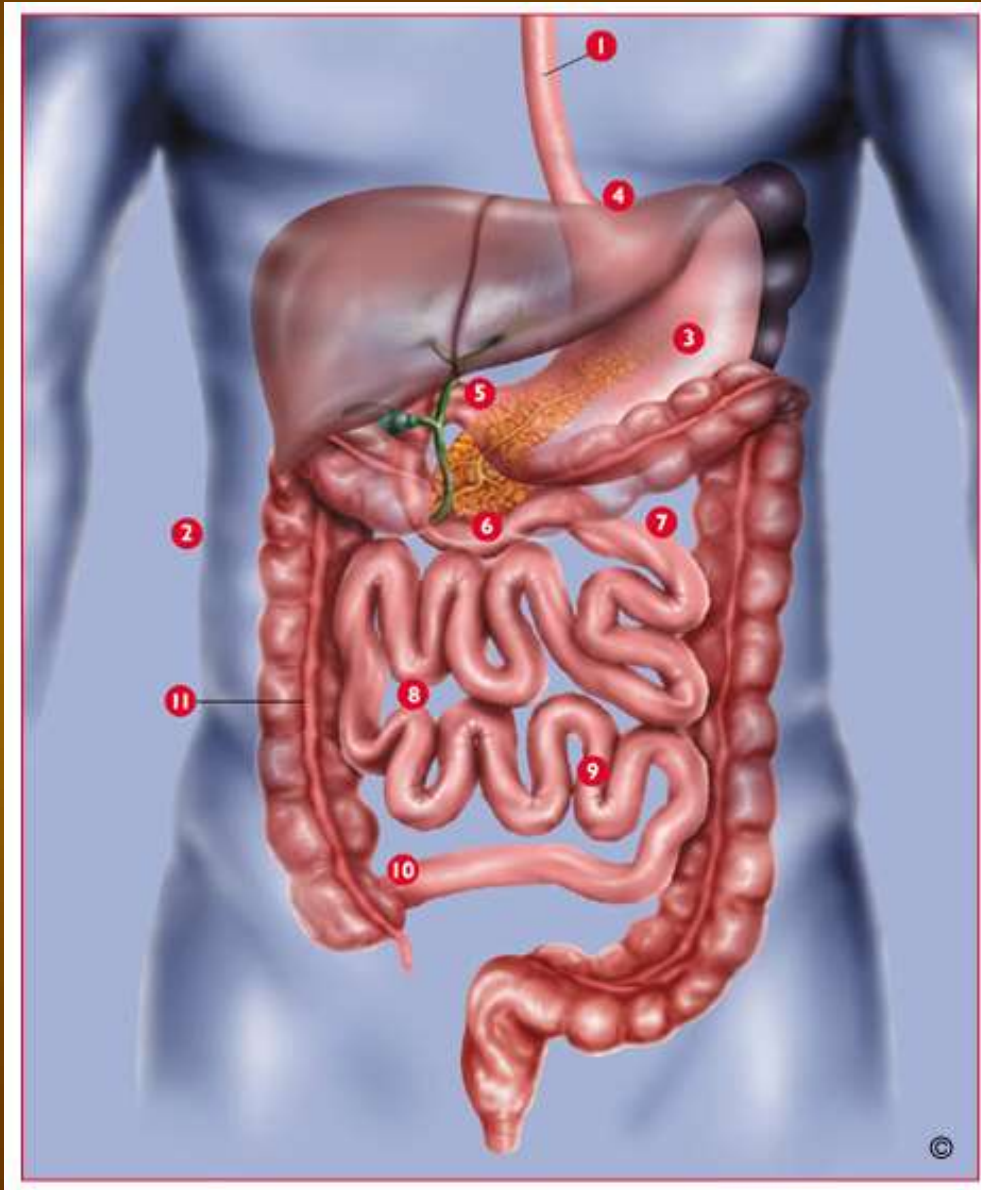


Pathophysiology of esophagus



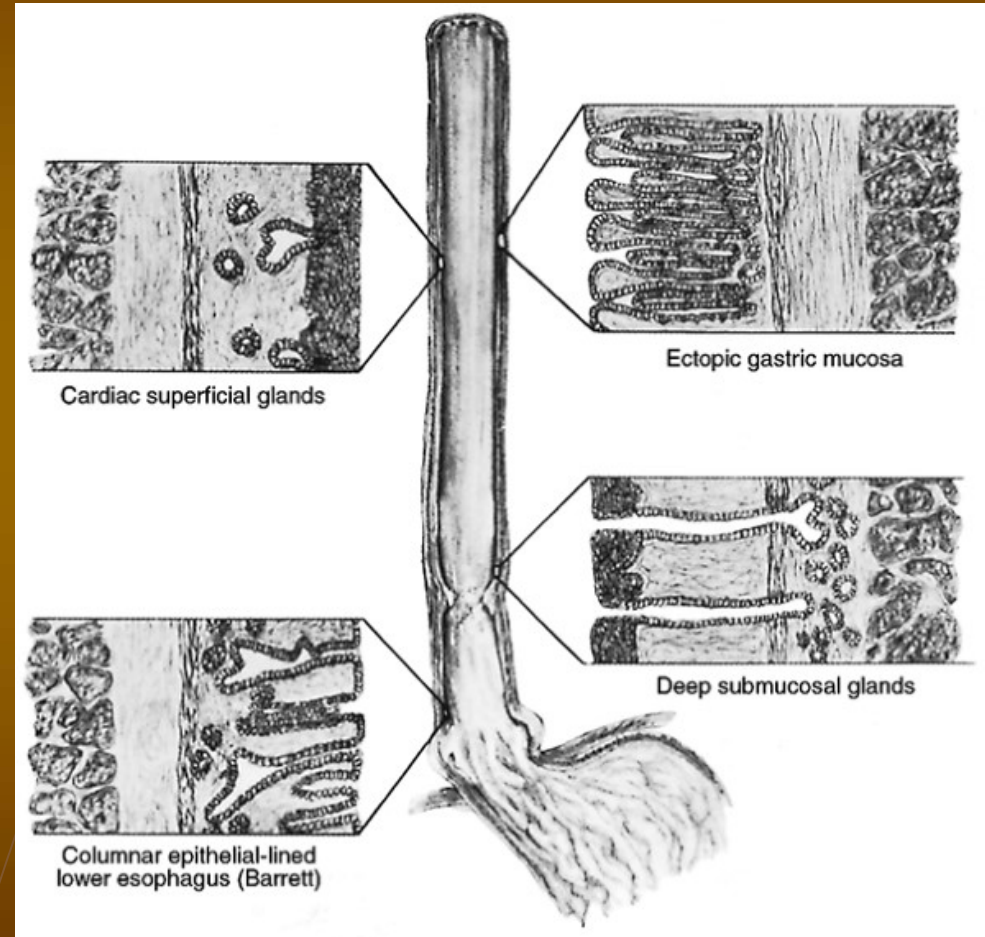
The GIT



- 1- esophagus
- 2- peritoneal cavity
- 3- stomach (1.5l)
- 4- gastroesophageal junction
- 5- pylorus
- 6- small intestine (4.5 – 6m)
 - 7- duodenum
 - 8- jejunum
 - 9- ileum
- 10- ileocecal valve
- 11- large intestine
 - ascendent
 - transversal
 - descendent colon
 - rectum + anus

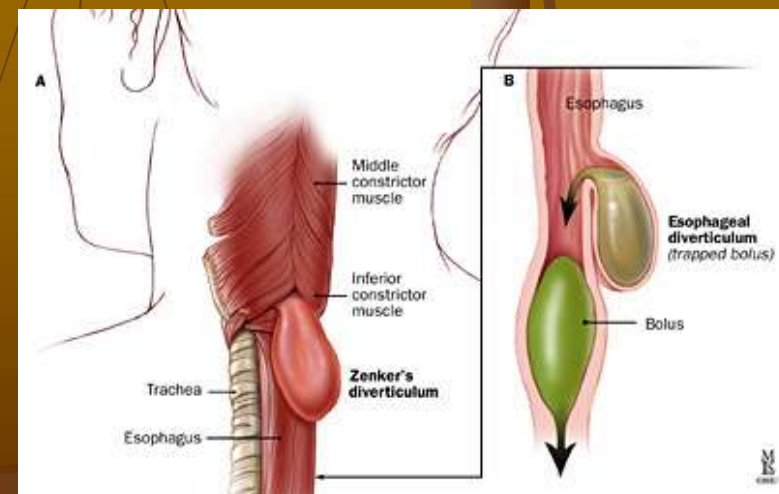
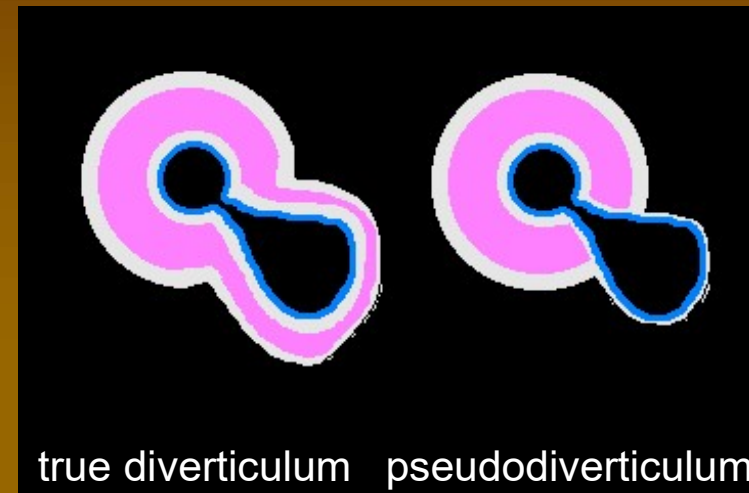
Esophagus - anatomy

- Upper sphincter (cricopharyngeal muscle)
- Upper 2/3 – skeletal muscle, squamous epithelium
- Lower 1/3 – smooth muscle
- Lower sphincter (LES)
- Cylindrical epithelium in the terminal part



Esophageal diverticula

- true diverticula (traction) – include muscular layer
- pseudodiverticula – only mucous layer (e.g. Zenker diverticulum)
- Combined diverticula
- Localization
 - Pharyngoasophageal
 - Midthoracic (epibronchial)
 - Epiphrenic



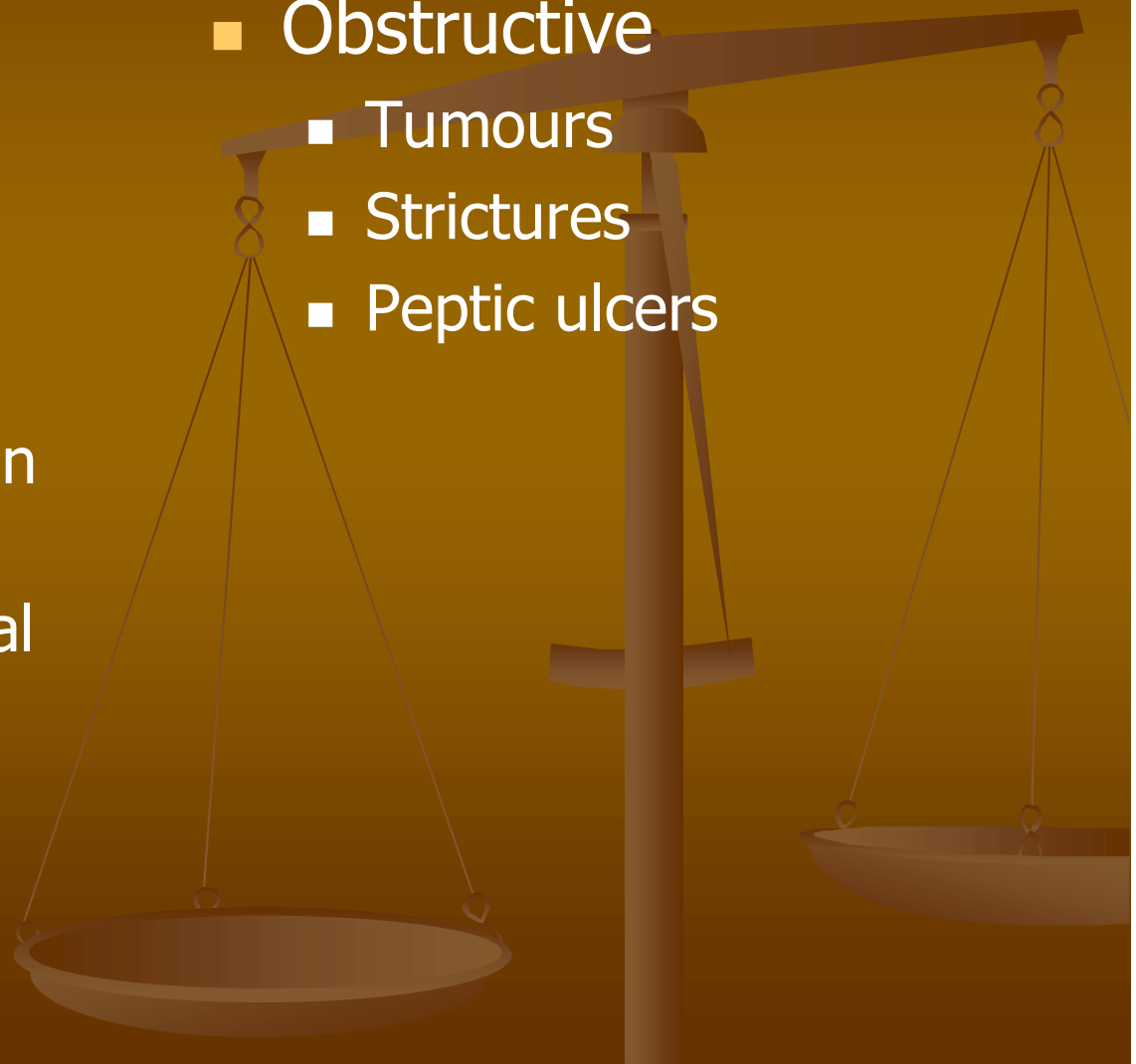
Dysphagia

■ Functional

- Inflammation in gastroesophageal reflux
- Sclerodermia
- Neuropathy (e.g. in diabetes)
- Amyotrophic lateral sclerosis
- Chagas disease
- Achalasia

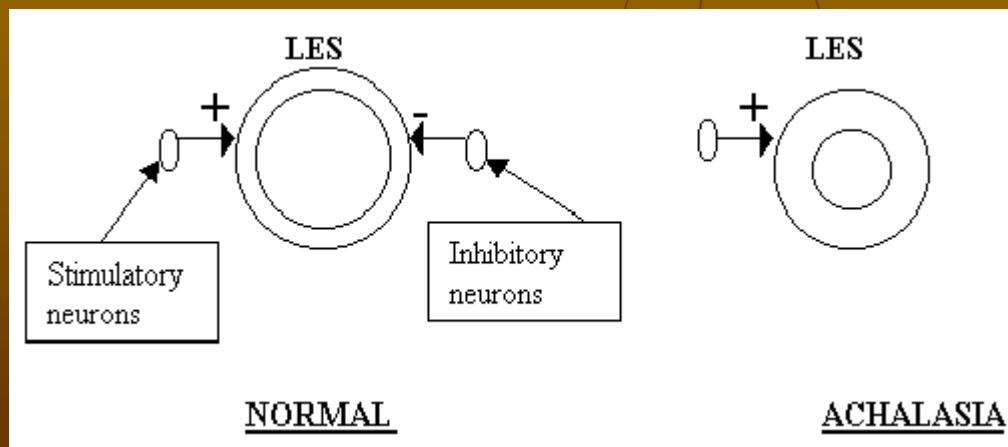
■ Obstructive

- Tumours
- Strictures
- Peptic ulcers



Esophageal achalasia

- The lower sphincter is incapable of relaxation
- This leads into esophageal dilatation and loss of peristaltic movements
- The primary cause is the disorder of myenteric plexus (plexus Auerbach), which produces NO
- Most often, it is caused by autoimmune destruction

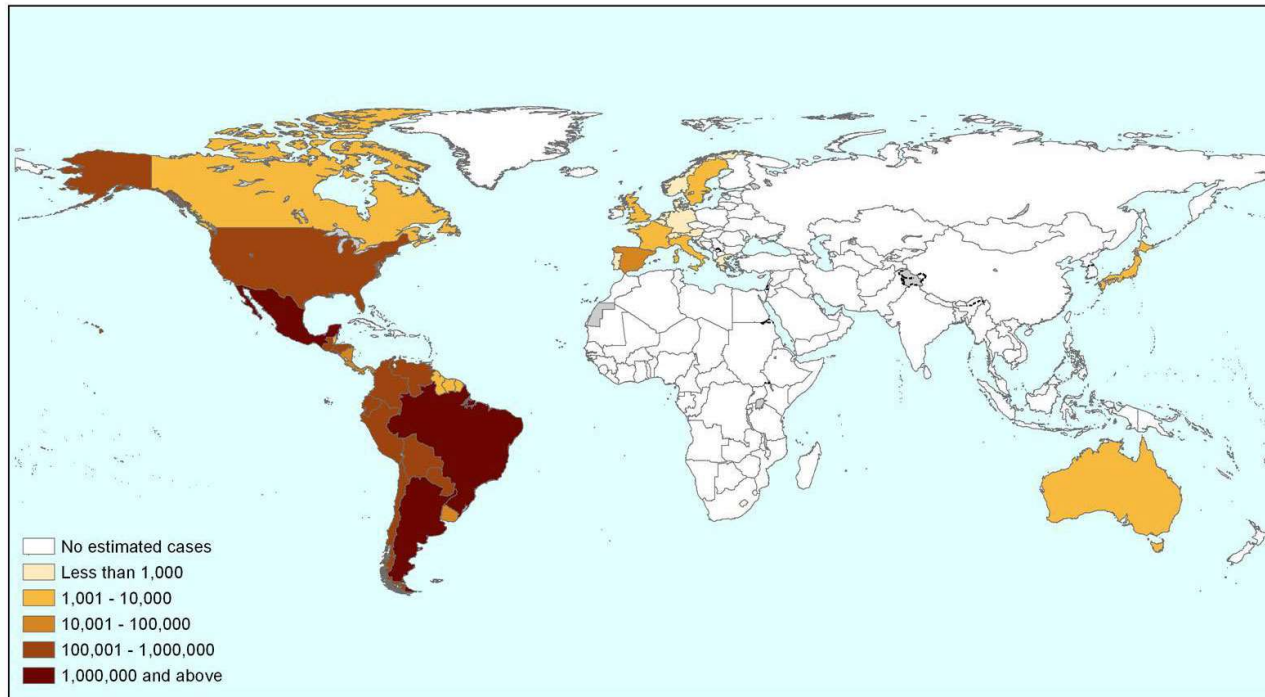


Chagas disease

- Infection by *Trypanozoma cruzi*
- About 15 000 000 victims (mostly in latin America)
- Acute stage: local oedema (often paraorbitally)
- Chronic stage: megacolon, megaesophagus, malnutrition, Chagasic cardiomyopathy, CNS involmment

We will update this map regularly (version: June 2009)

Estimated global population infected by *Trypanosoma cruzi*, 2009



Sources:

1. OPS/HDM/CD/425-06 Estimación cuantitativa de la enfermedad de Chagas en las Américas.
2. Gueri-Guttenberg RA, Grana D.R., Giuseppe Ambrosio, Milei J. Chagasic cardiomyopathy: Europe is not spared! European Heart Journal (2008); 29: 2587-2591.
3. Schmunis G. A. Epidemiology of Chagas Disease in non-endemic countries: the role of international migration. Mem Inst Oswaldo Cruz, Rio de Janeiro, Vol. 102(Suppl. I): 75-85, 2007.
4. De Ayala A.P. Pérez-Molina J.A, Norman F, and López-Vélez R. Chagasic cardiomyopathy in immigrants from Latin America to Spain. Emerging Infectious Disease Volume 15, Number 4—April 2009.
5. According to the numbers of inmigrants registered for 2007 in the website of the Japanese Ministry of Justice and estimated seroprevalence for non endemic countries according to Paricio-Talayero J.M. Vigilancia epidemiológica de la transmisión vertical de la enfermedad de Chagas en tres maternidades de la Comunidad Valenciana. Enferm Infecc Microbiol Clin 2008;26(10):609-13.

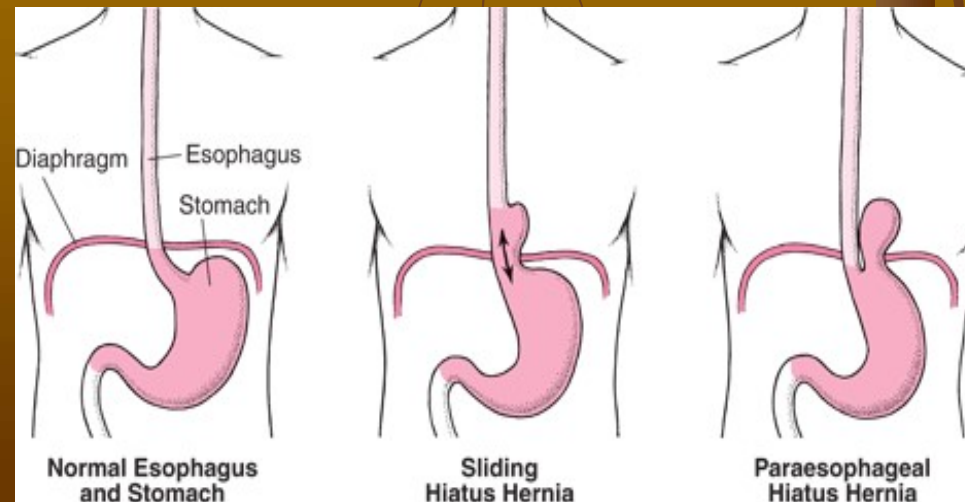
Hiatal hernias

■ sliding

- Lower esophageal sphincter and upper part of stomach slides into thoracic cavity
- Low external pressure in the thoracic cavity leads into the loss of function of LES and gastroesophageal reflux

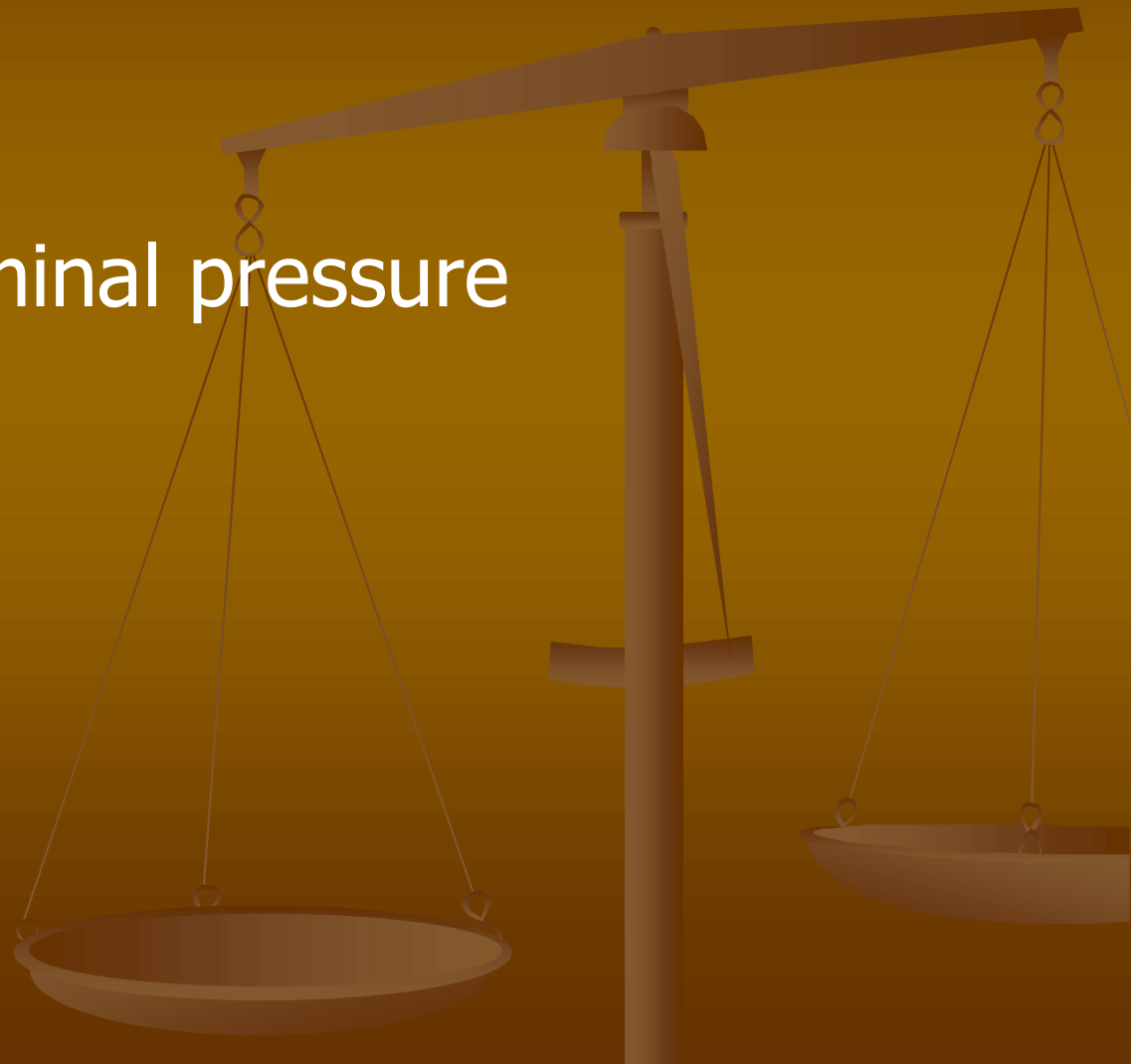■ paraesophageal

- Part of stomach's fundus is squeezed into thoracic cavity parallel with esophagus
- This can lead into its incarceration or strangulation with necrosis (life-threatening)
- Mostly, it manifests by pain and vomiting



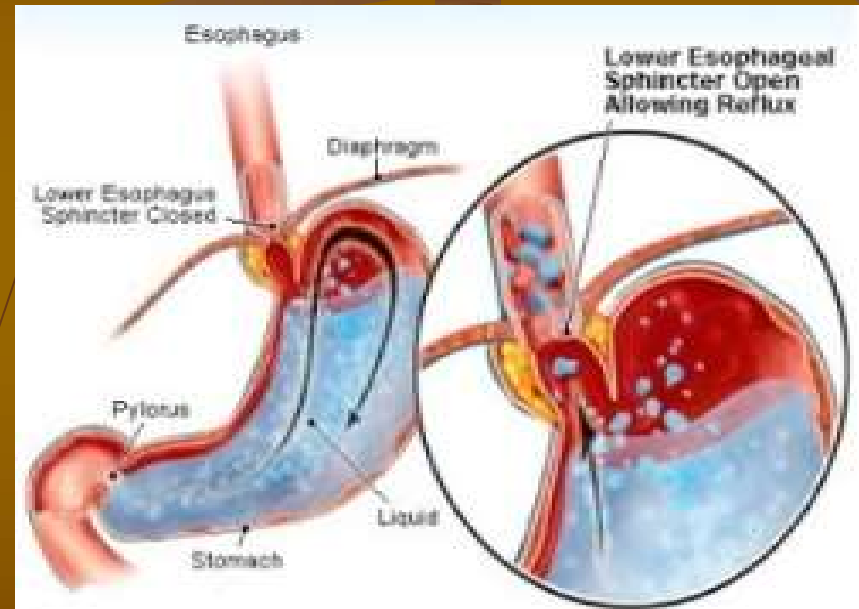
Hiatal hernias – risk factors

- Wide hiatus
- Obesity
- High intraabdominal pressure
- Gravity



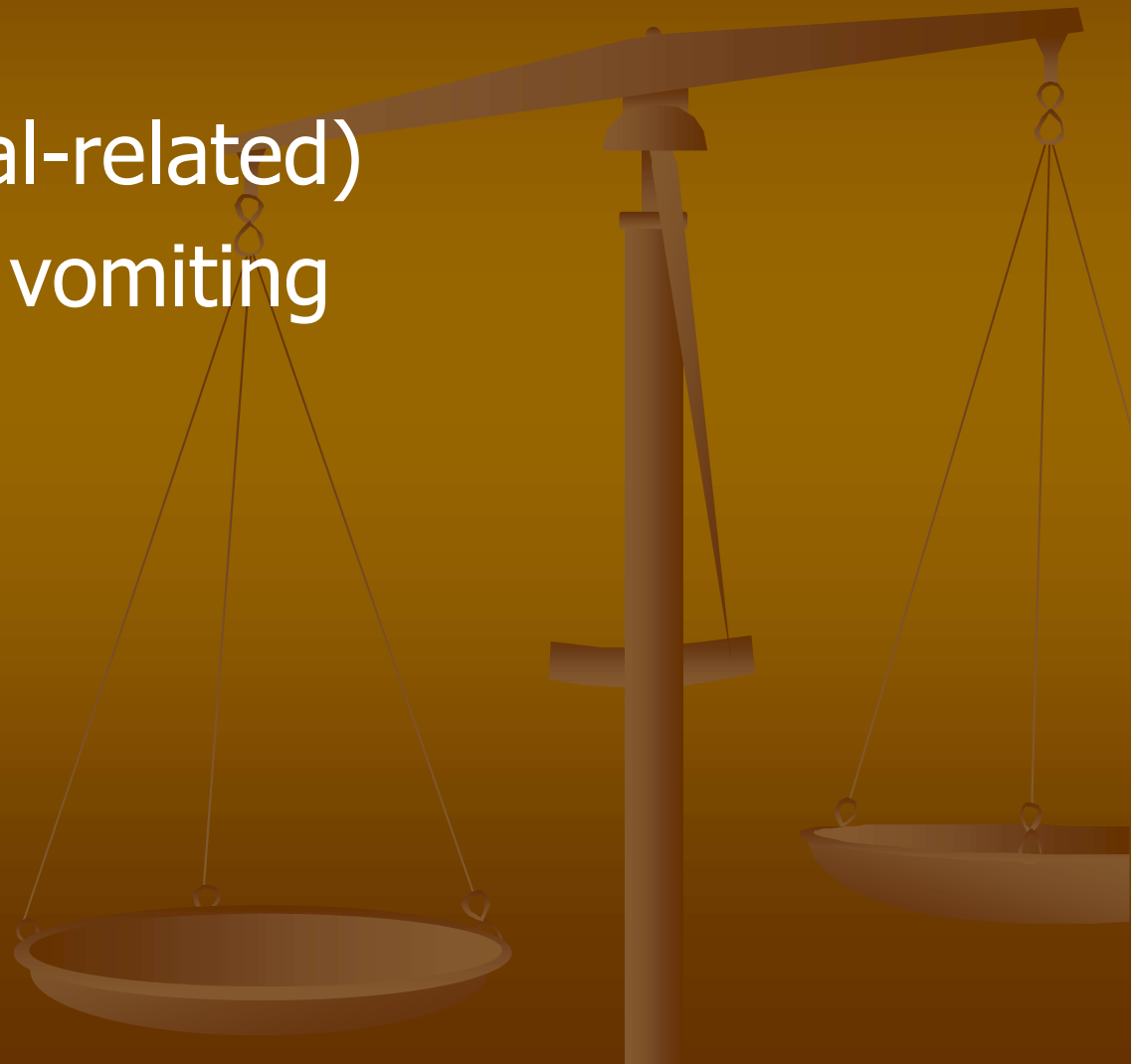Gastroesophageal reflux disease (GERD)

- Retrograde movement of gastric juice
- Loss of anti-reflux barrier
 - LES
 - Peristalsis
 - Angle between esophagus and fundus
- Aggressive action of HCl and proteases (pepsin) cause damage to the esophagus
- Sometimes, it occurs also in healthy people
- Frequently accompanies sliding hiatal hernia



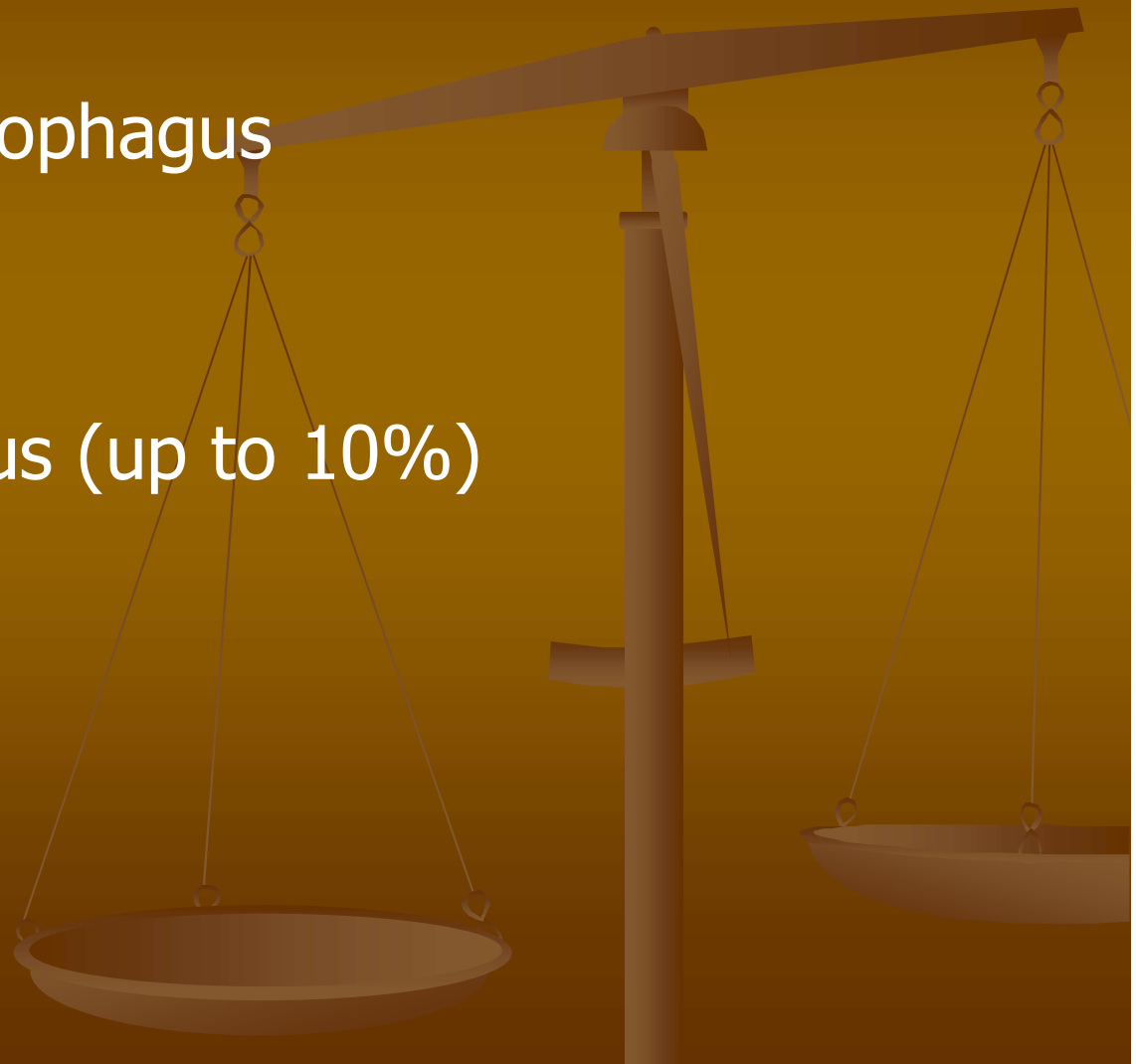
GERD - symptoms

- Heartburn
- Chest pain (meal-related)
- Regurgitation – vomiting
- Dysphagia



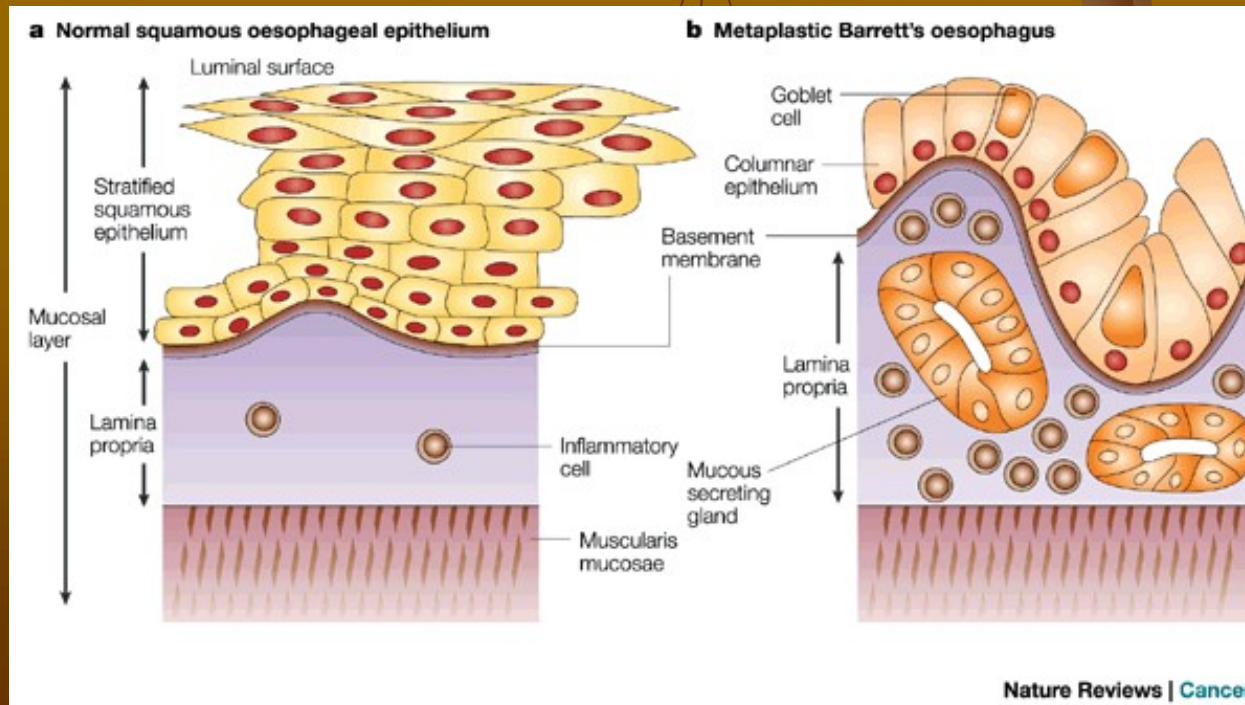
GERD - complications

- Reflux esophagitis
- Peptic ulcers in esophagus
- Strictures
- Bleeding
- Barrett's esophagus (up to 10%)
- Tumours

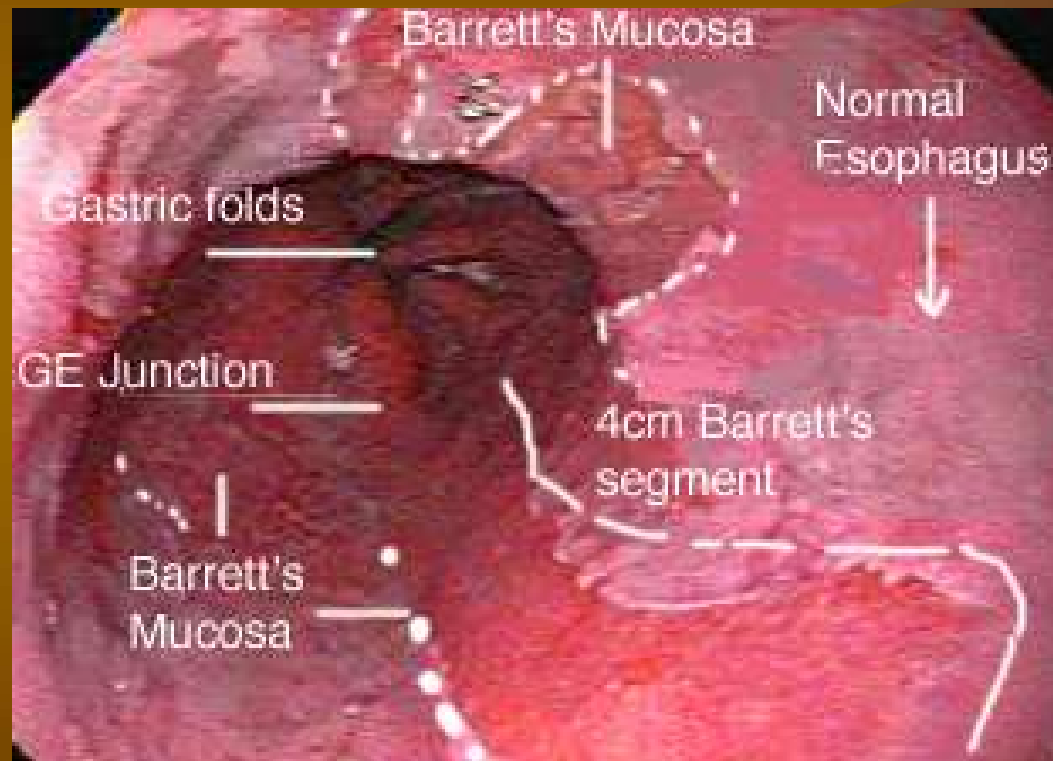


Barrett's esophagus

- Intestinal metaplasia in chronic GERD
- Change in cellular differentiation – squamous epithelium -> cylindrical (columnar)
- Precancerosis (cca 10 times higher relative risk of adenocarcinoma)
- Other risk factors: alcohol intake, high HCl secretion, decrease in motility

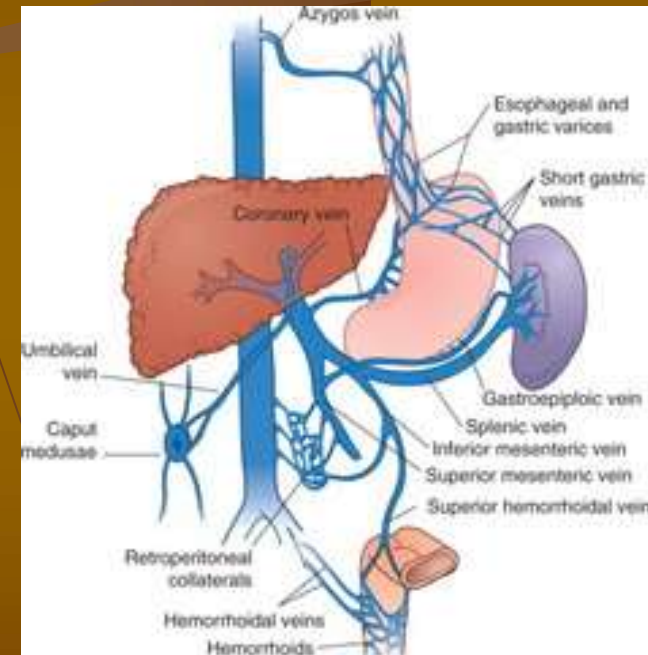


Barret's esophagus in gastroscopy



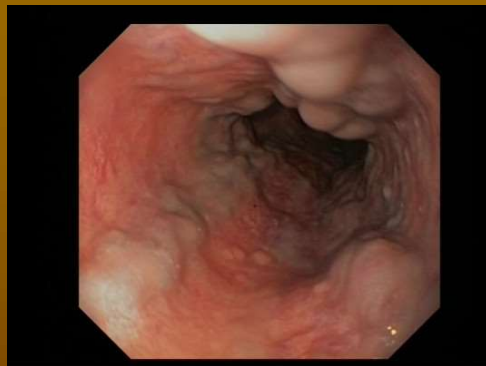Esophageal varices

- During portal hypertension (caused by e.g. liver cirrhosis, liver tumour, portal thrombosis, schistosomiasis), blood flows through anastomoses between portal and systemic circulation instead of through the liver
- That leads into remodeling of these collaterals and forming of varices
- They include esophageal varices, hemorrhoidal varices, swelling of paraumbilical veins („caput Medusae“) and collaterals to vena azygos in the retroperitoneum

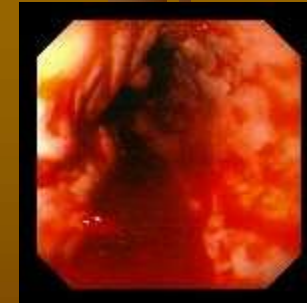

Esophageal varices - complications

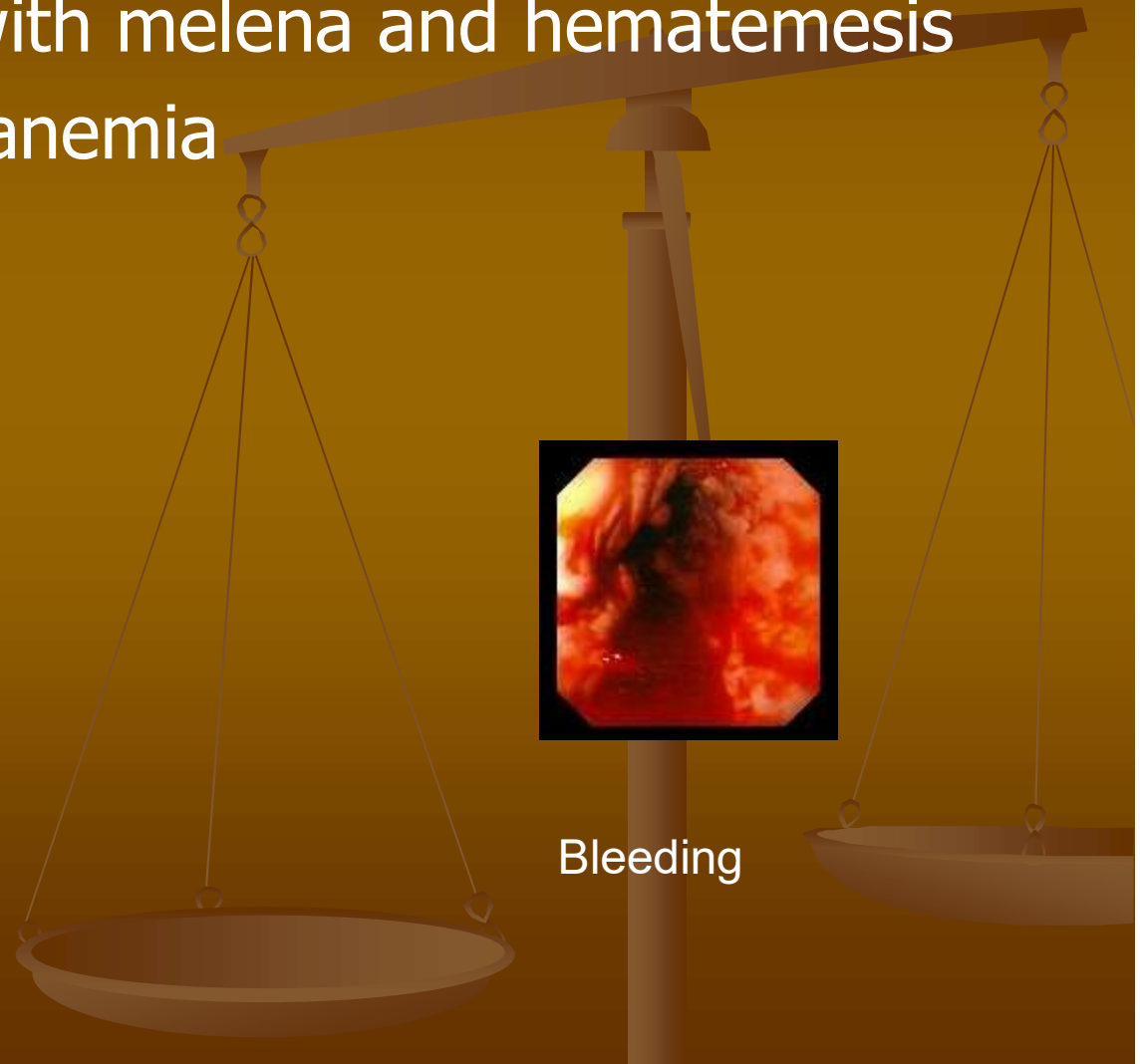
- Severe bleeding with melena and hematemesis
- Posthemorrhagic anemia



Esophageal varices



Bleeding



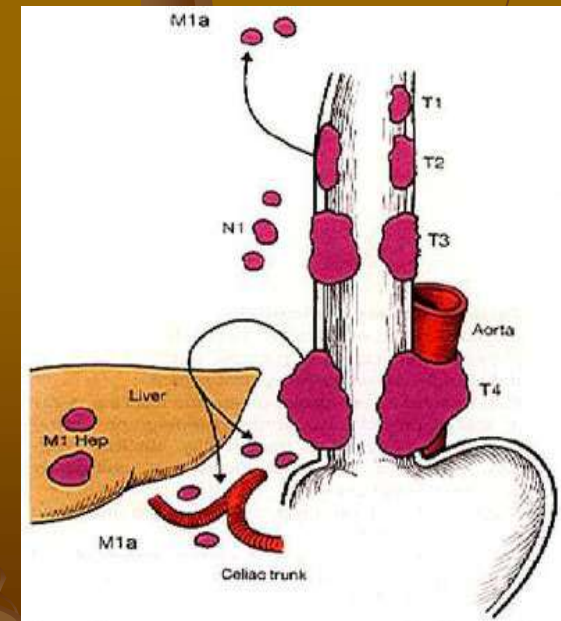
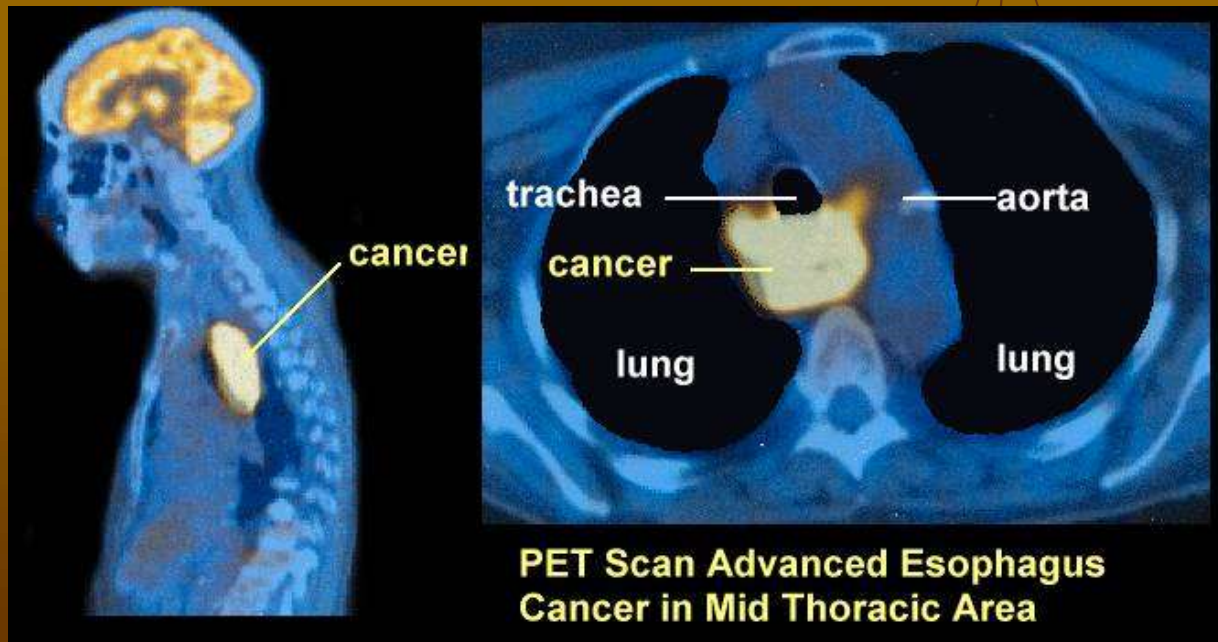
Esophageal tumours

■ Benign

- Leiomyoma
- Hemangioma
- Fibroma

■ Malignant

- Adenocarcinoma
- Squamous cell carcinoma
- Melanoblastoma



T-N-M classification