

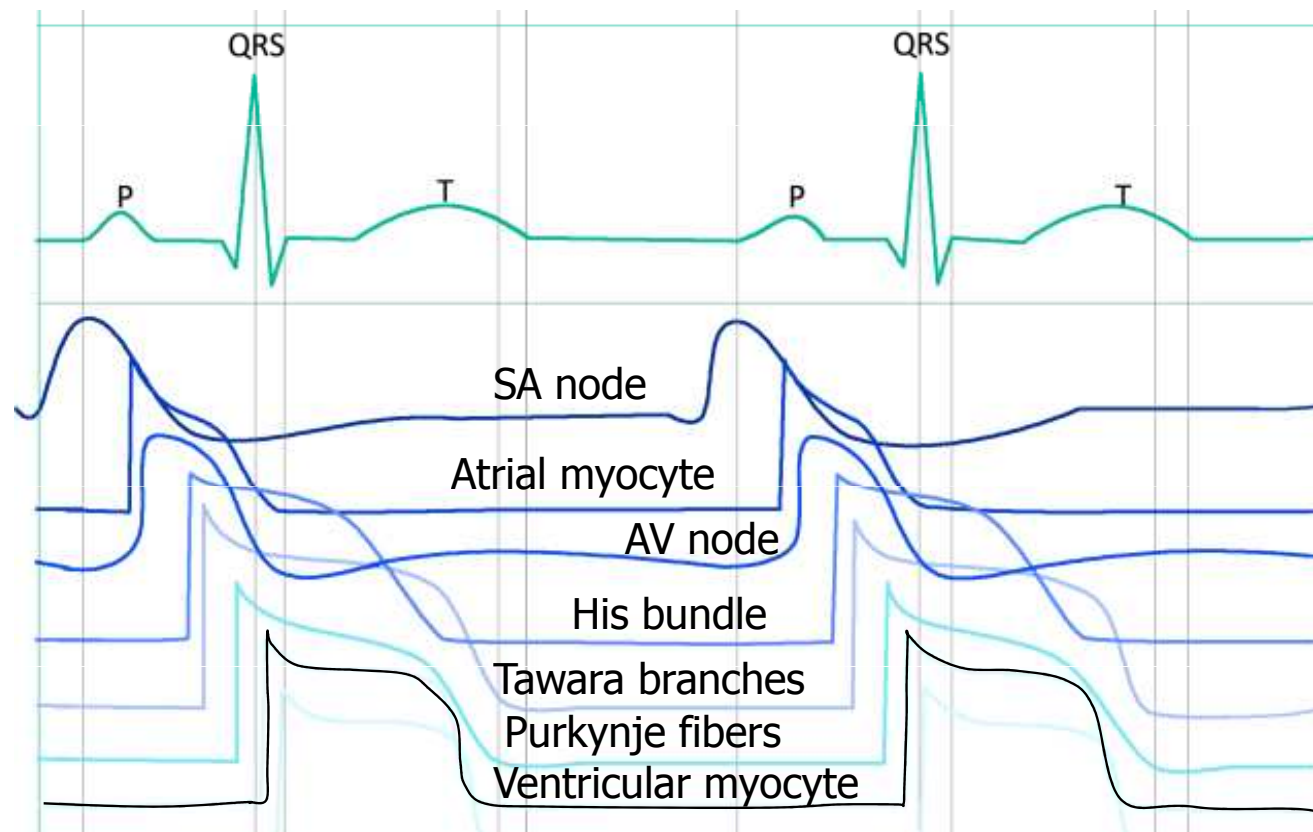
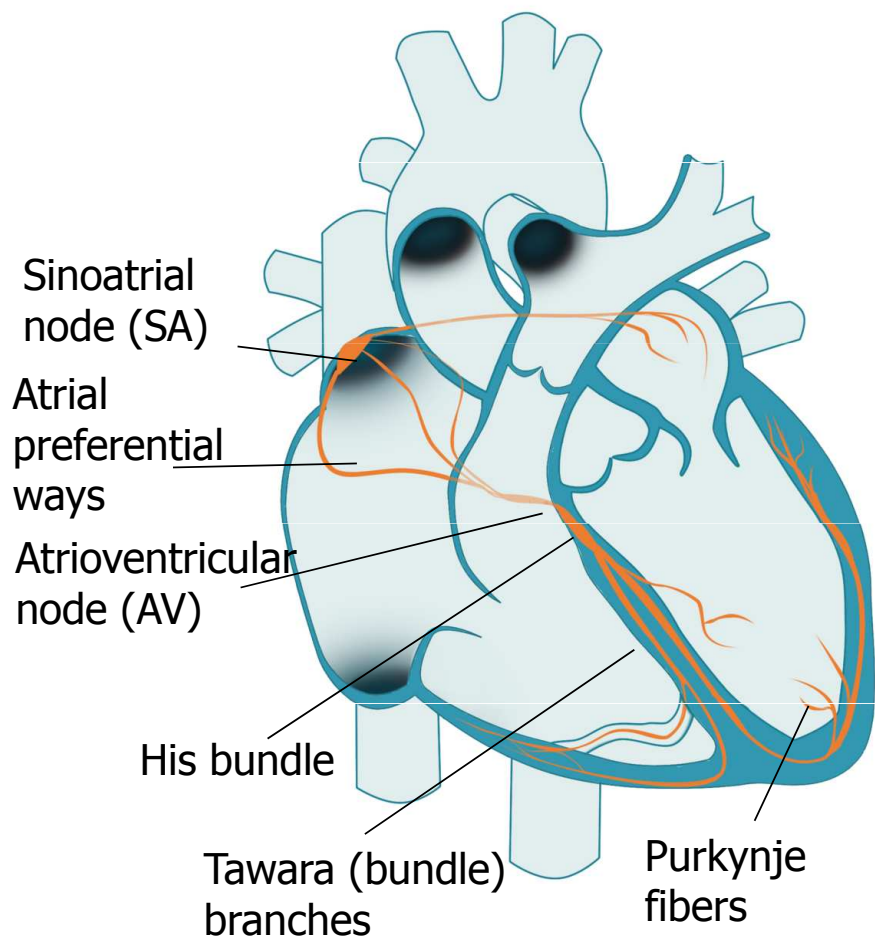
ECG – Electrocardiography

Practical Exercises in Physiology (Spring semester: 4th - 6th weeks)

Electrocardiography

- Definition: recording the cardiac electrical activity from the surface of the body
(el. heart activity can also be obtained from the esophageal leads or the heart surface itself, but these methods are used by other names)

Cardiac conduction system

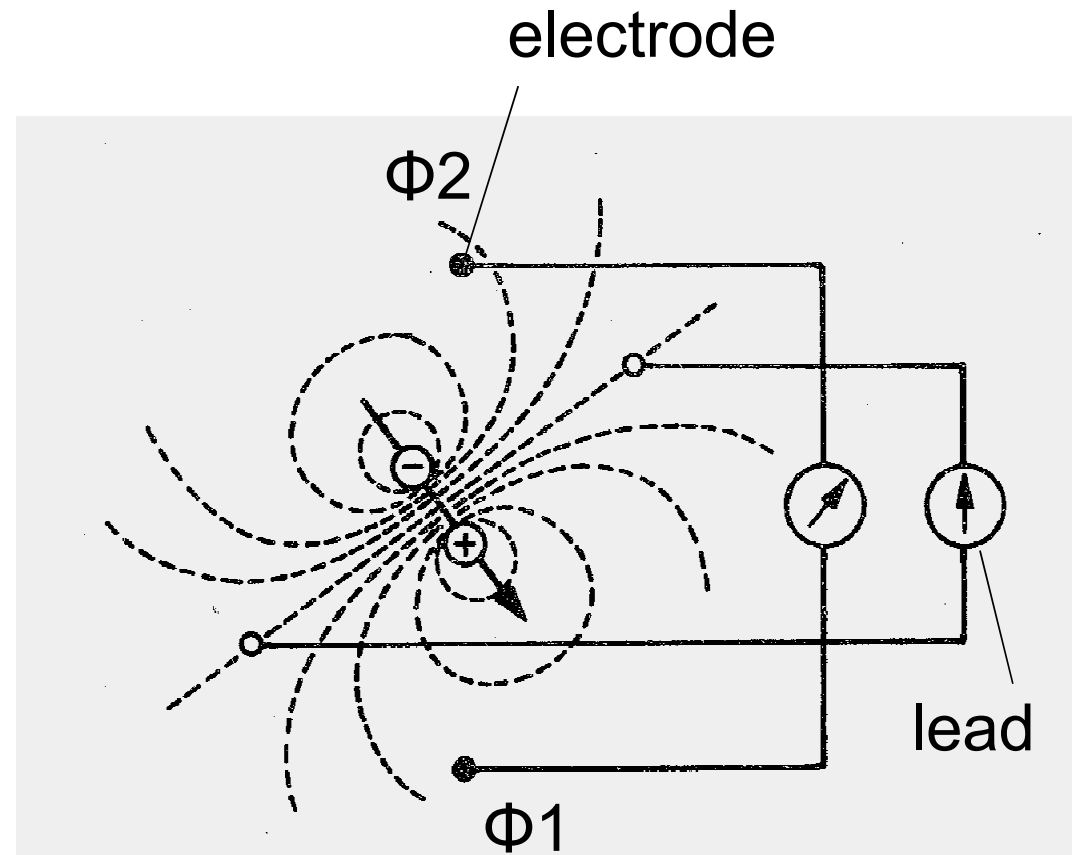


Cardiac conduction system

- Function: AP formation and preferential conduction
 - The atriums are separated from the chambers by a non-conductive fibrous septum - the only way is through the AV
 - Sinoatrial node (SA) - natural frequency 100 bpm (mostly under parasympathetic damping effect), conduction velocity 0.05 m/s
 - Preferred internodal atrial ways - conduction velocity 0.8 - 1 m / s
 - Atrioventricular node - single conductive connection between atria and ventricles, natural frequency 40 - 55 bpm, conduction velocity only 0.05 m / s (nodal delay)
 - His bundle – conduction velocity 1–1,5 m/s
 - Tawara (bundle) branches – conduction velocity 1–1,5 m/s
 - Purkynje fibers – conduction velocity 3–3,5 m/s
- } natural frequencies of 20 - 40 bpm, they have slow spontaneous depolarization
- Sinus rhythm - AP starts at the SA node
 - Junction rhythm - AP is formed in the AV node or His bundle
 - Tertiary (ventricular) rhythm - AP is formed in bundle branches or Purkynje fiber
 - Ventricular myocardial activation - from inside to outside, markedly synchronized, determined by the onset of excitement
 - Repolarization of ventricular myocardium - in the opposite direction, less sharp, repolarization isles
 - Note: natural frequency is the frequency of AP formation unaffected by neural and hormonal control

Electric dipole

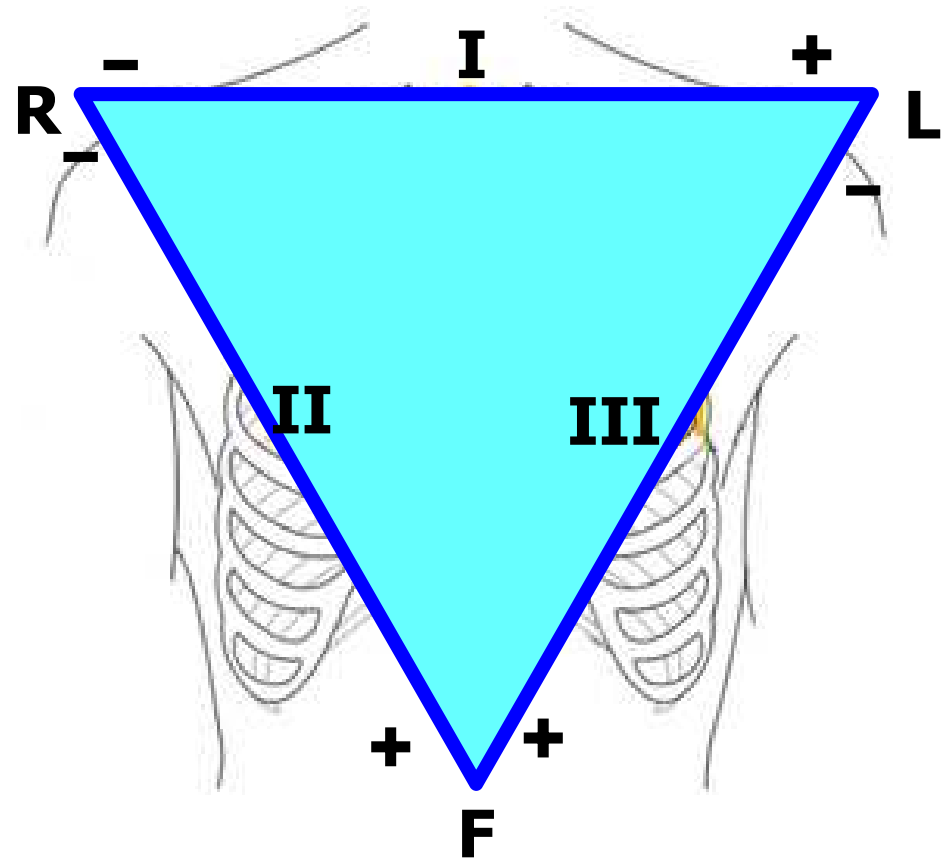
- Electrode: records electrical potential (Φ)
- Electrical lead: connection of two electrodes
 - It records the voltage between the electrodes
 - Voltage: difference of el. potentials ($V = \Phi_1 - \Phi_2$)



Einthoven triangle

(standard, limb, bipolar leads)

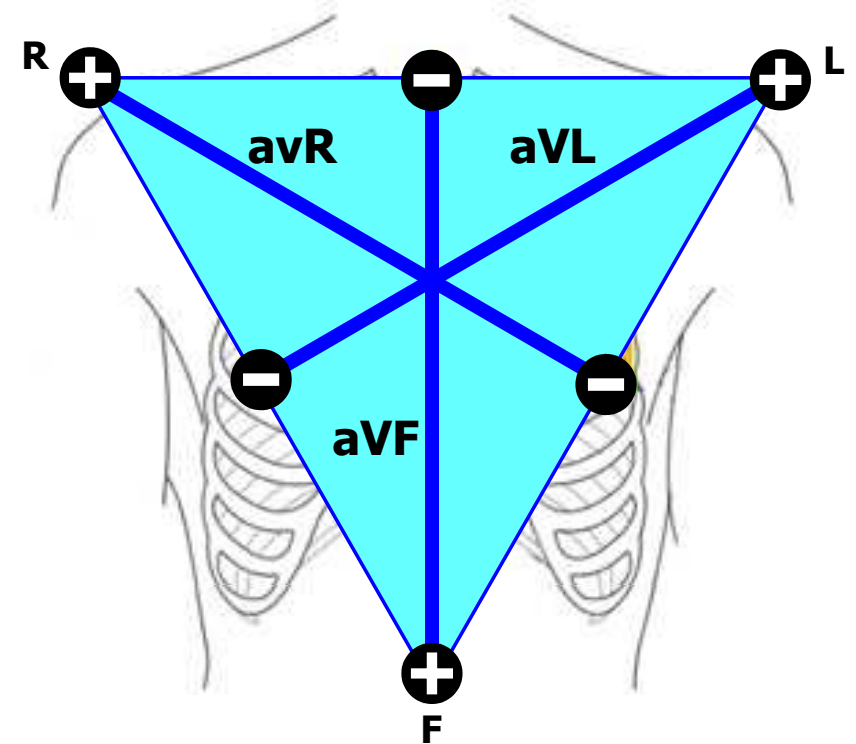
- Bipolar leads: both electrodes are active (variable electrical potential)
- Electrode colors:
R: red, L: yellow, F: green



Goldberger leads

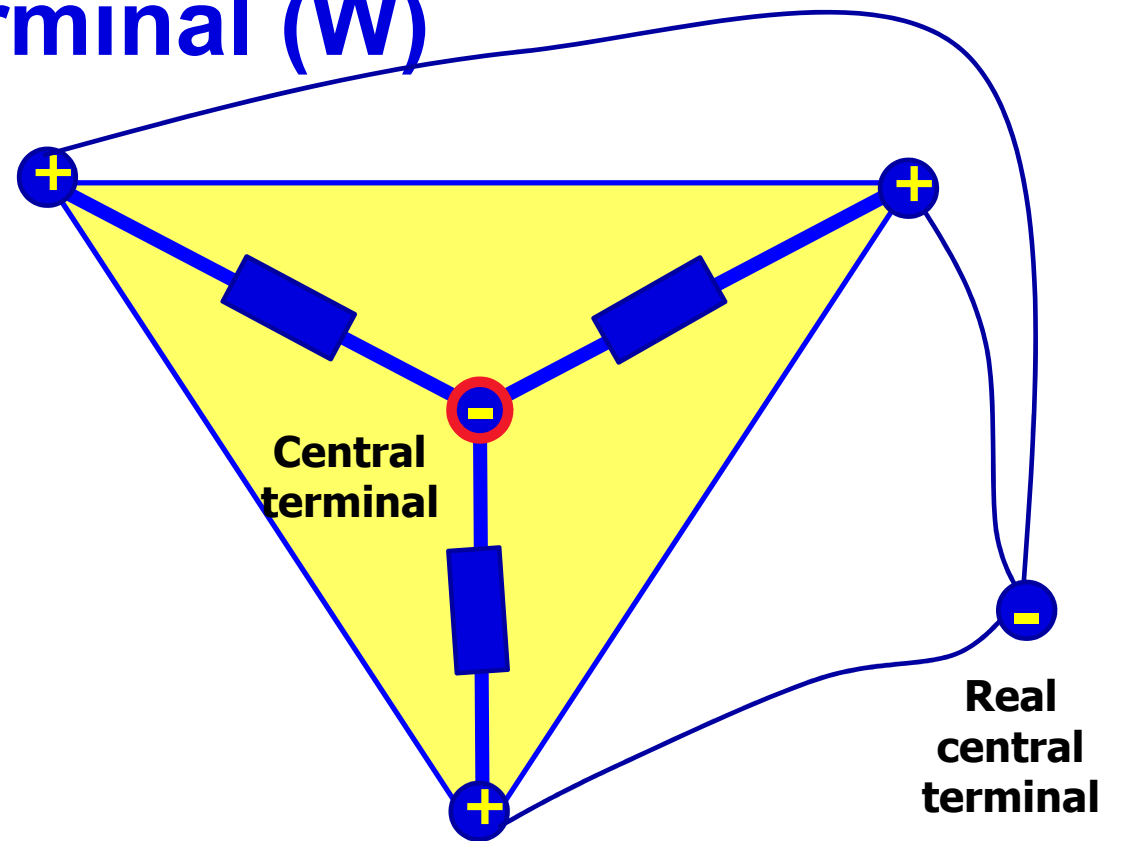
(augmented, limb, unipolar leads)

- Unipolar leads: one electrode is active (variable electric potential) and the other is inactive (constant electric potential, usually 0 mV)
- The active electrode is always positive



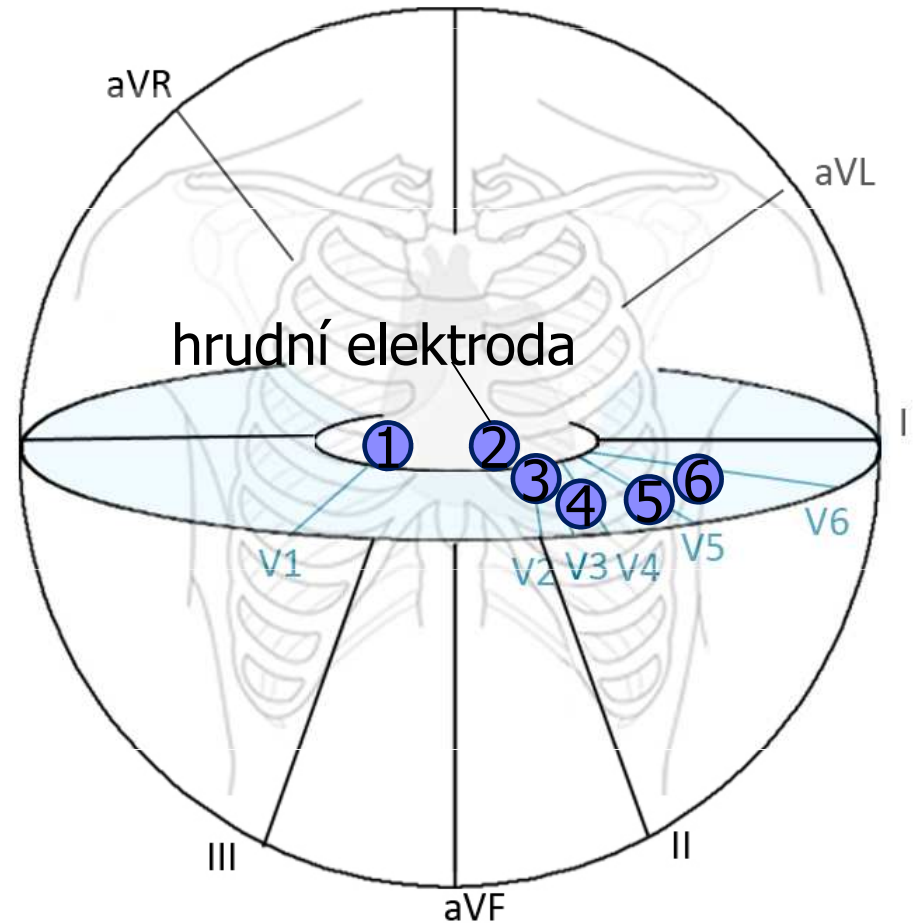
Wilsonova central terminal (W)

- It is formed by the connection of limb electrodes through resistors
- electrically represents the center of the heart (it is actually led out or it is calculated)
- Inactive electrode (constant potential)

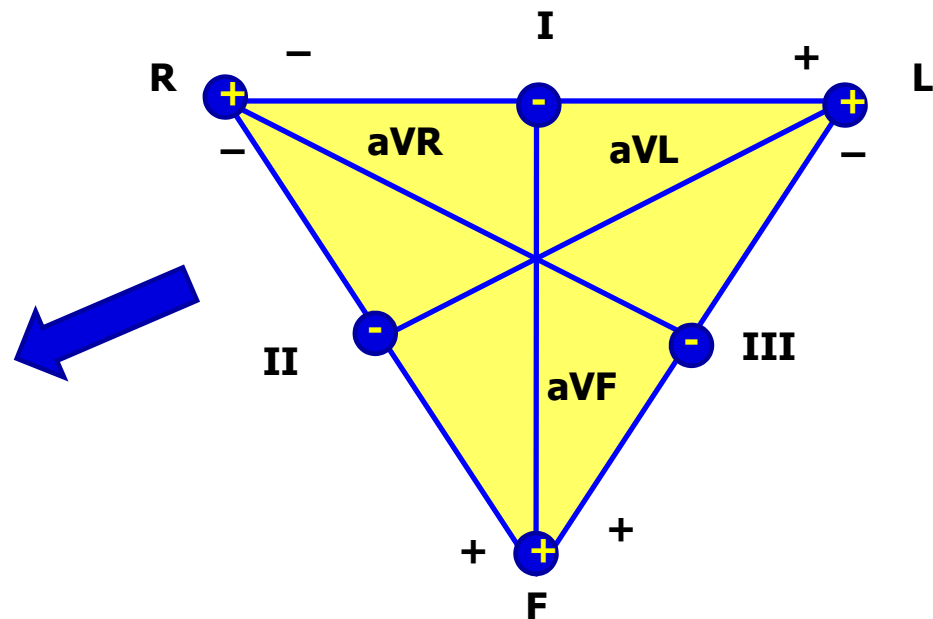
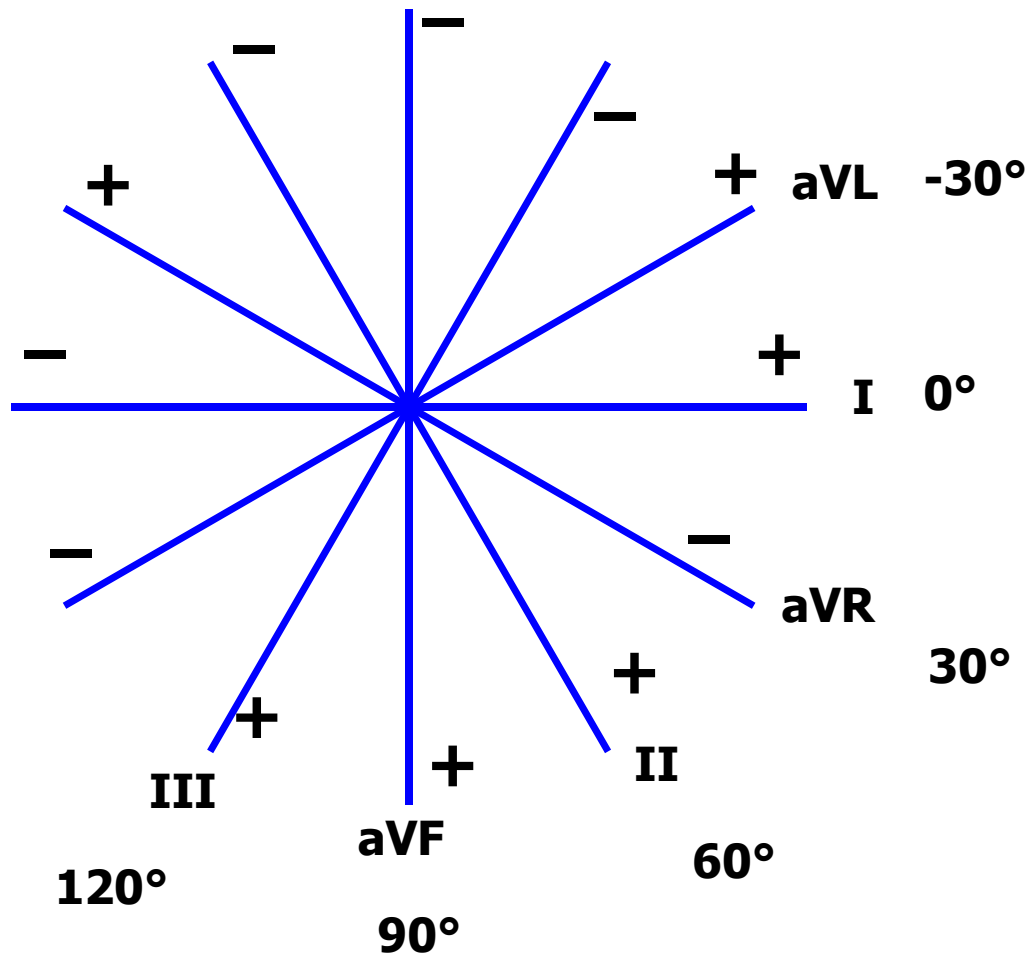


Chest leads

- Chest lead: connection of chest electrode and central terminal
- Unipolar leads: chest electrode is active (positive) and central terminal is inactive (0 mV potential)

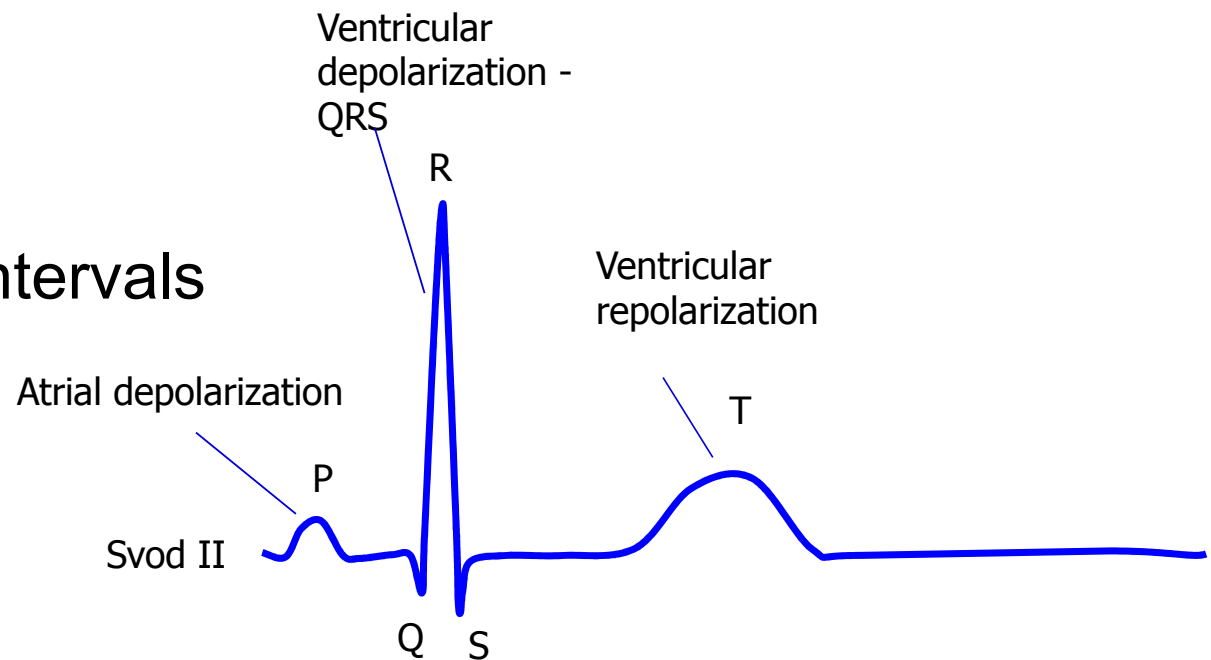


Leads according to Cabrera



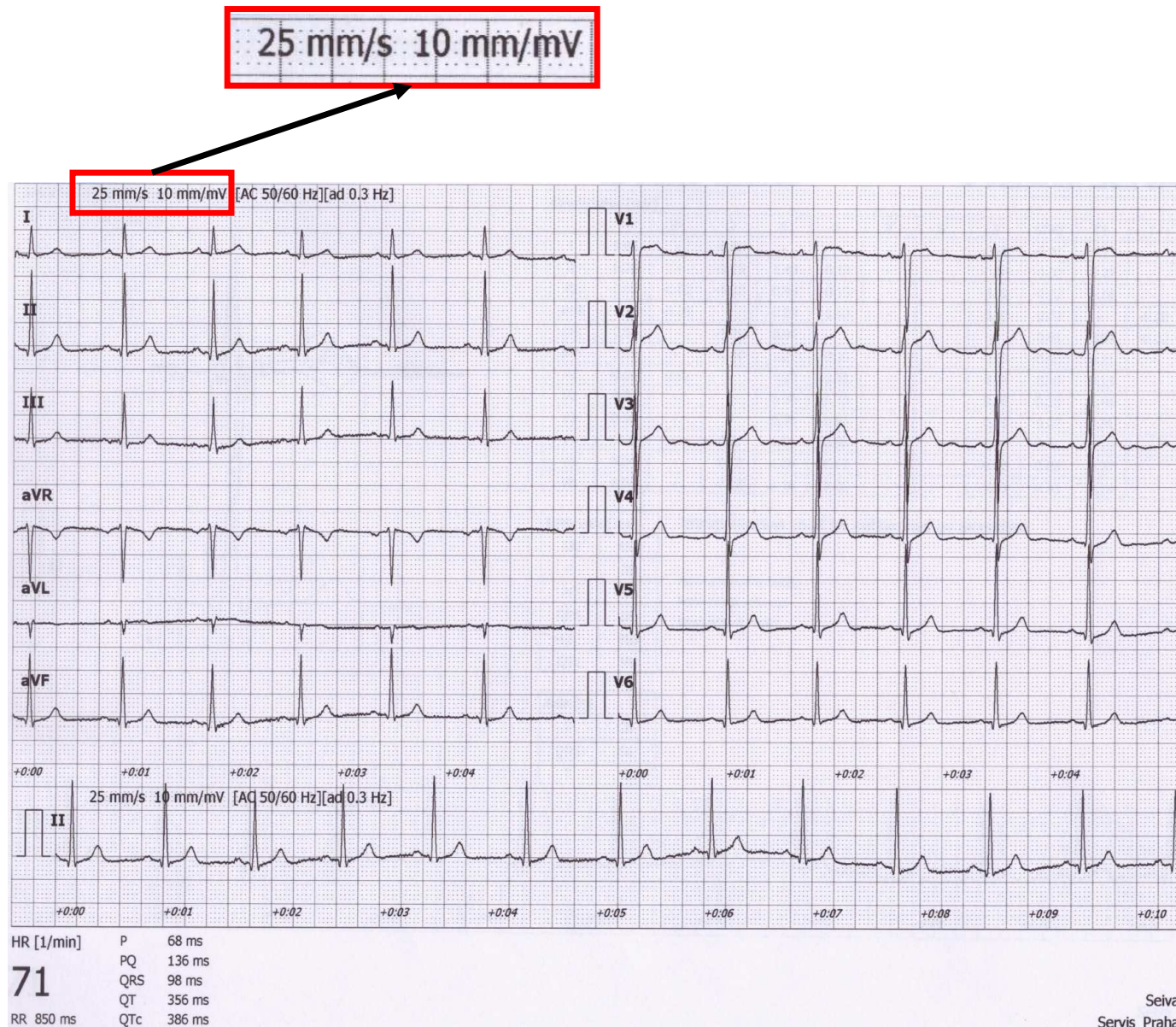
Analysis of ECG

1. Heart action
2. Heart rhythm
3. Heart rate
4. Waves, segments and intervals
 - P wave
 - PQ interval
 - QRS complex
 - ST segment
 - T wave
 - QT interval
5. Electrical heart axis



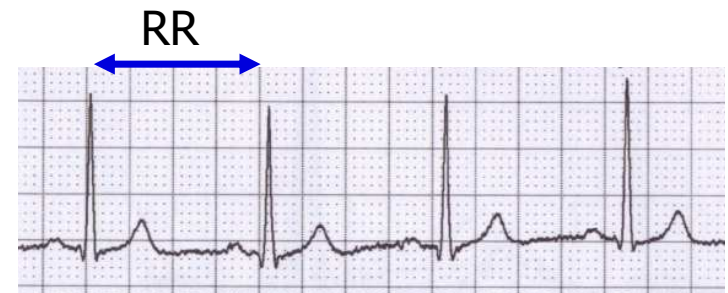
Analysis of ECG

- A millimeter grid of paper will help in fast analysis
- See the paper speed (here 25 mm / s)
 - How many ms is one mm?
 - It is good to know how much mV is one mm



1) Heart action

- Regularity of distances between QRS complexes - RR intervals
- Calculate difference: $RR - \text{mean } RR$
(you only need to choose the shortest and longest RR in the record)
- Regular action: difference $< 0,16$ s
- Irregular action: difference $> 0,16$ s
 - Usually pathological
 - Beware of significant sinus respiratory arrhythmia - it is very physiological. If you are unsure, ask the patient to hold their breath during recording
- Note: if one extrasystole is present, but otherwise the action is regular, it is called regular



2) Heart rhythm

- Heart rhythm is determined by the source of action potentials that lead to ventricular depolarization

ventricular depolarization is crucial, because it determines cardiac output

- **Sinus rhythm**

- AP begins in SA node
- On ECG: present P wave (atrial depolarization) before QRS

- **Junction rhythm**

- AP begins in AV node or His bundle, the frequency is usually 40-60 bpm
- P wave is not before QRS, QRS is normal (narrow)
- Heart rate is low (40-60 bpm)
- Atrial depolarization can be present in the ECG if the ventricular impulses are transferred to the atria - wave is after QRS and has opposite polarity because it runs in opposite direction

- **Tertial (ventricular) rhythm**

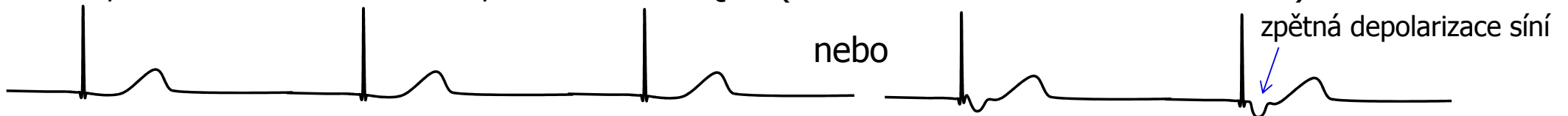
- AP begins in other parts of the conduction system, frequency 30-40 bpm
- QRS has a strange shape (wider), because it spreads in a non-standard direction in the ventricles

2) Srdeční rytmus

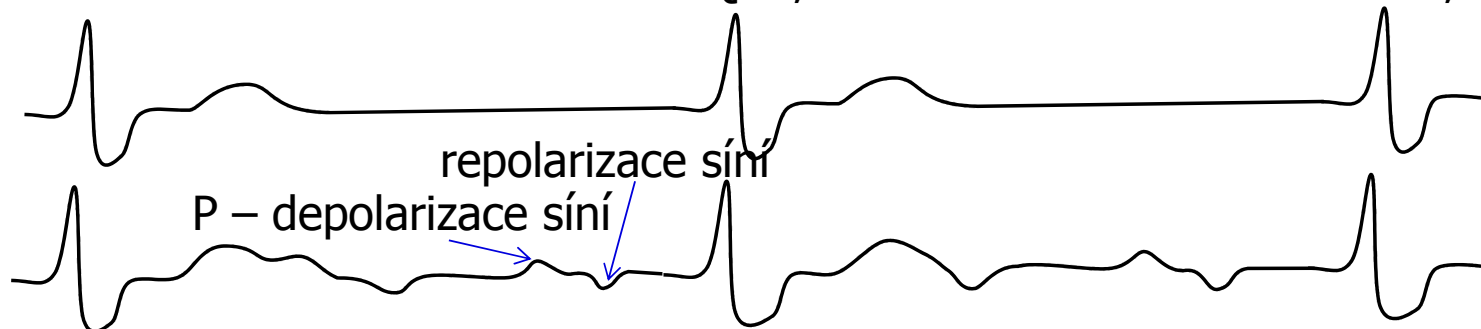
Sinusový rytmus – před každým QRS je přítomna vlna P – vzruch začíná v SA uzlu, ne na něj navázaná depolarizace komor



Junkční rytmus – nejsou přítomné normální vlny P před QRS – vzruch začíná v AV uzlu nebo Hisově svazku, nízká srdeční frekvence, ale normální QRS (v komoře se vzruch šíří normálně)



Terciální (komorový) rytmus – nejsou přítomné vlny normální P vázané na QRS, vzruch začíná někde v komorách – deformované QRS, hodně nízká srdeční frekvence, například AV blok III. stupně



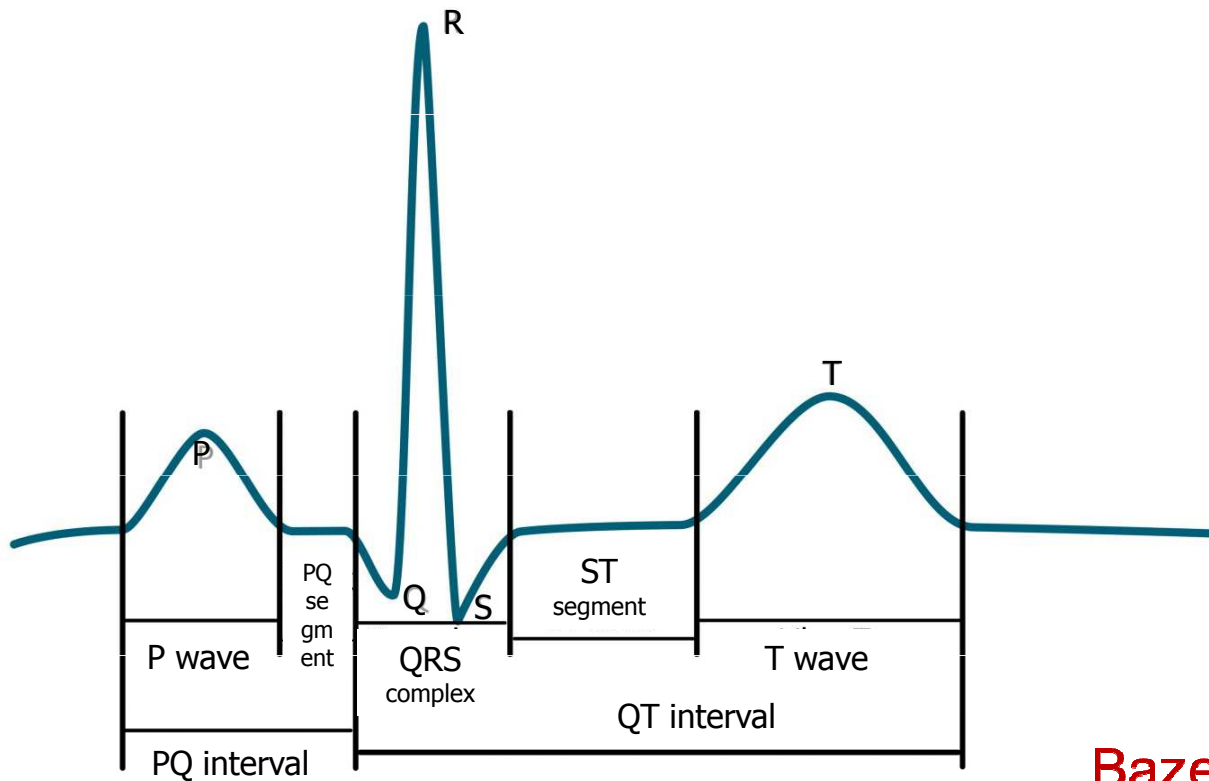
AV blok III. stupně – komory si jedou terciální rytmus, síně si jednou svůj rychlejší rytmus určený SA uzlem, který se ale nepřevádí do komor

3) Heart rate (HR)

- Frequency of ventricular contraction (because it determines cardiac output); on ECG - frequency of ventricular depolarizations
- $HR = 1 / RR$ bpm
- Physiological: 60 - 90 bpm at rest

- Tachycardia: > 90 bpm in rest
 - Can be sinus (increase sympathetic activity, medication, ...)
 - Tachyarrhythmias: rhythm is not sinus
- Bradycardia: < 60 bpm
 - Can be sinus (increase sympathetic activity, sport heart - physiological)
 - $HR < 50$ bpm, rhythm probably is not sinus

4) Waves, segments, intervals



Name	Norm
wave P	80 ms
interval PQ (PR)	120-200 ms
segment PQ (PR)	50-120 ms
Q	-
complex QRS	80-100ms
R	-
S	-
segment ST	80-120 ms
interval QT	< 420ms
wave T	160 ms

Bazett's formula: $QTc = \frac{QT}{\sqrt{RR}}$

QT depends on RR interval –
correction of QT on RR

4) Waves, segments, intervals

name	Place and description	Physiological background	Norm
wave P	First round wave (negative or positive)	Atrial depolarization	80 ms
Interval PQ (PR)	Interval from beginning of P to beginning of Q (or R, if Q is not present)	Time interval from SA node activation to the Purkynje fibers activation	120-200 ms
segment PQ (PR)	From P wave end to beginning of Q (or R, if Q is not present)	Complete atrial depolarization, AP transfer from AV to ventricles	50-120 ms
Q	First negative deflection	Depolarization of septum and papilar muscles	-
complex QRS	From beginning of R to end of S	Ventricular depolarization	80-100ms
R	Positive deflection	Main ventricular depolarization	-
S	Negative deflection after positive deflection.		-
segment ST	Interval of isoelectric line between end of QRS and beginning of T wave	Complete depolarization of ventricles	80-120 ms
Interval QT	From beginning of Q (or R) to the end of wave T	Electrical systole	< 420ms
wave T	Second round wave (negative or positive)	Ventricular repolarization	160 ms

4) Waves

Wave P:

- Is present?
- Is positive/negative, one-peak/two-peak, high(>0,25mV)/normal/low?

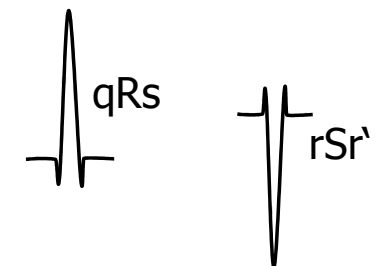
QRS:

Q: first negative deflection

R: first positive deflection

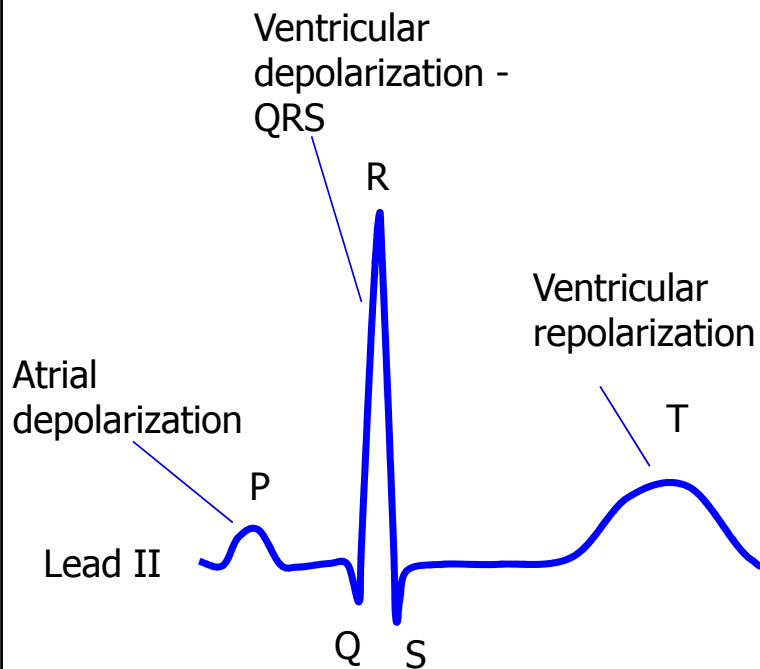
S: negative deflection after positive deflection

- small deflection (pod 0,5 mV) – small letter
- Strong deflection – capital letter
- Second positive deflection (')



Wave T:

- Is positive/negative/bipolar?
- Does it have the same polarity as the strongest QRS deflection?
 - Yes: concordant (ok), No: discordant (pathology)
- Bipolar T:
 - Preterminal negative (-/+)
 - Terminal negative (+/-)



5) Electrical heart axis

Electrical heart axis: average direction of the electric heart vector during ventricular depolarization (QRS complex)

(can also be determined for atrial depolarization: P, or ventricular repolarization: T, but in practice we will analyse ventricular depolarization)

Heart axis is physiologically directed down, left, back - refers to the real placement of the heart in the chest.
- Here we solve only the frontal plane (limb leads)

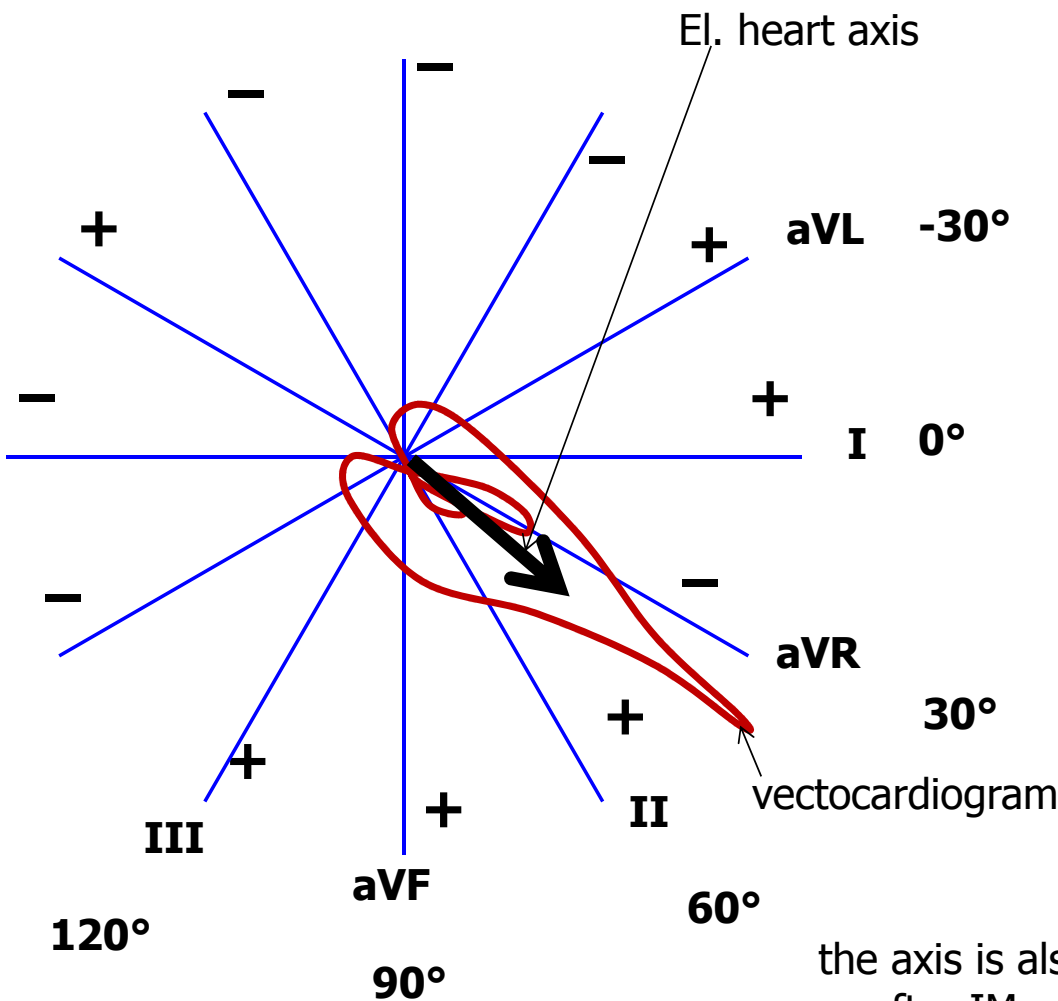
Physiological range:

- Middle type $0^{\circ} - 90^{\circ}$
- Left type $-30^{\circ} - 0^{\circ}$
- Right type $90^{\circ} - 120^{\circ}$

Pathological range:

- Right deviation: $> 120^{\circ}$ (P ventricular hypertrophy, dextrocardia)
- Left deviation: $< -30^{\circ}$ (L ventricular hypertrophy, pregnancy, obesity)

the axis is also changed when Tawara branches are blocked or after IM, missing el. activity of part of chambers



Electrical heart axis - evaluation

- Because the el. axis is related to ventricular depolarization in the frontal plane, use QRS in limb leads: I, II, III.
- Calculate the sum of QRS oscillations in leads I, II, III.

When the oscillation is down, it is negative. When the oscillation is up, it is positive. Use a millimeter grid

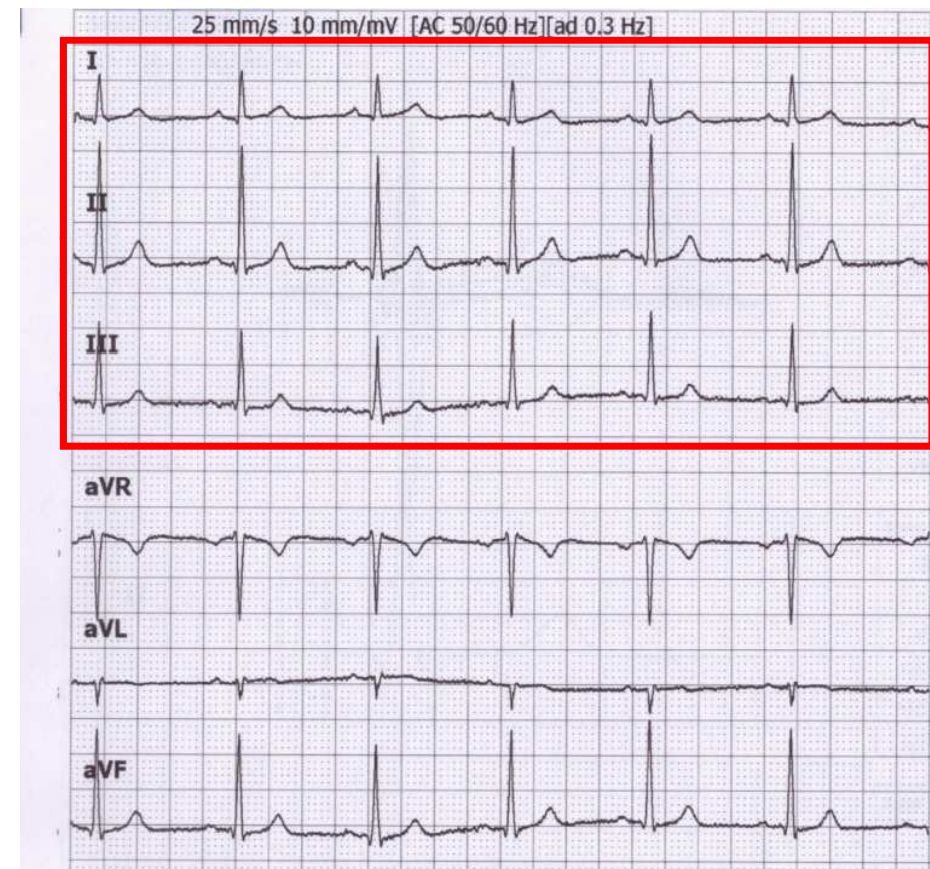
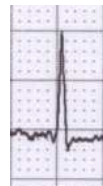- Lead I: $Q_I = -1$; $R_I = 6$; $S_I = 0$;
 $QRS_I = 5$



- Lead II: $Q_{II} = -1$; $R_{II} = 17$; $S_{II} = -1$;
 $QRS_{II} = 15$

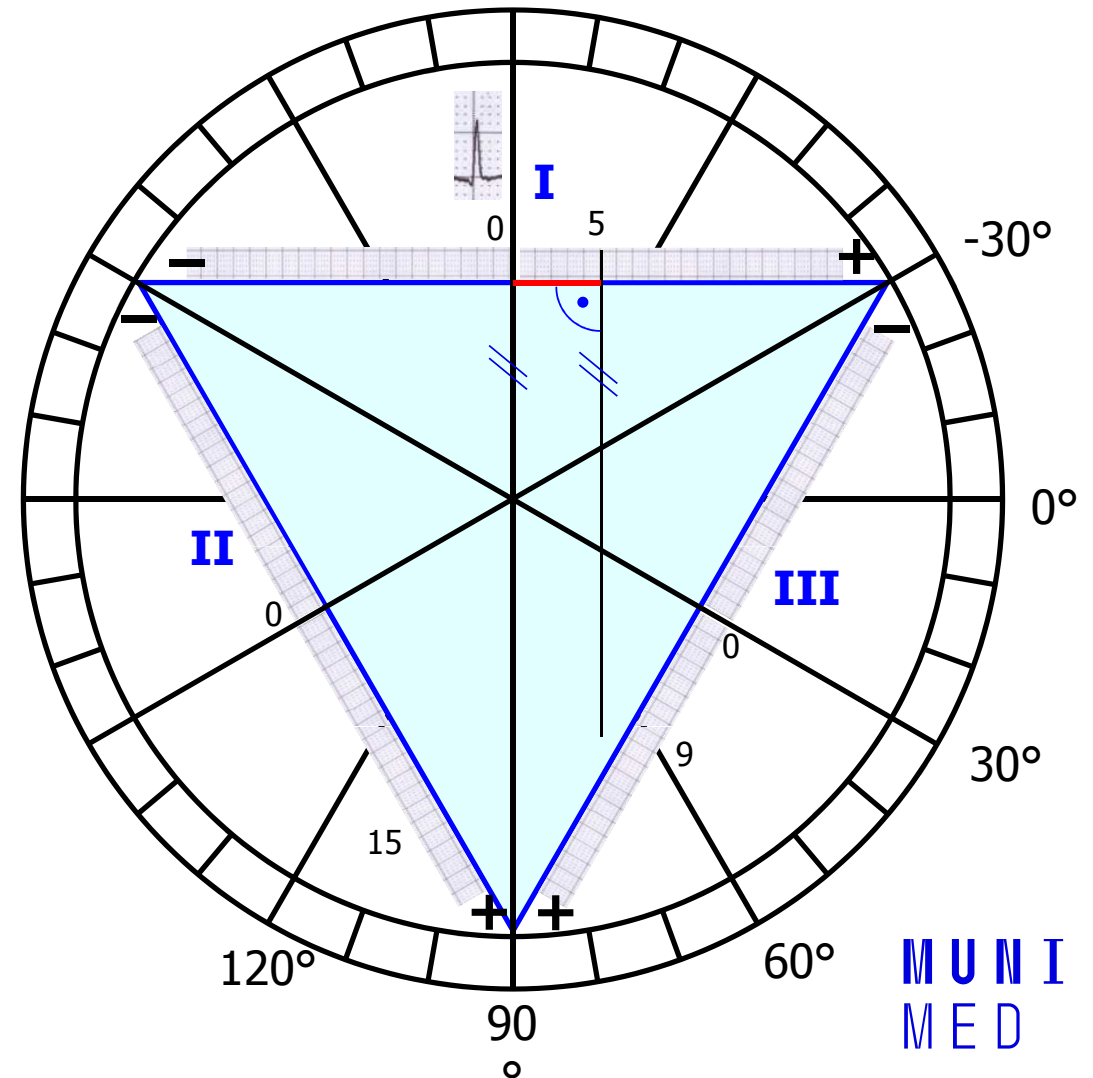


- Lead III: $Q_{III} = 0$; $R_{III} = 10$; $S_{III} = -1$;
 $QRS_{III} = 9$



Electrical heart axis - evaluation

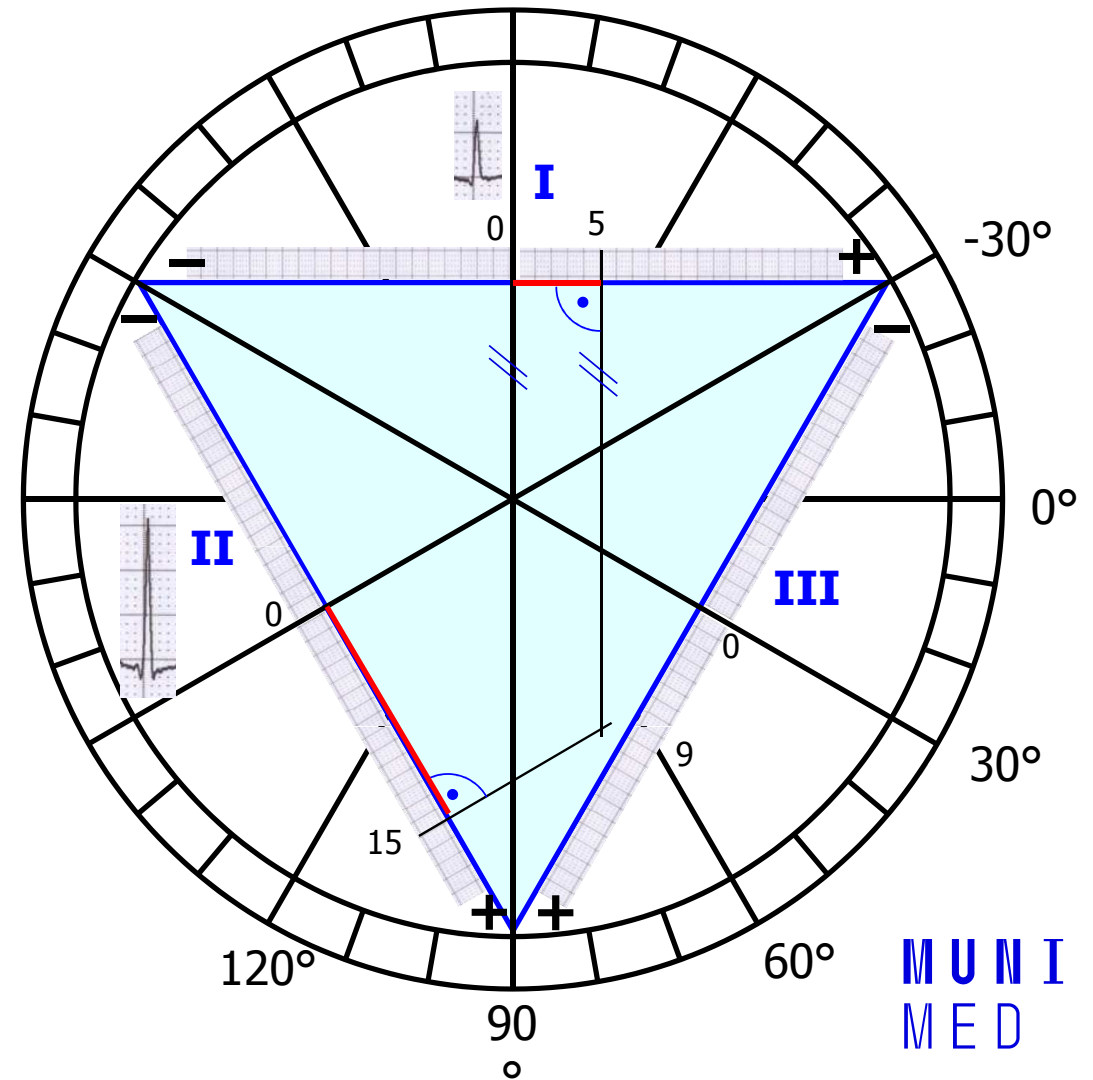
- Draw the Einthoven Triangle with Goldberger augmented Leads
- Mark the angles around the triangle (in the circle)
- Lead I:
 - 0 at lead I is in the center of lead
 - $QRS_I = 5$, so from 0, measure 5mm towards the positive electrode, make a mark (or any other units, ratio is important)
 - If the sum of QRS is negative, you will go towards the negative electrode
 - Run a line from the mark perpendicular to the I lead (parallel to the aVF lead)



Electrical heart axis - evaluation

— Lead II:

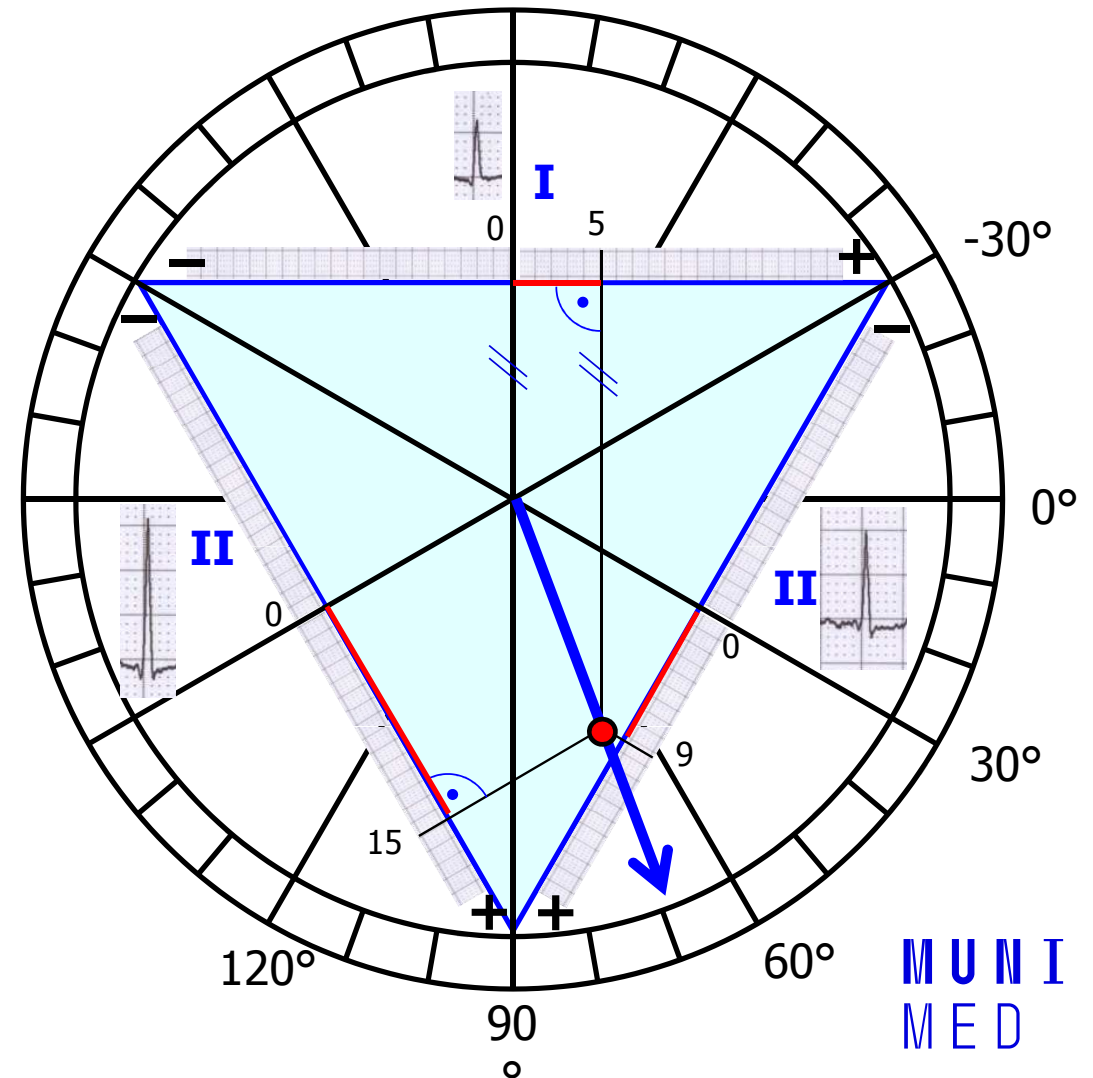
- 0 at lead II is again in the center of lead
- $QRS_{II} = 15$, so from 0, measure 15 mm towards the positive electrode, make a mark (again, if the sum of QRS is negative, you will go towards the negative electrode)
- Run a line from the mark perpendicular to the II lead (parallel to the aVL lead)



Electrical heart axis - evaluation

- Lead III:
 - The same way draw line for $QRS_{III} = 9$
- Draw an arrow that starts at the center of the triangle and passes the cross of the drawn lines
- This arrow shows the direction of the cardiac electrical axis in the frontal plane
- Note. logically, only lines from two leads are sufficient

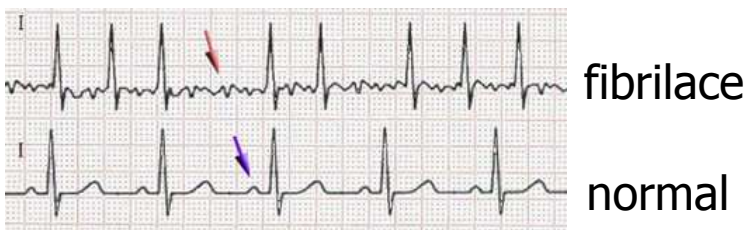
The cardiac electrical axis for ventricular depolarization in the frontal plane is 70°



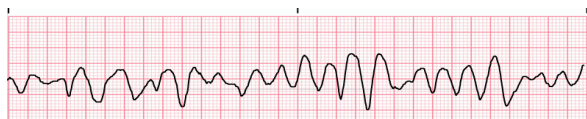Diagnostické využití EKG

Arytmie: porucha srdečního rytmu

Fibrilace: nesynchronizovaná aktivita kardiomyocytů



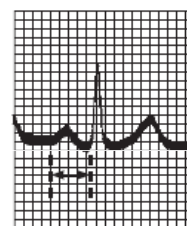
síňová fibrilace
(chybí P, „zubatá“ izolinie, RR nepravidelné, frekvence 80 – 180 bpm)



komorová fibrilace
(srdce nefunguje jako pumpa, poškození mozku po 3 – 5 minutách fibrilace)

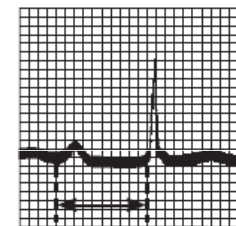
25

Atrioventrikulární blokáda: porucha převodu vzruchu ze síní na komory



PR = 0.16 s

Normal complex

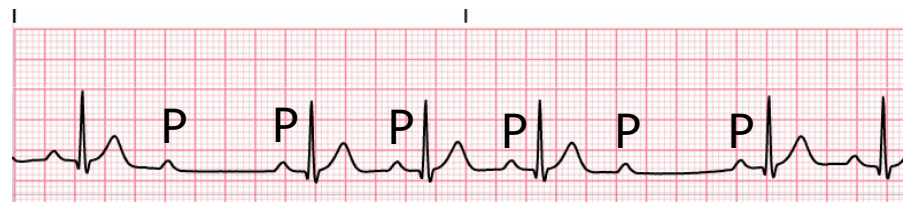


PR = 0.38 s

AV blok I. stupně

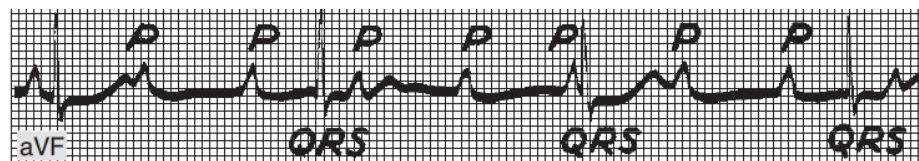
(prodloužení převodu vzruchu ze síně na komory, prodloužený PQ int.)

AV blok II. stupně



(některé vzruchy se nepřevodou: výskyt P, po kterých nenásleduje QRS)

AV blok III. stupně



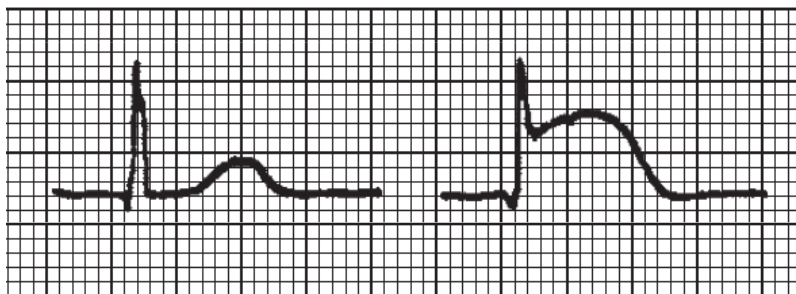
Kompletní blokáda převodu vzruchů ze síní na komory, P a QRS se objevují nesynchronizovaně

Diagnostické využití EKG

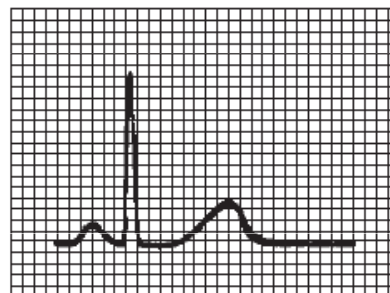
ischemie srdce, infarkt myokardu

A

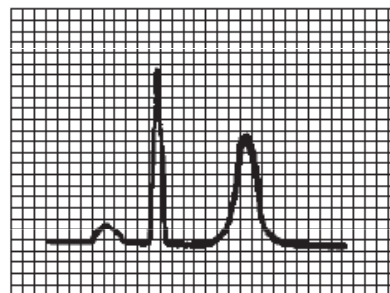
B (elevace ST)



elektrolytová nerovnováha - hyperkalémie



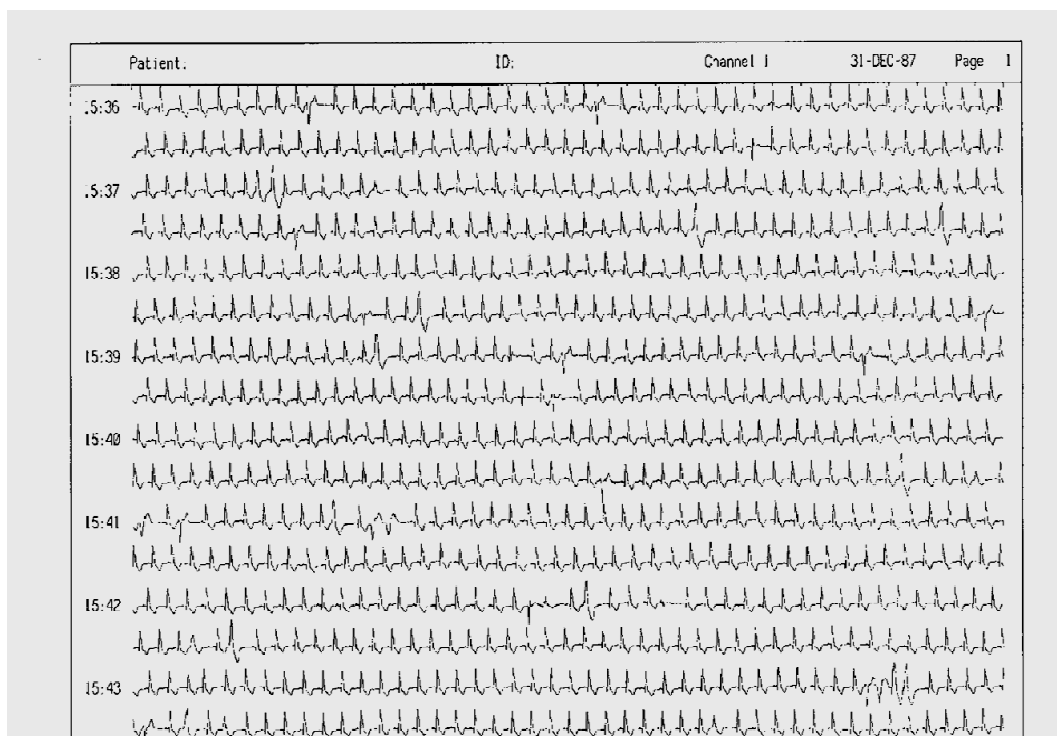
Normal tracing (plasma K^+ 4–5.5 meq/L).



Hyperkalemia (plasma K^+ \pm 7.0 meq/L).

Diagnostické využití EKG

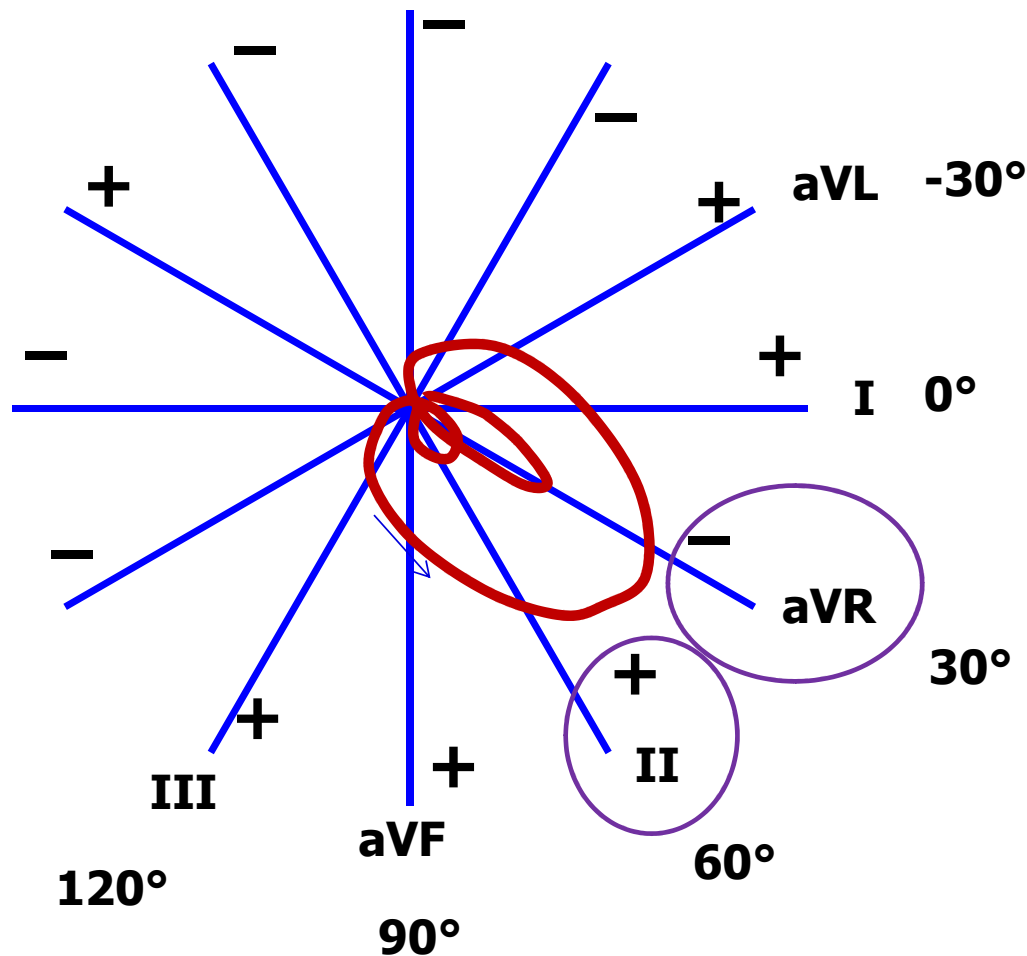
24-hodinové monitorování EKG (Holter)



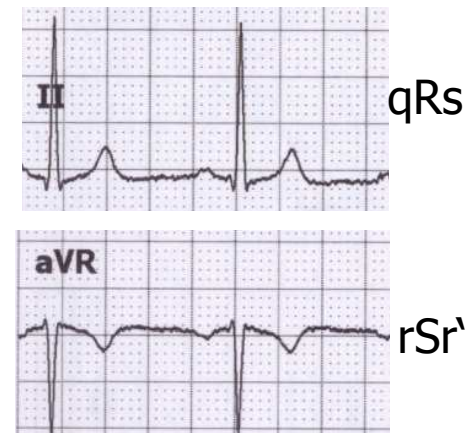
**MUNI
MED**

Dodatek k EKG

Svod II a aVR

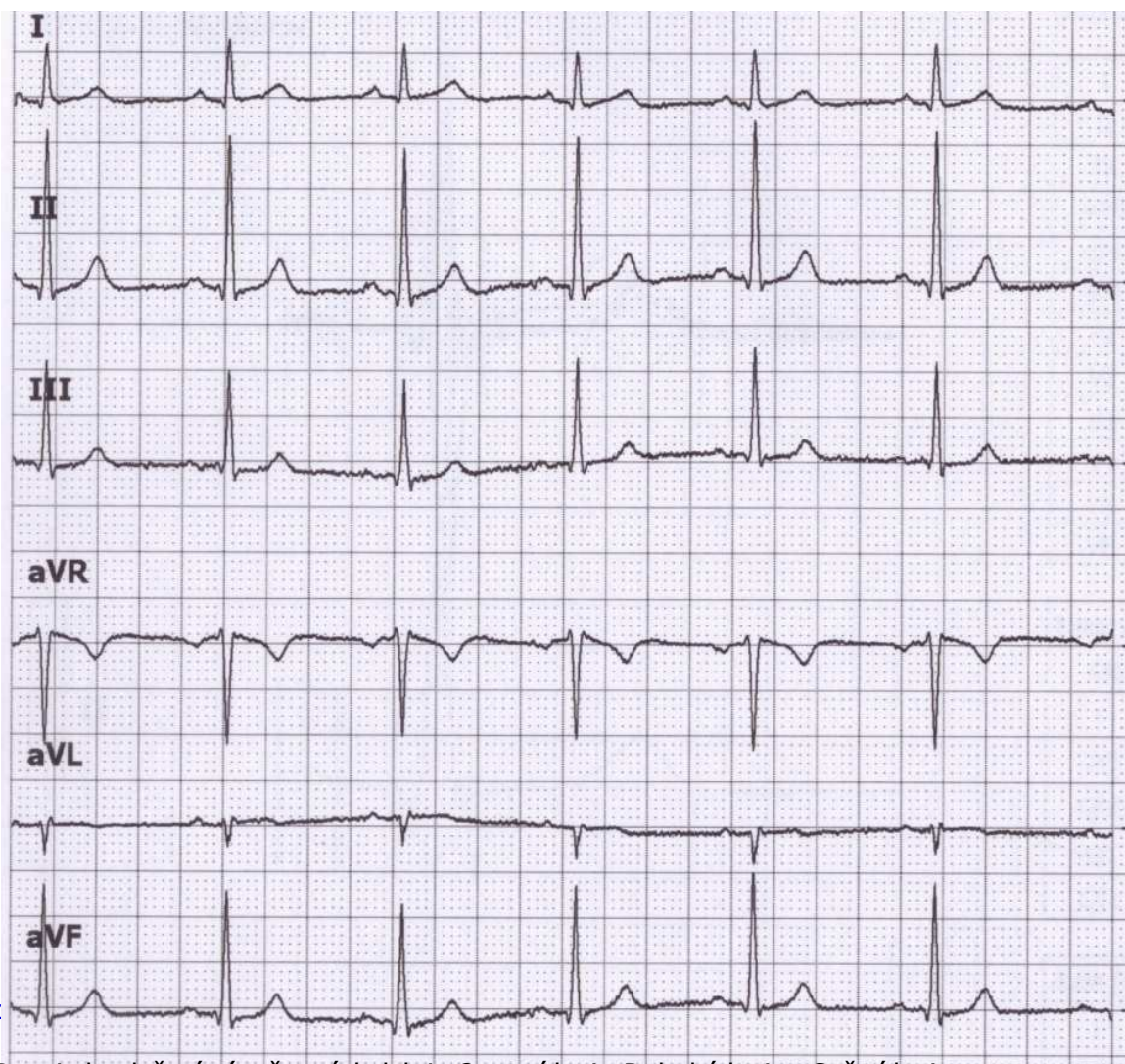


Všimněte si vzhledu EKG ve svodu II a aVR. Oba svody se dívají na elektrickou srdeční aktivitu z podobného úhlu (odchylna jen 30°), ale aVR má opačnou polaritu (dívá se na srdce vzhůru nohama v porovnání s II). Proto jsou svody II a aVR podobné, jen vůči sobě zrcadlově obrácené.



aVR má obvykle negativní T a P

QRS ve svodech a el. osa



výchylky QRS	součet výchylek QRS	Zápis QRS
Q = -1 R = 6 S = 0	QRS = 5	qR
Q = -1 R = 17 S = -1	QRS = 15	qRs
Q = 0 R = 10 S = -1	QRS = 9	qRs
Q = 1 R = -11 S = 0	QRS = -10	rSr'
Q = 0 R = -3 S = 0	QRS = -3	qR'
Q = -1 R = 13 S = -1	QRS = 11	qRs

výchytky součet QRS
QRS

I
Q = -1
R = 6 QRS = 5
S = 0

II
Q = -1
R = 17 QRS = 15
S = -1

III
Q = 0
R = 10 QRS = 9
S = -1

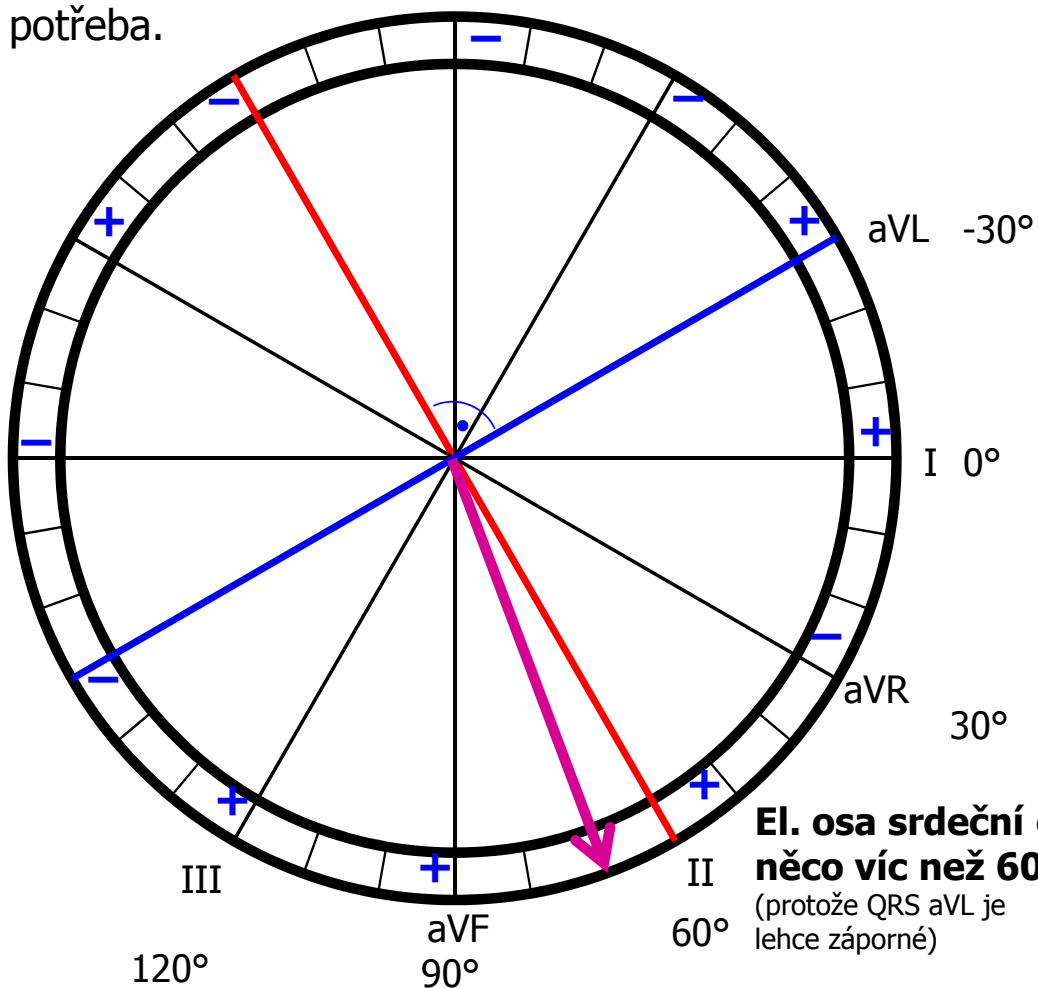
aVR
Q = 1
R = -11 QRS = -10
S = 0

aVL
Q = 0
R = -3 QRS = -3
S = 0

aVF
Q = -1
R = 13 QRS = 11
S = -1

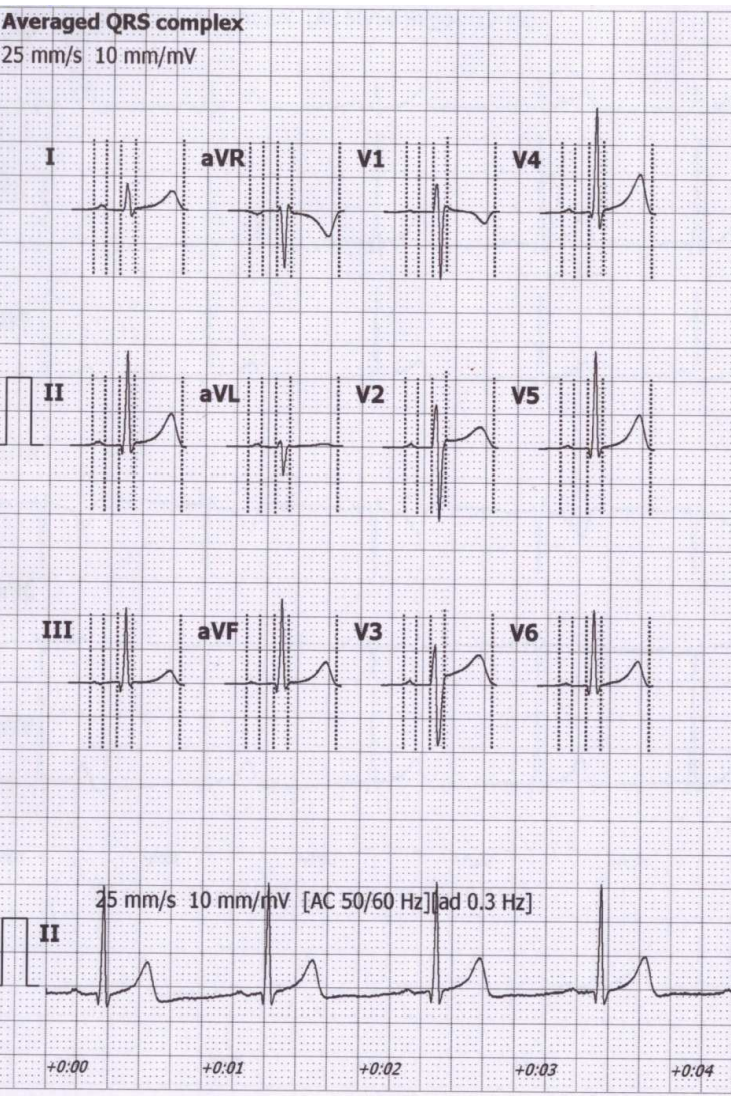
Elektrická osa jinak

Najděte svod s největším a nejmenším součtem výchytek (jen tak od oka) – tyto svody budou na sebe kolmé. Úhel svodu s největším součtem QRS bude určovat přibližně el. osu srdeční. Nebude to dokonale přesné, ale to v praxi ani není potřeba.



El. osa srdeční o něco víc než 60°
(protože QRS aVL je lehce záporné)

Určení elektrické osy srdeční – jak to dopadlo podle počítače?



Amplitudes [mV]											
	P+	P-	Q	R	S	R'	S'	J	ST40	T+	T-
I	0.06	-	-	0.40	-0.09	-	-	0.03	0.03	0.28	-
II	0.05	-	-0.14	1.40	-0.12	-	-	0.03	0.05	0.48	-
III	0.02	-0.03	-0.16	1.10	-0.07	-	-	0.01	0.02	0.21	-
aVR	-	-0.05	-	0.07	-0.85	0.09	-	-0.03	-0.04	-	-0.37
aVL	0.04	-	-	0.11	-0.40	0.05	-	0.01	0	0.04	-
aVF	0.03	-	-0.15	1.25	-0.09	-	-	0.02	0.03	0.34	-
V1	0.02	-0.02	-	0.41	-1.02	0.09	-	0.08	0.03	-	-0.18
V2	0.05	-	-	0.63	-1.10	-	-	0.11	0.11	0.30	-
V3	0.06	-	-	0.59	-0.92	-	-	0.09	0.15	0.42	-
V4	0.05	-	-0.09	1.55	-0.26	-	-	0.04	0.07	0.58	-
V5	0.04	-	-0.16	1.43	-0.14	-	-	0.02	0.05	0.51	-
V6	0.04	-	-0.15	1.12	-0.13	-	-	0.01	0.04	0.37	-

Intervals [ms]	
RR	1031
P	81
PQ	173
QRS	93
QT	401
QTc	395

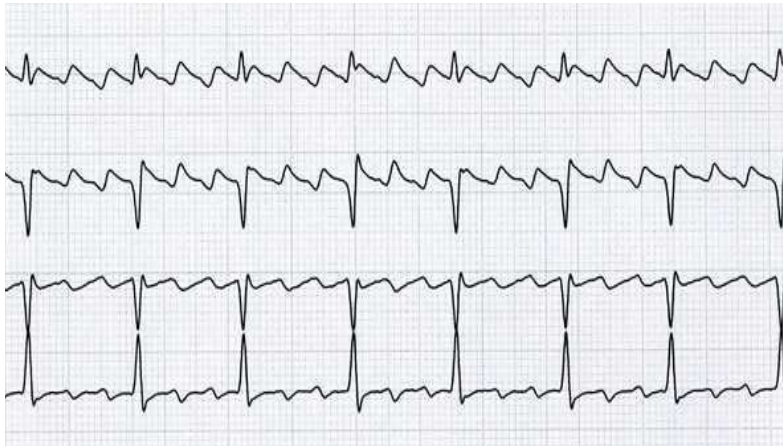
Interpretation must be authorized by physician

Automatic marker setting
Patient's age unknown
Bradycardia

Axis [°]	
P	15
QRS	72
T	49

el. osa pro depolarizaci síní
72° el. osa pro depolarizaci komor
 el. osa pro repolarizaci komor

Flutter síní

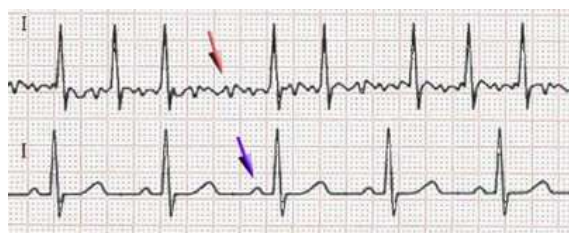


- Pravidelné pilovité zuby mezi QRS. Pravidelné RR, tachykardie.
- Podkladem je krouživý vzruch (re-entry) v síních.
- Pravidelnost je dána počtem „otoček“ vzruchu na převedení na komory (na obrázku: 3 otočky na 1 převedení na komory).
- Pokud flutter nevymizí, mění se ve fibrilaci síní.

Fibrilace

Fibrilace: nesynchronizovaná aktivita kardiomyocytů

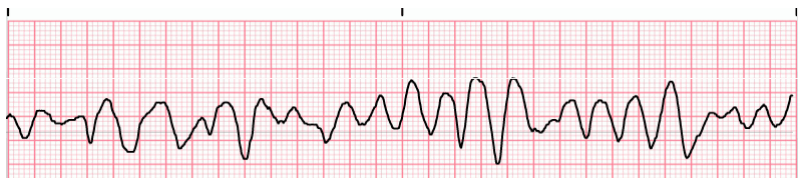
Síňová – chybí P, slabě nepravidelně „zubatá“ izolínie, RR nepravidelné, frekvence 80 – 180 bpm, není život ohrožující, ale vyčerpává srdce



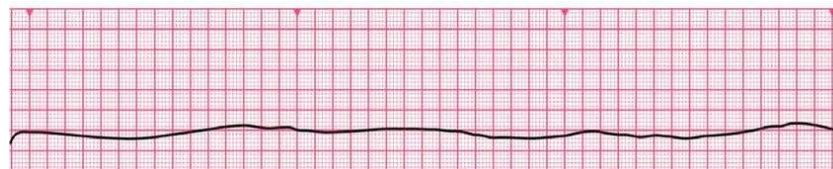
fibrilace

normal

Komorová – srdce nefunguje jako pumpa, nulový srdeční výdej, poškození mozku po 3 – 5 minutách fibrilace, bez včasné defibrilace se kardiomyocyty vyčerpají a přechází v asystolii

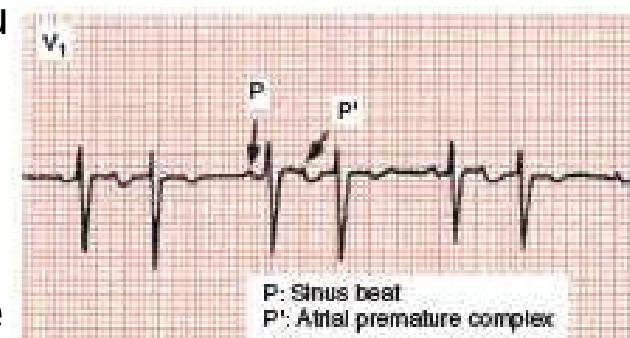
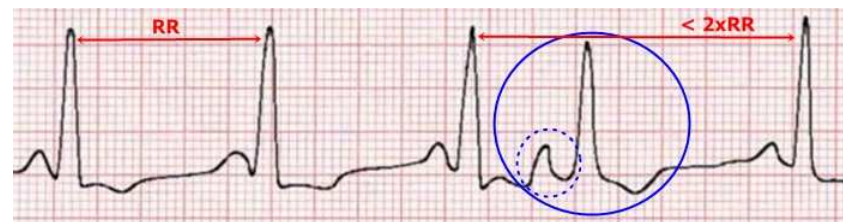


Asystolie – není přítomná elektrická aktivita, nedá se řešit defibrilací

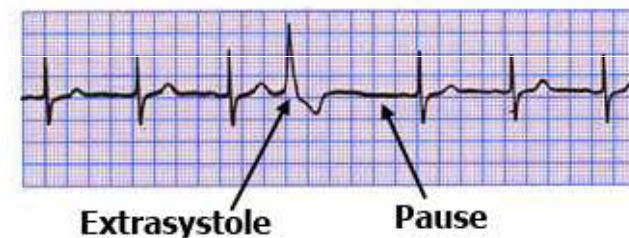

Extrasystoly

- Supraventrikulární – ektopický vzruch vzniká v síni nebo v převodním systému AV
 - QRS komplex extrasystoly má normální tvar (vzruch se komorou šíří normálně),
 - vlna P nemá normální tvar (může být záporná či zakrytá QRS),
 - může být s postextrasystolickou pauzou (pokud se vzruch šíří zpětně síněmi a vybije SA)
- Ventrikulární – ektopický vzruch vzniká v komoře
 - QRS komplex nemá normální tvar („obluda“)
 - při pomalé srdeční frekvenci je bez kompenzační pauzy (extrasystola je vmezeřená mezi normální QRS) o sinusovém rytmu,
 - nebo obsahuje kompenzační pauzu, pokud další vzruch pocházející z SA uzlu přijde v čase, kdy je komora ještě refrakterní



Ventricular Extrasystole



Ischemie srdce

elevace ST
(Pardeho vlna)

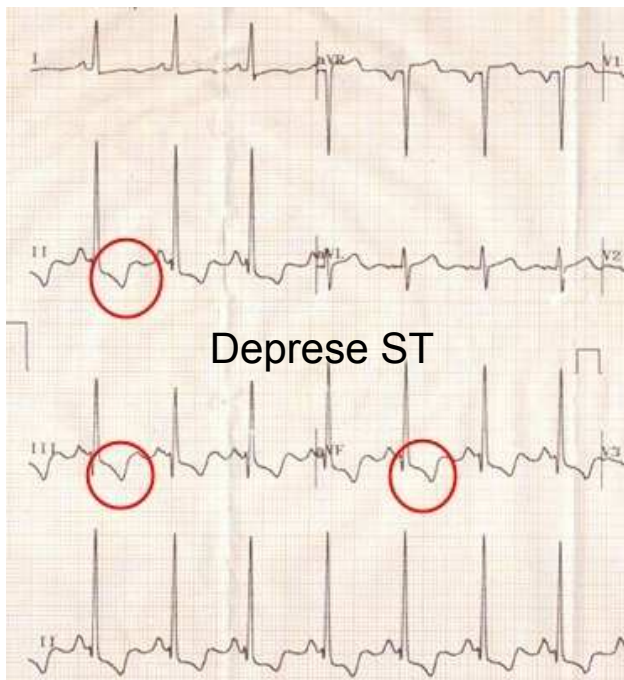
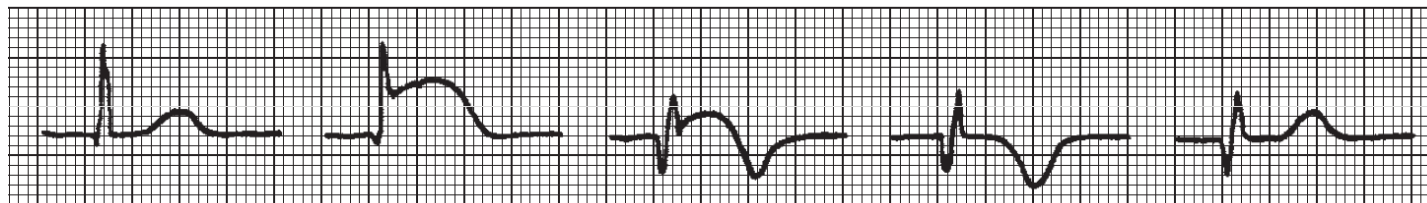
A

B

C

D

E



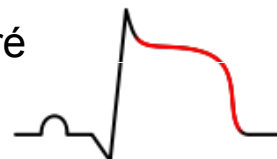
Transmurální infarkt

Patologické Q

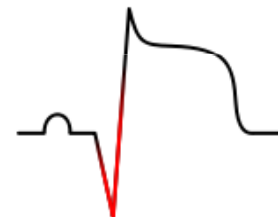
Negativní T (obrácený směr repolarizace)



Elevace ST – některé části tkáně se depolarizují se zpožděním



Patologické Q





11 Rhythms Nurses Need to Know

Basic EKG/ECG Rhythms

Common & Formal Rhythm Names	6 Second Rhythm Strip	Identifiers
S H O C K A B L E	V-Fib Ventricular Fibrillation	 NO PULSE Rate: Unmeasurable Irregular, No P Wave, No QRS
	V-Tach Ventricular Tachycardia	 NO PULSE Wide QRS Rate: Fast (100-250 bpm) Regular, No P Wave, Wide QRS
	Torsade de Pointes Type Of Ventricular Tachycardia	 NO PULSE Rate: Very Fast (200-250 bpm) Tall and Short Waves Irregular, No P Wave, Wide QRS
*Synchronized Cardioversion possible for SVT if medication ineffective.		
SVT* Supraventricular Tachycardia	 Rate: Very Fast (150-250 bpm) Regular, P Wave Hidden, Normal QRS	
STEMI ST Elevation Myocardial Infarction	 ST Elevation Reg or Irreg, P Wave, ST Elevated	
A-Fib Atrial Fibrillation	 ↑ Erratic Waves ↑ * QRS normally narrow but not always Irregular, No P Wave, Normal QRS*	
A-Flutter Atrial Flutter	 ↑ "Sawtooth" Pattern ↑ Reg or Irreg, No P Wave, Normal QRS	
PVC Premature Ventricular Contraction	 PVC PVC ← No P Waves → Irregular, No P Wave, Wide QRS	
Sinus Brady Sinus Bradycardia	 Rate: Slow (<60 bpm) Regular, P Wave, Normal QRS	
Sinus Tach Sinus Tachycardia	 Rate: Fast (> 100 bpm) Regular, P Wave, Normal QRS	
NSR Normal Sinus Rhythm	 Rate: Normal (60-100 bpm) Regular, P Wave, Normal QRS	