

**CARDIAC RESERVE
and
HEART FAILURE**

CARDIAC RESERVE = maximal CO / resting CO

4 - 7

CORONARY RESERVE = maximal CF / resting CF

3,5

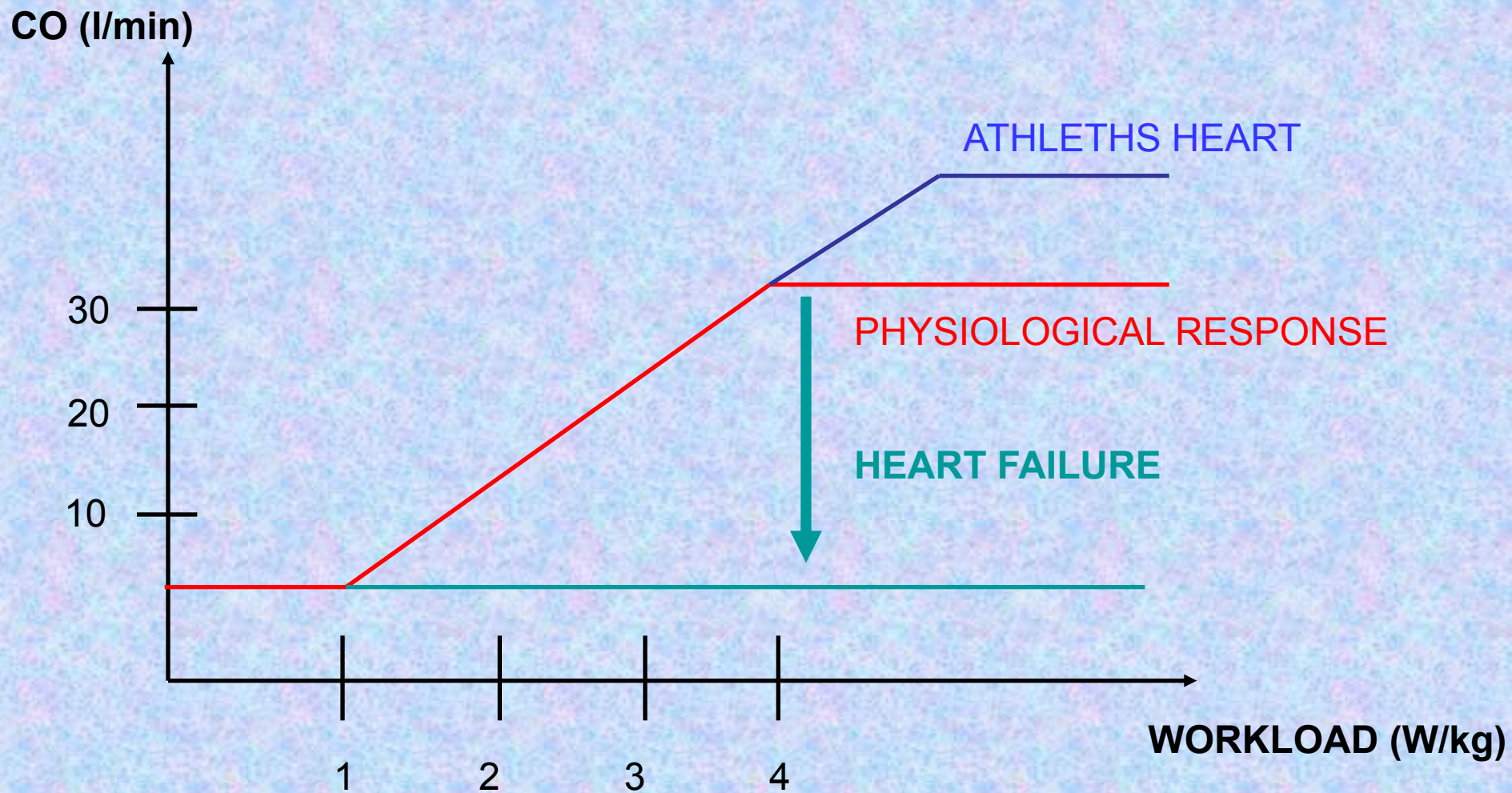
CHRONOTROPIC RESERVE = maximal HF / resting HF

3 - 5

VOLUME RESERVE = maximal SV / resting SV

1,5

CARDIAC RESERVE



HEART FAILURE

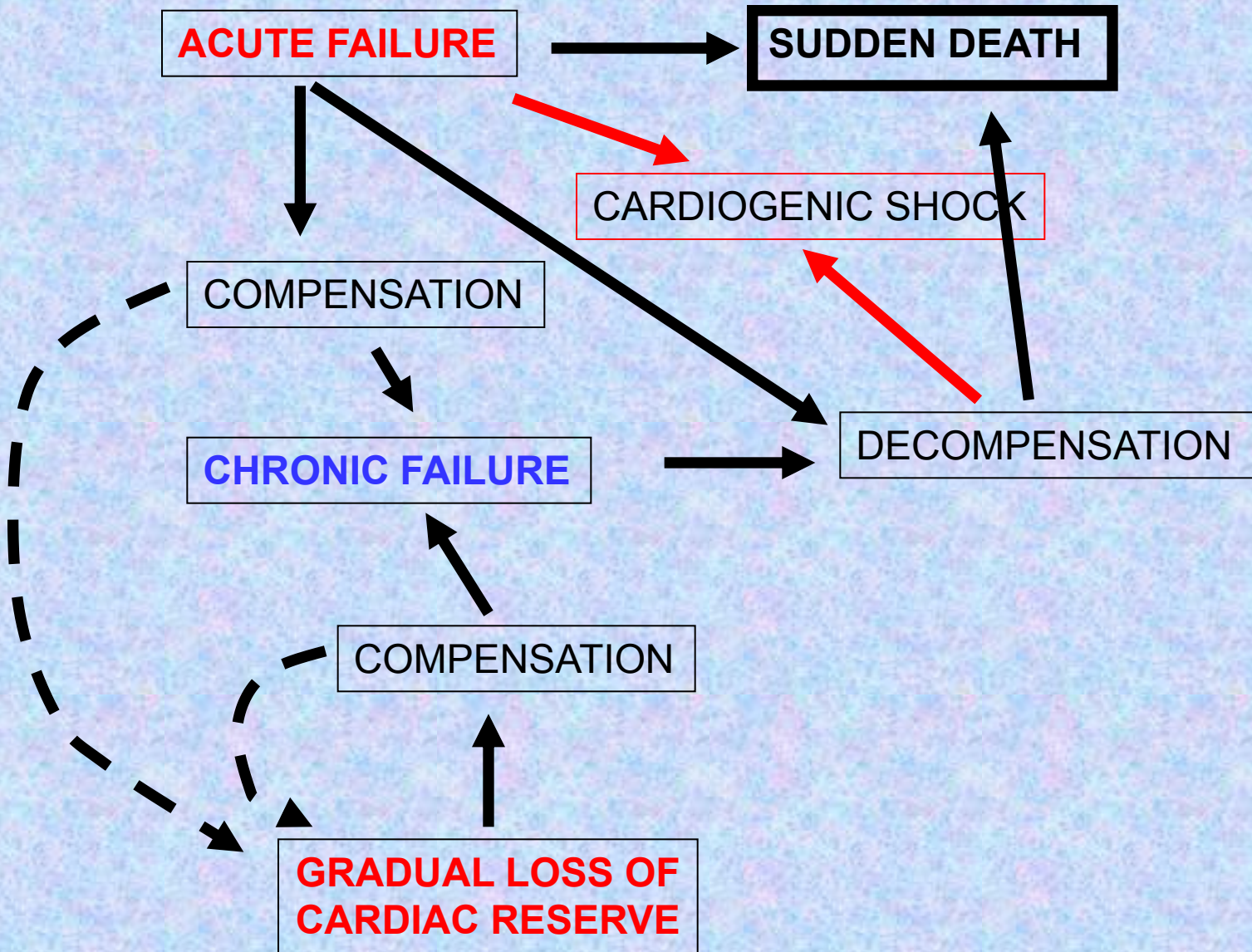
The heart is not able pump sufficient amount of blood into periphery at normal venous return.

MOST OFTEN CAUSES:

- Severe arrhythmias
- Overload – *volume* (aortal insufficiency, a-v shunts) or *pressure* (hypertension and aortal stenosis – left overload, pulmonary hypertension and stenosis of pulmonary valve – right overload)
- Cardiomyopathy

SYMPTOMS: fatigue, oedemas, venostasis, dyspnoea, cyanosis

ACUTE x CHRONIC. COMPENSATED x DECOMPENSATED.



HEART FAILURE CAUSES

MECHANICAL

- Pressure overload (valvular stenosis, hypertension)
- Volume overload (valvular insufficiency, water retention)
- Aneurysma
- Dyssynergy
- Endo-myocardial restriction

MYOCARDIAL

- Cardiomyopathy
- Myocarditis
- Metabolic disorders
- Loss of myocardial mass

DYSHRYTHMIAS

- Tachyarhythmias
- Bradyarhythmias
- Fibrillation
- Blocks

CIRCULATORY FAILURE

- The main function of circulation is keep a good organ and tissue perfusion

$$BP = CO \times TPR$$

Circulatory failure is a generalized inadequate blood flow in the body that causes tissue damage due to reduced blood flow - reduced transport of oxygen (and other nutritional factors). The cardiovascular system itself (cardiac muscle, vascular walls, vasomotor system, and other parts of circulation) worsens when coming „circulatory shock“

CIRCULATORY FAILURE

$$BP = CO \times TPR$$

CO decrease:

✓ lower volume in circulation – lower venous return

decrease of filling pressure and by Frank-Starling principle decrease of CO

Clinical: e.g. hemorrhagic shock, hypovolemic shock

Therapy: infusion (e.g. of physiological solution)

CIRCULATORY FAILURE

$$BP = CO \times TPR$$

CO decrease:

- ✓ vasodilatation of venous system - sudden periphery vasodilatation – e.g. sudden loss of vasomotor tone : **vasomotor syncope** (neurogenic shock-brain damage, deep anesthesia)
- ✓ emotional activation of parasympathetic signals to slow the heart and also activation of inverse sympathetic signals to dilate the peripheral vasculature : **vasovagal syncope** (emotional disturbance-fainting in young people)

CIRCULATORY FAILURE

$$BP = CO \times TPR$$

CO decrease:

✓ **lower pumping function of the heart**

e.g. myocardial infarction, severe dysfunction of the heart valves, cardiac arrhythmias

Result: cardiogenic shock

= circulatory shock, which results from the weakened ability of the heart as a pump;
(85% of people who develop a cardiogenic shock will not survive)

CIRCULATORY FAILURE

$$\text{BP} = \text{CO} \times \text{TPR}$$

Circulatory shock without the change of CO

Abnormal increase in metabolic demands of the organism
(so great that physiological CO is insufficient)

Abnormal tissue perfusion – e.g. septic shock (blood poisoning)

(inadequate supply of nutrients or inadequate production of waste substances from tissues)

CIRCULATORY FAILURE

$$BP = CO \times TPR$$

TPR decrease:

- ✓ **toxic vasodilatation (by histamin-allergy) – anaphylactic shock - sting by a bee**
- ✓ **Dysbalance of autonomy nervous system – sympathetic part – decrease of sympathetic tone of vessels** vegetative collapse - dysbalance of the autonomic nervous system (decrease in the influence of sympathetic to the vascular tone – everything is related to the situations described in vasodilation of the venous system)

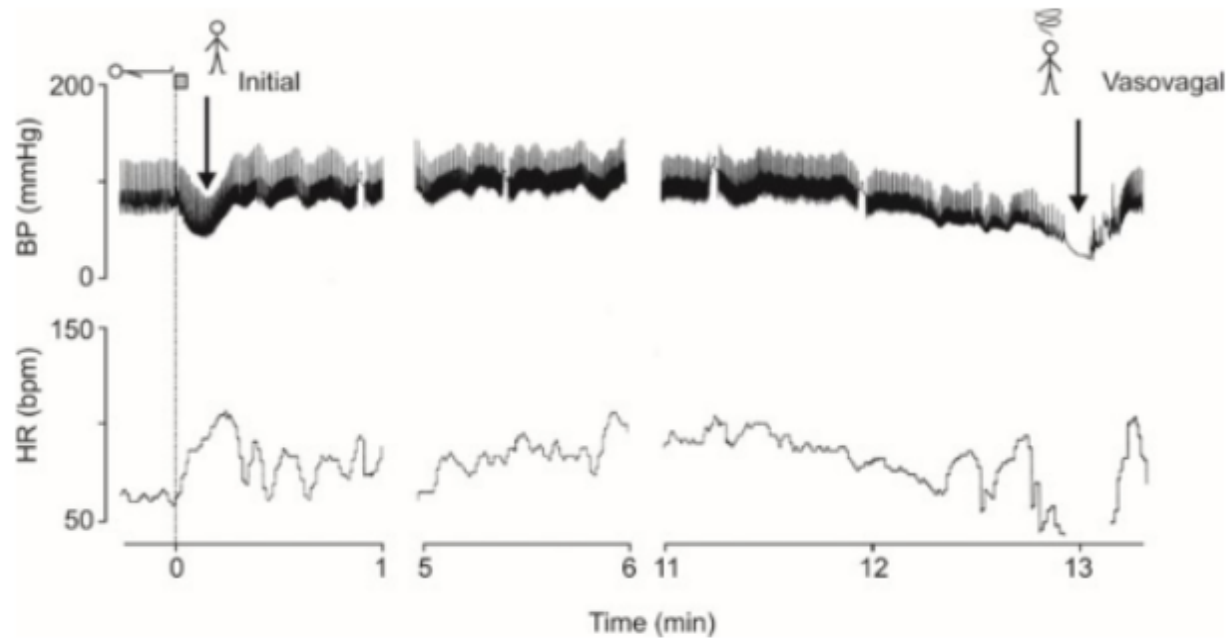
NYHA classification

Functional Capacity	Objective Assessment
Class I	Patients with cardiac disease but without resulting limitation of physical activity. Ordinary physical activity does not cause undue fatigue, palpitations, dyspnea, or anginal pain.
Class II	Patients with cardiac disease resulting in slight limitation of physical activity. They are comfortable at rest. Ordinary physical activity results in fatigue, palpitation, dyspnea, or anginal pain.
Class III	Patients with cardiac disease resulting in marked limitation of physical activity. They are comfortable at rest. Less than ordinary activity causes fatigue, palpitation, dyspnea, or anginal pain.
Class IV	Patients with cardiac disease resulting in inability to carry on any physical activity without discomfort. Symptoms of heart failure or the anginal syndrome may be present even at rest. If any physical activity is undertaken, discomfort is increased.

Source: Adapted from New York Heart Association, Inc., *Diseases of the Heart and Blood Vessels: Nomenclature and Criteria for Diagnosis*, 6th ed. Boston, Little Brown, 1964, p. 114.

- **SYNCOPE** - a manifestation of brain ischemia that arises with a sudden drop in blood pressure due to failure in circulation
 - if the lying - consciousness returns quickly - within one minute
- Syncope is defined as a transient loss of consciousness due to cerebral hypoperfusion, characterized by a rapid onset, short duration, and spontaneous complete recovery

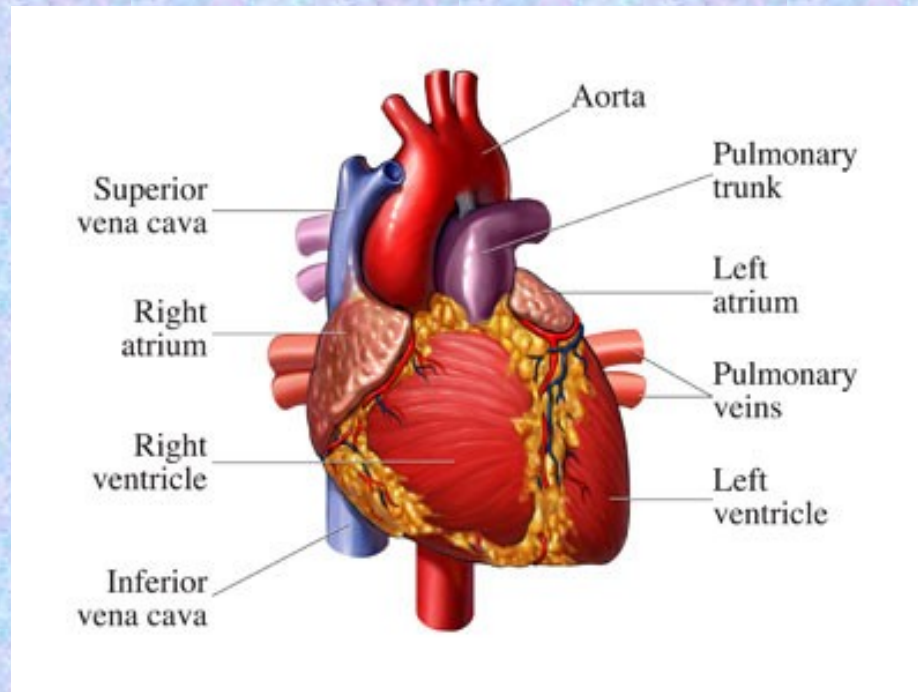
- If the pressure drops for several hours, they are metabolic changes in the ischemic organs and developing „a shock“
- **SHOCK** = is acute circulatory insufficiency syndrome with manifestations of tissue ischemia in a different areas of the body



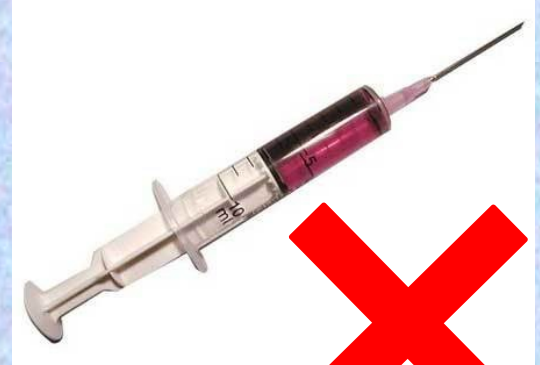This figure shows the usefulness of a continuous tracing of finger arterial pressure (BP) and heart rate (HR) during cardiovascular reflex testing in a patient with vasovagal syncope. Drugs administration test with the [Finapres® Guided Autonomic Testing](#) application

EXAMINATION TECHNIQUES

IN CARDIOLOGY

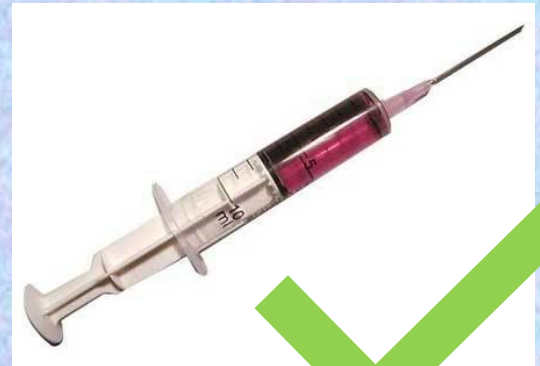

- **Non-invasive methods**



- **Invasive methods**

- (by puncture needle or catheter)



NON – INVASIVE METHODS

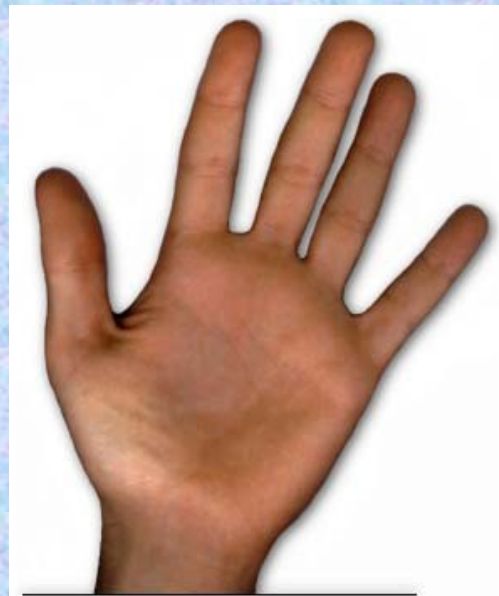
Basic – used together with examination of patients



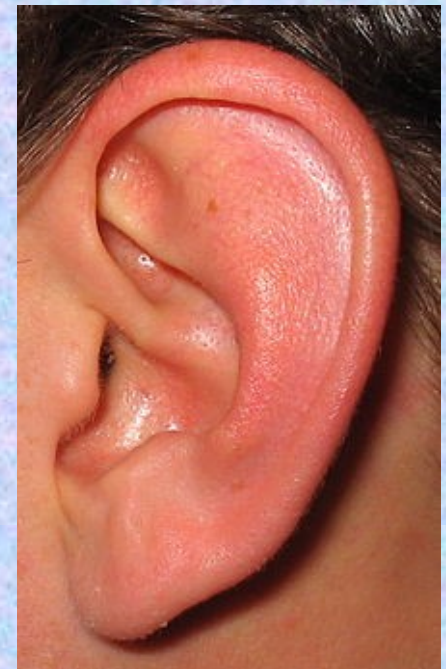Inspection



Percussion

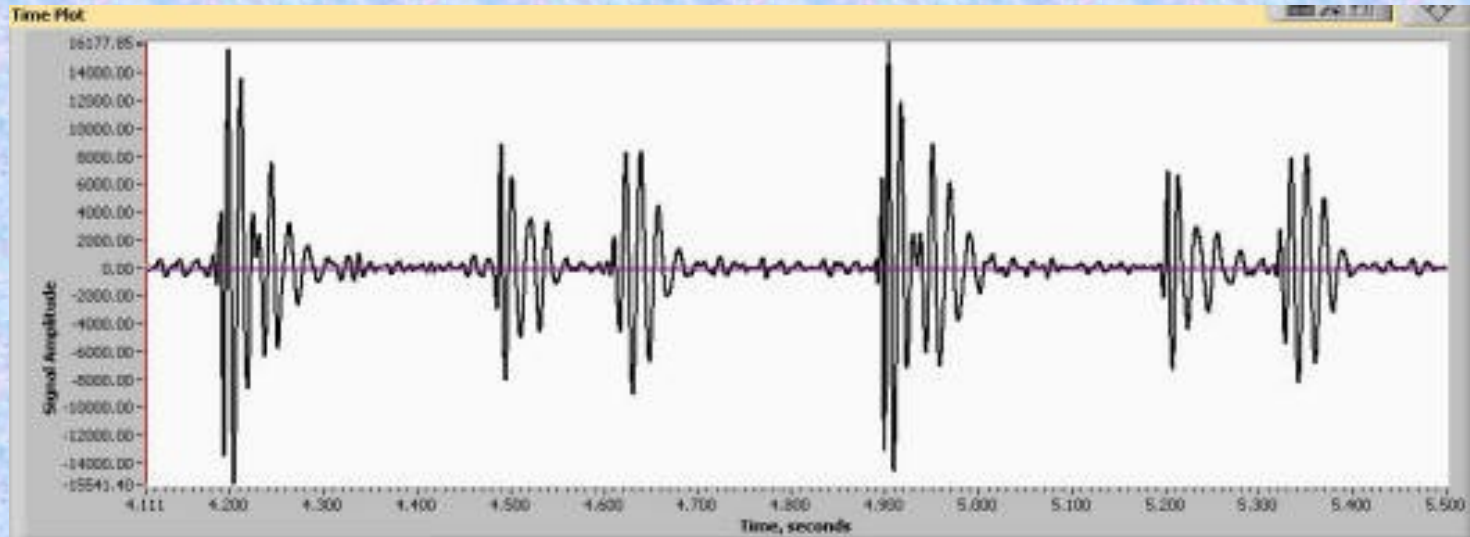


Palpation



Auscultation

- **PHONOCARDIOGRAPHY**



S1

S2

S3

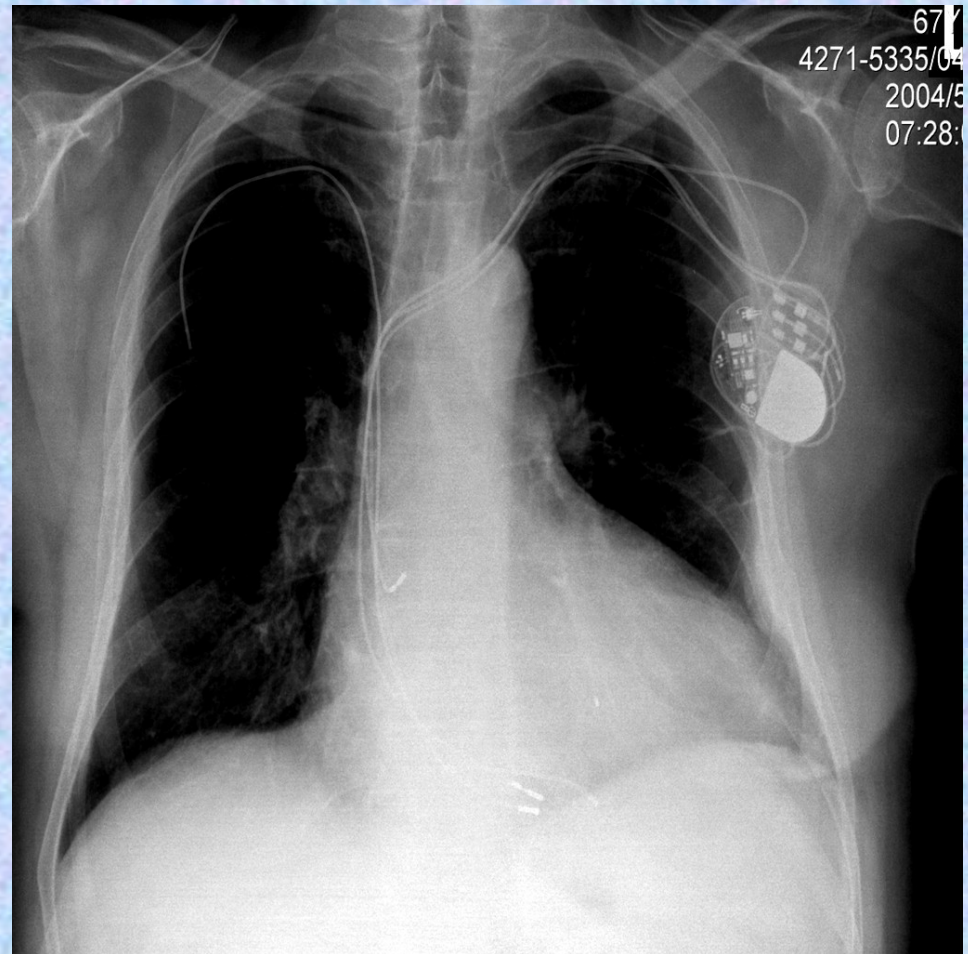
S1

S2

S3

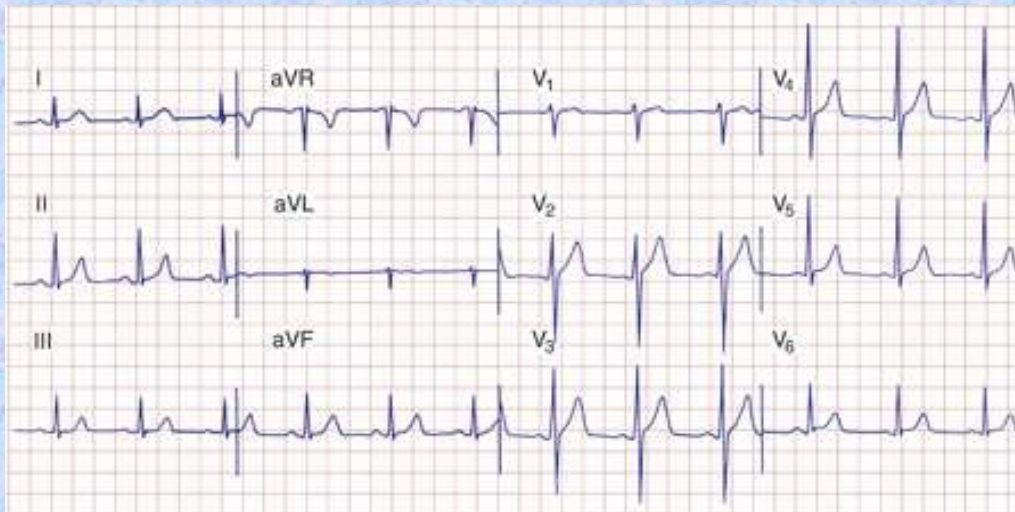
X-ray

Chest x-ray provides useful information about cardiac size and shape, as well as the state of the pulmonary vasculature, and may identify noncardiac causes of the patient's symptoms



ELECTROCARDIOGRAPHY

- A routine 12-lead ECG
- The major importance of the ECG is to assess cardiac rhythm and determine the presence of left ventricle hypertrophy or prior myocardial infarction or QRS width
- Normal ECG excludes left ventricle dysfunction

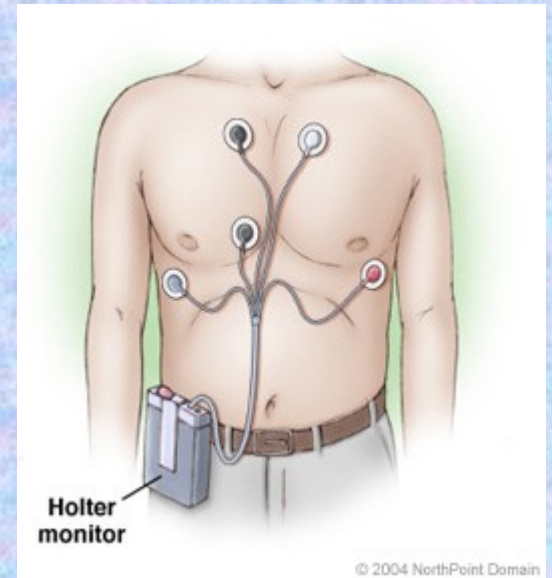


Source: Longo DL, Fauci AS, Kasper DL, Hauser SL, Jameson JL, Loscalzo J: *Harrison's Principles of Internal Medicine, 18th Edition*: www.accessmedicine.com

Copyright © The McGraw-Hill Companies, Inc. All rights reserved.

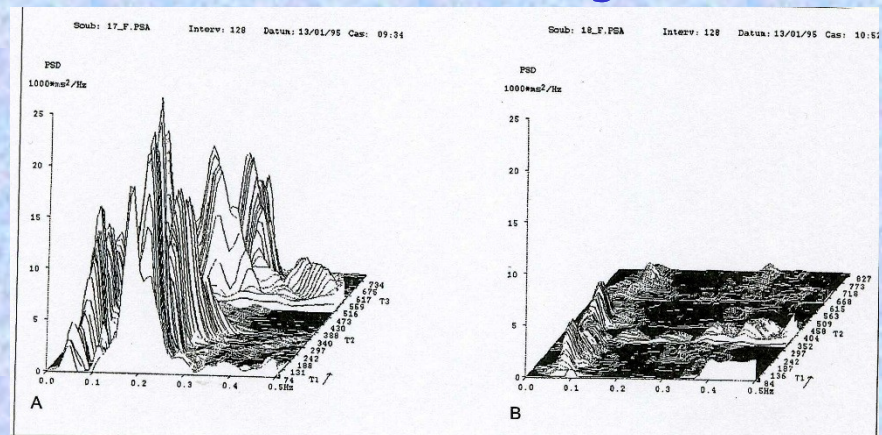
ELECTROCARDIOGRAPHY

- **HOLTER MONITORING**
- 24-hour ECG record



✓ *estimation of heart rate variability*

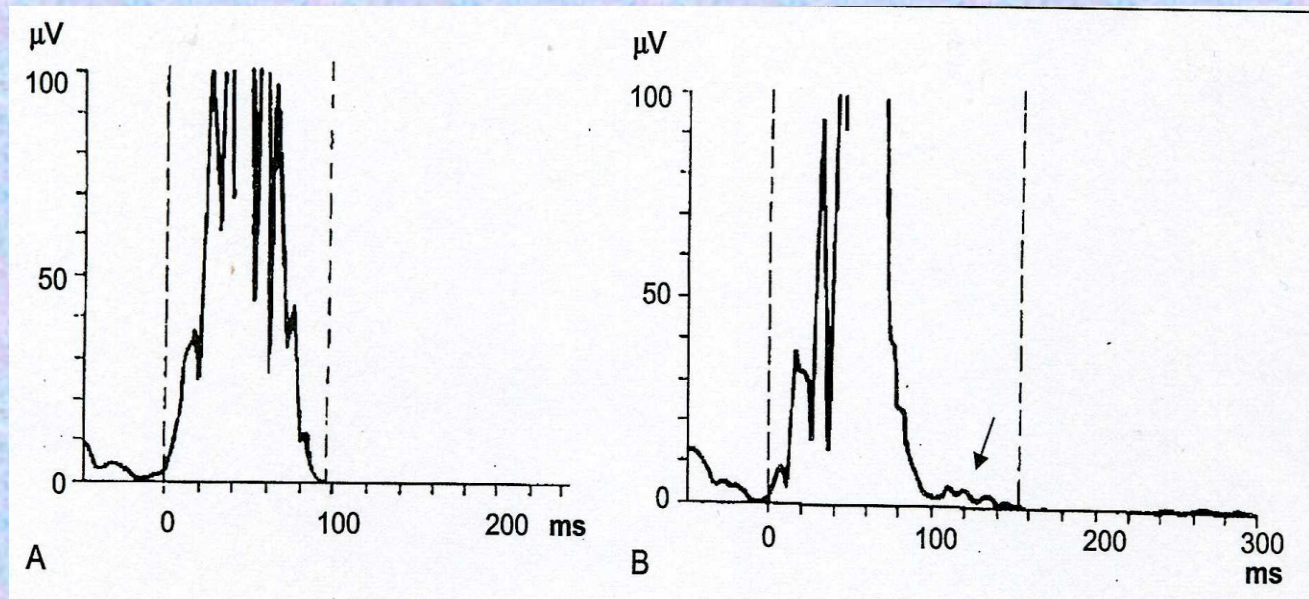
- time analysis
- spectral analysis



ELECTROCARDIOGRAPY

- **HOLTER MONITORING**

✓ *late potentials*



Reveal - implantable recorder

**Patient Activator and
Reveal® Plus ILR**



**Medtronic CareLink®
Programmer**



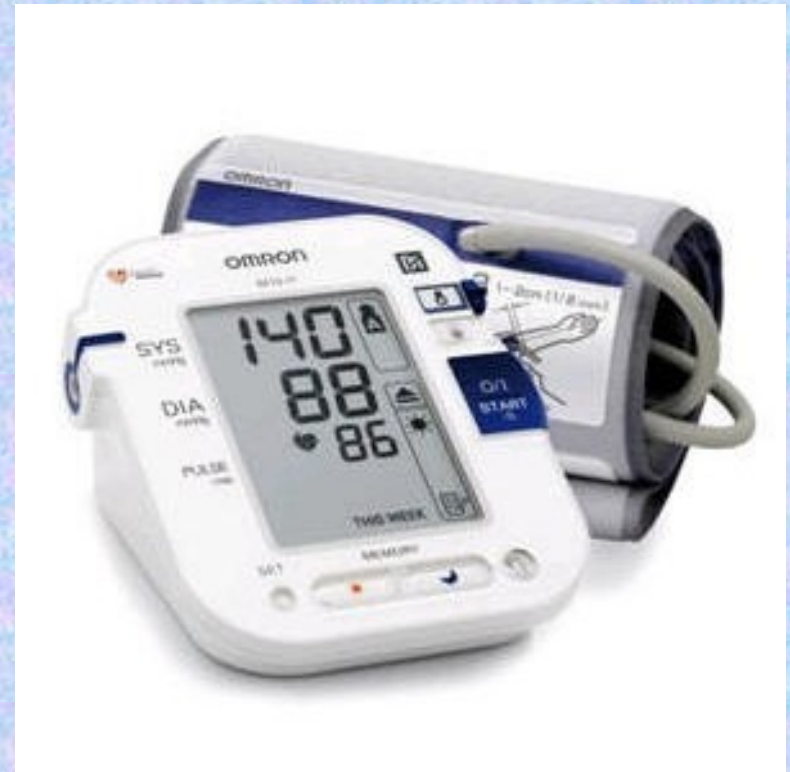- small device, without electrodes
- recorder of ECG during syncope
 - activation by patients
 - or autoactivation
- continuously monitoring 36 month, 42 min episodes at memory
- simple implantation, simple evaluation.

BLOOD PRESSURE MEASUREMENT



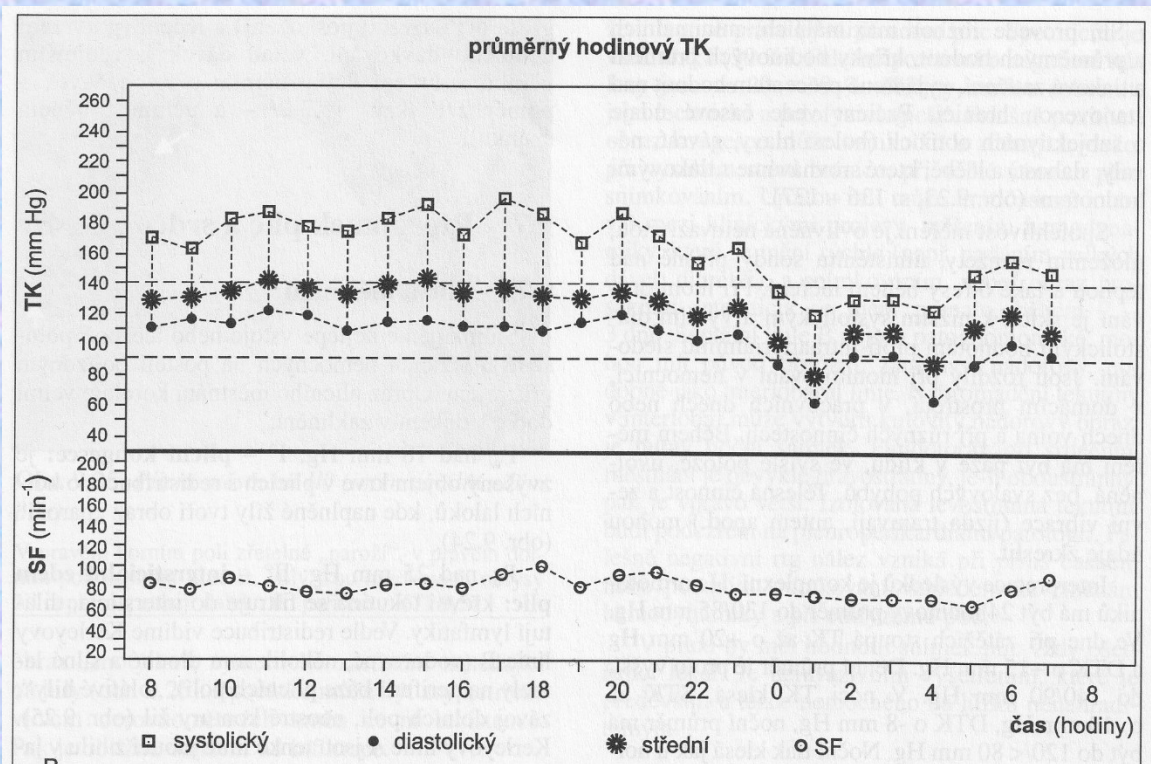
AUSCULTATORY METHOD

OSCILOMETRIC METHOD



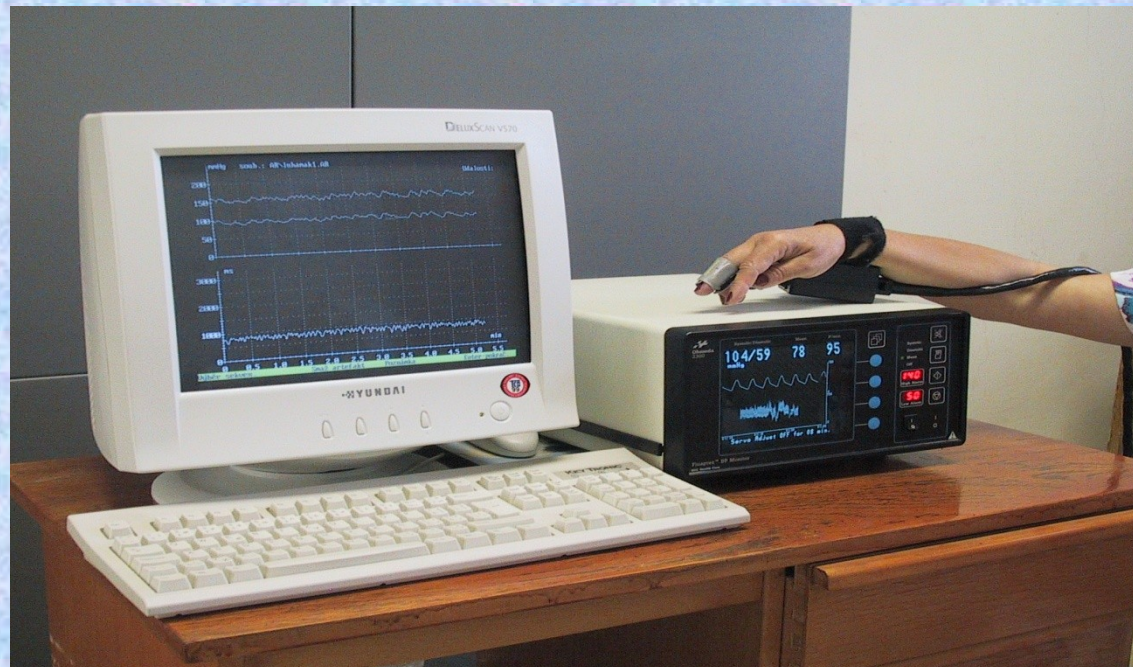
BLOOD PRESSURE MEASUREMENT

- **AMBULATORY BLOOD PRESSURE MONITORING - ABPM**



BLOOD PRESSURE MEASUREMENT

- continuously beat-to-beat measurement
- Peñáz principle - photoplethysmography

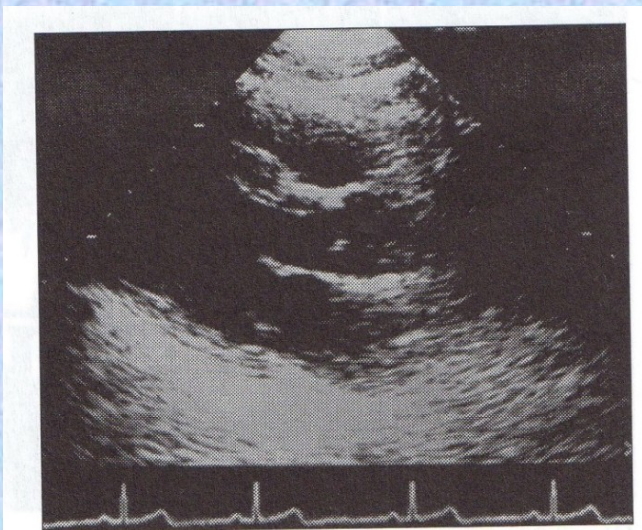
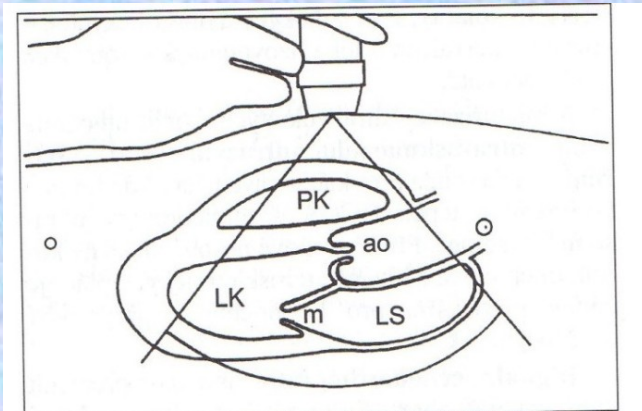


- We need than **pressure in the cuff corresponded to the pressure of the digital artery**
- **Method: photoplethysmography**
- Recorded photoelectric plethysmogram
- The new term: **Transmural pressure** – P_t (the pressure across the wall of the artery)
- BP, P_c (pressure in cuff), P_t
- We estimated: **$BP = P_c - - - P_t = 0 - - -$**
 photoplethysmogram registered the highest amplitude of oscillation --
 - we measure the **MAP**
- **Step by step** increase of P_c , in the moment of the highest amplitude – **feed-back loop** started for obtained(keeping) the constant volume of the finger

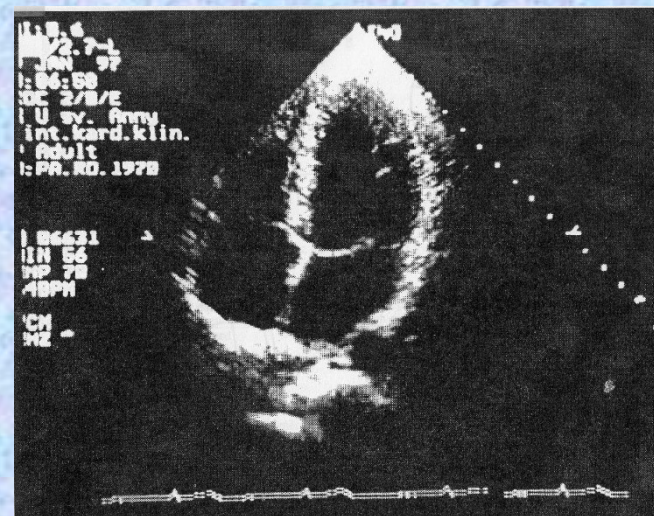
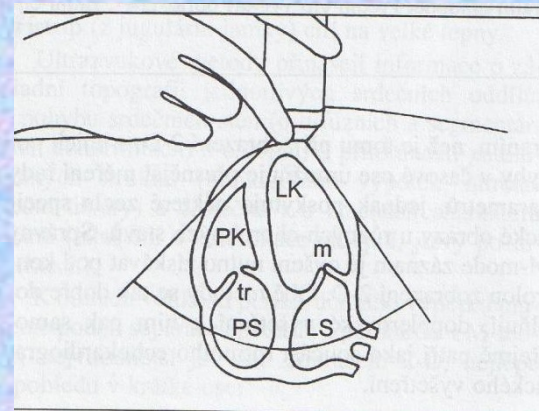
ECHOCARDIOGRAPHY

most widespread methods

PARASTERNAL LONG-AXIS VIEW

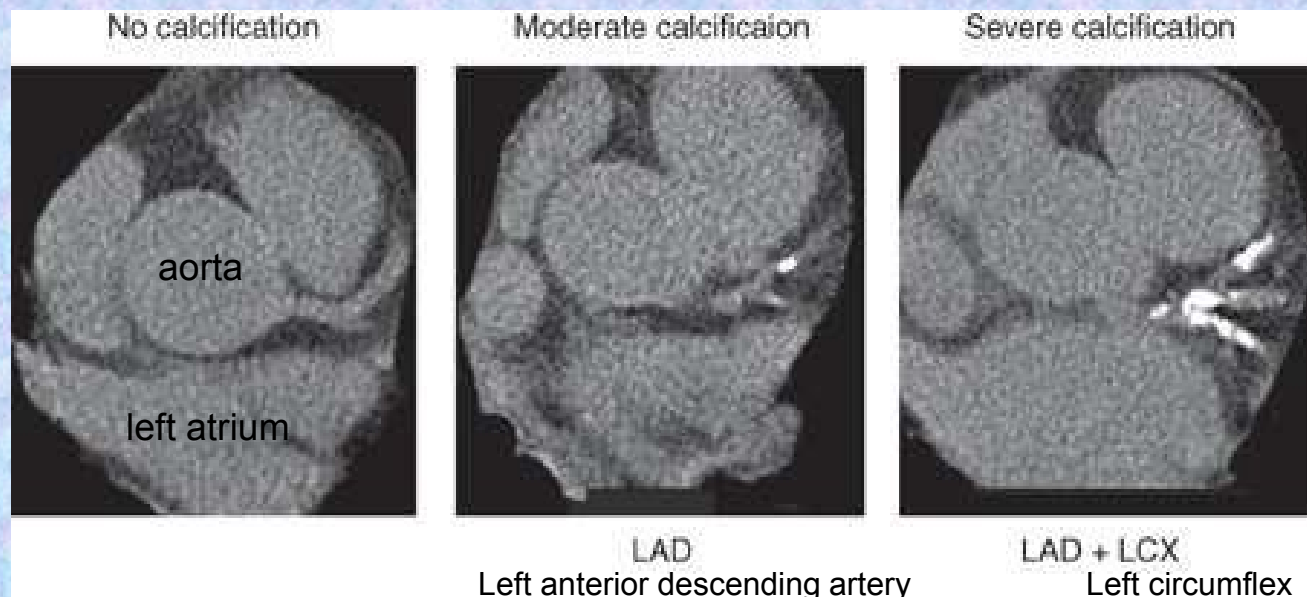


APICAL VIEW



COMPUTED TOMOGRAPHY

- CT is a fast, simple, noninvasive technique that provides images of the myocardium and great vessels;
- CT uses x-rays to create tomographic slices of objects-this is accomplished by rotating an x-ray beam around the object and measuring the transmission of x-rays through the object at many angles, called projections

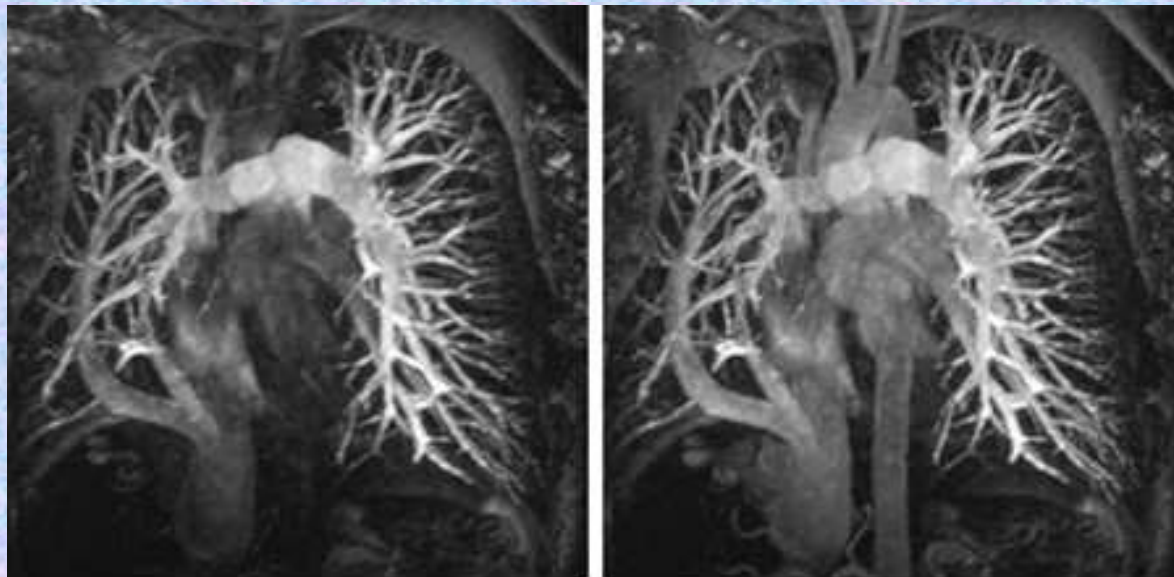


Source: Longo DL, Fauci AS, Kasper DL, Hauser SL, Jameson JL, Loscalzo J: *Harrison's Principles of Internal Medicine, 18th Edition*: www.accessmedicine.com

Copyright © The McGraw-Hill Companies, Inc. All rights reserved.

MAGNETIC RESONANCE IMAGING

- Based on the magnetic properties of hydrogen nuclei
- Used to quantify accurately EF, ESV, EDV, cardiac mass
- Without the need for ionizing radiation

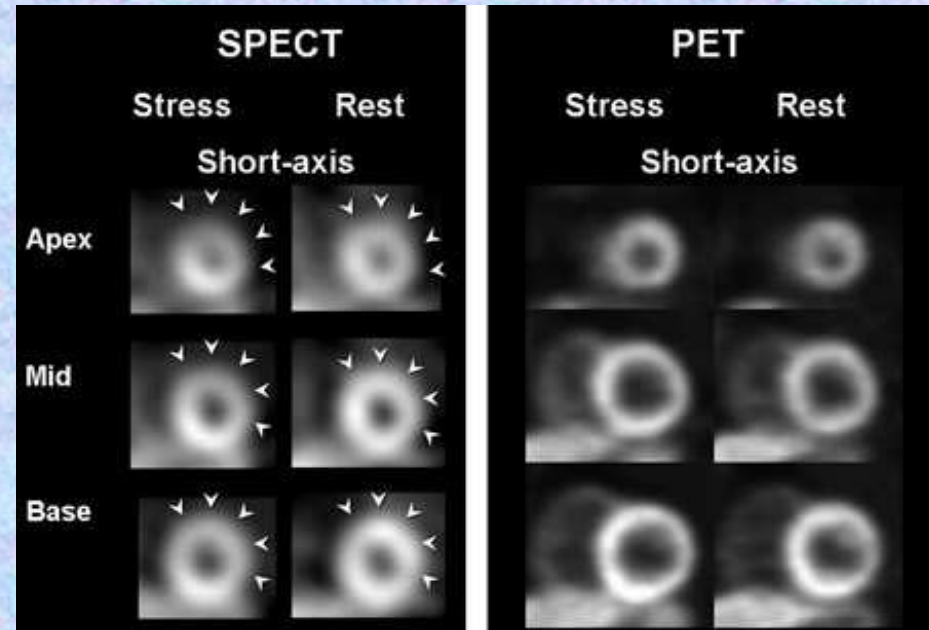


Source: Longo DL, Fauci AS, Kasper DL, Hauser SL, Jameson JL, Loscalzo J: *Harrison's Principles of Internal Medicine, 18th Edition*: www.accessmedicine.com

Copyright © The McGraw-Hill Companies, Inc. All rights reserved.

NUCLEAR CARDIOLOGY

- Nuclear (or radionuclid) imaging requires intravenous administration of isotopes
- Single photon emission computed tomography
SPECT and positron emission tomography
PET



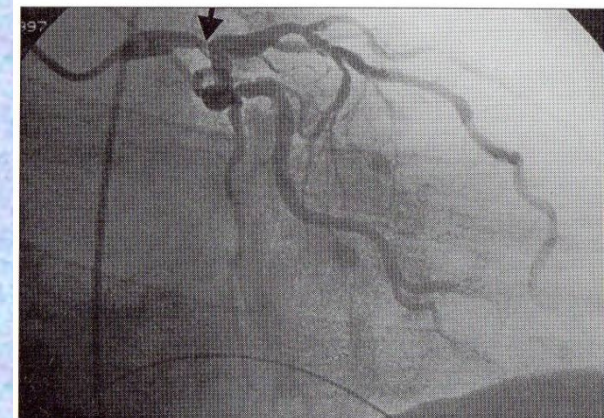
Source: Longo DL, Fauci AS, Kasper DL, Hauser SL, Jameson JL, Loscalzo J: *Harrison's Principles of Internal Medicine, 18th Edition*: www.accessmedicine.com
Copyright © The McGraw-Hill Companies, Inc. All rights reserved.

INVASIVE TECHNIQUES

- **CARDIAC CATHETERIZATION**
- ***Right heart catheterization*** – uses a balloon-tipped flotation catheter that is inserted into the **femoral or jugular vein**. Using fluoroscopic guidance, the catheter is advanced to the *right atrium - right ventricle – pulmonary artery* and *pulmonary wedge position* (as a surrogate for left atrial pressure = wedge pressure)

INVASIVE TECHNIQUE

- **CARDIAC CATHETERIZATION**
- ***Left heart catheterization*** – with the aid of fluoroscopy, the catheter is guided to ascending *aorta* – across the aortic valve into *left ventricle* (inserted into a.femoralis, a.axillaris, a.brachialis)
- A needle-tipped catheter to puncture the atrial septum during right heart catheterization
- **+ *coronary angiography***



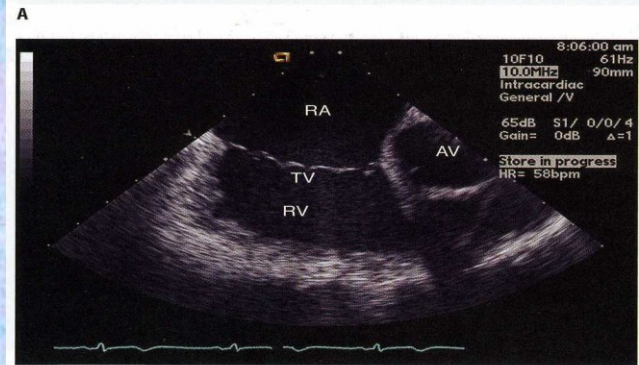
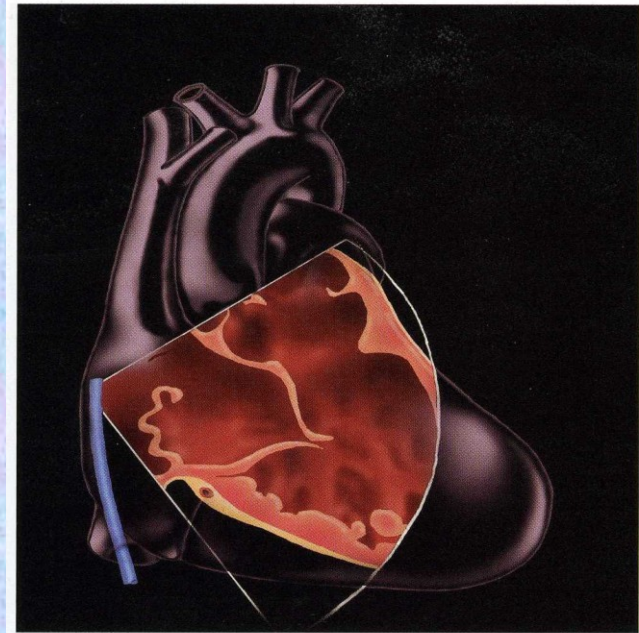
INVASIVE TECHNIQUE

- How do we use cardiac catheterization?
 - ✓ Pressure measurement
 - ✓ Blood flow measurement
 - ✓ Biopsy of tissue
 - ✓ Blood samples for oxygen-saturation analysis to screen for intracardiac shunts
 - ✓ Electric potentials measurement

Intracardiac Echocardiography

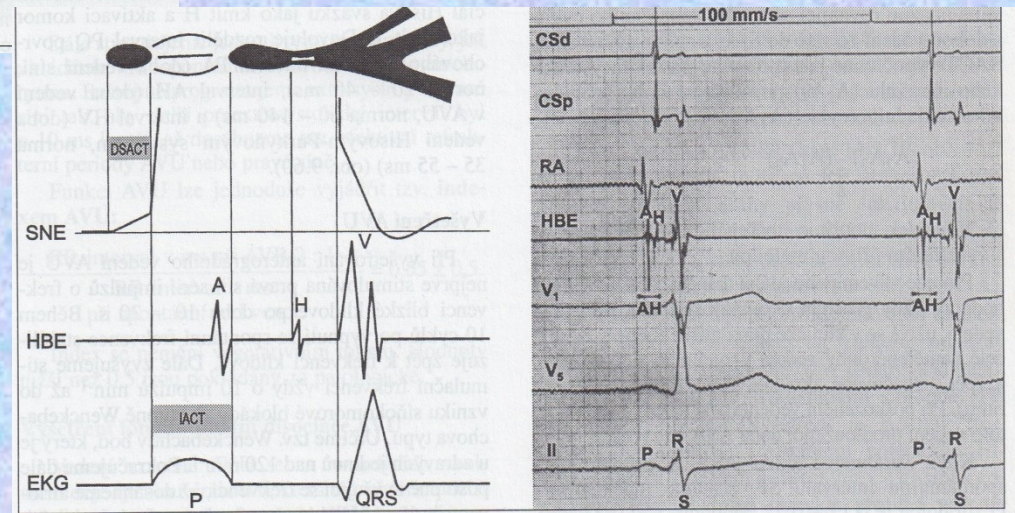
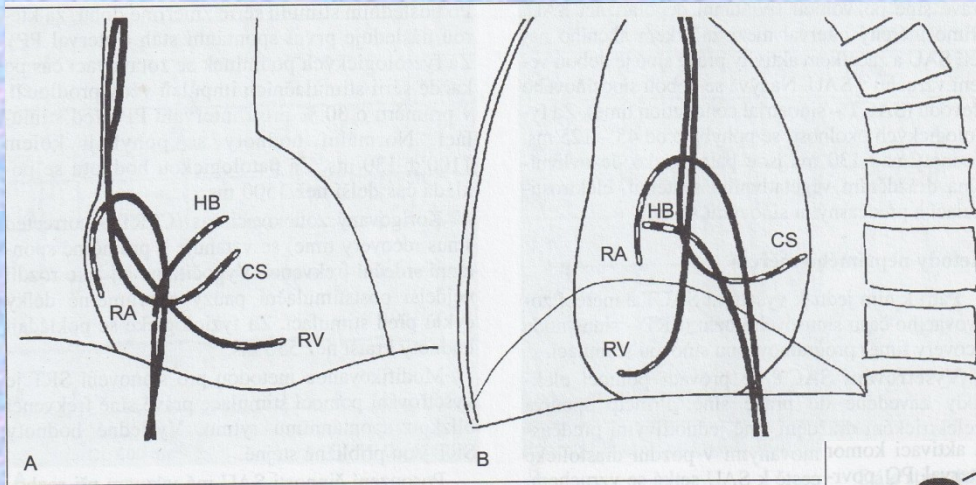
Is an intravascular ultrasound modality that provides diagnostic imaging of cardiac structures from within the heart.

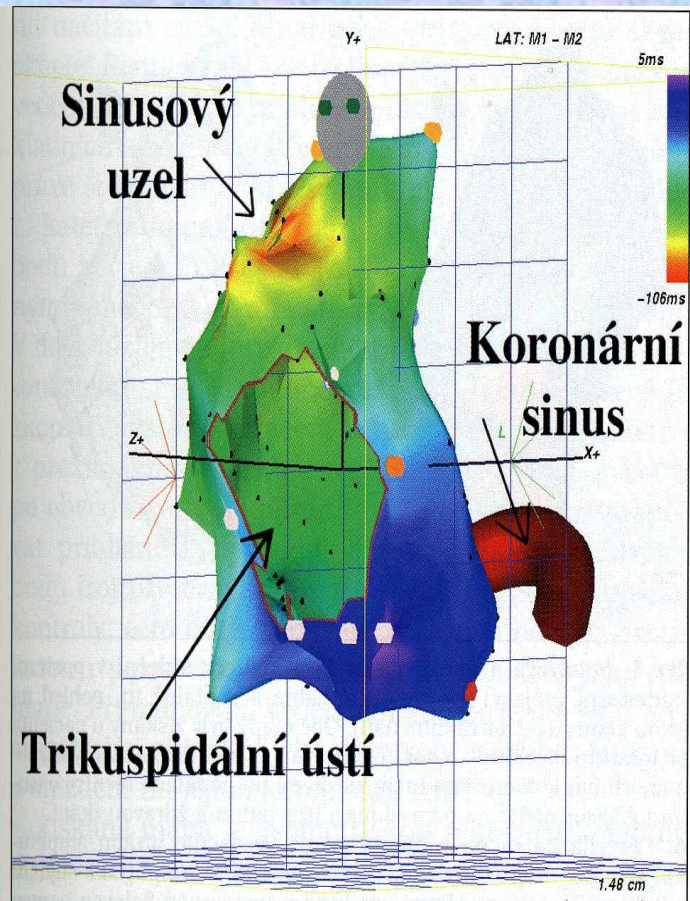
The first catheters used high frequency transducers (20-40 MHz) containing a single ultrasound crystal that rapidly rotated at the end of catheter



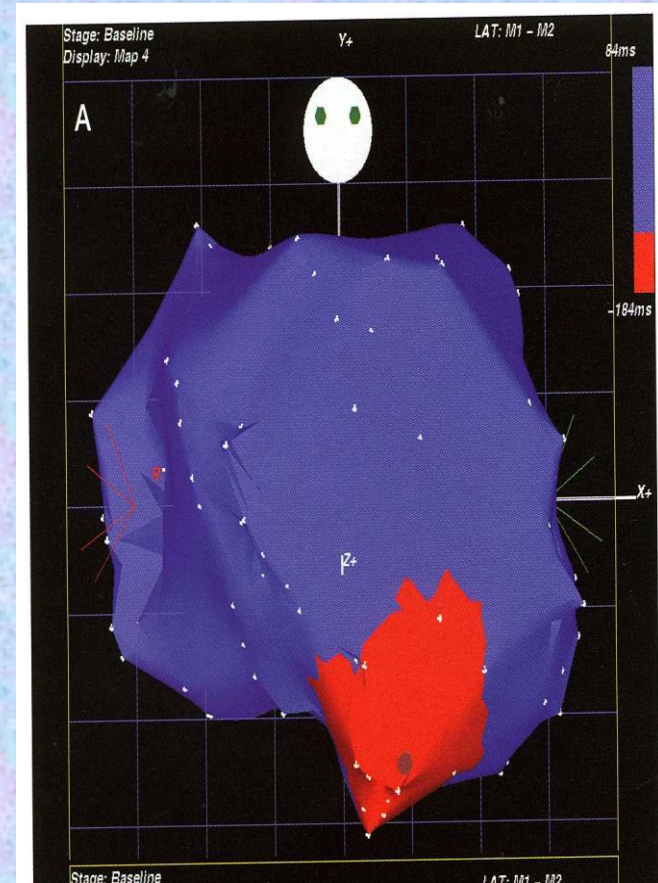
INVASIVE TECHNIQUE

- ELECTROPHYSIOLOGY EXAMINATION

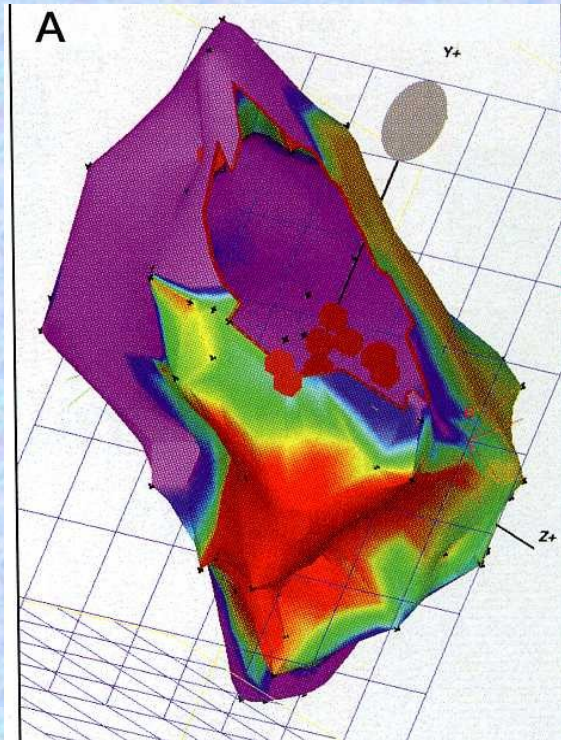




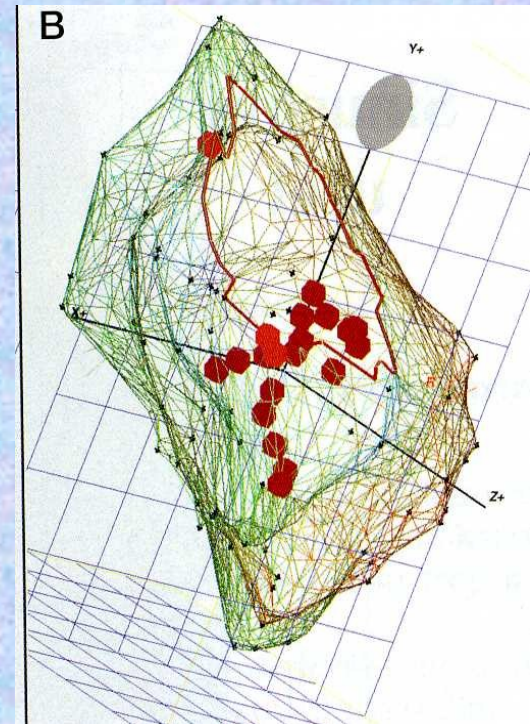
Activation map - Activation map of right atrium in left sloping projection - Sinus rhythm



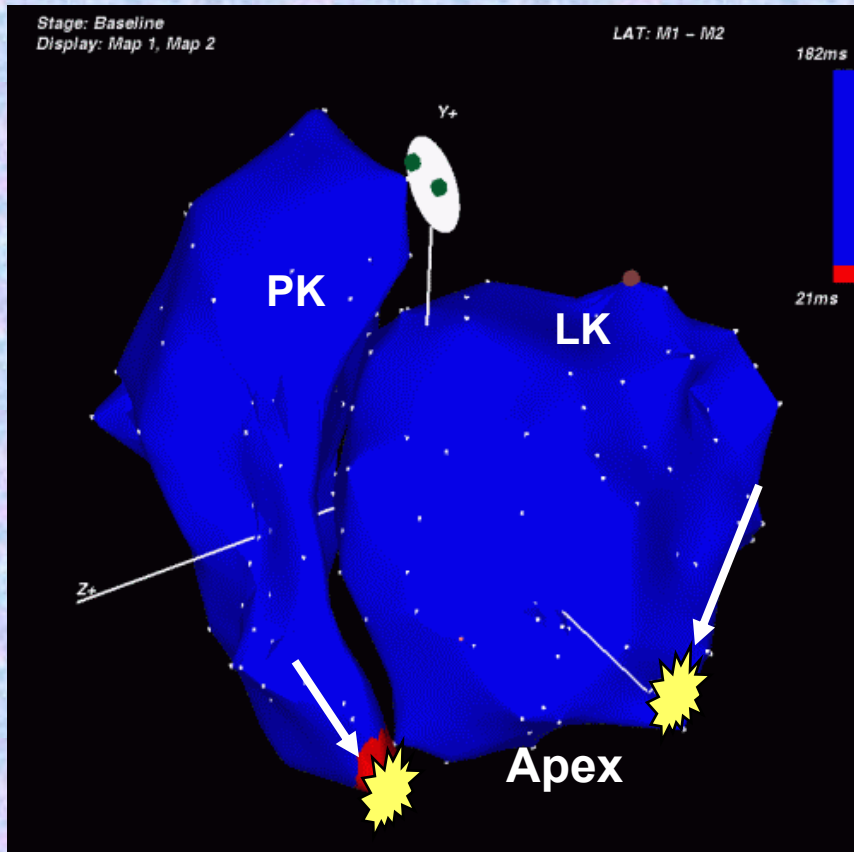
Activation propagation map - propagation of left ventricular map



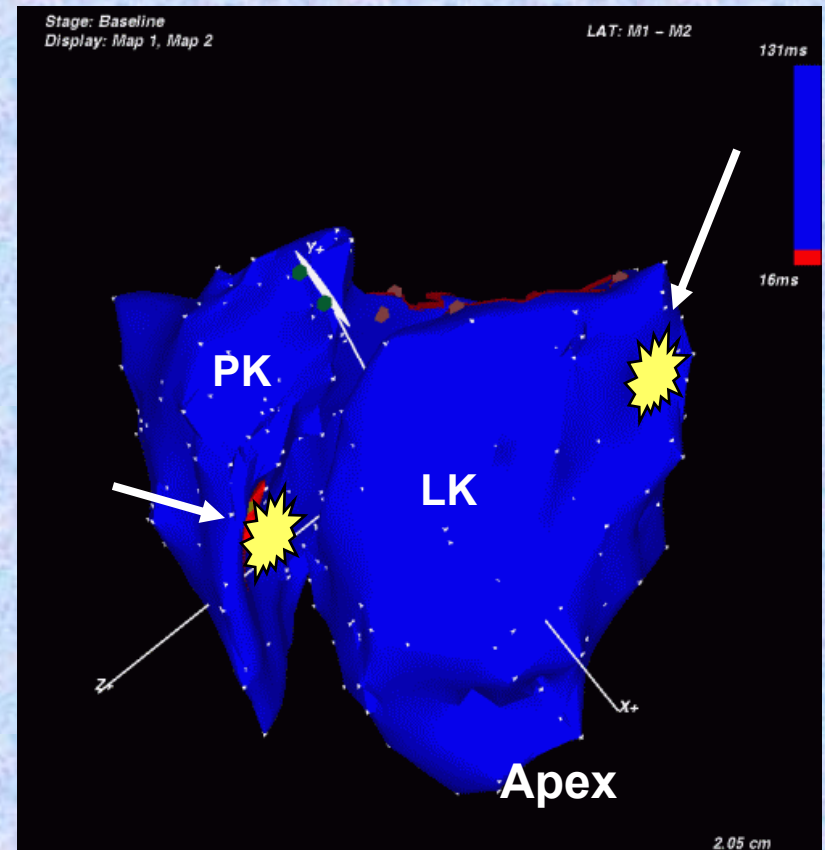
Voltage map – red color – places with a lower voltage, violet – healthy myocardium



Voltage map in network design – visibility of the catheter

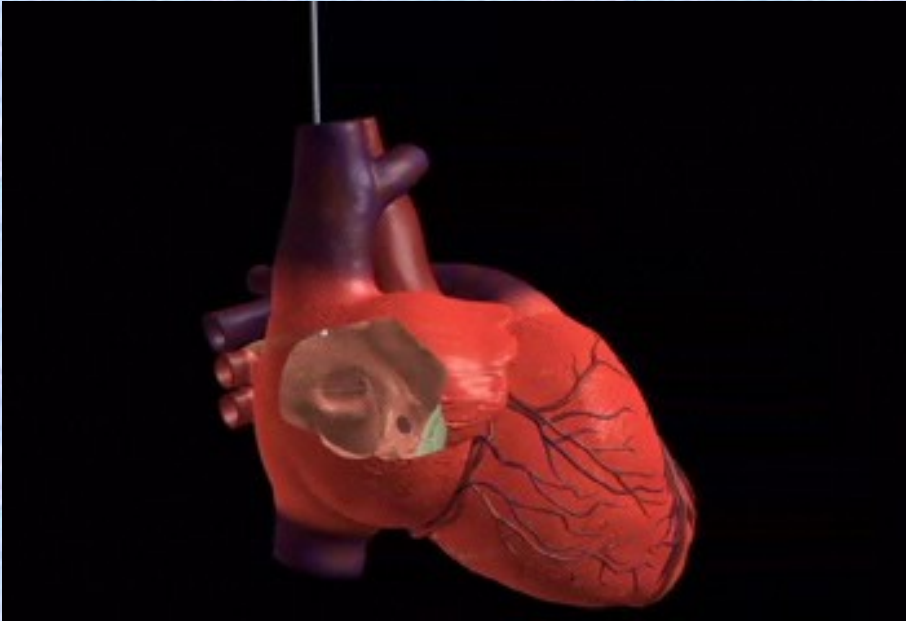


Kombinace elektrody v hrotu PK a
anteriorní větvi CS - LVAT **150 ms**

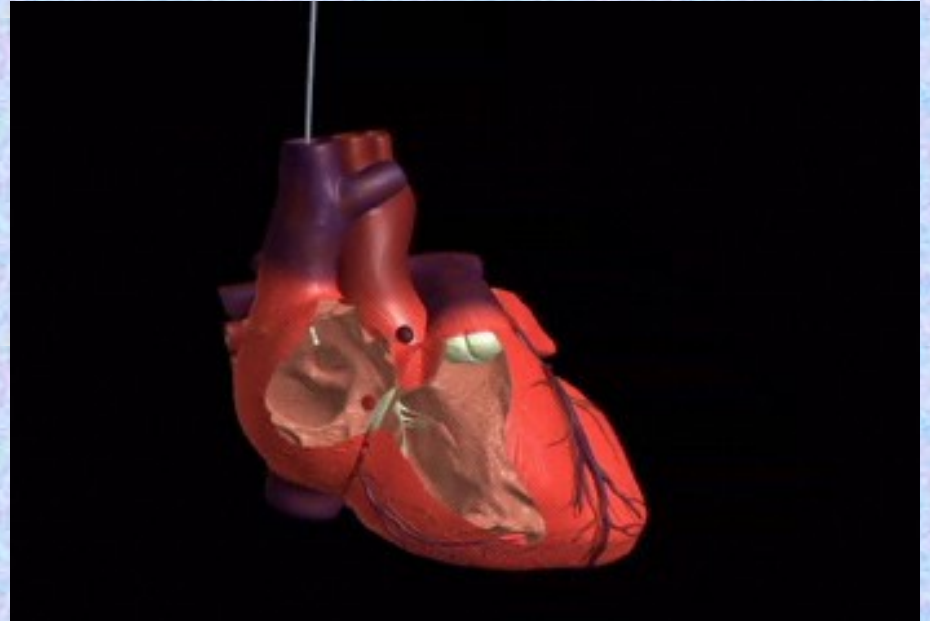


Poloha elektrody v PK
na midseptu - LVAT **82 ms**

Electrodes for cardiostimulation

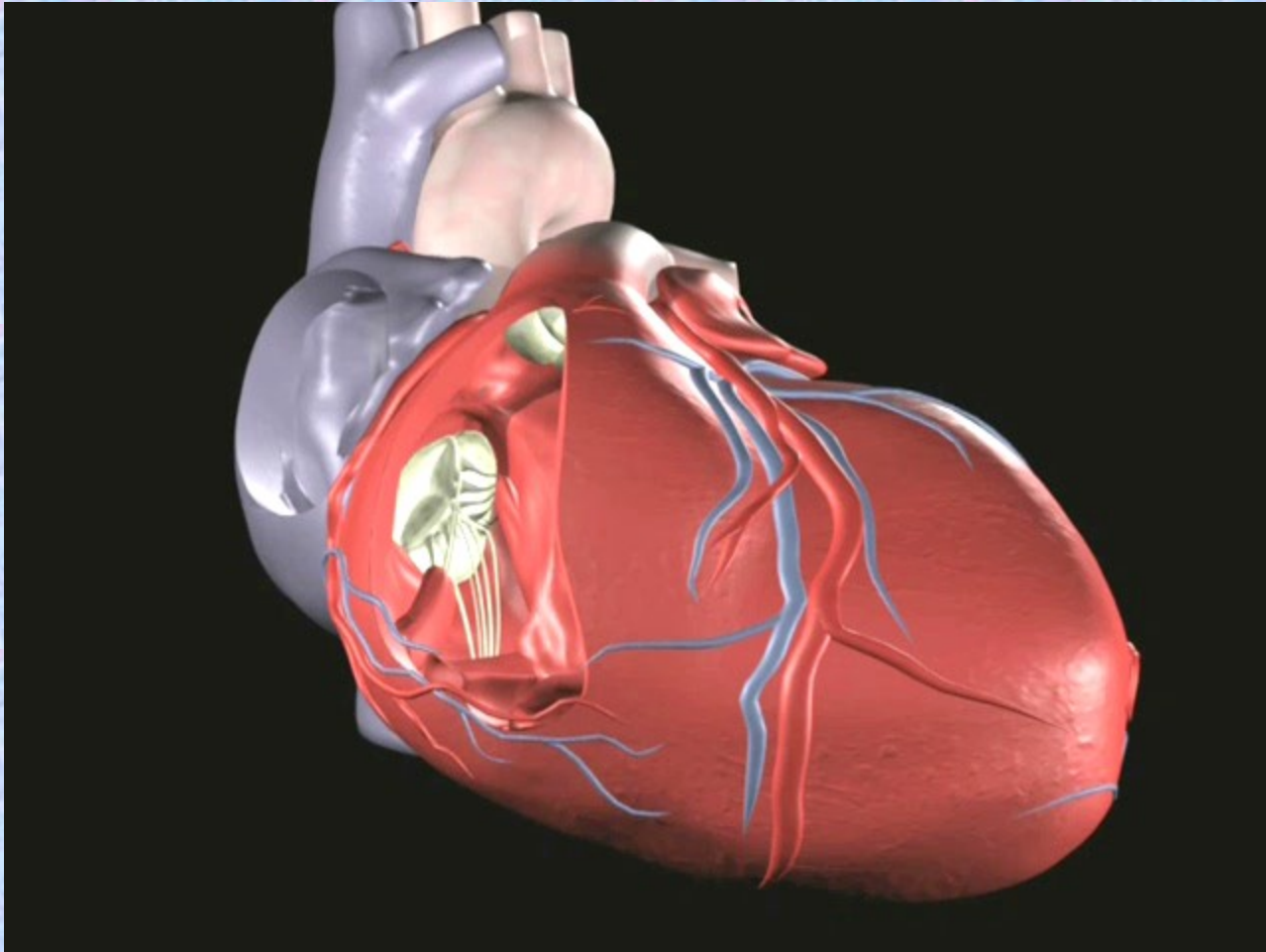


Electrode in right atrium and auricle



Electrode in right ventricle

Electrodes for cardiostimulation



Resynchronization therapy

