

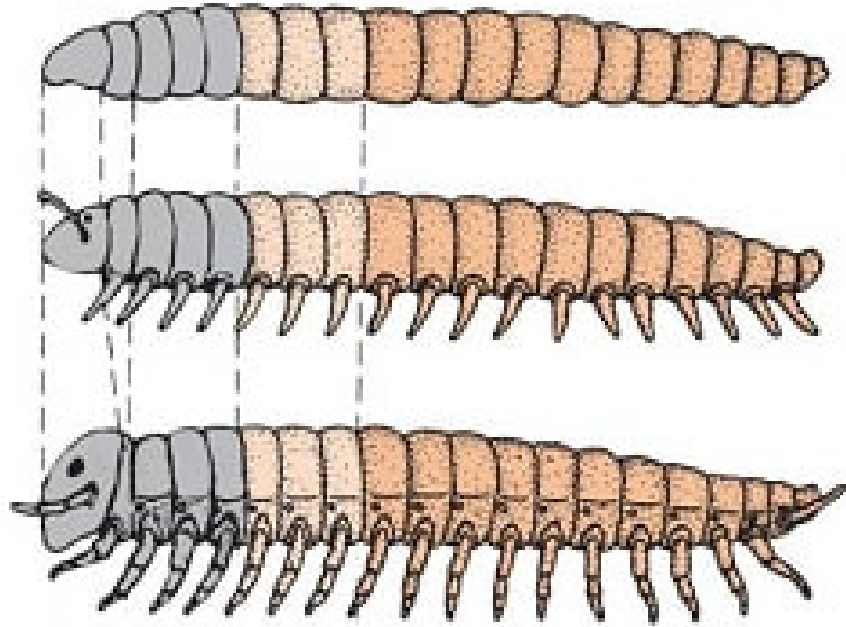
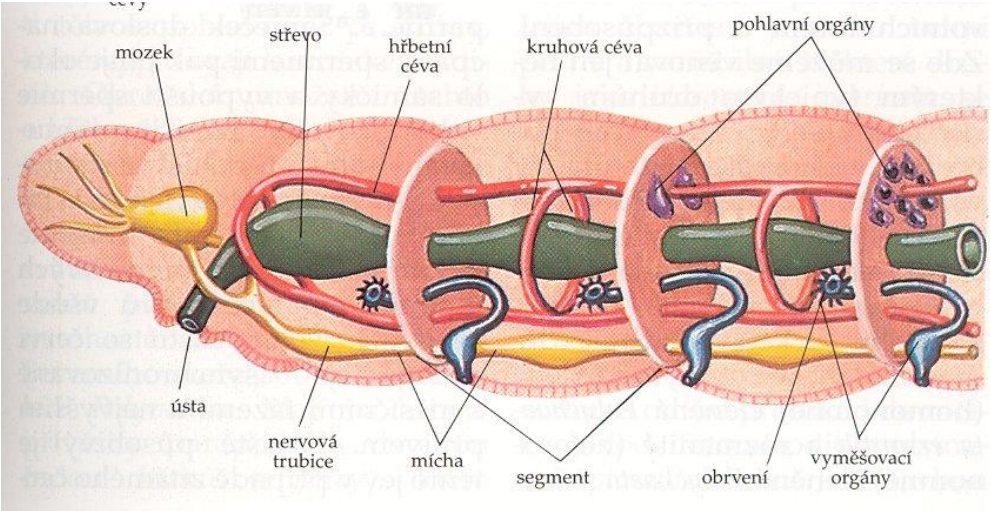
Face development and defects

(face, jaws, palates, nose)

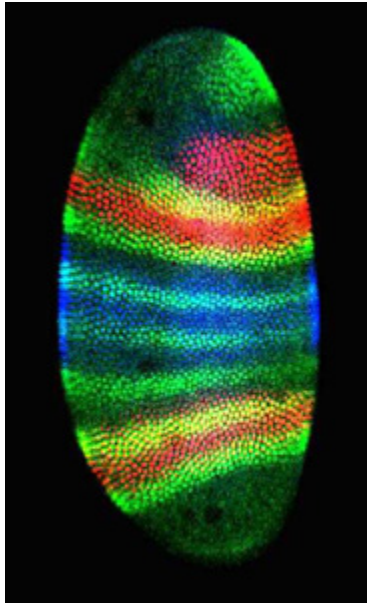
5. 5. 2021

Jan Křivánek

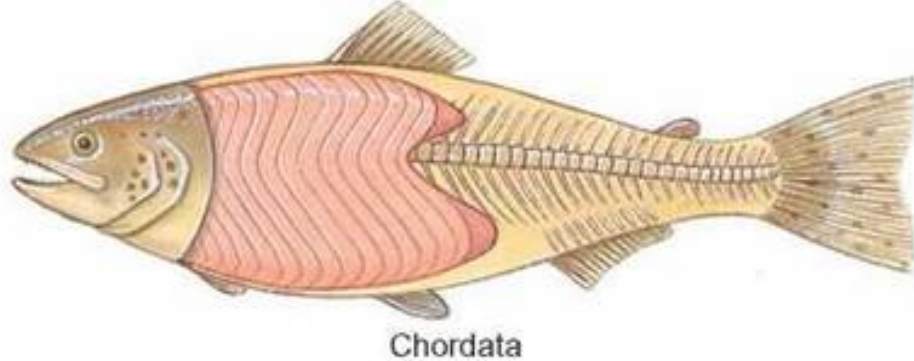
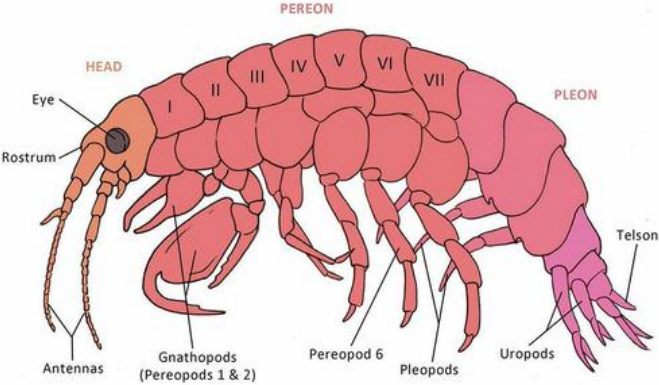
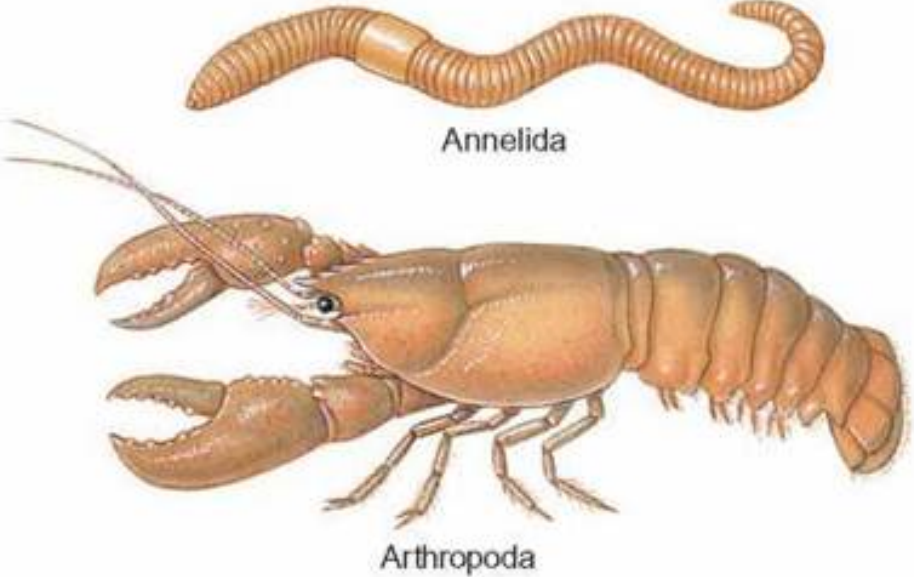
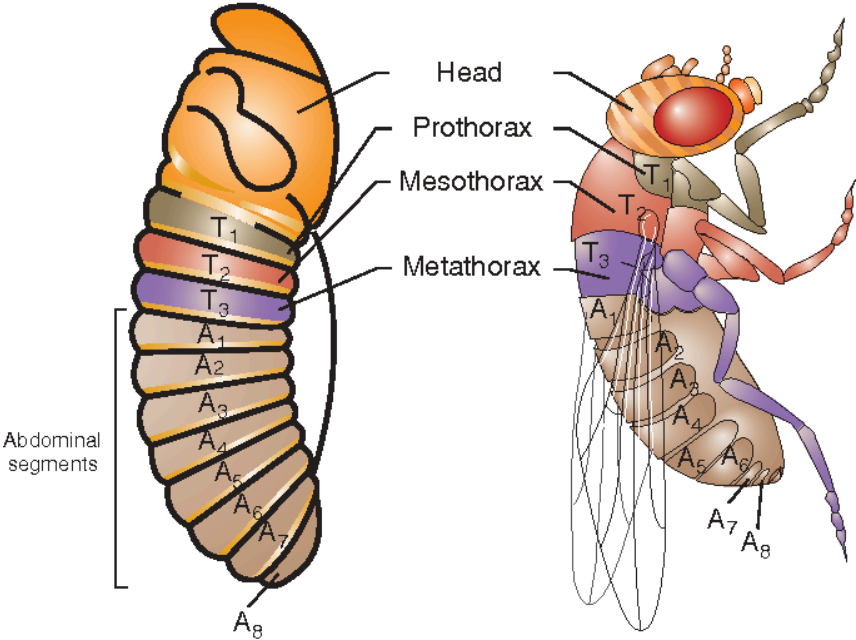
Body segmentation



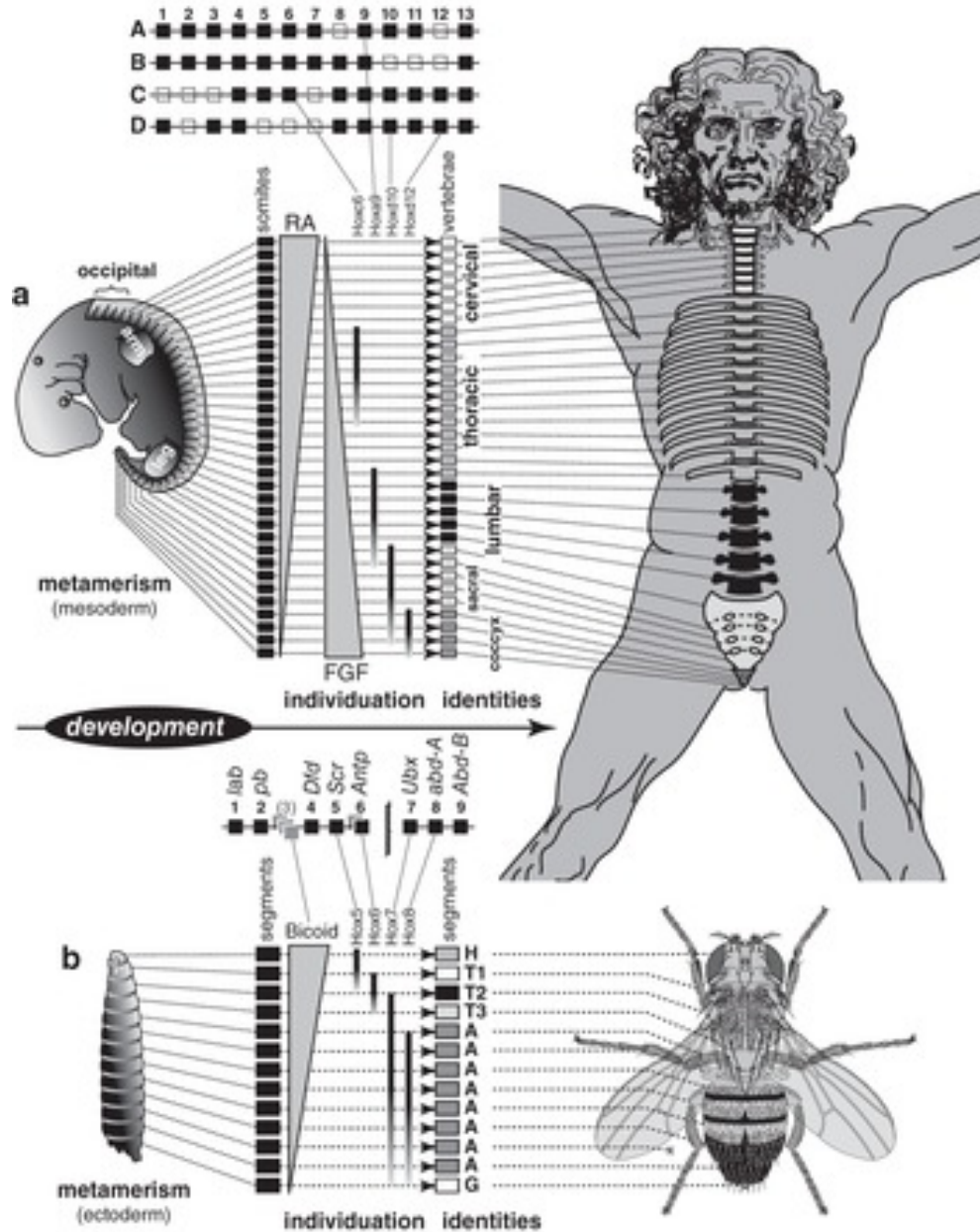
Body segmentation



(d) Segment identity is preserved throughout development.



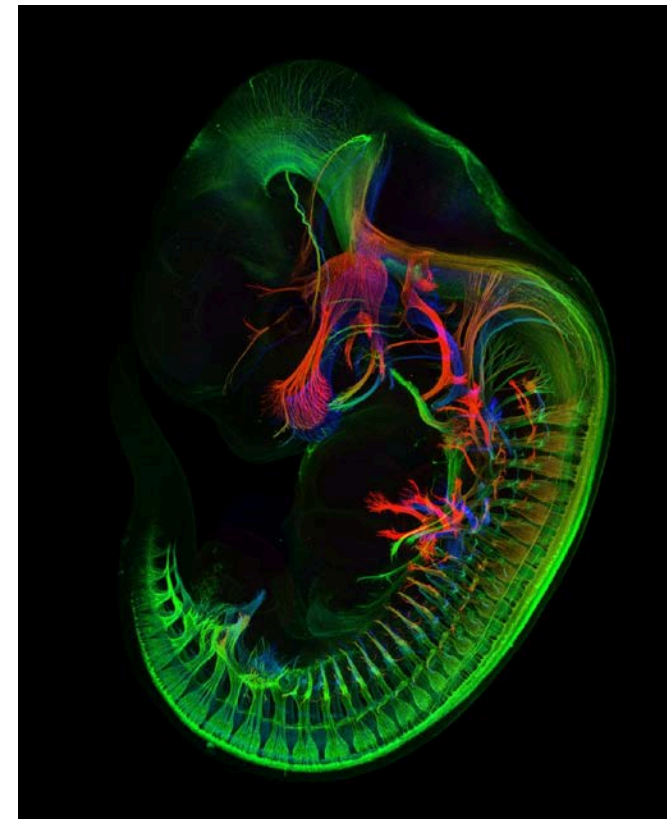
Body segmentation – is a human body segmented?



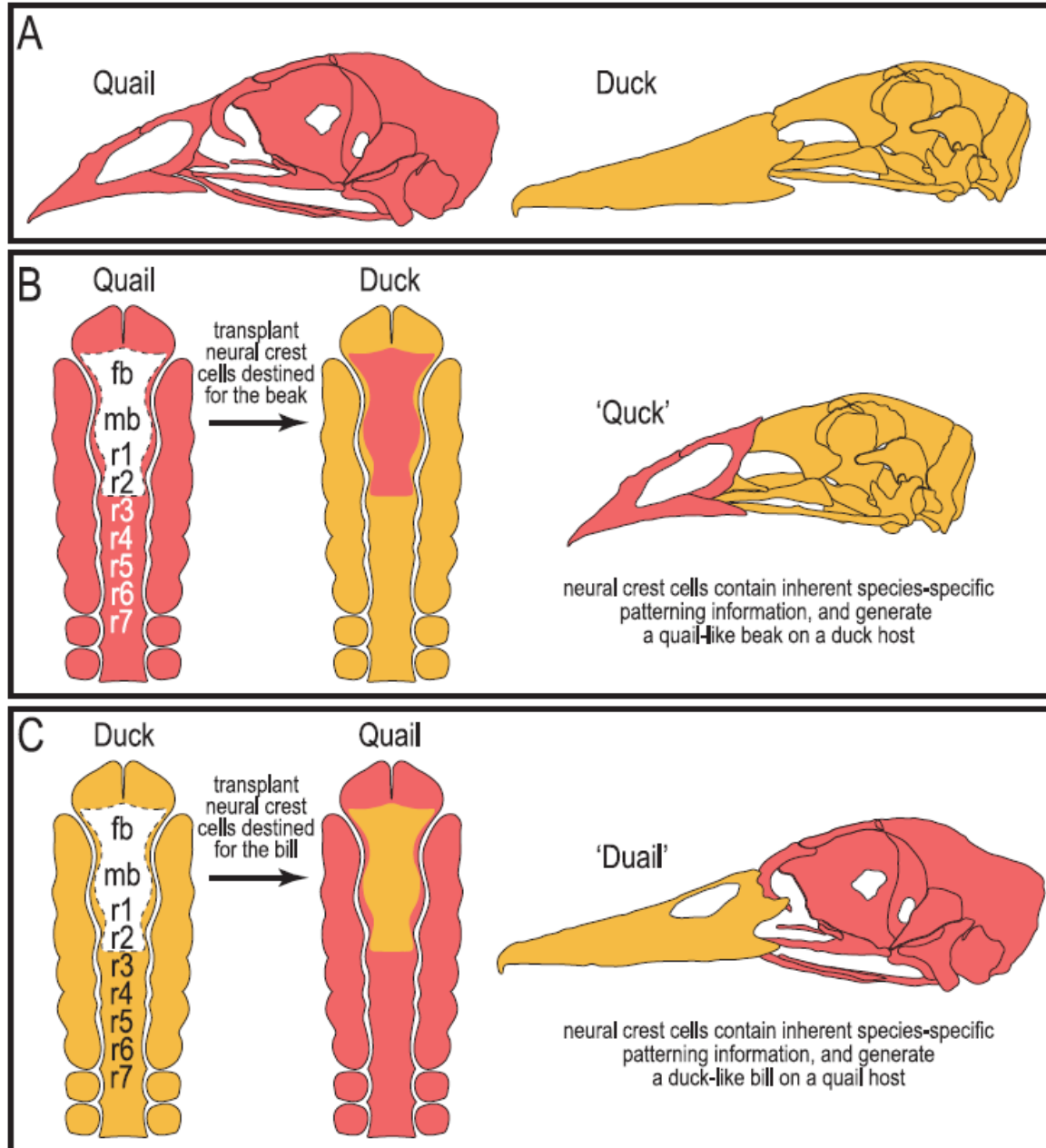
The same segmentation pattern as in a primitive species

The same signalling pathways

We are the result of minor changes in signalling pathways and its final tuning

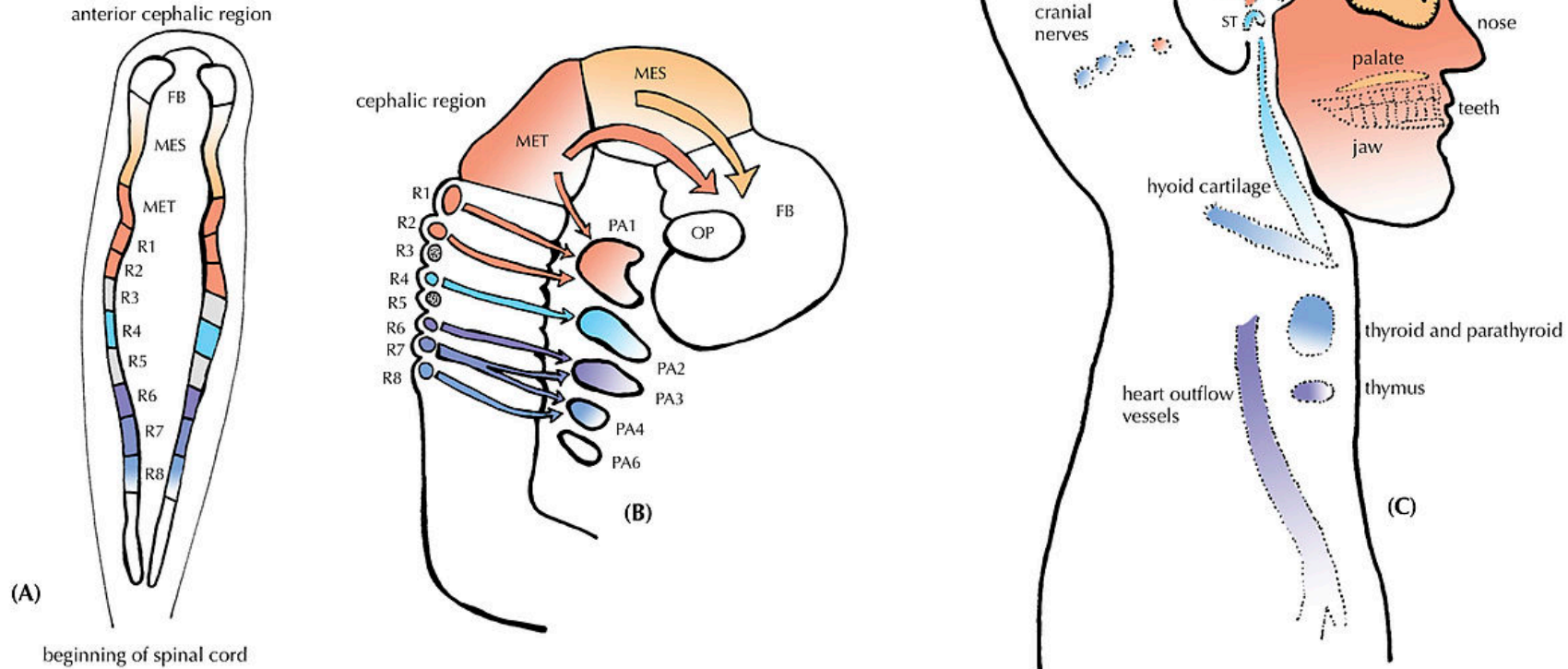


Face development – Neural crest



Neural crest

Figure 1. The sites of origin, migration, and arrival of cranial neural crest cells. (A) Embryonic neural tube showing the mesencephalon, metencephalon, and rhombomeres, with the dorsal face of tube coloured to show the location of neural crest before migration. (B) Sagittal view of embryo, showing paths of migration of cranial crest cells. (C) Sagittal view of adult human, showing the origins of various cranial crest derivatives.



MES mesencephalon
 MET metencephalon
 FB forebrain
 OP optic vesicle
 R1 rhombomere 1
 R2 rhombomere 2
 R3 rhombomere 3
 R4 rhombomere 4
 R5 rhombomere 5

R6 rhombomere 6
 R7 rhombomere 7
 R8 rhombomere 8
 PA1 first pharyngeal arch
 PA2 second pharyngeal arch
 PA3 third pharyngeal arch
 PA4 fourth pharyngeal arch
 PA6 sixth pharyngeal arch

IN incus
 ML malleus
 ST stapes

Origin of structures in adult organism

- Frontonasal process
- First pharyngeal arch
- Second pharyngeal arch
- Third pharyngeal arch
- Fourth pharyngeal arch

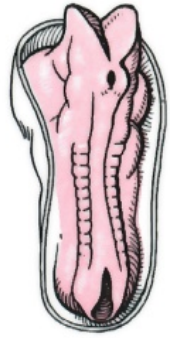
Development from zygote

https://www.youtube.com/watch?v=1zpV5rzWXMA&ab_channel=GetAnimatedMedical

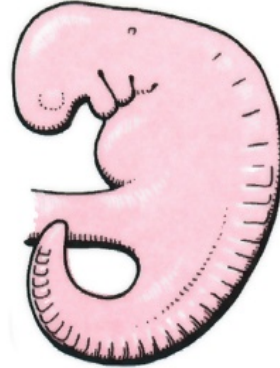
Face development

https://www.youtube.com/watch?v=FhhWG3XzARY&ab_channel=FacultyofDentistry%2CUniversityofToronto

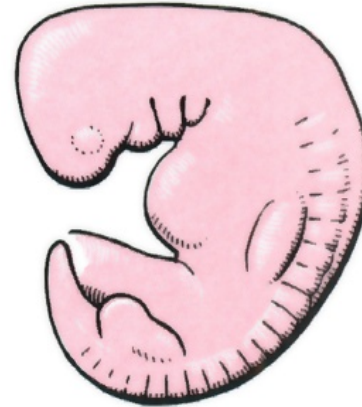
https://www.youtube.com/watch?v=iLbqzTIZ6yA&ab_channel=Osmosis



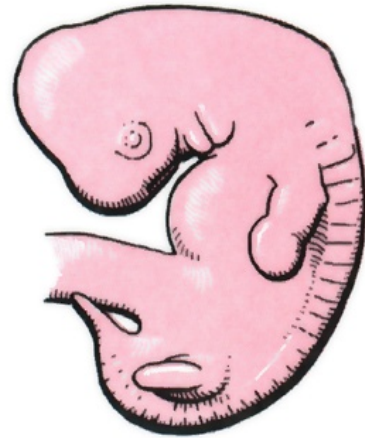
23 dnů



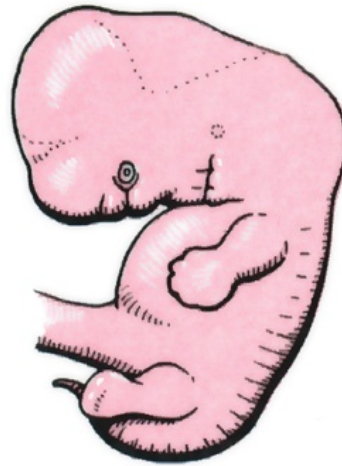
konec 4. týdne



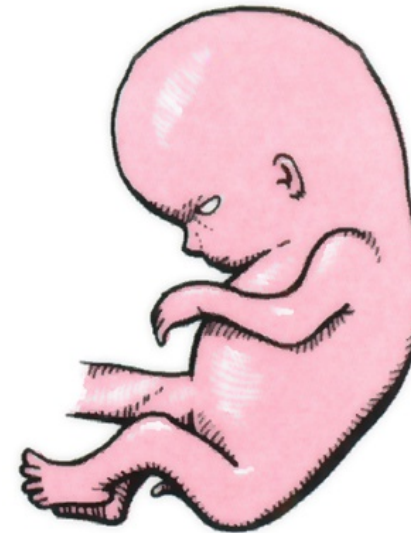polovina 5. týdne



polovina 6. týdne

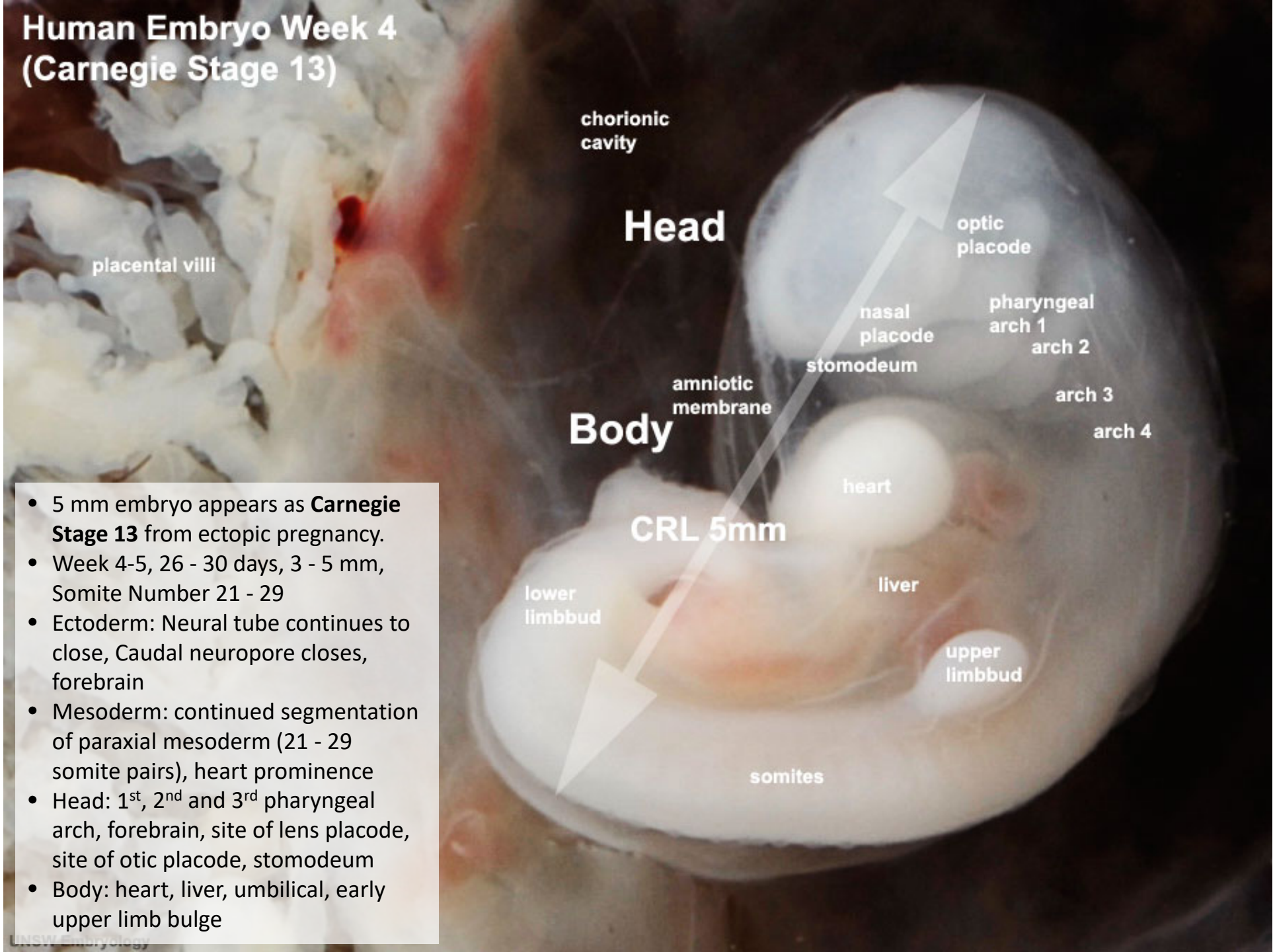


polovina 7. týdne



konec 8. týdne

Human Embryo Week 4 (Carnegie Stage 13)



- 5 mm embryo appears as **Carnegie Stage 13** from ectopic pregnancy.
- Week 4-5, 26 - 30 days, 3 - 5 mm, Somite Number 21 - 29
- Ectoderm: Neural tube continues to close, Caudal neuropore closes, forebrain
- Mesoderm: continued segmentation of paraxial mesoderm (21 - 29 somite pairs), heart prominence
- Head: 1st, 2nd and 3rd pharyngeal arch, forebrain, site of lens placode, site of otic placode, stomodeum
- Body: heart, liver, umbilical, early upper limb bulge

Human fetus at the end of 1st month of development

By the end of 1st month, the embryo has a form of short tube C-shaped curved dorsal side of embryo is convex and adjacent to amnion, cephalic end of the embryo is more advanced in development than caudal one

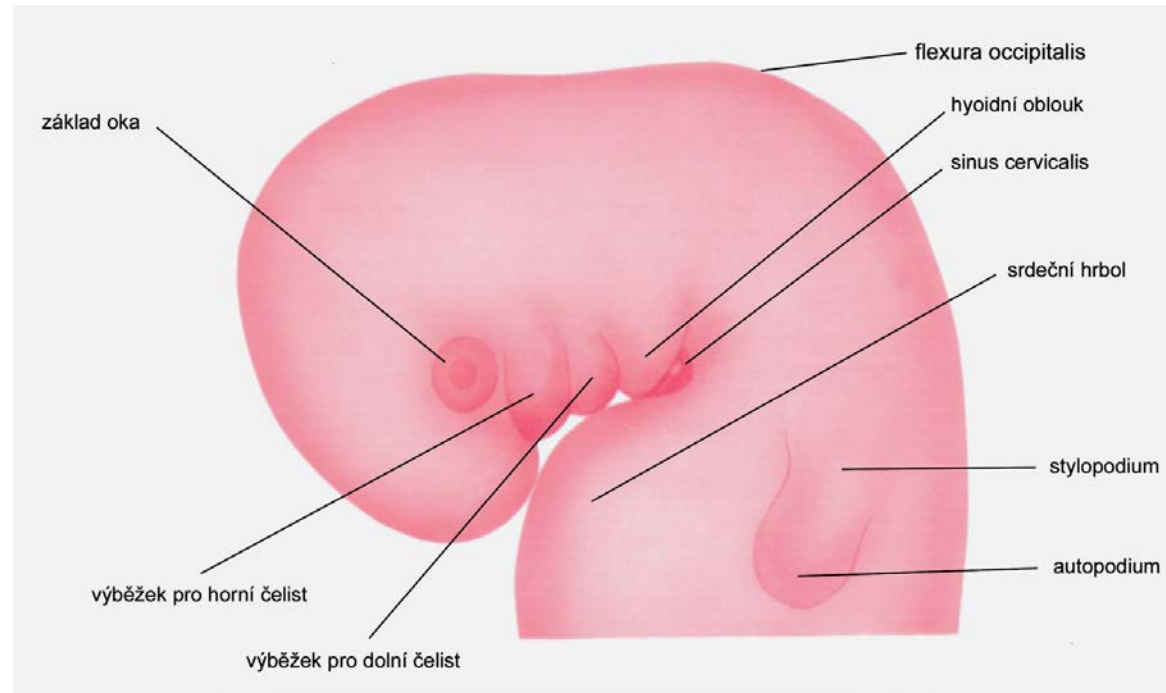
Body parts: head, neck, body and tail

Length of the embryo is 8 -10 mm

Frontal prominence with prosencephalon

Mesencephalic prominence with mesencephalon - flexura cephalica

Occipital prominence with rhombencephalon - flexura occipitalis



Human fetus at the end of 1st month of development

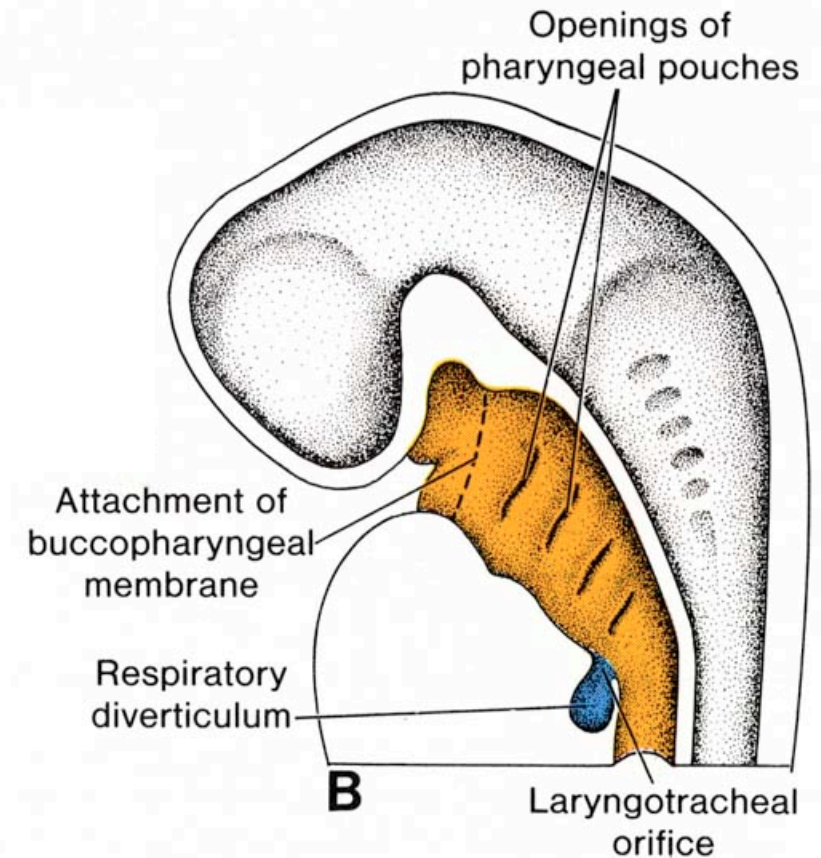
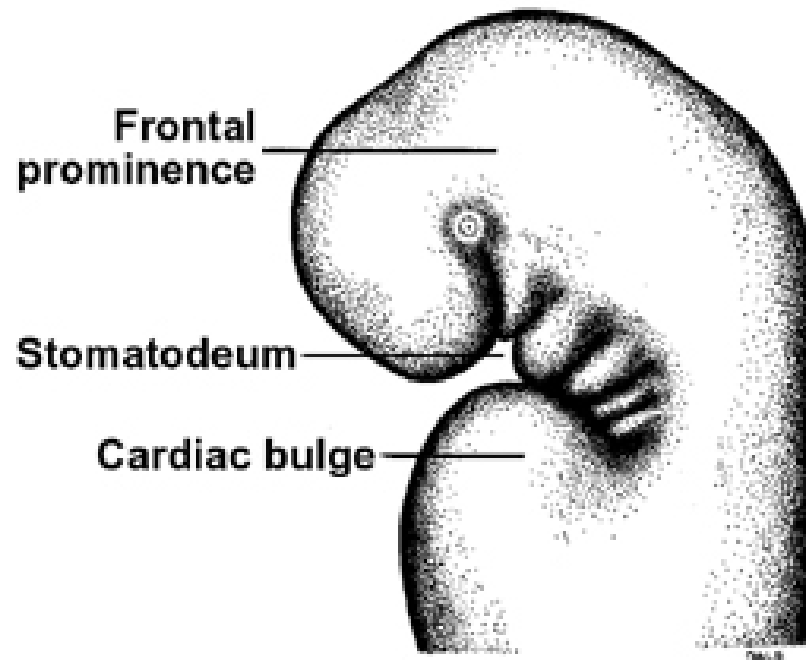
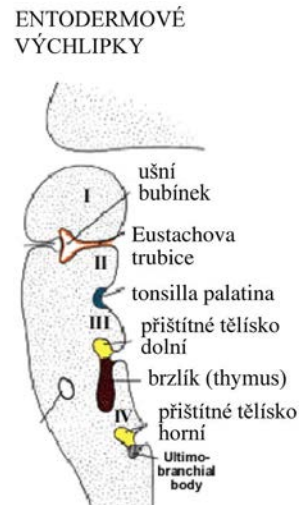
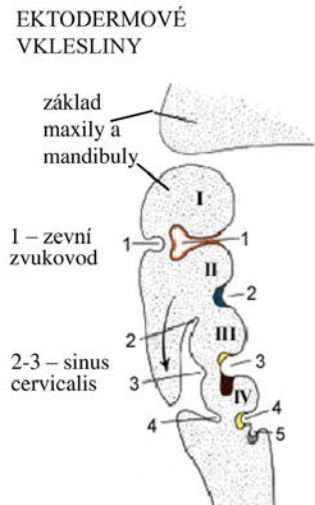
Pharyngeal (branchial) apparatus:

6 Branchial arches

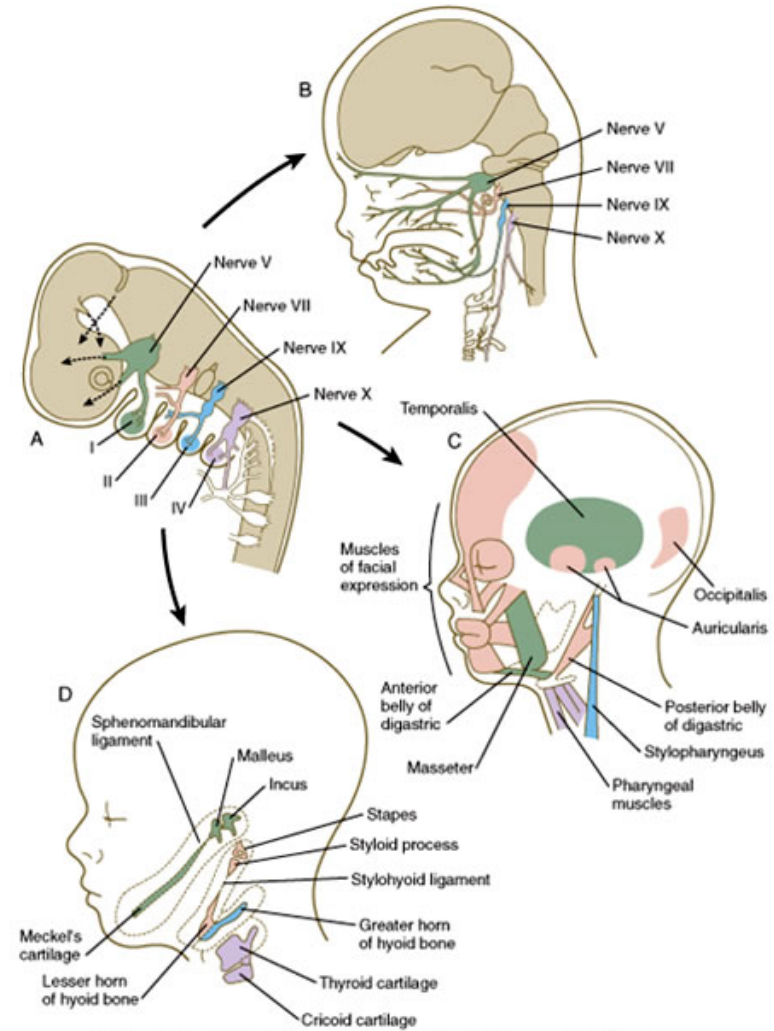
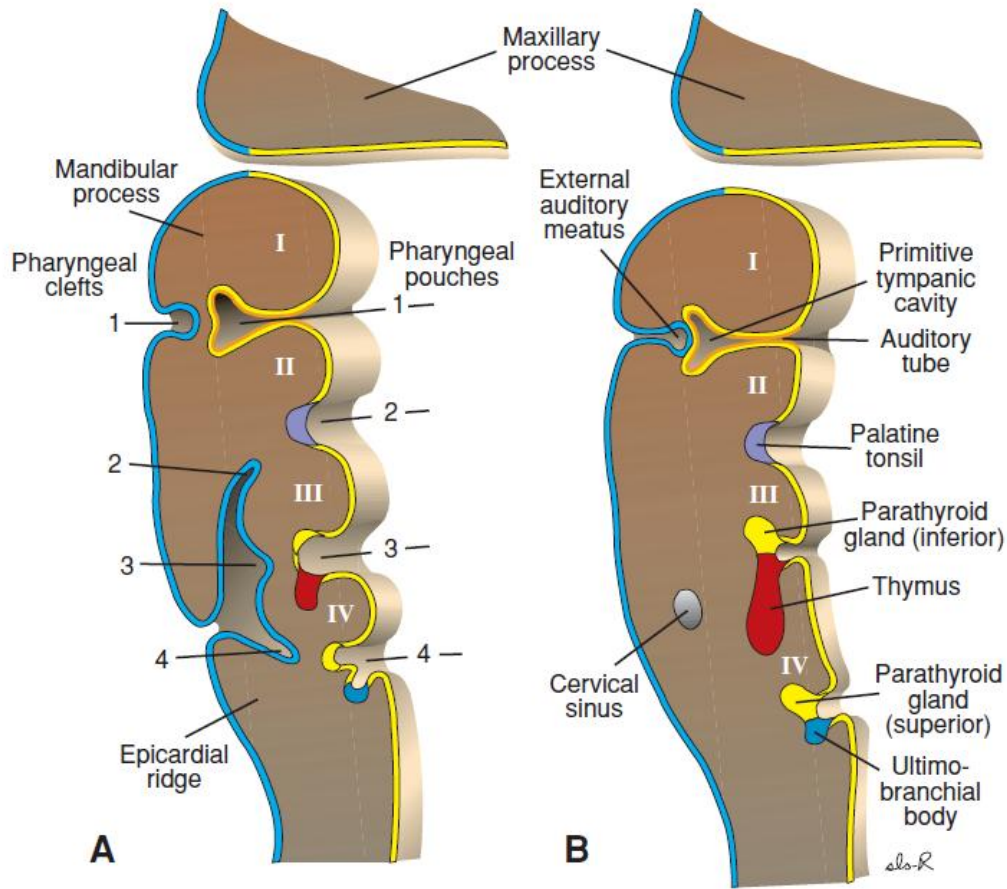
4 Branchial clefts (grooves) (ectodermal)

5 Branchial pouches (entodermal)

Separated by **membranae obturantes**



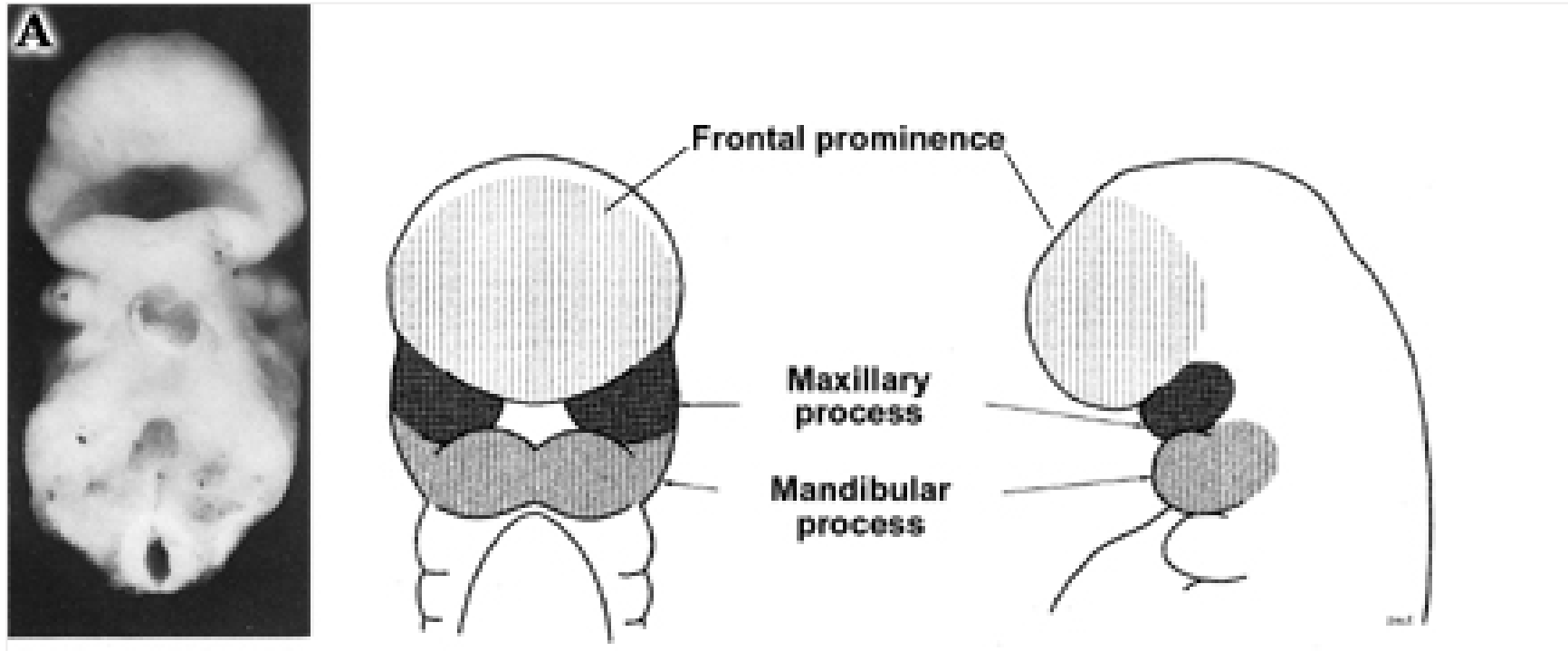
Branchial apparatus



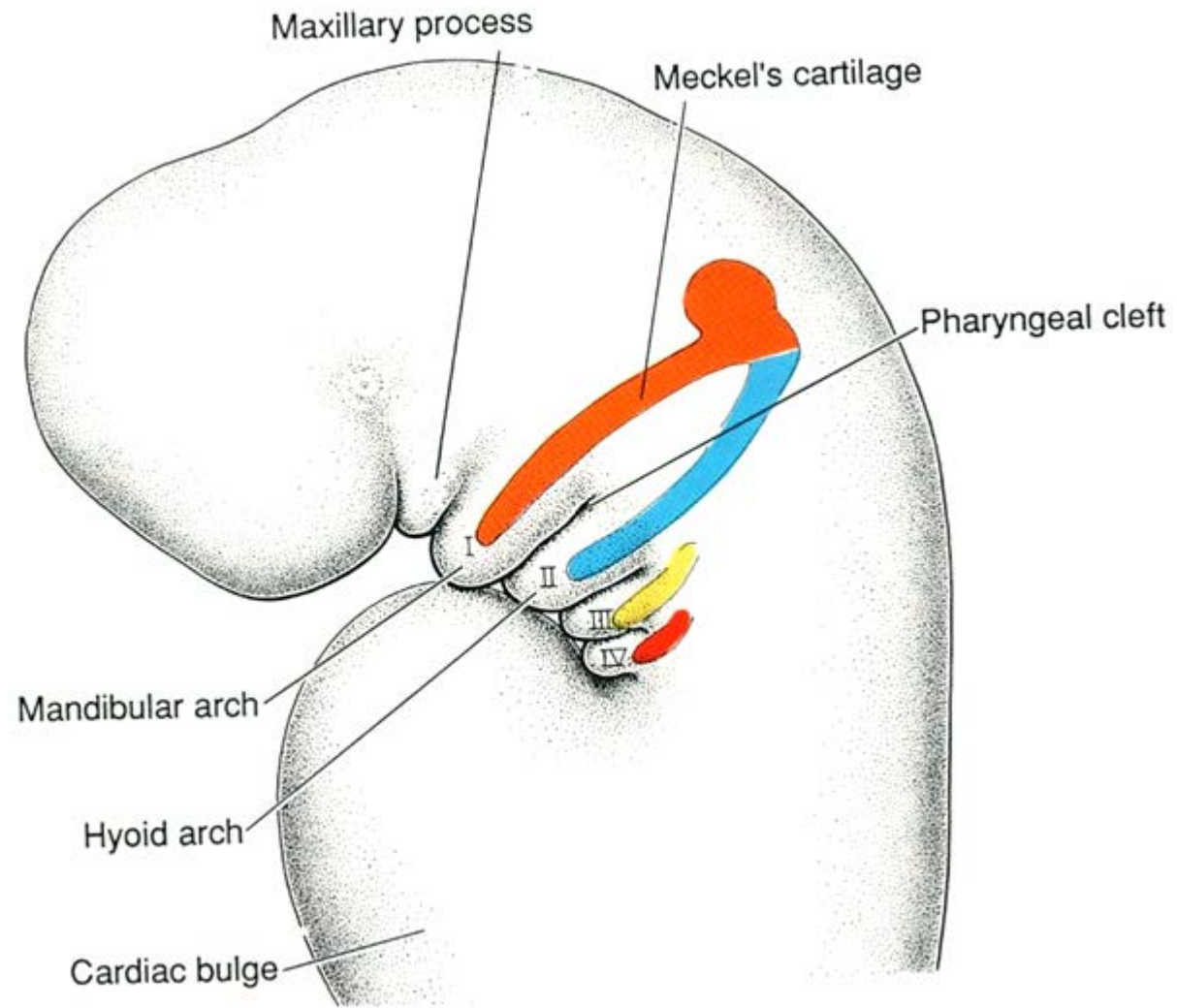
Carlson: Human Embryology and Developmental Biology, 4th Edition.
Copyright © 2009 by Mosby, an imprint of Elsevier, Inc. All rights reserved.

1. Pharyngeal arch (mandibular) is divided into :

- **Processus maxillaris**
- **Processus mandibularis**



Branchial apparatus



Face development

By the end of 4th week of development the face development is initiated around the primitive mouth opening: **stomodeum**

The oral cavity develops from the stomodeum or primitive mouth

Bottom of the stomodeum is constituted by oropharyngeal membrane (membrana oropharyngea)

Development is organized by 2 centers:

- **Prosencephalic**
- **Rhombencephalic**

5 processes limit the stomodeum:

- **Frontonasal** prominence
- Paired **maxillary** prominences (processus maxillares)
- Paired **mandibular** prominences (processus mandibulares)

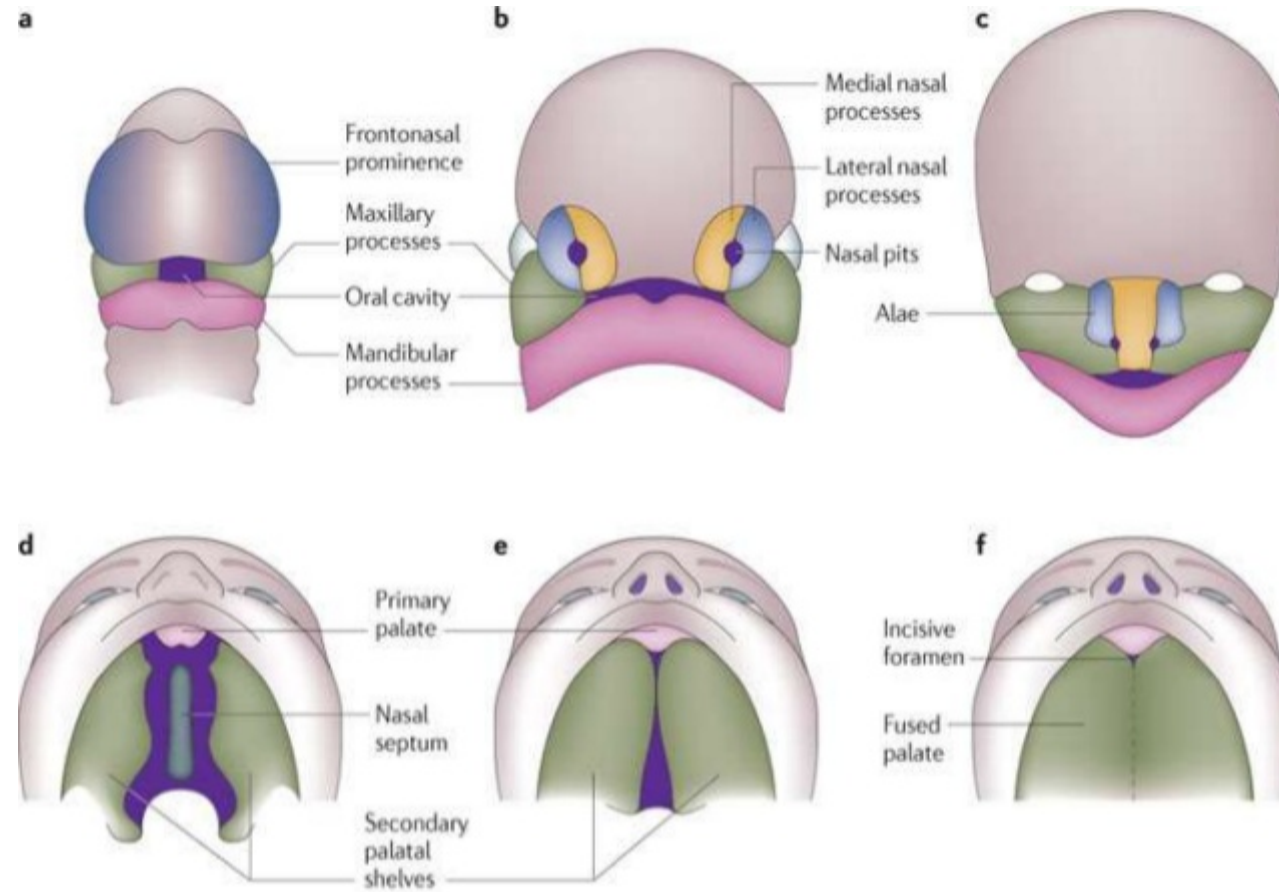
The base of the prominences is formed by an **ectomesenchyme**, which populated them from the lower mesencephalic and upper rhombencephalic section of the neural crest.

The surface of the prominences is covered by an **ectoderm**, which also lines the stomodeum.

Prominences are initially separated from each other by deep grooves. It is a dynamic process - it starts at the end of the 4th and beginning of 5th week of development and ends at about the 8th week. It depends on the proliferation of the ectoderm and ectomesenchyme of the prominences and their further divisions, movements and different growth rates.

It is terminated by the fusion of the protrusions.

Face development



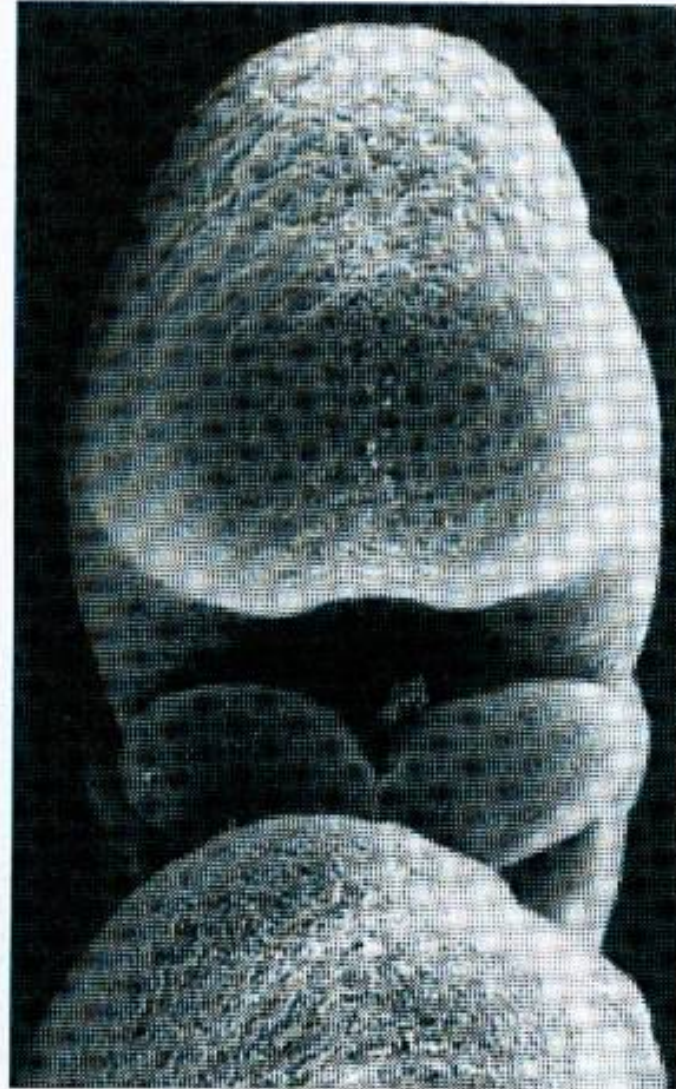
Face development

Initiation

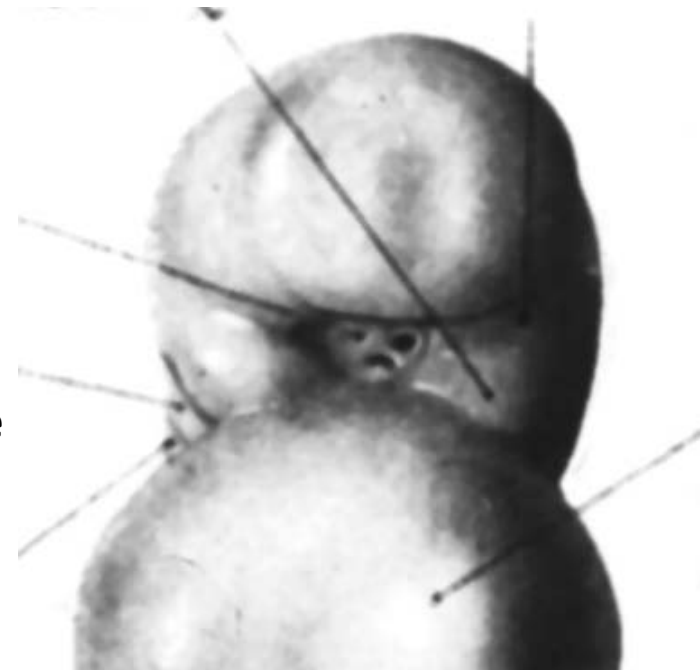
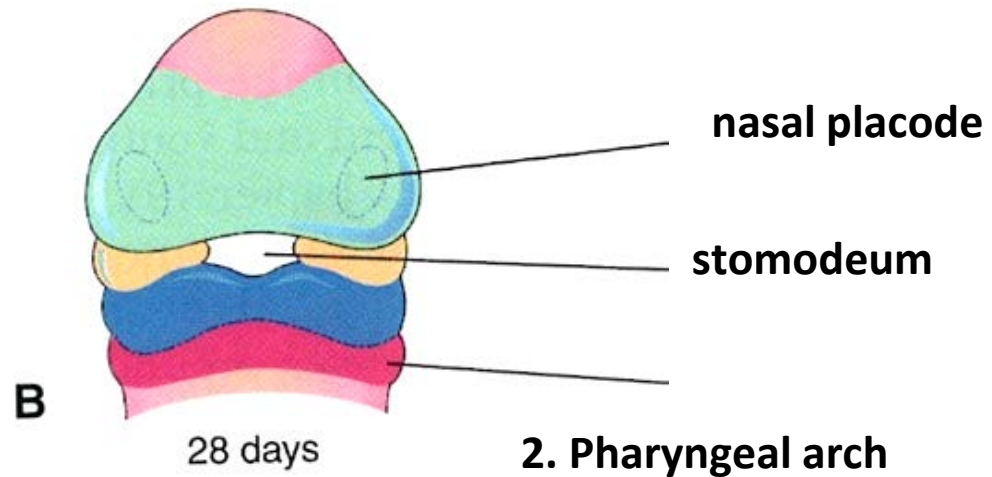
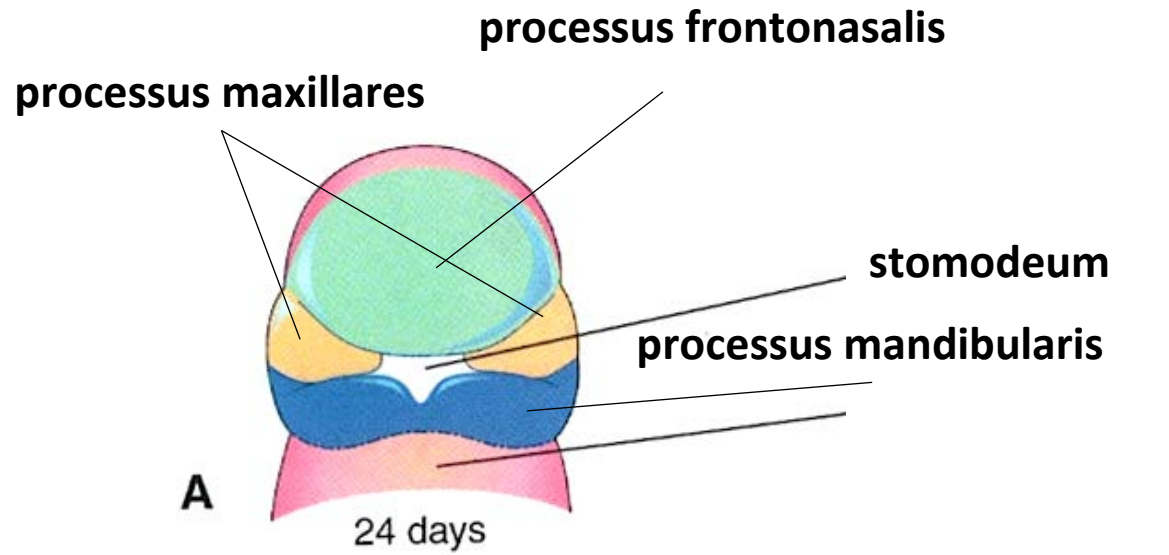
**Frontonasal prominence
(processus frontonasalis)**

**Paired prominences for upper jaw
(processus maxillares)**

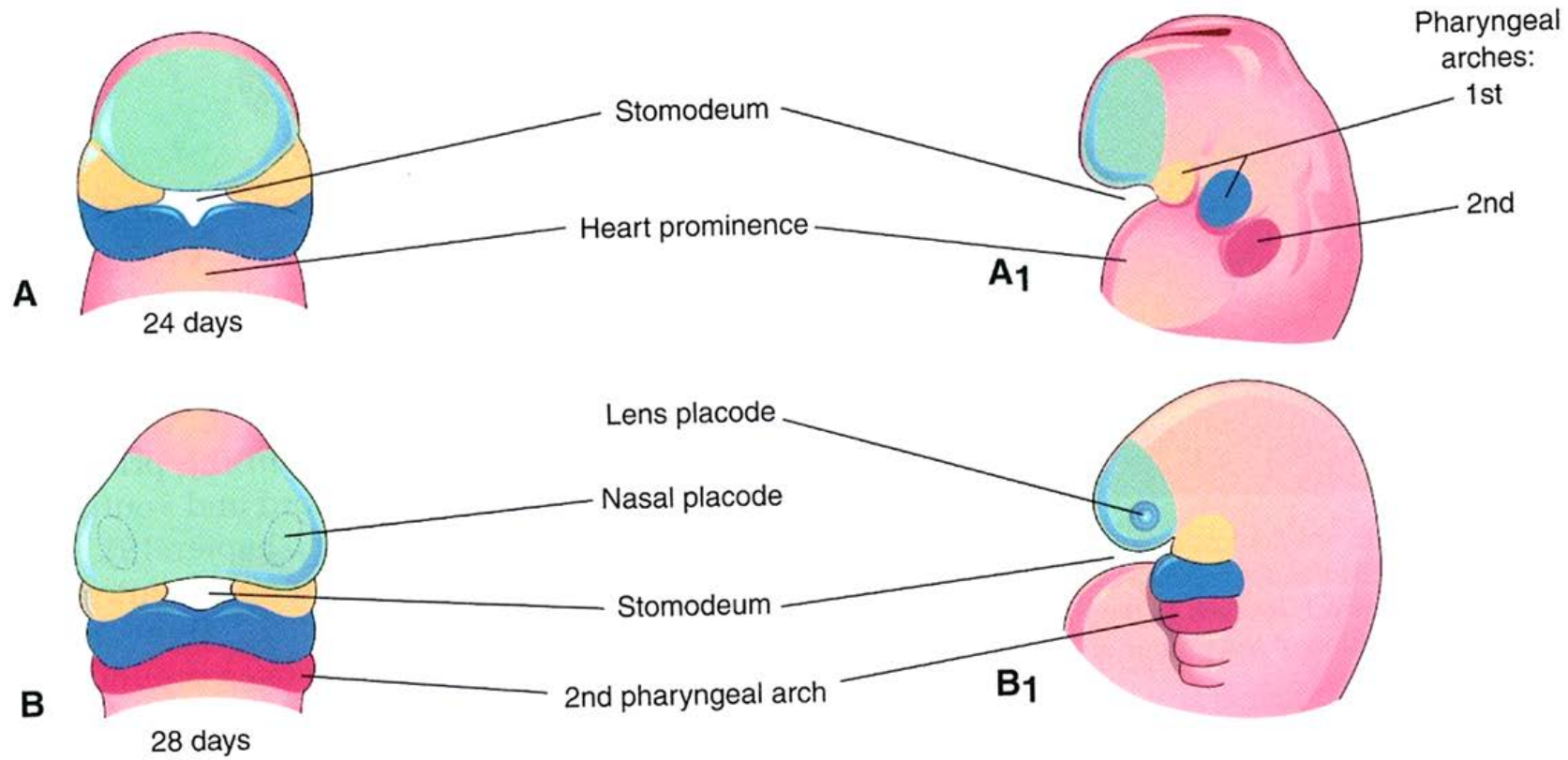
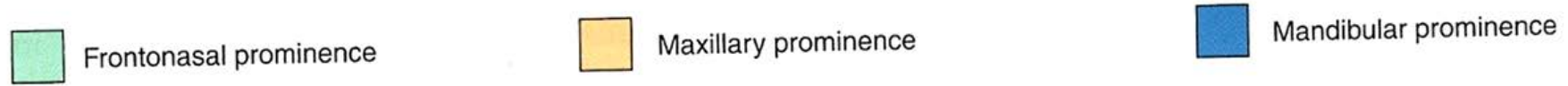
**Paired prominences for lower jaw
(processus mandibulares)**

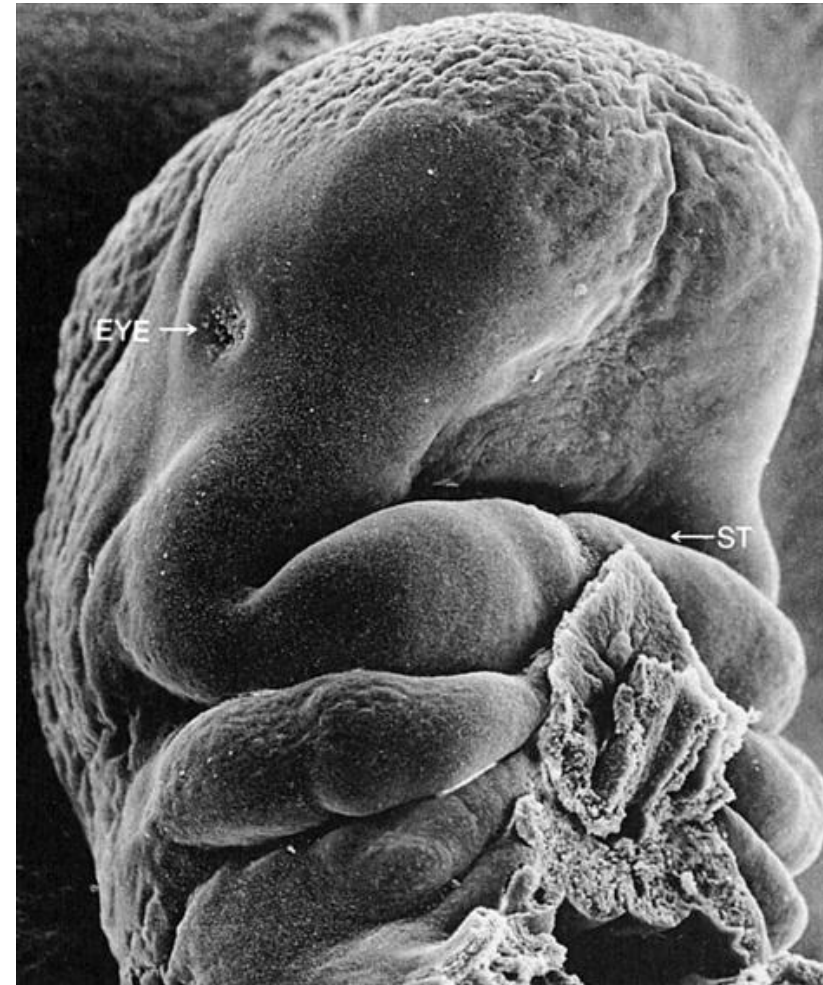
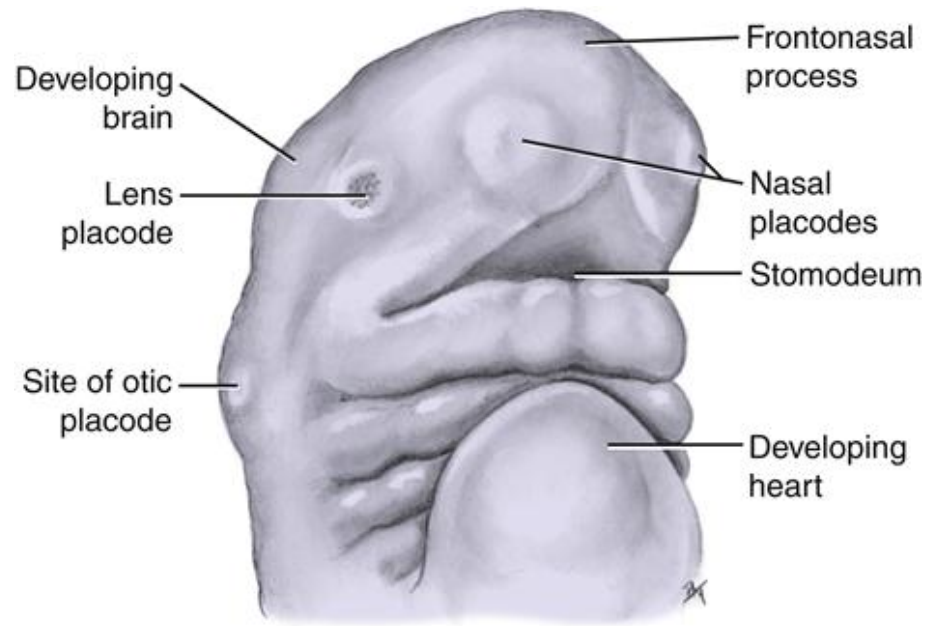


4th week

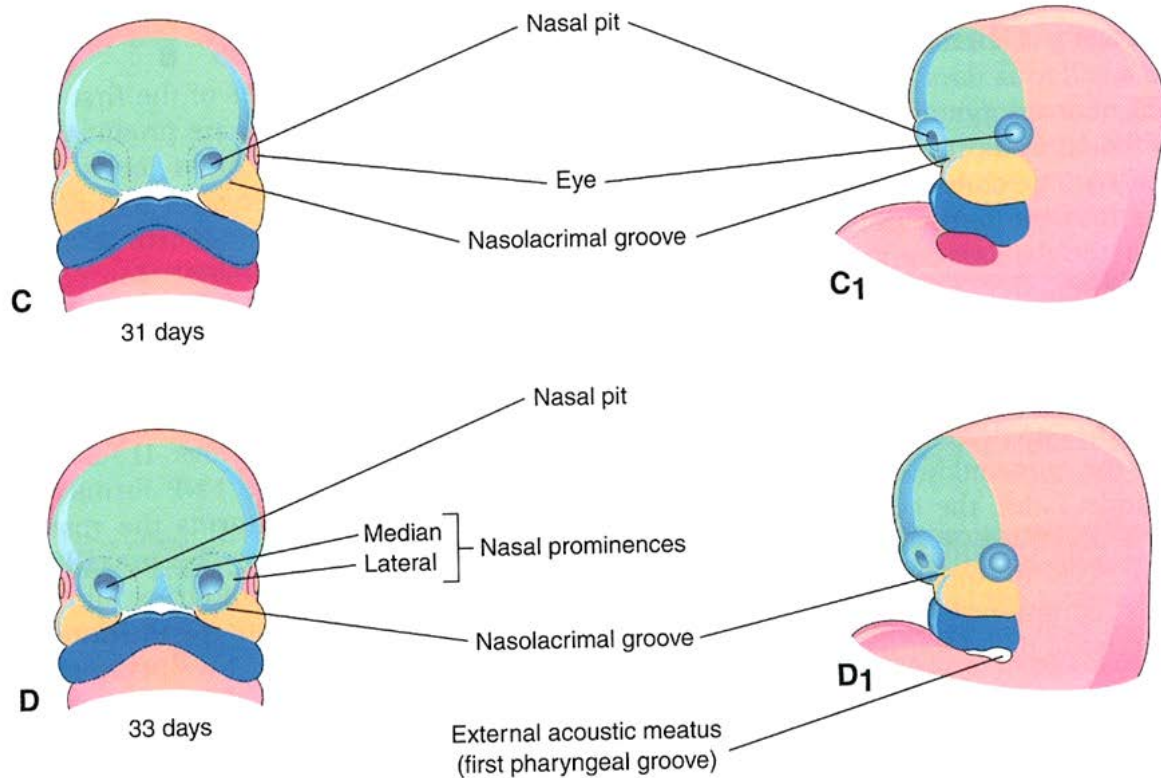
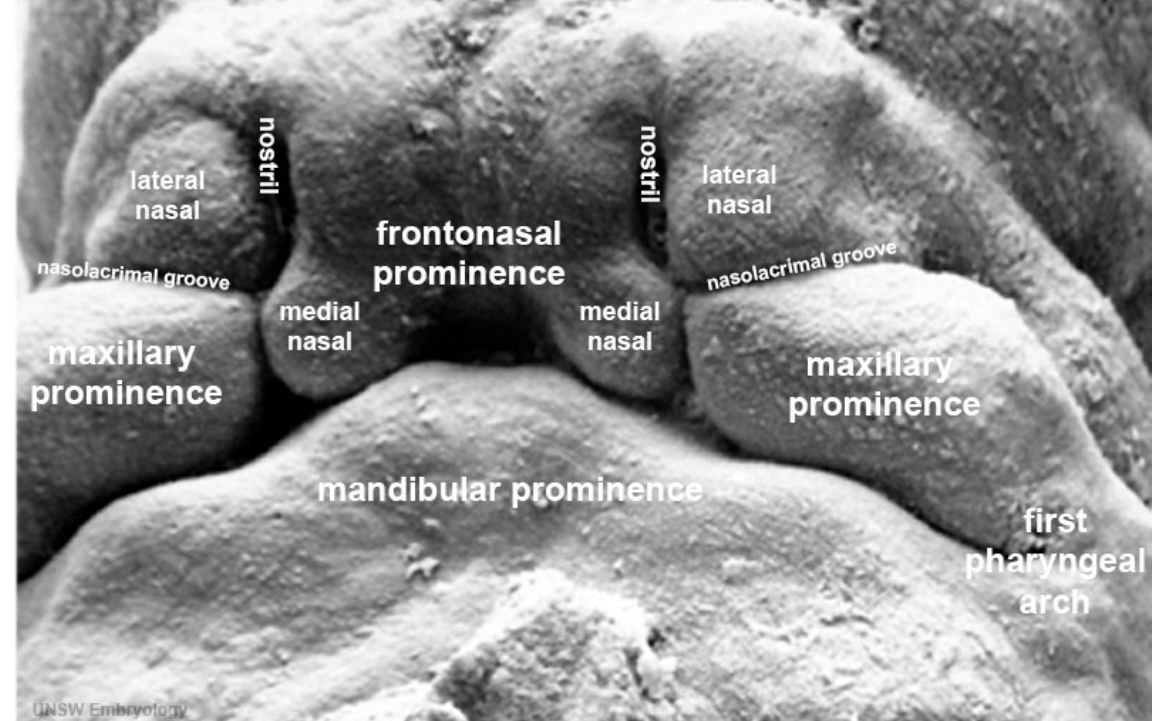


Face development

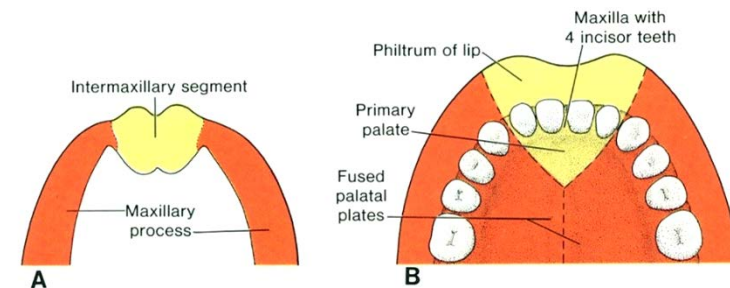




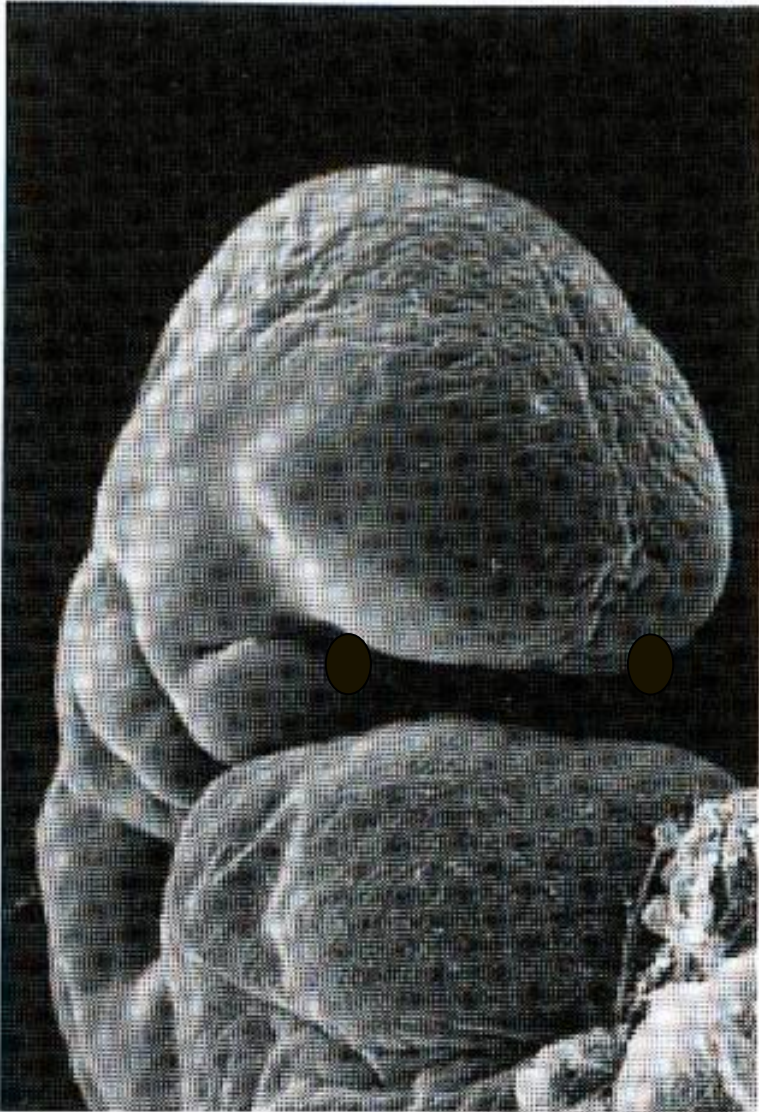Human Embryo Face
(SEM, week 7, Carnegie stage 18)



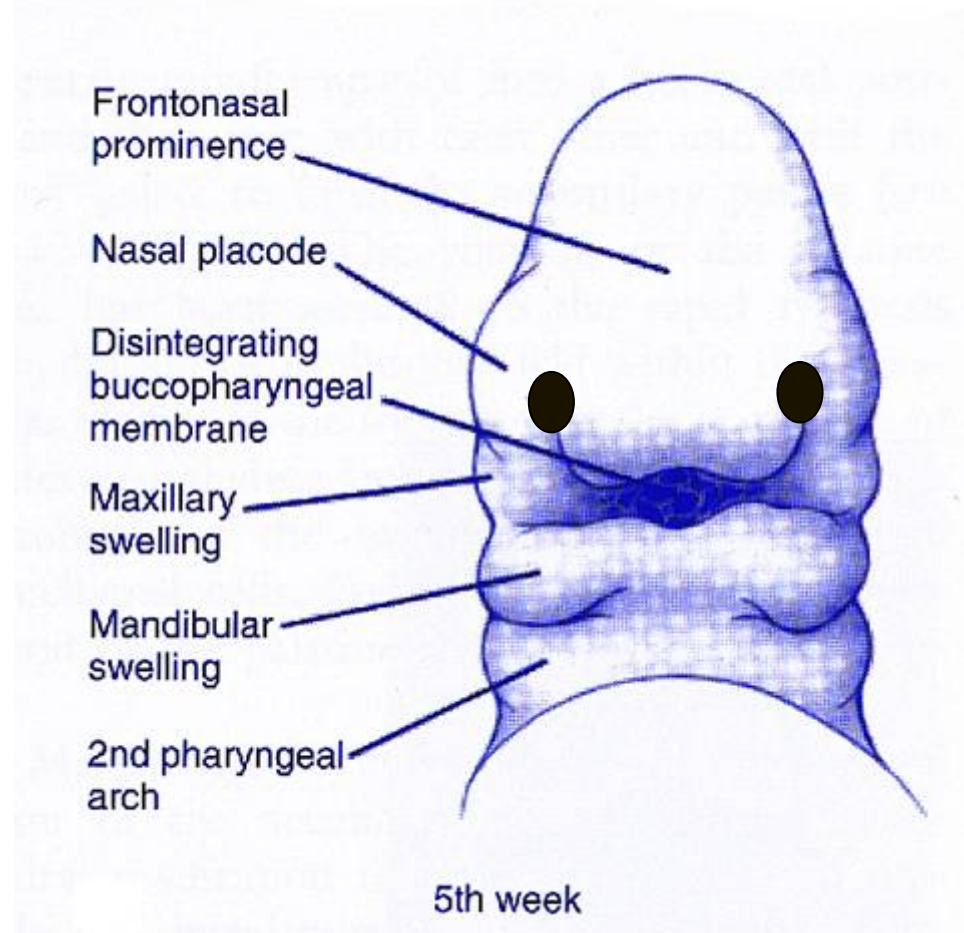
- Nasal pits surrounded by paired prominences – **medial and lateral nasal prominence**
- **Area triangularis** (nose)
- **Intermaxillary segment** (medial part of upper lip, part of upper jaw, primary palate)



Frontonasal prominence (gives rise to forehead, nose and middle part of upper lip - *philtrum*)



4th week

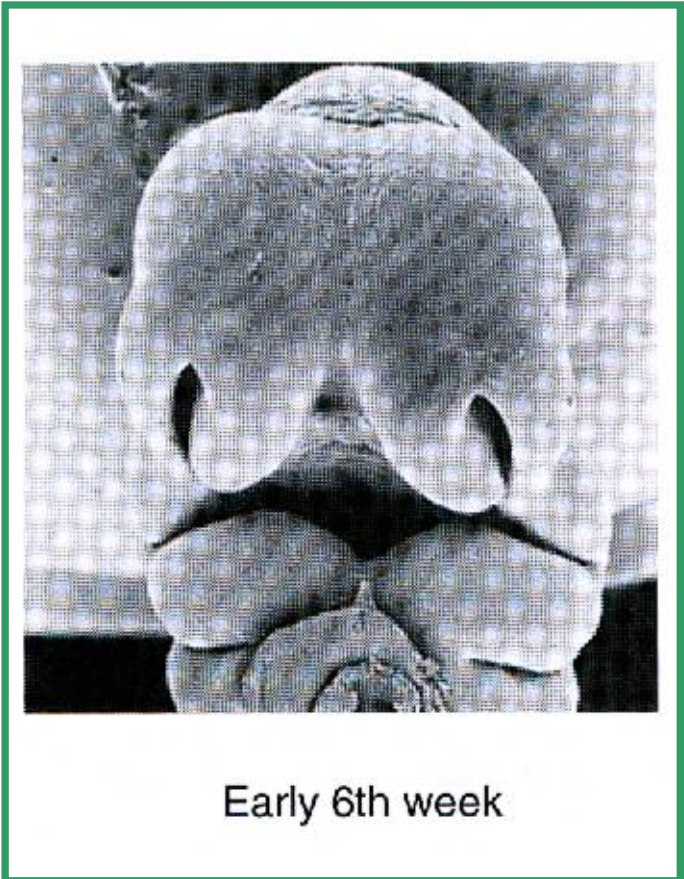
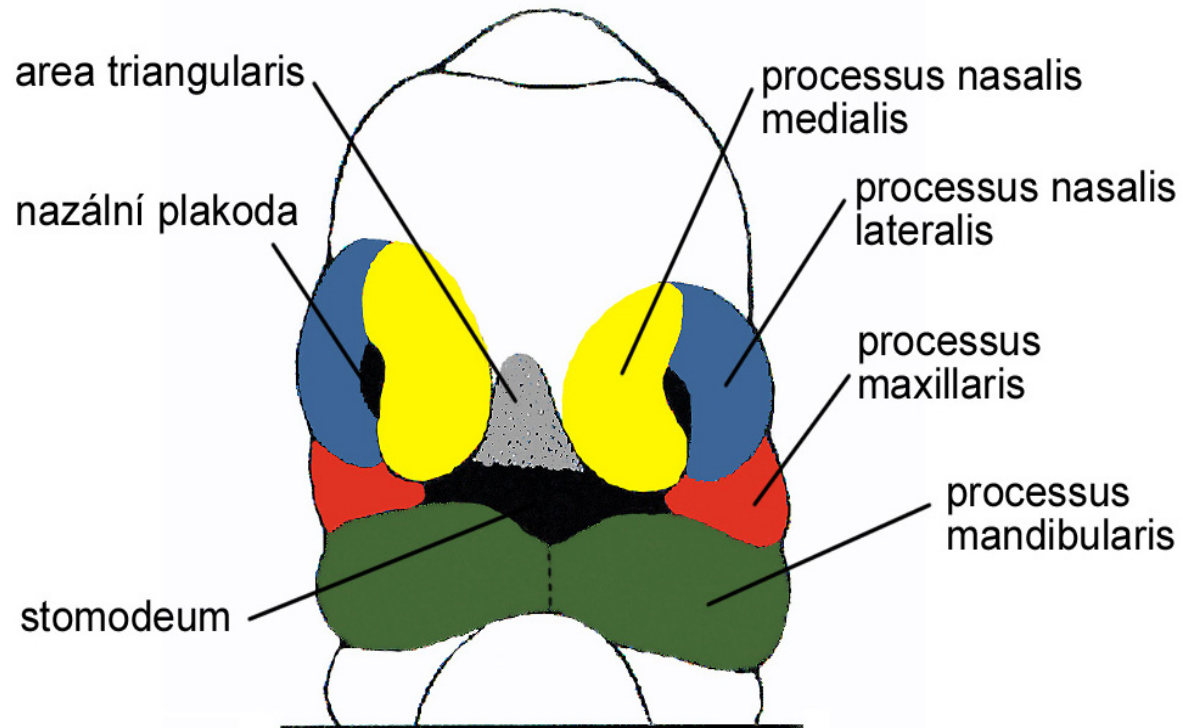


After the formation of nasal pits the ectomesenchyme is divided into parts:

Processus nasalis medialis

Processus nasalis lateralis

*Triangular area between medial nose processes is called **area triangularis***



Intermaxillary segment

By the end of the **5th week**, the **medial nasal prominences fuse with each other to form the intermaxillary segment**

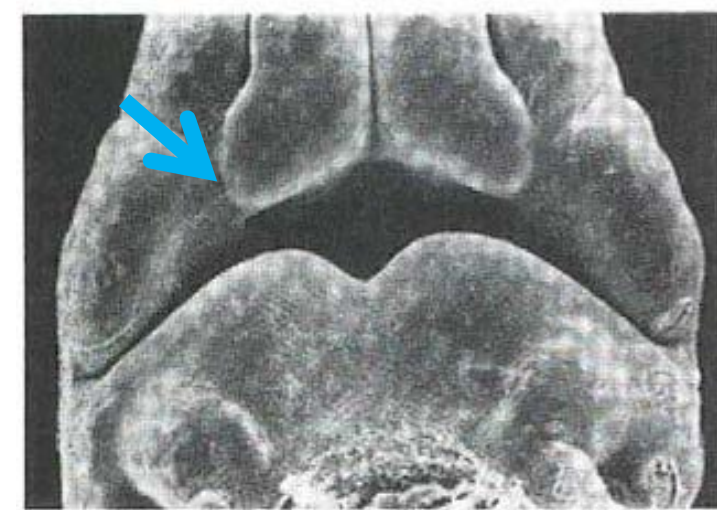
The segment proliferates caudally and inserts between ends of maxillary prominences which merge with it during the **6th week**

The intermaxillary segment gives rise to:

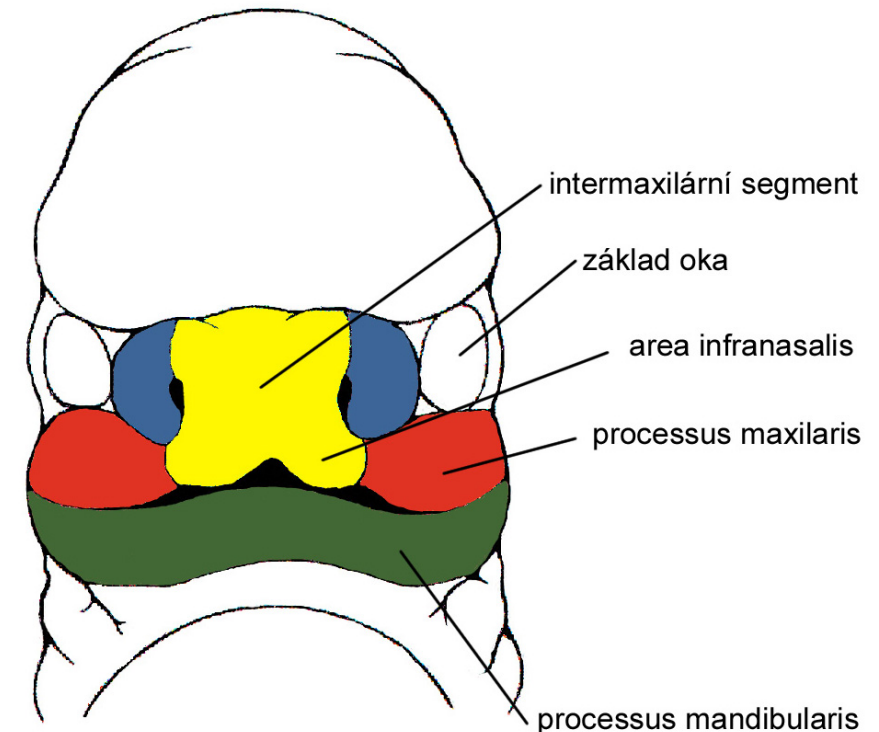
- a) middle portion of the upper lip, or philtrum
- b) the premaxillary part of the maxilla
- c) the primary palate

At first, lateral nasal prominences are separated from the maxillary prominences by a furrow, called the **nasolacrimal groove**

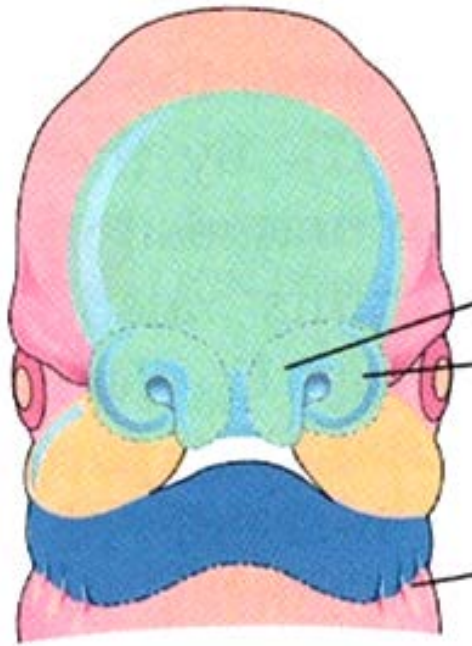
During next days, the maxillary prominences enlarge and fuse with lateral nasal prominences.



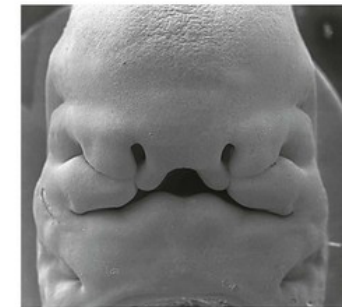
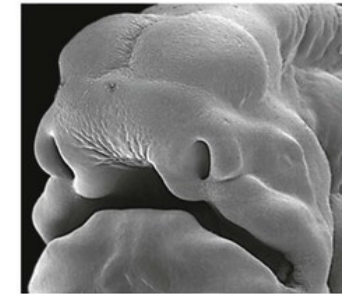
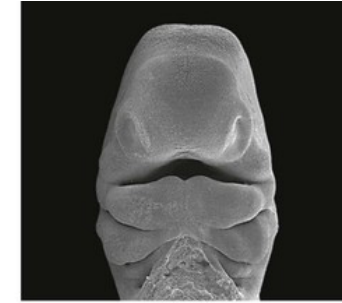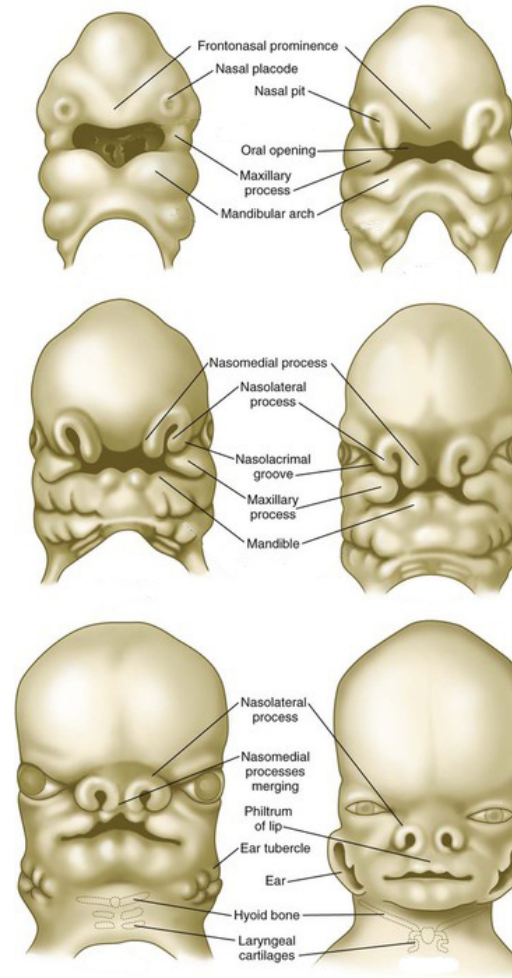
Early 7th week



Face development



35 days

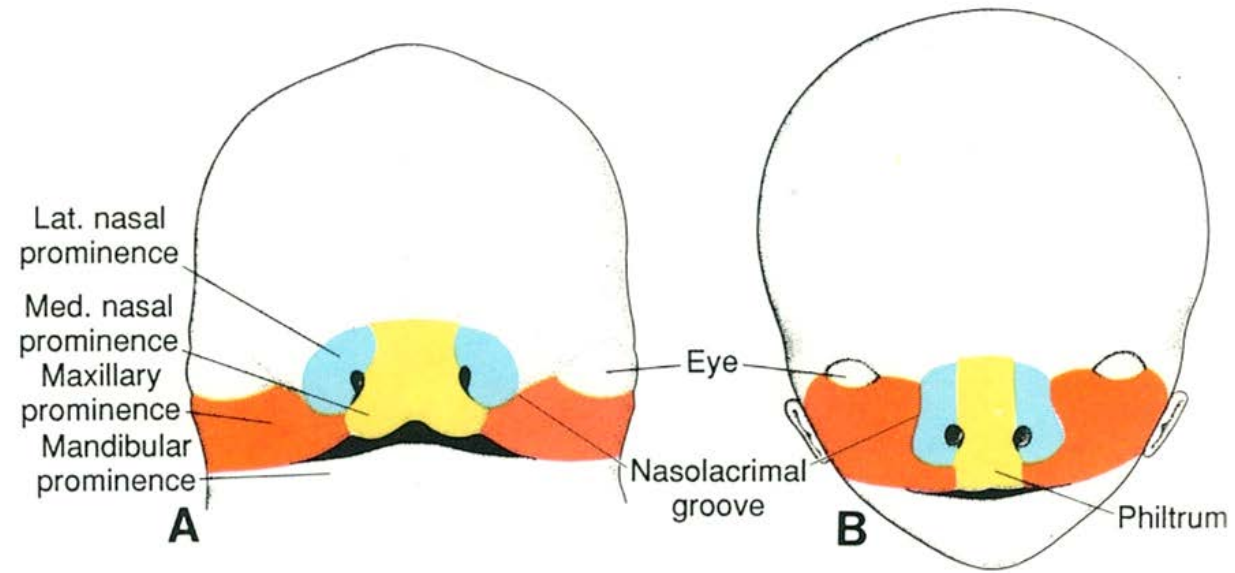


Maxillary prominences fuse with:

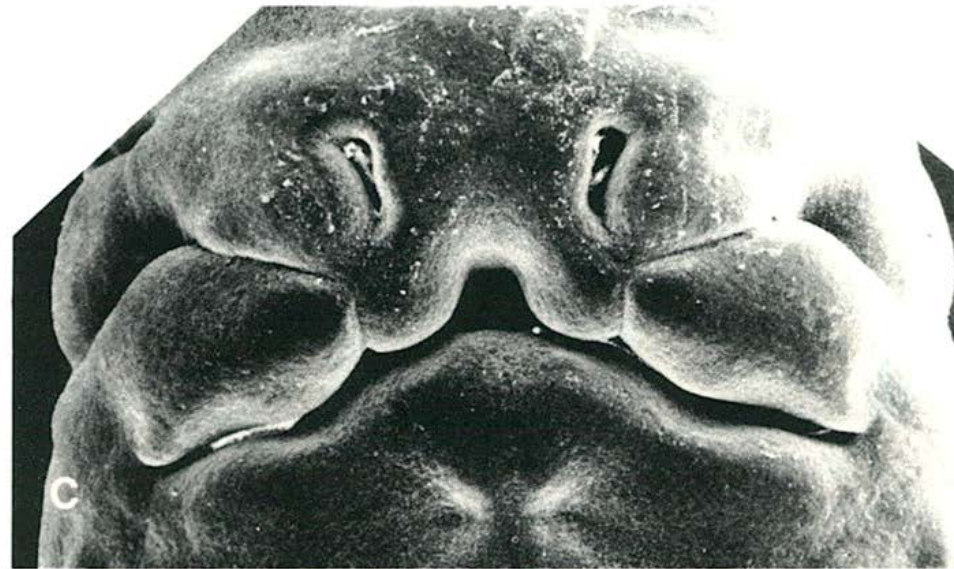1. **Intermaxillar segment** (formation of upper lip and palate)
2. **Lateral nasal prominences** (the rest of upper lip and part of nose)

Lateral nasal prominences are divided from the maxillary prominences by - **sulcus nasolacrimalis**

Face development



7th week



Summary of face development timing

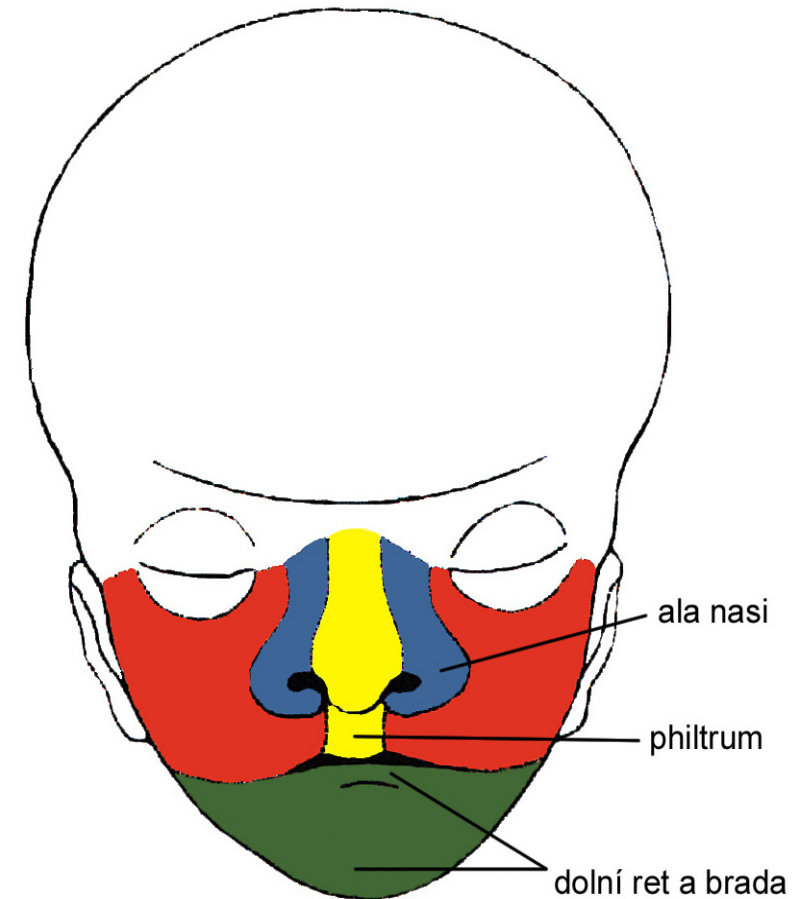
Between **5. - 7. week**

Beginning of 5th week: fusion of medial edges of mandibular prominences: **lower lip and chin**

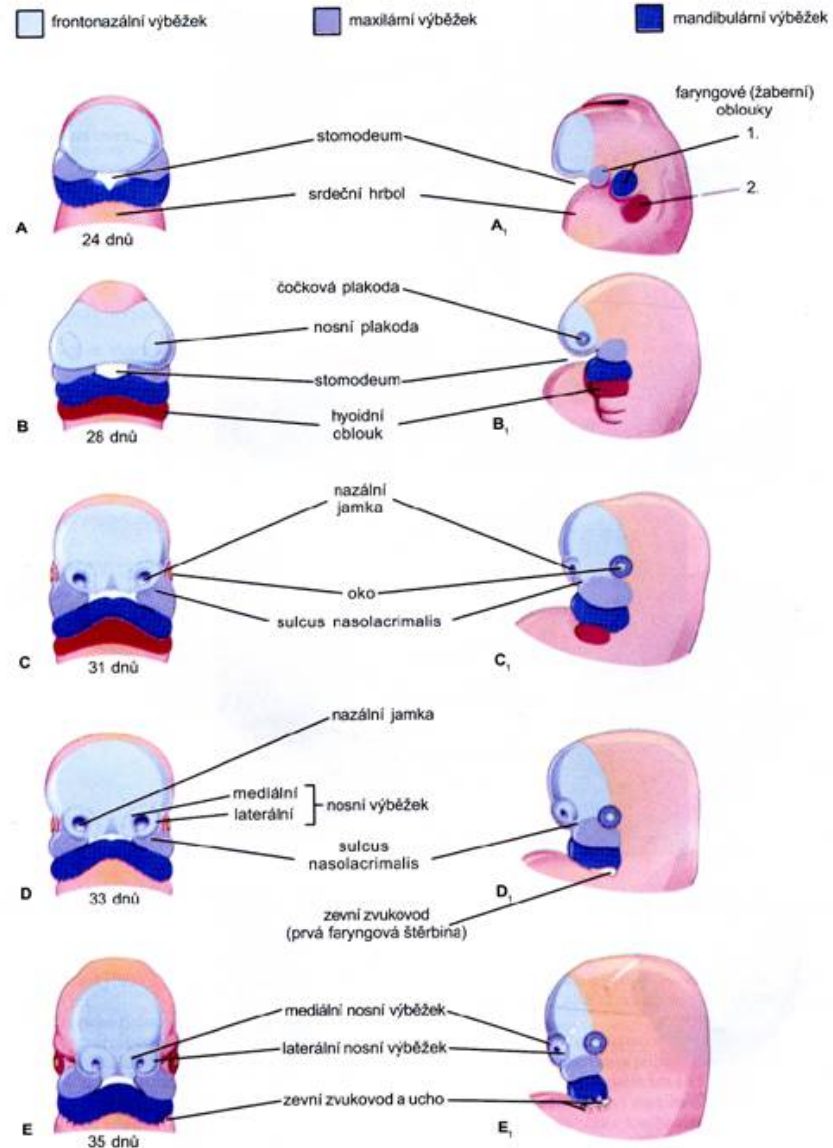
Beginning of 6th week: fusion of medial edges of maxillary prominences with intermaxillary segment: **upper lip**

In the middle of 7th week: processus nasalis lateralis (at both sides) fuse with the upper part of maxillary prominence

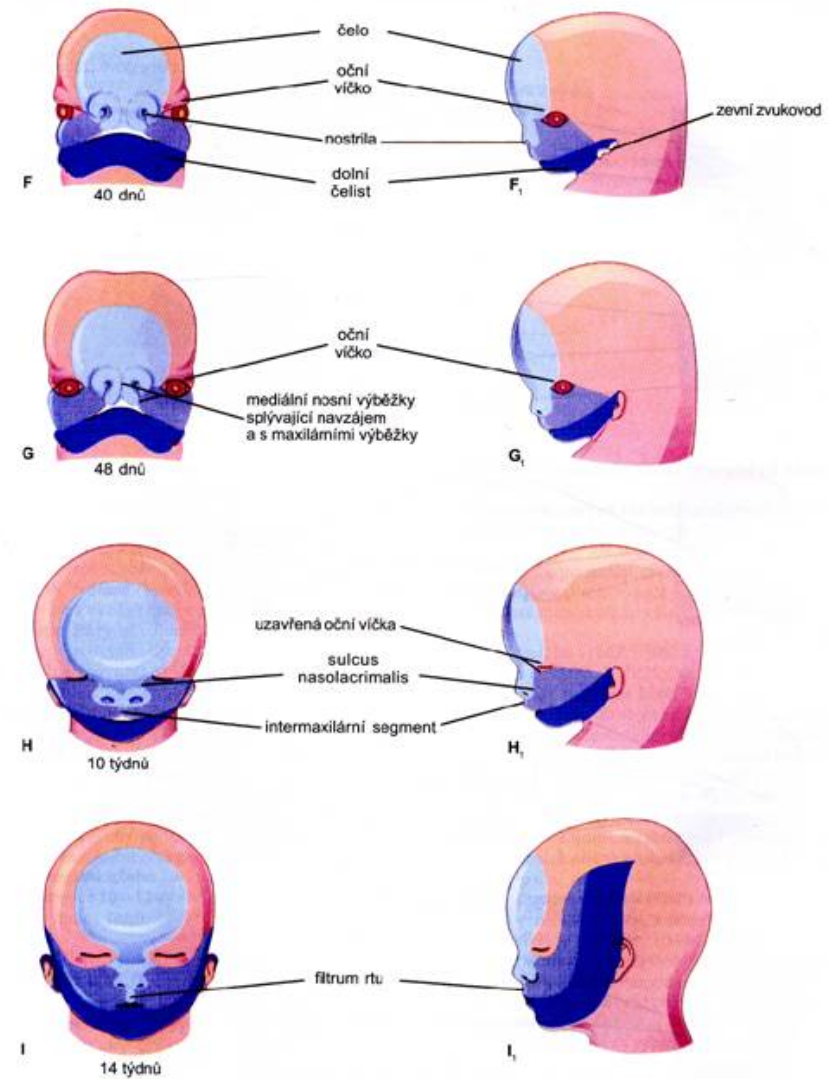
Between 7th-8th week: the fusion of maxillary and mandibular processes: narrowing of **rima oris**



Face development - summary



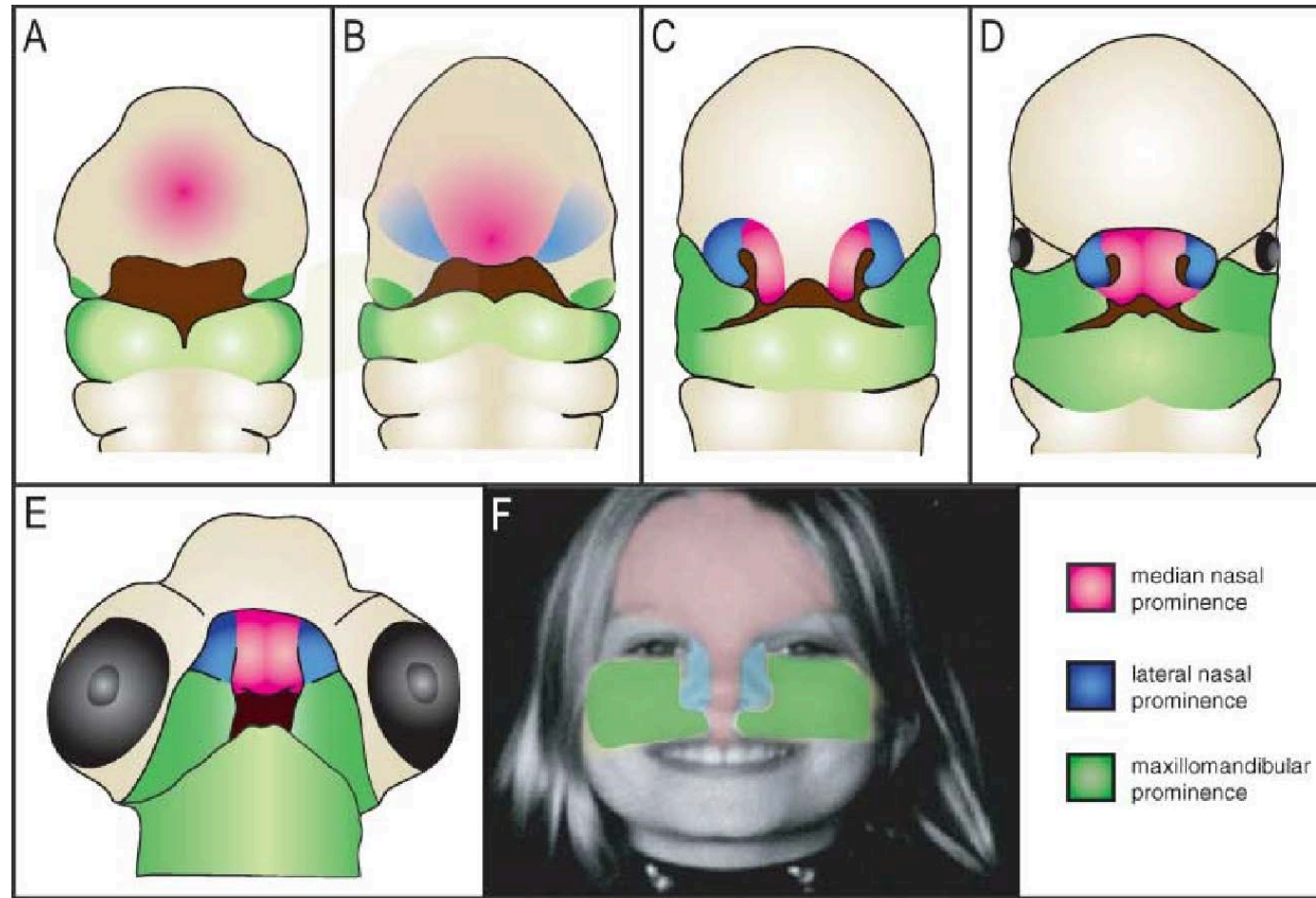


Obr. 10-26. Schémata zobrazující stadia vývoje lidského obličje.
 Ilustrace pokračuje na příští stránce



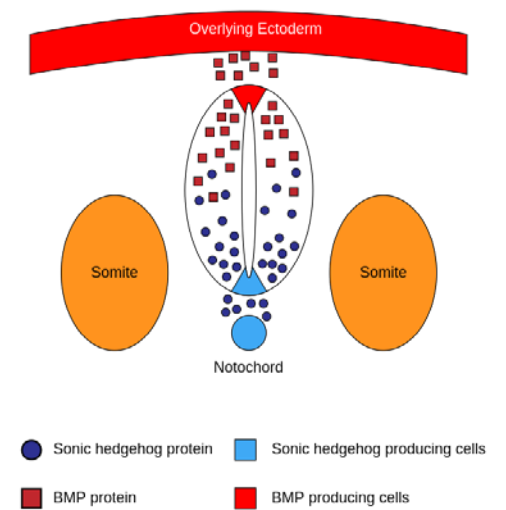
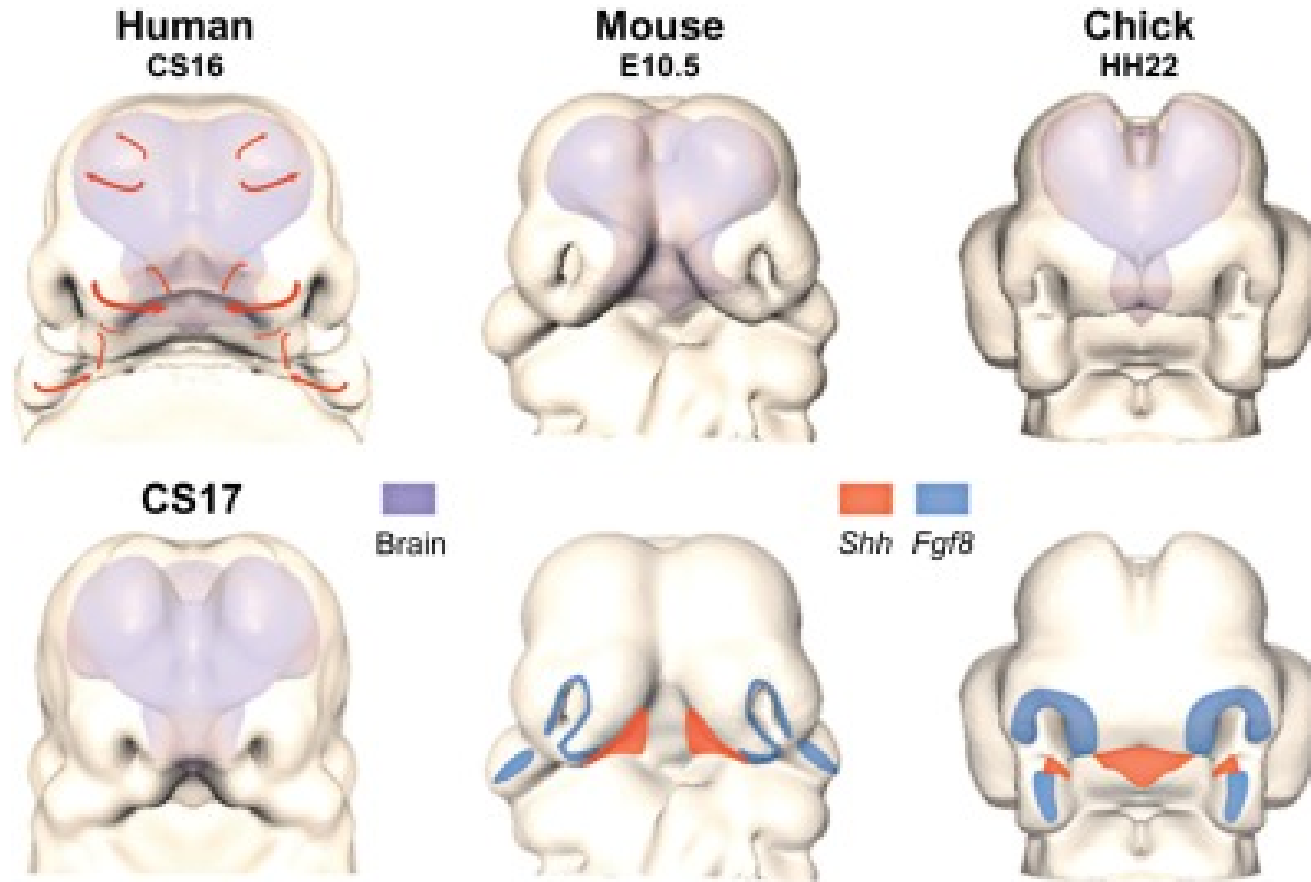
Obr. 10-26. Pokračování

Face development

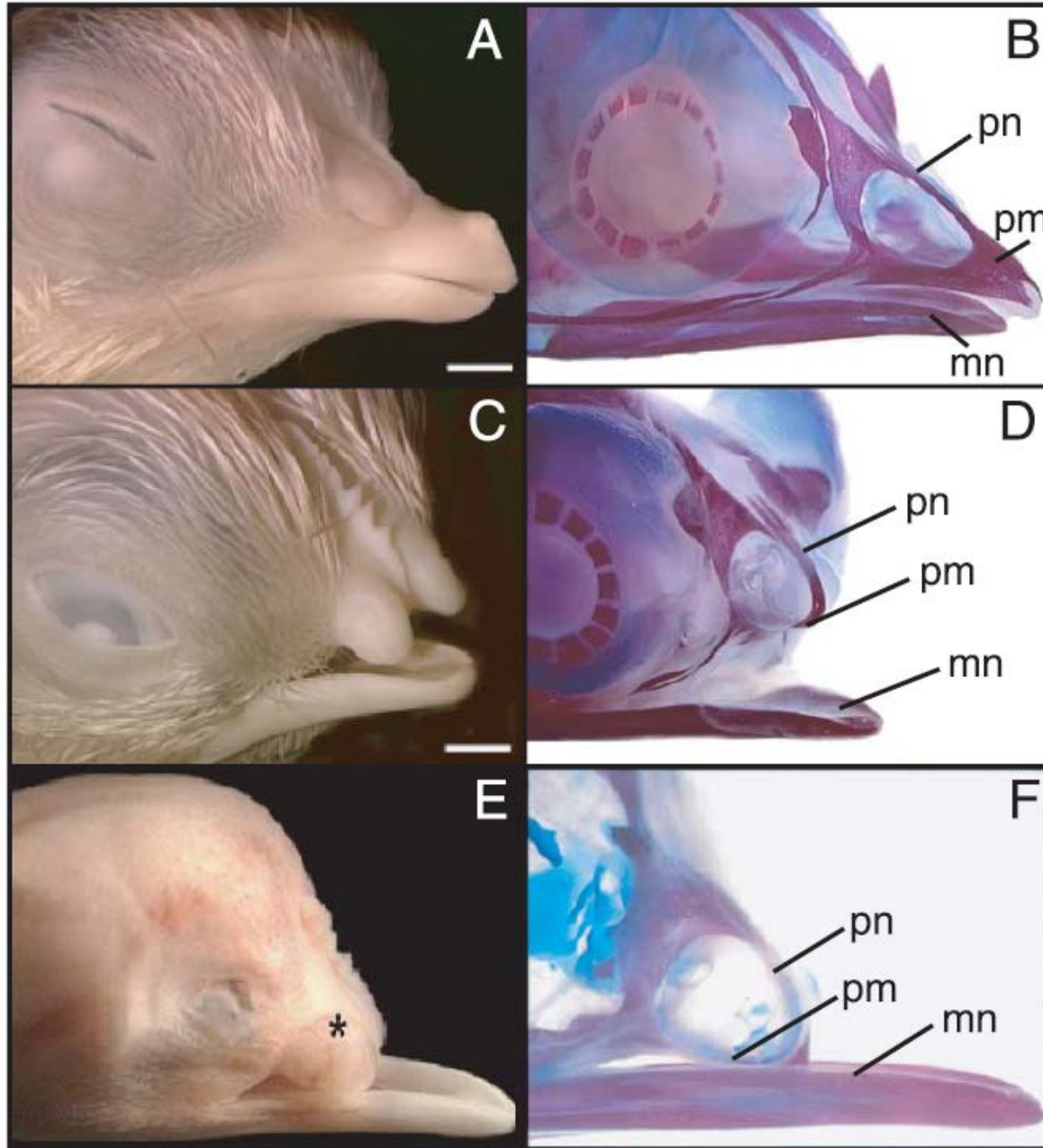


Shh a FGF

Face development – Shh (Sonic Hedgehog)



Face development



Normal

Cyclopamine (teratogen)

anti-SHH Ab

Orofacial clefts

Clefts emerge when the development of prominences was incorrect: **prominences did not fuse, were not established, belated migration or proliferation**

Facial clefts belong to the most common defects

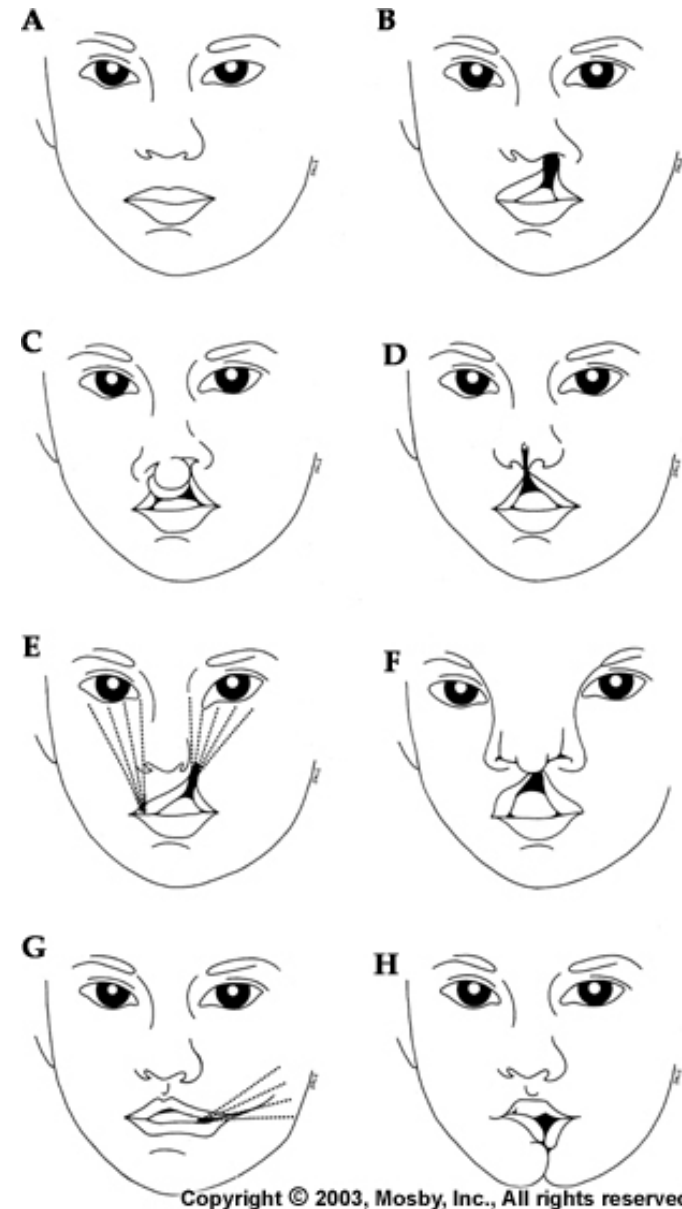
Incidence: 1,7 : 1 000 newborns

Clefts of the upper lip

Median clefts of the lower lip and chin (mandible)

Oblique facial clefts

Lateral, or transverse, facial clefts



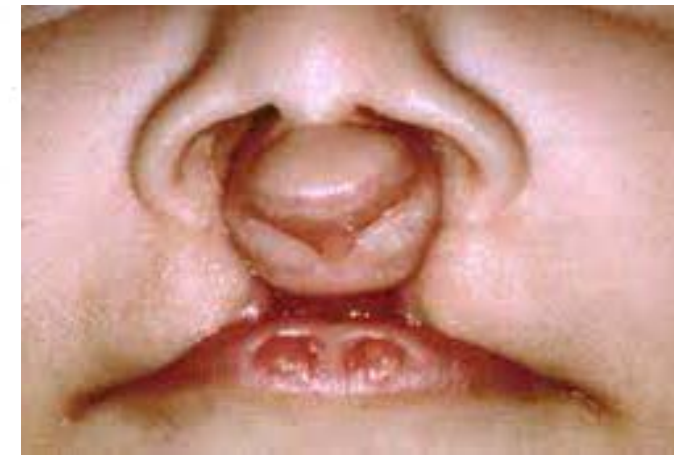
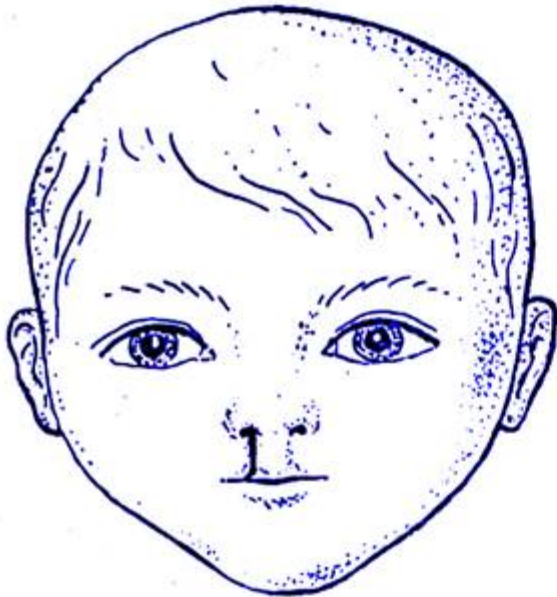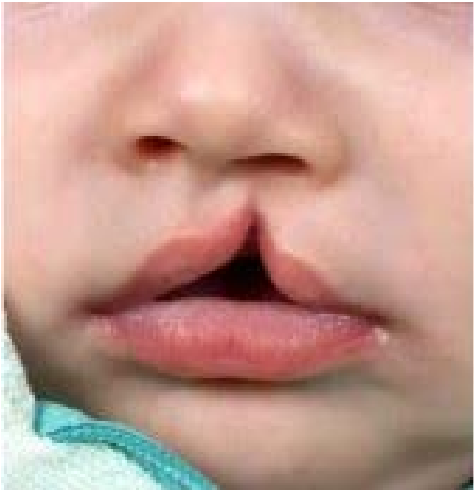Clefts of the upper lip - cheiloschisis superior

Lateral or medial

Lateral:

- **Unilateral cleft lip** - results from failure of maxillary prominence to merge with the lateral edge of intermaxillary segment on the one side
- **Bilateral cleft lip** - results from failure of mesenchymal masses of both maxillary prominences to merge with lateral edges of intermaxillary segment

cheiloschisis unilateralis / cheiloschisis bilateralis

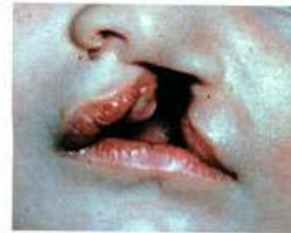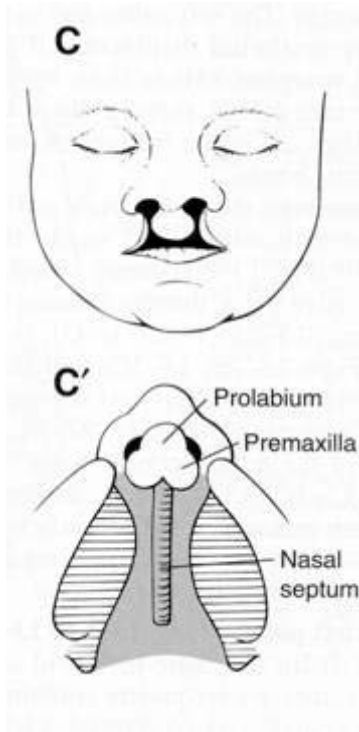

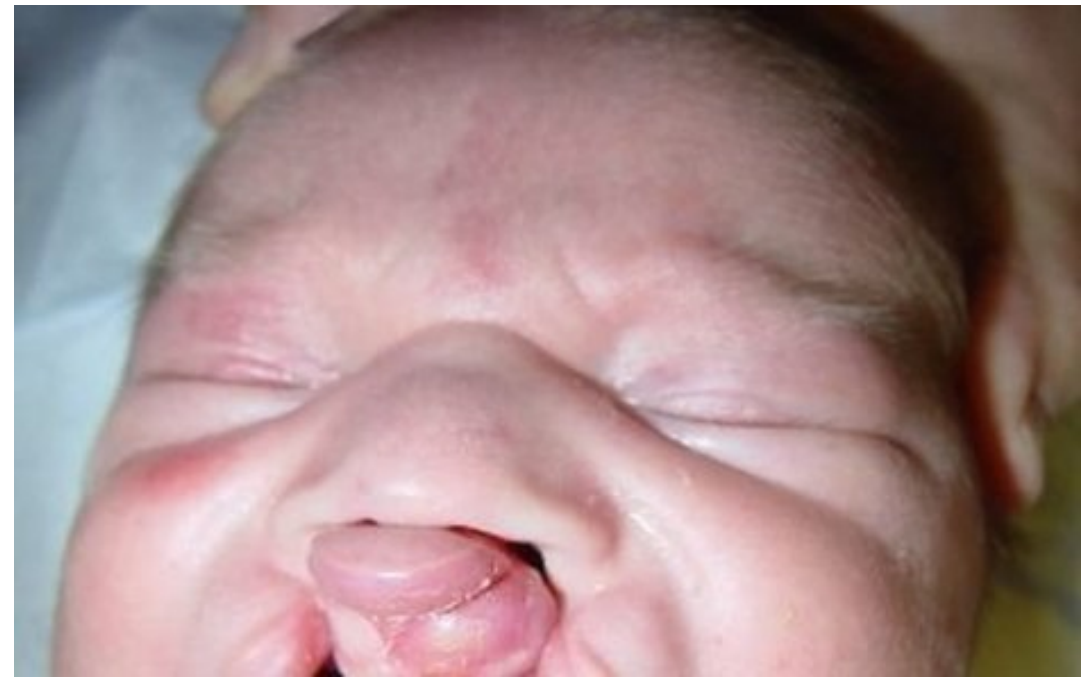
(Bi)lateral clefts of the lip and palate

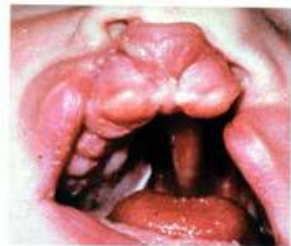Bilateral clefts of the lip and maxilla are very hard defect

Clefts can be uni and bilateral

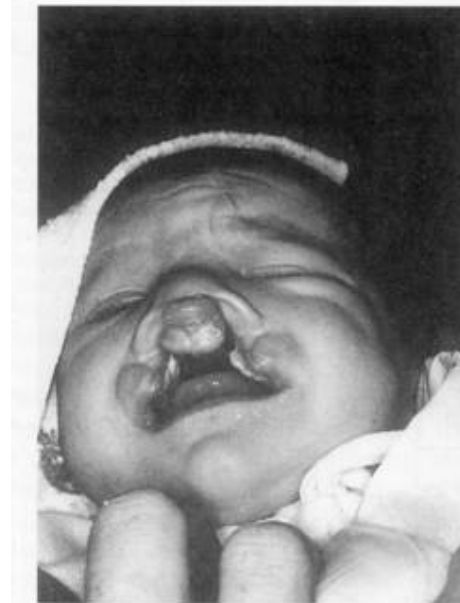The child can not suck and is in danger of aspiration of food



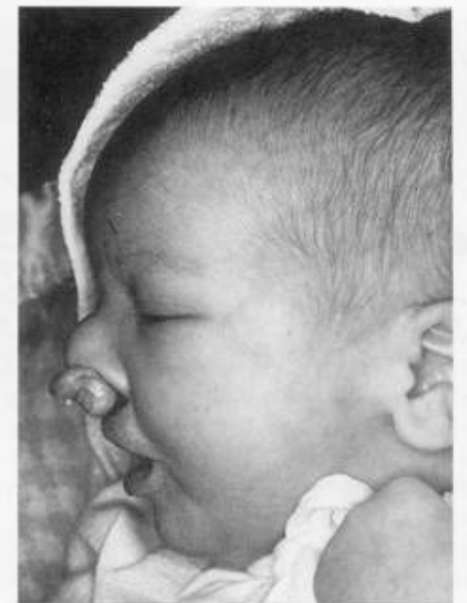Unilateral cleft lip.



Bilateral cleft lip.



A



B

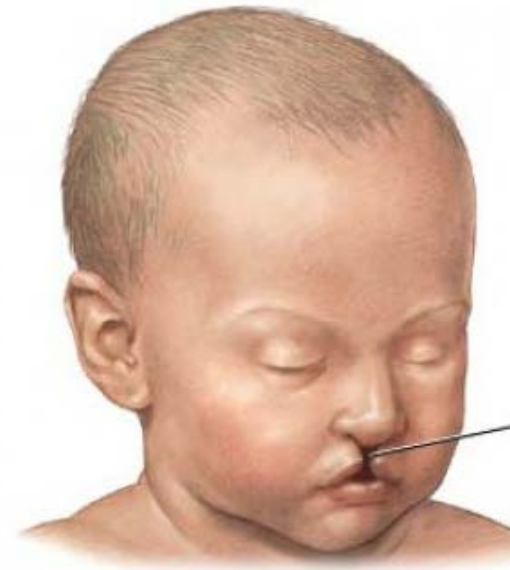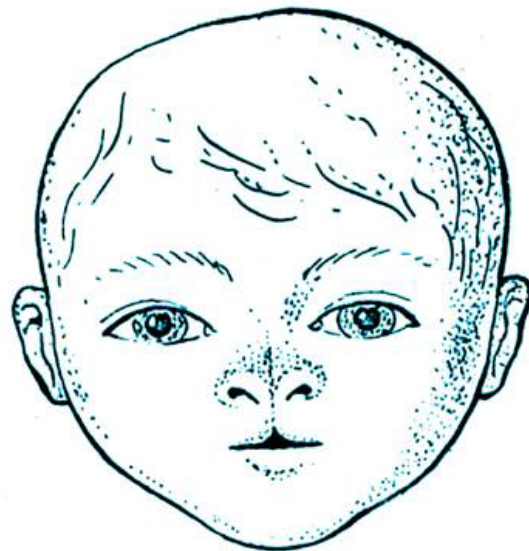
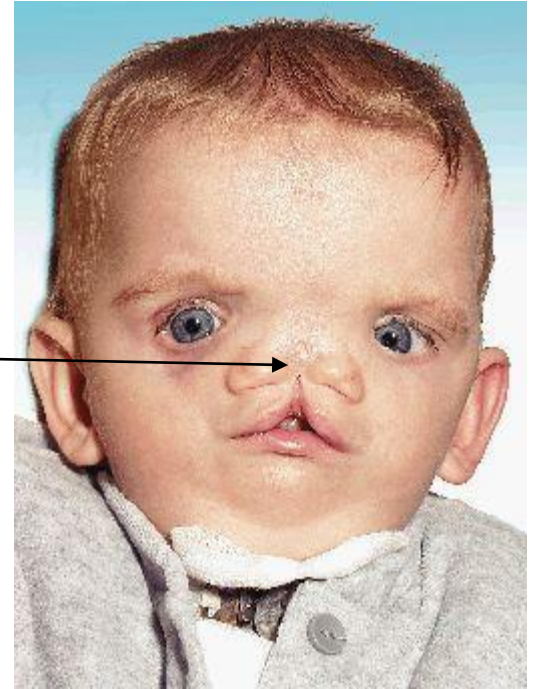
Median cleft lip (labium leporinum) cheiloschisis mediana

Is caused by delay in development of intermaxillary segment due failure of the medial nasal prominences (processus nasales mediales) to merge

Rarely with the cleft of apex nasi
Variable

Critical period: 27. - 35. day

The median cleft lip is one of symptoms of the **Mohr syndrome**



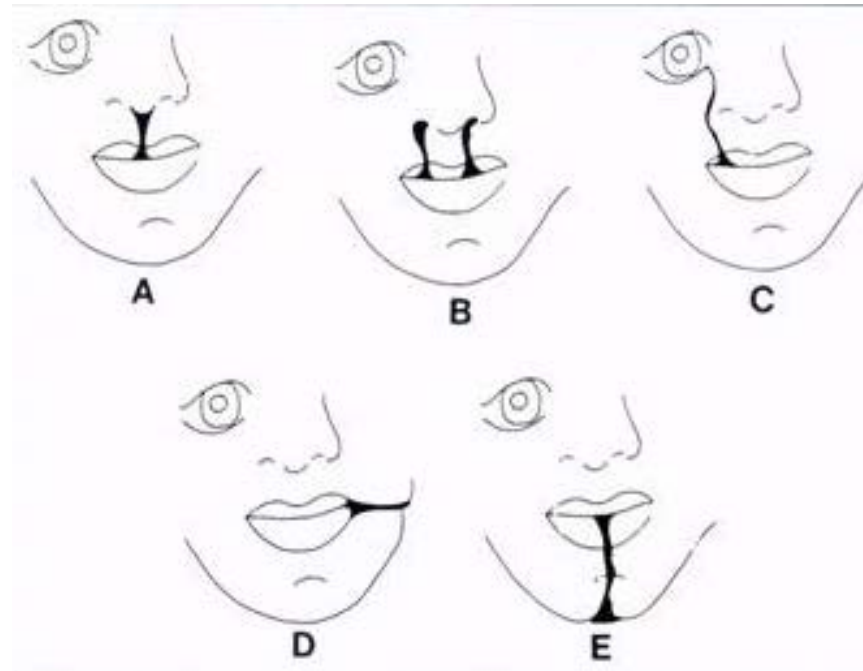
Oblique facial cleft (coloboma faciale, fissura orbitofacialis)

Uni- or bilateral, arises if the nasolacrimal groove is preserved

Combined always with the unilateral lip cleft and extends to the medial margin of the orbit

Results from failure of the mesenchymal masses of the maxillary prominences to merge with lateral and medial nasal prominences

rare

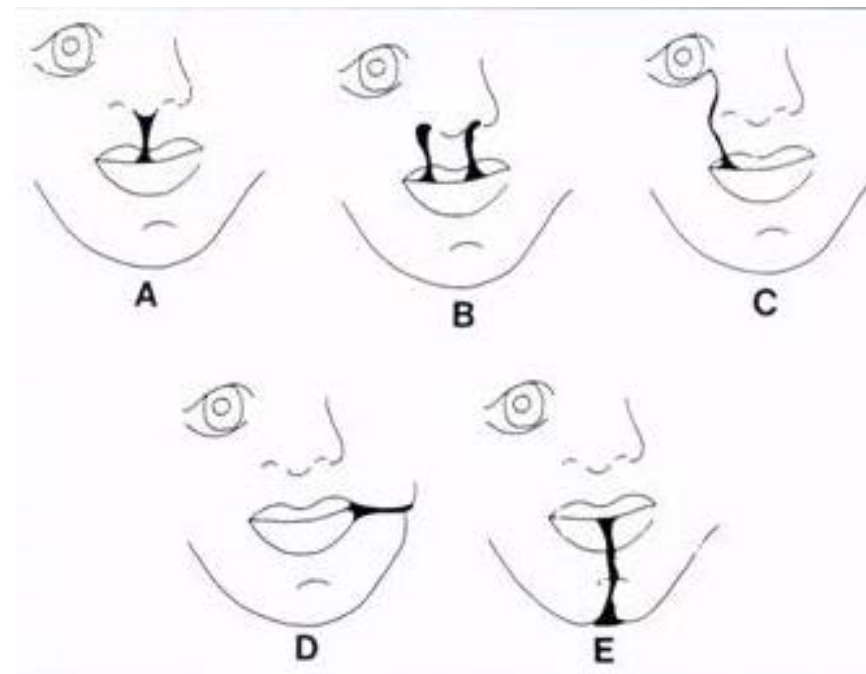
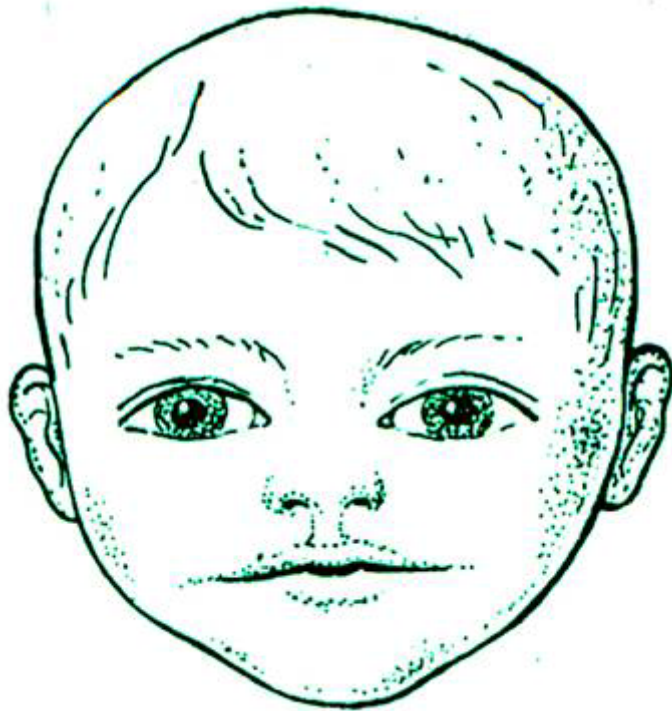

Lateral/transverse facial cleft fissura transversa faciei, macrostomia

Runs from the mouth toward the ear

Bilateral clefts results in a very large rima oris (macrostomia or „frog mouth“)

Results from failure of the lateral parts of the maxillary and mandibular prominences to merge
very rare

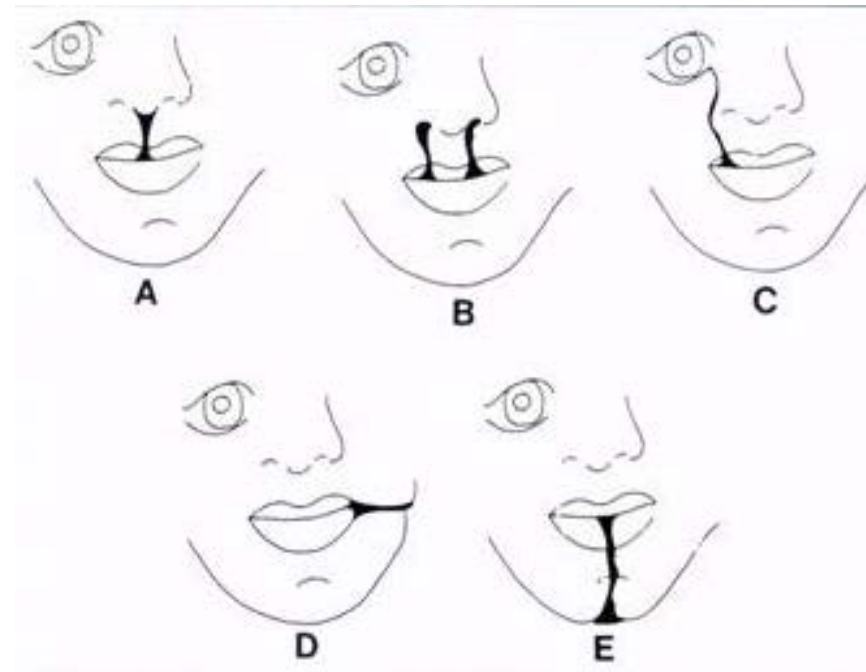



Median cleft of the lower lip and chin (mandible) cheiloschisis et gnathoschisis inferior

Cleft resulting from failure of the mesenchymal masses of the mandibular prominences to merge completely with each other

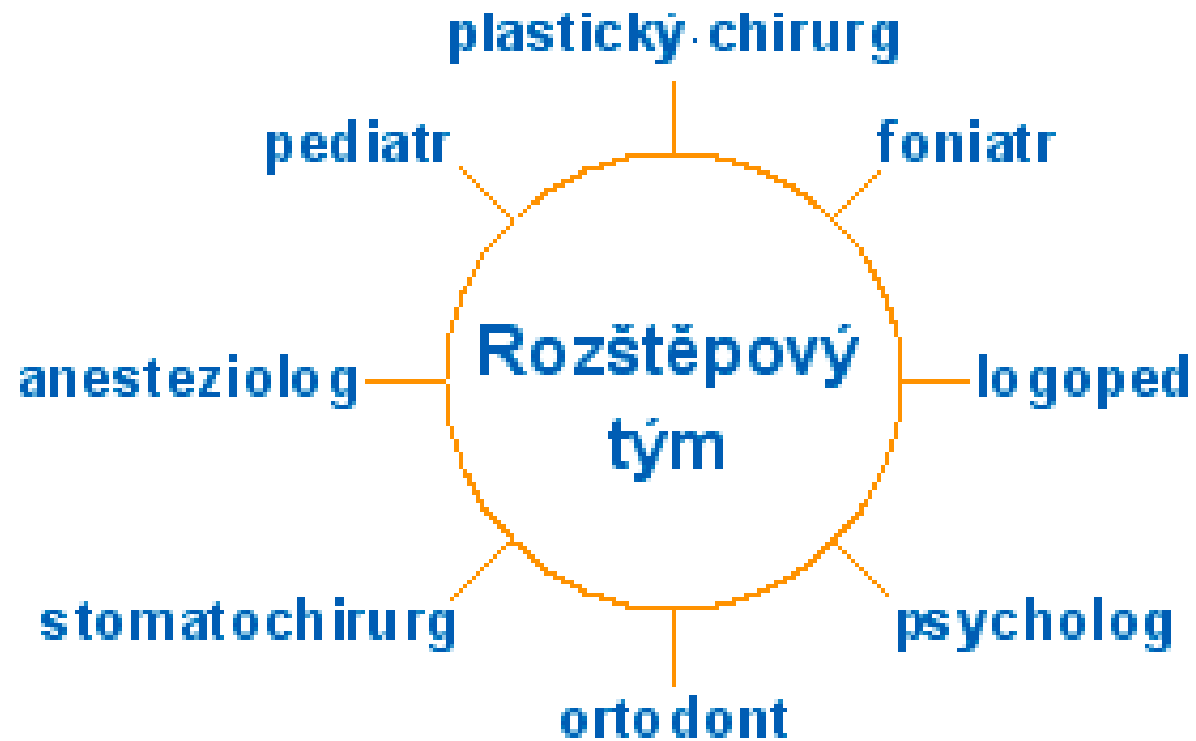
Always connected with cleft of the mandible and tongue

rare



Treatment: a comprehensive approach (cleft teams)

plastic surgeon, dentist - orthodontist, phoniatrist / anthropologist, event. psychologist



Development of oral cavity

Oral cavity develops from the stomodeum or primitive mouth

5 processes limit the stomodeum:

frontonasal prominence

paired maxillary prominences (processus maxillares)

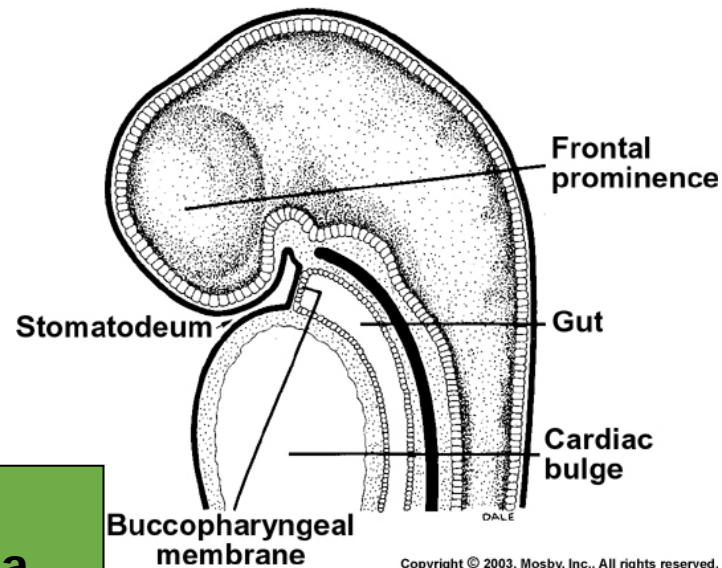
paired mandibular prominences (processus mandibulares) on sides

Stomodeum communicates with the body surface via primitive oral entrance

Bottom of the stomodeum - oropharyngeal membrane (membrana oropharyngea)

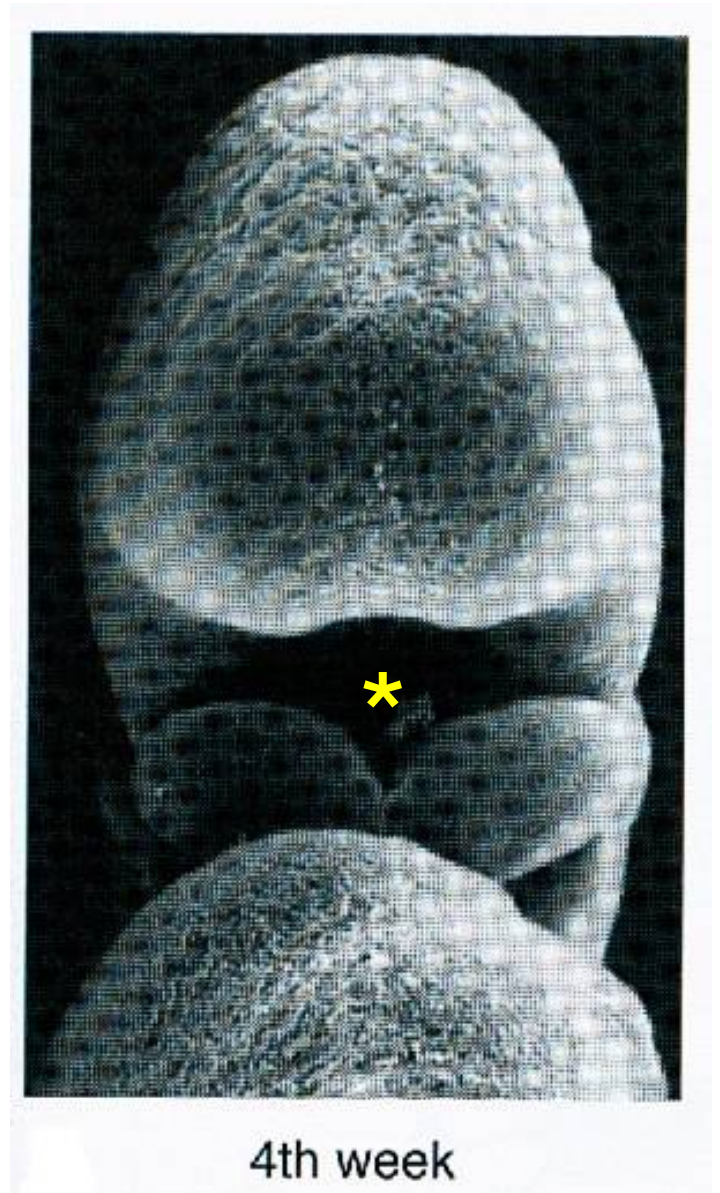
When the oropharyngeal membrane ruptures, the stomodeum becomes continuous with the foregut

Roof of the stomodeum consists of a mesenchyme and ectoderm of the frontonasal prominence



**membrana
oropharyngea**

Copyright © 2003, Mosby, Inc., All rights reserved.



Palatogenesis

Begins at the 7th week

Completed by the end of the 12th week

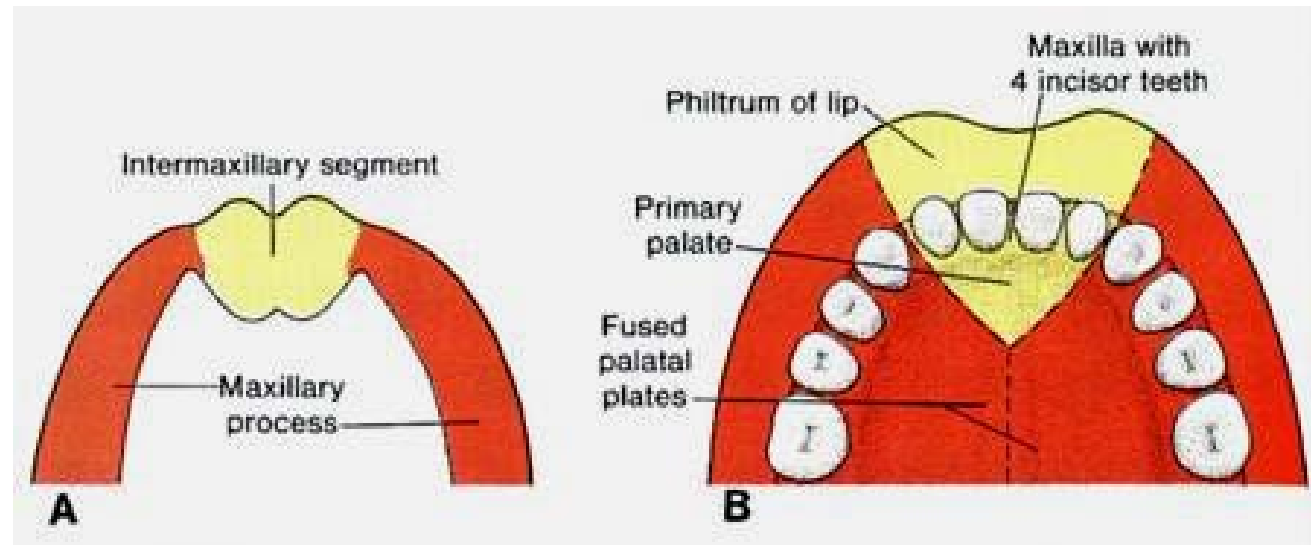
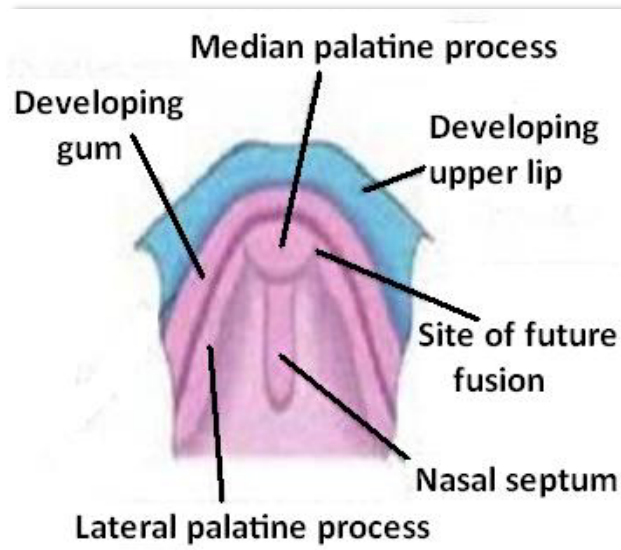
The most critical period for the development of palate is from the beginning of 7th week to the beginning of 9th week

3 primordia:

Unpaired medial palate process and **paired lateral palate processes** (palatal shelves)

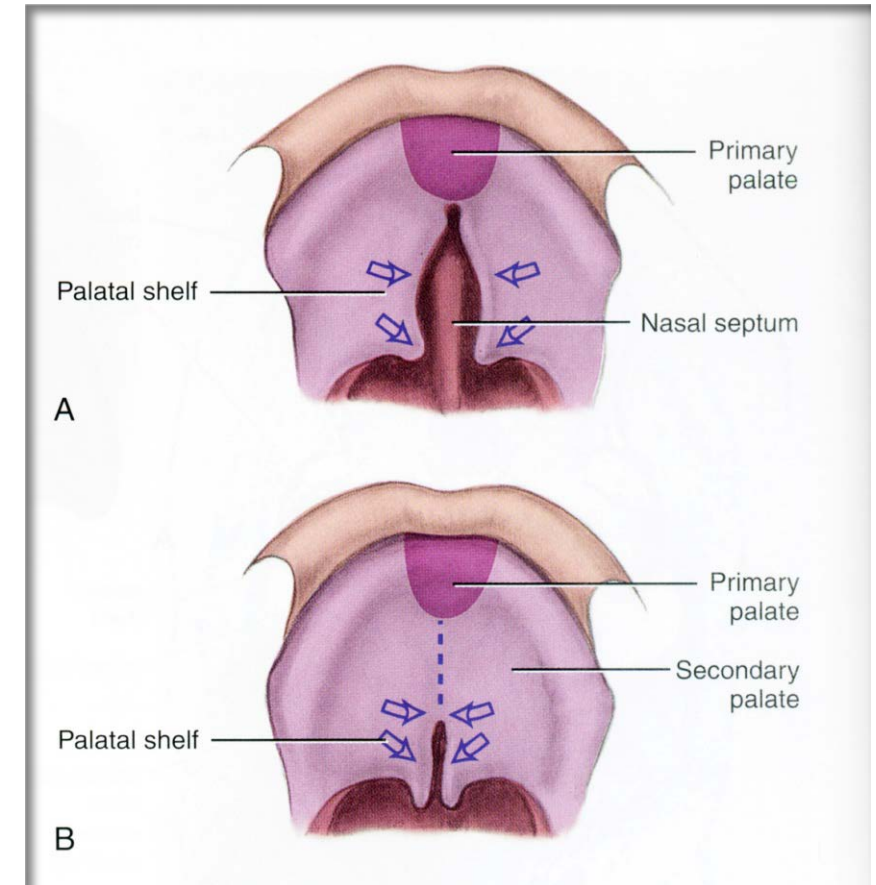
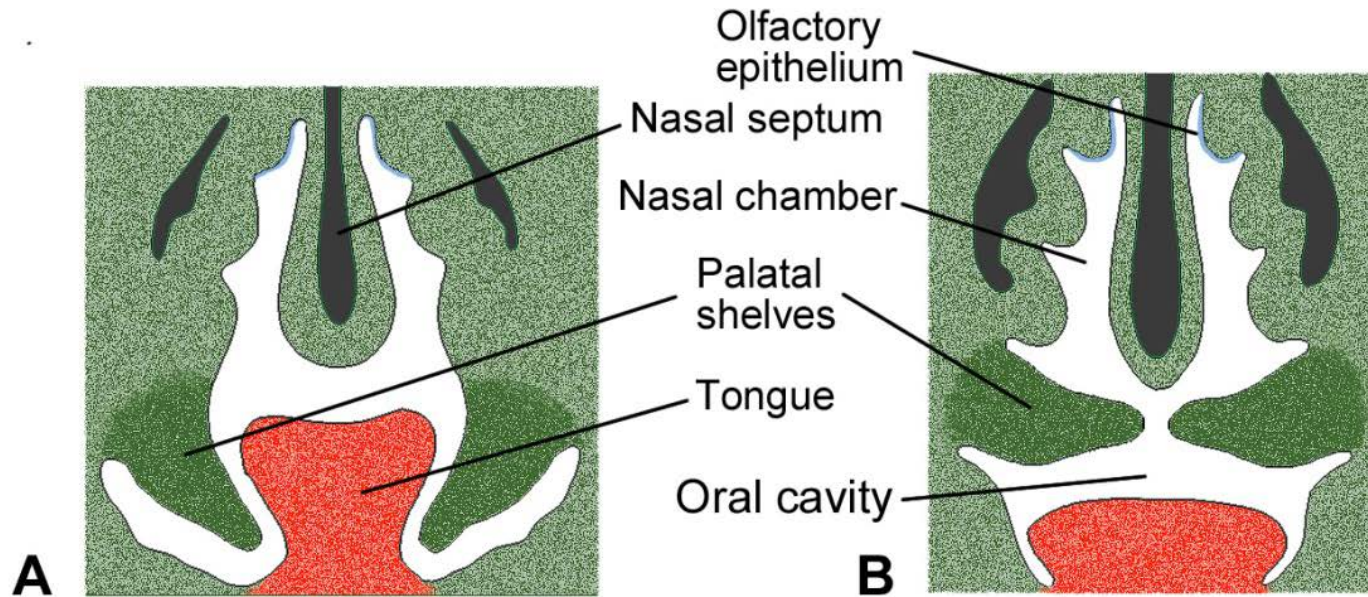
a) The medial palate process

Grows from the dorsal side of the intermaxillary segment at the end of the 5th week and gives rise to primary palate



Palatogenesis

b) Lateral palate processes - grow out from medial aspects of the maxillary prominences and give rise to the secondary palate
lateral palate processes are formed by mesenchyme, are covered by ectoderm and have shelf-like form (palatal shelves)



Palatal shelves initially grow in caudal direction and laterally along to primordium of the tongue later, due more rapid vertical growth of mandibular processes the tongue descends caudally

Palatogenesis

During the 10th week shelves meet in the midline to finally fuse

The site of fusion of both lateral palate processes is known as **raphe palati**

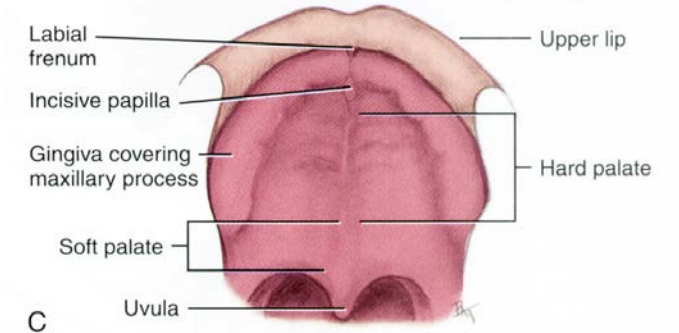
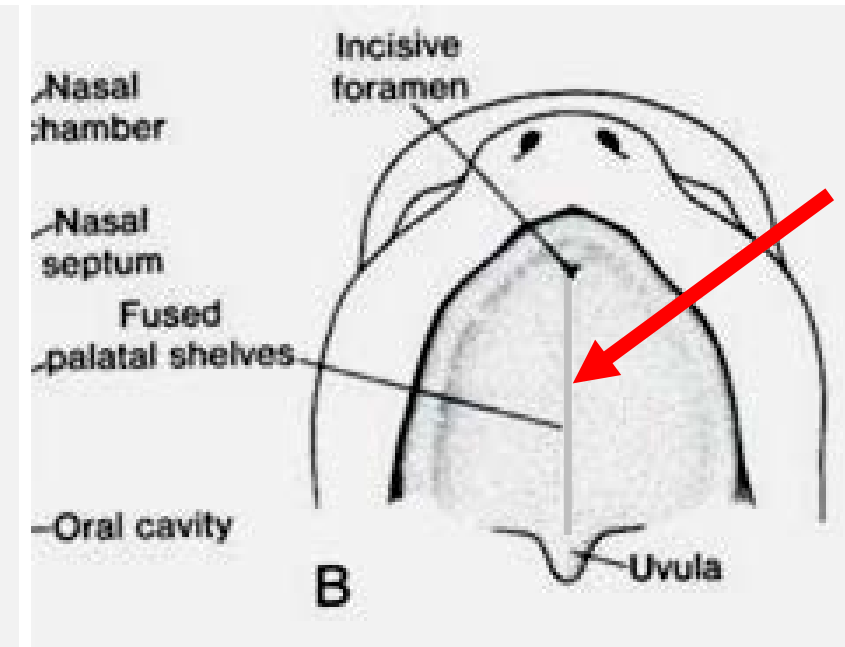
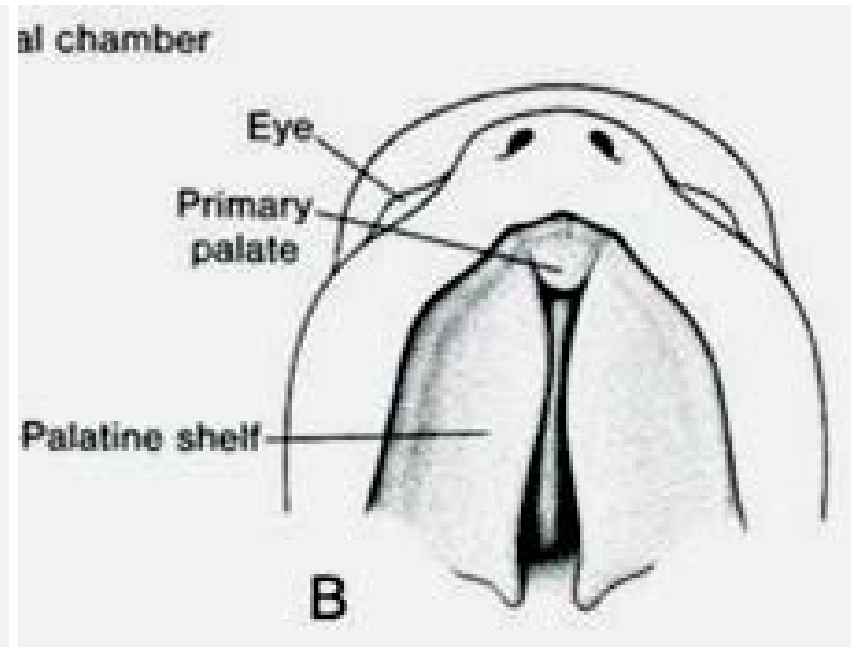
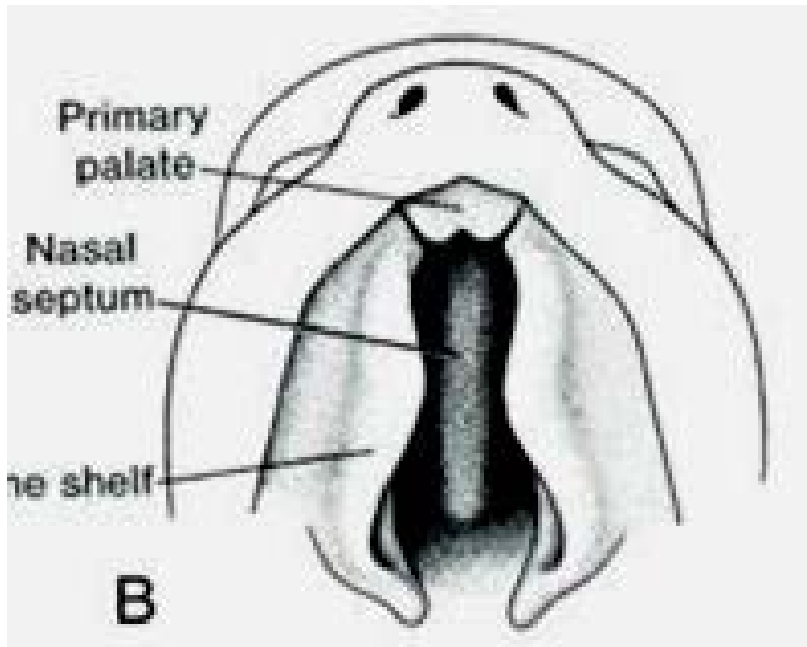


FIGURE 5-10 Later stages of nasal septum development showing its fusion with the final palate (A and B) in order to separate the nasal and oral cavities completely (C).



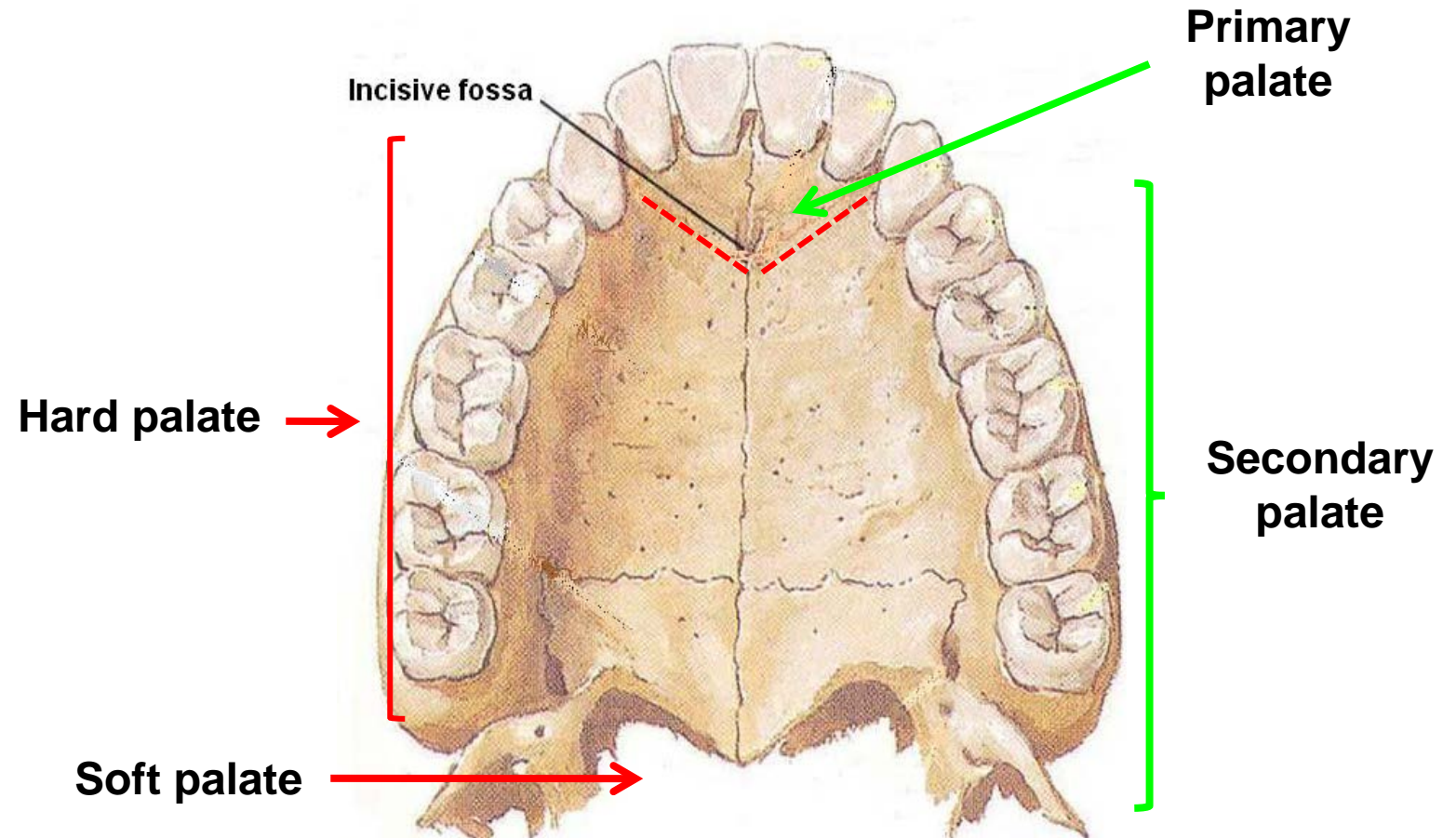
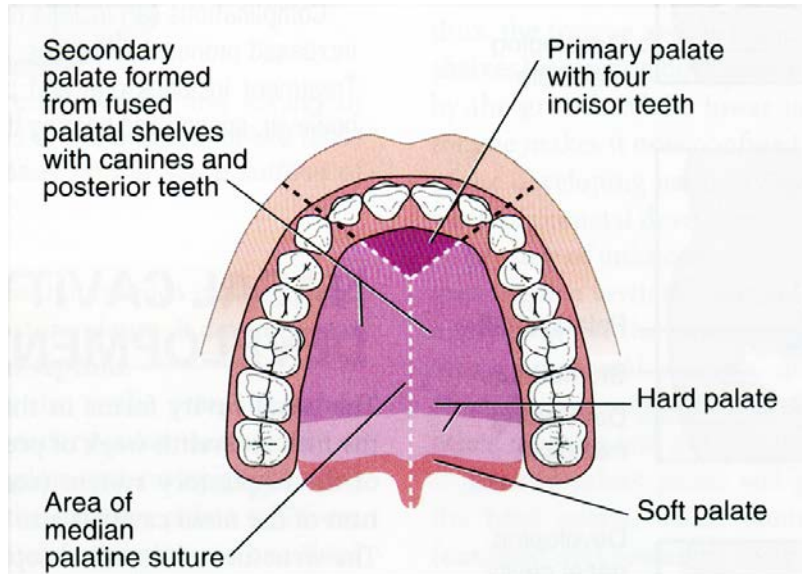
Palatogenesis

definitive palate originates by fusion of ventral edges of both lateral palatal shelves with the medial palate process

Line of fusion corresponds to the incisive canal (canalis incisivus)

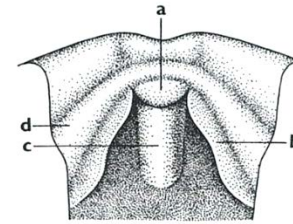
The region of medial palate process (primary palate) and ventral parts of lateral palate processes undergo endesmal ossification

The posterior portions of the lateral palate processes do not undergo ossification and give rise to the soft palate and uvula

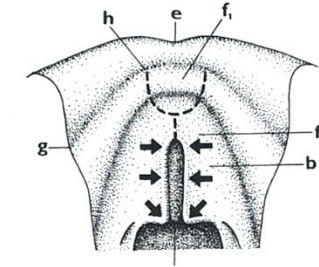


Palatogenesis

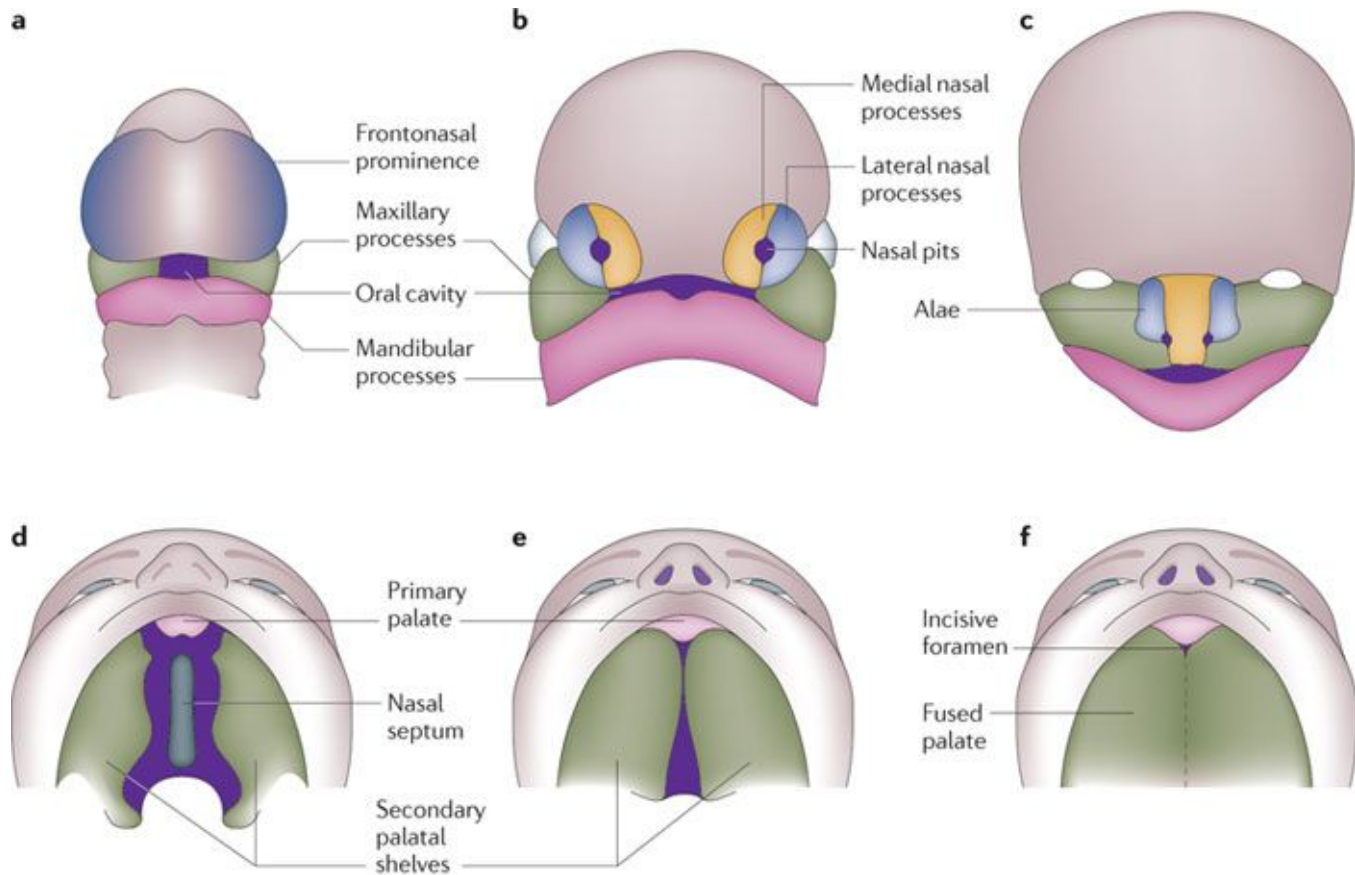
- **Primary palate** (intermaxillary segment)
- **Secondary palate** (lateral maxillary plates)



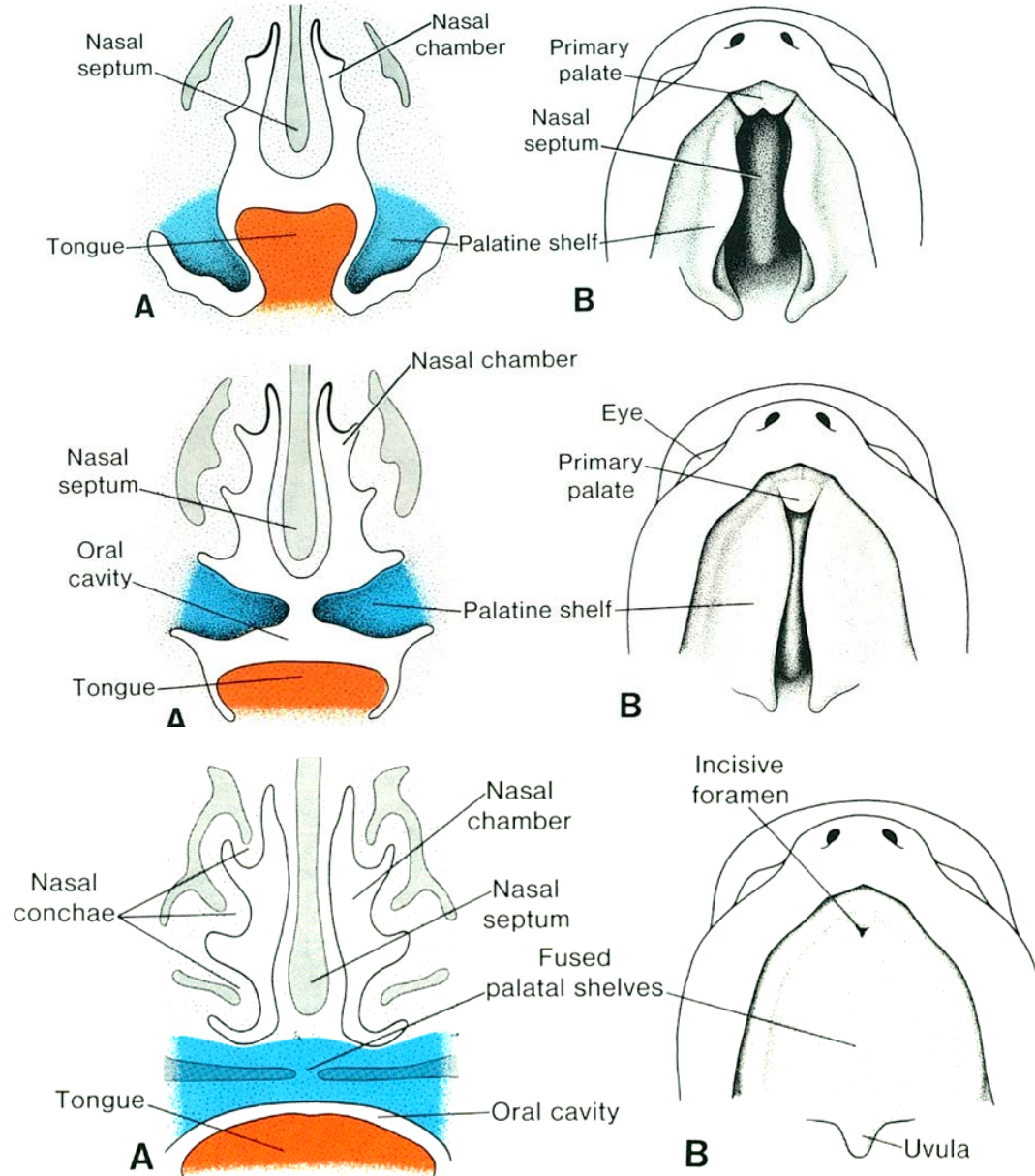
A



B



Palatogenesis



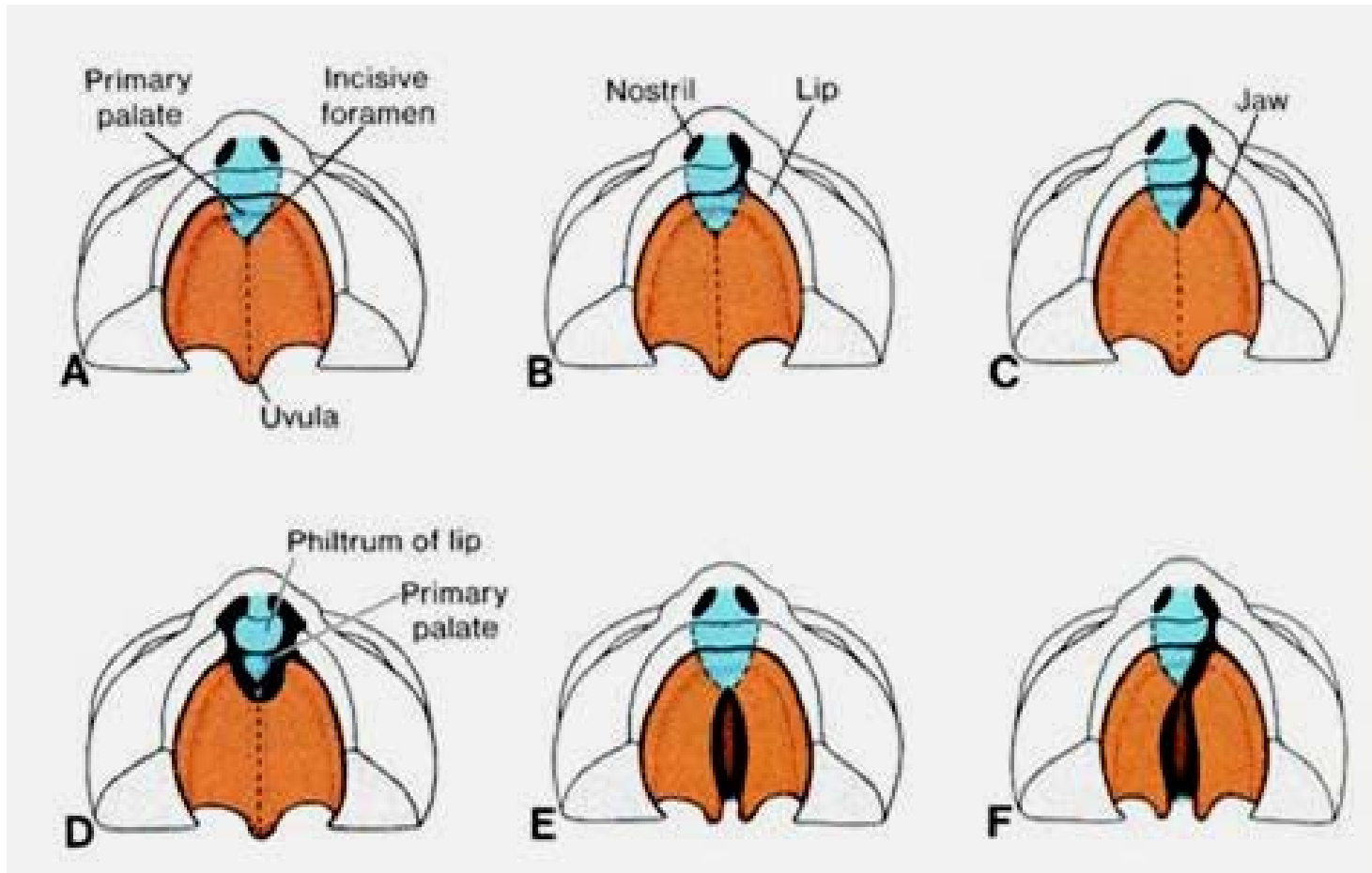
Palate clefts

Can be of isolated character or associated with clefts of the and upper lip

Complete or incomplete

unilateral or bilateral

The **incidence** of palate clefts is **1 : 2500** live births



Clefts of primary palate (C, D)

clefts of both primary and secondary palate (E)

clefts of secondary palate (F)

Clefts of primary palate (C,D)

Anteriorly to the incisive foramen

The primary and secondary palates are separated

Results from failure of fusion of lateral palatal shelves with the primary palate

Unilateral/bilateral

Clefts of both primary and secondary palates (E)

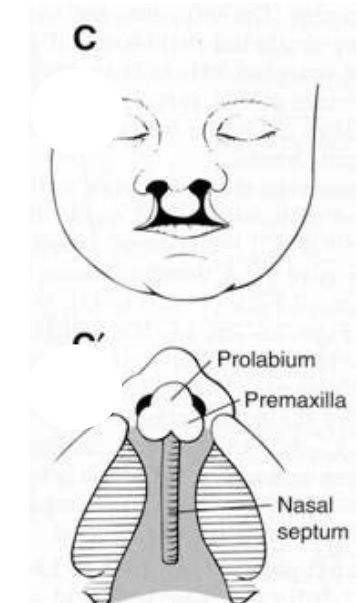
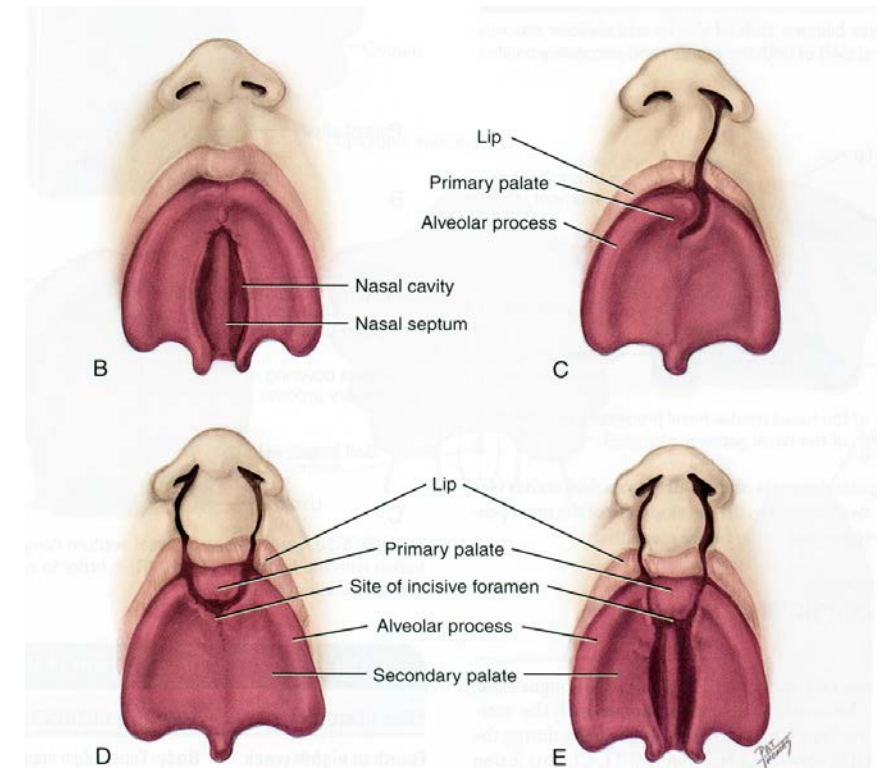
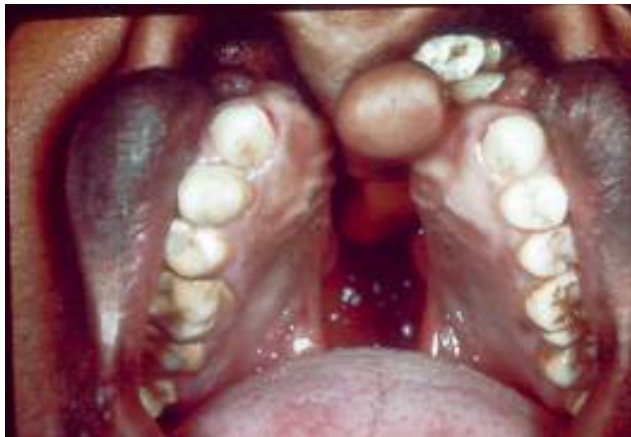Both anteriorly and posteriorly to the incisive foramen

Lateral palate processes are not fused and separated from the primary palate

The nasal septum is free

Usually associated with lateral cleft of the maxilla and upper lip -

cheilognathopalatoschisis unilateralis / bilateralis (very serious malformation)



Clefts of secondary palate (palatoschisis)

Posteriorly to the incisive foramen

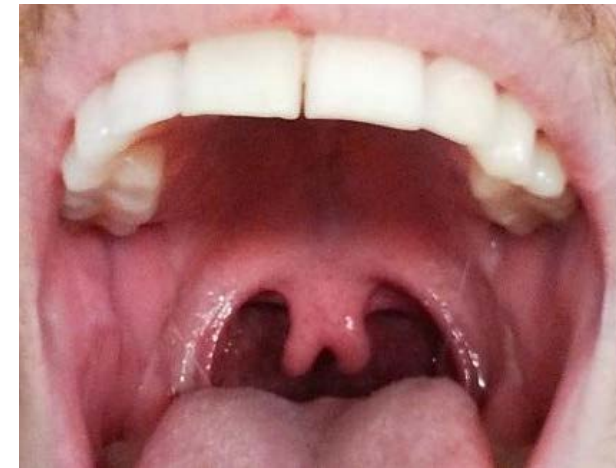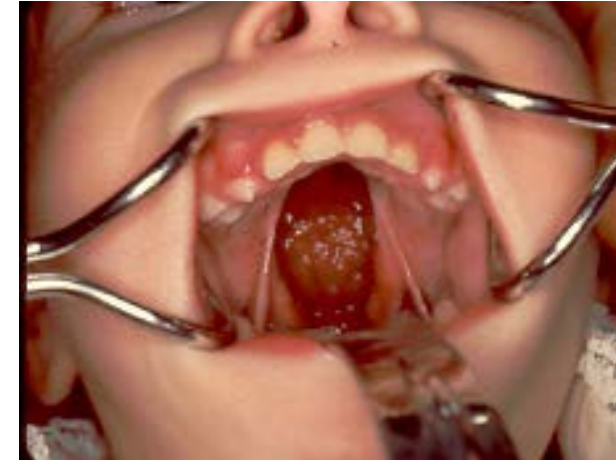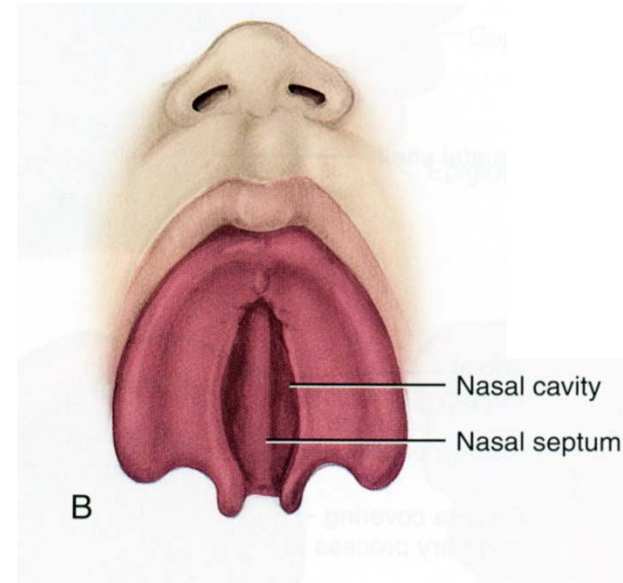
Cause: lateral palatine processes do not fuse

Affect the all sections of palate (hard, soft and uvula - staphyloschisis / uvula bifida)

Clefts of the secondary palate occur more frequently in females than males (3:2)

Pierre-Robin syndrom: cleft of palate, hypoplasia of the lower jaw, glossoptosis and pseudomacroglosia - malformation with recessive inheritance bound to the X chromosom

Staphyloschisis (uvula bifida) – rozštěp uvuly



Critical period in palatogenesis:

37. - 53. day (cleft of primary or both palates)

53. - 57/58. day (cleft of secondary palate)

Prediction of clefts (in general)

Healthy parents having child with cleft:

2% probability of the cleft of the second child

7% probability of the cleft (if both has cleft)

One parent had cleft and child with cleft is born

15% probability of the cleft of the next child

Oral vestibule development

Oral vestibule develops from the **labiokingival lamina** (vestibular lamina)

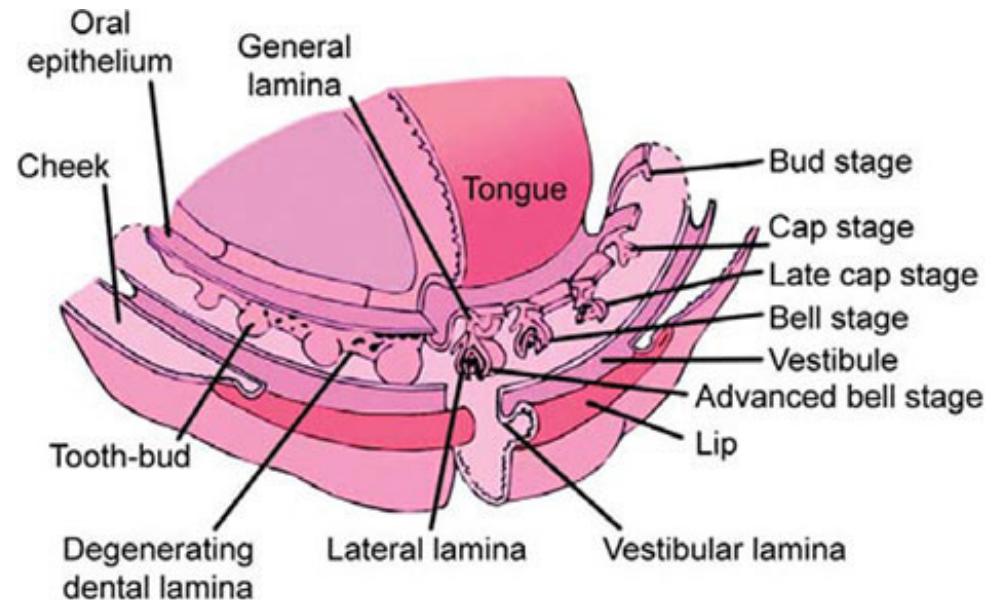
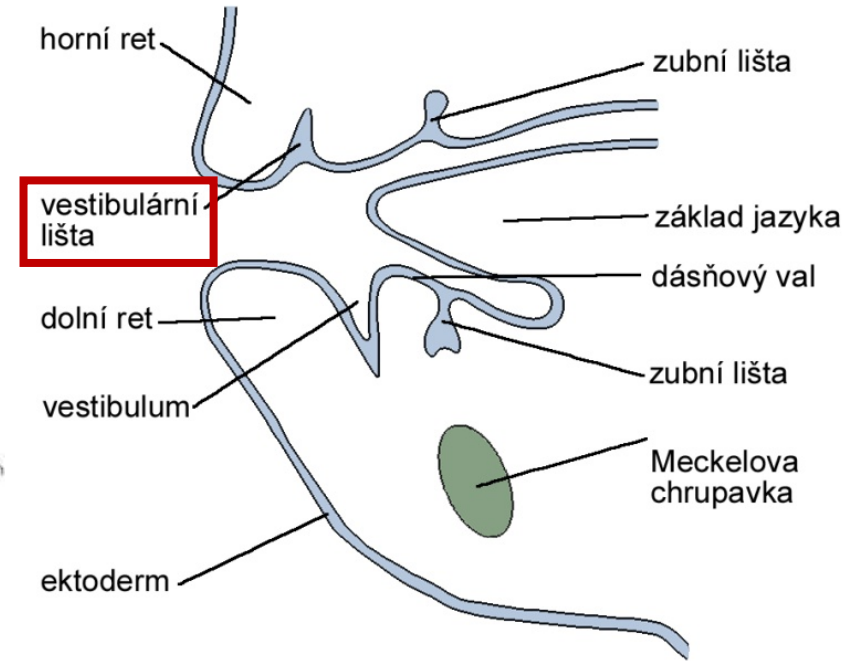
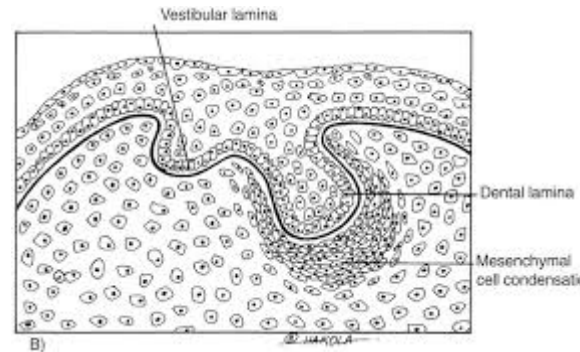
Emerges during the **6th week**

Thickened area of the ectoderm, fast proliferation of ectoderm against mesenchymal core of prominences that delineate the stomodeum

Cells in the center of lamina then undergo apoptosis - **labiokingival groove** is established

Ventral section - the definitive lip

Dorsal section - the gingival ridge (torus)



Development of maxilla and mandible

Maxilla

Paired bone, intramembranous ossification

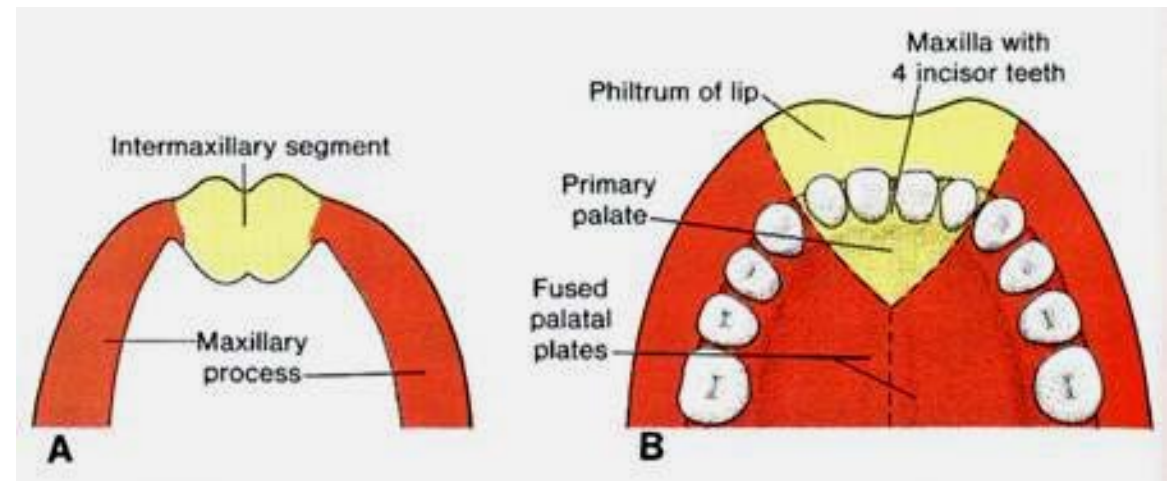
Fusion of 3 parts:

Frontal part of the bone with incisors (intermaxilla) - intermaxillary segment

Lateral parts of the bone - both maxillary prominences (processus maxillares)

Lateral parts fuse to the frontal segment in incisive suture (sutura incisiva) on both sides

Ossification begins between 6 - 8 week



maxilla in newborns is shallow because has not formed alveolar processes yet (developed during the eruption of deciduous dentition)

Development of maxilla and mandible

Mandible

develops partly by intramembranous, partly by intracartilaginous ossification

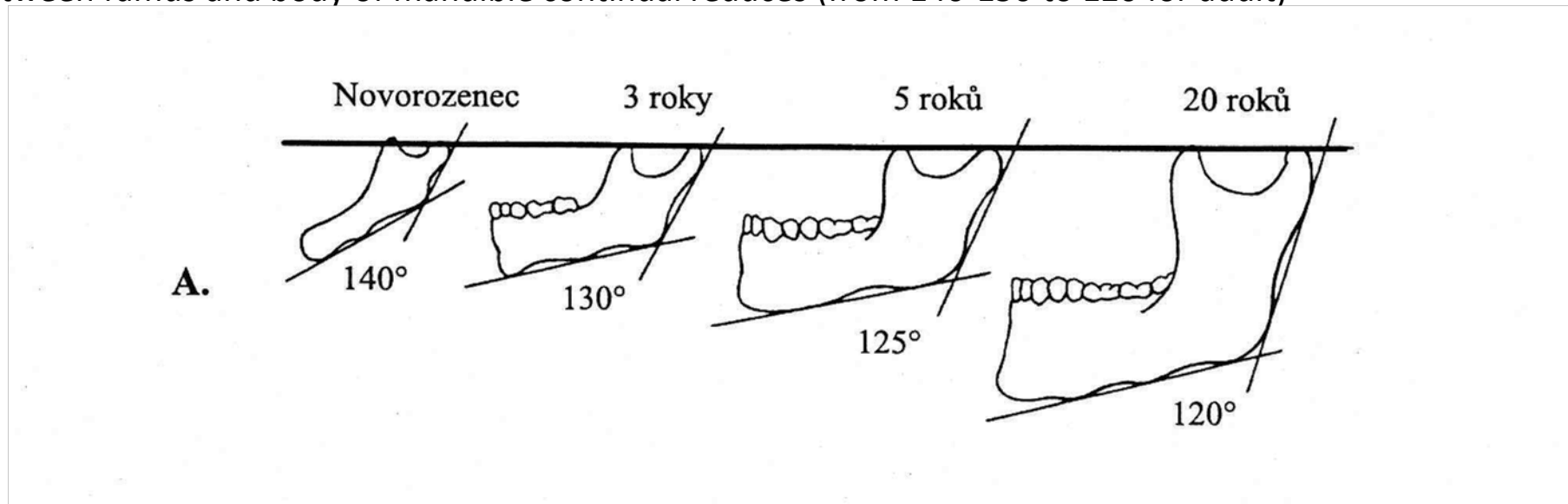
Body of mandible and both ramus of mandible are of intramembranous origin (for ossification is used mesenchyme located anterolateral to the Meckel cartilage that support the mandibular prominences)

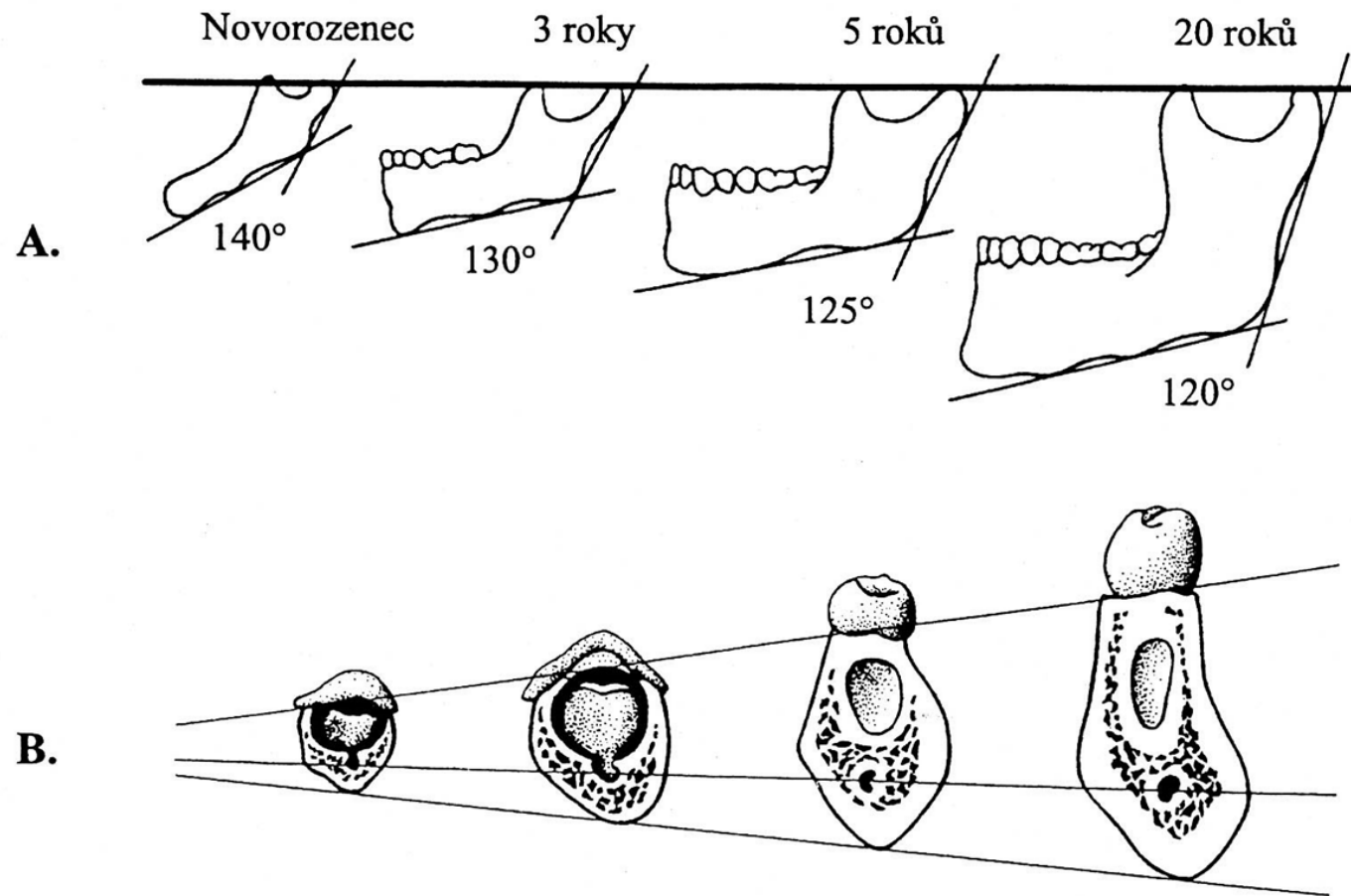
Ossification begins in the 6th week.

Condyle and coronoid process develop by intracartilaginous ossification (condyle between 12 - to 20 weeks, coronoid process yet later)

Lower jaw of neonates is low and its development continues in postnatal period

The angle between ramus and body of mandible continual reduces (from 140-150 to 120 for adult)

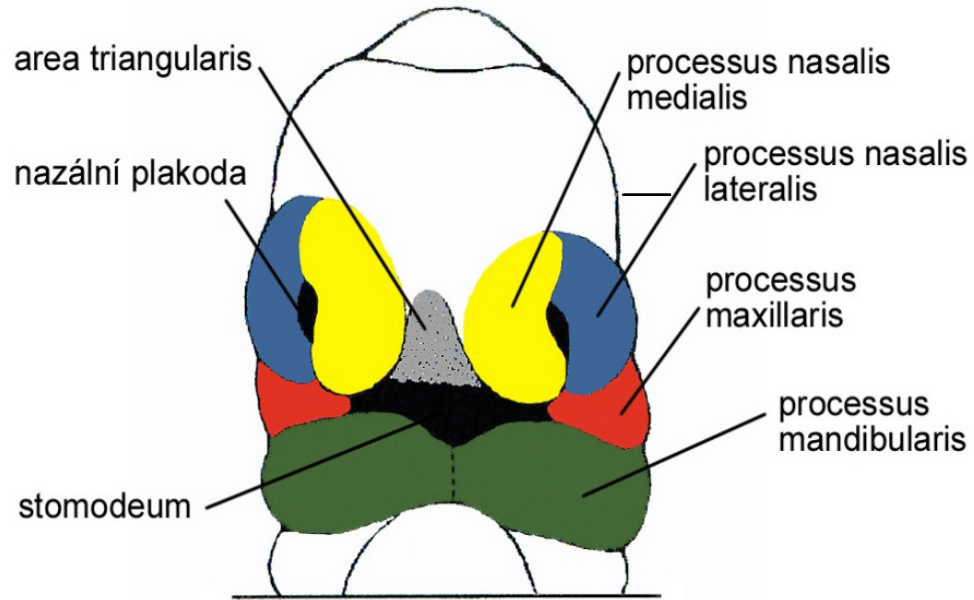




Obr. 16-3. Změny mandibuly v postnatálním vývoji. **A.** Zvětšuje se délka ramus mandibulae a zmenšuje se úhel mandibuly. **B.** Vývoj alveolární části vede k celkovému zvětšení tloušťky. Horizontální linie na obrázku prochází přes canalis mandibulae.

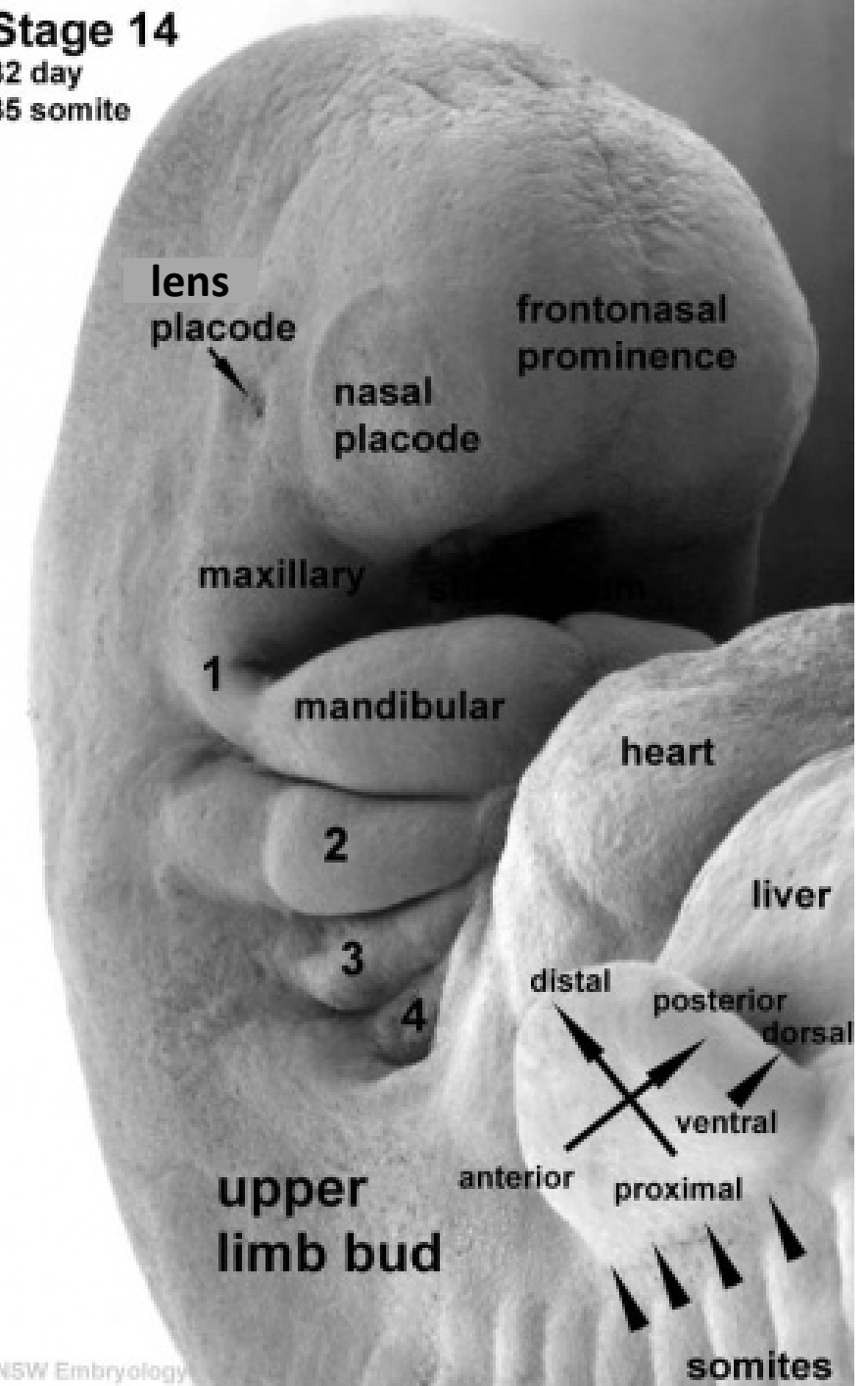
Nasal cavity

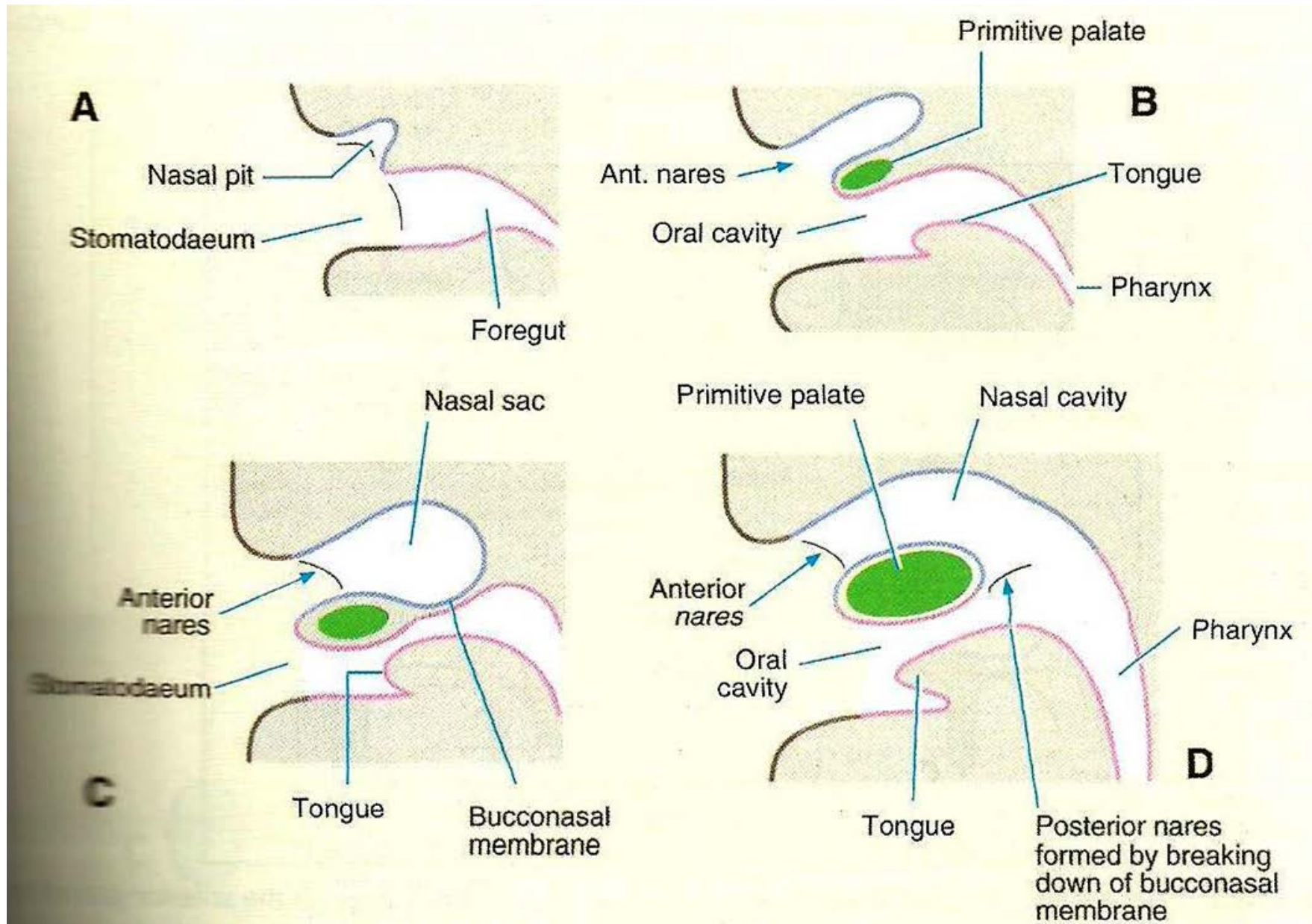
Nasal placodes → Nasal pits → Nasal sacs, grows dorsocaudally to roof of stomodeum, from which are initially separated by the oronasal membrane



Stage 14

32 day
 35 somite

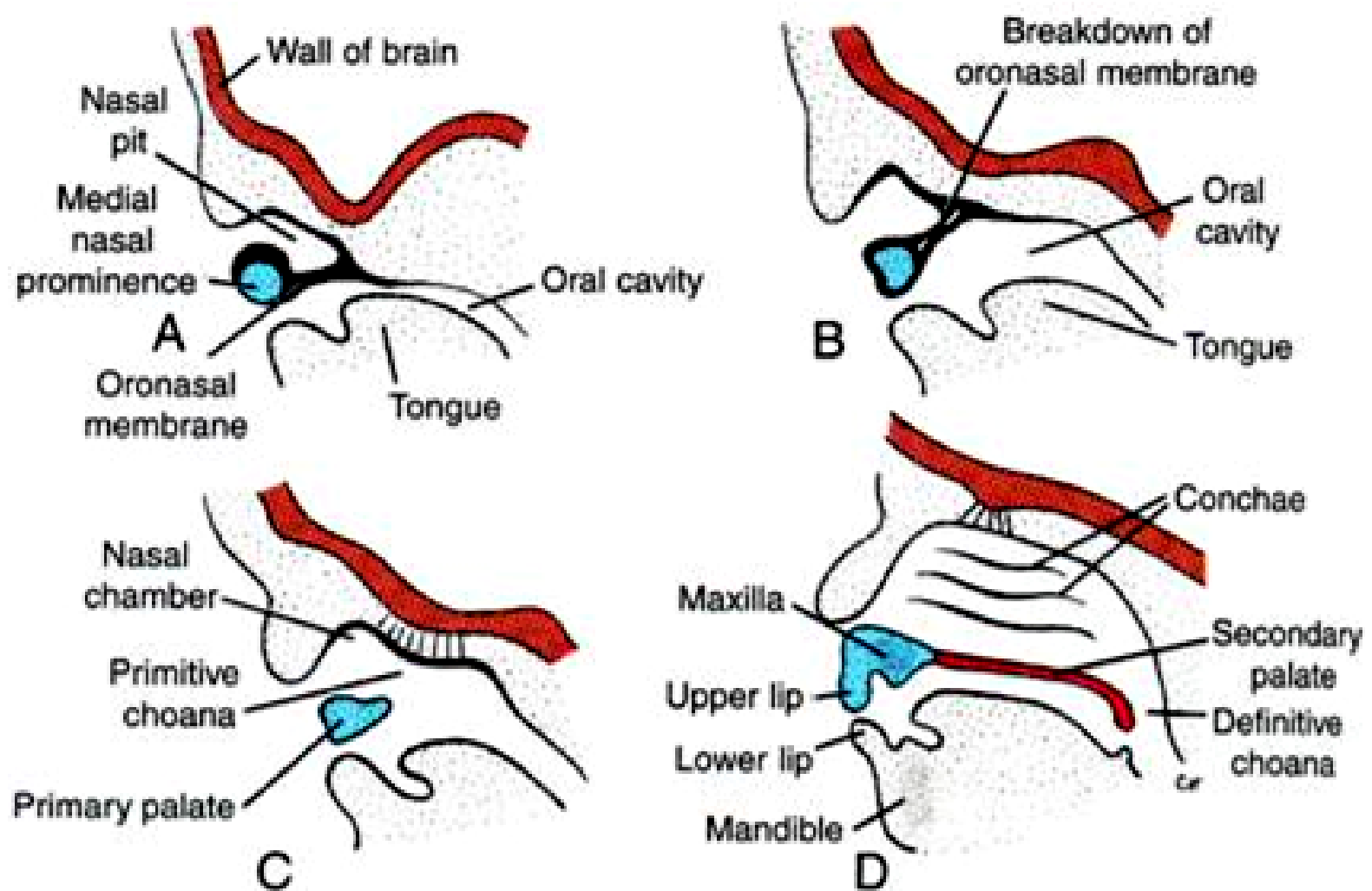




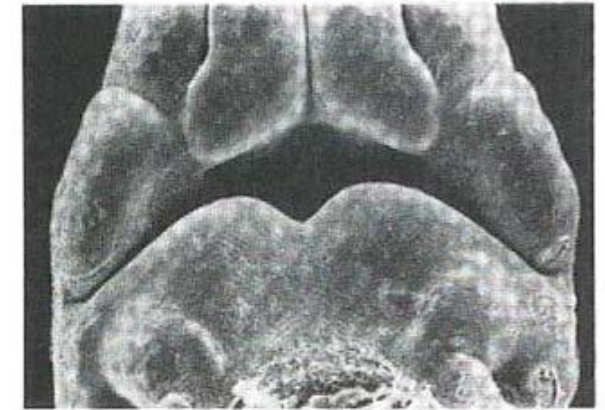
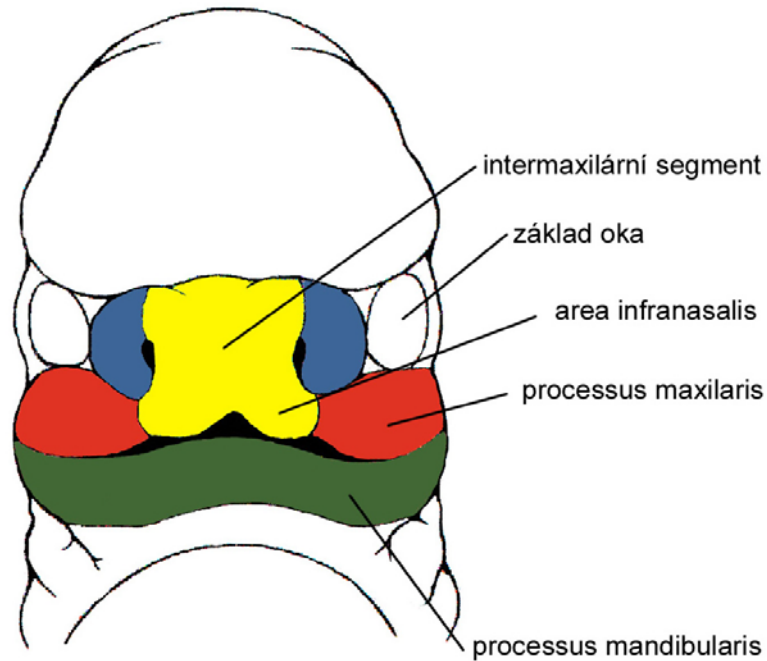
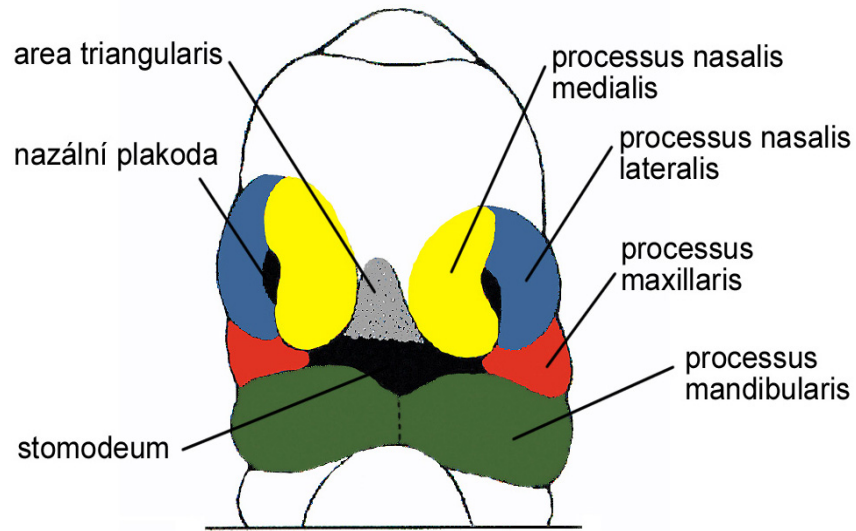
Connection of nasal and oral cavities

During the 5th week the oronasal membrane perforates via openings - the primitive choanae and both nasal sacs communicate to the stomodeum to form common mouth and nasal cavity (**oronasal cavity, only for +/-7 days**) - see C
 Sagittal sections through nasal pit and stomodeum:

Double-layered **oronasal membrane** (ectoderm of nasal cavity and stomodeum)



Nose development



Early 7th week

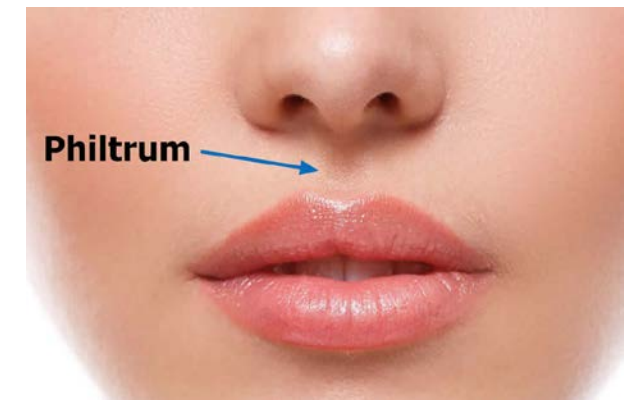Nose develops from 3 primordia simultaneously with development of face:

Middle and upper part of the intermaxillary segment - gives rise to the **apex**

Lateral nasal processes give rise to **Dorsum et radix nasi, alae nasi**

All primordia rapidly proliferate ventrally and nose protrudes (firstly flattened structure)

Lower part of intermaxillary segment – **philtrum**



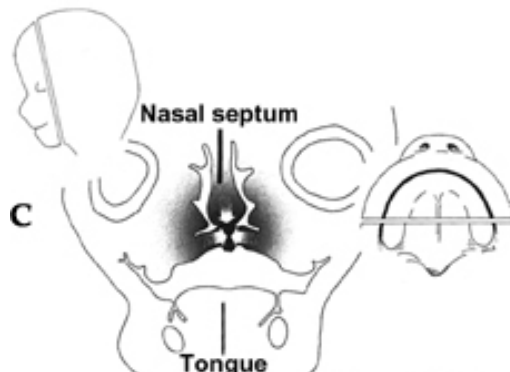
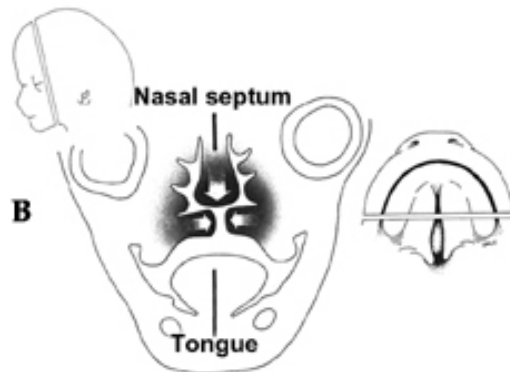
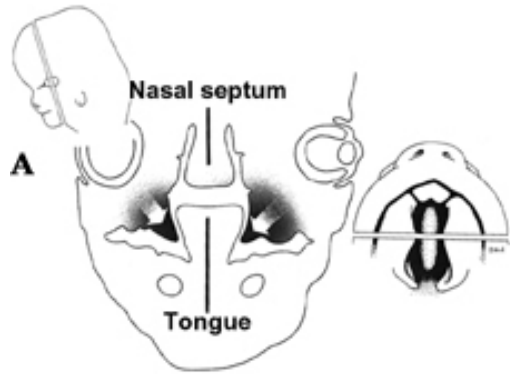
Vývoj nosu a nosních dutin

Septum nasi - grows from the intermaxillary segment in form of vertical plate, which fuses with lateral palate processes in the middle line (during 9-10th week)

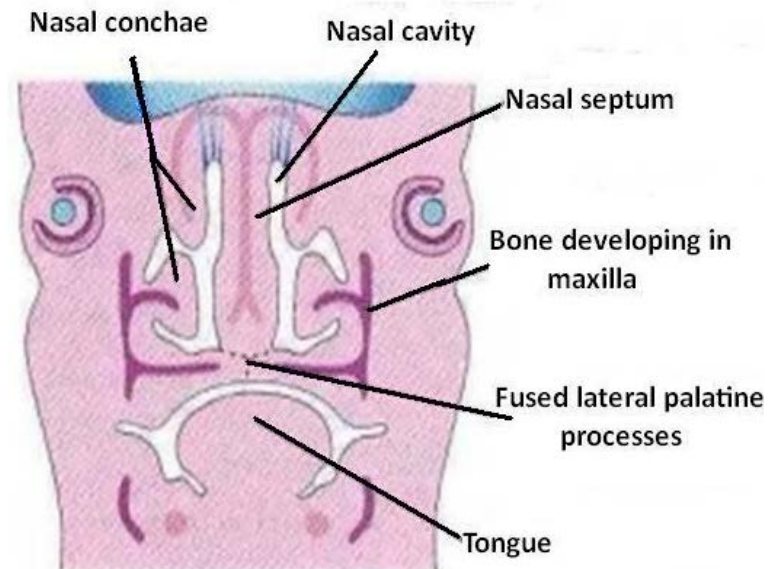
At the time of development of the septum, bases of conchae develop on the lateral wall of each nasal fossa (lower, middle and upper)

After 13 week, the ectoderm covering roof of both nasal fossae transforms in the olfactory epithelium consisting of olfactory cells (unipolar neurons), whose axons constitute **fila olfactoria**

The epithelium of sinuses is of the ectodermal origin



Copyright © 2003, Mosb



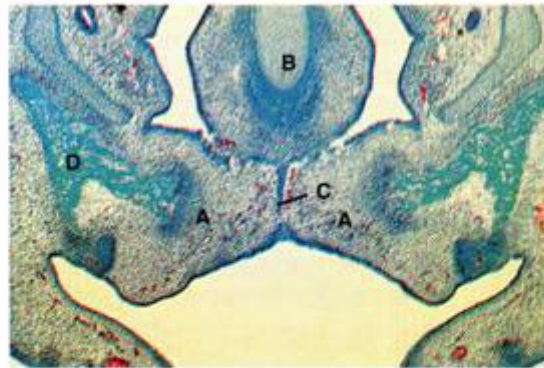
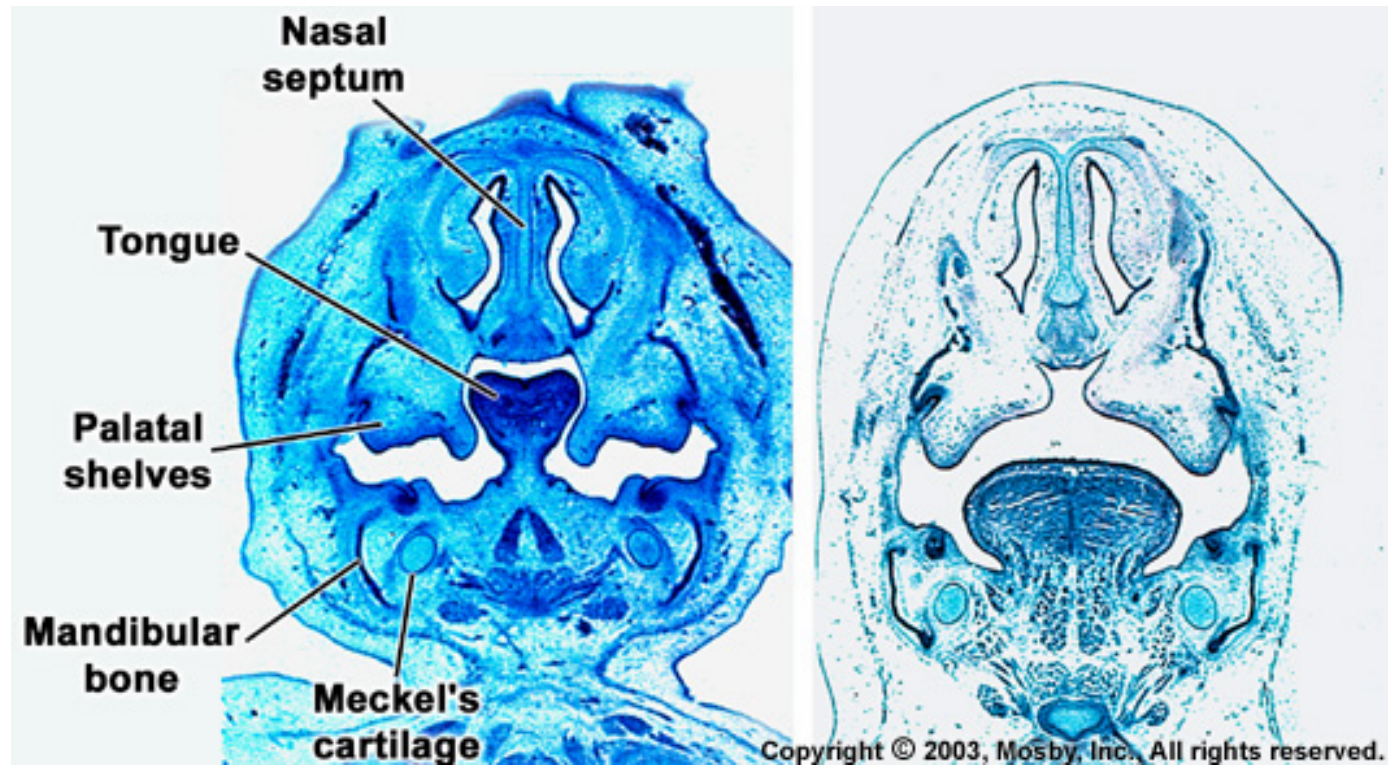


Fig. 18.5 Coronal section through developing oronasal regions following contact of the palatal shelves (A) and secondary nasal septum (B). C = Midline epithelial seam; D = developing bone of maxilla (Masson's trichrome; $\times 30$).

Developmental defects of the nose

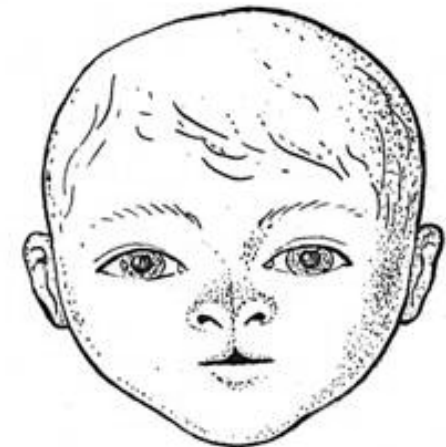
Defects are of rare occurrence

Occur separated or in association with anomalies of the upper lip and jaw or whole face

Aplasia (agenesis) of the nose - caused by lack of nasal placodes

Hypoplasia of the nose - a small nose with a single cavity combined with micrognathia

Nasoschisis (nares bifides) - median cleft of the nose - caused by non-fused medial nasal prominences
The extent of cleft is variable - from shallow groove on the nose apex to the complete duplication of the nasal septum



Atresia introitus nasi (vestibuli nasi) - vestibulum nasi is closed by thin funnel shaped membrane (caused of persistence of epithelial plugs, which obturate nostrils of the fetus in the 3rd month)

Atresia choanarum – choana is closed with connective tissue membrane or bone plate
persistence of the oronasal (buconasal) membrane

1: 10 000

autosomal dominant inheritance

Other defects: nasus duplex (rhinodynia), proboscis

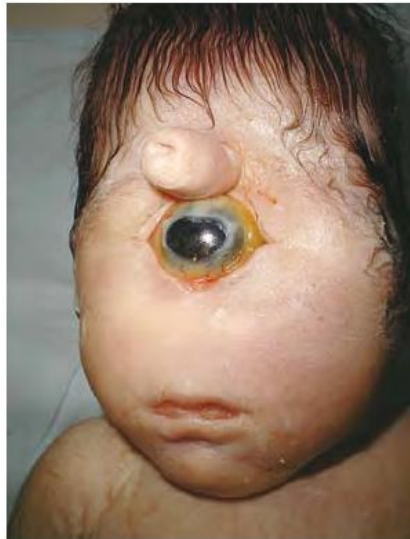
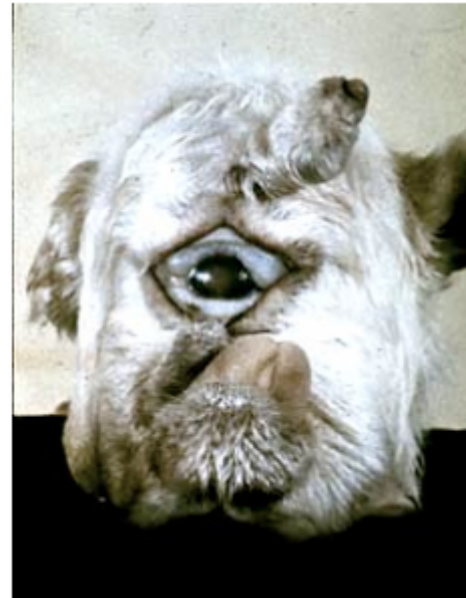
Figura 3. Foto del recién nacido. Se observa ojo único central, con probóscide, confirmando la etmocefalia.



Veratrum californicum

