

Tooth development

...from initiation until eruption

Neural crest migration (towards the oral epithelium)

Dental lamina formation (epithelial thickening)

Bud stage

Cap stage

Bell stage

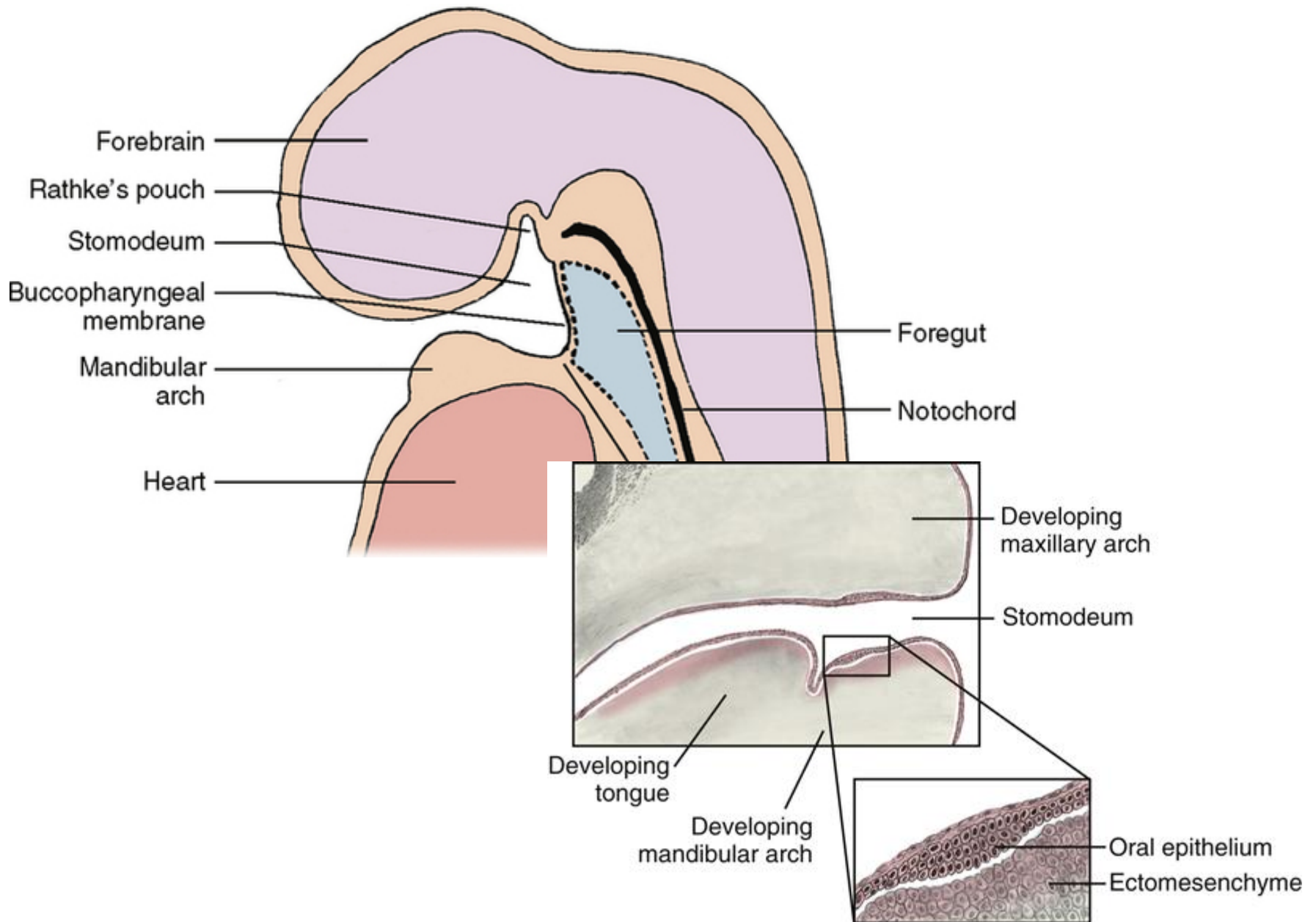
Aposition (hard tissues formation)

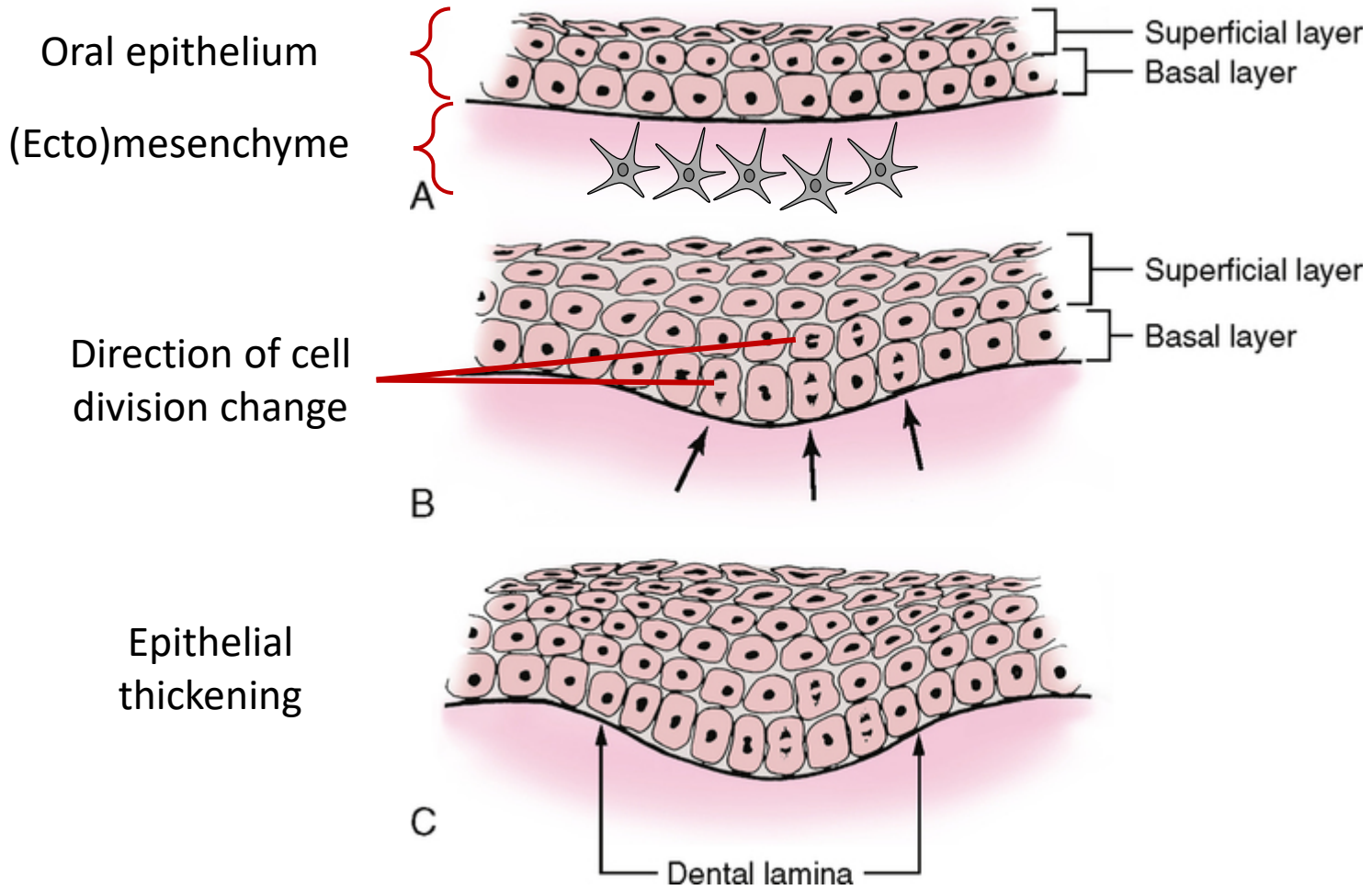
Root formation

Eruption

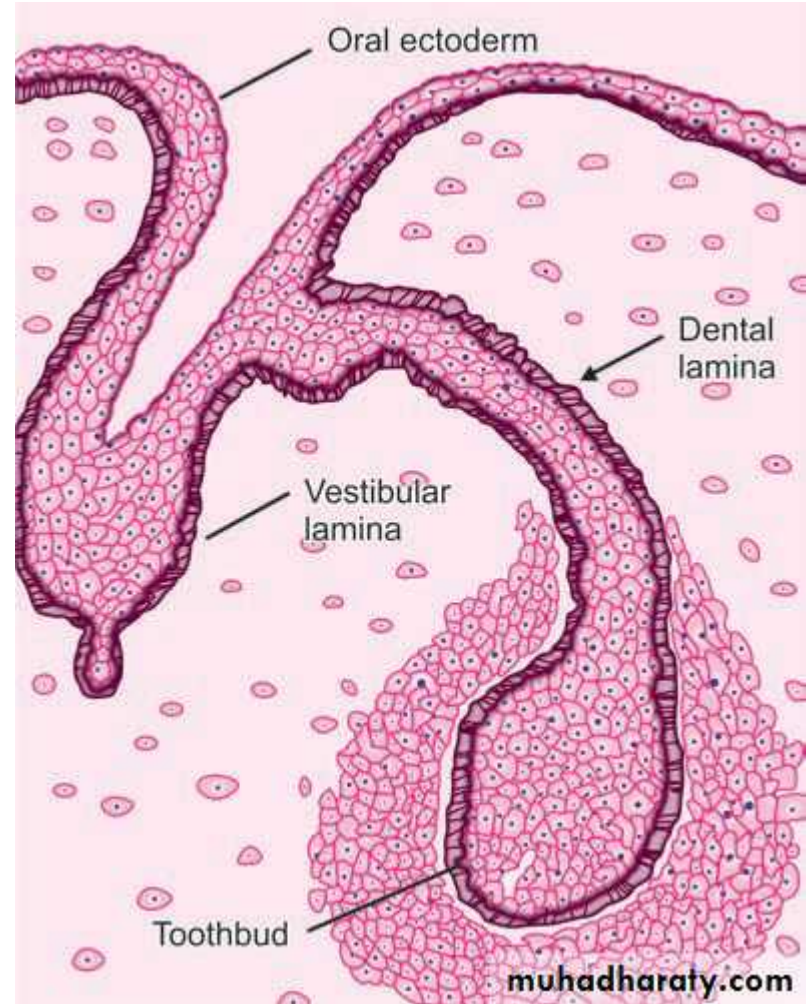
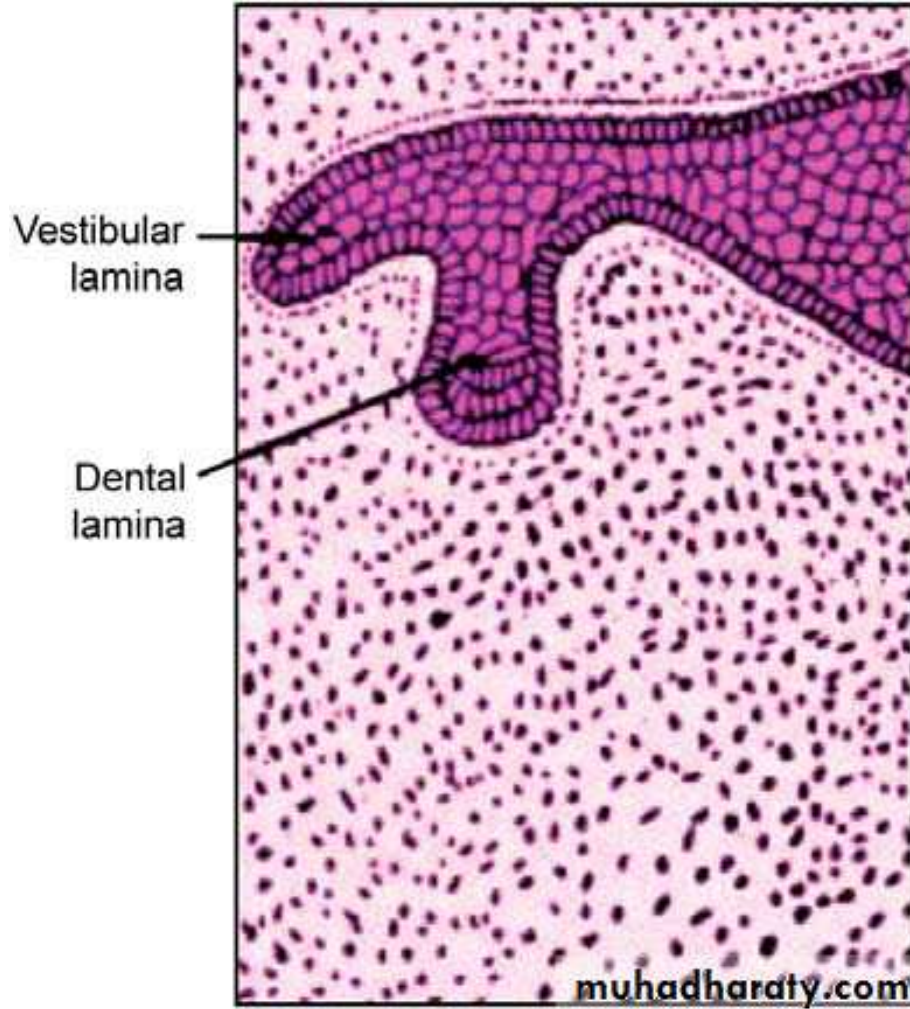


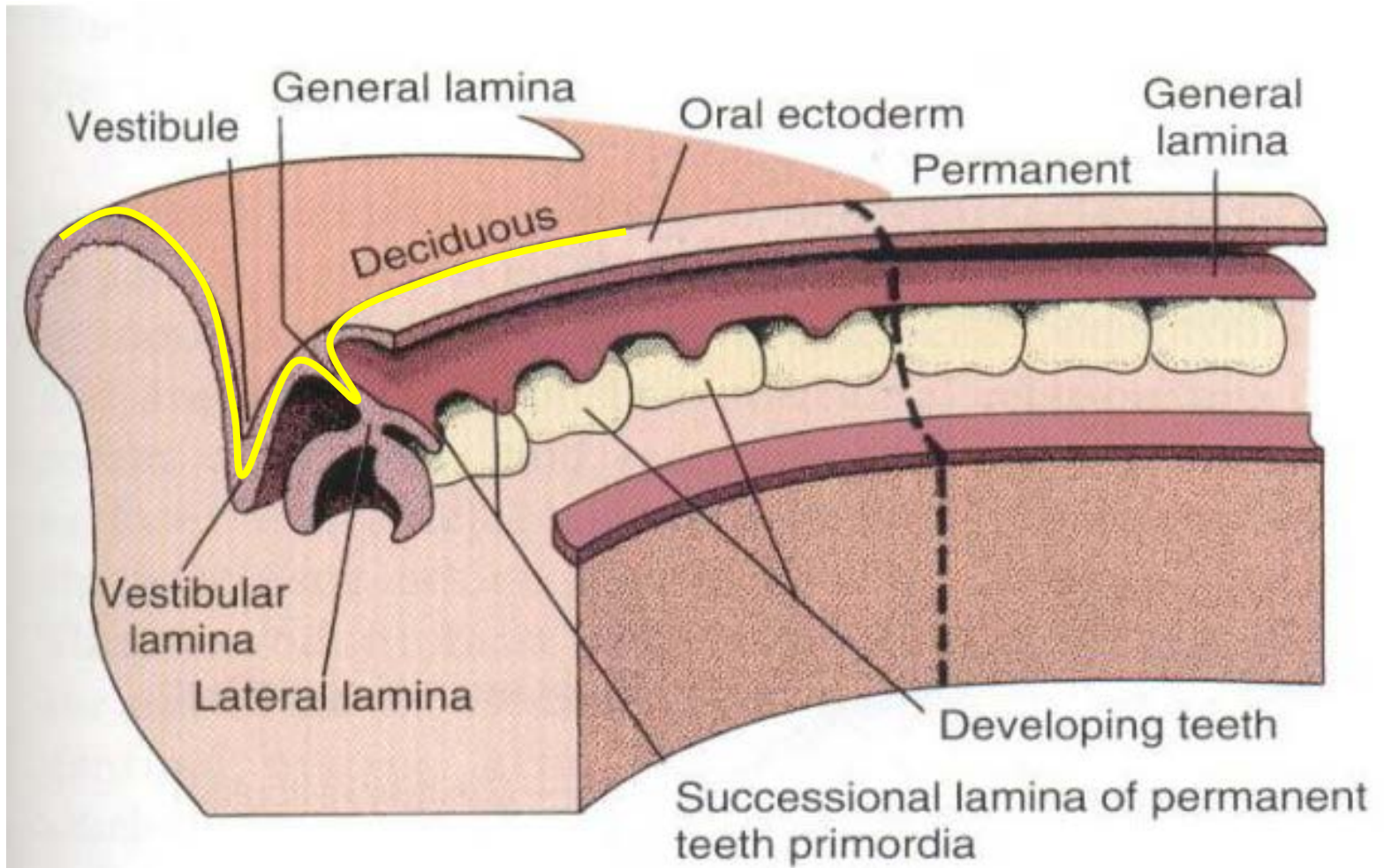
Dental development initiation



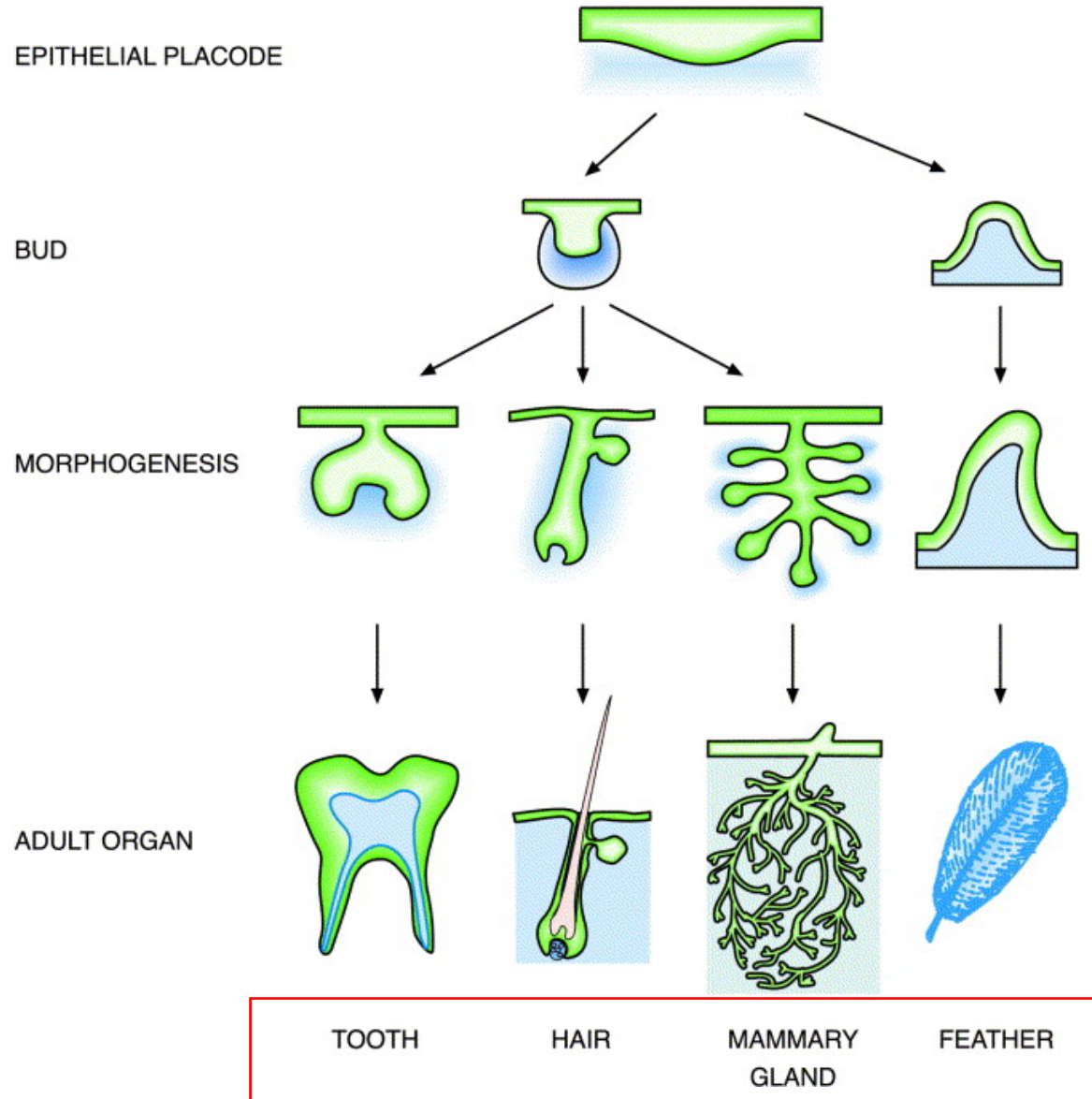


Dental vs. Vestibular lamina



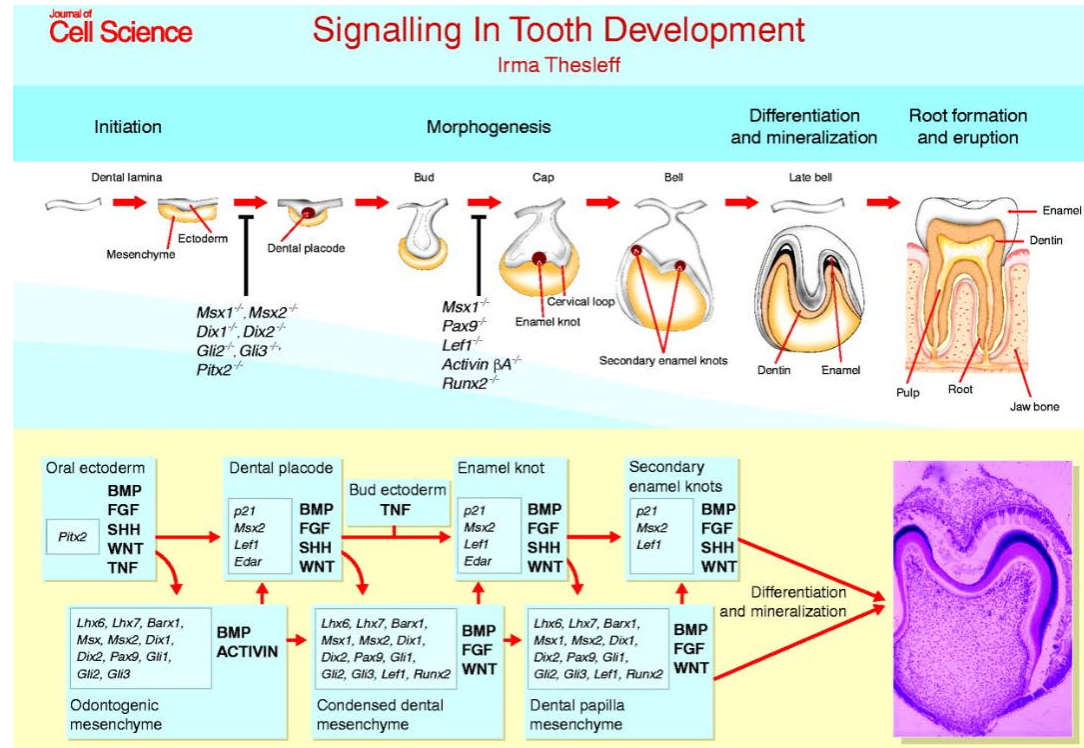


Ectodermal – to – (ecto)mesenchymal interactions



Ectodermal – to – (ecto)mesenchymal interactions

Complicated interaction system (reciprocal)



- Inner enamel epithelium induces differentiation of odontoblasts from ectomesenchyme
- Ectomesenchyme transplantation under oral ectoderm induces its conversion into enamel protein producing cells
- Transplantation of ectomesenchyme of incisor under molar ectoderm – **incisor**
- Transplantation of molar ectomesenchyme under cutter ectoderm – **molar**

Odontogenesis (dental development)

Primary dentition as well as permanent dentition develop from both ectoderm and ectomesenchyme

- **Ectodermal origin** – enamel (ameloblasts), ERM
- **Ectomesenchymal origin** – dental pulp, dentin, cementum, periodontium, alveolus
- **Similar morphogenesis**
- **Proliferation, migration, embryonal induction, apoptosis**

Primary information for tooth development (number, size) originates from ectomesenchyme (damage to cranial neural crest or its removal causes anodontia)

Ectomesenchyme induces proliferation and differentiation of oral ectoderm into odontogenic epithelium and primary dental lamina

The interaction of ectomesenchyme and oral ectoderm ultimately leads to the formation of a complete organ

Evolutionary conserved pathways

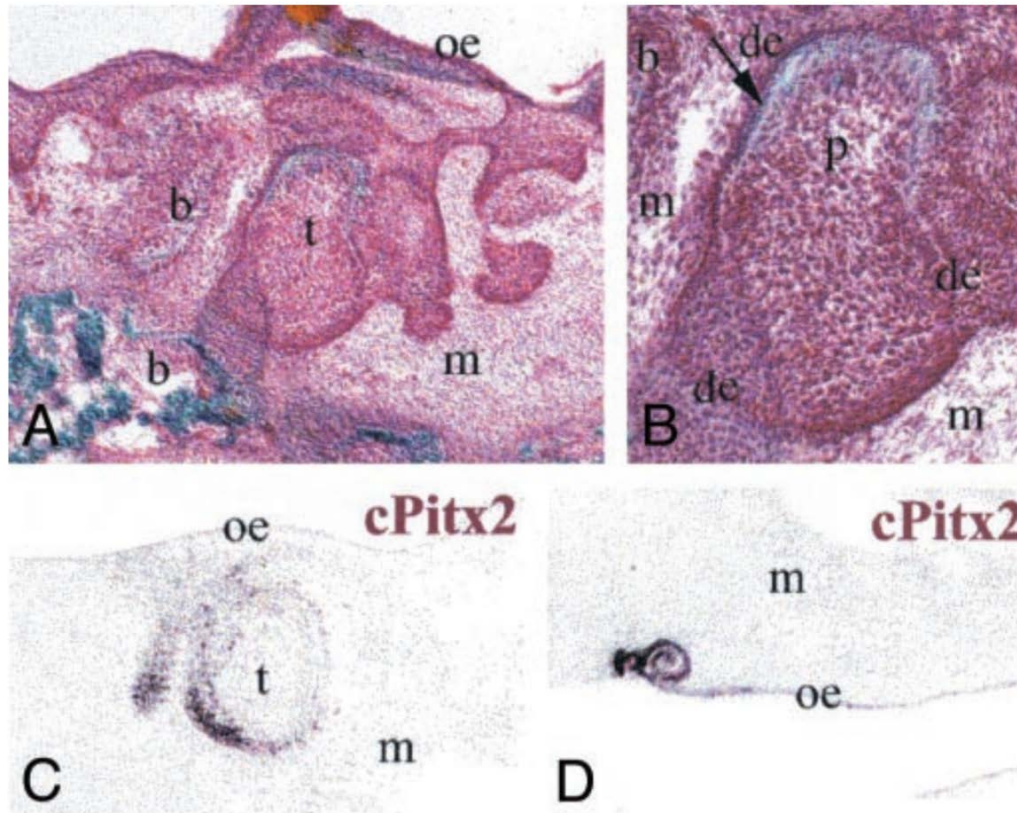
Do birds have teeth?



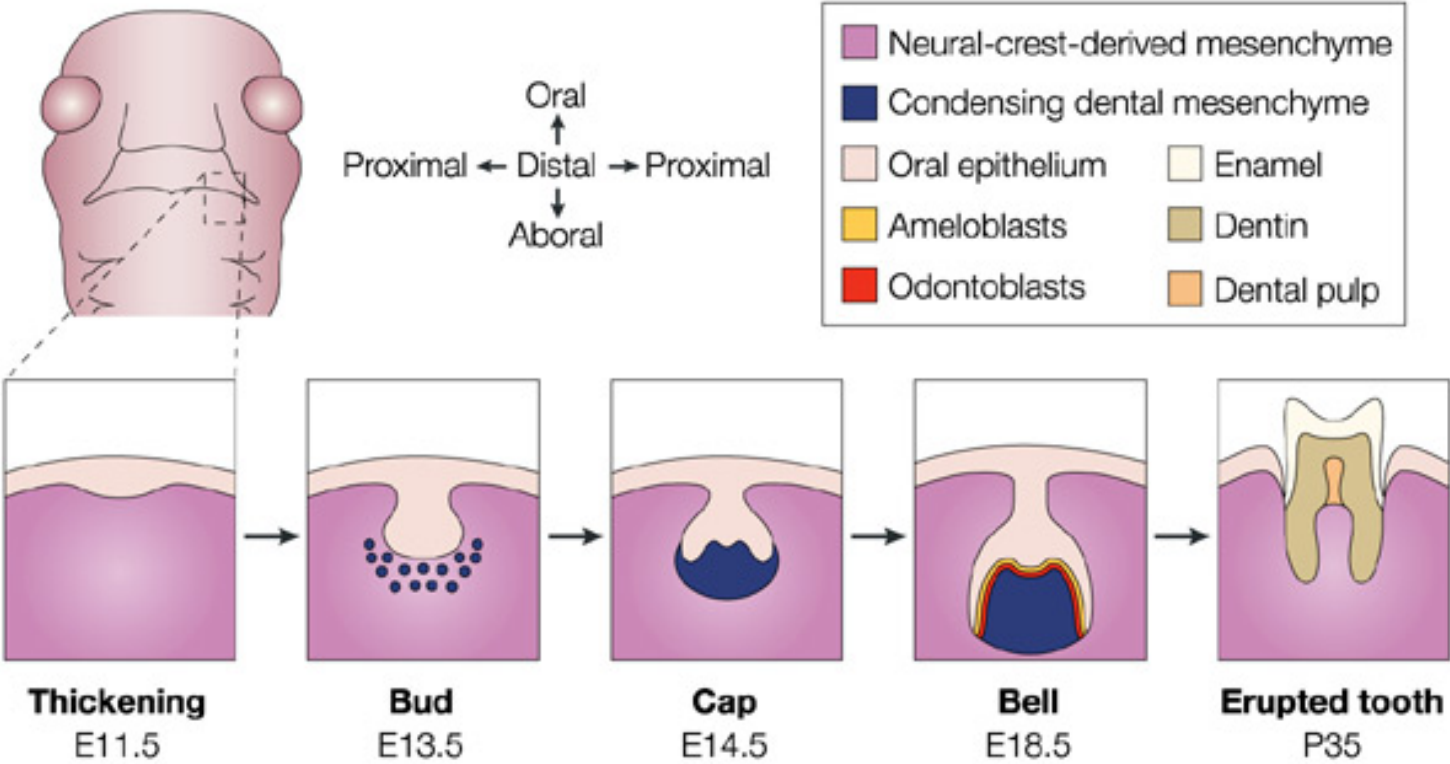
Do birds have teeth?

- Ptáci ztratili zuby asi před 70-80 miliony let
- Recent birds lost the ability to form teeth around 70–80 million years ago
- Still, birds retain the evolutionary conserved tooth-forming pathways in both oral epithelium and ectomesenchyme
- *In vitro* co-culture and *in vivo* transplantation experiments

Mouse ectomesenchyme ←————→ Chicken oral epithelium



Developmental stages of tooth - overview

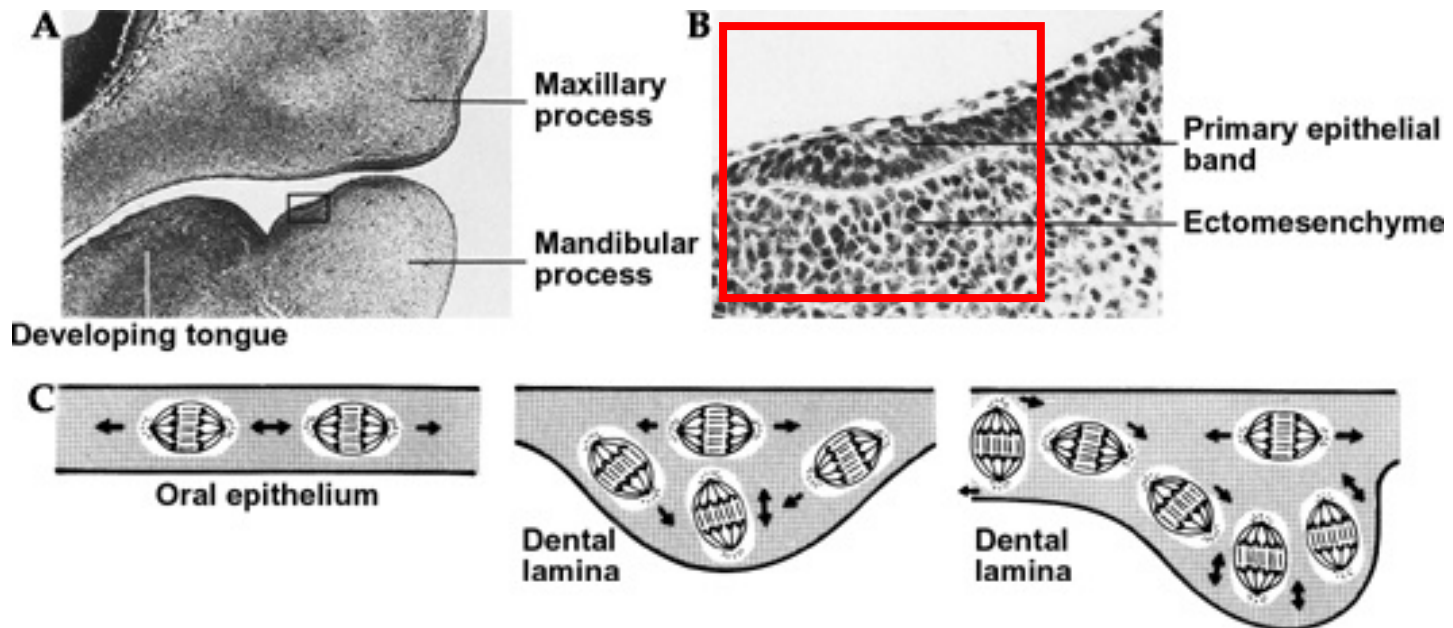


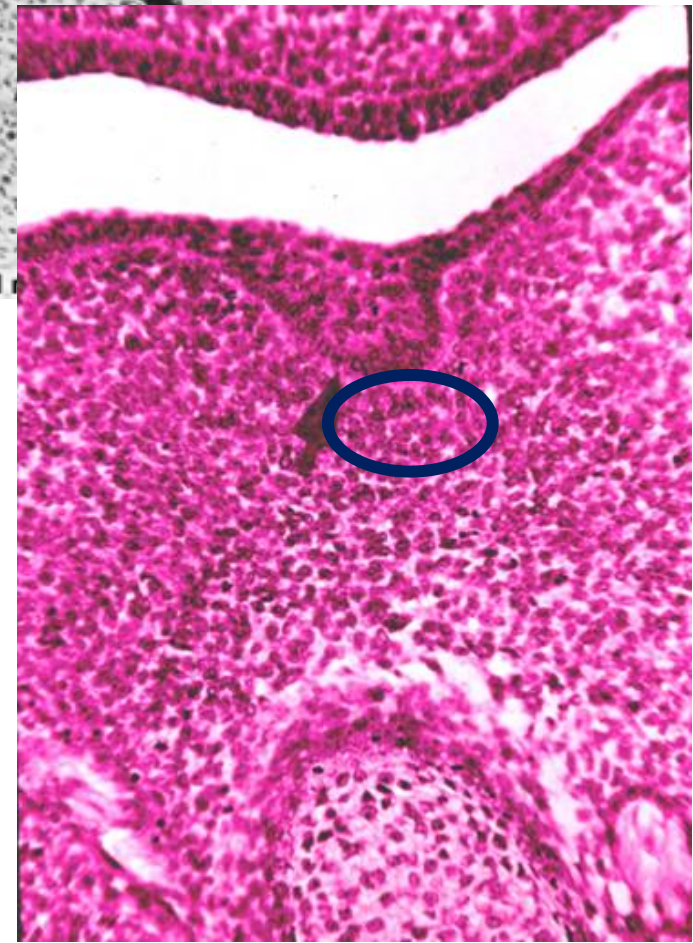
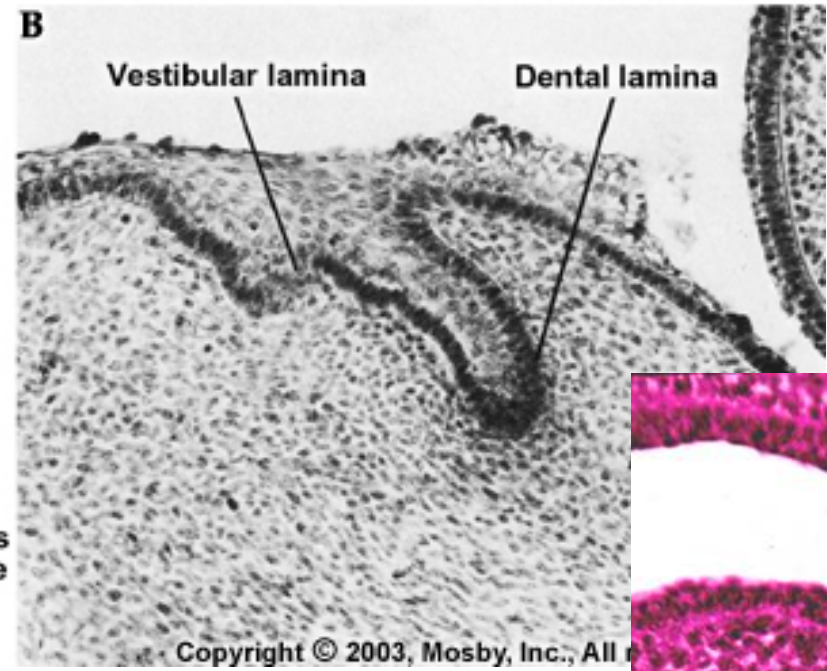
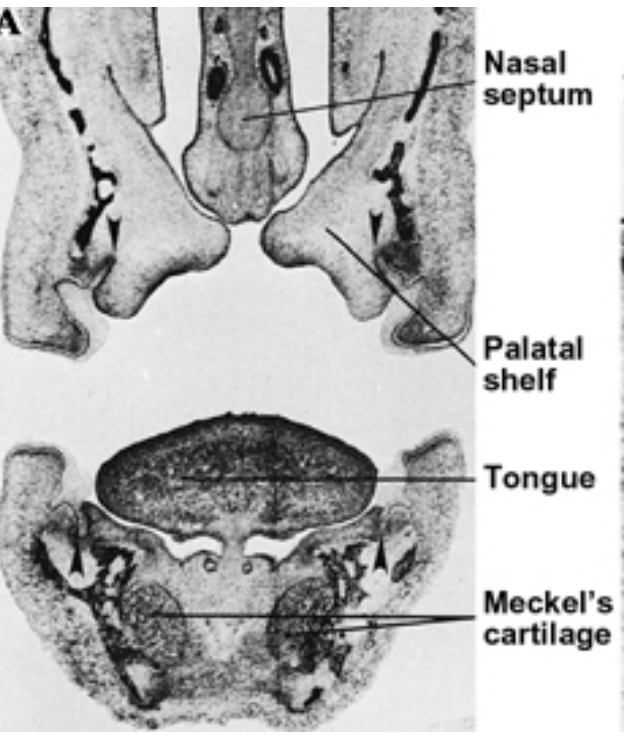
Primary dentition development

Kondenzace ektomezenchymu pod ektodermem dásňového valu na budoucí horní a dolní čelisti (po založení předsíně - vestibulum oris) - **ve druhé polovině 6. týdne** nitroděložního života

Ectomezenchymal condensation under the oral ectoderm in the upper and lower jaw in the second half of the **6th week** of intrauterine life

Ectomezenchyme stimulates the basal layer cells of the oral ectoderm to cell division which leads to primary **dental lamina** formation





Bud stage

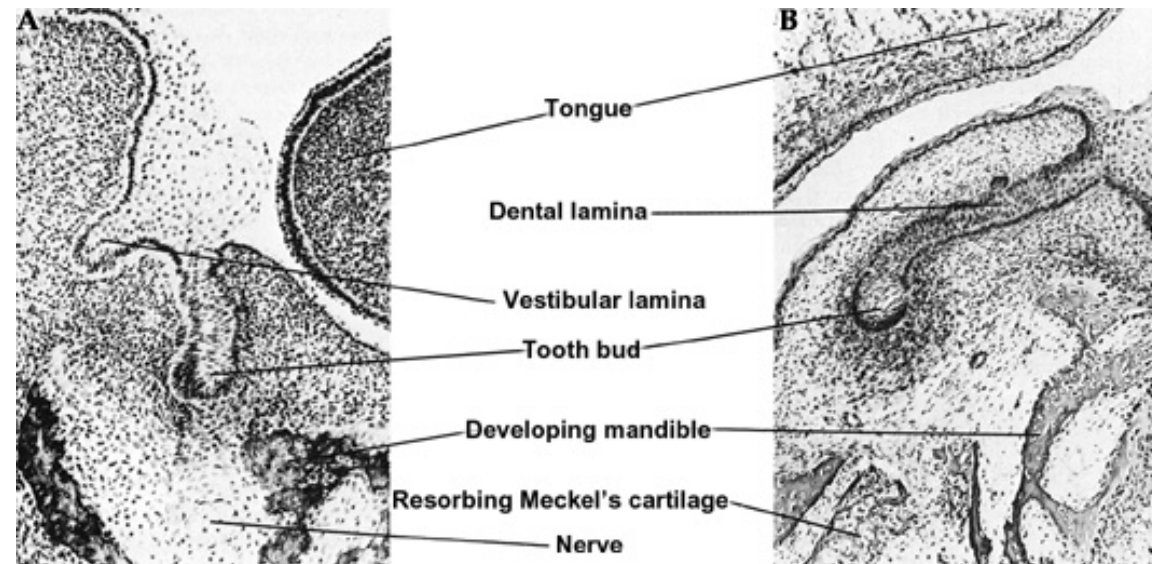
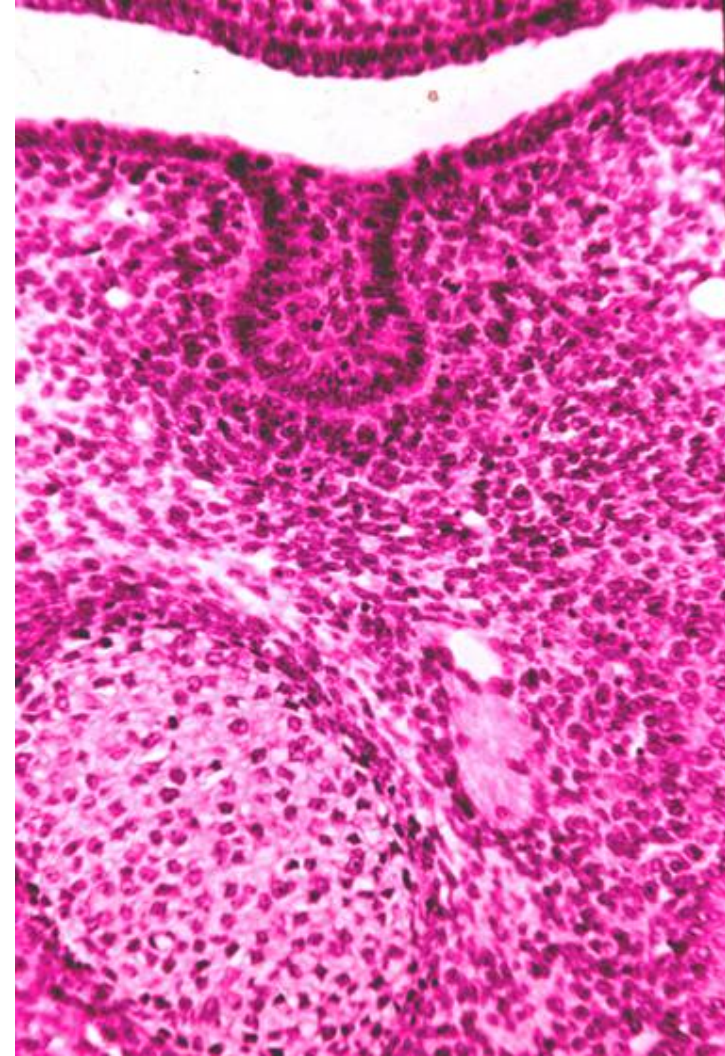
After setting up the maxillary and mandibular dental lamina, 10 dental buds (primordia) are formed on both: maxilla and mandible

The buds proliferate on the side neighboring with ectomesenchyme and increase in size

Primordia formation:

end of the 7th to the beginning of 8th week

(mandibular - firstly)

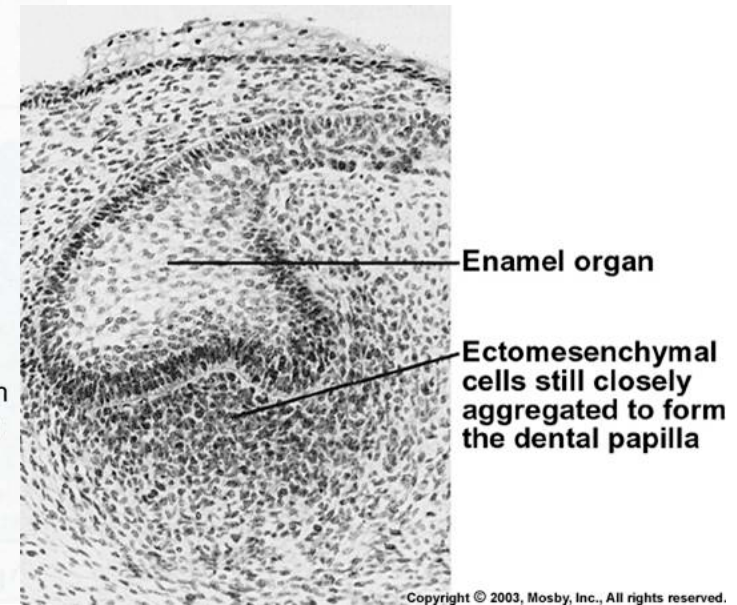
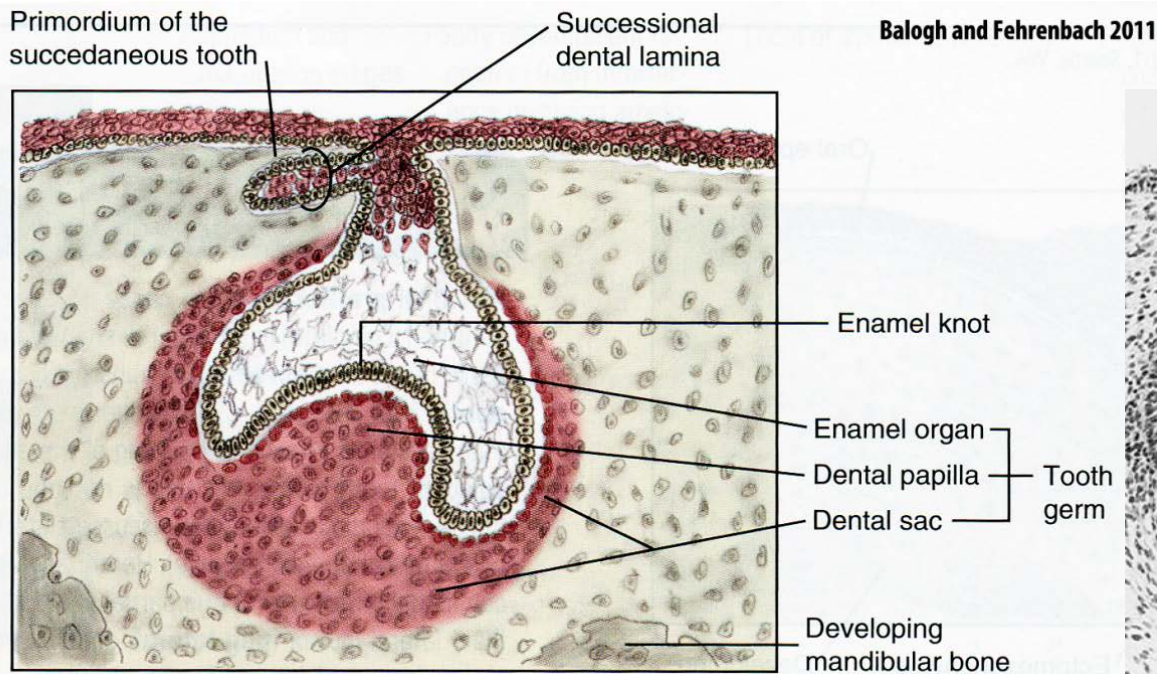


Cap stage

9. - 10. week of development

Enamel knot formation in the middle of the bud leads to the epithelial overgrowth on sides and formation of the „Cap“

Ectomesenchyme is entrapped and forms dental papilla



Histological differentiation of cells: cells on the surface of the dental follicle become cubic to low cylindrical, while the inner cells become polymorphic (the origin of future stellate reticulum)

Similar process in dental papilla

Basal membrane - ***lamina basalis ameloblastica***

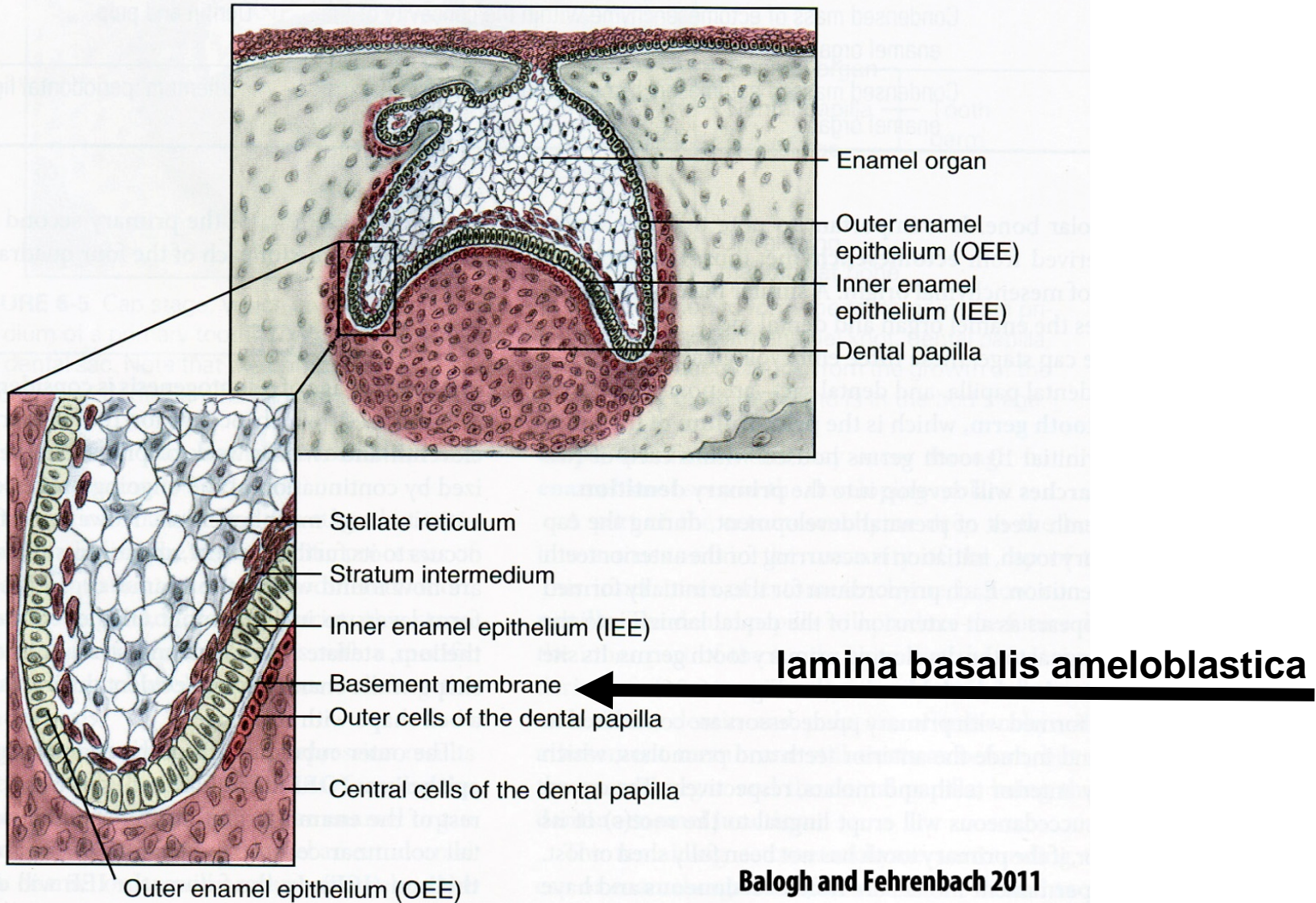
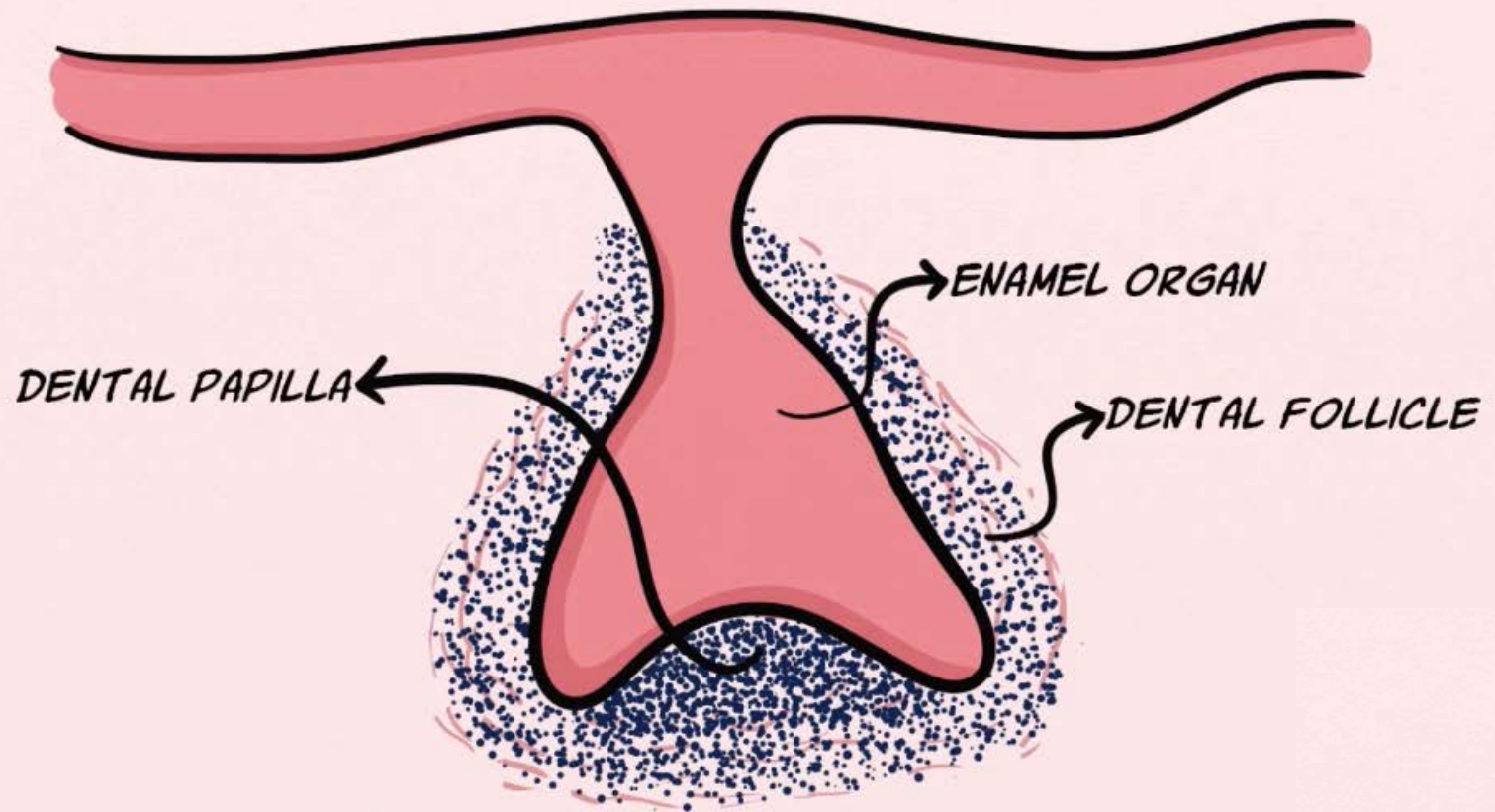
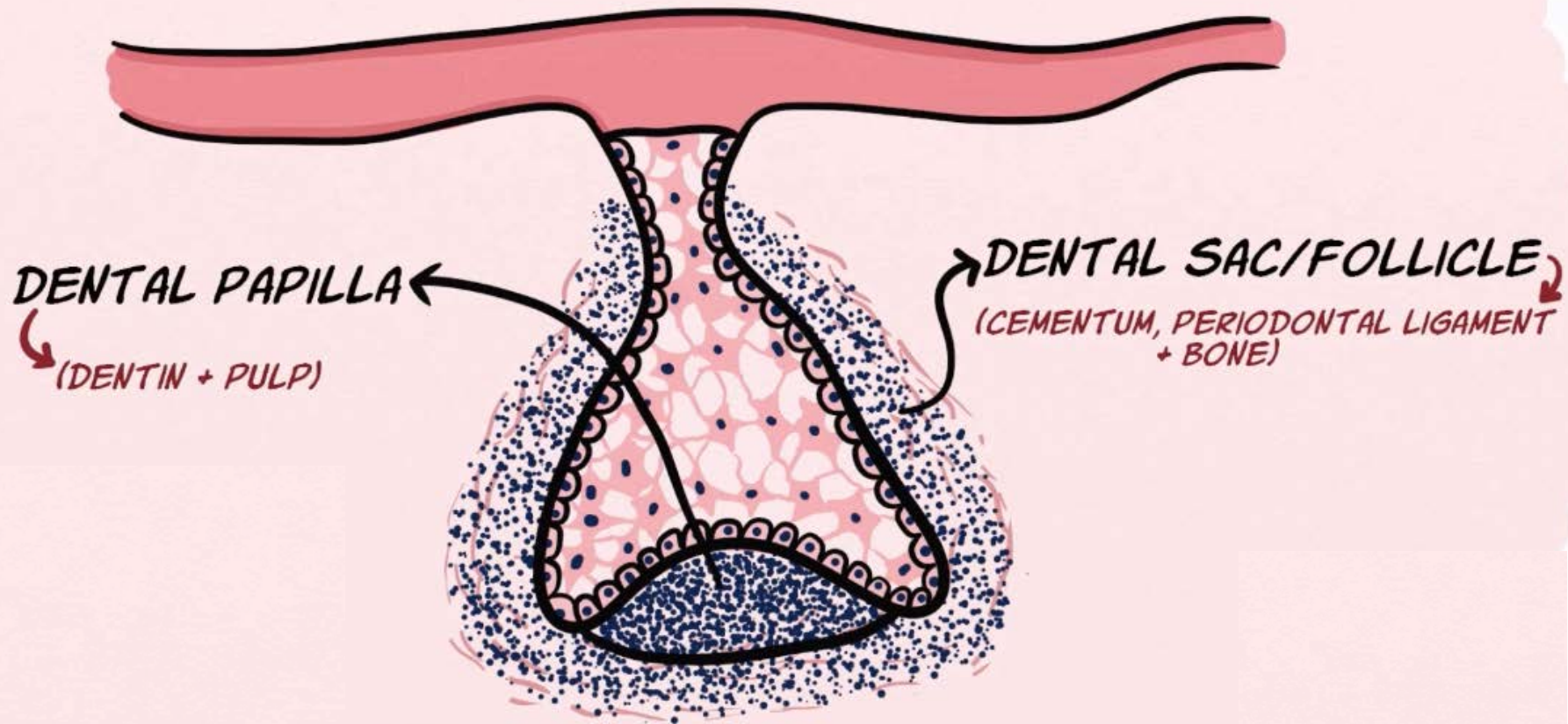


FIGURE 6-7 Bell stage, which exhibits differentiation of the tooth germ to its furthest extent. Both the enamel organ and dental papilla have differentiated into various layers in preparation for the apposition of enamel and dentin.

TOOTH GERM/DENTAL ORGAN = ENAMEL ORGAN + DENTAL PAPILLA + DENTAL FOLLICLE



CAP STAGE



Bell stage

10. - 12. week

Enamel organ in contact with dental papilla

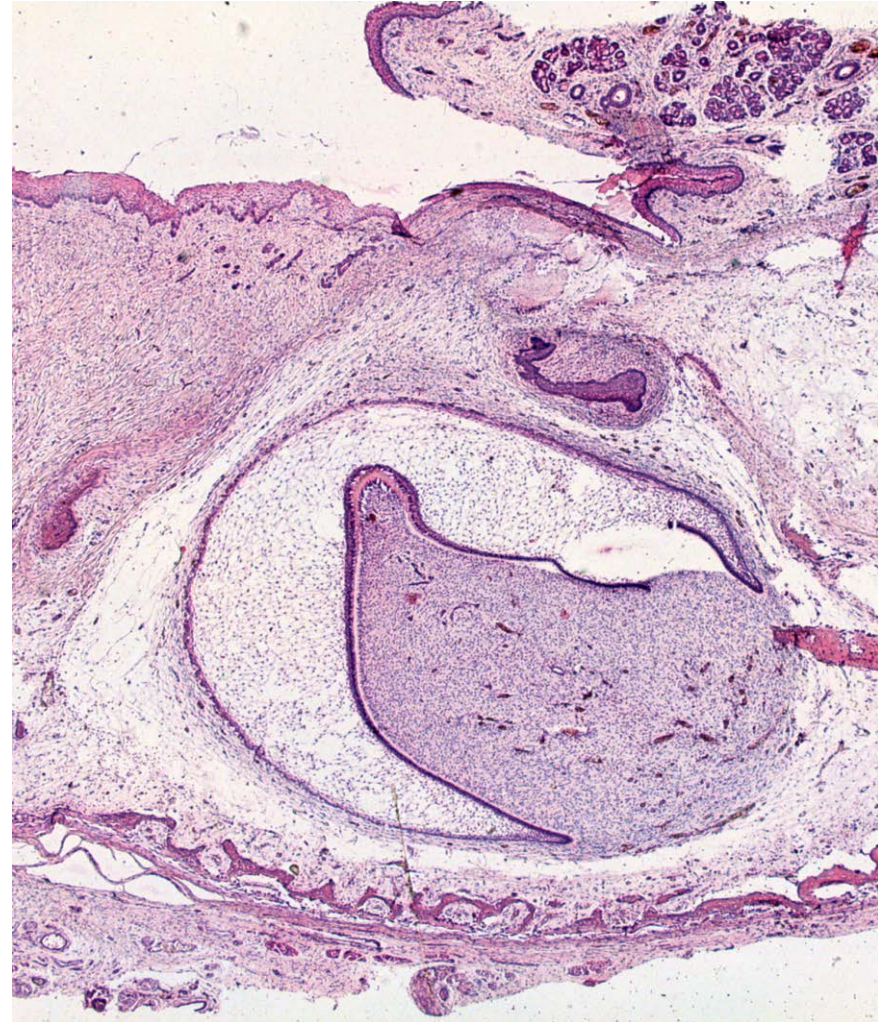
Enamel organ have 4 layers

Inner enamel epithelium – On the border with ectomesenchyme on dental papilla surface. Tall columnal cells (up to 50 μm) about 4 μm thick. Cells annealed to *I. basalis ameloblastica*.

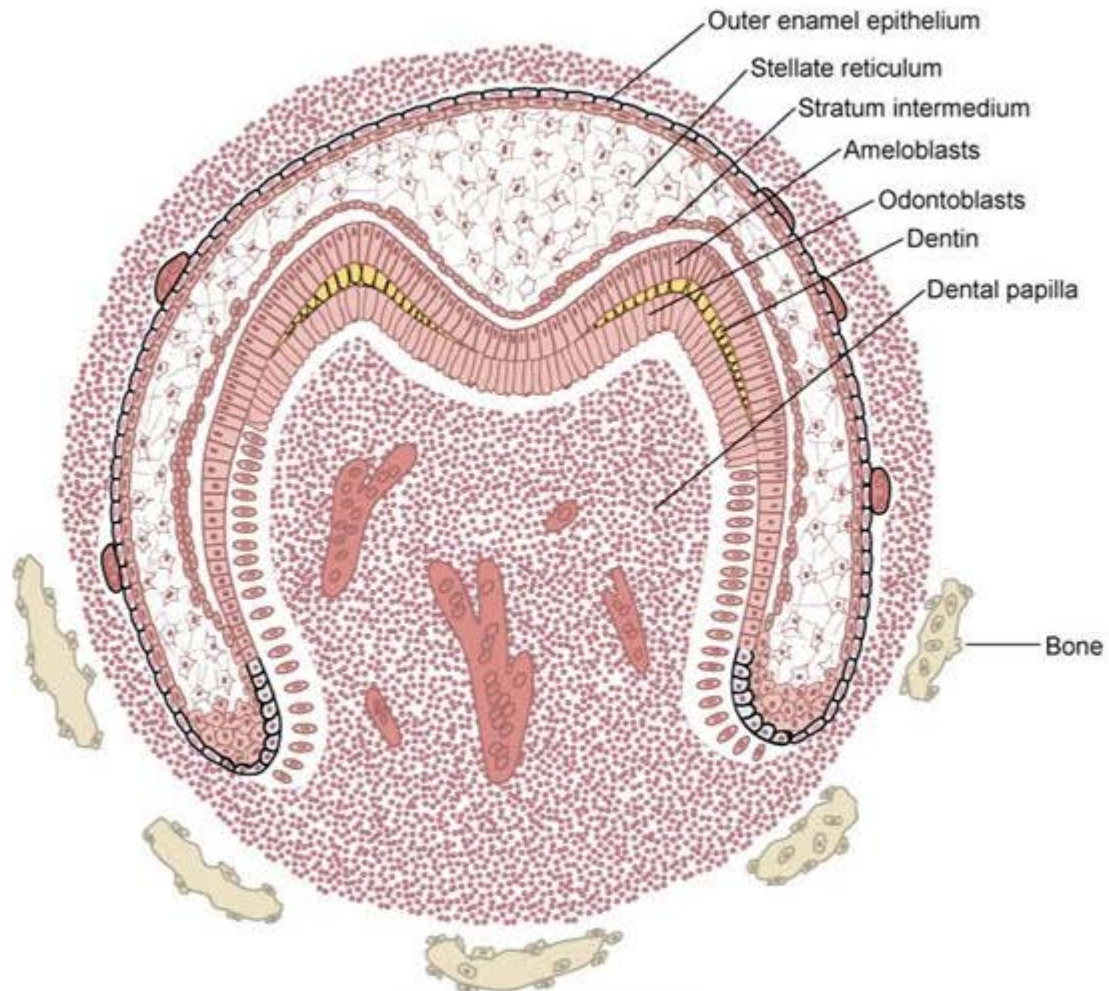
Stratum intermedium – contains 3-5 layers of flattened cells divided by intercellular space and connected with desmosomes

Stellate reticulum – epithelial cell reticulum, star-shaped cells

Outer enamel epithelium – have its own basal lamina, in the beginning cubical and later flattened cells



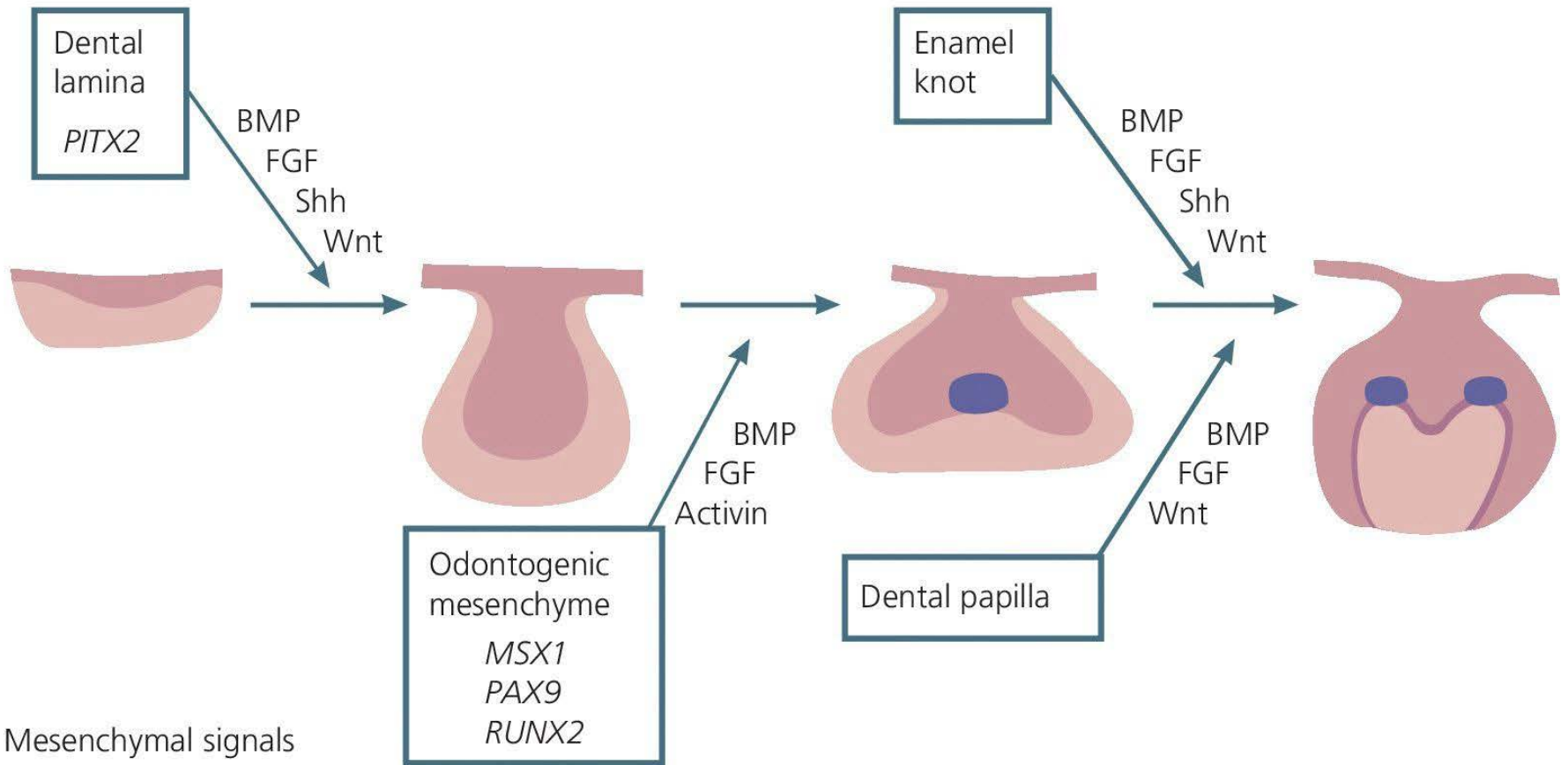
Bell Stage



Copyright © 2014 by Mosby, an imprint of Elsevier Inc.

Enamel knot

Epithelial signals




Developmental stages (timing)

6 - 7. week

Initiation stage/sixth to seventh week

Dental lamina

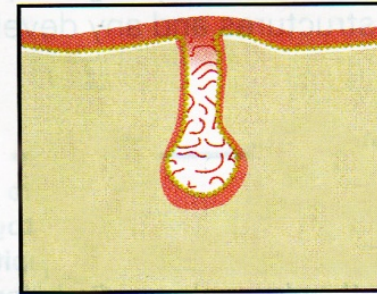


Induction

8. week

Bud stage/eighth week

Bud stage

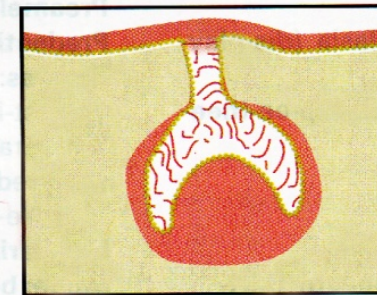


Proliferation

9. - 10. week

Cap stage/ninth to tenth week

Cap stage

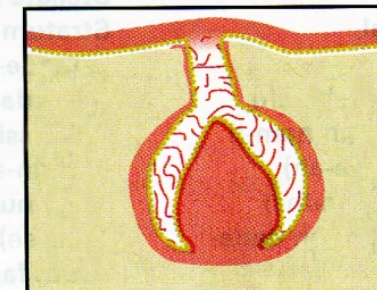


Proliferation, differentiation,
morphogenesis

11. - 12. week

Bell stage/eleventh to twelfth week

Bell stage

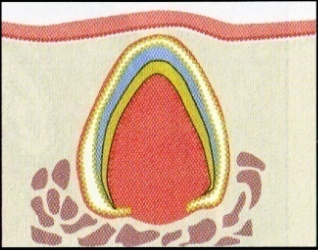
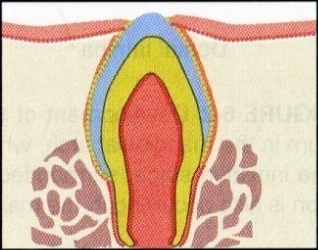


Proliferation, differentiation,
morphogenesis

Balogh and Fehrenbach 2011

Developmental stages (timing)

Beginning of
4. m. intra-utero

STAGE/TIME SPAN*	MICROSCOPIC APPEARANCE	MAIN PROCESSES INVOLVED	DESCRIPTION
Apposition stage		Induction, proliferation	Dental tissue types secreted in successive layers as matrix
<i>post partum</i>		Maturation	Dental tissue types fully mineralize to mature form

Balogh and Fehrenbach 2011

Aposition

- Period of hard tooth tissue formation
- Begins during the **second half of 4th month** of foetal development

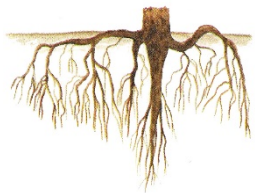


Crown – formed firstly (dentin, enamel)

Enamel and dentin aposition begins in the place of signaling center and spread apically

Enamel formation = **amelogenesis**

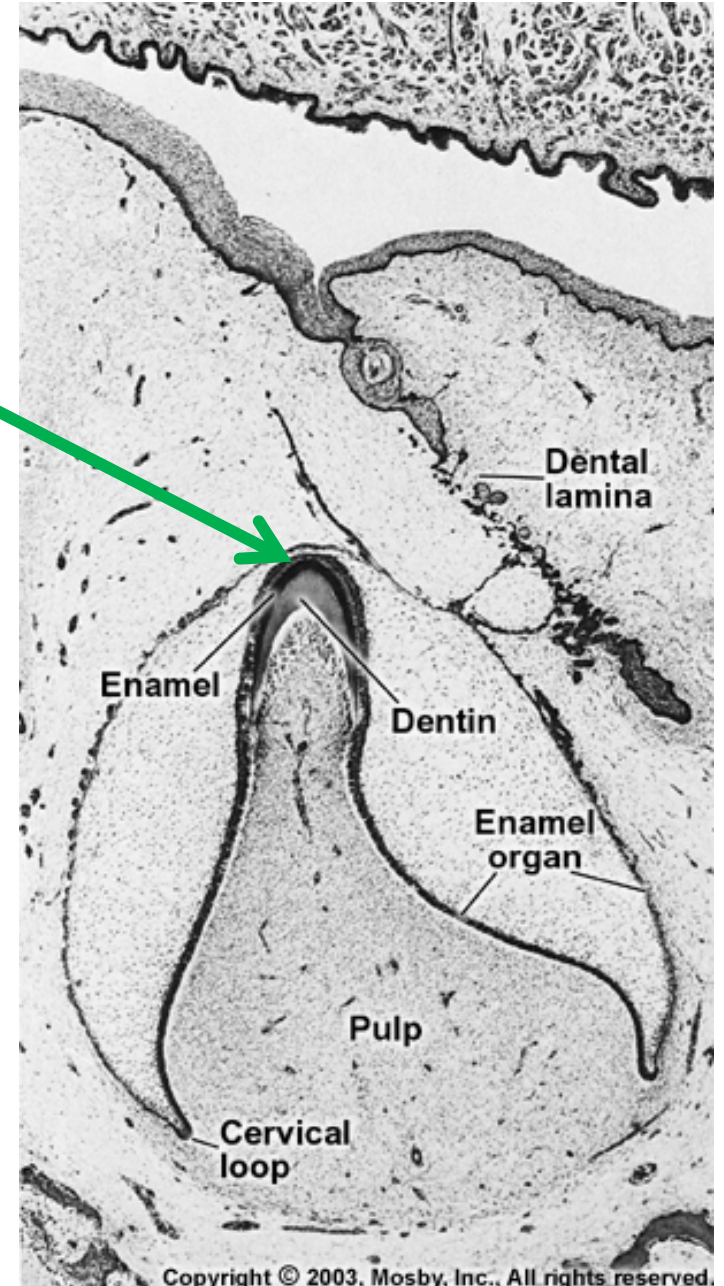
Dentin formation = **dentinogenesis**



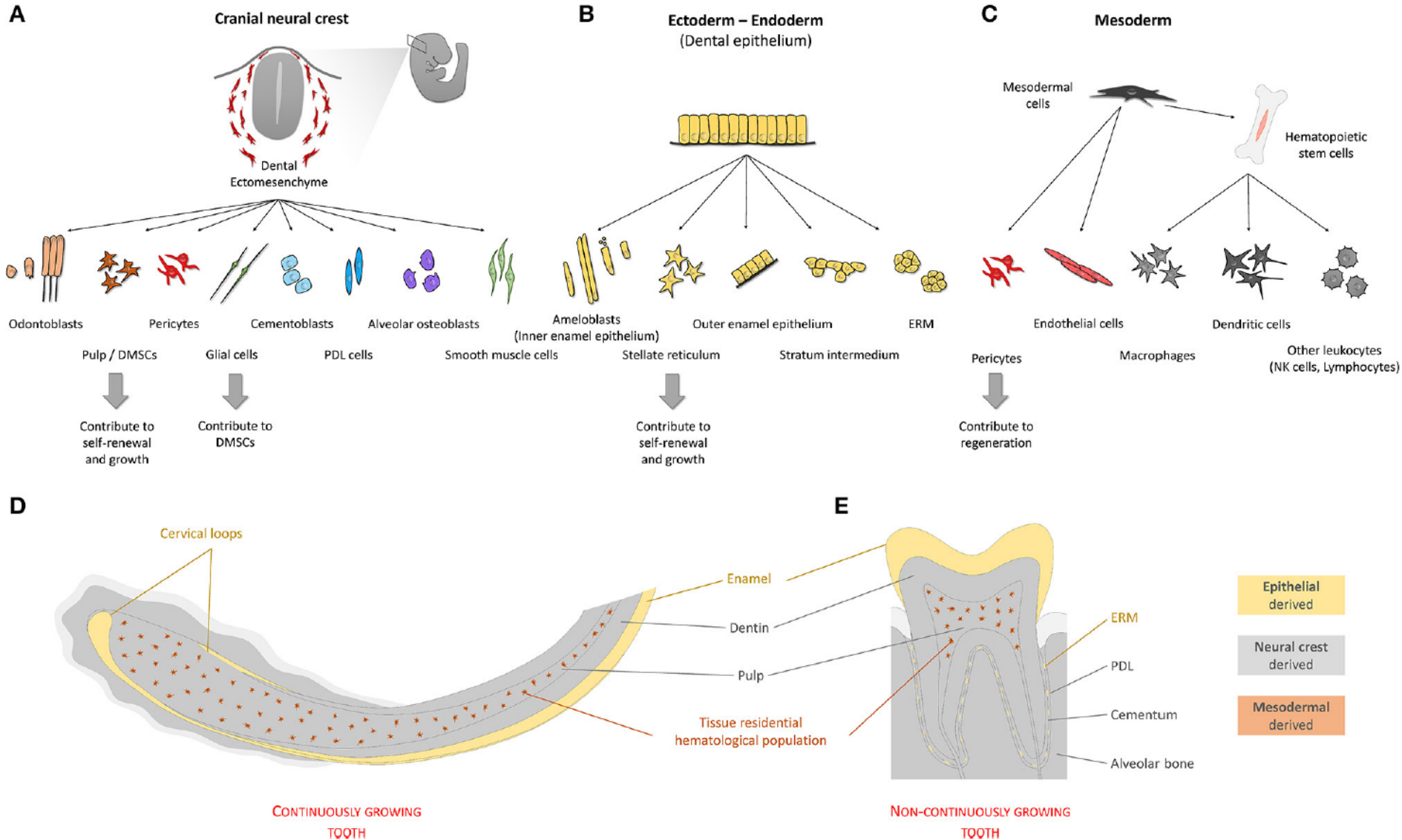
Root – emerges later (dentin and cementum)

Cementum formation = **cementogenesis**

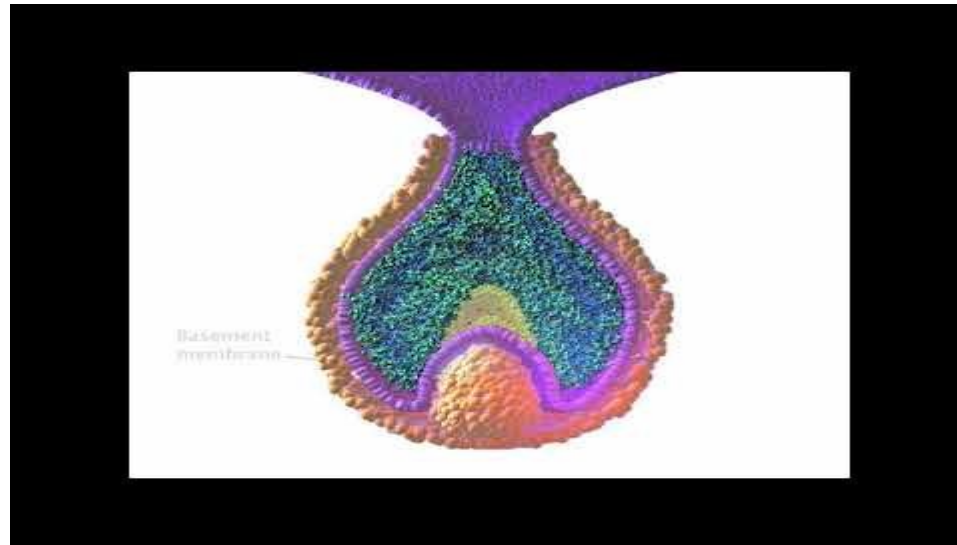
Mineralization
starting point



Cell types in tooth and their origin



<https://www.youtube.com/watch?v=QLNBjHgUHSU>



Chronology of primary and secondary dentition formation

Table 26.1 Chronology of tooth development and the order of eruption

Chronology of the deciduous dentition					Chronology of the permanent dentition				
Tooth	First evidence of calcification (months in utero)	Crown completed (months)	Eruption (months)	Root completed (years)	Tooth	First evidence of calcification	Crown completed (years)	Eruption (years)	Root completed (years)
<i>Maxillary</i>					<i>Maxillary</i>				
A	3-4	4	7	1½-2	1	3-4 months	4-5	7-8	10
B	4½	5	8	1½-2	2	10-12 months	4-5	8-9	11
C	5	9	16-20	2½-3	3	4-5 months	6-7	11-12	13-15
D	5	6	12-16	2-2½	4	1½-1¾ years	5-6	10-11	12-13
E	6-7	10-12	21-30	3	5	2-2½ years	6-7	10-12	12-14
					6	Birth	2½-3	6-7	9-10
					7	2½-3 years	7-8	12-13	14-16
					8	7-9 years	12-16	17-21	18-25
<i>Mandibular</i>					<i>Mandibular</i>				
A	4½	4	6½	1½-2	1	3-4 months	4-5	6-7	9
B	4½	4½	7	1½-2	2	3-4 months	4-5	7-8	10
C	5	9	16-20	2½-3	3	4-5 months	6-7	9-10	12-14
D	5	6	12-16	2-2½	4	1¾-2 years	5-6	10-12	12-13
E	6	10-12	21-30	3	5	1¼-2½ years	6-7	11-12	13-14
					6	Birth	2½-3	6-7	9-10
					7	2½-3 years	7-8	12-13	14-15
					8	8-10 years	12-16	17-21	18-25

Unless otherwise indicated all dates are postpartum. The teeth are identified according to the Zsigmondy system.

All dates are postpartum. Teeth are identified according to the Zsigmondy system.

Crown development

- **Polarity change** of cells in inner enamel epithelium (**IEE**)
- **Preameloblasts** differentiate as a first ones (epithelium differentiate faster then ectomesenchyme)
- **Preodontoblasts** differentiate based on mutual interactions with preameloblasts
- **Lamina basalis ameloblastica degradation**
- Maturation of **preodontoblasts into odontoblasts** = dentin synthesis initiation
- Followed by maturation of **preameloblasts into ameloblasts** = enamel synthesis initiation

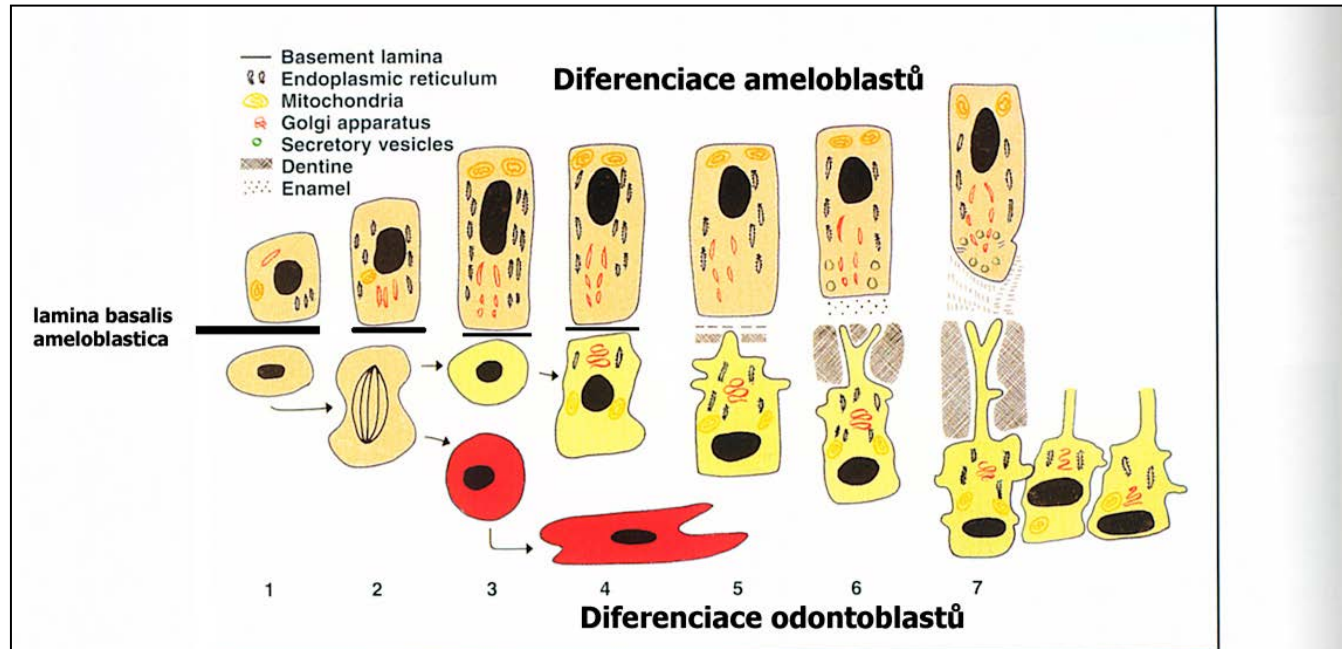
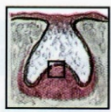

Fig. 23.1 Life cycle of the odontoblast (lower cell line) related to that of the ameloblast (upper cell line). 1 = Ameloblast begins to differentiate first. 2 = Peripheral ectomesenchymal cells divide, with some daughter cells migrating below the odontoblast layer. 3 = Acting on a signal from the ameloblast, the preodontoblasts begin to differentiate. 4 = Synthetic organelles increase in size and number, especially Golgi apparatus and rough endoplasmic reticulum. 5 = Nucleus moves basally as the cell becomes polarised. A number of odontoblast processes begin to form. One odontoblast process becomes enlarged and begins to secrete matrix. 6 = The odontoblast retreats as matrix is laid down, leaving behind a single main process. Once a narrow layer of matrix is laid down mineralisation commences. 7 = Once the first layer of dentine is laid down the differentiated ameloblast begins to deposit matrix.



Balogh and Fehrenbach 2011

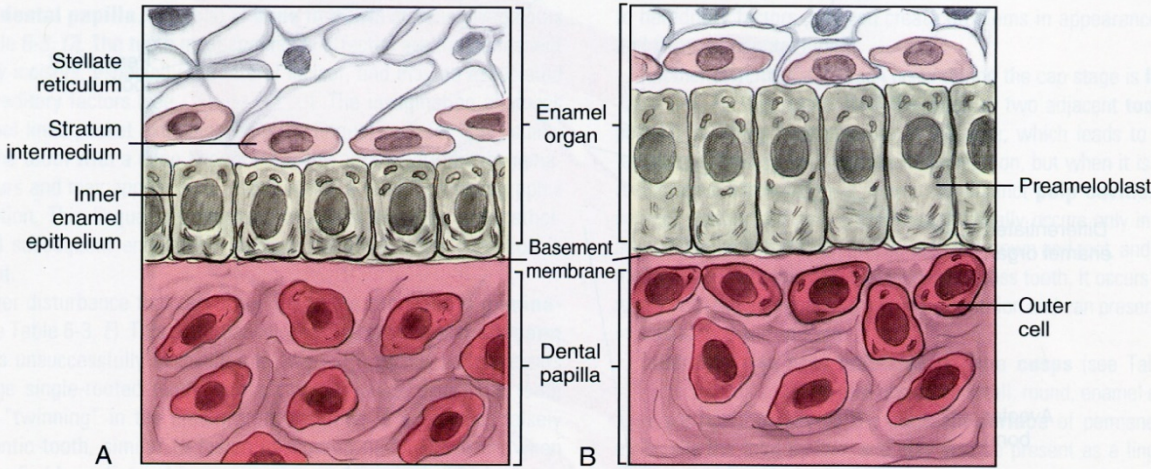


FIGURE 6-9 Close-up of inner enamel epithelium of the enamel organ differentiating into the preameloblasts, the future cells that will secrete enamel matrix. **A:** Inner enamel epithelial cells, with their central nuclei, line up along the basement membrane. **B:** Inner enamel epithelial cells that have elongated and repolarized their nuclei to become preameloblasts. Note the outer cells of the dental papilla

Balogh and Fehrenbach 2011

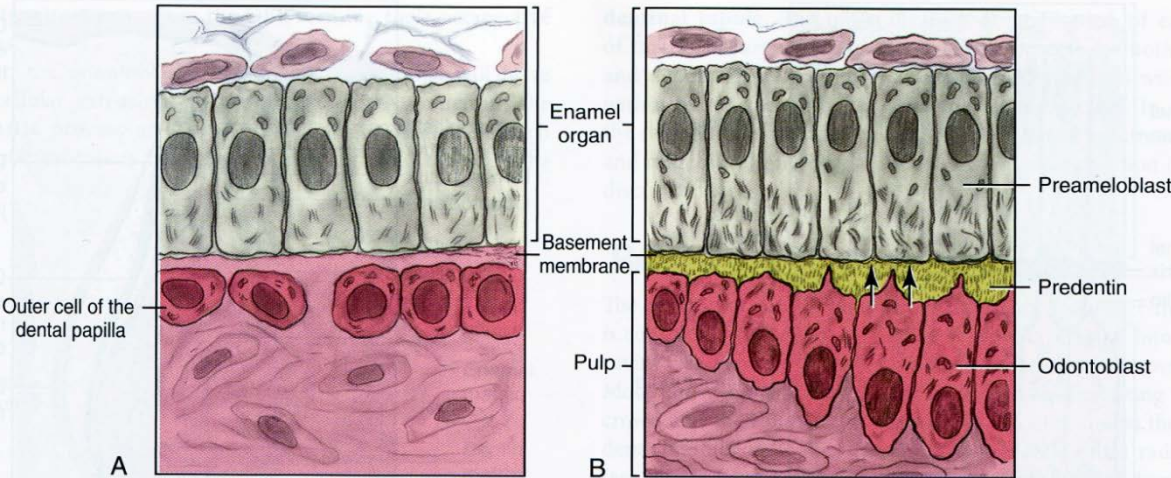
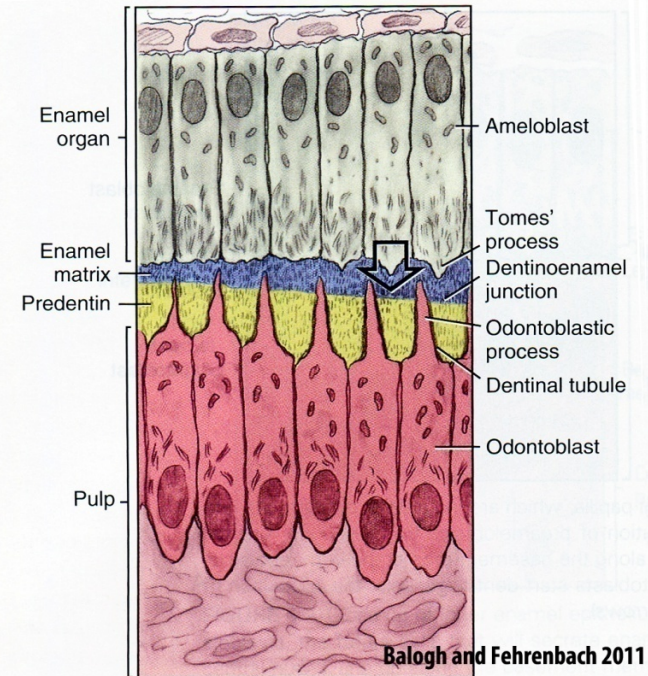


FIGURE 6-10 Close-up of the outer cells of the dental papilla, which are induced to differentiate into the odontoblasts and form predentin after the formation of preameloblasts from the inner enamel epithelium. **A:** Outer cells of the dental papilla line up along the basement membrane with repolarization of their nuclei to become odontoblasts. **B:** Odontoblasts start dentinogenesis, the apposition of predentin on their side of the basement membrane (arrows).

Repolarization of inner enamel epithelium
→ preameloblasty

Repolarization of dental papilla cells
→ preodontoblasty

Lamina basalis ameloblastica degradation –
by maturation of preameloblasts into
ameloblasts



Balogh and Fehrenbach 2011

FIGURE 6-12 Preameloblasts being induced to differentiate into ameloblasts and beginning amelogenesis from Tomes' process (large arrow), with the apposition of enamel matrix on their side of the basement membrane. Later this membrane will disintegrate and mineralize to form the dentinoenamel junction. Note that the predentin is thicker than the enamel matrix because the odontoblasts differentiate and start matrix production earlier than the ameloblasts. The predentin forms around the dentinal tubules that contain the odontoblastic process attached to the odontoblasts.

Amelogenesis

Amelogenesis

Apexes of differentiated ameloblasts after repolarization are directing towards the deposited dentin matrix and odontoblasts. Base (with nuclei) is located next to the stratum intermedium

Thin and long cells (50 μm), apical part of cells contain Golgi apparatus and rER (secretory grain formation)

Ecrine secretion of granules above the junction complexes

Granules contains proteins essential for enamel backbone formation:

a) Amelogenins (90 %)

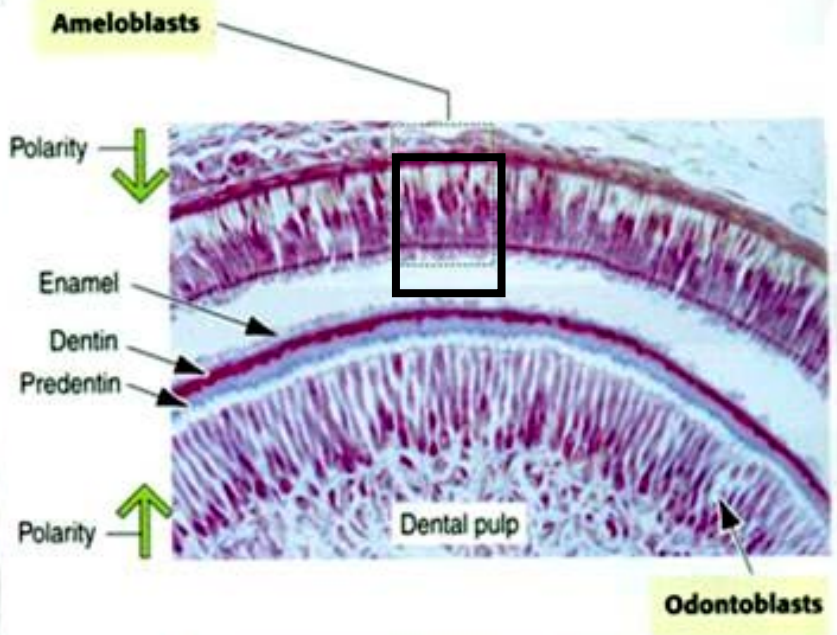
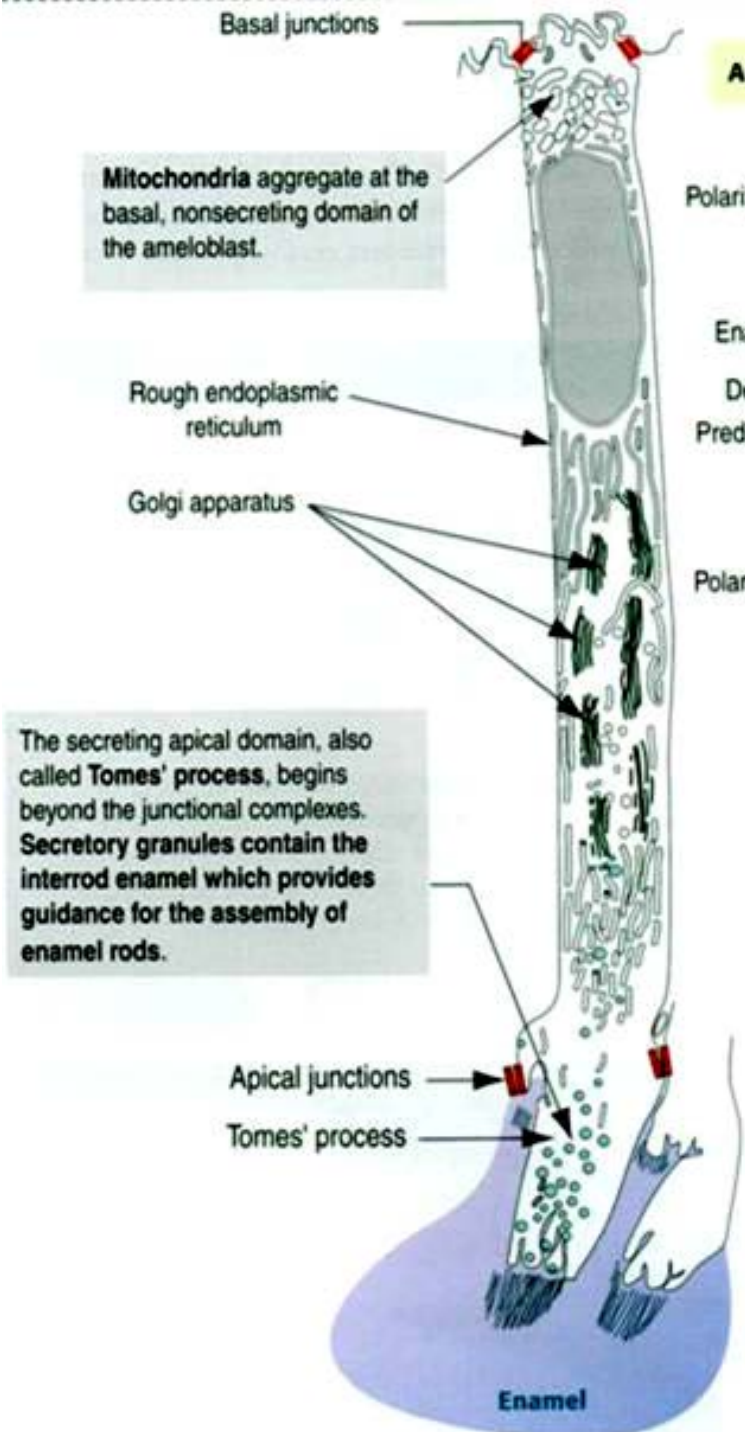
- Main product of ameloblasts secretory stage
- Spherical polymers, regulation of enamel prisms growth

b) Non-amelogenins

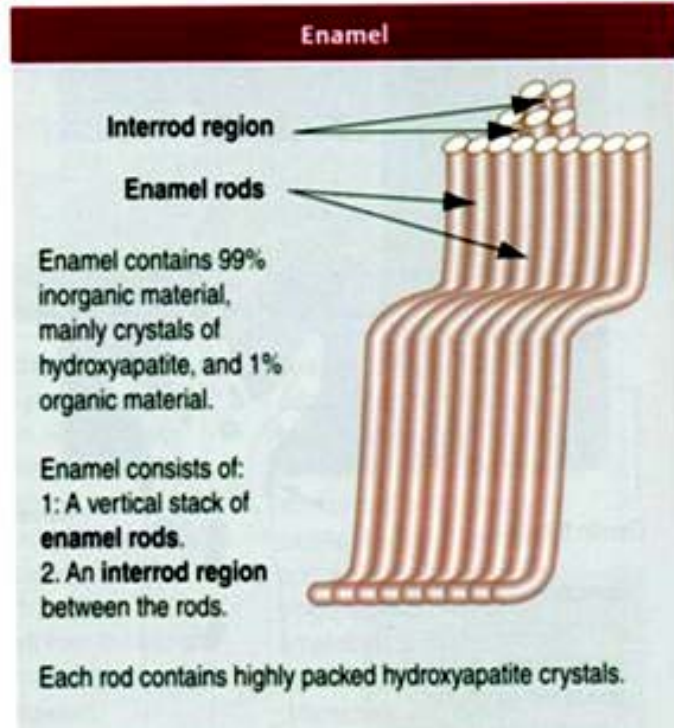
- Enamelin – Nucleation and direction of growth regulation of crystals
- Ameloblastin – Adhesive molecule
- Kalikrein 4 – Protease secreted by ameloblasts in the final secretory stage
- Tuftelin – Stabilizes connection to dentin

c) Proteins with enzymatic activity

- Metalloproteases (MMP20) – amelogenin degradation
- Alkalic phosphatase, phosphomonoesterase and serinprotease 1



The secreting apical domain, also called **Tomes' process**, begins beyond the junctional complexes. **Secretory granules** contain the **interrod enamel** which provides guidance for the assembly of enamel rods.



Amelogenesis

All ameloblasts are gradually engaged in enamel secretion and each creates single prism.

Prisms grow from the apical ends of the ameloblasts.

Prisms doesn't grow continuously, but periodically (with regular alternation of the maximum secretory activity phase and the resting phase)

During one cycle the prism is prolonged by about 15-30 micrometers with the manifestation on the dental cuts – the Retzius lines – (ending by perikymata)

Period length: about 4 days

Prisms formation - 3 phases:

- **Organic backbone formation** – proteins, glykopolysacharides, lipids
- **Mineralization** - crystallization centers are formed in the matrix. Hydroxylapatite is deposited here in the form of submicroscopic crystals
- **Maturation** - crystal growth associated with organic matrix loss

Incremental enamel lines

Result of periodical ameloblasts activity

a) Day lines

- Cause prisms cross-striation, very thin (2,5 - 6 μm)
- Circardial rhythms

b) Stripes of Retzius (enamel striae)

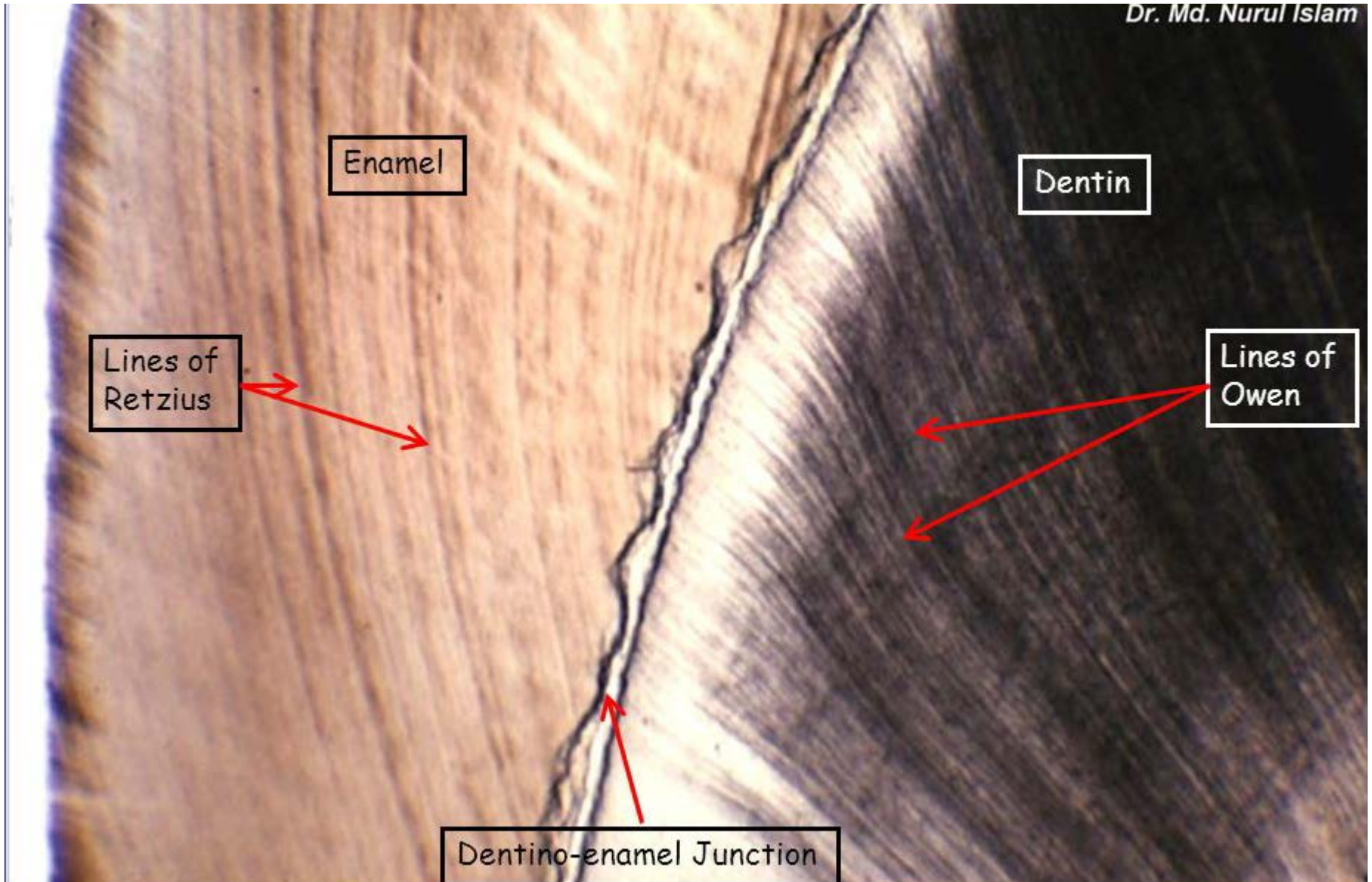
- Can be observed under optical microscope on ground sections
- From DEJ to enamel surface
- Forms perikymata

c) Neonatal line

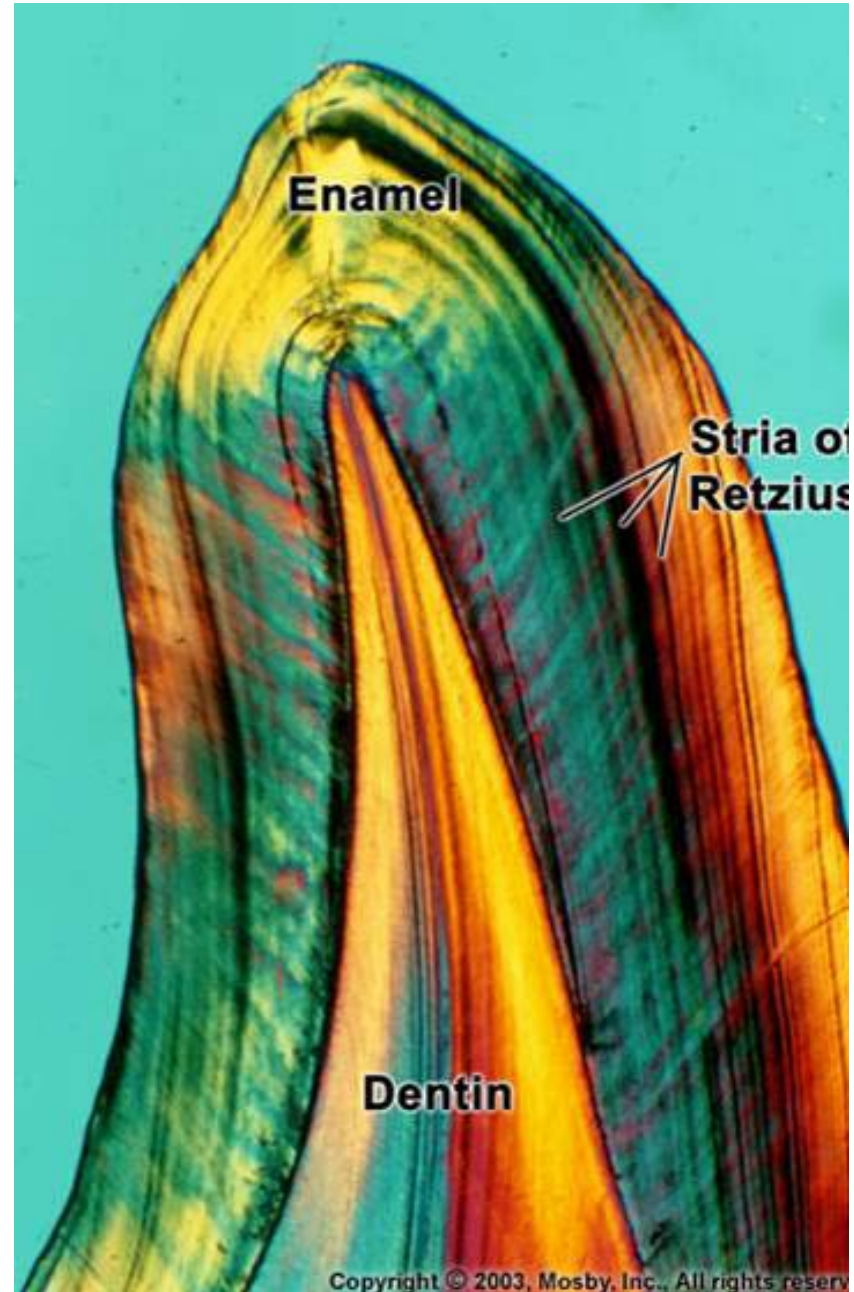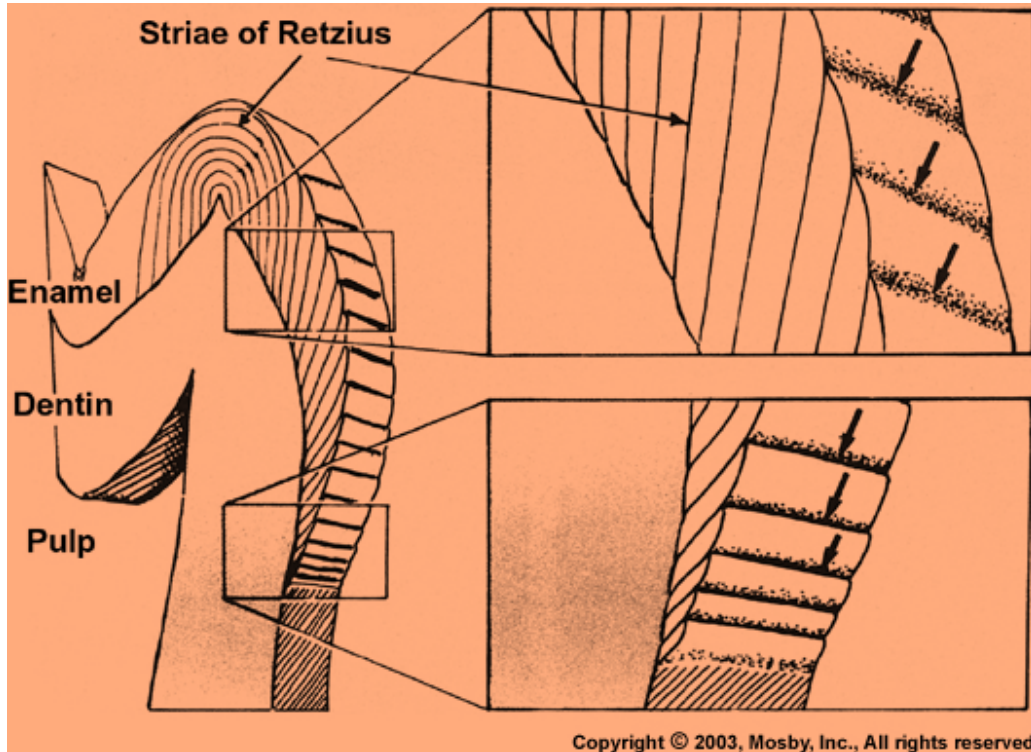
- Belongs to Striae of Retzius
- Due to abrupt change in nutrition

Retziusovy linie

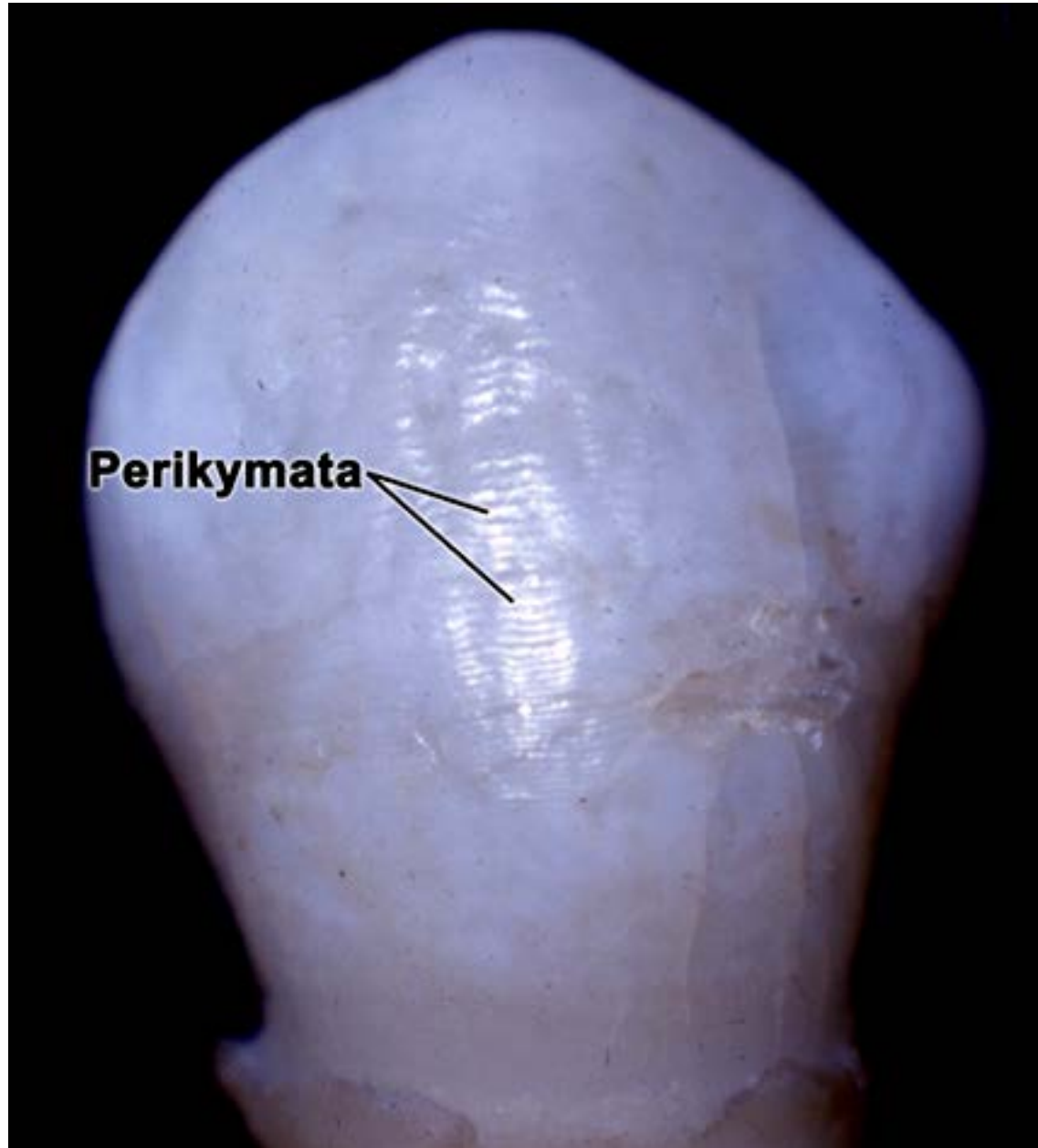
Dr. Md. Nurul Islam




Retzius striae



Perikymata



Neonatal line



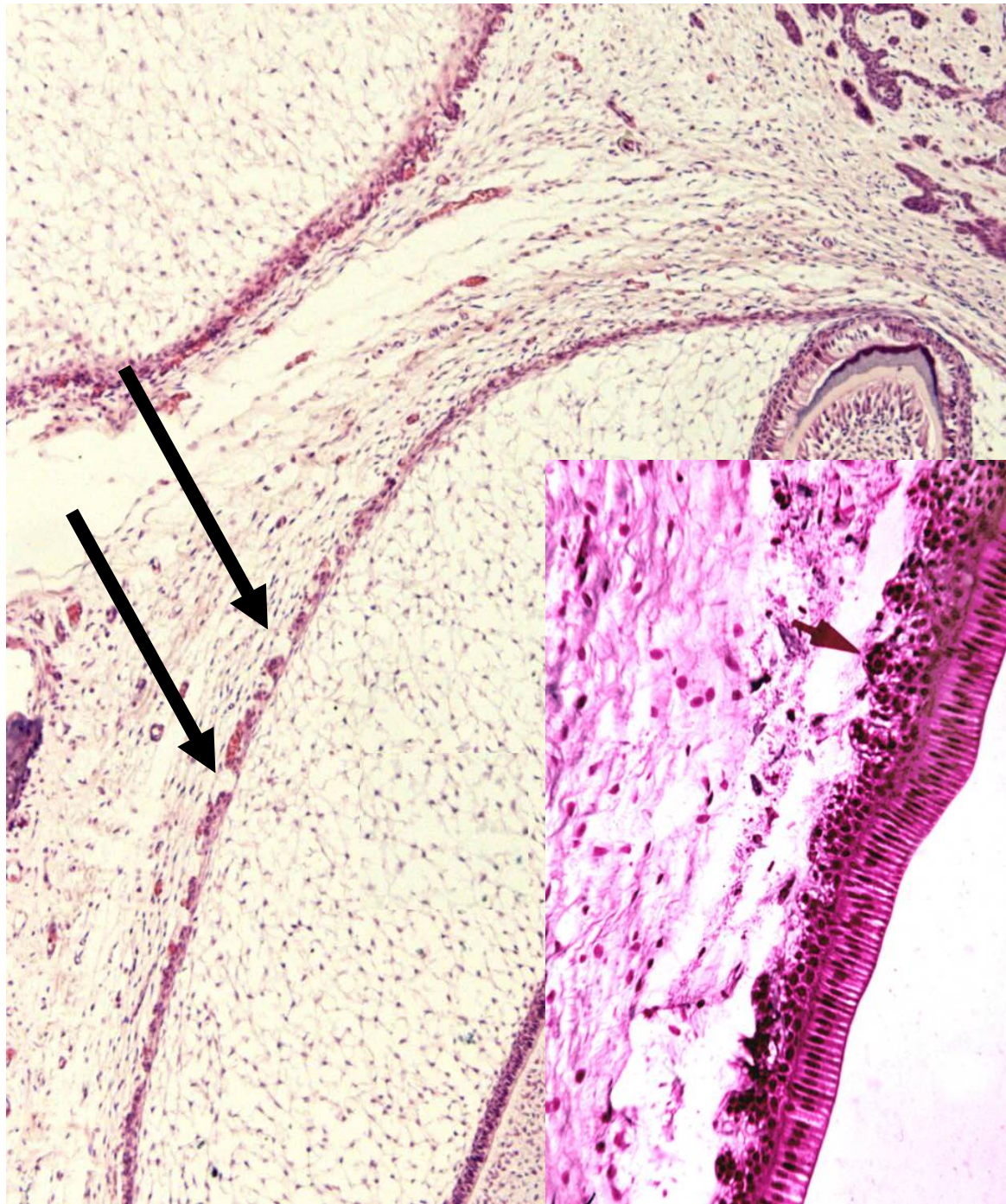
Nutrition of ameloblasts

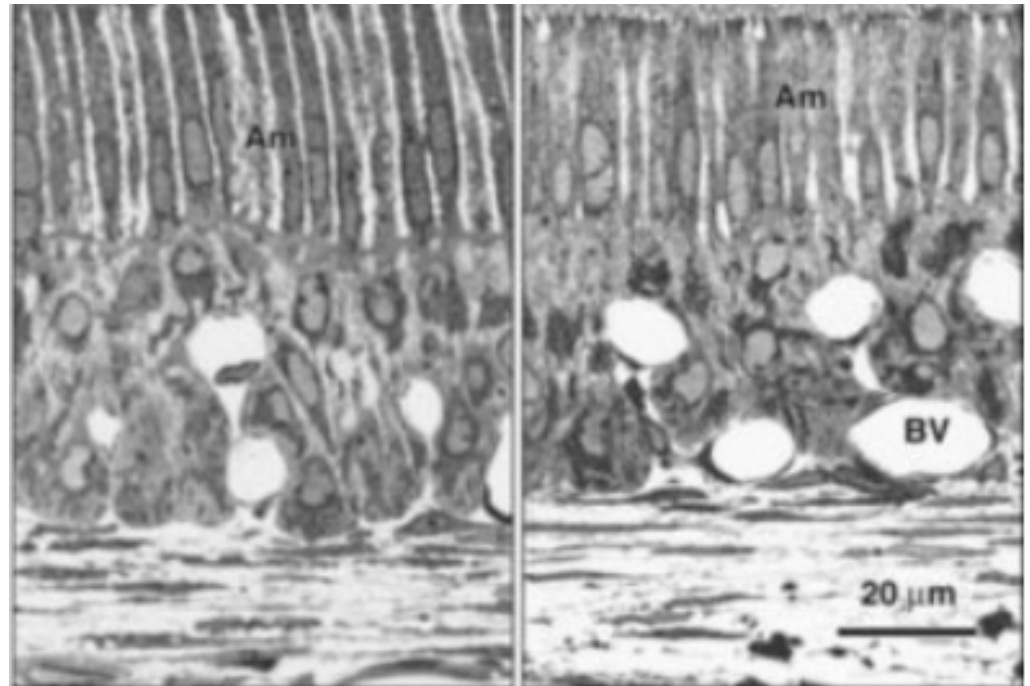
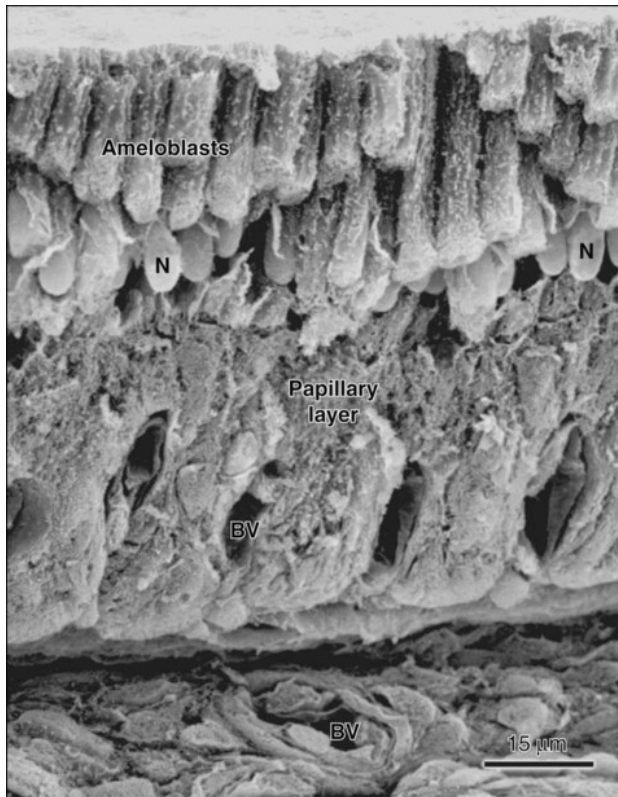
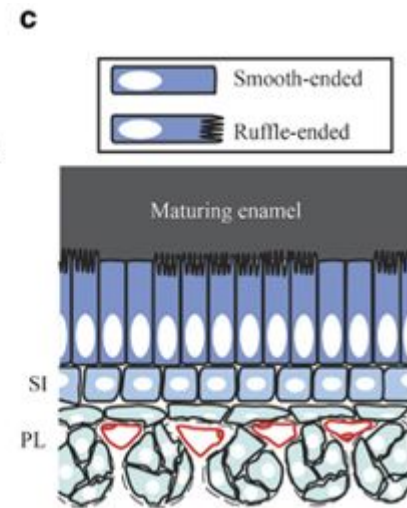
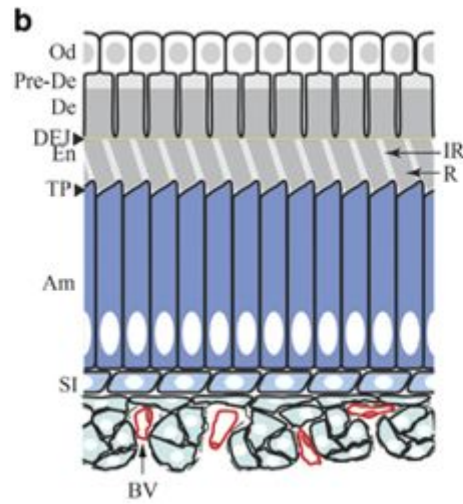
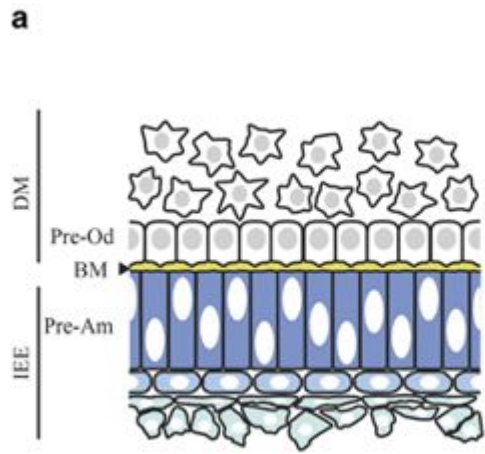
Develops before the formation of prisms - focal death of cells from the outer enamel epithelium (apoptosis)

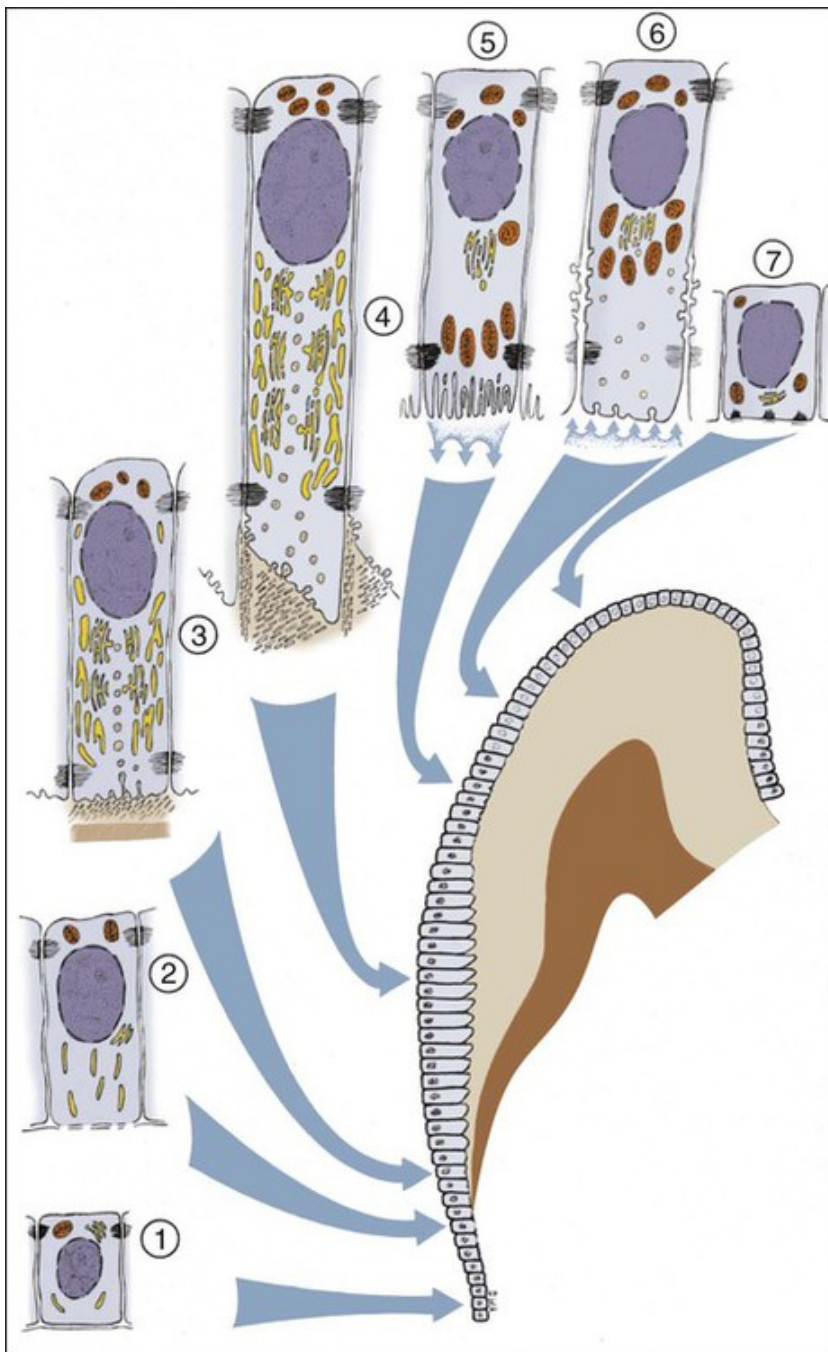
Through these openings in the outer enamel epithelium, blood vessels penetrate into the stellate reticulum - providing ameloblast nutrition

Reduction of epithelial reticulum and intracellular mucoid substance

Finally stays only:
**Stratum intermedium +
Ameloblasts**








Schematic representation of the various functional stages in the life cycle of ameloblasts as would occur in a human tooth

- 1) Morphogenetic stage
- 2) Histodifferentiation stage
- 3) Initial secretory stage (no Tomes' process)
- 4) Secretory stage (Tomes' process)
- 5) Ruffle-ended ameloblast of the maturative stage
- 6) Smooth-ended ameloblast of the maturative stage
- 7) Protective stage

Before the end of secretory activity, the ameloblasts form a thin layer of organic substance on the enamel surface - **cuticula dentis**

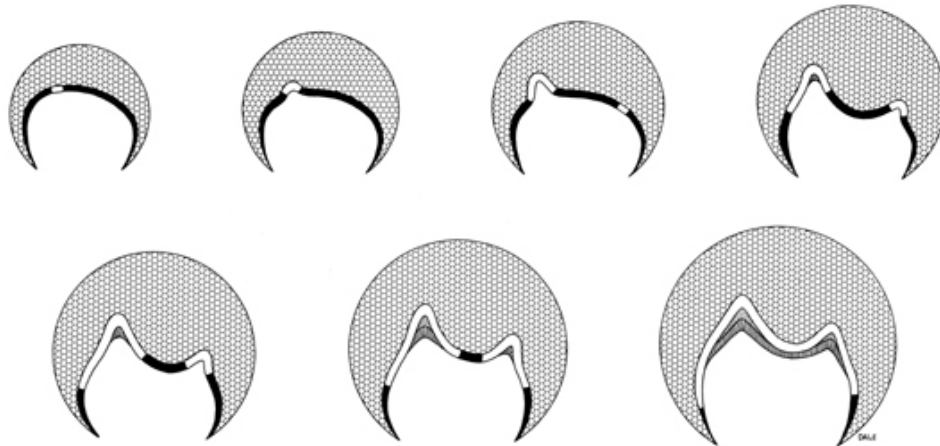


After the end of the secretion, the ameloblasts shorten and blend into the stratum intermedium cells, resulting in the so-called **reduced enamel epithelium** - protects the crown during its pruning.

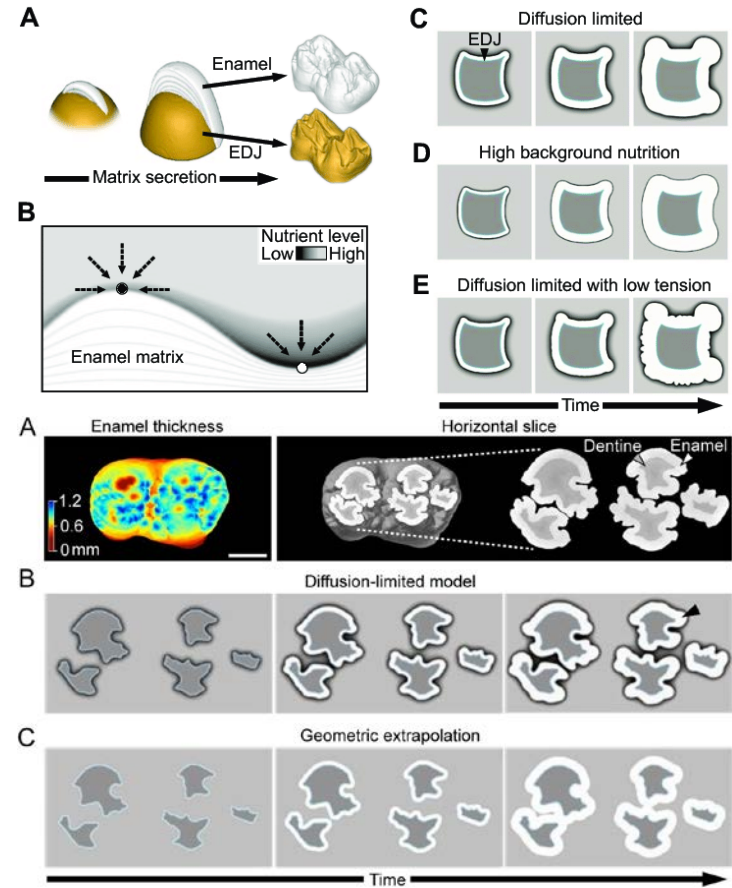
Crown shape

Zodpovědné procesy:

1. Primary patterning of tooth shape – **enamel knots**
2. The number of **growth centers** in the dental cup - the sites where cells start secretory activity. They are defined during the differentiation of ameloblasts by the mechanisms of embryonic induction by odontoblast signalling molecules
3. Ameloblasts nutrition during enamel production (*Häkkinen et al., 2019 BioRxiv*)



Copyright © 2003, Mosby, Inc., All rights reserved.



Dentinogenesis

Dentinogenesis

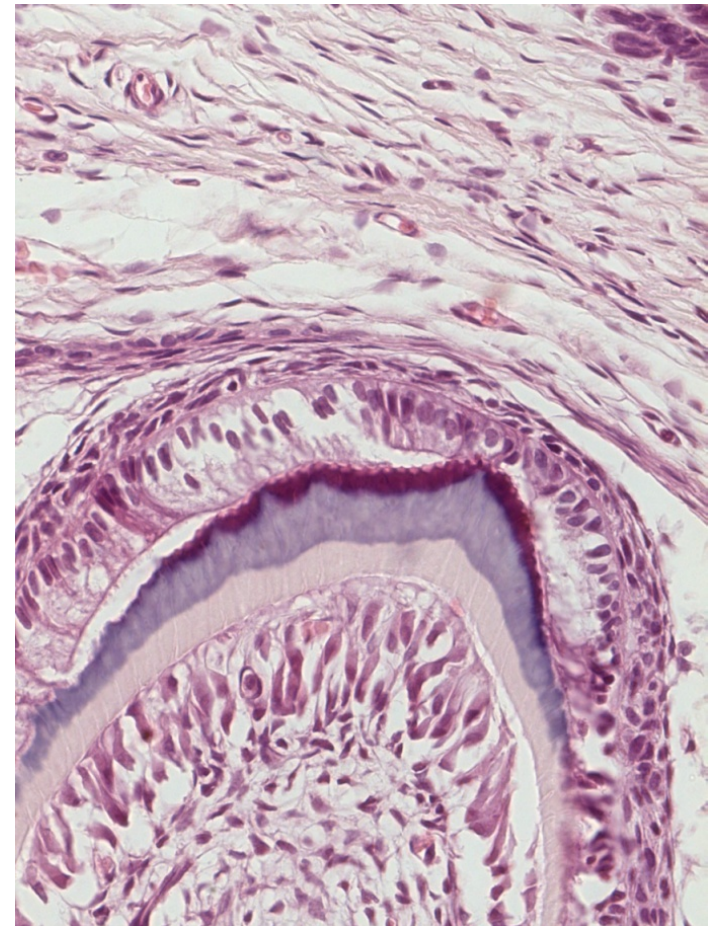
The dentine matrix is secreted by the odontoblasts that originate from the surface layer of the ectomesenchyme of the dental papilla

Odontoblasts located on the growth center (top of the dental papilla) initiates secretory activity

Dentine matrix precursors are collected in odontoblasts' apices located opposite to ameloblasts' apices

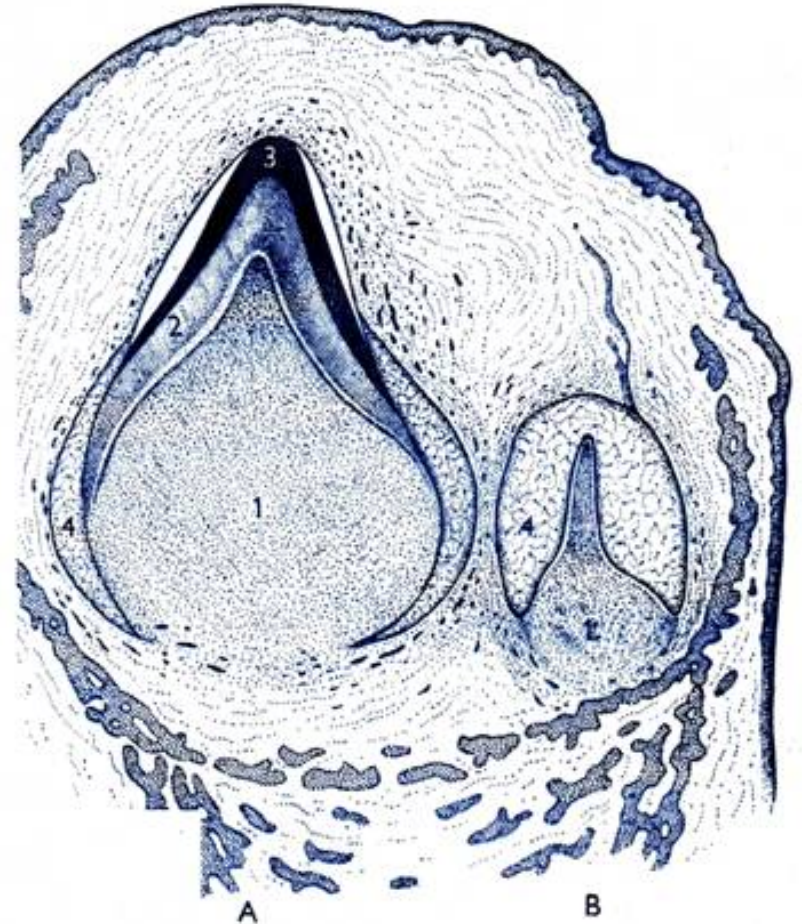
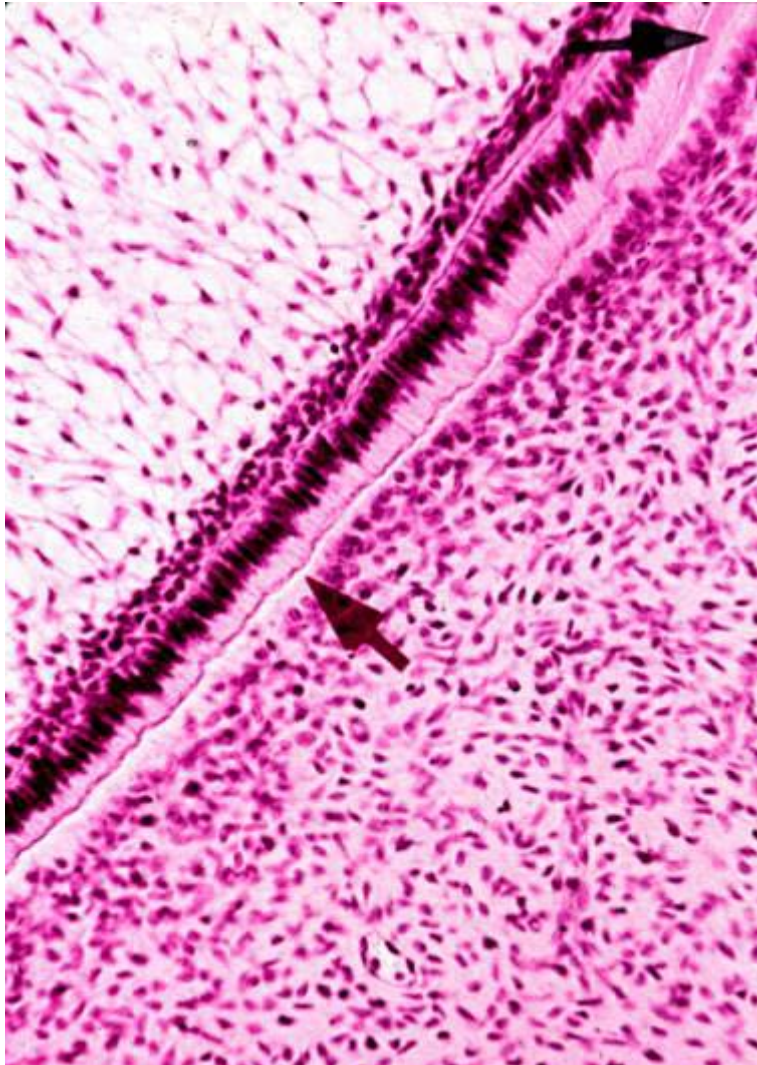
Firstly formed matrix is non-calcified composed of **Collagens (I + III)** and **proteoglycans** (versican, keratansulphate, decorin, chondroitinsulphate)

Odontoblasts and ameloblasts are moving away from each other during matrix formation



In addition to the odontoblasts on the growth center, also odontoblasts of other dental papilla compartments are gradually involved into matrix production

All odontoblasts forms together a dentine base of the crown (and later root)



Obr. 83.
Vývoj zubu. Dobaňazý zub ve stadiu sponice (A), časné stadium vývoje zubu trvalého (B). Zubní papila (1), dentin (2), sklera (3), orgán skloviny (4).

In the first layers of matrix are only reticular fibres

Radial bundles – **Korff's bundles** - can be visualized by silver salts (in mantle dentine)

Only after depositing the Korff's bundles, odontoblasts will begin to deposit collagen fibers that run longitudinally - perpendicular to the dentinal tubules

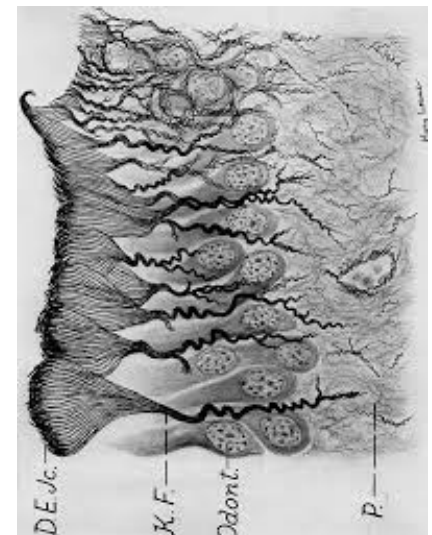
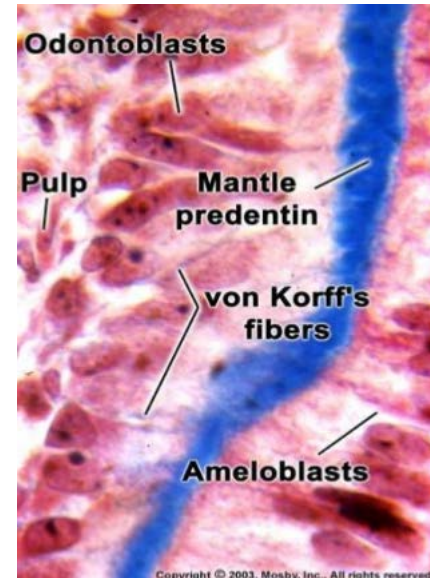
Calcification of the dentin matrix is a complex process of participation of the alkaline phosphatase enzyme. Its activity had been demonstrated both in the bodies and the processes of odontoblast.

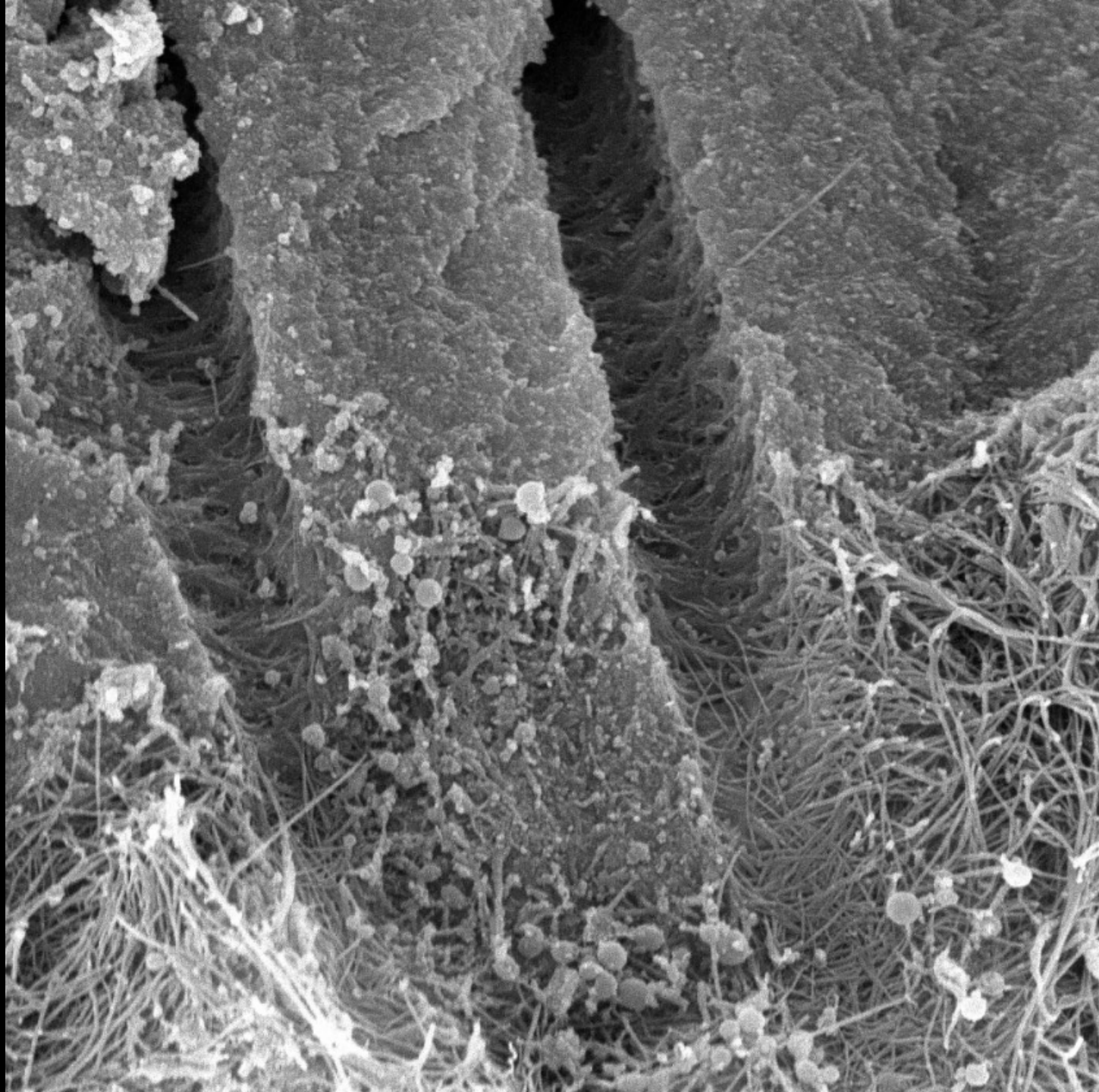
4 day increments calcify together

(*subcrystalline crystallization centers* → *calcispheres and interglobular regions* → *calcisphere merging*)

Dentine matrix in the closest proximity of odontoblasts never calcify

= **predentin**





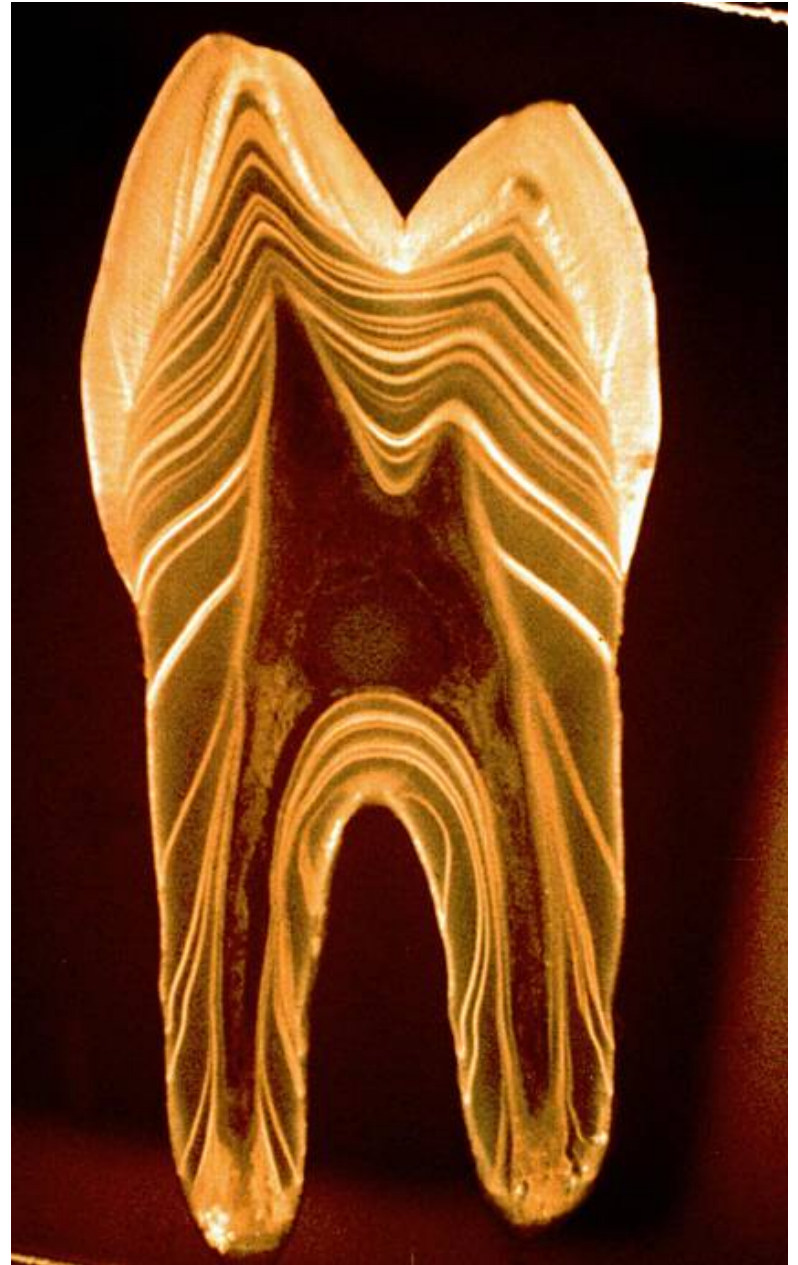
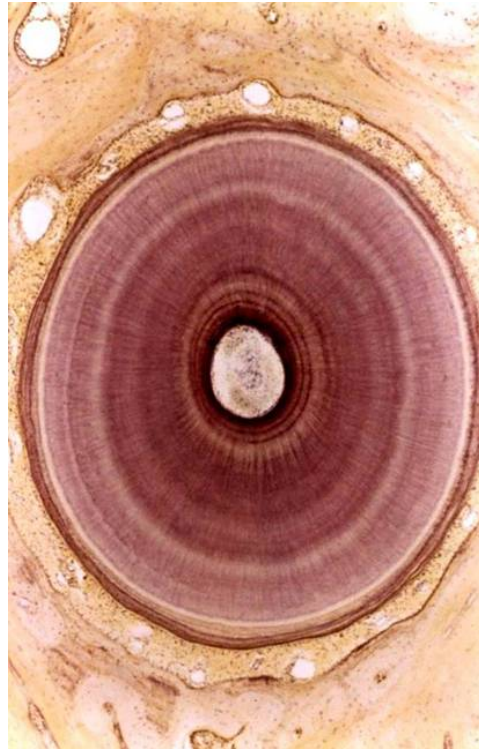Periodical matrix formation

4-8 $\mu\text{m}/\text{day}$

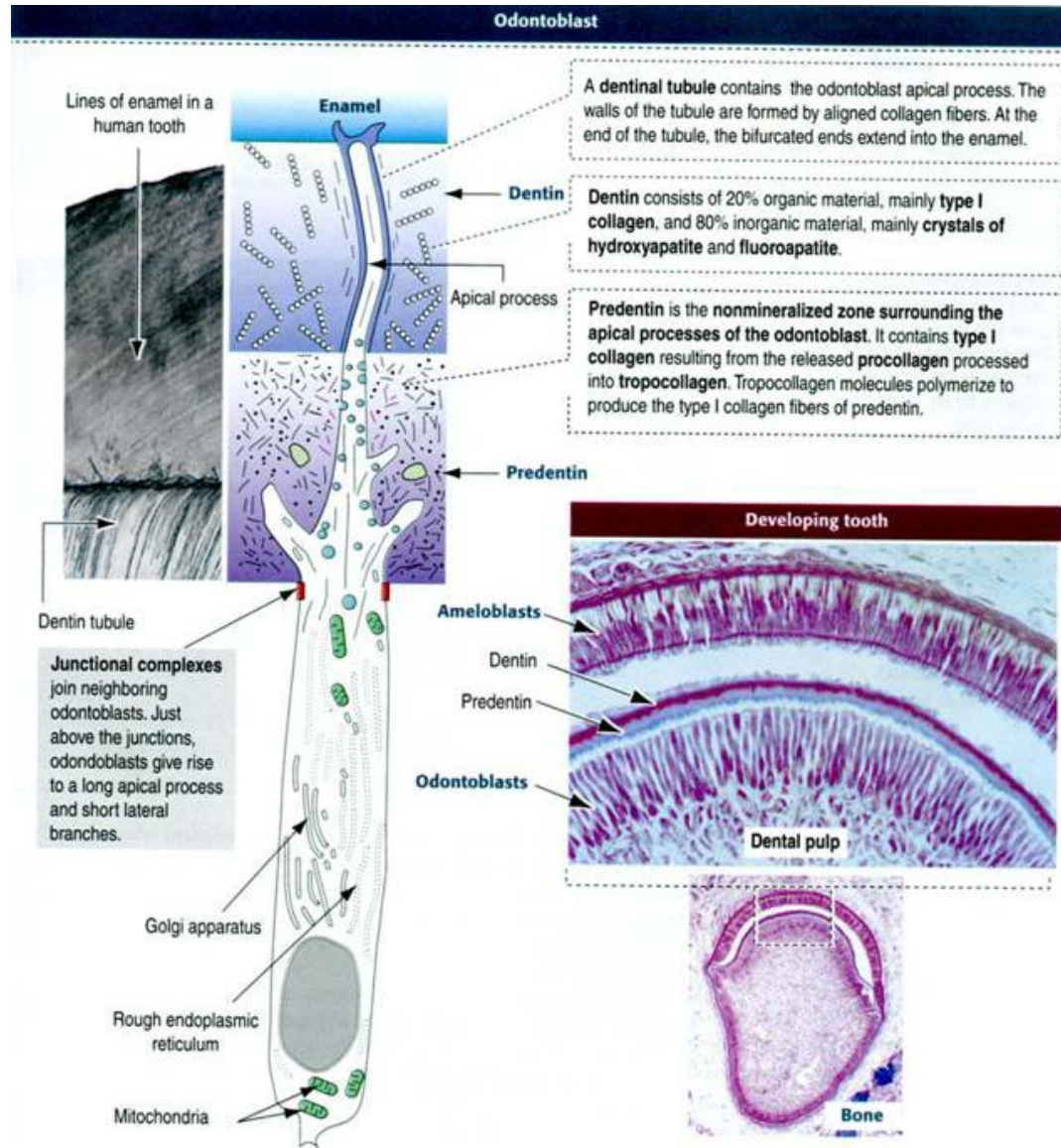
(Ebner's lines on decalcified slides)

4 day increments calcify together

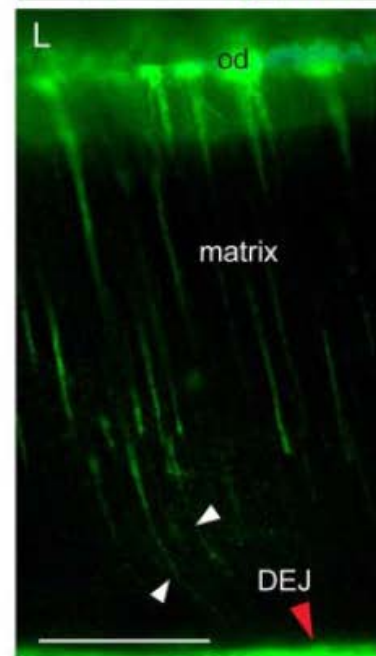
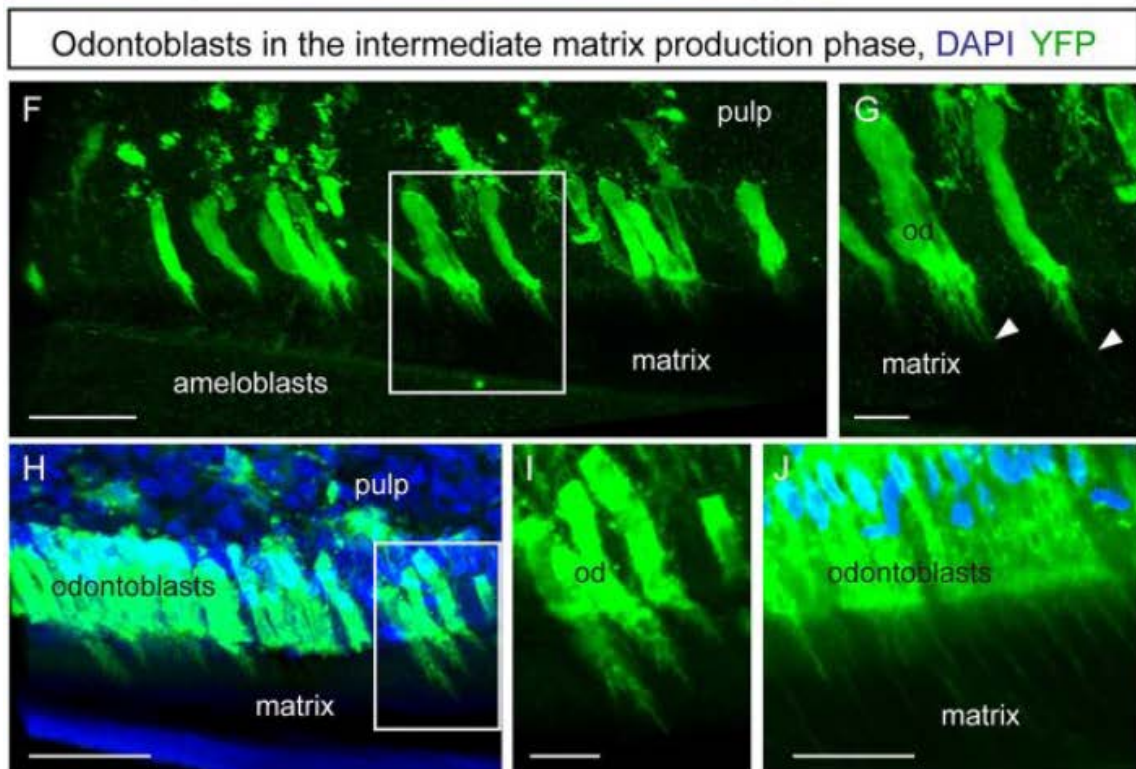
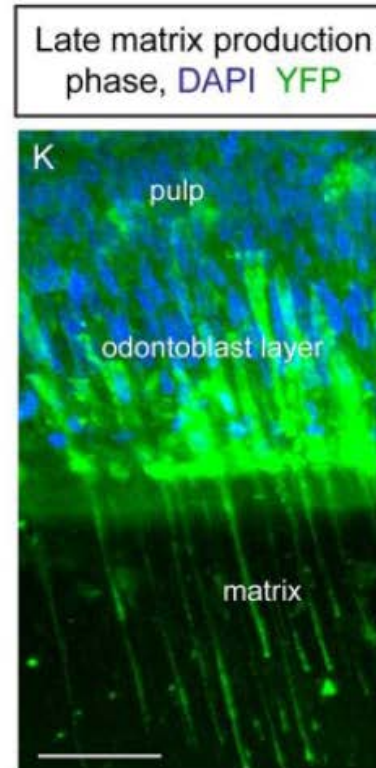
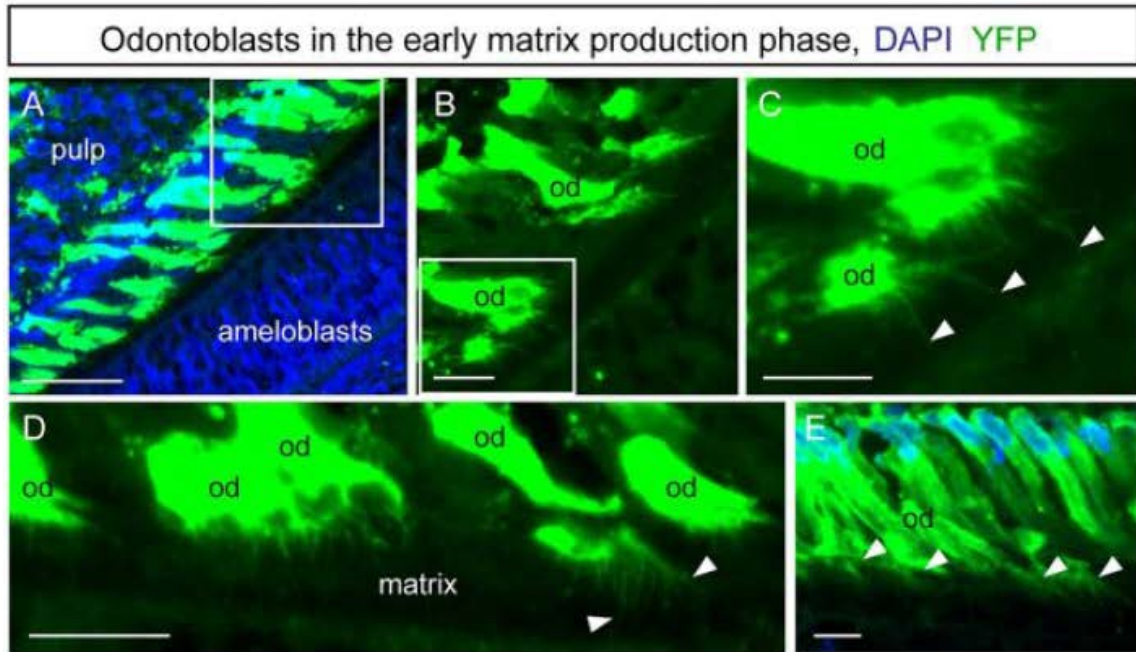
(Owen's line on dental cuts)



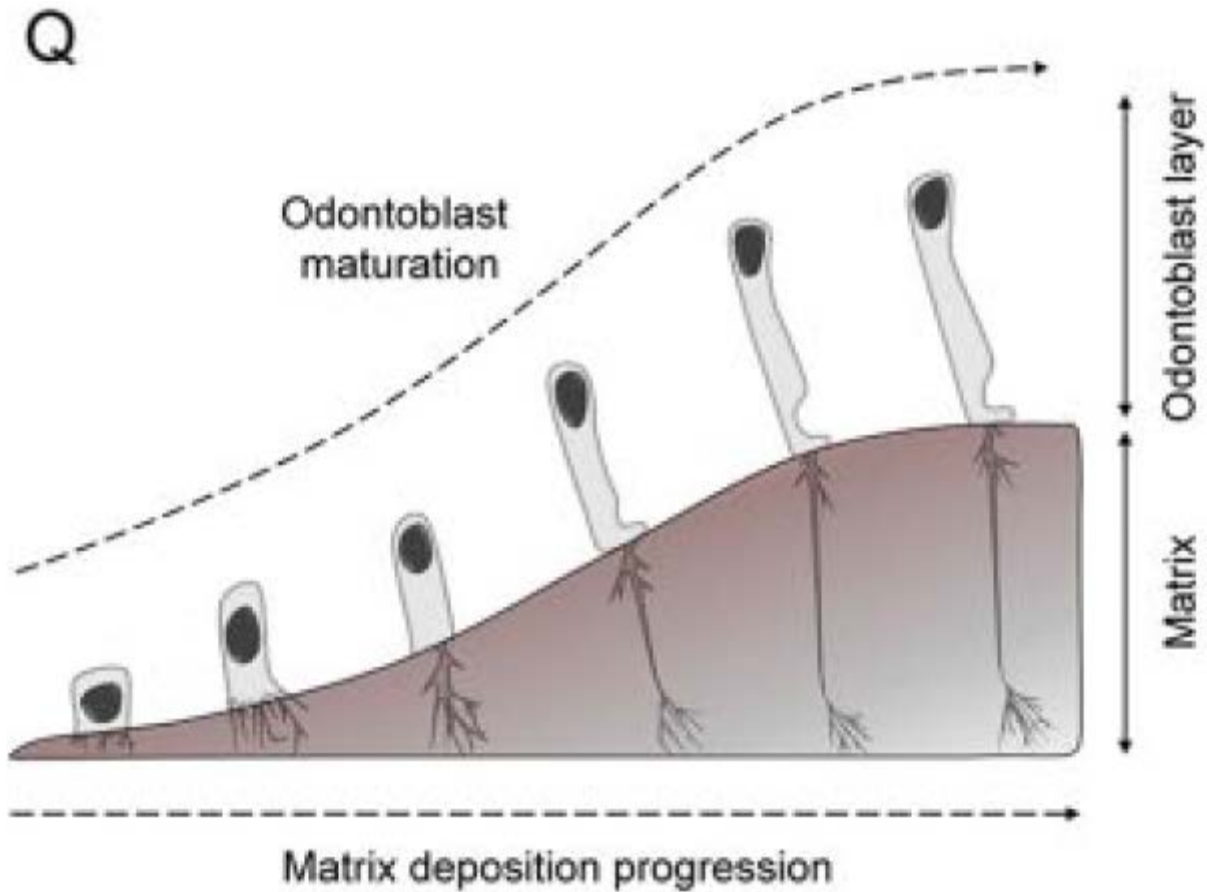
As the dentine matrix grows, the apical parts of the odontoblasts are pulled out into thinner and thinner processes, and after calcification of the matrix, they are permanently embedded as Tomes' fibers in the dentin channels



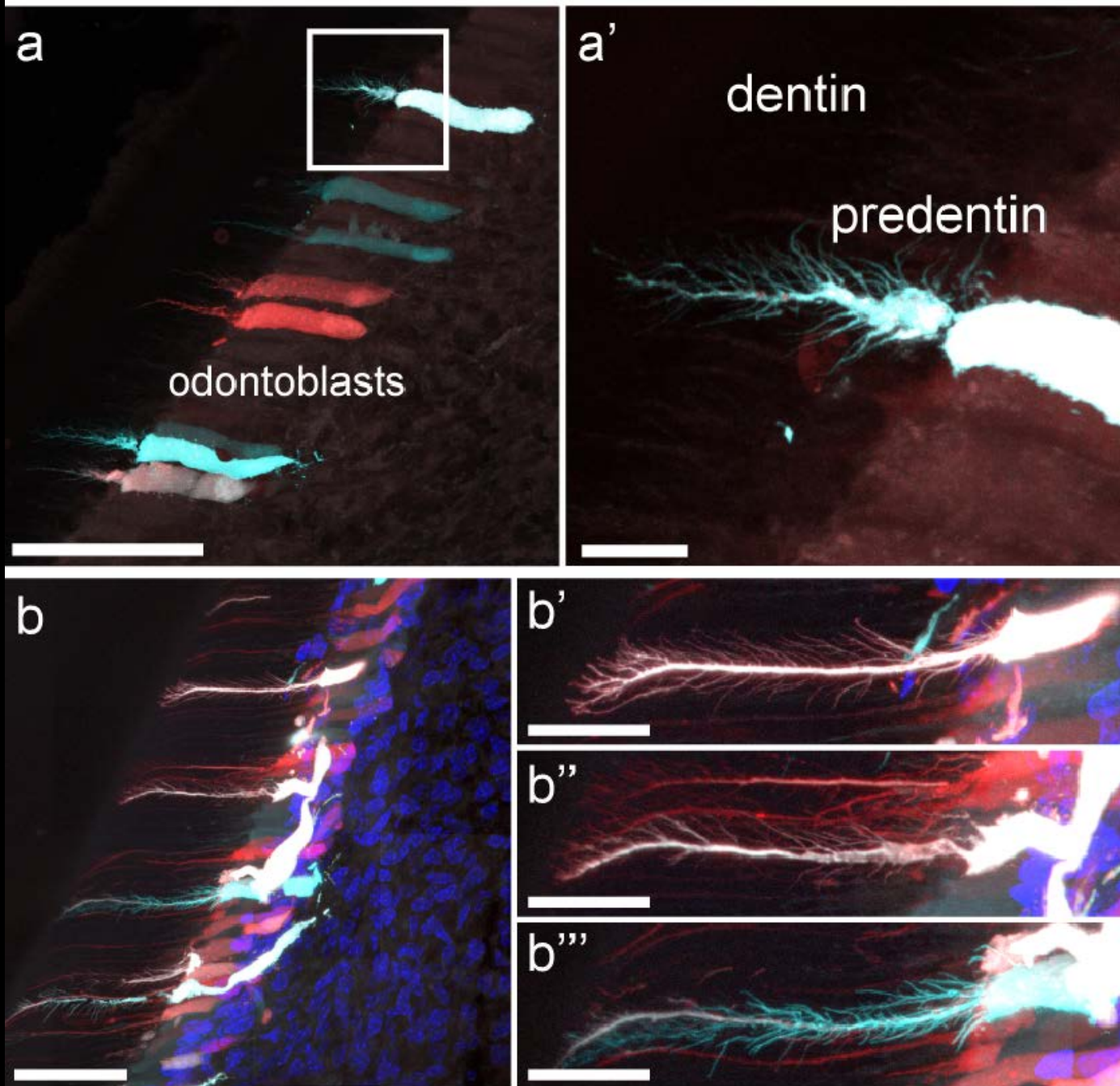
Odontoblasts development



Odontoblasts development



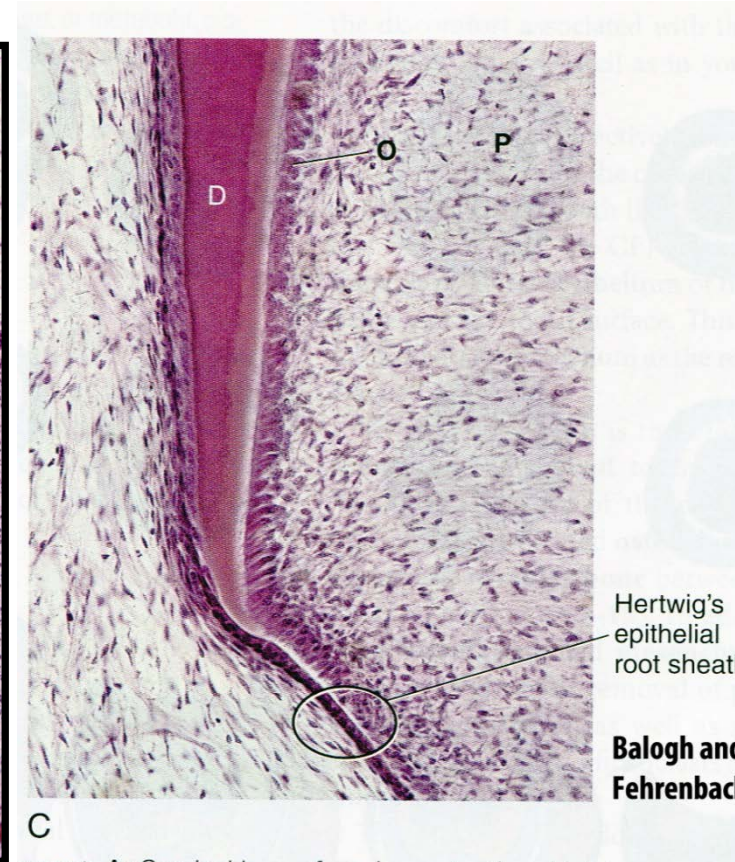
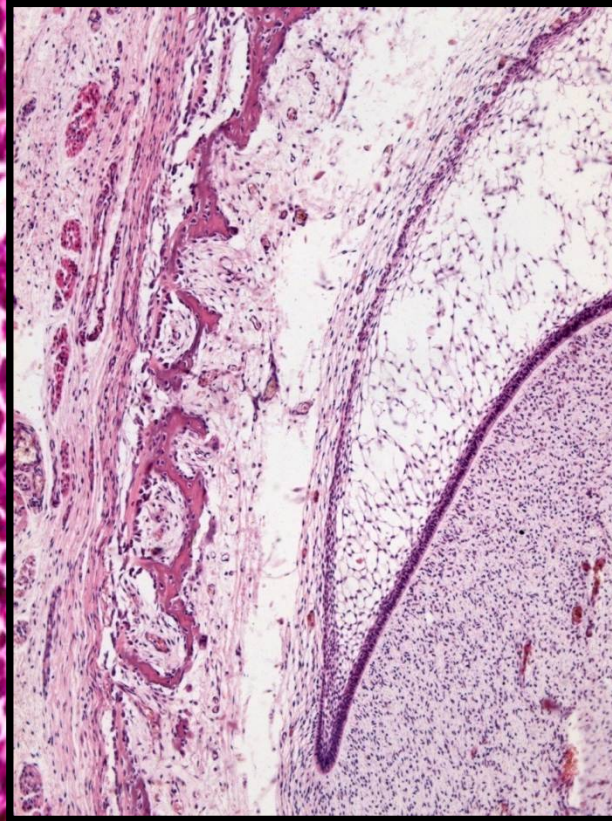
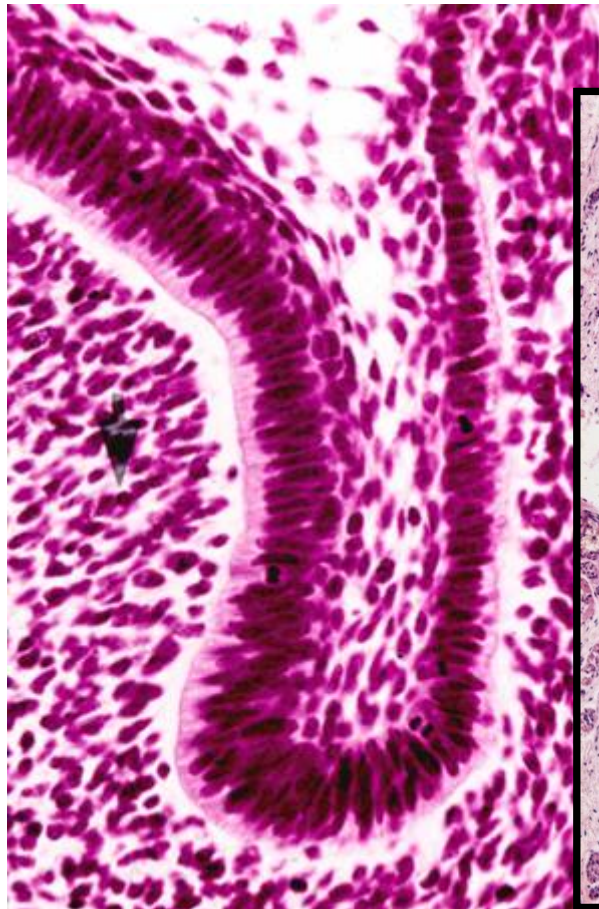
Odontoblasts dentinal processes analysis



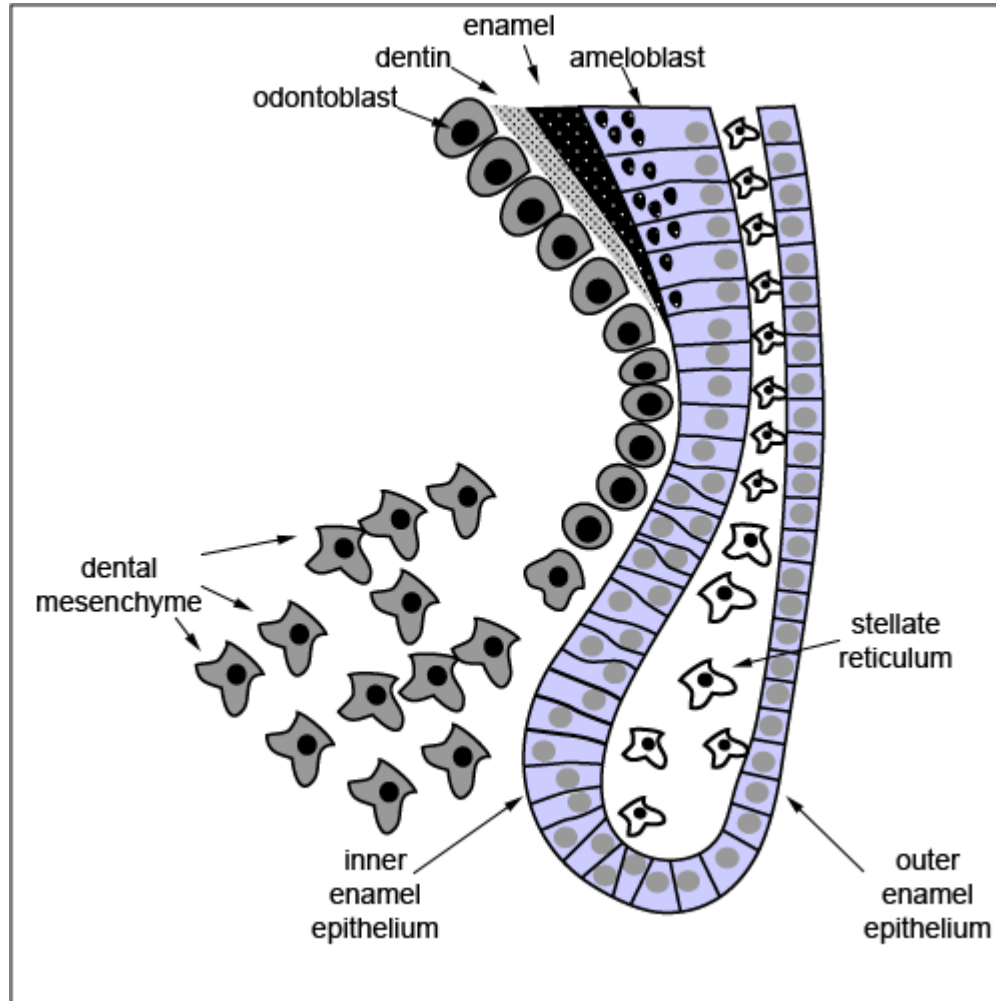
Root development

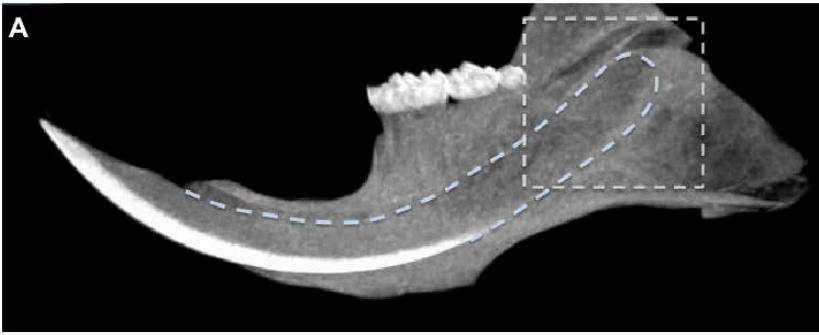
Root development

- The root dentine begins to develop only after the crown dentine is deposited
- Development is under the **supervision of the enamel organ**
- Cells from the **cervical loop** proliferate towards the apex of the future root
- Proliferating and extending part of the dental cup, consisting only of IEE and OEE = **Hertwig's epithelial root sheath (HERS)**

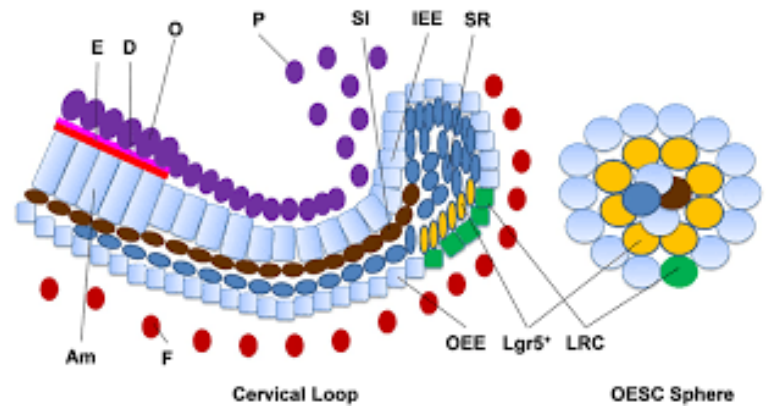
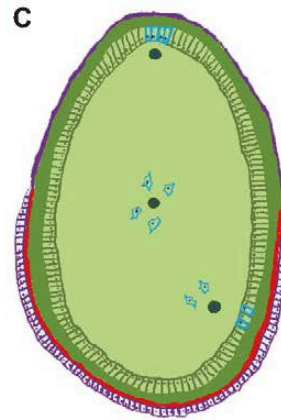
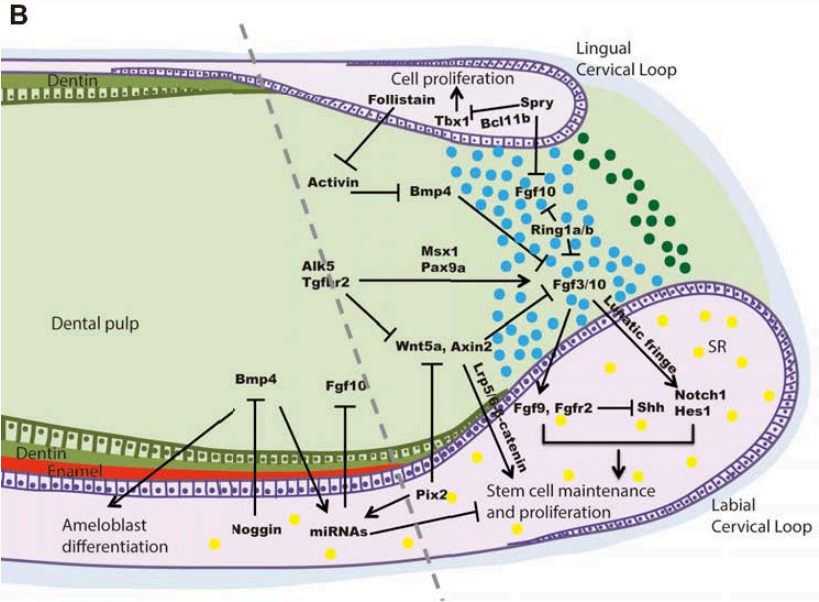


Cervical loop





- Maintaining of **Stem cell niche**
- Extensive signalization both inside and outside the epithelium
- Model system for the study of tissue regeneration and repair



(Paul T Sharpe, *Development* 2016)

Dentinogenesis (root)

The inductive effect of the Hertwig's epithelial root sheath (HERS) provide differentiation signals to ectomesenchyme to differentiate into odontoblasts that initiate the deposition of the dentin matrix of the root

Once the dentine of the root is formed, HERS disintegrate and cells of ectomesenchymal-origin from dental sac migrate near the root to form cementum and periodontium

Remnants of the Hertwig sheath in periodontium exist as **Epithelial Rests of Malassez (ERM)**

Shape of root depends on the shape of apical opening

Apical opening of HERS can be:

- **circular** - one root
- **divided by horizontal discs** - called diaphragms on several secondary apical holes

The number of diaphragms determines the number of roots (branches) of the tooth (in multi-root tooth diaphragm divides papilla into sections)

Apical part of HERS

Balogh and Fehrenbach 2011

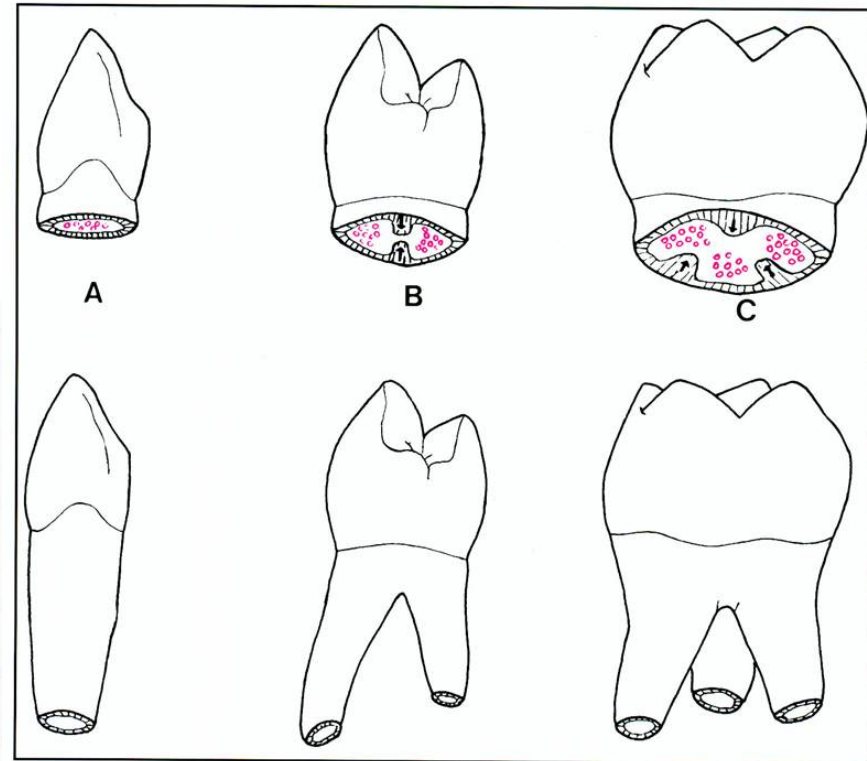
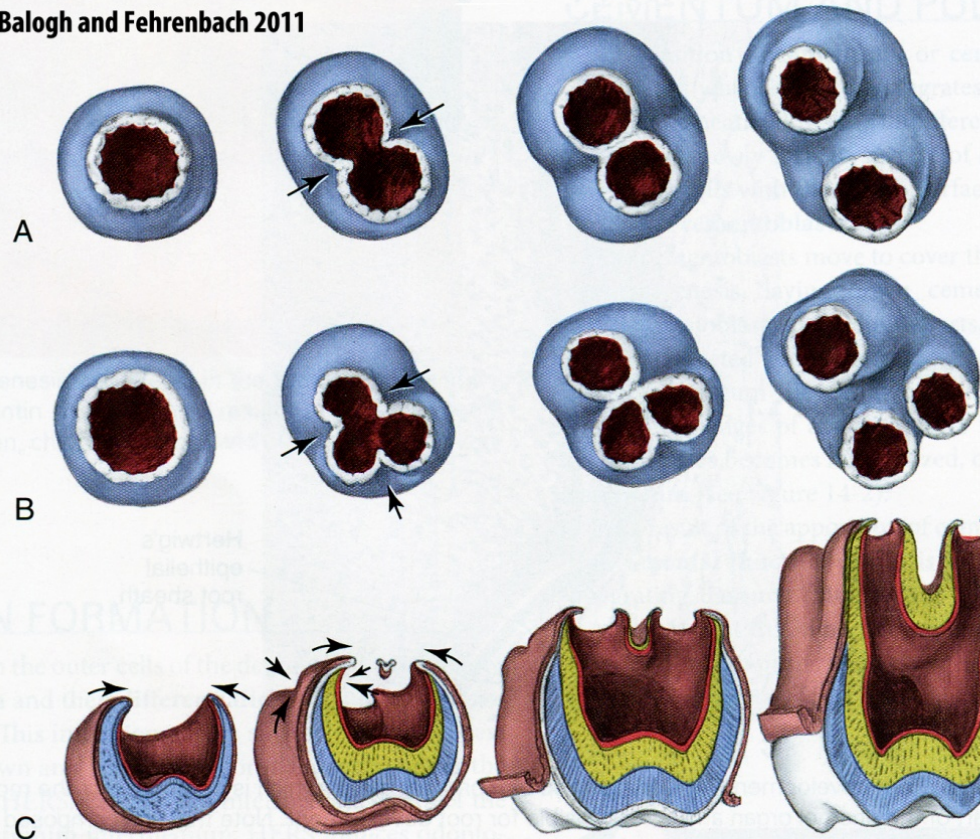
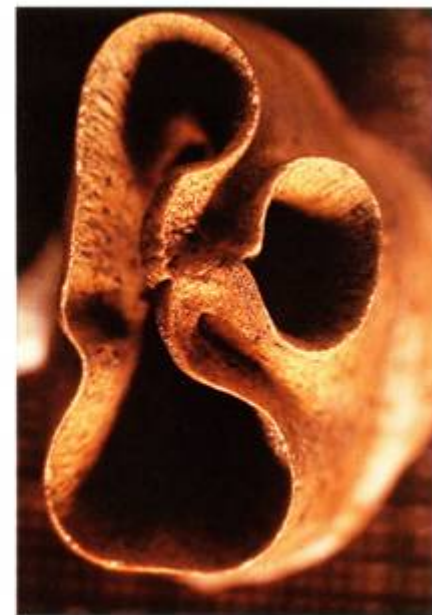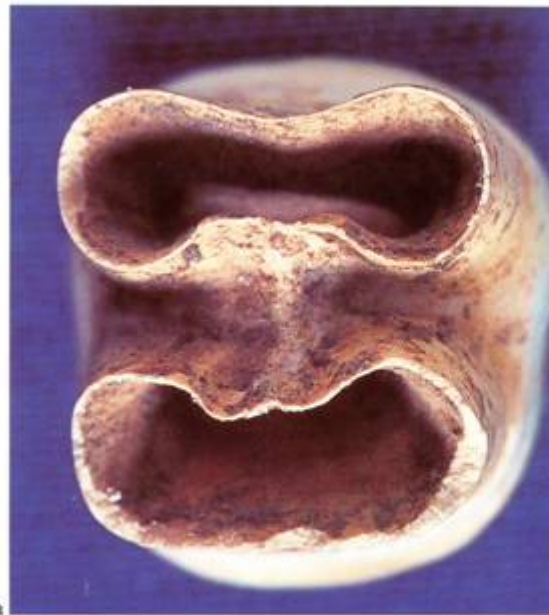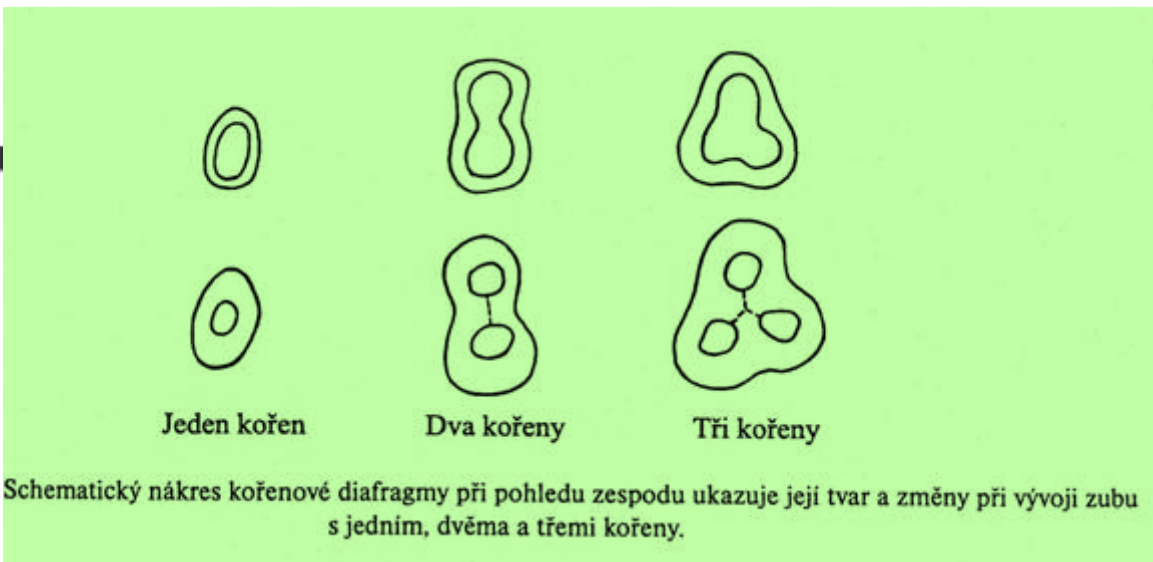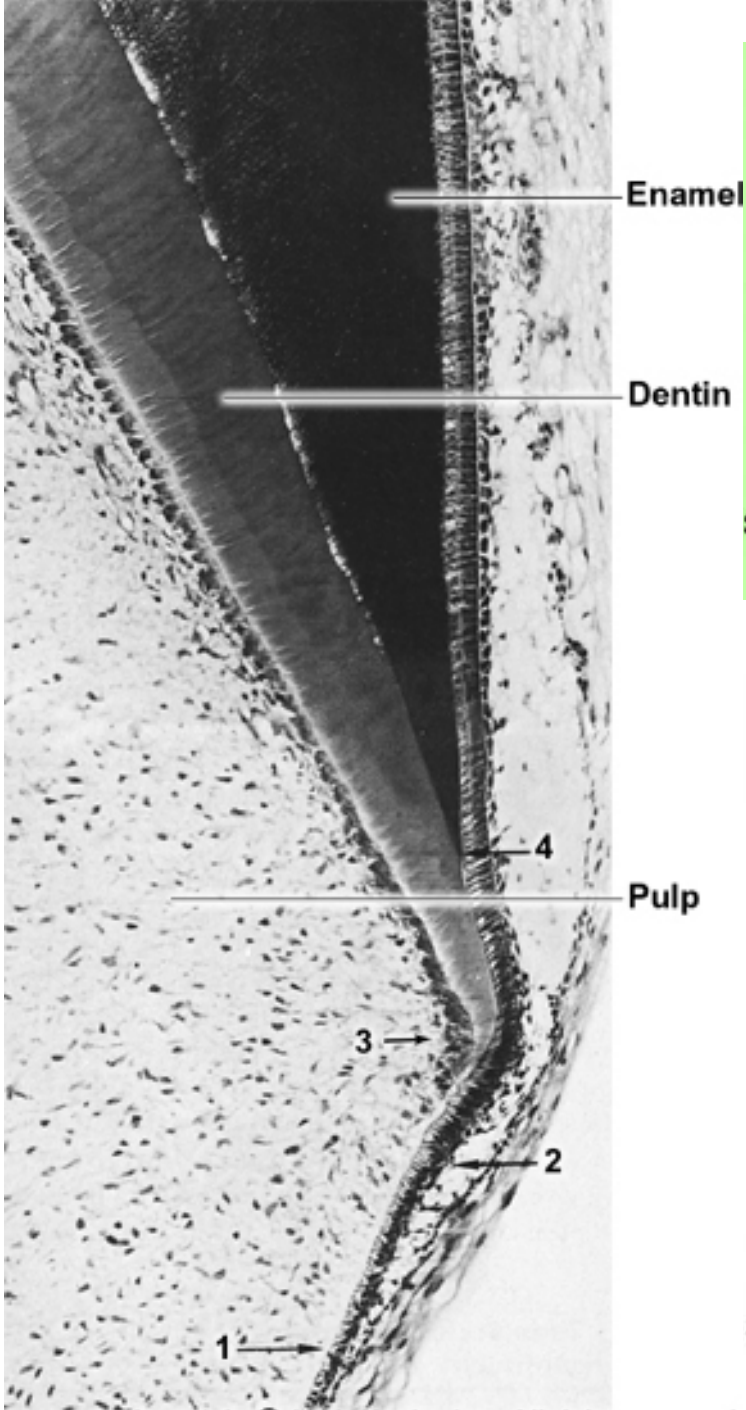


FIGURE 6-21 Apical view of multiroot development from horizontal extensions (*arrows*) of the cervical loop for (A) a two-rooted tooth, and (B) a three-rooted tooth. Cross section that shows the division that produces three roots (C) on a permanent maxillary molar.



25.2 Apices of developing roots. (a) Two-rooted tooth; (b) three-rooted tooth.

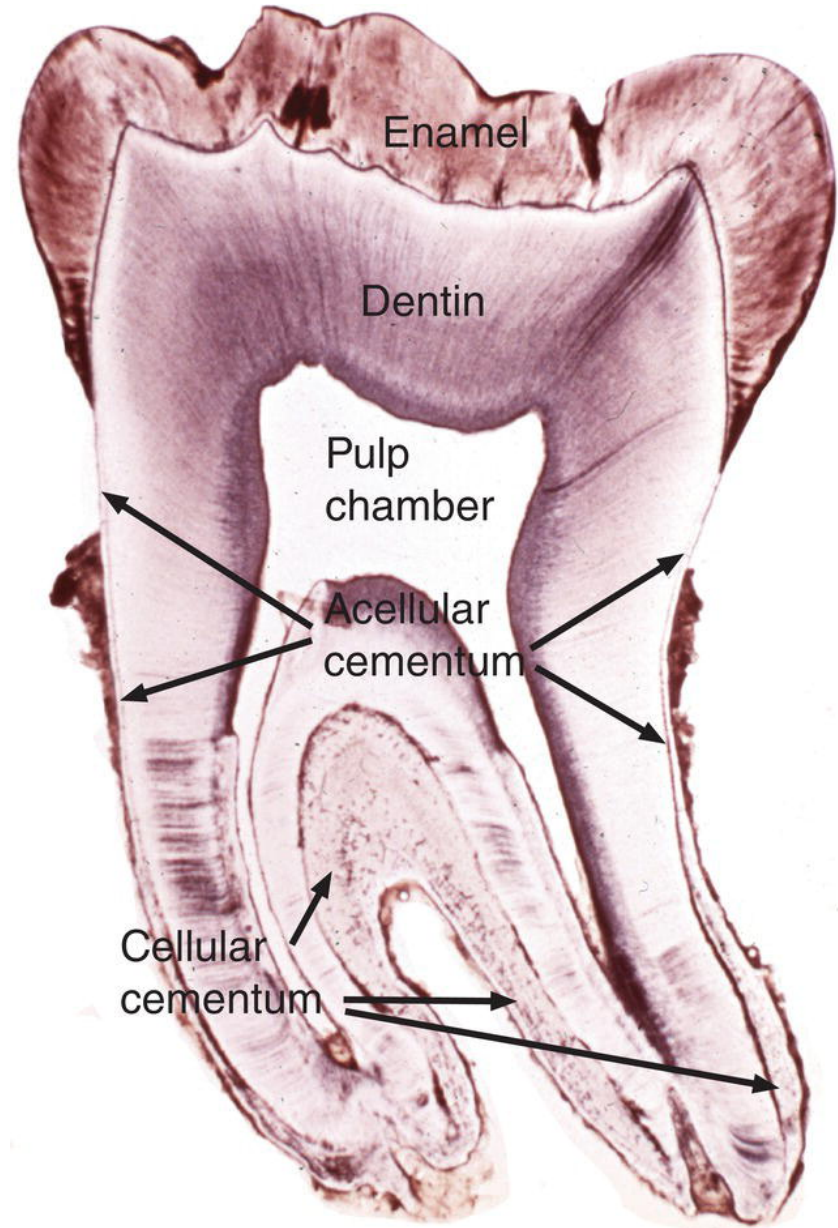
Cementogenesis

Dental cementum

- Hard, bone-like tissue covering the root of the tooth
- Yellowish color
- Avascular tissue
- Does NOT rebuild (as opposed to bone tissue)
- Can be resorbed by cementoclasts - during the tooth replacement
- During life, is being replaced by the apposition of new layers of vital tissue

Composed of:

- Cellular part
- ECM



Microscopic anatomy

Cementocytes, Cementoblasts, Cementoclasts

Extracellular matrix (ECM) = Cementum

Acellular (primary)

Cellular (secondary)

Cells

Cementoblasts

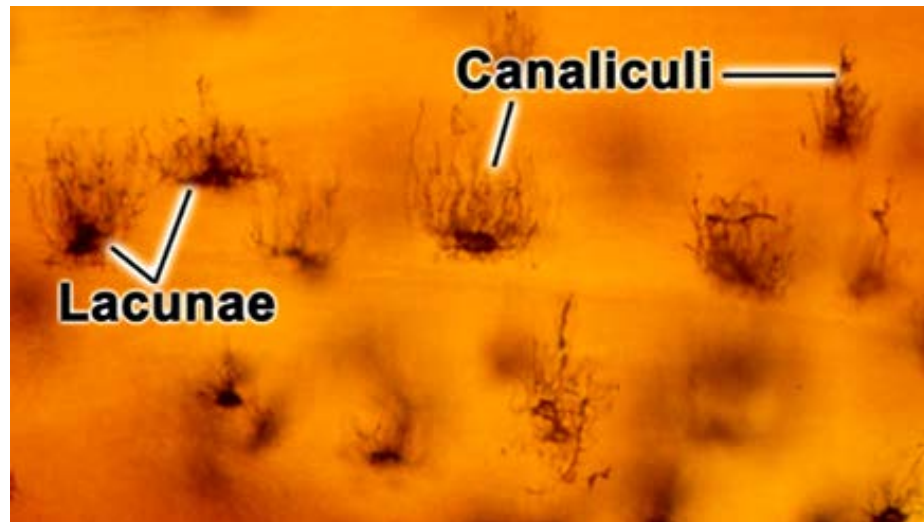
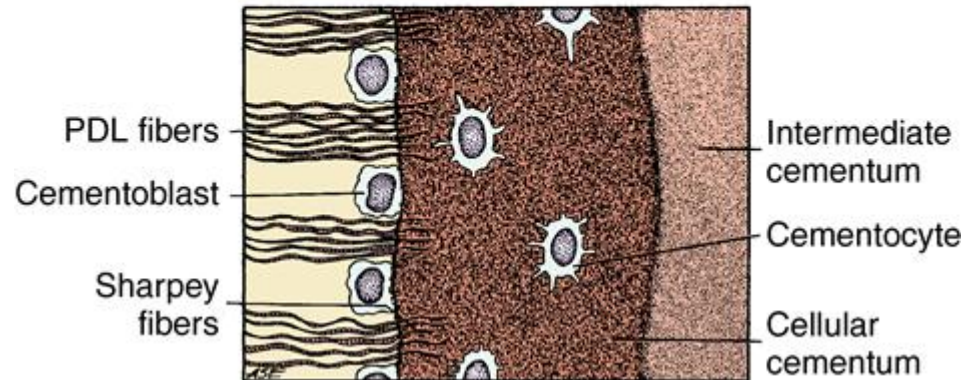
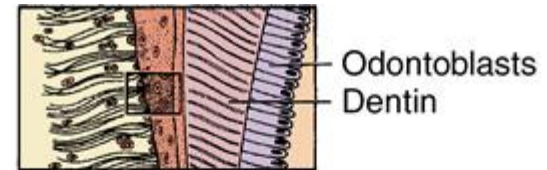
Actively involved in ECM formation

Cementocytes

Cells surrounded by cementous tissue, bodies placed in cavities, processed in small tubules (similar to Osteocytes in Bone)

Cementoclasts

Involved in cementum resorption in temporary teeth



Cementum matrix

Collagen fibres and calcified amorphous mass
Collagen fibres run in bundles (orientation is determined by the forces on teeth)

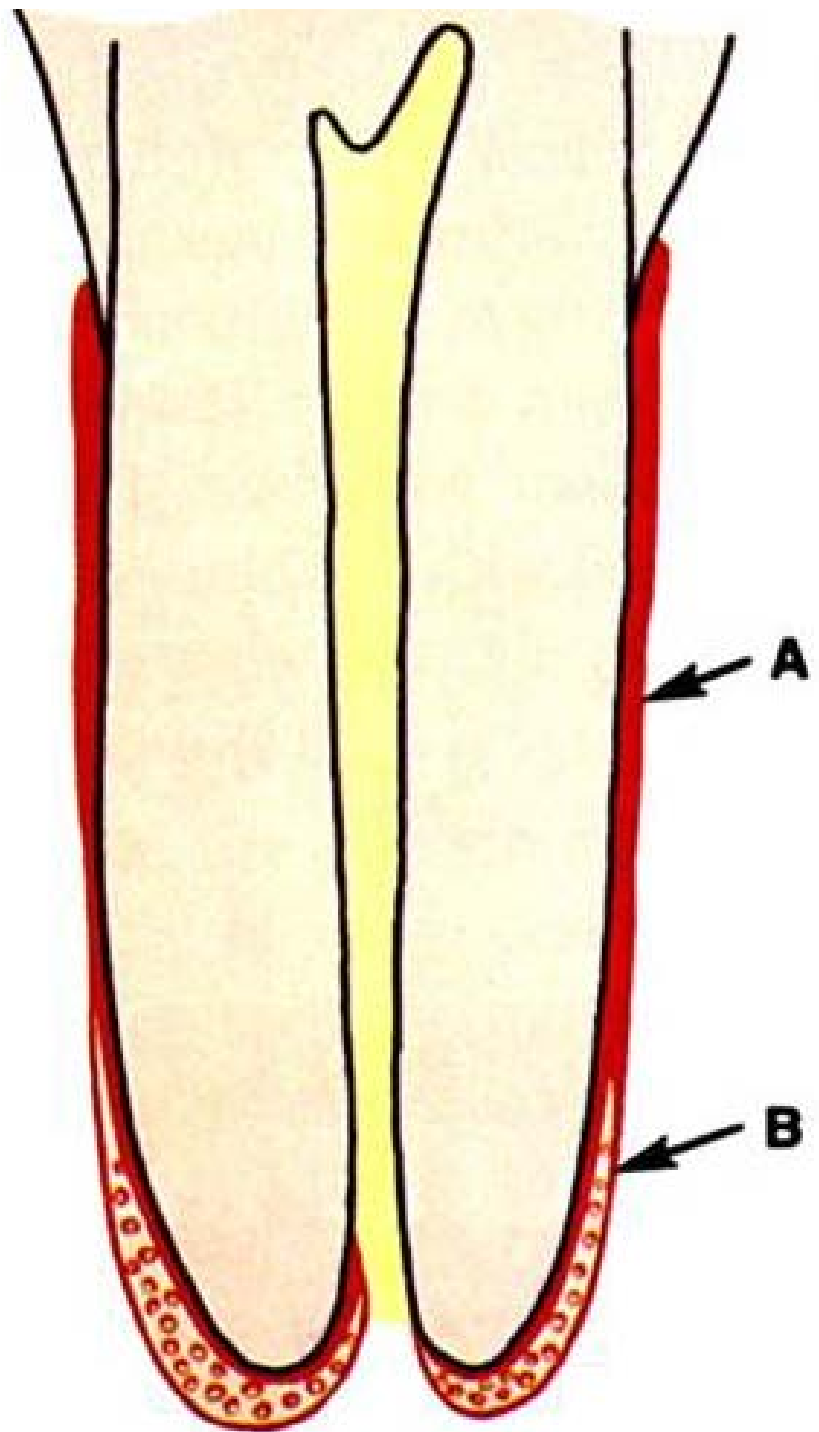
Cementum is divided by origin into:

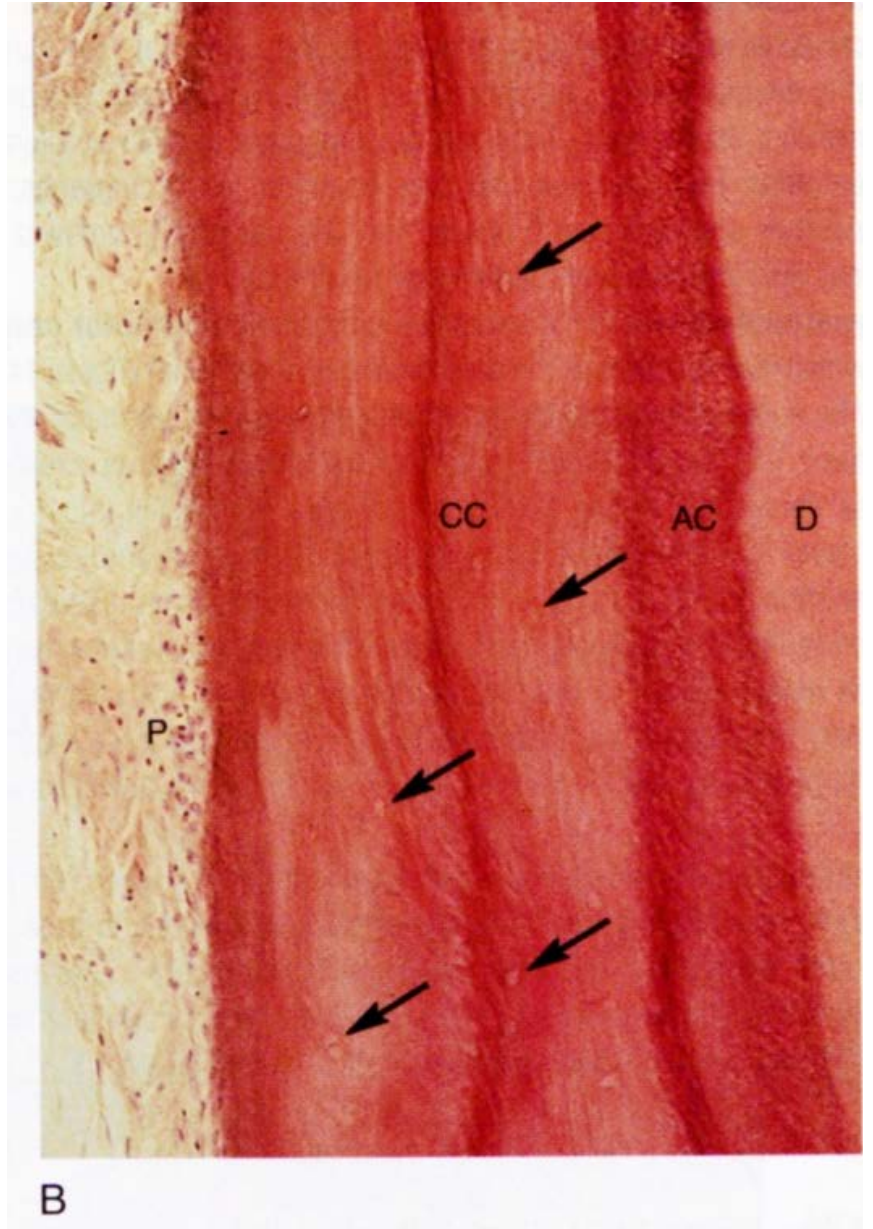
Primary (acellular)

Does not contain cementocytes
In the range of the entire tooth root
Directly connected to the dentine
Thickness: **10 to 200 μm**

Secondary (cellular)

Contains cementocytes
Especially on dental apices
Grows **up to 500 μm thick**





B

Cementogenesis

Begins after the disintegration of the Hertwig's epithelial sheath

Its place will be taken by ectomesenchymal cells that form a **cementogenic mantle** around the root of the dentine base

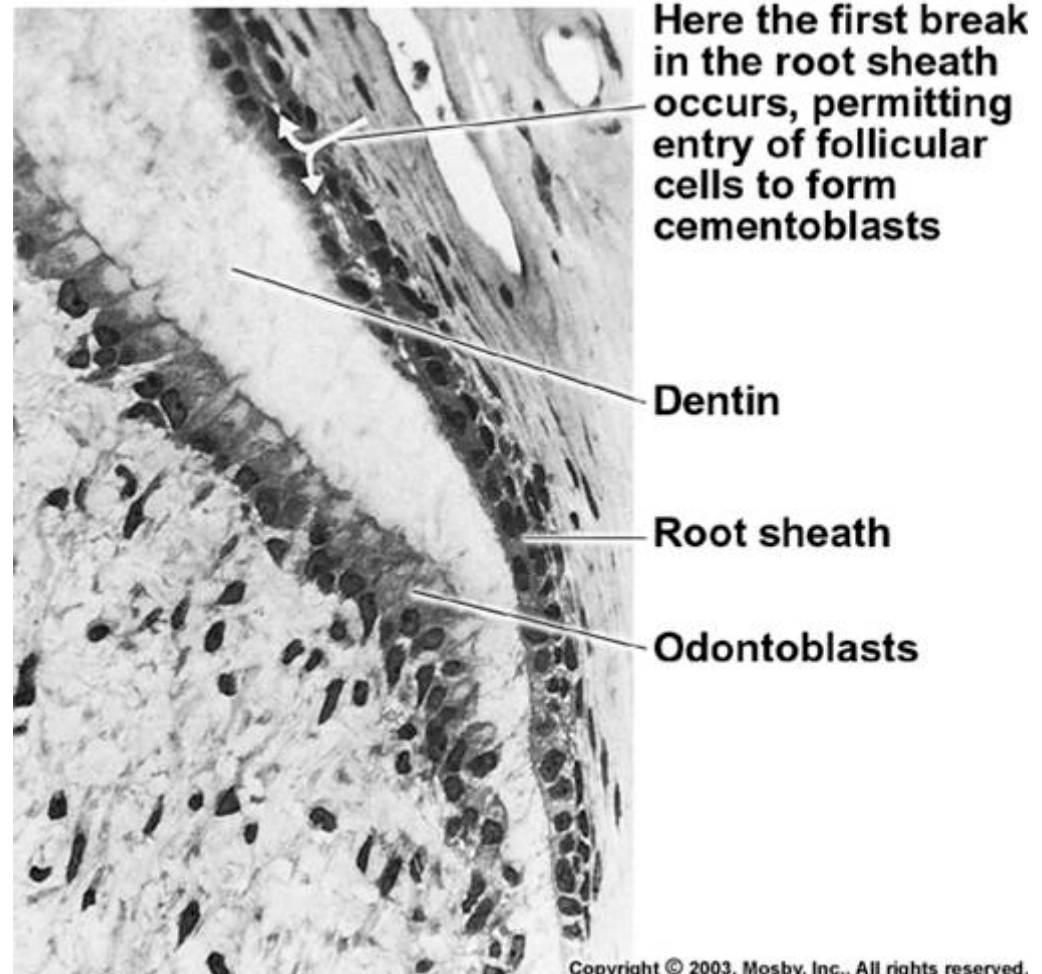
By differentiation of ectomesenchymal mantle – cementoblasts are formed

In the beginning, the cementum is deposited very slow, so cementoblasts have time to relocate into superficial layers

- **acellular (primary) cementum**

In the period just before eruption, cementoblasts forms the matrix much faster which prevents cells to migrate on the surface and they will remain permanently entrapped inside

- **Cellular (secondary) cementum**



Chronology of primary and secondary dentition formation

Table 26.1 Chronology of tooth development and the order of eruption

Chronology of the deciduous dentition					Chronology of the permanent dentition				
Tooth	First evidence of calcification (months in utero)	Crown completed (months)	Eruption (months)	Root completed (years)	Tooth	First evidence of calcification	Crown completed (years)	Eruption (years)	Root completed (years)
<i>Maxillary</i>					<i>Maxillary</i>				
A	3-4	4	7	1½-2	1	3-4 months	4-5	7-8	10
B	4½	5	8	1½-2	2	10-12 months	4-5	8-9	11
C	5	9	16-20	2½-3	3	4-5 months	6-7	11-12	13-15
D	5	6	12-16	2-2½	4	1½-1¾ years	5-6	10-11	12-13
E	6-7	10-12	21-30	3	5	2-2½ years	6-7	10-12	12-14
					6	Birth	2½-3	6-7	9-10
					7	2½-3 years	7-8	12-13	14-16
					8	7-9 years	12-16	17-21	18-25
<i>Mandibular</i>					<i>Mandibular</i>				
A	4½	4	6½	1½-2	1	3-4 months	4-5	6-7	9
B	4½	4½	7	1½-2	2	3-4 months	4-5	7-8	10
C	5	9	16-20	2½-3	3	4-5 months	6-7	9-10	12-14
D	5	6	12-16	2-2½	4	1¾-2 years	5-6	10-12	12-13
E	6	10-12	21-30	3	5	1¼-2½ years	6-7	11-12	13-14
					6	Birth	2½-3	6-7	9-10
					7	2½-3 years	7-8	12-13	14-15
					8	8-10 years	12-16	17-21	18-25

Unless otherwise indicated all dates are postpartum. The teeth are identified according to the Zsigmondy system.

All dates are postpartum. Teeth are identified according to the Zsigmondy system.