

# Orthodontic treatment

- MUDr. Alena Bryšová, Ph.D.



# Orthodontic treatment

**MALOCCLUSION** is a manifestation of genetic and environmental interaction on the development of the orofacial region



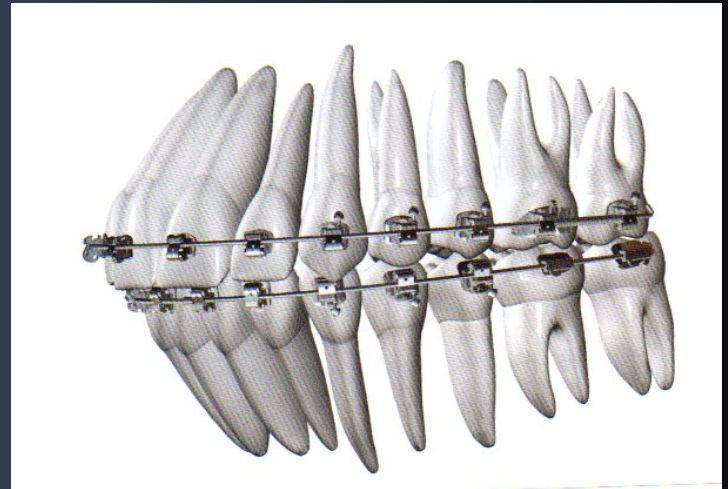
# GOALS OF TREATMENT:

- Ideal functional occlusion
- Ideal soft tissue proportions and adaptation
- Ideal jaw, skeletal and dental relationship



# Ideal occlusion

- correct relationship of molars
- correct overjet and overbite
- correct angulation, inclination of teeth
- no rotated teeth
- no spacing
- flat plane of occlusion



# Objectives of orthodontic treatment

- Aesthetics
- Treatment of impacted teeth
- Prevention of dental injuries
- Before prosthetic treatment
- Decay prevention
- Prevention and treatment of chewing malfunction and jaw joint disorders



# Methods of orthodontic treatment

- Orthodontics movement of teeth
- Orthopedic movement – effects of growth
- Myofunctional therapy
- Serial extraction, controlled extraction
- Ortho – prosthetic treatment
- Ortho – surgical treatment



# Orthodontic treatment

## 1. Orthodontic treatment by infants

- clefts
- syndromes and defects that complicate nutrition and breathing

We use - individual removable plates



# Orthodontic treatment

## 2. Deciduous teeth

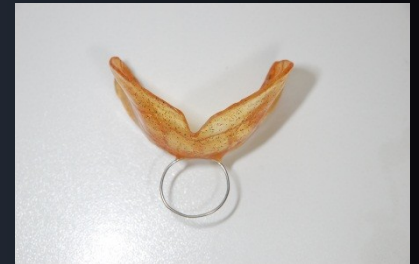We treat - bite defects

inverted bite

cross bite

- bad habits

We use – removable appliances





# Orthodontic treatment

## 3. 6-9 years [ 1. phase of mixed dentition]

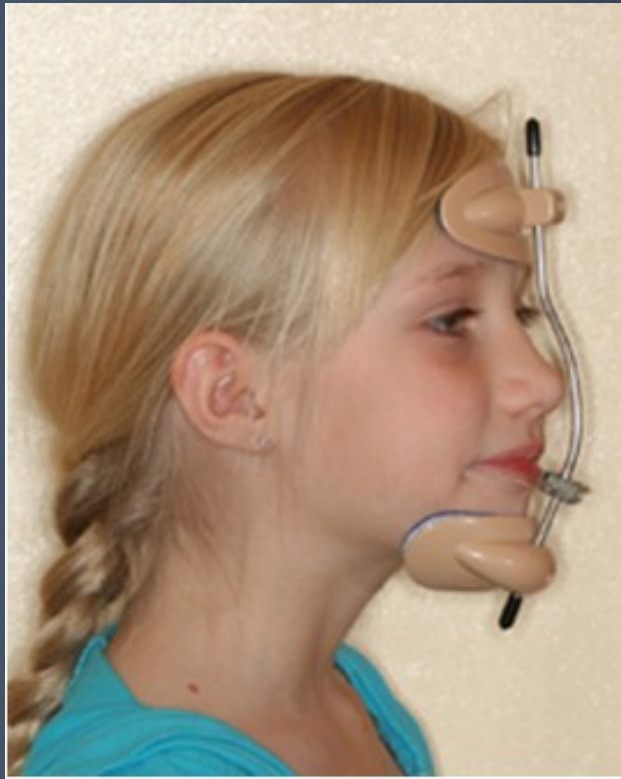The best time for treatment :

- cross bite
- inverted bite
- impacted incisors
- diastema more than 3 mm
- big primary crowding

We use : removable appliances  
small fixed appliances  
face mask for inverted bite by class III



# Face mask



# Orthodontic treatment

## 4. 9-12 year [second phase of mixed dentition]

- Large forming ability of the tissues
- We can use and influence the growth
- Growth mandible from the joints

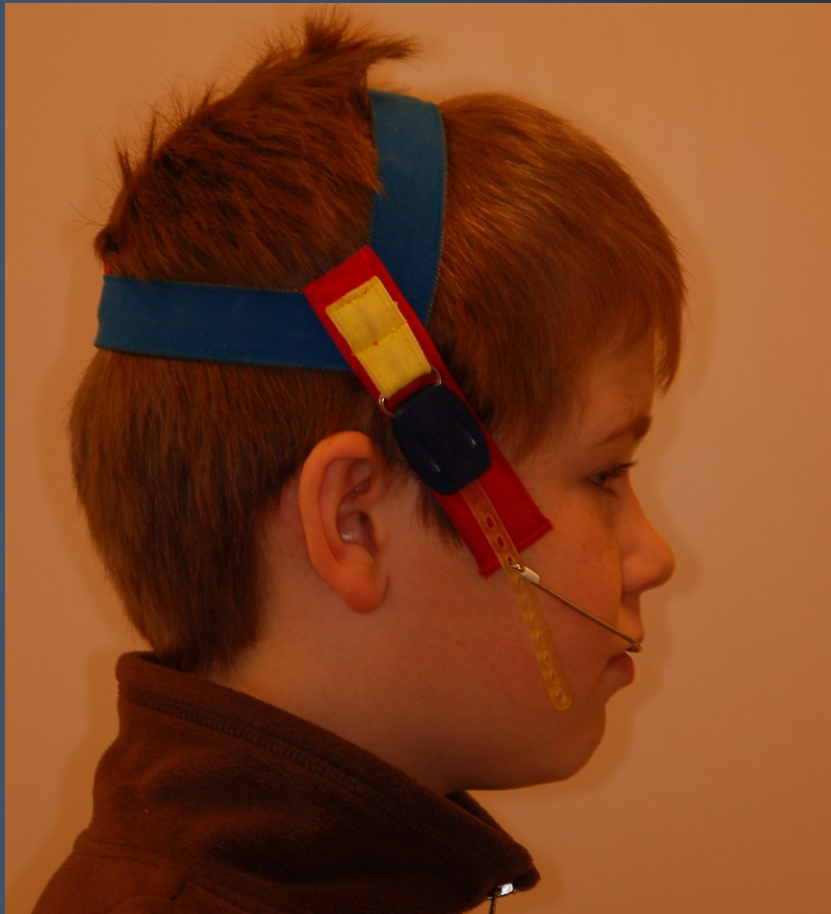- We treat:
- previous untreated anomalies
  - crowding
  - Angle class II – div. 1 and 2
  - overjet more than 5 mm
  - deep bite
  - movements teeth after the early loss of teeth and anodontia
  - Controlled tooth eruption
  - Suspected retention of canines, premolars

### The best time for functional appliances

- removable appliances
- Small fixed appliances
- Headgear appliance



# headgear



# Orthodontic treatment

## ■ 5. Permanent teeth

We treat:

- All anomalies, previous untreated anomalies,
- Angle class III
- Crowding
- Open bite, deep bite
- Impacted tooth
- Skeletal anomalies

Adult therapy – periodontics problems, preprosthetic therapy

- problems with TMJ
- bruxism

We use : fixed appliances

extraction

surgical treatment by big skeletal anomalies



# Therapy of ortodontical anomalies

## ■ Conservativ

- orthodontical appliances :
  - removable
  - fixed

## ■ Surgical

- extraction of teeth
- surgical expositions of crowns of retined tooth
- surgical movements of maxila, mandible



# Othodontic treatment

- Removable appliances:
  1. Active
  2. Passive
  3. Functional



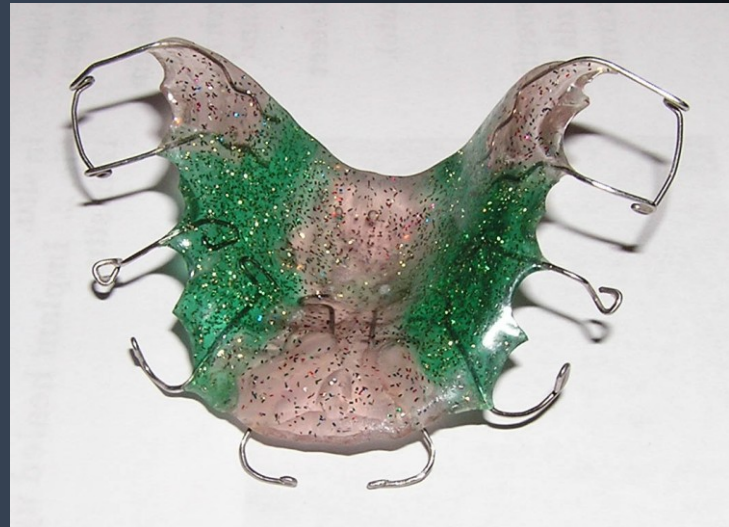## ■ Active removable appliances

- Treatment of anomalous position of teeth [inclination, rotation of incisors]
- Treatment the dental arch shape
- Individual resin plates
- Active elements : springs, screws, wire bows





# Removable active appliances



# Removable appliances - active



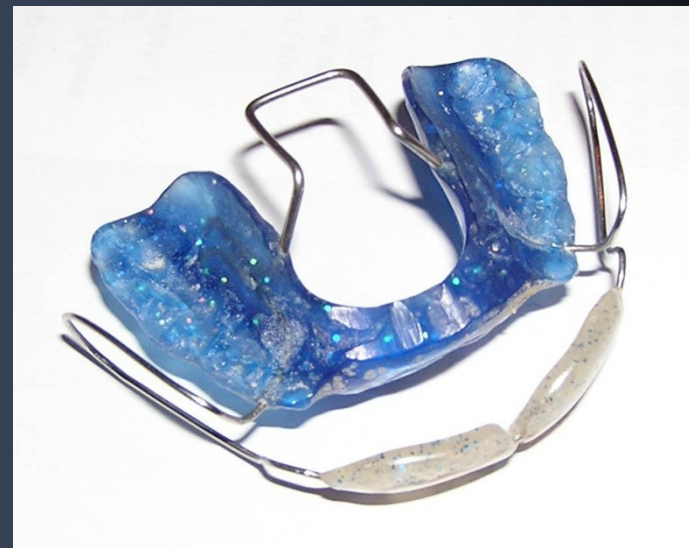
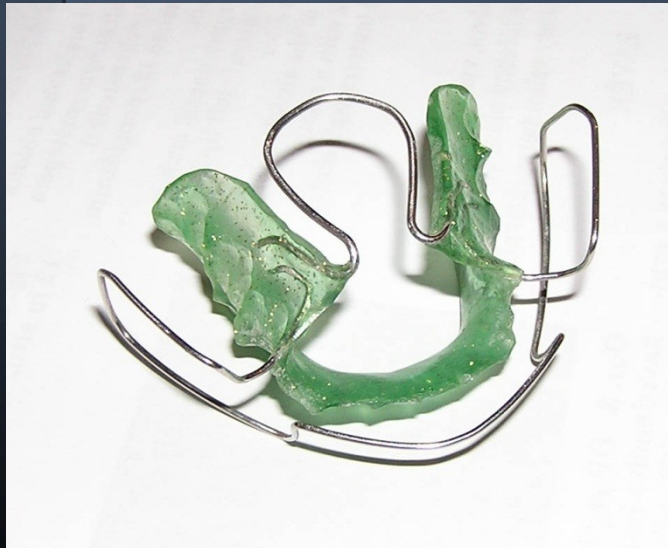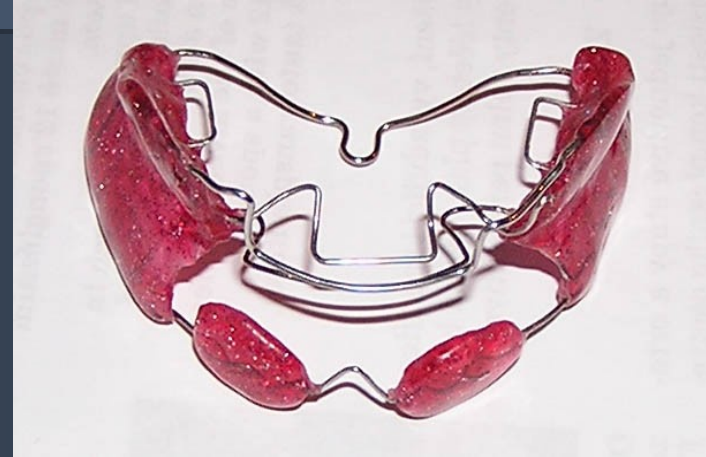# Functional appliances

- modifying extent and direction of orofacial growth
- exploit muscular activity and soft tissue stretch to stimulate dental and bone changes
- operates at the time of maximum growth of orofacial region = 9-12 years old children
- We need **construction bite**
- Type of functional appliances :
  - Bionator, Klampt, Maxilator – class II and open bite
  - Fränkel appliance – class III





# Removable functional appliances



# Functional appliances-Maxilator



# Functional appliances - Klampt

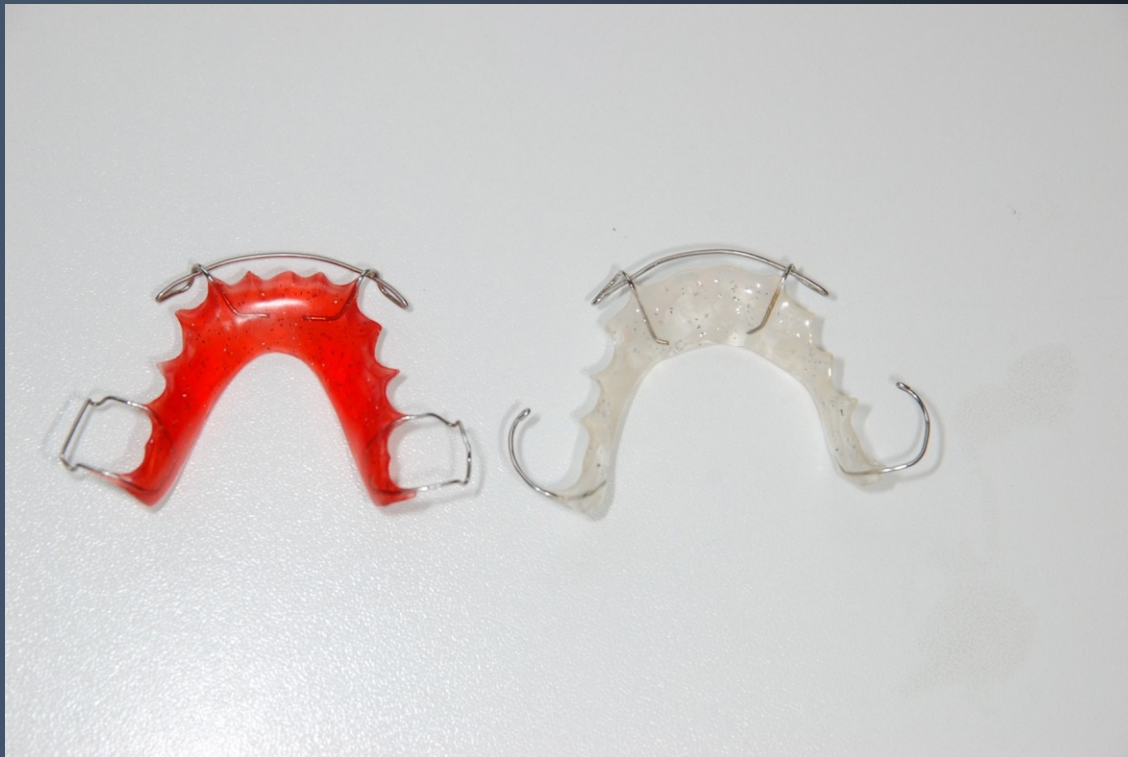



# Functional appliances - Bionator



# Removable appliances- passive





# Thank You for Your attention

Questions – email – [alena.brysova@fnusa.cz](mailto:alena.brysova@fnusa.cz)

Consultation – Orthodontic department - St. Anne's Hospital, building D2b – Thursday 1-2 p.m.

