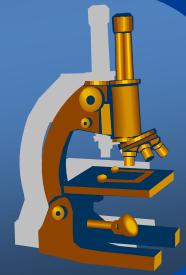


General pathology histopath. practice

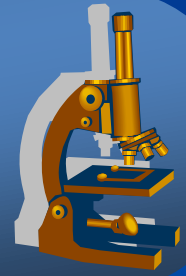


General pathology II.

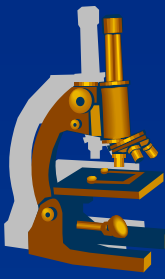
Circulation disorders

Inflammation I

Circulation disorders



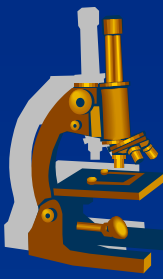
Circulation disorders



- x Local
- x Systemic
- x Shock

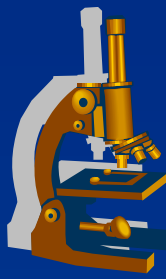
Circulation disorders

LOCAL



- x Thrombosis
- x Embolism
- x Haemorrhage
- x Oedema
- x Hyperemia
- x Ischemia
- x Infarction

Thrombosis



× main cause of local circulation disorders

» **intravital** formation of a pathological blood clot (thrombus) **within vascular system**, due to platelets aggregation + transformation of fibrinogen into fibrin
possible obstruction of the blood flow through the circulatory system«

Circulation disorders

× Local

⇒ **thrombosis**

⇒ *embolism*

⇒ *hemorrhage*

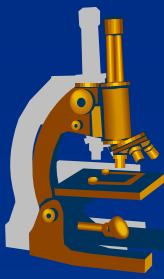
⇒ *oedema*

× Systemic

⇒ *cardial*

⇒ *extracardial*

Thrombosis



3 basic pathogenetic mechanisms:

⇒ endothelial cell injury

- the most important (trauma, AS, immune complexes, viruses, bacteria, inflammations, toxins) – FXII activation

⇒ blood flow disturbance

- stagnation past the point of injury, venous stasis in leg veins

⇒ blood constituents change, coagulopathy

- congenital: e.g. genetic mutation FV (Leiden)
- acquired: hormonal contraception, tumor dissemination, DIC, hyperlipidemia, smoking

Circulation disorders

×Local

⇒ **thrombosis**

⇒ *embolism*

⇒ *hemorrhage*

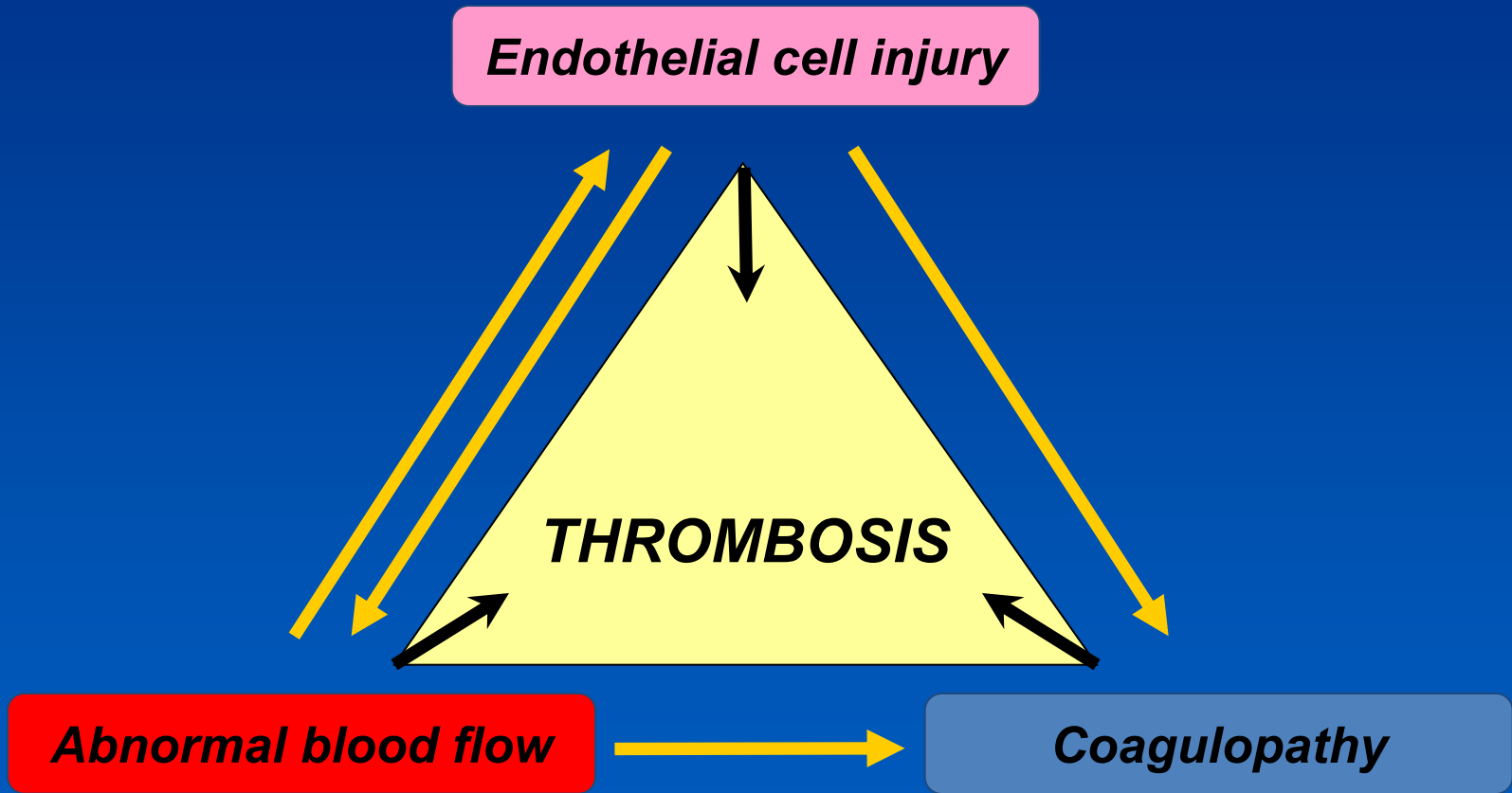
⇒ *oedema*

×Systemic

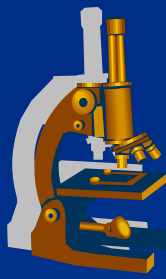
⇒ *cardial*

⇒ *extracardial*

Pathogenetic mechanism



Thrombosis



GROSS:

- ⇒ *mural thrombus (cardial cavities, arteries)*
- ⇒ *obturating (veins)*

Circulation disorders

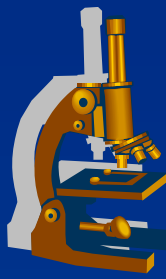
×Local

- ⇒ **thrombosis**
- ⇒ *embolism*
- ⇒ *hemorrhage*
- ⇒ *oedema*

×Systemic

- ⇒ *cardial*
- ⇒ *extracardial*

Thrombosis



MICRO:

⇒ *red*

- erythrocytes, in leg veins - stasis

⇒ *white*

- thrombocytes, fibrin – cardial valves – turbulent flow

⇒ *mixed*

- combination of both (stratified thrombus, e.g. cardial and aortic aneurysm)

⇒ *fibrin thrombus*

- microscopic size, in small calibre arteries and capillaries, fibrin + platelets, CNS, kidney, lungs by shock, infections

Circulation disorders

× Local

⇒ **thrombosis**

⇒ *embolism*

⇒ *hemorrhage*

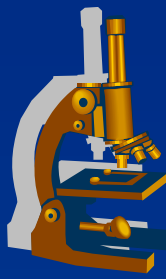
⇒ *oedema*

× Systemic

⇒ *cardial*

⇒ *extracardial*

Thrombosis



FATE OF THROMBI

- ⇒ *vessel wall hypoxia » platelet grow factors » reparative fibroproductive inflammation» thrombus fixation to the vessel wall » fibroblasts » **thrombus retraction** » **recanalization** + ORGANIZATION*
- ⇒ *growth of the thrombus*
- ⇒ *breaking off of the thrombus ⇨ embolism*
- ⇒ *fibrinolysis*

Circulation disorders

×Local

⇨ **thrombosis**

⇨ *embolism*

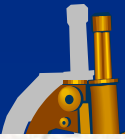
⇨ *hemorrhage*

⇨ *oedema*

×Systemic

⇨ *cardial*

⇨ *extracardial*



Source: Robbins basic pathology

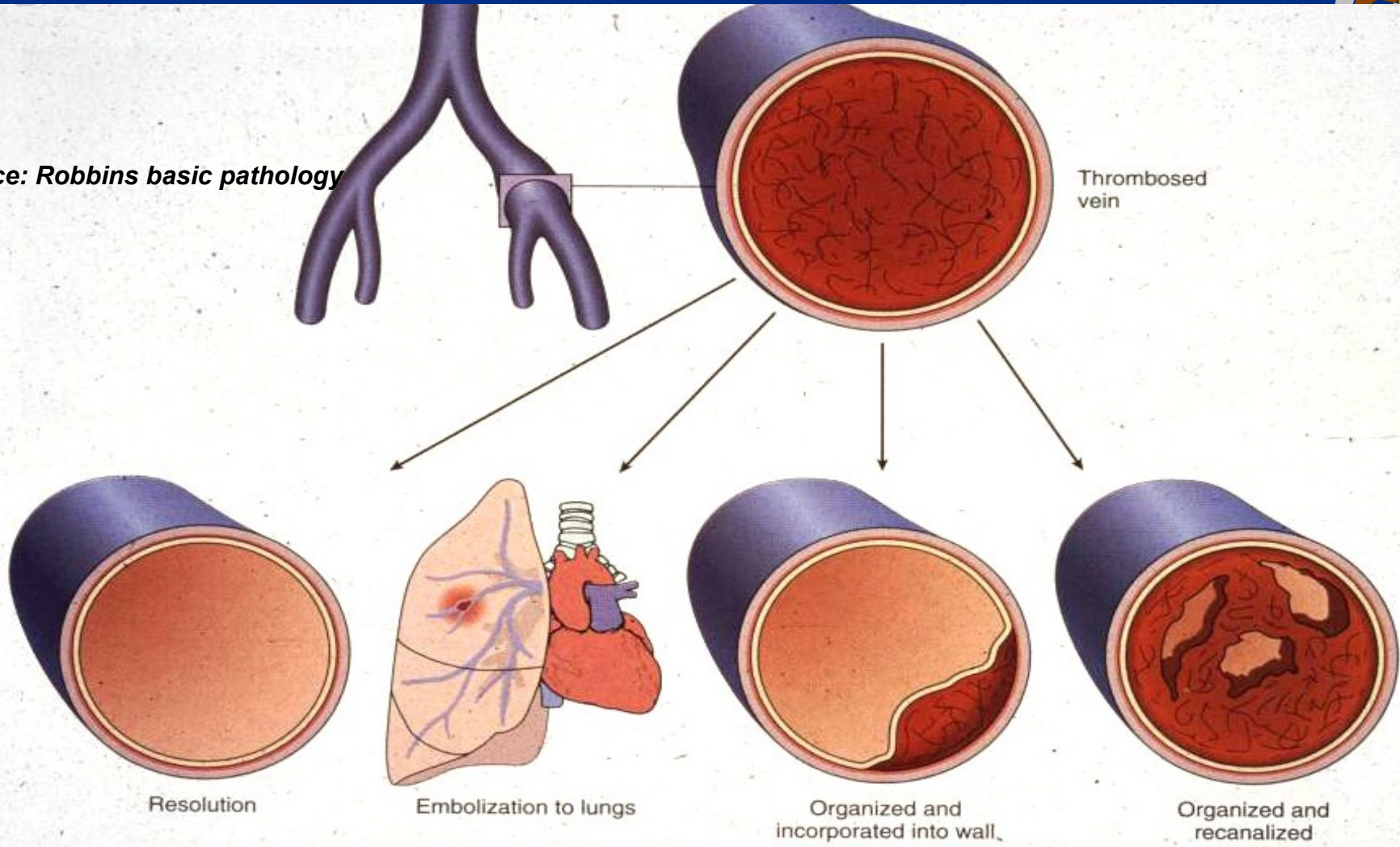
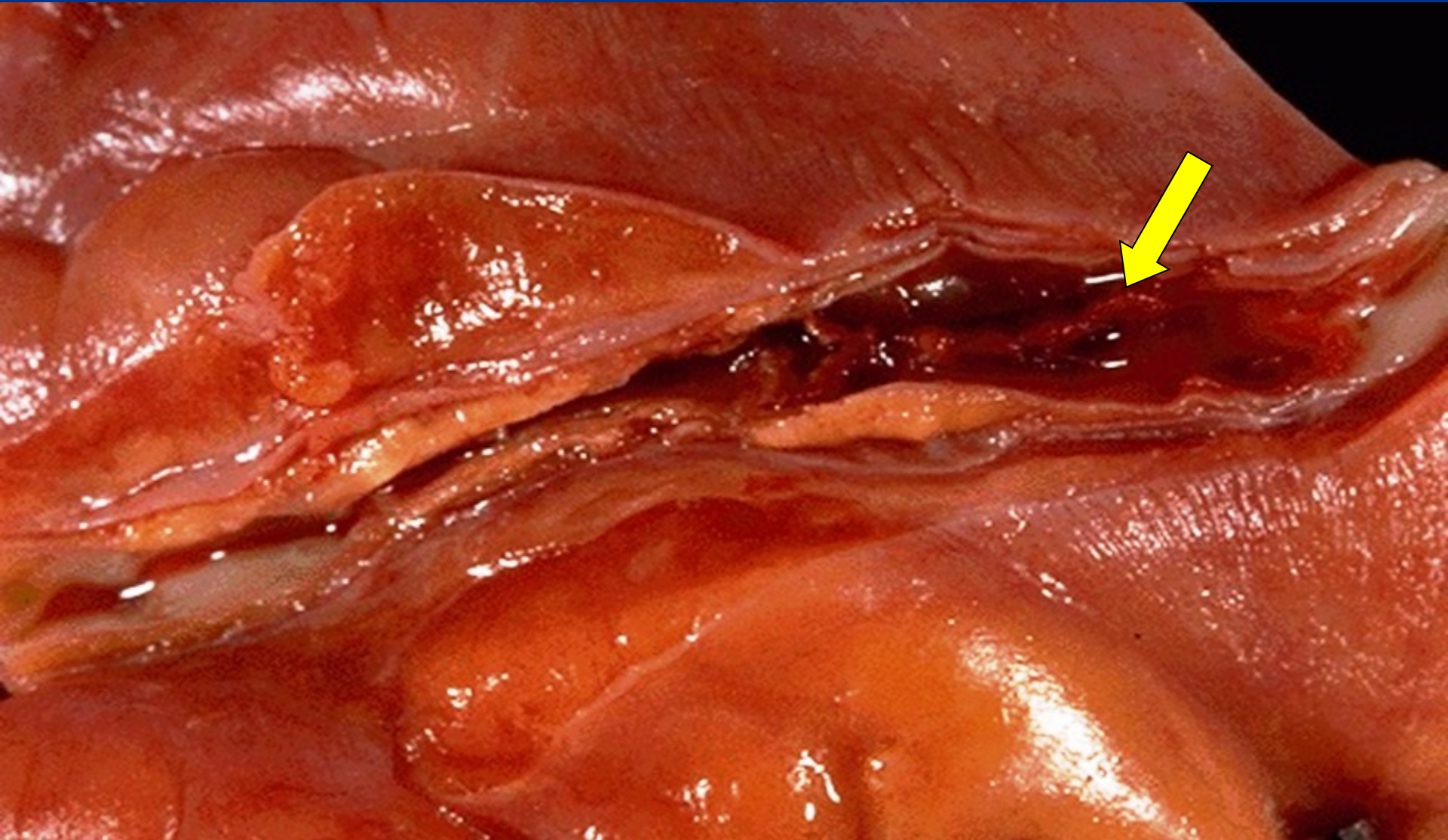

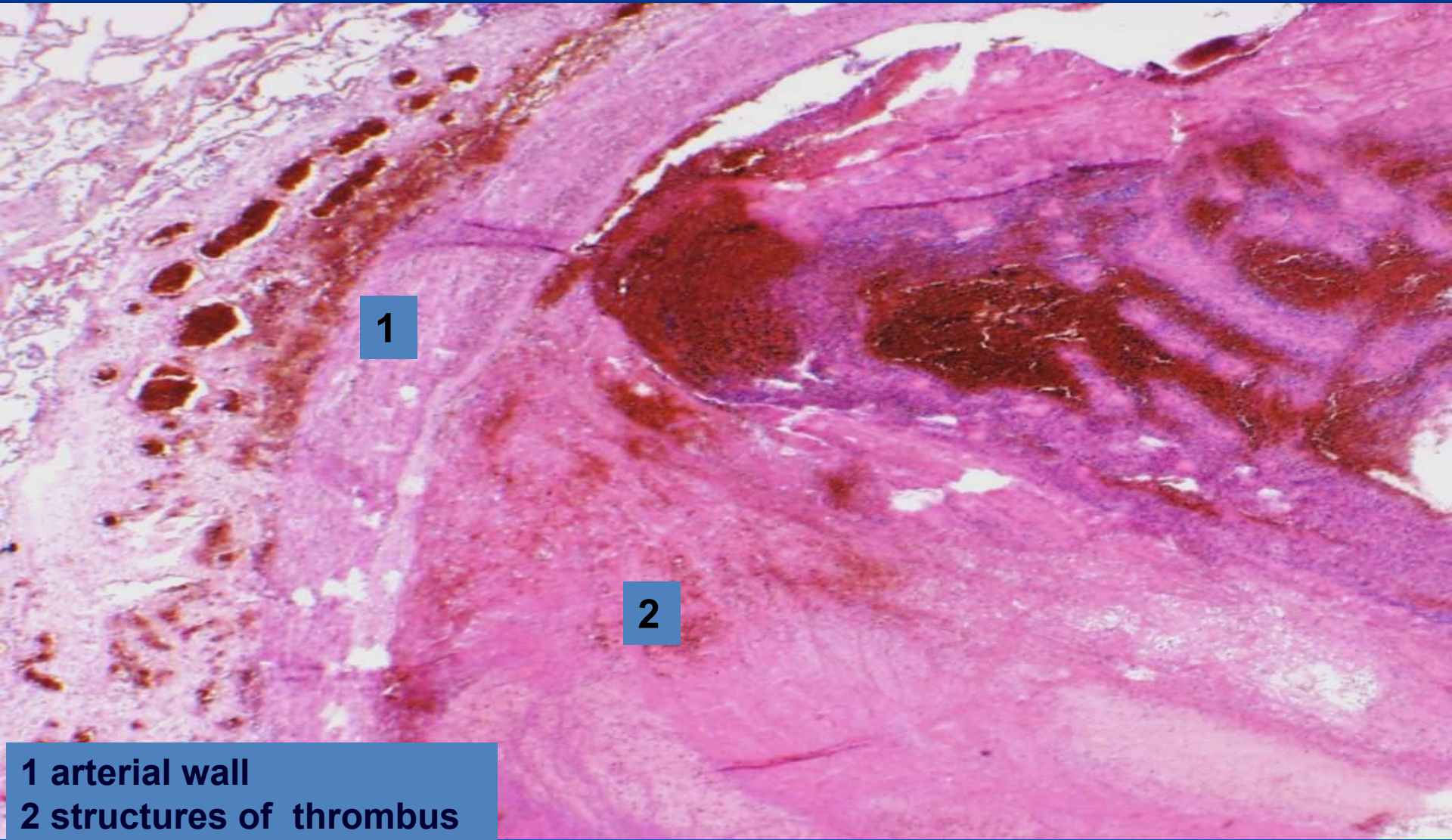
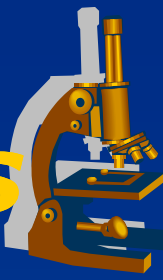


Figure 4-10

Coronary artery thrombosis



Organized mixed thrombus



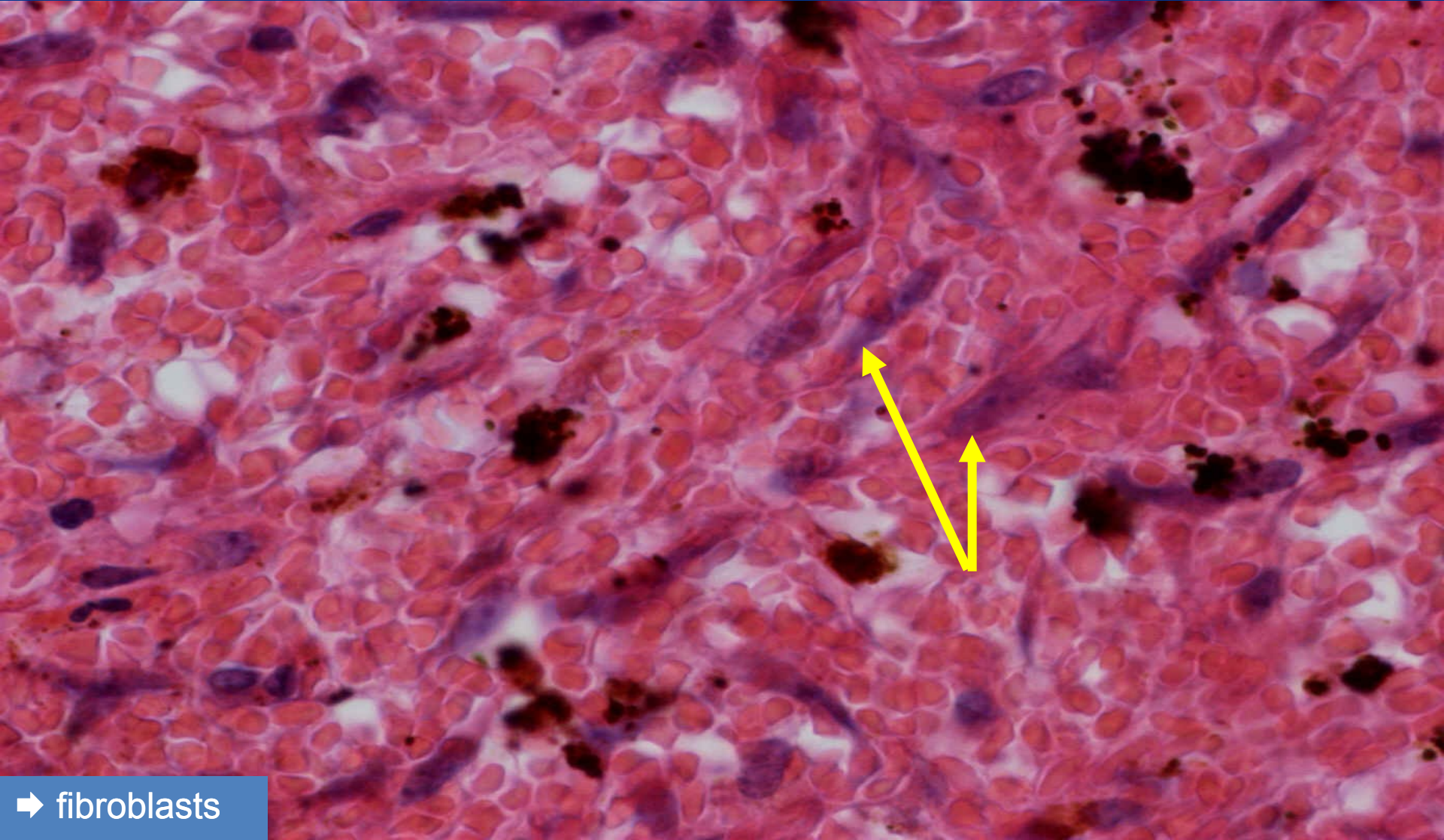
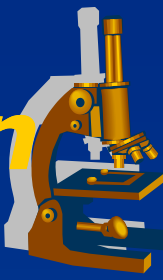
1

2

1 arterial wall
2 structures of thrombus

Mixed thrombus - organization

(detail 600x)



➔ fibroblasts

Microcirculation thrombosis DIC



× Acquired coagulopathy, mortality 40%

× Etiopathogenesis:

release of tissue factor (a part of the cell membranes) into blood or endothelial damage

× Causes:

⇒ **Obstetric complications:**

- intravenous embolism of amniotic fluid
- placental abruption

⇒ **Infections**

- meningococcal, staphylococcal sepsis, acute pancreatitis

⇒ **Shock**

⇒ **Tissue trauma** (burns, major surgery)

DIC



x 1st phase: hypercoagulation

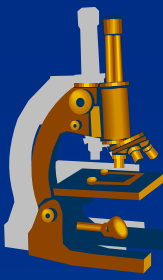
⇒ *Morphology:*

- multiple fibrin thrombi in the microcirculation
- brain, lungs, kidney, heart, liver – ischemia, multi-organ failure
- microangiopathic haemolytic anaemia

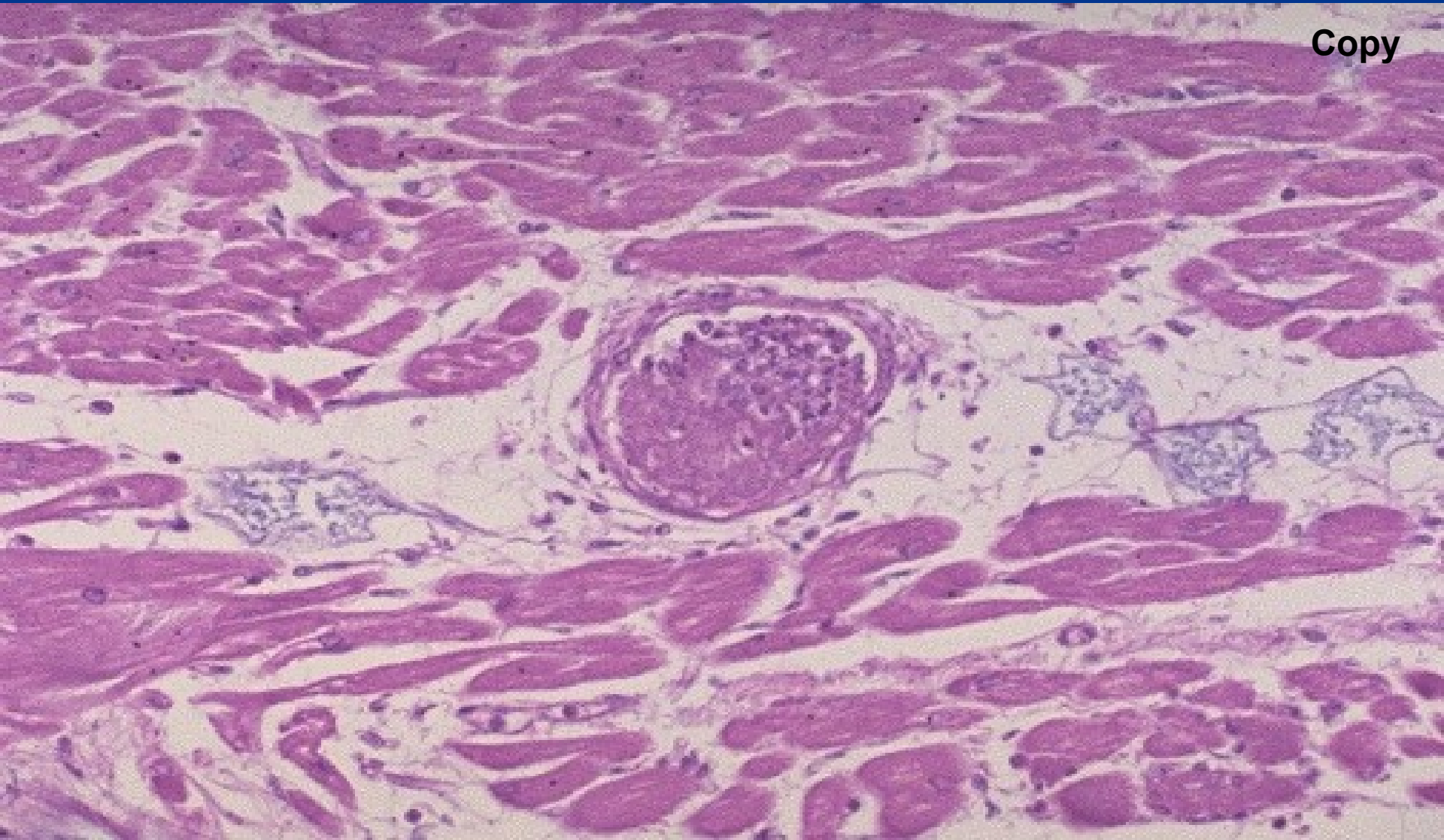
x 2nd phase: hypocoagulation:

- ⇒ *consumption of coagulation factors/fibrin degradation products*
- ⇒ *extreme hypocoagulability, fatal bleeding (surgical wounds, mucous membranes)*

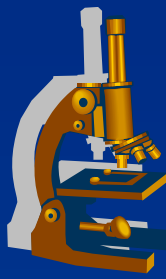
Fibrin thrombus



Copy



Embolism



= a mass of movable material in the vascular system able to become lodged within a vessel and **block its lumen.**

× thrombembolism:

- ⇒ *most common*
- ⇒ *from veins (deep v. of legs) into pulmonary arteries*
- ⇒ *from heart/aorta into systemic arteries*

× paradoxical embolism:

- ⇒ *from veins into arteries via foramen ovale apertum*

Circulation disorders

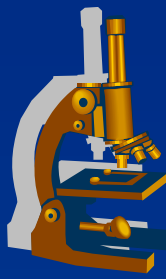
× Local

- ⇒ *thrombosis*
- ⇒ **embolism**
- ⇒ *hemorrhage*
- ⇒ *oedema*

× Systemic

- ⇒ *cardial*
- ⇒ *extracardial*

Embolism



× Localization:

- ⇒ *venous embolism*
- ⇒ *arterial embolism*
- ⇒ *paradoxical embolism*
- ⇒ *portal embolism*

Circulation disorders

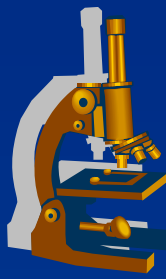
× Local

- ⇒ *thrombosis*
- ⇒ ***embolism***
- ⇒ *hemorrhage*
- ⇒ *oedema*

× Systemic

- ⇒ *cardial*
- ⇒ *extracardial*

Embolism



× Classification:

- ⇒ *thrombotic*
- ⇒ *air*
- ⇒ *fat*
- ⇒ *cellular (tumor dissemination)*
- ⇒ *subcellular (DNA)*
- ⇒ *amniotic fluid*

Circulation disorders

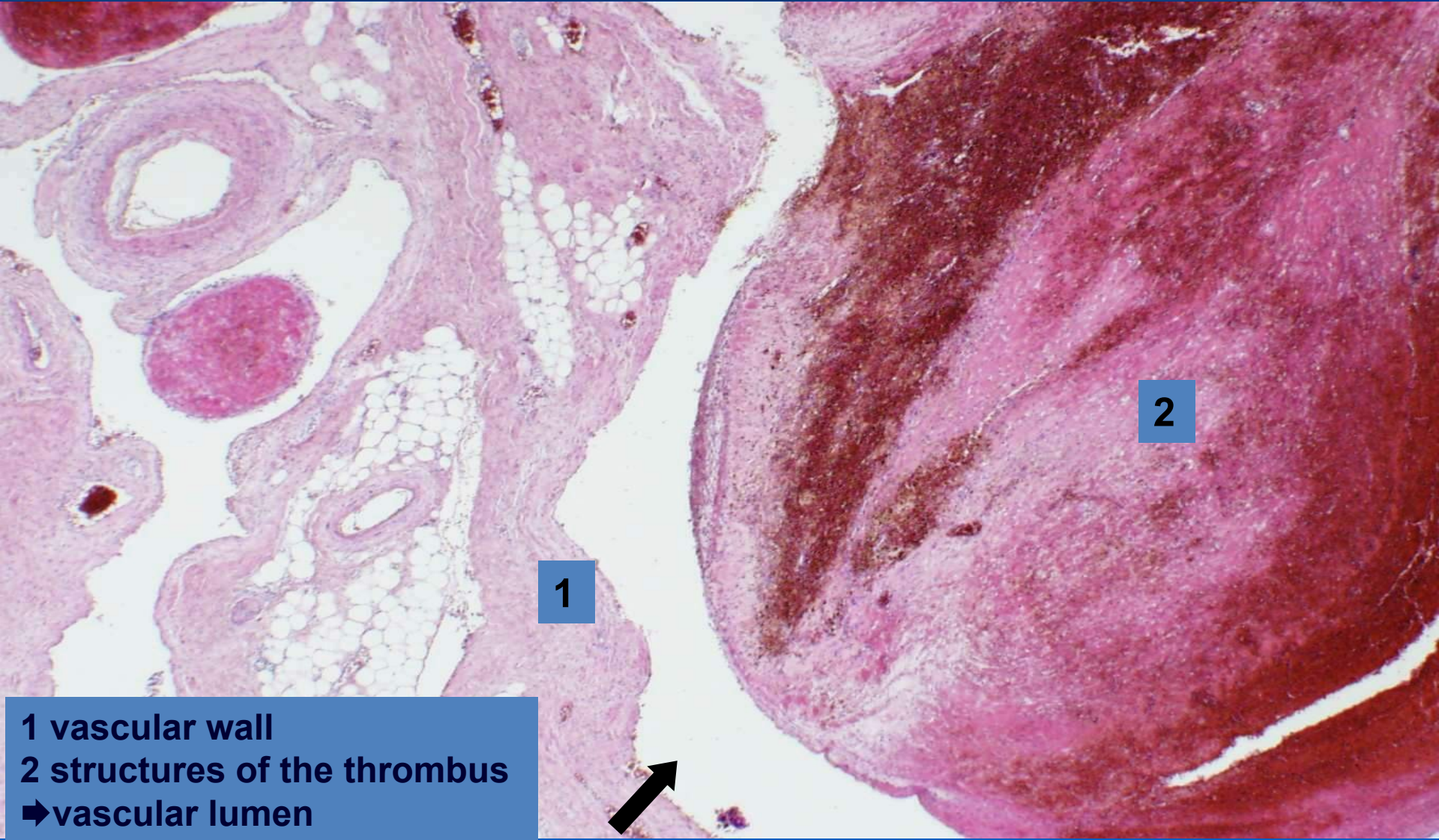
× Local

- ⇒ *thrombosis*
- ⇒ ***embolism***
- ⇒ *hemorrhage*
- ⇒ *oedema*

× Systemic

- ⇒ *cardial*
- ⇒ *extracardial*

Partially organized mixed blood clot



1

2

1 vascular wall
2 structures of the thrombus
➡vascular lumen

Haemorrhage



= loss of blood from the circulatory system, accumulation of blood in the intersticium – HAEMATOMA

✗ localization:

⇒ *external x internal*

✗ origin:

⇒ *arterial, venous, capillary*

✗ appearance:

⇒ *petechiae, ecchymosis (subcutaneous), apoplexy (massive)*

Circulation disorders

✗ Local

⇒ *thrombosis*

⇒ *embolism*

⇒ ***hemorrhage***

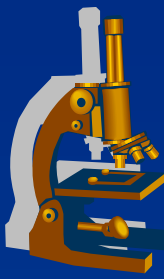
⇒ *oedema*

✗ Systemic

⇒ *cardial*

⇒ *extracardial*

Oedema



Abnormal accumulation of fluid in the intersticium.

× Types:

⇒ *localized*

⇒ *generalized*

Circulation disorders

× Local

⇒ *thrombosis*

⇒ *embolism*

⇒ *hemorrhage*

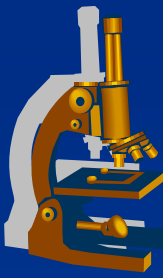
⇒ ***oedema***

× Systemic

⇒ *cardial*

⇒ *extracardial*

Oedema



× Causes:

- ⇒ *venous: ↑ intravenous pressure (e.g. chronic cardiac failure)*
- ⇒ *inflammatory: increase of endothelial permeability*
- ⇒ *hypoalbuminaemic: reduced oncotic pressure*
- ⇒ *lymphostatic oedema*

Circulation disorders

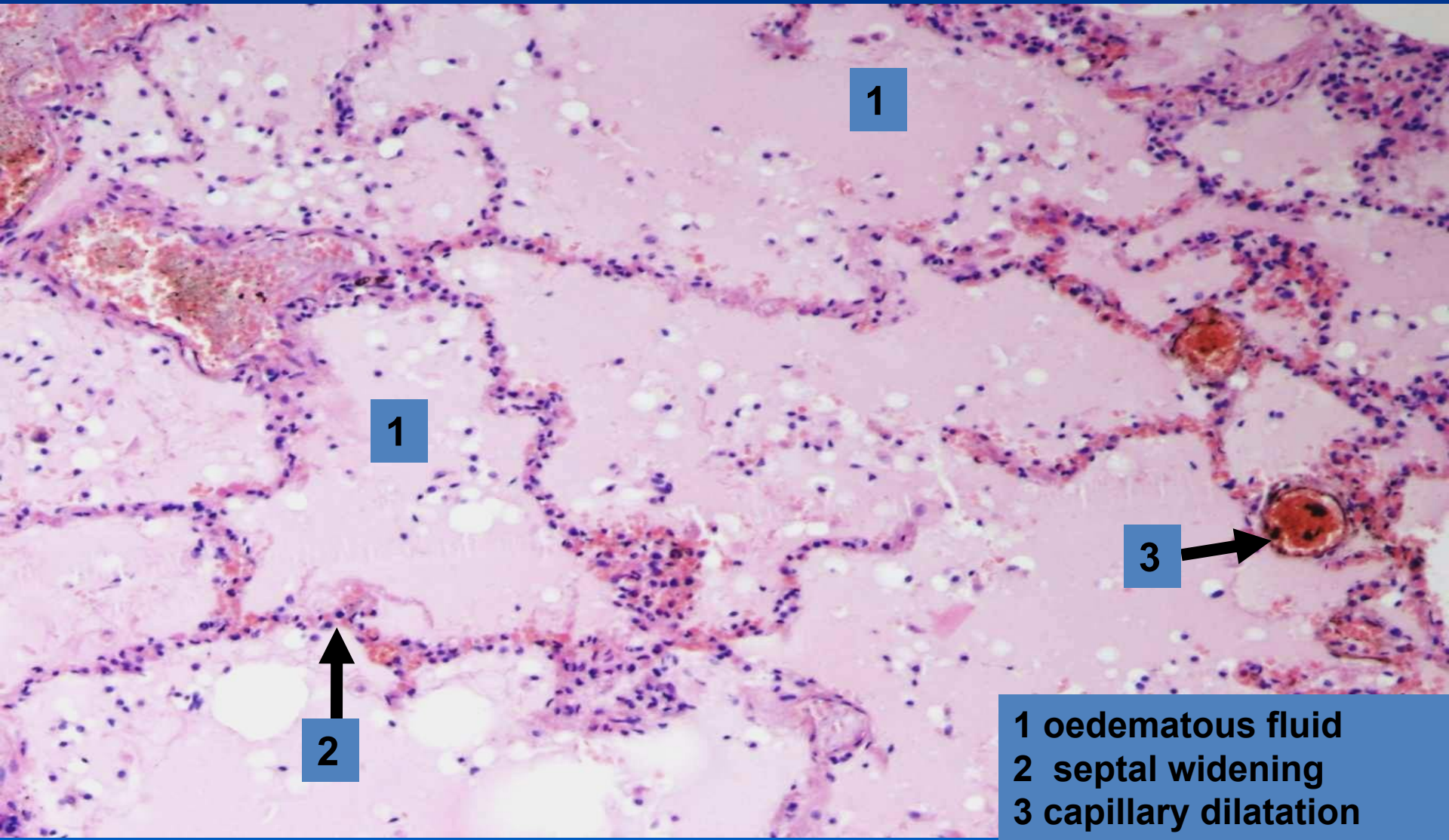
× Local

- ⇒ *thrombosis*
- ⇒ *embolism*
- ⇒ *hemorrhage*
- ⇒ ***oedema***

× Systemic

- ⇒ *cardial*
- ⇒ *extracardial*

Pulmonary oedema



1

1

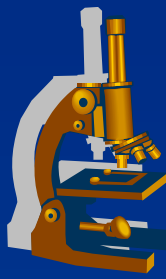
3

2

1 oedematous fluid
2 septal widening
3 capillary dilatation

Circulation disorders

SYSTEMIC



CAUSES:

× HEART

(ischemic heart disease, myocarditis, cardiomyopathy, pericarditis, valvular heart disease, endocarditis)

× VESSELS

(systemic hypertension, pulmonary hypertension)

× BLOOD DISORDERS

(polycythemia vera, anemia)

Circulation disorders

× Local

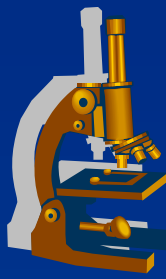
- ⇒ thrombosis
- ⇒ embolism
- ⇒ hemorrhage
- ⇒ oedema

× Systemic

- ⇒ cardiac
- ⇒ extracardial

Circulation disorders

SYSTEMIC



× All causes subsequently manifest as
HEART FAILURE

Left ventricle failure

Right ventricle failure

Congestive heart failure – both ventricles

⇒ „forward“ failure – usually low cardiac output

⇒ „backward“ failure – venous congestion

cardiogenic shock

Circulation disorders

× Local

⇒ thrombosis

⇒ embolism

⇒ hemorrhage

⇒ oedema

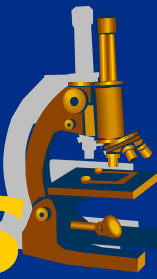
× ***Systemic***

⇒ cardiac

⇒ extracardial

Circulation disorders

MORPHOLOGICAL ASPECTS



× HEART:

⇒ *Dilatation (without hypertrophy)*

- acute cardiac failure (pulmonary embolism)

⇒ *Hypertrophy*

- **concentric** × **eccentric** (+ dilatation)
- Starling`s principle, depletion of adaptation mechanisms

Circulation disorders

× Local

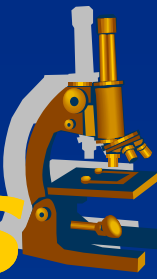
- ⇒ *thrombosis*
- ⇒ *embolism*
- ⇒ *hemorrhage*
- ⇒ *oedema*

× Systemic

- ⇒ **cardial**
- ⇒ *extracardial*

Circulation disorders

MORPHOLOGICAL ASPECTS



× EXTRACARDIAL

- ⇒ *venous congestion +/- cyanosis*
- ⇒ *oedema (pulmonary, systemic)*
- ⇒ *induration*

Circulation disorders

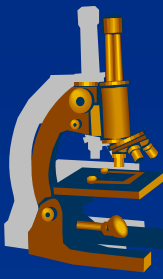
× Local

- ⇒ *thrombosis*
- ⇒ *embolism*
- ⇒ *hemorrhage*
- ⇒ *oedema*

× Systemic

- ⇒ *cardial*
- ⇒ ***extracardial***

Heart failure



x LV x RV

x ACUTE x CHRONIC failure

Heart failure



× LV failure:

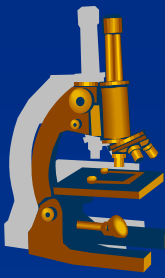
⇒ *acute - morphology:*

- congestion in pulmonary circulation
- pulmonary oedema

⇒ *chronic - morphology:*

- chronic pulmonary venous congestion – „brown“ lung induration (siderophages), later signs of RV failure

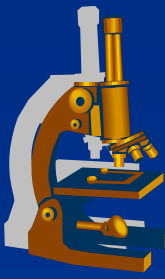
Pulmonary oedema



- x** Left-sided heart failure
(LV insufficiency, mitral stenosis)

- x** congestion in pulmonary veins, capillaries

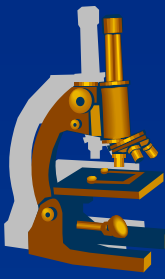
Pulmonary oedema



x GROSS:

- ⇒ enlarged, heavy lung of tougher consistency,*
- ⇒ fluid running out from tissue and bronchi*
- ⇒ in chronic venous congestion: superimposed oedema in the setting of tougher, rusty tissue*

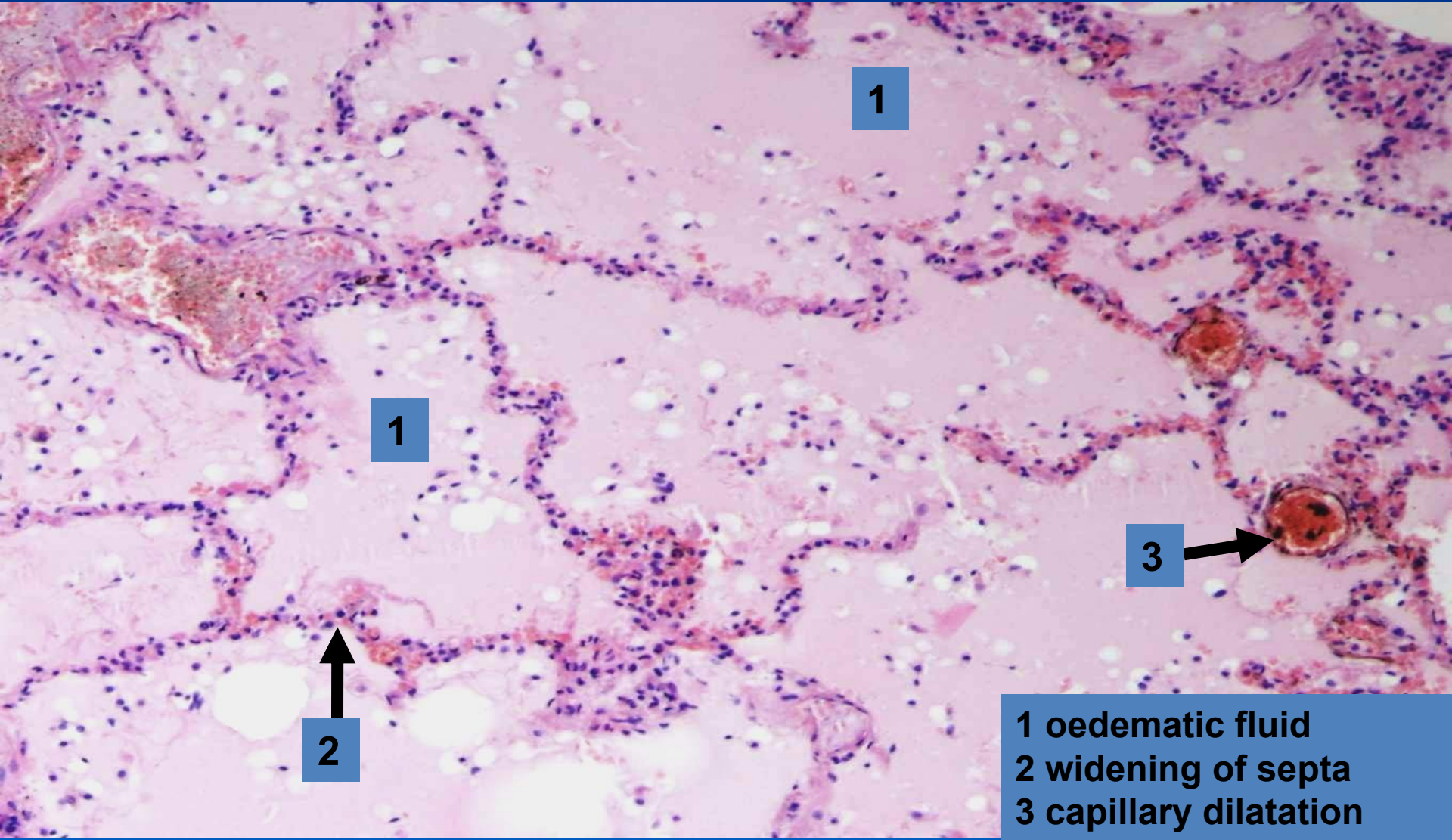
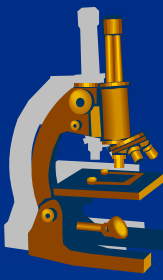
Pulmonary oedema



x MICRO:

- ⇒ *dilatated septal capillaries filled with blood*
- ⇒ *widened septa*
- ⇒ *intraalveolar homogenous eosinophilic material (oedematic fluid)*
- ⇒ *long-standing: extravasation and breakdown of red blood cells (haemosiderin, siderophages)*

Pulmonary oedema



1

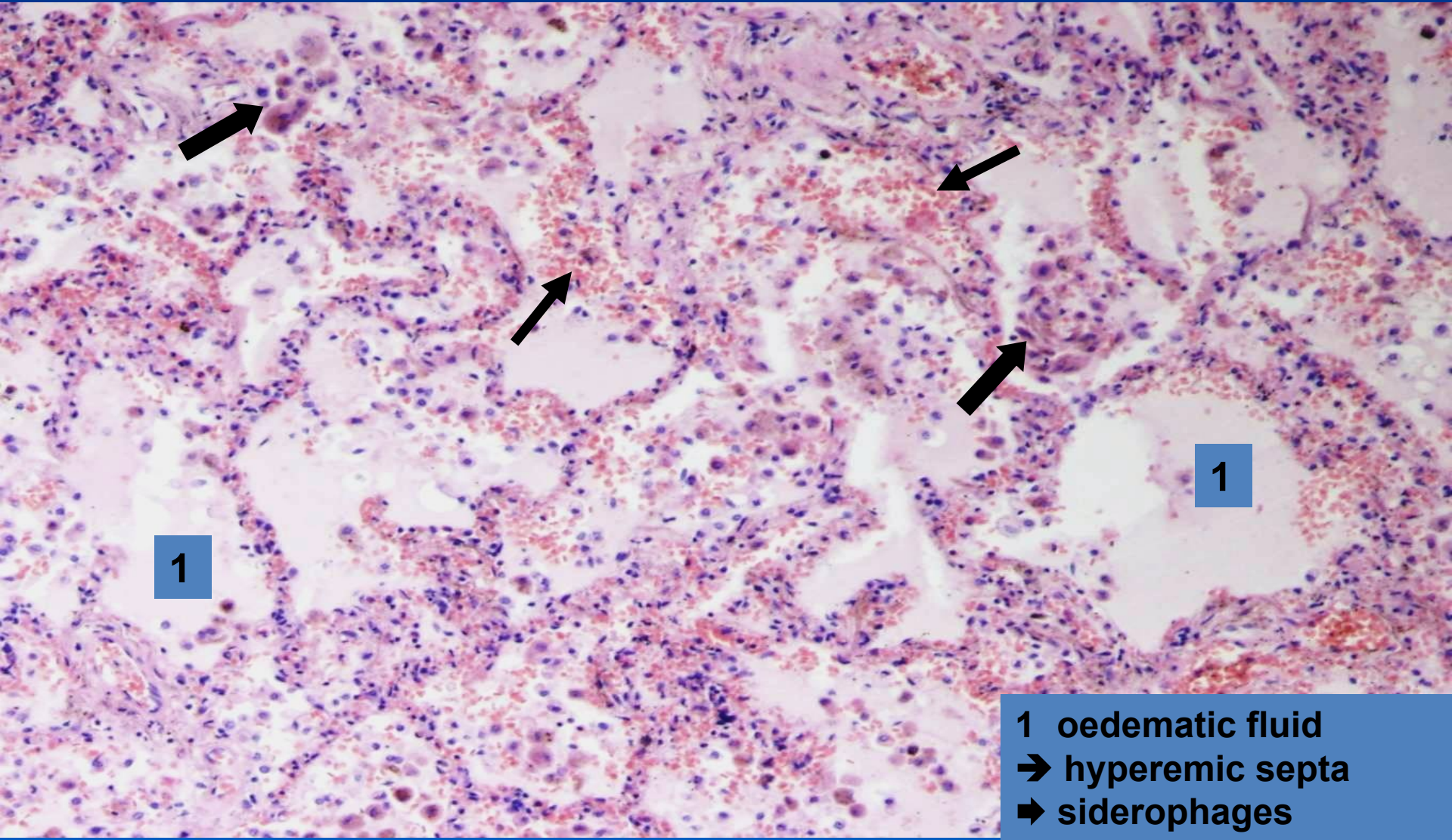
1

3

2

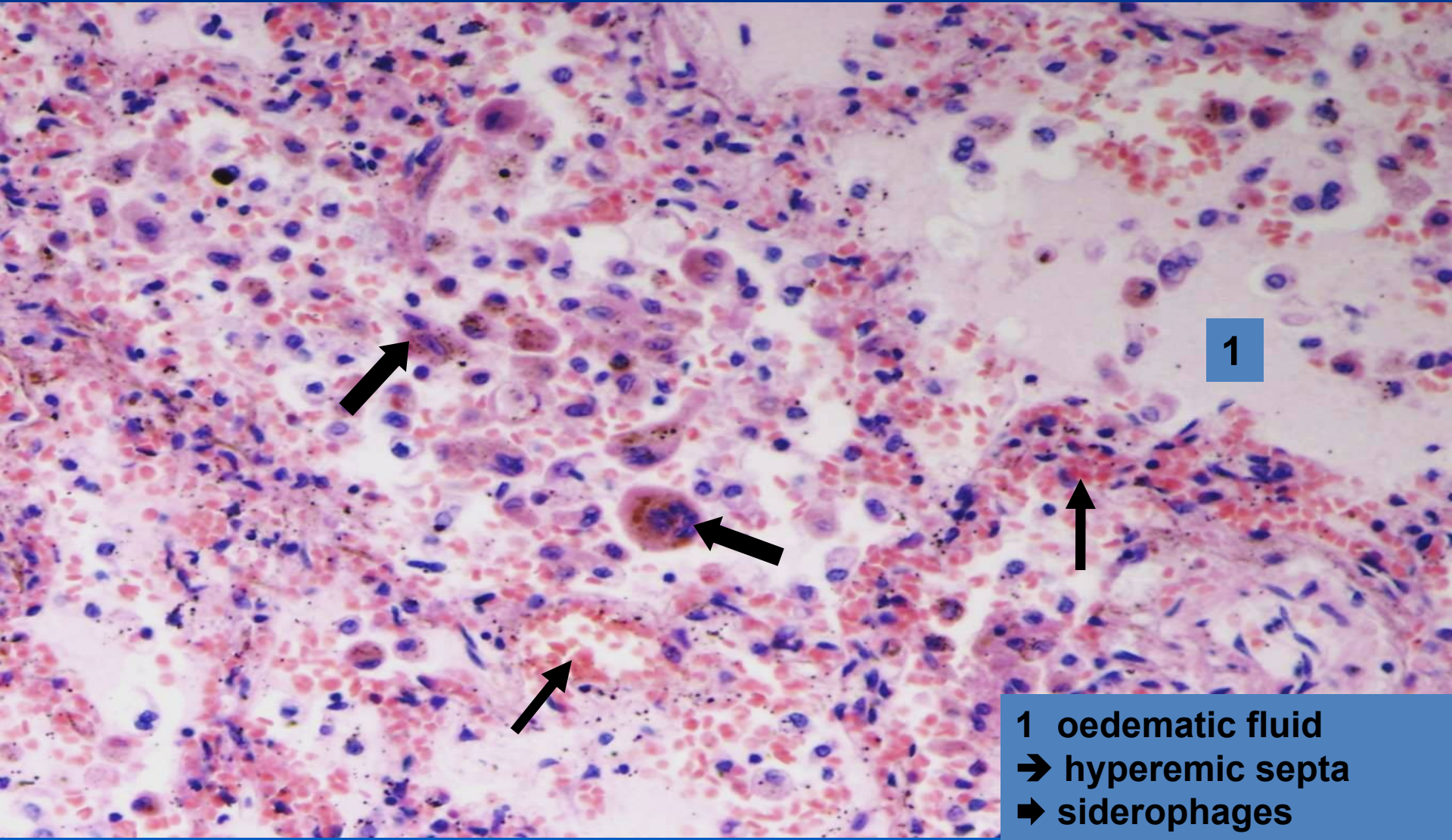
1 oedematous fluid
2 widening of septa
3 capillary dilatation

Chronic pulmonary venous congestion



- 1 oedematous fluid
- hyperemic septa
- siderophages

Chronic pulmonary venous congestion (detail)



1

1 oedematic fluid
→ hyperemic septa
➡ siderophages

Heart failure



x RV insufficiency:

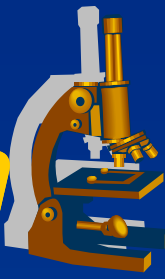
⇒ *acute - morphology:*

- acute cor pulmonale (massive thrombembolism)
- acute congestion in systemic circulation (splanchnic region) → congestive necrosis

⇒ *chronic - morphology:*

- chronic hepatic venous congestion, congestion in portal region (spleen, mucous membranes of GIT), kidneys
- congestive skin/soft tissue changes – trophic, oedemas
- venous congestion in brain

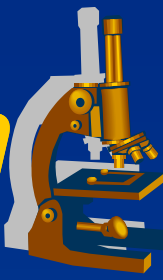
Hepatic venous congestion



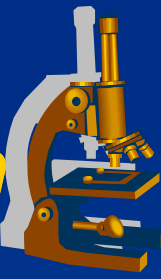
x GROSS:

- ⇒ *enlarged, heavy liver*
- ⇒ *dark – reddish brown color*
- ⇒ *cardiac fibrosis (induration)*
- ⇒ *combination with chronic hypoxemic steatosis –
nutmeg liver*

Hepatic venous congestion ***("nutmeg" liver)***



Hepatic venous congestion



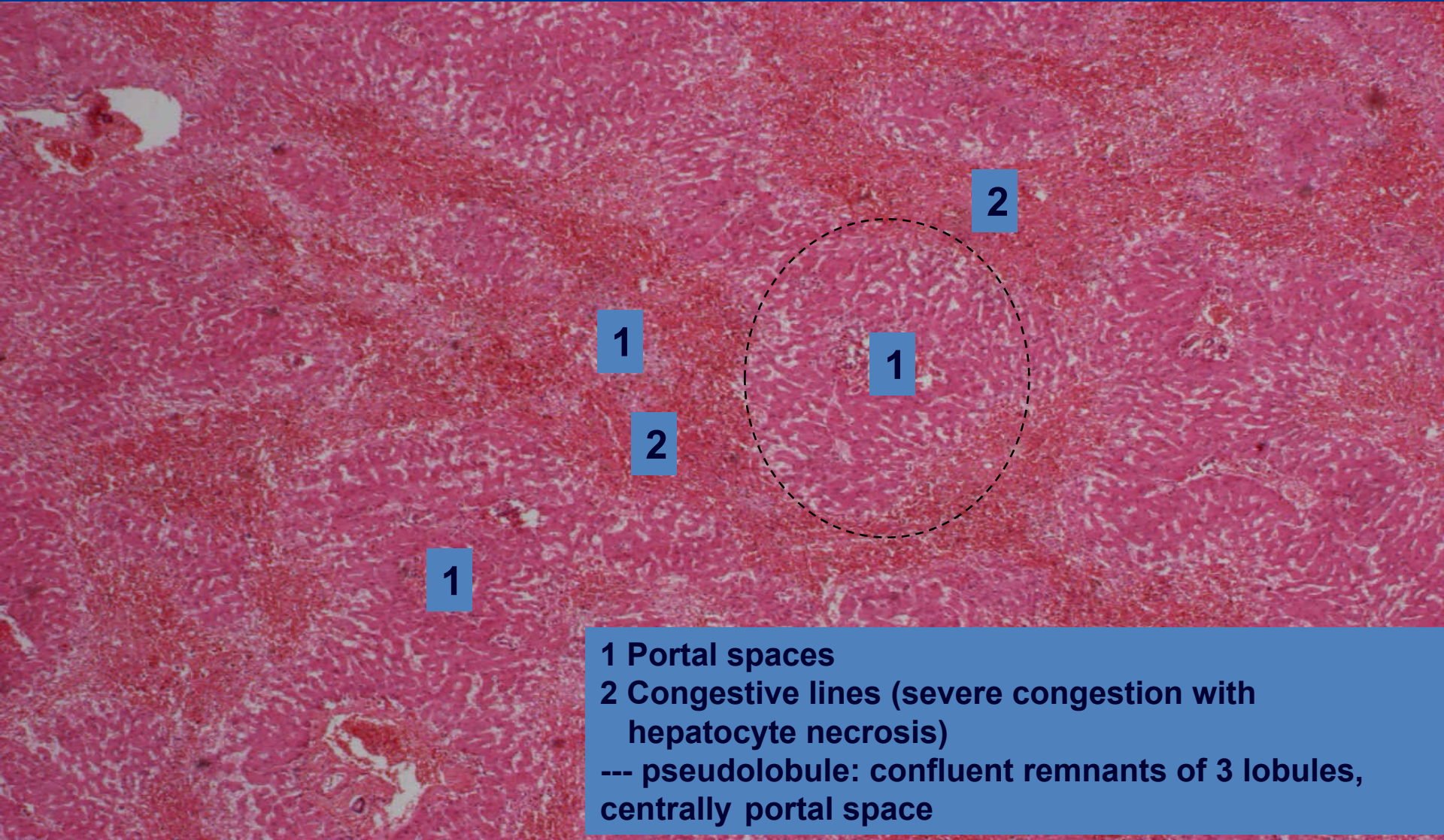
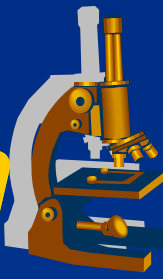
x MICRO:

⇒ *central veins and sinusoidal dilatation*

⇒ *centrolobular hepatocytic atrophy, necrosis*

⇒ *„lines“ of congestion*

Hepatic venous congestion

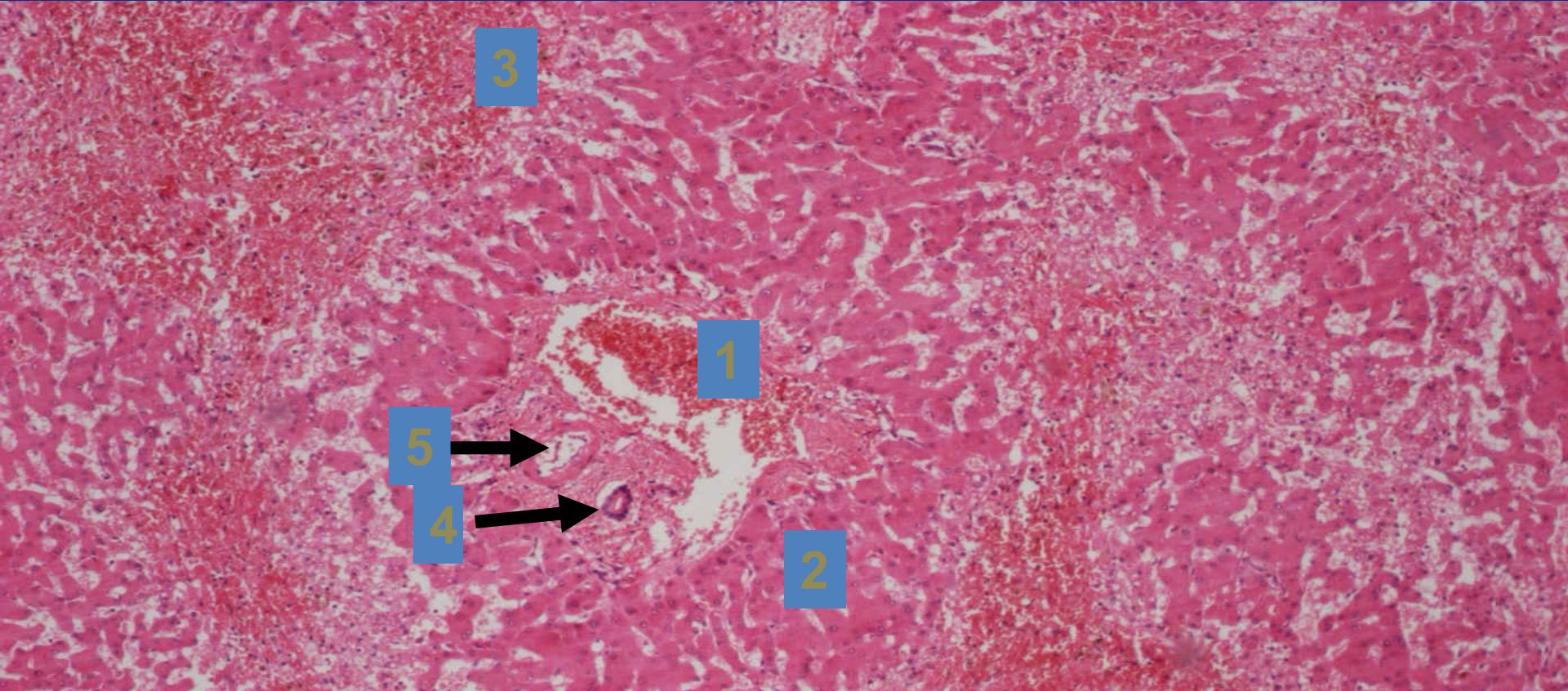
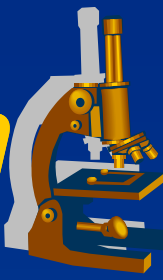


1 Portal spaces

2 Congestive lines (severe congestion with hepatocyte necrosis)

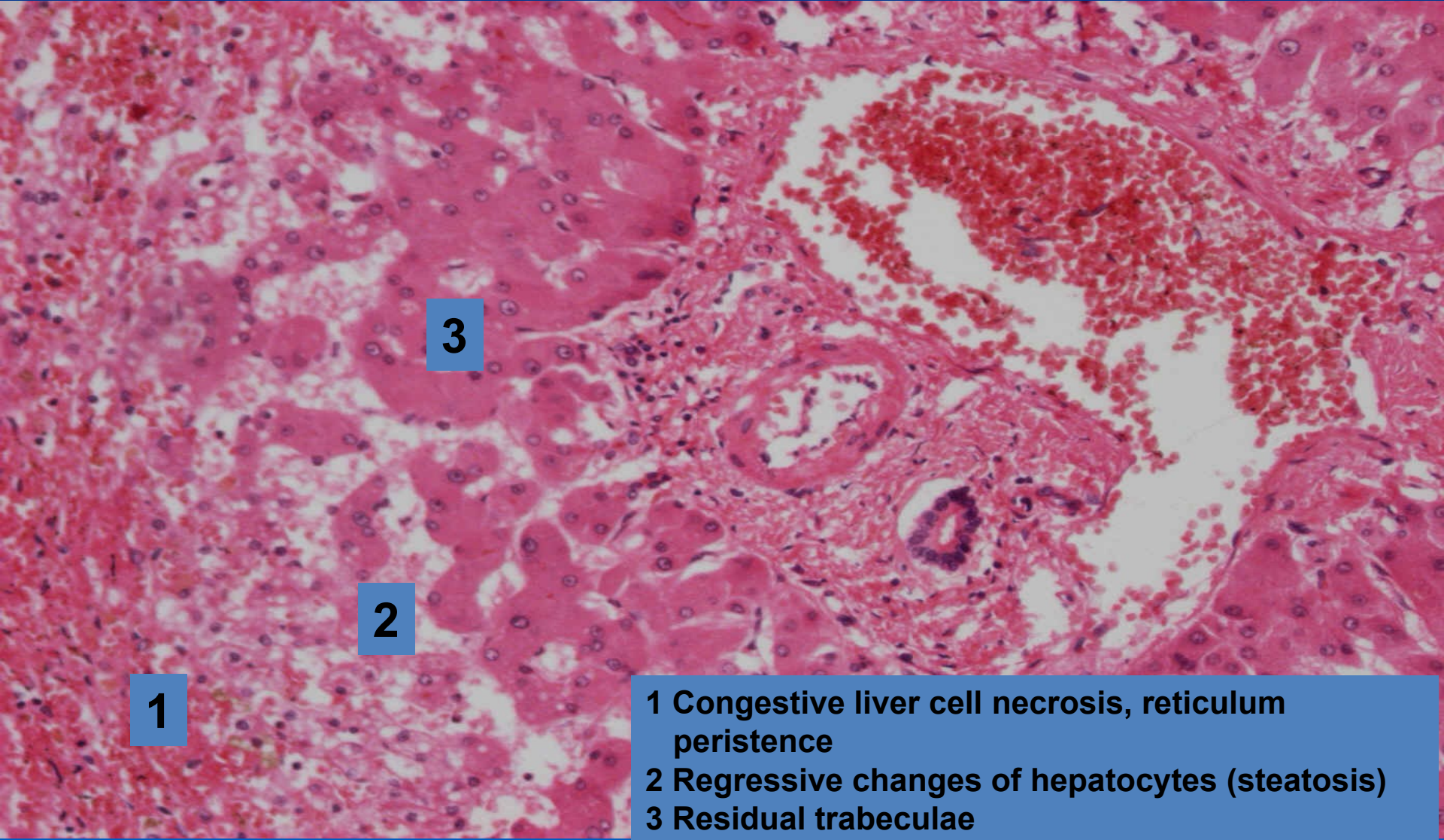
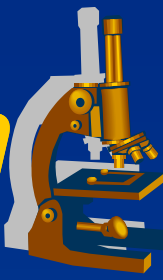
--- pseudolobule: confluent remnants of 3 lobules, centrally portal space

Hepatic venous congestion ***("nutmeg" liver), detail***



- 1 Portal space-dilatation of portal vein branch**
- 2 Pseudolobule**
- 3 Congestion lines**
- 4 Bile duct**
- 5 Hepatic artery branch**

Hepatic venous congestion ***("nutmeg" liver), portal area detail***



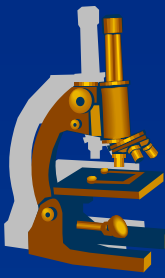
1

2

3

- 1** Congestive liver cell necrosis, reticulum persistence
- 2** Regressive changes of hepatocytes (steatosis)
- 3** Residual trabeculae

Shock



» *Life-threatening medical condition that occurs due to inadequate substrate for aerobic cellular respiration. In the early stages this is generally an inadequate tissue level of oxygen (low organ perfusion).*«

✘ **Lethal without adequate medical therapy.**

Shock



✘ Factors:

⇒ *Insufficient circulating volume (hypovolaemic)*

- ↓ peripheral vascular resistance
- ↑ vascular wall permeability
- blood loss

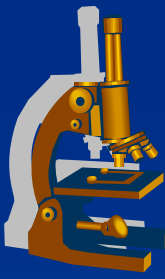
⇒ *Low cardiac output (cardiogenic)*

- Acute heart failure

(acute myocardial infarction, massive pulmonary embolism, cardiac tamponade, tension pneumothorax)

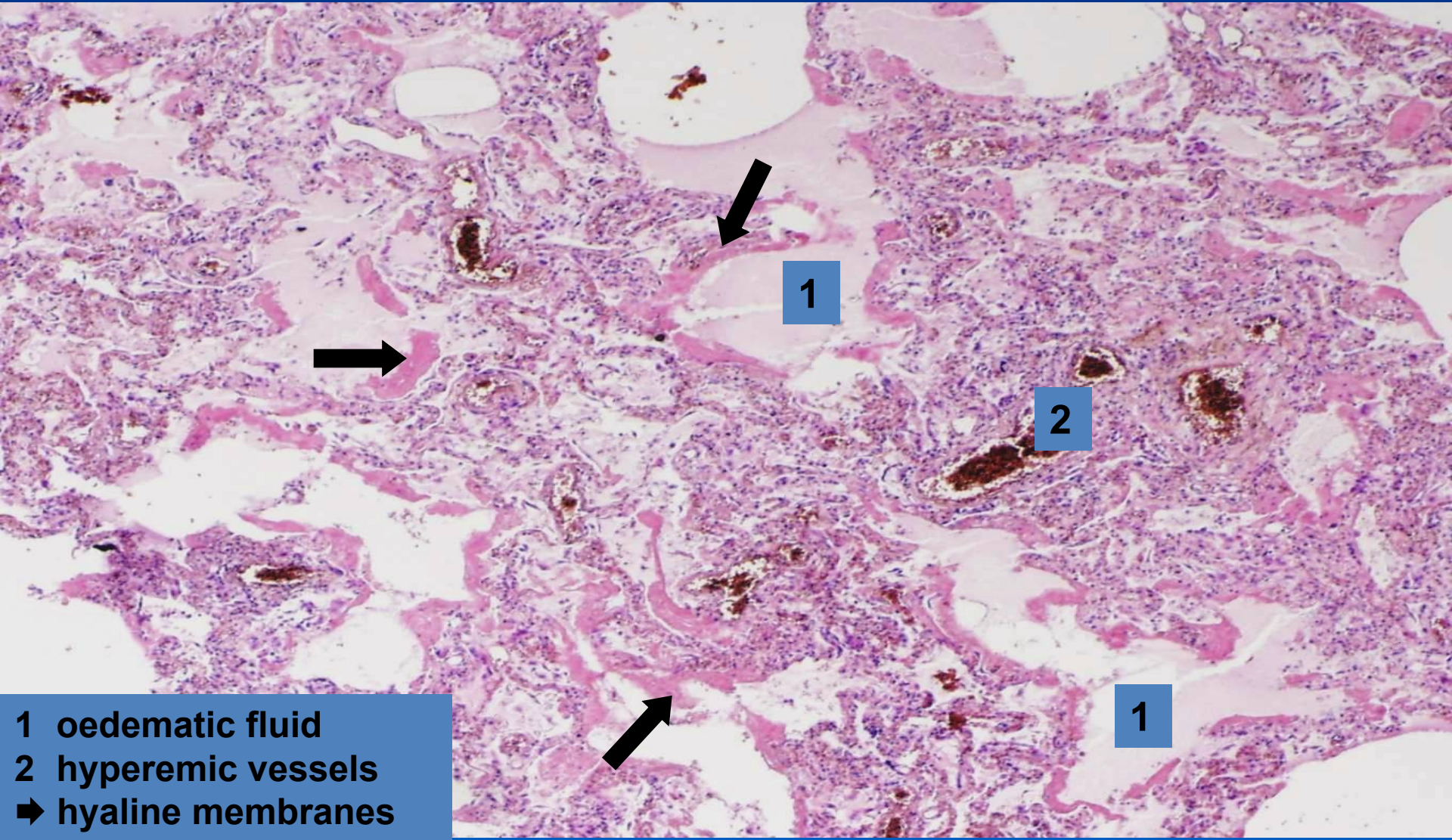
⇒ *Infection (bacterial toxæmia)*

Shock - MORPHOLOGY



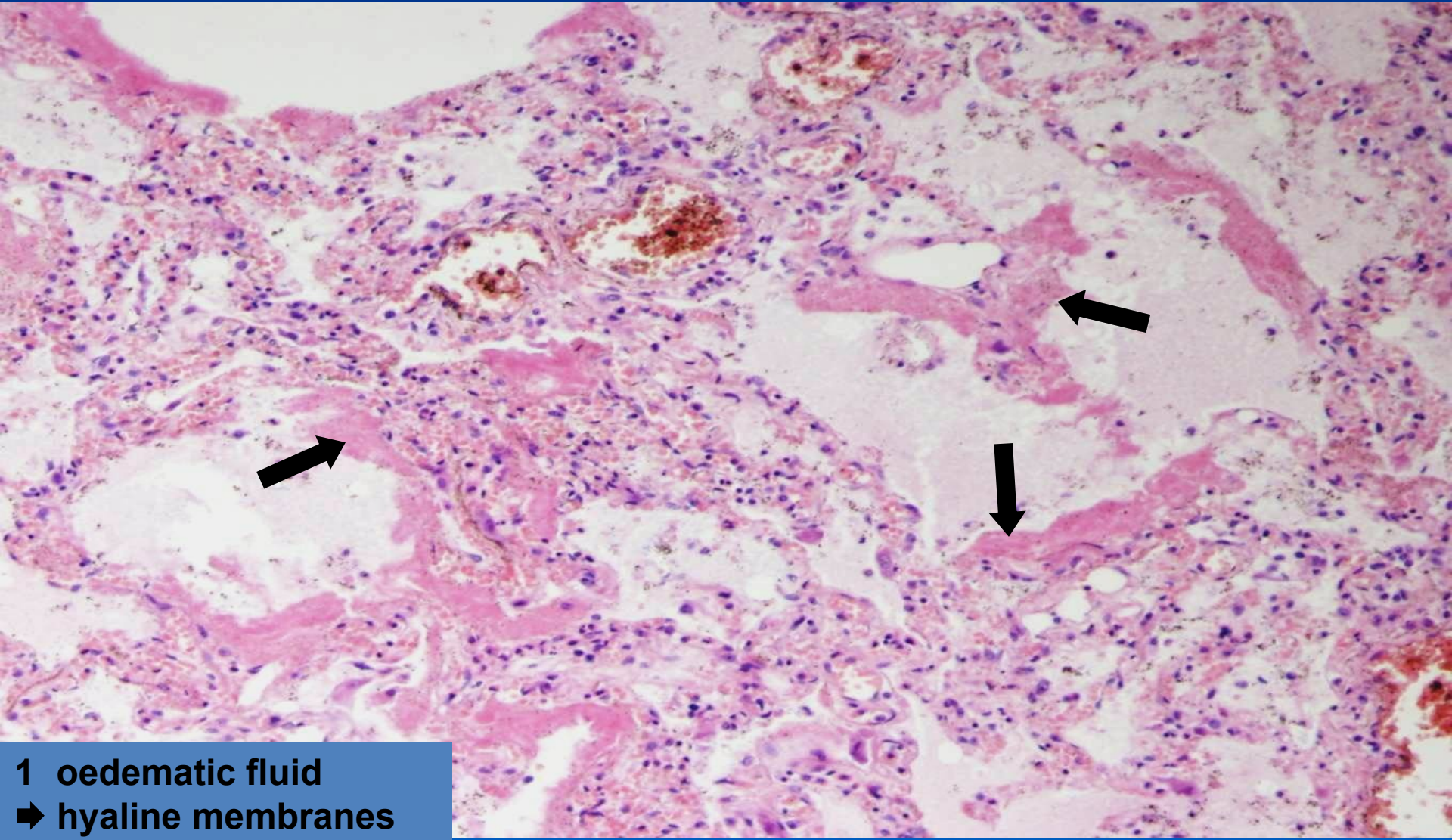
- x Multiple organ failure (organ ischemia)**
 - ⇒ *brain***
 - ⇒ *heart***
 - ⇒ *kidney – acute tubular necrosis (ATN)***
 - ⇒ *lungs – diffuse alveolar damage/ acute respiratory distress syndrome (DAD/ARDS)***
 - ⇒ *adrenal glands, gastrointestinal tract***

DAD/ARDS



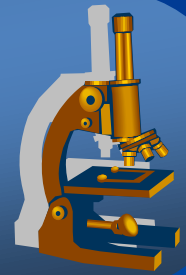
- 1** oedemetic fluid
- 2** hyperemic vessels
- ➡** hyaline membranes

DAD/ARDS ***(detail)***



1 oedemetic fluid
➔ hyaline membranes

Inflammation



Inflammation



= *PROTECTIVE RESPONSE* intended to eliminate harmful agents, accompanied with **alterative, exudative, proliferative components and immune response.**

✗ types:

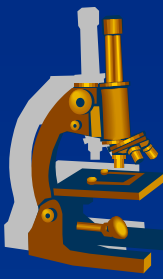
⇒ *acute inflammation*

⇒ *chronic inflammation*

⇒ *nonspecific inflammation*

⇒ *granulomatous inflammation (specific)*

Inflammation



x Macroscopic appearances:

⇒ *rubor (redness)*

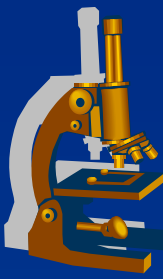
⇒ *calor (heat)*

⇒ *dolor (pain)*

⇒ *tumor (swelling)*

⇒ *functio laesa (loss of function)*

Inflammation



x Microscopic appearances:

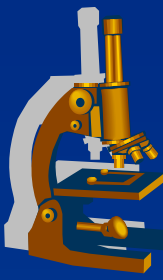
⇒ **ALTERATION:**

- regressive changes, necrosis

⇒ **EXUDATION:**

- vascular leakage of protein-rich fluid and blood cells
- ***exudate X transudate***

Inflammation



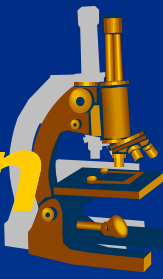
⇒ ***PROLIFERATION:***

- proliferation of fibroblasts and capillaries
- formation of granulation and fibrous tissue

⇒ ***IMMUNE RESPONSE:***

- antigen presentation
- T and B-lymphocytes reaction
- production of antibodies by plasma cells
- memory cells

NONSPECIFIC inflammation



Classification:

⇒ ***alterative:***

- alteration of tissue
- *viral hepatitis, prion diseases [Creutzfeld-Jacob, BSE], diphtheric myocarditis*

⇒ ***exudative:***

- most common, exudation prevails
- superficial and deep
- *serous, fibrinous, nonpurulent, purulent, gangrenous*

⇒ ***proliferative:***

- formation of fibrous tissue

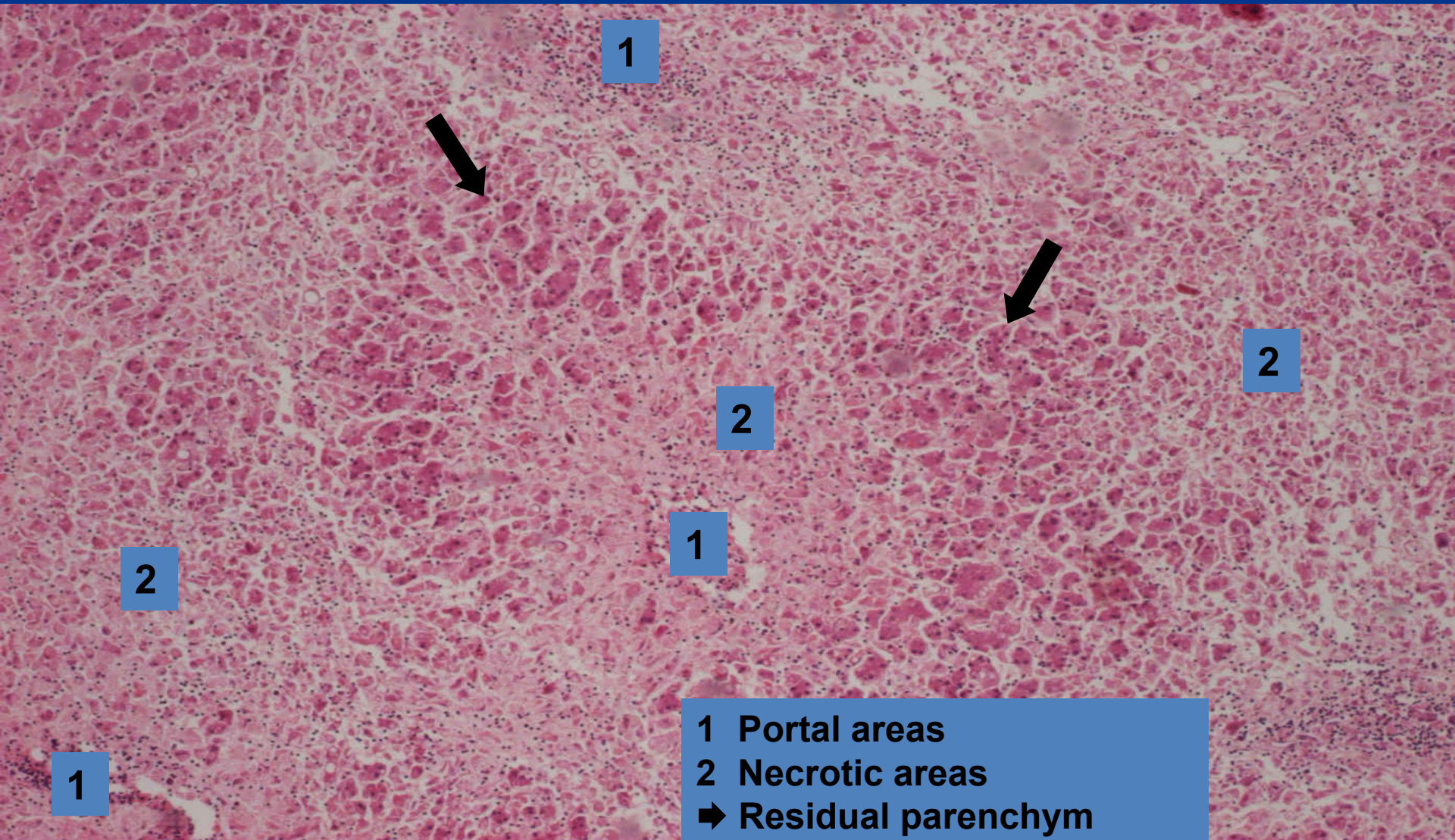
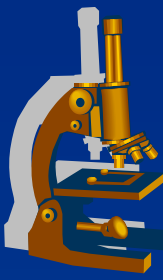
Alterative inflammation ***(liver necrosis)***



copy

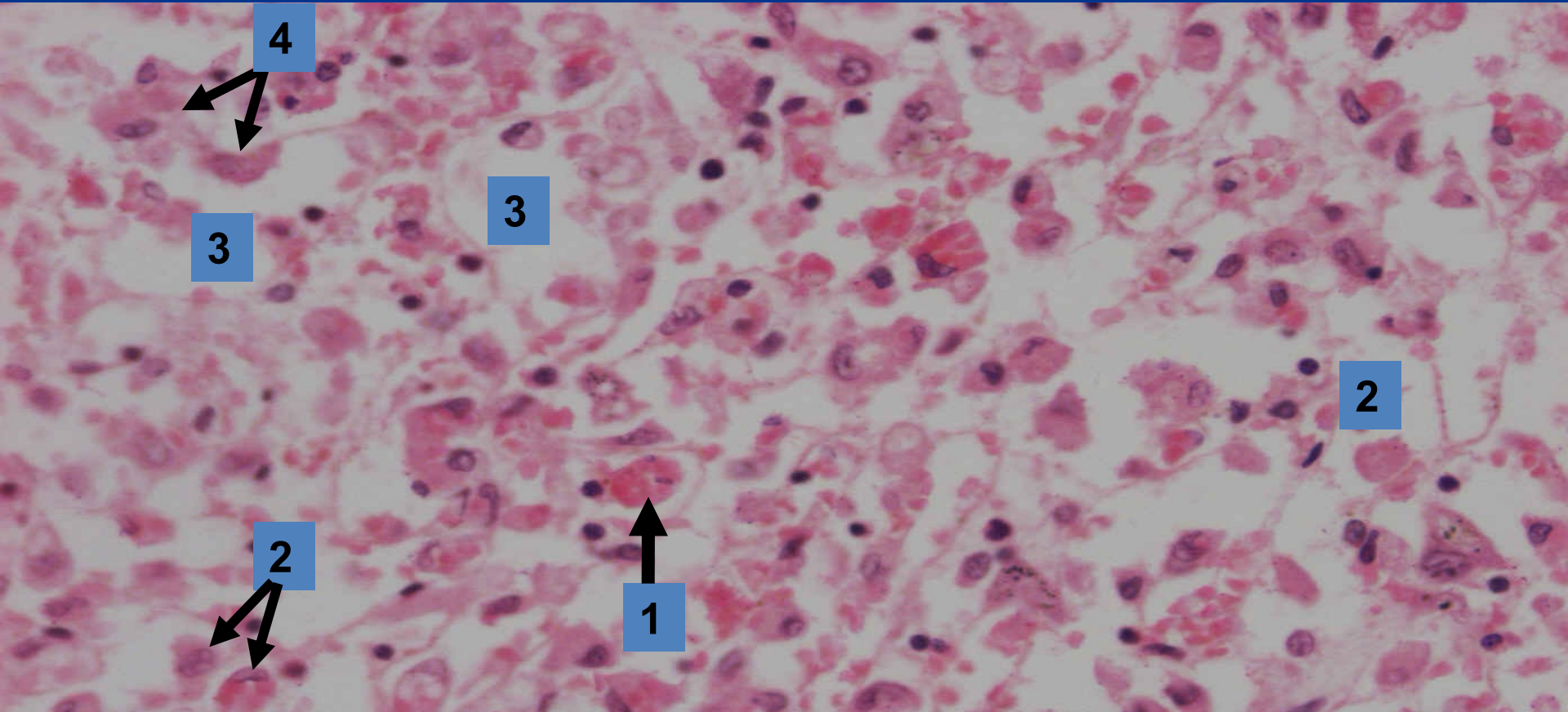


Alterative inflammation *(massive necrosis)*



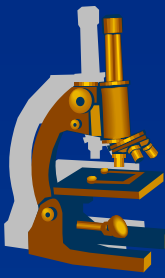
- 1 Portal areas
- 2 Necrotic areas
- ➔ Residual parenchyma

Alterative inflammation ***(massive necrosis - detail)***



- 1 Necrotic cell
- 2 Regressively changed hepatocytes
- 3 Sinusoids
- 4 Kupffer cells

Exudative inflammation



x topography of inflammatory changes:

⇒ ***superficial*** (*mucous membrane, serous membranes, skin*)

⇒ ***deep*** (*interstitium*)

x exudate components:

⇒ ***serous***

⇒ ***fibrinous***

⇒ ***nonpurulent***

⇒ ***purulent***

⇒ ***gangrenous***

Exudative inflammation



xserous:

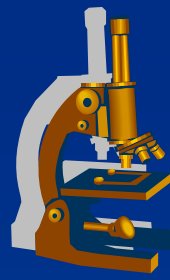
⇒ *watery exudate*

- few proteins (fibrinogen)
- in mucous membranes – catarrhal (mucus)

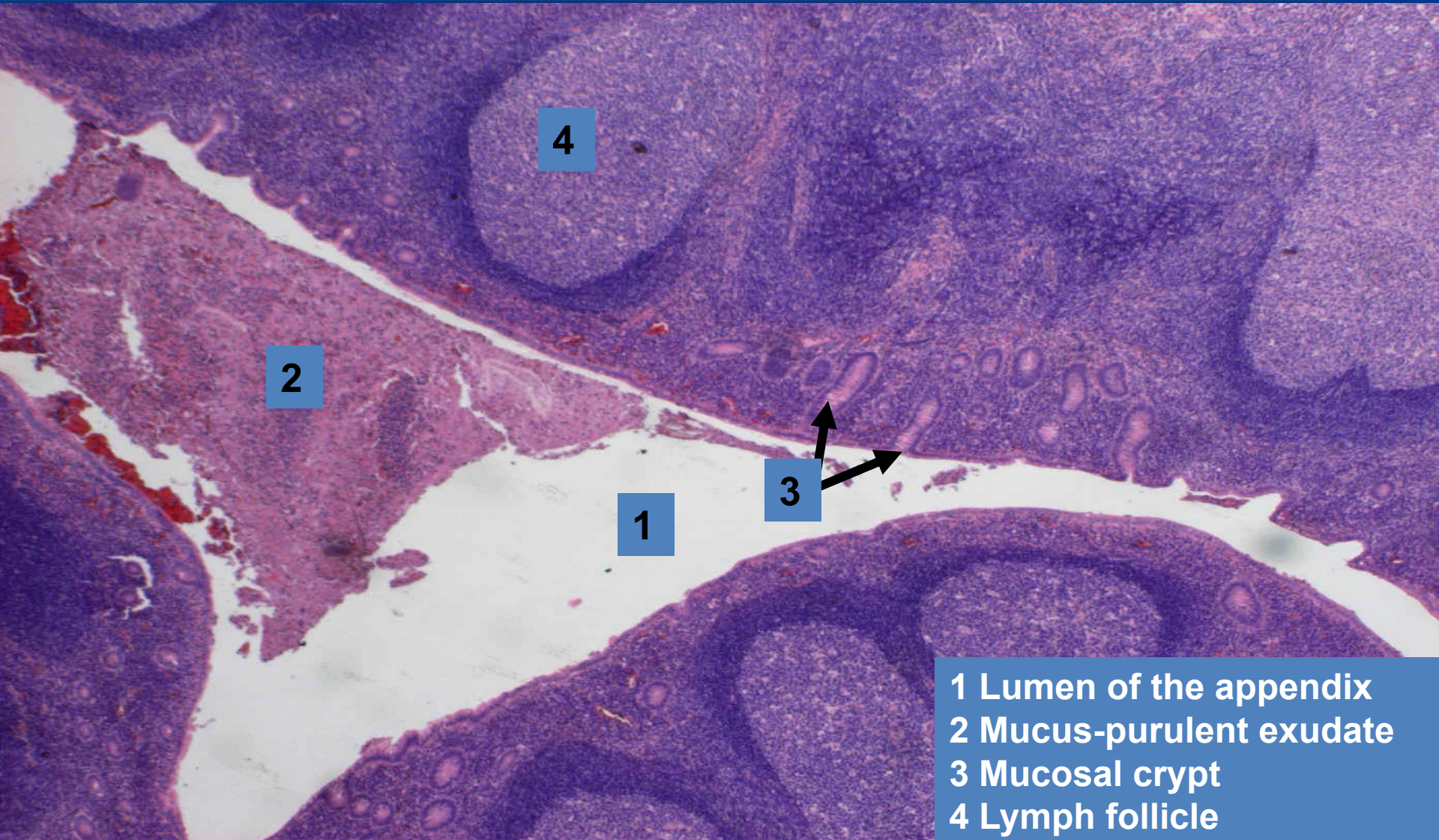
⇒ *heals by inhibition of exudation*

⇒ *examples:*

- **superficial:** catarrhal appendicitis
- **deep (interstitial):** urticaria (hives)



Acute catarrhal appendicitis ***(superficial serous inflammation)***



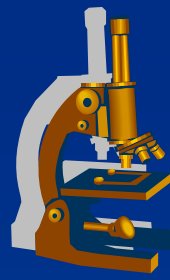
2

4

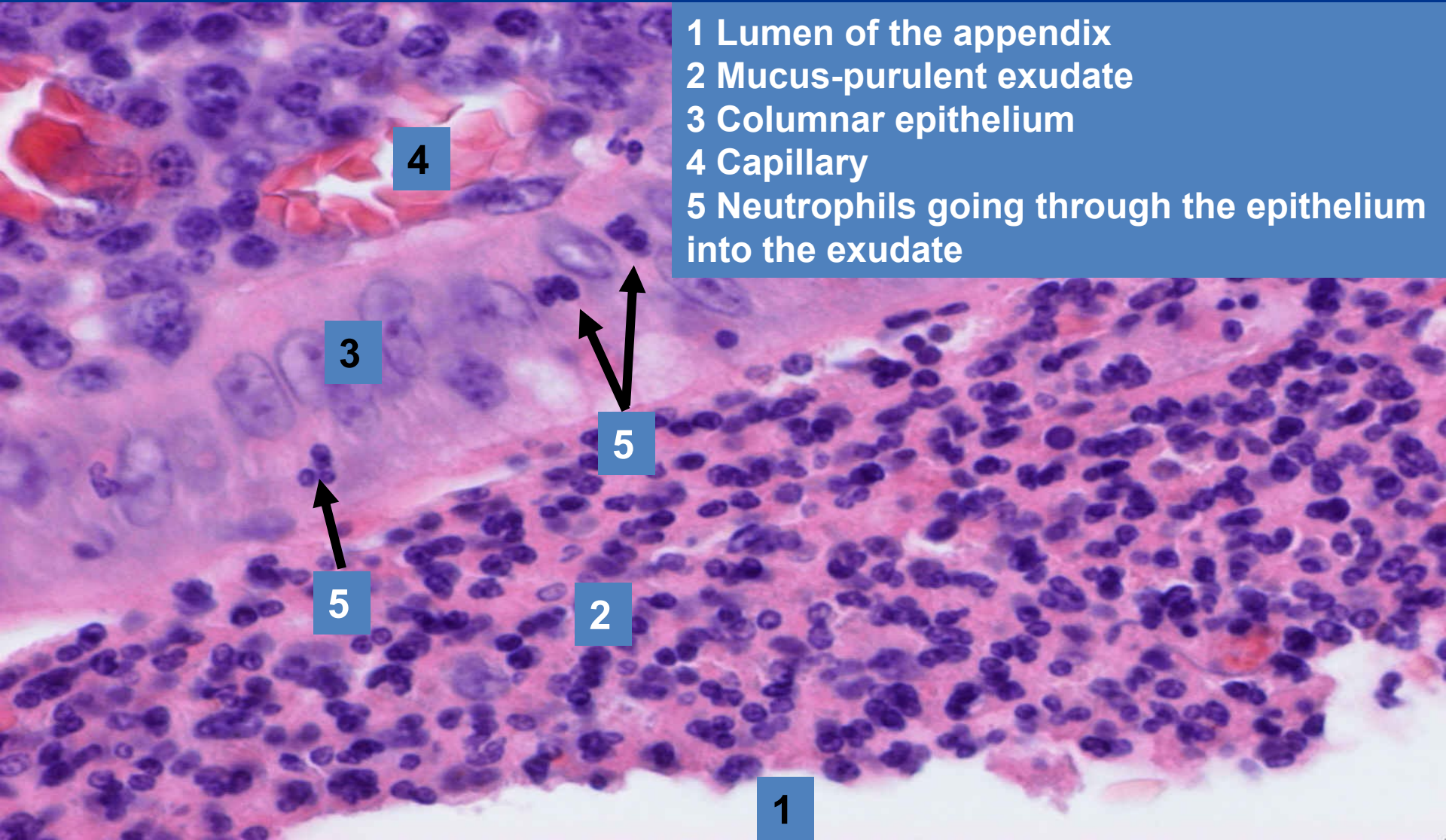
1

3

- 1 Lumen of the appendix
- 2 Mucus-purulent exudate
- 3 Mucosal crypt
- 4 Lymph follicle

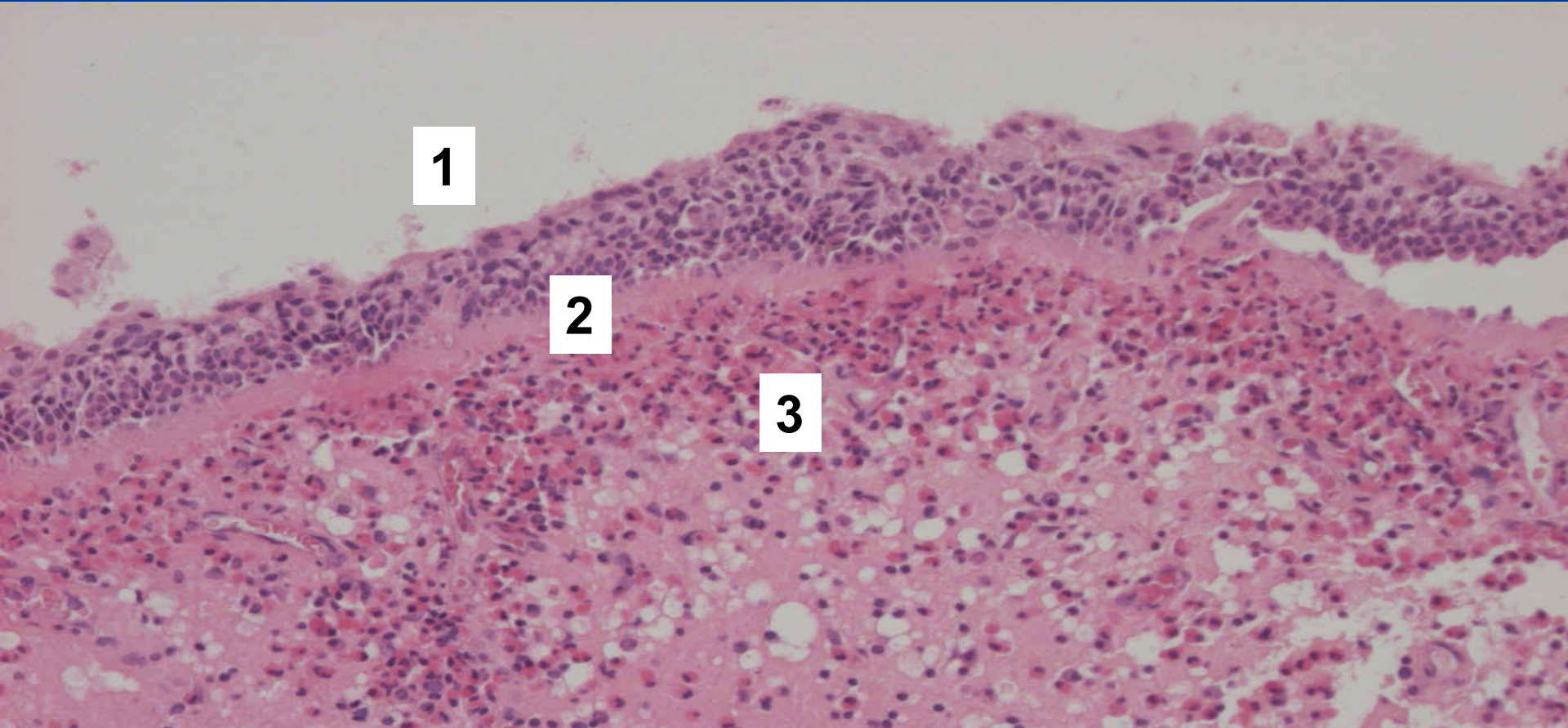


Acute catarrhal appendicitis ***(superficial serous inflammation)***



- 1 Lumen of the appendix
- 2 Mucus-purulent exudate
- 3 Columnar epithelium
- 4 Capillary
- 5 Neutrophils going through the epithelium into the exudate

Polypous chronic rhinitis ***(superficial serous inflammation)***



1

2

3

- 1 Epithelium with squamous metaplasia**
- 2 Thickened basal membrane**
- 3 Oedematous stroma with eosinophilic and plasma cell infiltration, dilatated lymphatic vessels**

Polypous chronic rhinitis ***(superficial serous inflammation)***

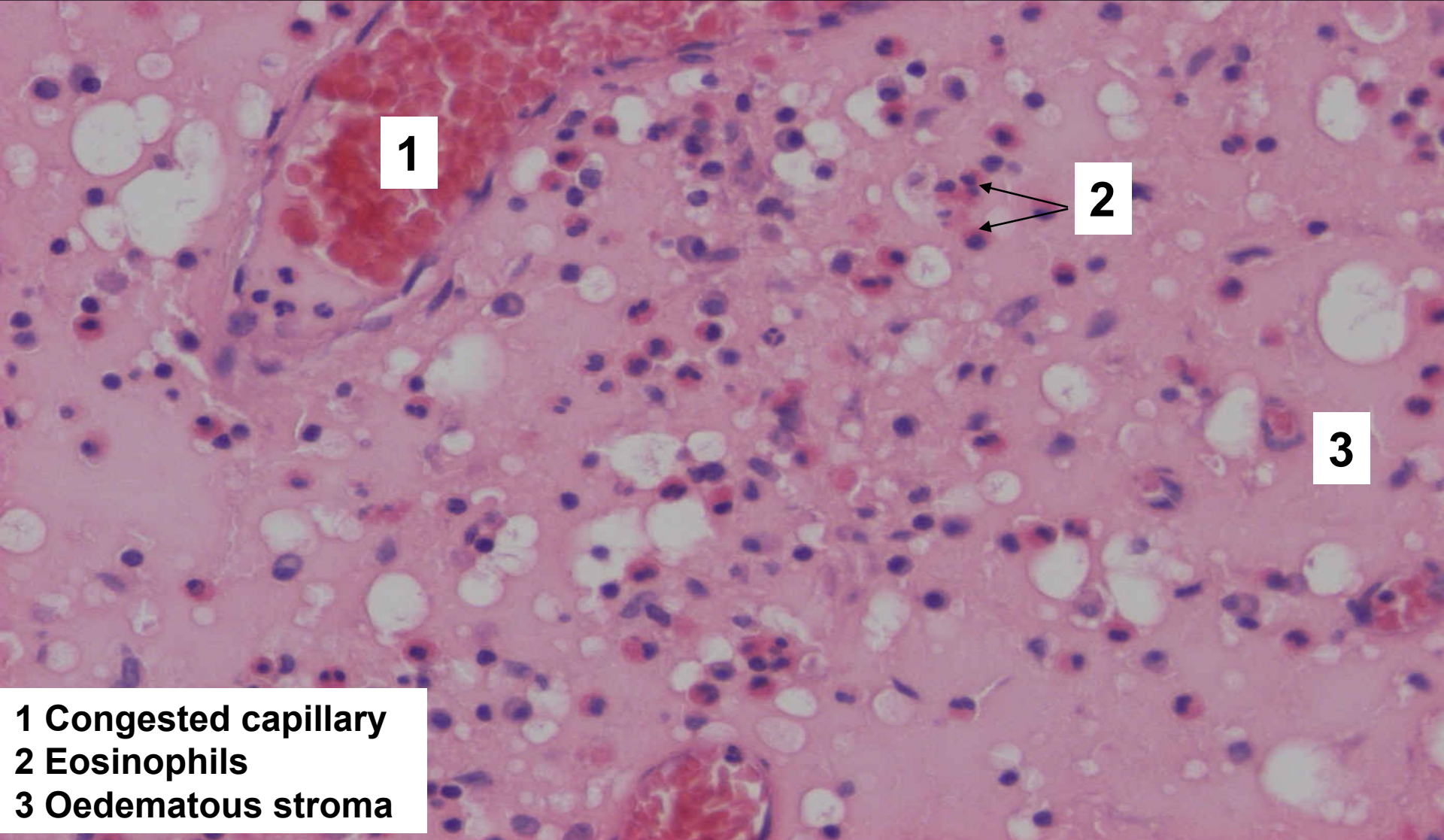


1

2

1 Ciliated epithelium
**2 Oedematous stroma with
inflammatory infiltrate**

Polypous chronic rhinitis ***(superficial serous inflammation)***



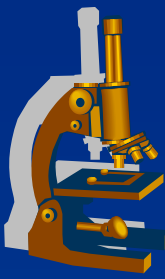
1

2

3

- 1 Congested capillary**
- 2 Eosinophils**
- 3 Oedematous stroma**

Exudative inflammation



x fibrinous:

⇒ *content of fibrinogen – fibrin*

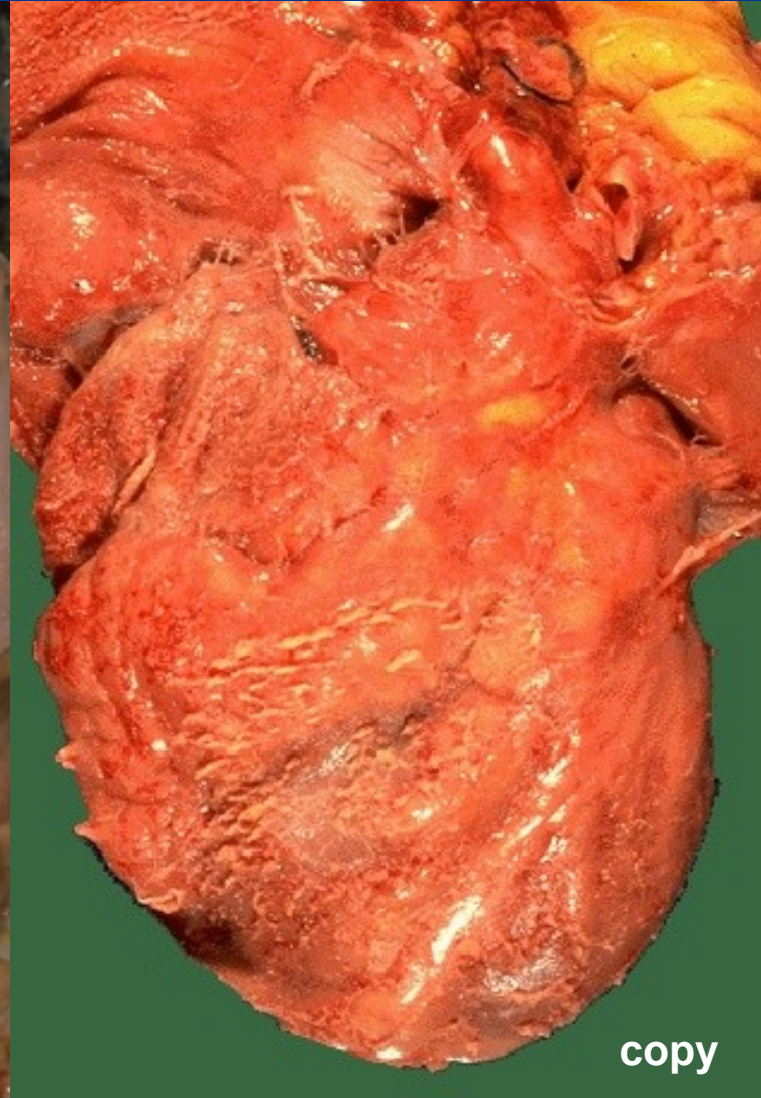
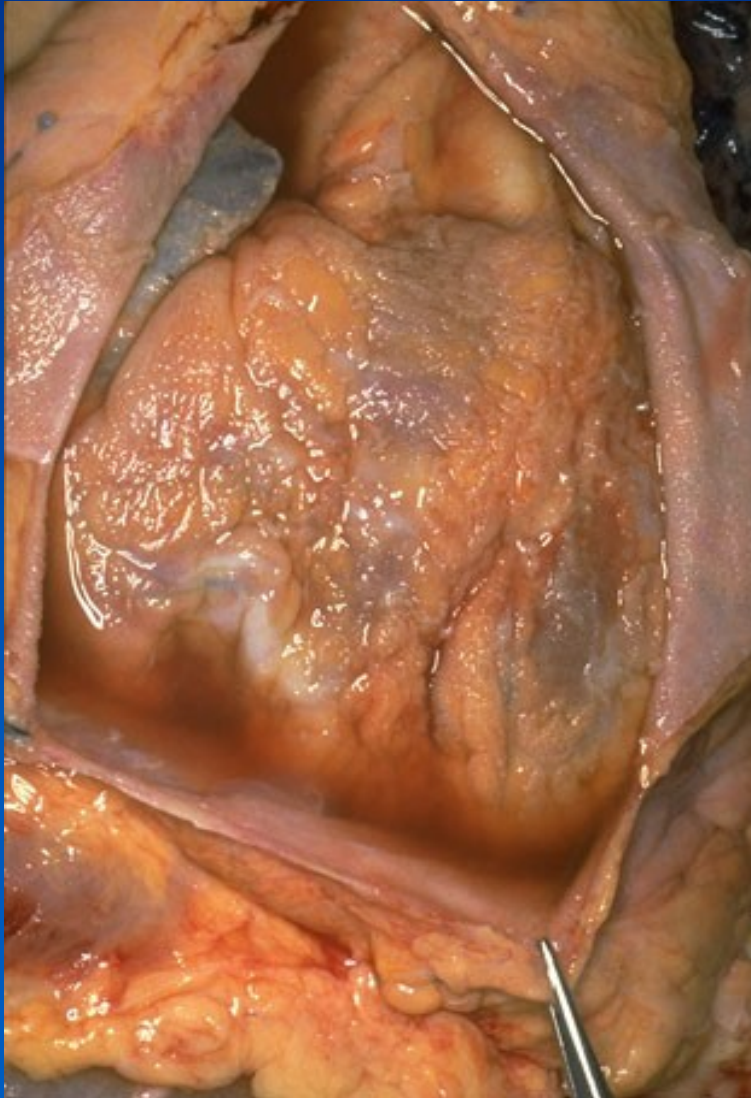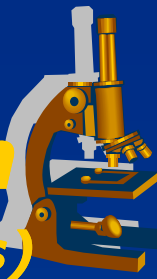
- gross: yellow-greyish *plaques*
- micro: eosinophilic fine fibers

⇒ *healing is more complicated (productive inflammation)*

⇒ *examples:*

- superficial inflammation of serous membranes:
 - **fibrinous pericarditis** (upon uremia) = cor villosum, hirsutum
- superficial infl. of mucous membranes (**PSEUDOMEMBRANES**):
 - **plaque-like inflammations**
- deep:
 - **rheumatic fever**

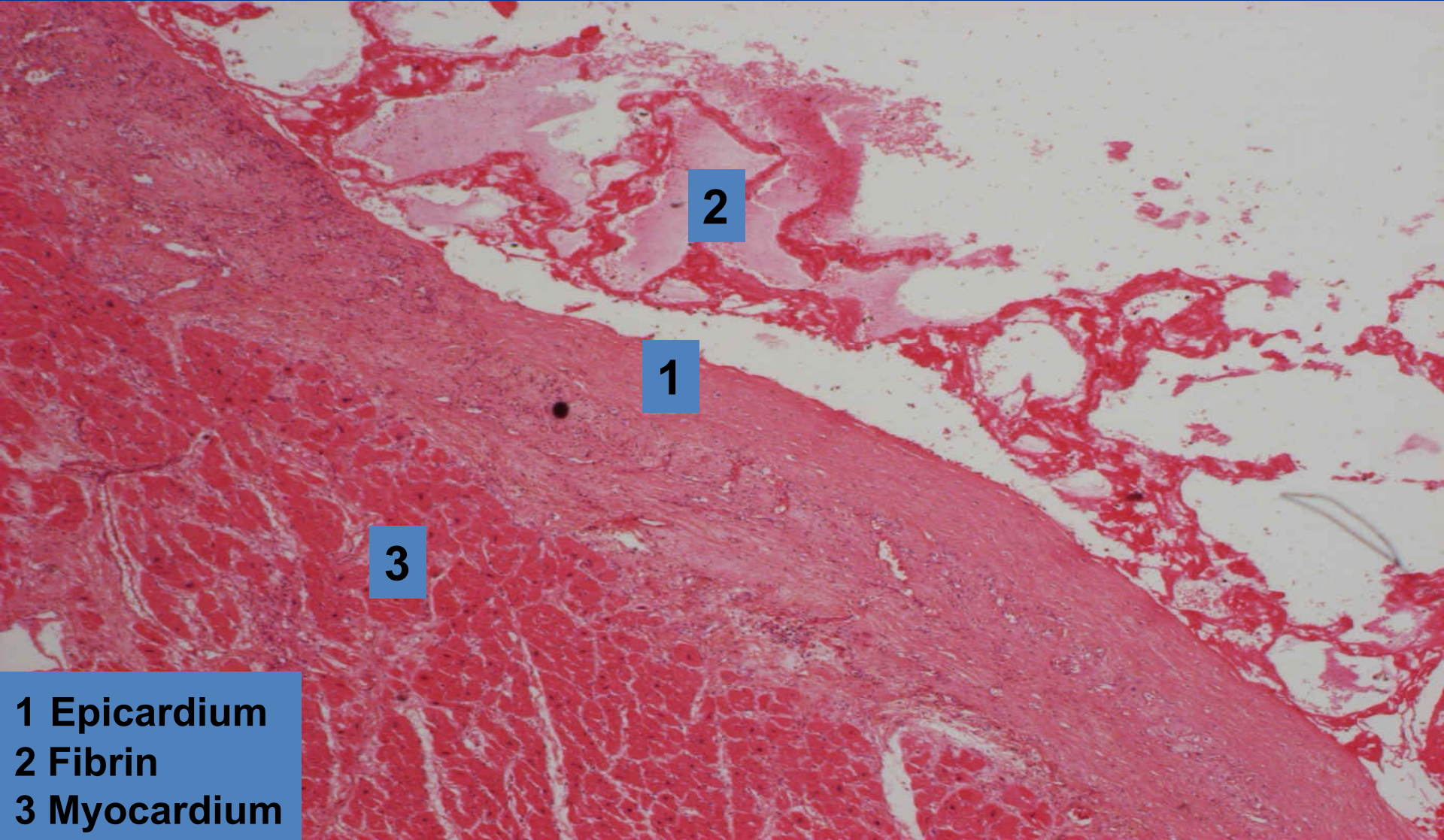
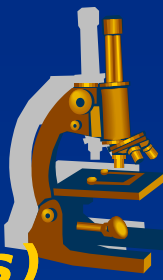
Fibrinous pericarditis – cor villosum ***(superficial fibrinous inflammation of serous membranes)***



copy

Fibrinous pericarditis

(superficial fibrinous inflammation of serous membranes)



2

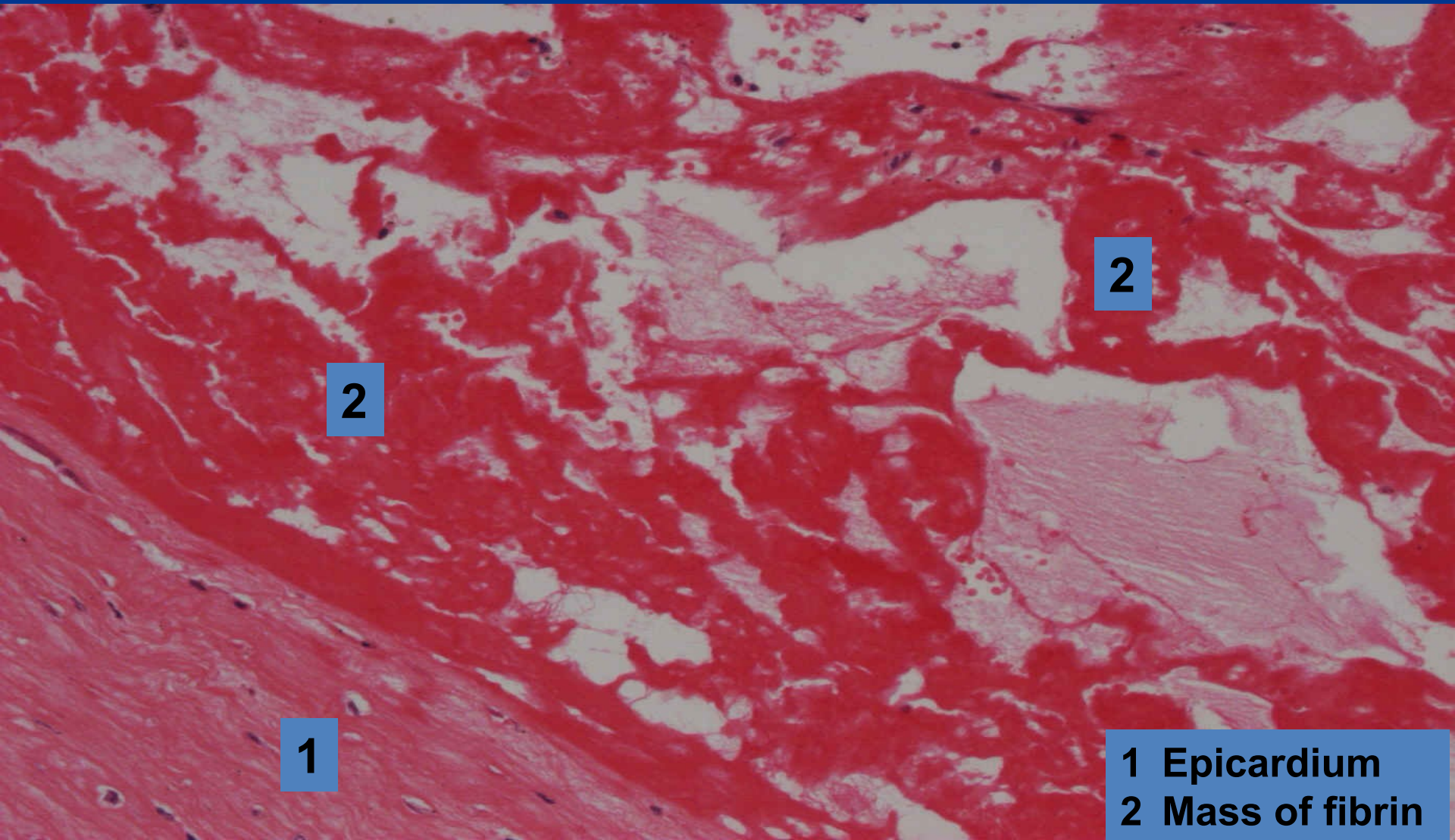
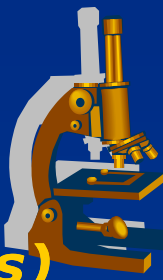
1

3

- 1 Epicardium
- 2 Fibrin
- 3 Myocardium

Fibrinous pericarditis

(superficial fibrinous inflammation of serous membranes)

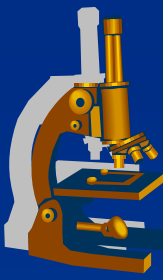


2

2

1

1 Epicardium
2 Mass of fibrin



Exudative fibrinous mucosal inflammation

Classification due to mucosal damage:

x croupous

⇒ *little alteration, plaque is loose on the surface*
(*croupous pneumonia*)

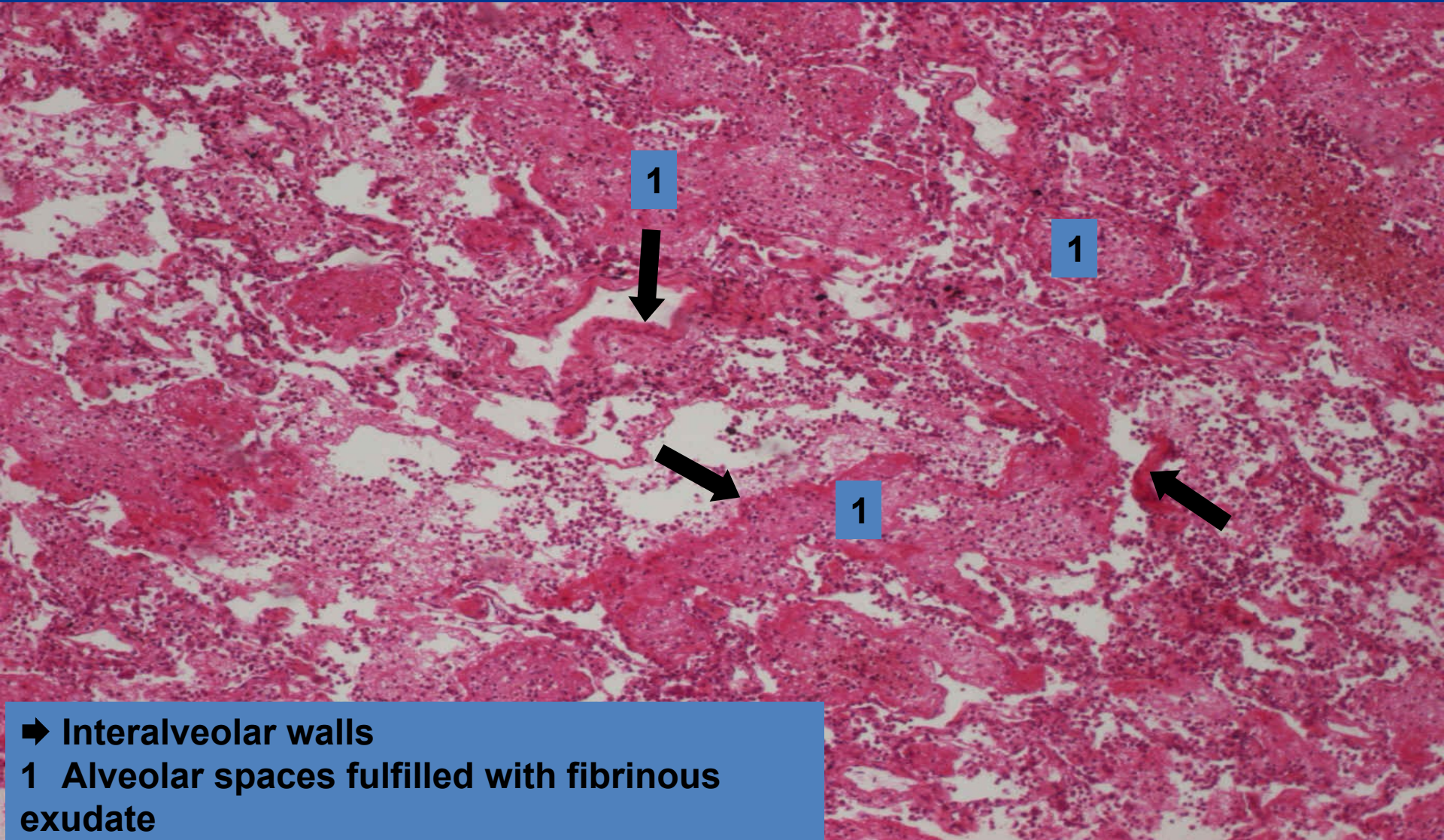
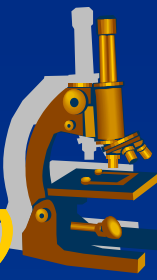
x diphtheric

⇒ *deeper mucosal necrosis, after the pseudomembrane is peeled off »*
ulcus
(*pseudomembranous colitis*)

x escharotic

⇒ *extensive deep necrosis*
(*necrotising tracheitis in flu*)

Lobar pneumonia ***(superficial fibrinous mucosal inflammation)***



1



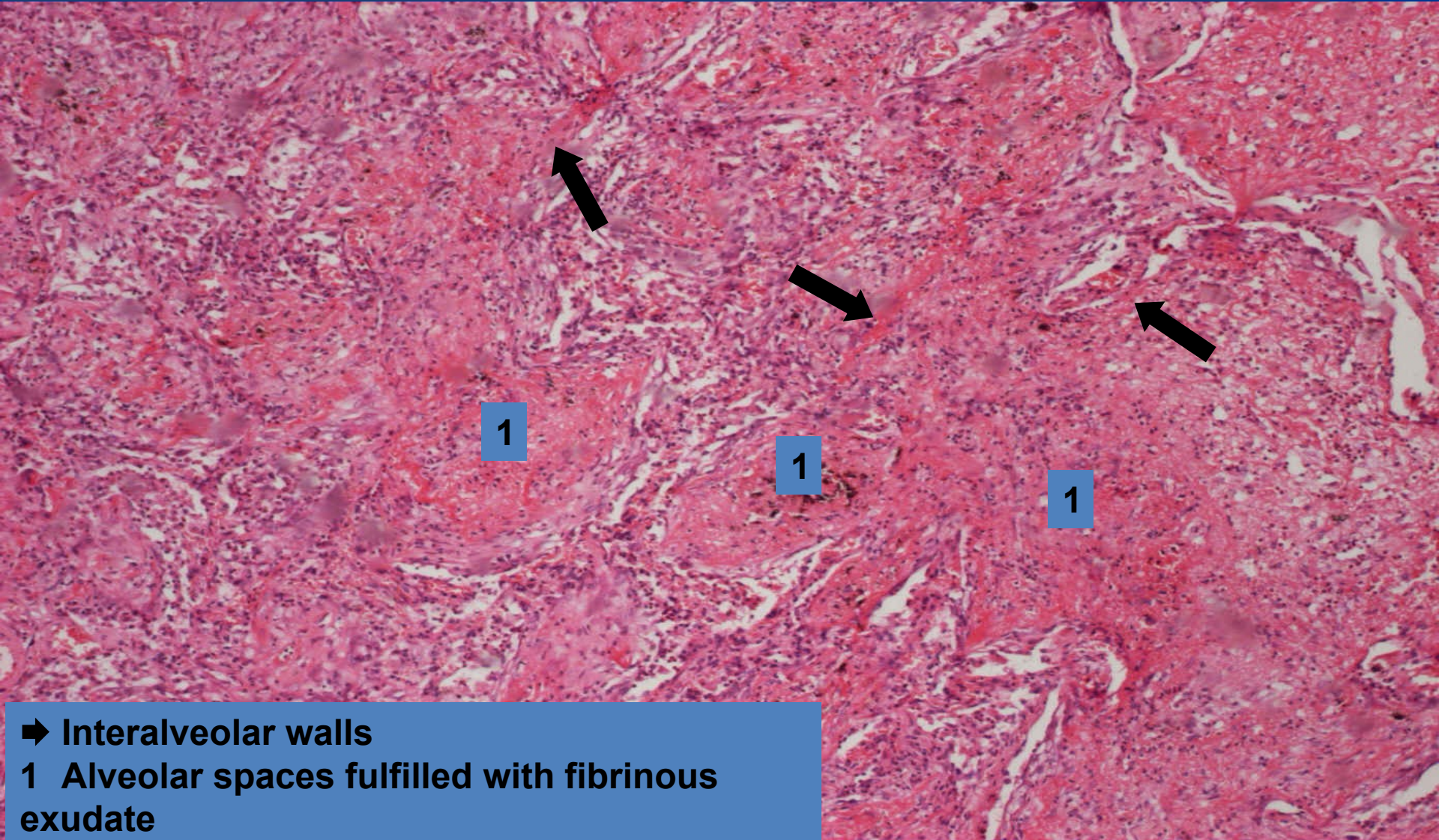
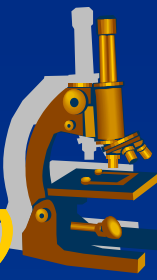
1

1



➔ Interalveolar walls
1 Alveolar spaces fulfilled with fibrinous exudate

Lobar pneumonia ***(superficial fibrinous mucosal inflammation)***

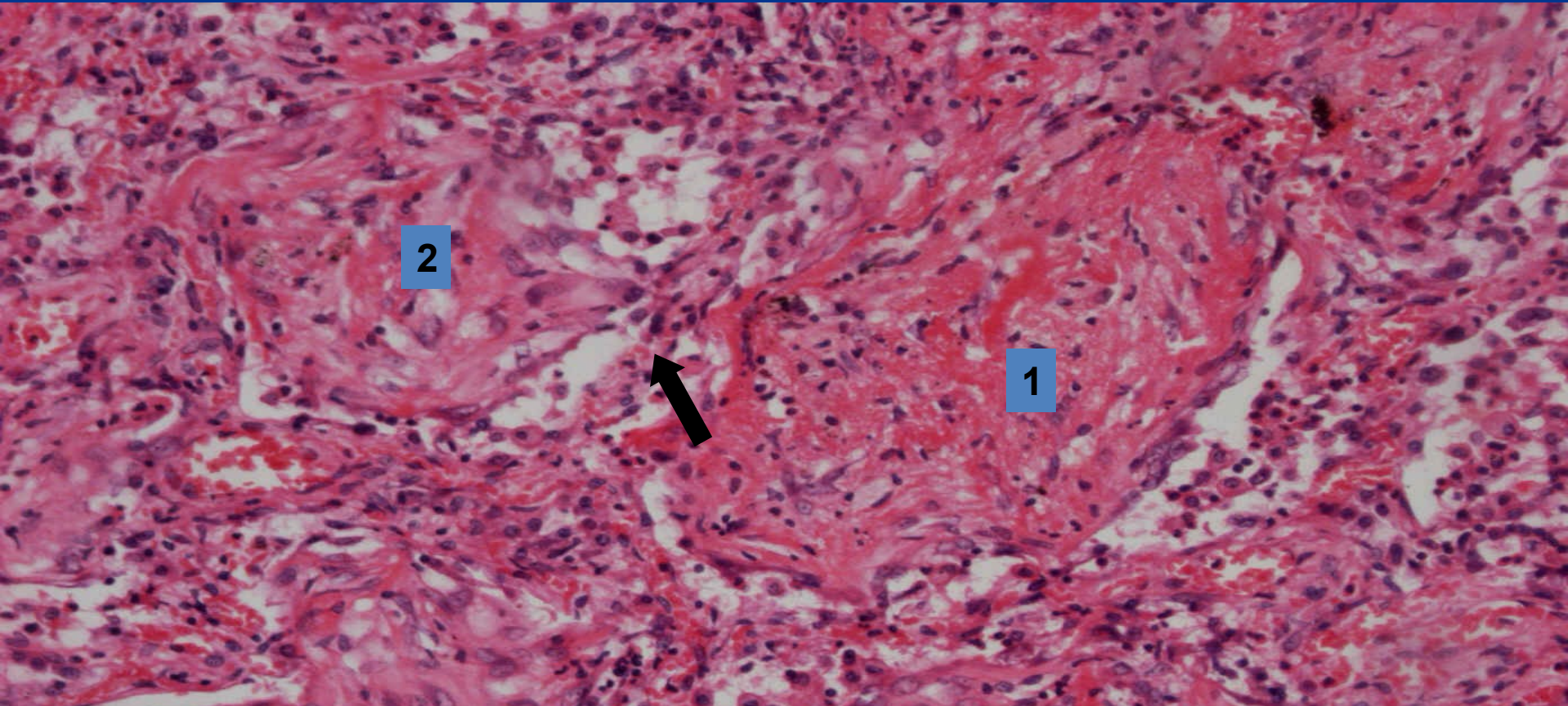
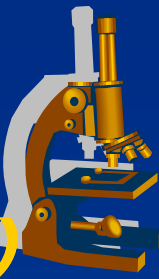


➡ Interalveolar walls

1 Alveolar spaces fulfilled with fibrinous exudate

Lobar pneumonia - detail

(superficial fibrinous mucosal inflammation)



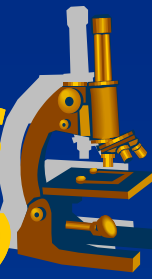
2

1

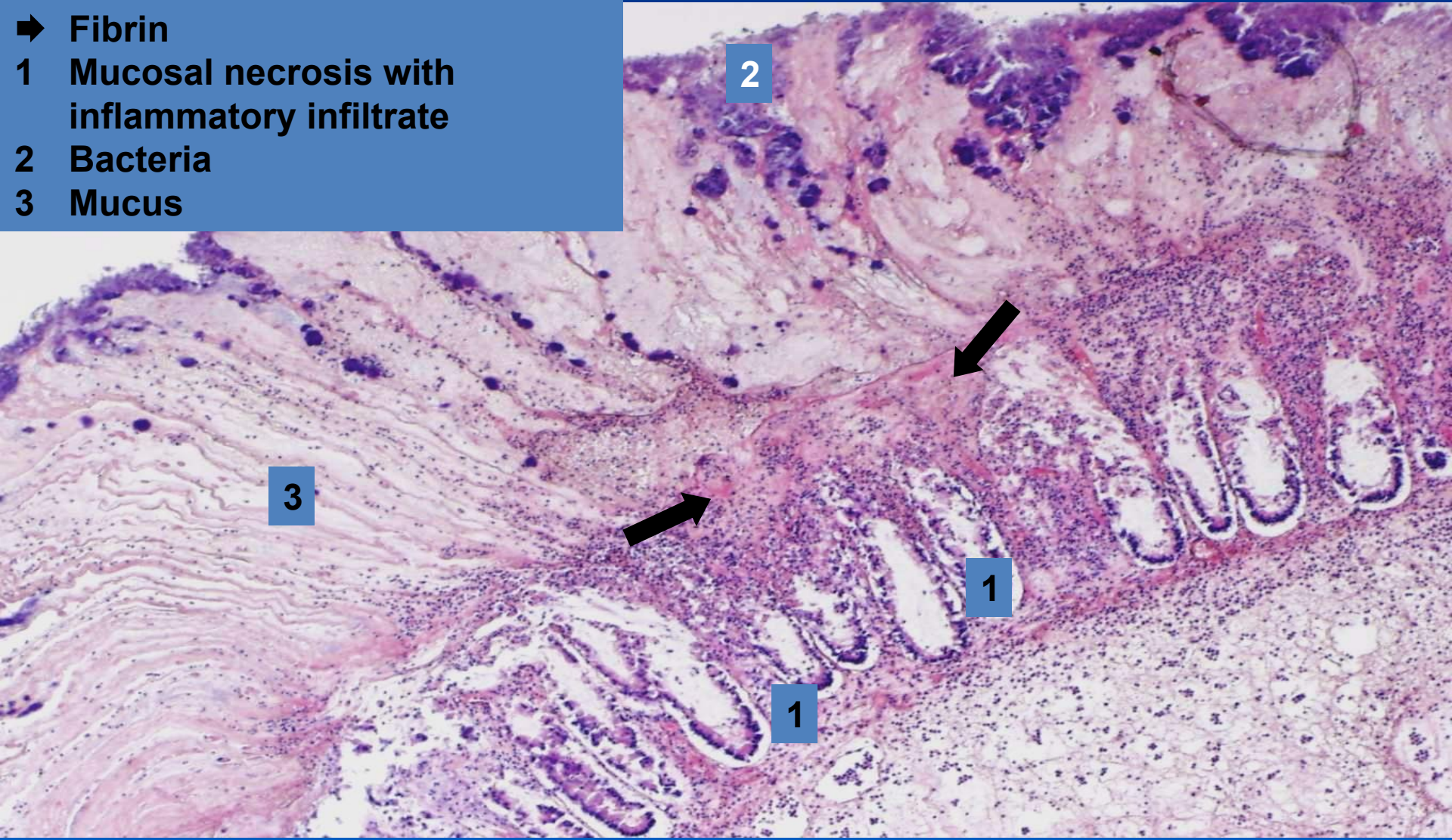


- ➔ Interalveolar wall
- 1 Croupous (fibrinous) exudate
- 2 Fibrinous exudate with fibroblasts (beginning of organization)

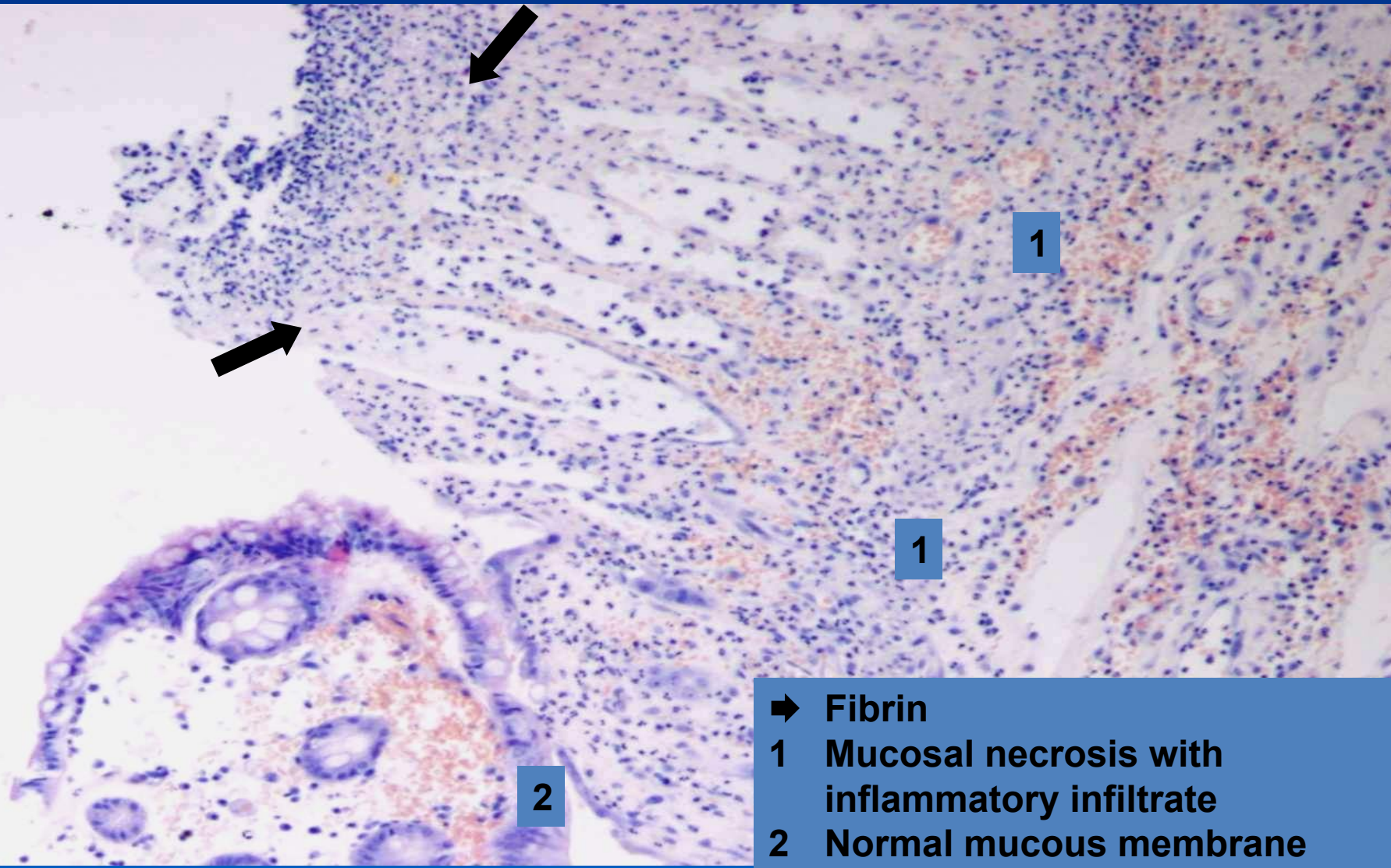
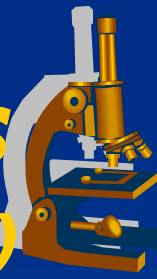
Pseudomembranous colitis ***(superficial fibrinous mucosal inflammation)***



- ➔ Fibrin
- 1 Mucosal necrosis with inflammatory infiltrate
- 2 Bacteria
- 3 Mucus



Pseudomembranous colitis ***(superficial fibrinous mucosal inflammation)***



- ➔ Fibrin
- 1 Mucosal necrosis with inflammatory infiltrate
- 2 Normal mucous membrane

Rheumatic fever



- ✗ Relapsing inflammatory disease esp. in children (1-5 weeks after streptococcal A infection)
- ✗ forming of antibodies cross-reactive with antigens in the heart, joints...
- ✗ dg. based on anamnesis and 2 of 5 main (Jones) criteria:
 - erythema marginatum, chorea, carditis, subcutaneous nodules, migratory polyarthritits of the large joints*

Rheumatic fever



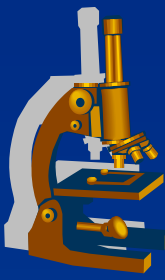
xGROSS:

- ⇒ **vegetations** - (friable, bulky, wart-like outgrowths) on the edges of the heart valves (mainly aortic and mitral)
- ⇒ after years leaflet thickening and commissural fusion
- ⇒ thickening, shortening and fusion of the chordae tendinae

xMICRO:

- ⇒ **Aschoff bodies** – inflammatory lesion within the heart
- ⇒ fibrinoid necrosis of fibrous tissue
- ⇒ central zone of degenerating with surrounding chronic inflammatory infiltrate (lymphocytes, plasma cells, histiocytes, activated macrophages called Antischkow cells)

Exudative inflammation



x purulent:

⇒ **PRODUCTION OF PUS:**

neutrophil-rich exudate

⇒ **GROSS:**

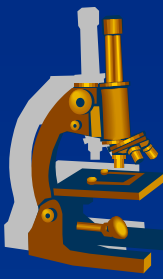
superficial pus, pus accumulation (abscess)

⇒ *heals by inhibition of exudation and/or by proliferative inflammation*

⇒ *examples:*

- **superficial inflammation of meninges:**
 - purulent meningitis
- **superficial mucosal inflammation:**
 - catarrhal-purulent bronchopneumonia
- **deep (interstitial):**
 - phlegmona (e.g. phlegmonous appendicitis)
 - abscess

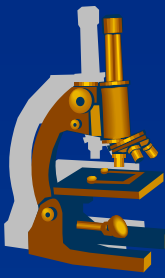
Purulent leptomeningitis



Aetiology:

- ✗ *Escherichia coli* and β streptococci
 - ⇒ *in newborns*
- ✗ *Haemophilus influenzae*
 - ⇒ *in infants and children*
- ✗ *Neisseria meningitis*
 - ⇒ *in adolescents and young adults*
- ✗ *Streptococcus pneumoniae* and *Listeria monocytogenes*
 - ⇒ *in old people*

Purulent leptomeningitis



SYMPTOMS:

x meningeal irritation:

⇒ *headache, photophobia, irritation, nuchal rigidity, consciousness failures*

x lumbar puncture:

⇒ *opaque or purulent liquor with higher CSF pressure*

Purulent leptomeningitis

MORPHOLOGY



x GROSS:

- ⇒ *congested and leaked pia mater with pus*
- ⇒ *purulent-opaque liquor*

x MICRO:

- ⇒ *meninges infiltrated with neutrophils*
- ⇒ *vessels congested with blood, thrombosis » hemorrhagic brain infarction*

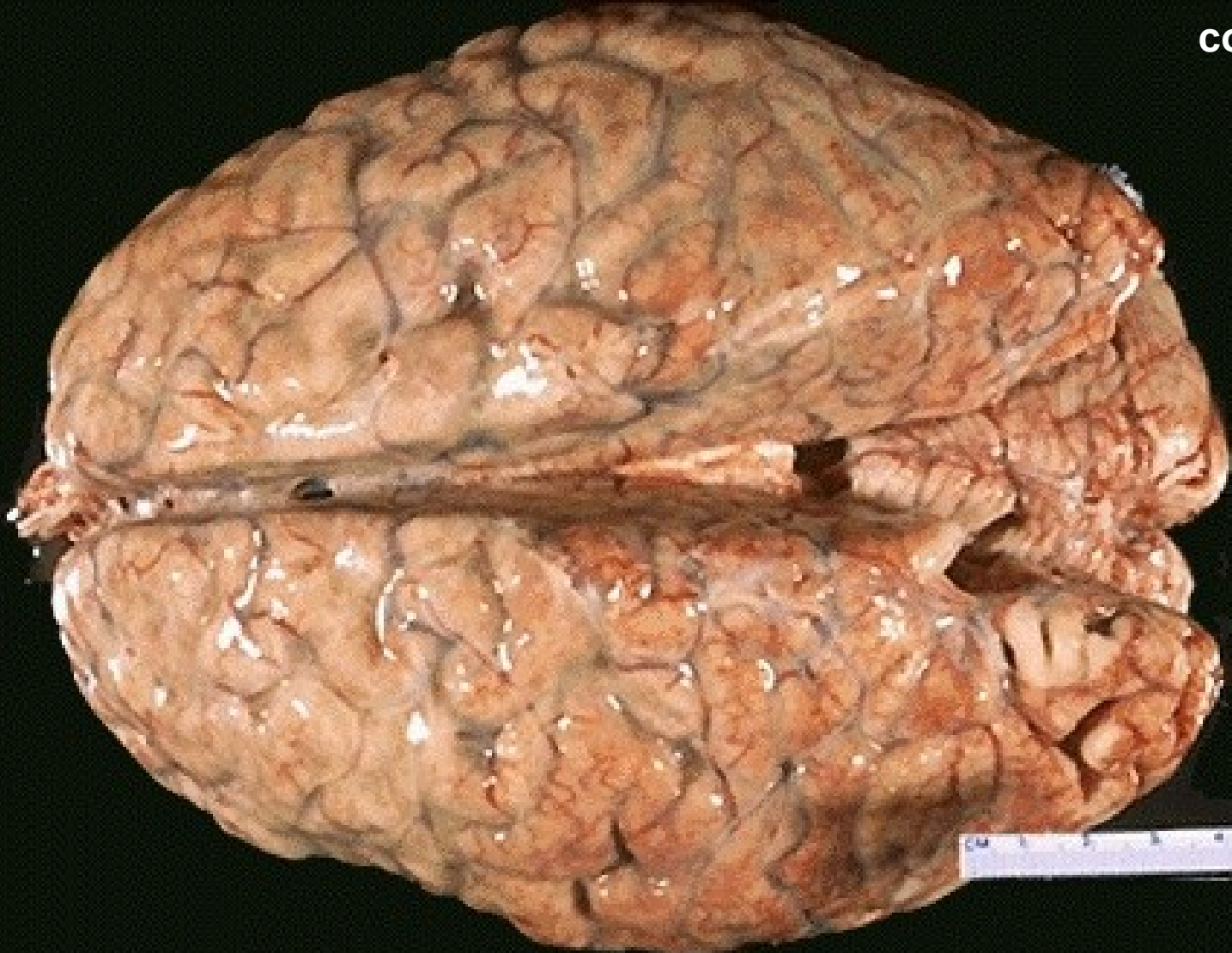x COMPLICATIONS:

*possible fibrosis of meninges resulting in hydrocephalus;
epilepsy*

Purulent leptomeningitis ***(superficial purulent inflammation)***

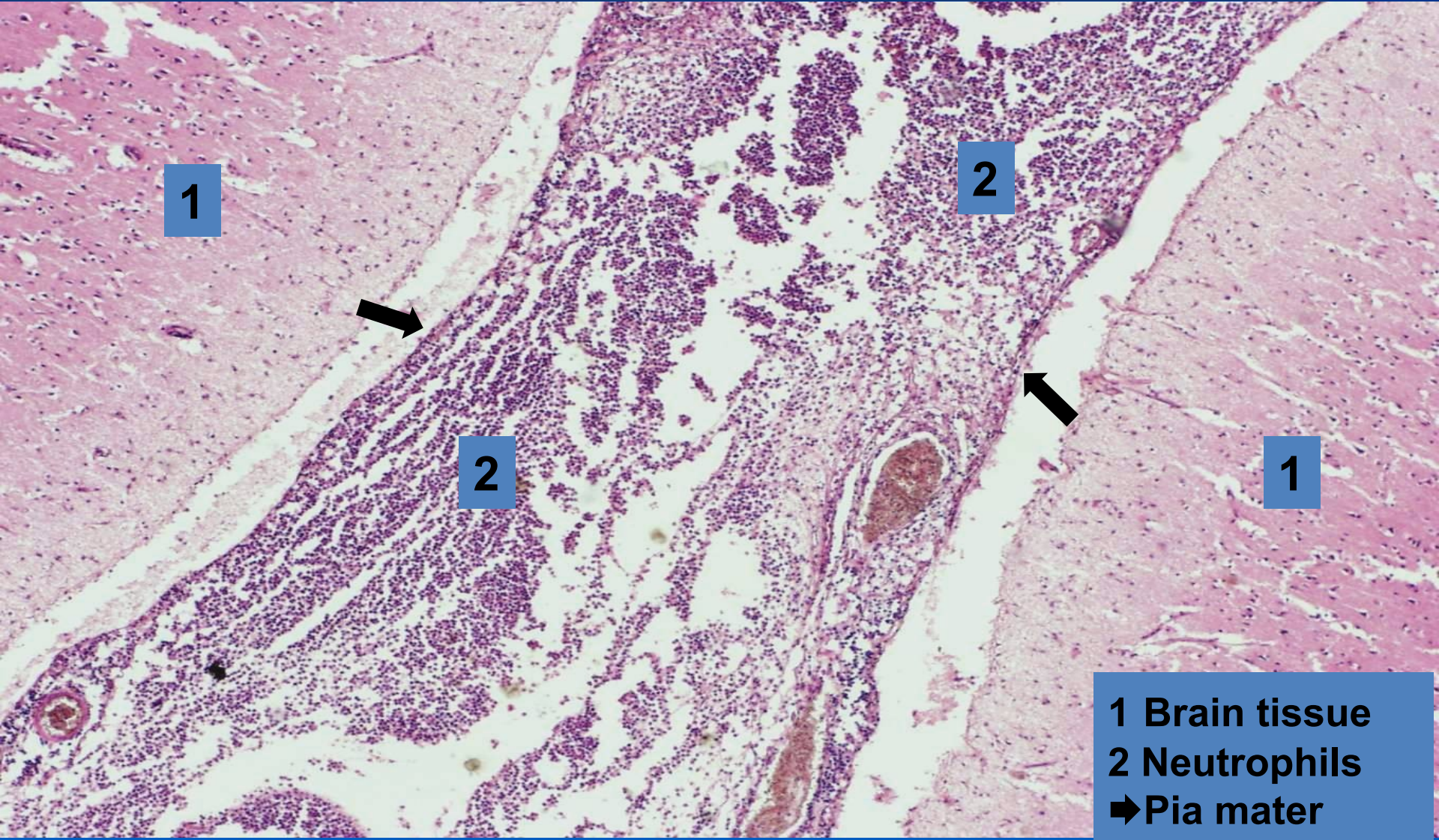


copy



Purulent leptomeningitis

(superficial purulent inflammation)



1

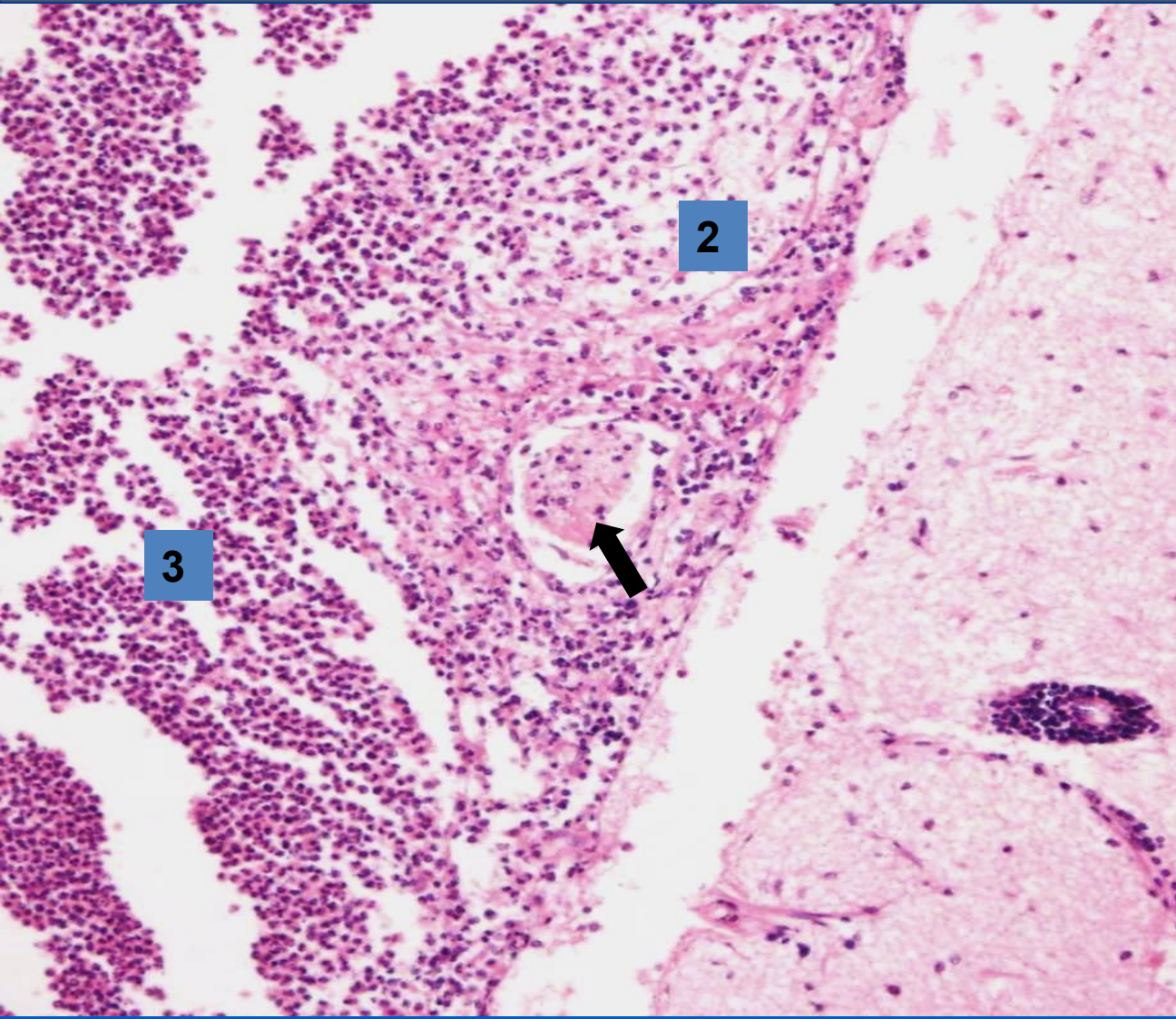
2

2

1

1 Brain tissue
2 Neutrophils
➔ Pia mater

Purulent leptomeningitis ***(superficial purulent inflammation - detail)***



- 1 Brain cortex
- 2 Pia mater with purulent infiltrate
- 3 Neutrophils
- ➔ Arteriole in pia mater

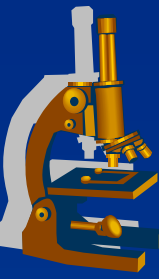
3

2

1

Bronchopneumonia

(Superficial purulent mucosal inflammation)



x GROSS:

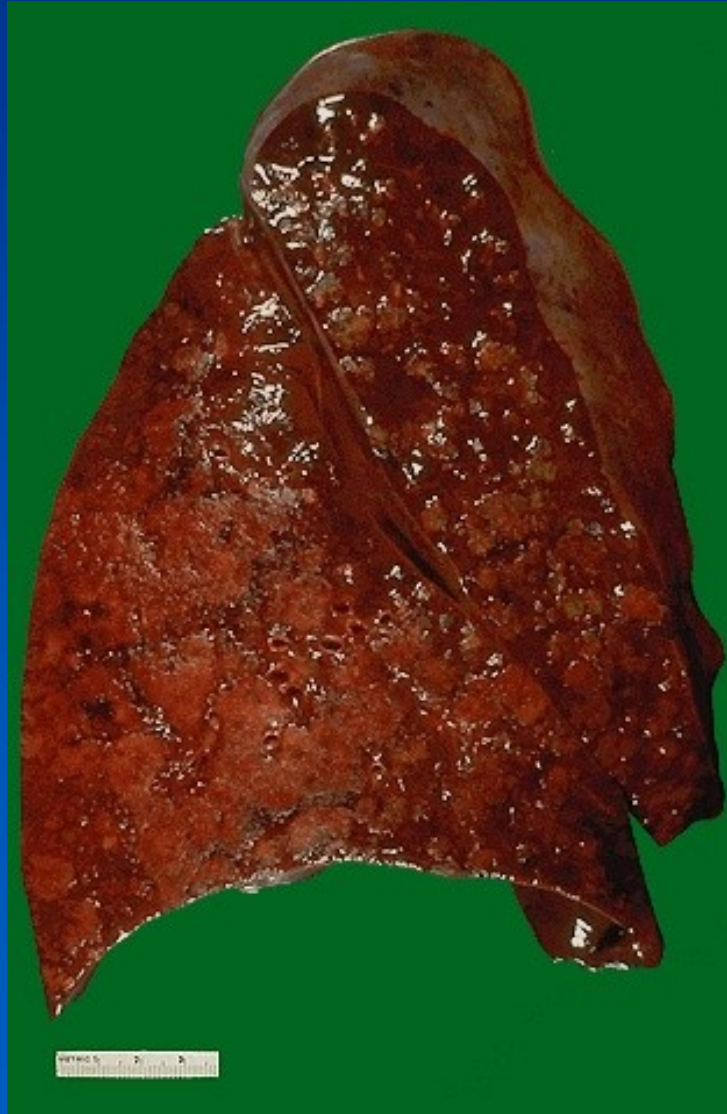⇒ *various stages of inflammation in the lung at the same time*

x MICRO:

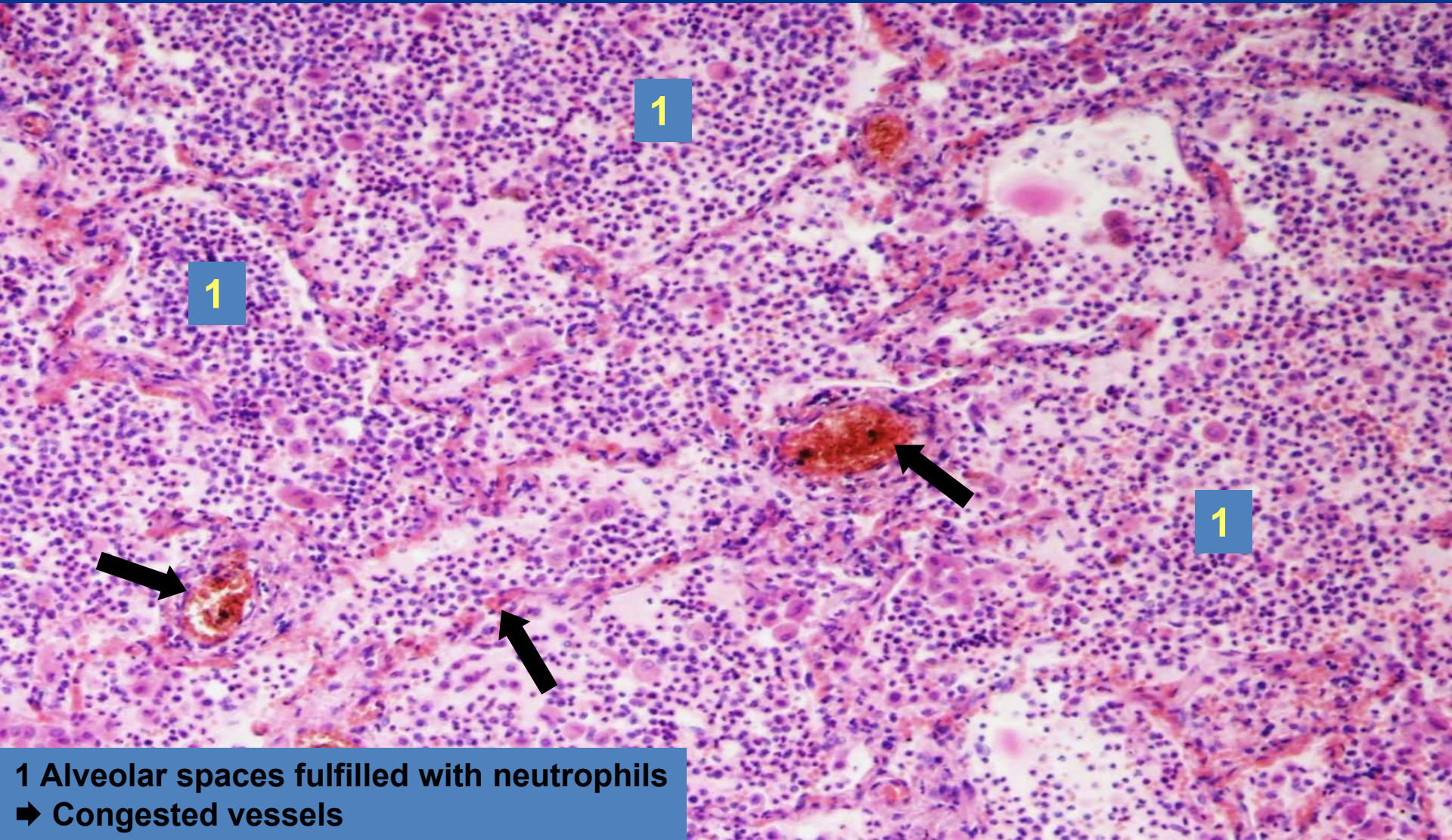
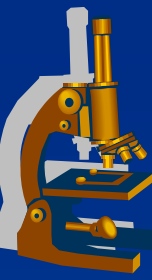
⇒ *alveolar spaces fulfilled with neutrophils*

⇒ *small amount of fibrin in the exudate compared to lobar pneumonia*

Bronchopneumonia



Purulent bronchopneumonia ***(superficial purulent mucosal inflammation)***



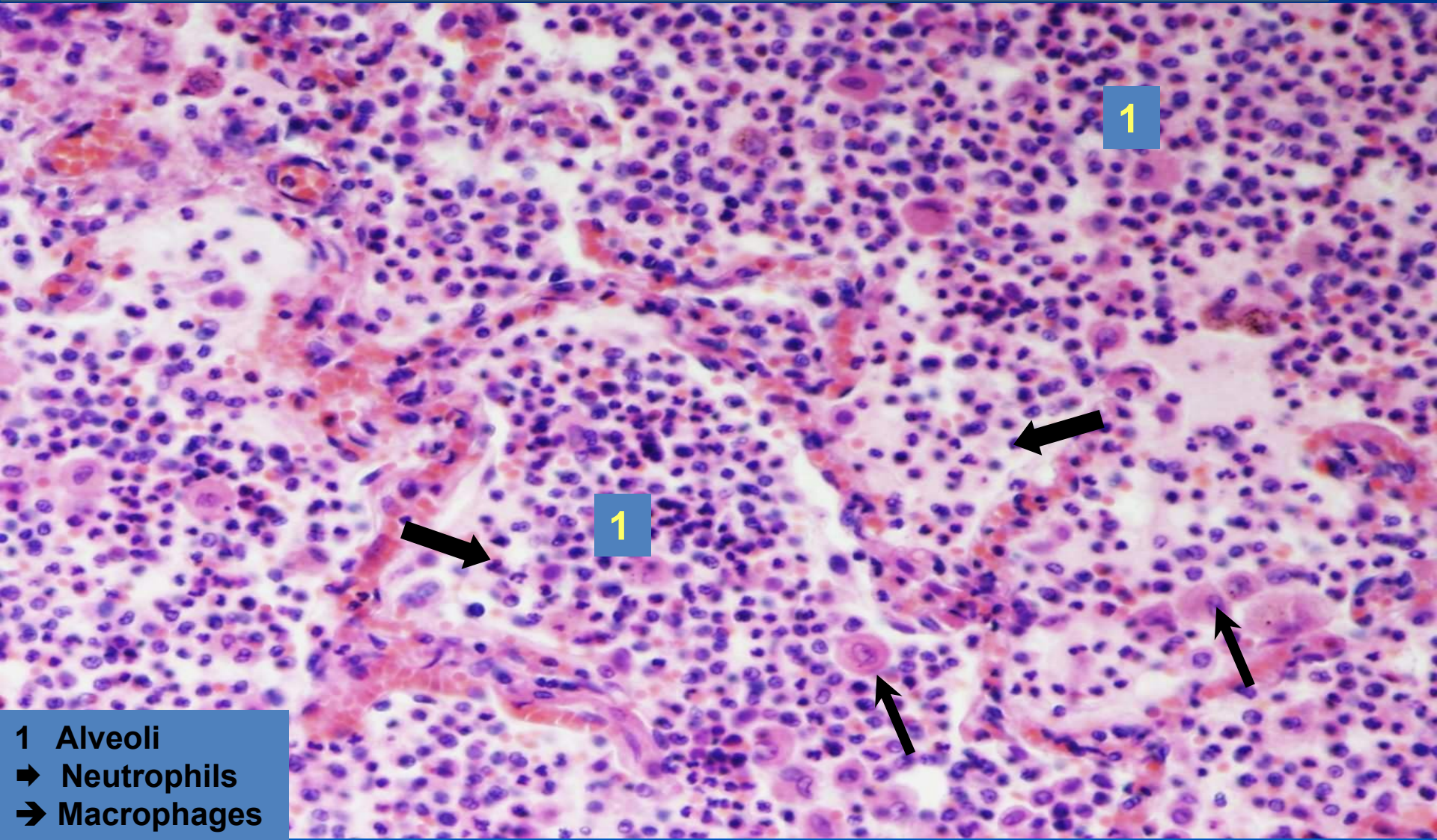
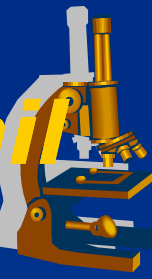
1

1

1

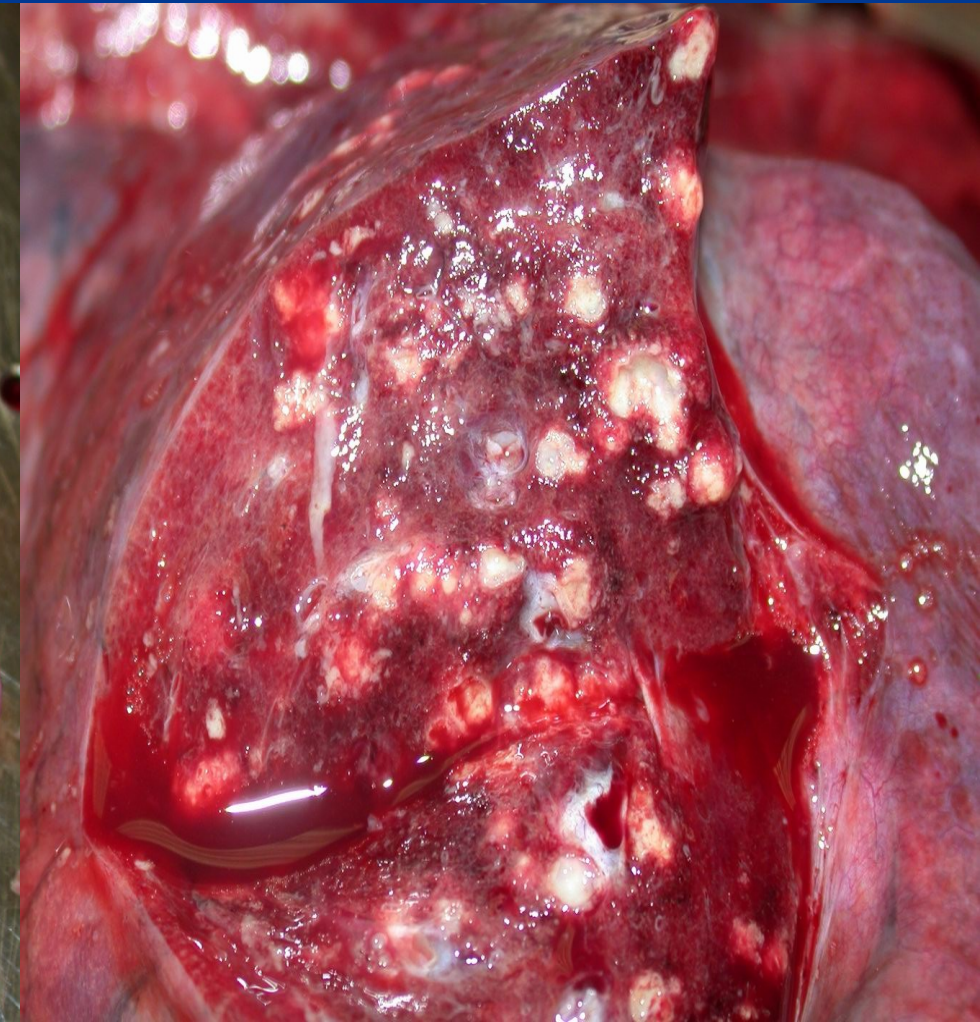
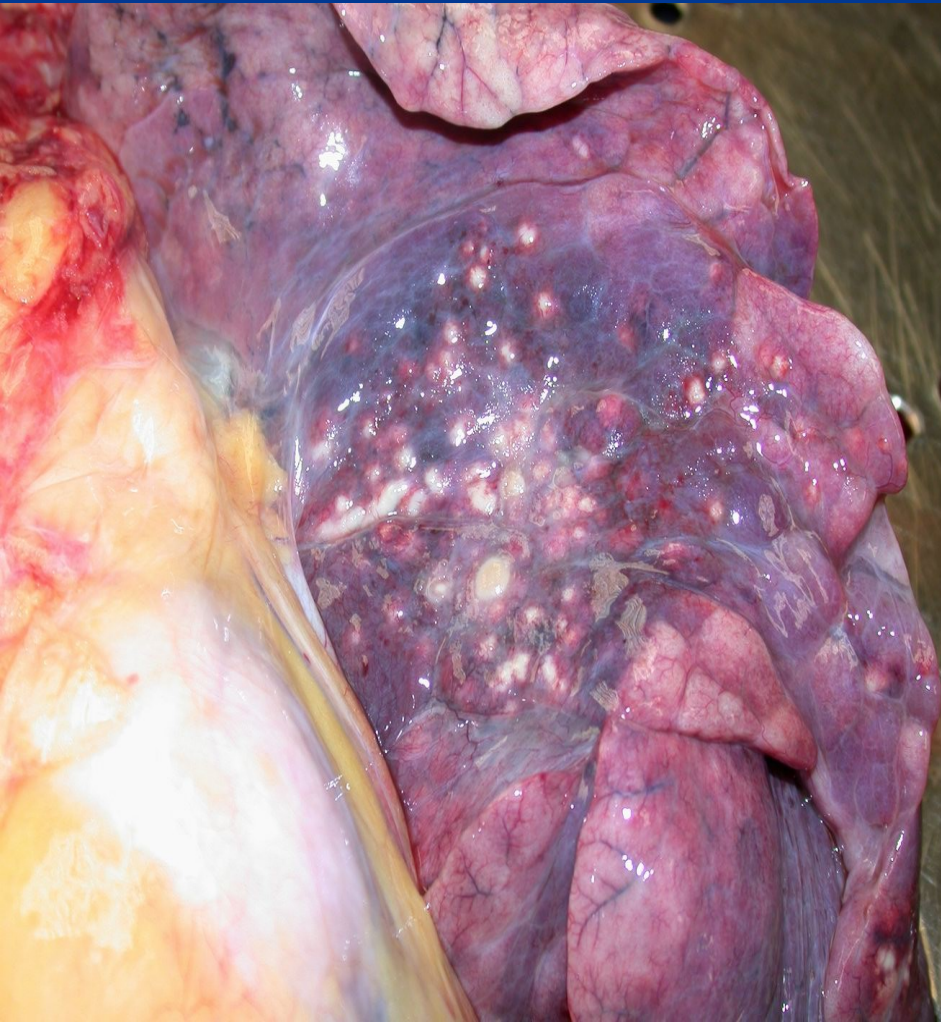1 Alveolar spaces fulfilled with neutrophils
➔ Congested vessels

Purulent bronchopneumonia - detail ***(superficial purulent mucosal inflammation)***

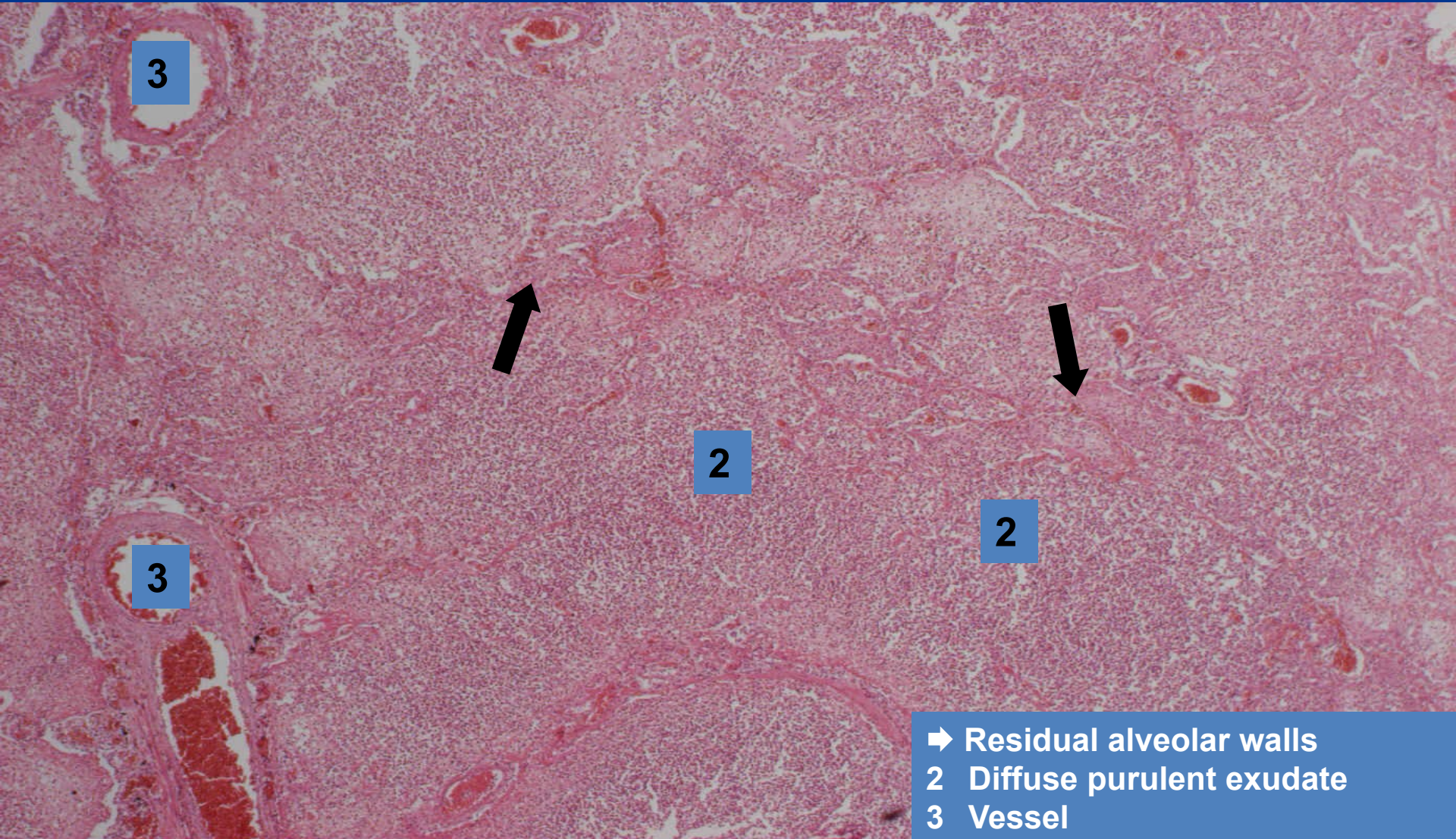
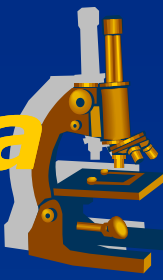

- 1 Alveoli
- ➔ Neutrophils
- ➔ Macrophages

Abscessing bronchopneumonia ***(abscessing purulent inflammation)***

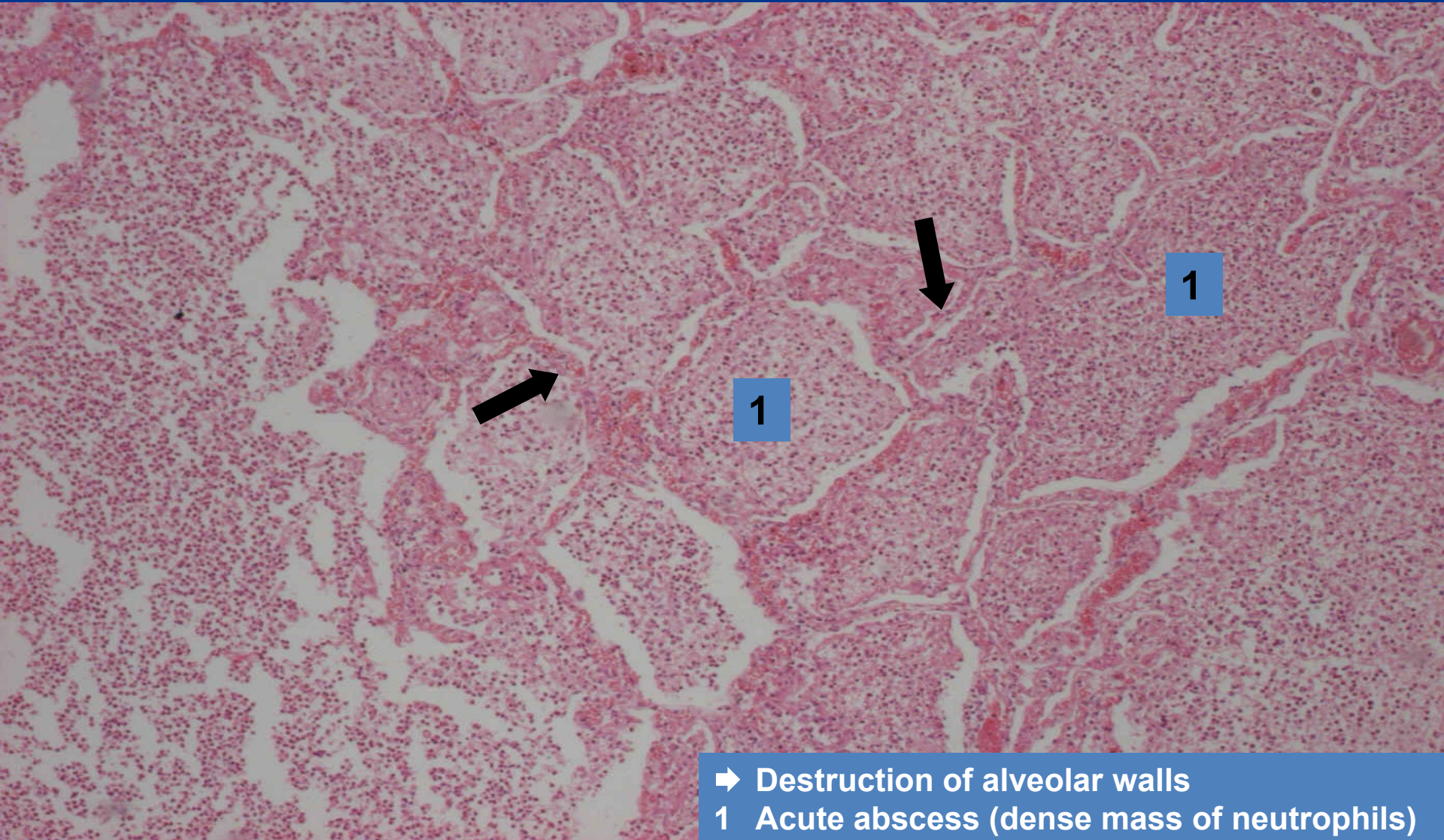

Abscessing bronchopneumonia ***(abscessing purulent inflammation)***



- ➔ Residual alveolar walls
- 2 Diffuse purulent exudate
- 3 Vessel

Abscessing bronchopneumonia ***(abscessing purulent inflammation)***



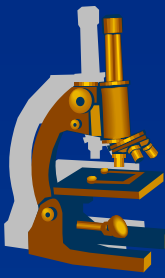
- ➔ Destruction of alveolar walls
- 1 Acute abscess (dense mass of neutrophils)

Phlegmonous appendicitis ***(interstitial purulent inflammation)***



- x** most common cause of „acute abdomen“, surgical intervention necessary.
- x** **CLINICALLY:**
 - ⇒ *in any age, commonly children – young adults.*
 - ⇒ *right mesogastric or hypogastric pain; nausea, vomiting, rectal raised temperature, sensitive abdomen, leukocytosis.*

Phlegmonous appendicitis



x MORPHOLOGY:

⇒ **GROSS:**

- hyperemic serosa, hemorrhage, pus.

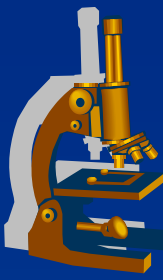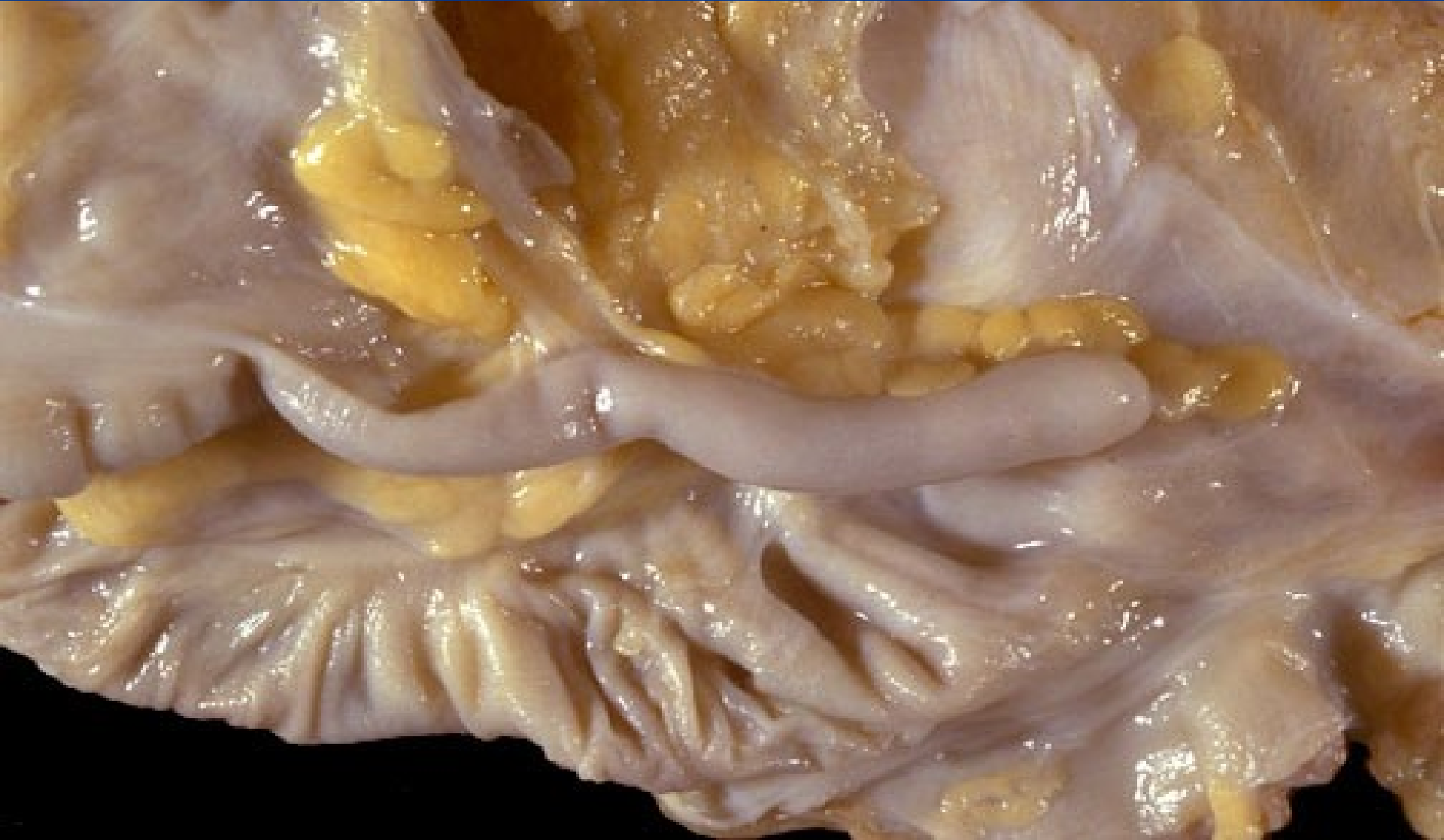
⇒ **MICRO:**

- diffuse interstitial neutrophilic infiltration (phlegmona), purulent periappendicitis.

x COMPLICATIONS:

- ⇒ *perforation, purulent peritonitis, pyelophlebitis, portal thrombosis, pyemia, liver abscessi, sepsis.*

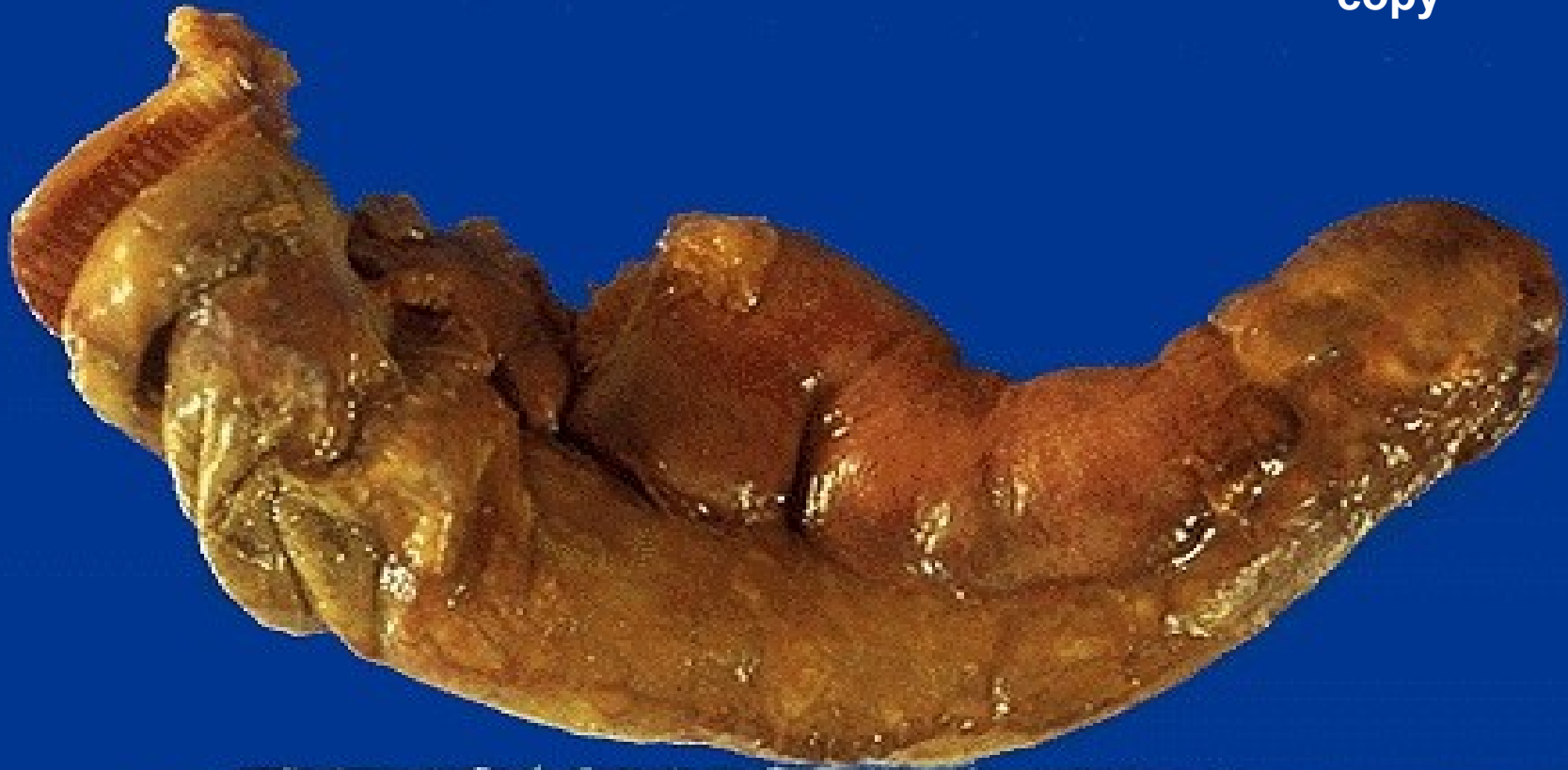Appendix - normal



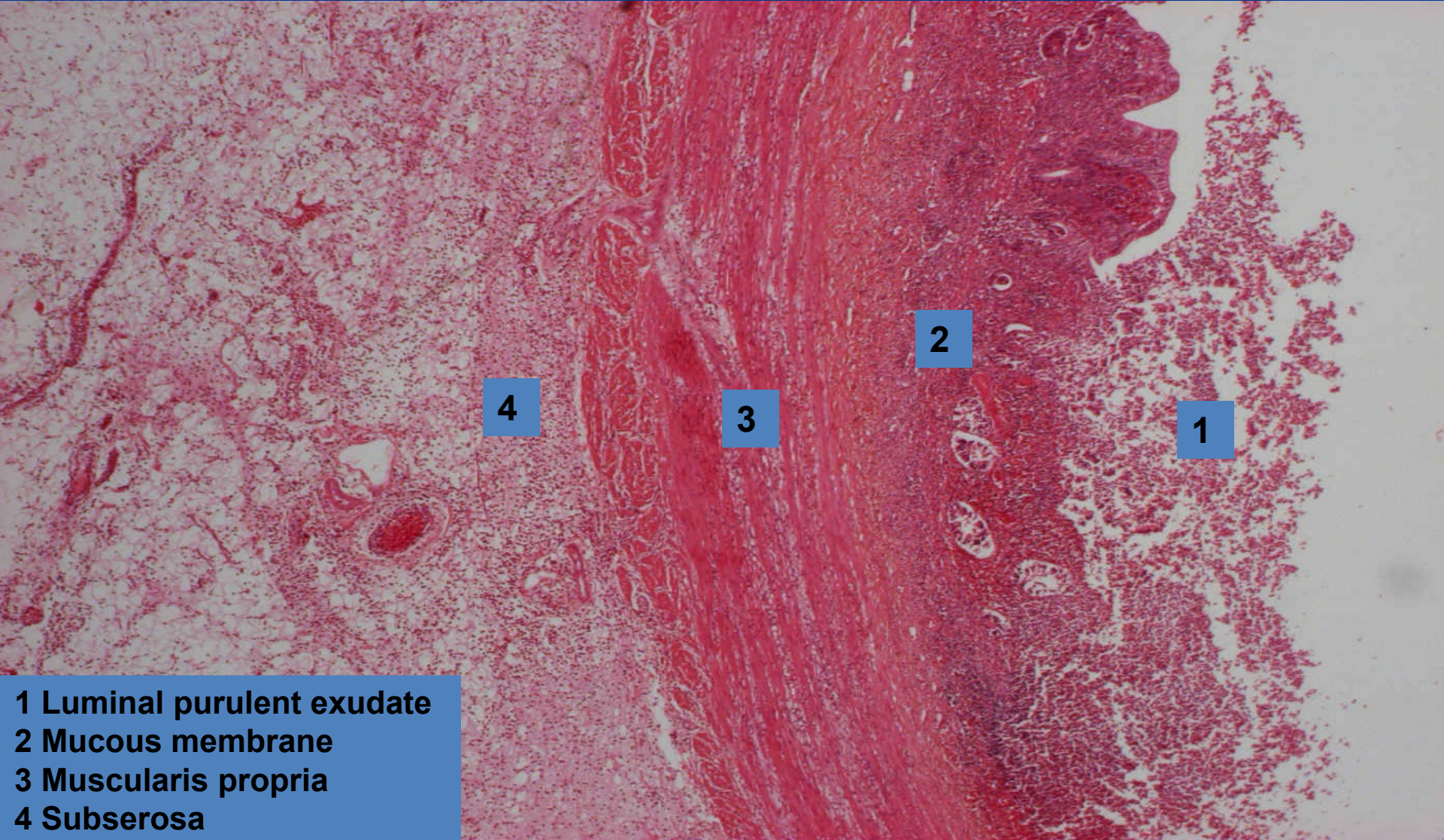
Phlegmonous appendicitis (*interstitial purulent inflammation*)



copy



Phlegmonous appendicitis ***(interstitial purulent inflammation)***



4

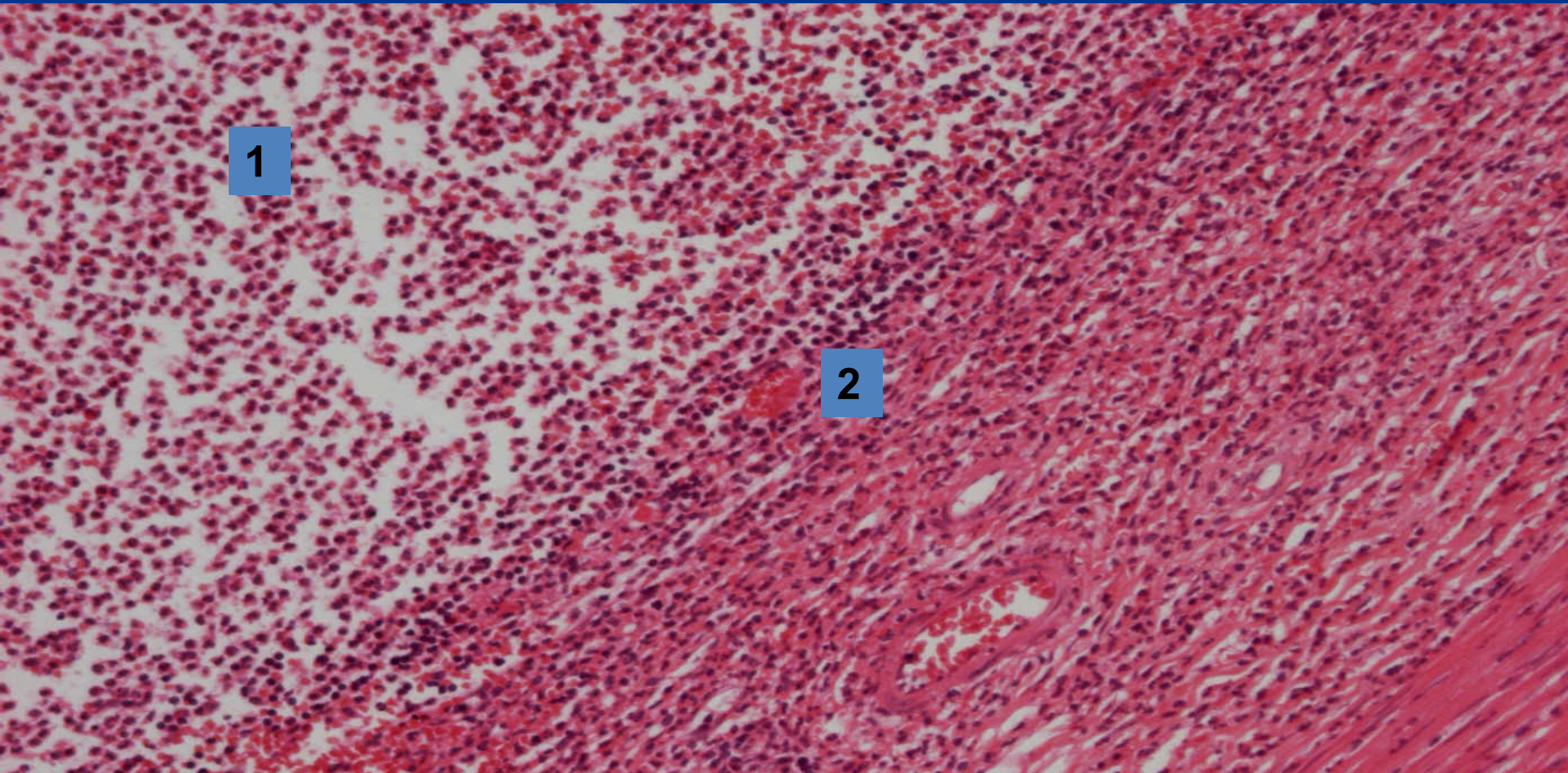
3

2

1

- 1 Luminal purulent exudate
- 2 Mucous membrane
- 3 Muscularis propria
- 4 Subserosa

Phlegmonous appendicitis ***(interstitial purulent inflammation)***



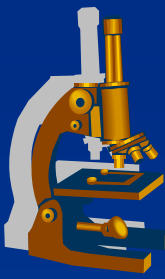
1

2

3

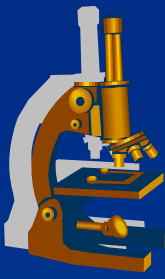
- 1 Luminal purulent exudate
- 2 Mucosa with diffuse neutrophilic infiltration – absence of epithelium
- 3 Muscularis propria

Acute pyelonephritis



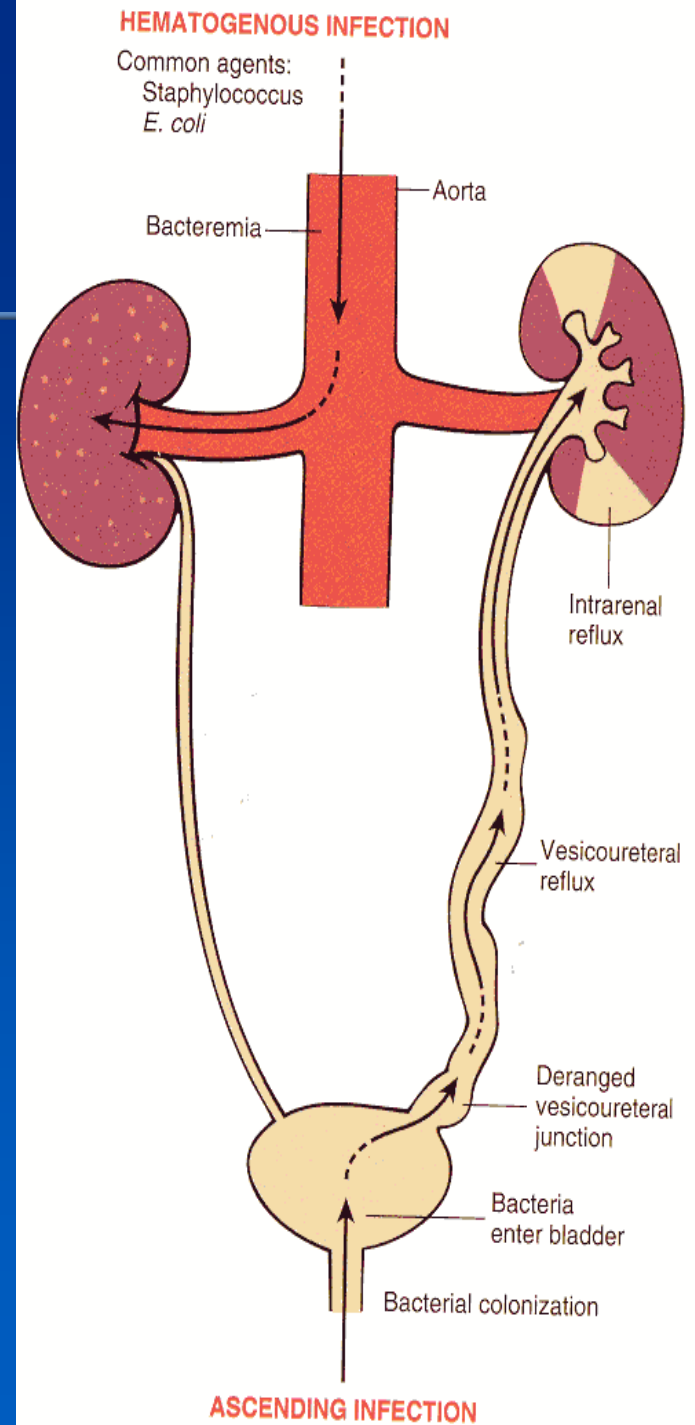
- ✘ Common purulent renal inflammation, bacterial infection by *Escherichia coli*, *Proteus*, *Klebsiella*, *Enterobacter*
- ✘ **Ascending** infection by urine reflux in urinary tract inflammation
- ✘ **Descending (haematogenous)** infection in septicaemia, rare

Acute pyelonephritis

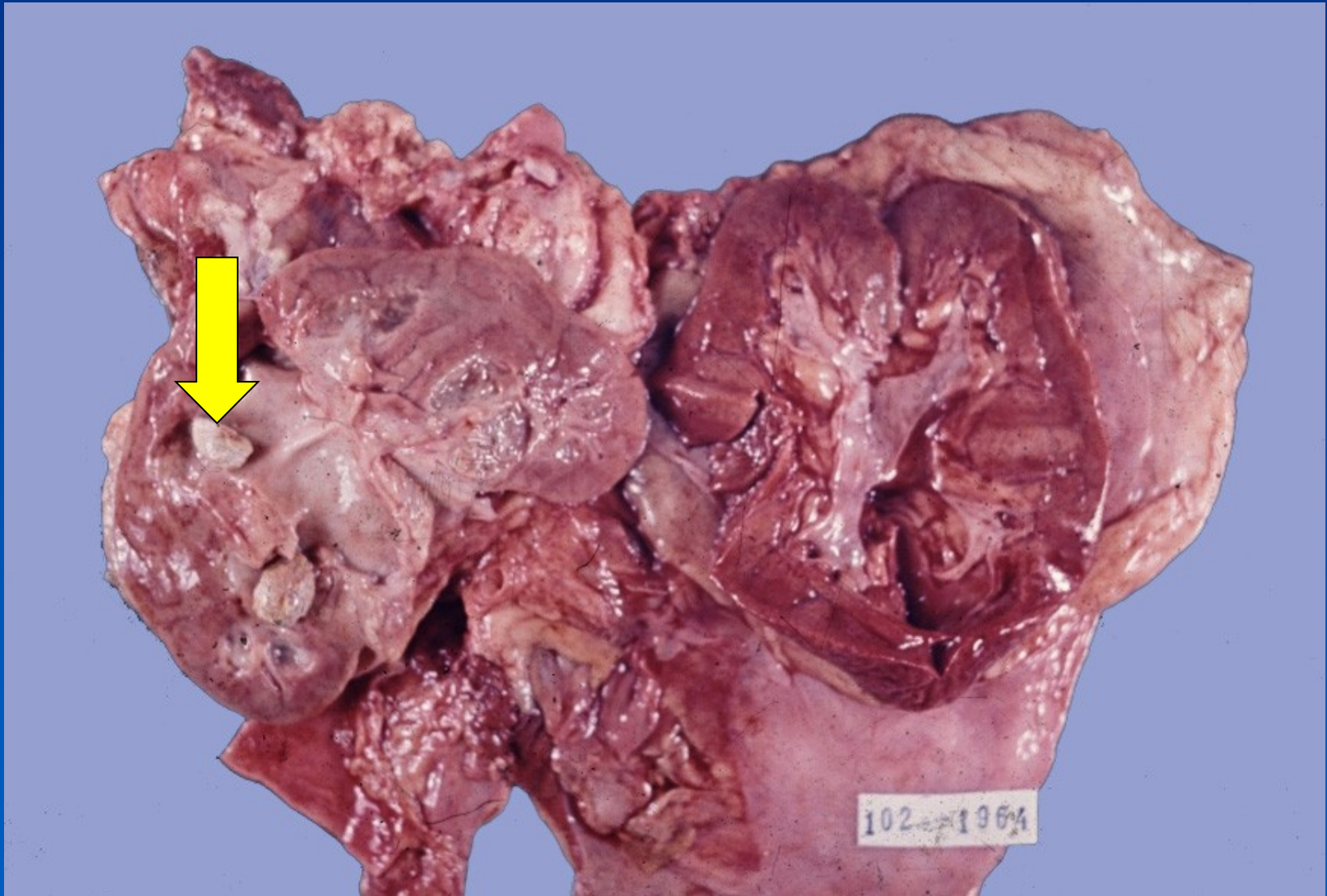


- ✗ Facilitated by DM, gout, all causes of obstructive uropathy (e.g. nephrolithiasis, tumors, urinary tract anomalies incl. vesicoureteric and intrarenal reflux)
- ✗ Instrumental interventions (cathetrization, cystoscopy)
- ✗ GROSS:
 - ⇒ *enlarged kidney, cortical and medullary abscesses*
- ✗ MICRO:
 - ⇒ *purulent neutrophilic exudate in tubules and interstitium, oedema*

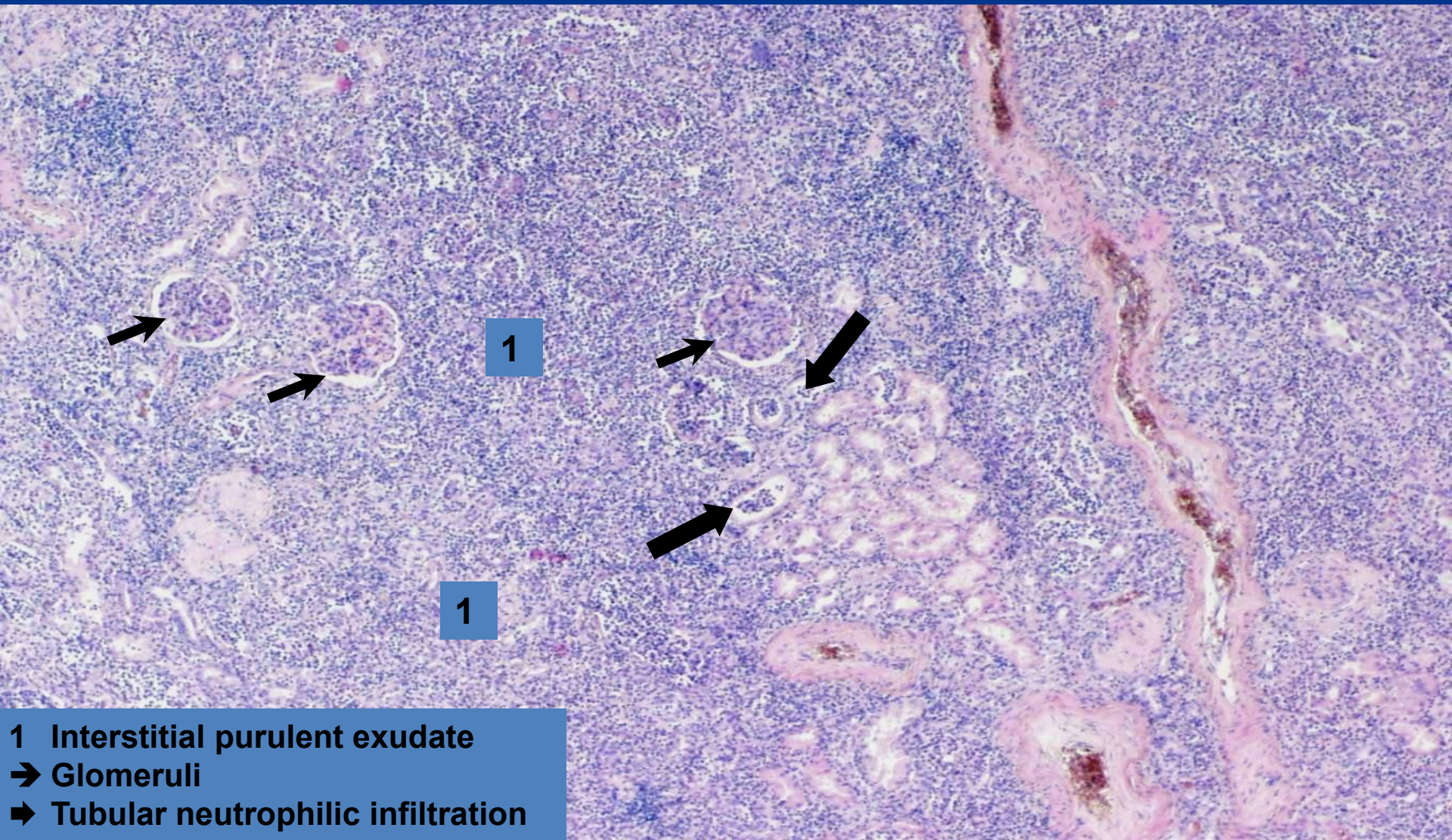
Acute pyelonephritis



Acute pyelonephritis with nephrolithiasis

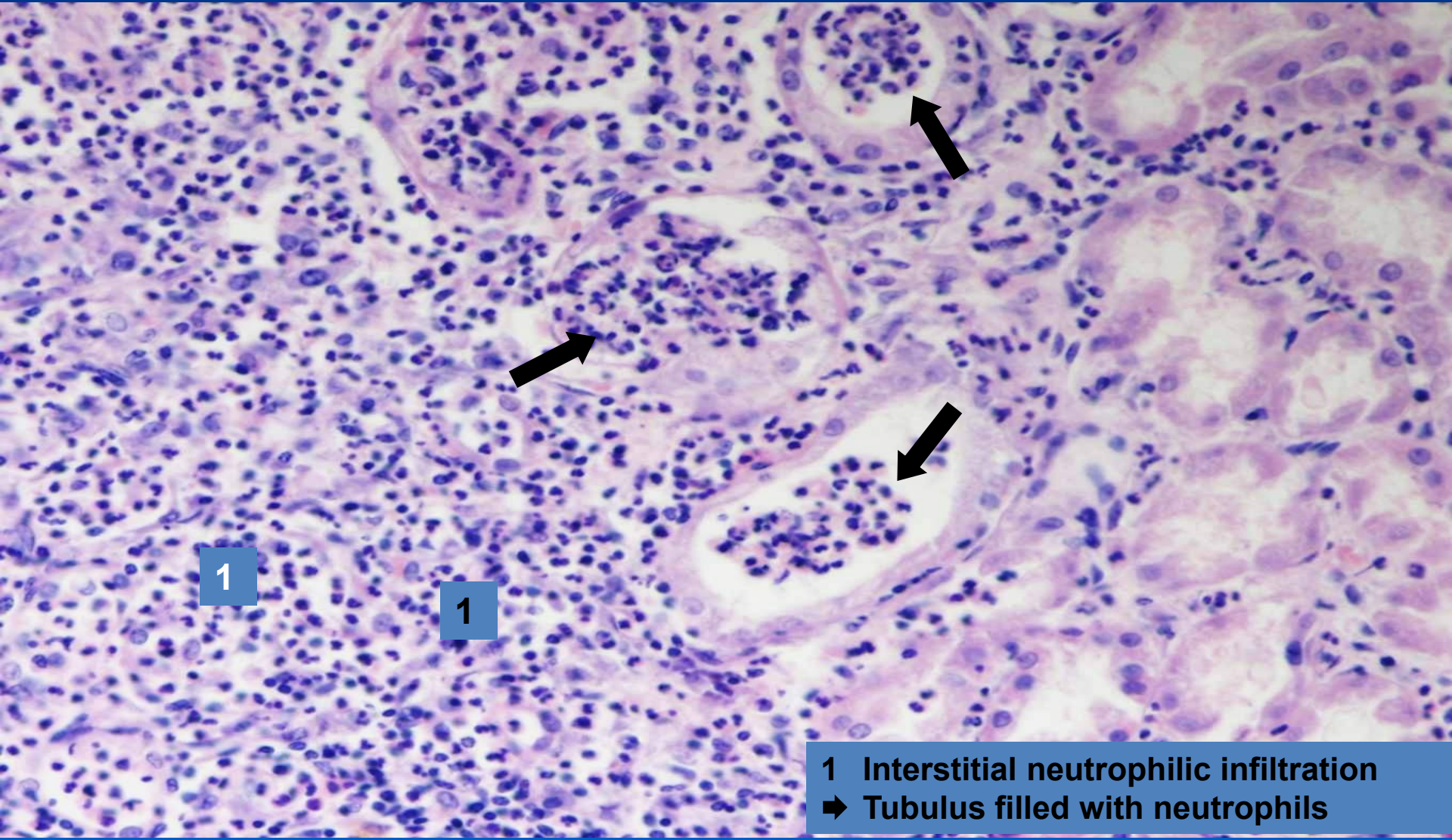


Purulent pyelonephritis ***(interstitial purulent inflammation)***



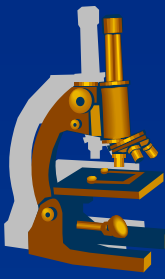
- 1** Interstitial purulent exudate
- Glomeruli
- ➔** Tubular neutrophilic infiltration

Purulent pyelonephritis ***(interstitial purulent inflammation)***



- 1 Interstitial neutrophilic infiltration
- ➔ Tubulus filled with neutrophils

Exudative inflammation



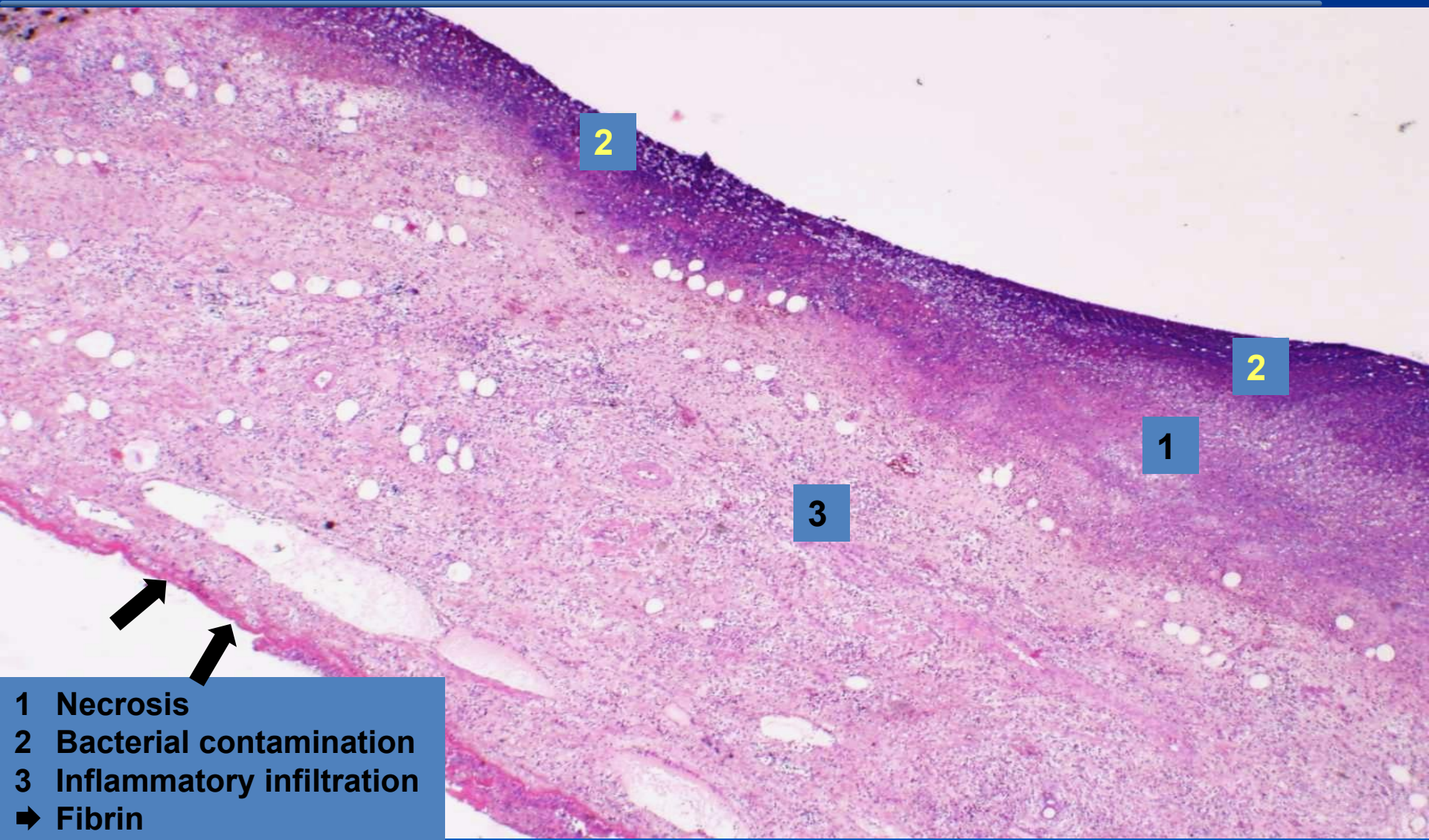
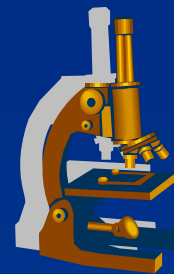
x gangrenous:

⇒ ***necrosis modified with putrid bacteria***

⇒ ***examples:***

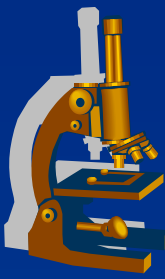
- gangrenous cholecystitis

Gangrenous cholecystitis ***(gangrenous inflammation)***



- 1 Necrosis
- 2 Bacterial contamination
- 3 Inflammatory infiltration
- ➔ Fibrin

Exudative inflammation



x non-purulent:

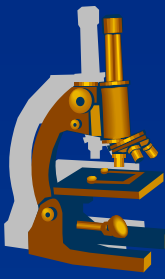
⇒ ***exudate made by chronic inflammatory cells***

(lymphocytes, plasma cells = mononuclear inflammatory infiltration)

⇒ ***examples:***

- **interstitial pneumonia**
- **Hashimoto`s lymphocytic thyreoiditis**

Primary (atypical) interstitial pneumonia



x etiology:

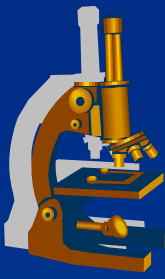
- ⇒ *viral (influenza A, B; RSV, adenoviruses, rhinoviruses, HSV, CMV)*
- ⇒ *small bacteria (Mycoplasma pneumoniae)*
- ⇒ *fungi (Pneumocystis carinii).*

x symptoms:

- ⇒ *fever, dyspnoea, dry cough, auscultation may be normal (empty alveoli), x massive changes on X-ray*

x possible in normal hosts, more common in immunosuppressed

Primary (atypical) interstitial pneumonia



x GROSS:

⇒ *focal or diffuse regions of hyperaemia, in fulminant cases with consolidation (ARDS – adult respiratory distress syndrome).*

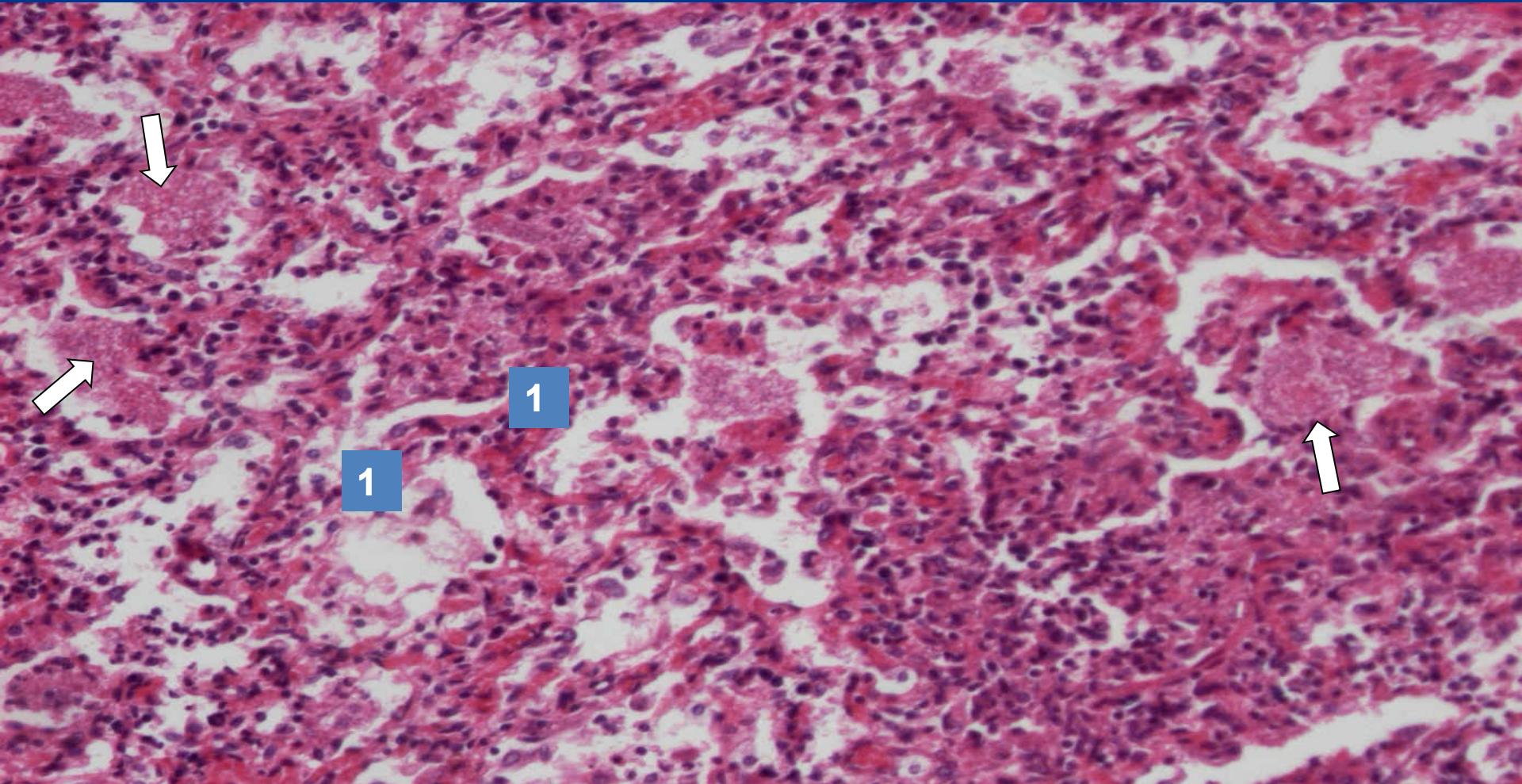
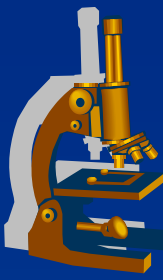
x MICRO:

⇒ *interstitial pneumonitis - oedematous septa with mononuclear infiltrate.*

⇒ *hyaline membranes (ARDS)*

⇒ *common secondary bacterial infection*

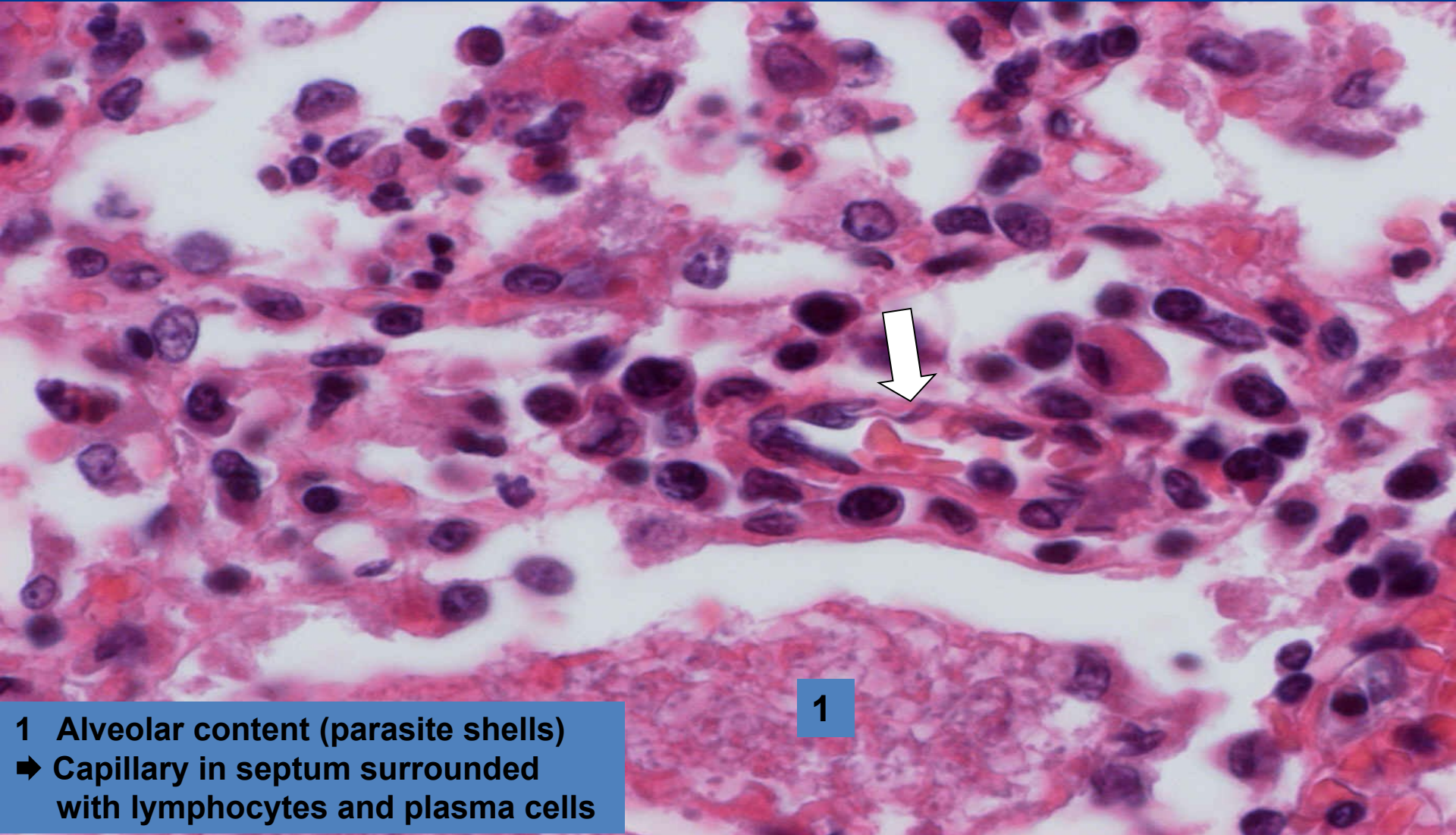
Interstitial pneumocystic pneumonia *(non-purulent inflammation)*



1 Alveolar septa filled with mononuclear infiltration
➔ Alveolar content (parasite shells)

Interstitial pneumocystic pneumonia - detail

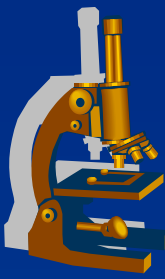
(non-purulent inflammation)



1

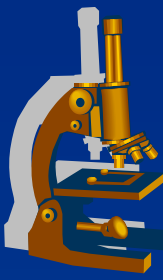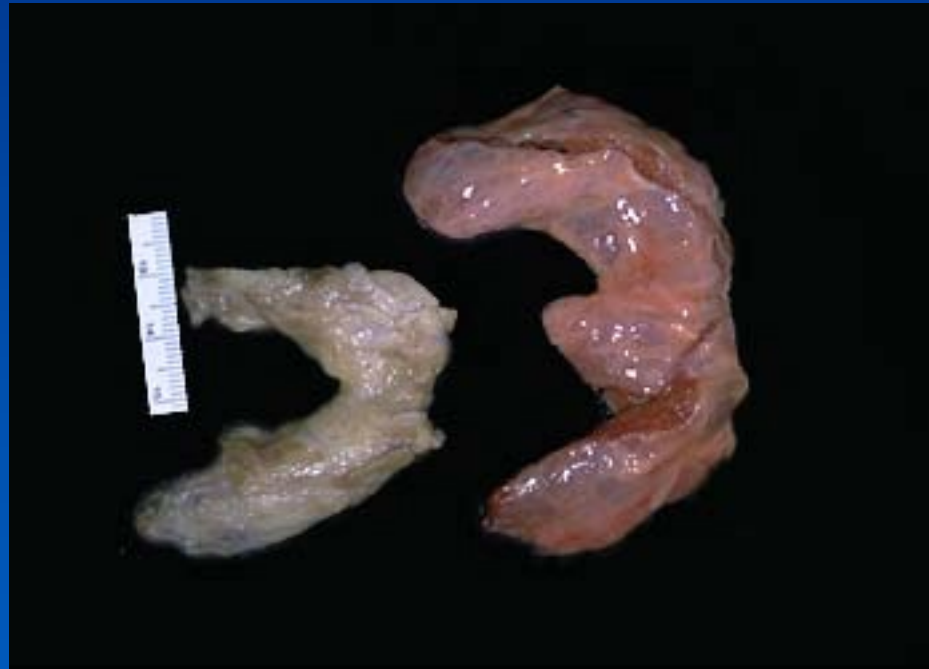
1 Alveolar content (parasite shells)
➔ Capillary in septum surrounded
with lymphocytes and plasma cells

Hashimoto thyroiditis



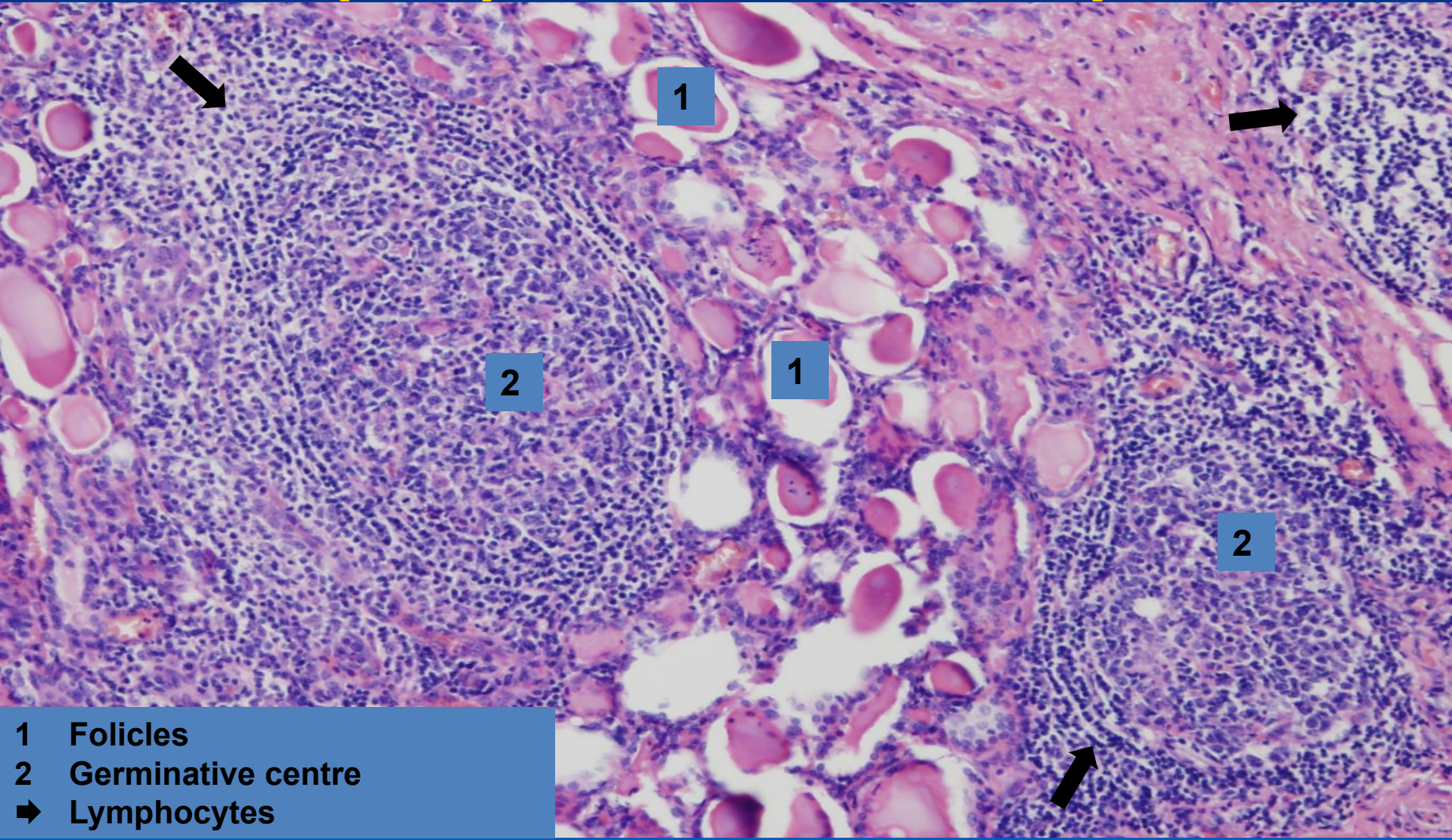
- x autoimmune
- x antibodies against various th. antigenes
- x loss of th. follicular cells
- x lymphocytic infiltration
- x neoformation of lymphoid follicles
- x risk of other autoimmune diseases, thyroid tumors

Chronic thyreoiditis



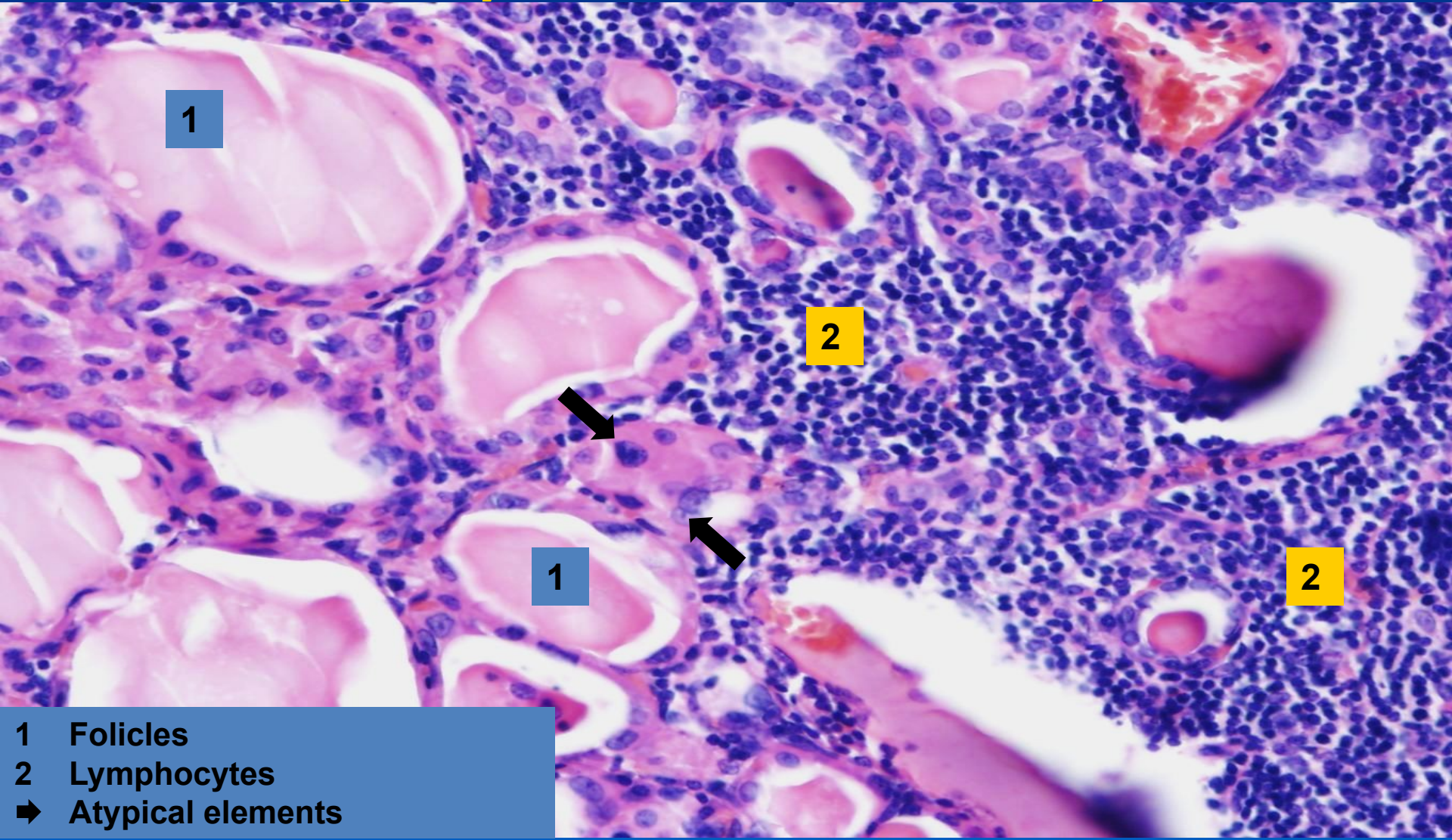
Hashimoto`s lymphocytic thyreoiditis

(non-purulent inflammation)



- 1 Folicles
- 2 Germinative centre
- ➡ Lymphocytes

Hashimoto`s lymphocytic thyreoiditis – detail (non-purulent inflammation)



1

2

1

2

- 1 Follicles
- 2 Lymphocytes
- ➔ Atypical elements