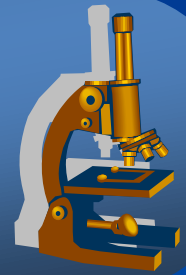


General pathology practice



General oncology I

Tumors: epithelial
mesenchymal
neuroectodermal
germ-cell tumors

1. Epithelial tumors



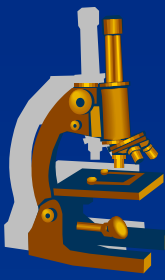
- ✗ originate in superficial (covering) or glandular epithelium
- ✗ tumor cells maintain epithelial features:
 - ⇒ *cohesivity (they adhere to each other)*
 - ⇒ *surface covering (tigmotaxis)*
 - ⇒ *immunohistochemical positivity of epithelial markers*

Epithelial tumors



x CLASSIFICATION

	BENIGN	MALIGNANT
SUPERFICIAL EPITHELIUM TUMORS	PAPILLOMAS	CARCINOMAS
GLANDULAR EPITHELIUM TUMORS	ADENOMAS	ADENOCARCINOMAS



Benign epithelial tumors

Benign epithelial tumors



- ✗ originate in squamous-cell or transitional epithelium
- ✗ mainly exophytic growth
- ✗ papillary or wart-like appearance
- ✗ a special form - inverted papilloma (endophytic growth)
- ✗ 2 types according to the amount of fibrous stroma:
 - ⇒ **soft papilloma** (*lower amount of fibrous stroma*)
 - e.g. squamous cell papilloma of the oral cavity
 - transitional papilloma of the urinary bladder (rare)
 - ⇒ **fibroepithelial papilloma** (*more fibrous stroma*)
 - e.g. verruca vulgaris (skin wart)

Verruca vulgaris (common wart)



✗ etiology: HPV infection

✗ gross:

⇒ *papules with a rough surface*

✗ micro:

⇒ *acanthosis*

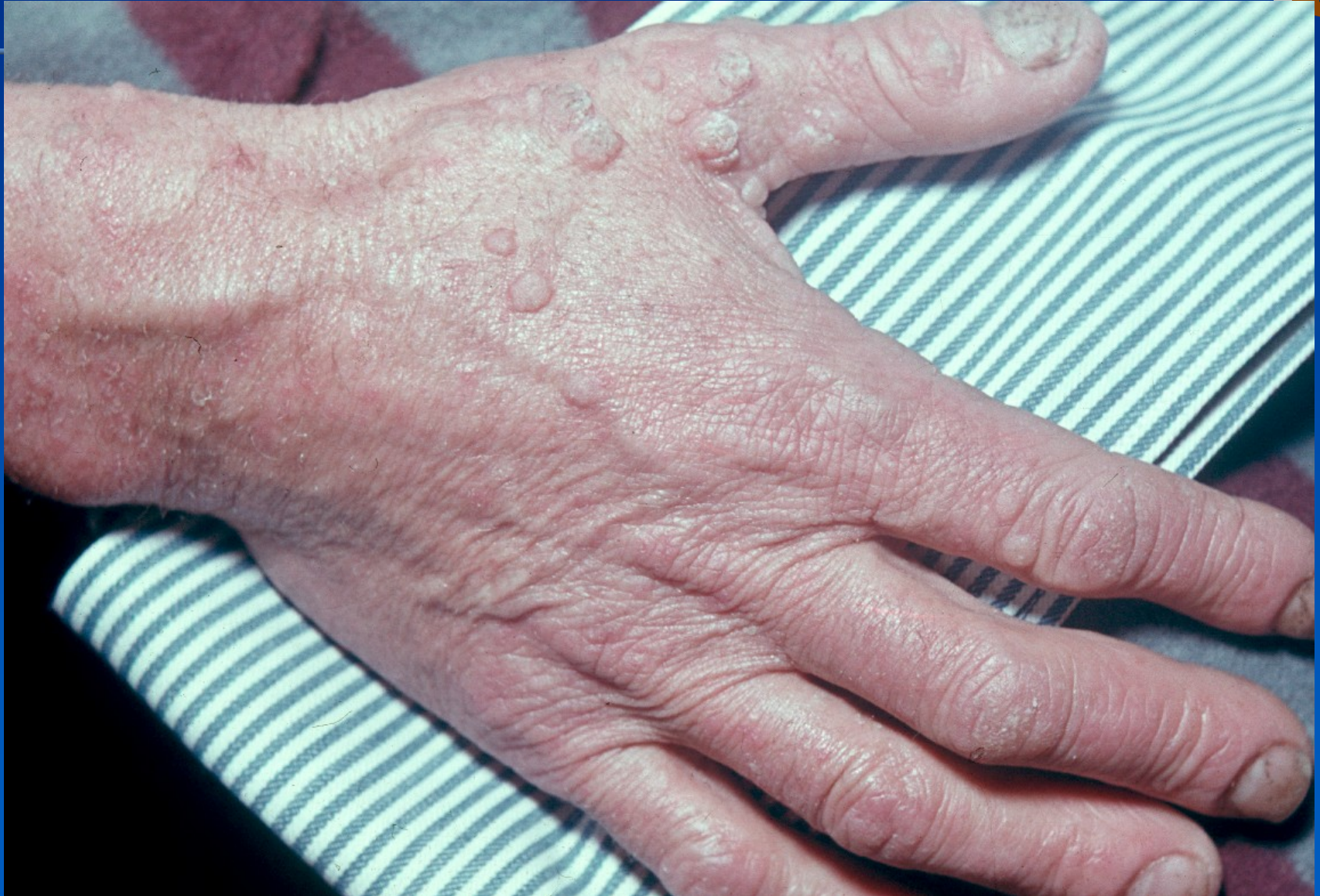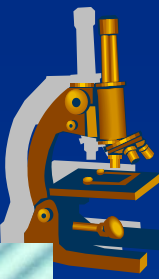
⇒ *hyperkeratosis, parakeratosis*

⇒ *papillomatosis*

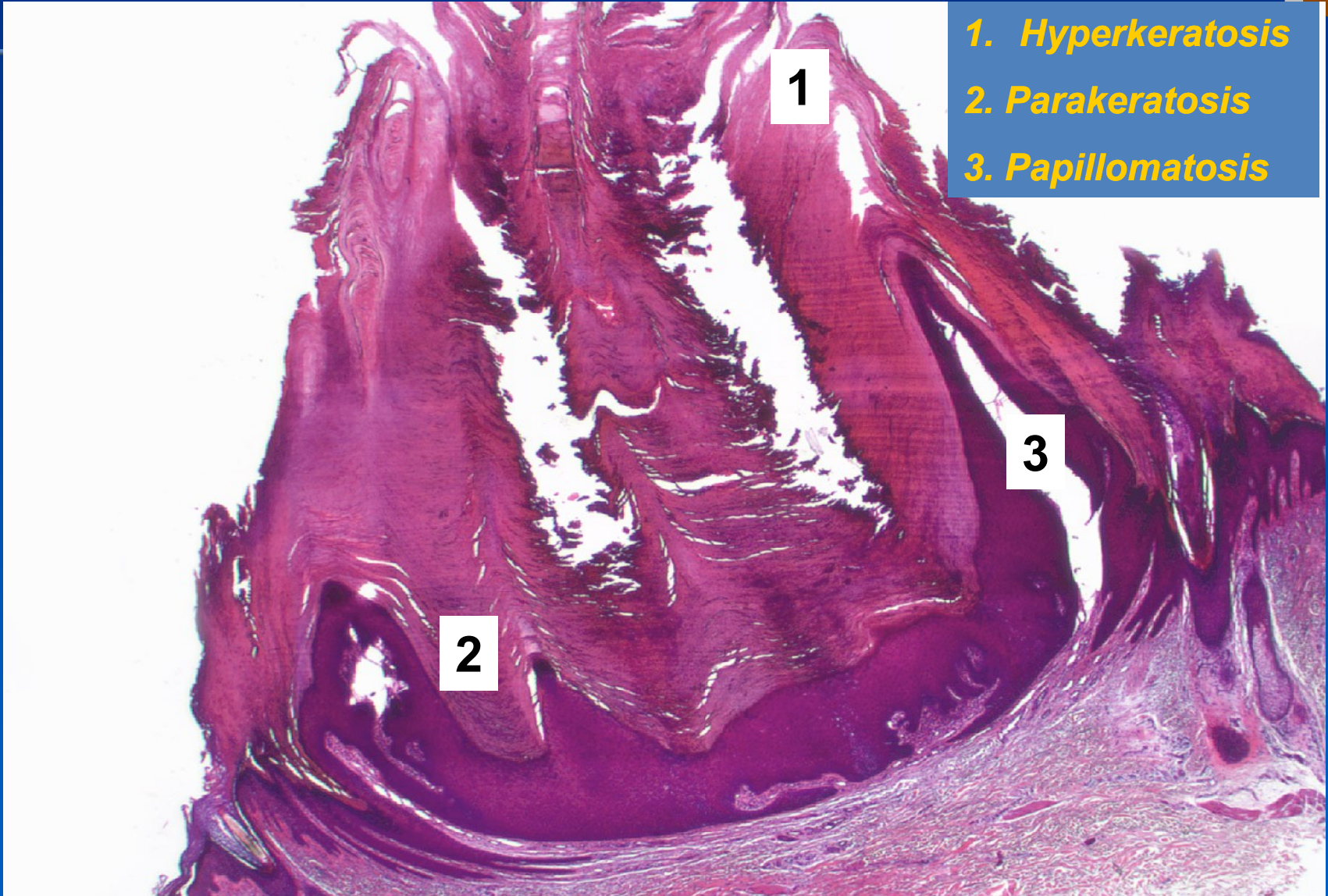
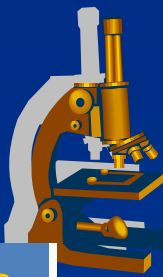
⇒ *koilocytosis*

- viral alteration of keratinocytes: enlarged cells with cytoplasmic vacuolization, nuclear hyperchromasia and perinuclear halos

Verruca vulgaris (wart)



Verruca vulgaris (wart)

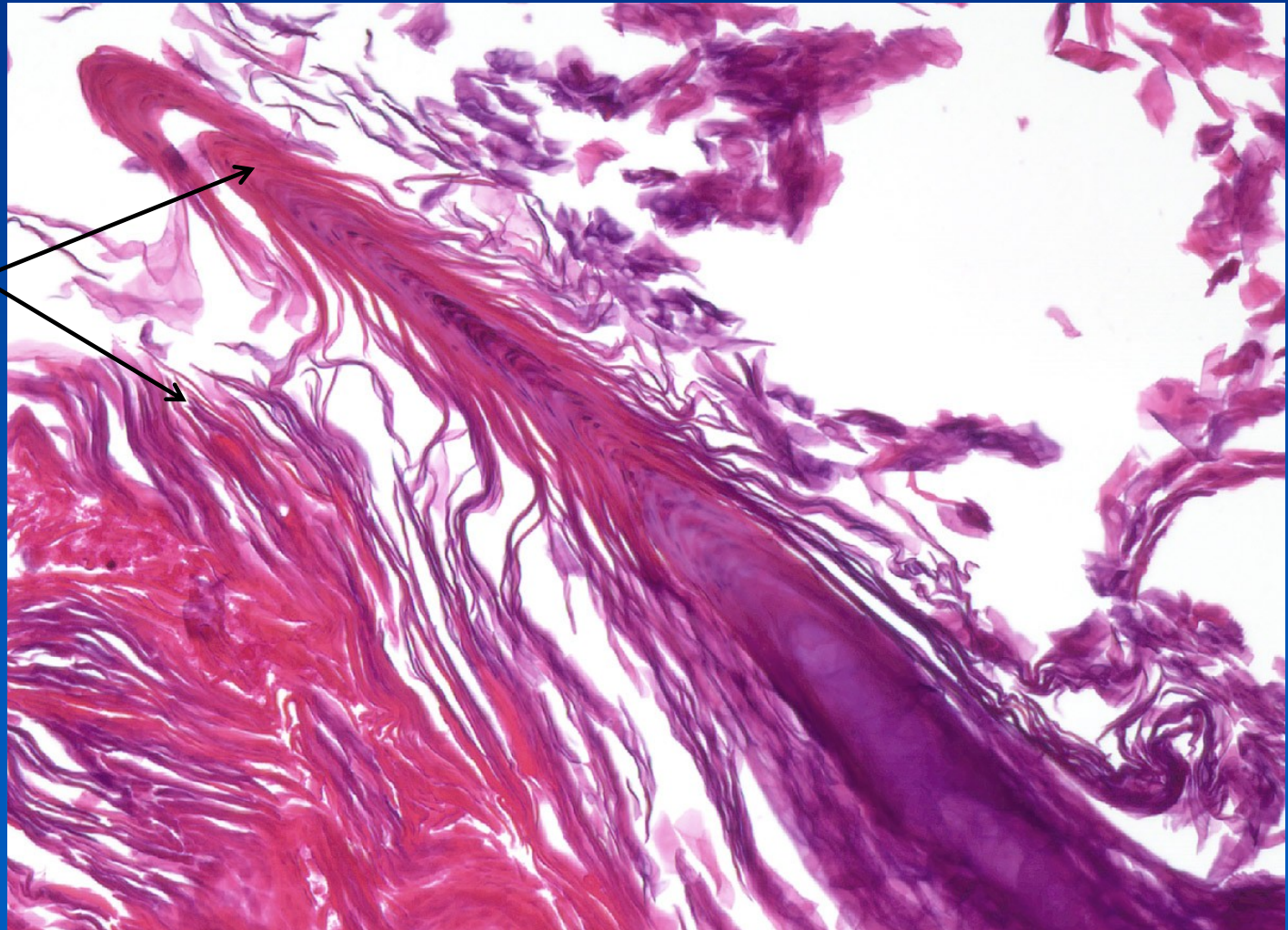


1. *Hyperkeratosis*
2. *Parakeratosis*
3. *Papillomatosis*

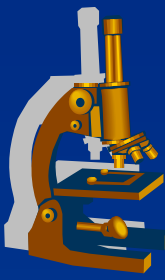
Verruca vulgaris (wart)



Parakeratosis



Seborrheic keratosis



- ✗ common epidermal tumor (benign)

- ✗ Gross:

 - ⇒ *flat or exophytic wart-like outgrowths*

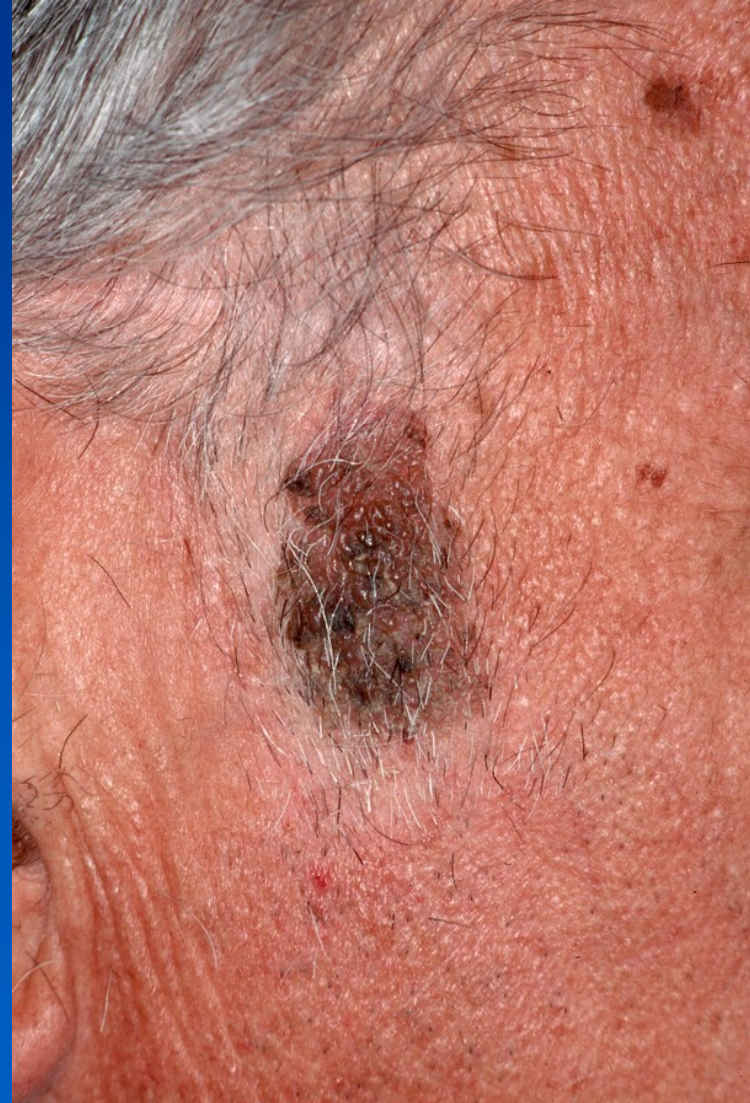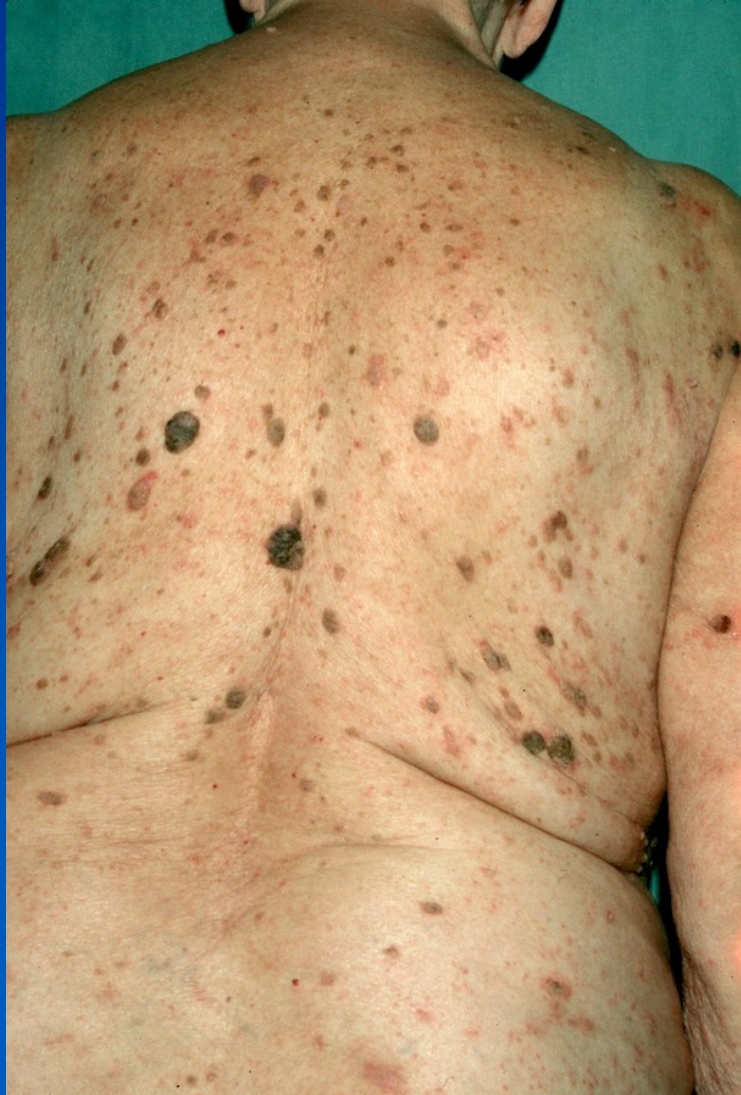 - ⇒ *sometimes with brown coloration*

- ✗ Micro:

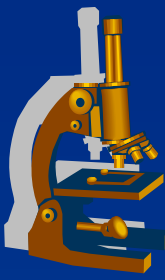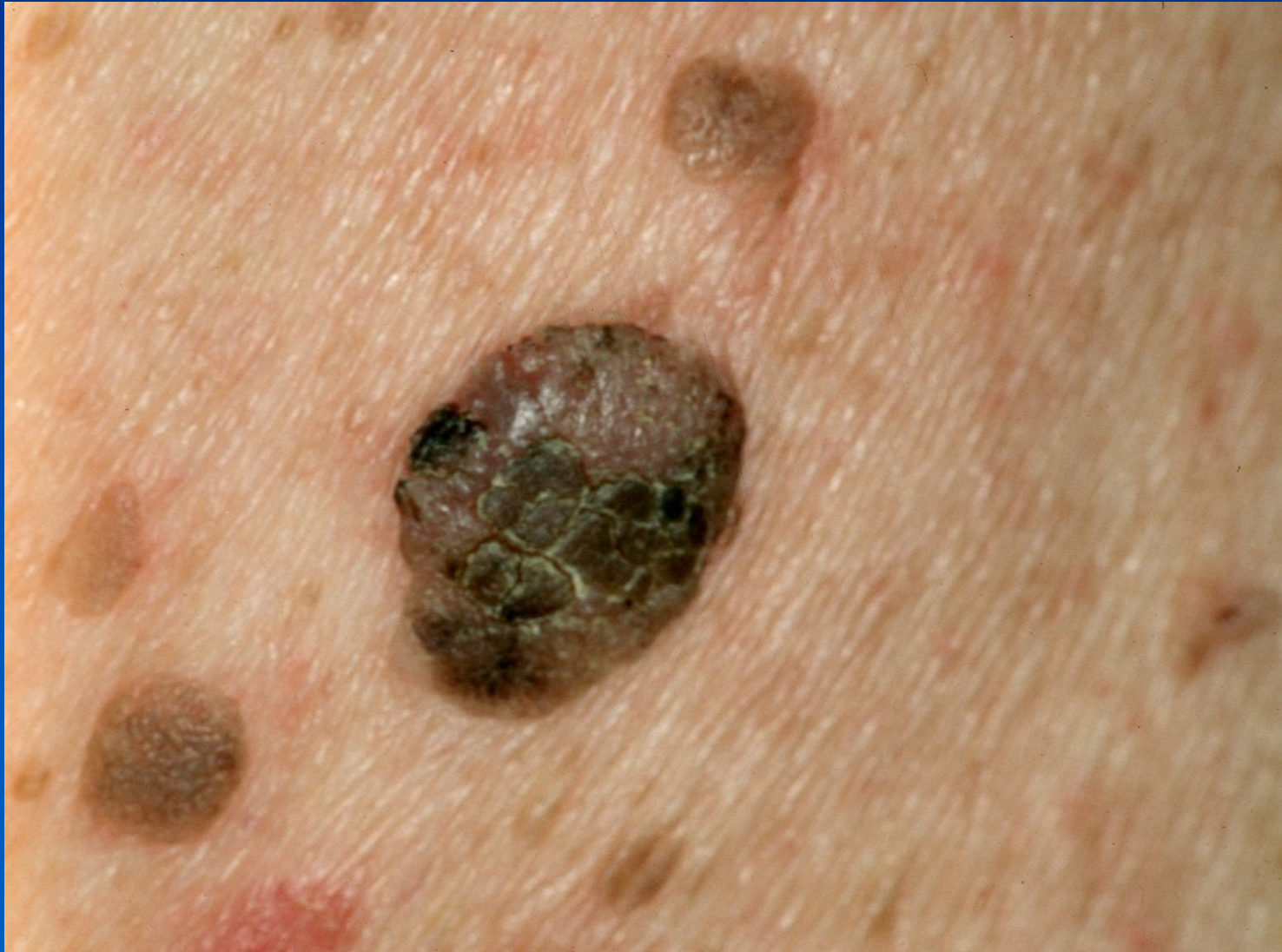
 - ⇒ *proliferation of basaloid cells (small, round cells that resemble basal cells)*

 - ⇒ *keratin pearls (horn pseudocysts)*

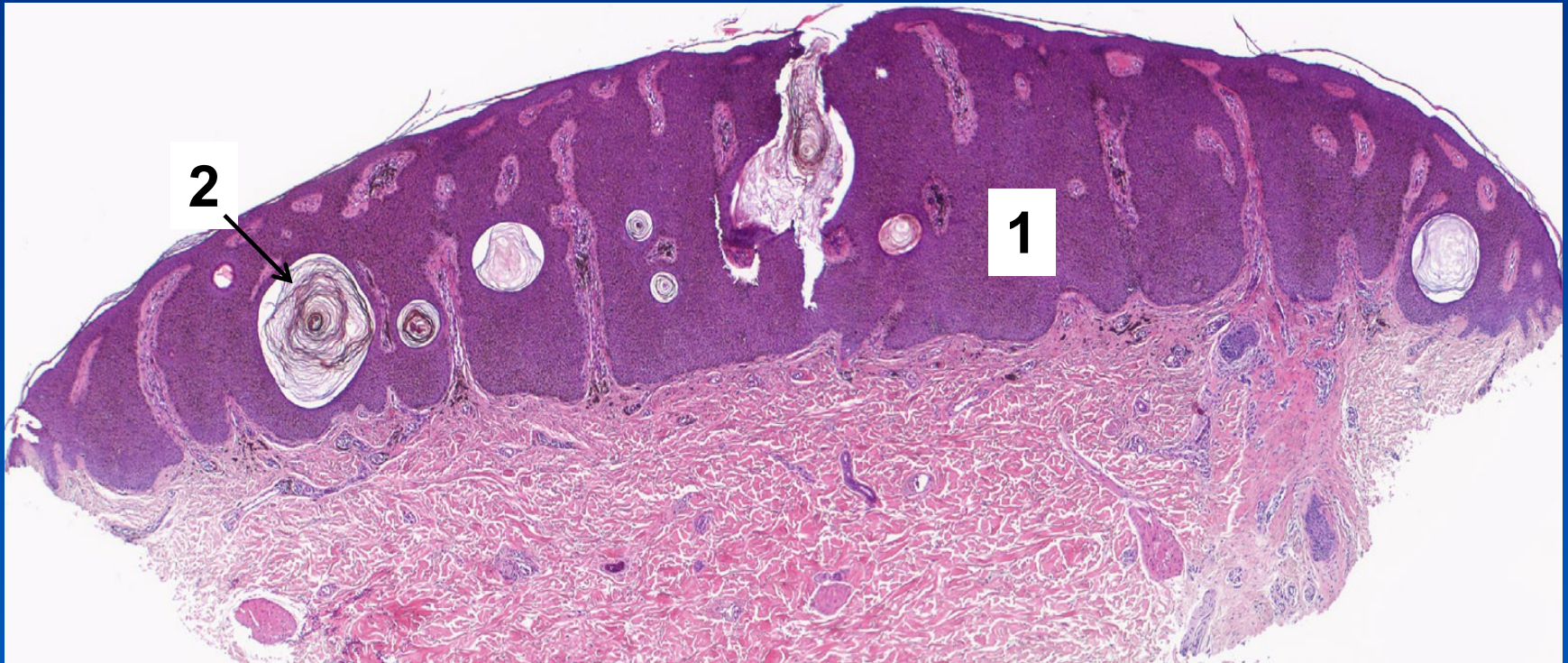Seborrheic keratosis



Seborrheic keratosis



Seborrheic keratosis



1. Nests of tumor cells
2. Keratinisation

Cervical dysplasia



✗ squamous cell precancerosis associated with HR (high risk) HPV infection:

⇒ **HR HPV:**

- mainly 16, 18, 31, 33, 35

✗ LR (low risk) HPV (6,11) →→ koilocytic changes in the squamous cell epithelium

⇒ **cytopathic effect of HPV**

Cervical dysplasia



× most used classification (now obsolete!)

× **CERVICAL INTRAEPITHELIAL NEOPLASIA (CIN):**

⇒ *CIN I:*

- changes in the basal third of the epithelium:
 - anisokaryosis
 - nuclear hyperchromasia
 - disorder of the cells` orientation
 - nuclear superposition

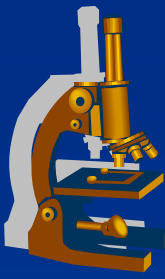
⇒ *CIN II:*

- changes in the lower 2/3 of the epithelium

⇒ *CIN III:*

- changes even in the superficial layer of the epithelium

Cervical dysplasia

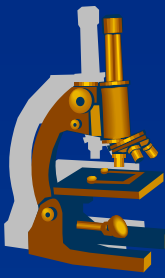


✗ now mostly 2 categories used:

⇒ **LG SIL** (*low grade squamous intraepithelial lesions*)

⇒ **HG SIL** (*high grade squamous intraepithelial lesions*)

Cervical dysplasia



✗ dysplastic changes (particularly LG SIL) may regress with time

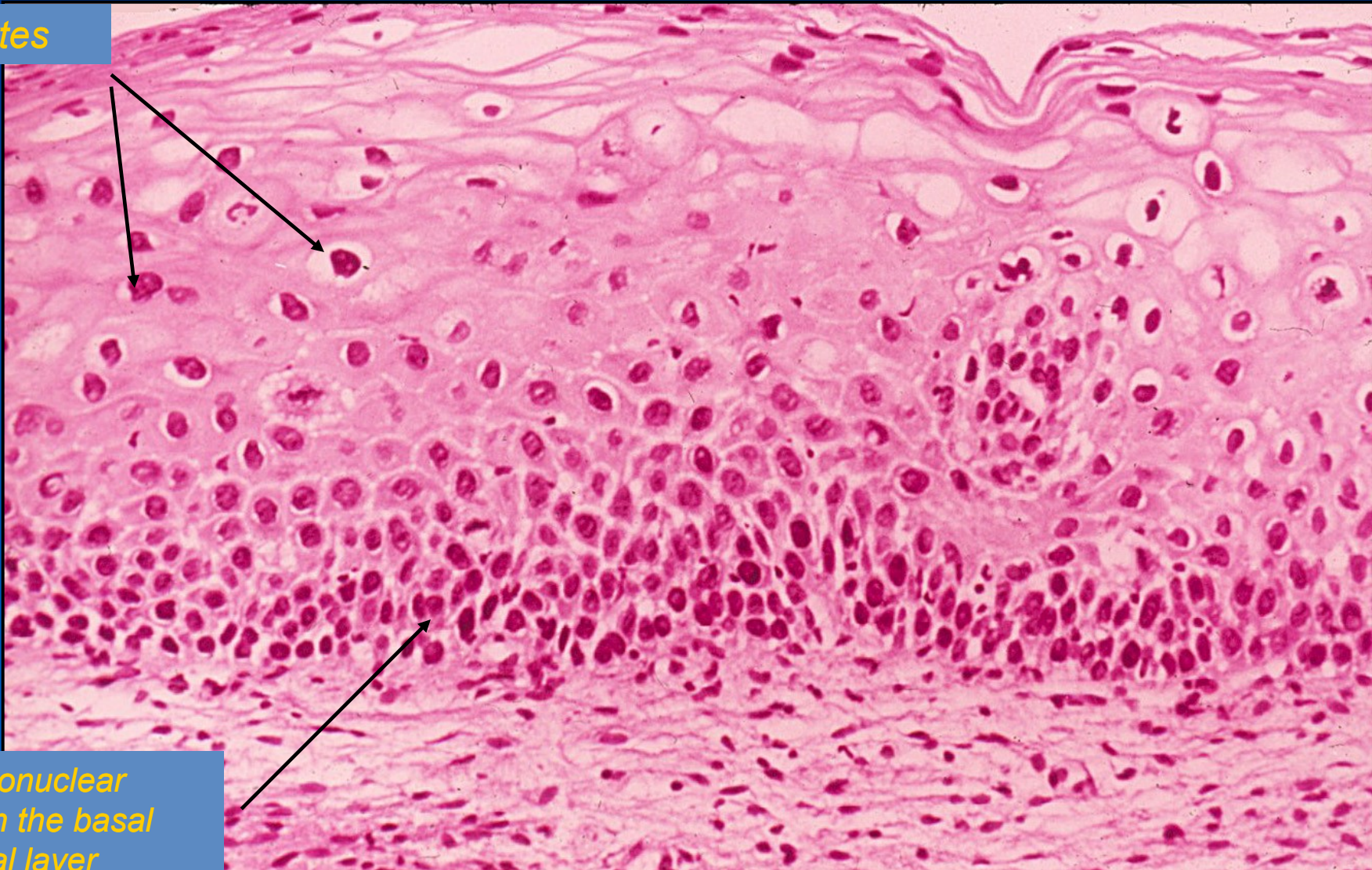
⇒ *due to clearance of the virus*

✗ HG SIL (i.e. CIN II and CIN III) has high probability of progression into the **squamous cell carcinoma**

Cervical dysplasia ***– mild epithelial dysplasia CIN I***



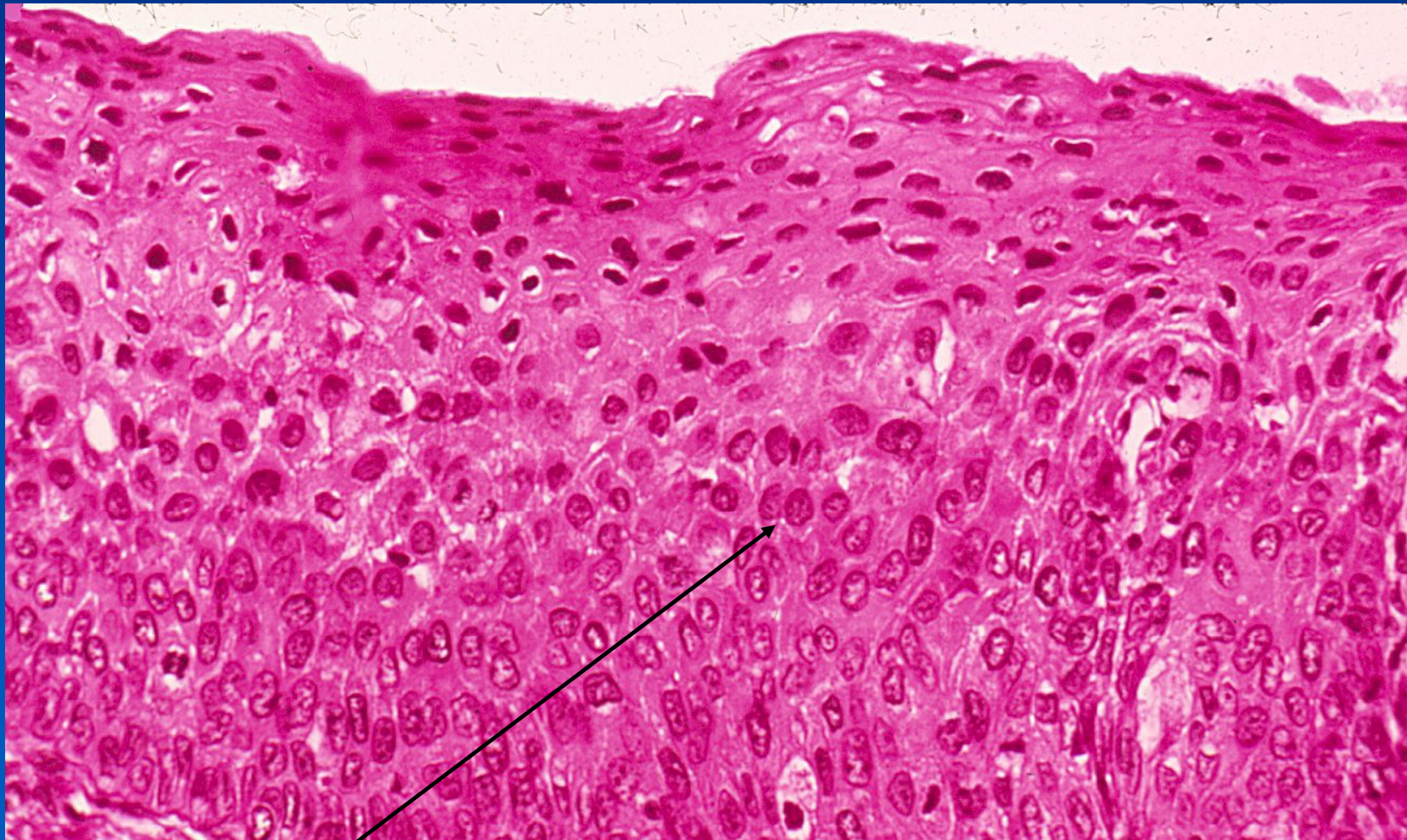
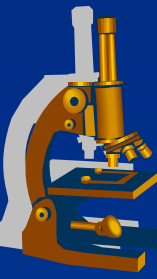
koilocytes



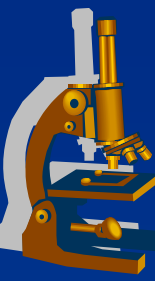
mild cytonuclear atypia in the basal epithelial layer

Cervical dysplasia

– moderate epithelial dysplasia CIN II



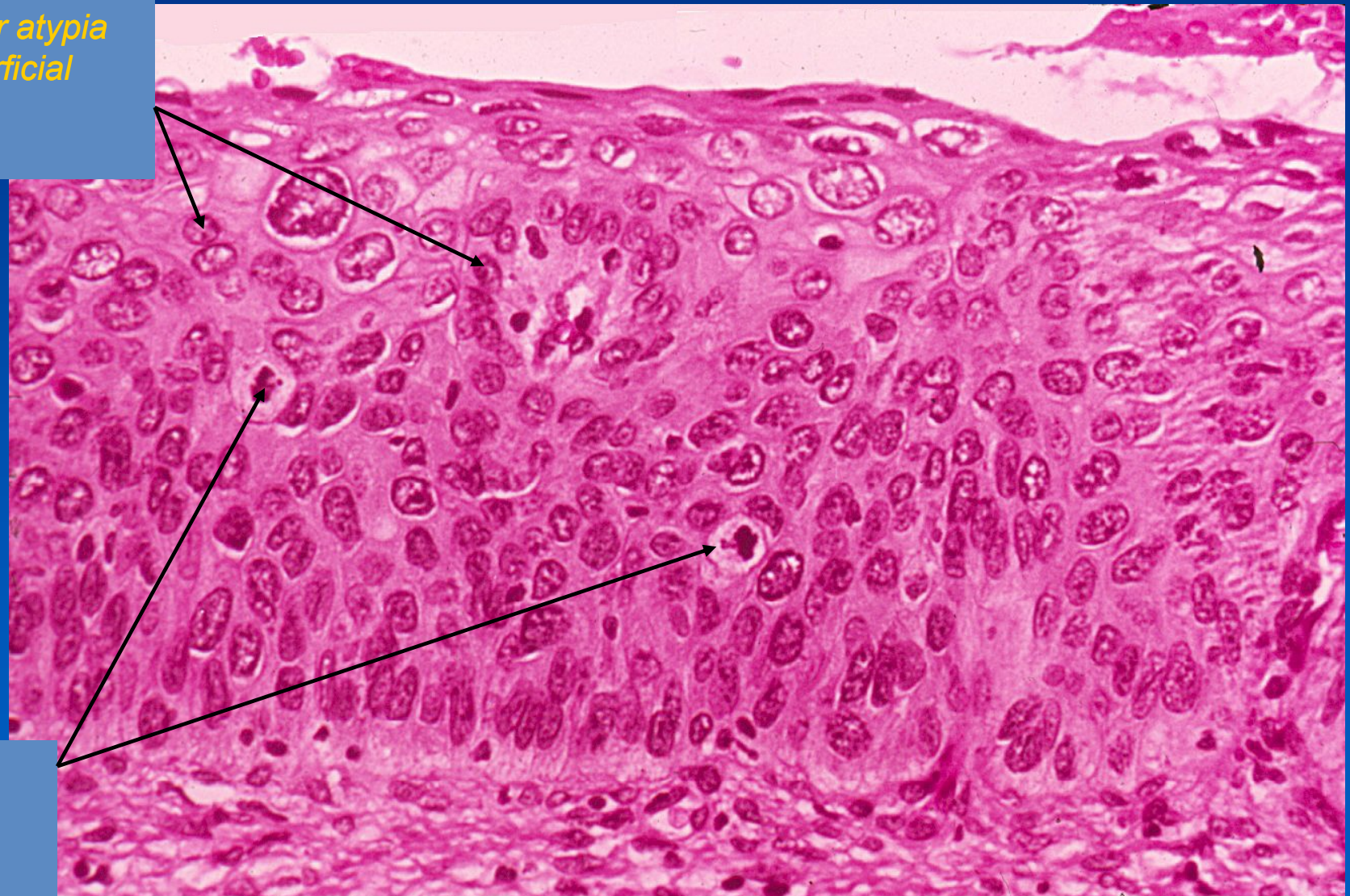
Cytonuclear atypia in the lower 2/3 of the epithelium



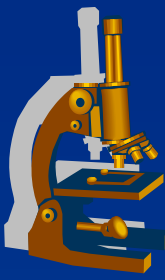
Cervical dysplasia

– severe epithelial dysplasia CIN III

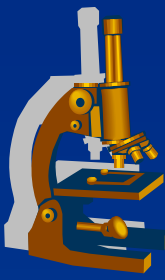
***Cytonuclear atypia
in the superficial
third of the
epithelium***



***Regular
mitotic
figures***



Malignant epithelial tumors



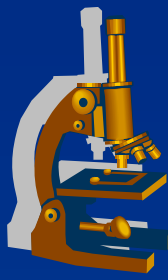
Squamous cell carcinoma

- x** malignant tumor of the squamous cell epithelium

- x** synonyms:
 - ⇒ *spinocellular, epidermoid carcinoma, spinalioma*

- x** growth:
 - ⇒ *exophytic*
 - ⇒ *endophytic (inwards)*

- x** often necrotic +/- ulcerative disintegration
- x** roughly granular and dry on the cut section



Squamous cell carcinoma

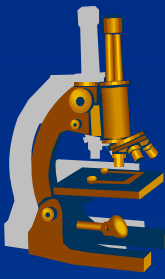
✘ Micro:

⇒ *nests of tumor cells*

⇒ *keratinisation:*

- extracellular keratinisation
 - cancrioid pearls
- monocellular keratinisation

⇒ *intercellular bridges*

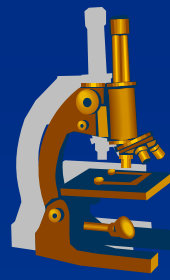


Squamous cell carcinoma

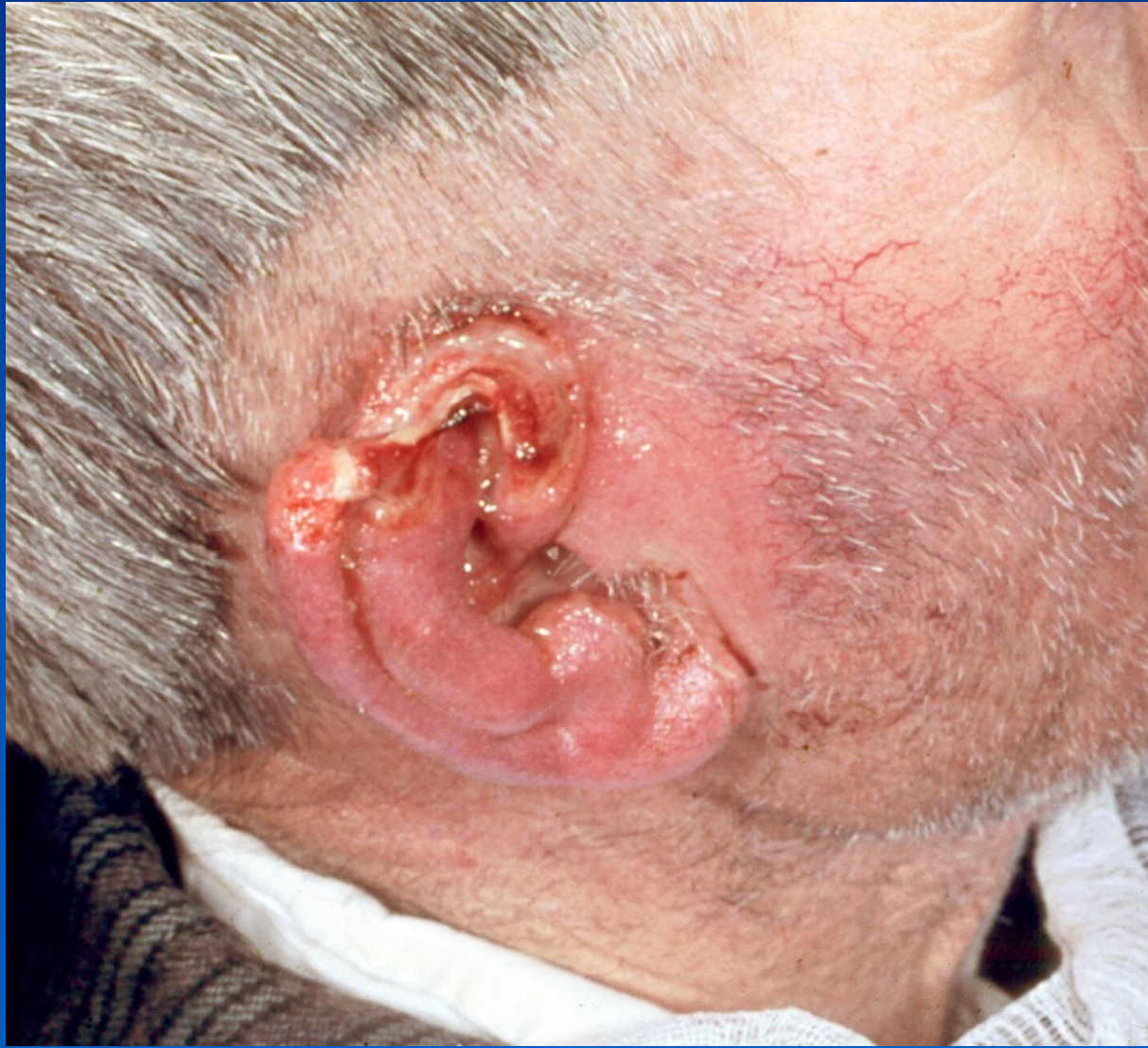x prognosis depends on the location:

⇒ *very good prognosis in the skin (curative surgical excision)*

**⇒ *generally unfavorable prognosis in the internal organs
(depends also on the stage of the disease)***



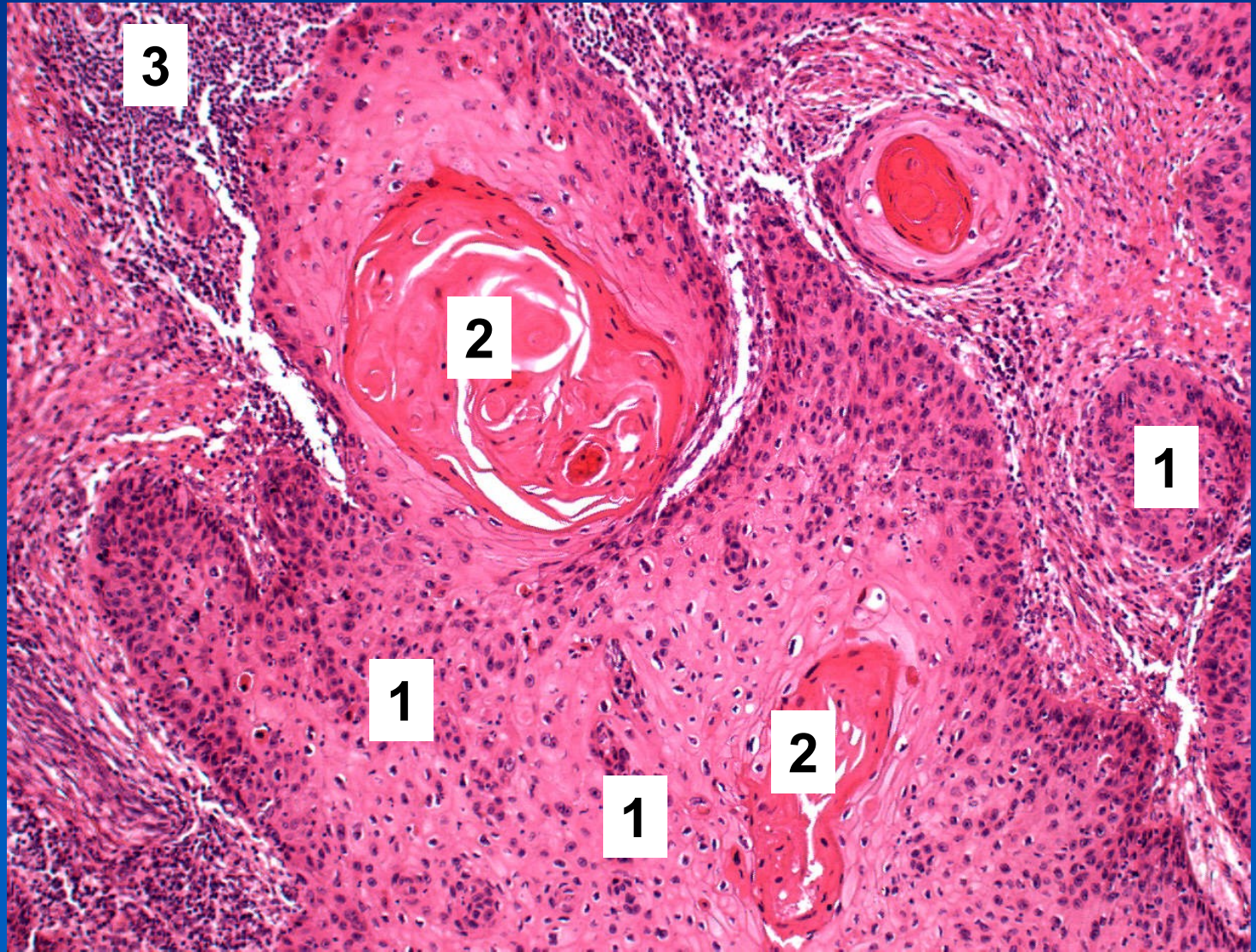
Squamous cell carcinoma



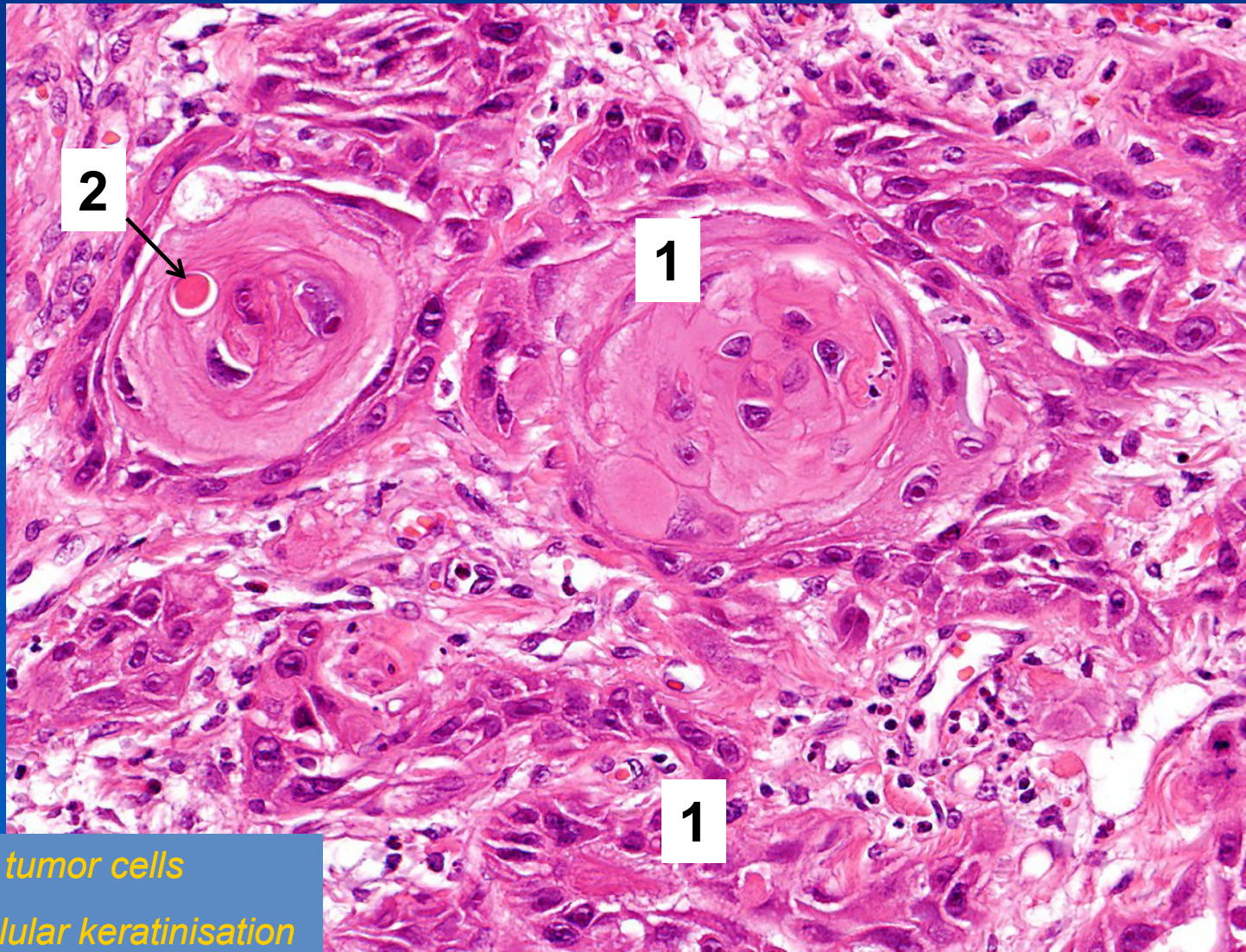
Squamous cell carcinoma well differentiated, keratinised



1. *Solid nests of tumorous keratinocytes*
2. *Cancroid pearls*
3. *Stroma of the tumor*



Squamous cell carcinoma well differentiated, keratinised



2

1

1

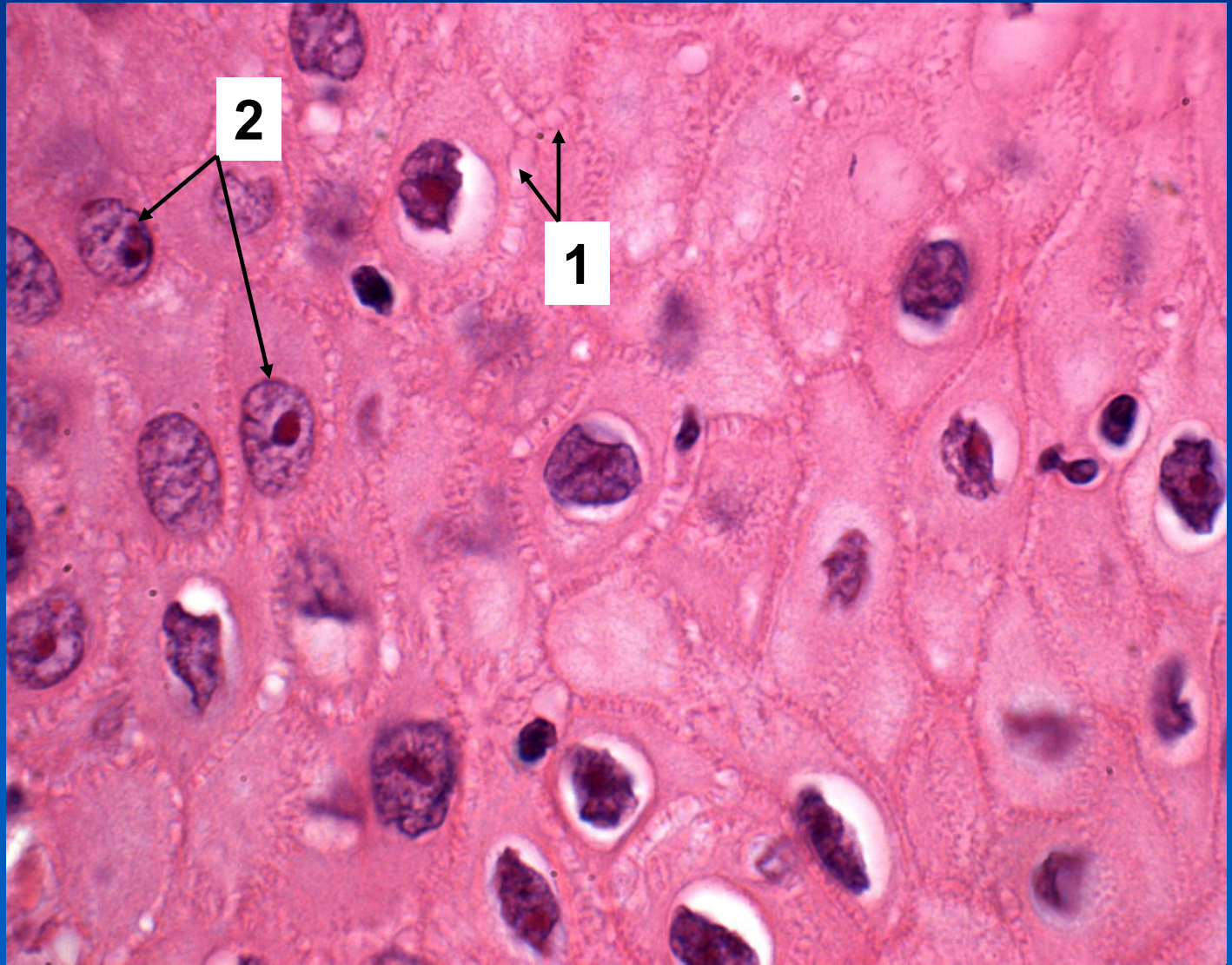
1. Nests of tumor cells

2. Monocellular keratinisation

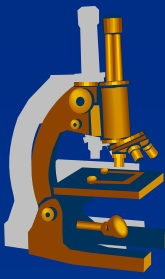
Squamous cell carcinoma well differentiated, keratinised



1. *Intercellular bridges – tonofilaments*
2. *Nucleus with distinct nucleolus*

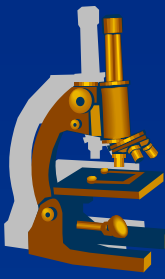


Basal cell carcinoma



- x very frequent skin tumor in higher age
- x typically in areas with chronic sun exposure
- x rare metastases!

Basal cell carcinoma



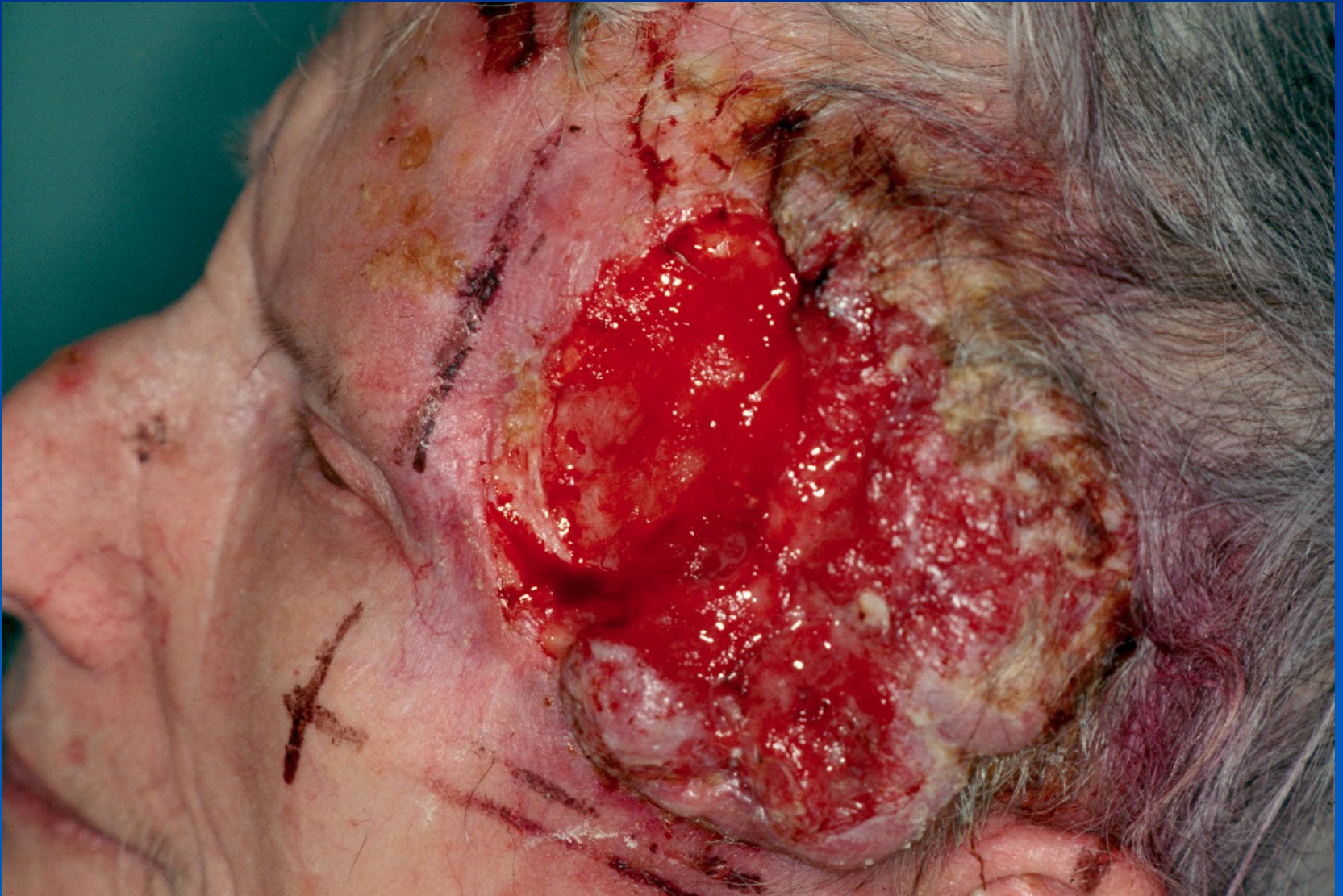xGross:

- ⇒ *pearly papules*
- ⇒ *later ulceration*
- ⇒ *unhealing, progressive tendency*

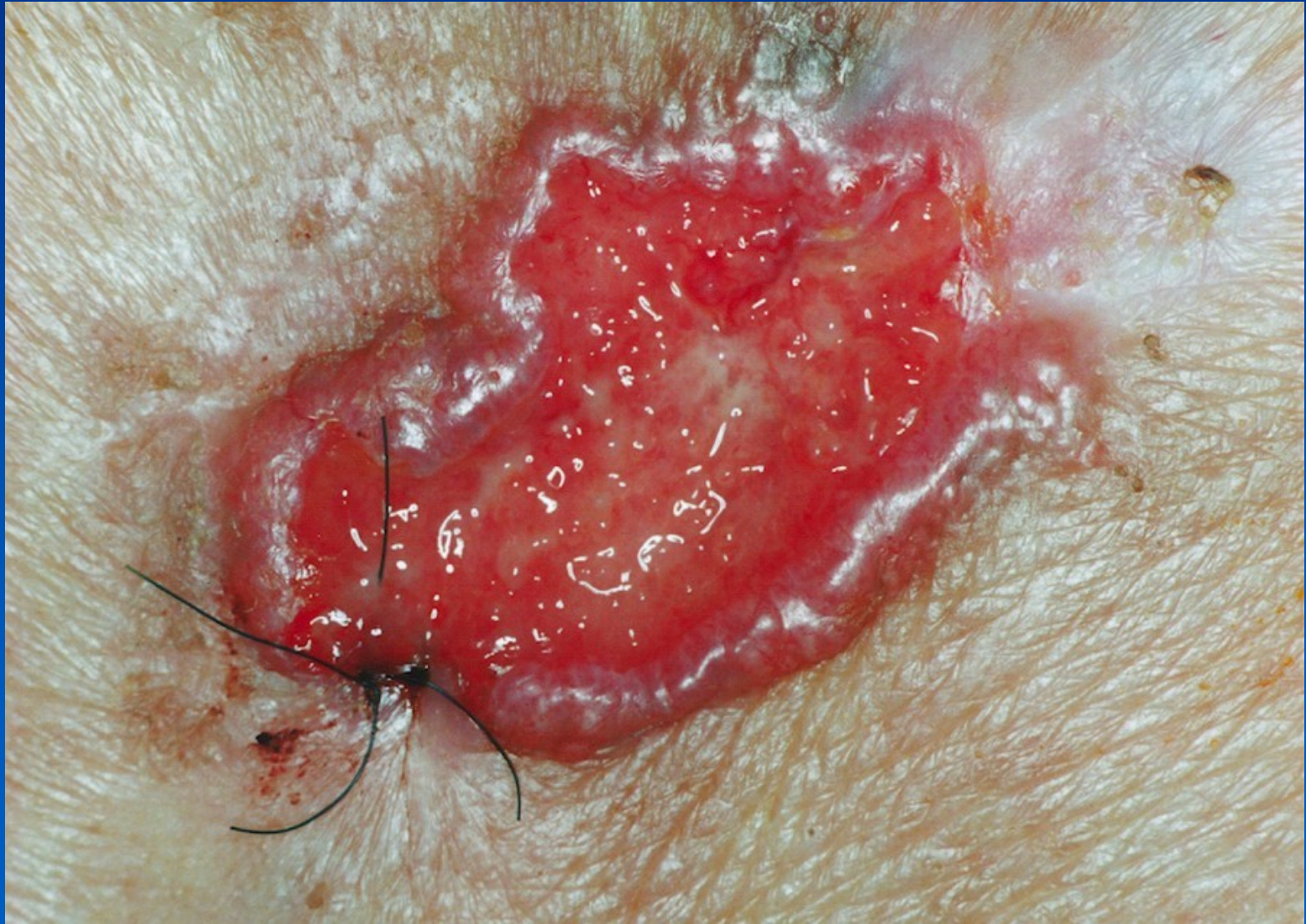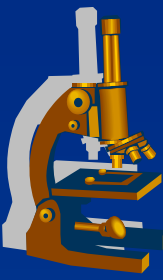
xMicro:

- ⇒ *small basaloid cells in nodules or small nests*
- ⇒ *peripheral palisading*
- ⇒ *commonly high mitotic activity*

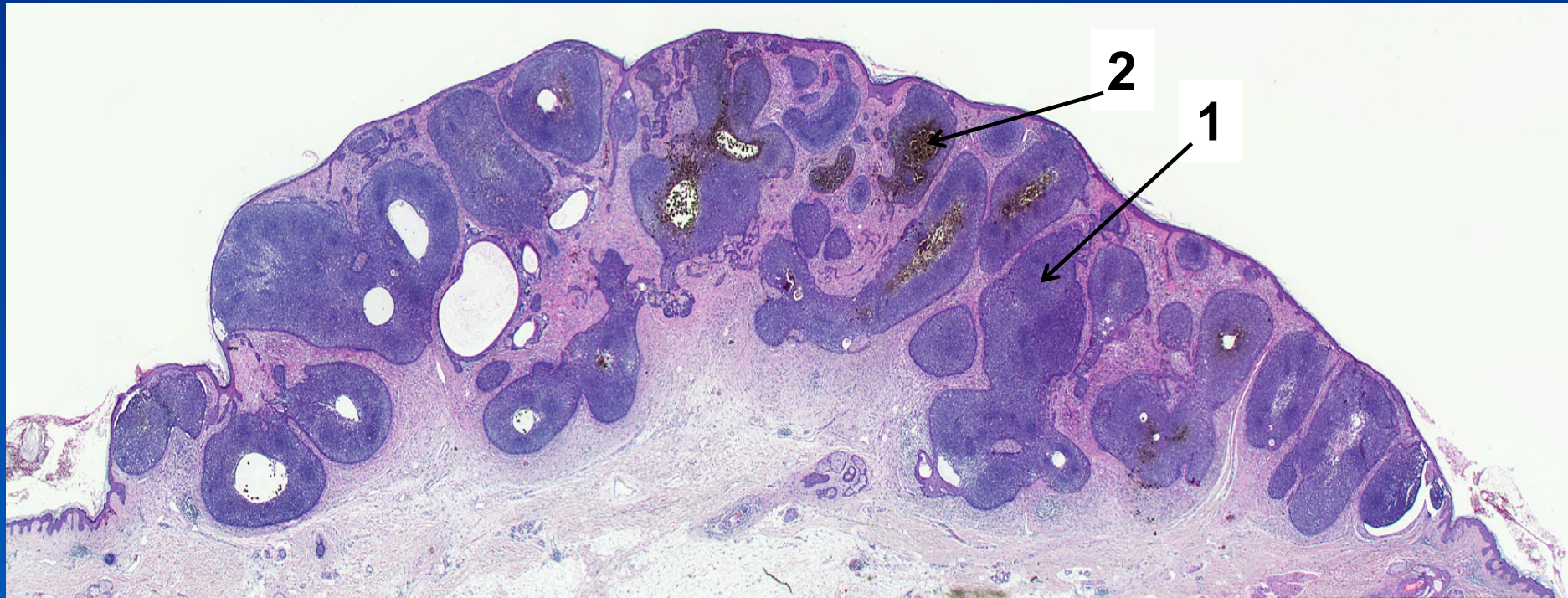
Basal cell carcinoma



Basal cell carcinoma



Basal cell carcinoma



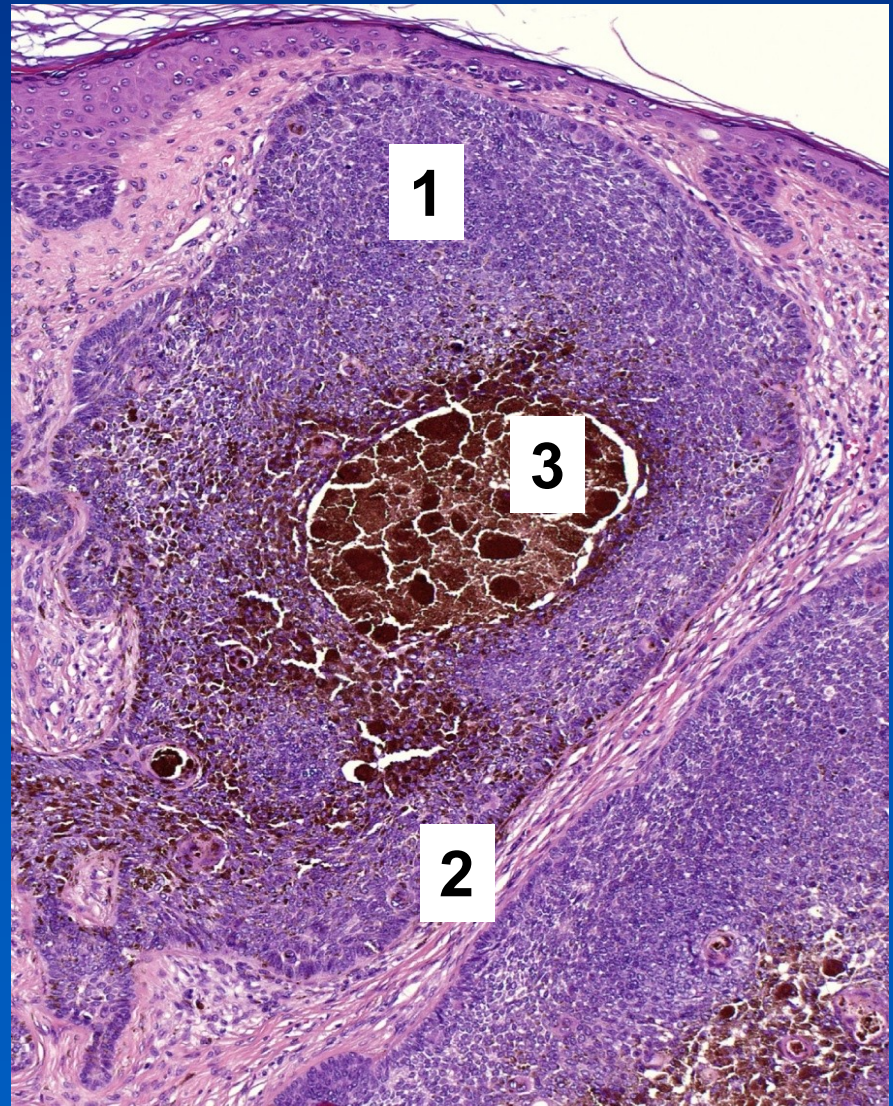
1. Nests of basophilic tumorous epithelium

2. Melanin pigmentation

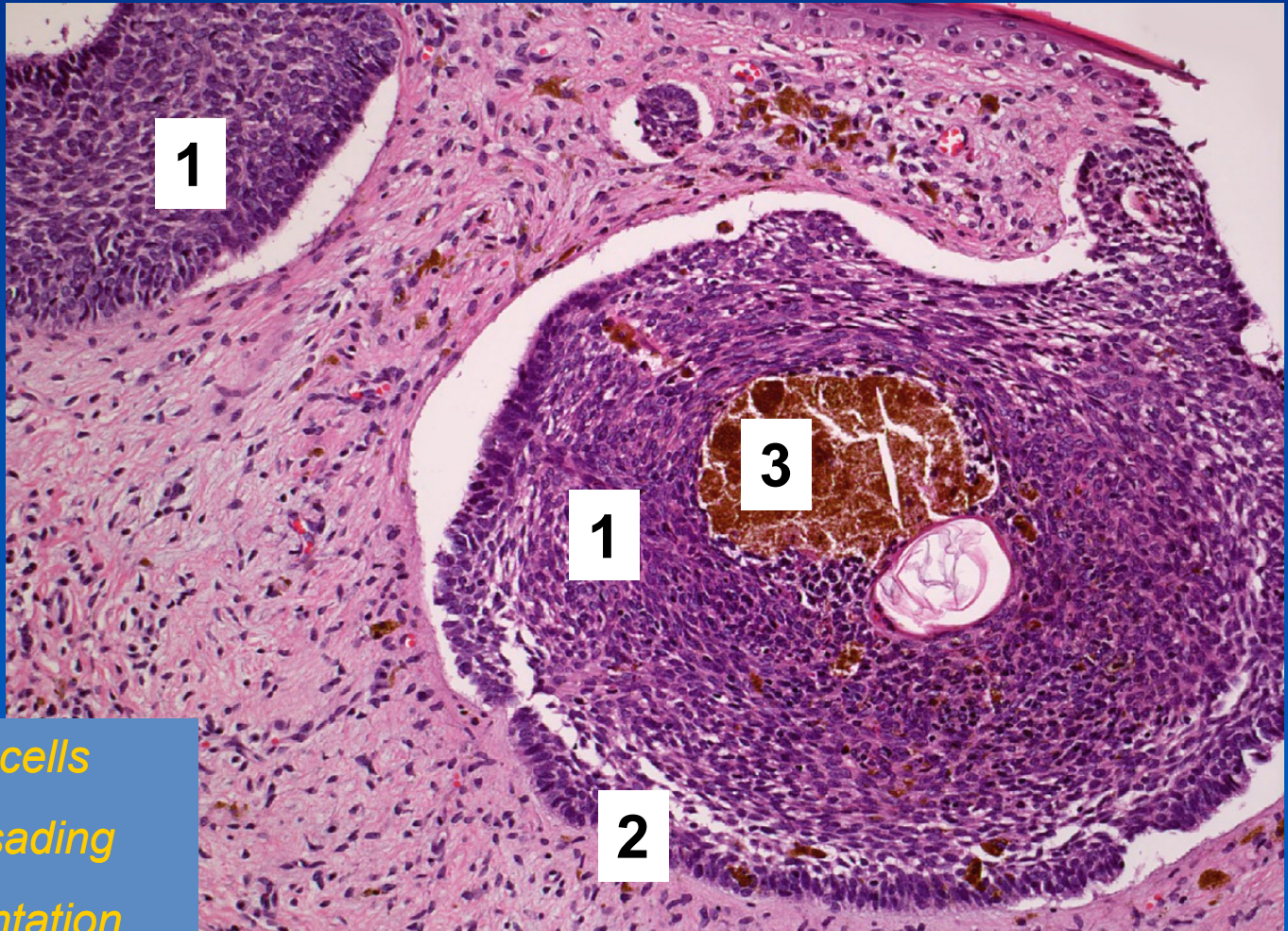
Basal cell carcinoma



1. *Nests of tumor cells*
2. *Peripheral palisading*
3. *Melanin pigmentation*

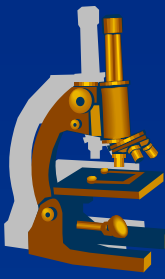


Basal cell carcinoma



1. Nests of tumor cells
2. Peripheral palisading
3. Melanin pigmentation

Urothelial (transitional) cell tumors of the urinary bladder



xWHO classification:

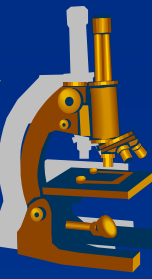
⇒ ***papilloma***

⇒ ***papillary urothelial neoplasms of low malignant potential (PUNLMP)***

⇒ ***papillary urothelial carcinoma***

- low grade
- high grade
- Invasive
- noninvasive

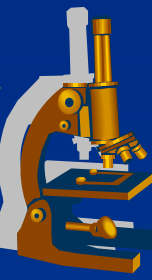
Papillary urothelial neoplasms of low malignant potential (PUNLMP)



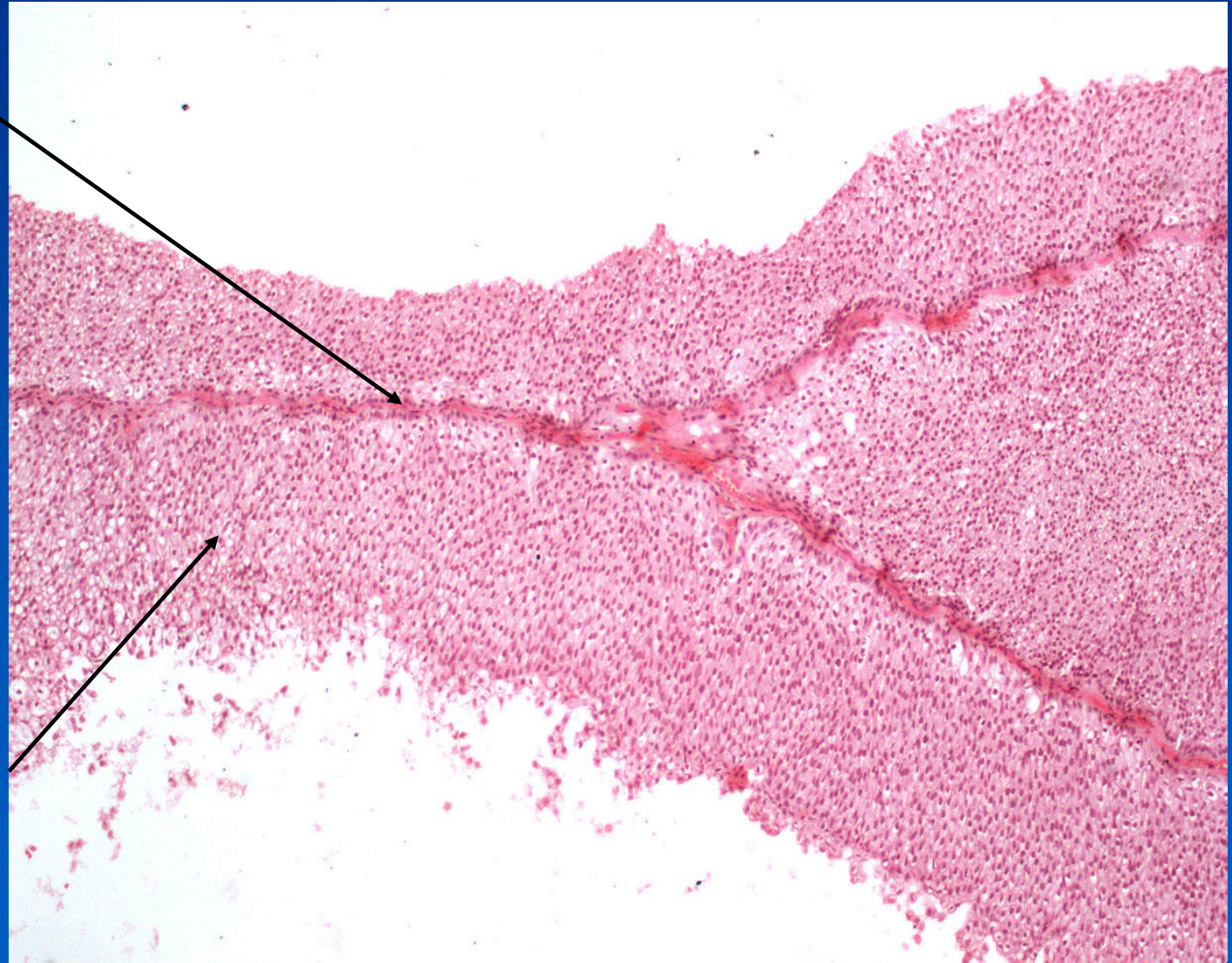
xMicro:

- ⇒ normal width or slightly more layers of the transitional epithelium***
- ⇒ slightly enlarged nuclei***
- ⇒ low mitotic activity***
- ⇒ typically delicate papillary formations with hyperplastic urothelium and preserved stratification***

Papillary urothelial neoplasms of low malignant potential (PUNLMP)

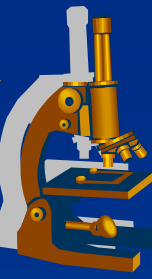


Delicate fibrovascular stroma



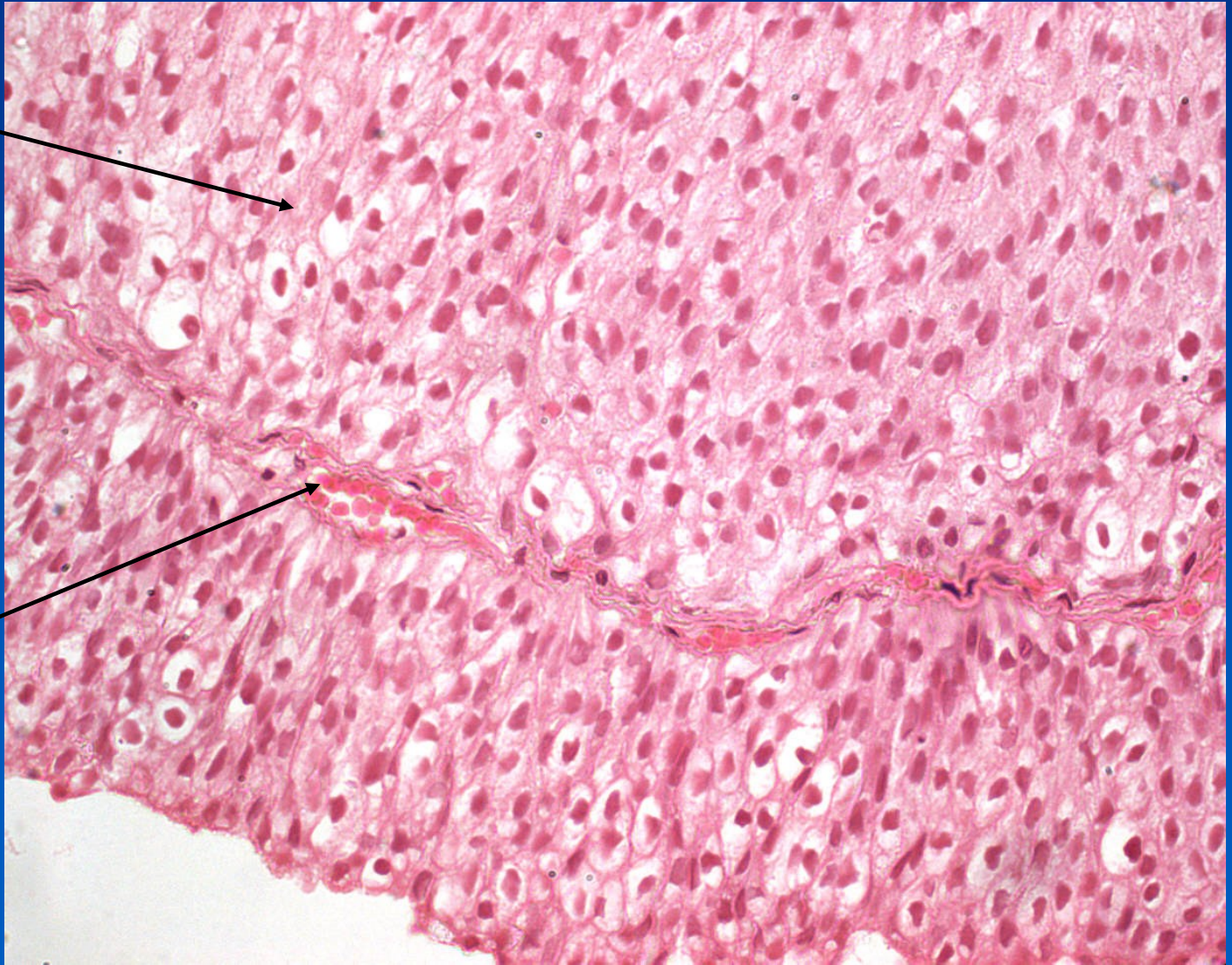
Increased number of urothelial layers

Papillary urothelial neoplasms of low malignant potential (PUNLMP)

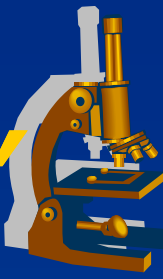


Hyperplastic urothelium with minimal cytonuclear atypia

Delicate fibrovascular stroma



Papillary urothelial carcinoma, low grade



× Micro:

⇒ *architecture:*

- disordered papillary architecture with fused papillae

⇒ *increased number of cell layers*

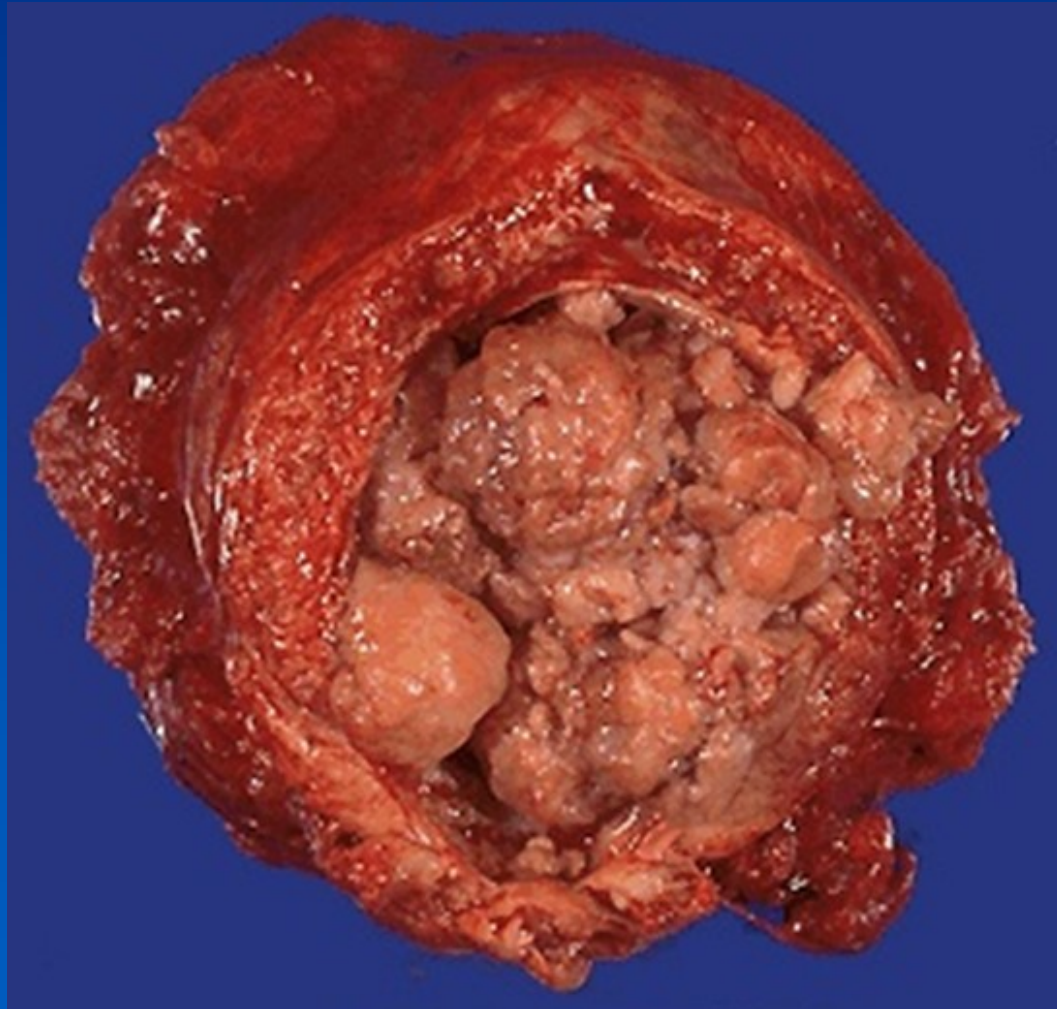
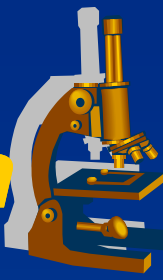
⇒ *cytological features:*

- low grade anisokaryosis
- enlarged nuclei
 - rarely noticeable nucleoli

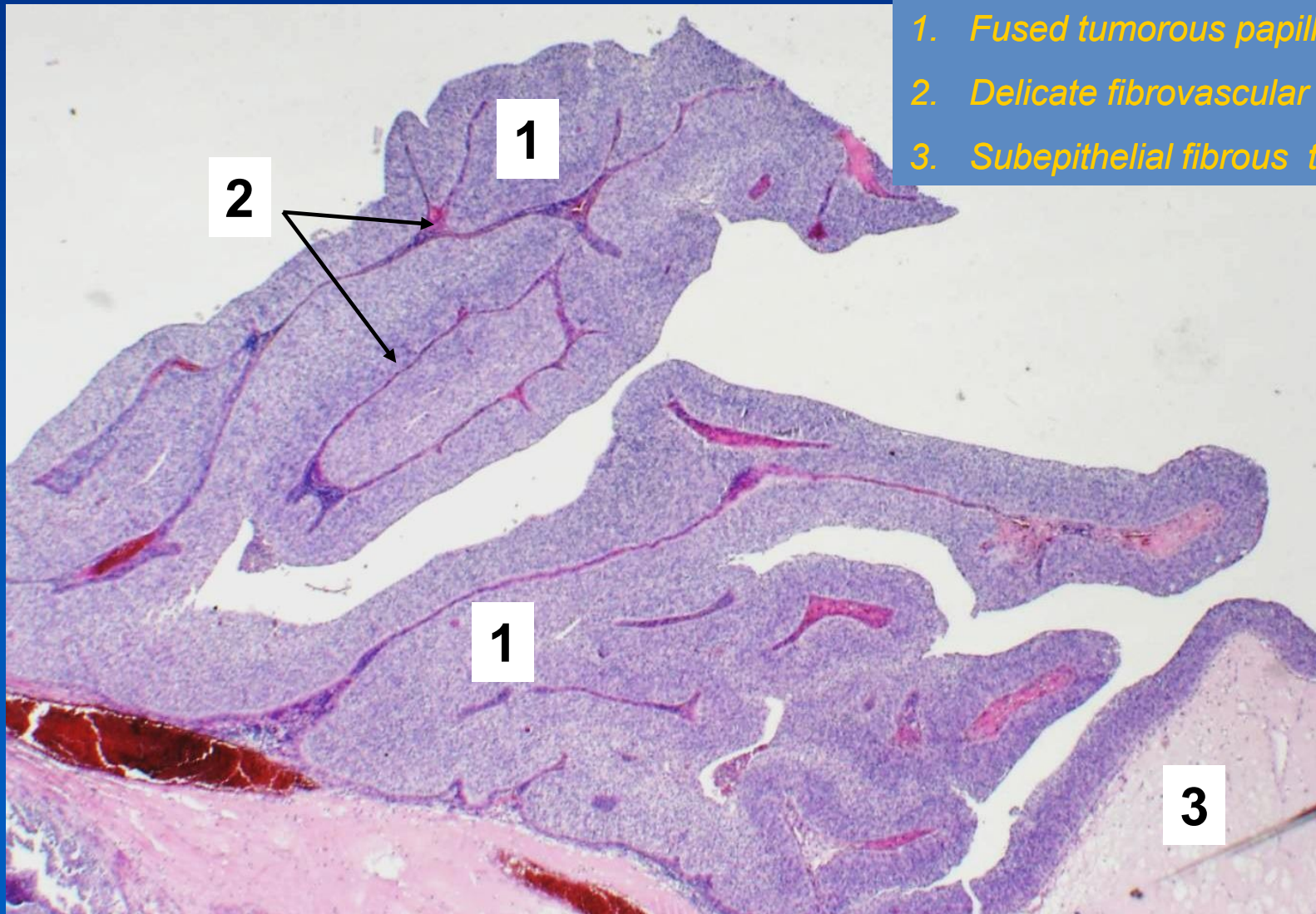
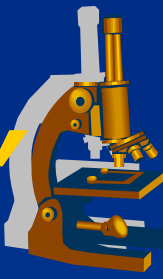
⇒ *low mitotic activity*

⇒ *possible stromal invasion*

Papillary urothelial carcinoma

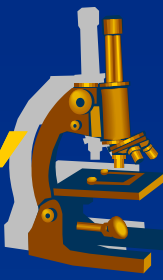


Papillary urothelial carcinoma, low grade

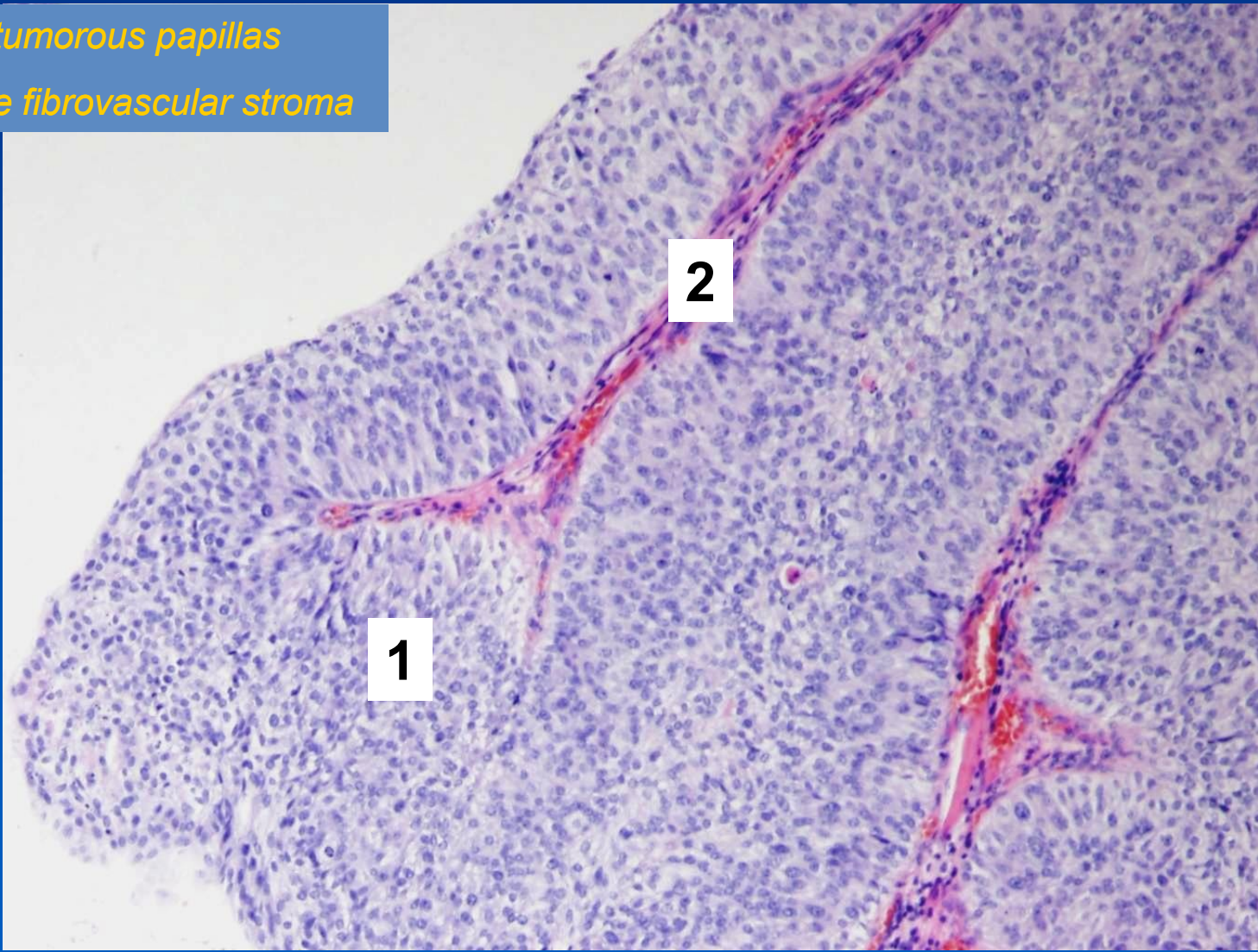


- 1. Fused tumorous papillae*
- 2. Delicate fibrovascular stroma*
- 3. Subepithelial fibrous tissue*

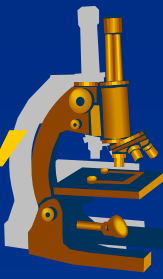
Papillary urothelial carcinoma, low grade



- 1. Fused tumorous papillas*
- 2. Delicate fibrovascular stroma*



Papillary urothelial carcinoma, high grade



x Micro:

⇒ *architecture:*

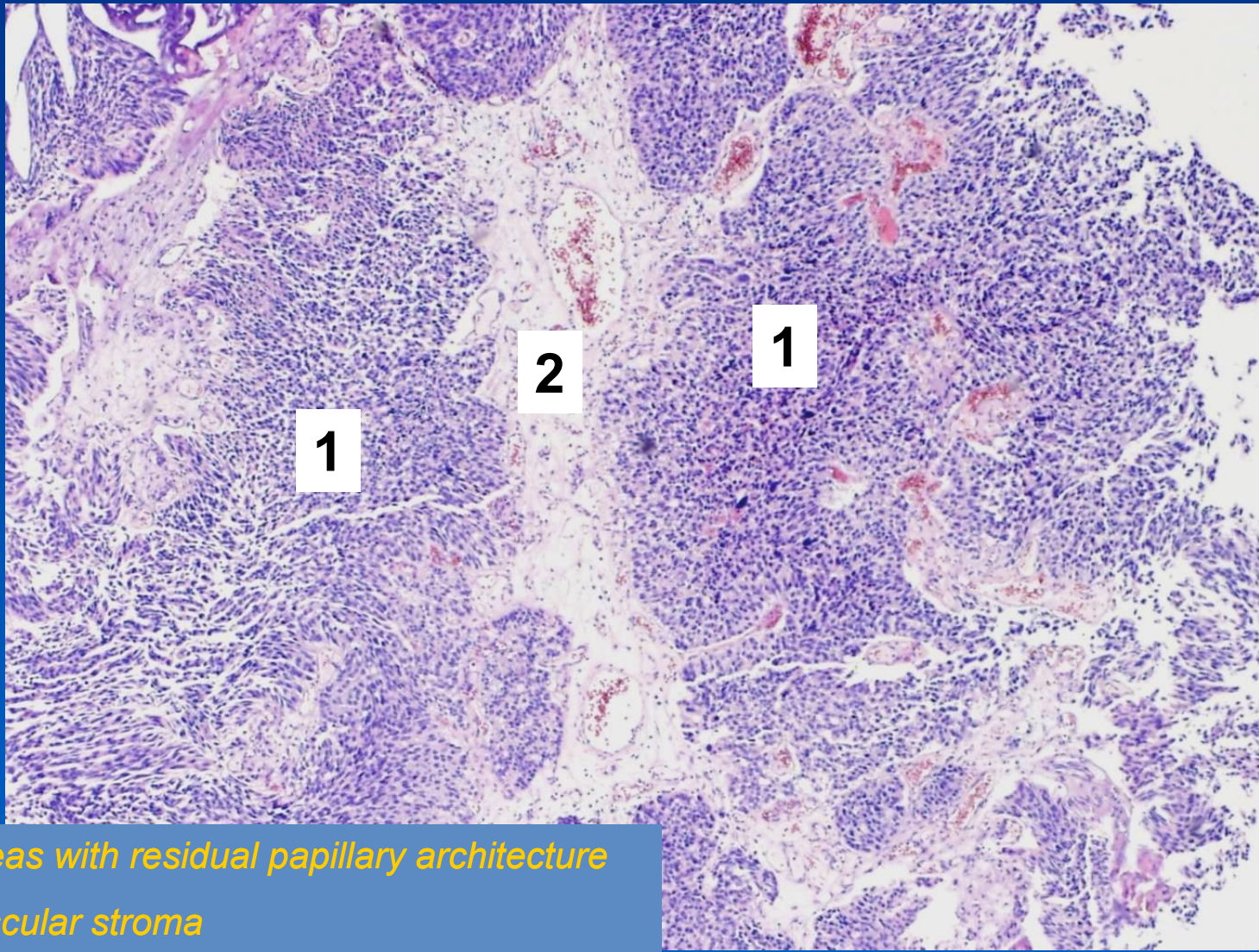
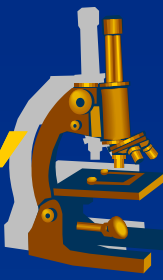
- focal residual papillary architecture
- solid areas common

⇒ *loss of urothelial stratification*

⇒ *cytological features:*

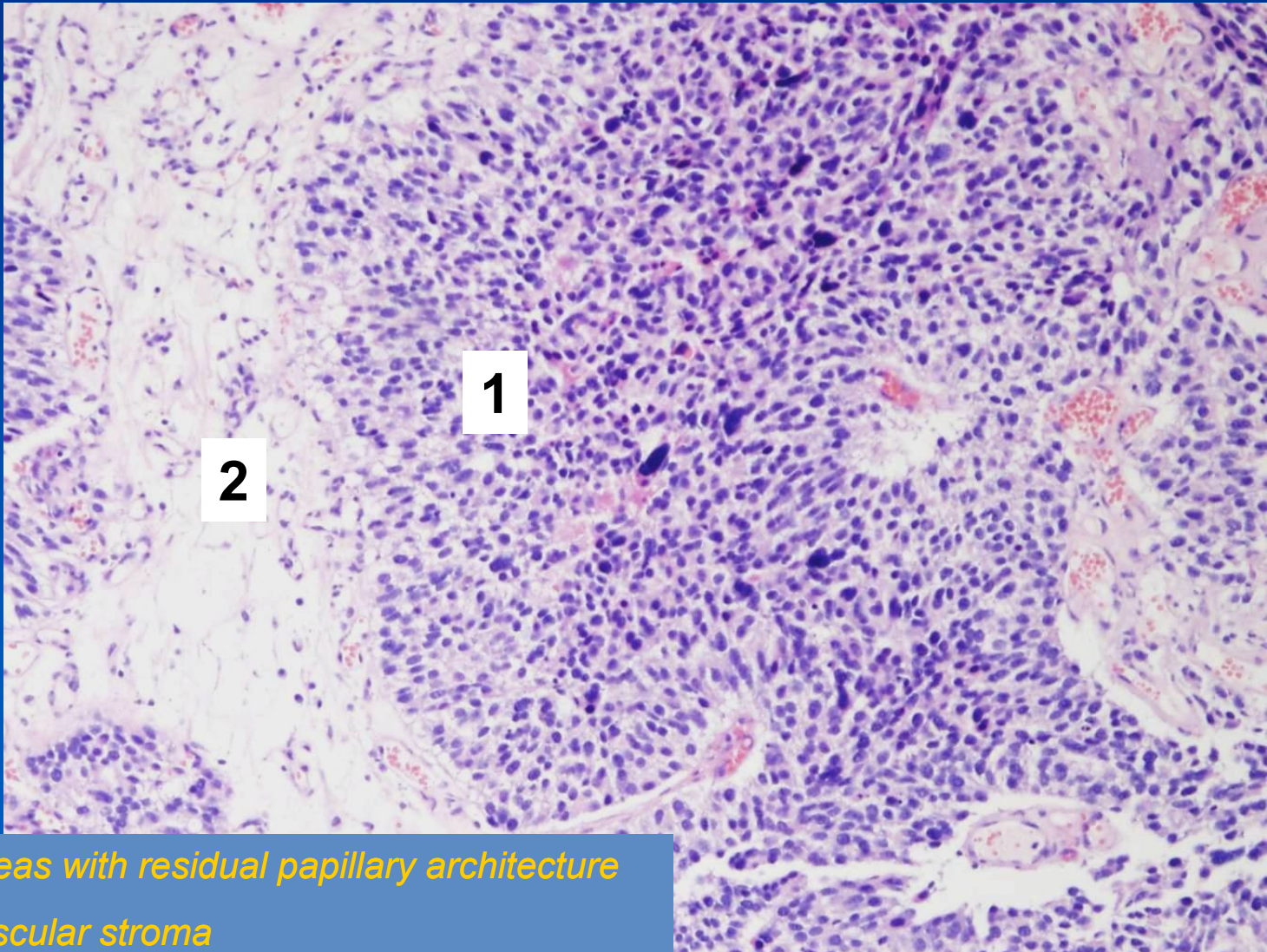
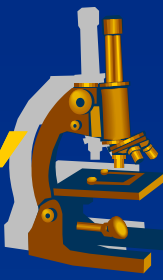
- high degree of anisocytosis and anisokaryosis
- frequent mitoses, including atypical

Papillary urothelial carcinoma, high grade



- 1. Solid areas with residual papillary architecture*
- 2. Fibrovascular stroma*

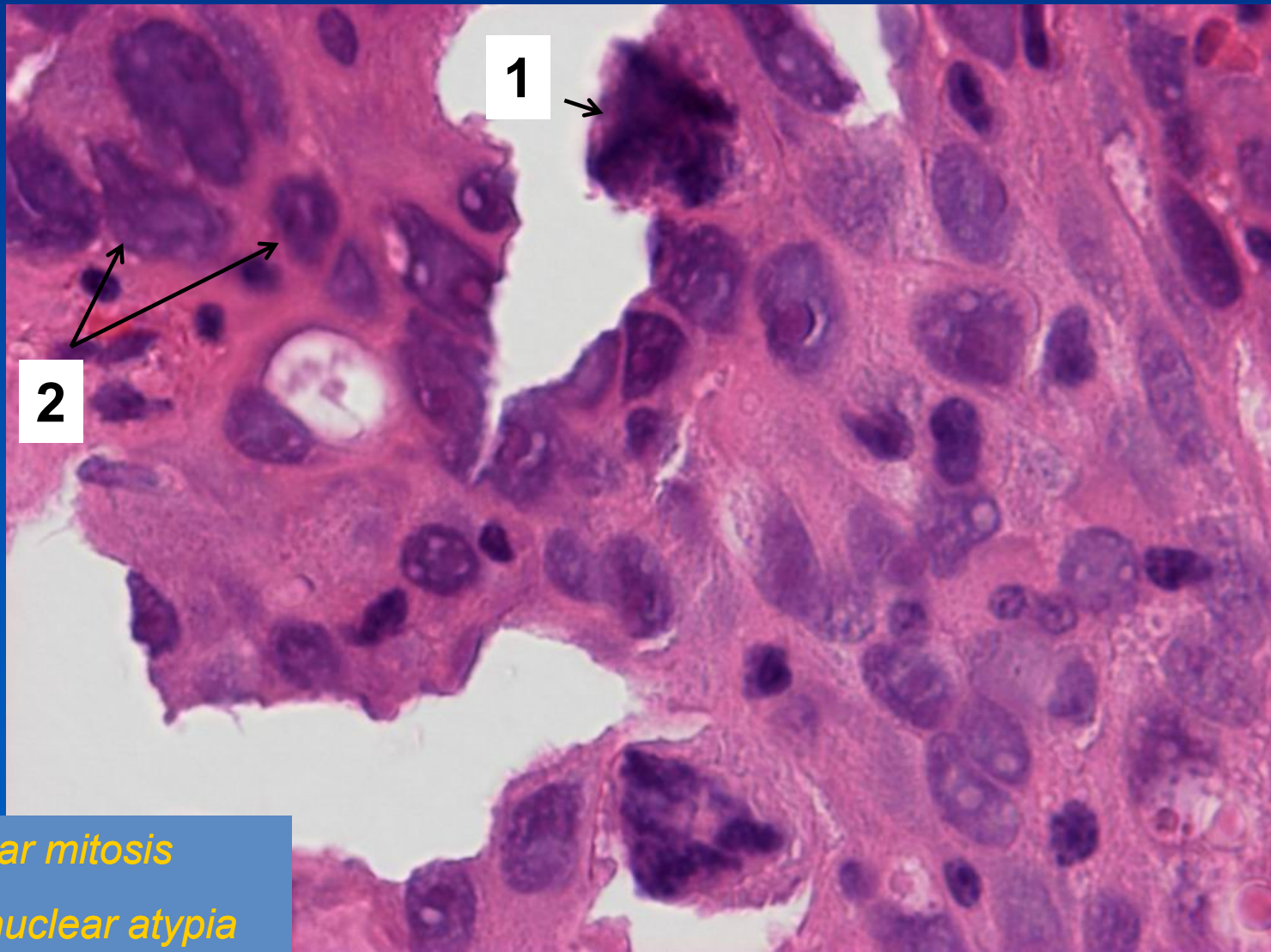
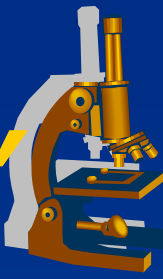
Papillary urothelial carcinoma, high grade



1. *Solid areas with residual papillary architecture*

2. *Fibrovascular stroma*

Papillary urothelial carcinoma, high grade

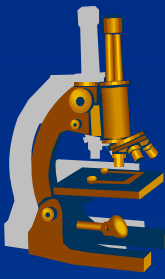


1

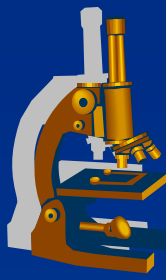
2

1. *Tripolar mitosis*

2. *Cytonuclear atypia*



Glandular epithelium tumors

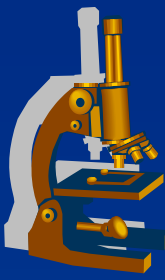


Glandular epithelium tumors

- × imitate various glandular structures

- × certain types with mucus production
 - ⇒ ***proof by histochemical staining methods:***
 - PAS (neutral mucopolysaccharides)
 - ALCIAN (acid mucopolysaccharides)

- × classification:
 - ⇒ ***adenoma***
 - benign tumors
 - tubular or villous adenoma, cystic adenoma (cystadenoma), follicular adenoma, solid adenoma, ...
 - ⇒ ***adenocarcinoma***
 - malignant tumors
 - tubular, acinar, trabecular adenocarcinoma, cystic adenocarcinoma (cystadenocarcinoma), mixed adenocarcinoma, undifferentiated carcinoma



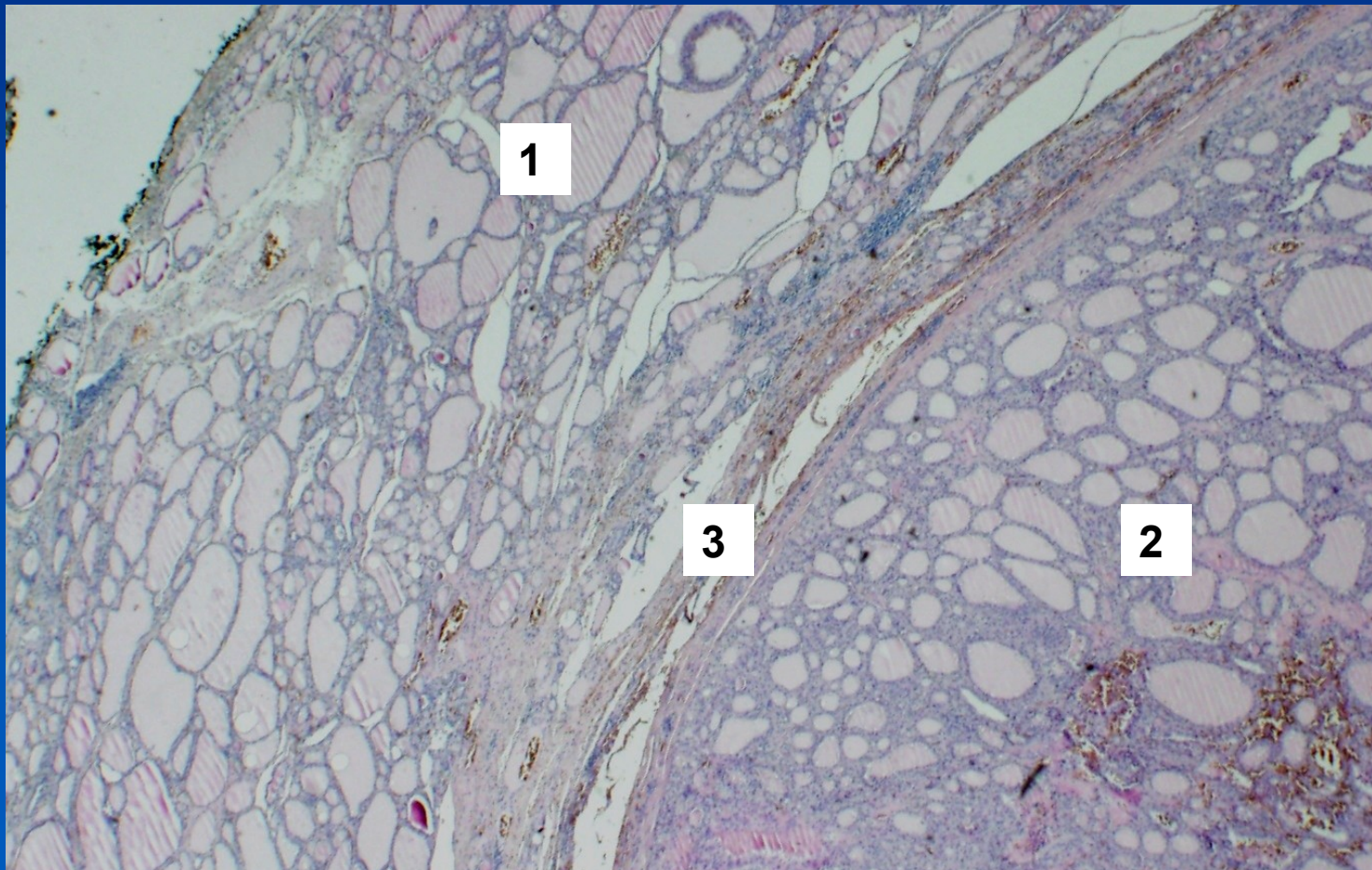
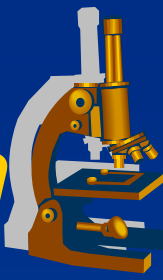
Benign glandular epithelium tumors

Follicular adenoma



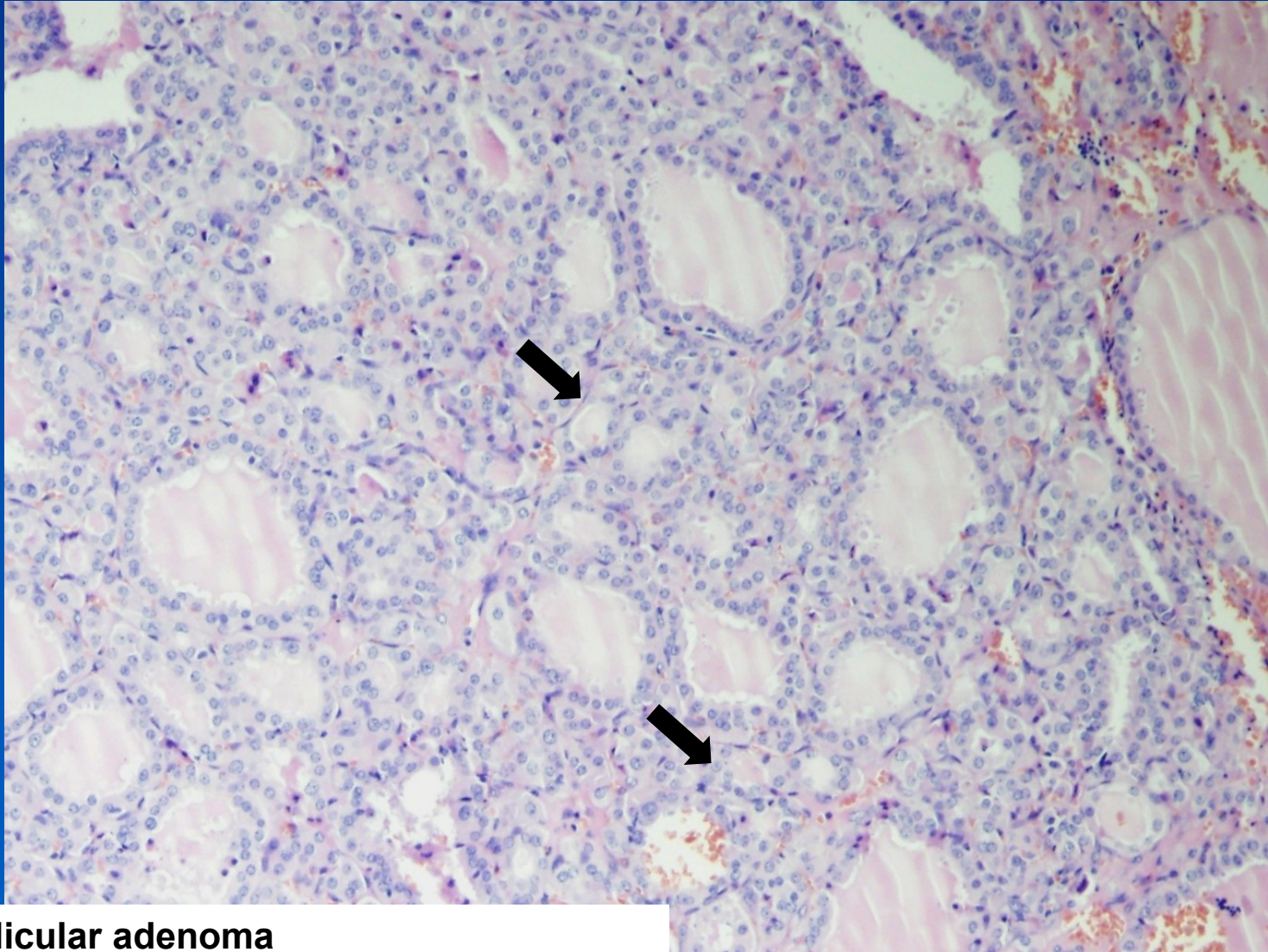
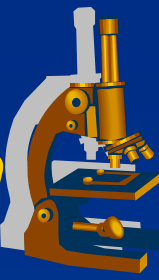
- × Mostly solitary
- × Encapsulated
- × pressure atrophy of adjacent parenchyma
- × diff. dg. × follicular carcinoma
 - ⇒ *similar histologic structure, transcapsular invasion into surrounding thyroid tissue and/or angioinvasion necessary for ca diagnosis*
- × Diagnosis possible only with complete biopsy

Follicular thyroid adenoma



- 1 thyroid parenchyma with follicles
- 2 structure of adenoma
- 3 Fibrotic capsule (adenoma)

Follicular thyroid adenoma



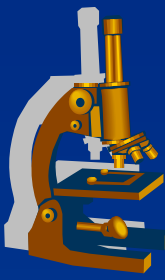
➔ microfollicular adenoma

Polyps



- ✗ gross descriptive term
- ✗ pedunculated or sessile
- ✗ classification:
 - ⇒ *non-neoplastic*
 - ⇒ *neoplastic*
- ✗ they can be:
 - ⇒ *solitary*
 - ⇒ *multiple*
 - ⇒ *numerous (> 100 = polyposis)*

Non-neoplastic polyps of the GIT (see PSP3)



x without malignant potential

x 3 basic types:

⇒ ***hyperplastic polyps***

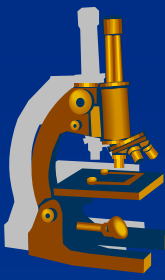
⇒ ***juvenile polyps***

- mostly in children
- also juvenile polyposis syndrome

⇒ ***Peutz-Jeghers polyps***

- uncommon hamartomatous polyps
- or Peutz-Jeghers syndrome (AD)
 - multiple polyps in the GIT

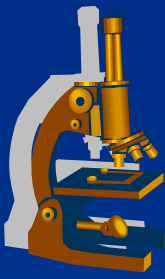
Neoplastic polyps – adenomas (GIT)



- ✗ adenomas arise as the result of epithelial proliferation and dysplasia

- ✗ adenocarcinomas mostly arise in preexisting adenomatous lesions

Neoplastic polyps - adenomas



xMicro:

⇒ *epithelial dysplasia*

⇒ *tall cells with darker cytoplasm (lack of mucus)*

⇒ *darker, elongated nuclei, hyperchromasia,
distinct nucleoli*

⇒ *mitoses*

Neoplastic polyps - adenomas



✘ subtypes of GIT adenomas according to the epithelial architecture:

⇒ ***tubular***

- mostly pedunculated, > 75% tubular glandular architecture

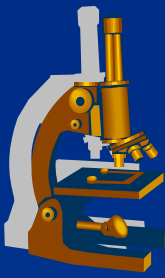
⇒ ***villous***

- often sessile, finger-like projections, > 50% villous structure

⇒ ***tubulovillous***

- 25 – 50% villous component

Neoplastic polyps - adenomas



x risk of malignant transformation depends on:

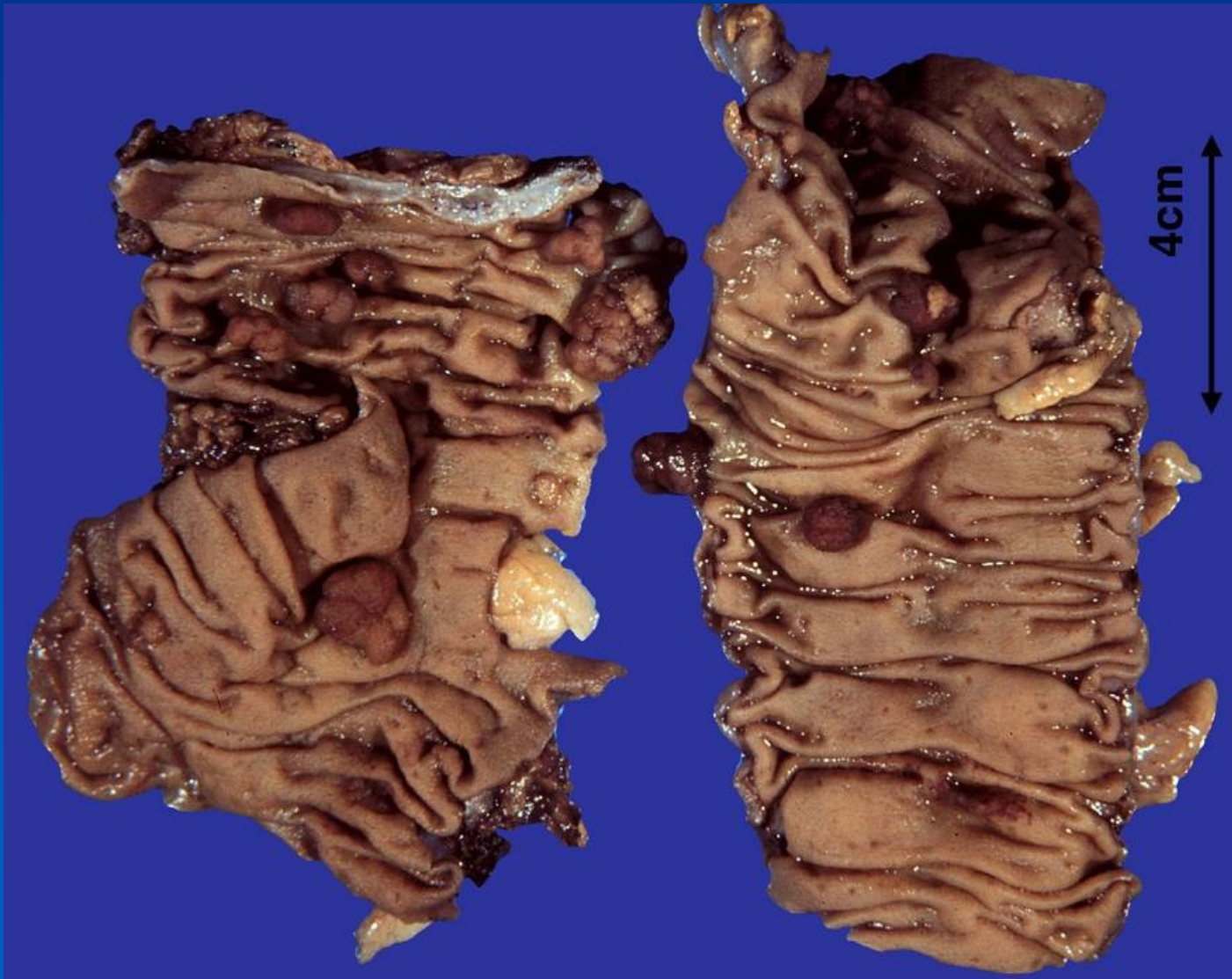
⇒ ***polyp size***

⇒ ***histologic type***

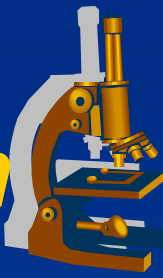
⇒ ***severity of epithelial dysplasia***

- worse in large villous polyps

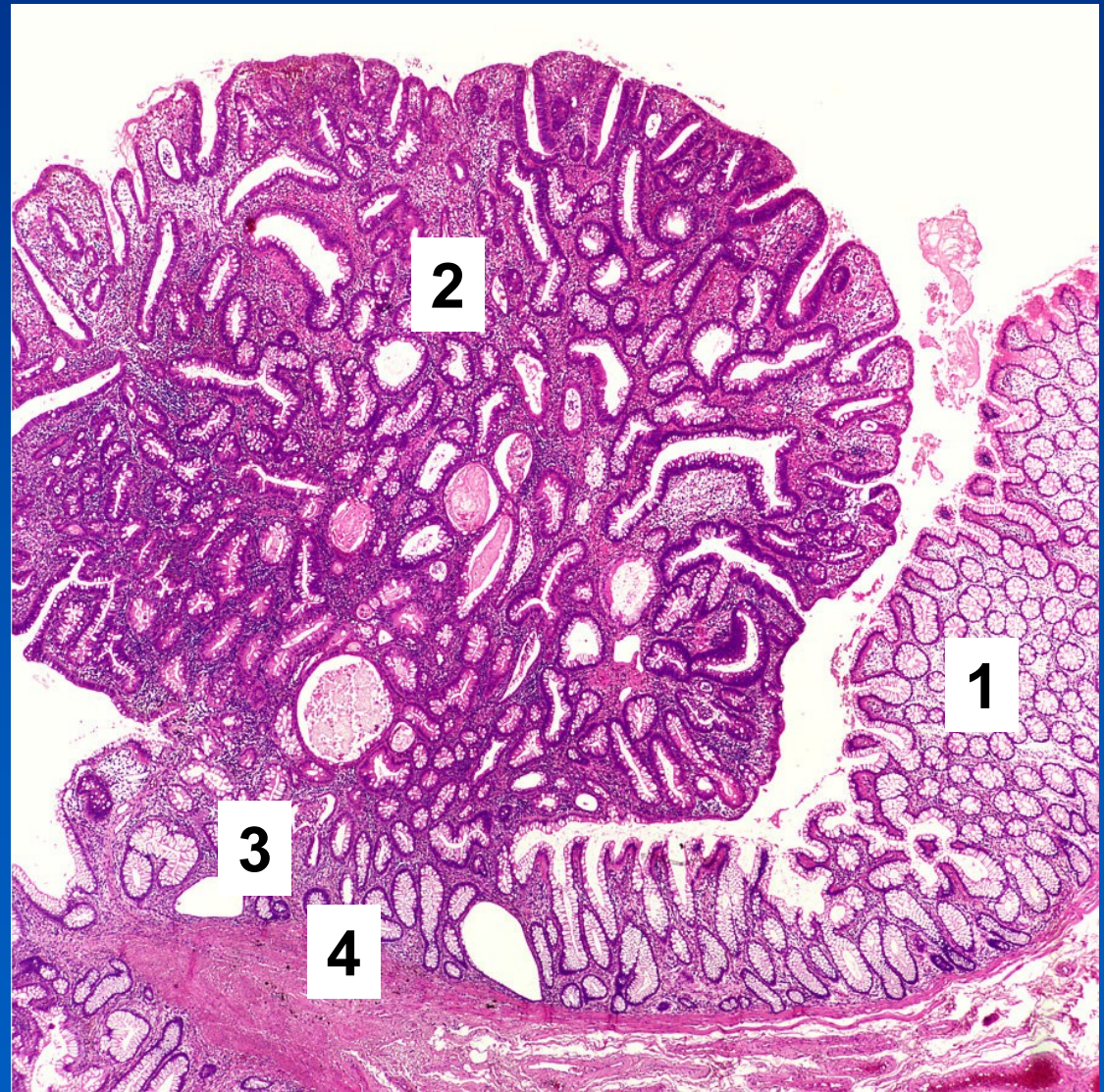Neoplastic polyps - adenomas



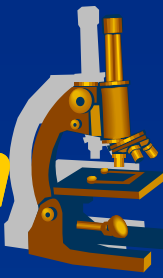
Tubular adenoma of the colon



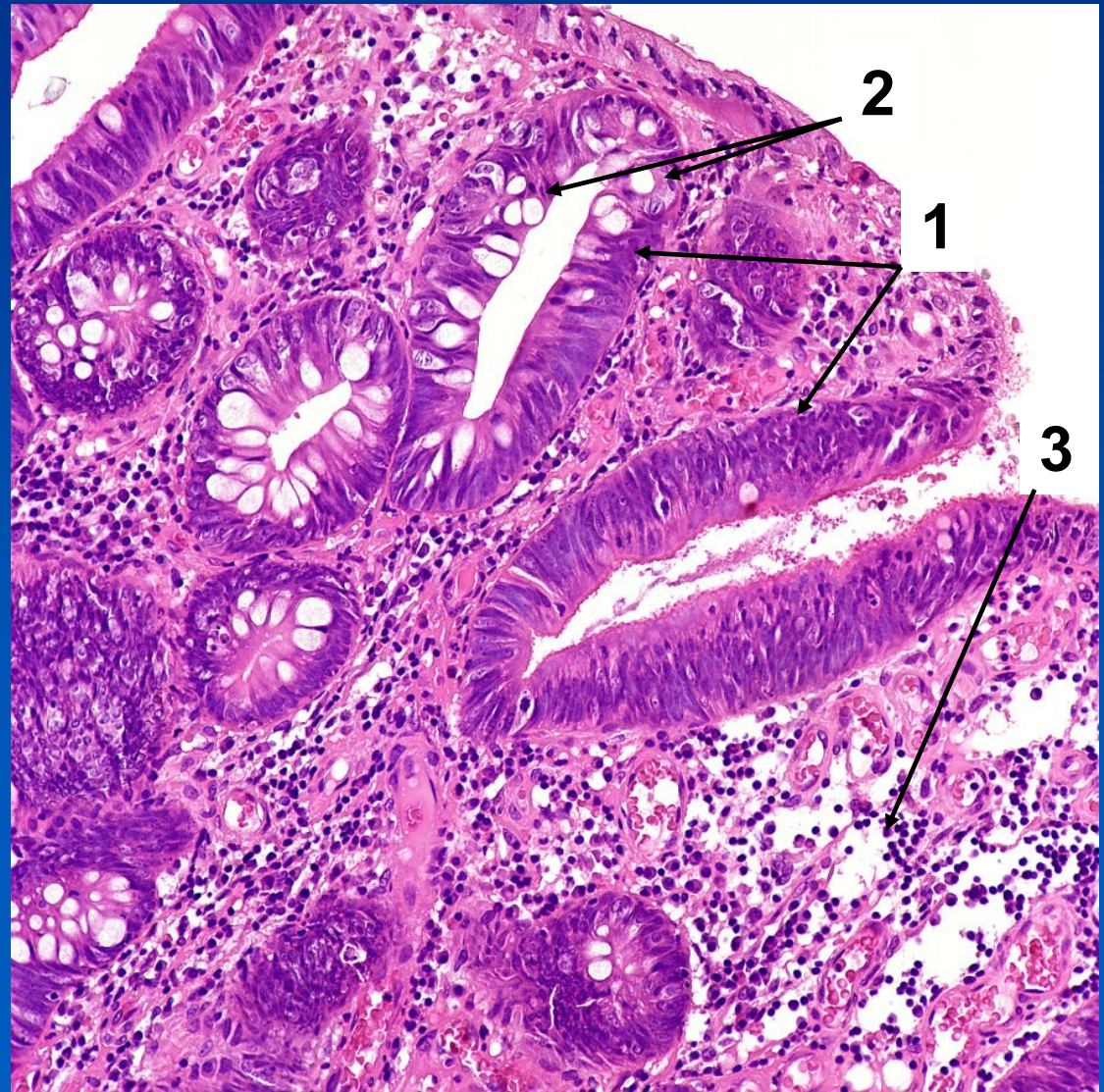
1. *Colonic mucosa*
2. *Pedunculated tubular adenoma*
3. *Stalk*
4. *Lamina muscularis mucosae*

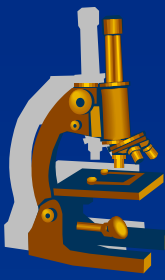


Tubular adenoma of the colon



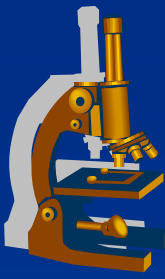
- 1. Low and high grade dysplastic changes*
- 2. Goblet cells*
- 3. Mucosal stroma with inflammatory infiltrate*





Malignant glandular epithelium tumors

Adenocarcinomas



✘ General adenocarcinoma structure/consistency:

⇒ *medullary*

- more tumor cells, less stroma

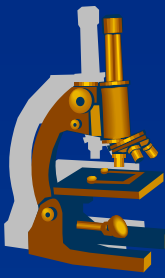
⇒ *scirrhous*

- more desmoplastic stroma

⇒ *simple*

- balanced ratio of stroma and tumor cells

Adenocarcinomas



✗ Examples of adenocarcinoma structure in the GIT:

⇒ *intestinal (tubular)*

⇒ *diffuse (scirrhous)*

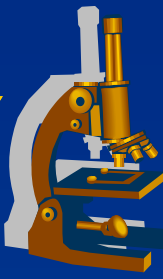
⇒ *gelatinous (mucinous)*

Adenocarcinoma - intestinal type



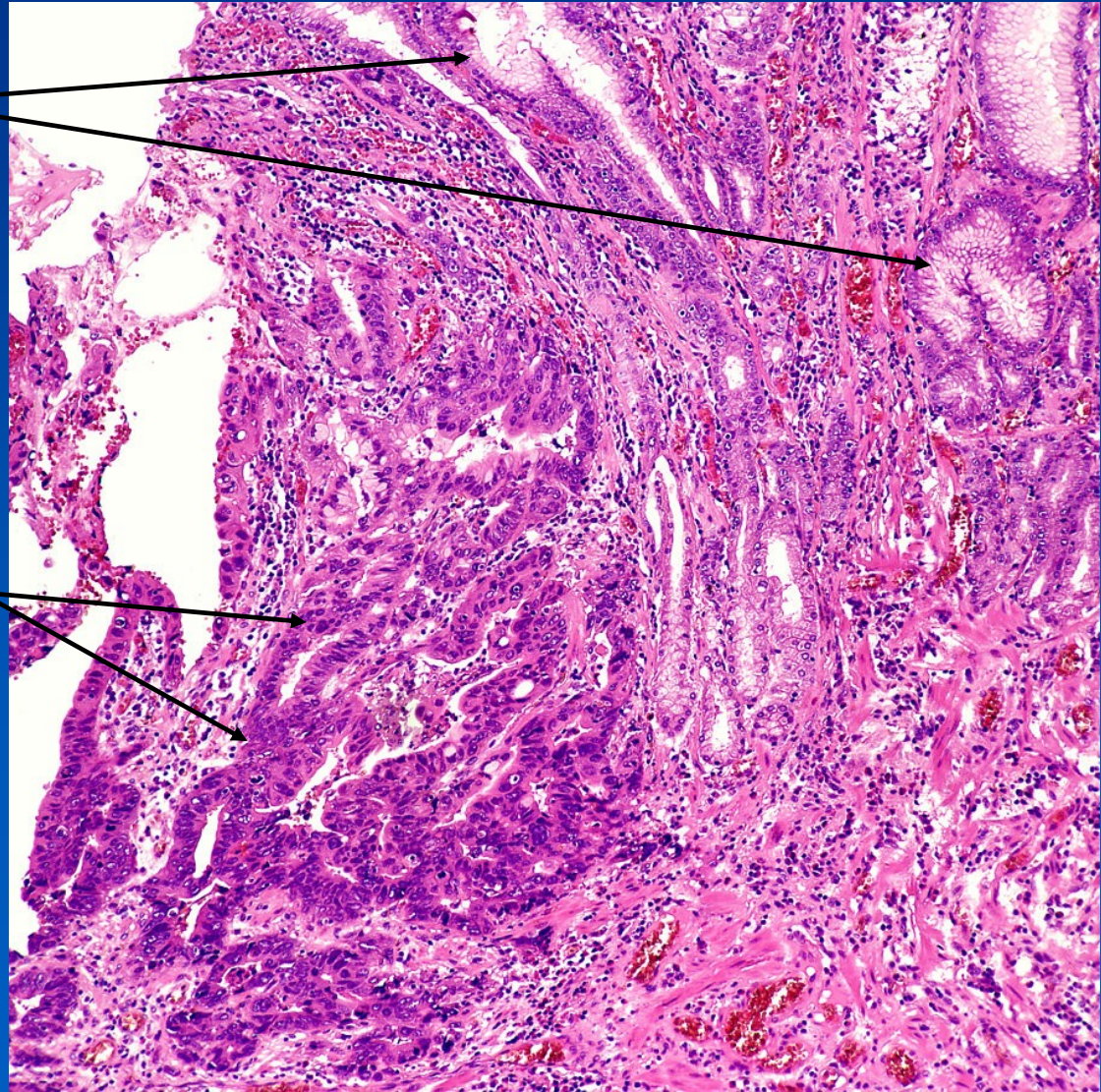
- ✗ tubular/glandular structure
- ✗ invasive growth (+/- destruction) into the wall
- ✗ increased mitotic activity
- ✗ tumor glands of irregular in shape and size
- ✗ variable mucus production
 - ⇒ *extracellular*
 - ⇒ *intracellular*

Adenocarcinoma, moderately differentiated, tubular

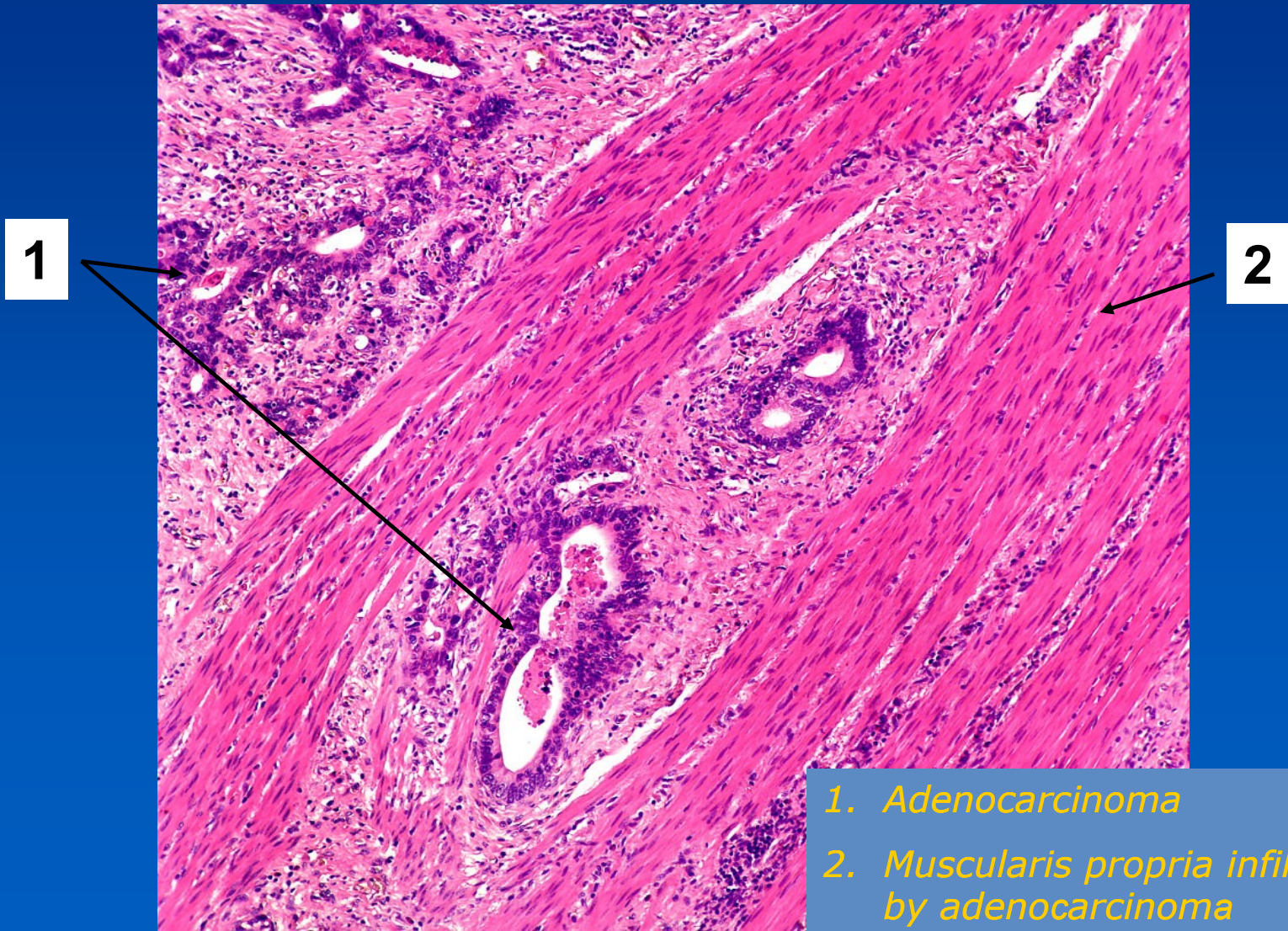


Peripheral non-neoplastic epithelium

Invasive, moderately differentiated tubular adenocarcinoma

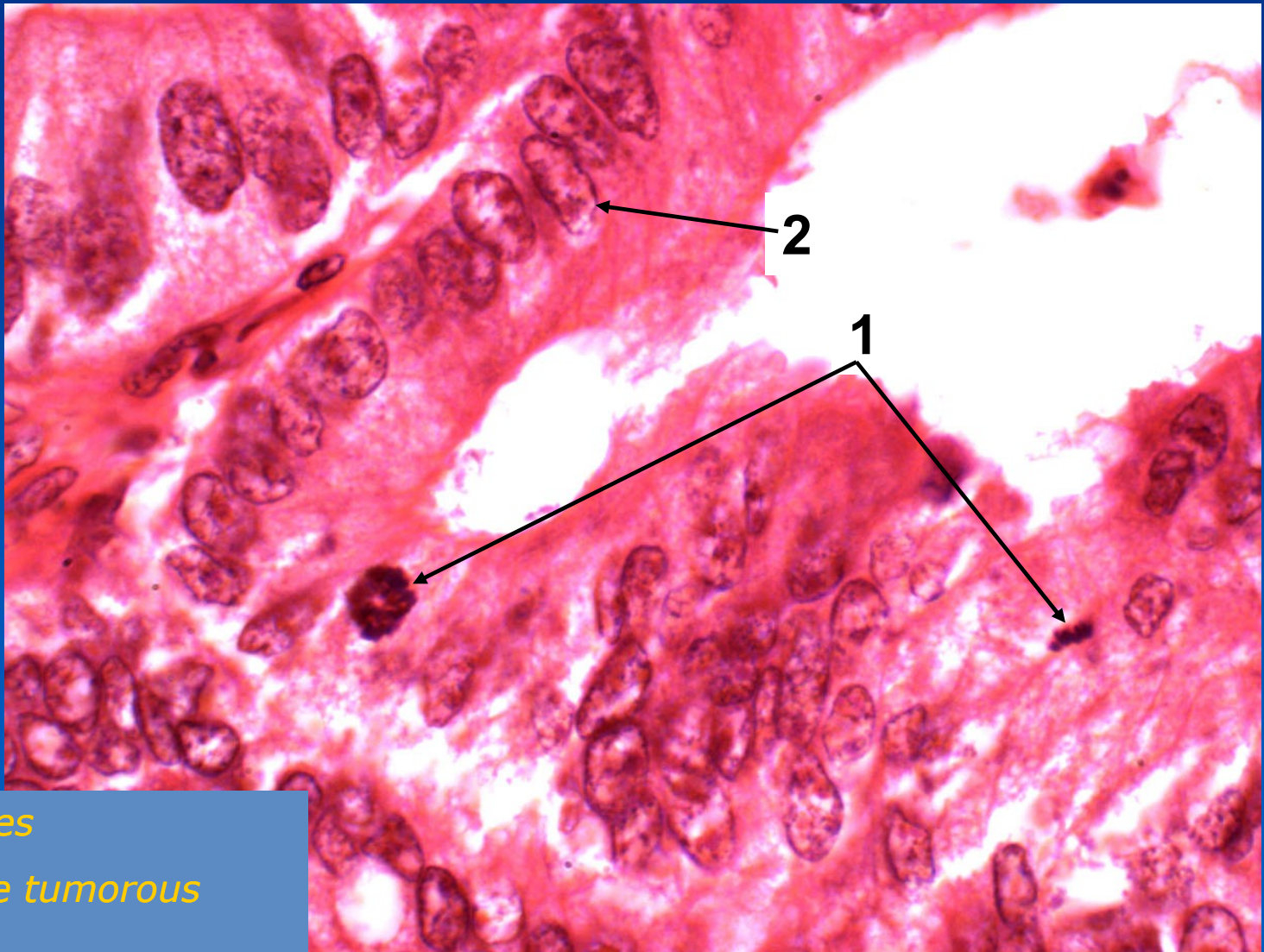


Adenocarcinoma infiltrating the muscularis propria



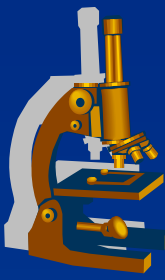
1. Adenocarcinoma
2. Muscularis propria infiltrated by adenocarcinoma

Tubular adenocarcinoma in detail



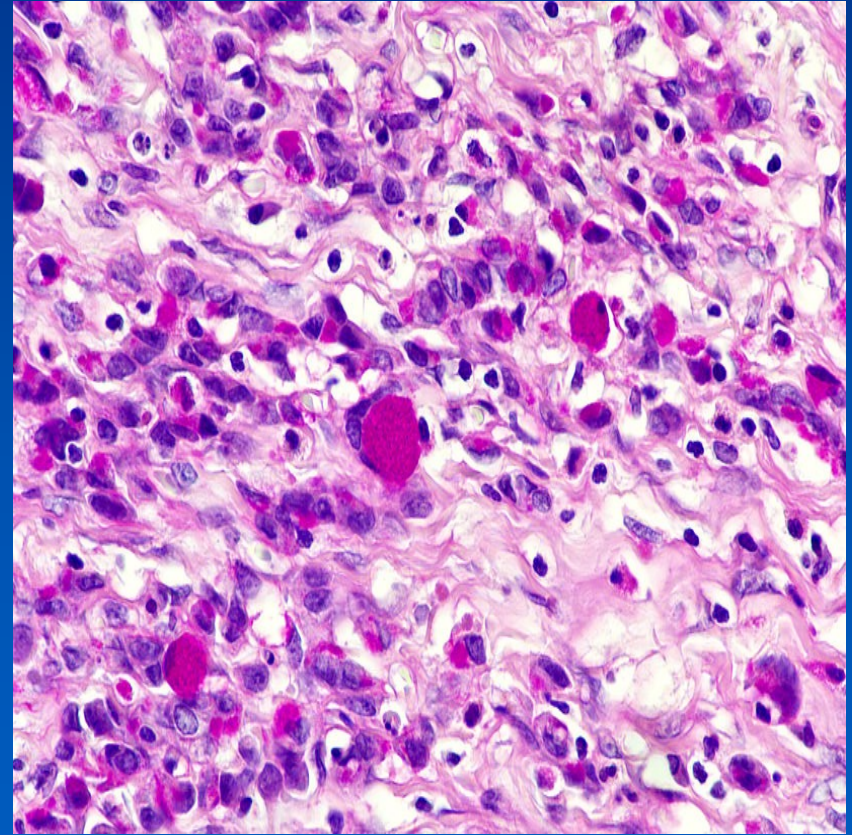
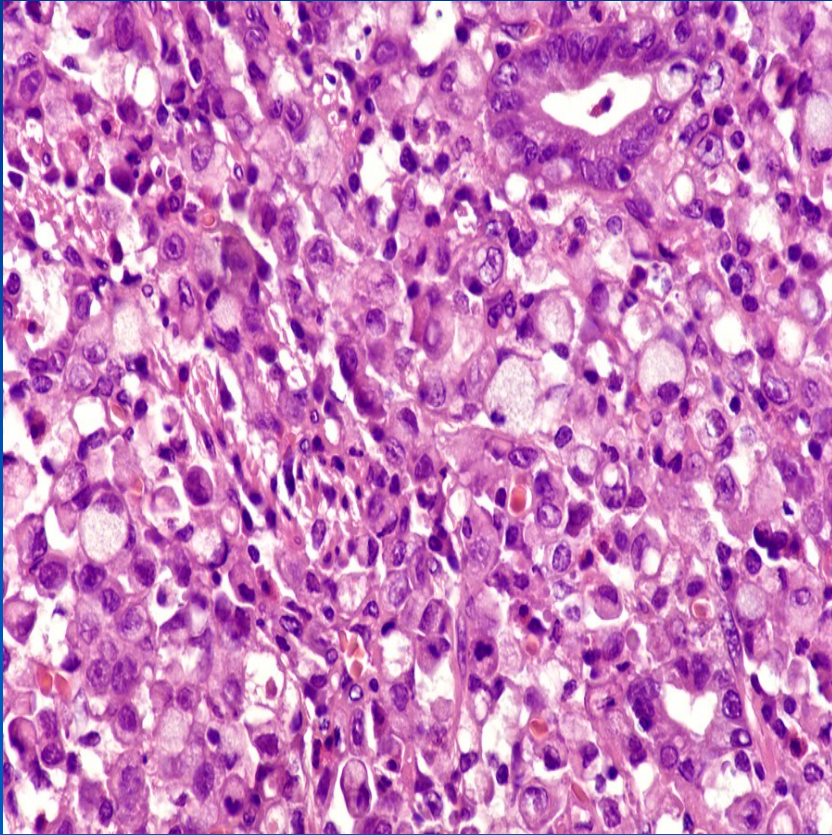
- 1. Mitotic figures*
- 2. Atypia of the tumorous epithelium*

Diffuse adenocarcinoma

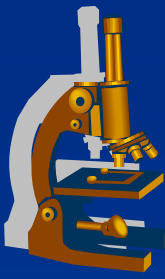


- ✗ discohesive tumor cells in small groups or isolated
- ✗ signet-ring cells
- ✗ increased amount of interstitial fibrous tissue
- ✗ desmoplastic stromal reaction
- ✗ scirrhous adenocarcinoma with prevalent stroma
 - ⇒ *tough consistence*

Diffuse adenocarcinoma

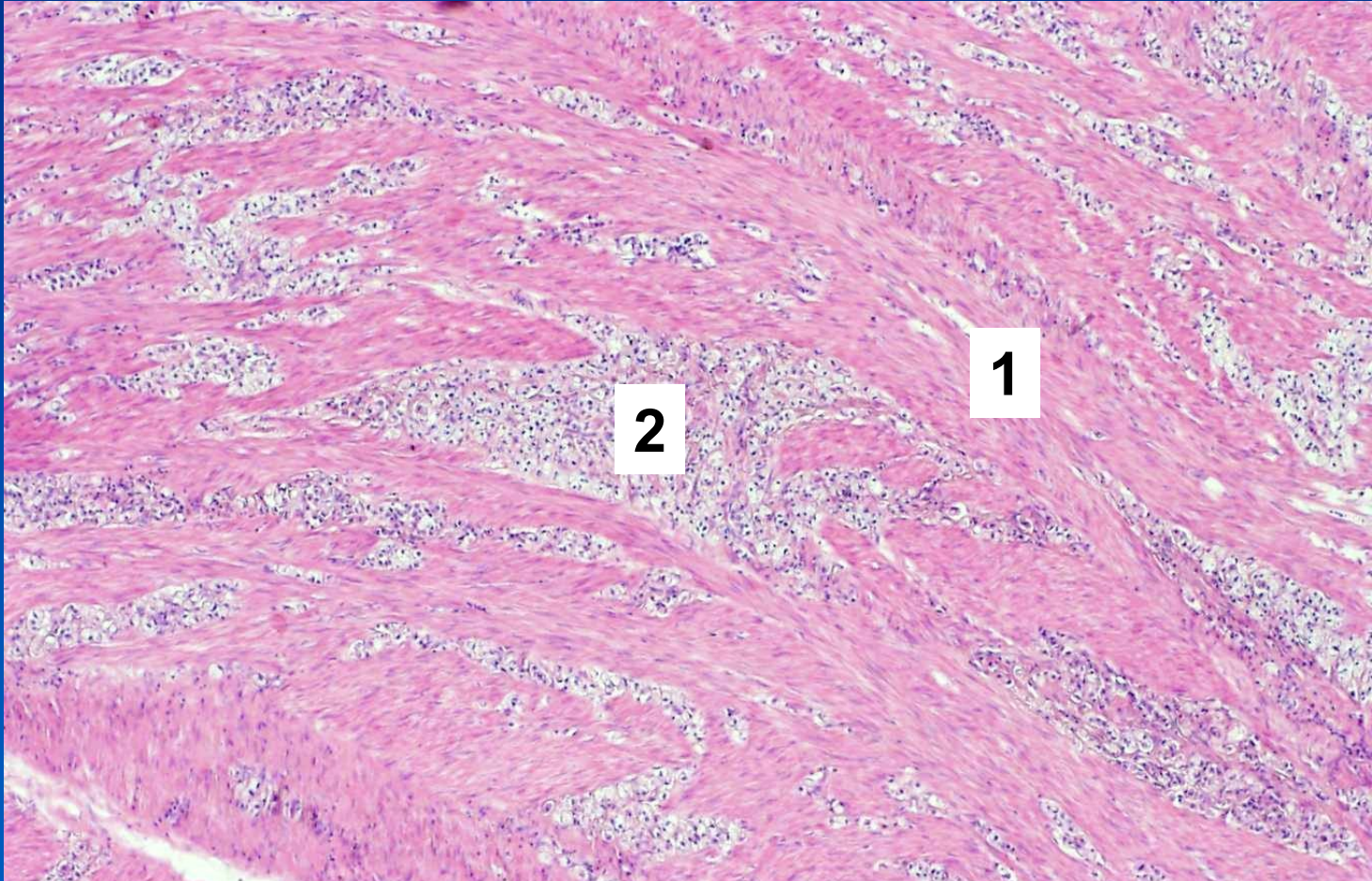


Gelatinous adenocarcinoma



- × jelly-like consistence
- × extensive extracellular production of epithelial mucus, mucin lake formation
- × intracellular mucus production with ***signet ring cells***:
 - ⇒ large cytoplasmic mucin vacuole displaces nucleus to the periphery of the cell
- × possible disperse tumor cells in mucin lakes

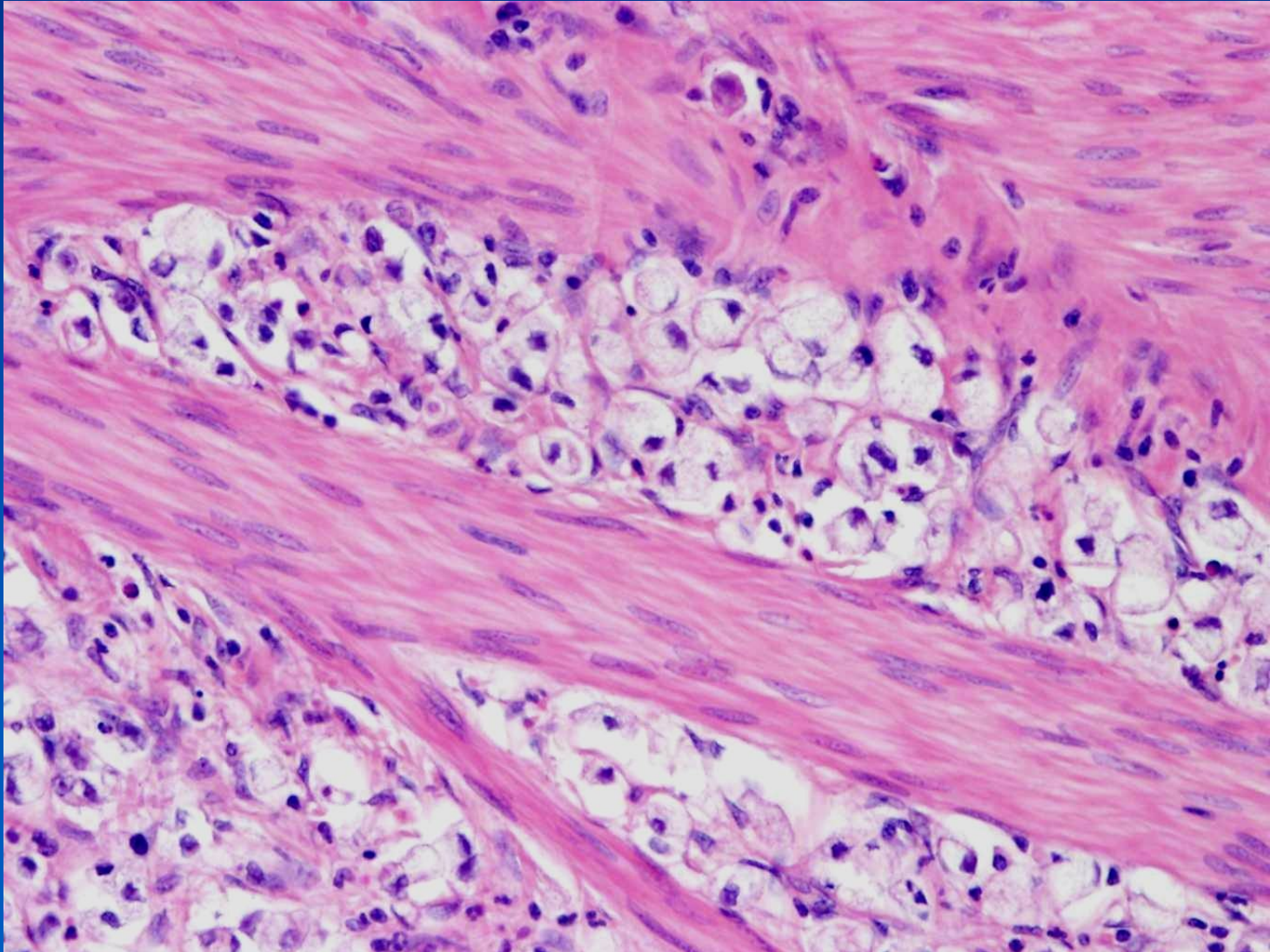
Signet-ring cells infiltrating the muscularis propria



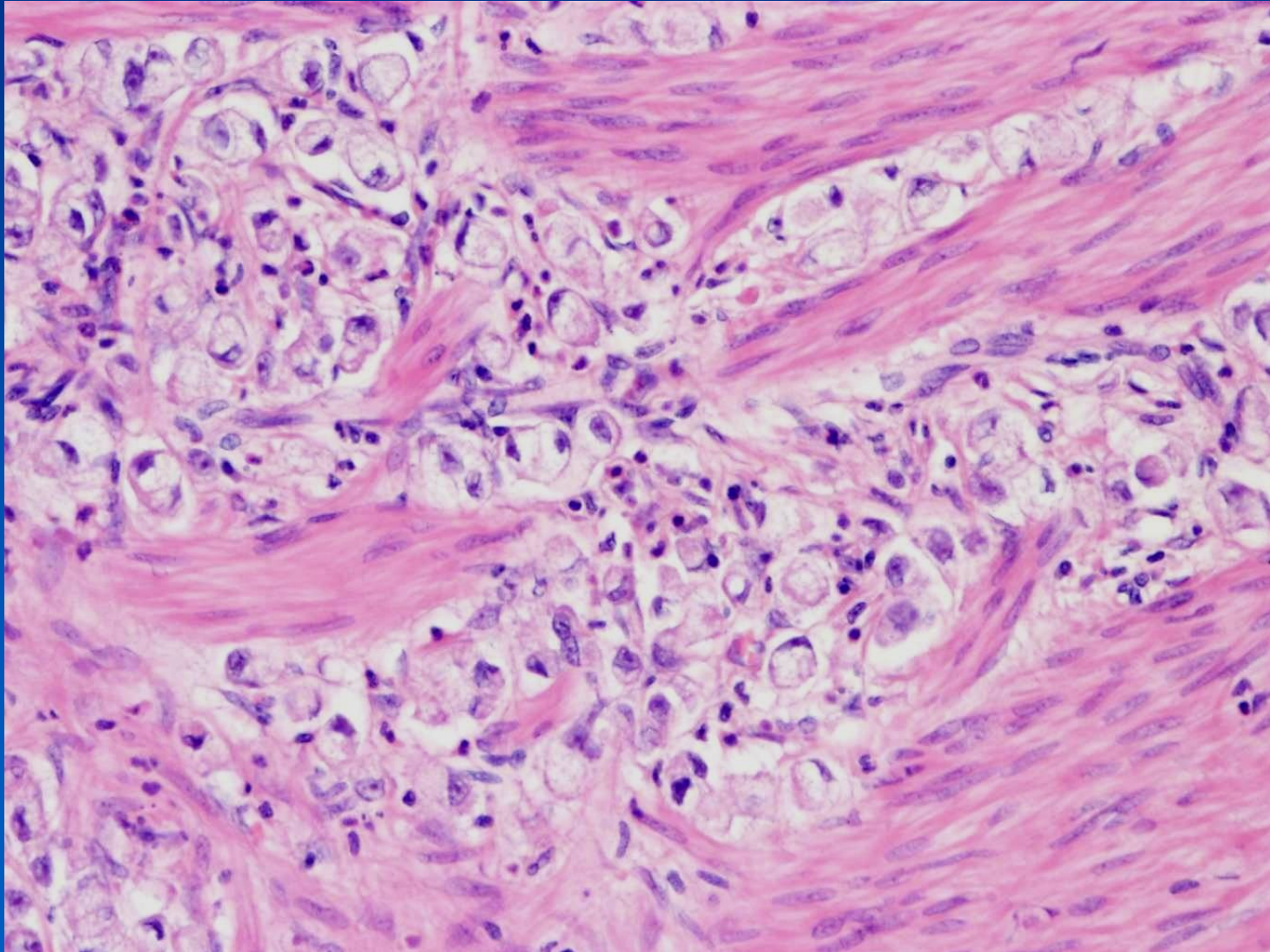
1. *Muscularis propria*

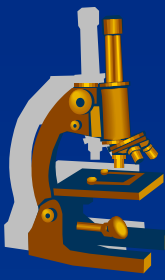
2. *Signet-ring cells infiltrating the muscularis propria*

Signet-ring cells in detail



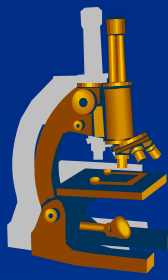
Signet-ring cells in detail





Hepatocellular carcinoma

- ✘ 5th worldwide the most common malignancy in males, 8th in females
- ✘ Makro:
 - ⇒ *multinodular form:*
 - multiple circular bearings in both lobes
 - ⇒ *massive form:*
 - large bulky node with small satellite deposits
 - ⇒ *difusse form:*
 - multiple small deposits pervading almost the entire liver



Hepatocellular carcinoma

✘ Micro:

⇒ *architecture:*

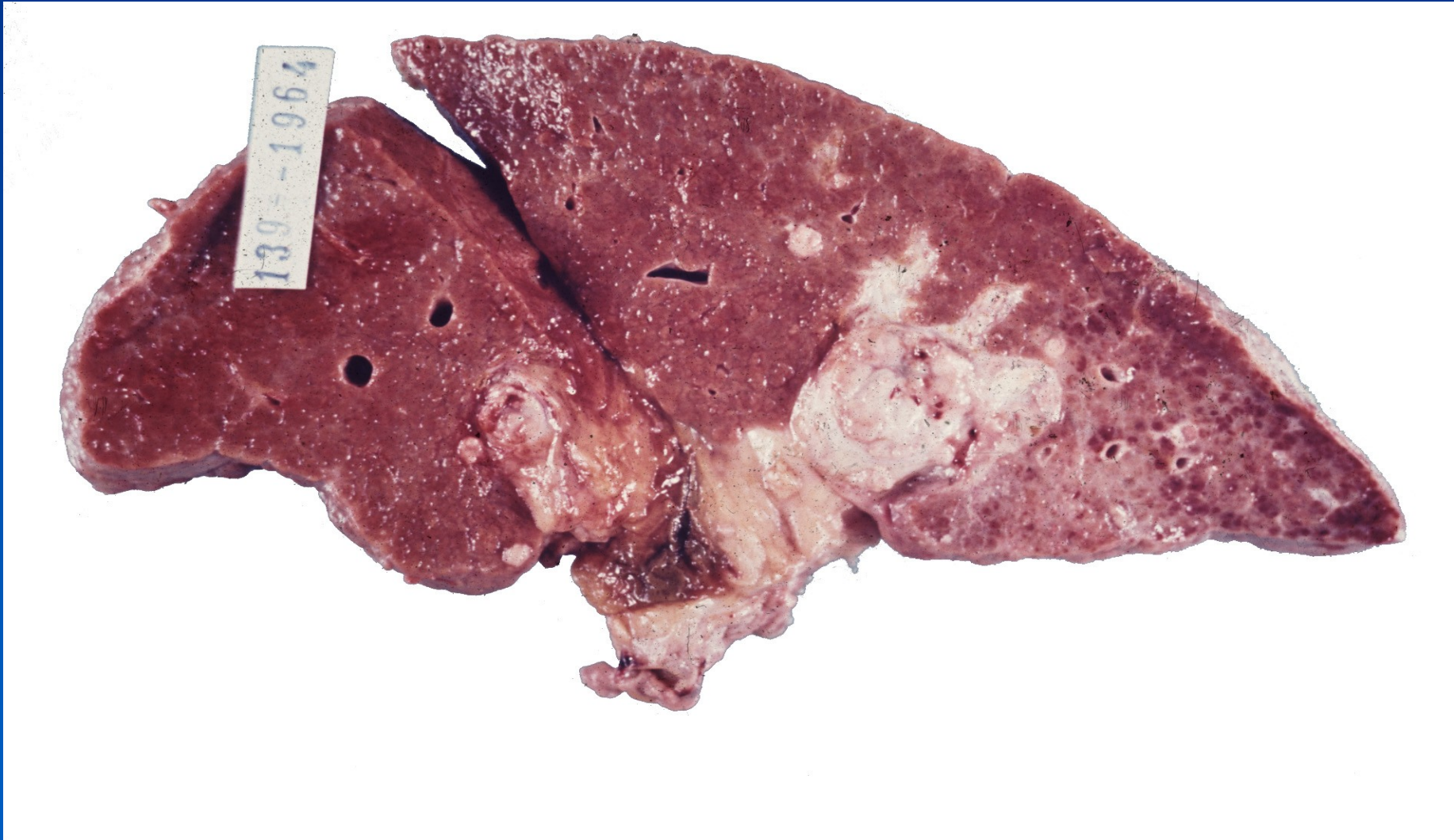
- trabecular
- acinar +/- pseudoglandular
- solid

⇒ *cytology tumors cells:*

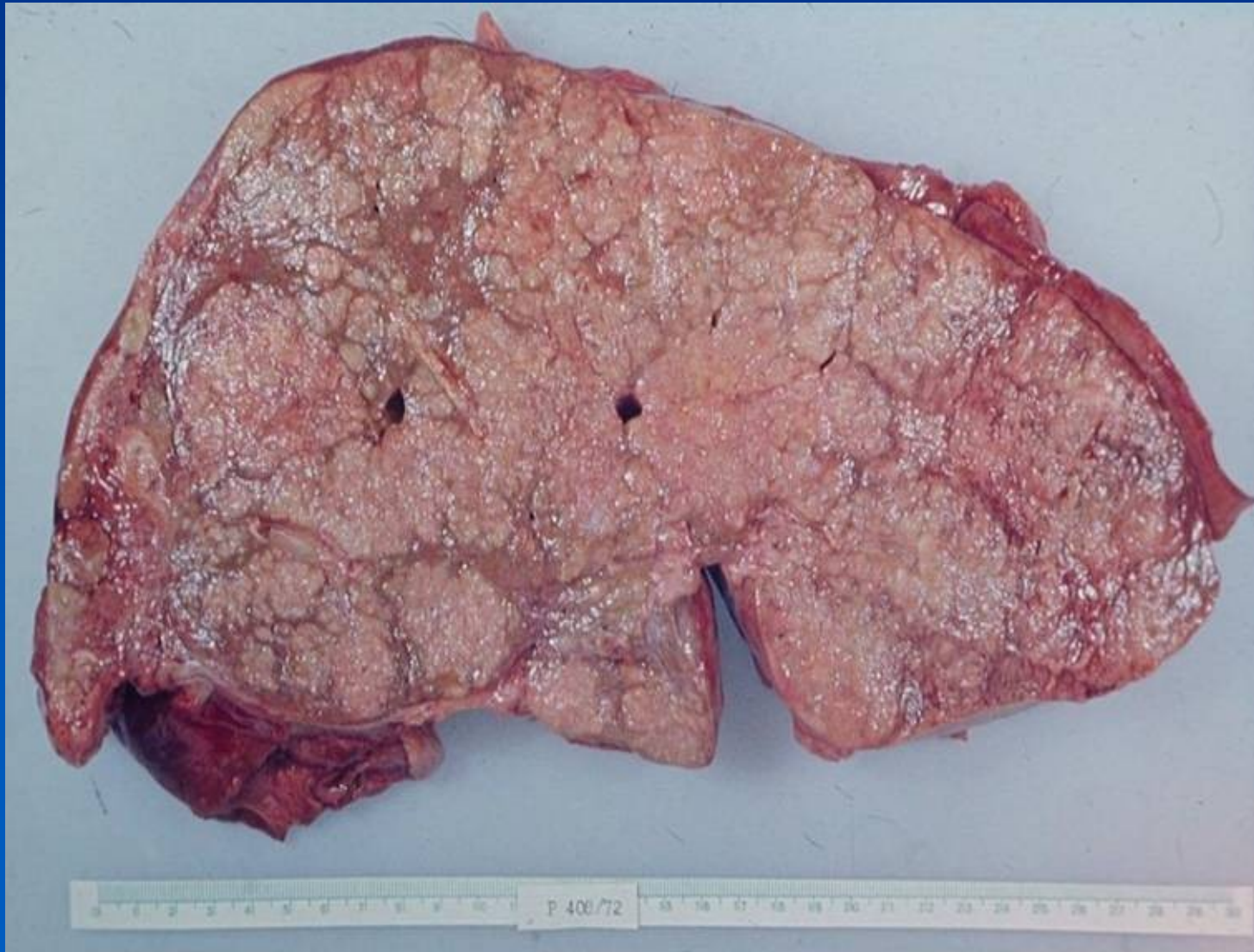
- enlarged nuclei + nucleoli
- ↑ mitotic activity, atypias
- eosinophilic – pale cytoplasm

⇒ *Possible steatosis, bile production*

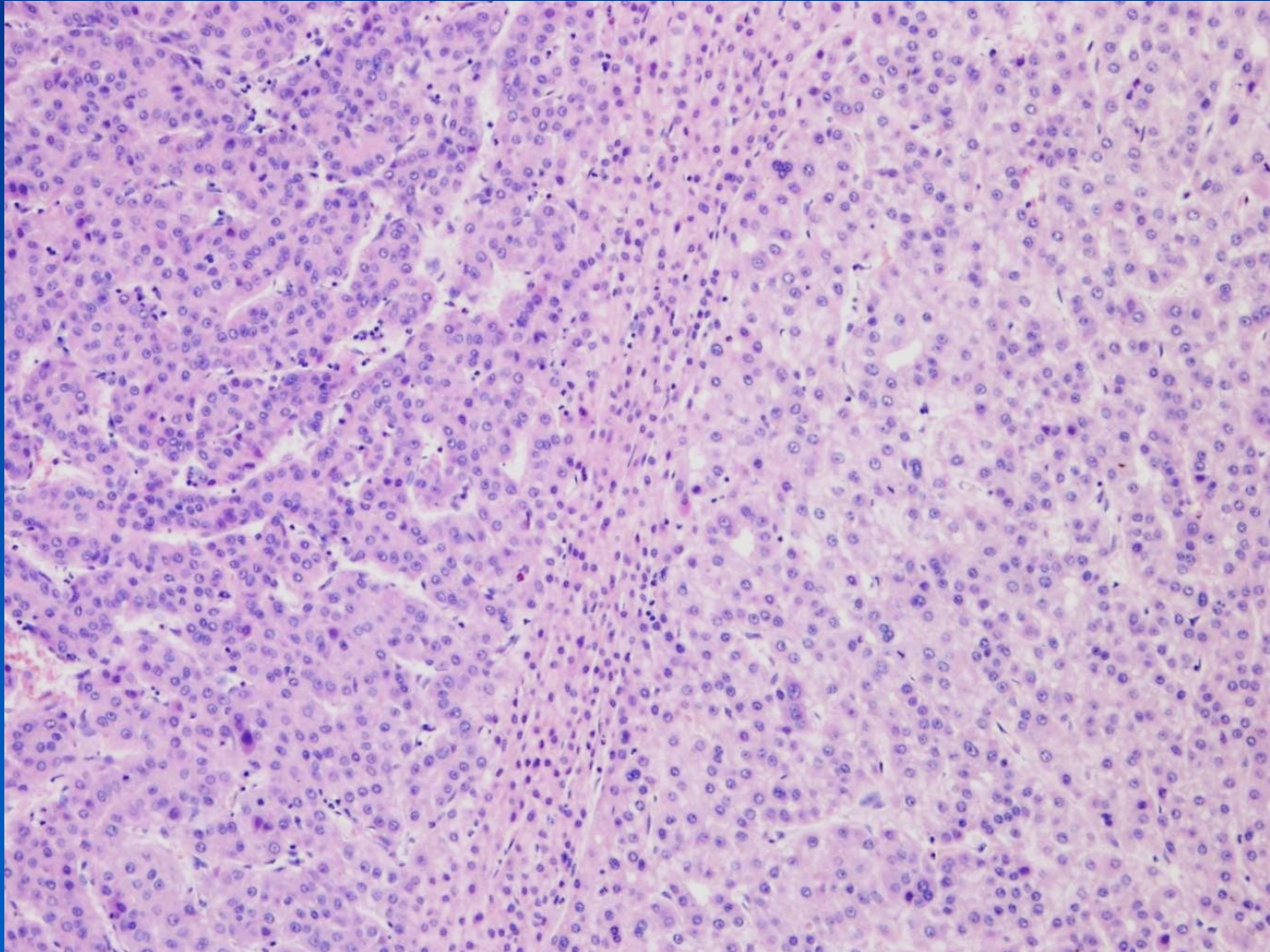
Hepatocellular carcinoma – massive form



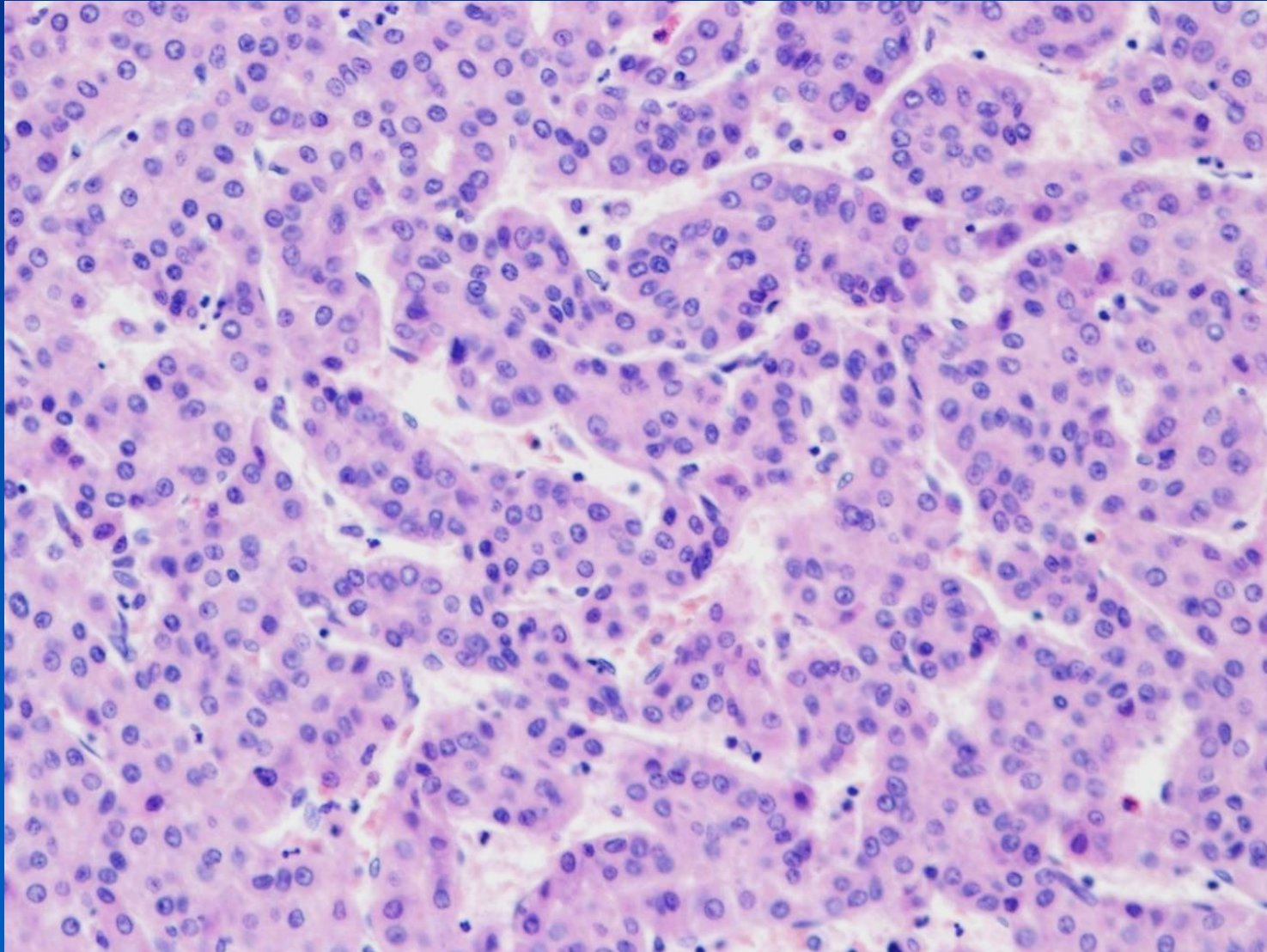
Hepatocellular carcinoma – difusse form



Hepatocellular carcinoma – trabecular arrangement



Hepatocellular carcinoma – trabecular arrangement



Clear cell carcinoma



✗ common form of renal cell carcinoma
⇒ *derived from the epithelium of proximal tubules*

✗ eponym: *Grawitz tumor*

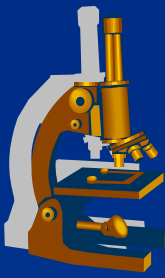
✗ Gross:

⇒ *variable form, commonly well-demarcated*

⇒ *variegated on cut section:*

- yellow (lipids)
- red (hemorrhage)
- grey (fibrous tissue)

Clear cell carcinoma



x **Micro:**

⇒ ***variable architecture:***

- compact-alveolar, trabecular, tubular, cystopapillary

⇒ ***polygonal cells with clear (watery) cytoplasm***

- glycogen and lipid deposits, dissolved during processing

⇒ ***round nuclei***

- Fuhrman nuclear grading (I-IV)

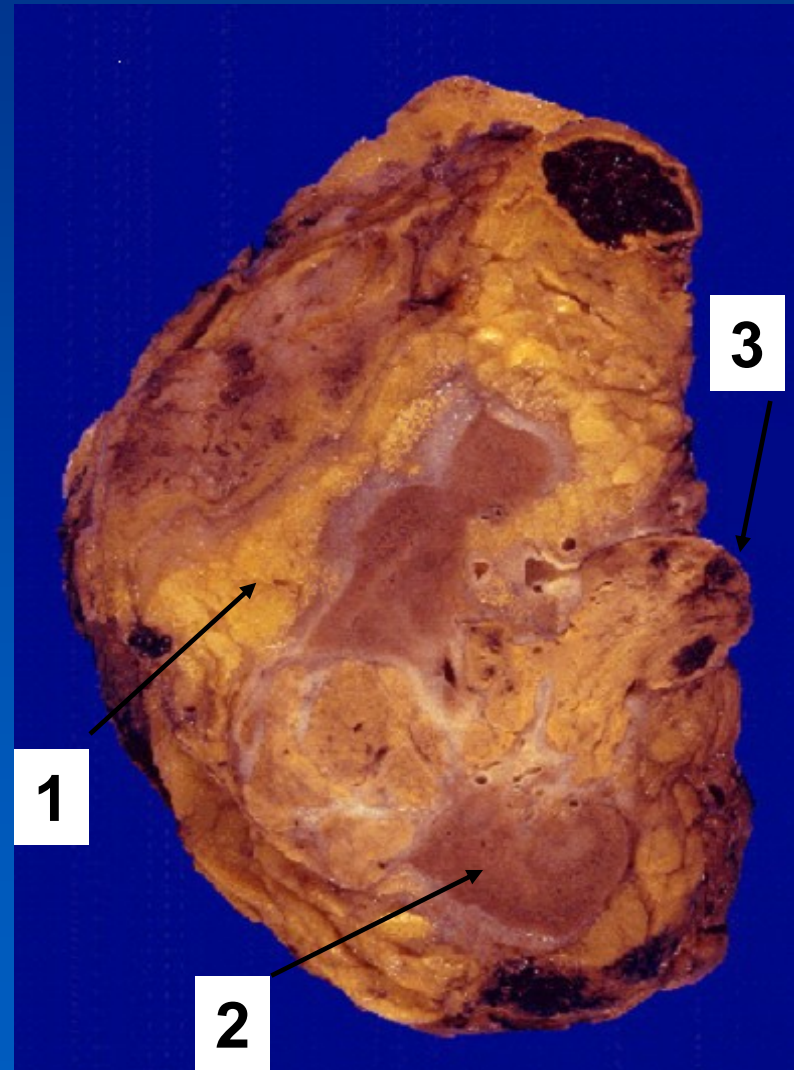
⇒ ***distinctive cell membrane (plant-like)***

⇒ ***low amount of fibrovascular stroma***

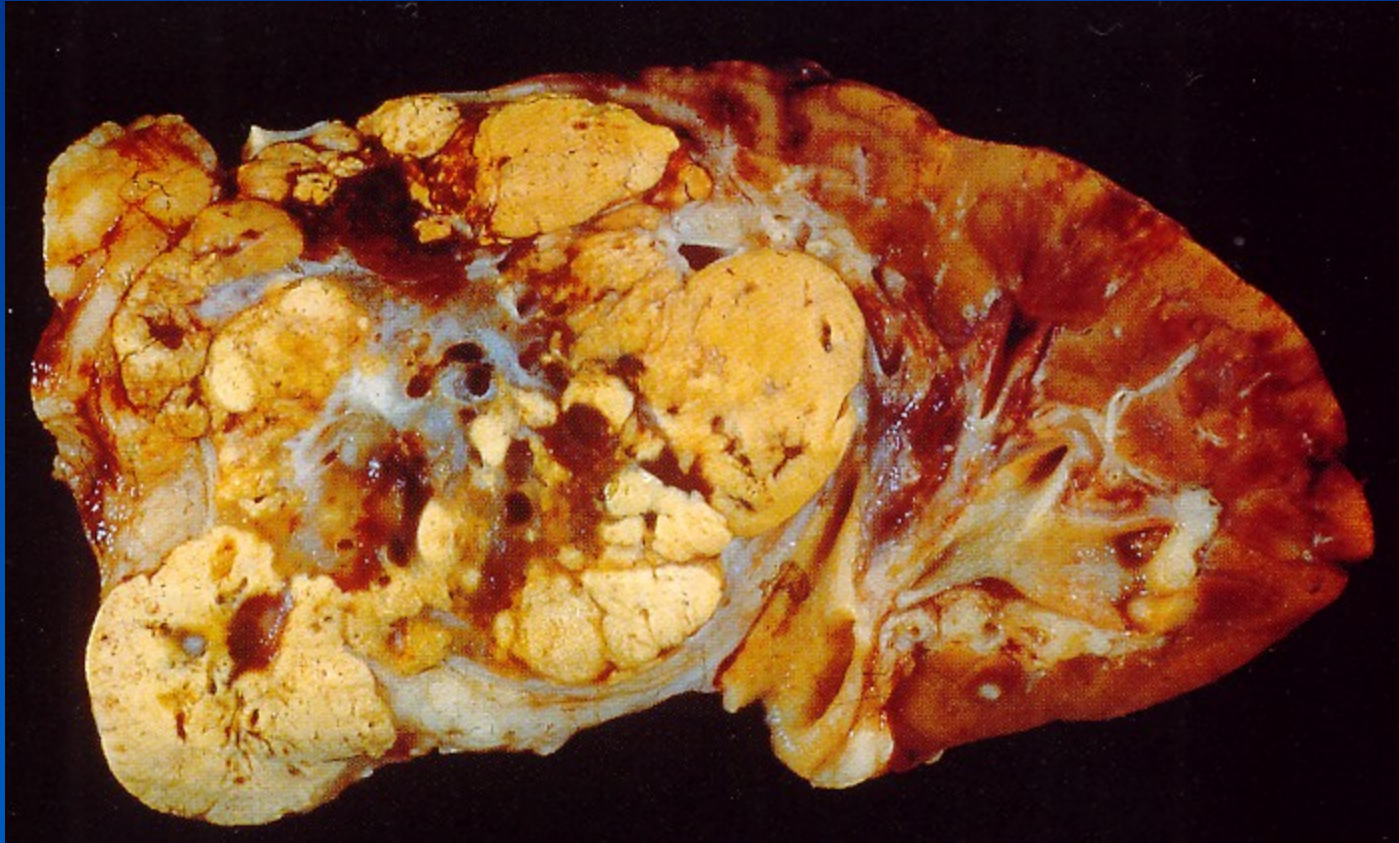Clear cell carcinoma



- 1. Tumor*
- 2. Residual renal parenchyma*
- 3. Tumor invading the renal vein*



Clear cell carcinoma



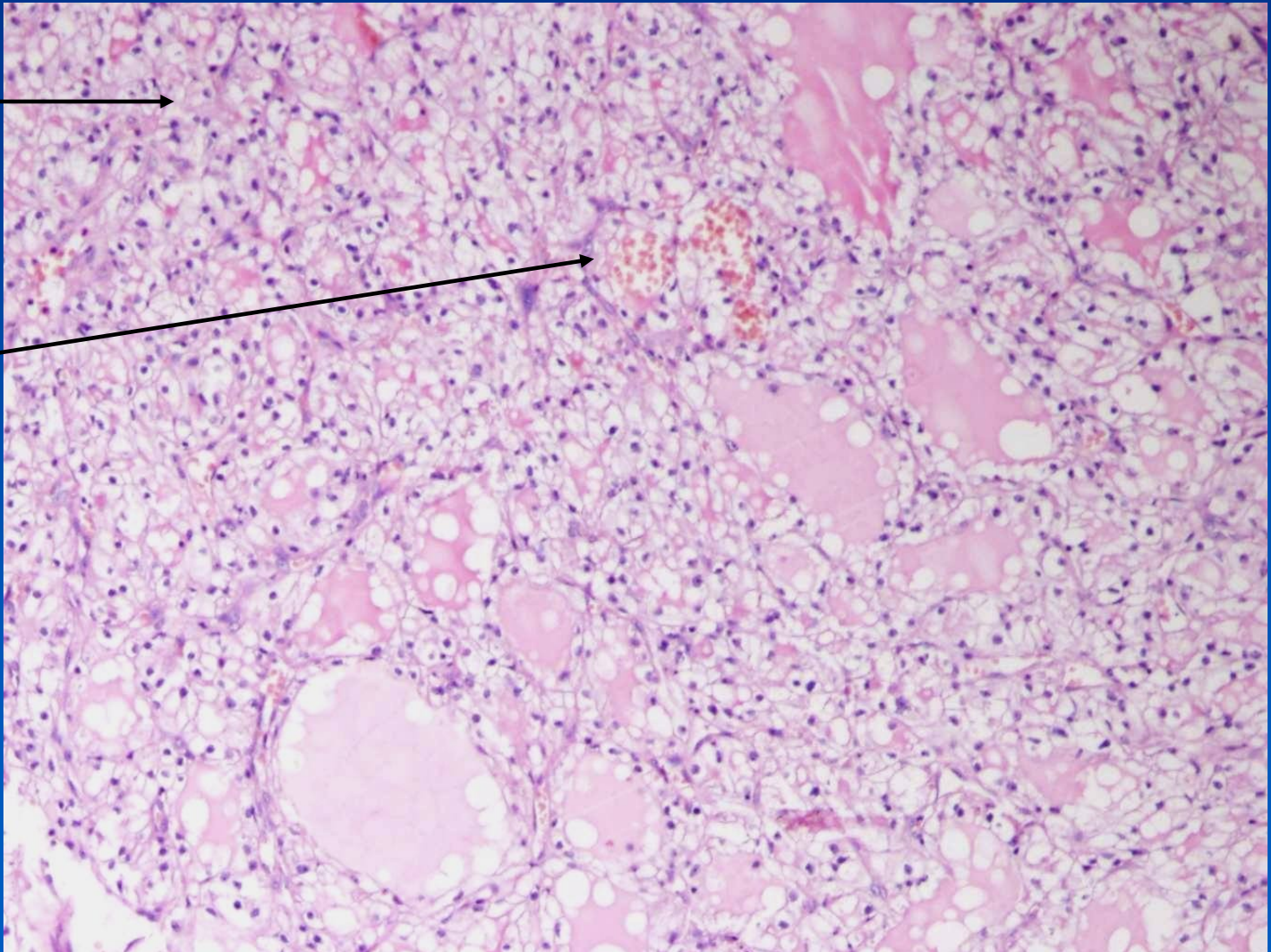
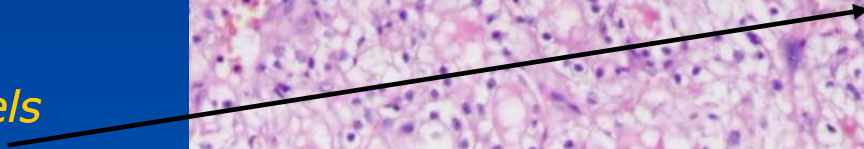
Clear cell carcinoma



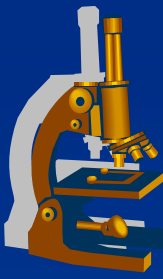
Tumor cells



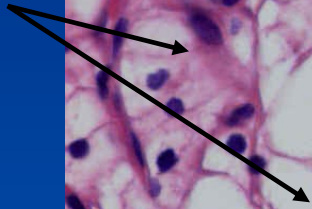
Vessels



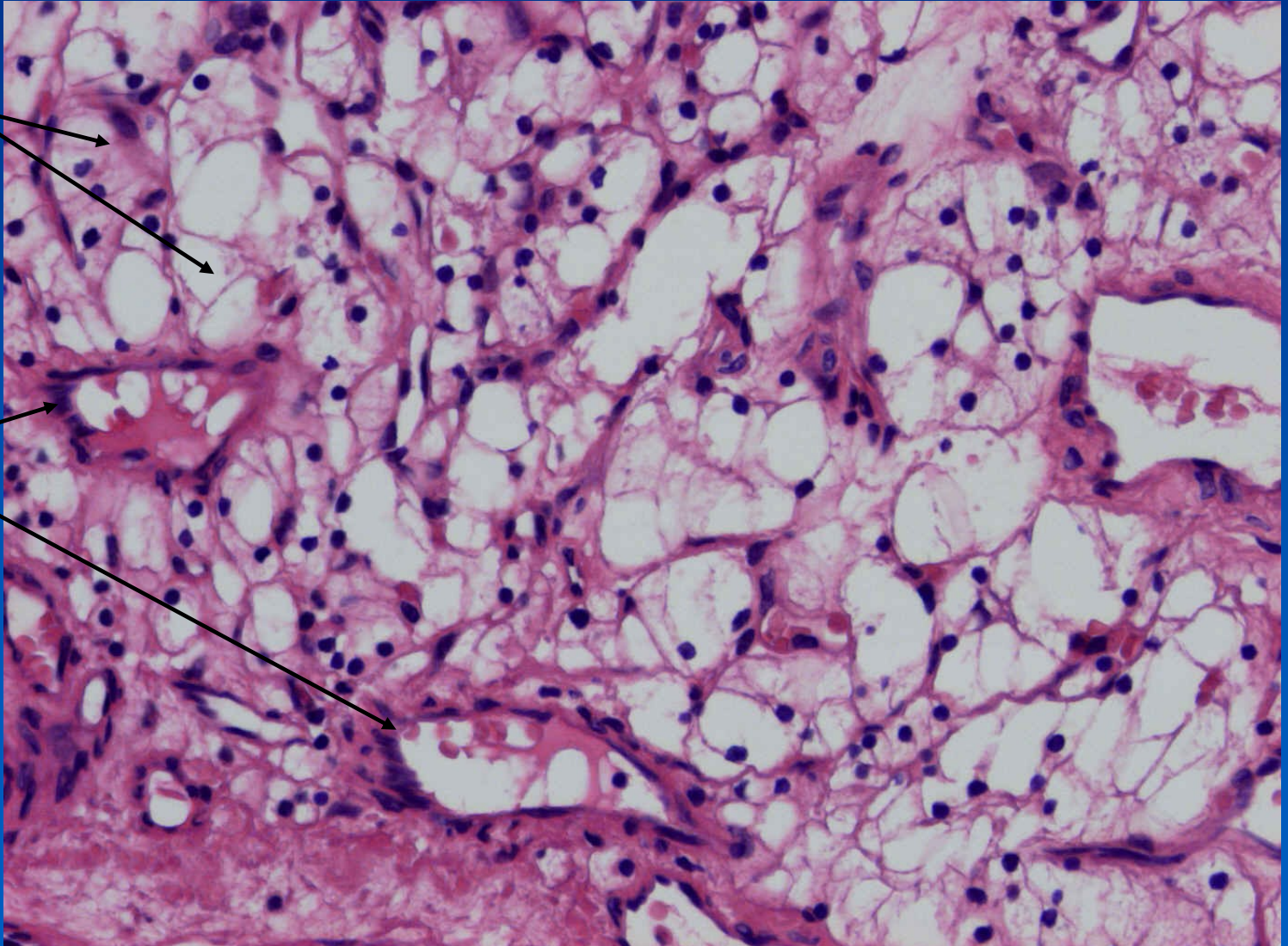
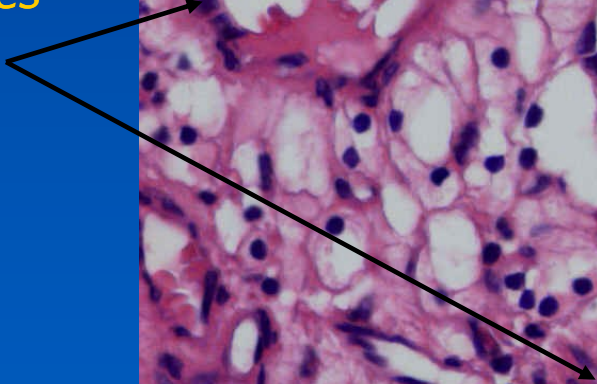
Clear cell carcinoma



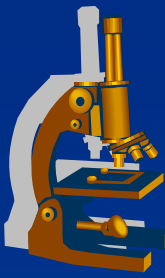
Tumor cells



Capillaries

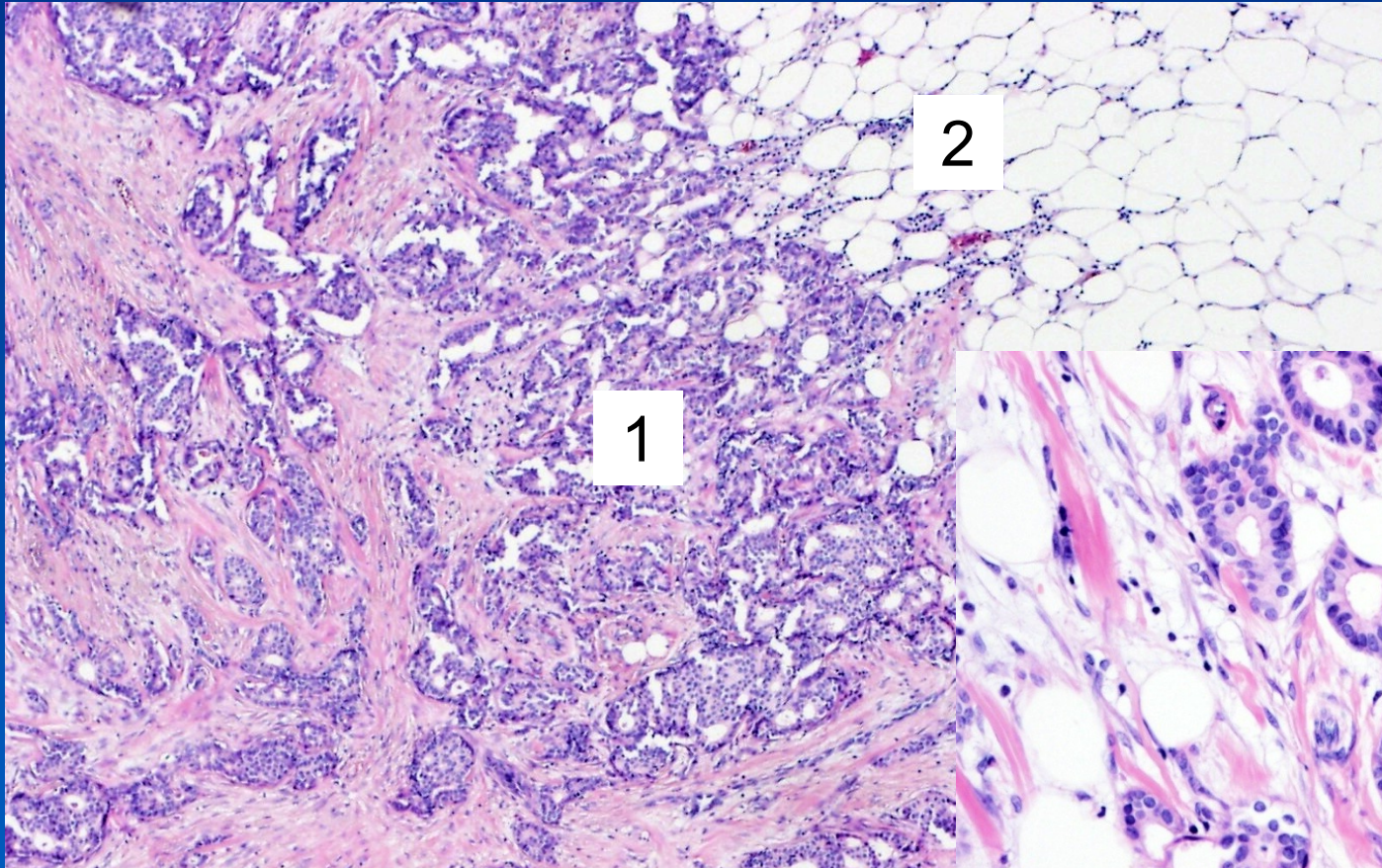


Mammary carcinoma, NOS

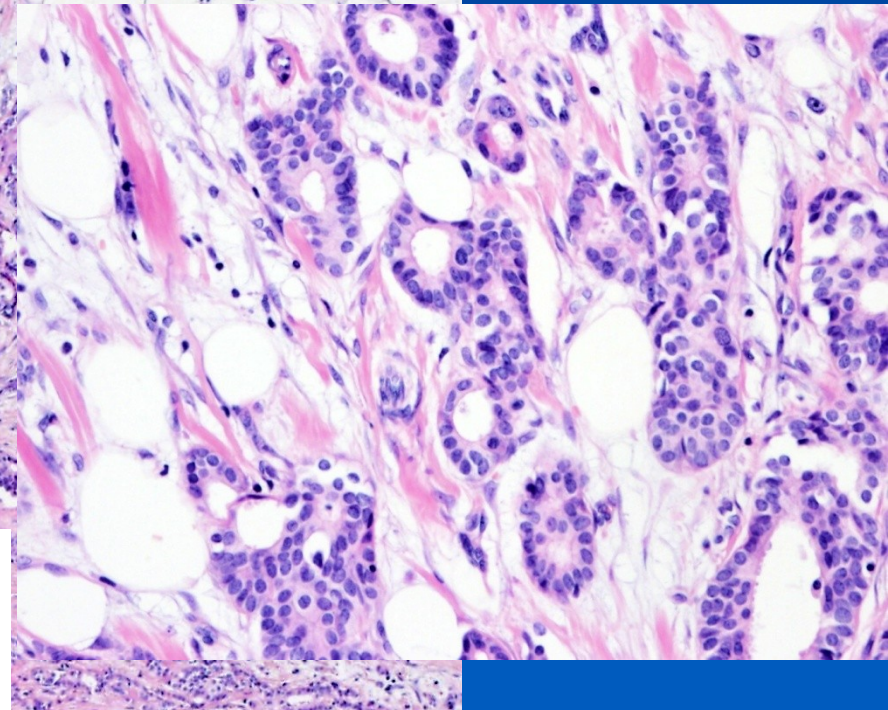


- ✗ most common
- ✗ former name – invasive ductal carcinoma
- ✗ gross:
 - ⇒ *firm lesion, irregular border*
- ✗ micro:
 - ⇒ *cohesive (E-cadherin+) tumor cells*
 - tubules, trabeculae, solid clusters
 - variable grade of nuclear pleomorphism, mitotic activity (gr. I-III)
 - ⇒ *loss of outer myoepithelial cell layer (p63-, SMA-)*
 - ⇒ *dense fibrotic stroma, desmoplasia*
 - ⇒ *infiltrative growth, commonly adjacent DCIS*

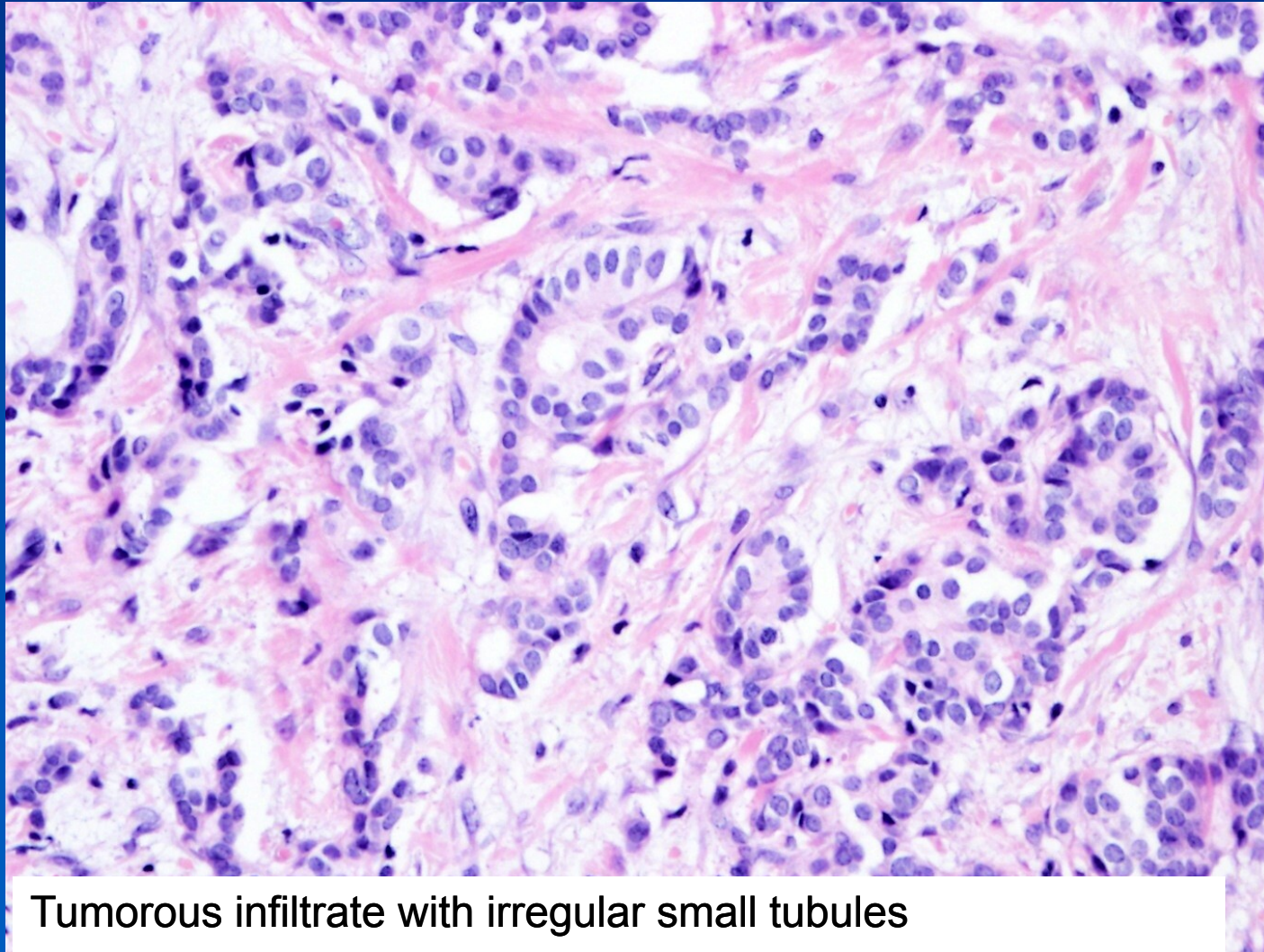
Mammary carcinoma, NOS



1 cohesive tumors infiltrate with sporadic tubules ojednělými tubuly
2 infiltration of adipose tissue



Mammary carcinoma, NOS

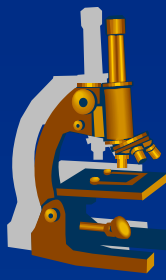


Tumorous infiltrate with irregular small tubules

Neuroendocrine neoplasms



- ✘ epithelial tumors with neuroendocrine differentiation
- ✘ represent a heterogeneous group of tumors
- ✘ characterized by the production of biogenic amines or hormones and mediators of hormonal effect
 - ⇒ *e.g. serotonin, neuropeptide,...*
- ✘ approximately 1/4 with endocrine function
 - ⇒ *carcinoid syndrome*
- ✘ secretory granules in the cytoplasm of tumor cells:
 - ⇒ ***detection mostly by immunohistochemistry!***
 - serotonin, chromogranin, S100, NSE, CD56
 - ⇒ *silver impregnation method (Grimelius)*



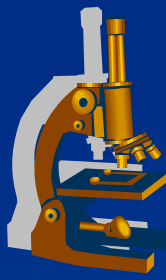
Neuroendocrine neoplasms

- ✘ new classification according ENETS (*European Neuroendocrine Tumor Society*) 2011

- ✘ differentiation by mitotic and proliferative activity :
 - ⇒ ***neuroendocrine tumors (carcinoid) G1***
 - proliferation index Ki67 ≤ 2 %
 - mitotic index ≤ 2 mitoses per 10 high resolution visual fields

 - ⇒ ***neuroendocrine tumors G2***
 - proliferation index Ki67 to 3 - 20 %
 - mitotic index 2 – 20 mitoses per 10 high resolution visual fields

 - ⇒ ***neuroendocrine carcinomas G3 (small cell or large cell type)***
 - proliferation index Ki67 >20 %
 - mitotic index > 20 mitoses per 10 visual fields high resolution



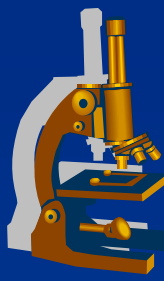
Carcinoid of the appendix

- ✘ by WHO classification 2010:
 - ⇒ *neuroendocrine tumor G1 (NET G1)*

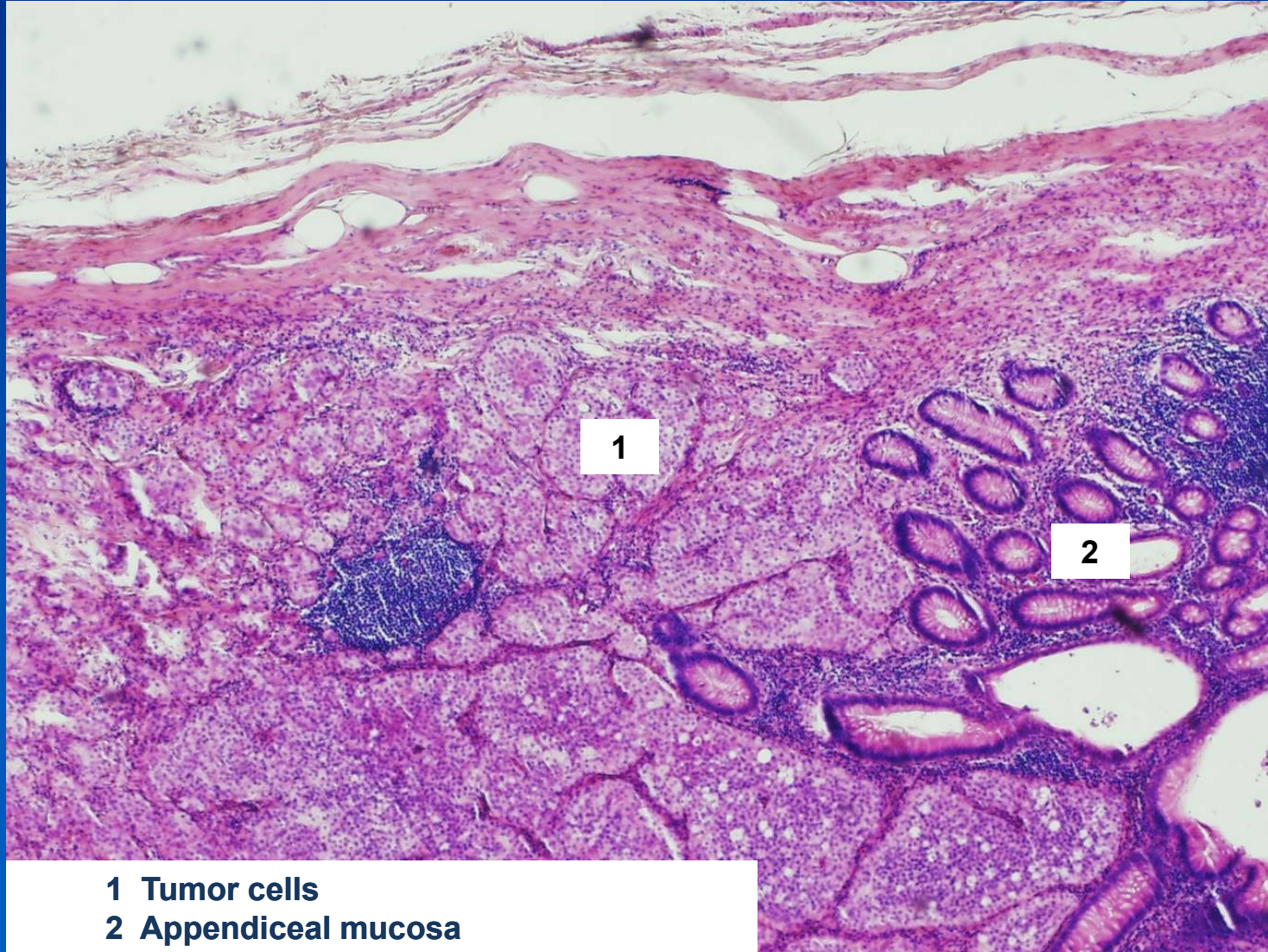
- ✘ by WHO classification 2000:
 - ⇒ *well differentiated neuroendocrine tumor*

- ✘ Gross:
 - ⇒ *small, round-shaped, flat nodules of yellowish colour, infiltrating the wall to different depth,*
 - ⇒ *superficially ulcerated or covered with normal mucosa,*
 - ⇒ *sometimes exophytic*

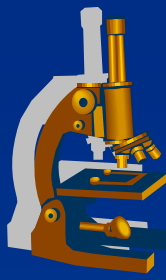
- ✘ Micro:
 - ⇒ *trabecular, glandular structures - tubules, palisading or compound structure*
 - ⇒ *regular cells with clear cytoplasm and round or oval-shaped nucleus; slight nuclear polymorphism*
 - ⇒ *low mitotic activity*
 - ⇒ *chromogranin A in cytoplasm*



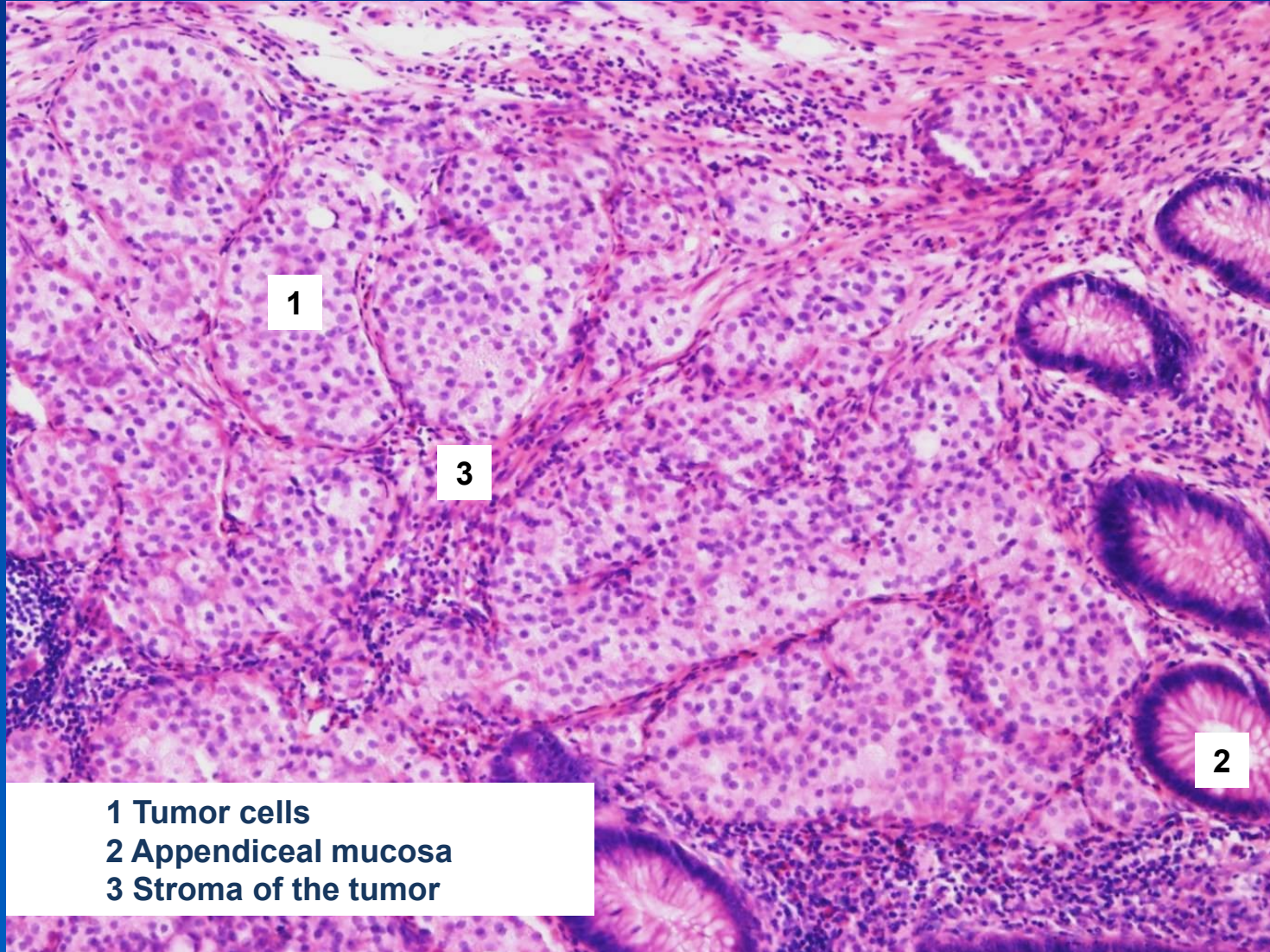
Carcinoid of the appendix



- 1 Tumor cells**
- 2 Appendiceal mucosa**

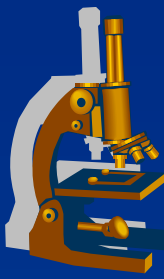


Carcinoid of the appendix



- 1 Tumor cells
- 2 Appendiceal mucosa
- 3 Stroma of the tumor

Small-cell carcinoma

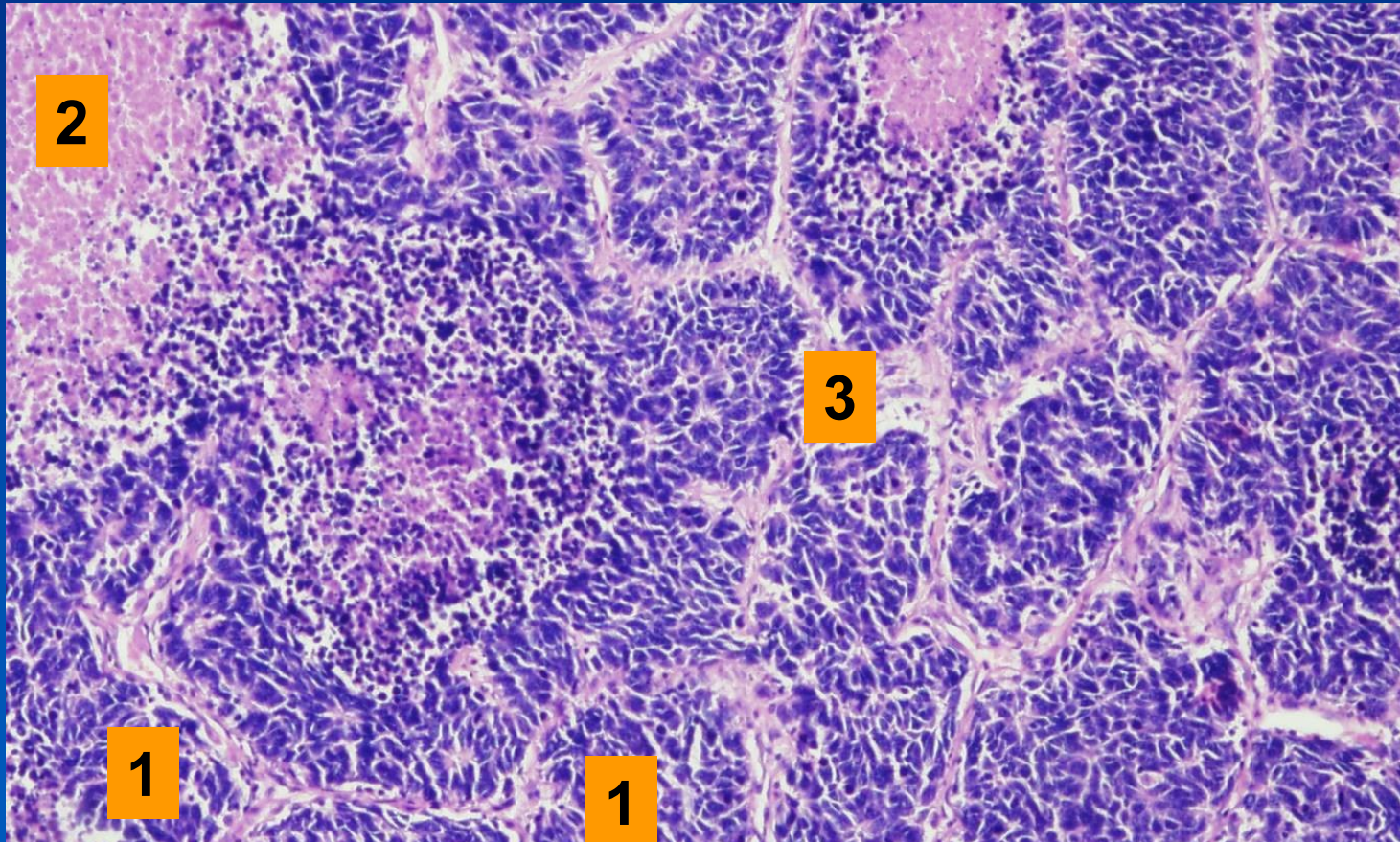
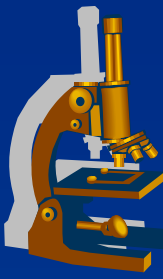


- ✗ undifferentiated neuroendocrine carcinoma
- ✗ the most malignant variety of lung carcinoma

✗ Micro:

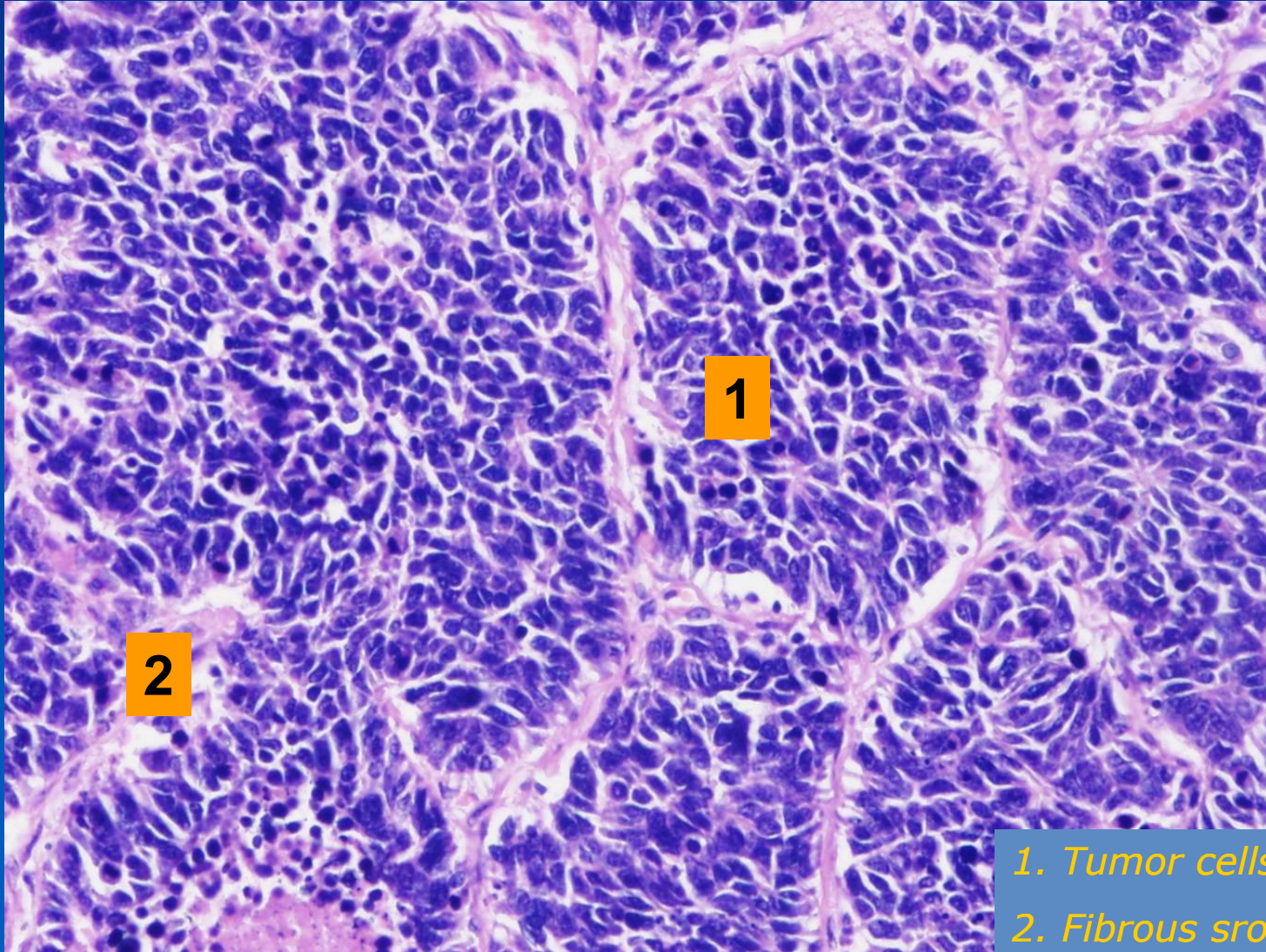
- ⇒ *small blue cells with hardly noticeable, scant cytoplasm*
- ⇒ *small, elongated, hyperchromatic nuclei without distinctive nucleoli (oat-cell carcinoma)*
- ⇒ *solid architecture*
- ⇒ *neuroendocrine secretory cytoplasmic granules*
 - chromogranin, synaptophysin

Small-cell lung carcinoma

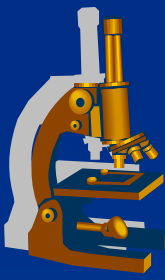


- 1. Solid infiltration with small tumor cells*
- 2. Necrosis*
- 3. Fibrous stroma*

Small-cell lung carcinoma



- 1. Tumor cells*
- 2. Fibrous stroma*



2. Mesenchymal tumors

2. Mesenchymal tumors



- × almost any localisation possible
- × highly heterogenous group of tumors
- × most of tumors arise *de novo*
- × *risk factors variable, among others:*
 - ⇒ chemical carcinogens (eg herbicides containing dioxin)
 - ⇒ scars
 - ⇒ implants containing PVC
 - ⇒ irradiation
 - ⇒ viruses (HHV8 and Kaposi sarcoma)
 - ⇒ inheritance (hereditary multiple lipomas)

2. Mesenchymal tumors



x biological behavior:

⇒ *benign tumors*

- fibroma, lipoma, hibernoma, myxoma, hemangioma, lymphangioma, leiomyoma, rhabdomyoma, chondroma, osteoma,...

⇒ *intermediate tumors*

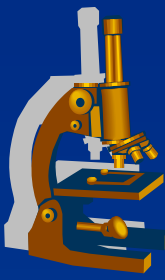
- locally aggressive, rarely metastasize
- fibromatosis

⇒ *malignant tumors (sarcomas)*

- higher metastatic potential

x benign tumors more common (mal:ben ~ 1:100)

Mesenchymal tumors



- ✘ classified according to the default parent tissue
- ✘ basic histological feature without typical epithelial formations, absence of mutual cell cohesiveness
- ✘ intercellular substance generally surrounds the individual tumor cells

Mesenchymal tumors



- ✗ immunohistochemical positivity of vimentin
- ✗ co-expression of other tissue-specific markers:

⇒ *S-100 (lipid tissue)*

⇒ *alpha-actin and/or desmin (muscle tissue)*

⇒ *factor VIII and CD31 (endothelium)*

Fibroma



✗ almost any localisation possible

⇒ *skin*

⇒ *mucous membranes*

⇒ *ovary*

✗ always benign

✗ commonly reactive non-neoplastic lesion

Fibroma



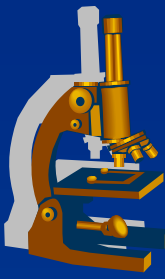
×Gross:

- ⇒ *well circumscribed, spherical*
- ⇒ *grey to pink on cut section*
- ⇒ *fascicular (bundled) structures*
- ⇒ *tough consistency*

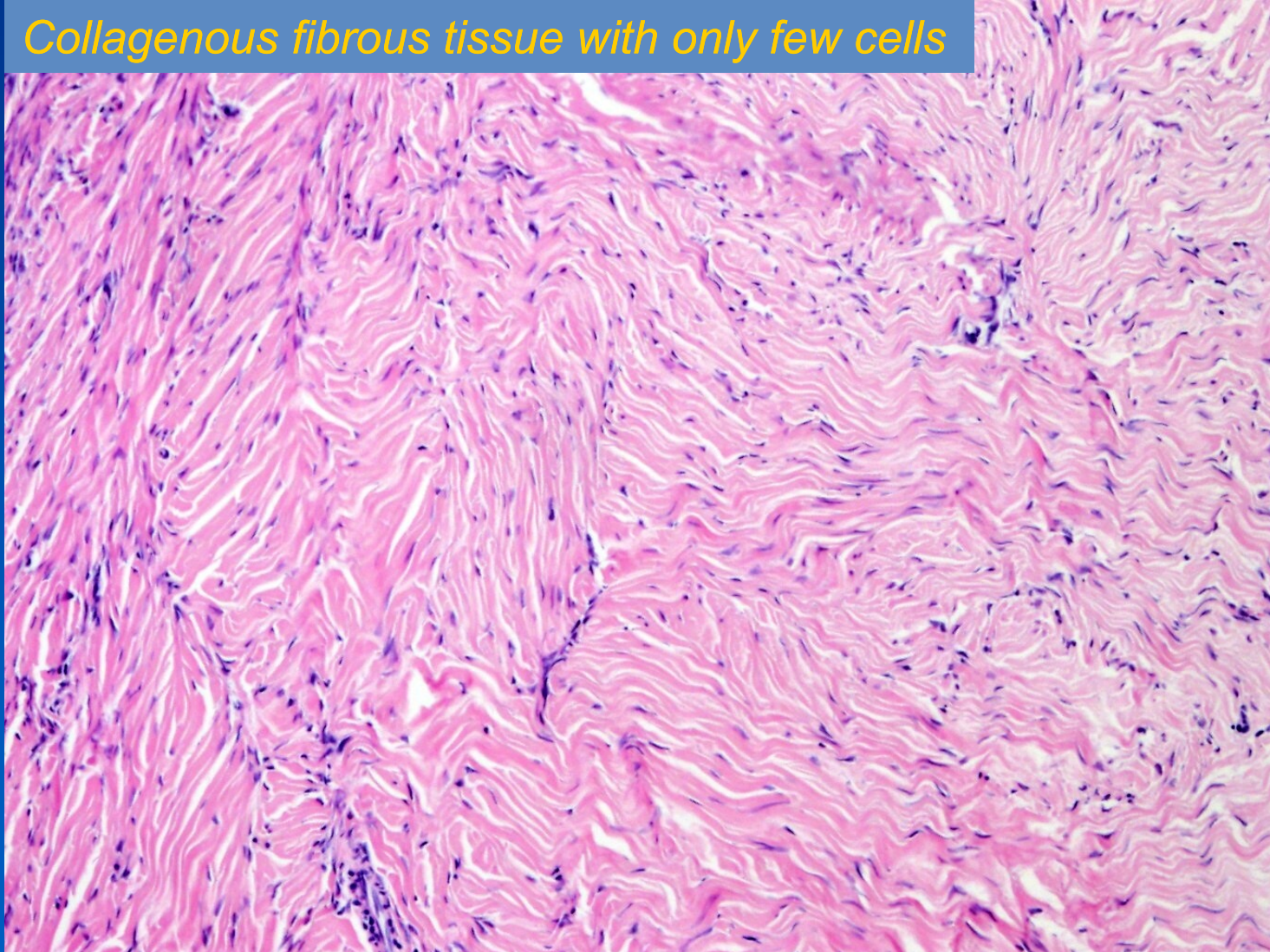
×Micro:

- ⇒ *accumulation of fibrous tissue*
- ⇒ *neoplastic fibroblasts*
 - *pointed nucleus, inconspicuous cytoplasm*
- ⇒ *production of collagenous intercellular matrix*
- ⇒ *low cellularity*

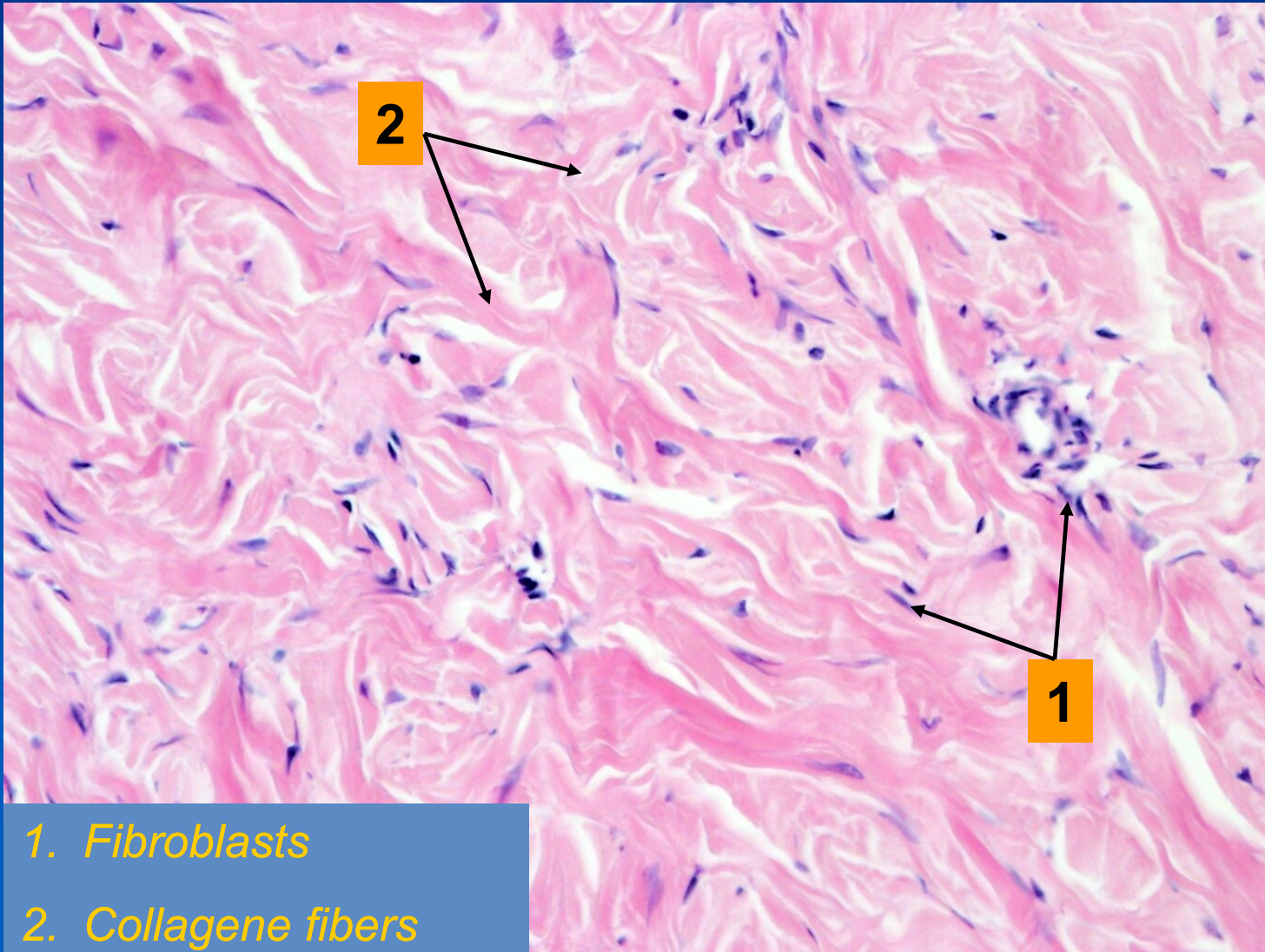
Fibroma



Collagenous fibrous tissue with only few cells

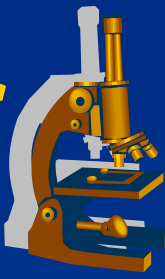


Fibroma



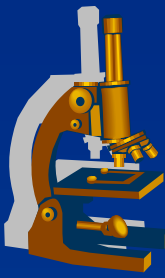
- 1. *Fibroblasts*
- 2. *Collagene fibers*

Undifferentiated pleomorphic sarcoma



- × former name malignant fibrous histiocytoma MFH
- × high-grade sarcoma
- × 30% of all soft tissue sarcomas
- × often in the thigh region (deep soft tissues)
- × mostly in older males
- × diagnosis per exclusionem after elimination of any other poorly differentiated mesenchymal or neuroectodermal tumor

Undifferentiated sarcoma



x gross:

⇒ *whitish tumor, „ fish-flesh“ appearance on cut section*

x micro:

⇒ *excessive pleomorphism of tumor cells and cellular architectonics*

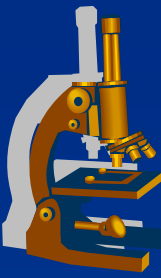
⇒ *bizarre multinucleate cells*

⇒ *frequent mitotic activity, necrosis*

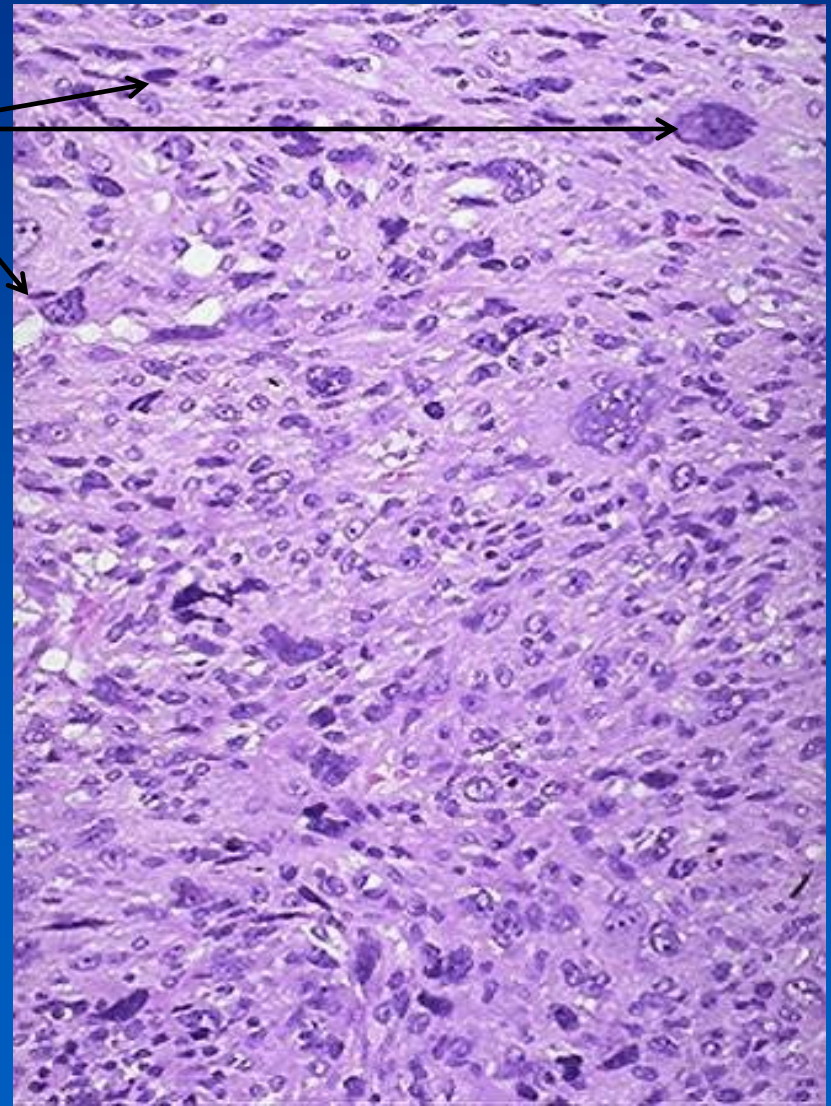
⇒ *variants:*

- spindle cell
- small round cell
- epithelioid
- pleomorphic
- NOS

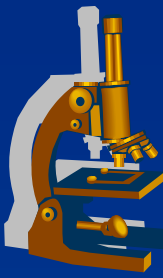
Undifferentiated sarcoma



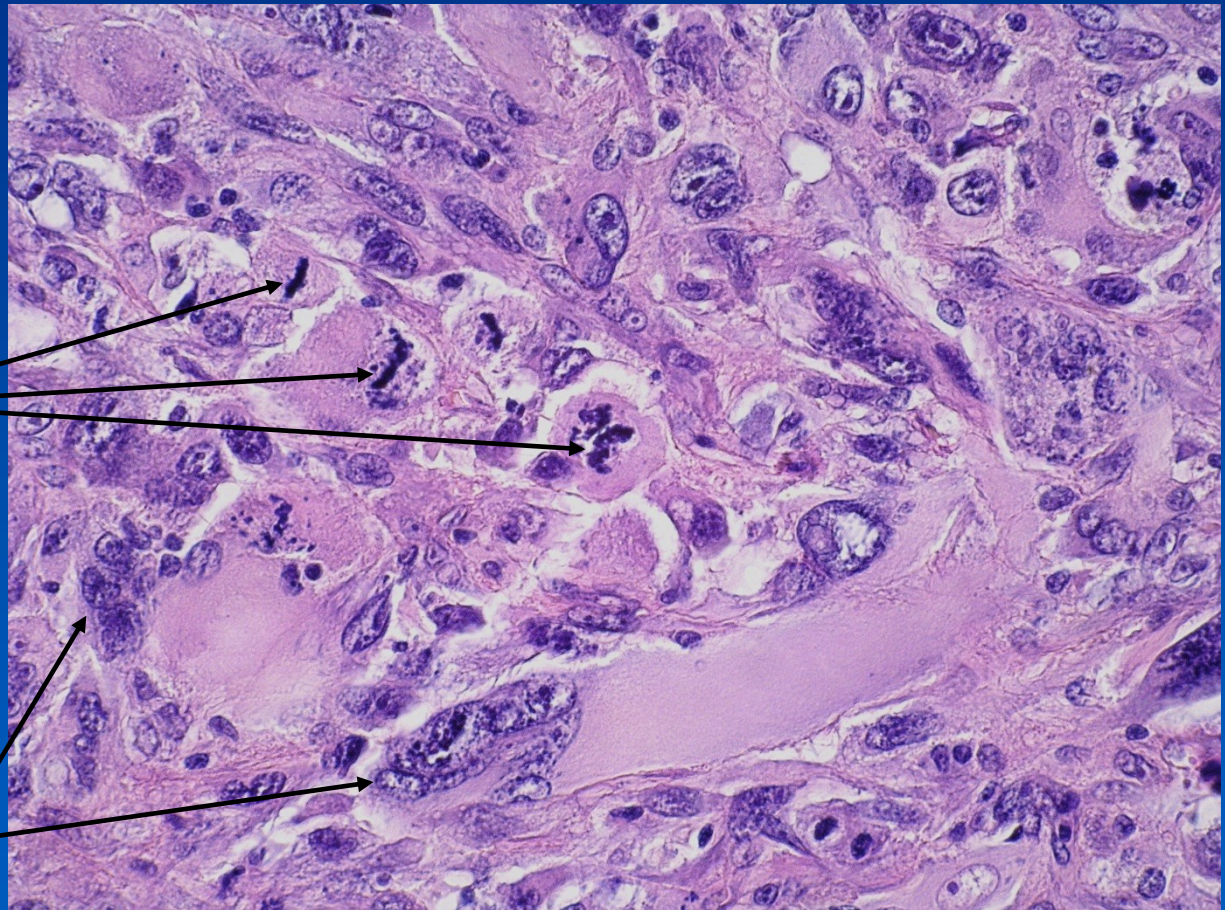
Pleomorphic nuclei of neoplastic cells



Undifferentiated sarcoma



Mitosis



Pleomorphic nuclei of neoplastic cells

Giant-cell tumor of bone

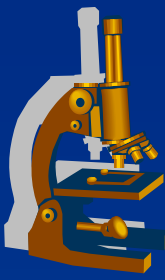


- ✗ unknown histogenesis of tumor cells

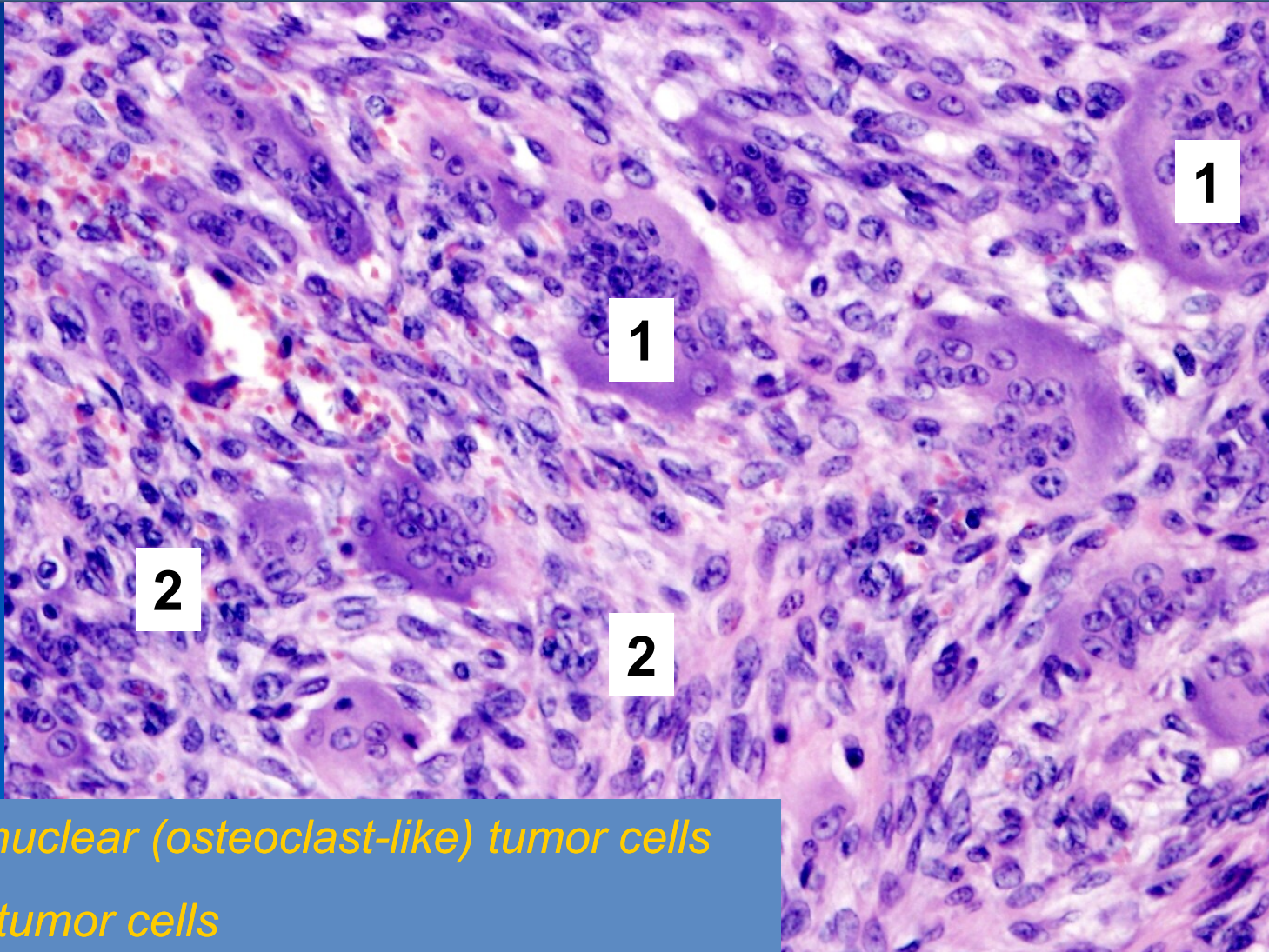
- ✗ former name osteoclastoma (osteoclast-type multinuclear giant cells)

- ✗ Gross:
 - ⇒ *red-brown large tumor in the epiphysis of long bones, destructive*

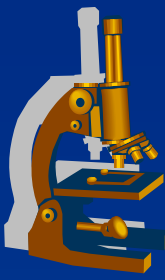
- ✗ Micro: 2 population of cells:
 - ⇒ *smaller oval mononuclear cells*
 - ⇒ *giant multinuclear cells (up to 100 nuclei)*



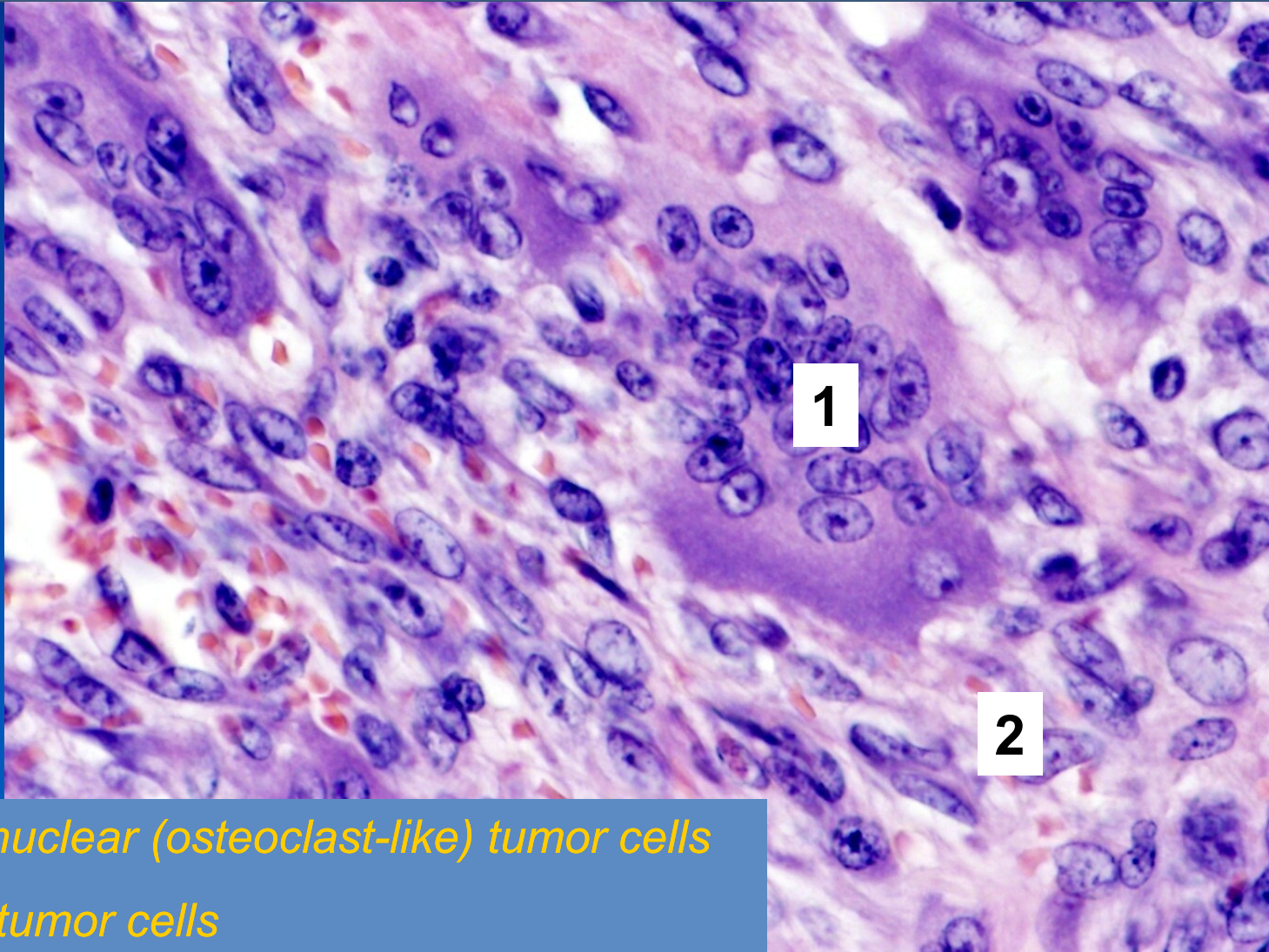
Giant-cell tumor of bone



- 1. Multinuclear (osteoclast-like) tumor cells*
- 2. Oval tumor cells*




Giant-cell tumor of bone



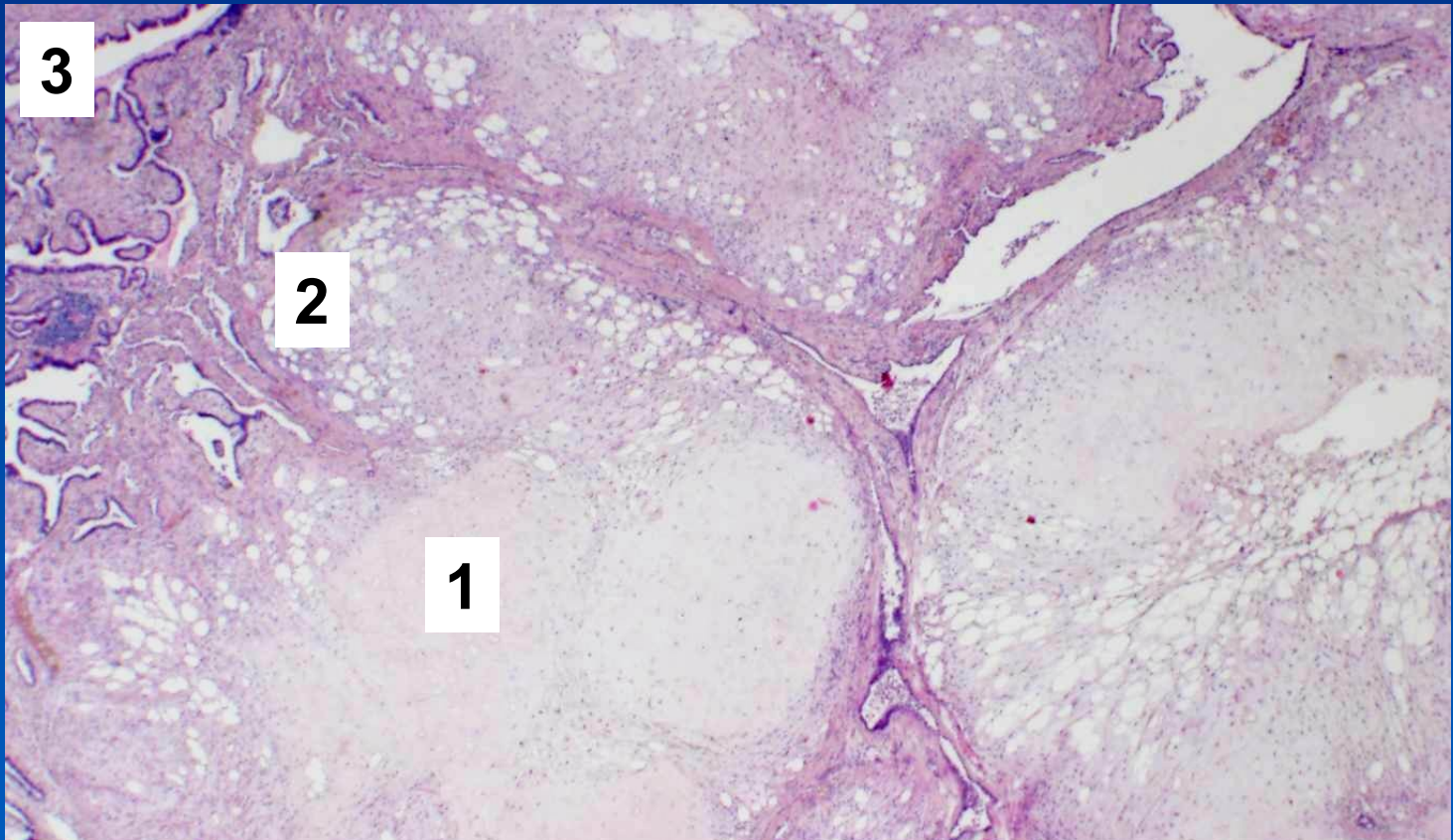
- 1. Multinuclear (osteoclast-like) tumor cells*
- 2. Oval tumor cells*

Chondrohamartoma of the lung




- x** HAMARTOMA = pseudoneoplastic lesion:
 - ⇒ *composed of mature tissue elements normally found at that site, but non-functional and growing in a disorganized mass*
- x** composed of cartilage, adipose and fibrous tissue, smooth muscle, respiratory epithelium
- x** cartilage usually prevails

Chondrohamartoma of the lung

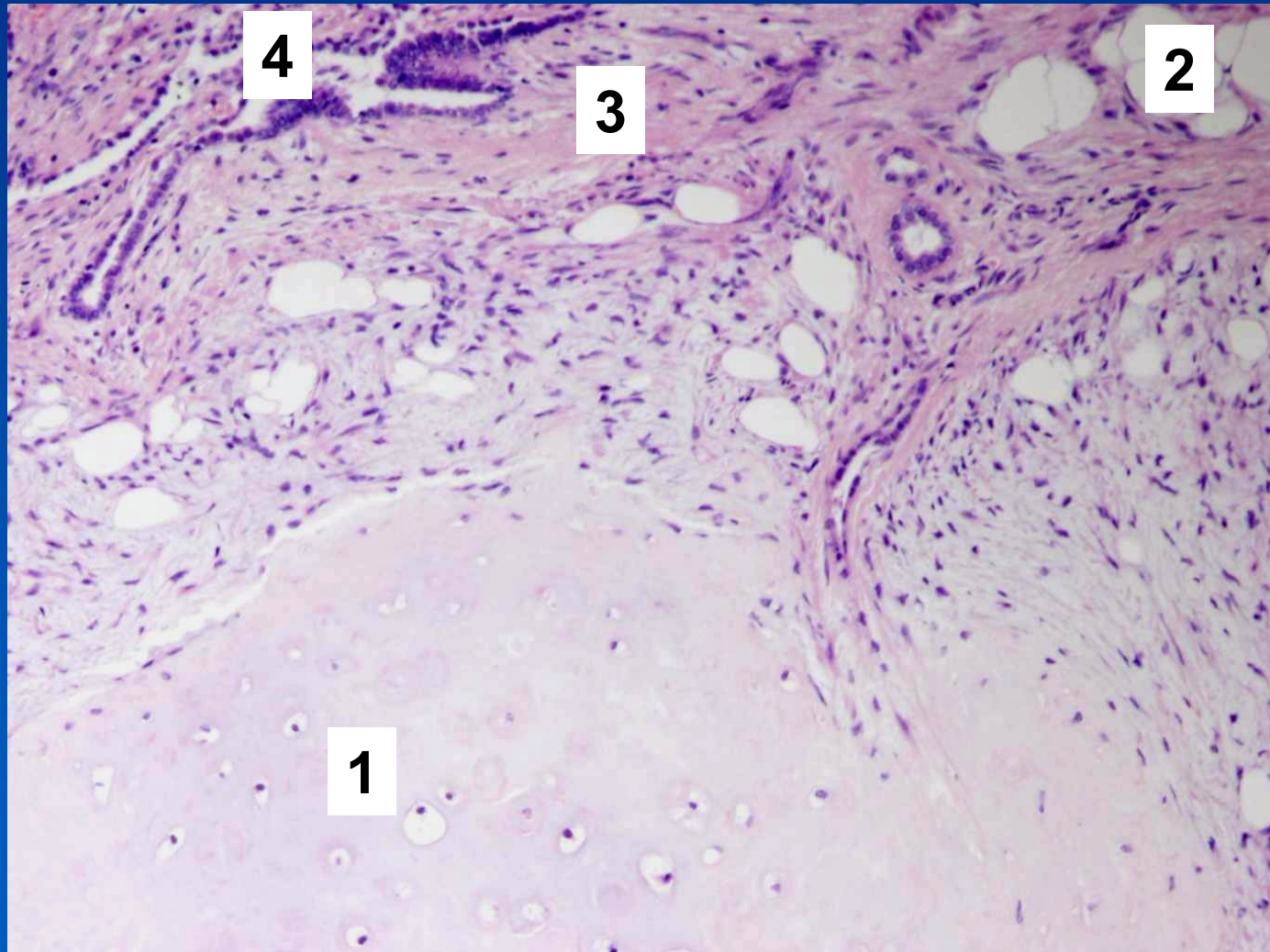


- 1. Cartilage*
- 2. Adipose tissue*
- 3. Tubular structures with respiratory epithelium*

Chondrohamartoma of the lung



1. Cartilage
2. Adipose tissue
3. Fibrous tissue
4. Tubular structures



Leiomyoma



✗ benign smooth muscle tumor, most common mesenchymal tumor

✗ Gross:

⇒ *well-circumscribed spheric nodule*

⇒ *often with regressive changes, fibrosis, calcification*

✗ Micro:

⇒ *interlacing or whorling bundles of spindle cells with inconspicuous eosinophilic cytoplasm*

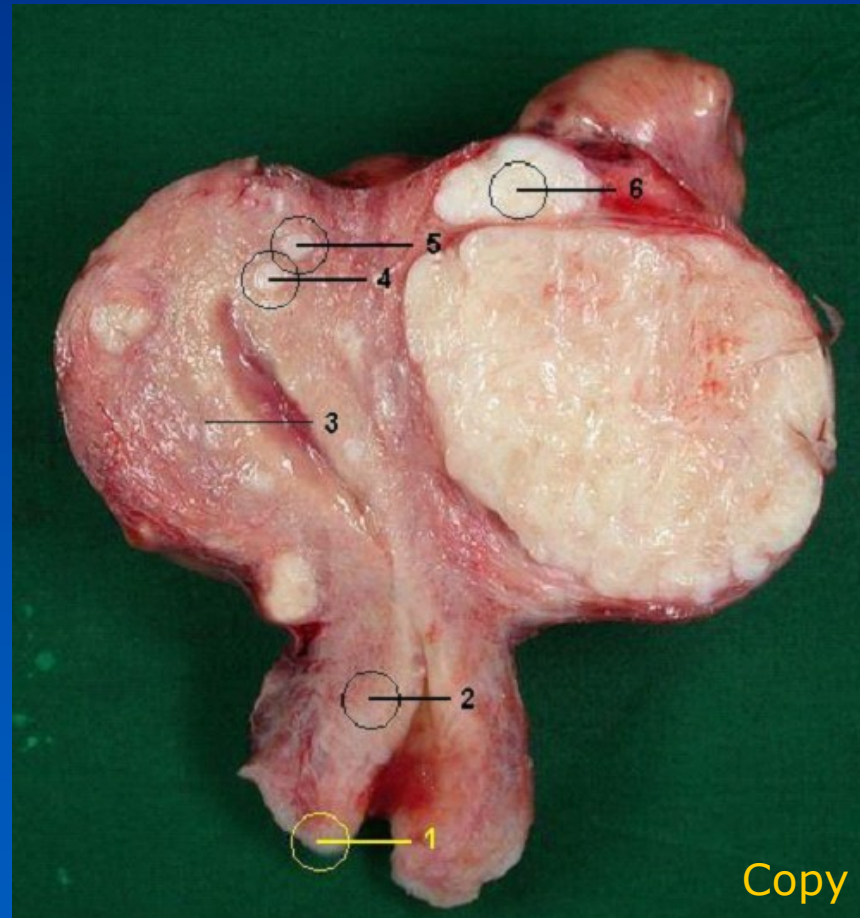
⇒ *cigar-shaped nuclei*

⇒ *no coagulative necrosis, low grade of reactive cytonuclear atypia possible*

Uterus myomatosus



1. *Portio vaginalis of the cervix*
2. *Endocervix*
3. *Body of the uterus*
4. *Submucosal leiomyoma*
5. *Intramural leiomyoma*
6. *Subserous leiomyoma*

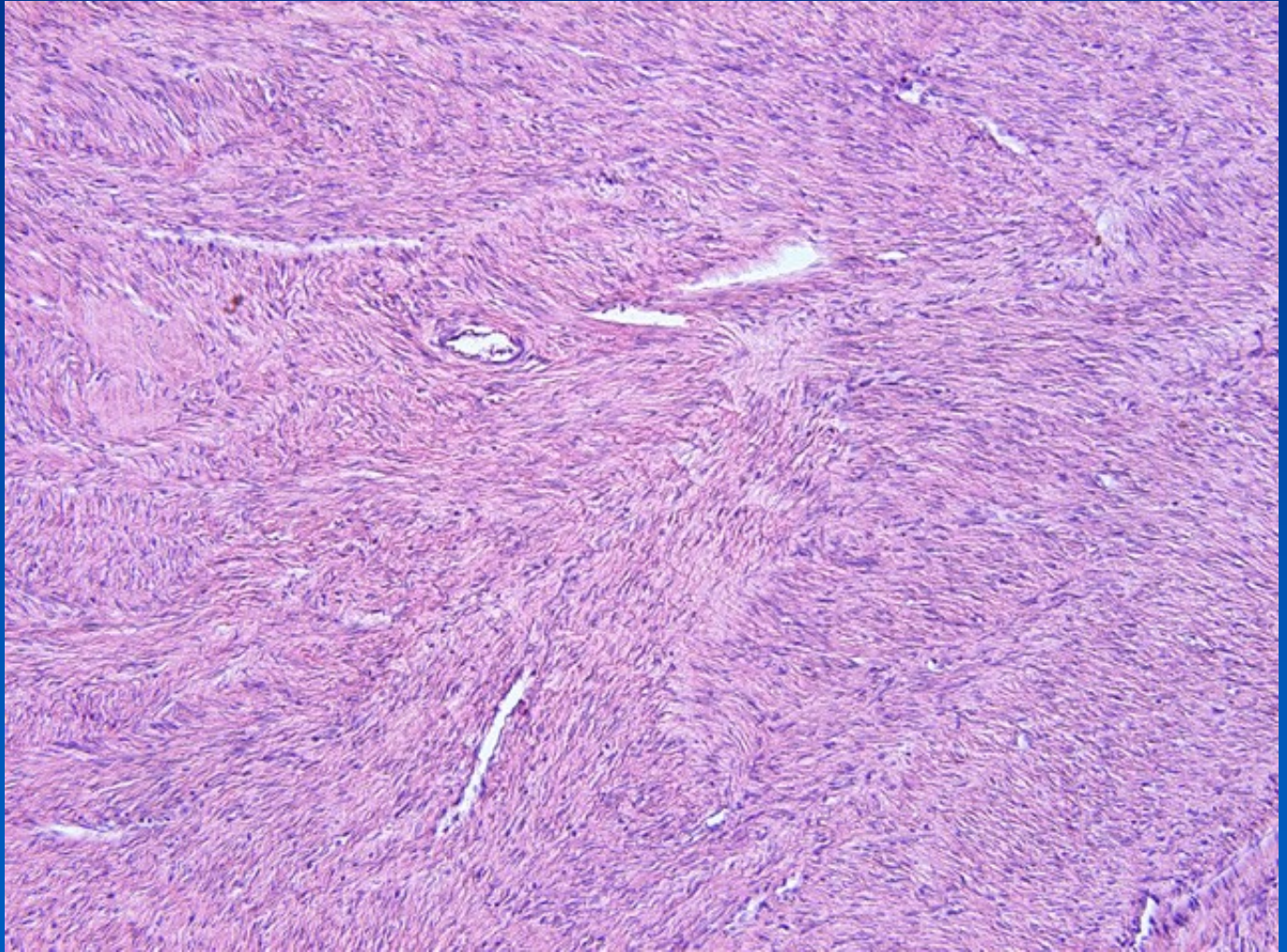


Copy

Leiomyoma



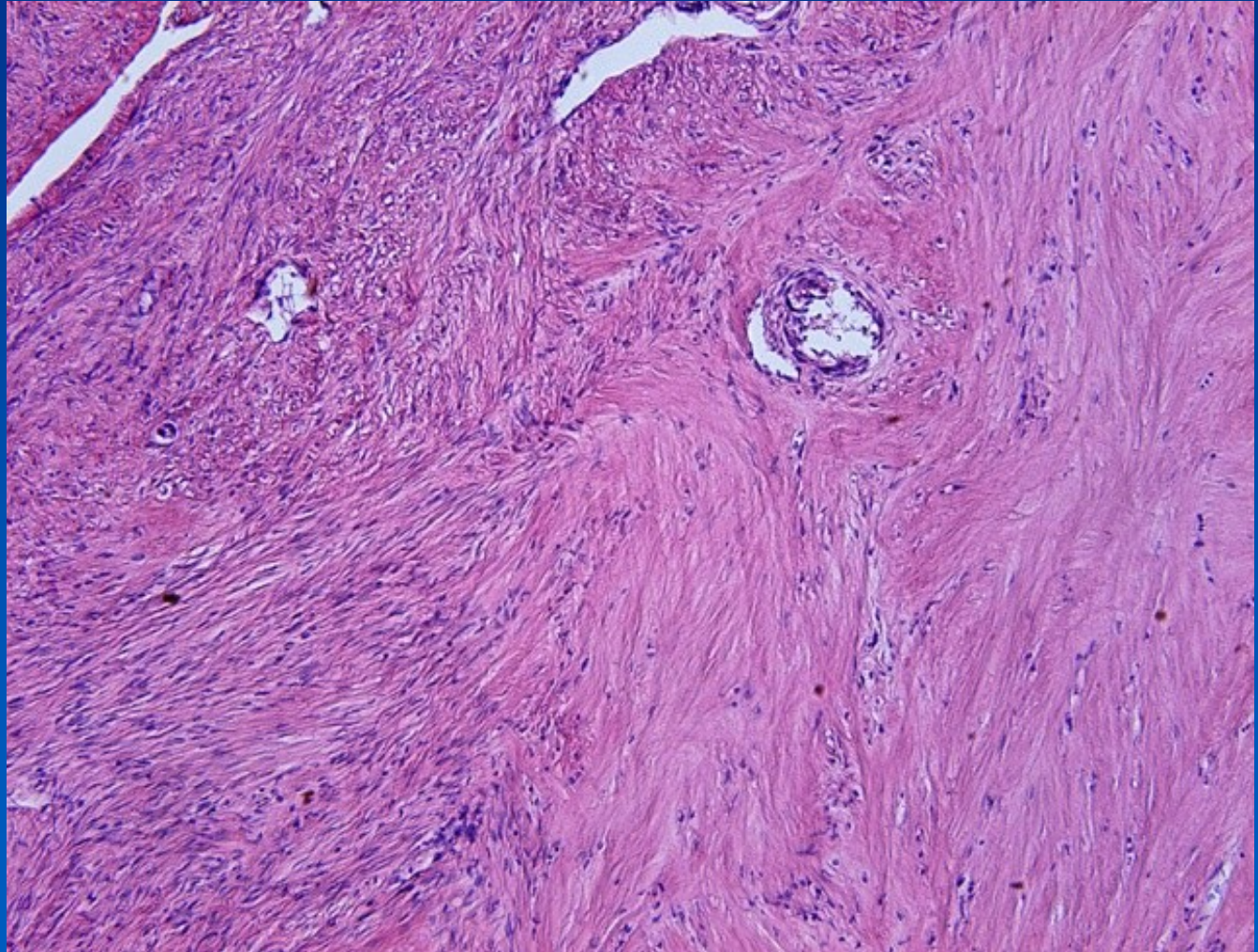
*Bundles of
spindle cells*



Leiomyoma



Bundles of spindle cells



Gastrointestinal stromal tumors (GISTs)



- ✗ cells of the origin:
 - ⇒ *Pacemakers GIT (Cajal cells) controlling peristalsis*

- ✗ immunohistochemistry:
 - ⇒ *CD 34 and CD 117 (c-kit) positivity*

- ✗ origin anywhere in the GIT: predominantly in the stomach and small intestine

- ✗ extragastrointestinal stromal tumors (EGIST) existing
 - ⇒ *e.g. in the pancreas, retroperitoneum, mesenterium of the small intestine, spleen, or pelvis*
 - ⇒ *extremely rare*

Gastrointestinal stromal tumors



x Gross:

- ⇒ *nodule in the wall, protruding into the lumen*
- ⇒ *mucosa over the tumor intact or ulcerated*

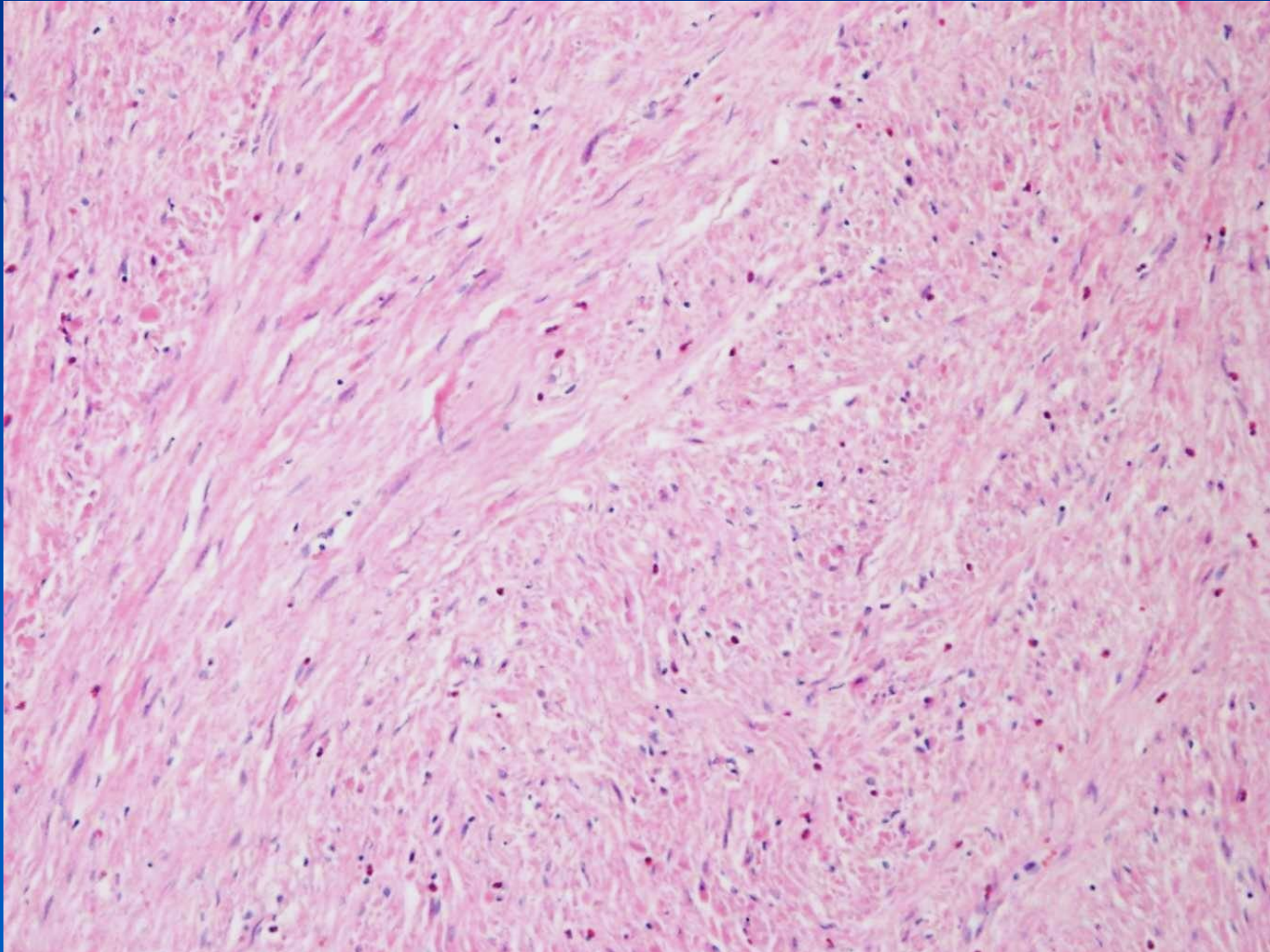
x Micro:

- ⇒ *elongated and/or epithelioid cells*

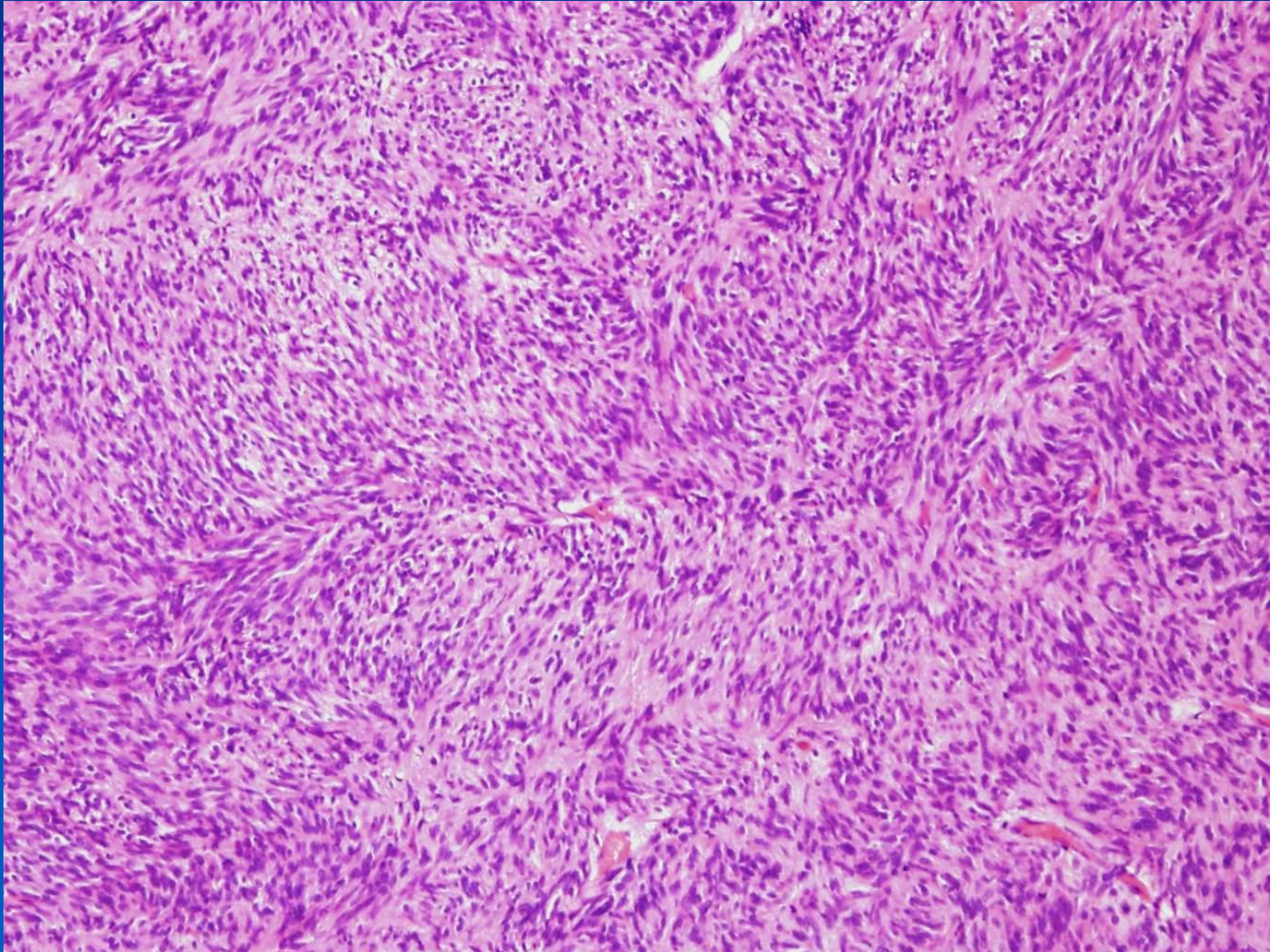
x prediction of biological behavior:

- ⇒ *mitotic count*
- ⇒ *size*
- ⇒ *localization*

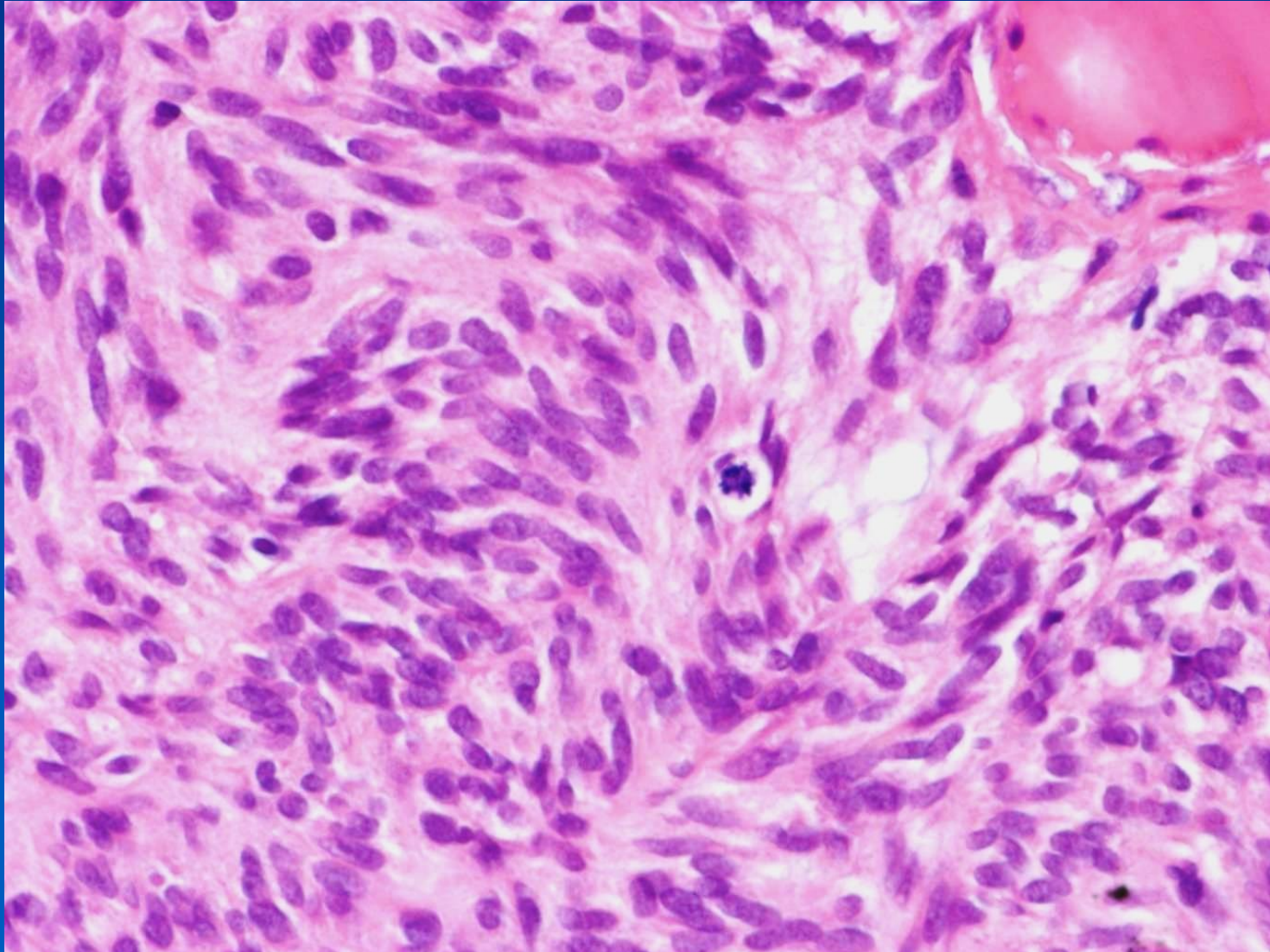
Gastrointestinal stromal tumors – low malignant



Gastrointestinal stromal tumors – highly malignant



Gastrointestinal stromal tumors – highly malignant



Hemangioma

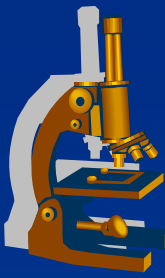


- ✘ benign tumor of blood vessels

- ✘ several subtypes according to vessels' calibre and architecture

- ✘ 3 basic types:
 - ⇒ *capillary hemangioma*
 - ⇒ *cavernous hemangioma*
 - ⇒ *arteriovenous hemangioma*

Capillary hemangioma



✗ often in the skin, subcutaneous tissues and mucosa

✗ Gross:

⇒ *bright red to blue patches or nodules*

✗ Micro:

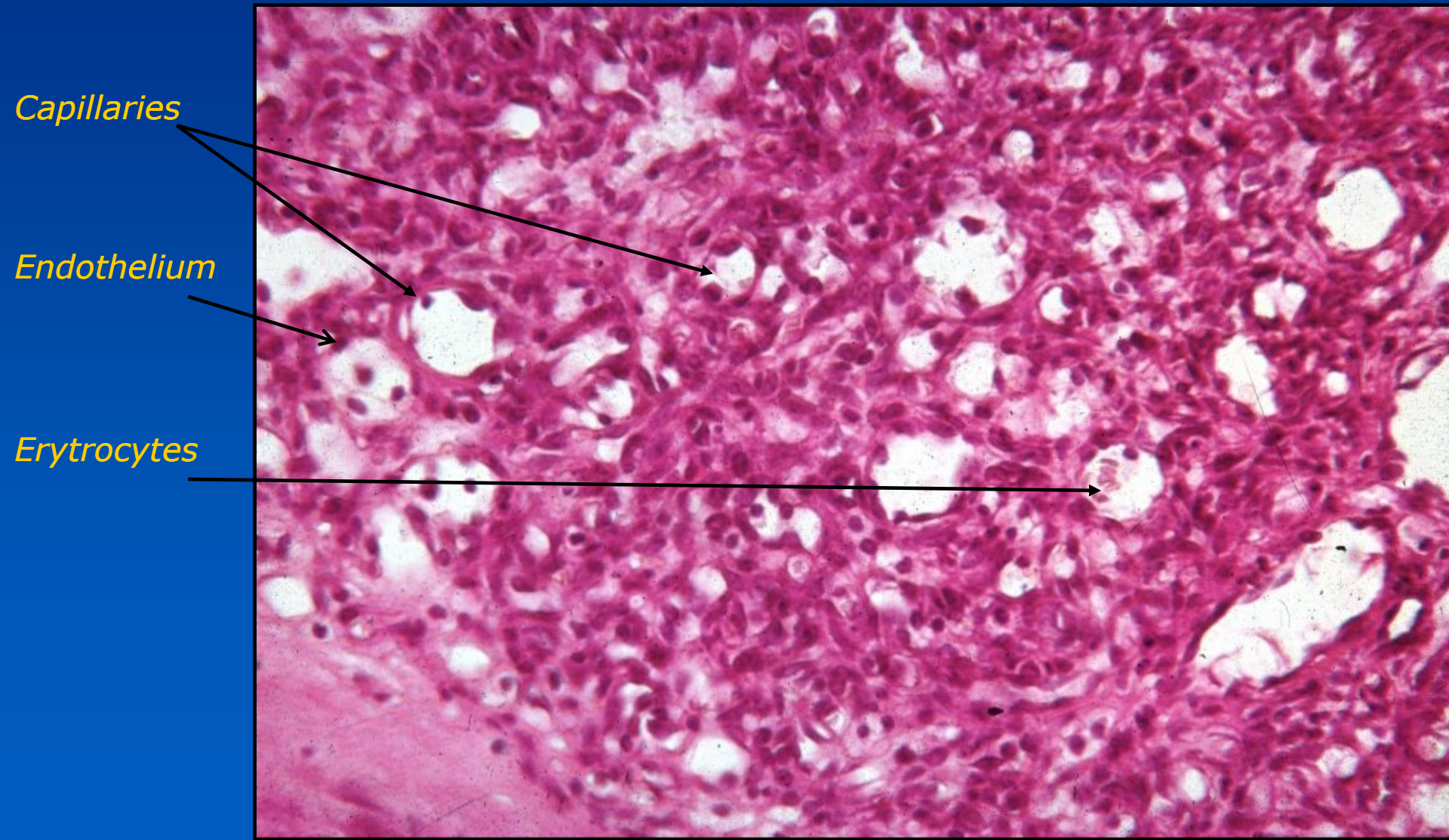
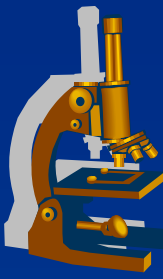
⇒ *aggregates of thin-walled capillaries*

⇒ *usually filled with blood, possible empty, compressed, thrombosed lumina*

⇒ *usually supplied with only 1 artery » regressive changes:*

- oedema
- hemorrhage
- fibrosis
- hemosiderin deposition after hemorrhage

Capillary hemangioma of the skin



Capillaries

Endothelium

Erythrocytes

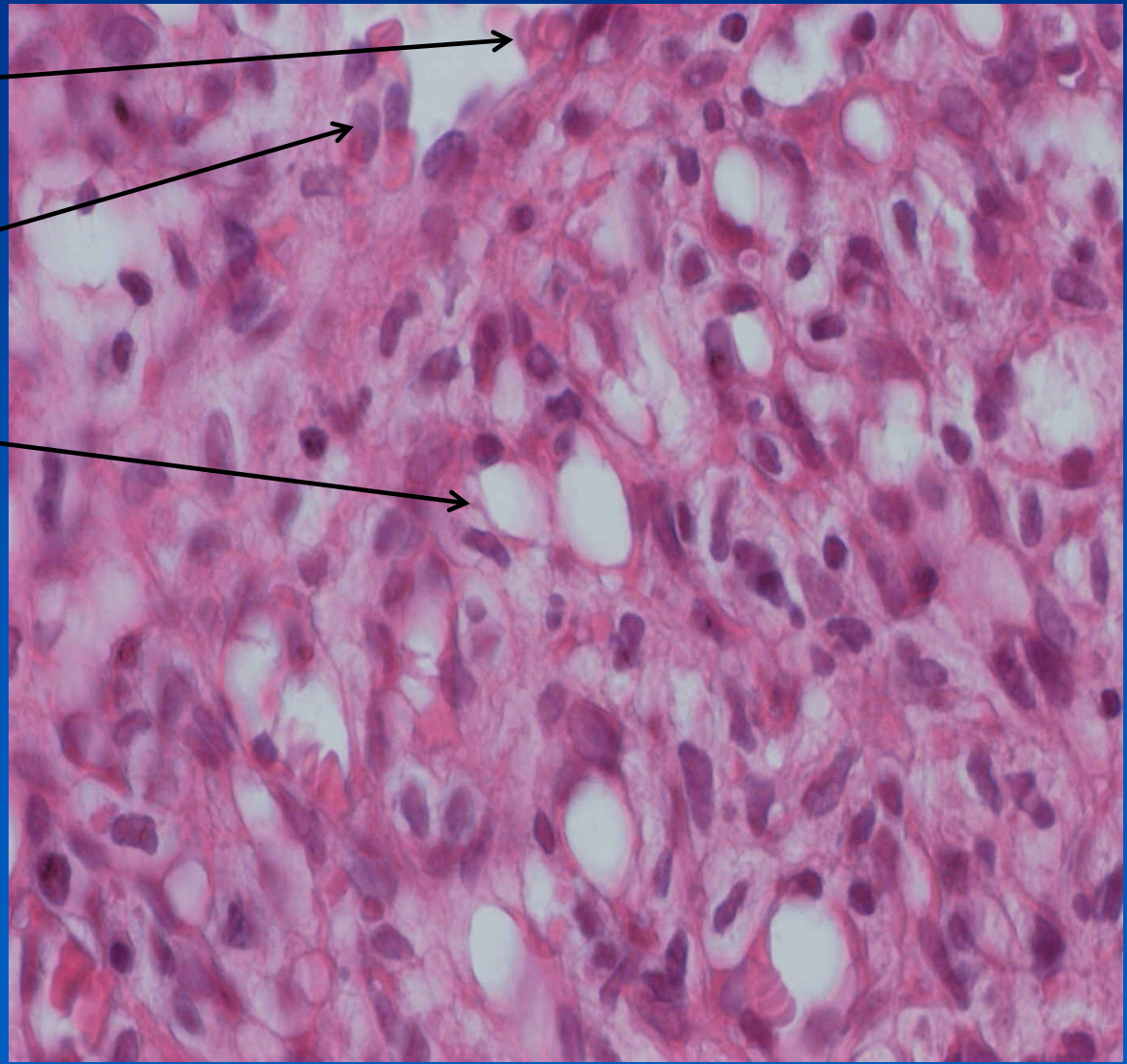
Capillary hemangioma of the skin



Erythrocytes

Endothelium

Capillaries



Cavernous hemangioma



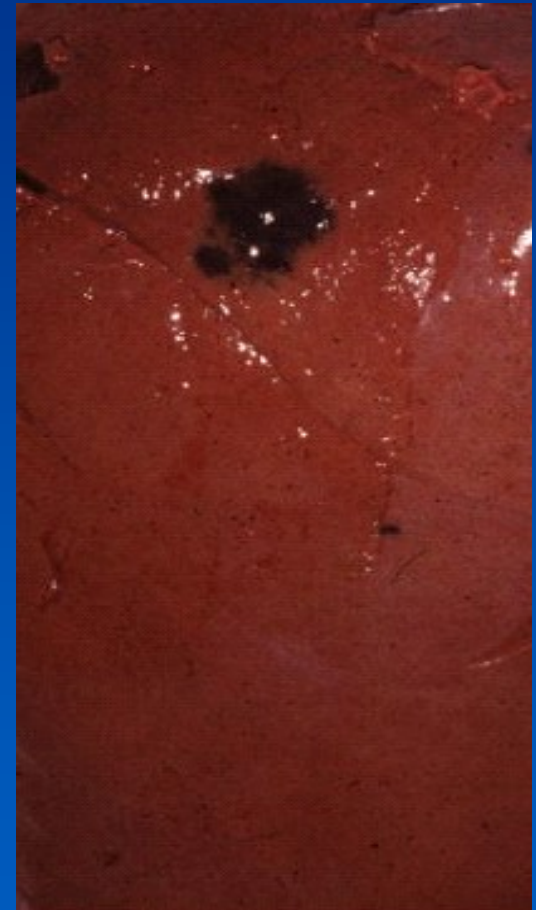
×Gross:

- ⇒ *red to blue nodule*
- ⇒ *can be of large size*
- ⇒ *mostly in the liver, less often in the spleen and skin*

×Micro:

- ⇒ *large, dilated vascular spaces, filled with blood, separated by fibrous septa (similar to corpora cavernosa)*

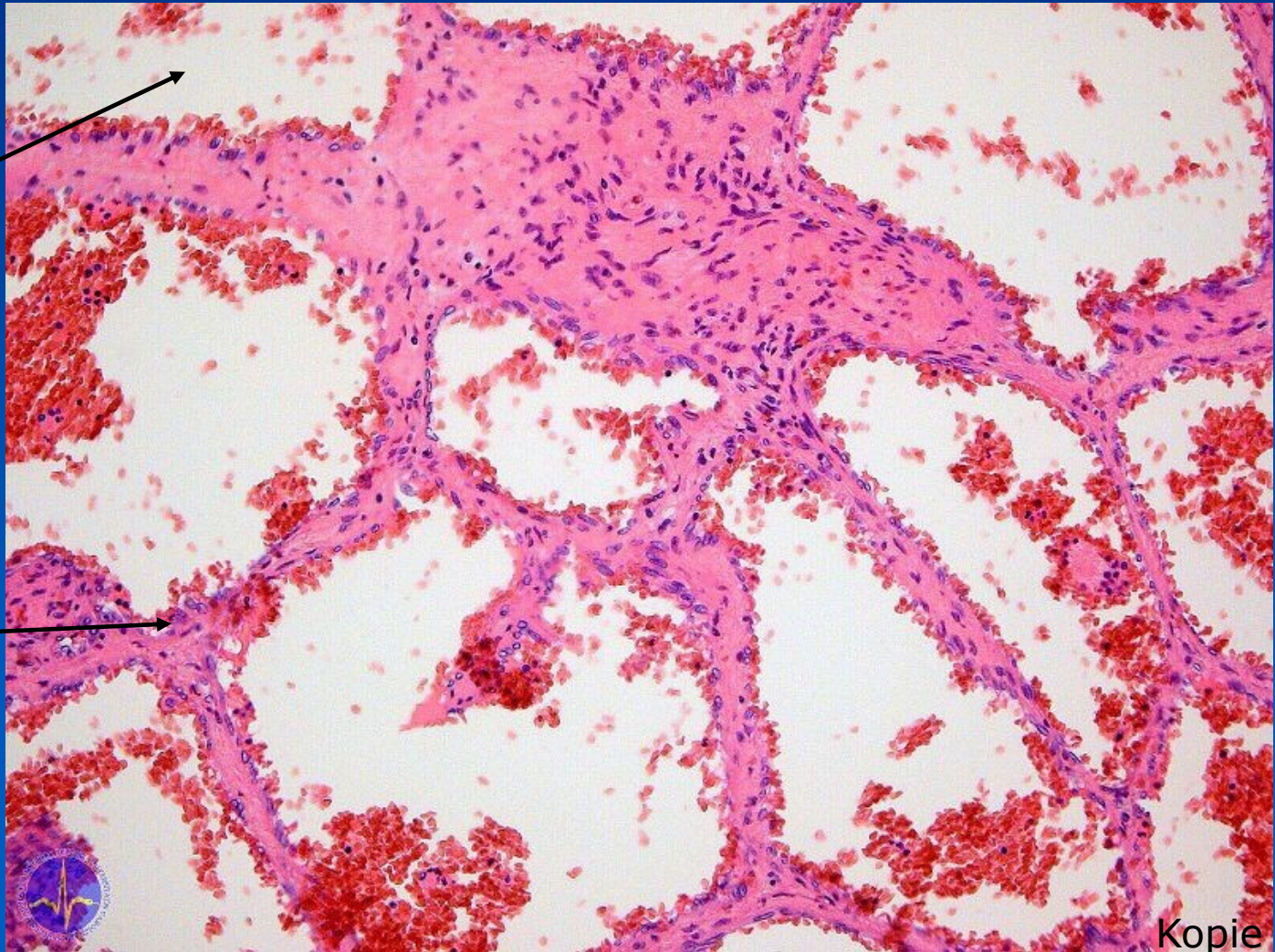
- ×risk of rupture with intraperitoneal hemorrhage



Cavernous hemangioma of the liver



*Blood-filled
spaces with
endothelial
lining*



Fibrous septa



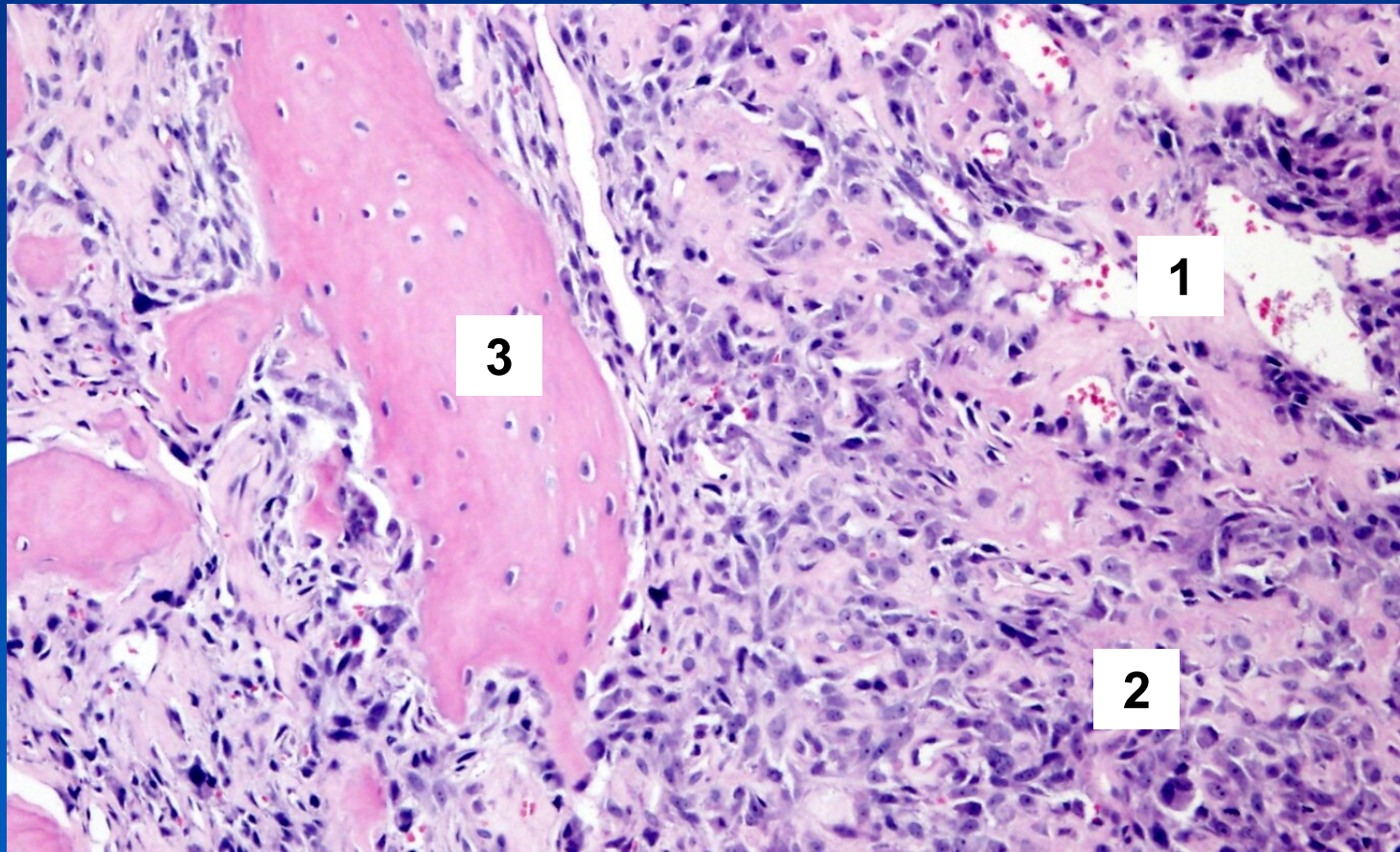
Kopie

Osteosarcoma



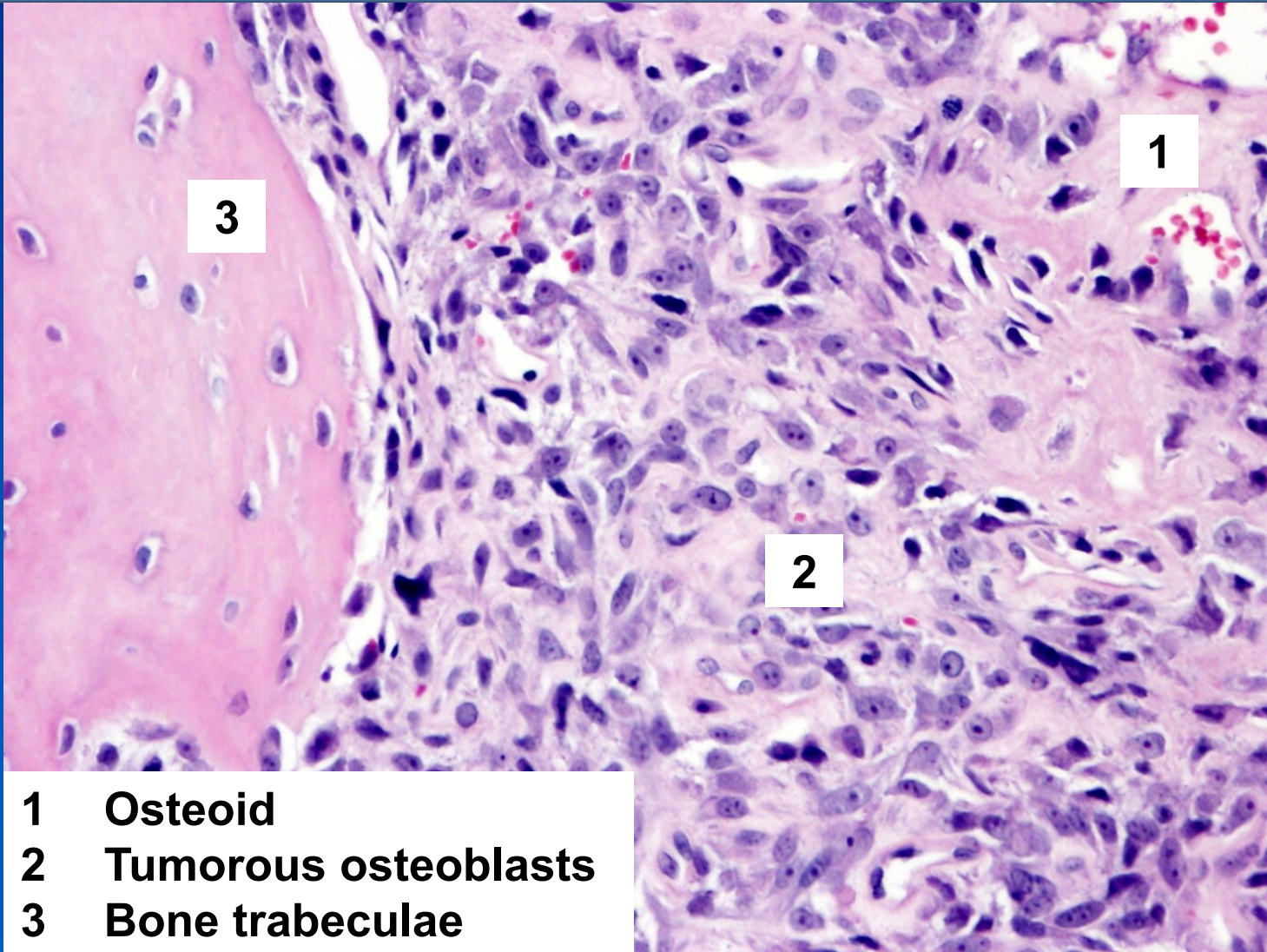
- ✗ young adults under the age of 25 (primary)
- ✗ mostly arises in the metaphyseal region of the long bones
- ✗ 70% occurring in the region of knee (distal femur and proximal tibia)
- ✗ Micro:
 - ⇒ *produces tumorous bone matrix (osteoid) – essential for diagnosis*
 - ⇒ *pleomorphic sm. spindle cells, high mitotic activity*
 - ⇒ *subtypes:*
 - fibroblastic, osteoblastic, chondroblastic

Osteosarcoma



- 1** Osteoid
- 2** Tumorous osteoblasts
- 3** Bone trabeculae

Osteosarcoma

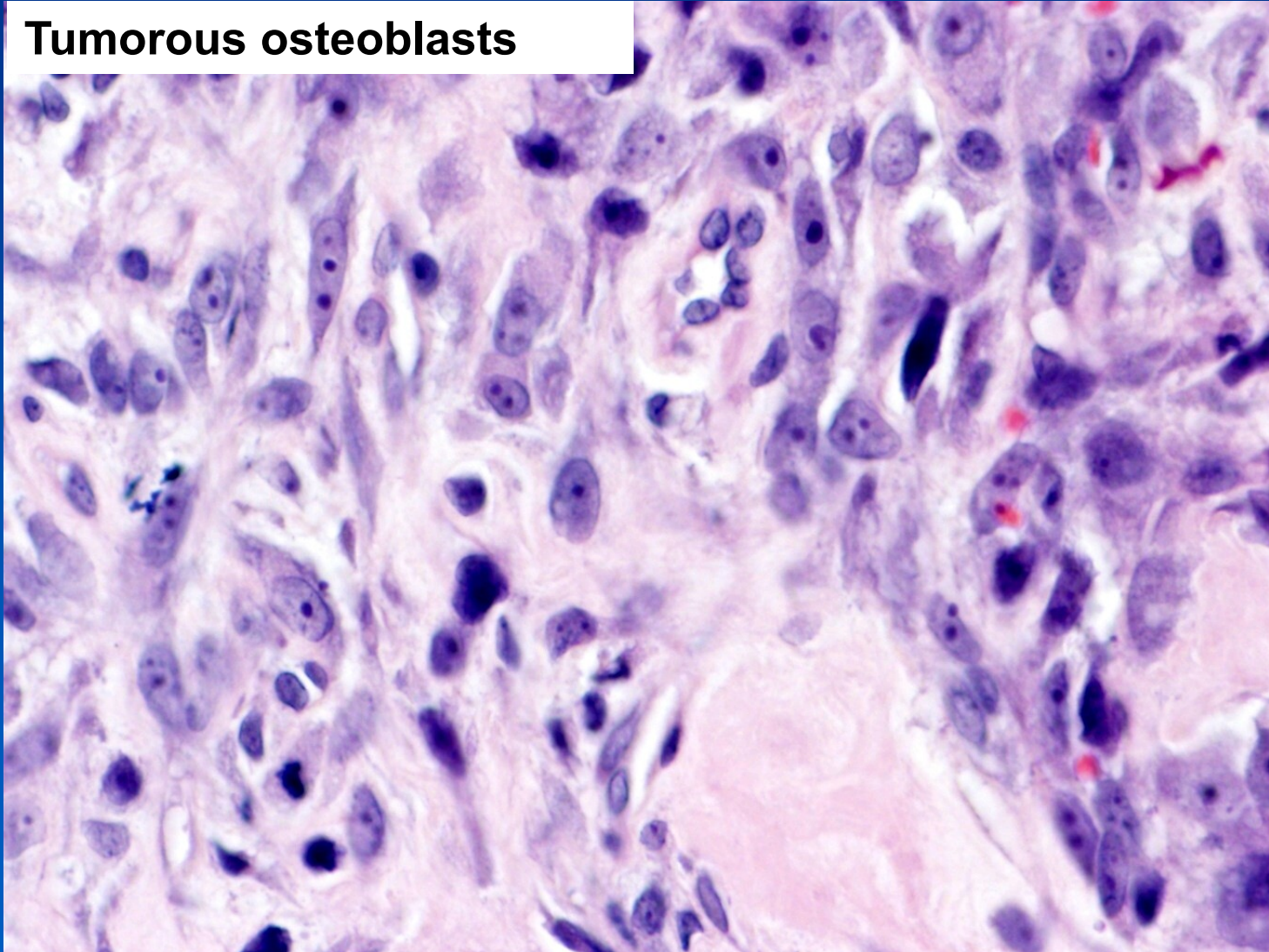


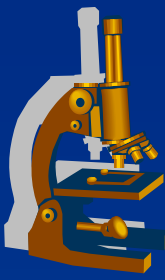
- 1** Osteoid
- 2** Tumorous osteoblasts
- 3** Bone trabeculae

Osteosarcoma



Tumorous osteoblasts





3. Neuroectodermal tumors

Neuroectodermal tumors



- x tumors of the central nervous system
- x peripheral neuroectodermal tumors
- x tumors of the autonomous nervous system
- x melanocytic tumors

Selected tumors of the CNS



× Astrocytic tumors:

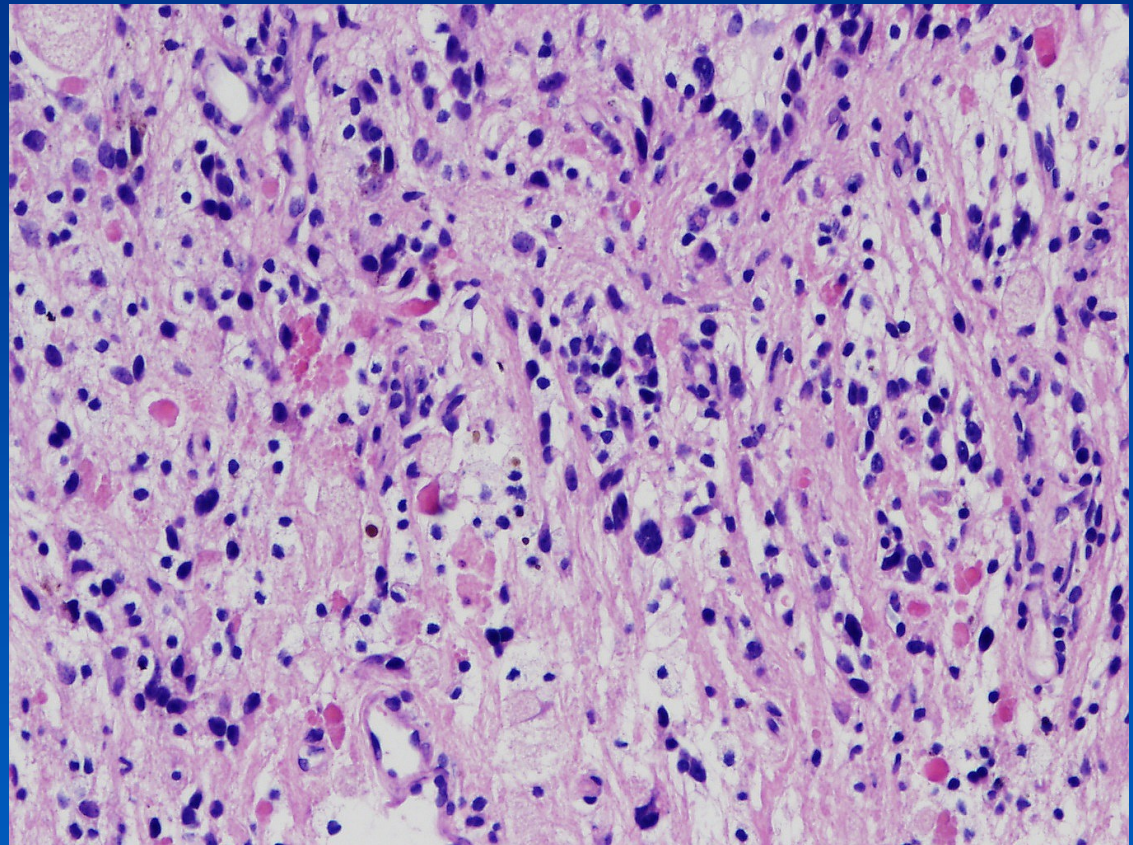
⇒ ***pilocytic astrocytoma*** (*Grade I of WHO class.*):

- two components:
 - solid areas with bipolar tumorous astrocytes – cells with long, thin, hair-like processes, eosinophilic Rosenthal fibers
 - microcystic areas, less cellular, with multipolar tumor cells with eosinophilic granular bodies
- calcification and small foci of necrosis may occur
- low mitotic activity, nuclear pleomorphism and hyperchromasia mostly absent
- glomerulus-like vascular proliferation

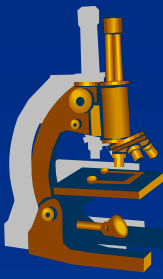
Pilocytic astrocytoma



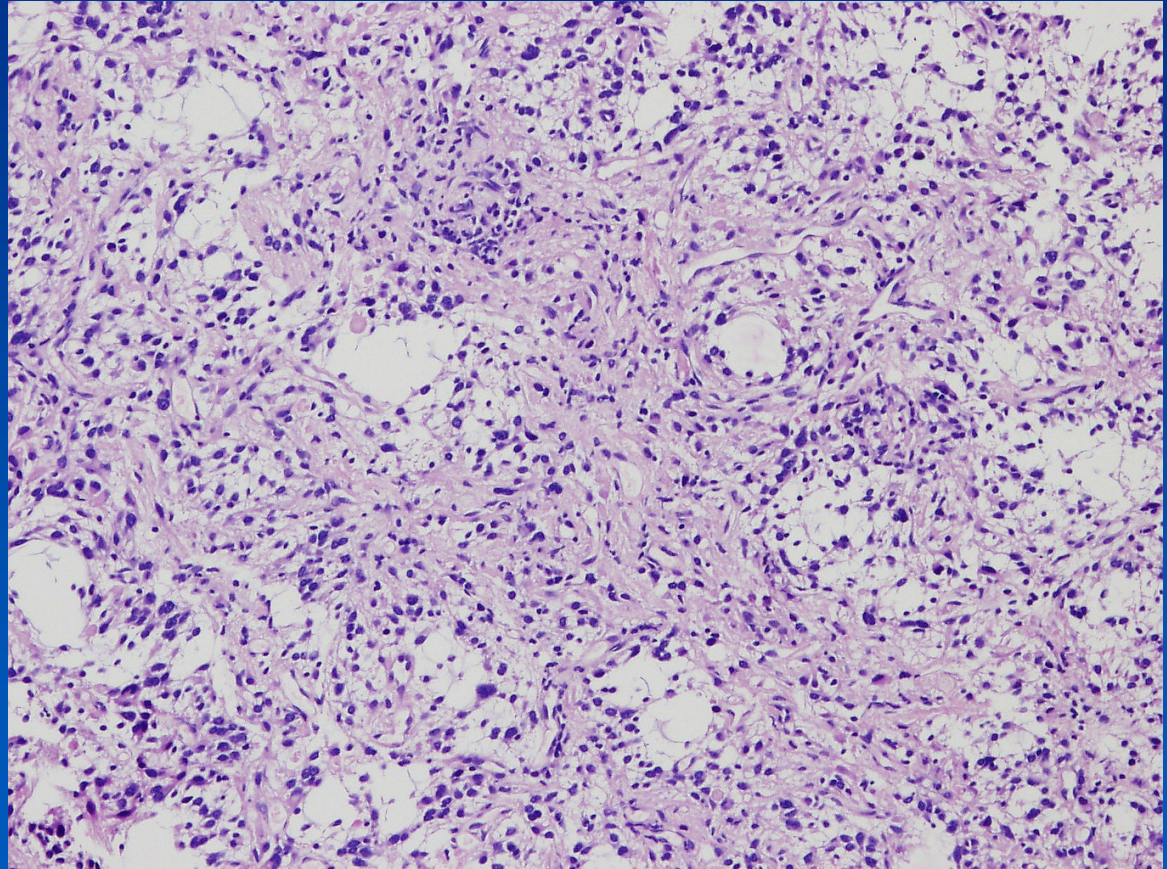
Bipolar cells with
eosinophilic granular
bodies and Rosenthal
fibers



Pilocytic astrocytoma



Microcystic area with
multipolar tumor cells



Selected tumors of the CNS

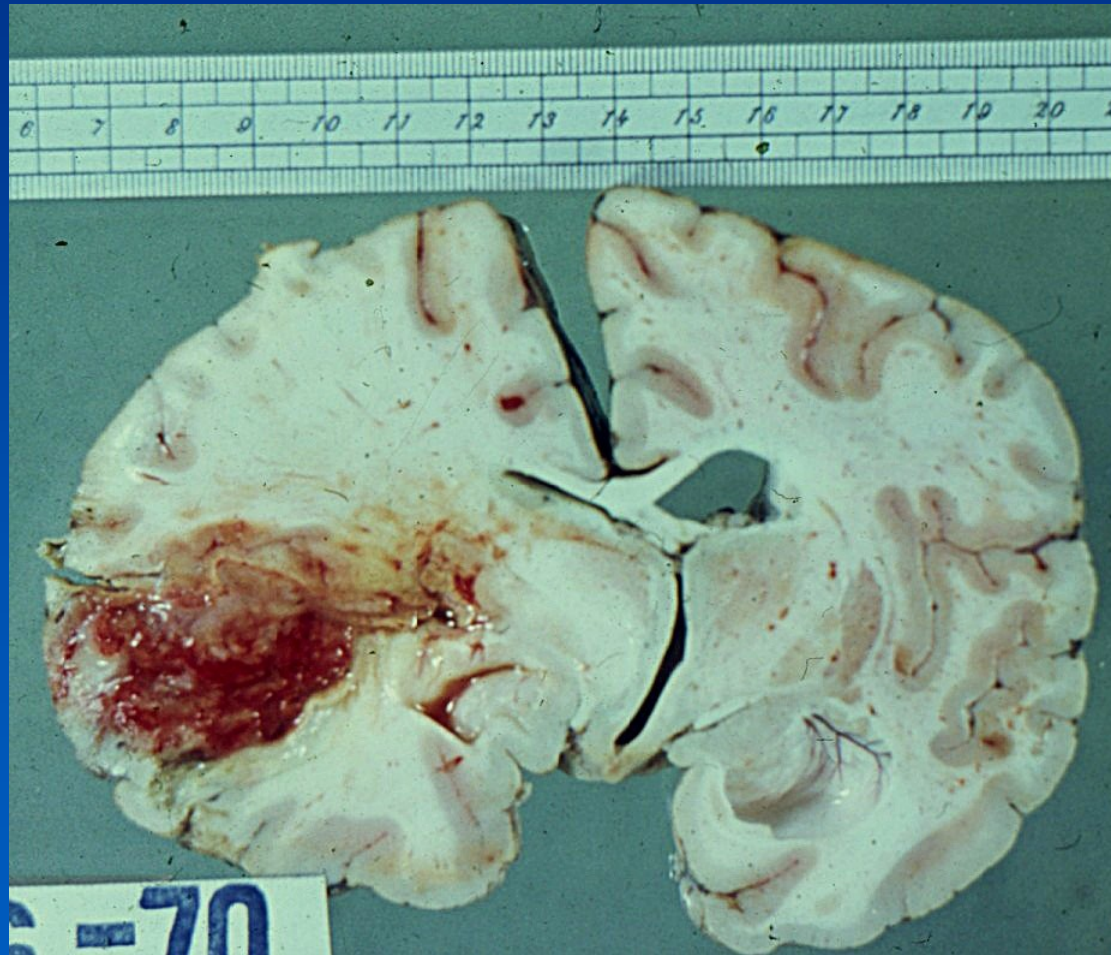


✘ Astrocytic tumors:

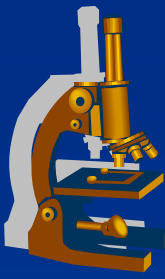
⇒ *glioblastoma* (WHO Grade IV):

- most aggressive malignant primary brain tumor in adults
- pleomorphic cells with marked cellular and nuclear atypia, high mitotic activity
- prominent microvascular proliferation and/or necrosis
- pseudopalisading pattern of cells on the periphery of necrosis
- regional tumor heterogeneity:
 - atypical pleomorphic areas may alternate with regions of more regular structure

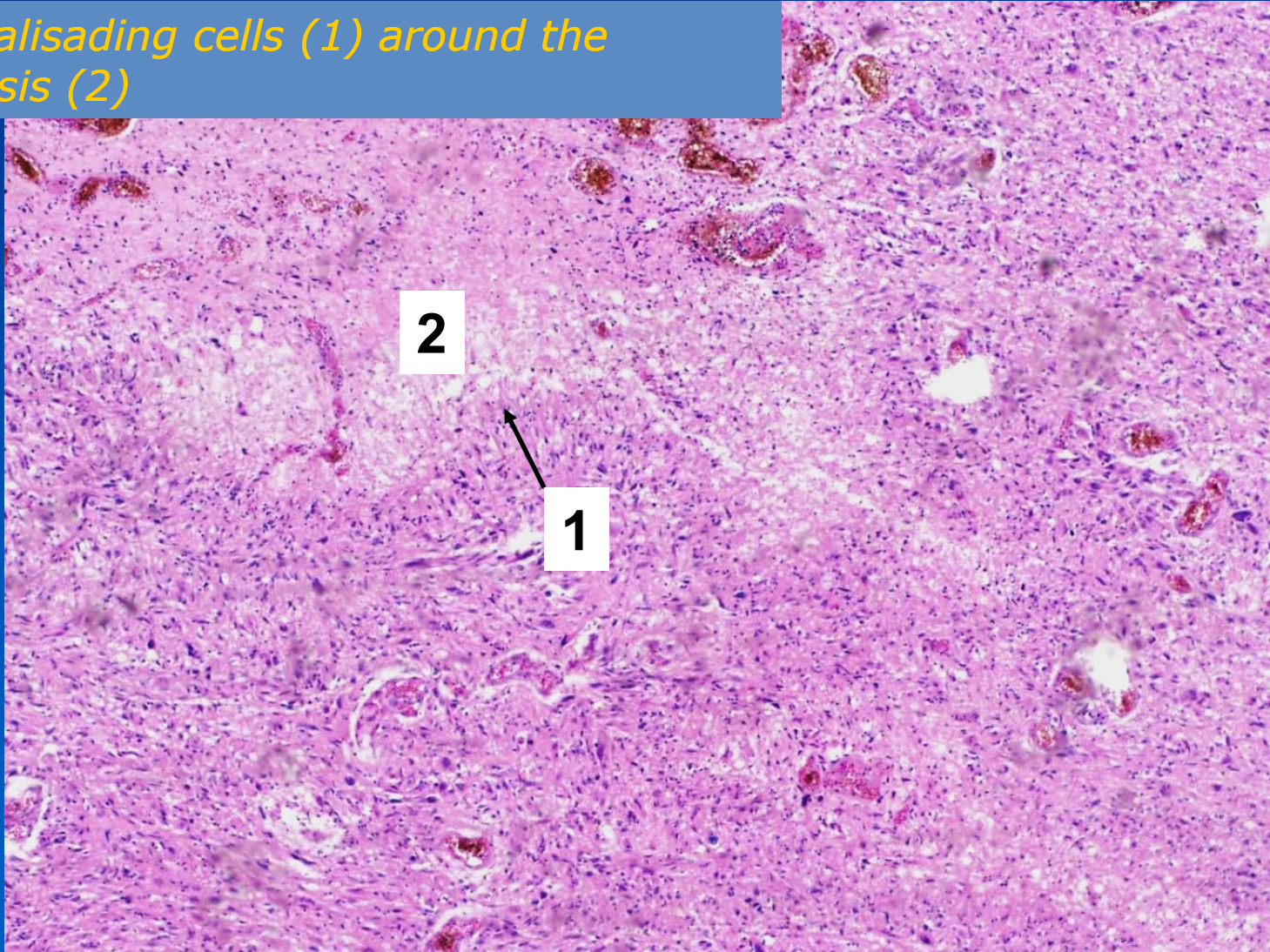
Glioblastoma



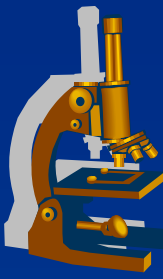
Glioblastoma



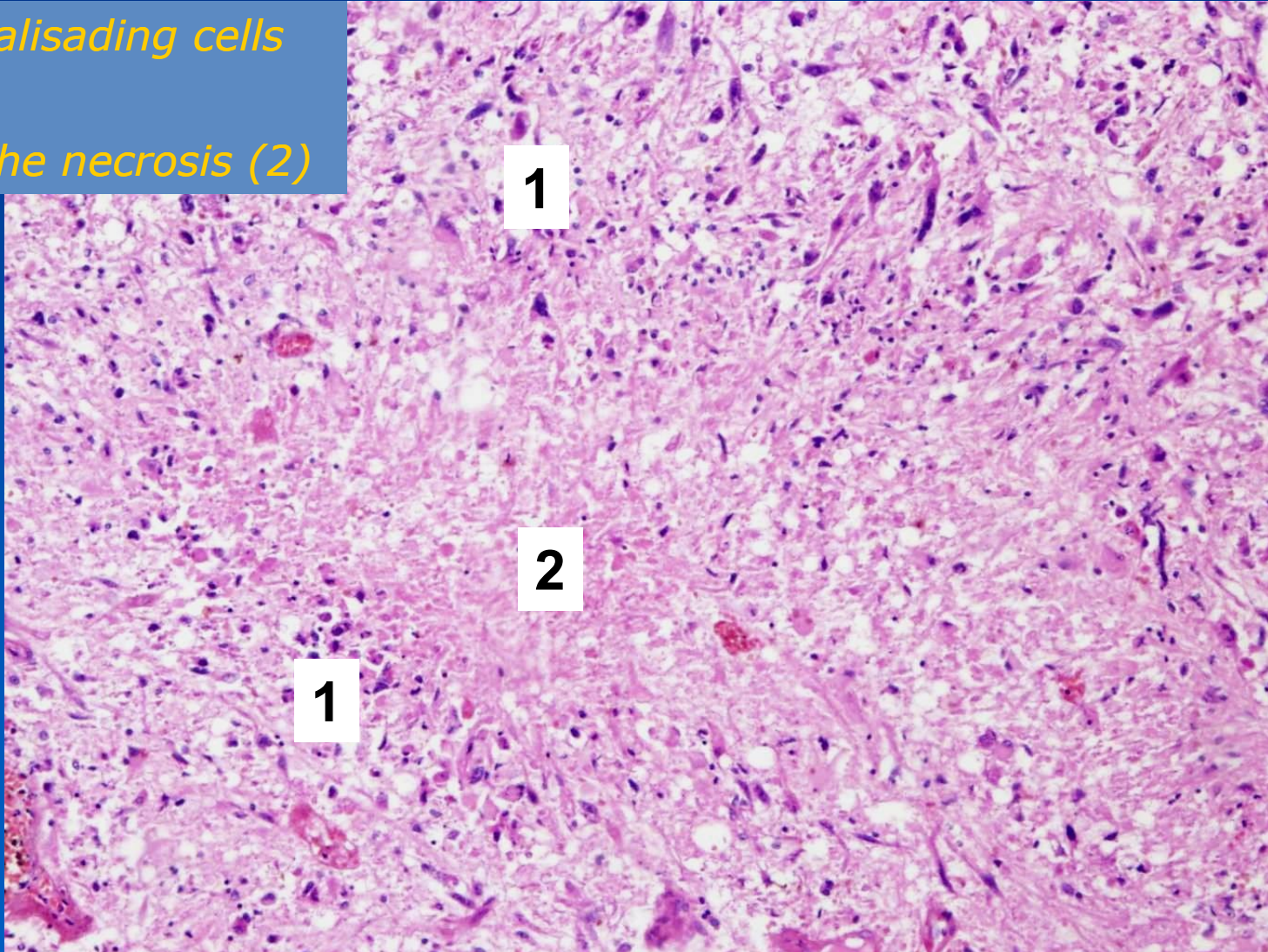
*Pseudopalisading cells (1) around the
necrosis (2)*



Glioblastoma multiforme



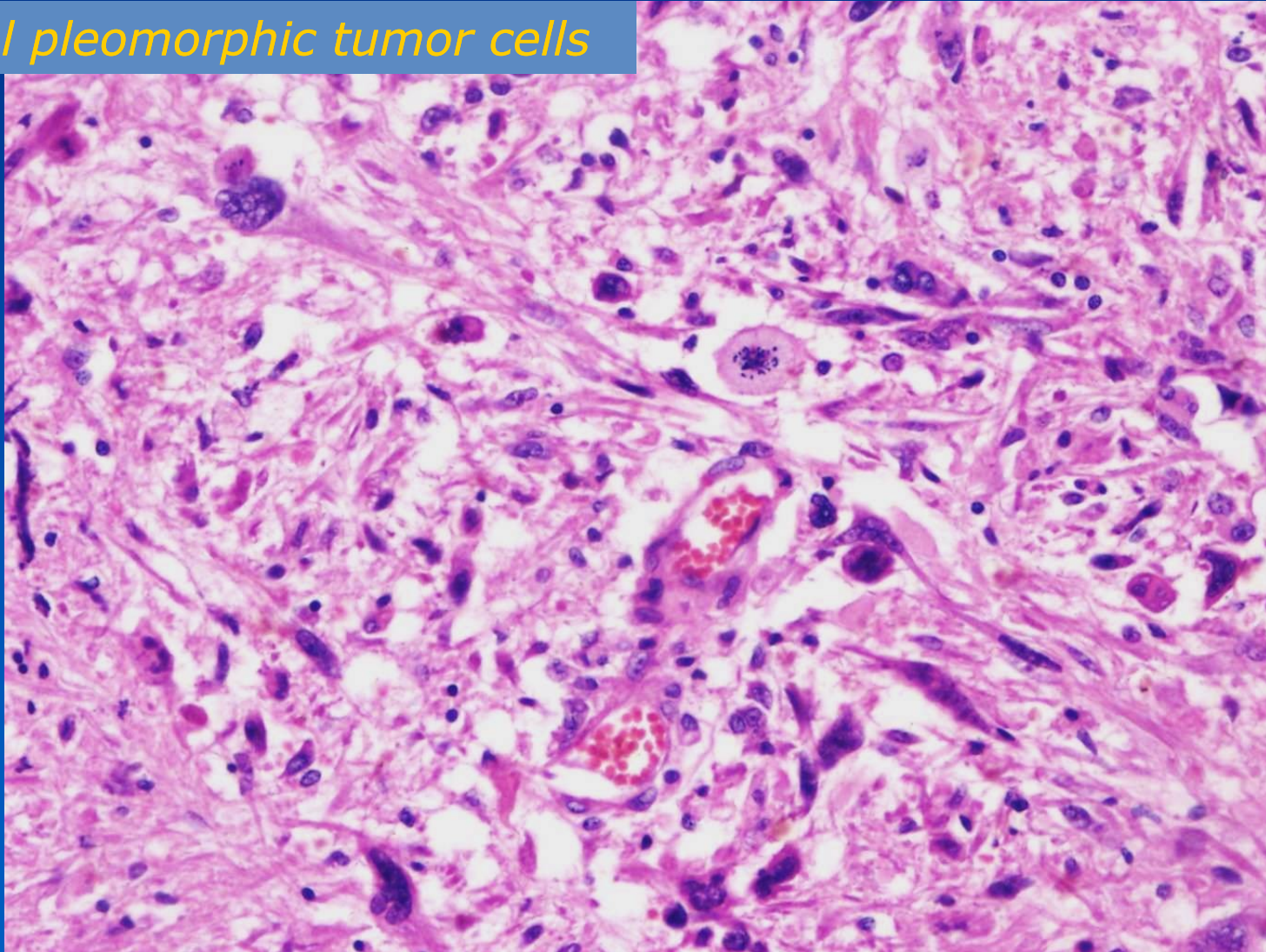
*Pseudopalisading cells
(1)
around the necrosis (2)*



Glioblastoma multiforme



Atypical pleomorphic tumor cells



Selected tumors of the CNS

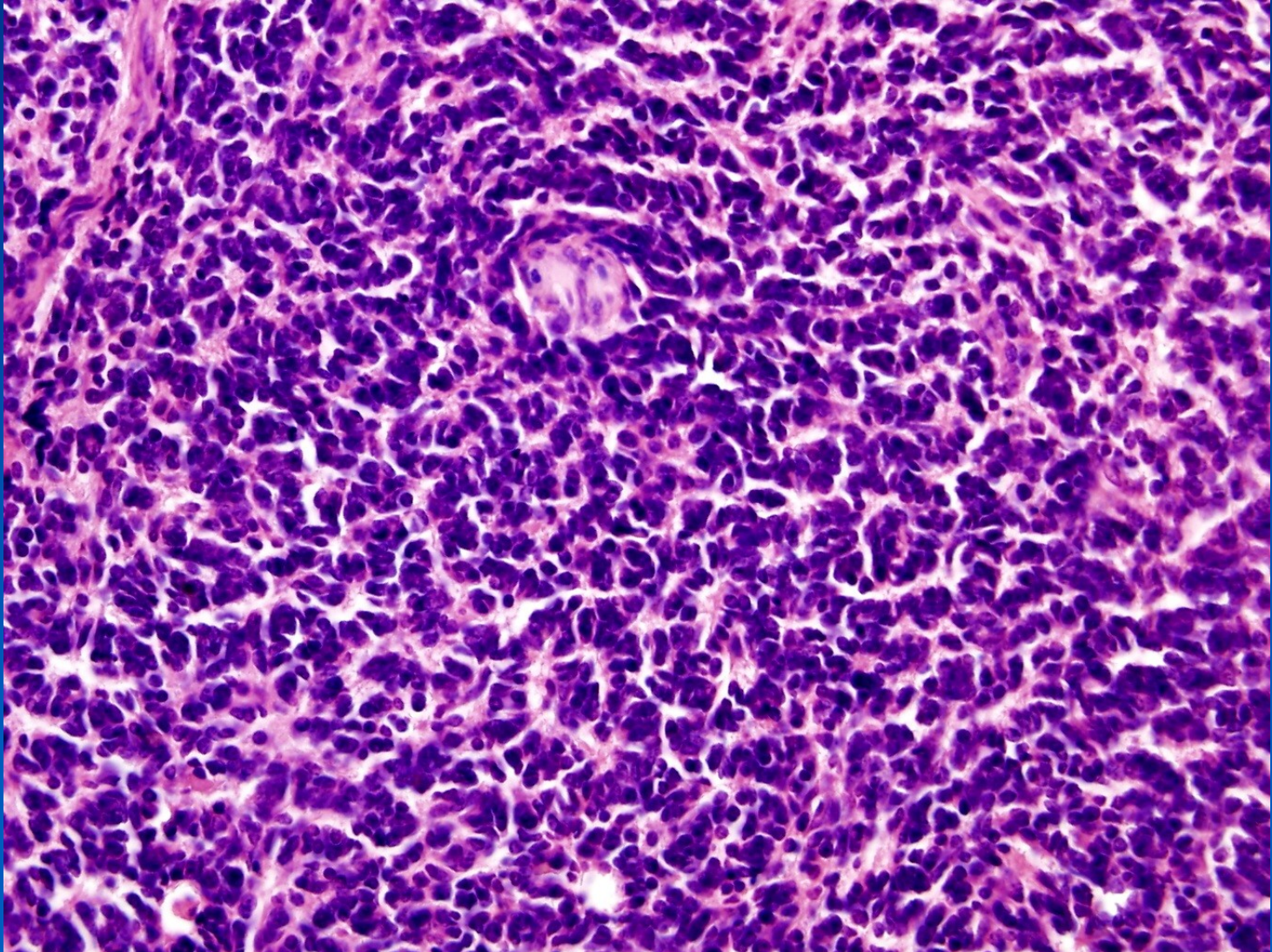
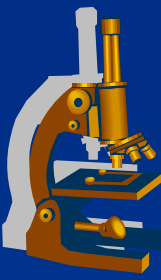


x Embryonal tumors:

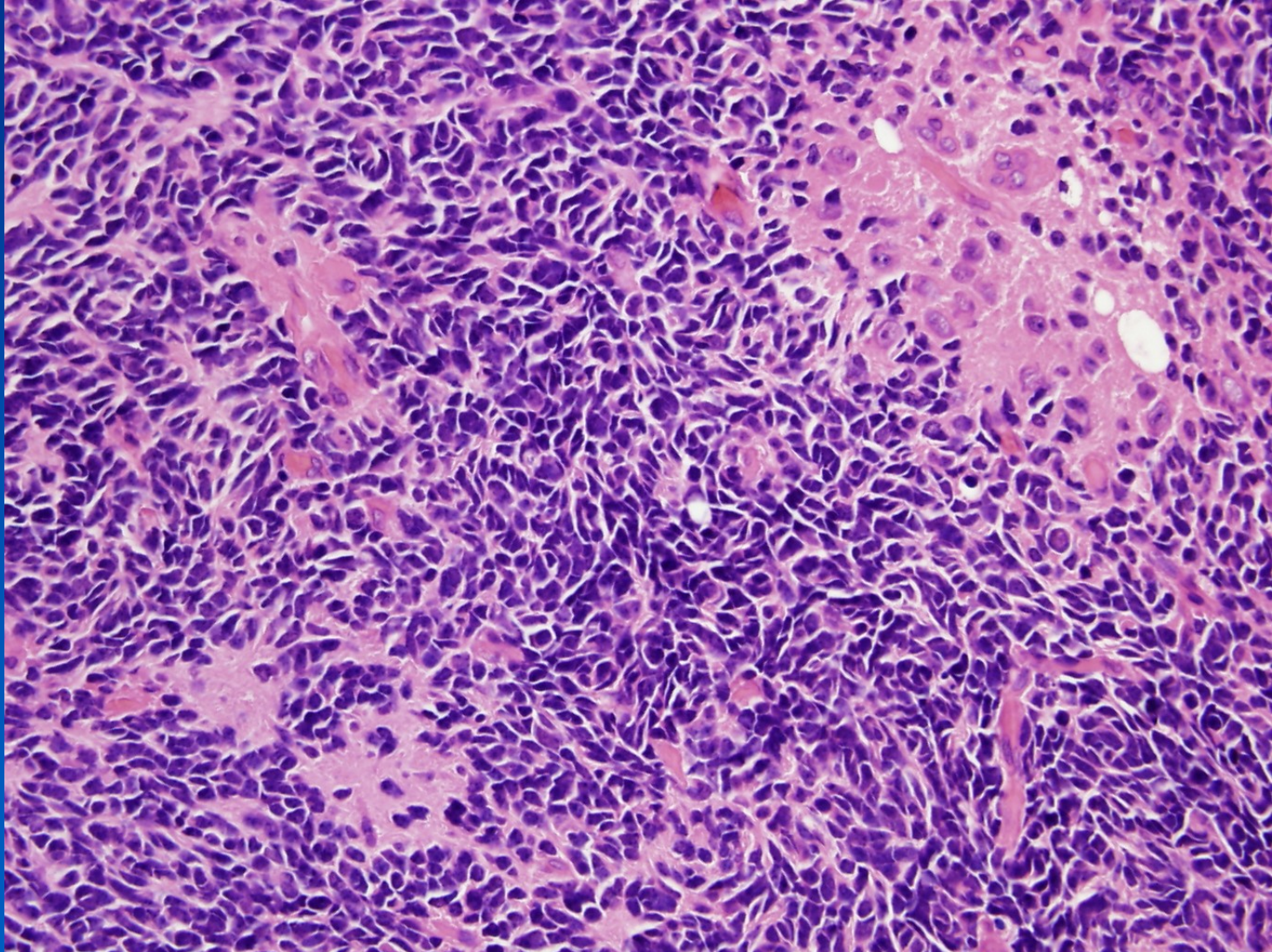
⇒ ***medulloblastoma*** e.g.:

- predominantly occurs in children, in the cerebellum
- extremely cellular: small, round or spindle tumor cells
- hyperchromatic nuclei with high mitotic activity
- characteristic ***neuroblastic Homer-Wright rosettes***:
 - groups of tumor cells arranged in a circle around a mesh of cytoplasmic processes

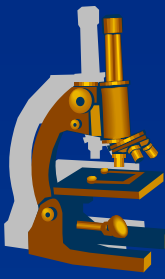
Medulloblastoma



Medulloblastoma



Tumors of meninges



x Meningioma (WHO Grade I):

⇒ **Gross:**

- different size, well-circumscribed, often spheric
- attached to the dura
- compresses underlying brain tissue

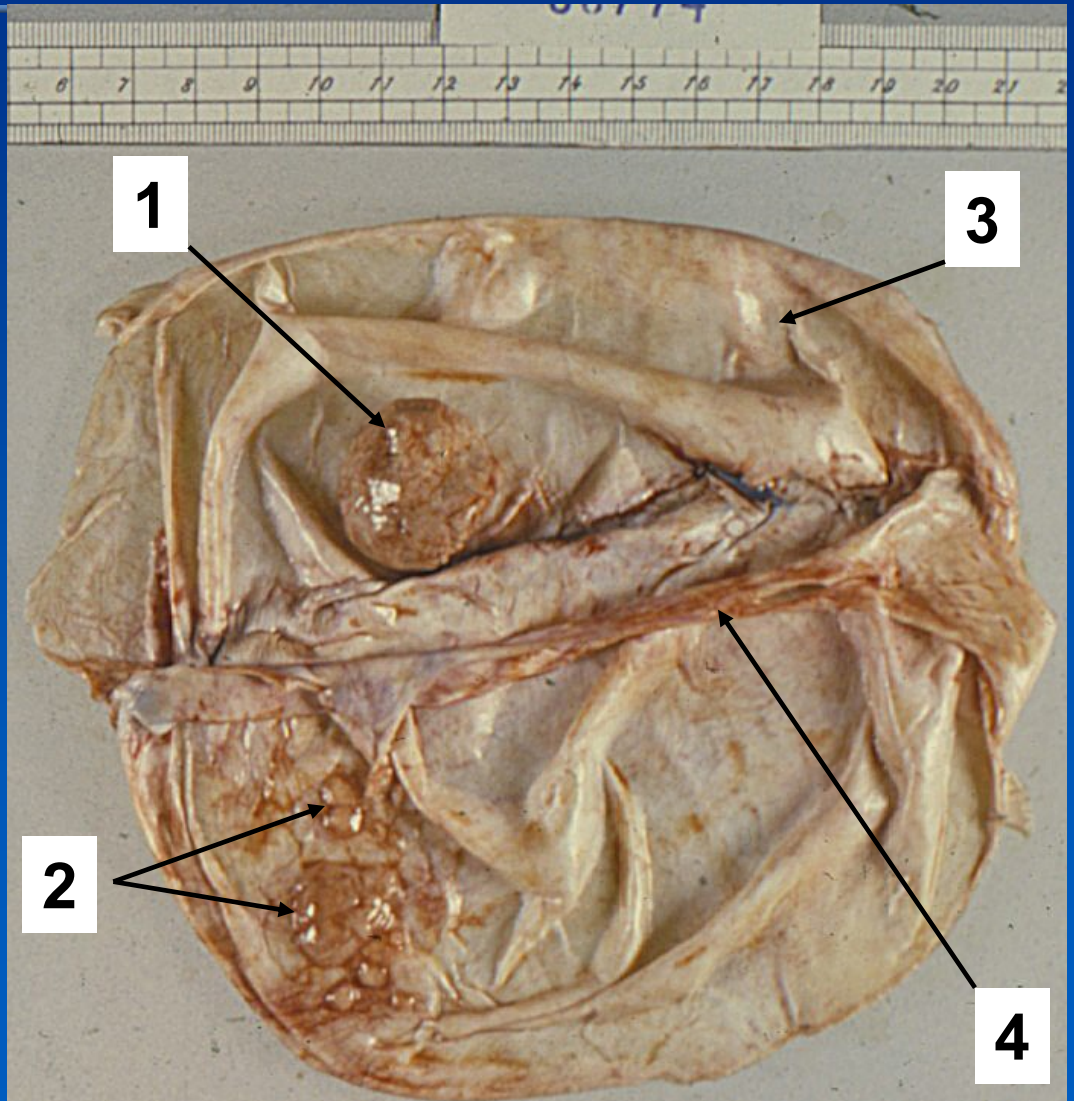
⇒ **Micro:**

- spindle cells arranged in whorls, bands, nodules
- frequent psammoma bodies:
 - basophilic, concentric, lamellated calcified structures

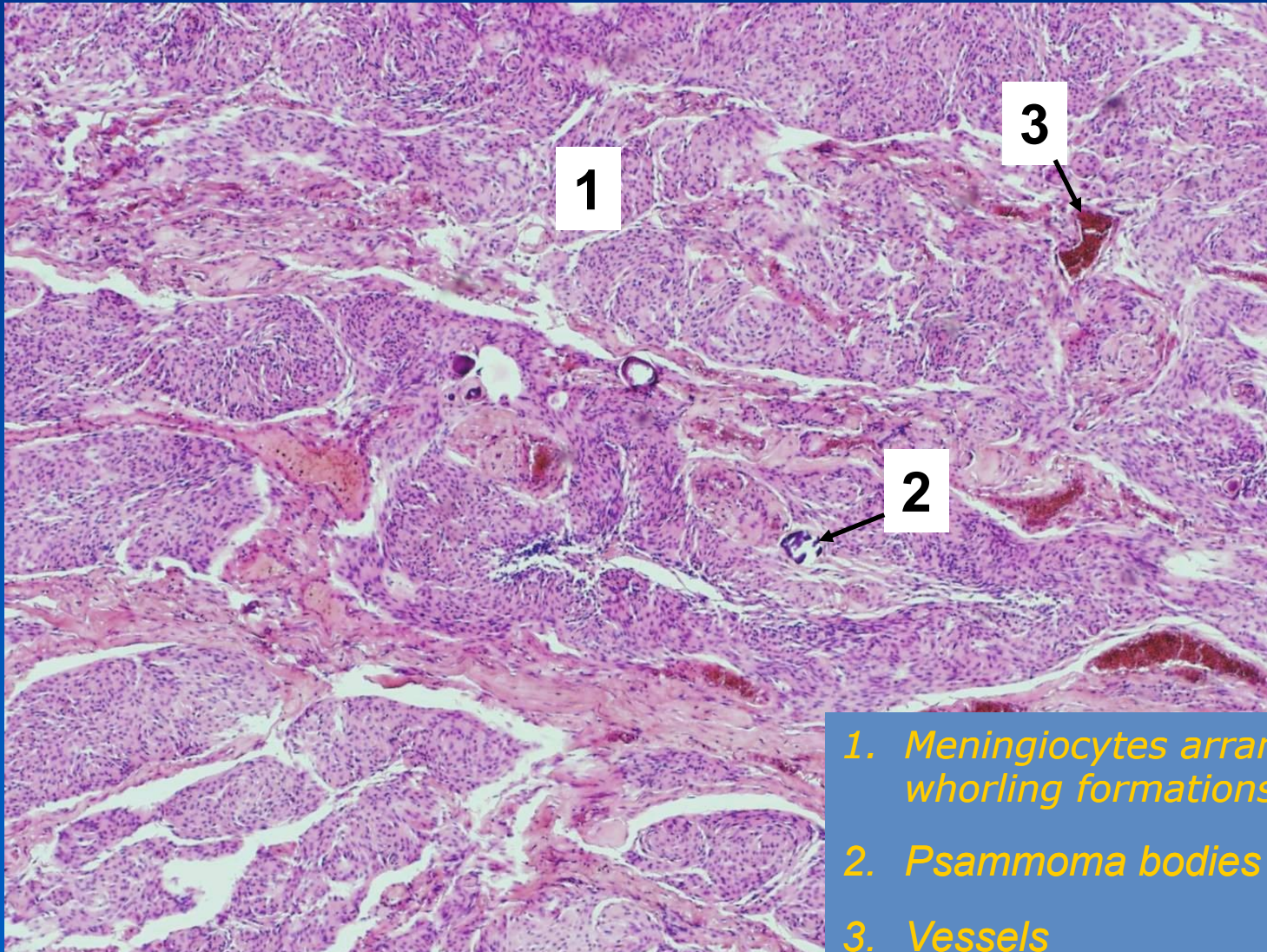
Meningioma



1. *Nodule of meningioma*
2. *Flat meningiomas*
3. *Dura mater*
4. *Falx cerebri*

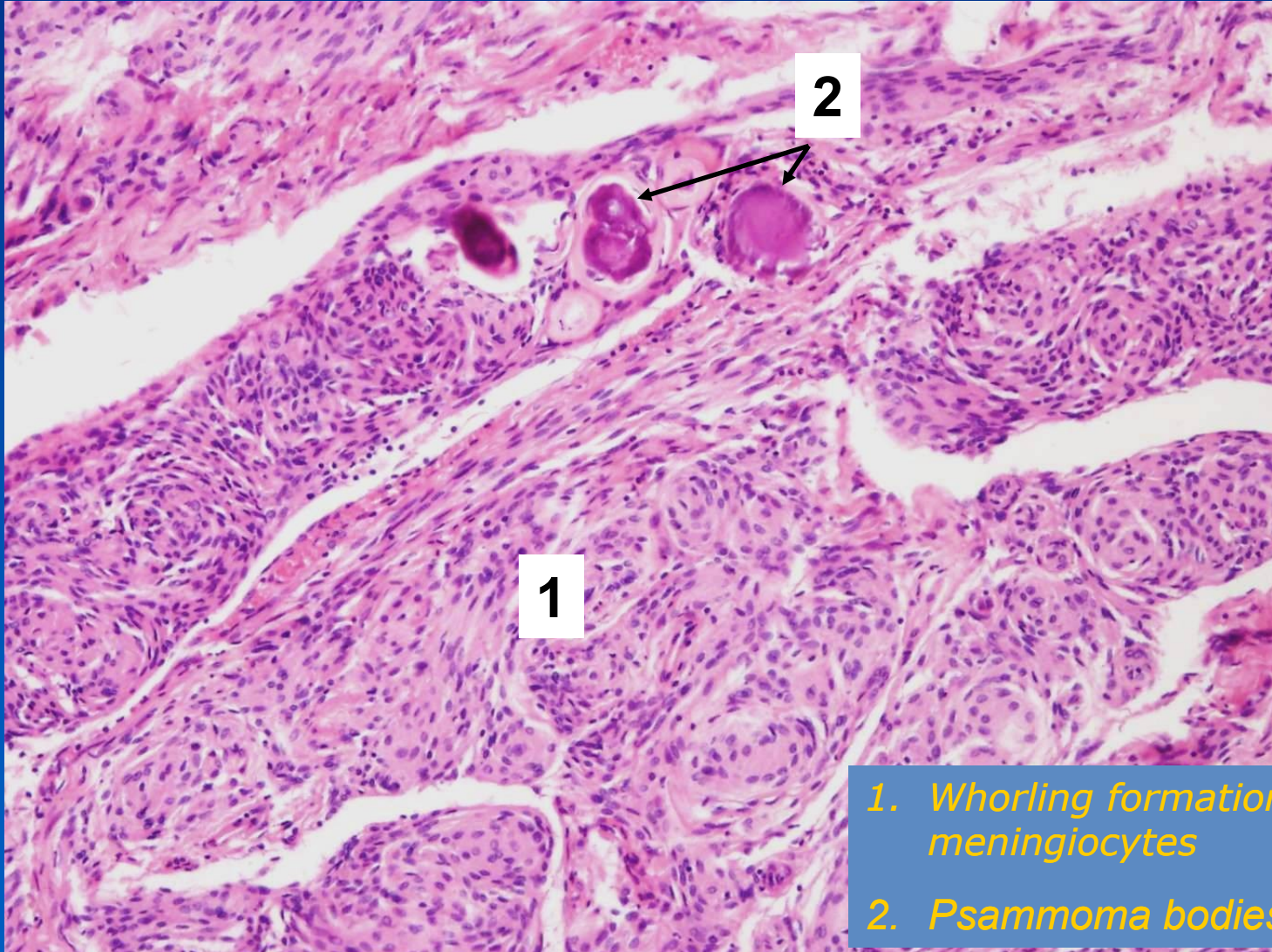


Meningioma



1. Meningiocytes arranged in whorling formations
2. Psammoma bodies
3. Vessels

Meningioma

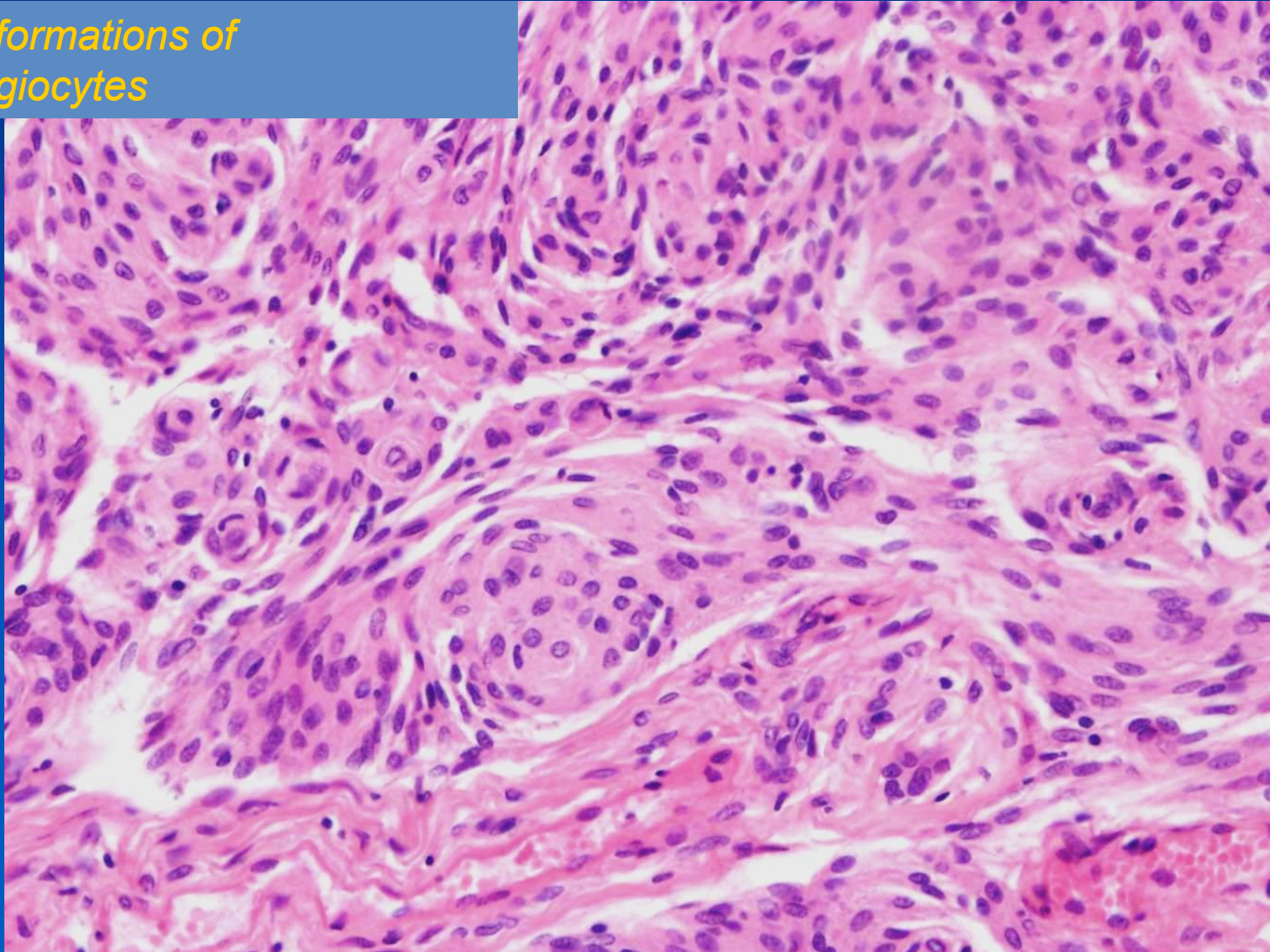


- 1. Whorling formations of meningiocytes*
- 2. Psammoma bodies*

Meningioma



*Whorling formations of
meningiocytes*



Selected peripheral neuroectodermal tumors



✗ schwannoma (neurinoma, neurilemmoma)

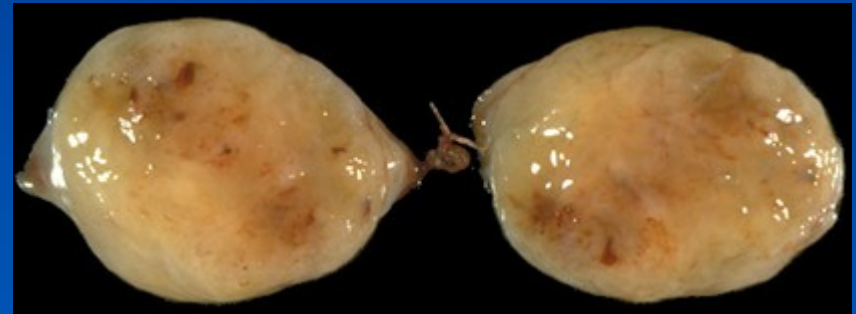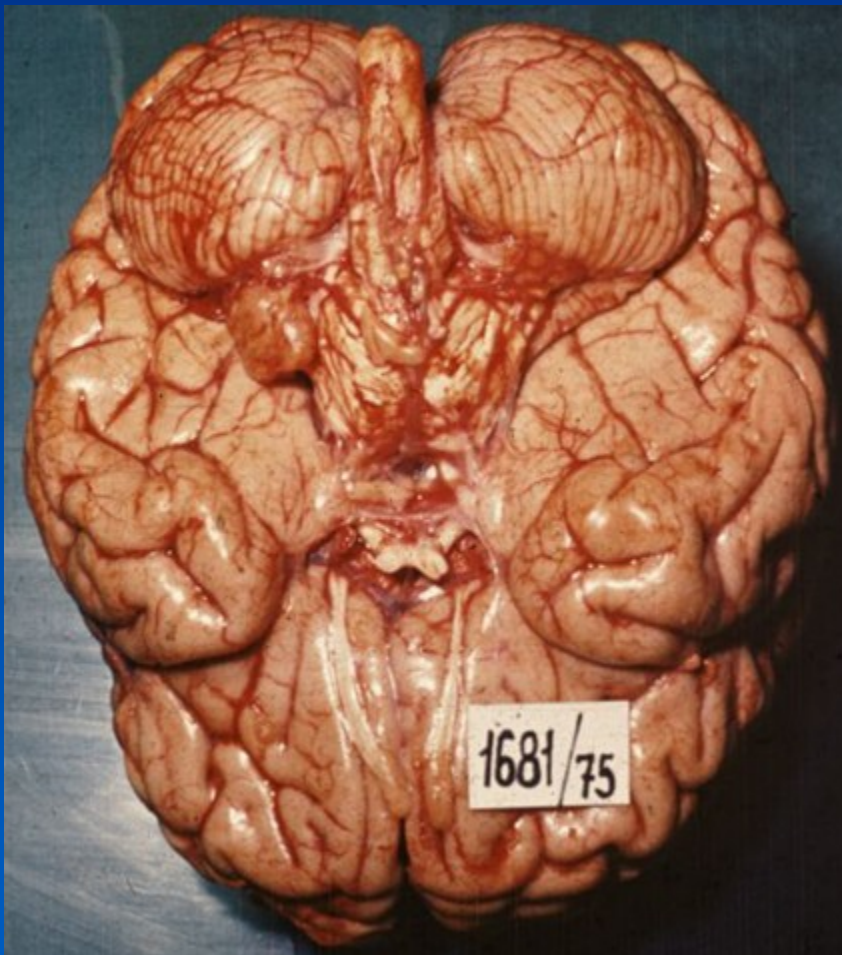⇒ *benign nerve sheath tumor*

⇒ *arise from Schwann cells in peripheral nerves or intracranially*

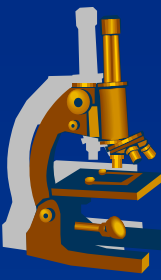
⇒ **Micro:**

- cellular areas with nuclear palisading and nuclear-free zones (**Antoni A pattern**)
- less cellular areas, often oedematous, with loose cell arrangement (**Antoni B pattern**)

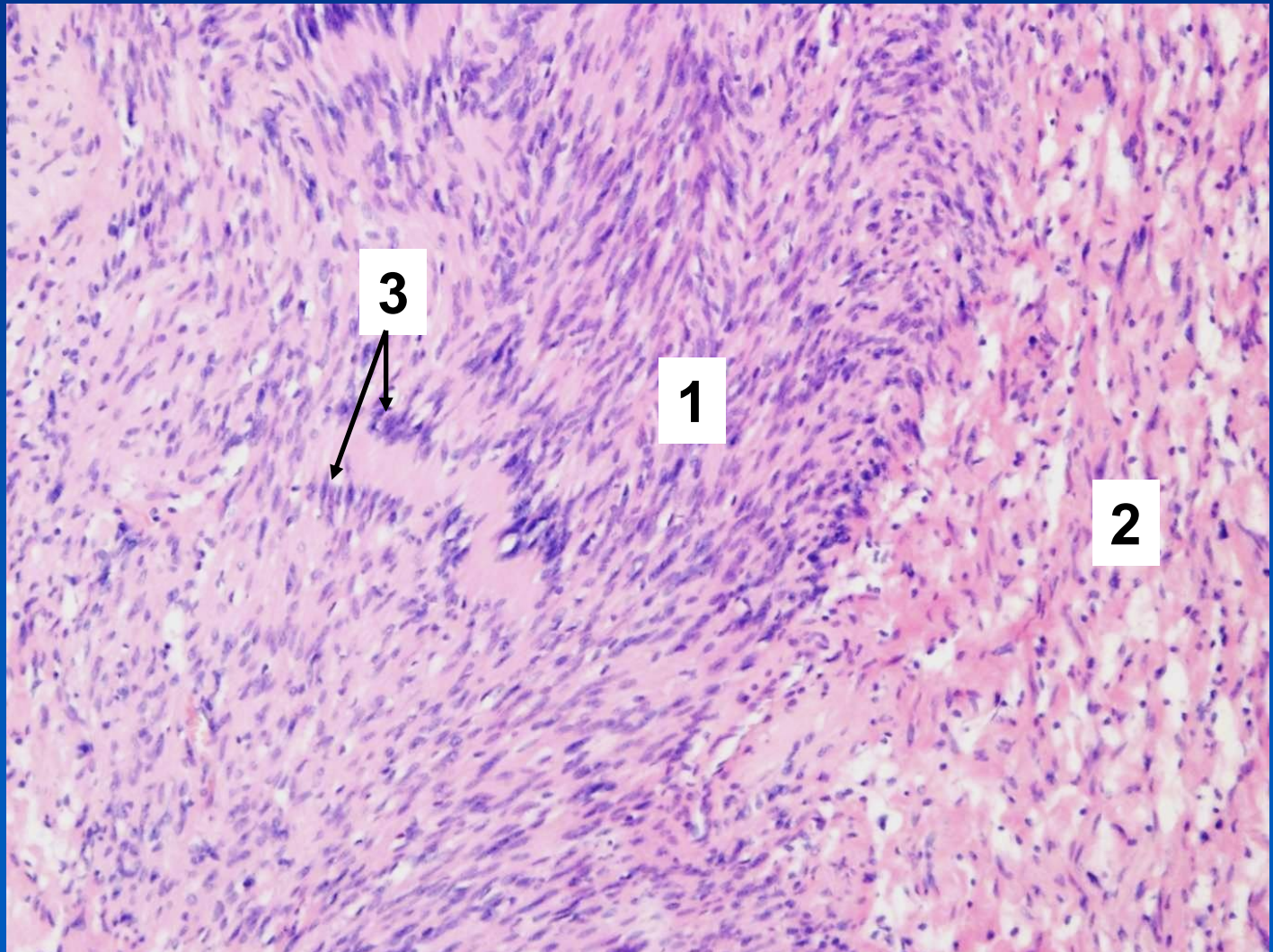
Schwannoma



Schwannoma



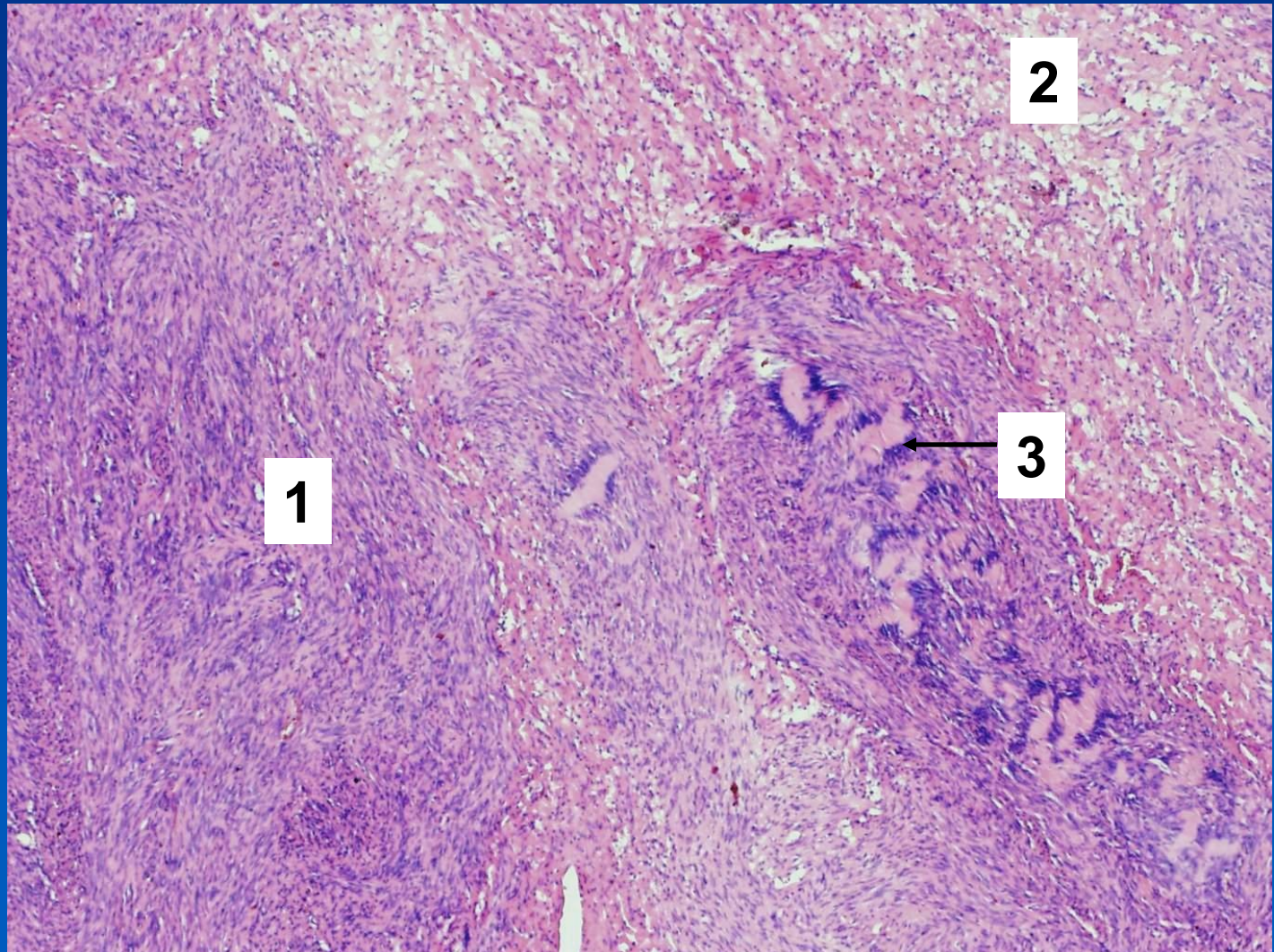
1. Antoni A
2. Antoni B
3. Palisading



Schwannoma



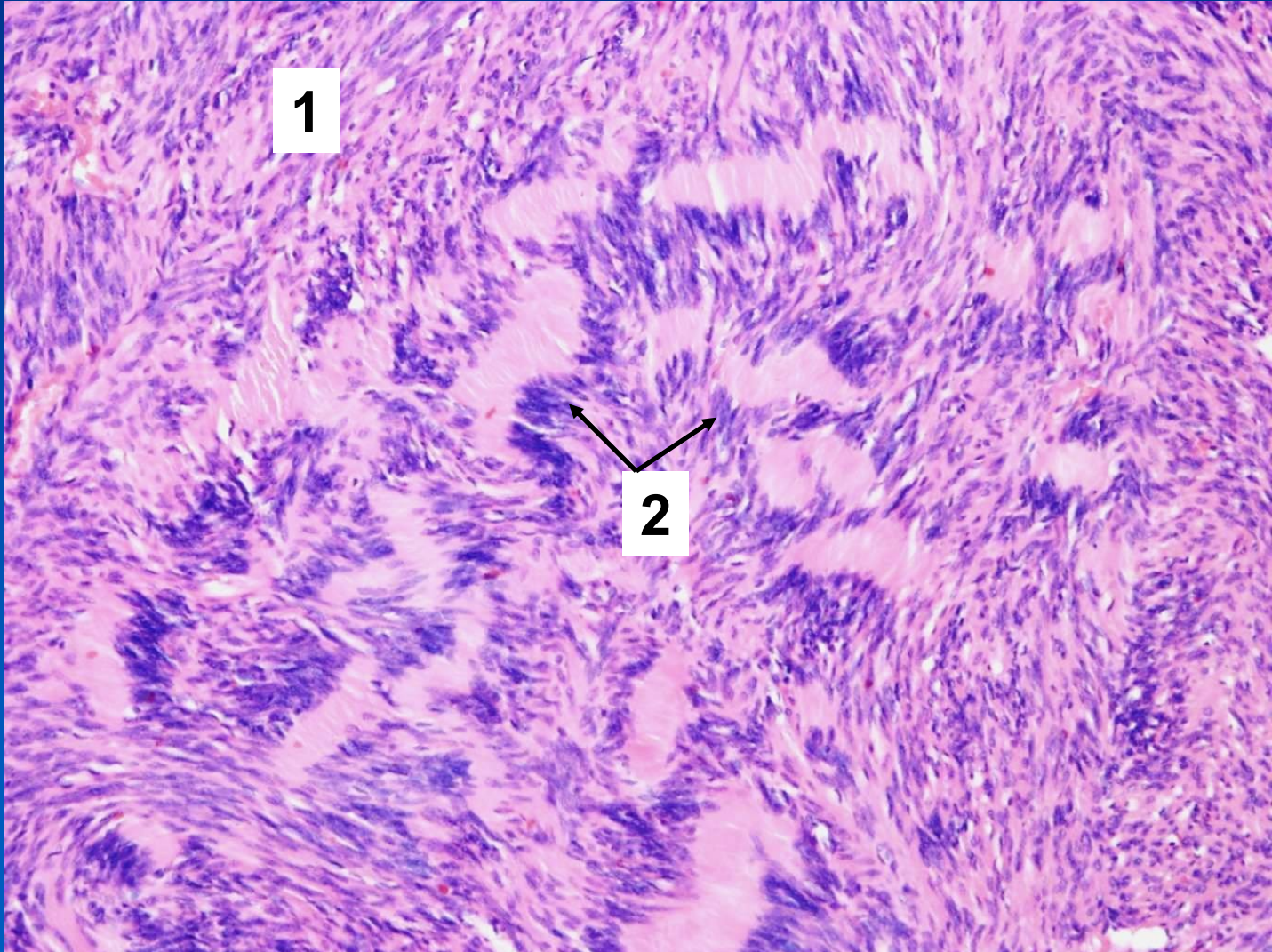
1. *Antoni A*
2. *Antoni B*
3. *Palisading*



Schwannoma



1. *Antoni A*
2. *Palisading*



Selected peripheral neuroectodermal tumors



x neurofibroma:

⇒ *nerve sheath tumor*

⇒ **2 forms:**

- *cutaneous neurofibroma* – in the dermis and subcutaneous fat, demarcated
- *plexiform neurofibroma* – anywhere along/expanding a nerve, potential for malignant transformation

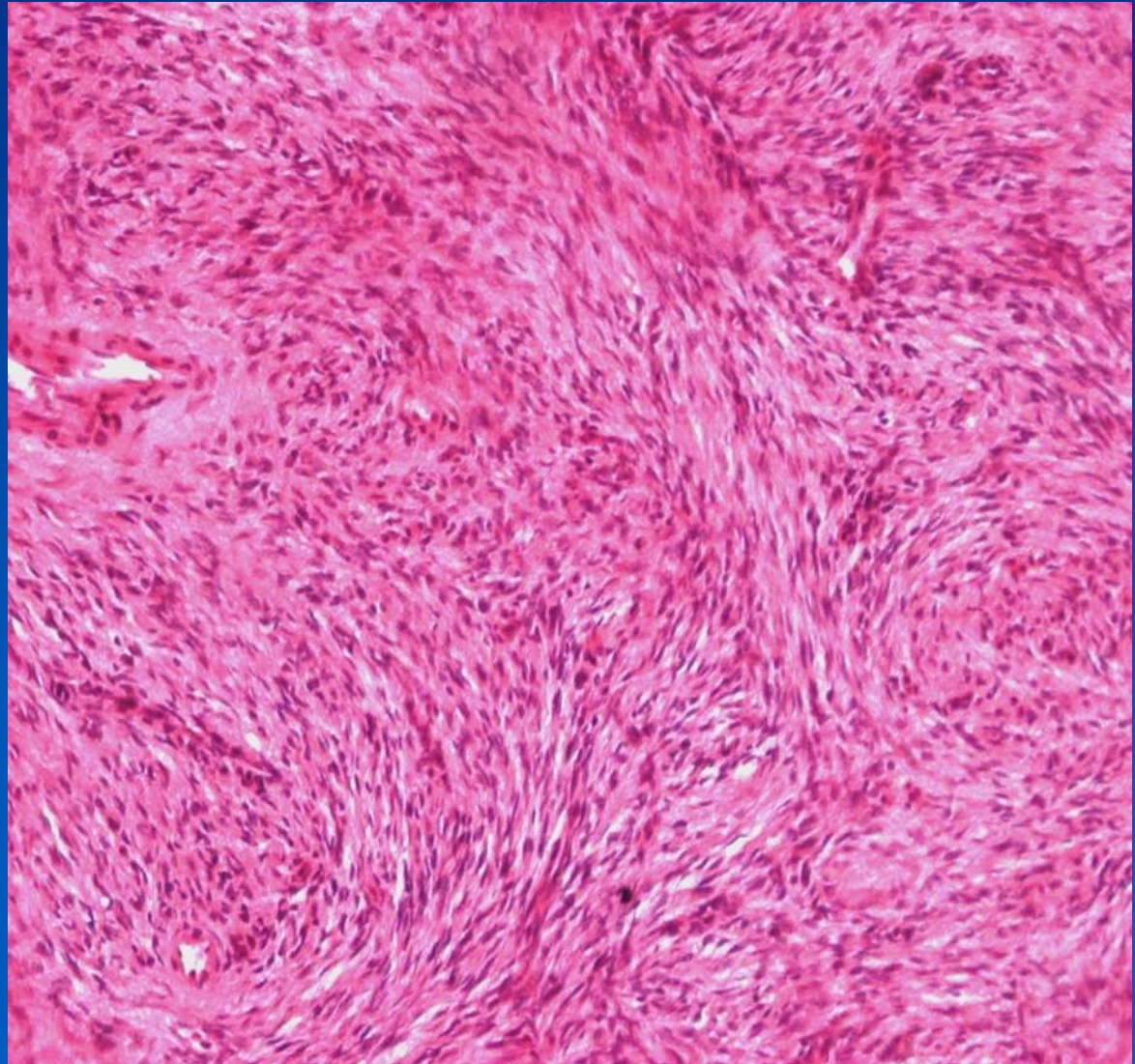
⇒ **Micro:**

- spindle cells with S-shaped nuclei
- highly collagenized stroma in cutaneous n.
- myxoid background in plexiform n.

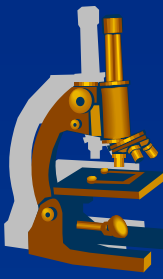
Neurofibroma



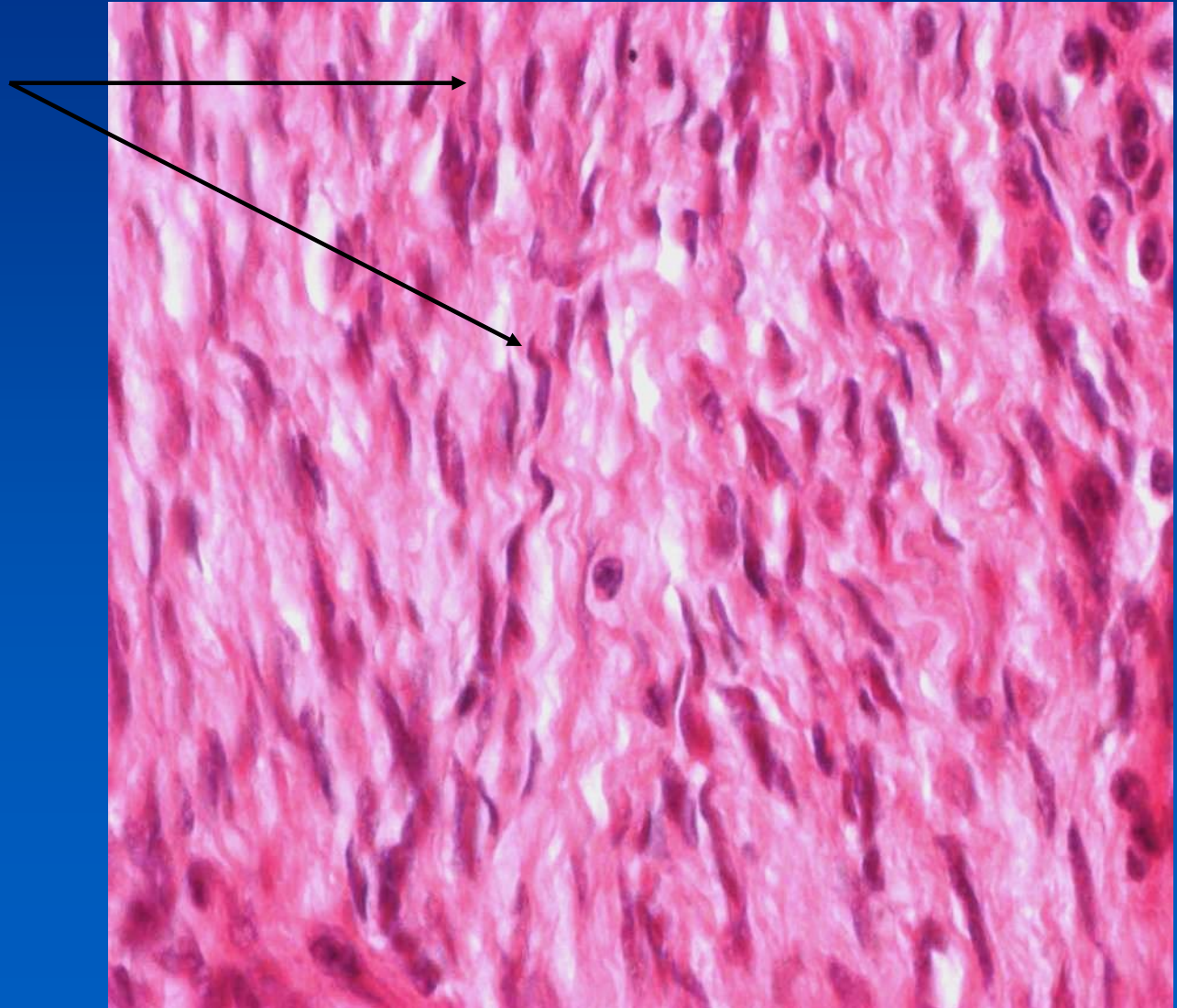
Spindle-like cells in the collagenized stroma



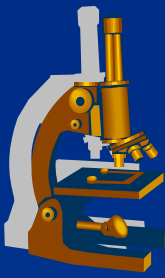
Neurofibroma



Wavy looking
S-shaped nuclei



Melanocytic lesions



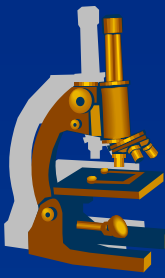
× Benign:

- ⇒ *freckles (ephelides)*
- ⇒ *benign solar lentigo*
- ⇒ *melanocytic nevi*
- ⇒ *Spitz nevus*
- ⇒ *dysplastic nevus*

× Malignant melanoma:

- ⇒ *nodular*
- ⇒ *superficial spreading*
- ⇒ *lentigo maligna*
- ⇒ *acral lentiginous melanoma*

Melanocytic nevus



✗ benign tumor, most types with rare malignant transformation

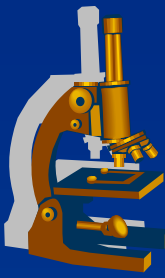
✗ Gross:

⇒ *tan to brown, small, solid foci in the skin*

⇒ *flat or elevated, with well-defined borders*

⇒ *congenital commonly larger in size*

Melanocytic nevus



✘Micro:

⇒ *junctional nevus*

- nests of melanocytes in the border between epidermis and dermis (junction zone)

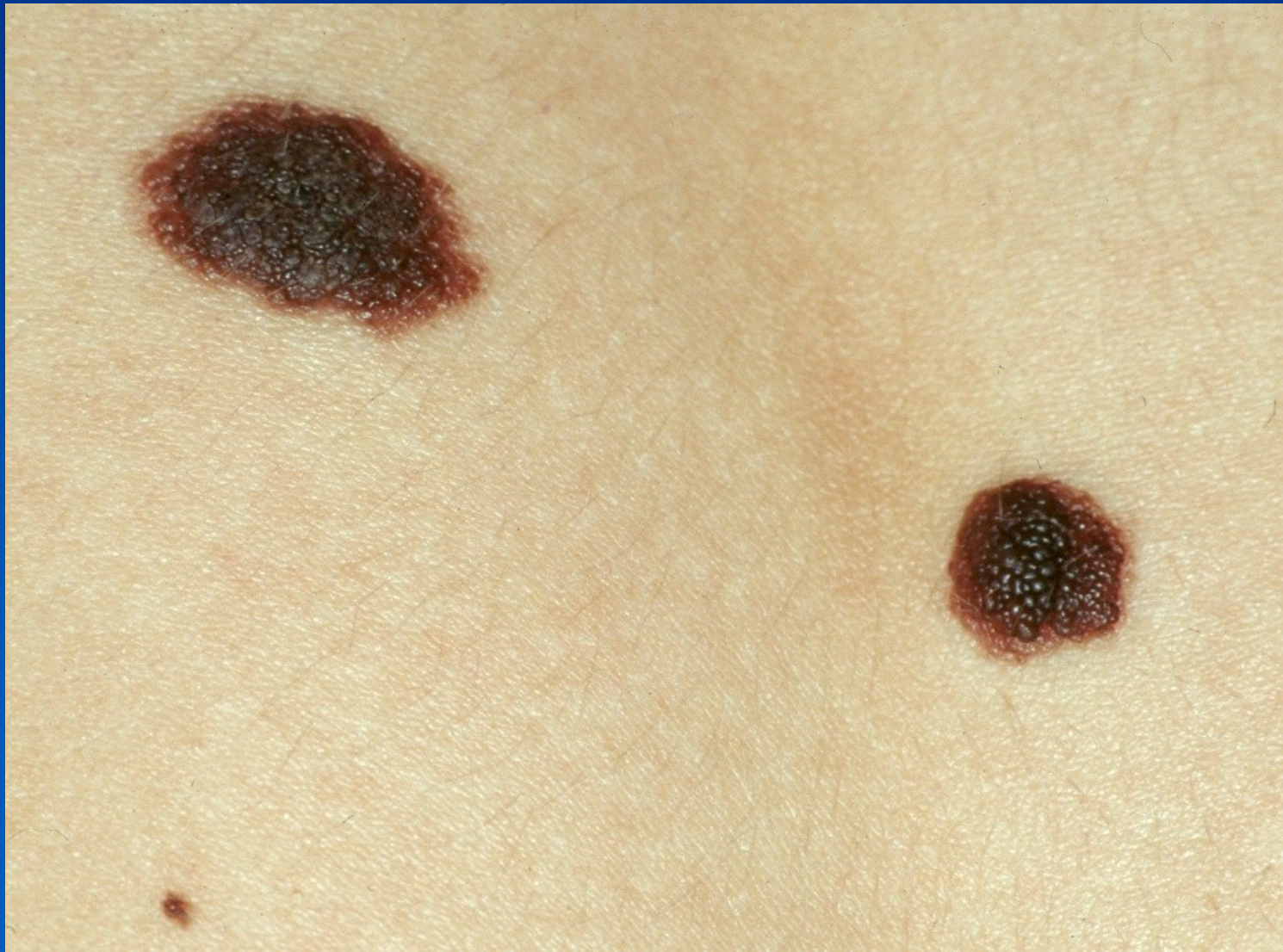⇒ *compound nevus*

- groups of melanocytes both in the junction zone and underlying dermis, arranged in nests or cords

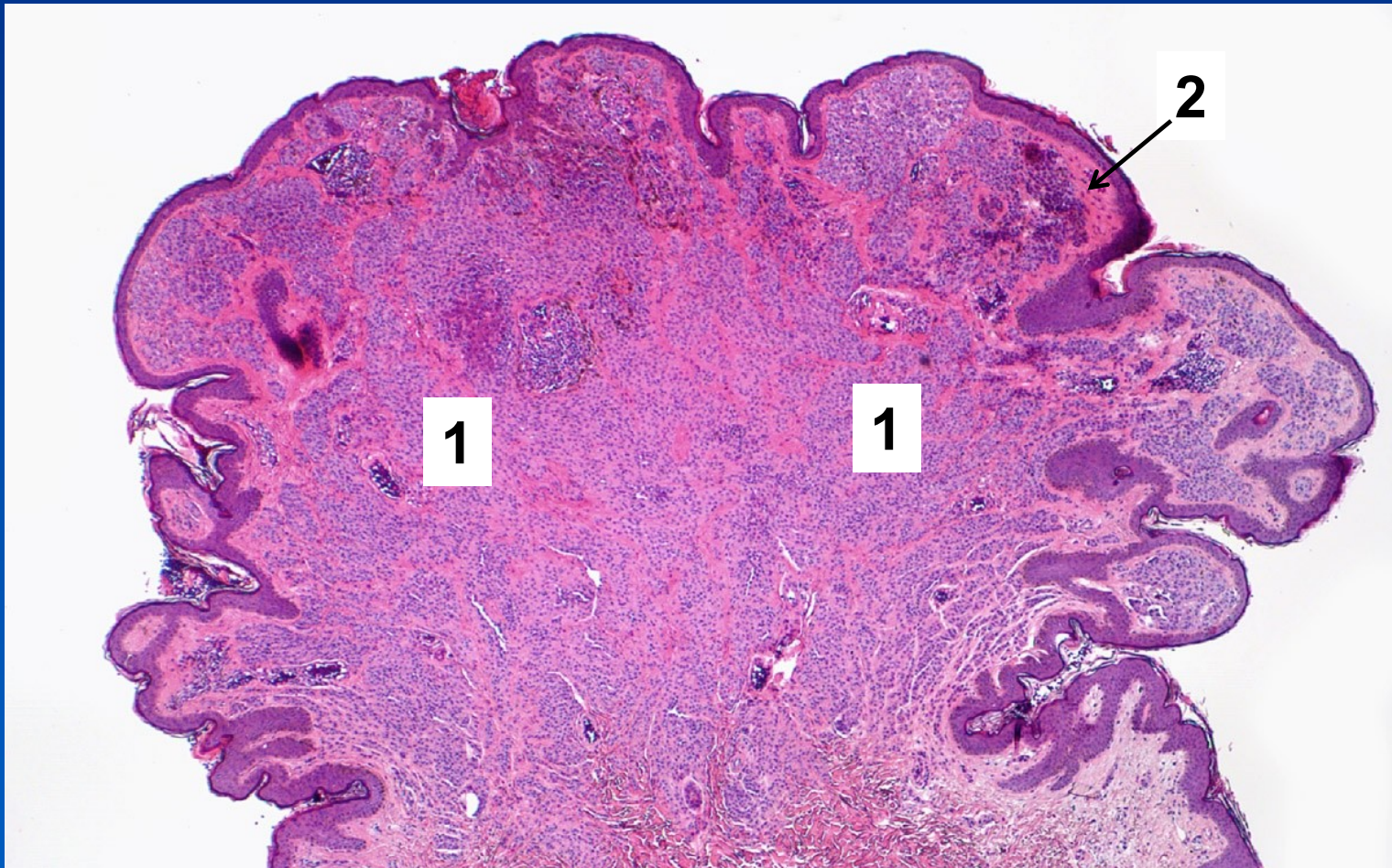
⇒ *intradermal nevus*

- the most mature stage of melanocytic nevus
- no epidermal nests, groups of melanocytes in dermis only

Melanocytic nevus



Intradermal melanocytic nevus



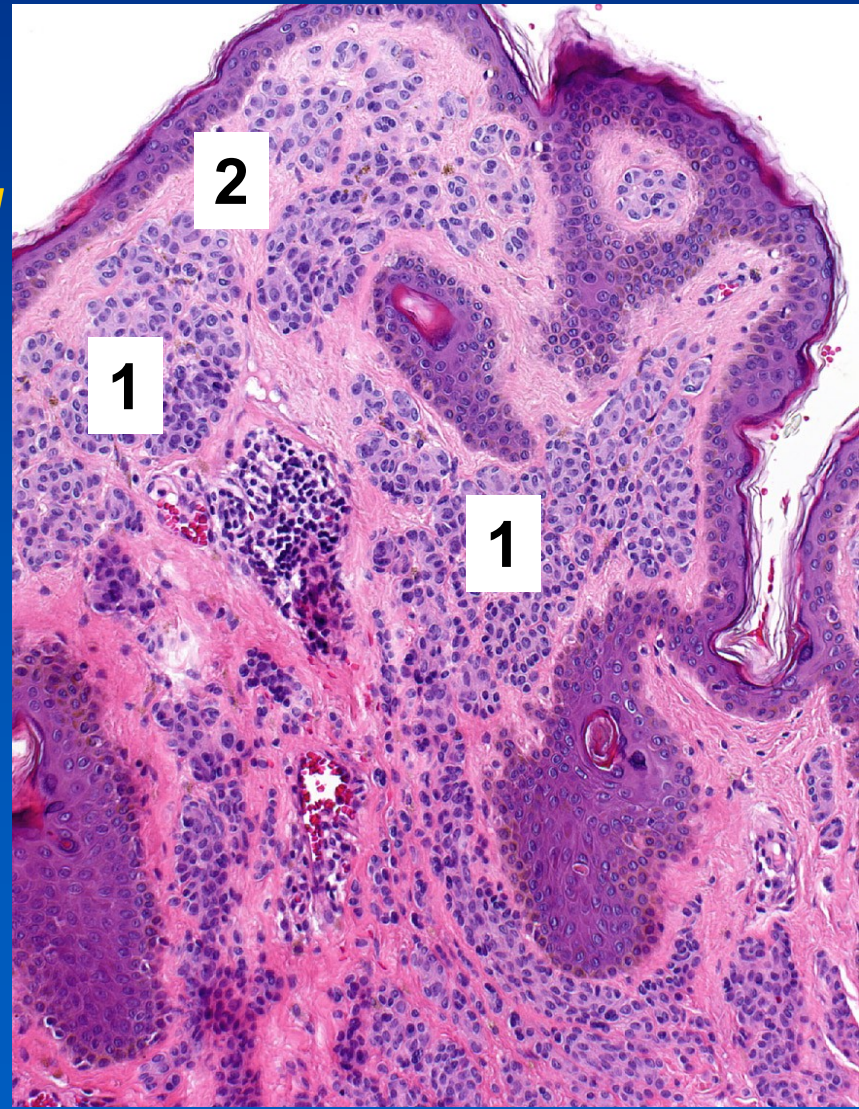
1. *Melanocytes*

2. *Papillary layer of the corium separating nests of melanocytes and epidermis*

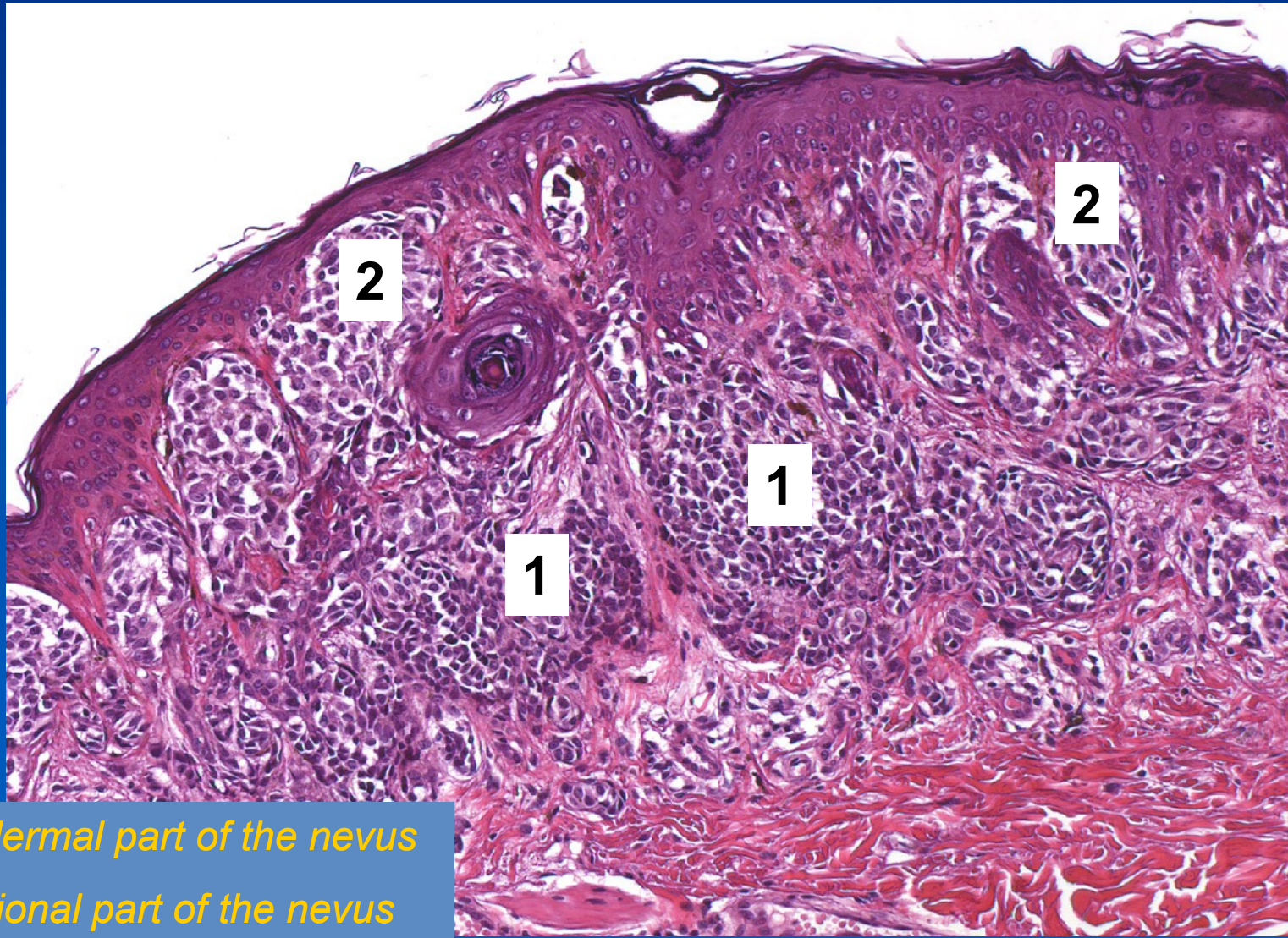
Intradermal melanocytic nevus



1. *Melanocytes*
2. *Papillary layer of the corium separating nests of melanocytes and epidermis*



Compound melanocytic nevus



1. Intradermal part of the nevus
2. Junctional part of the nevus

Malignant melanoma



x Arise:

⇒ *malignization of nevi (dysplastic)*

⇒ *de novo*

x Origin:

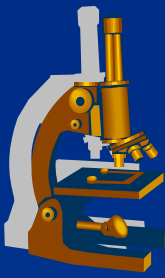
⇒ *skin*

⇒ *mucous membranes*

⇒ *meninges*

⇒ *eye*

Malignant melanoma



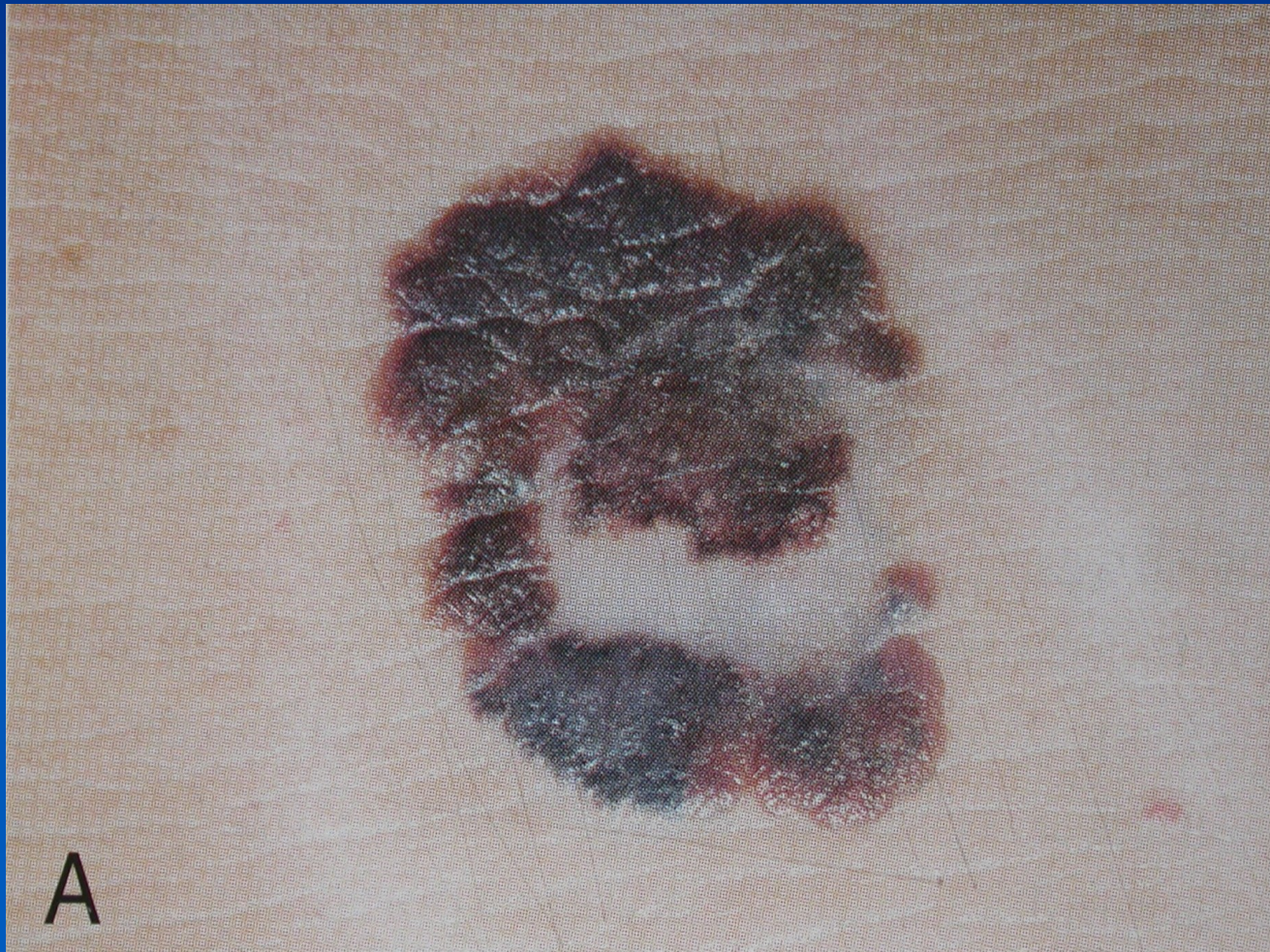xGross:

- ⇒ *in early stages similar to nevus*
- ⇒ **ABC - Asymetry**
- ⇒ **irregular Borders**
- ⇒ **variegated Color**
- ⇒ *ulceration and possible darkening in late stages*

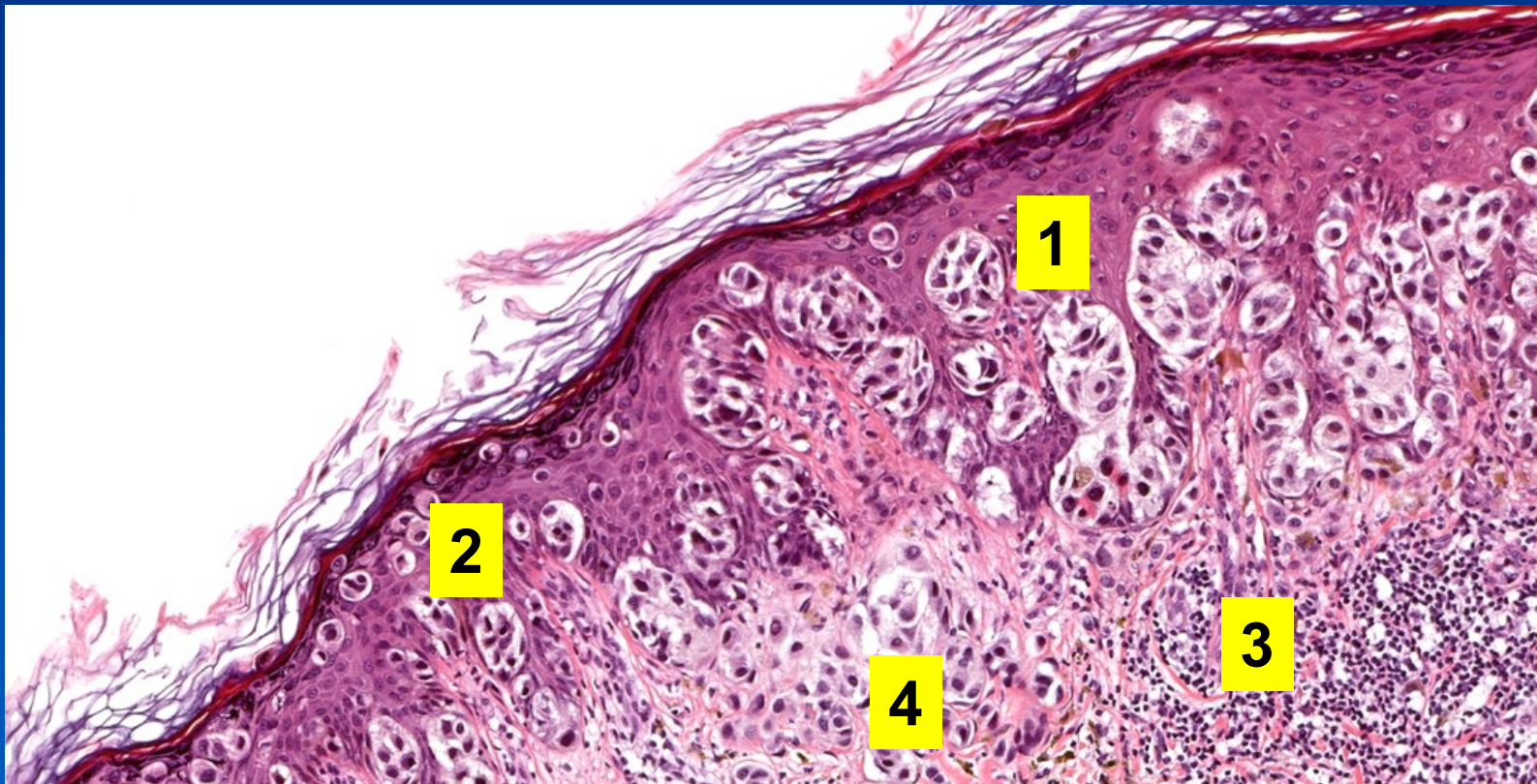
xMicro:

- ⇒ *atypical pleomorphic epitheloid or spindle-like cells*
- ⇒ *large hyperchromatic nuclei with prominent nucleoli*
- ⇒ *mitoses*
- ⇒ **asymmetric pigment deposition**
 - completely non-pigmented forms too
- ⇒ **immunoprofile:**
 - Melan A, S-100, HMB-45

Malignant melanoma – radial growth phase

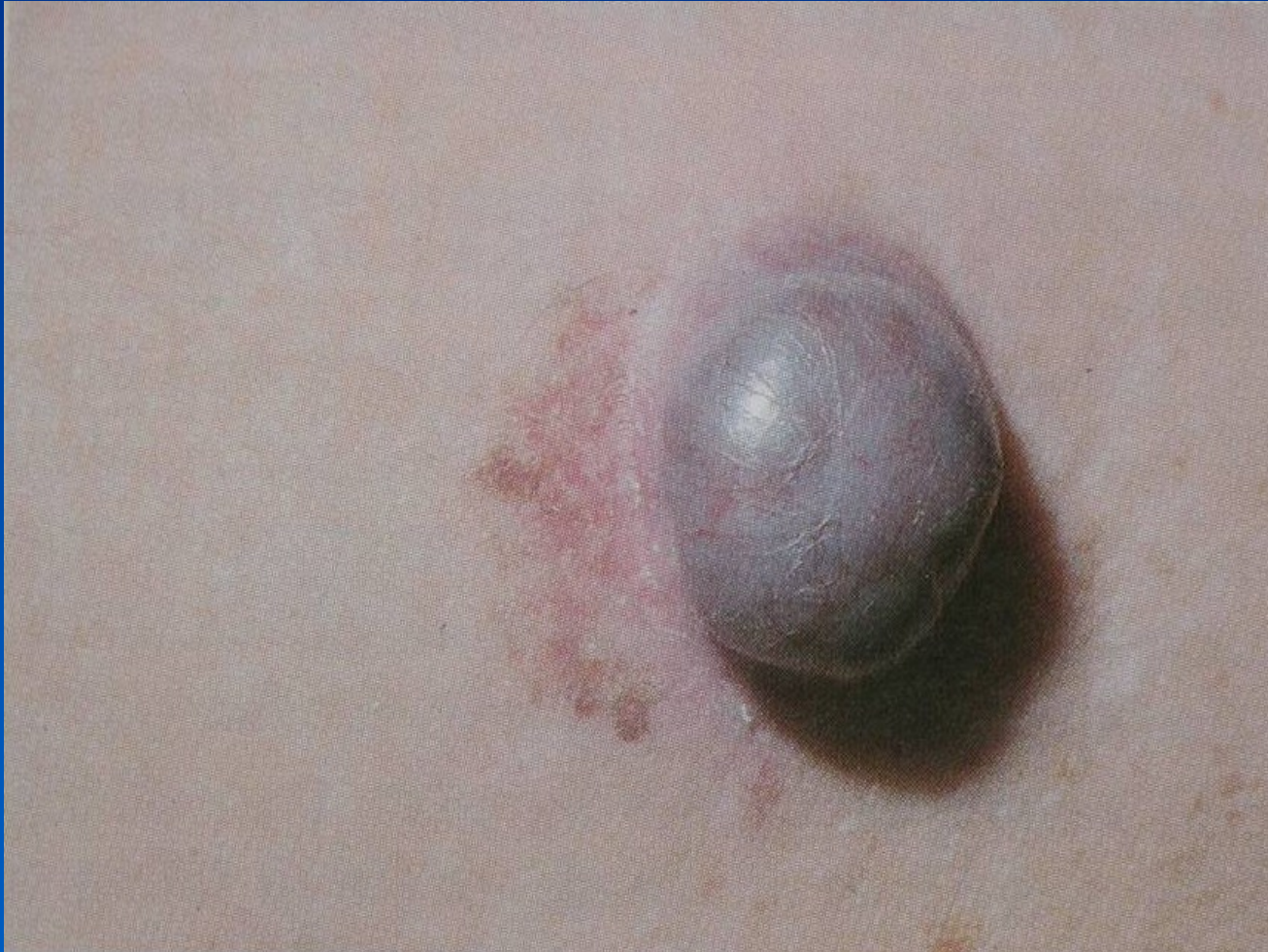

Malignant melanoma – radial growth phase

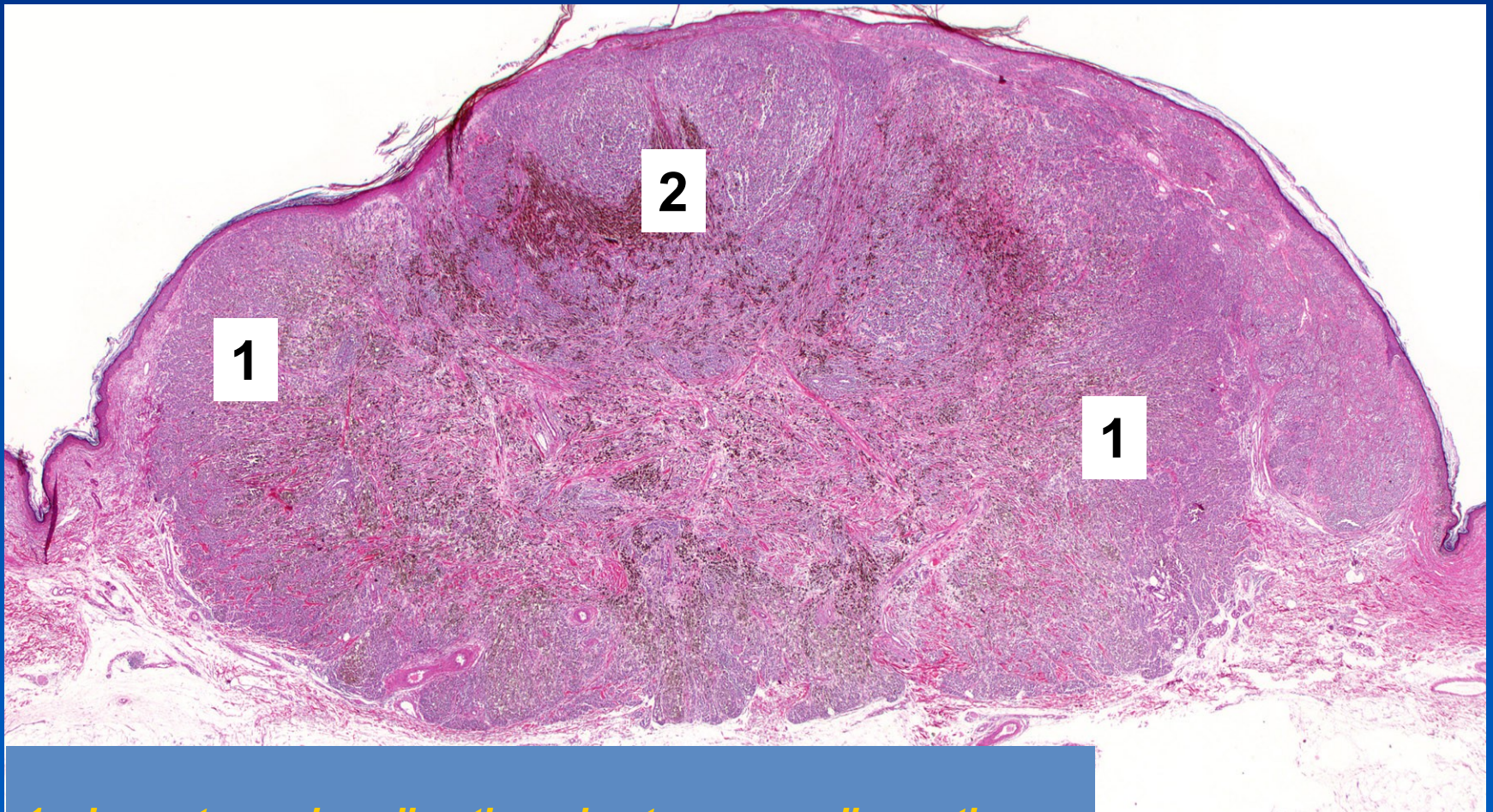
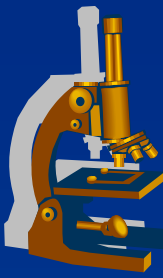


- 1. Nests of tumor cells in the junction zone***
- 2. Single melanocytes in the epidermis***
- 3. Lymphocytic infiltrate***
- 4. Invasion into the papillary dermis***

Melanoma w. nodularity

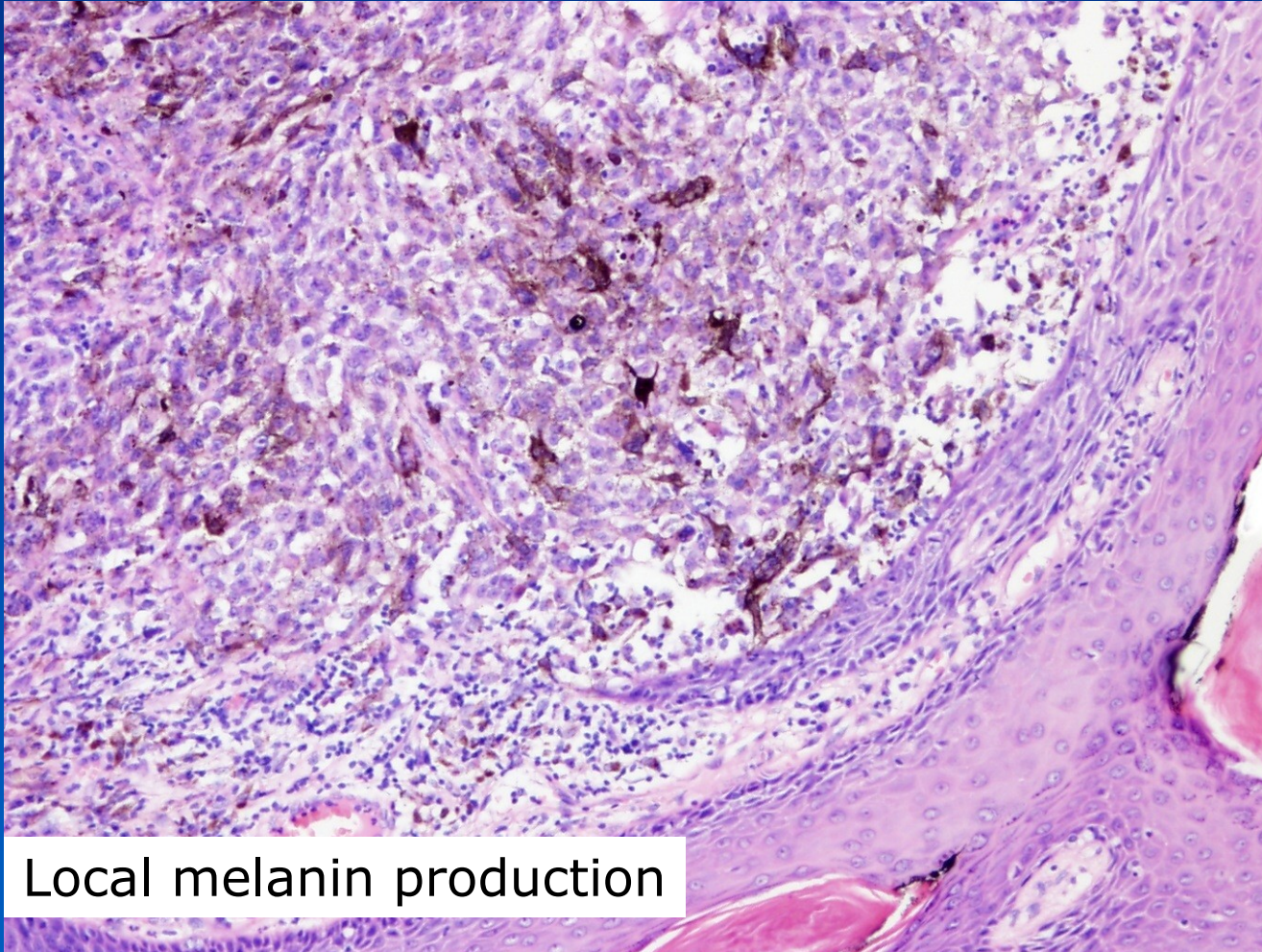
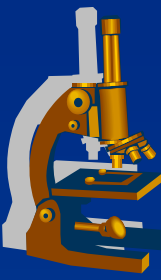


Nodular melanoma



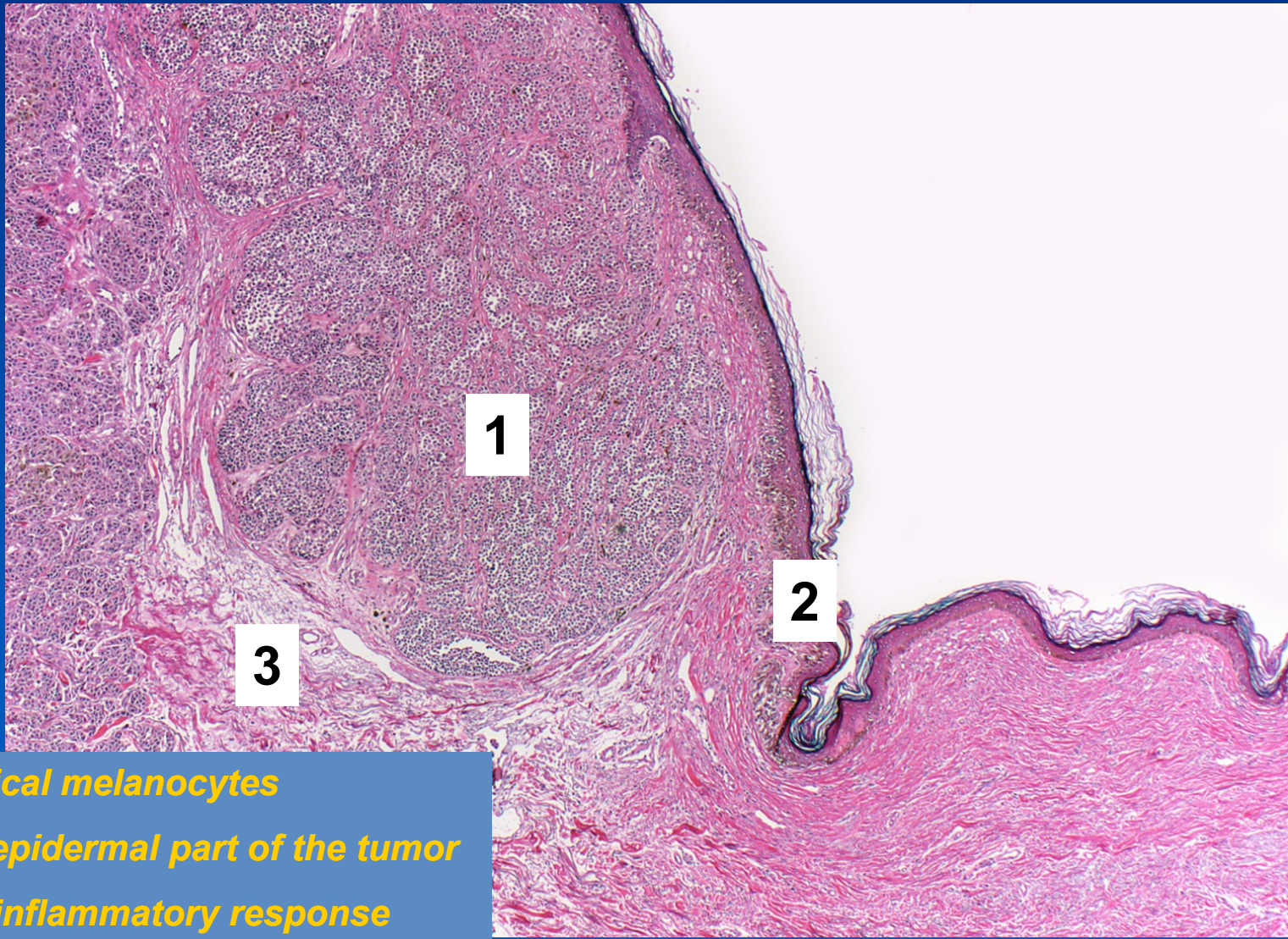
- 1. Large tumor invading the subcutaneous adipose tissue***
- 2. Melanin production***

Nodular melanoma



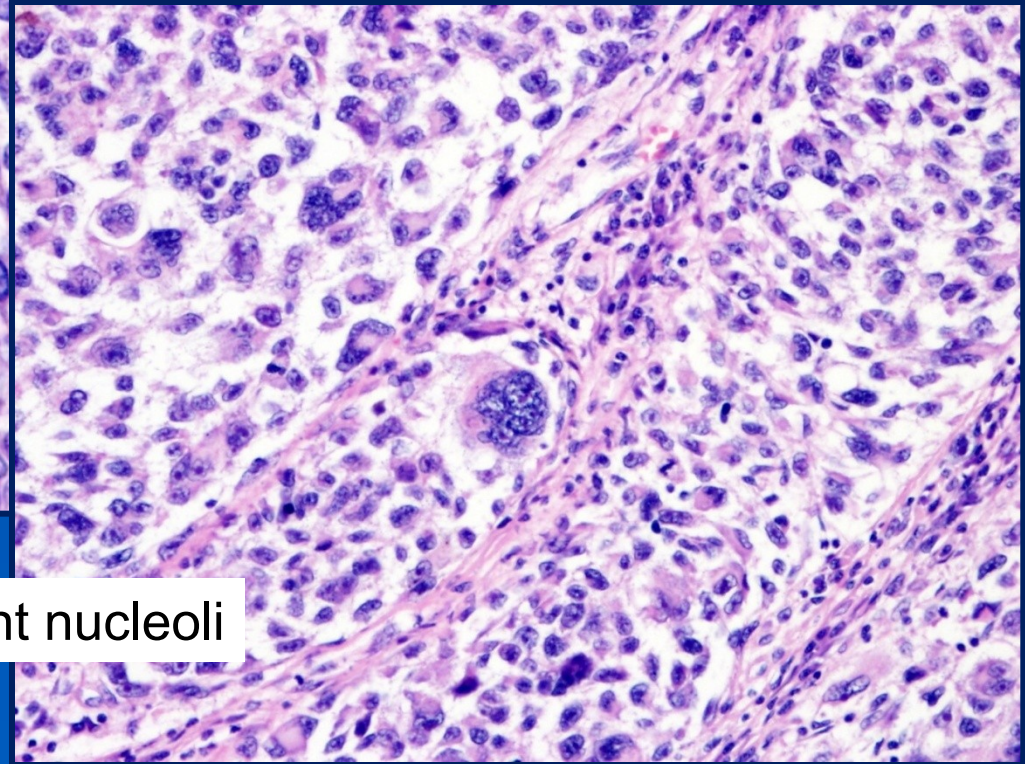
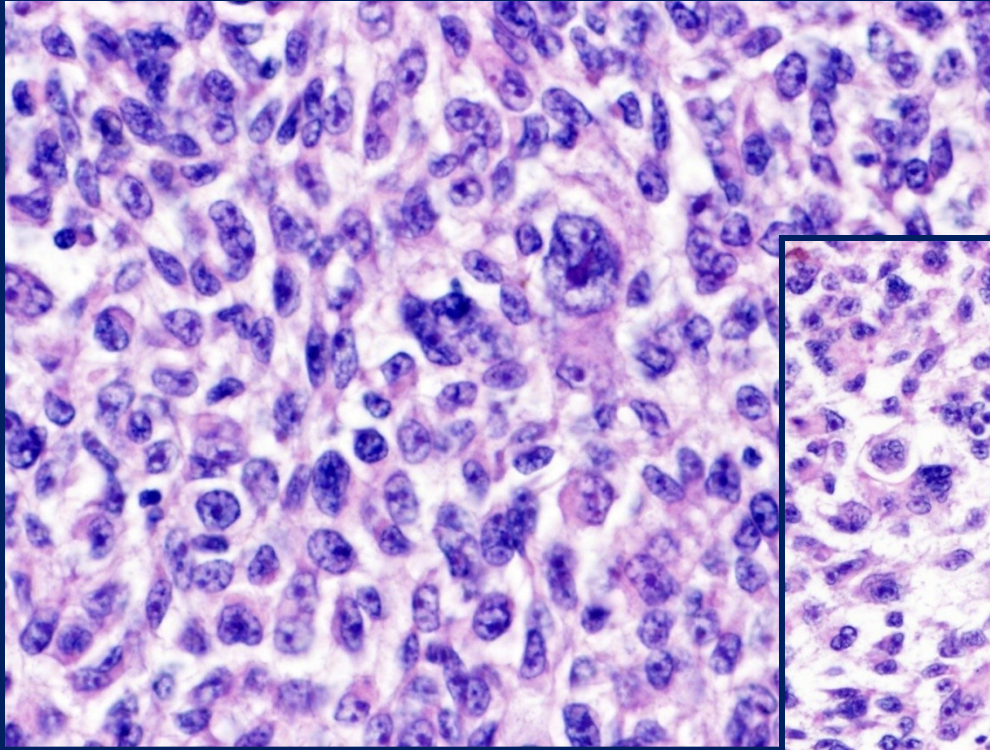
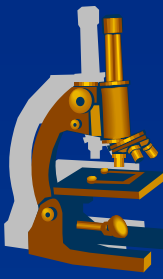
Local melanin production

Nodular melanoma

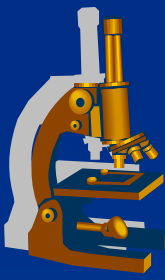


- 1. Atypical melanocytes***
- 2. Intraepidermal part of the tumor***
- 3. Low inflammatory response***

Nodular melanoma

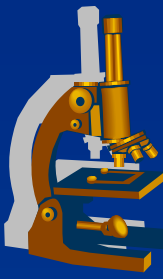


Atypical melanoblasts, prominent nucleoli



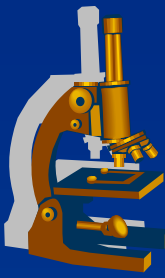
4. Germ cell tumors

Germ cell tumors



- ✗ usually in the gonads (ovary, testis)
- ✗ possible extragonadal localisation
 - ⇒ *anterior mediastinum, retroperitoneum, pineal gland*
- ✗ congenital origin
 - ⇒ *sacroccygeal teratoma e.g.*

Germ cell tumors



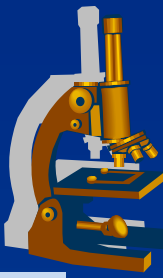
x classification:

⇒ tumors with one histologic type

- seminoma
- non-seminomatous tumors
 - choriocarcinoma
 - embryonal carcinoma
 - yolk sac tumor
 - teratomas
 - » *mature*
 - » *immature*
 - » *with malignant transformation of somatic elements*

⇒ mixed germ-cell tumors (with more than one histologic type)

Histogenesis of germ-cell tumors



Differentiation along gonadal lineages

(gonocyte, spermatogonium), without further differentiation potential

- **Seminoma**

Primordial germ cell

Totipotential cell

Undifferentiated cell

- **Embryonal carcinoma**

Extra-embryonic differentiation

- **Yolk sac tumor**

- **Choriocarcinoma**

Differentiation along somatic cell lines

- **Teratoma** (mature, immature, with malignant transformation of somatic elements)

- **(Polyembryoma)**

Seminoma



- ✗ about 50% of germ-cell neoplasms
- ✗ histologically identical to ovarian dysgerminomas
- ✗ Gross:
 - ⇒ *large, soft, well-circumscribed, homogenous, gray-pink in cut, with foci of necrosis*
 - ⇒ *destructive growth, often affects large areas of the testis*
 - ⇒ *usually intratesticular growth only*
 - ⇒ *late stages invade rete testis, epididymis testis, funiculus spermaticus, scrotal sac*

Seminoma



× Micro:

⇒ ***solid growth***

- exceptionally microcystic, solid-alveolar, tubular or cribriform

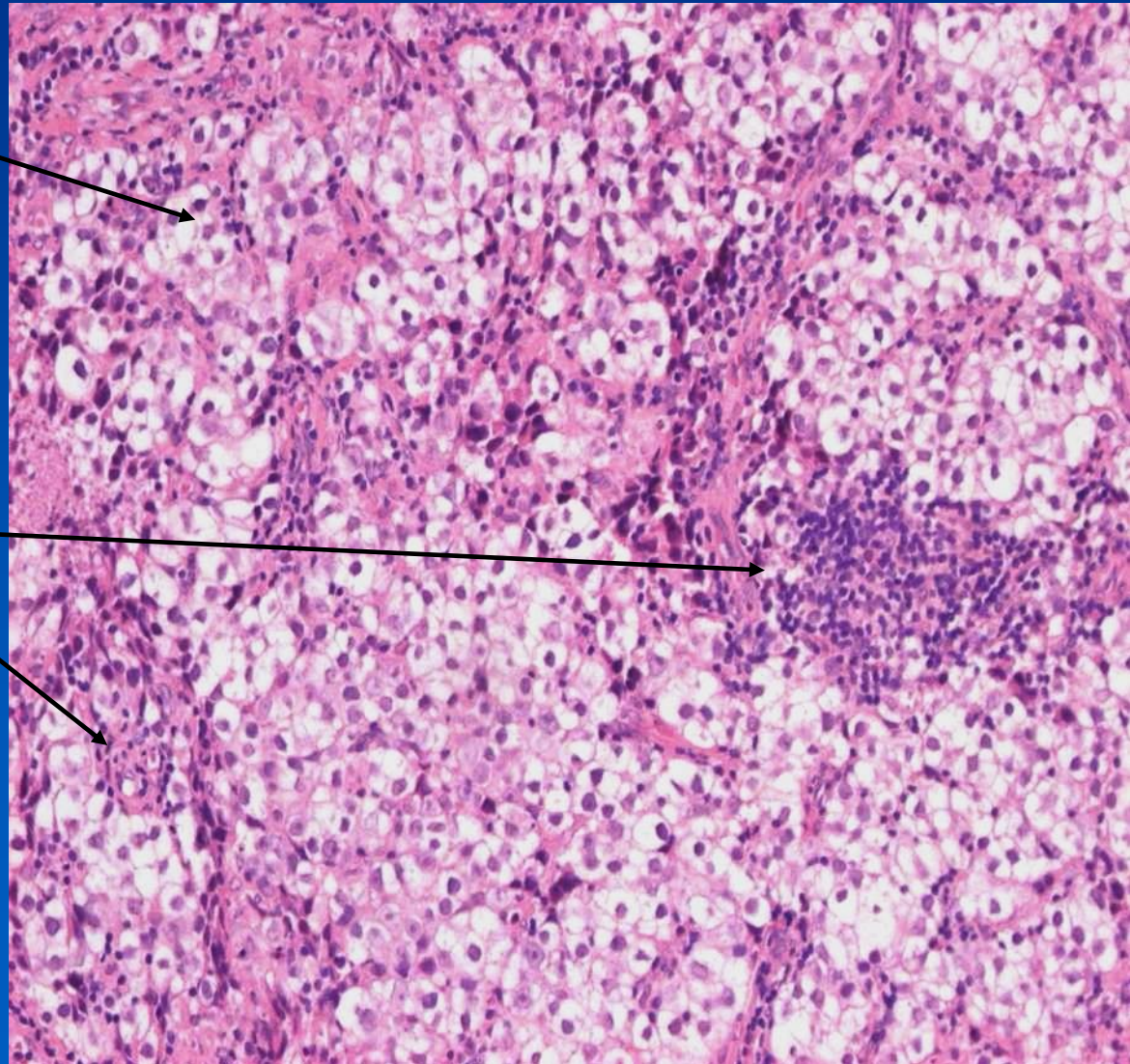
⇒ ***large, uniform cells with distinct cell borders***

⇒ ***clear, glycogen-rich cytoplasm***

⇒ ***large nuclei with one or two conspicuous nucleoli***

⇒ ***stroma of thin fibrovascular septa with lymphocytic infiltrate, reactive granuloma formation***

Classic seminoma



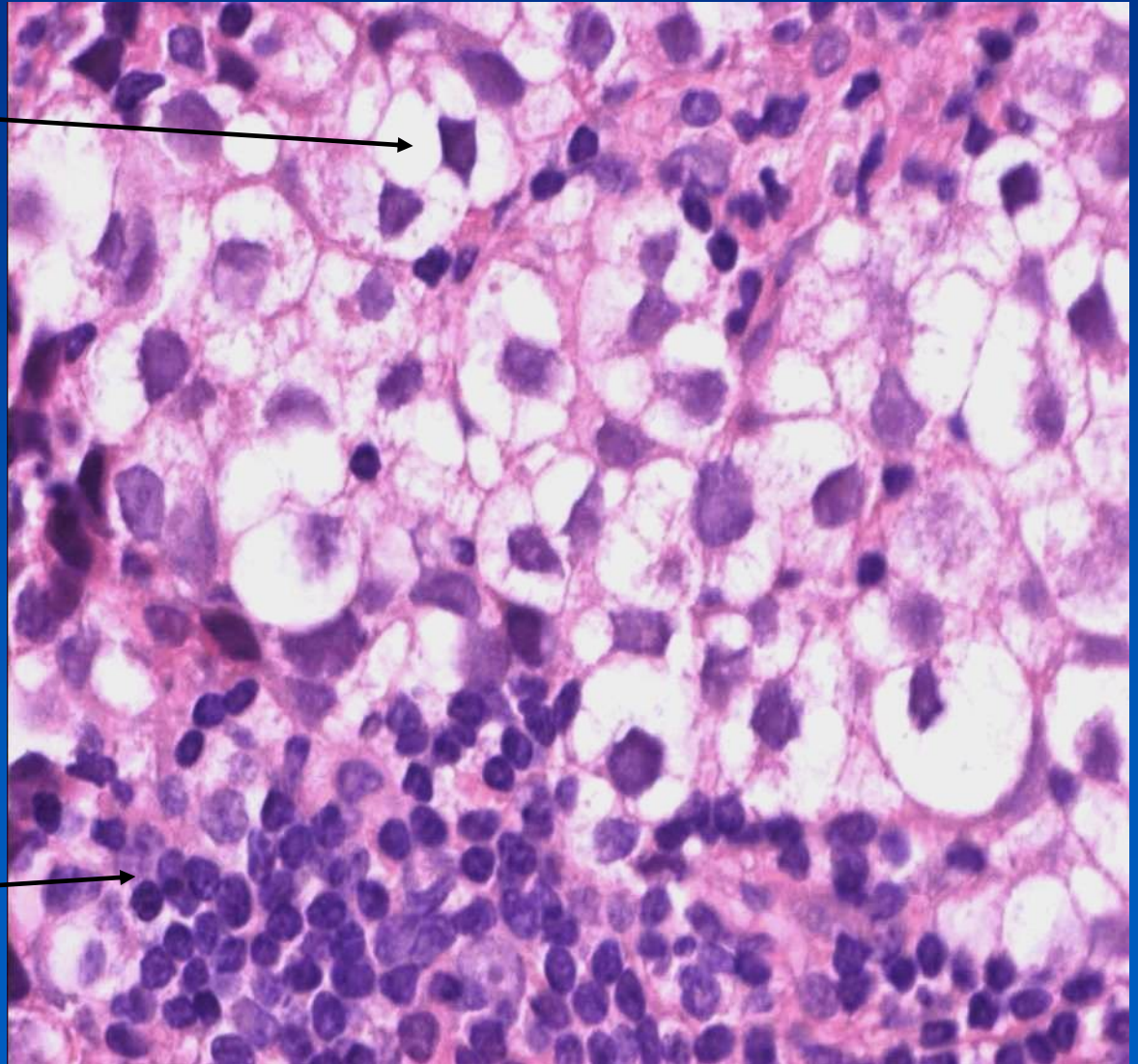
*Solid structures
of the seminoma*

*Fibrovascular
septa with
lymphocytic
infiltrate*

Classic seminoma

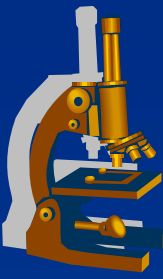


Tumor cells with clear cytoplasm



Fibrous septa with lymphocytic infiltrate

Nonseminomatous tumors



- ✗ germ cell differentiated into totipotential / extraembryonal cell lineage:
 - embryonal carcinoma
 - choriocarcinoma
 - yolk sac tumor

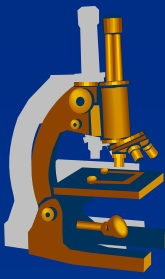
- ✗ differentiation along somatic cell lineage:
 - teratomas

Teratomas



- ✗ differentiation of neoplastic germ cell along somatic cell lines
- ✗ contains tissues of one / two / three primitive germ cell layers (endo-, meso-, ectoderm)
- ✗ Gross:
 - ⇒ *cystic (usually benign)*
 - ⇒ *solid*
- ✗ Micro:
 - ⇒ *different tissue types:*
 - brain, teeth, epithelial structures, neural tissue, endocrine organs, muscles, cartilage, bone...
 - often epidermoid or dermoid cysts with hairs

Teratomas



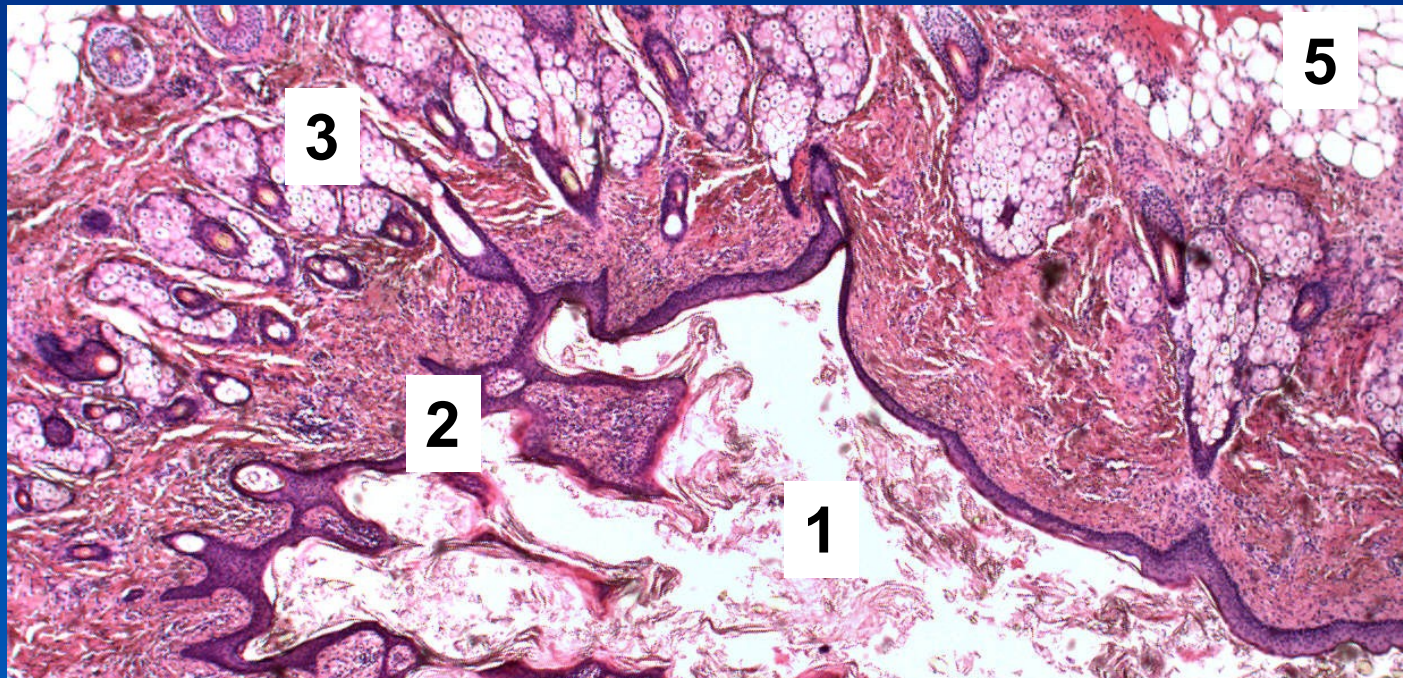
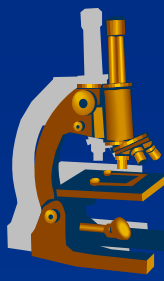
×3 histologic variants according to the maturity of particular structures:

⇒ *mature (organoid)*

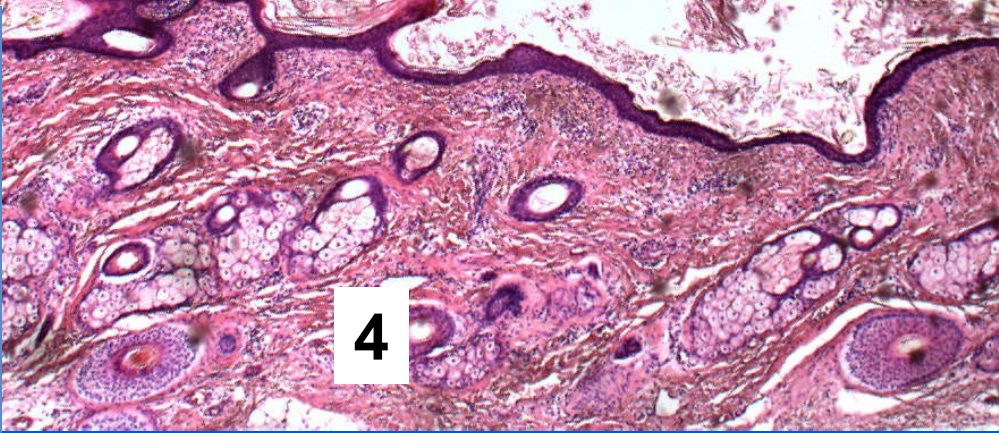
⇒ *immature (embryonal/fetal tissues)*

⇒ *with malignant transformation of somatic elements*

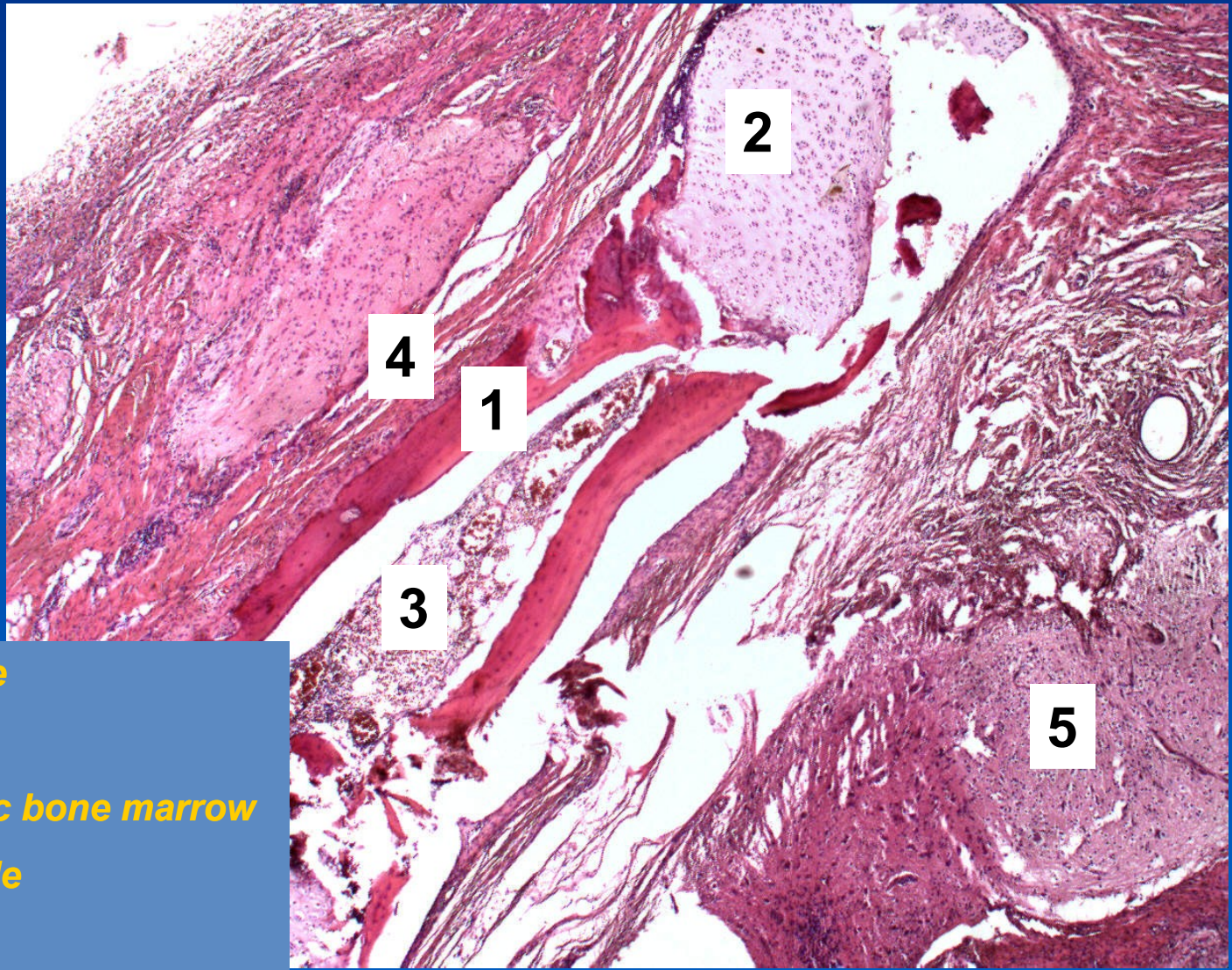
Dermoid cyst (mature teratoma)



- 1. Lumen of the cyst with keratinized epithelial cells**
- 2. Epidermis**
- 3. Sebaceous glands**
- 4. Hair follicles**
- 5. Adipose tissue**

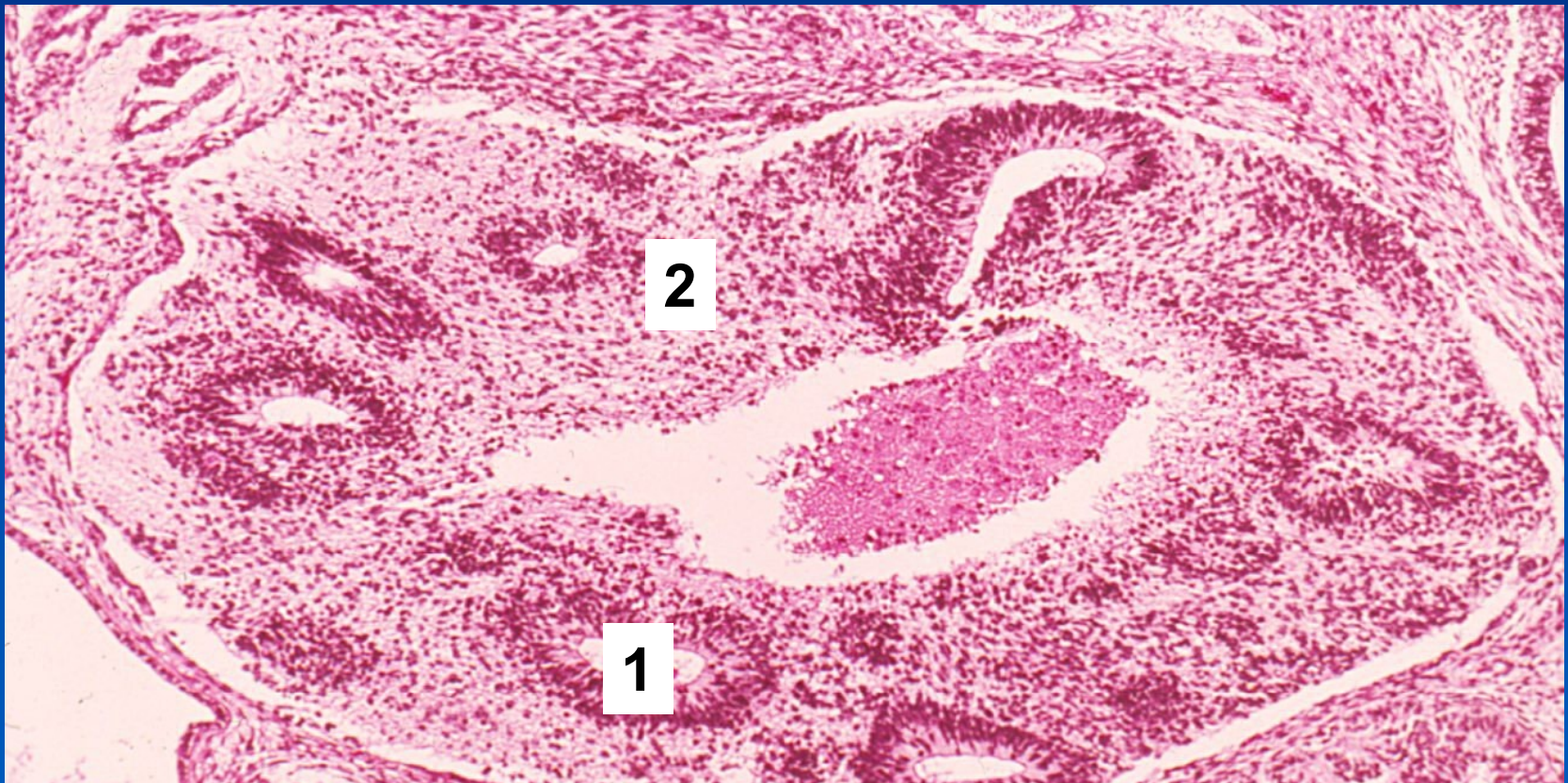


Dermoid cyst (mature teratoma)

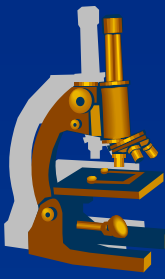


- 1. Lamellar bone***
- 2. Cartilage***
- 3. Hematopoietic bone marrow***
- 4. Striped muscle***
- 5. Neural tissue***

Immature teratoma

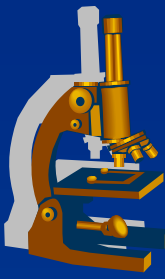


- 1. Immature neuroectodermal-like epithelium*
- 2. Glial cells*
- 3. Yolk-sac-like structures*



5. Mixed tumors

Mixed tumors



✘ consist of two or more tissue components of identical or different histogenesis and identical or different biological nature:

⇒ ***mixed mesenchymal tumors***

- angiofibroma, angioleiomyolipoma, ...

⇒ ***mixed mesenchymal/epithelial tumors***

- fibroadenoma, adenosarcoma, carcinosarcoma

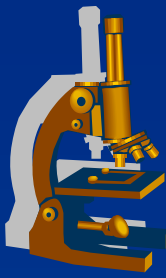
⇒ ***mixed malignant epithelial tumors***

- e.g. adenosquamous carcinoma

⇒ ***mixed germinal tumors***

- e.g. combination of seminoma and teratoma in one tumor

Fibroadenom mammy



- ✗ most common breast tumor in young females

- ✗ **benign**

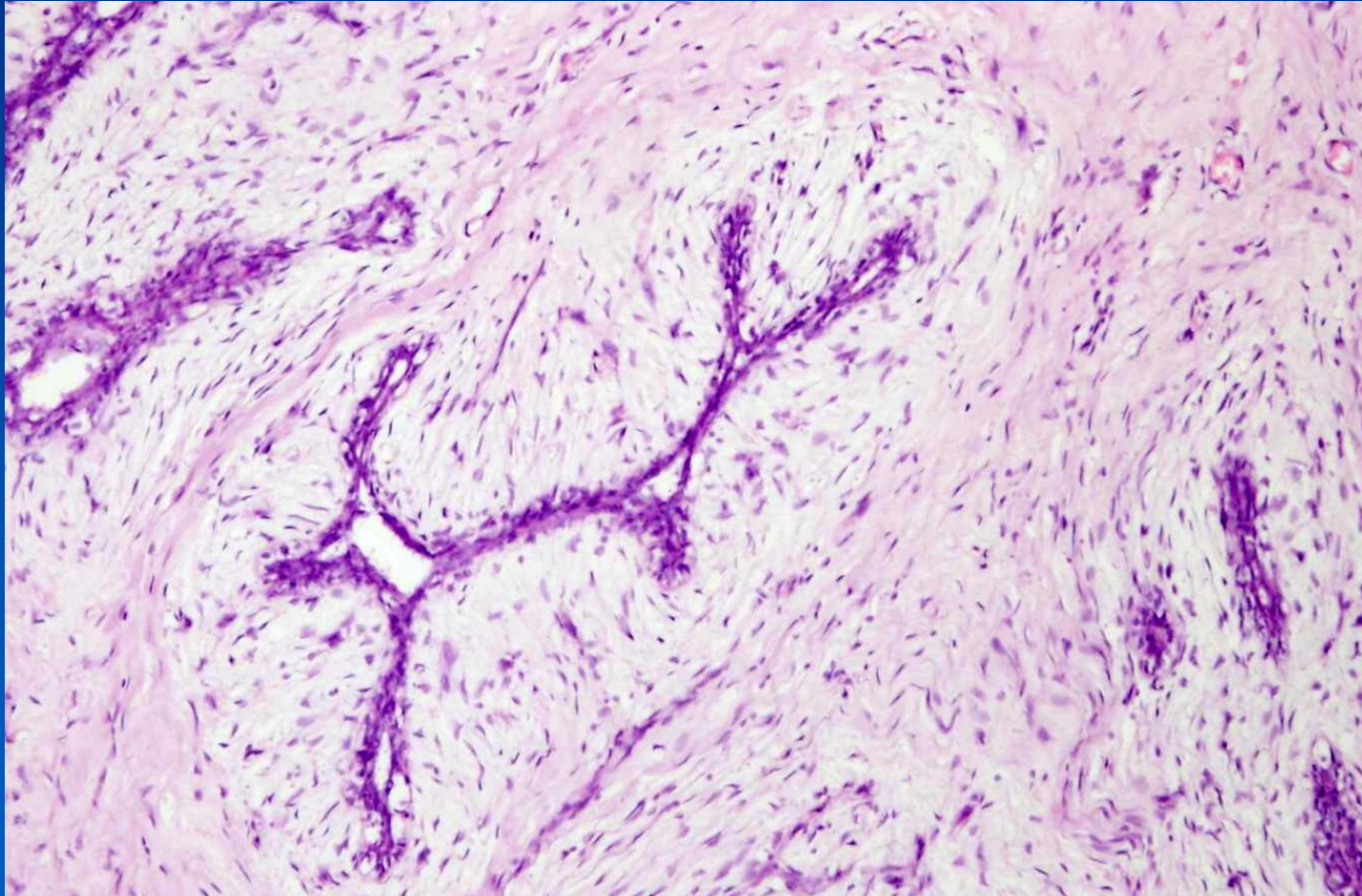
- ✗ **gross:**
 - ⇒ *circumscribed, mobile*

- ✗ **micro:**
 - ⇒ *proliferating ducts*

 - ⇒ *increased amount of stroma (edematous or hyalinised)*

 - ⇒ *2 types:*
 - pericanalicular, intracanalicular growth (no practical significance)

Fibroadenoma



Slit-like newly formed ducts compressed by edematous stroma