

Endodontics

**Pulpal and periodontal diseases –
diagnosis, therapy, prevention**



Aim of endodontic treatment

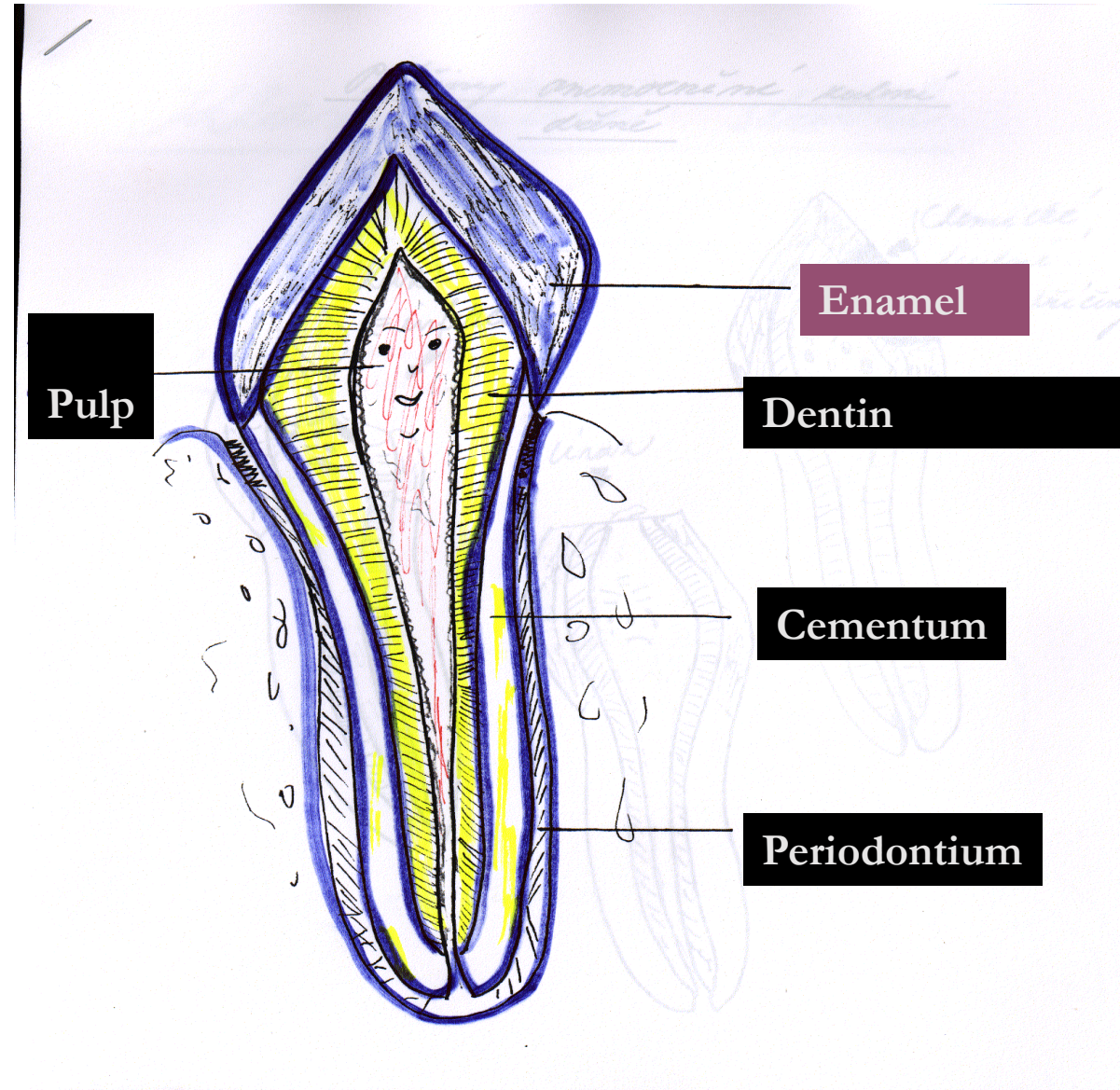
**Healing of pulp diseases or removal
bacteria from the root canal system
and regeneration of damaged periodontal
tissues. (Canal shaping, cleaning and filling)**

„ *Endodontist helps nature only* “

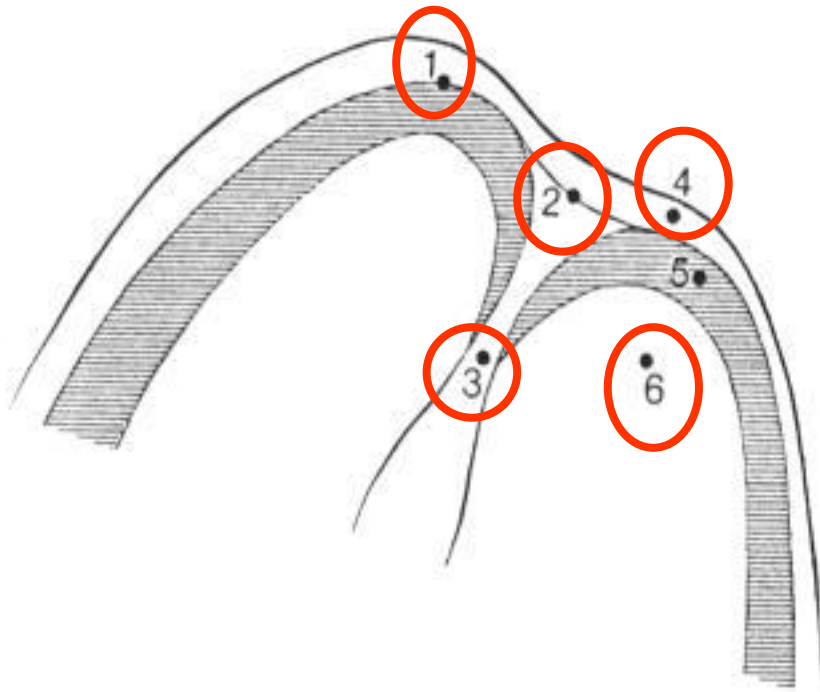
W.D.Miller



Morphology

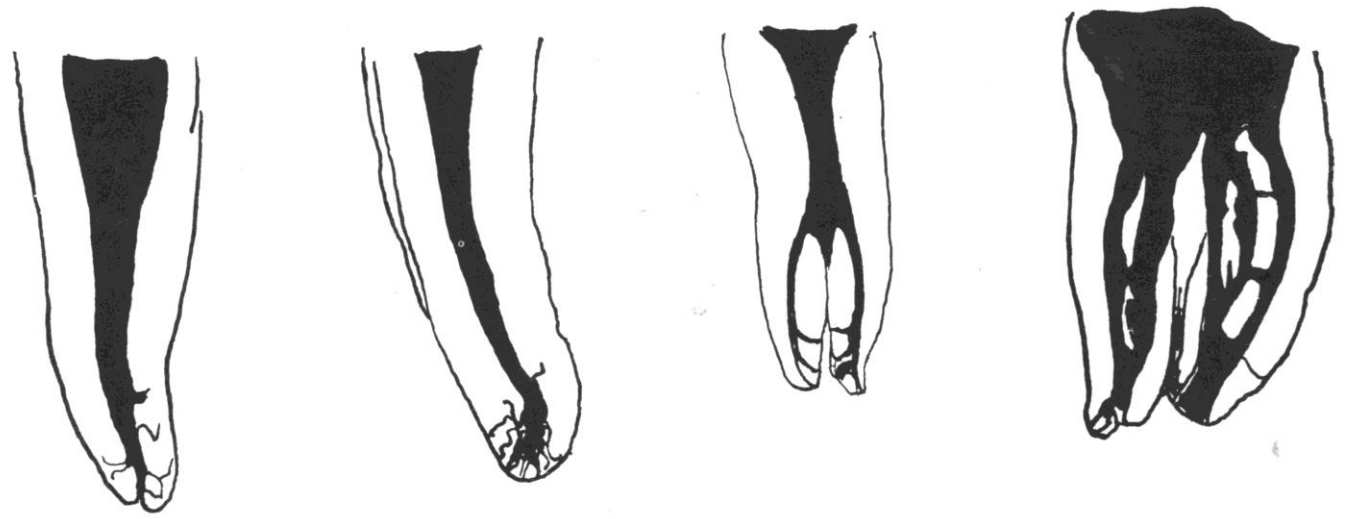
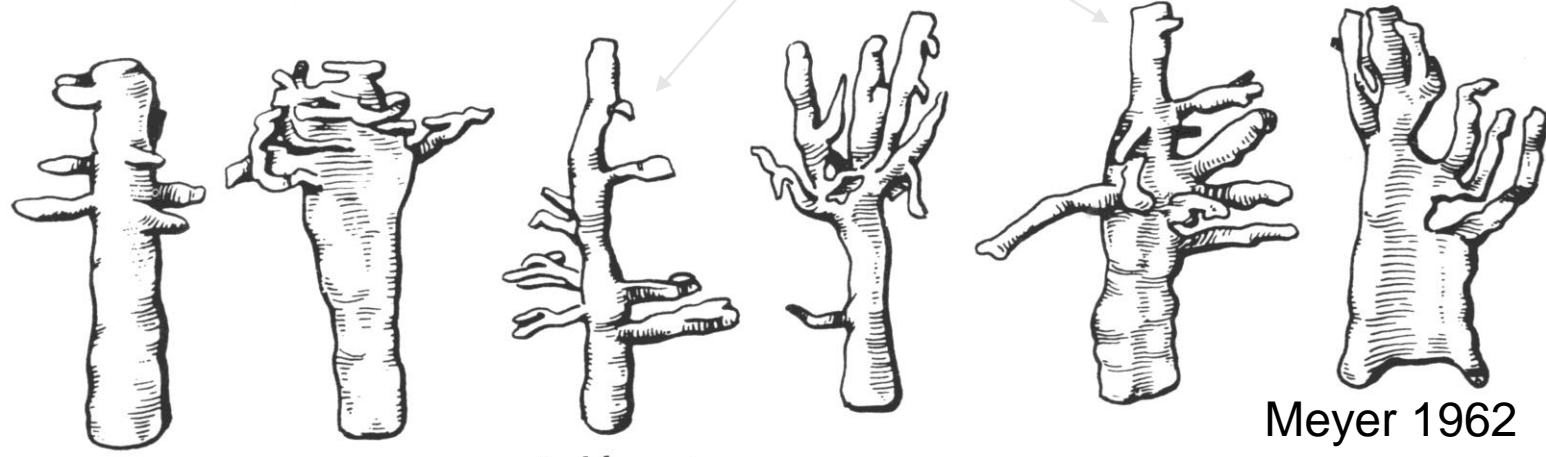
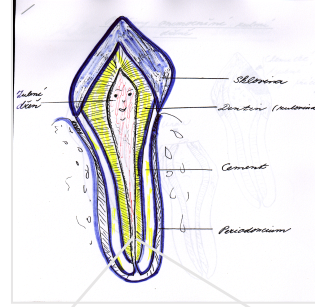


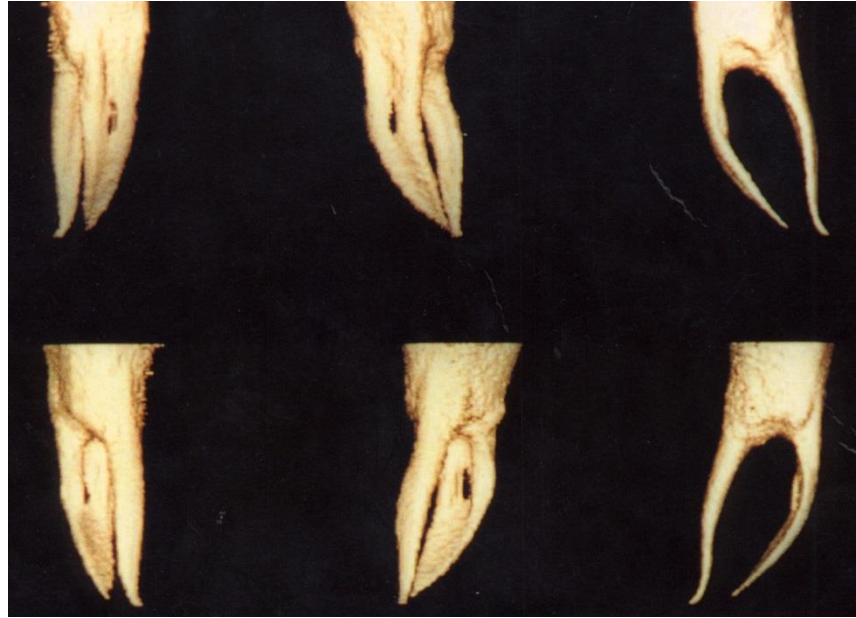Apical morphology



1. X – ray apex
2. Foramen apicale – spical foramen
3. Apical constriction
4. Periodontal ligament
5. Root cementum
6. Dentin







3D

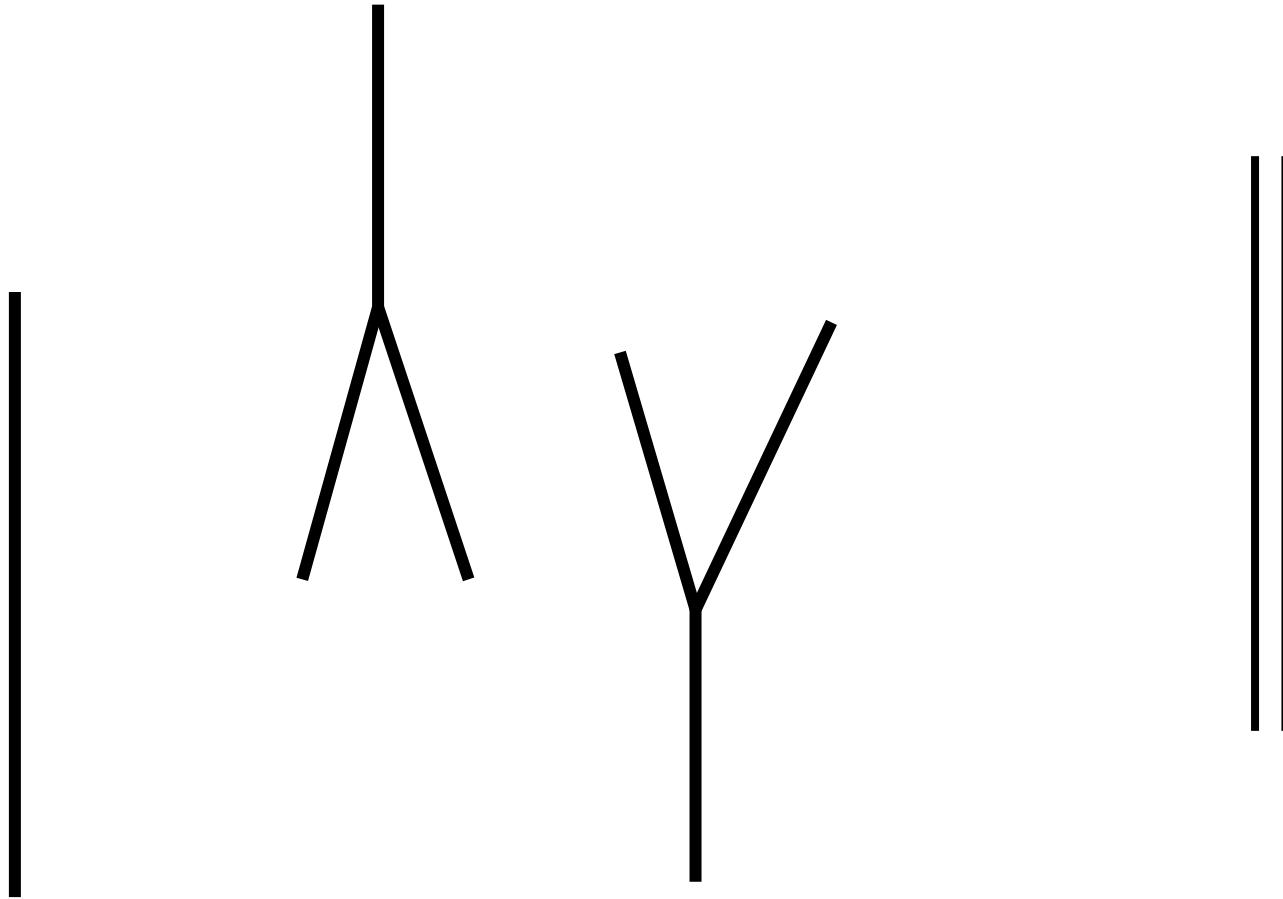
Meyers conclusions

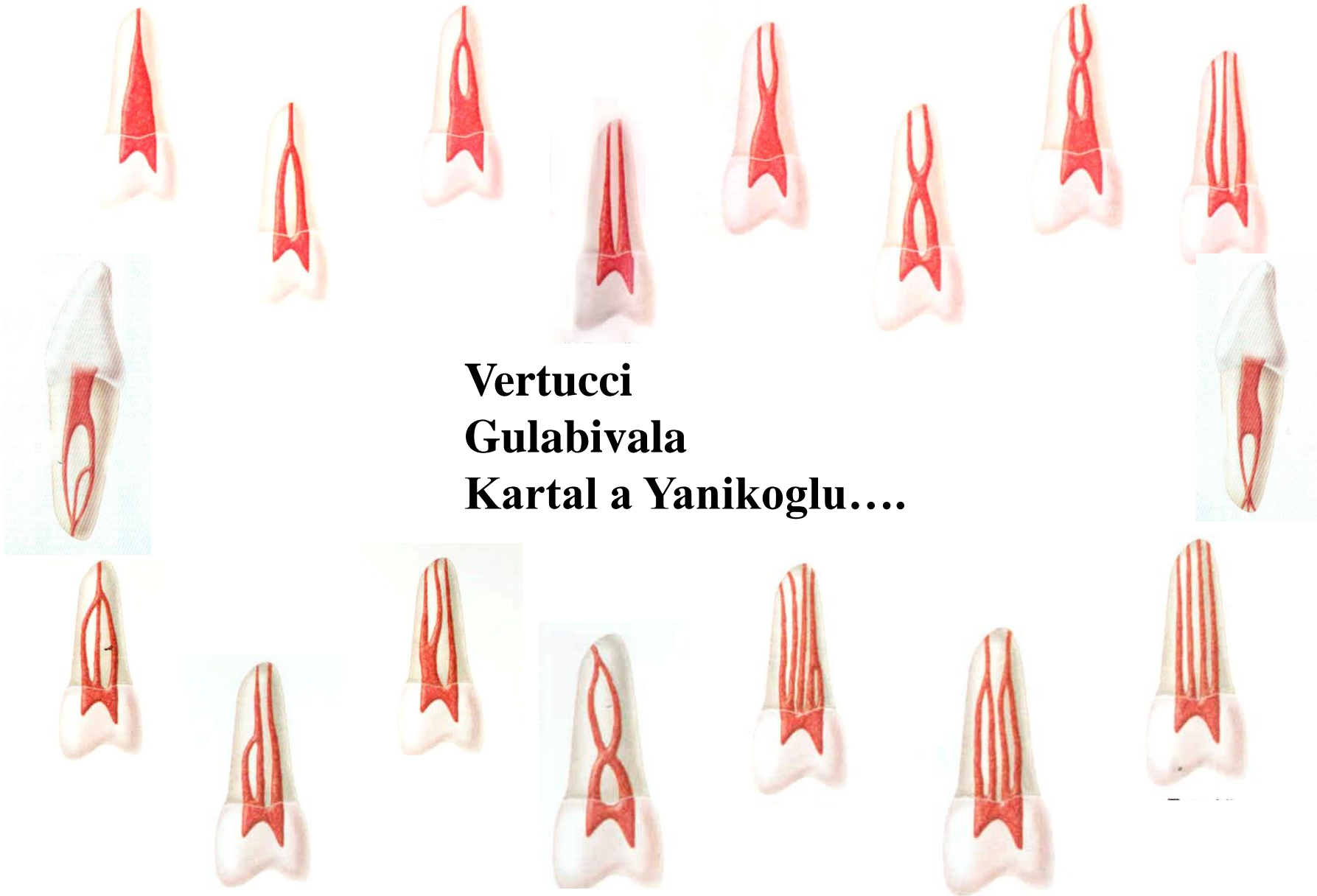- The root canal is not round but oval (long axis vestibuloral direction)
- The root canal does not go straight but it deflects distally
- The apical foramen is not on the top of the root but below it (distally or distoorally)

Meyer's conclusions

- The walls of the root canal between apical constriction to apical foramen are divergent
- The root canal system has usually more apical foramina (side branches - accessory root canals—ramifications)
- The ramifications are situated mostly in apical area (first apical mm)
- All foramina are situated in cementum

Basic forms of the root canal system (Weine)

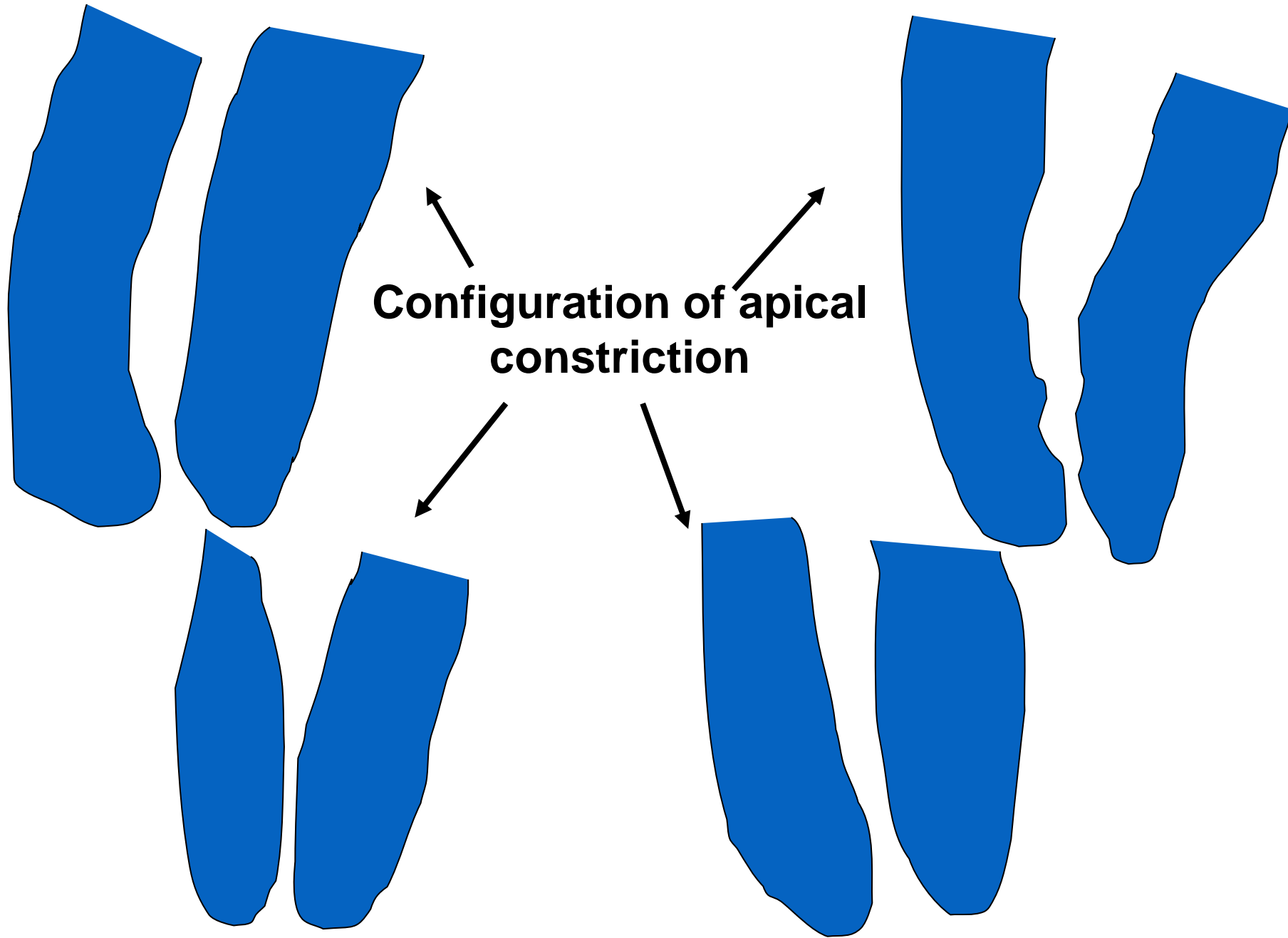




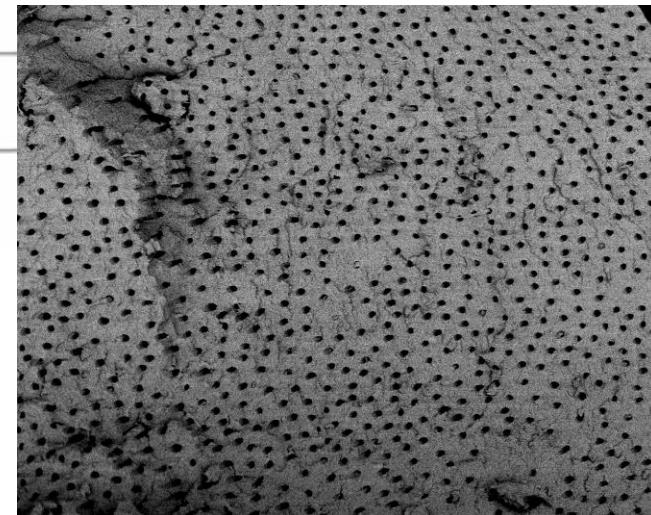
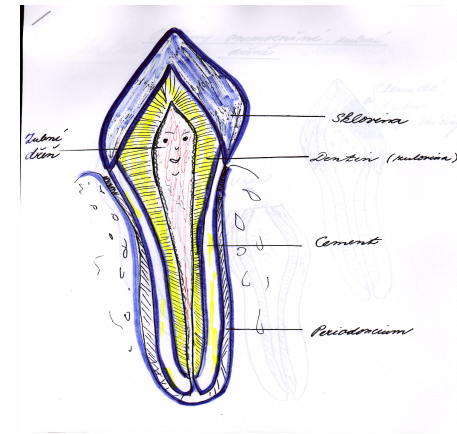
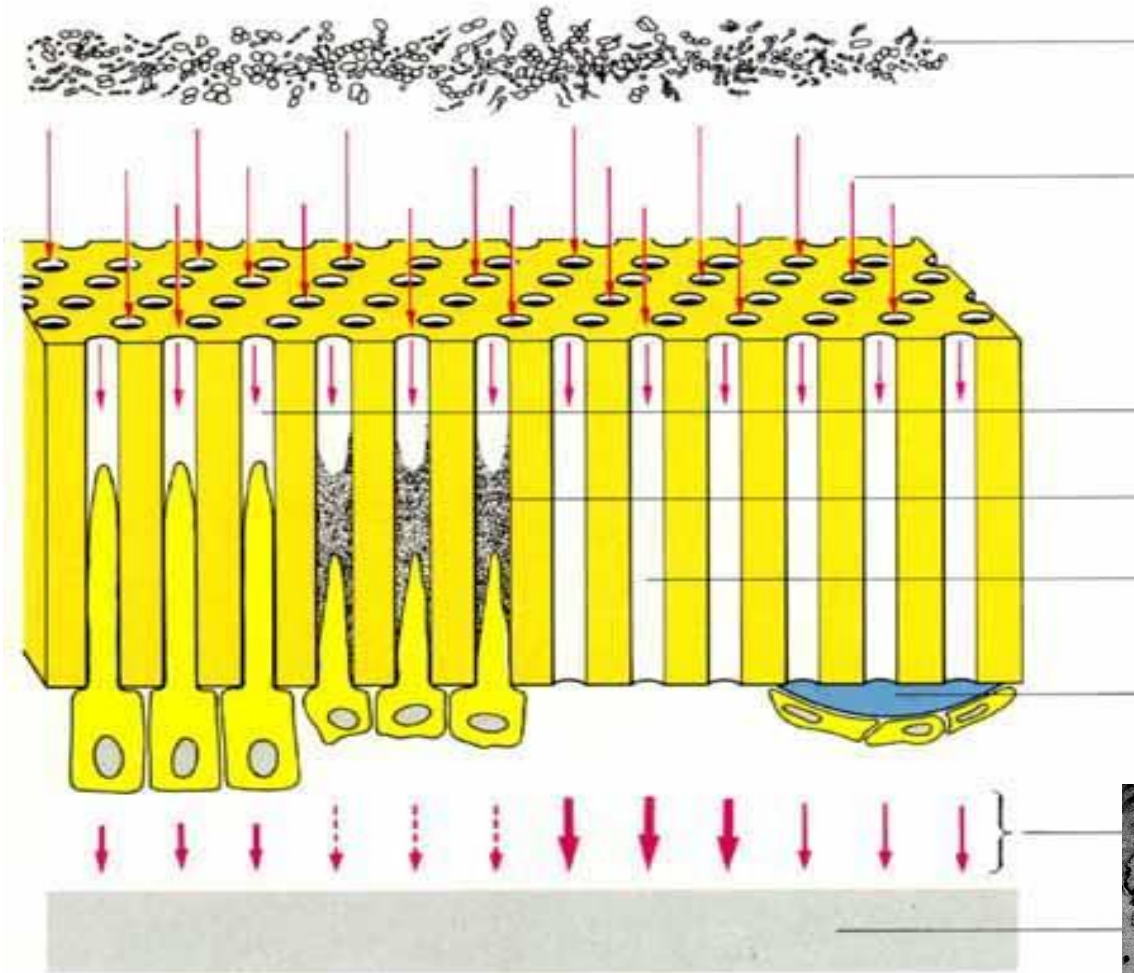
**Vertucci
Gulabivala
Kartal a Yanikoglu....**

Canal shaping terminates in apical constriction


- Small communication
- Less risk of periodontal damage
- Prevention of overfilling
- Prevention of apical transport of infectious material
- Possibility of good bacterial decontamination
- Possibility of good condensation of the root filling



- Macrocanal systém – root canals
- Microcanal systém – dentine tubules

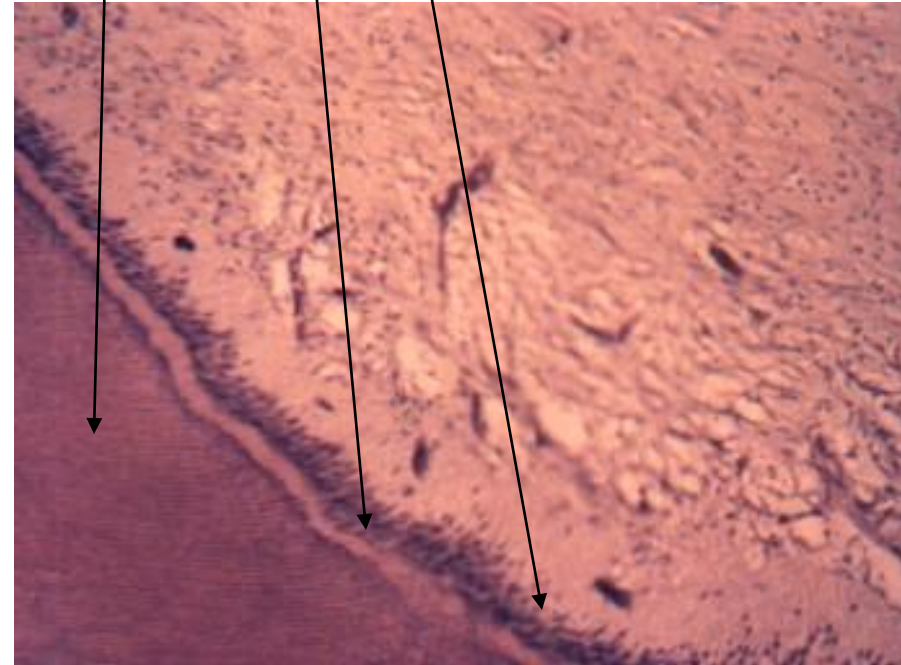
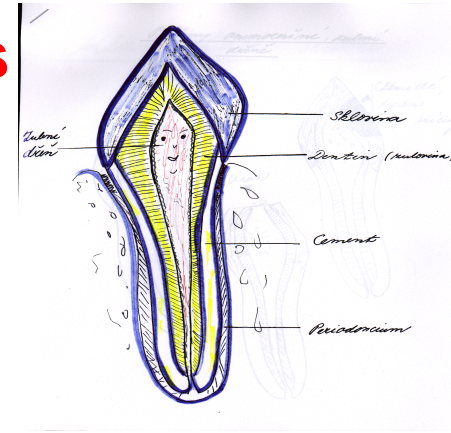


**Endodont: dentin and pulp
(morphological and functional unit)**



Dental pulp

Odontoblasts
Predentin
Dentin



Pulpal response to the irritation

- Sclerosis
- Tertiary dentin
- Dentin bridge

Endodontic diseases

- Pulpitis – reversible, irreversible
- Necrosis (Dental pulp lost its vitality)
- Gangraena (Necrotic pulp became infected)
- Apical periodontitis (inflammation that originates in dental pulp and spreads to the periodontal space)

Reasons

- Bacteria
- Mechanical irritants (overinstrumentation, trauma)
- Chemical (esp. phenolic based intracanal medicaments, overfilling, irrigants)

Two basic approaches in endodontic treatment

- Vital pulp therapy
- Root canal treatment

Vital pulp therapy VPT

Indirect pulp therapy IPT

- Indirect pulp capping
- Intermittent excavation

- Direct pulp therapy DPT

- Direct pulp capping
- Pulpotomy

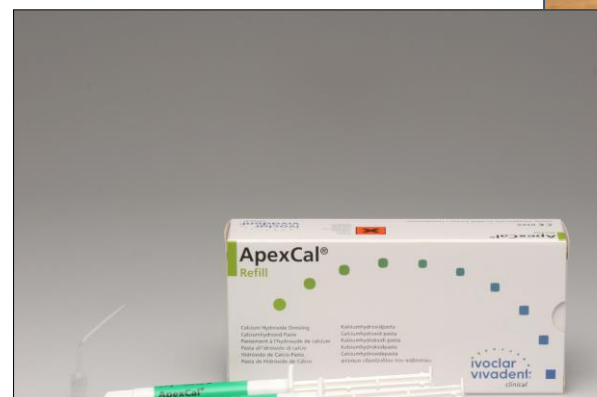
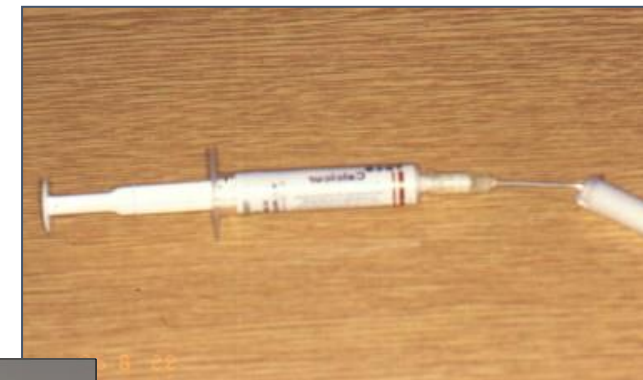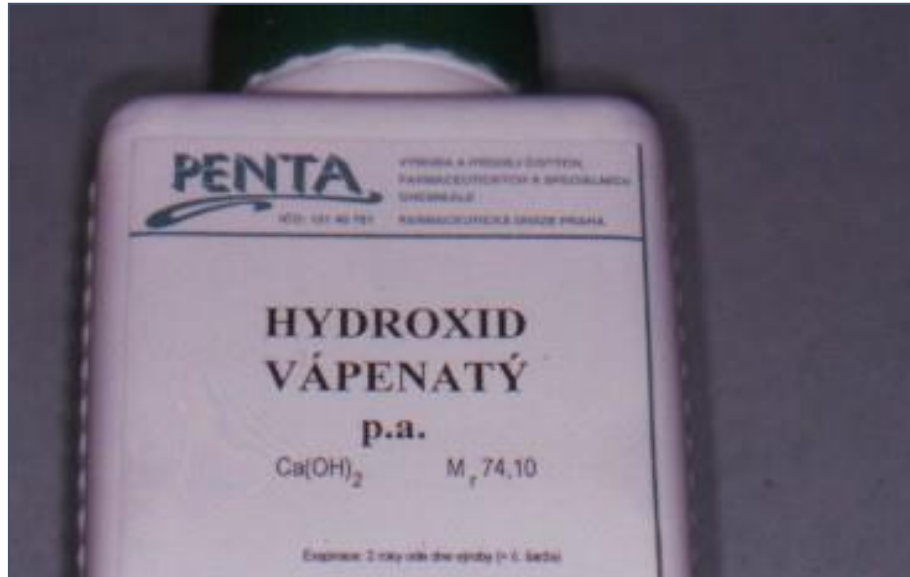
Calcium hydroxide

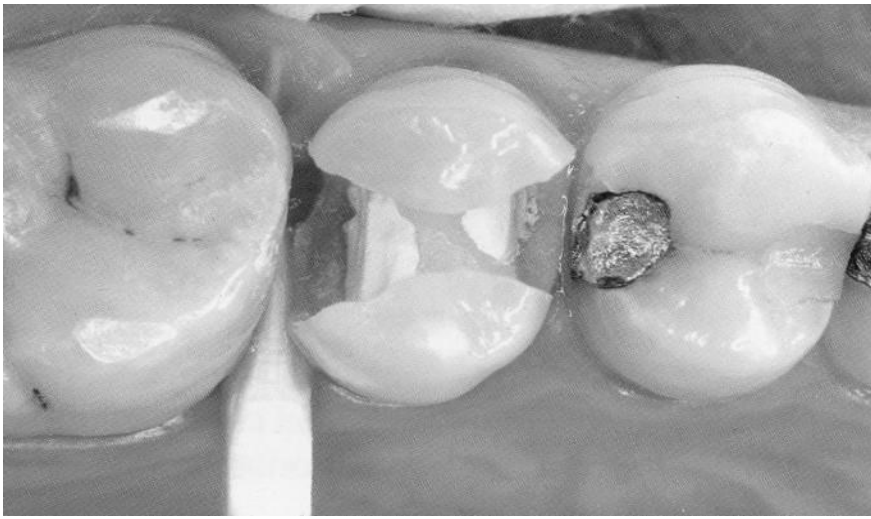
Antiflogistic

Dentinogenic

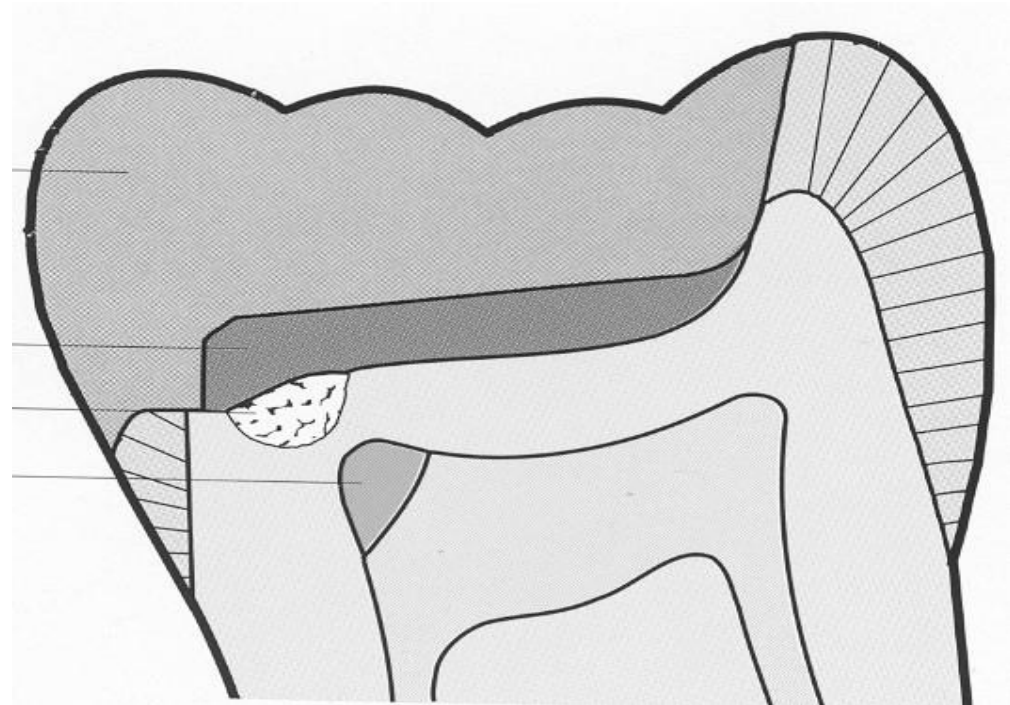
Antimicrobial effect

Dry soft dentine

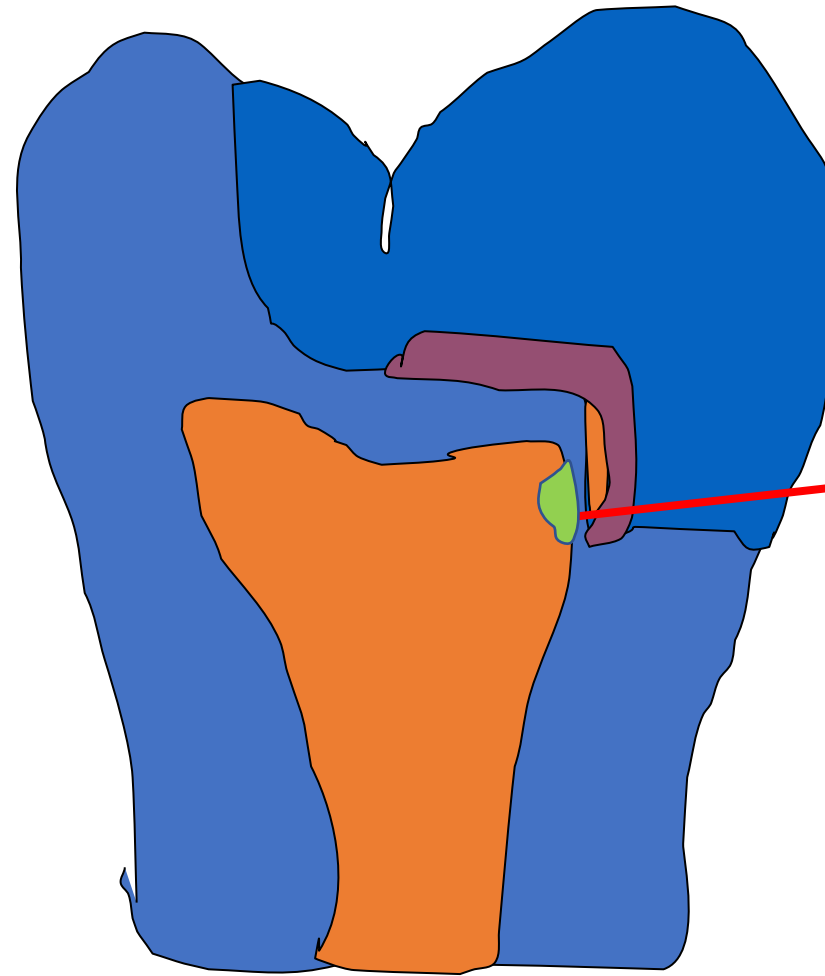




Indirect pulp capping



Indirect pulp capping



Dental caries next to dental pulp
In a small area small amount
of carious dentine on the pulpal wall
can be left, calcium hydroxide
permanent filling follows.

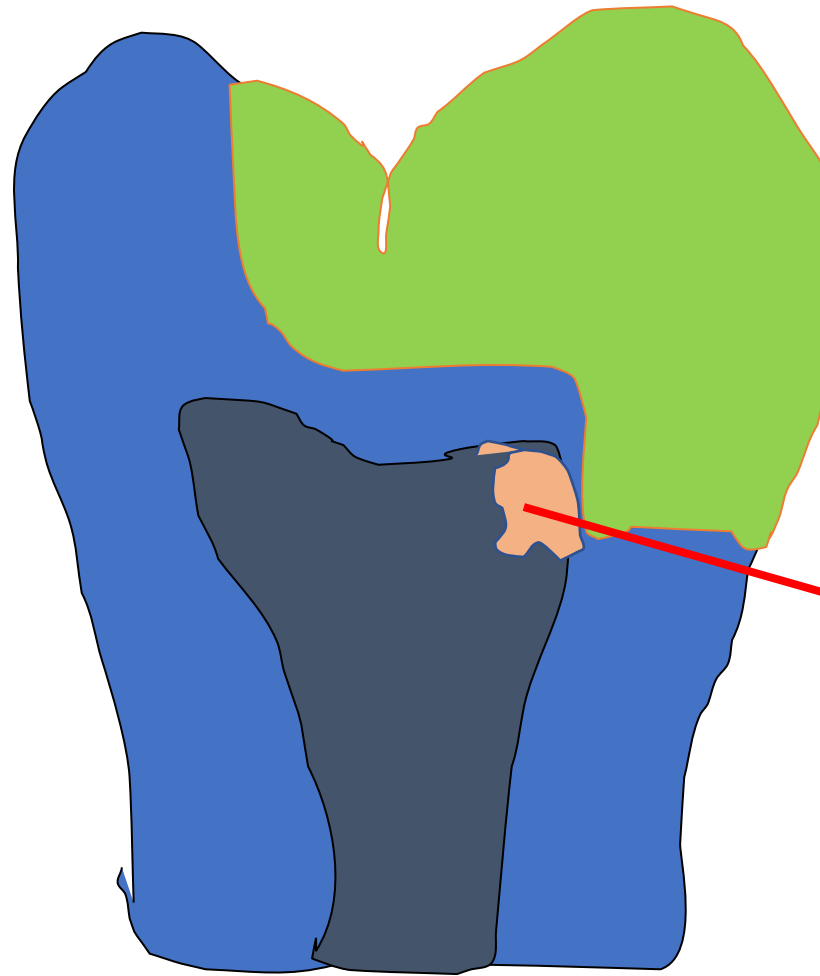
Tertiary dentin

Intermittent excavation

Dental caries next to dental pulp, Big amount of carious dentine. Calcium hydroxide is placed and temporary filling follows.

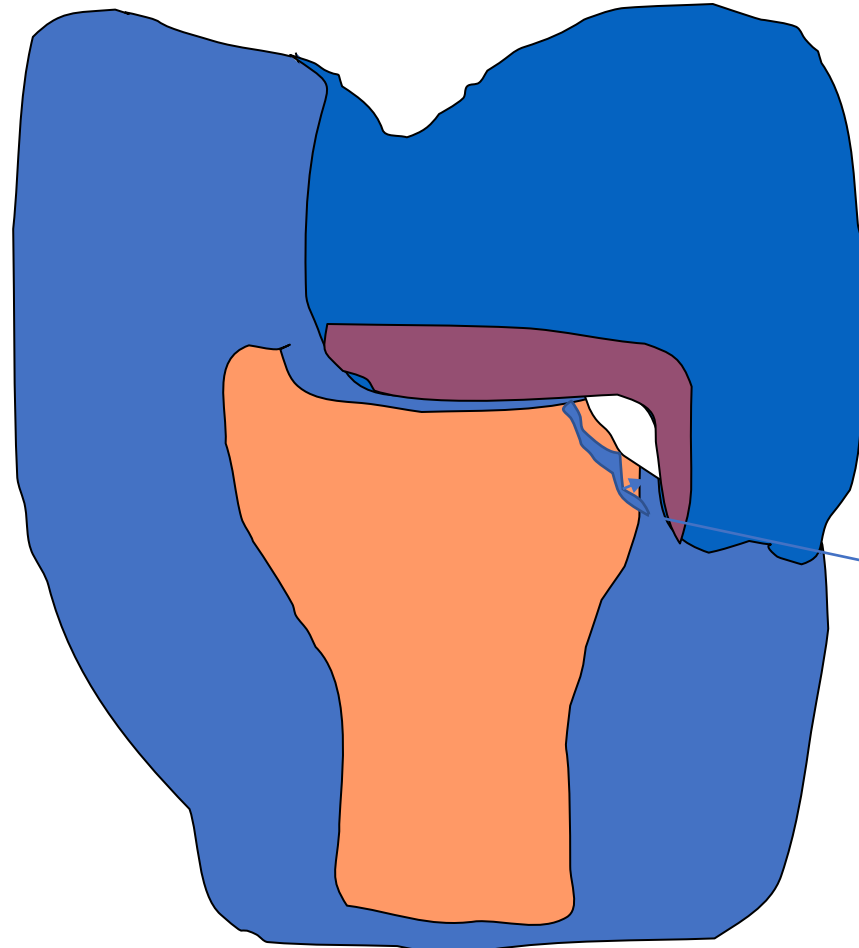
After six weeks the temporary filling is removed, carious dentine excavated and permanent filling follows

Tertiary dentin is being formed during this period. Calcium hydroxide has also antimicrobial effect and can dry up the soft dentine.



Tertiary dentin

Direct pulp capping

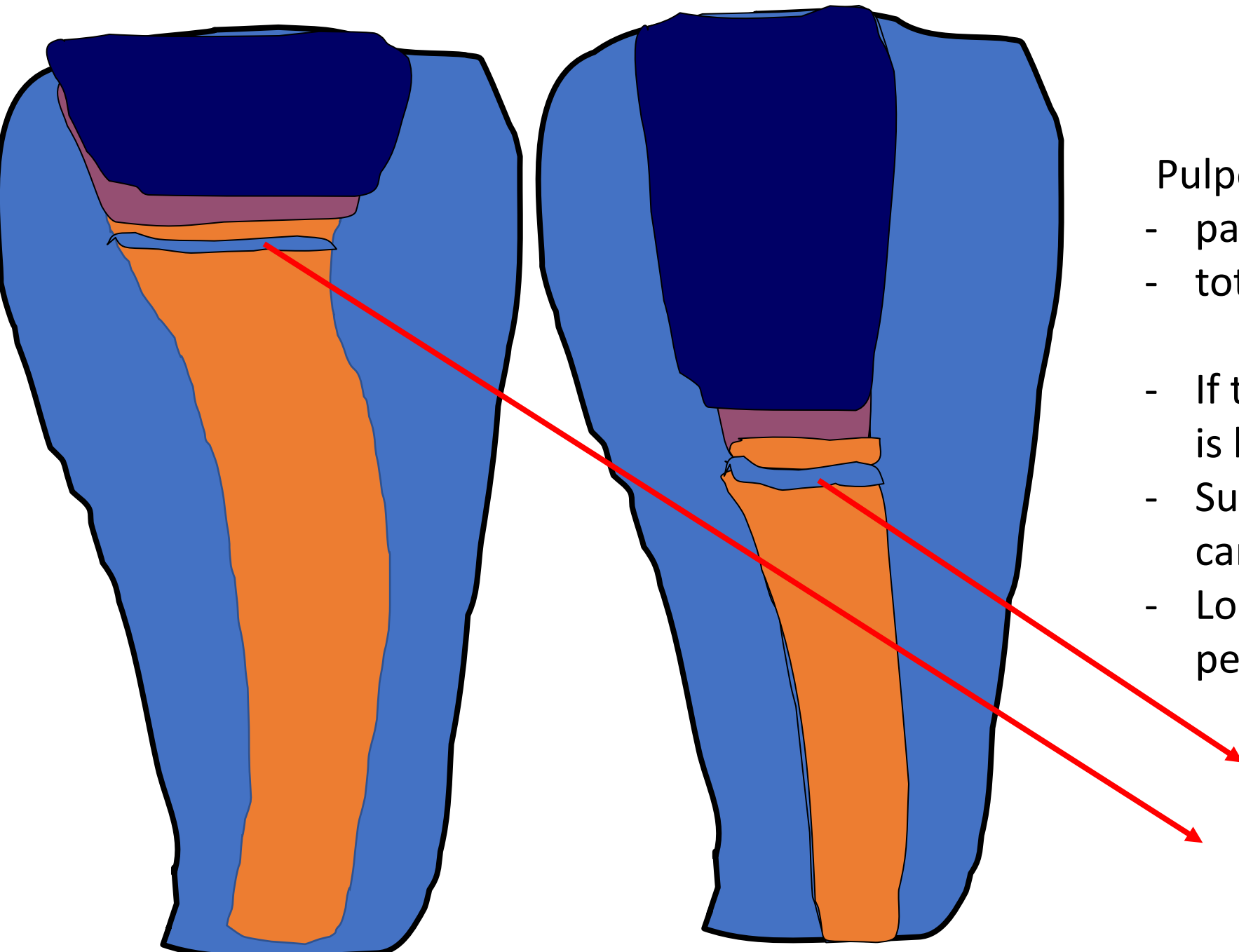


Directly on dental pulp,
permanent filling.

Perforation must

- be small (1mm and less)
- surrounded with intact dentine – no carious
- treated immediately

Dentine bridge –
new odontoblasts are differentiated



Pulpotomy

- partial
- total

- If the perforation is bigger
- Surrounded with carious dentine
- Longer time after perforation

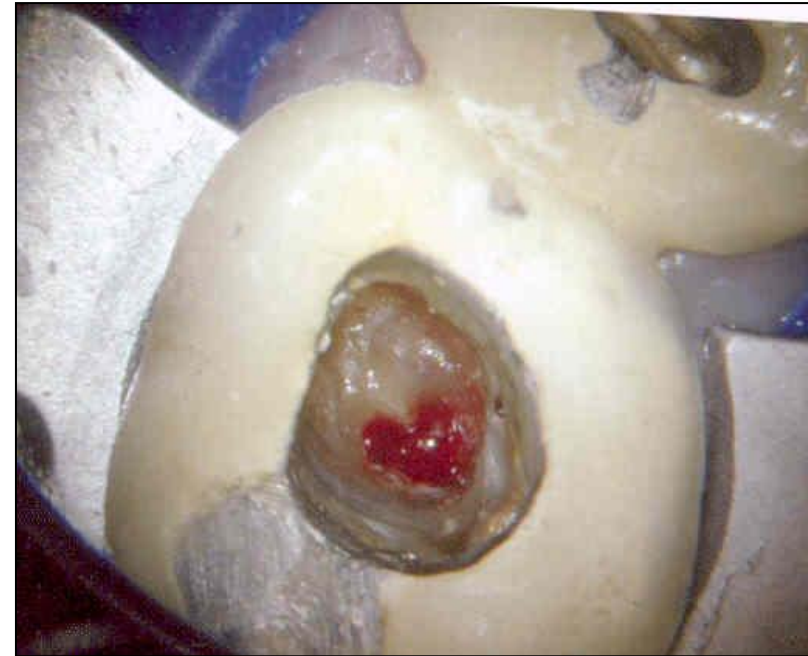Dentin bridge

Dentin bridge

- Dentin bridge :

New dentin that is produced
by new odontoblasts

That differentiate from
stem cells in dental pulp



Root canal treatment - RCT

- Preendo treatment
- Access opening
- Root canal shaping
- Root canal cleaning
- Root canal filling
- Postendo treatment