

Dental care

Bartáková Sonia

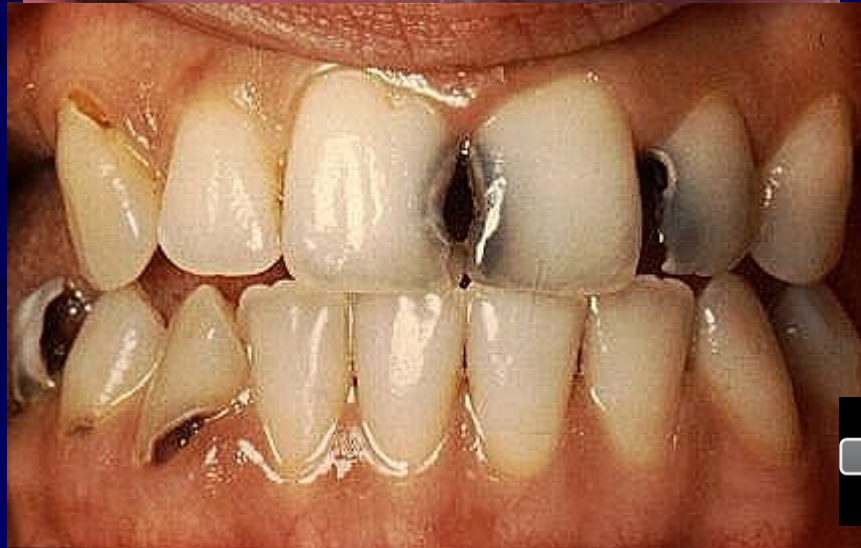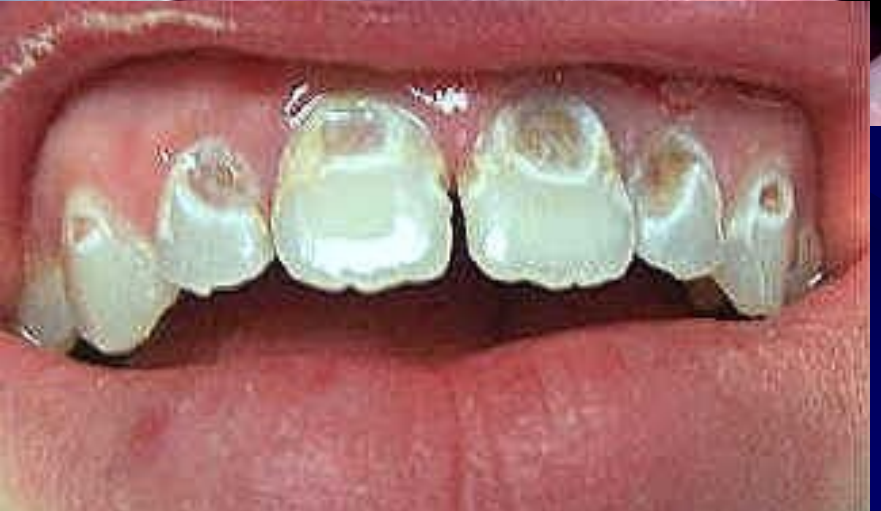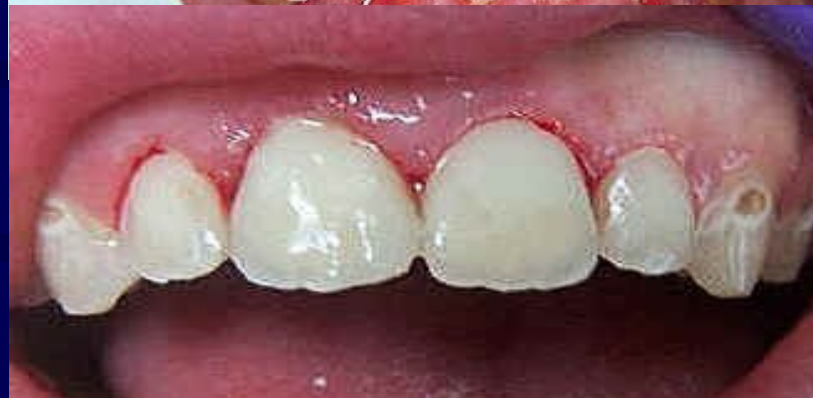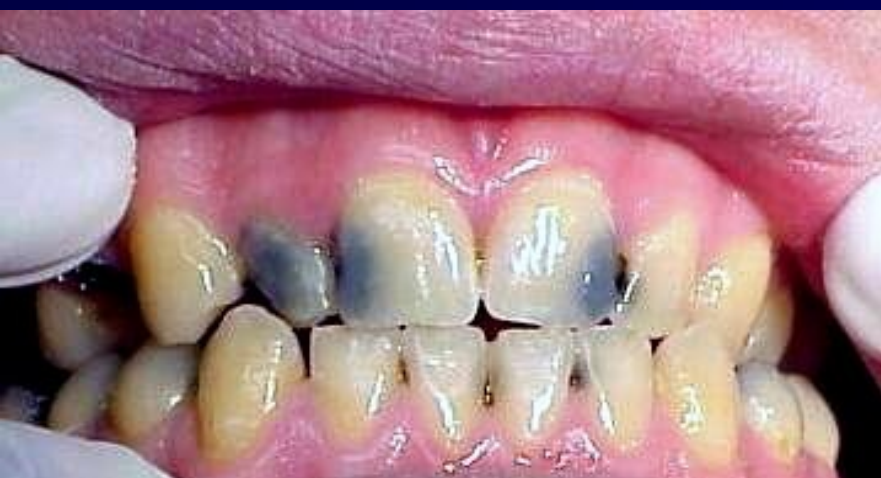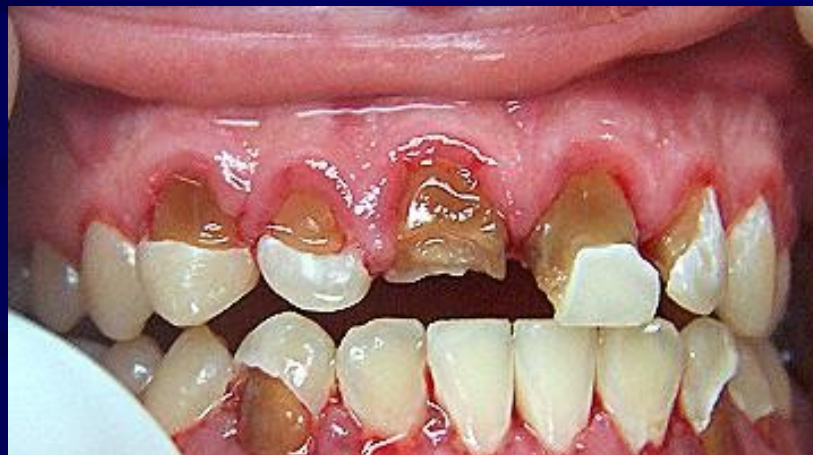Stomatologická klinika LF MU v Brně



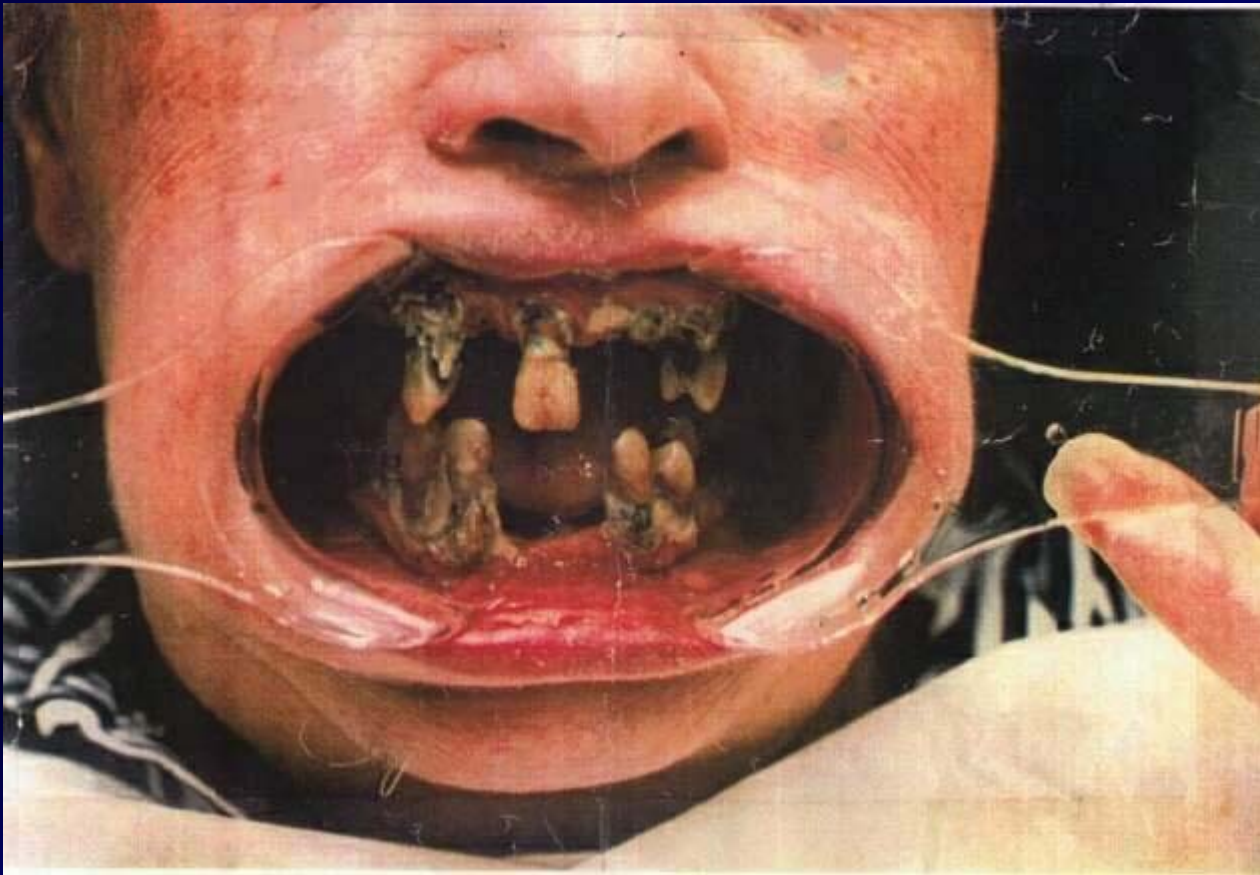




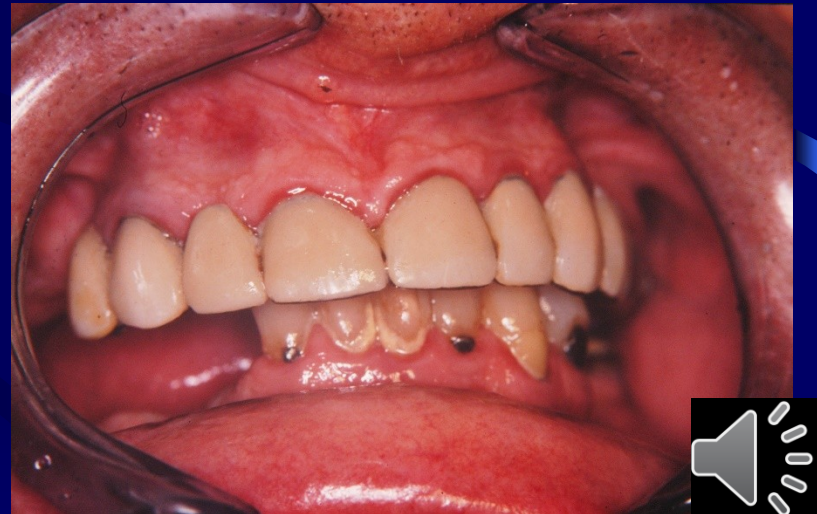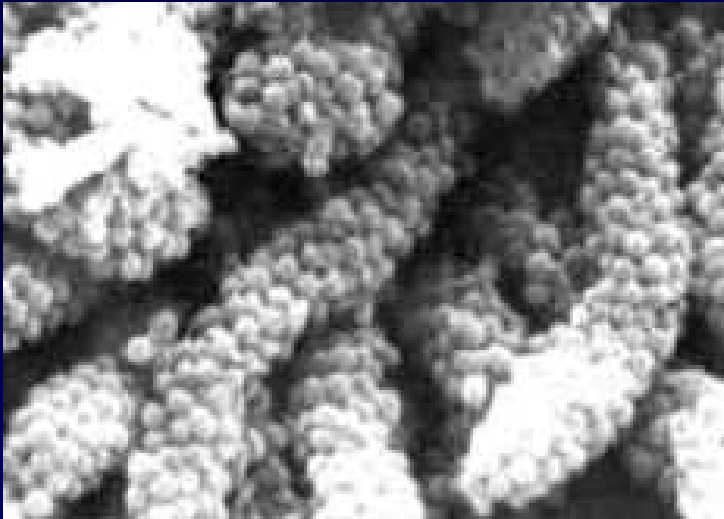

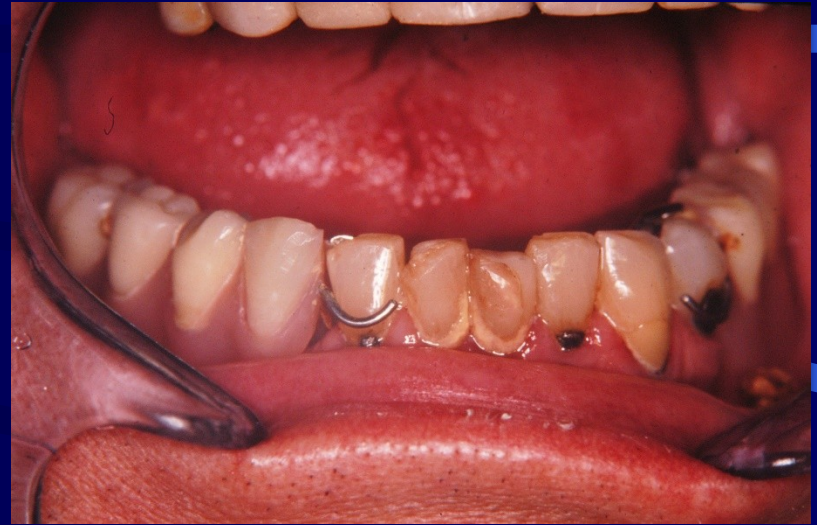Carries



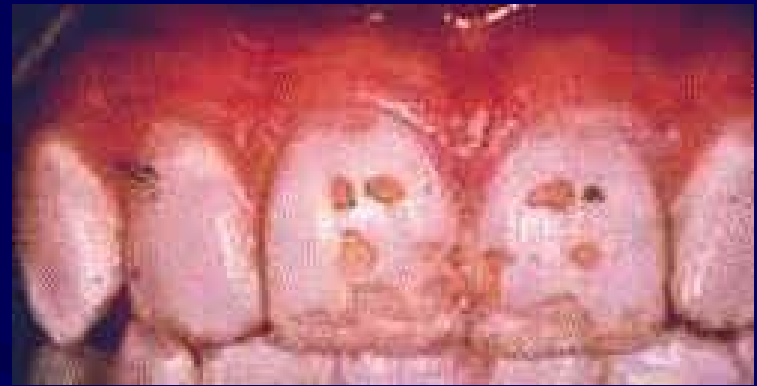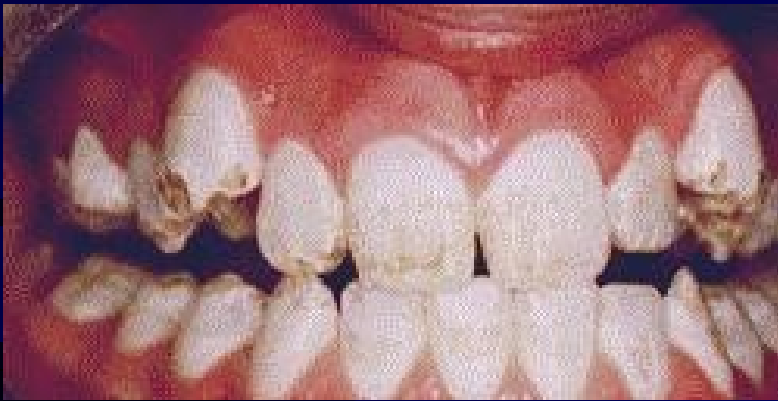Plaque, calculus, malhygiene



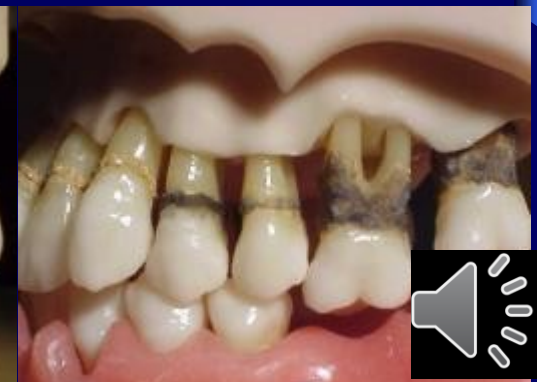
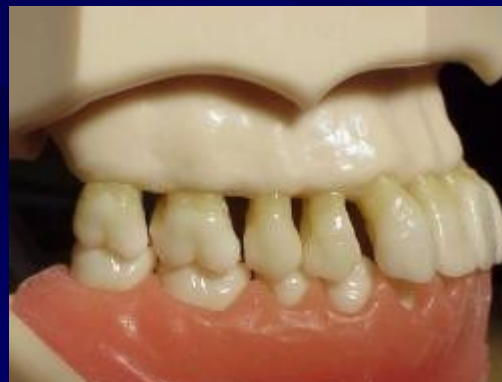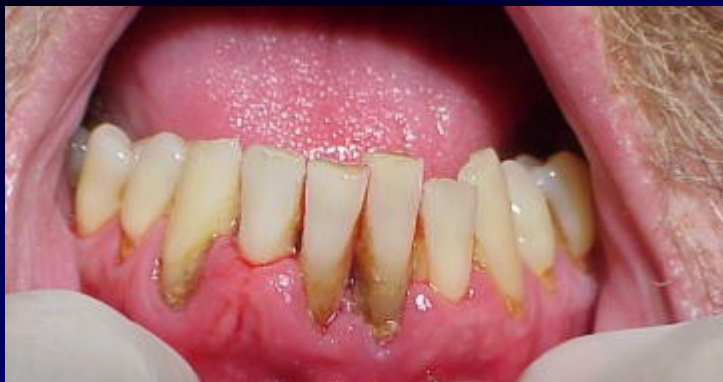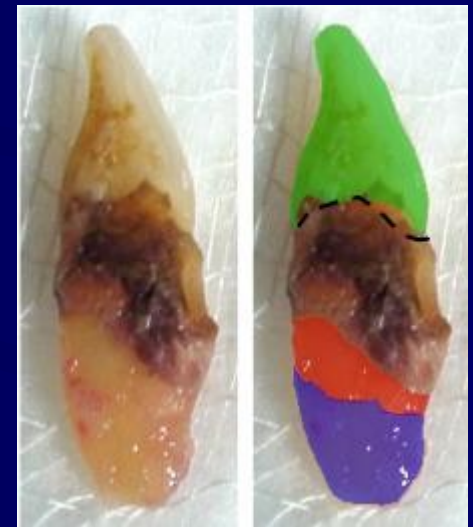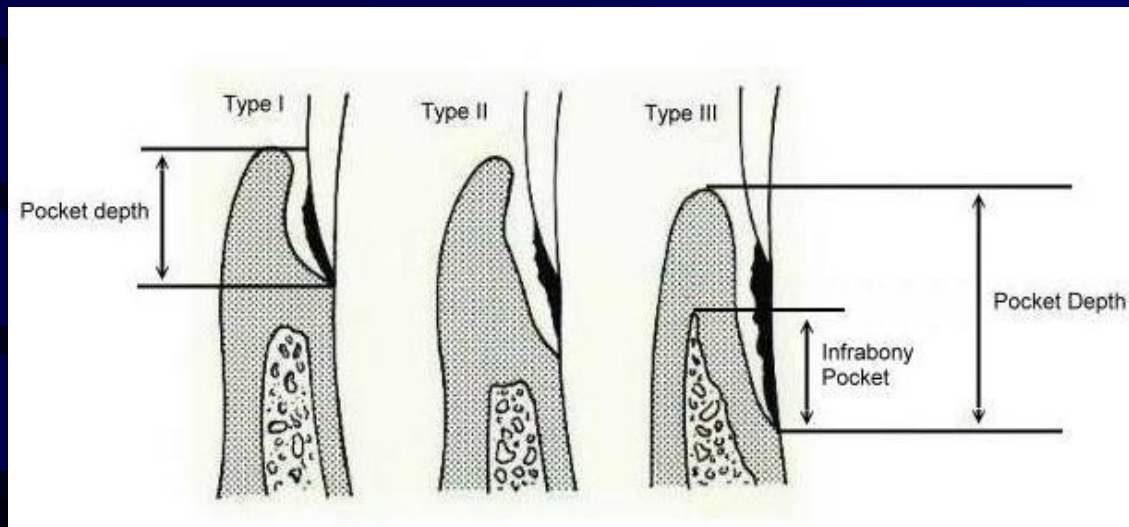
Plaque



St.post antibiotics



Tartar



Voldrich classification

- 1.class – 1a Denture with small defects (denture without 1 or 2 teeth)
- 1a Denture with big defects (denture without 3 or 4 teeth)
- 2.class Shortened dental arch unilaterally or bilaterally
 - with gaps of frontal teeth
 - without gaps of frontal teeth
- 3. class – Big defects – patient has only 1-3 teeth or small groups of the teeth
- 4. class – no teeth



Temporary crowns

1. Factory made

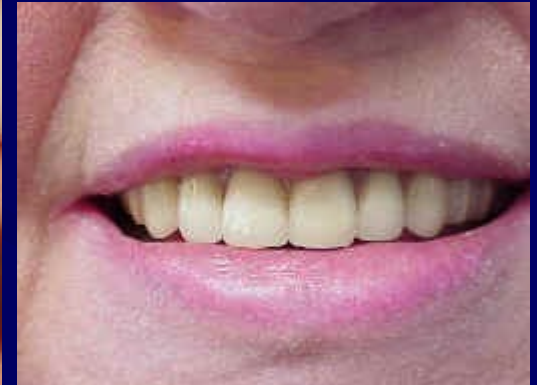
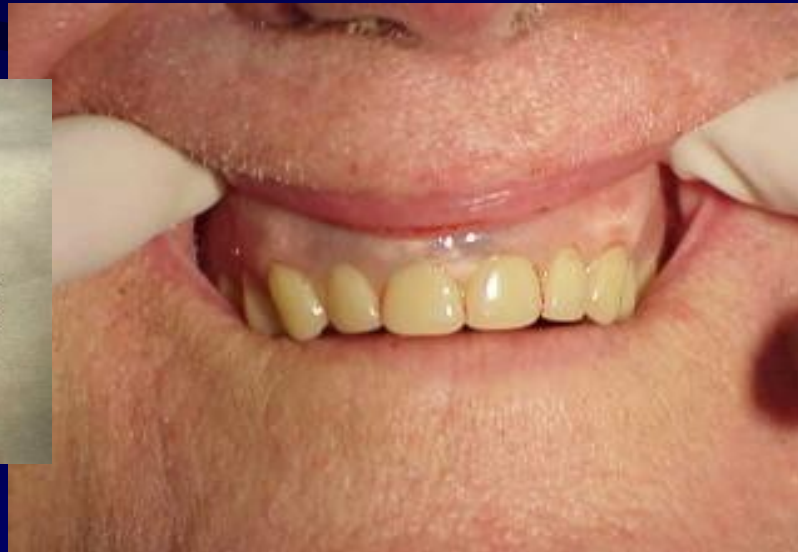
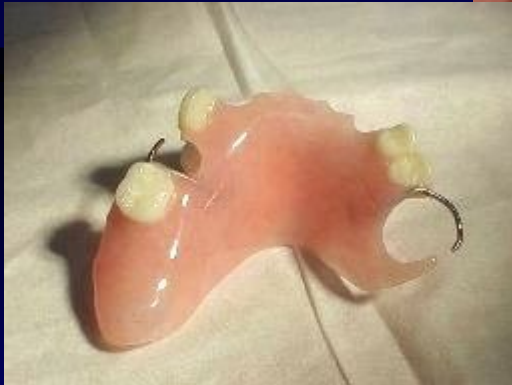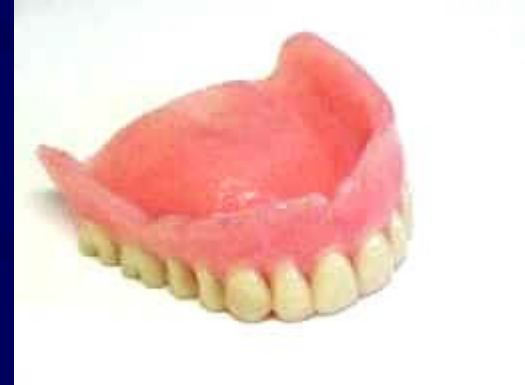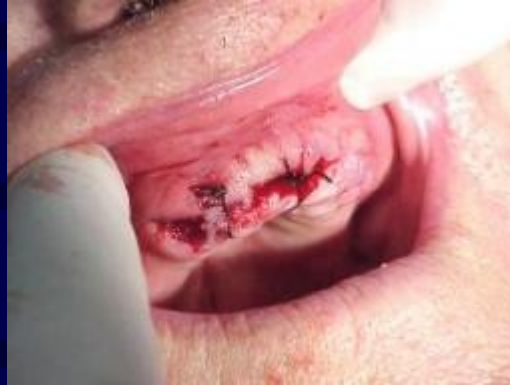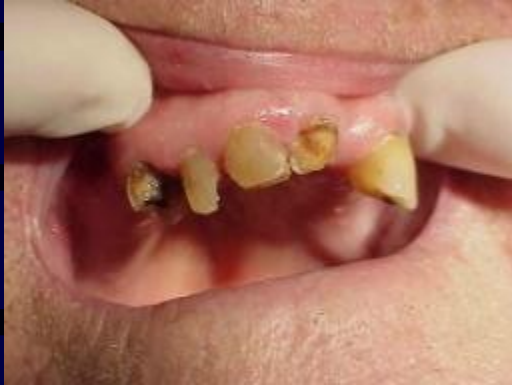2. Laboratory made

3. Stemp method



Immediate dentures only for 6 weeks



I.class

Dental arch

- a) Small gaps (1-2 teeth)
- b) Big gaps (more than 3 teeth)



Fixed dentures

1. Full metal crowns
2. Veneer crowns
3. Atraumatic crowns
4. Semicrowns
5. Inlay
6. Full ceramic crowns, metaloceramic crowns

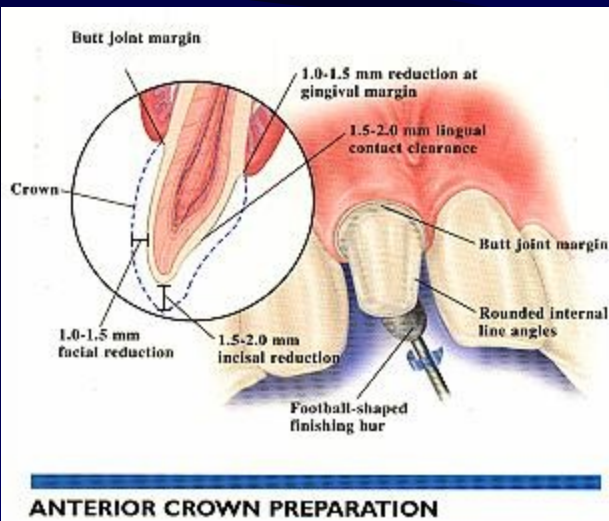
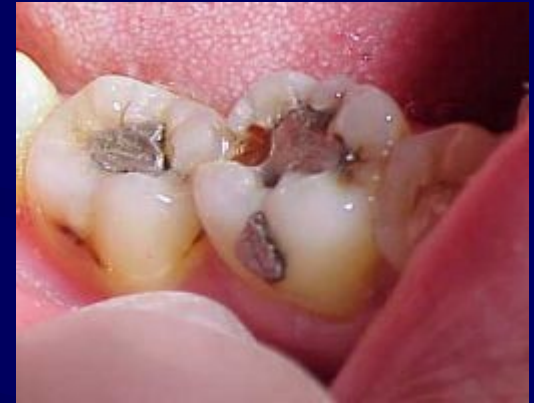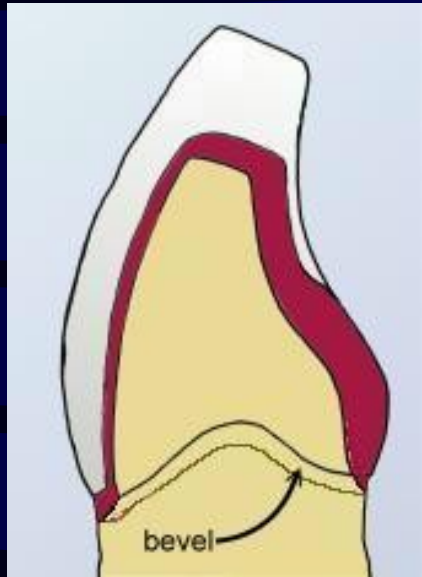


Ceramic at dentistry

- Metalokeramic crowns and bridges
- Fullceramic crowns
- Ceramic teeth for full dentures

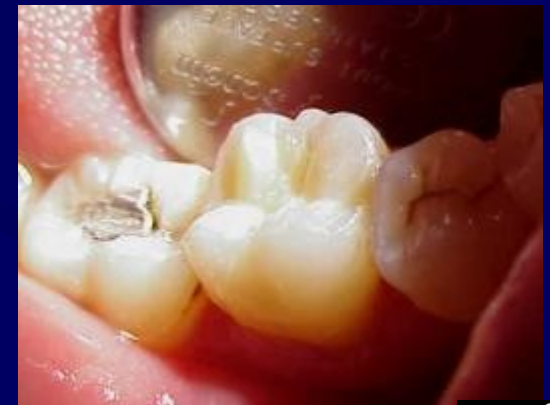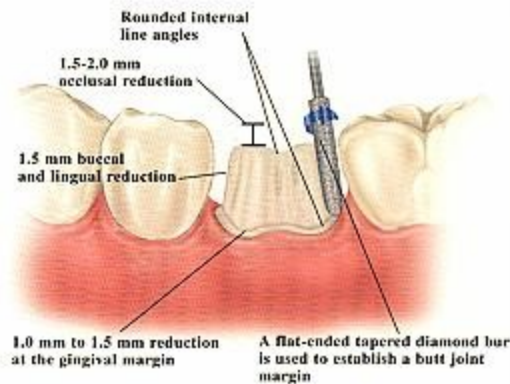


Metaloceramic crowns

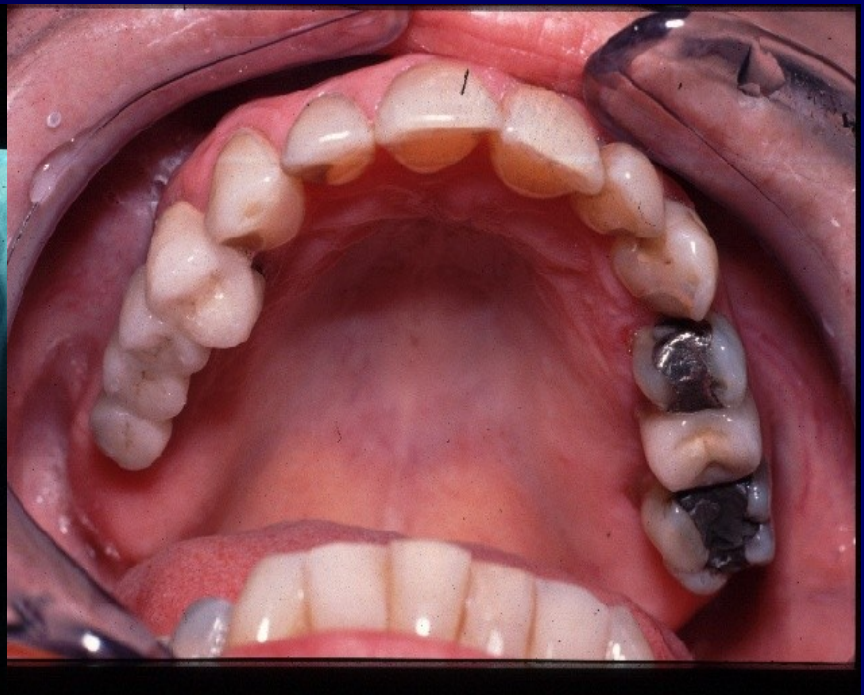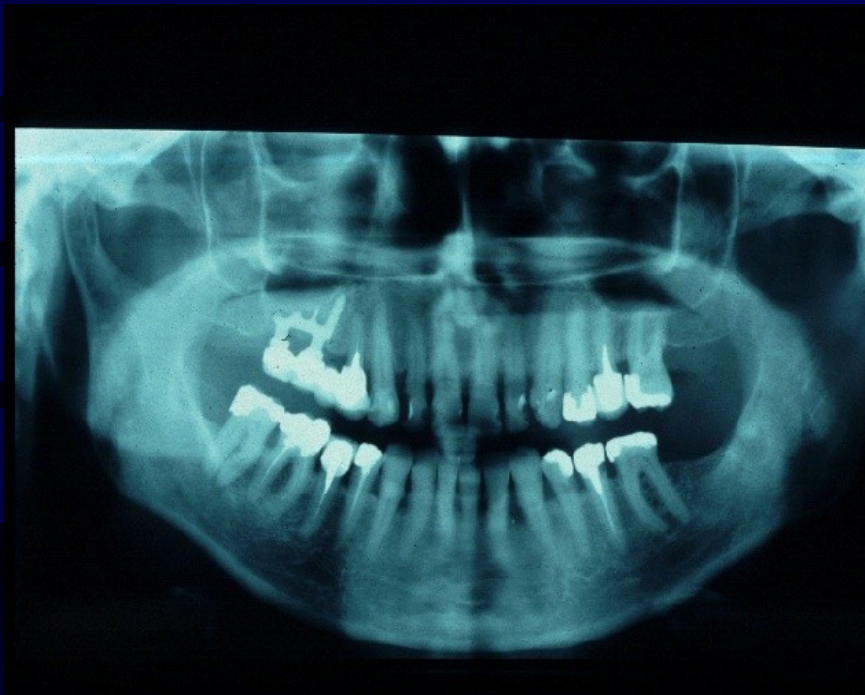


ANTERIOR CROWN PREPARATION

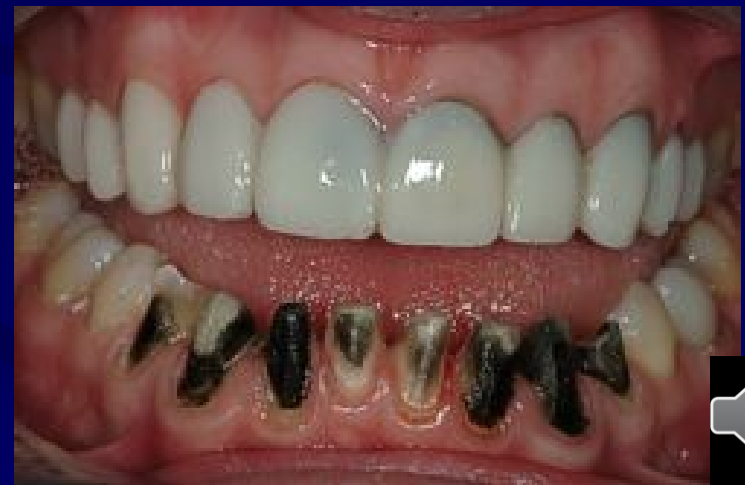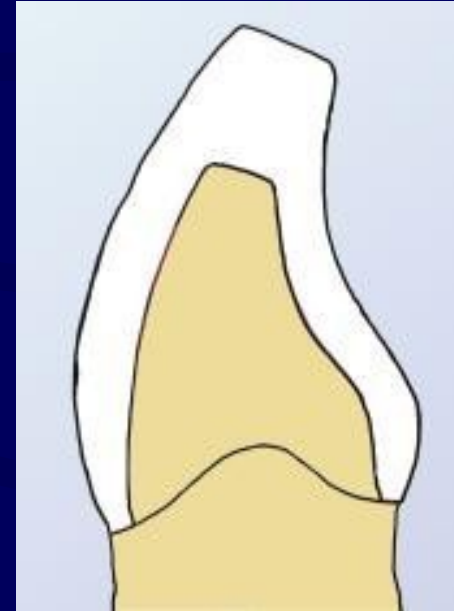
POSTERIOR CROWN PREPARATION



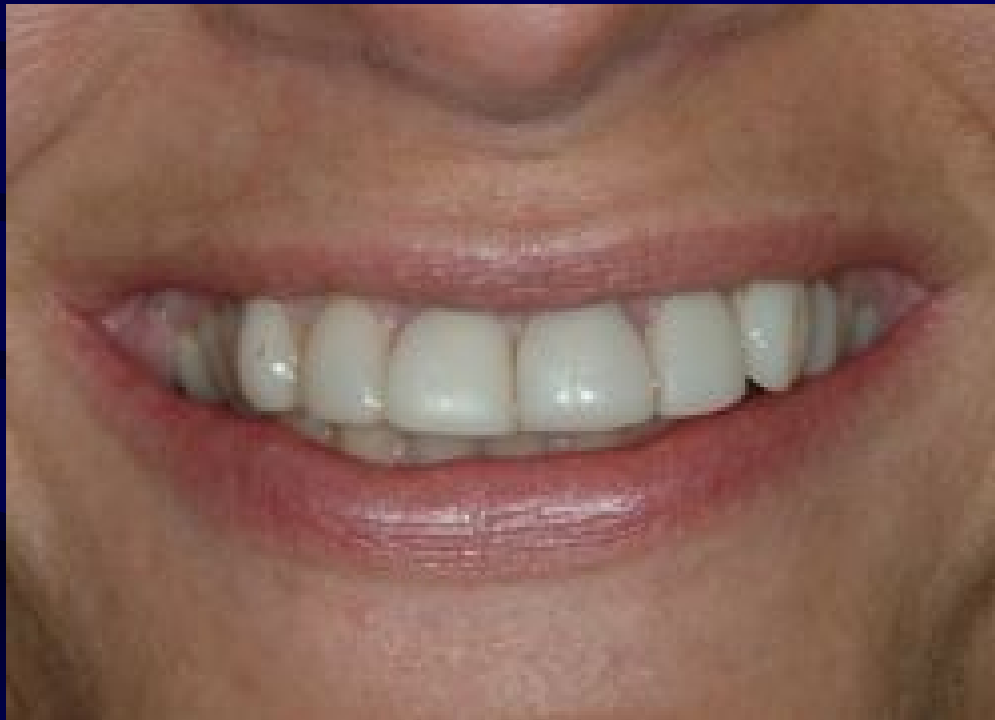Metaloceramic crowns



Fullceramic crowns



Resin crowns



Indication of bridge

- **Small gaps**
- **Pillars are near gaps**



Contraindication of the fixed denture

Absolutly

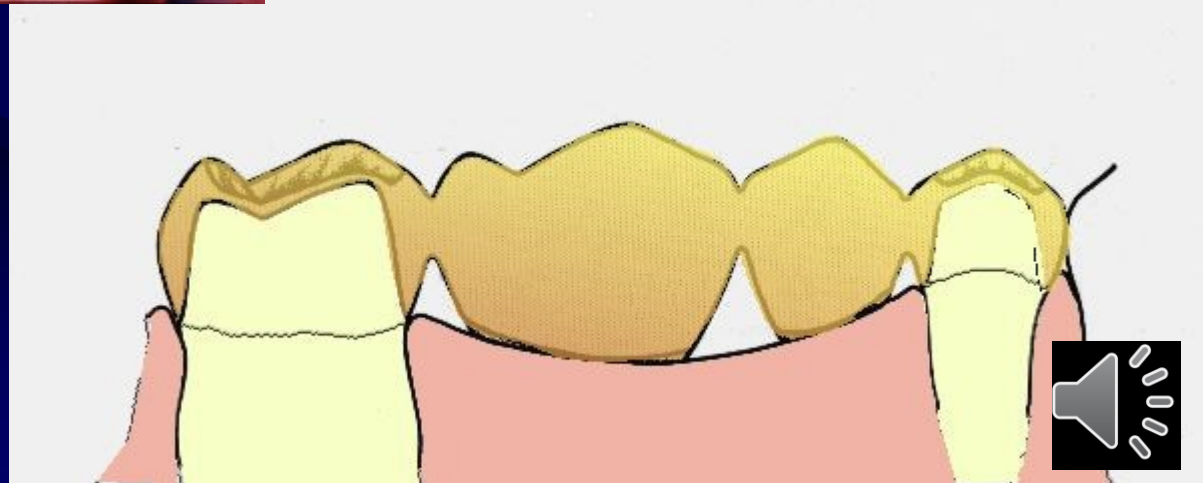
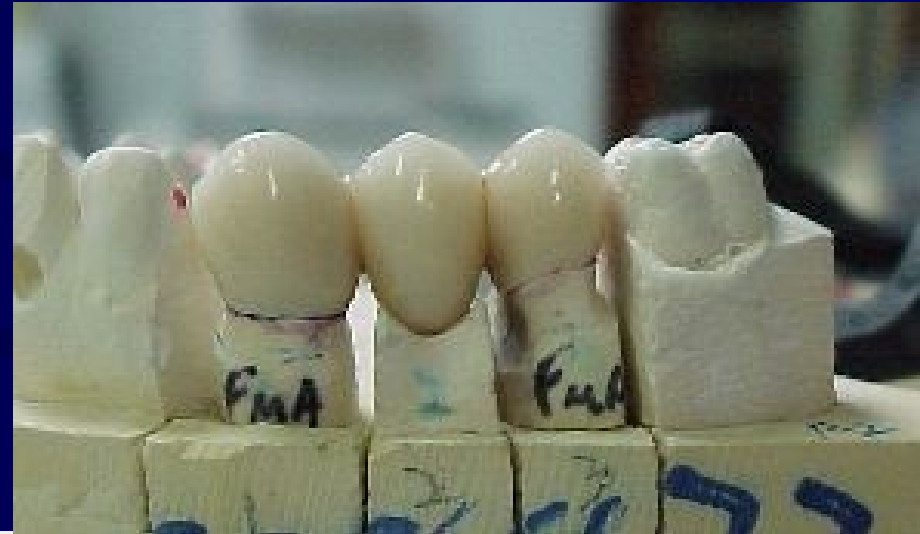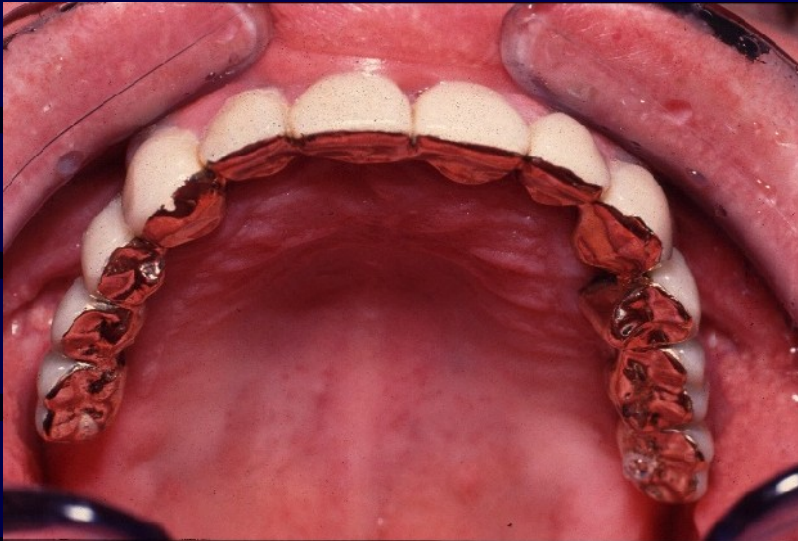
- Big gaps
- Bad biological factor
- Abnormal big gaps of frontat region

Relativly

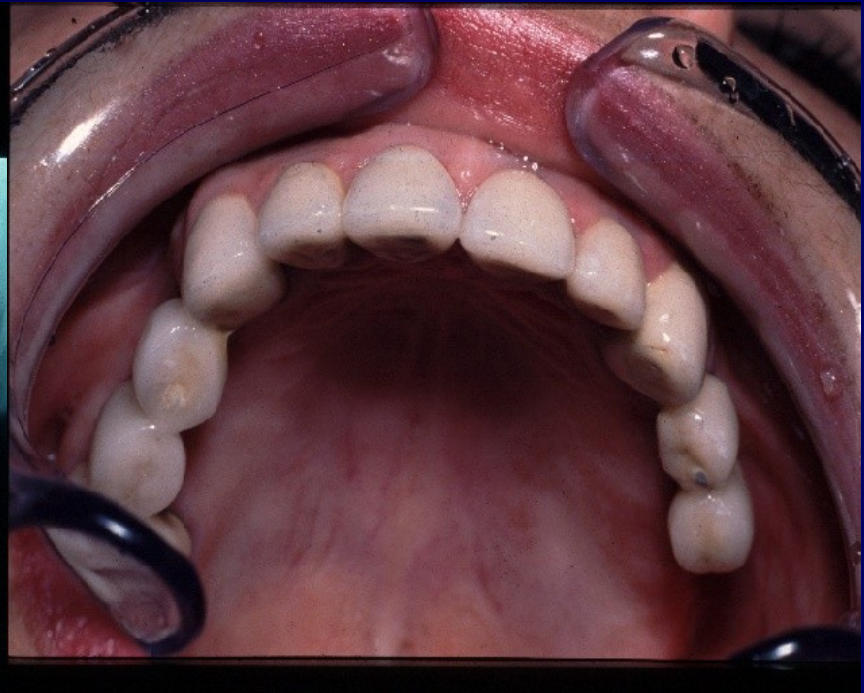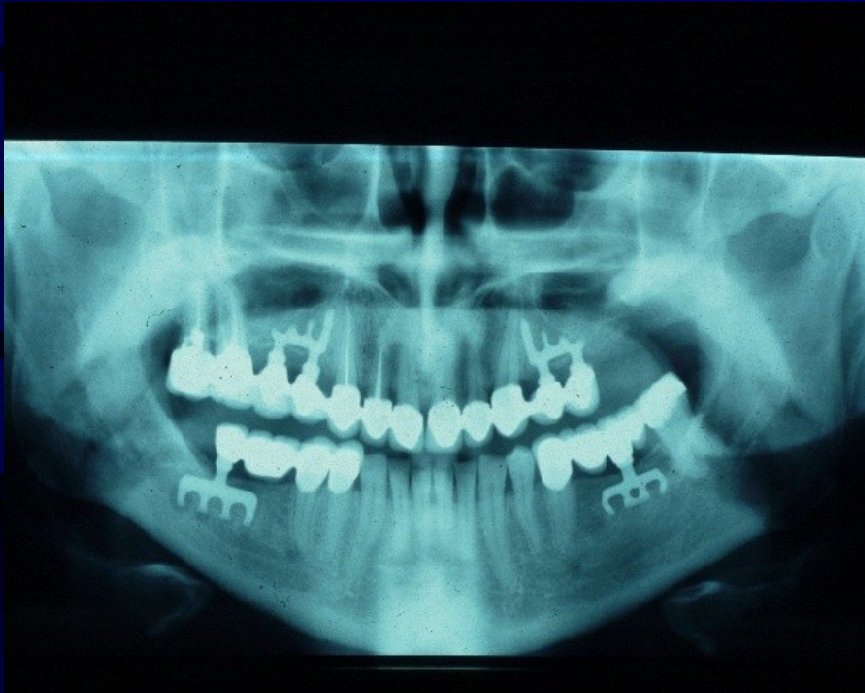
- Inflamations of the gimgiva,parodont
- Resorption of the bone



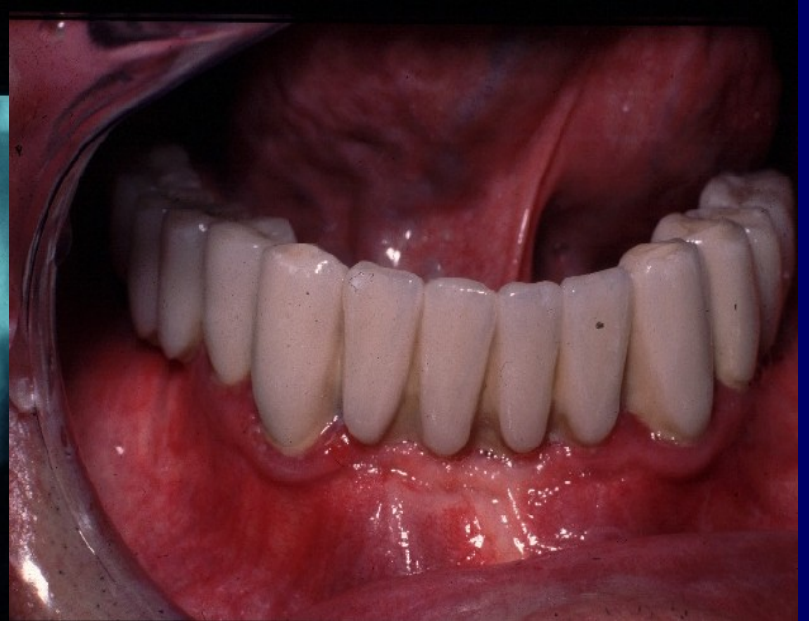
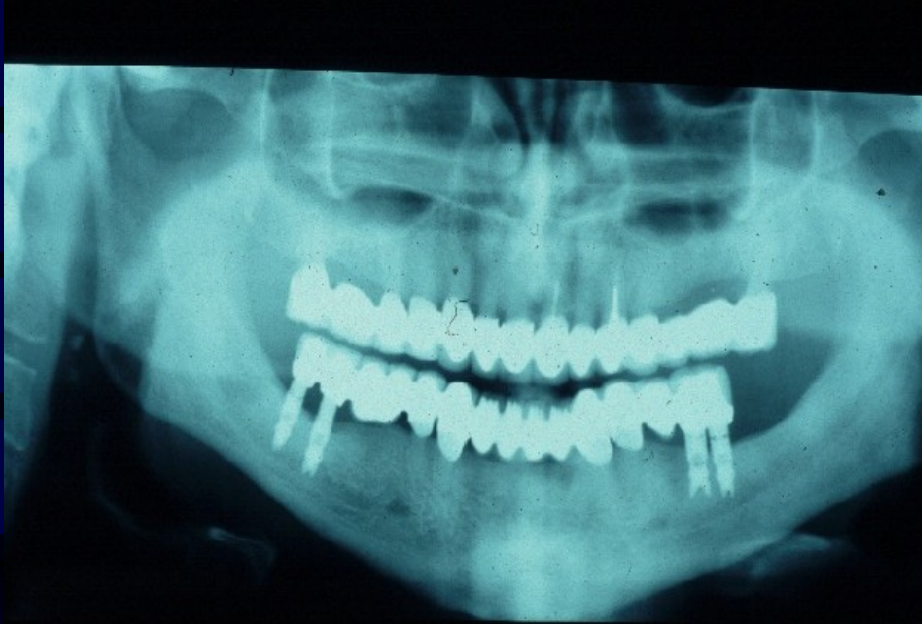
Faset(Veneer) and Metaloceramic bridge



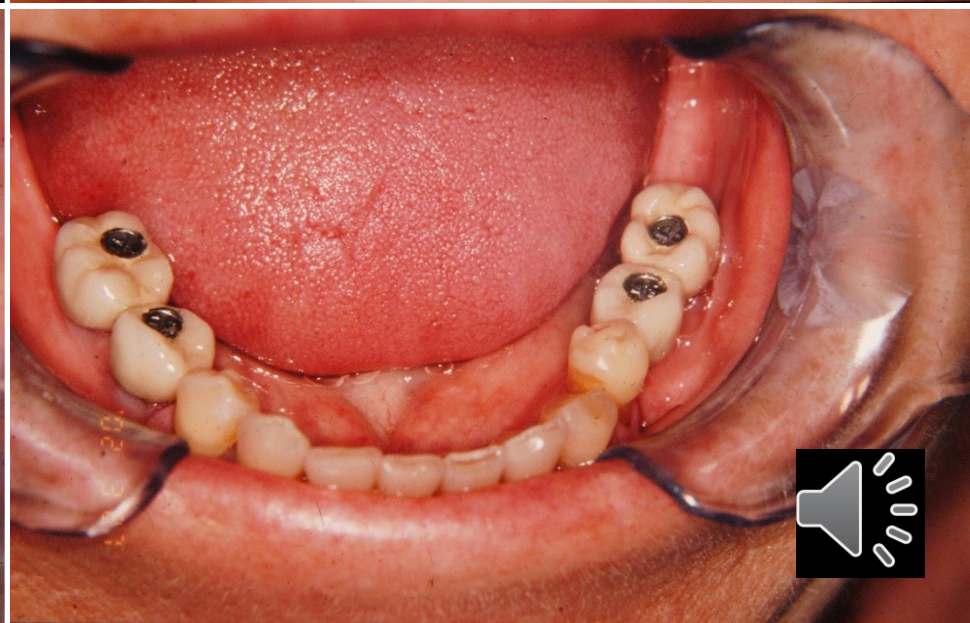
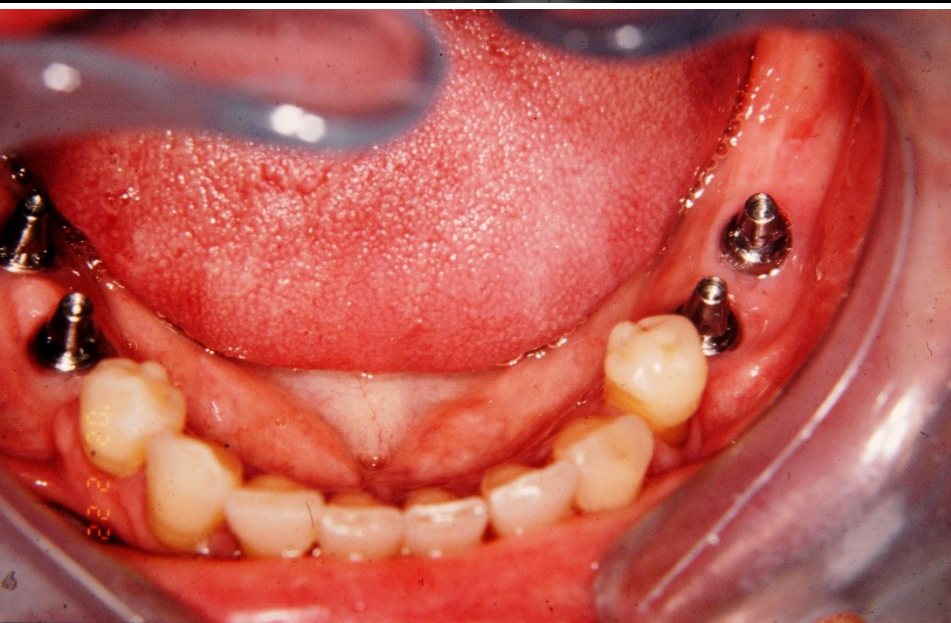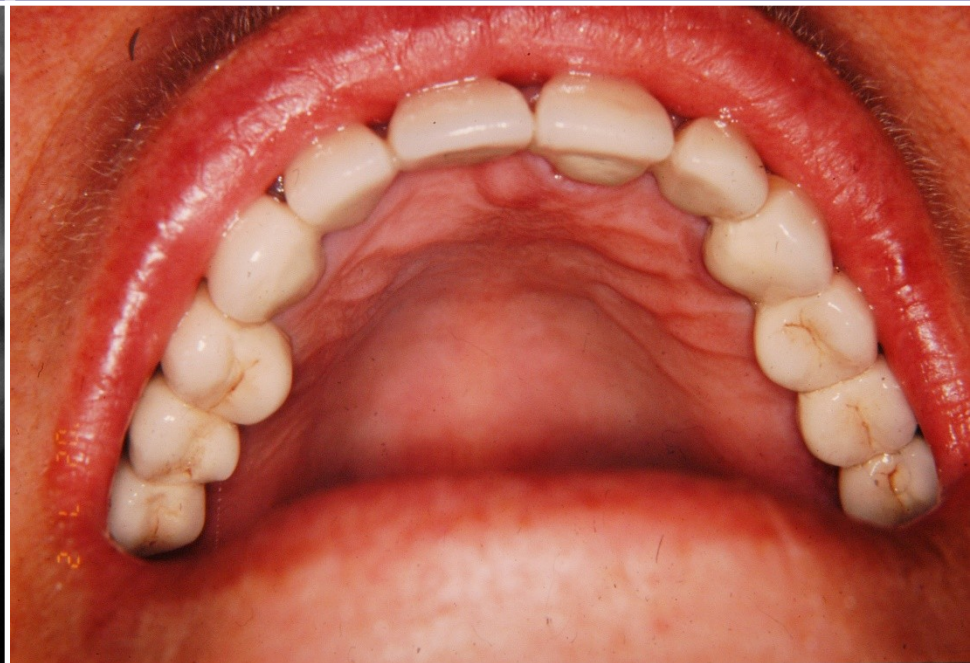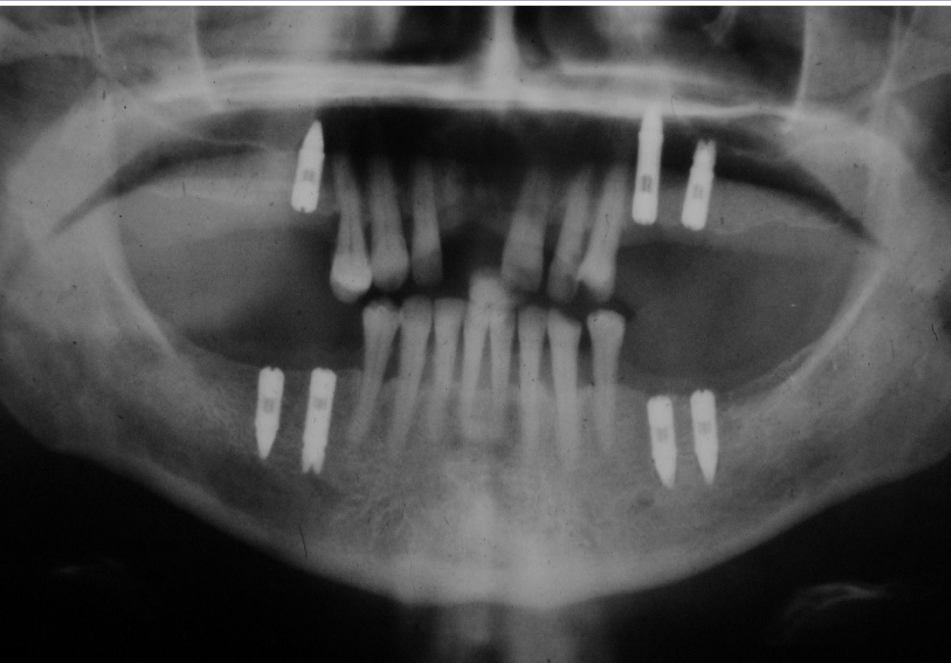
Metaloceramic bridge



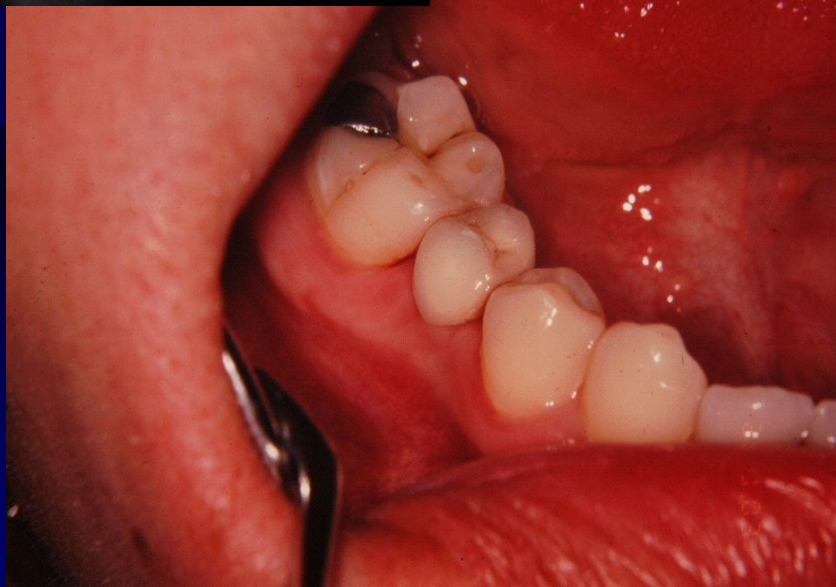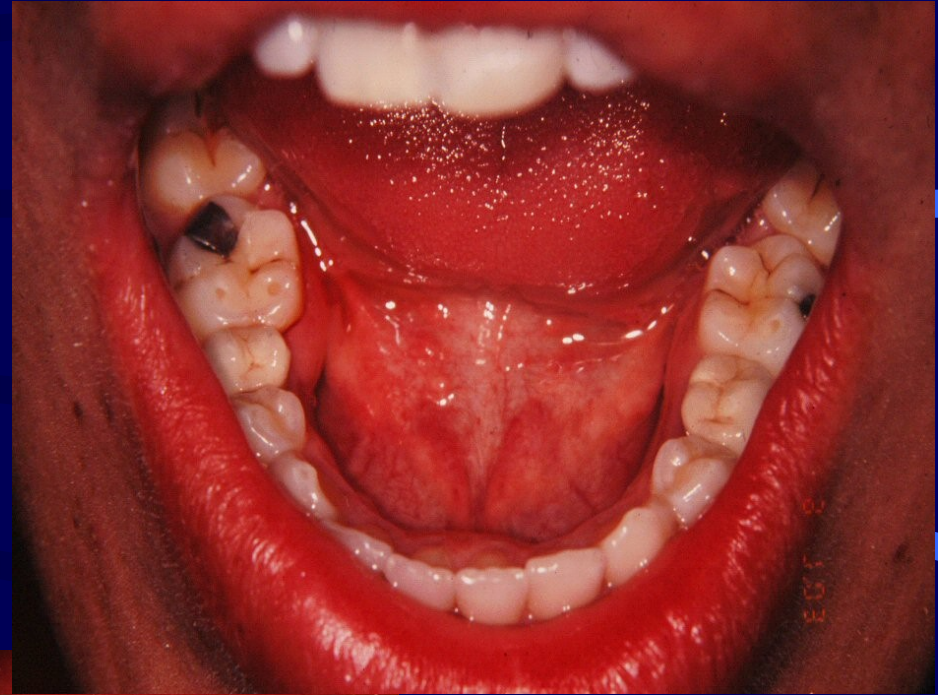
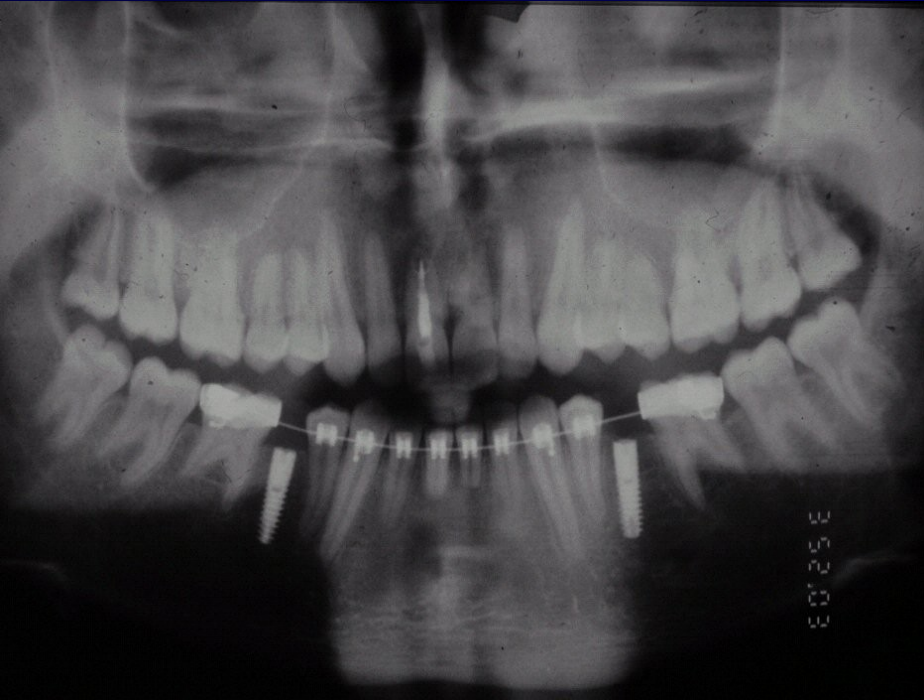
Metaloceramic bridge



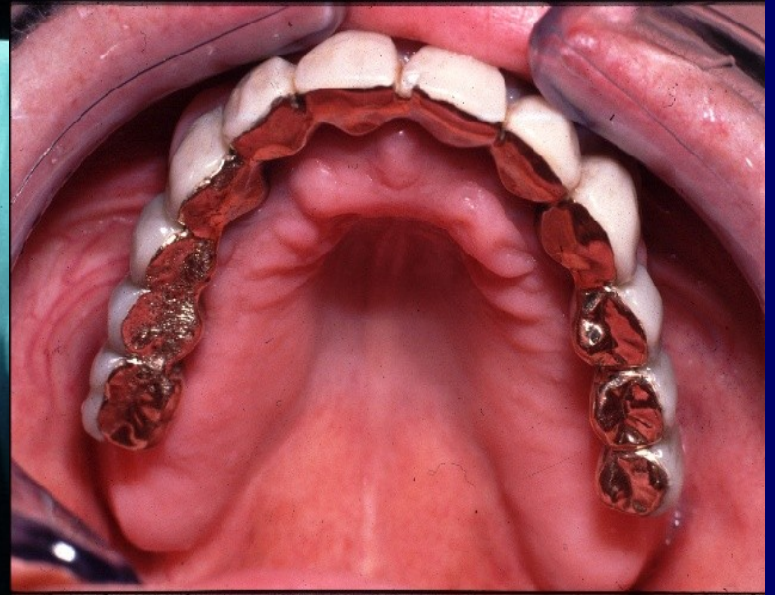
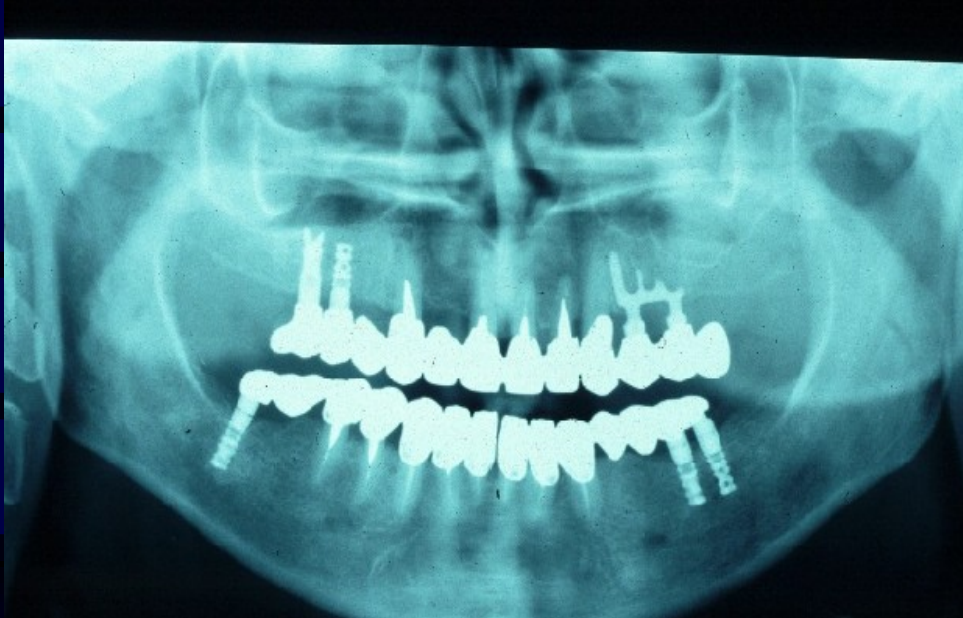Metaloceramic crowns on the implants



Metaloceramic crowns on the implants



Metalloceramic crowns on the implants



Removable denture II.class



II. Class of Voldrich classification

Shorted dental arch uni or bilaterally

- a) **Bilaterally without gaps**
- b) **Unilaterally without gaps**
- c) **Bilaterally with gaps**
- d) **Unilaterally with gaps**



Basic framework of removable dentures

- **Body of prosthesis**
- **Stabilizing Retainers**
- **Connecting framework**

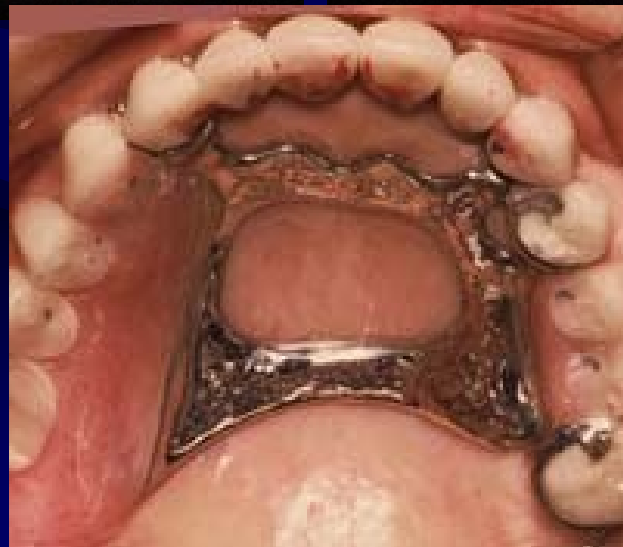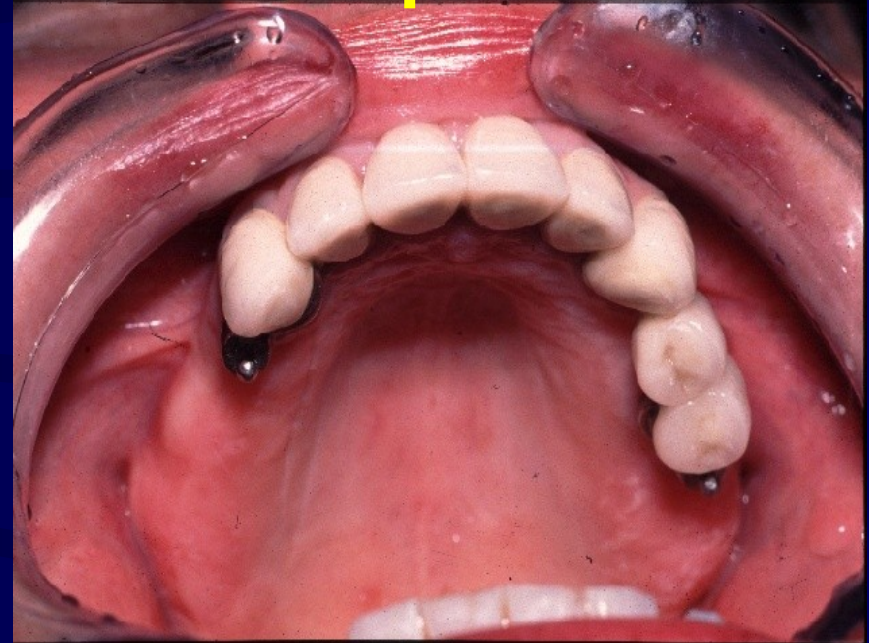
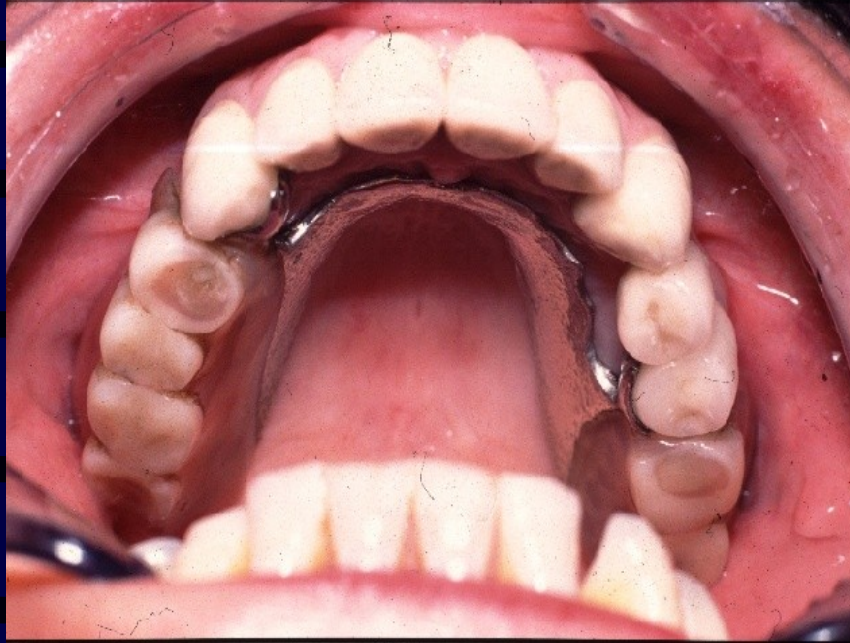


Lower jaw

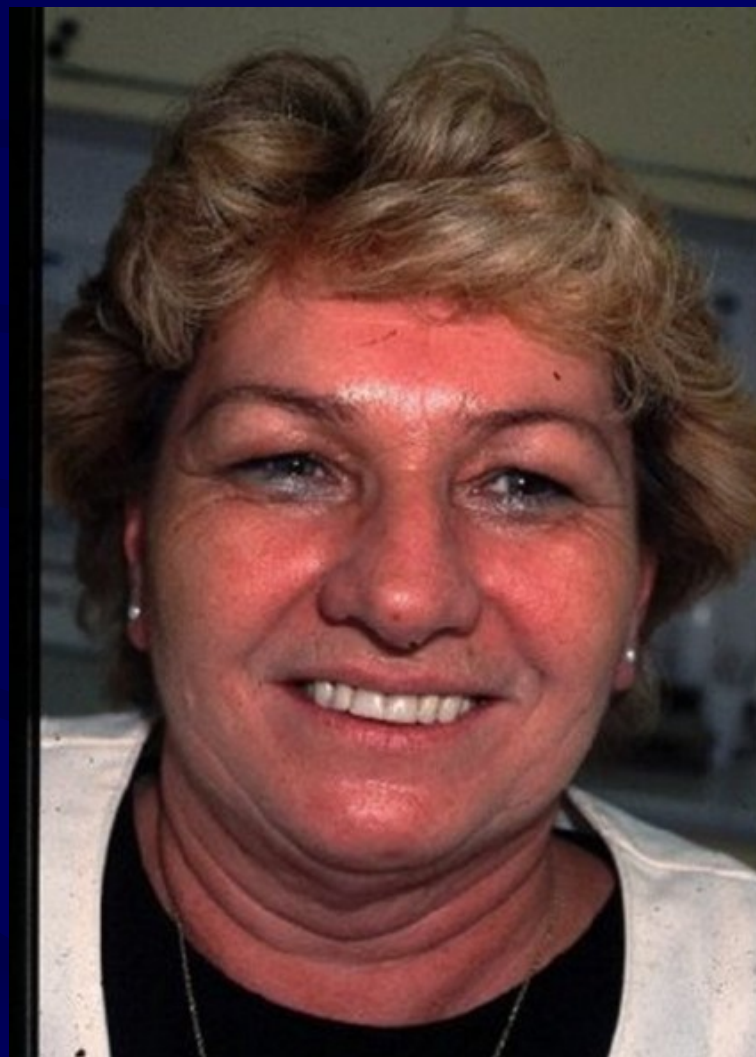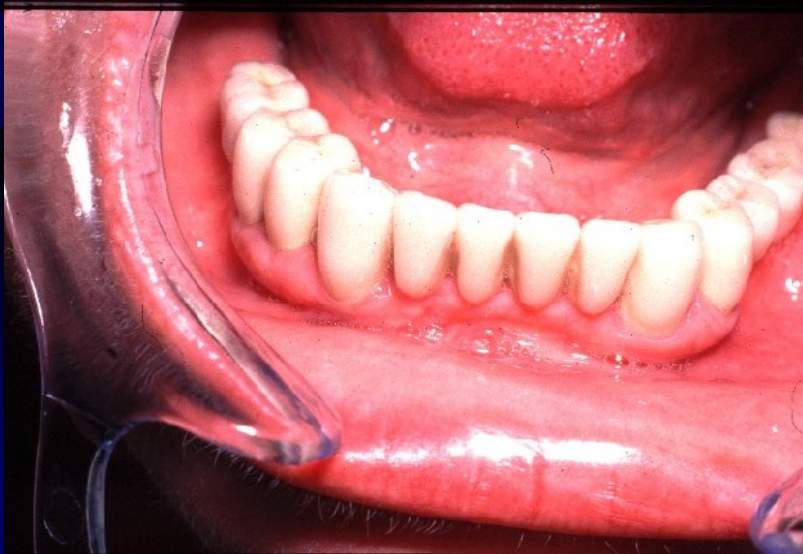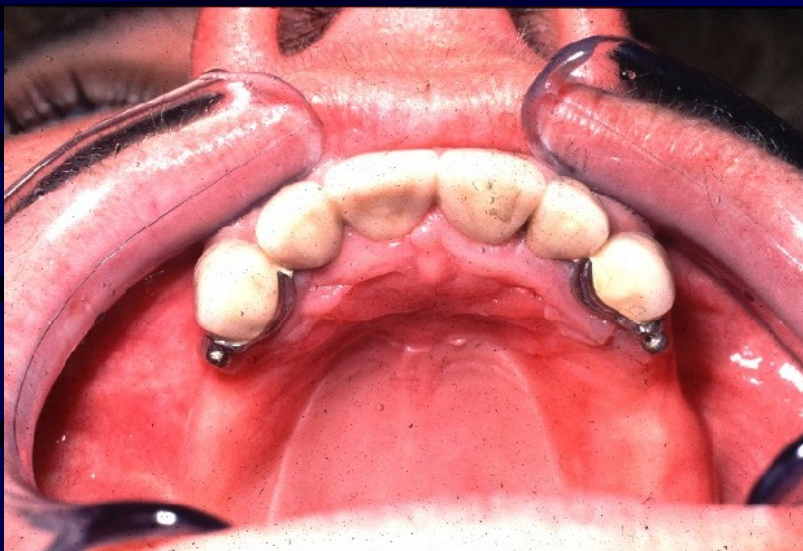- **Skeletal prosthesis with clasps**
- **Svenson plate or sublingual bar**
- **Skeletal prosthesis with attachments**



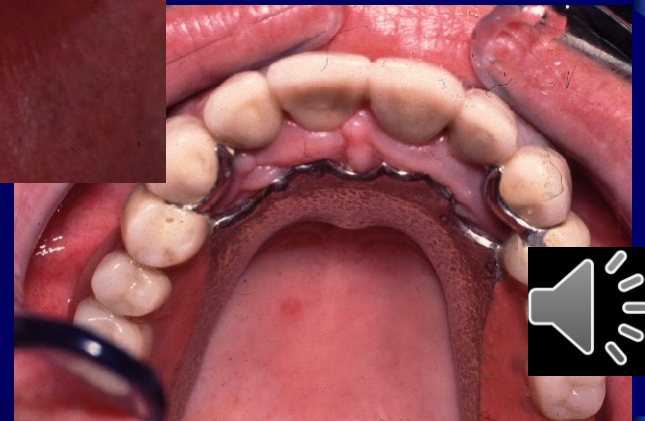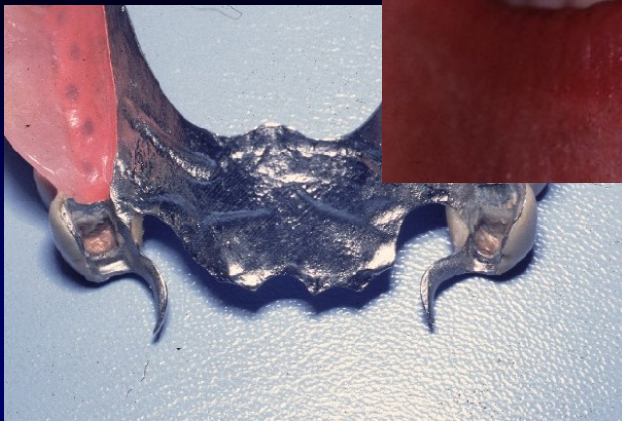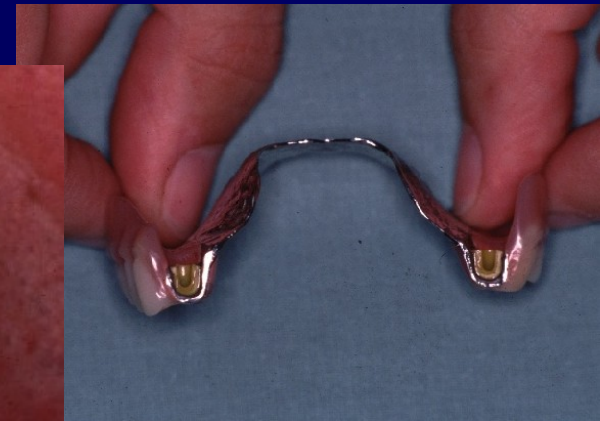
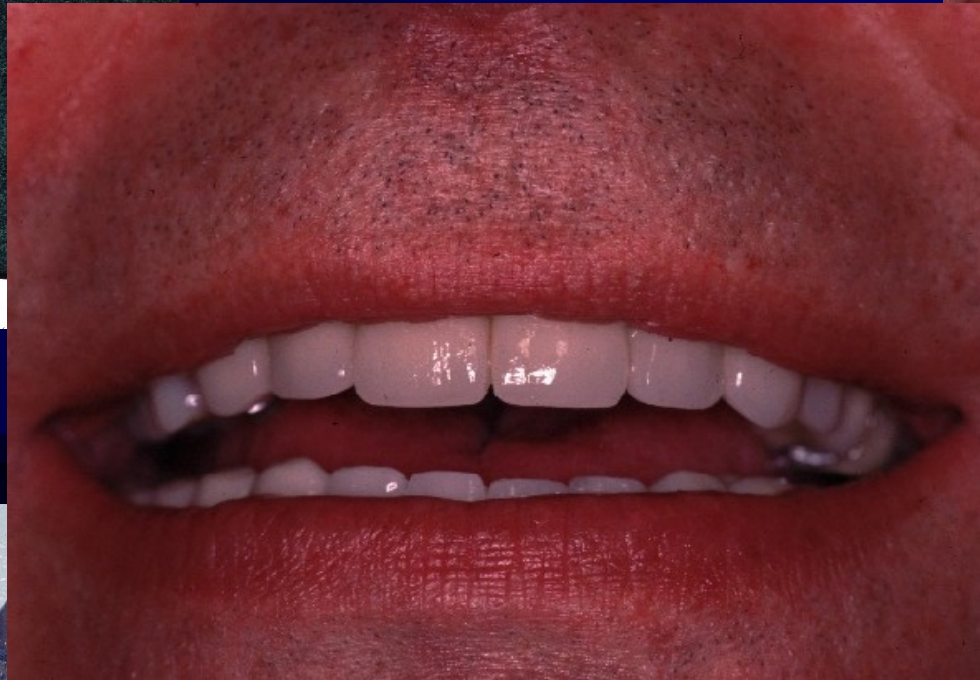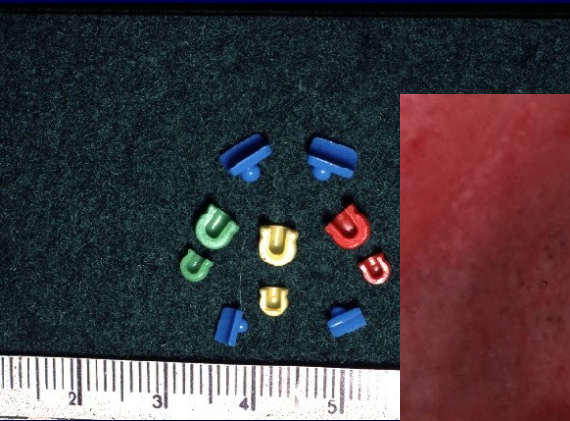
Metaloceramic bridge and hybrid prosthesis with attachments without clasps



Metaloceramic bridge and hybrid prosthesis with attachments without clasps



Skeletal prosthesis with attachments

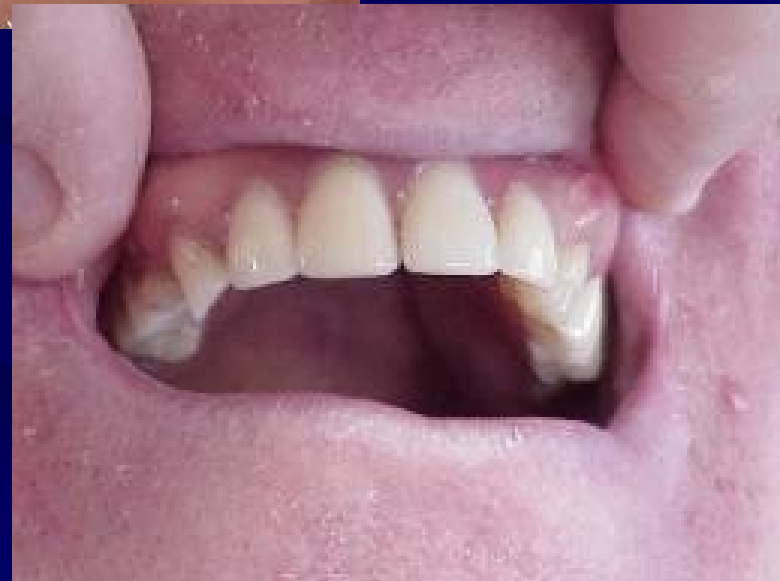
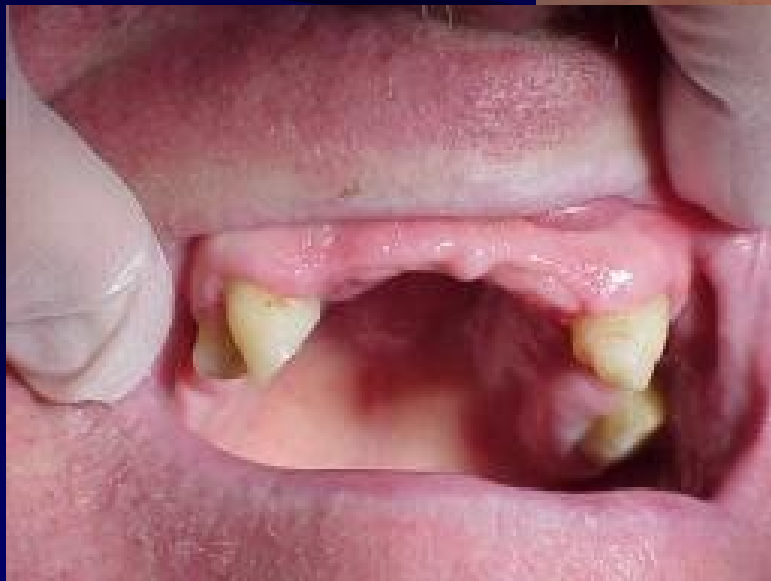
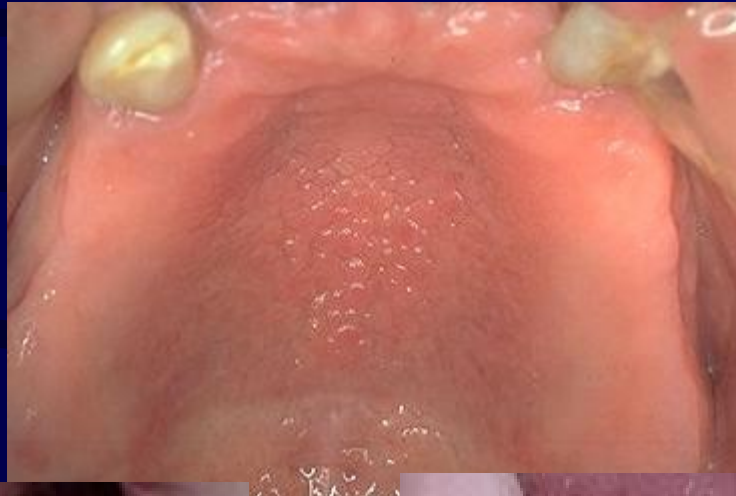III.class

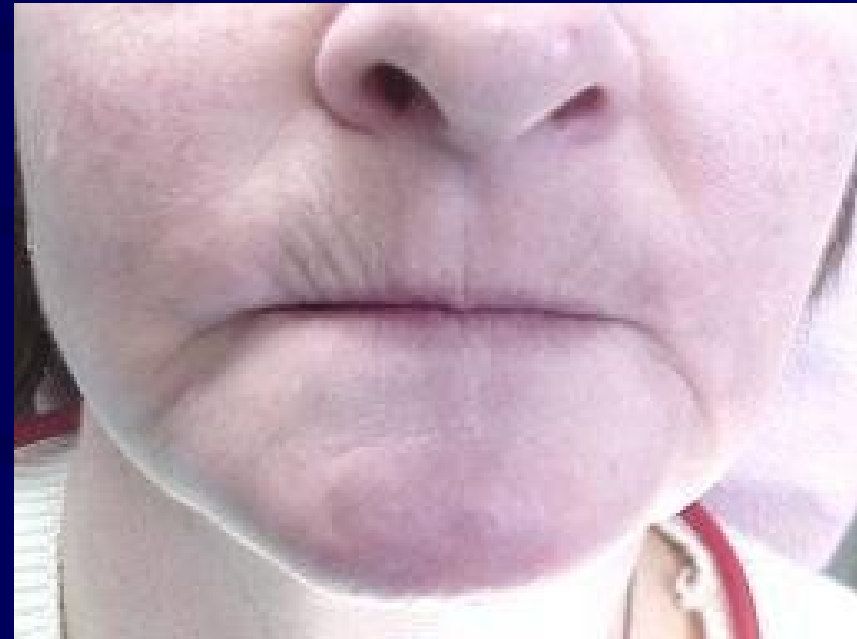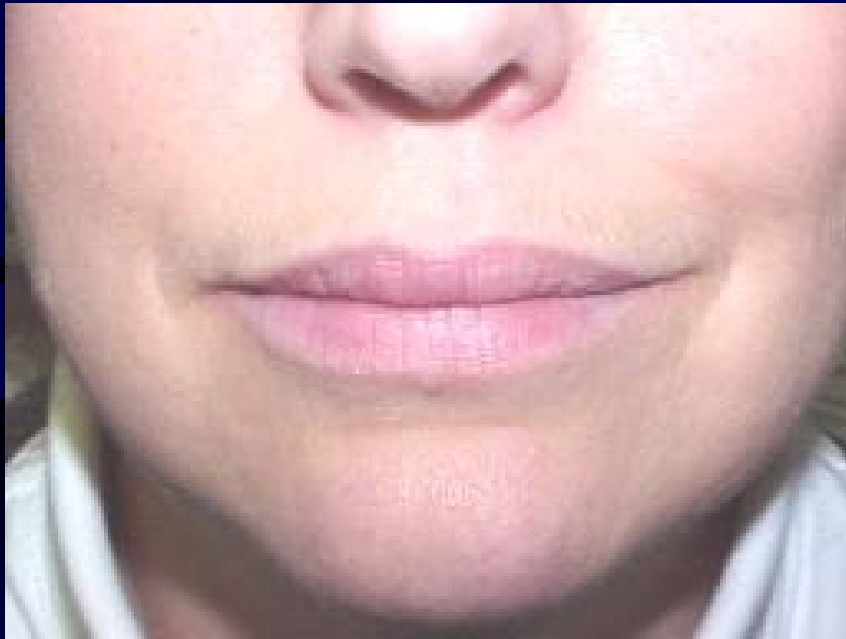The rest of the teeth



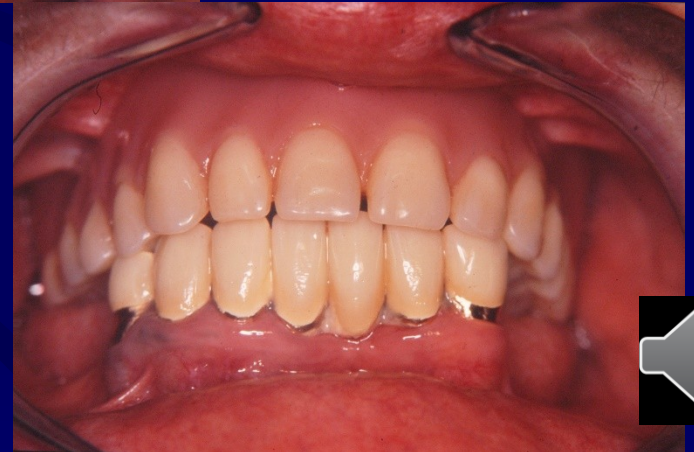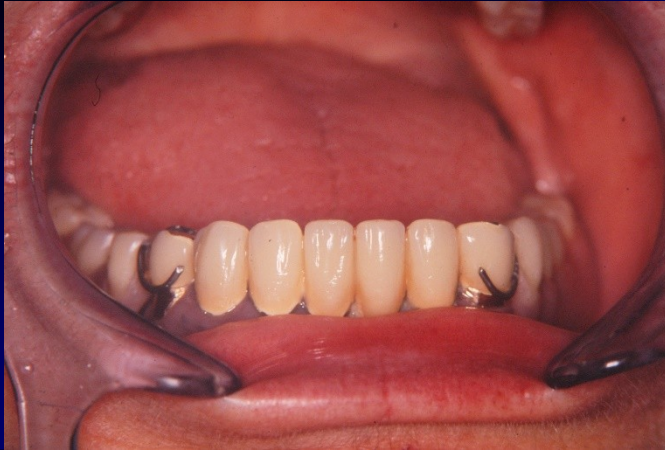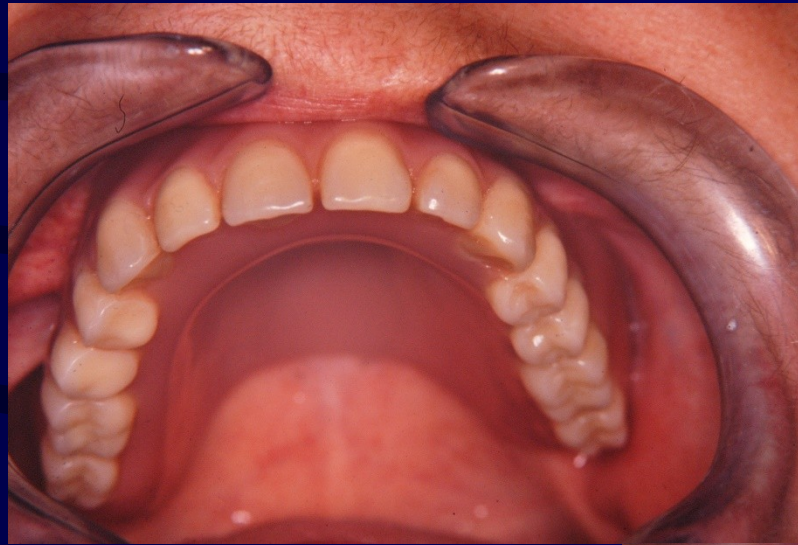Partial removable denture of the III.class of Voldrich



Full denture



Full denture



Implants



Another types

Bränemark
(Replace)

3 i

Compress

LTI

Ankylos

S.T.S

VNI

Dentim

Sofort VNI

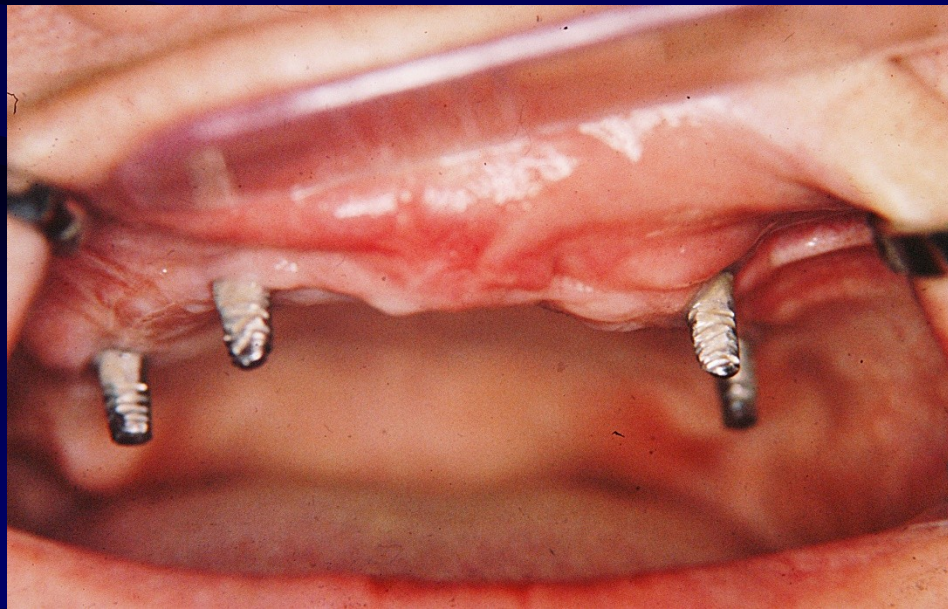
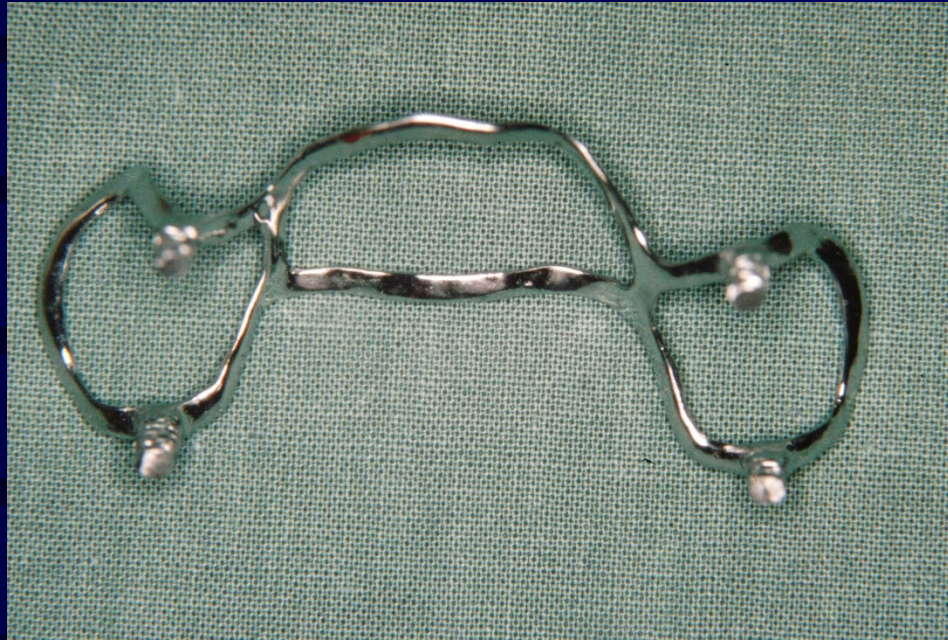I. a II. fase VM

I. a II. fase MTI

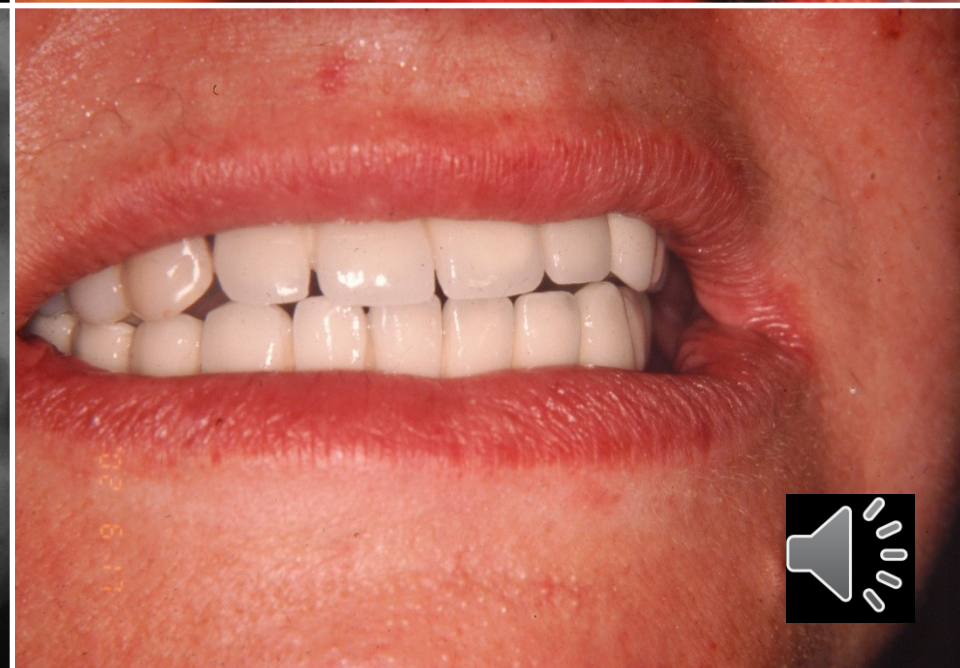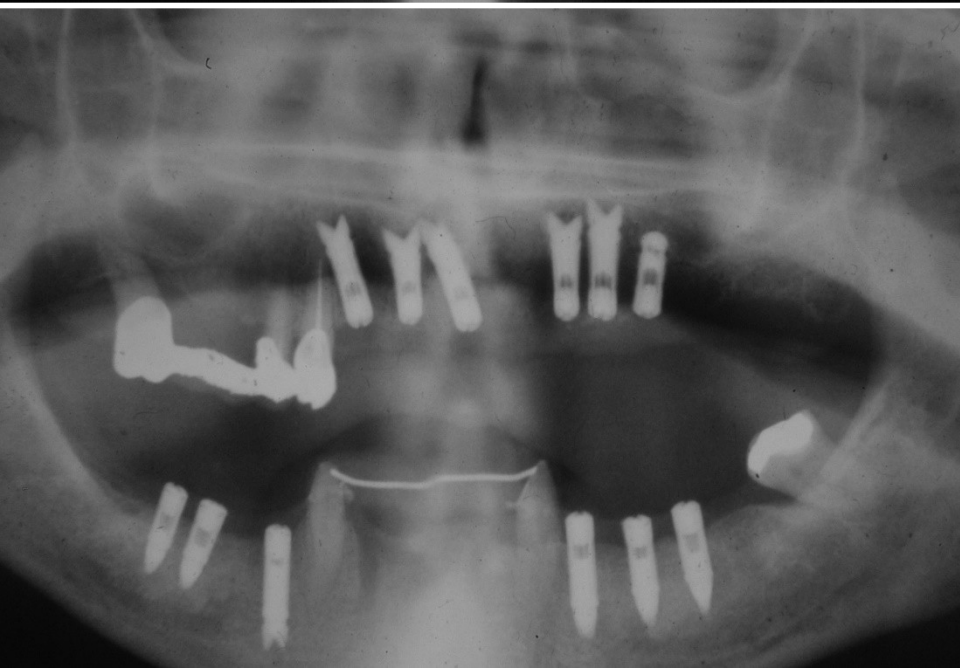
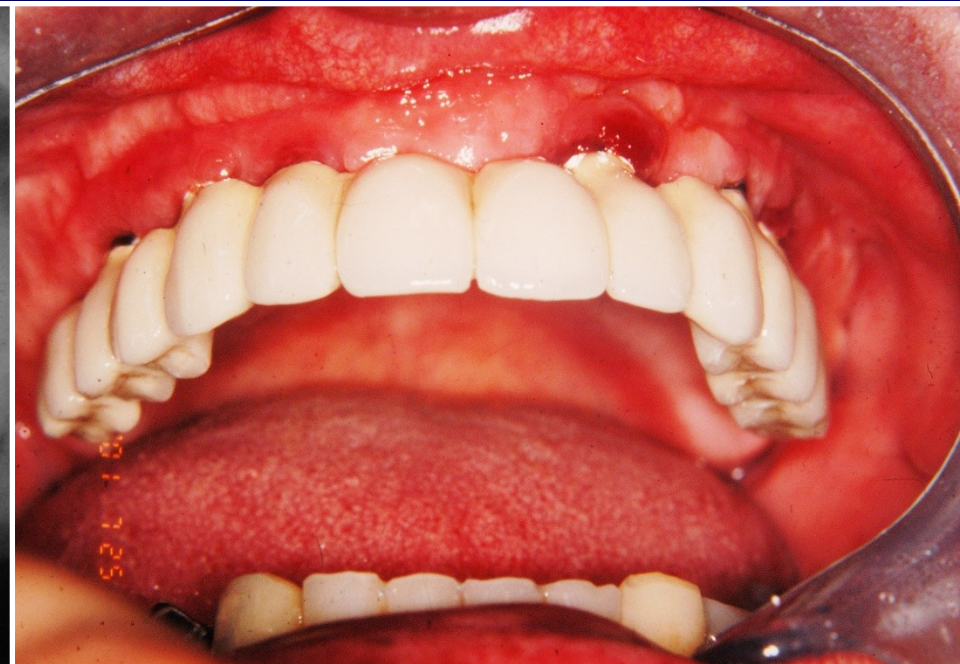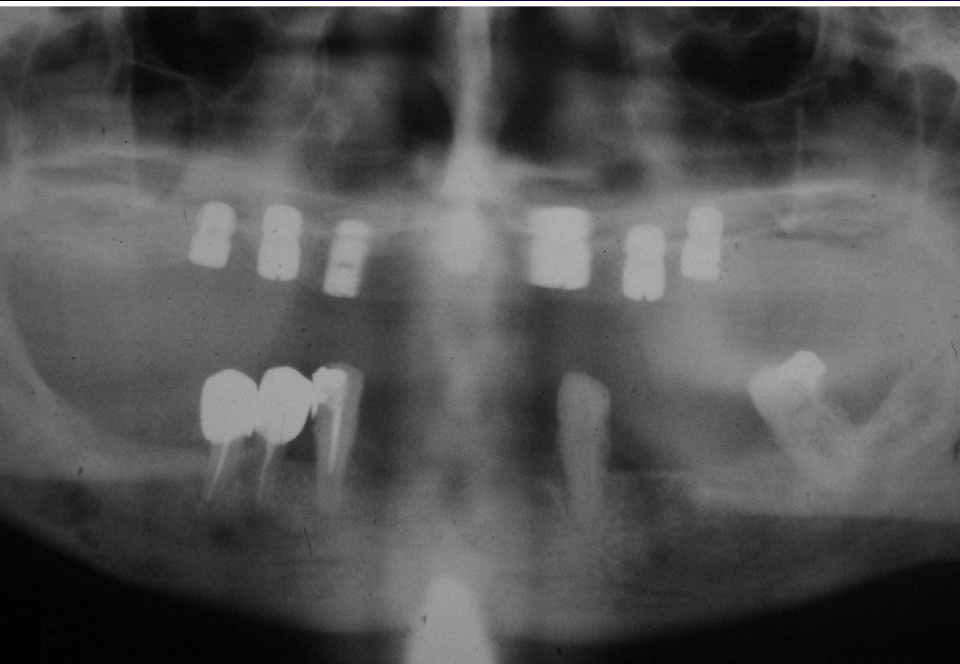
Timplant



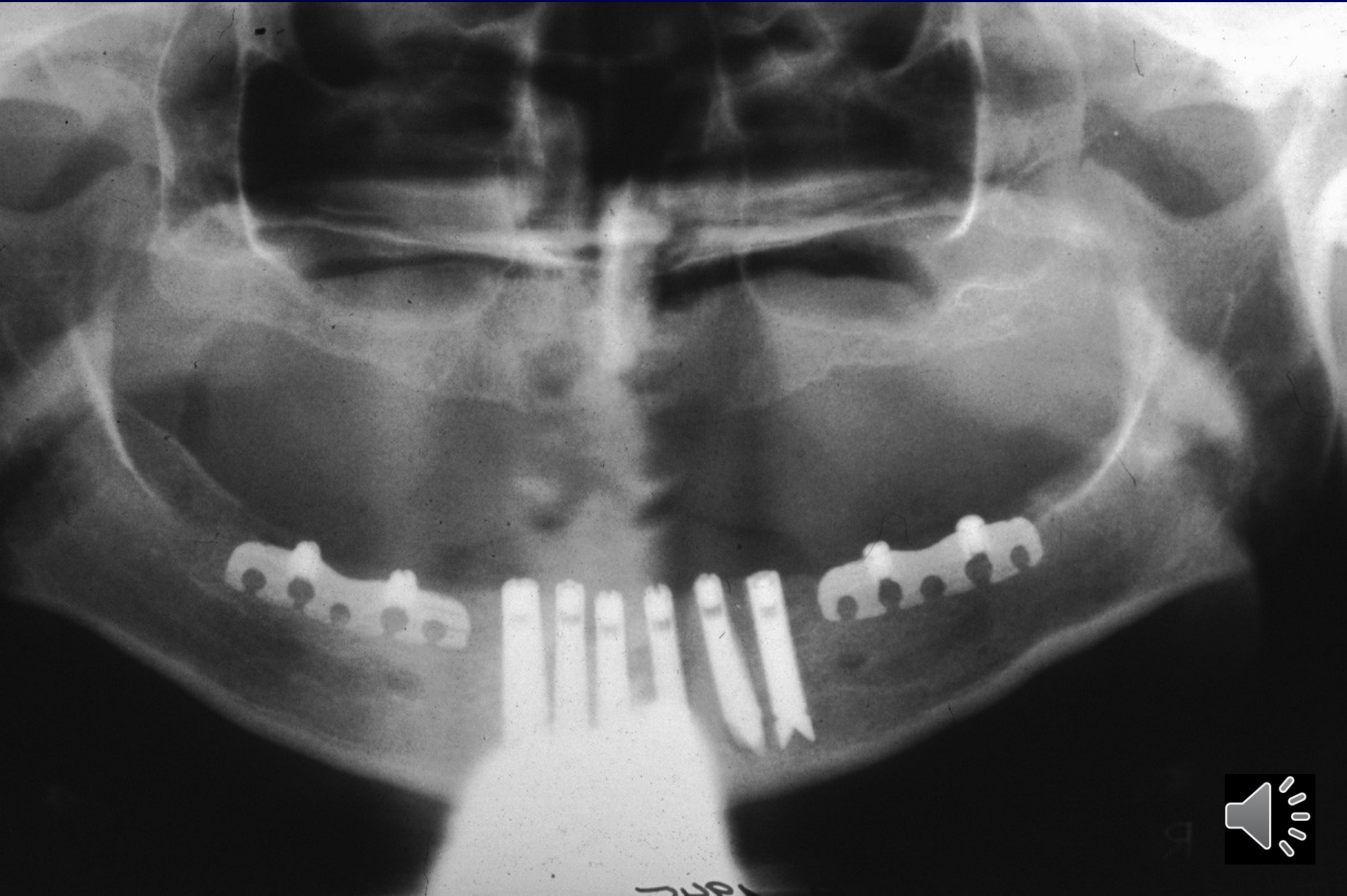
Implants



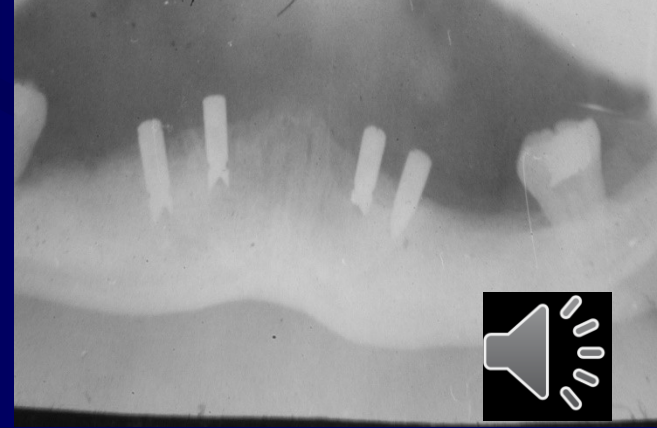
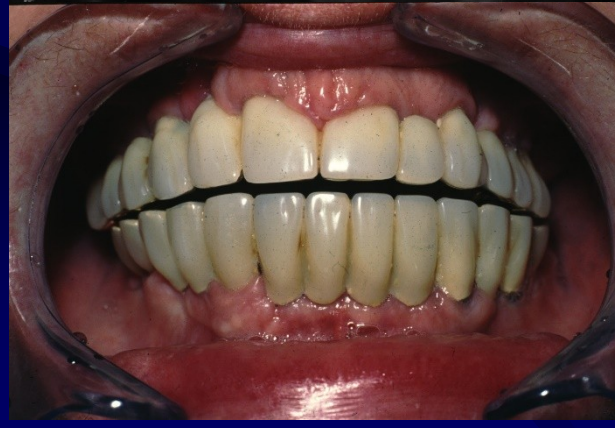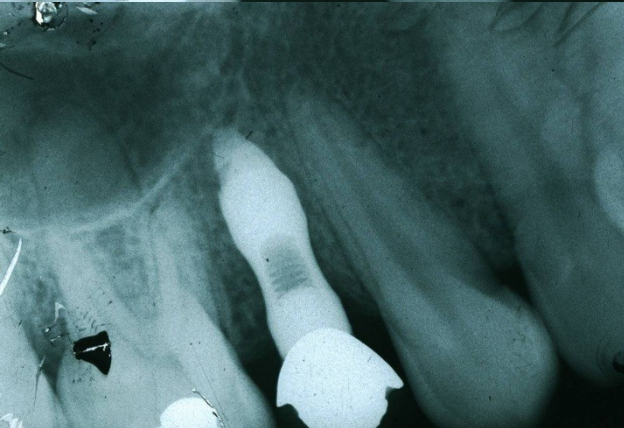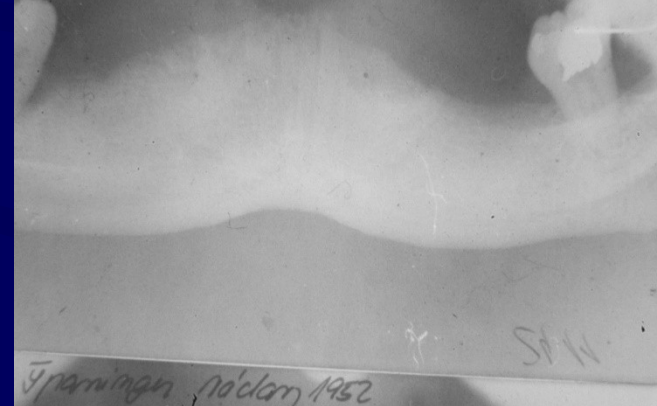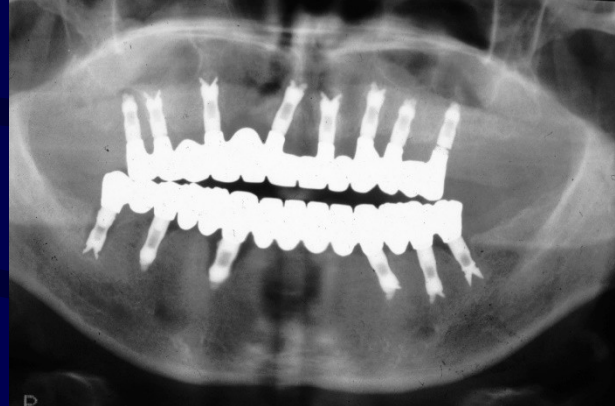
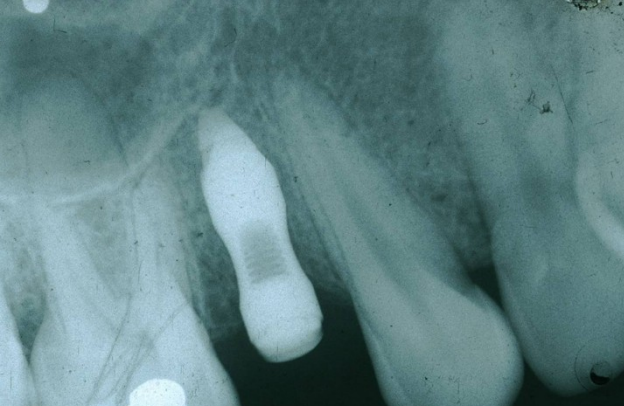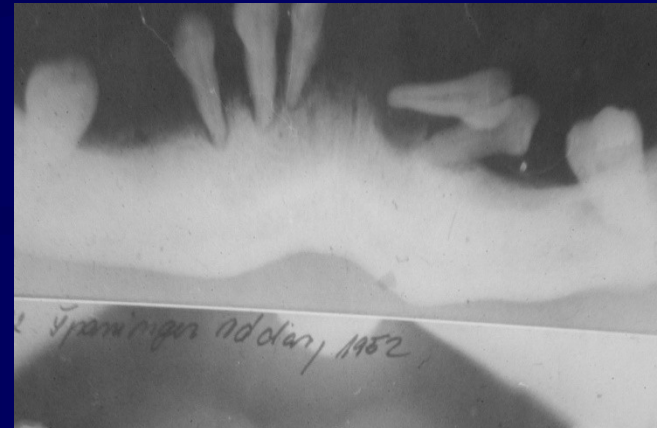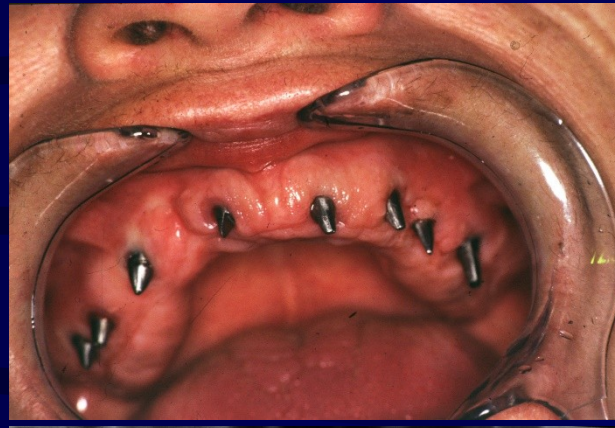
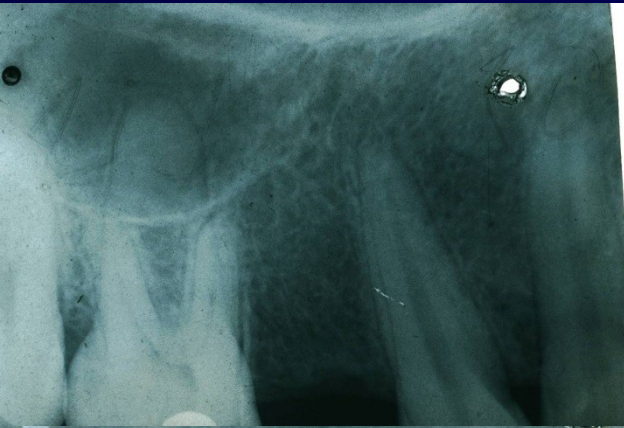
VNI implants



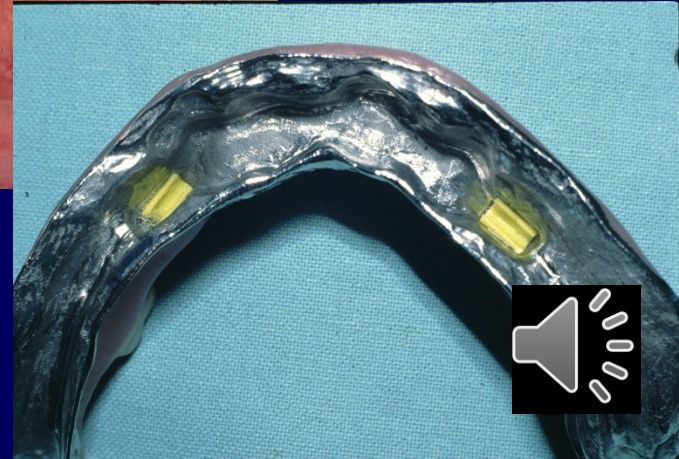
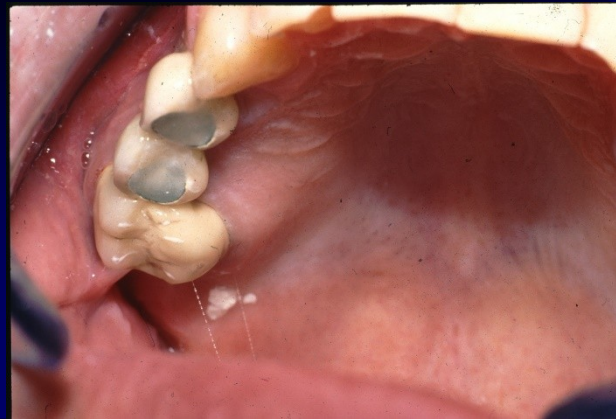
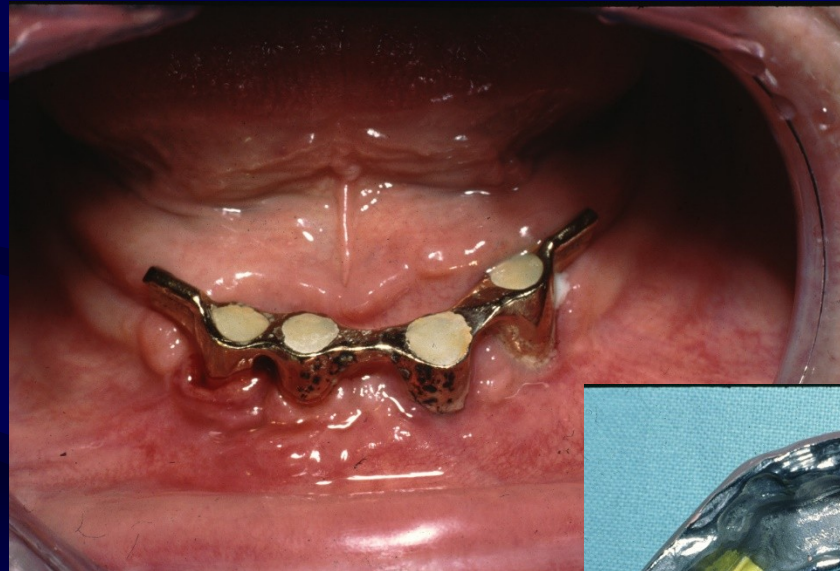
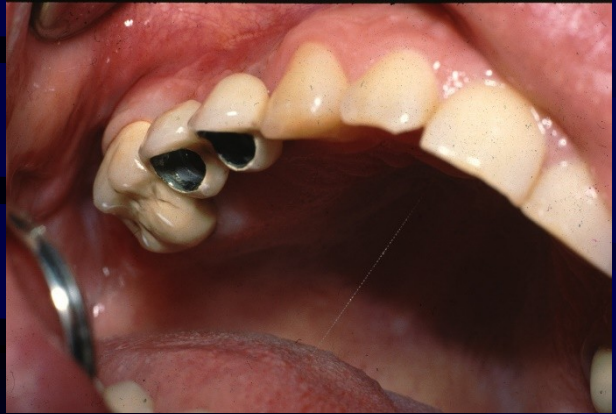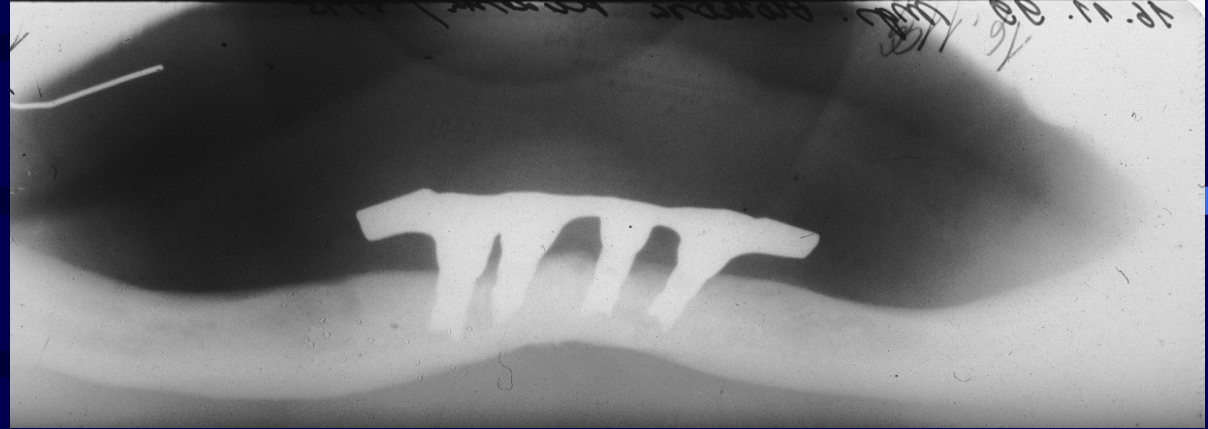
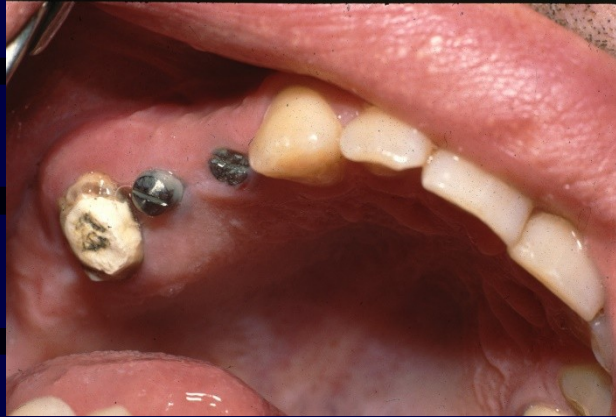Blade implants and cylindric implants

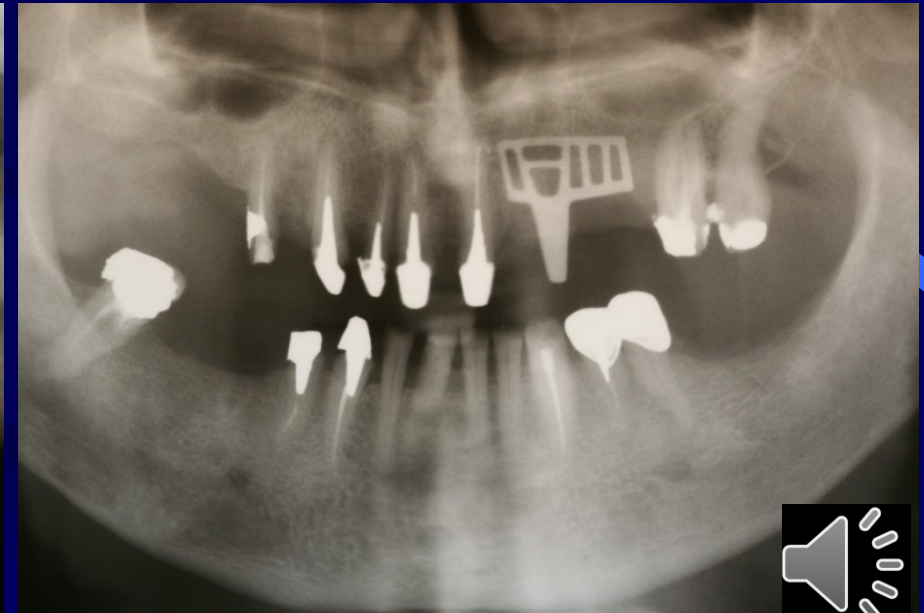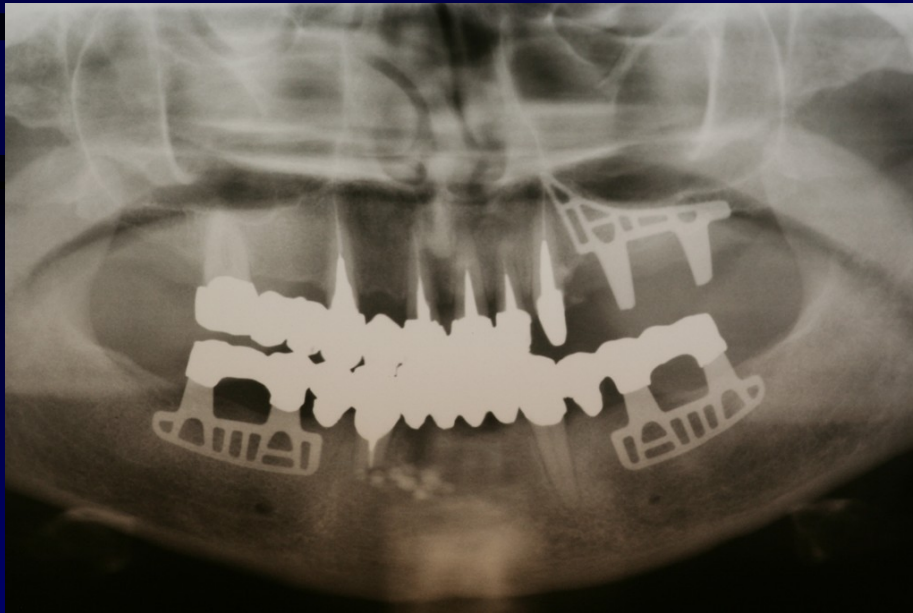
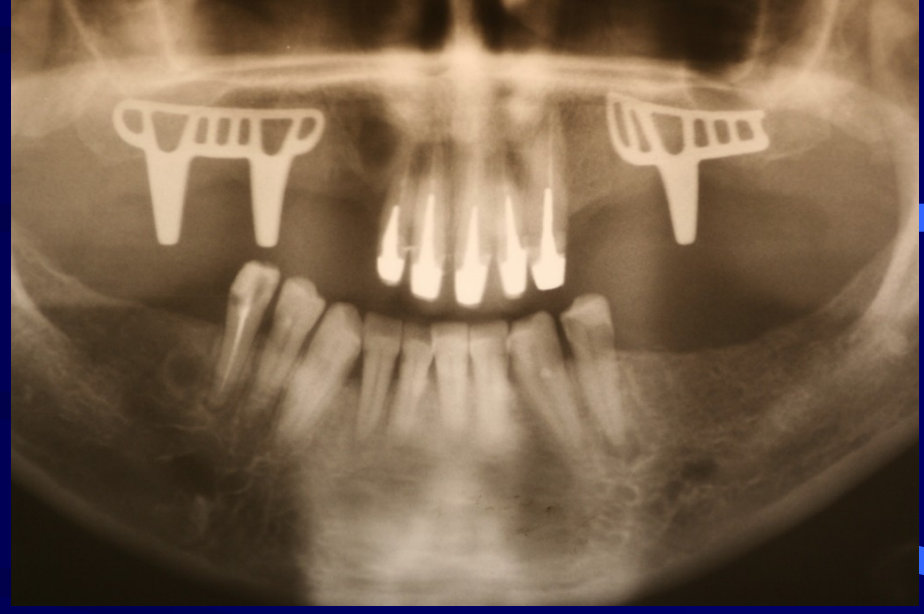

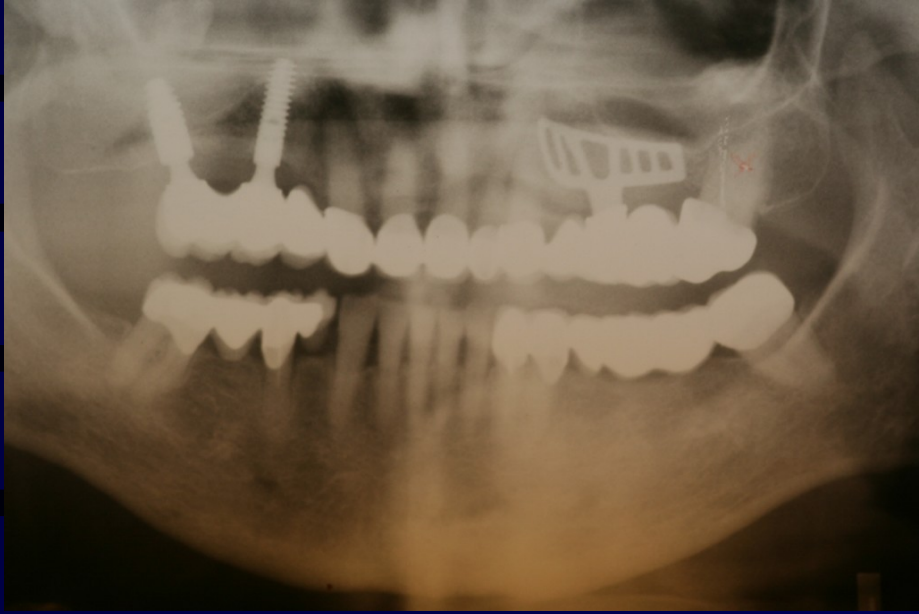
Brno's implantology— clinical applications VNI

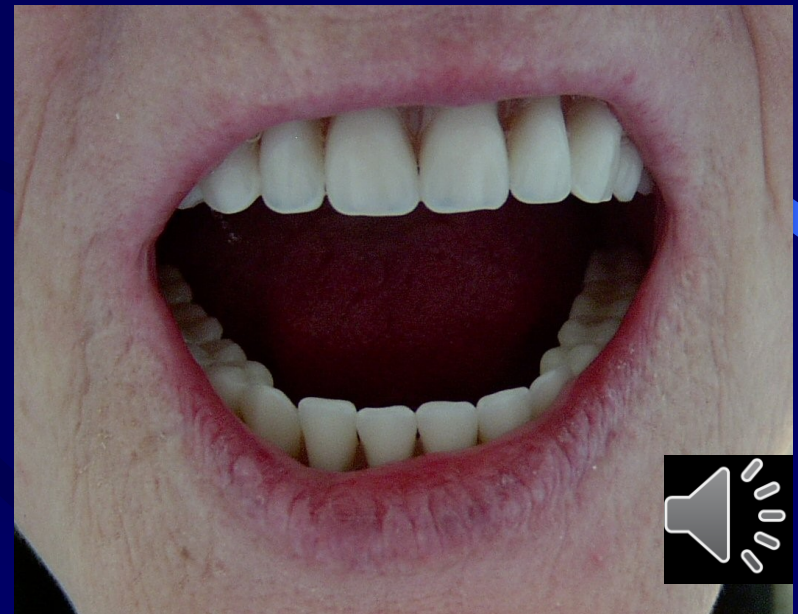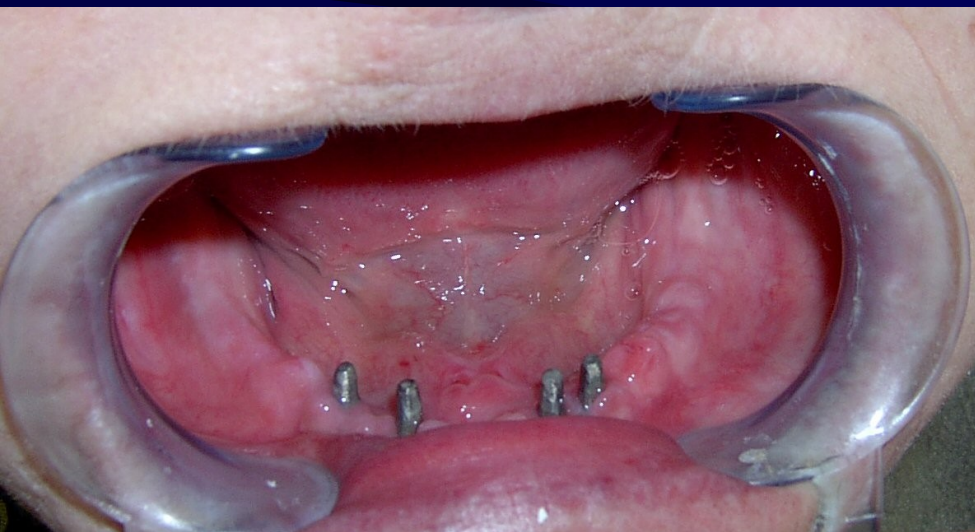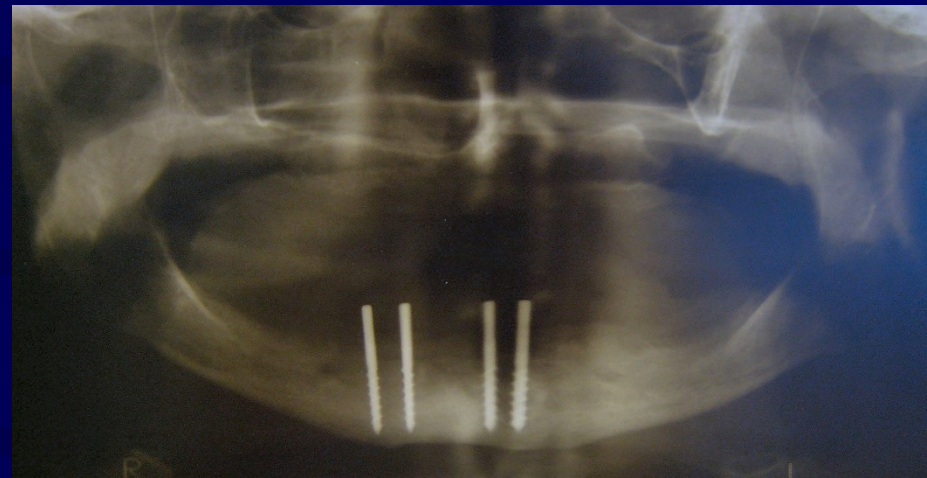
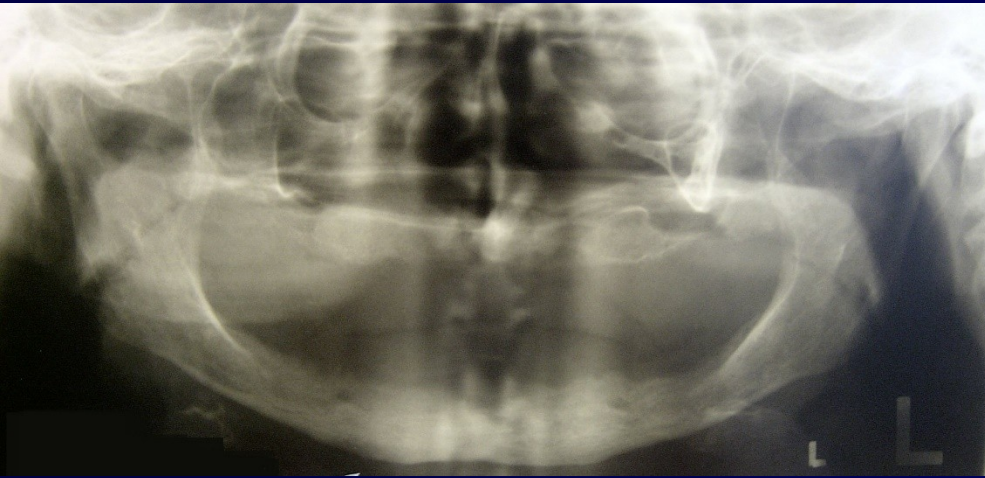


Brno's implantology – clinical applications VNI

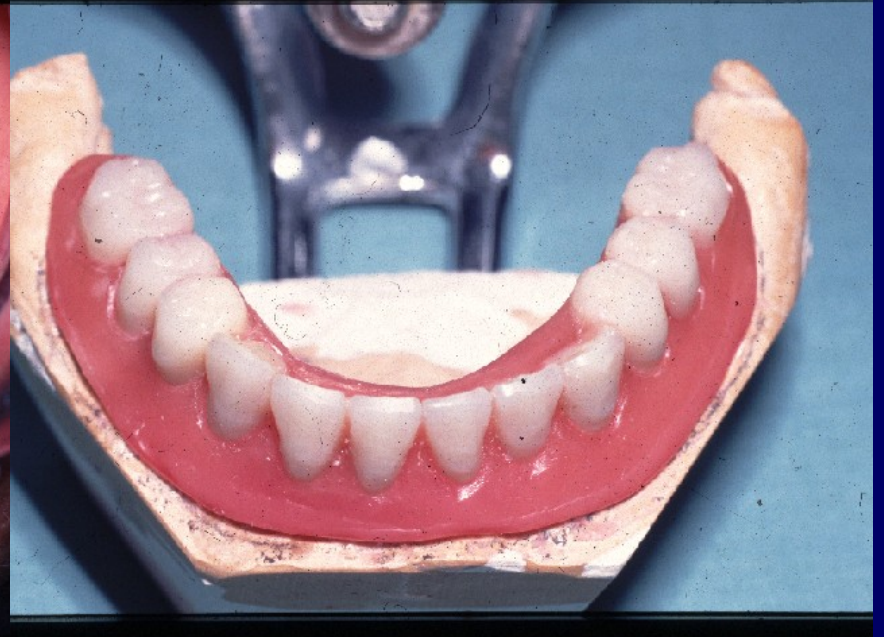
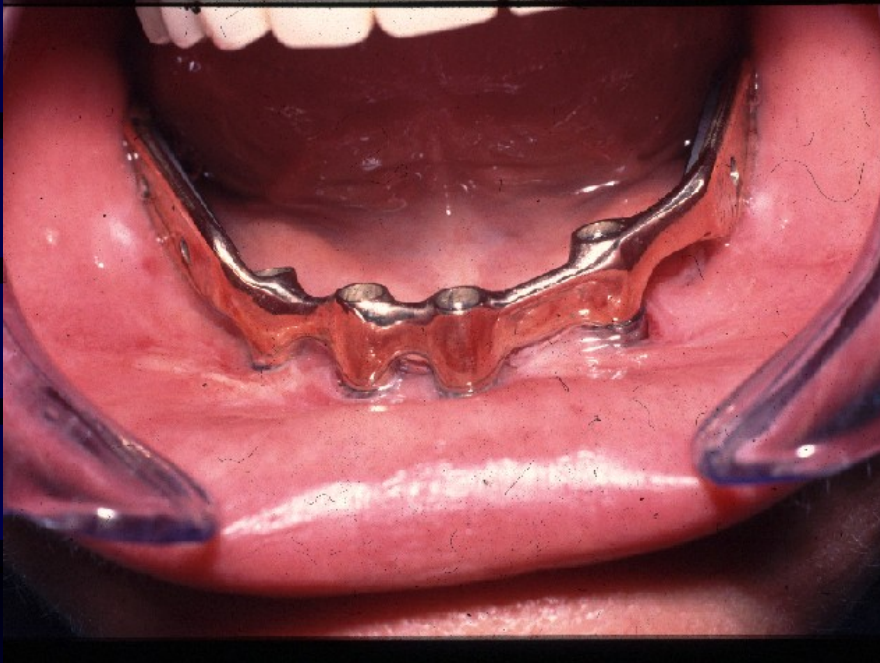


Bicorticals implants



Bar for hybrid prosthesis



- Thank you

Hilary Duff's New Teeth

Adams GREAT TASTE!
Chiclets
Peppermint Teeth
12 Teeth

Before

FreakingNews.com

