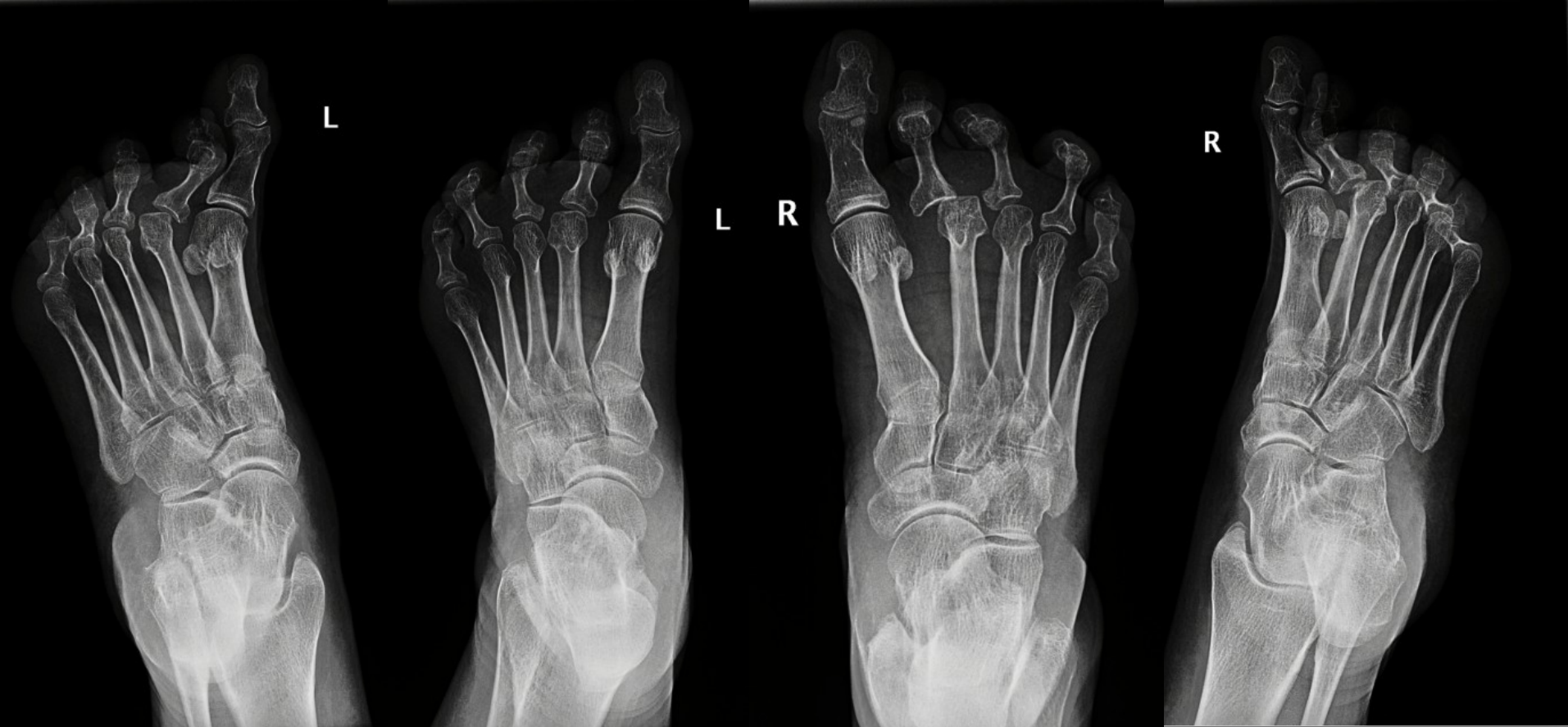



Transverse flatfoot – examination and therapy

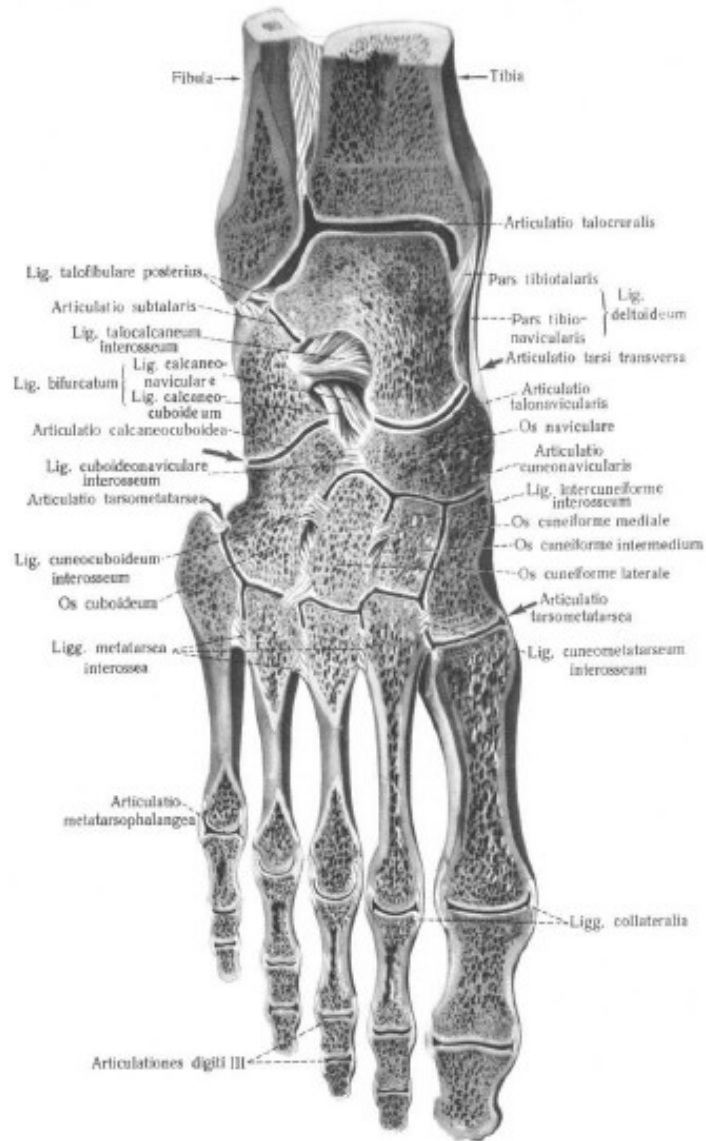
R. Zítka, M. Maršálek
FN Brno ORTK 22. října 2014

Metatarsalgia

- **Metatarsalgias** are **forefoot pains** localized distally from Lisfrank's joint
- **The clinical manifestation** is the transverse extension of the forefoot – transversely flat foot
- **This static deformity** is defined by divergence of marginal MTT, big toe valgosity, MTT varosity

followed by **I. MTT and V. MTT insufficiency** and **overload of II. -IV. MTT**

- "The leg is an work of art composed of 26 bones, 107 ligaments and 19 muscles" - once written by Leonardo da Vinci.
- The arch of the foot has **three components** on which it depends – **the bone component** consisting of the bones of the foot, their shape, the connective component formed by the **ligmentous apparatus** and the **muscular component**, the role of which is especially in the dynamic load of the foot



Art. talocruralis

Art. talocalcanearis

Art. Choparti

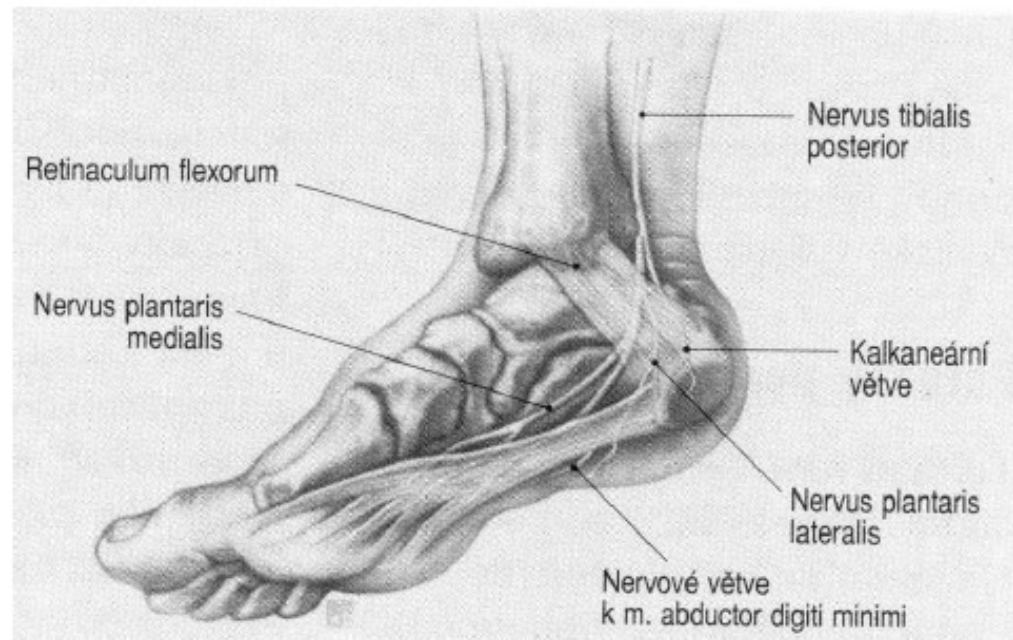
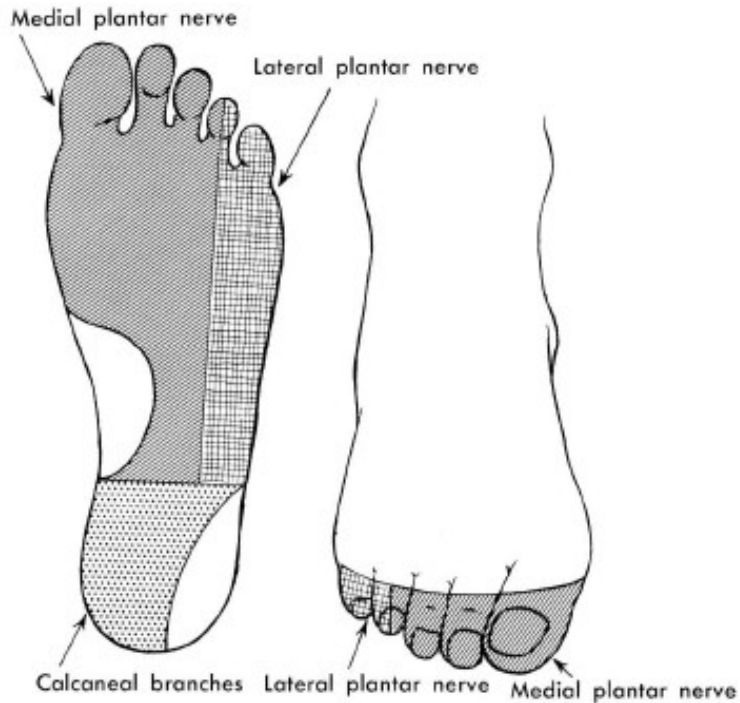
Art. Lisfranci

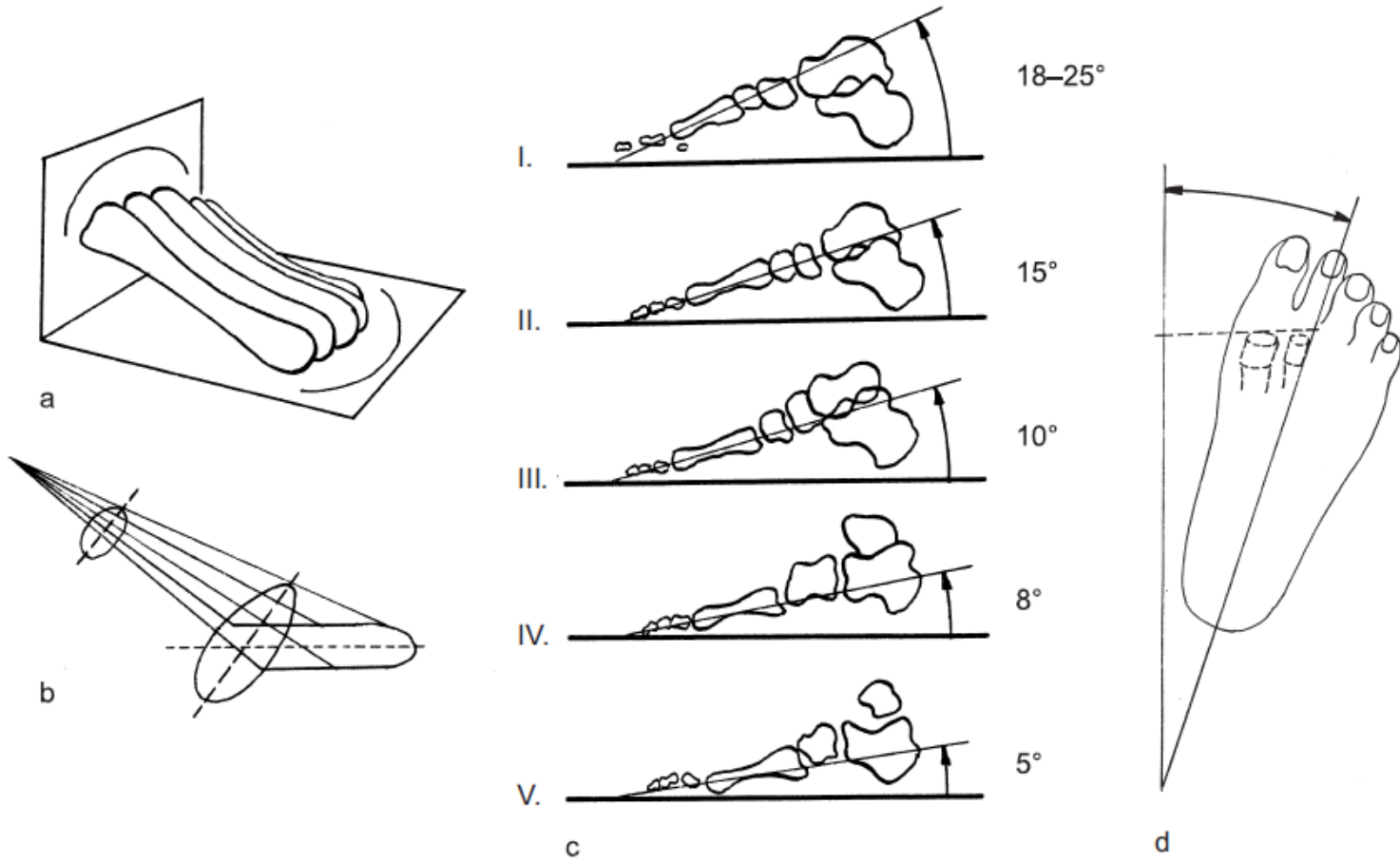
Art. metatarsophalangealis

Art. IP proximalis

Art. IP distalis

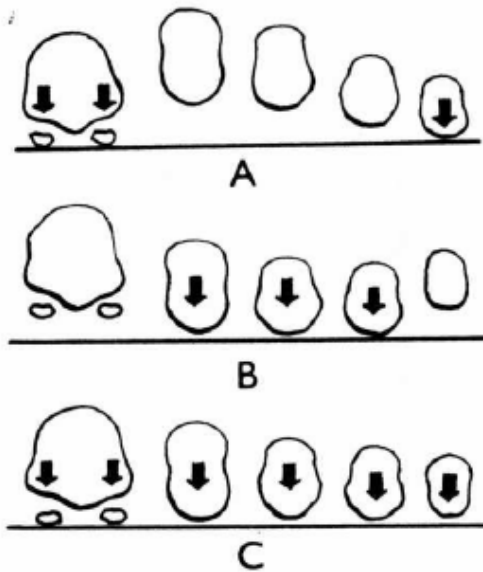
Inervation of the foot





Lake (1952) describes metatarses as a conical segment, slightly stretched by the anteposterior direction, the individual heads touch the ground in the arc, with the convex shape forward

Transverse Arch



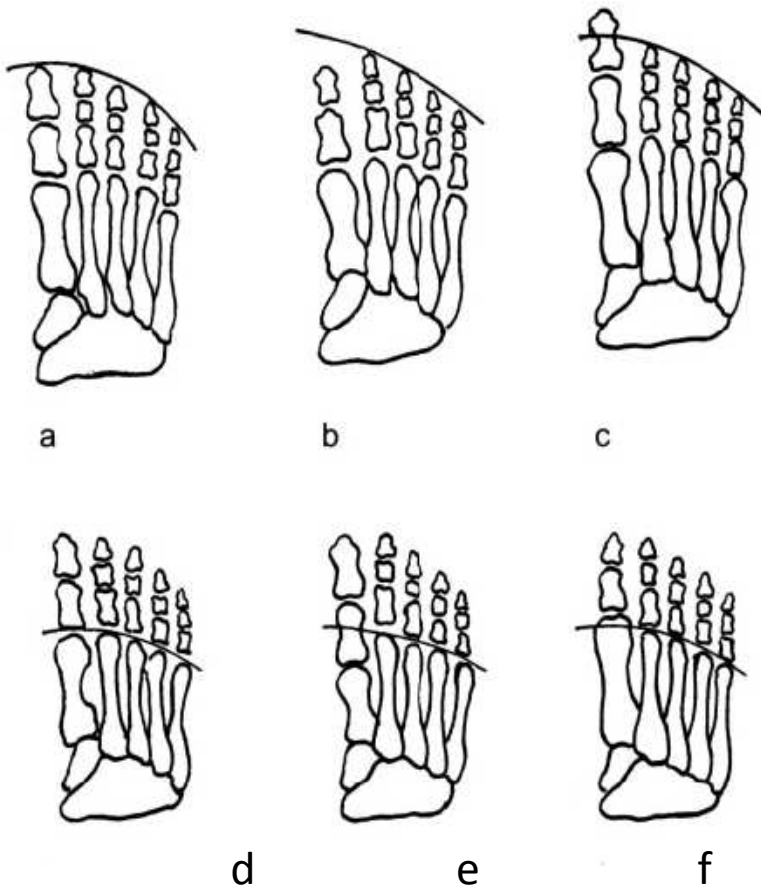
V úrovni 1 . a 5. metatarzu

V úrovni hlaviček 2.-4. metatarzu

Normální stav- všechny hlavičky
spočívají na podložce

Viladot 1975

Formule nohy



a kvadratická

b řecký typ

c egyptský typ

d plus minus index 28%

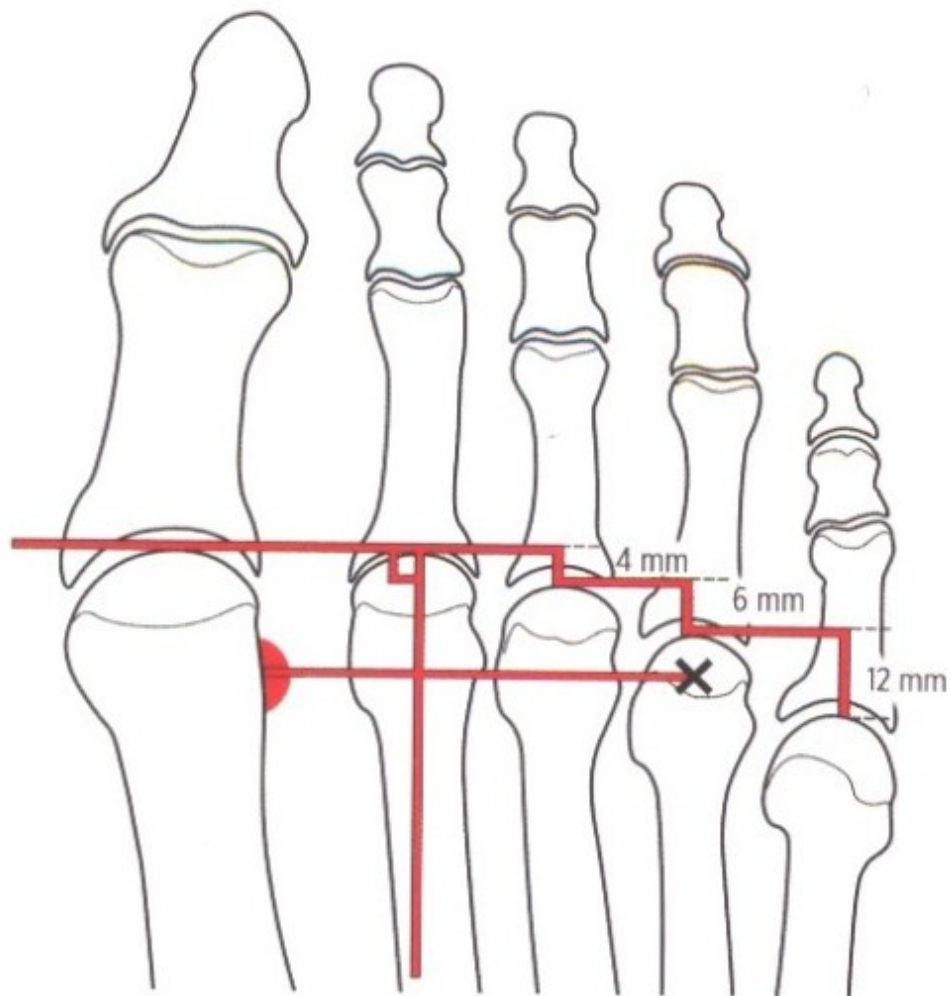
e index minus 56%

f index plus 16%

Metatarsalgia

Viladot - **overload of the front of the leg**

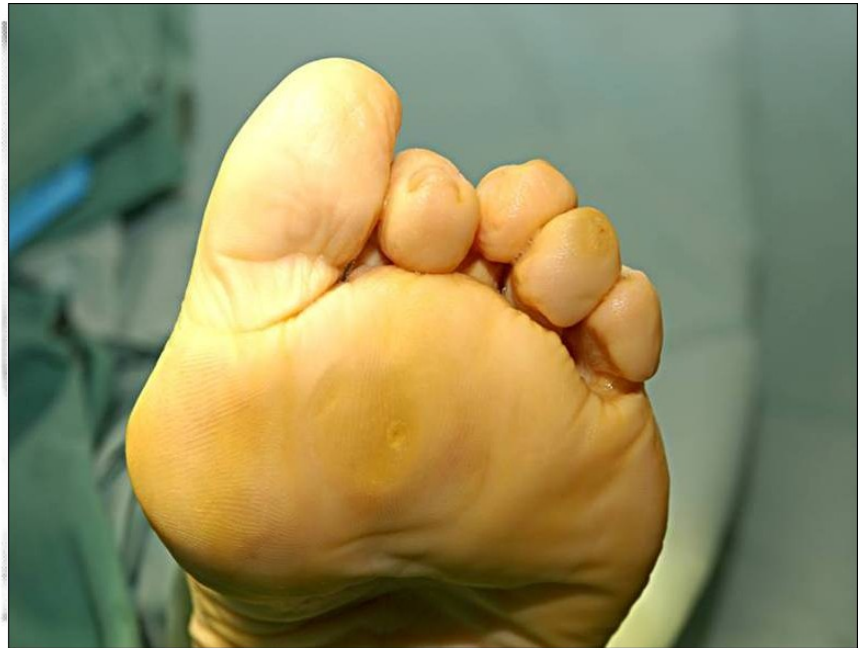- Women **with high heels**, pes cavus, pes equinus
- Involvement of MTT itself, there is a **change in pressure** under load on the foot
- Short I.MTT, hypermobility of I.MTT, after osteotomies (first ray insufficiency syndrome)
- Long I.MTT (first ray overload syndrome)
- Neurological and congenital impairment (central ray overload syndrome)
- Long metatarses (central ray overload syndrome)



Obr. 7.3.4 Maestro linie – schéma zachování plynulého oblouku hlaviček metatarzů. Při zachování správného tvaru oblouku nehrozí přenesená metatarzalgie po operaci.

Pes transversoplanus

Snížení příčné klenby
Konvexní oblouk plantárně
Prominence hlaviček MTT
Bolestivé kalozity
Kladívkové deformity prstů
Symptomy:
Bolestivé přednoží



Possible causes

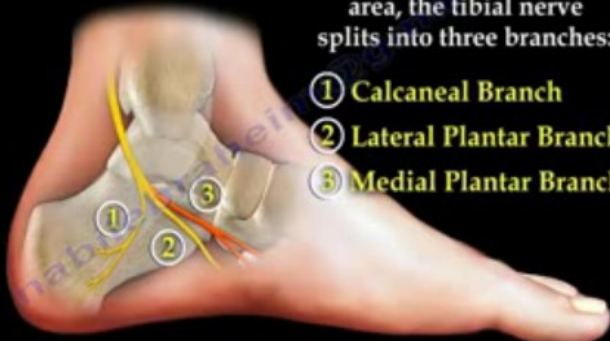- Fractures from overload (no. II and III MTT)
- Congenital short/long MTT, MTT hypoplasia
- Freiberg - Köhler disease (Kölher II)
- Morton neuralgia, tarsal tunnel syndrome
- Plantar fibromatosa
- Post-stress state, scars, contractures (peroneal, m. triceps surae)
- Tumors
- Systemic diseases – RA, collagenosis, psoriasis, on. blood vessels, DM
- Spinal root affectation during intervertebral disc protrusion
- Nerve diseases – DMO, paresis, myopathy
- Diseases of the connective system - Marfan's sy, Ehler-Danlos sy, Down sy.
- Iatrogeny – after surgery at I. MTT (shortening),

Morton's Neuroma

ANATOMY

Around the tarsal tunnel area, the tibial nerve splits into three branches:

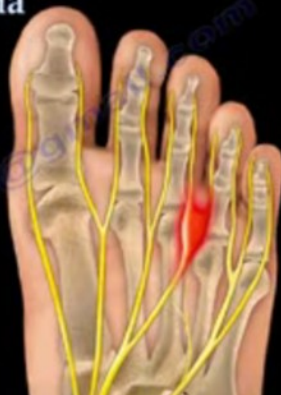- ① Calcaneal Branch
- ② Lateral Plantar Branch
- ③ Medial Plantar Branch



Morton's Neuroma

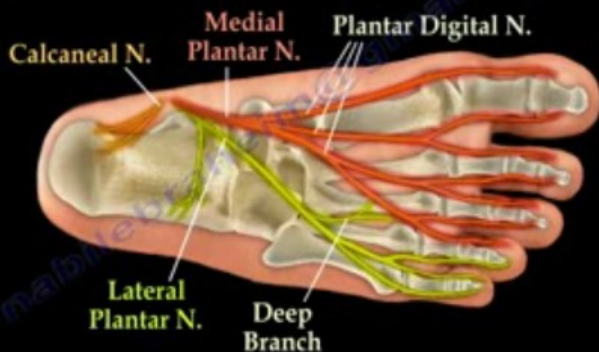
The neuroma is an enlargement and inflammation of a portion of the nerve.

Usually located in the third webspace between the metatarsal heads.



Morton's Neuroma

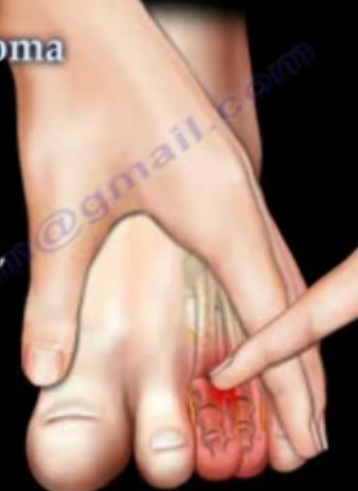At the bottom of the foot, the medial and lateral plantar nerves give rise to the digital nerves.



Morton's Neuroma

How do you test for Morton's Neuroma?

- applying pressure will cause pain, paresthesia, and tingling.
- a possible click and radiating pain into the affected toes produces the "Mulder's Sign".



Mulder's Sign

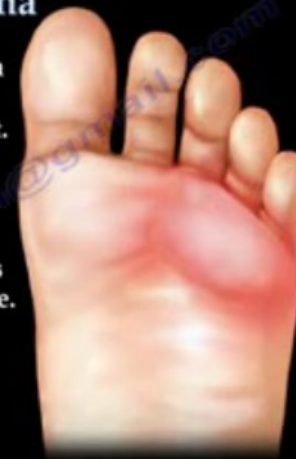Útlak III. digitálního nervu předním okrajem plantární fascie

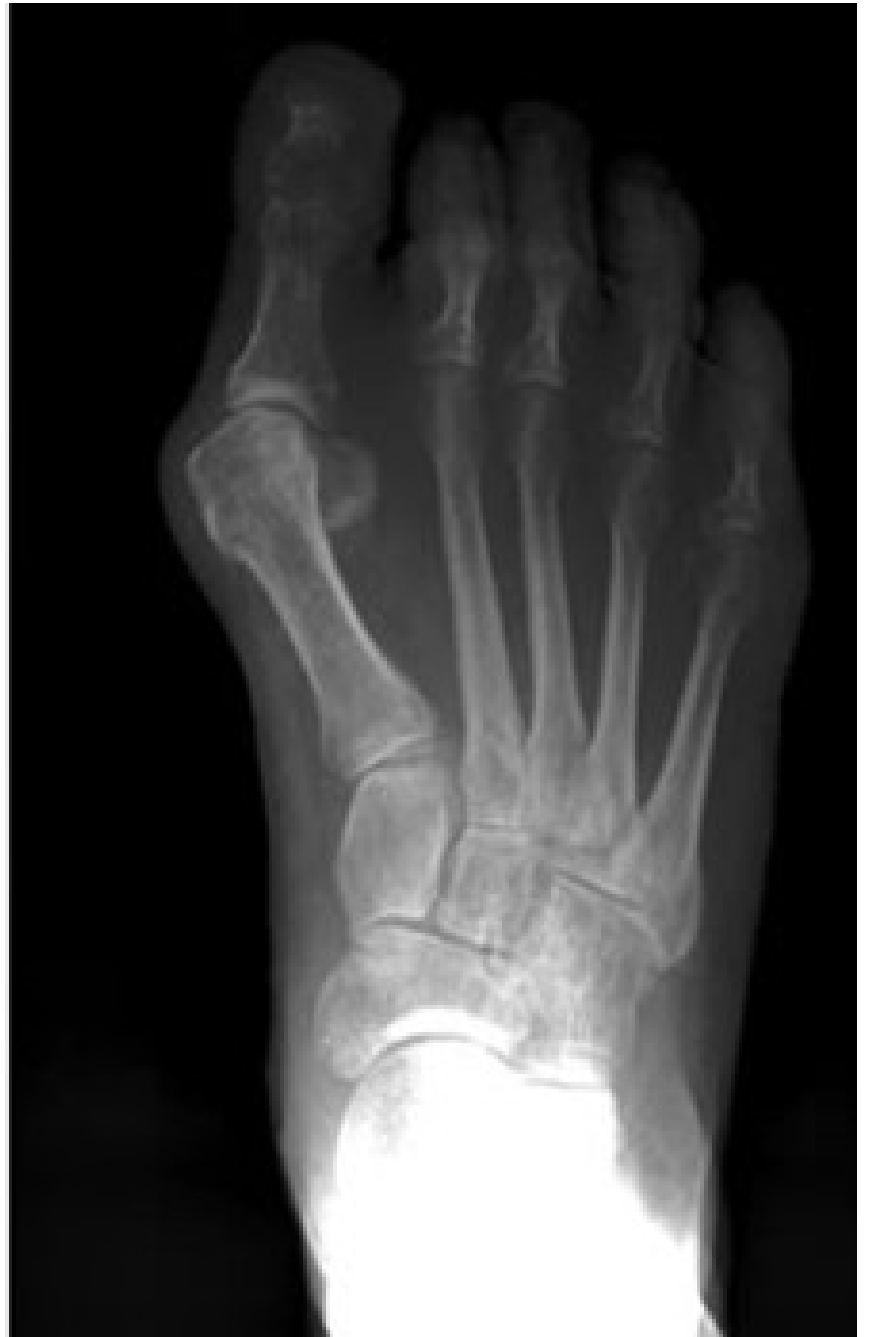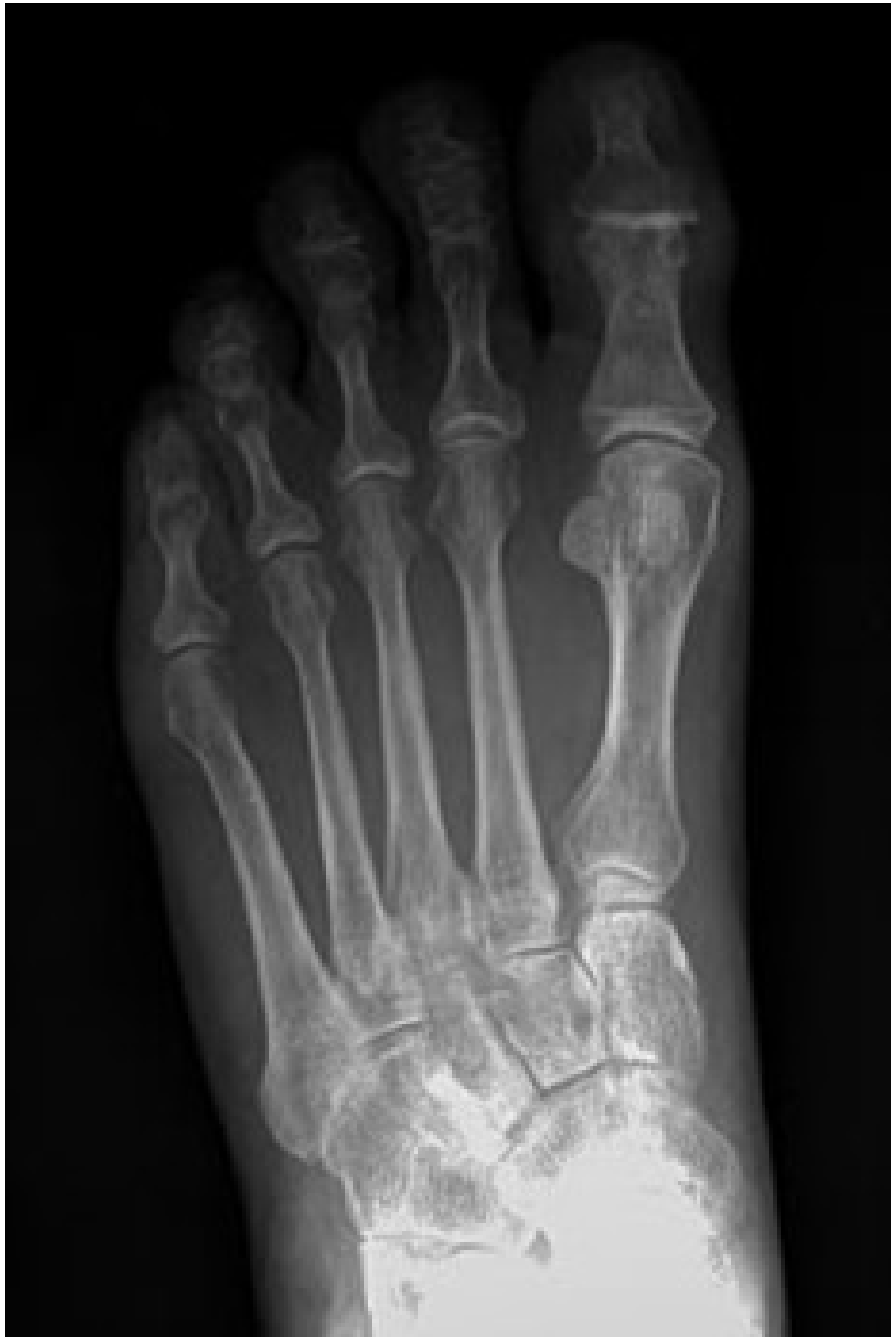Morton's Neuroma

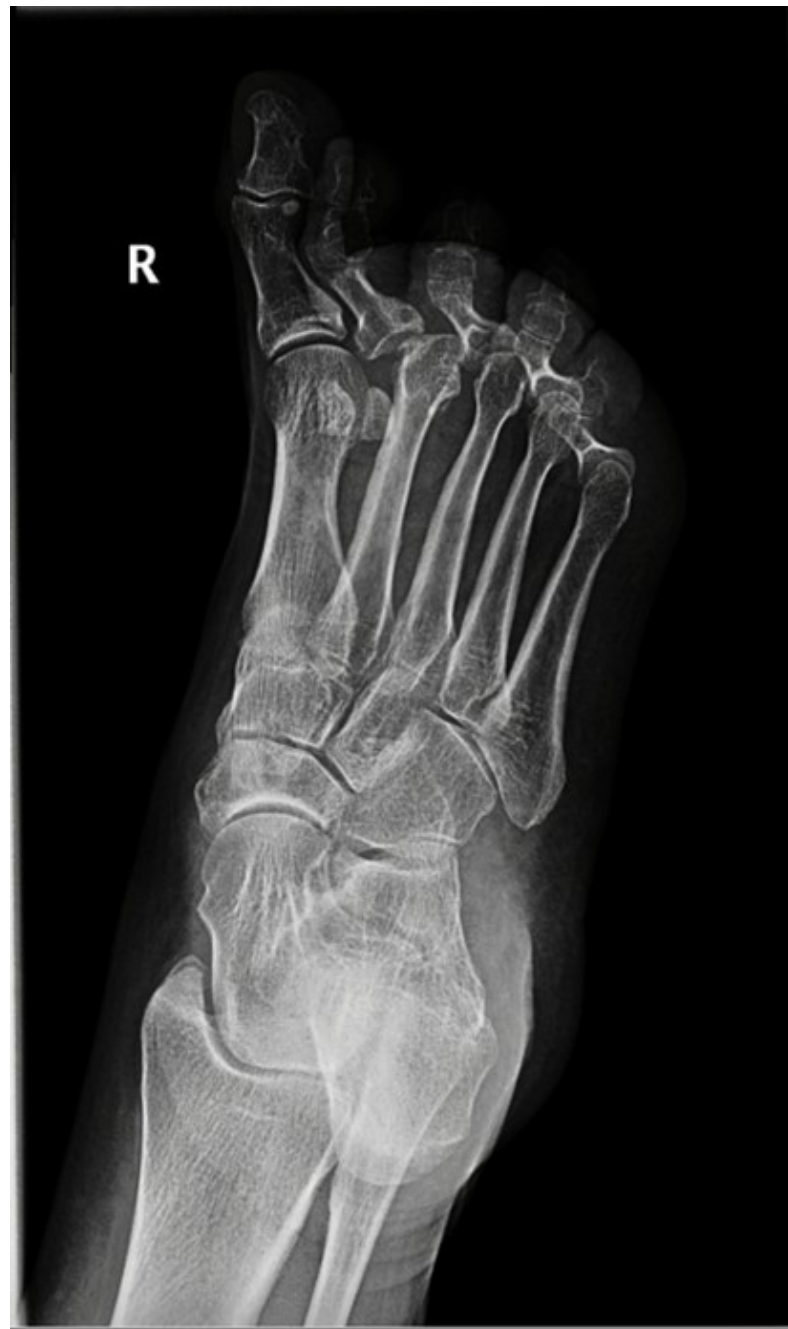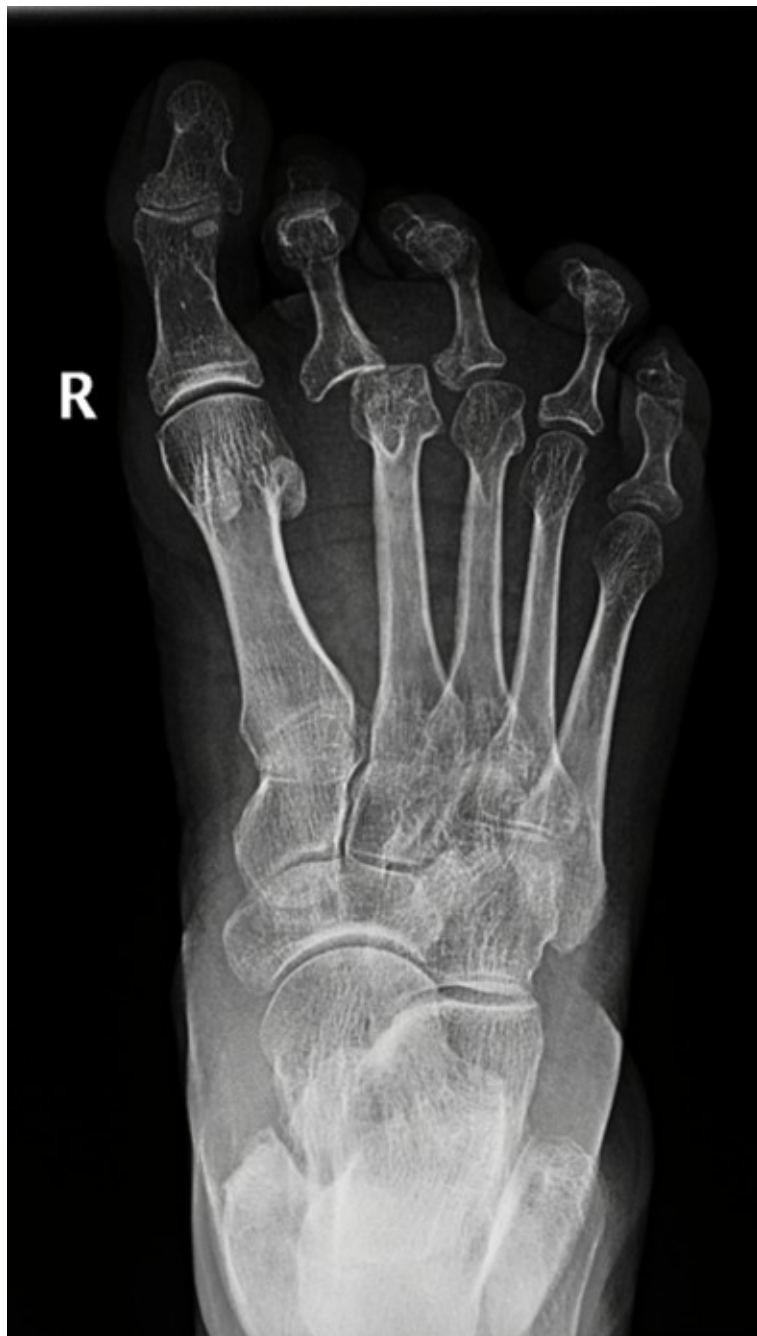Pain from Morton's neuroma is primarily located on the bottom of the ball of the foot.

The pain is made worse by walking, especially while wearing narrow shoes and is relieved by removing the shoe.

Numbness, paresthesia, and shooting pain towards the toes.

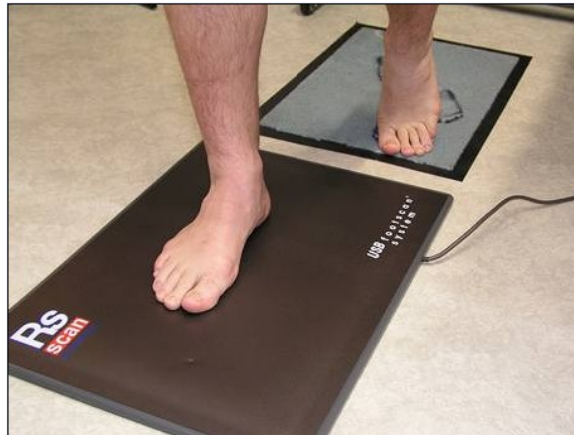
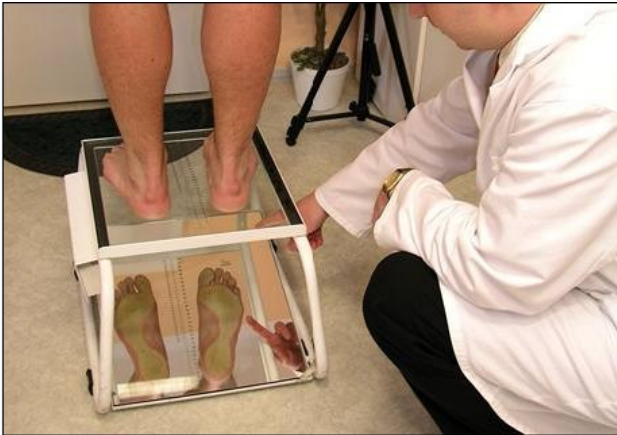




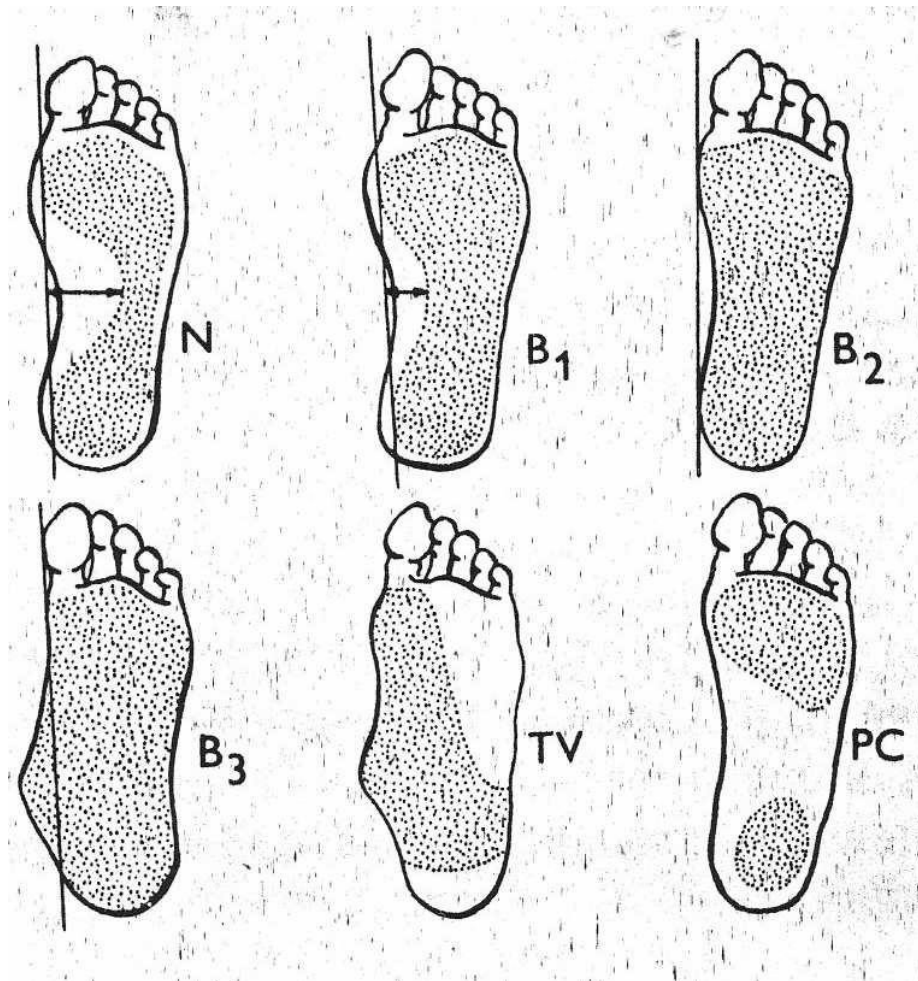
Examination

- Clinical, medical history
- X-ray legs AP image in the load, oblique, lateral projection in the load
- Podoscopy, pedogram

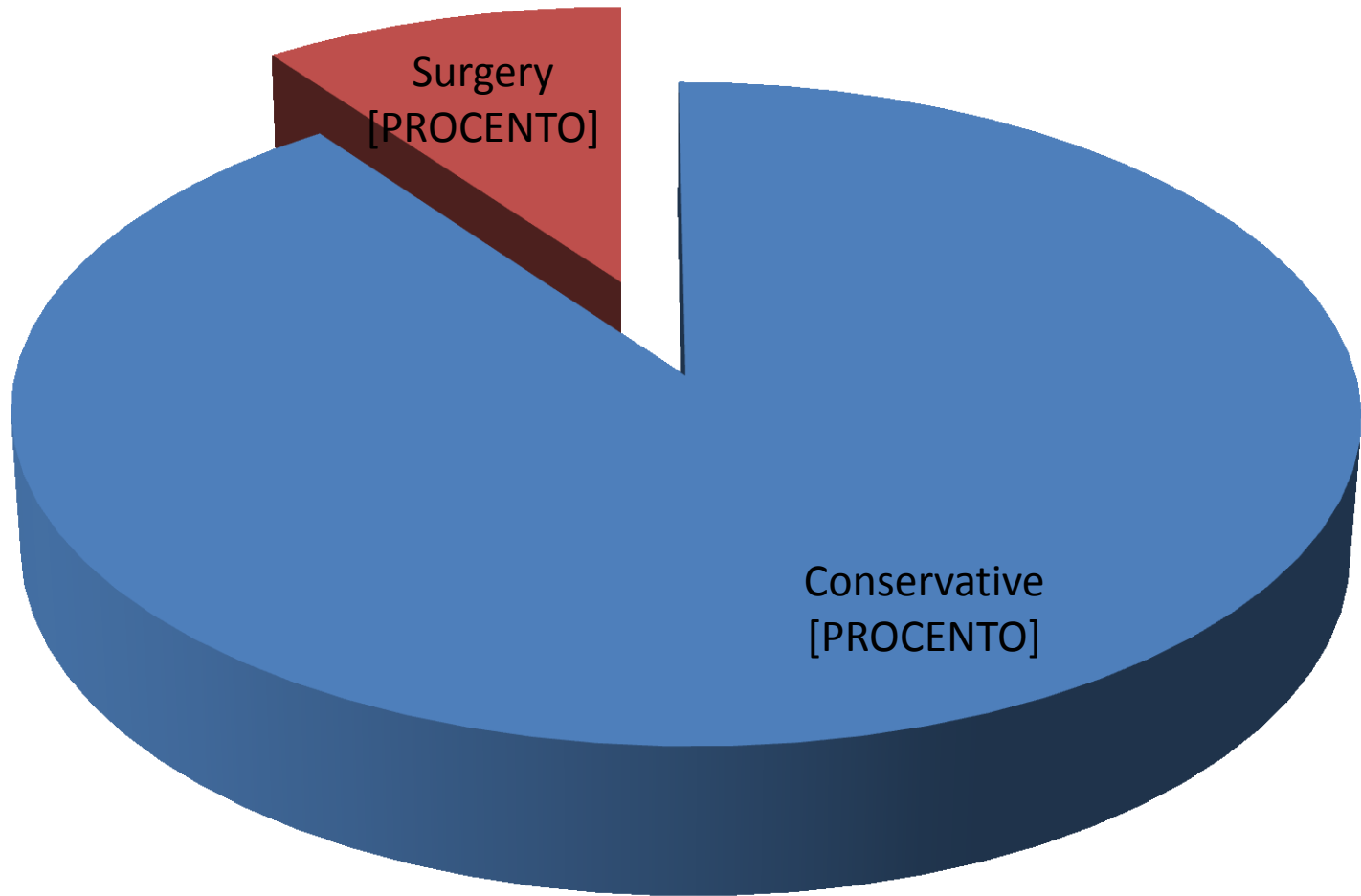


- Podoscopy, pedogram

Classification B1, B2, B3



Therapy of the flat foot



Conservative therapy

- **Wearing high-quality footwear** with longitudinal vault support and heel guide (fixed heel)
- **Load reduction, weight reduction**
- Treatment of varicose veins, compensation of DM
- Stimulation and facilitation of the face in everyday life – walking barefoot in soft uneven terrain (grass, sand)

Conservative therapy

- Passive support – **orthopaedic inserts** according to functional examination, individually manufactured shoes according to the podoscopy
- **retrocapital pelota** (hearts), increase of the outer edge of the insert, which ensures proper conduction of the wall heel.
- Corticosteroid injection
- Active therapy – physiotherapy

Rehabilitation / physiotherapy

- **The basis of physiotherapy** is sensomotor exercises
- foot facilitation
- training of pressure distribution on the foot, training of support of three points, small legs in the centered position of the joints of the lower limb
- soft tissue techniques are used, mobilization of the joints of the foot is carried out
- relaxation and stretching in hypertone and in shortening

Rehabilitation / physiotherapy

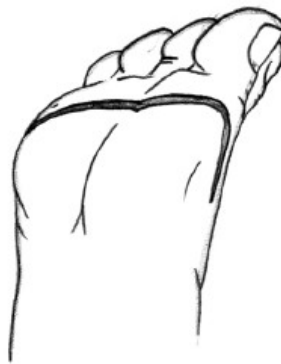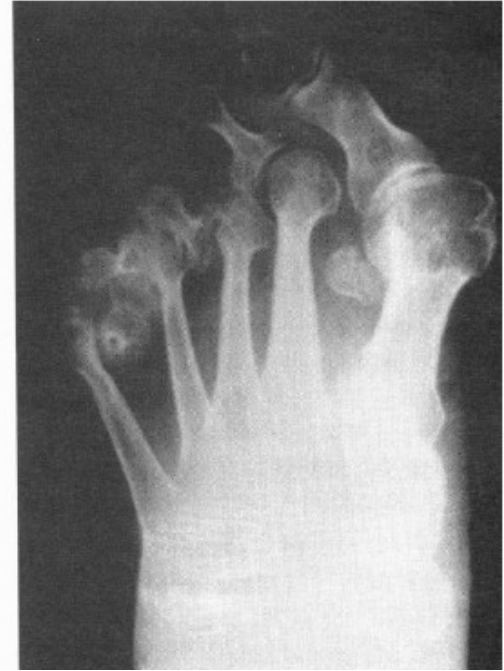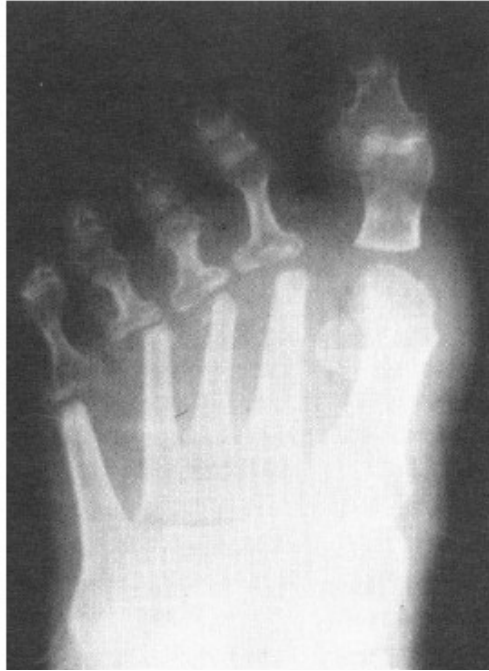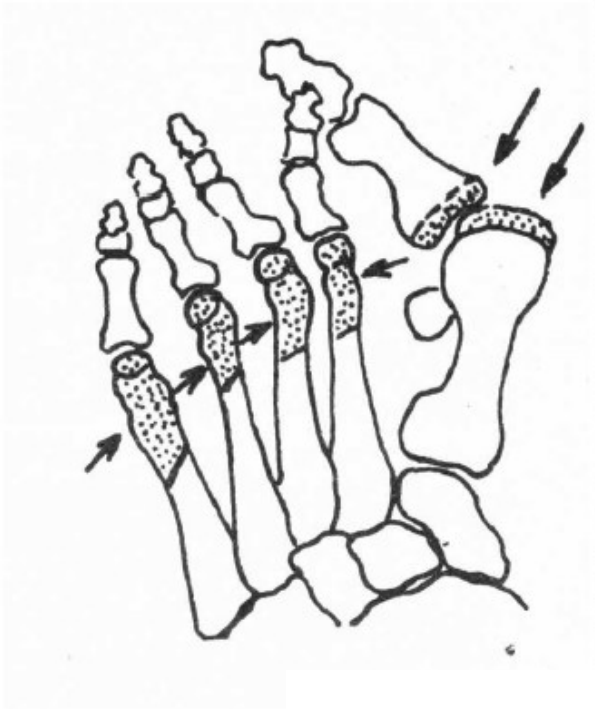- **From physical therapy:**
- antiedematous procedures – manual and instrumental lymphatic drainage
- water treatment – alternating and pedal baths, cold hot tubs are indicated
- For muscle relaxation we can use **ultrasound**, **electrotherapy** (diadynamic DD currents, TENS – transcutaneous electrical neurostimulation)

Surgical treatment

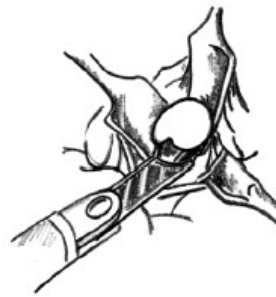
- Shortening osteotomy of metatarses
- Combination with hallux valgus operations
- Preoperative, free movement in MTP joints must be
- Hoffman 1912
- Mau 1940
- Giannestras 1945
- Wolf 1973
- Helal 1975
- Weil surgery 1985 - in the treatment of metatarsalgia is preferred in patients with restriction of movement, in subluxation and luxation in MTP joints
- BRT osteotomy 1991
- M. Vitek, V-TEK system 2009

Op. sec. Hoffmann

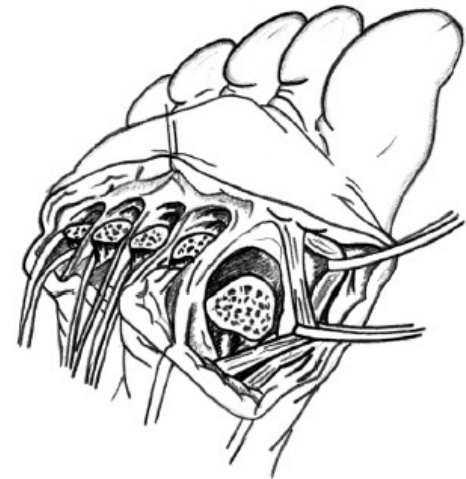
(1912)



a



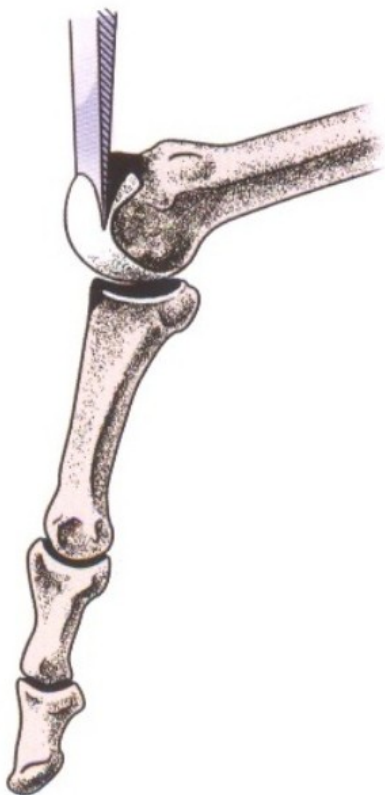
b



c

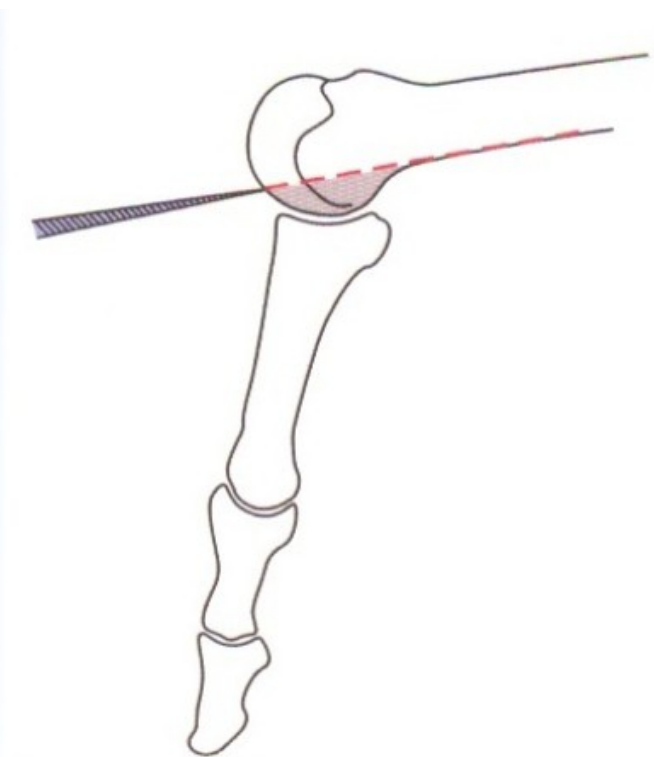
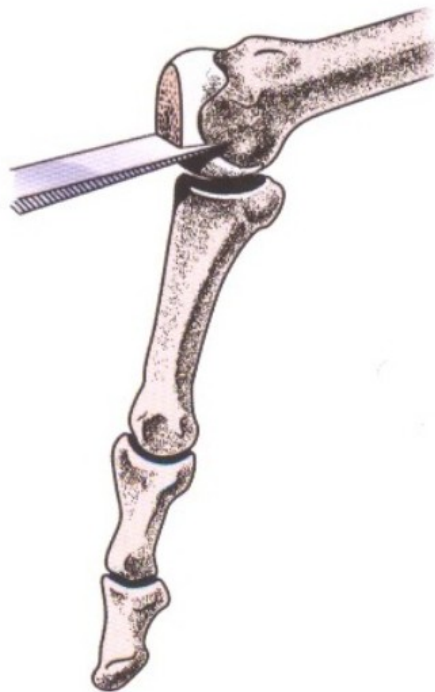
Table I. — Historical overview of approaches to forefoot reconstruction

AUTHOR	YEAR	CONTRIBUTION
Hoffman (25)	1912	Described pan-metatarsal head excision through a single plantar apex-distal incision just proximal to the interdigital web spaces, without extensor tenotomies. Argued that relaxation of the soft tissues by generous metatarsal resection obviated the need for soft tissue correction. The disadvantage of the distal plantar approach was injury to the neurovascular bundles.
Fowler (18)	1959	Described a combined dorsal and plantar approach. The dorsal incision included short longitudinal extensions along the 1 st and 5 th metatarsals. He advocated excision of the proximal halves of the phalanges, together with metatarsal head excisions. The plantar incision was used to excise the callus and perform a dermoplasty to relocate the fat pad beneath the metatarsal remnants.
Clayton (12)	1960	Suggested using a single straighter dorsal incision, with bony resection as described by Fowler, but with extensor tendon transections if required.
Kates <i>et al.</i> (28)	1967	Promoted a single curved plantar incision, excising an ellipse for further deformity correction. A pan-metatarsal head excision was performed, with the 1 st MTP joint stabilised with a Kirshner wire and a plaster boot applied with the lesser toes plantar flexed.
Lipscomb (29)	1968	Popularised three dorsal longitudinal incisions, with metatarsal head excisions. Originally suggested by Larmon (22) in 1951.



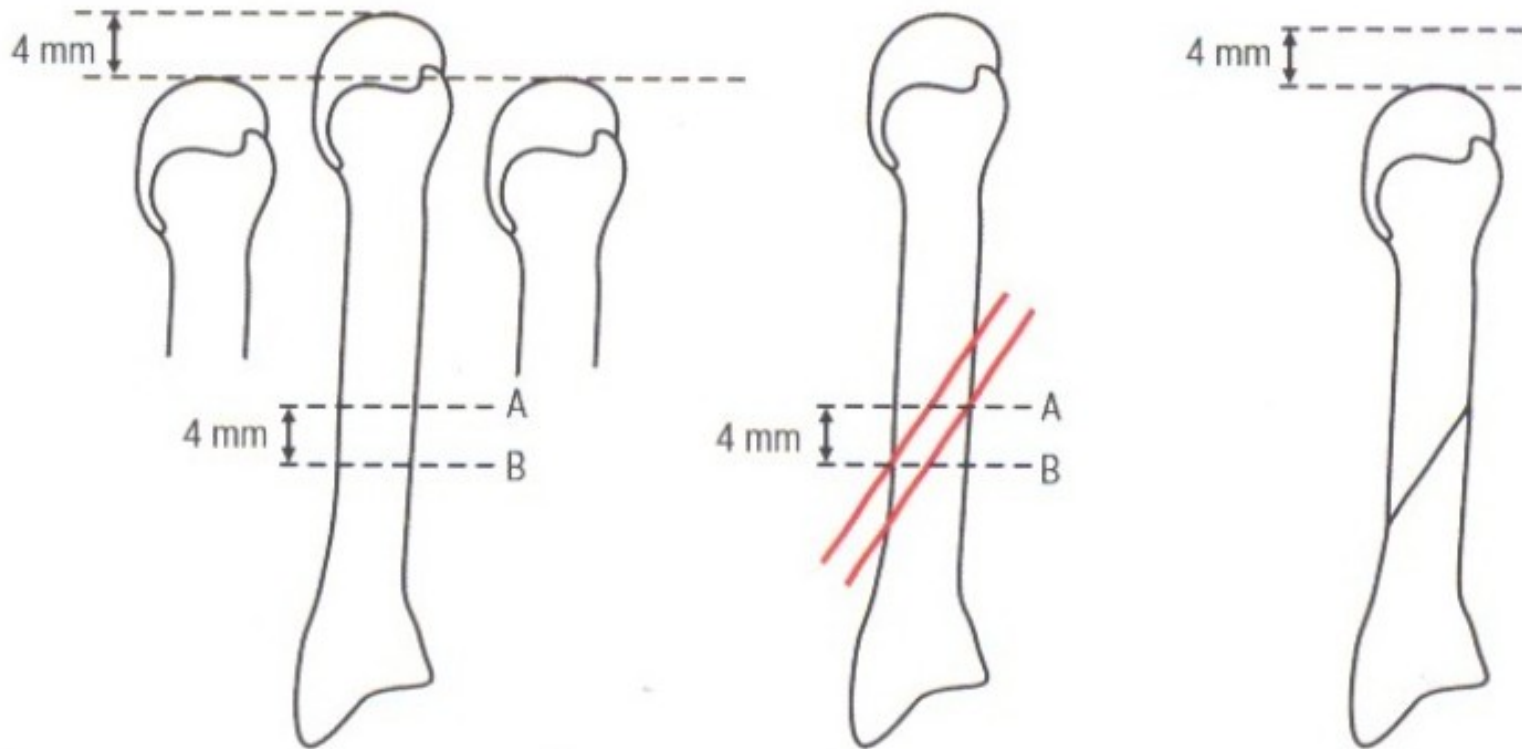
Obr. 7.3.1 Schéma operace podle DuVriese

Du Vries (1953)



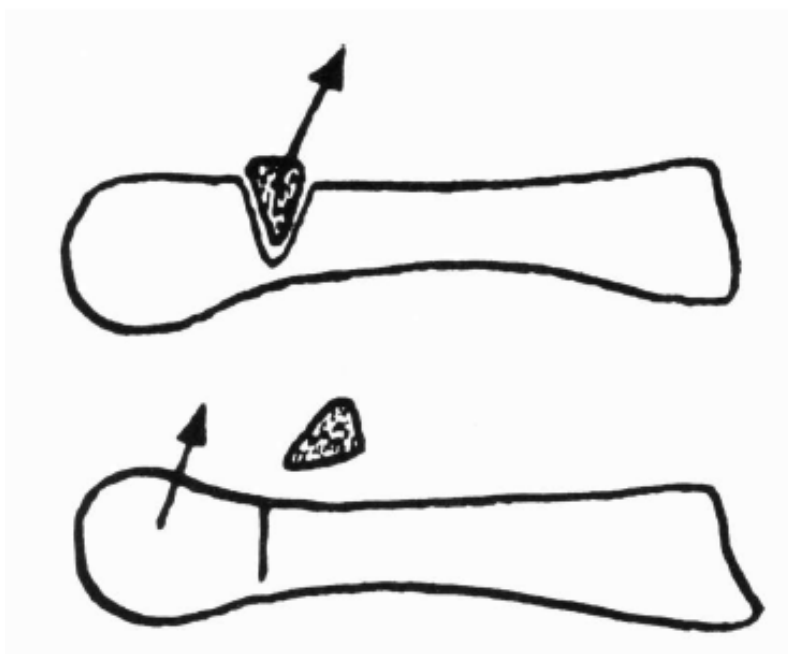
Obr. 7.3.2 Kondylektomie podle Coughlina

Mann a Coughlin




Obr. 7.3.3 Schéma šikmé zkracovací osteotomie

Giannestras (1945), modified later by Coughlin



Wolf (1973) operuje z podélné dorzální incize, malými Luerovými kleštěmi odstraní proximálně od hlavičky metatarzu část diafýzy tak, že zůstane neporušena plantární kortikalis. Tlakem prstů pak vytvoří subperiostální zlomeninu metatarzu. Pacient může ještě v den operace začít se zatížením operované nohy, pokud není v souvislosti s operací vbočeného palce požadován jiný režim. Z jedné kožní incize lze takto ošetřit i všechny tři metatarzy.

Op. sec. Wolf



Osteotomie sec. Helal

Helal (1975) doporučil šikmou teleskopickou osteotomii středních metatarzů v jejich distální polovině. Při osteotomii všech tří středních metatarzů se operuje ze dvou řezů, nad II. a mezi III. a IV. metatarzem. Oscilační pilou se kompletně přeruší kost v úhlu 45° , po osteotomii klouže distální fragment proximálně a dorzálně. Jestliže okraj distálního fragmentu příliš přečnivá dorzálně, odstraní se (obr. 24.79). Po operaci není zapotřebí sádrová fixace, se

Success rate 88%

Pakloub 15%

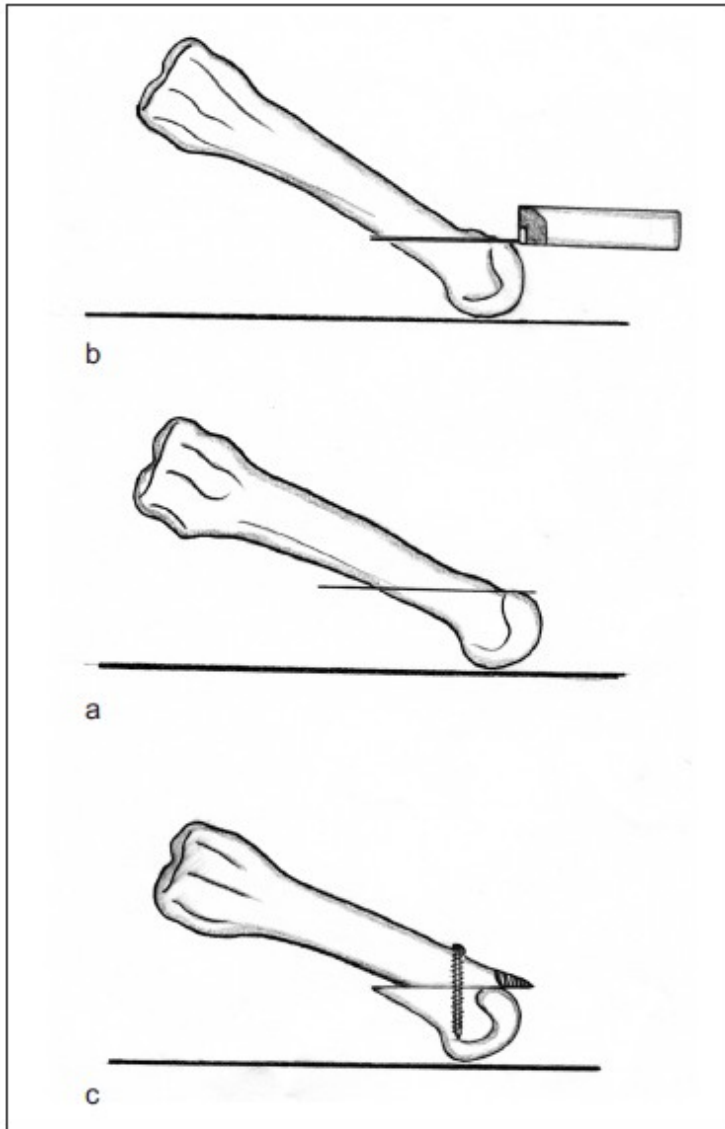
Turan and Lindren - same type of fixation operation
Screw



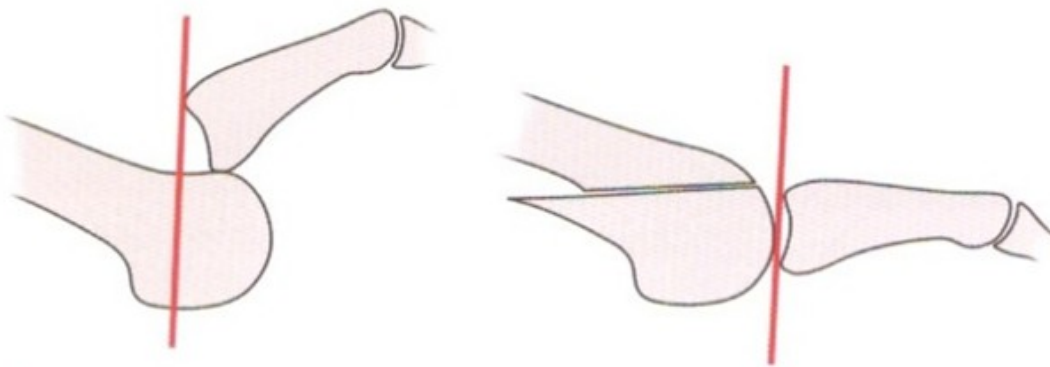
Lowel Scott Weil (Chicago, USA) 1985

Weilova operace je indikována při subluciacích a luxacích v MTP kloubech. Z dorzální incize je vedena horizontální osteotomie subkapitálně, distální fragment je posunut proximálně o 2–6 mm, z proximálního fragmentu se vytíná přebytečná dorzální kortikalis. Hlavička je spojena s diafýzou metatarzu šroubkem. Tato operace dává jisté a velmi dobré výsledky (obr. 24.80) a stala se v posledních deseti letech standardní procedurou na našem pracovišti.

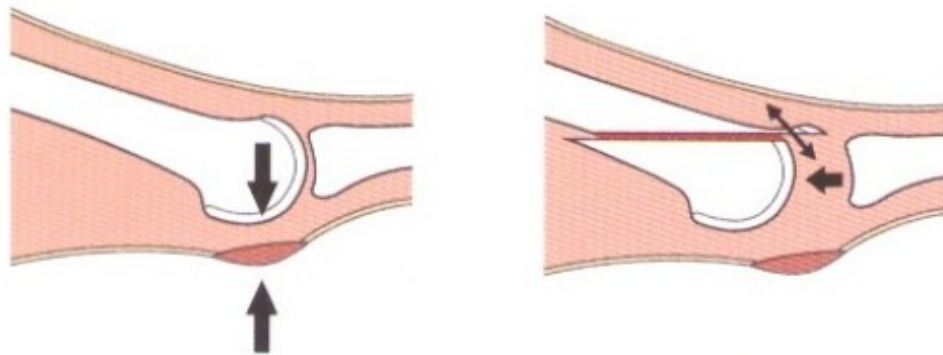
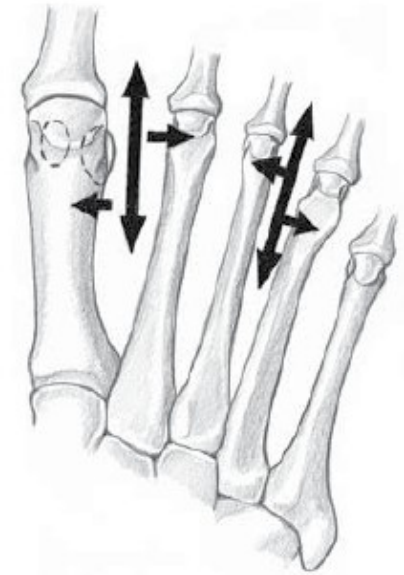
Osteotomy length 2.5- 3cm
"Z" sculpture of extensors



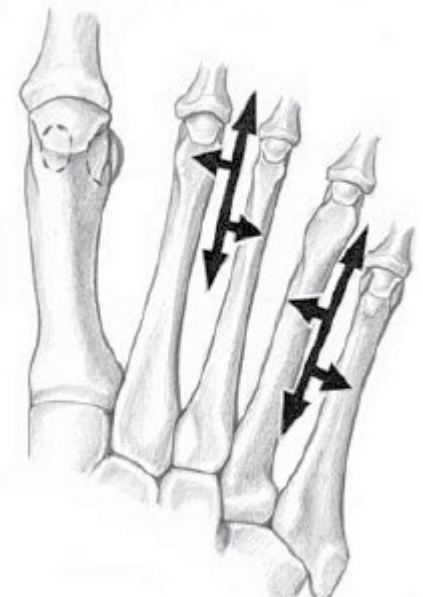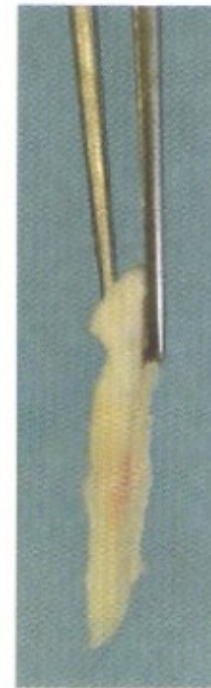
Obr. 24.80 Jednotlivé fáze Weilovy operace: a – osteotomie probíhá rovnoběžně s plantární plochou chodidla, b – distální fragment je posunut proximálně o 2–6 mm a zajištěn šroubkem, c – přečnávající dorzální část metatarzu je odstraněna



Obr. 7.3.5 Použití Weilovy osteotomie je indikováno k rekonstrukci luxace v MTP kloubu. Pouhou prolongací extenzorového aparátu bez zkrácení metatarzu se repozice postavení prstu nezdaří.

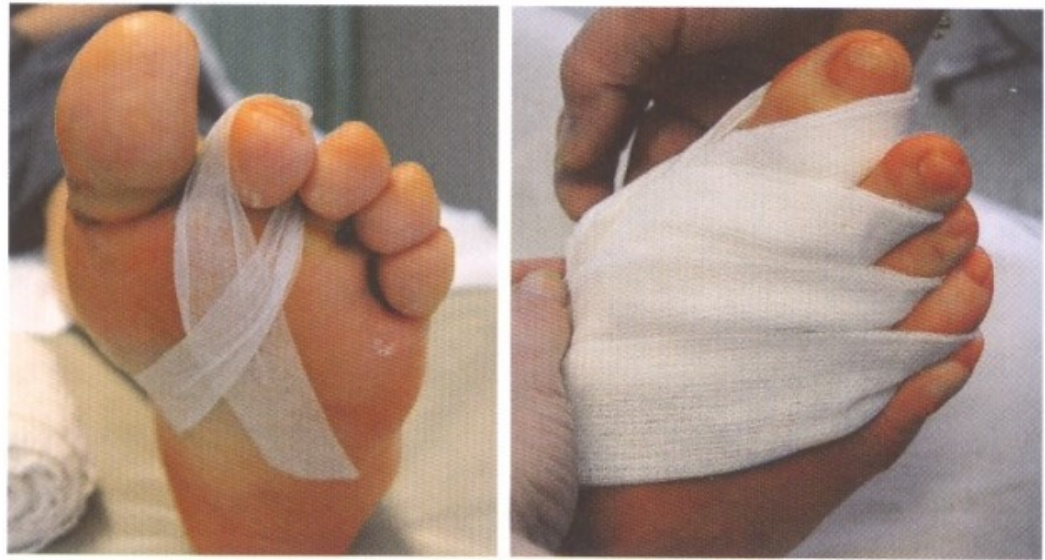

Obr. 7.3.6 Při proximálním posunu hlavičky nesmí dojít k plantarizaci hlavičky. Důležité je horizontální vedení osteotomie a vytěžení kostního plátku při dvojí osteotomii. Na obrázku vpravo vyjmutý kostní plátek při dvojí osteotomii.



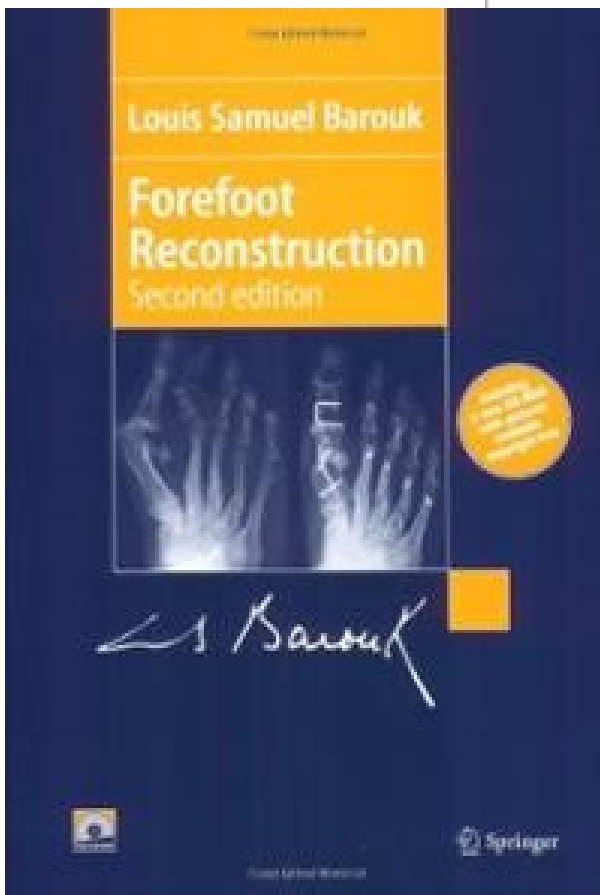
Postoperative care

- Limb to an **elevated position** 90% of the time in the first 10 postop. Days.
- **Correction fixation in light plantar flexion**
- Passive finger flexion exercises
- Removal of stitches **in 14 days**
- Verticalization in a special postoperative shoe 4-6 weeks
- X-ray feet AP under load and oblique scan 6 weeks after surgery



Obr. 7.3.10 Pooperační péče – korekční náplastová fixace při kontrakturách dorzálních struktur drží prst ve středním postavení po dobu hojení.





1991, 2nd. 2005



Fig. 18a1. The BRT* lesser metatarsal osteotomy.

BRT: Barouk Rippstein Toullec. From the left to the right: L. S. Barouk (Bordeaux), P. Rippstein (Zurich), E. Toullec (Bordeaux).

1. The BRT oblique osteotomy for metatarsal elevation provides a good stability because a proximal plantar hinge is preserved, and it is solidly secured with a FRS (or scarf screw) (**2**).

* Barouk (Bordeaux), Rippstein (Zurich), Toullec (Bordeaux).

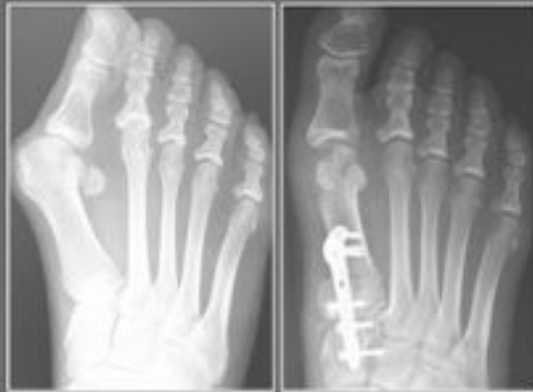
osteotomie BRT, kterou popsali Barouk, Rippstein a Toullec. Jedná se o šikmou osteotomii při bazi metatarzu se sklonem 60° s ponecháním periostu plantárně. Při osteotomii se vytne malý klín (asi 2–3 mm), postavení je fixováno Baroukovým šroubem.



Michael Vitek

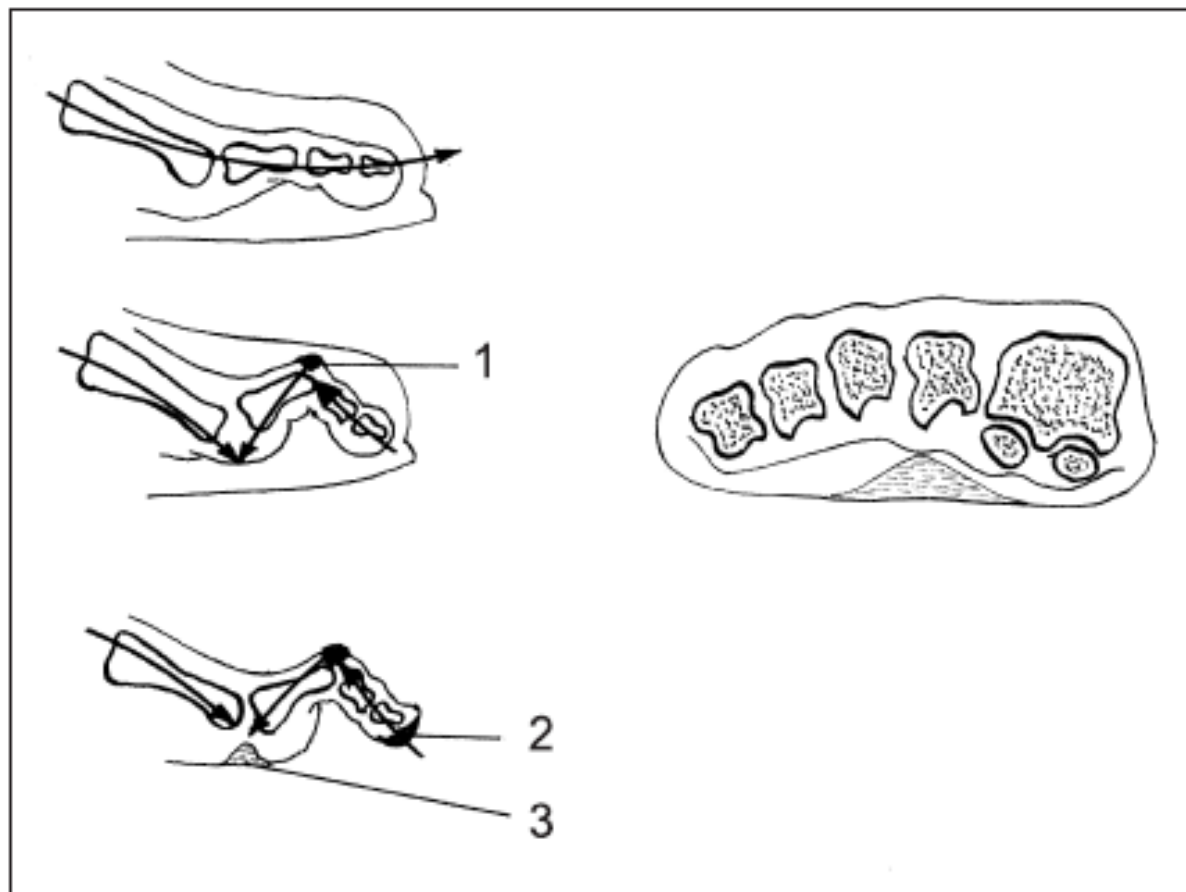
Neue Techniken in der Fußchirurgie Das V-tek-System

Bohrdrahtfreie Vorfußkorrekturen



LEHR-
Programm
gemäß
§ 14
JuSchG

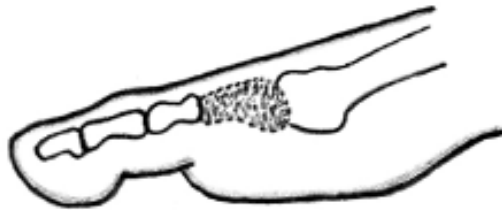
ABW · Wissenschaftsverlag



Obr. 24.88 Vznik otlaků u příčně ploché nohy, otlaky u kladívkových prstů: 1 – dorzální otlak (clavus) nad PIP kloubem, 2 – otlak na bříšku prstu, 3 – plantární otlak pod hlavičkou metatarzu

Hammer toe surgery

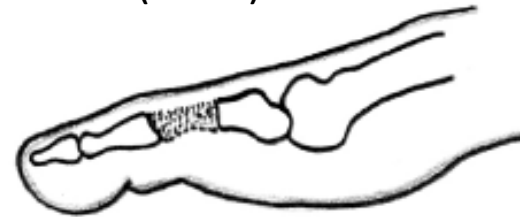Gocht (1925)



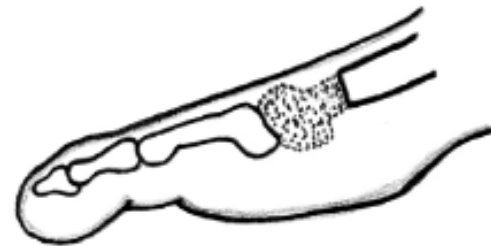
a

- při rigidní extenzní kontraktuře MTP kl.

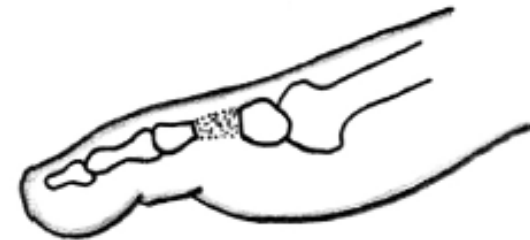
Post (1882)



b



c



d

Obr. 24.90 Typy resekčních hemifalangektomií: a – proximální hemifalangektomie základního článku prstu, b – distální hemifalangektomie základního článku, c – resekce hlavičky metatarzu, d – resekce střední části diafýzy článku