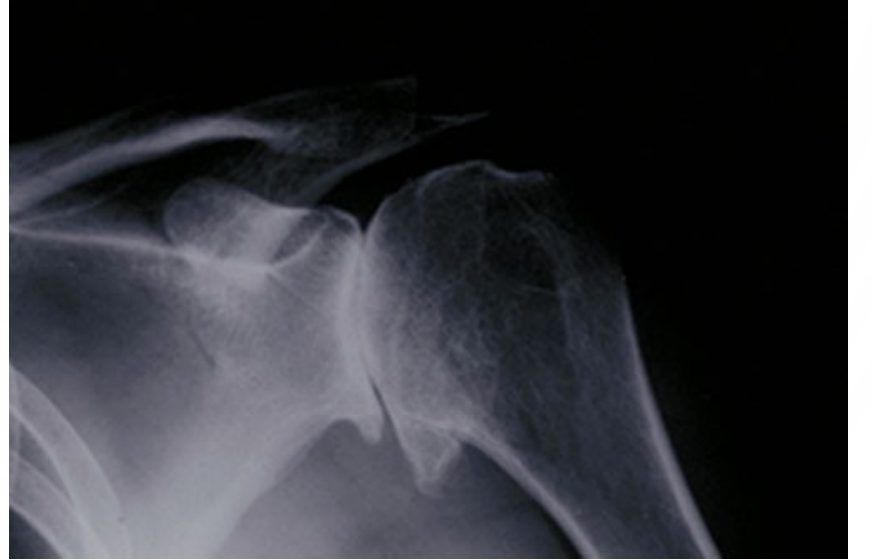
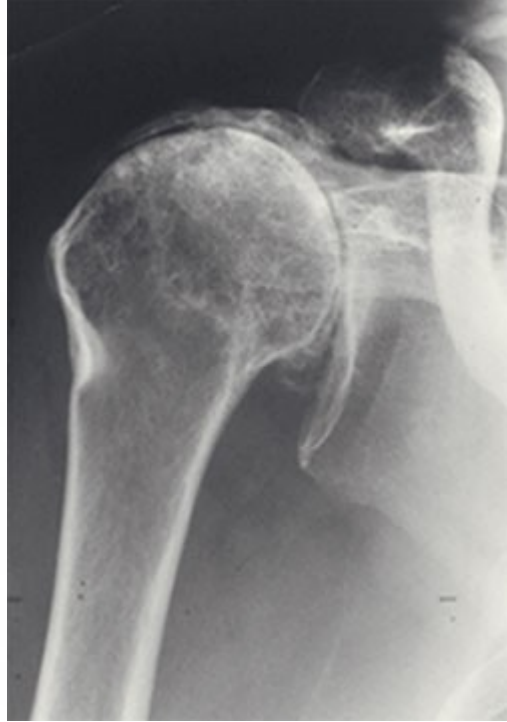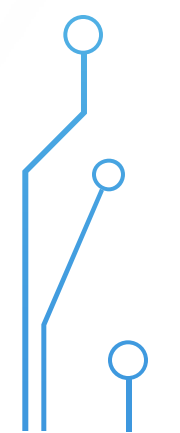

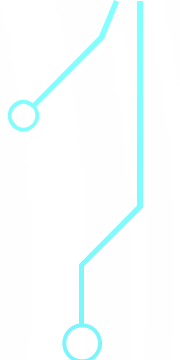
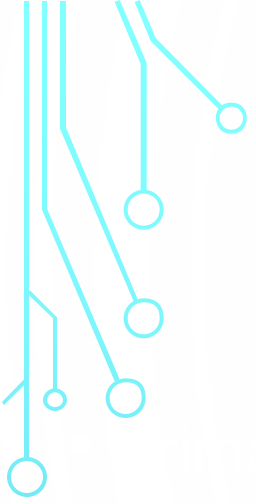
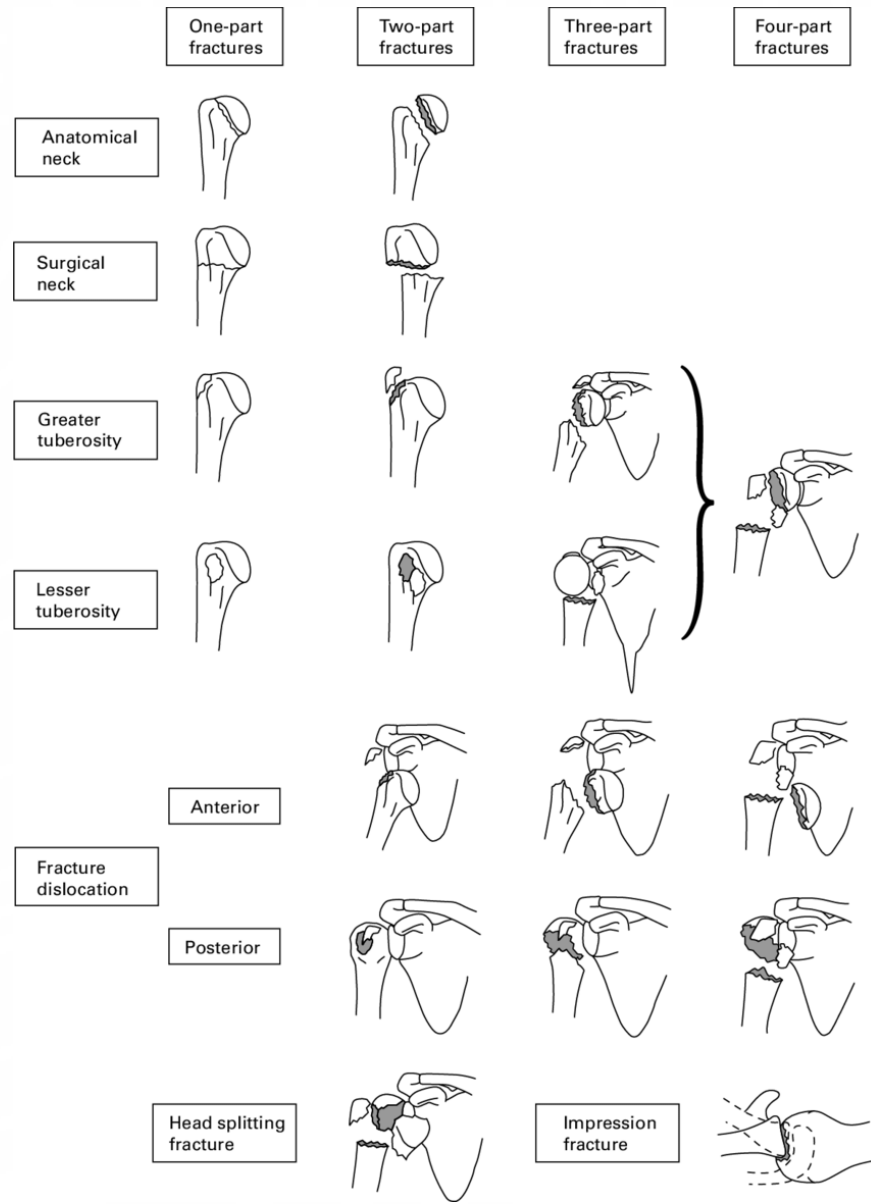




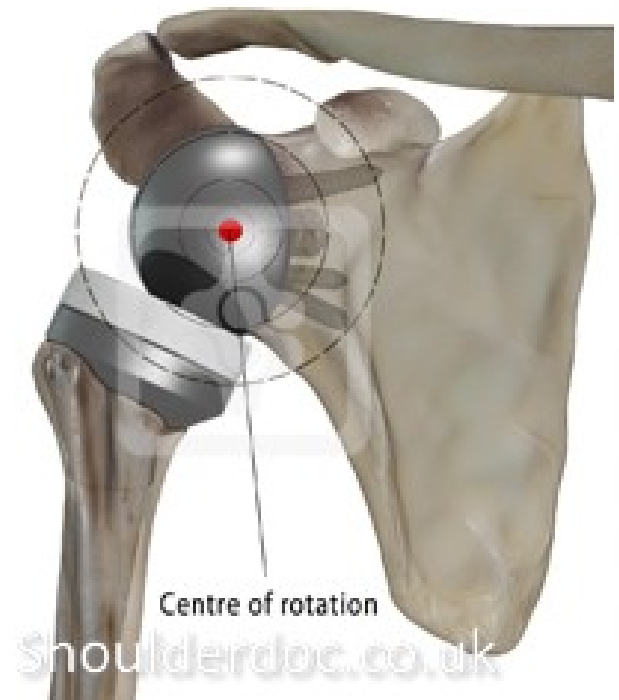
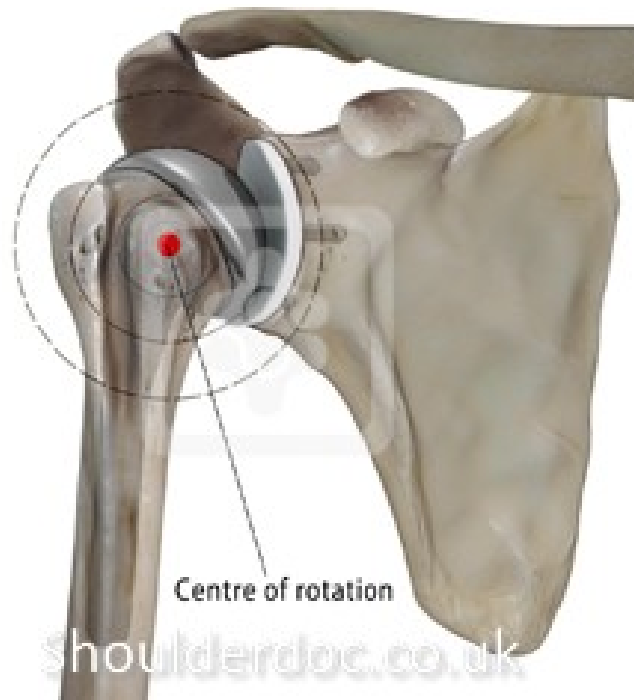
MUDR. JAN EMMER, I. ORTOPEDICKÁ KLINIKA FNUSA V BRNĚ



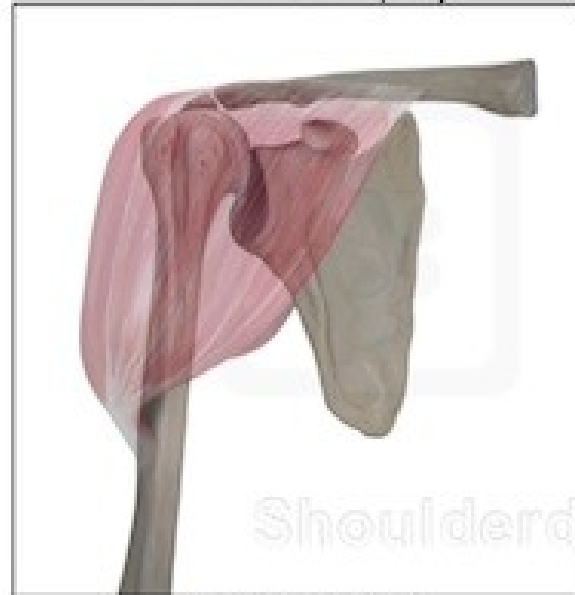<p>A:</p> <p>Unifocal Extra-articular 2-Part Fracture Intact Blood Supply</p>				
<p>B:</p> <p>Bifocal Extra-articular Possible injury to blood supply</p>				
<p>C:</p> <p>Articular fracture involving the anatomic neck high likelihood of necrosis</p>				





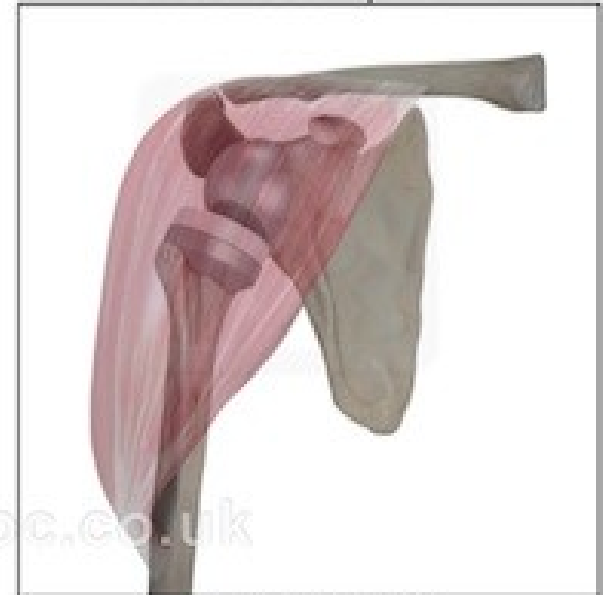

Rotator cuff arthropathy



Deltoid contracted

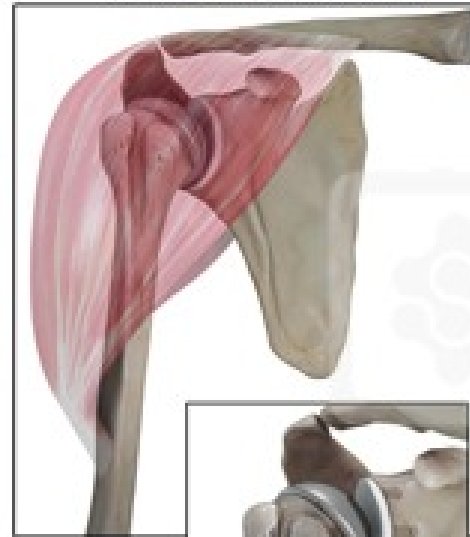
Reverse shoulder replacement



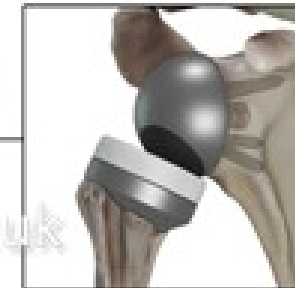
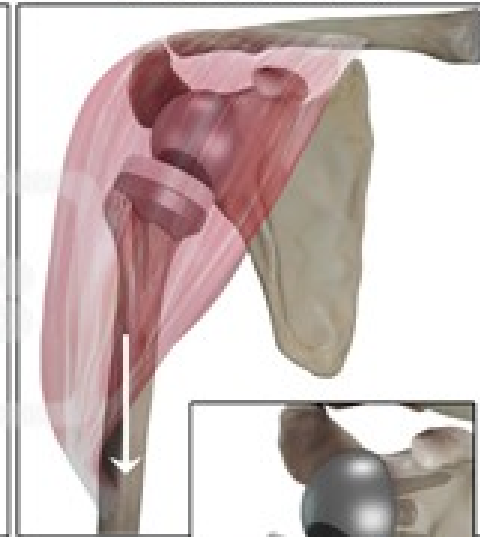
Deltoid retensioned

Shoulderdoc.co.uk

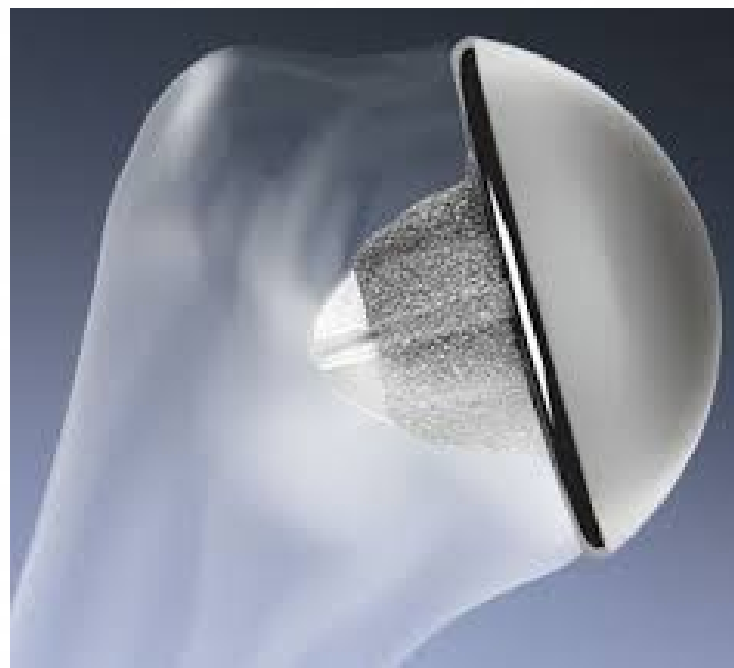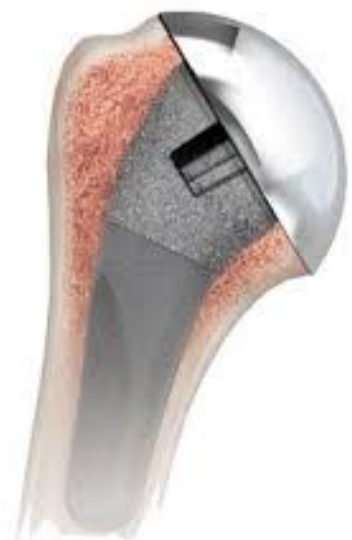Anatomical shoulder replacement

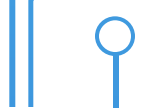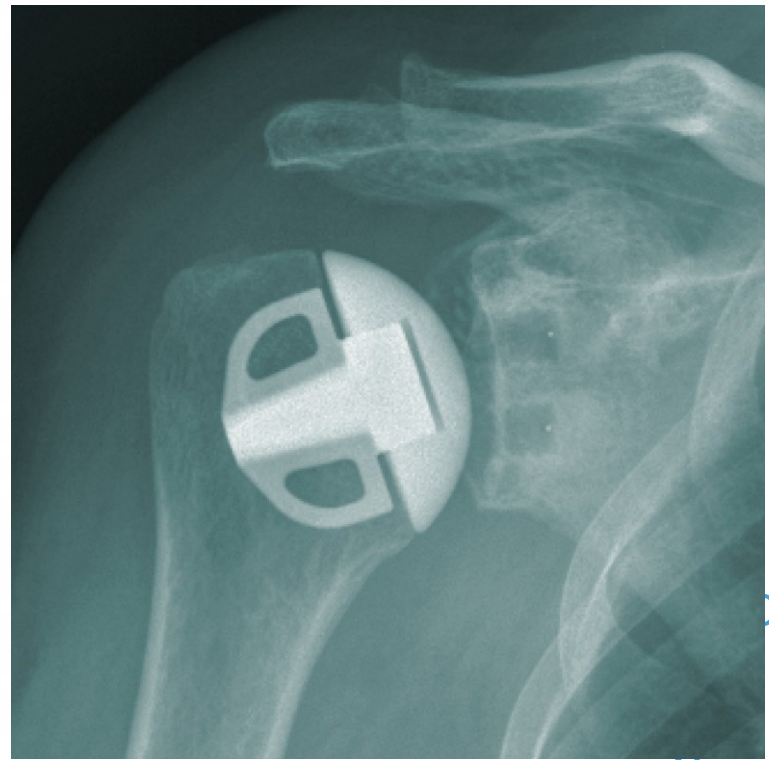
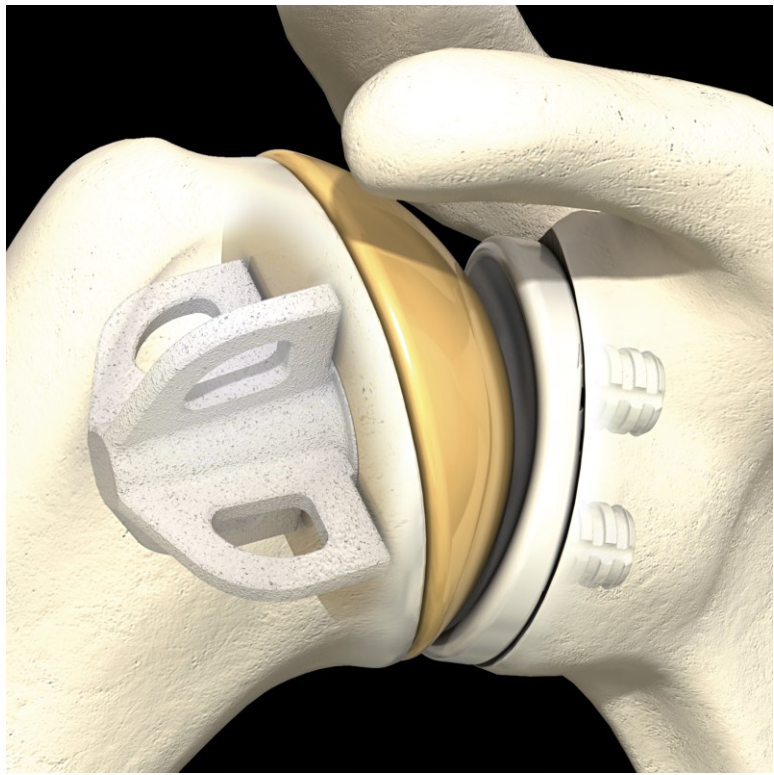
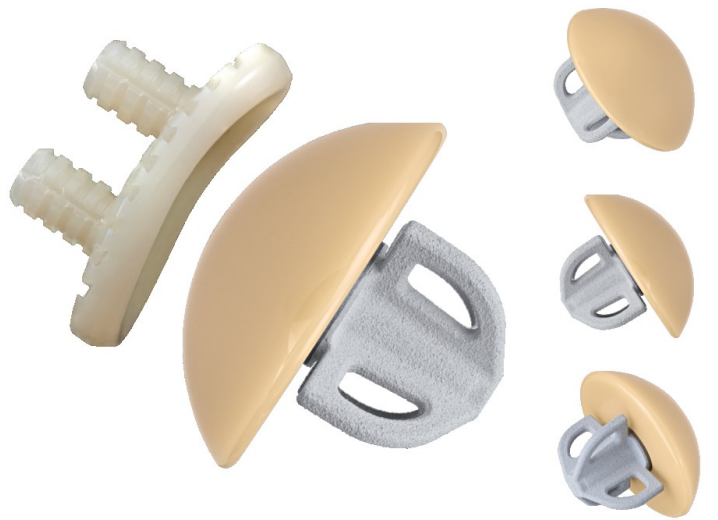
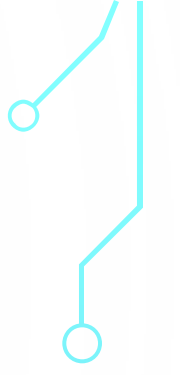
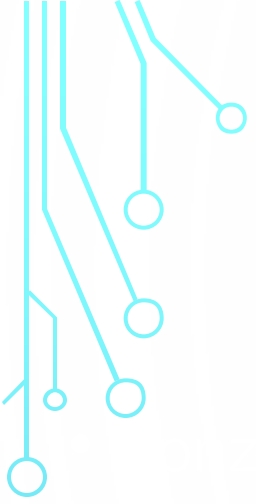


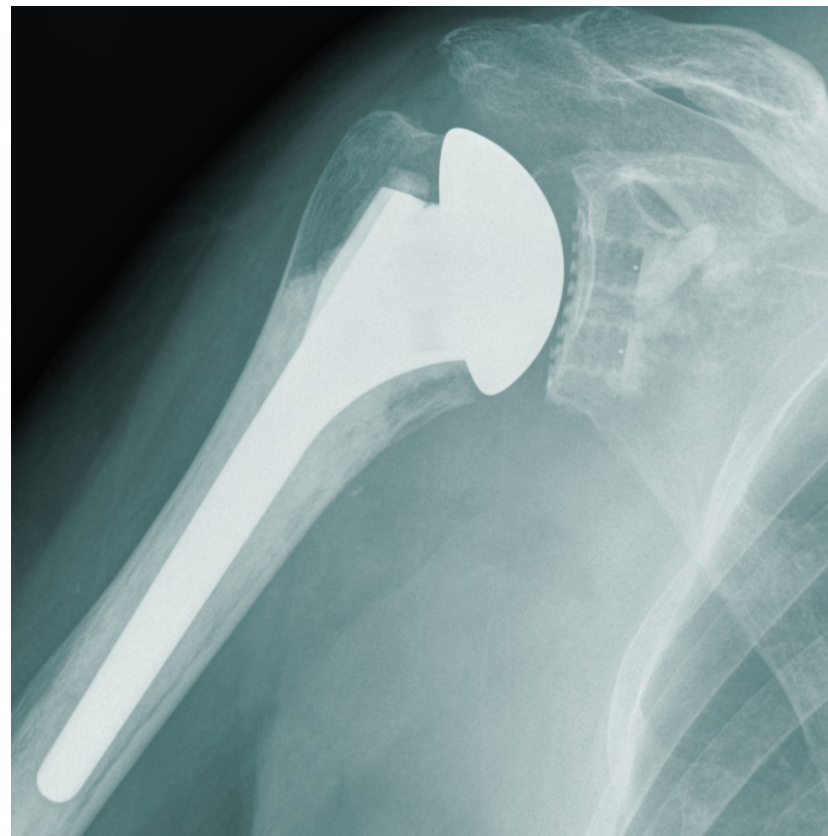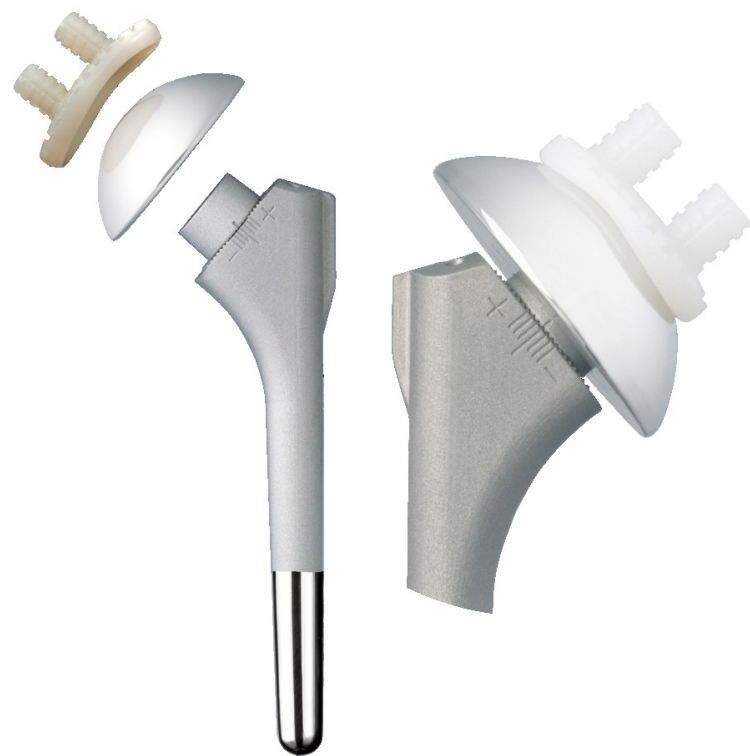Reverse shoulder replacement

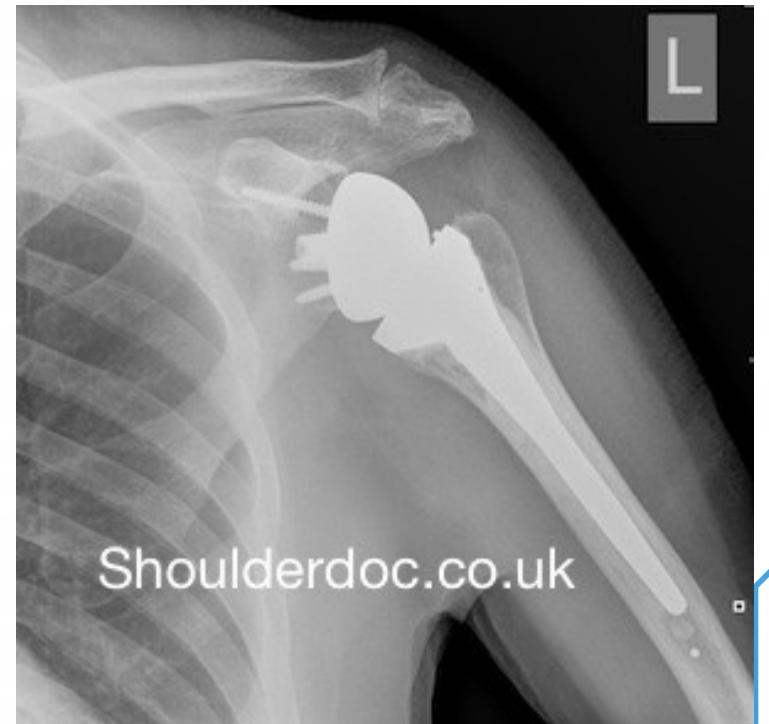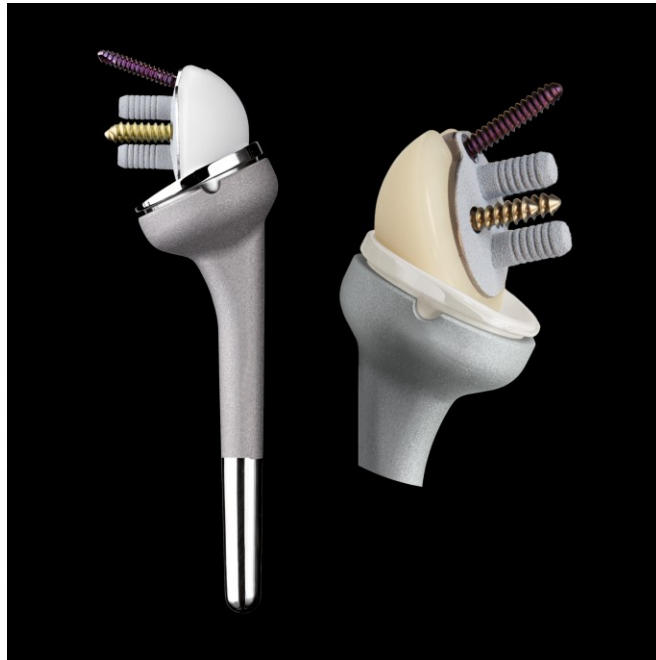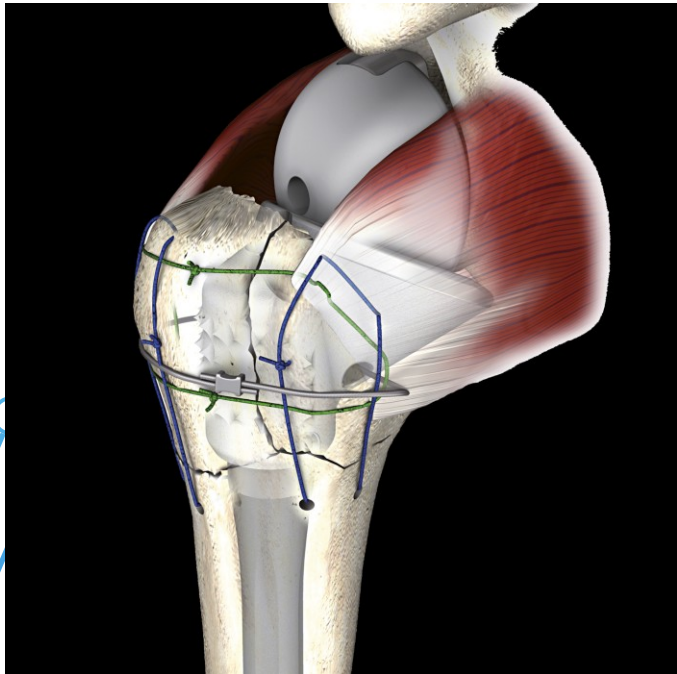


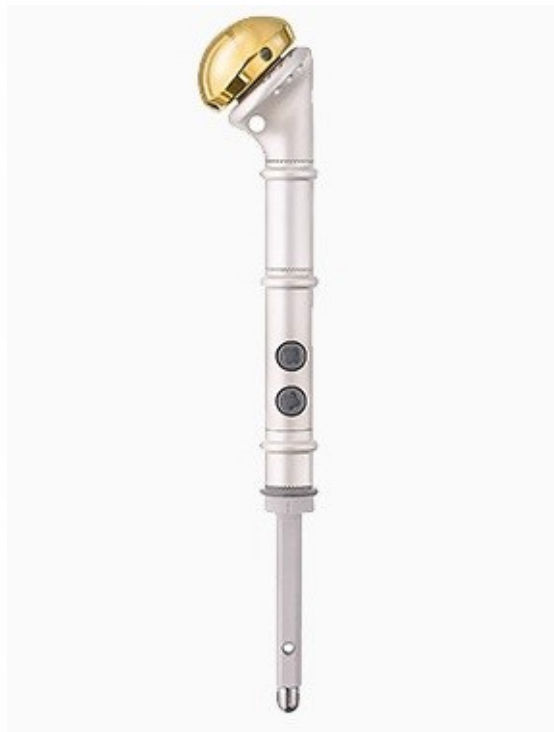Shoulderdoc.co.uk

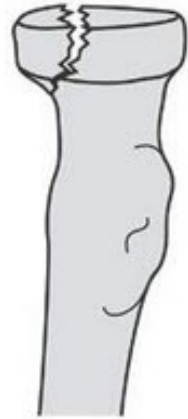
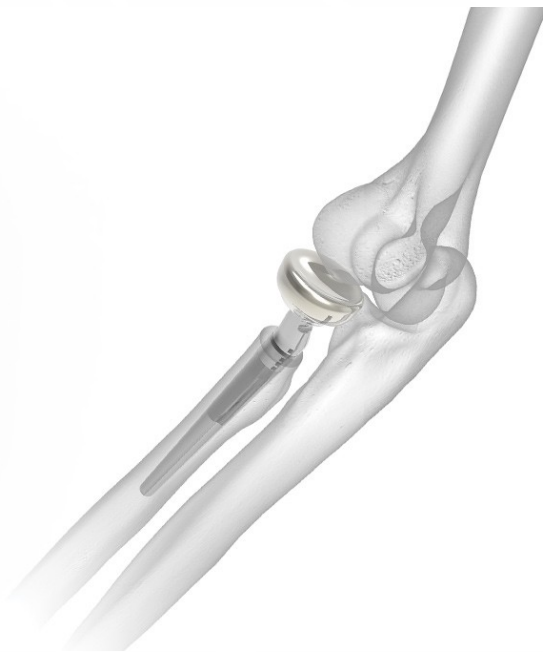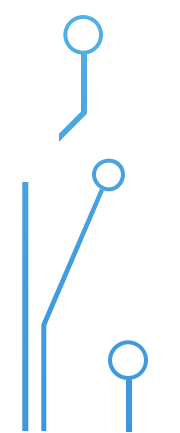
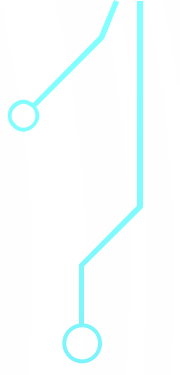
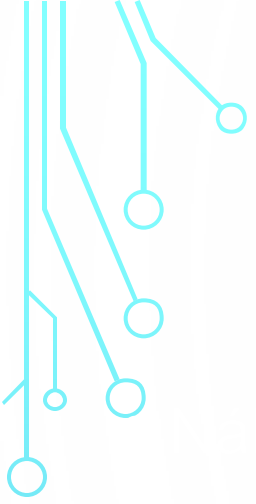




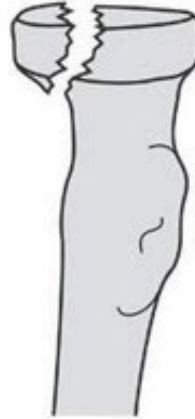




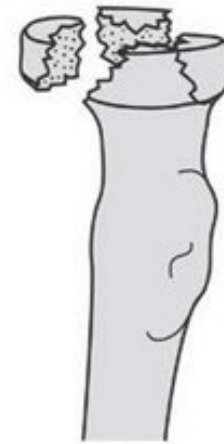




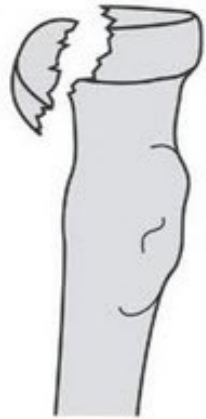I



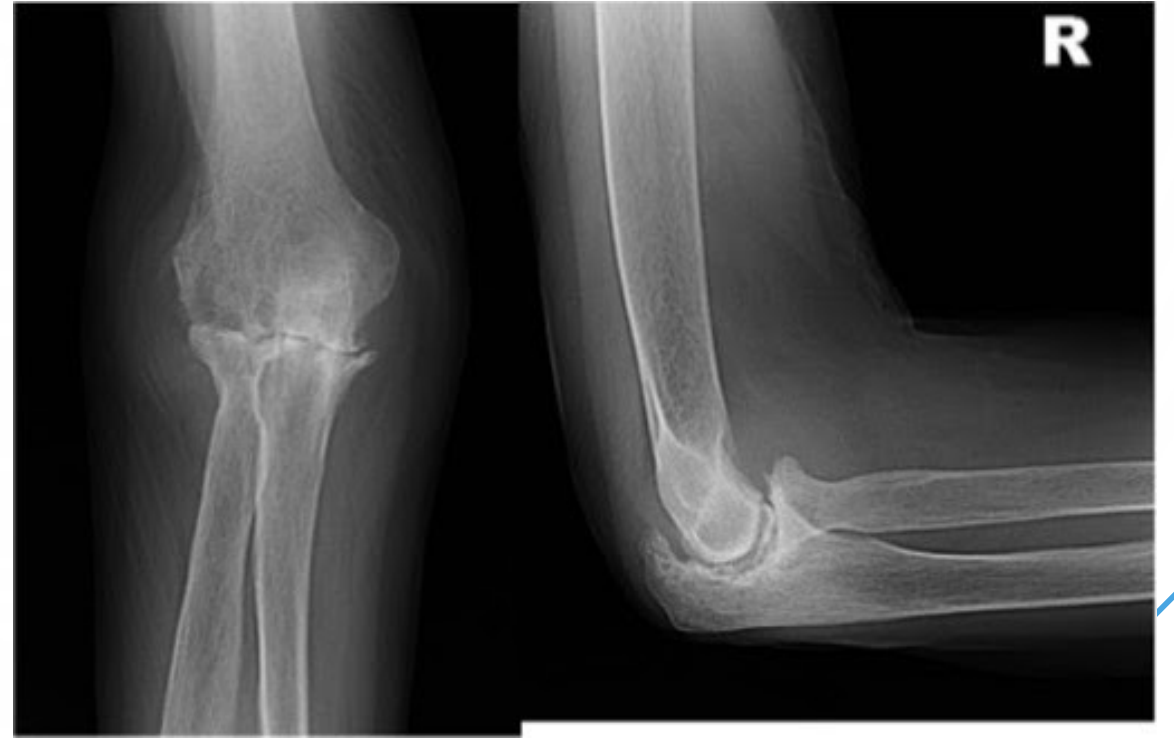II

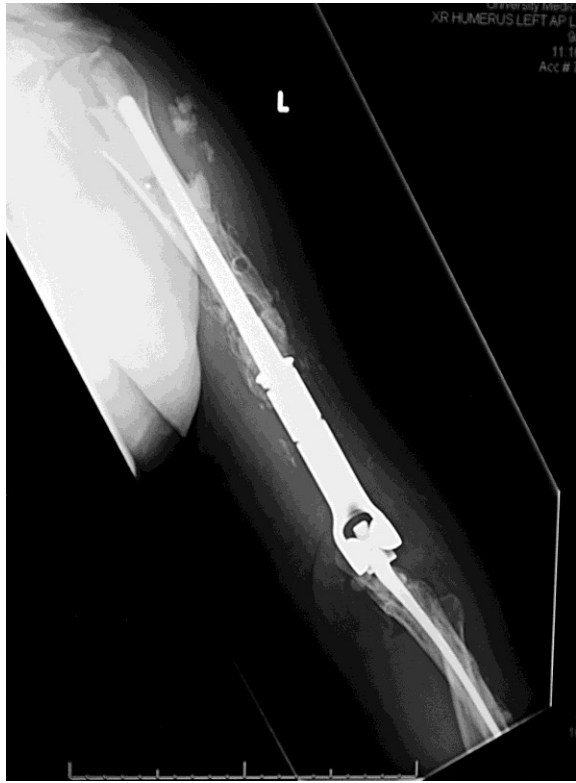

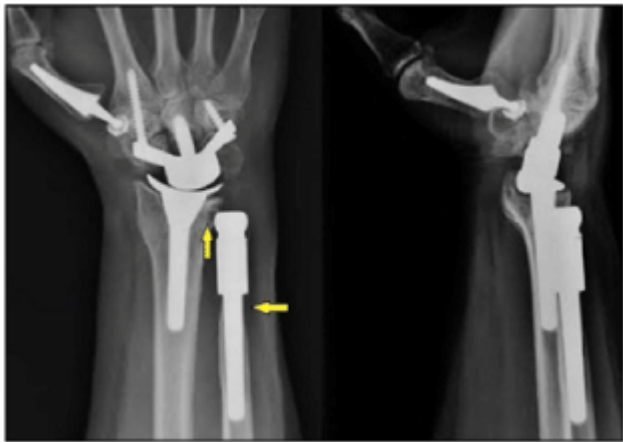
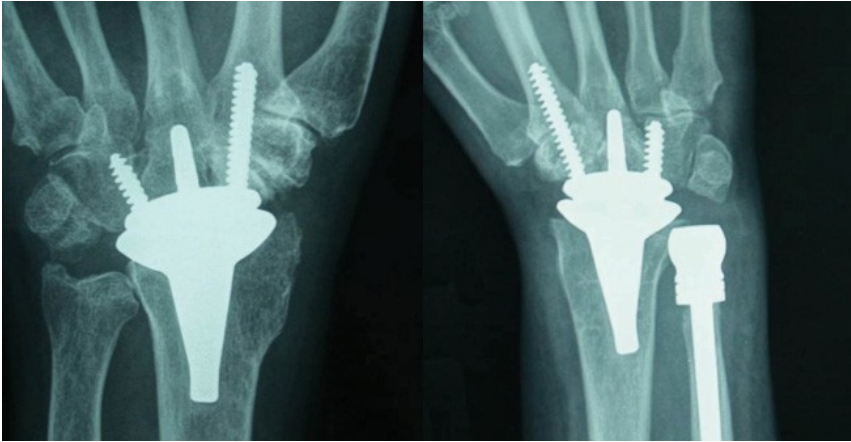
III

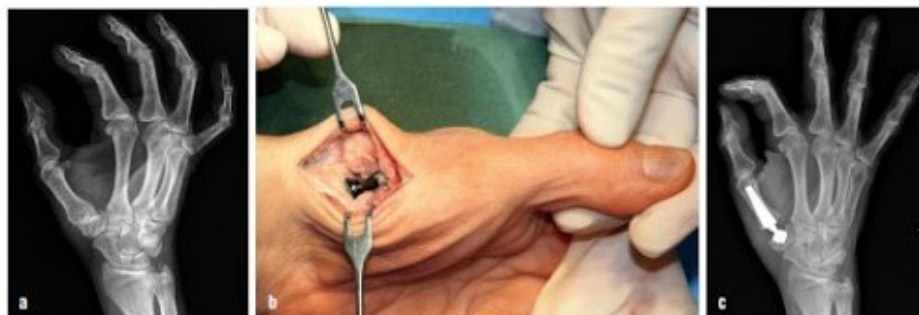

IV



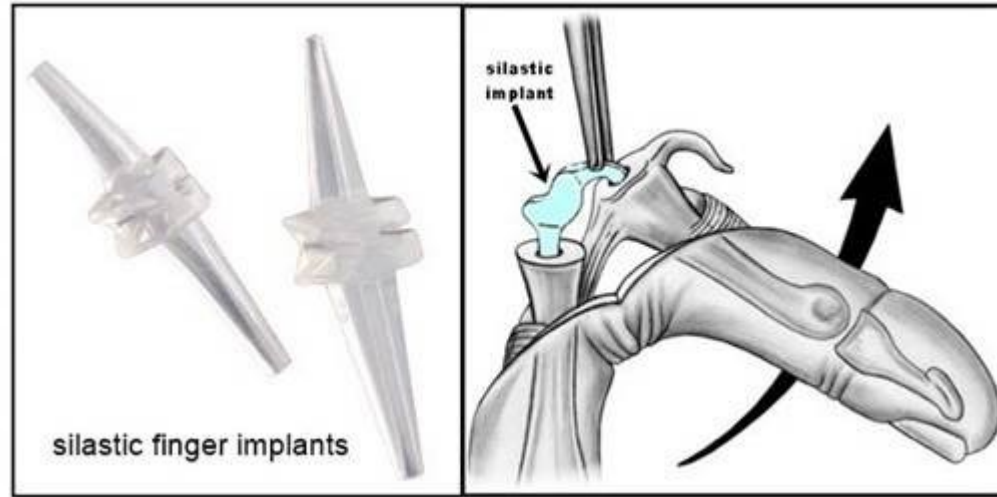






Obr. 2. Totální endoprotéza Beznoska kořenového kloubu palce ruky; rtg před operací (2a), intraoperační nálež (2b), rtg nálež po implantaci endoprotézy (2c).









Total Ankle Replacements - Designs



Hintegra (New Deal)



Ramses France MBA



Buechel Pappas Low Contact Stress LCS (Endotech)





