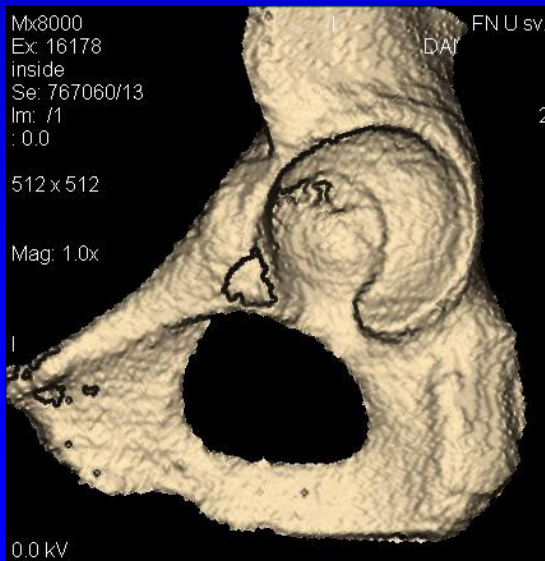
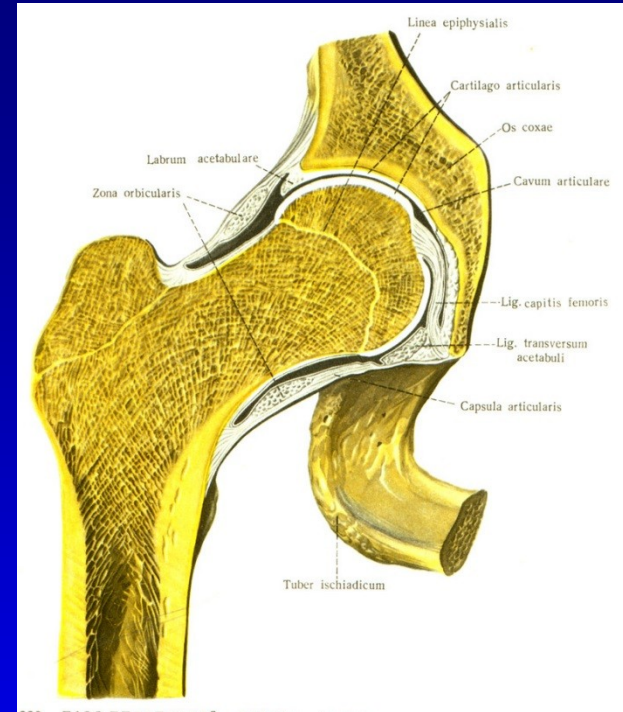


Total hip arthroplasty

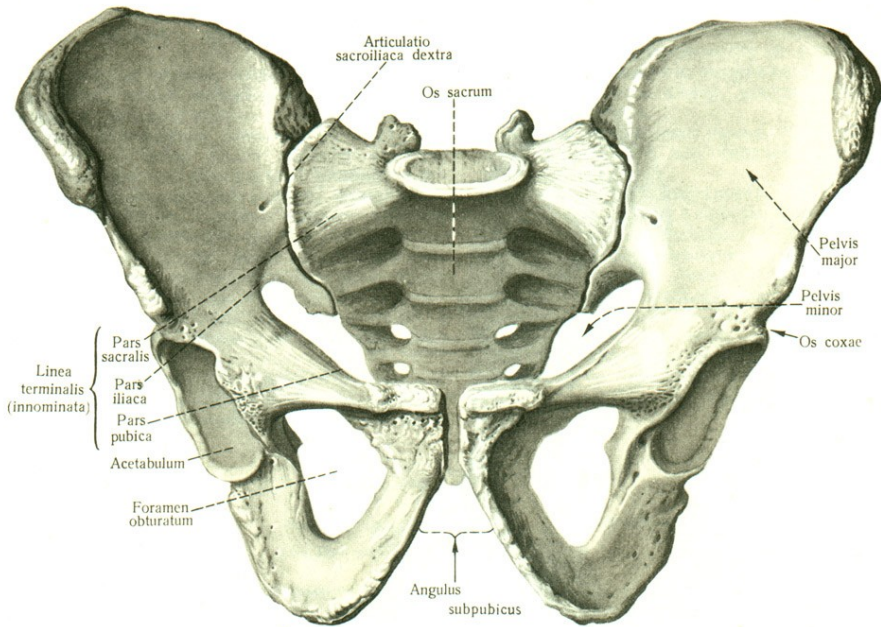
J. Emmer, Z. Rozkydal

Hip joint

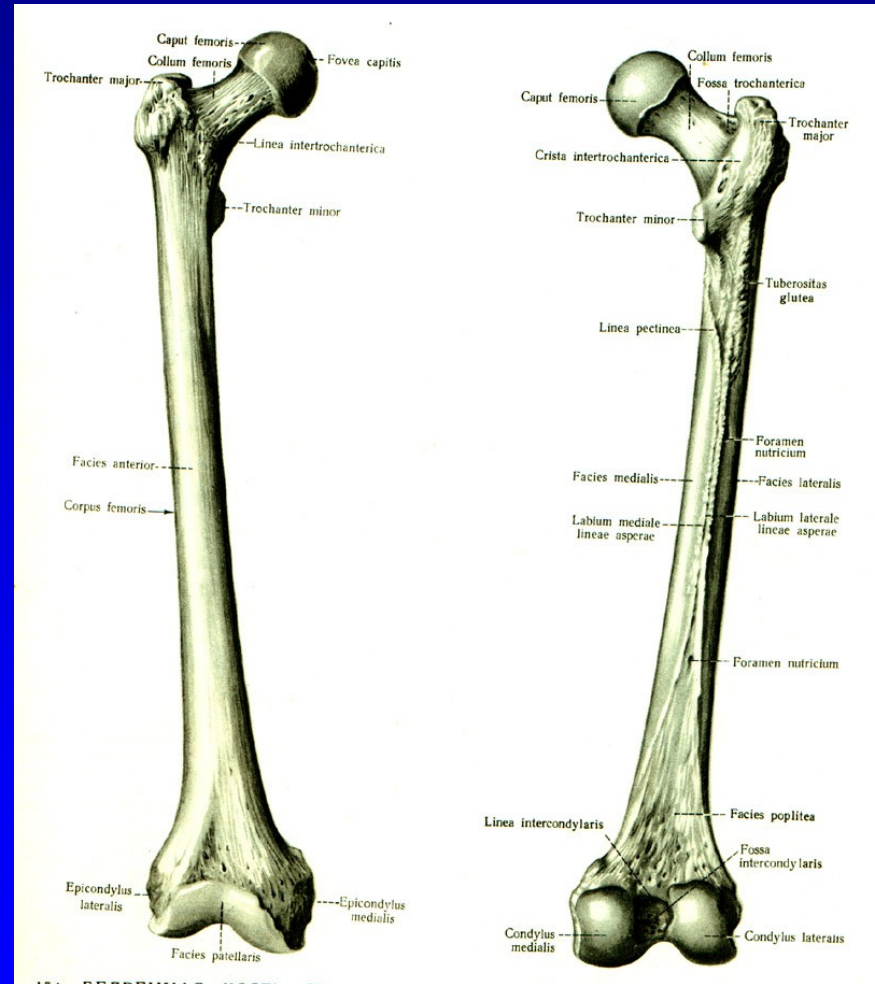
Enarthrosis



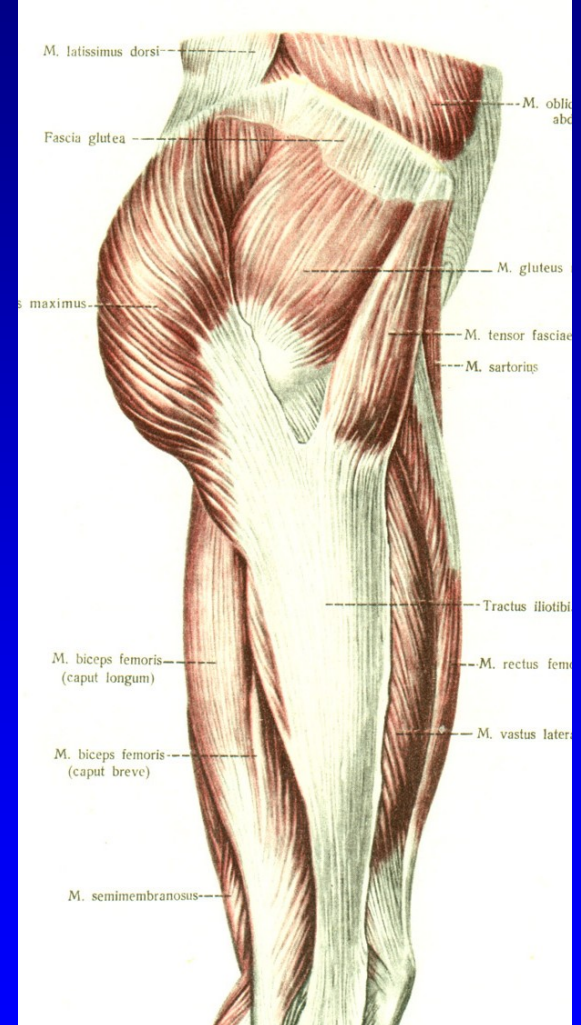
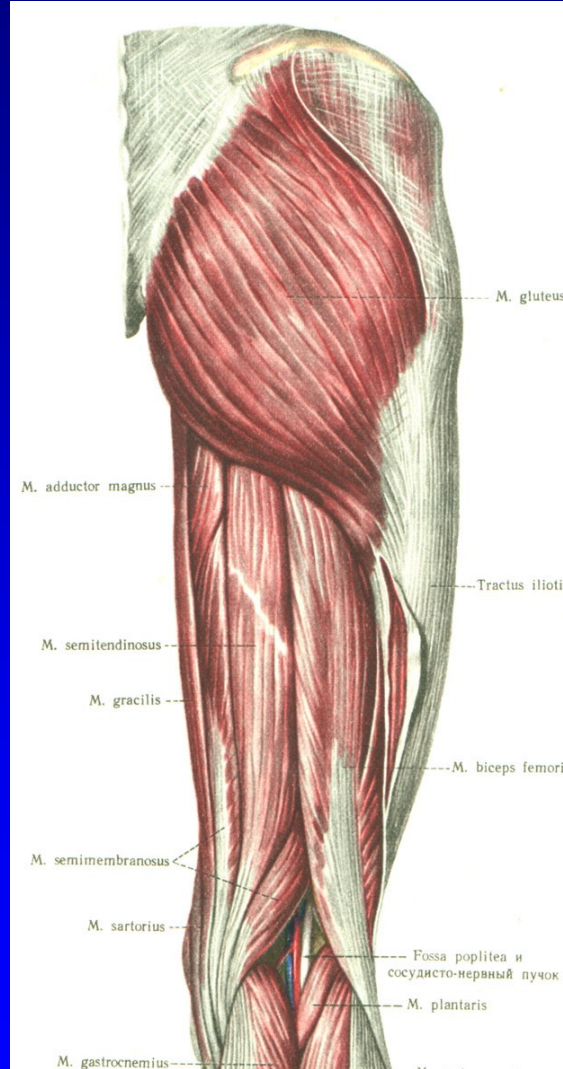
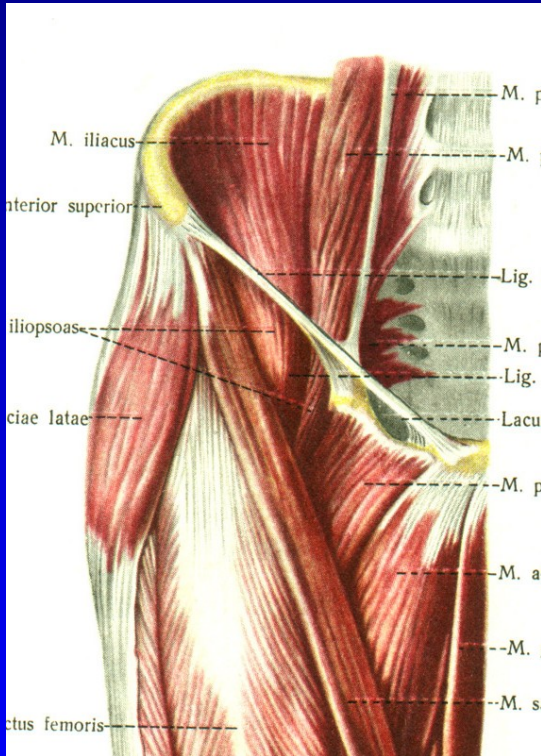
Pelvis



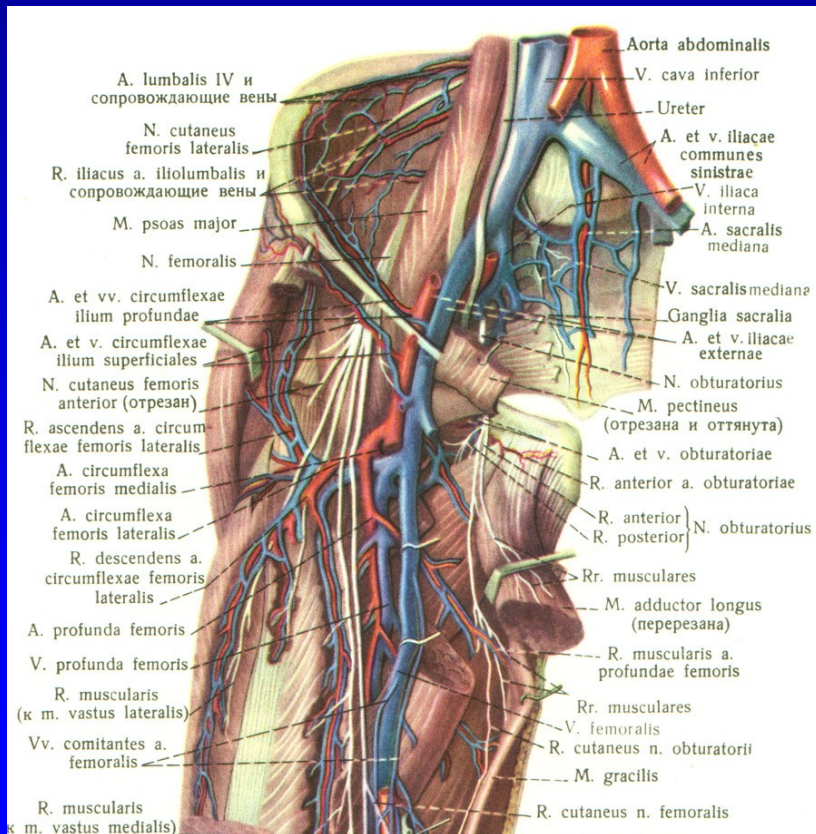
Femur



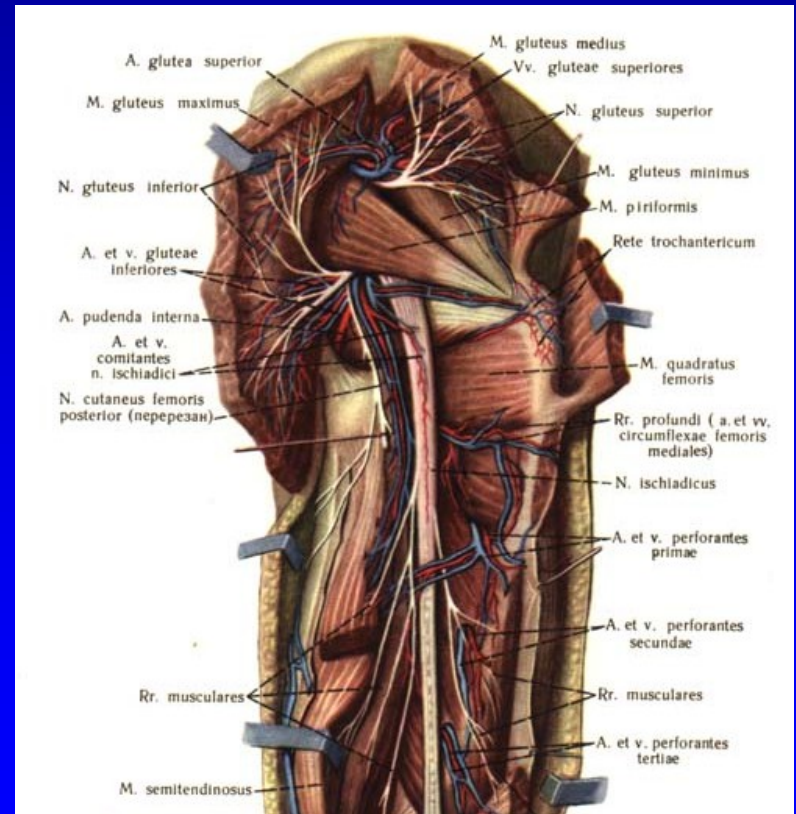
Muscles



Femoral nerve

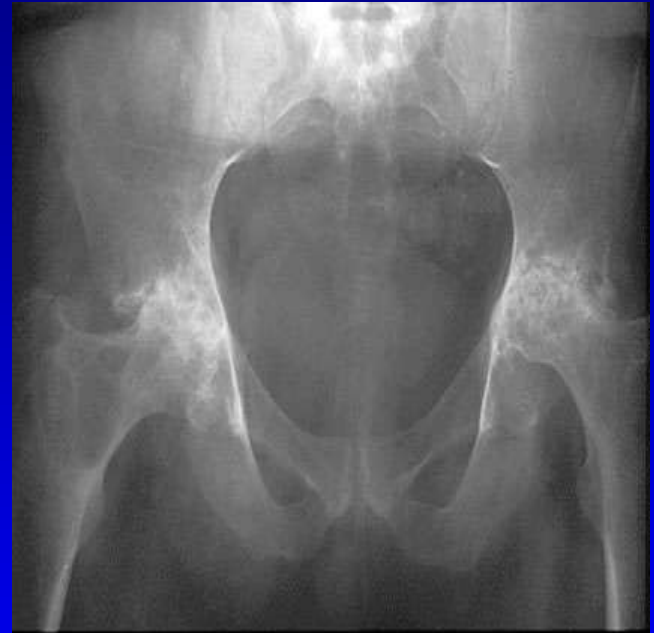
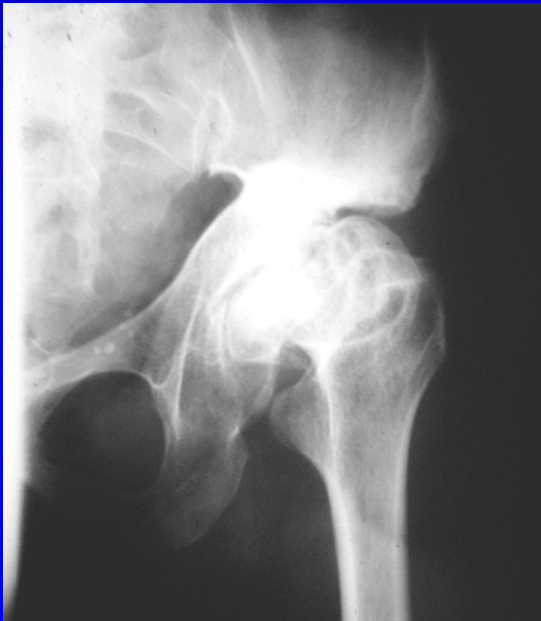
Sciatic nerve



THR indications

- Painful hip joint condition
- Poor effect of conservative therapy
- Life comfort deteriorated
- No salvage surgeries indicated



Indications

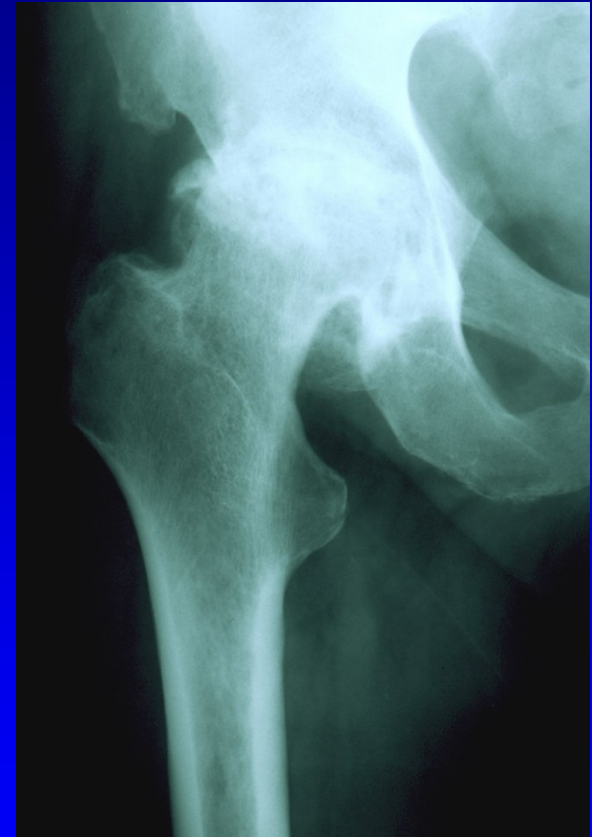Primary osteoarthritis

Secondary osteoarthritis:
congenital, posttraumatic,
after infection

Rheumatoid arthritis

Psoriatic arthropathy

Avascular necrosis
of the femoral head



Primary osteoarthritis

THR indications

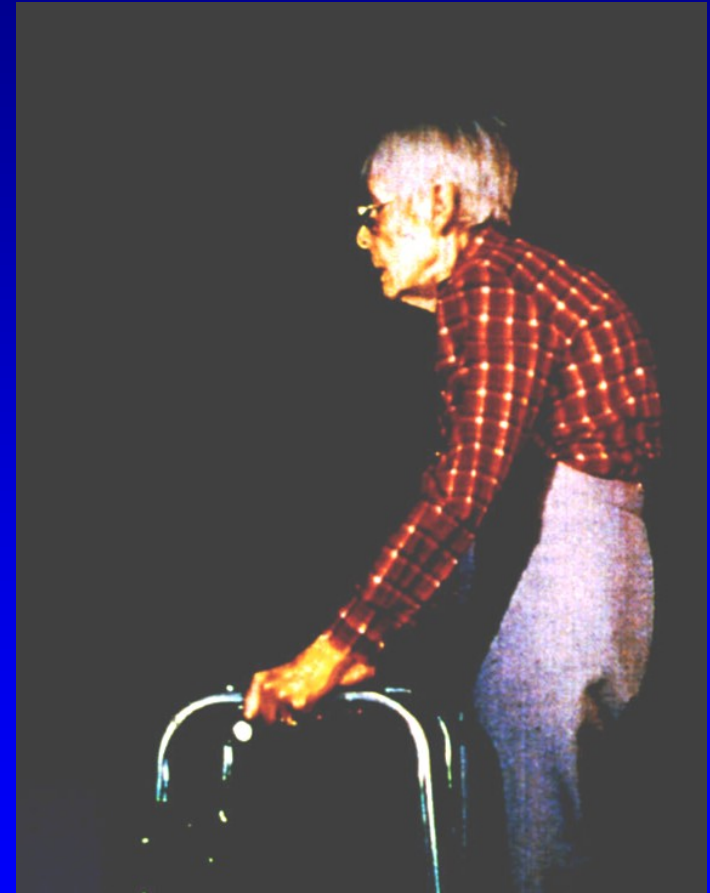
- OA primary
- OA secondary
- Psoriatic arthropathy
- Aseptic femoral head necrosis
- Rheumatoid arthropathy
- Tumors
- Intracapsular femoral neck fracture, no indication for OS or conservative therapy (vital indication!)

THR contraindications

- Poor general condition, poor physical status (ASA IV)
- Persistent infection
- Severe comorbidity with poor prognosis
- Extreme obesity
- No compliance

Contraindication

- Active infection of the hip
- Infection in the body
- General condition not good
- Neurogenic arthropathy
- Extreme low bone quality
- No cooperation of the patient
- elevated ESR, CRP



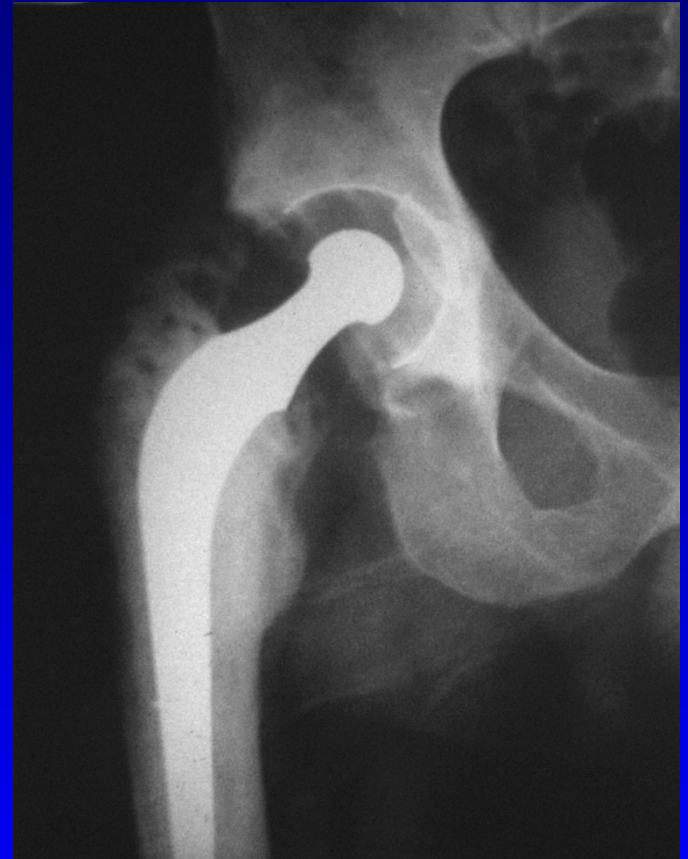
History

Sir John Charnley
Low friction arthroplasty
Acrylic dental cement


Polymethylmetacrylate
– bone cement



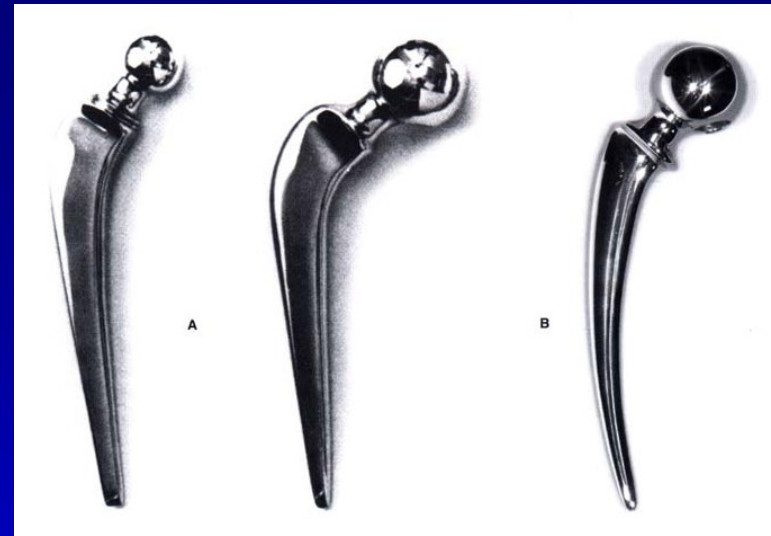1962



Low friction arthroplasty

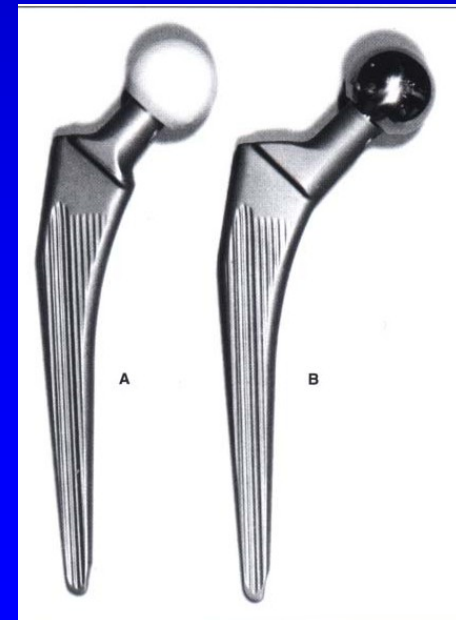


Prof. M. E. Müller




1964 -1965
Setzholzprothese

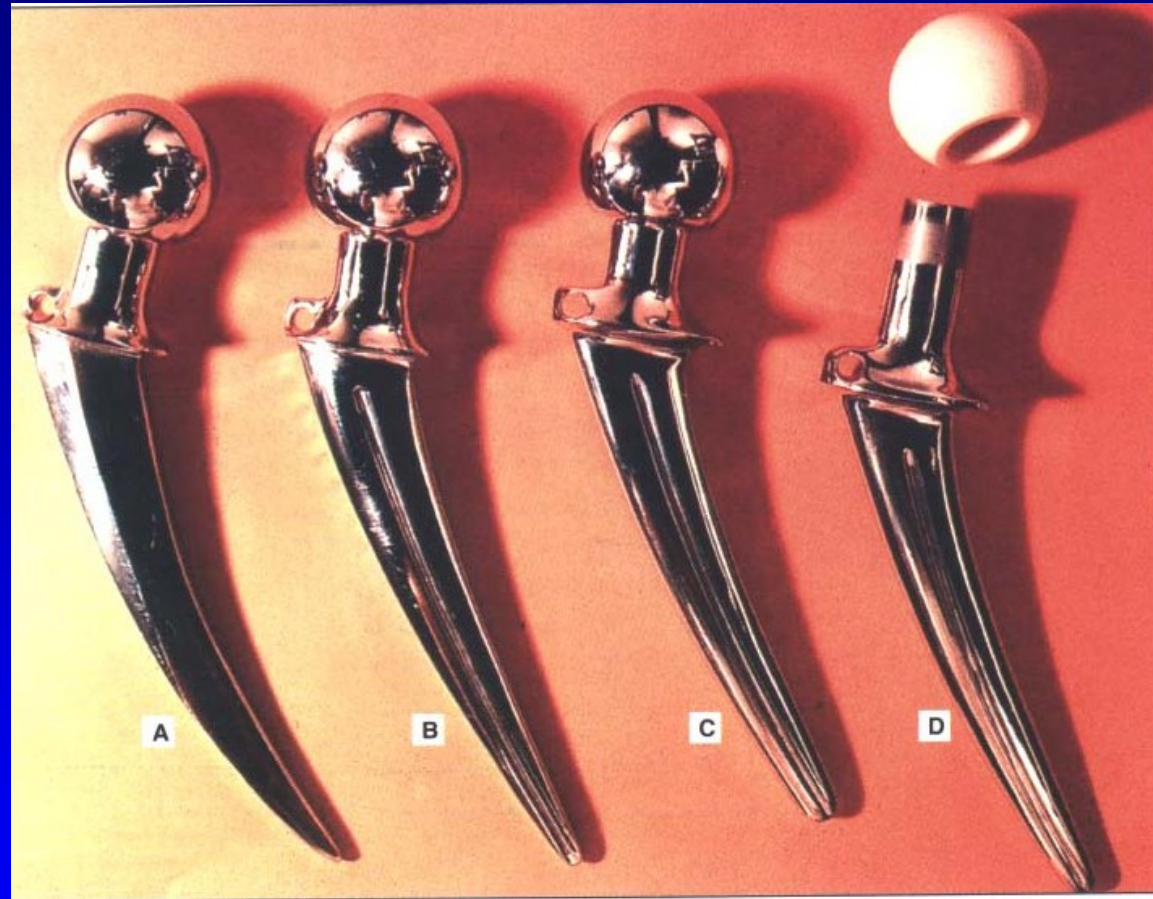
1966
Banana - shaped



1977
Geradschaftprothese



Prof. MUDR. Oldřich Čech, DrSc.



1972

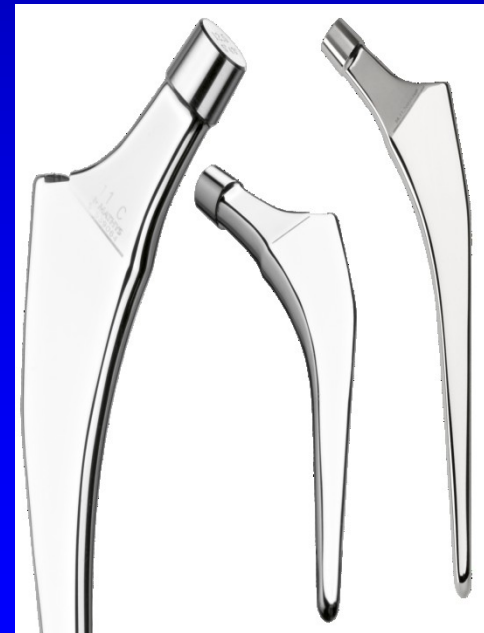
1986

Stems Poldi- Čech

THR fixation options

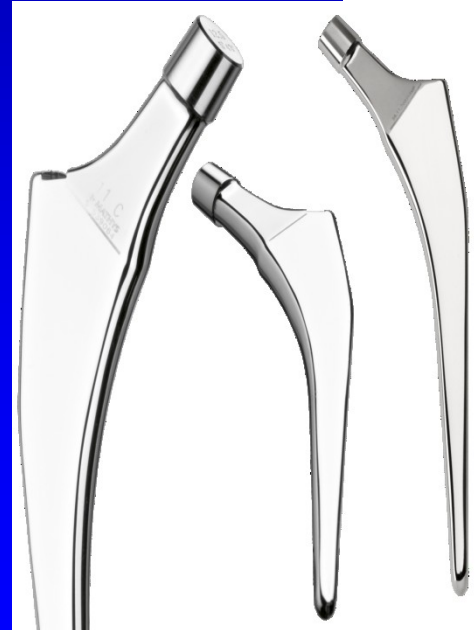

- Cemented

- Both components fixed with bony cement
- Older patients > 70 y.o.
- Poor bone quality - osteoporosis



THR fixation options

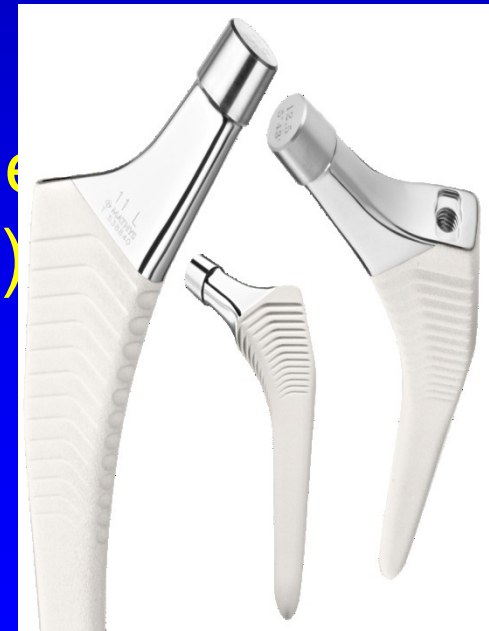- Hybrid
 - One component fixed with bone cement (femoral)
 - 65-70 y.
 - Better implant survival



THR fixation options

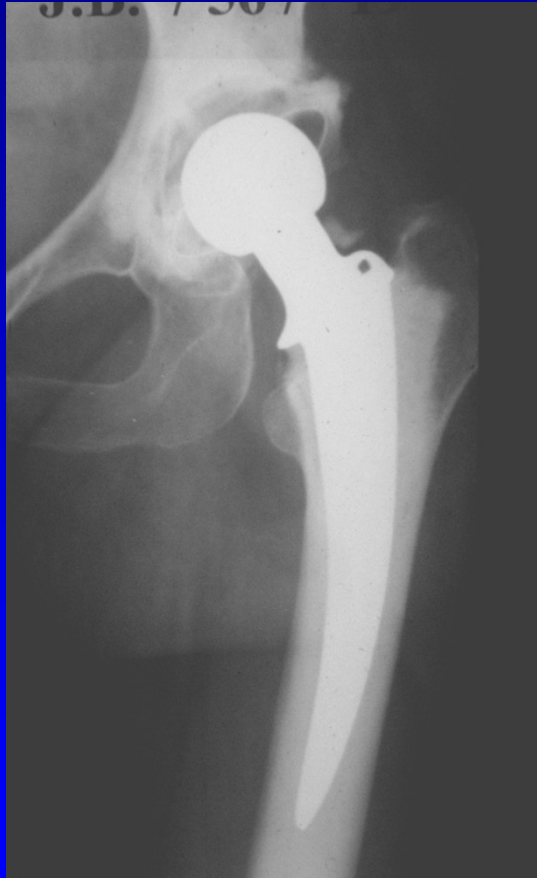- Cementless

- Both components fixed without cement
- age below 65 y.o.
- Good bone quality
- Contraindication for bone cement (allergy, right ventricle function)
- Best implant survival
- The most expensive

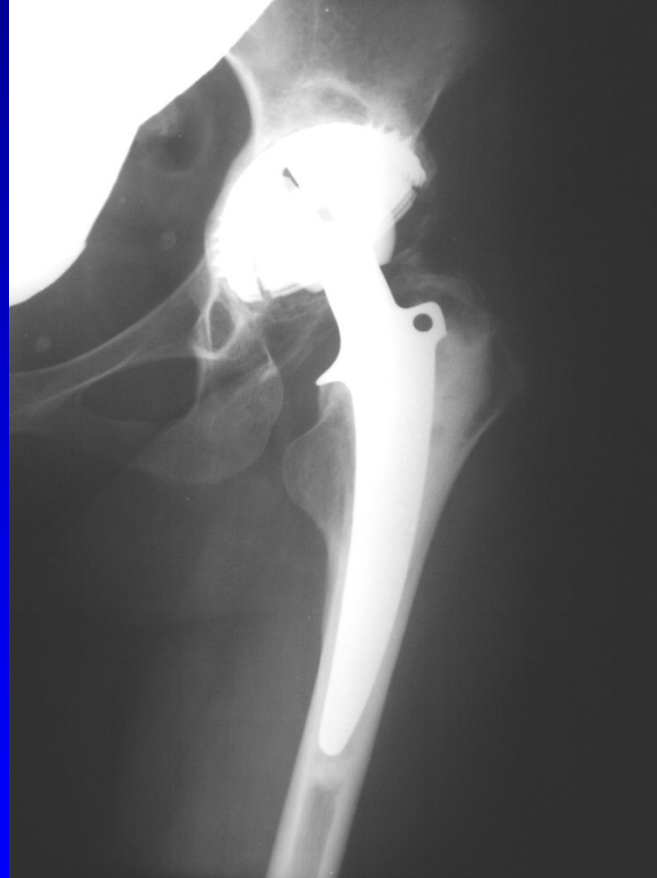

Fixation in the bone

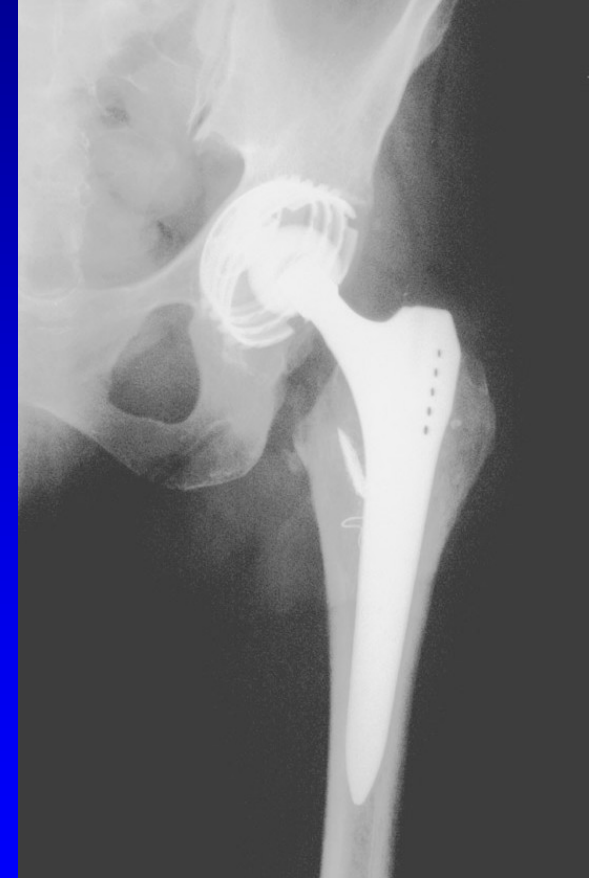Types of THA



Cemented



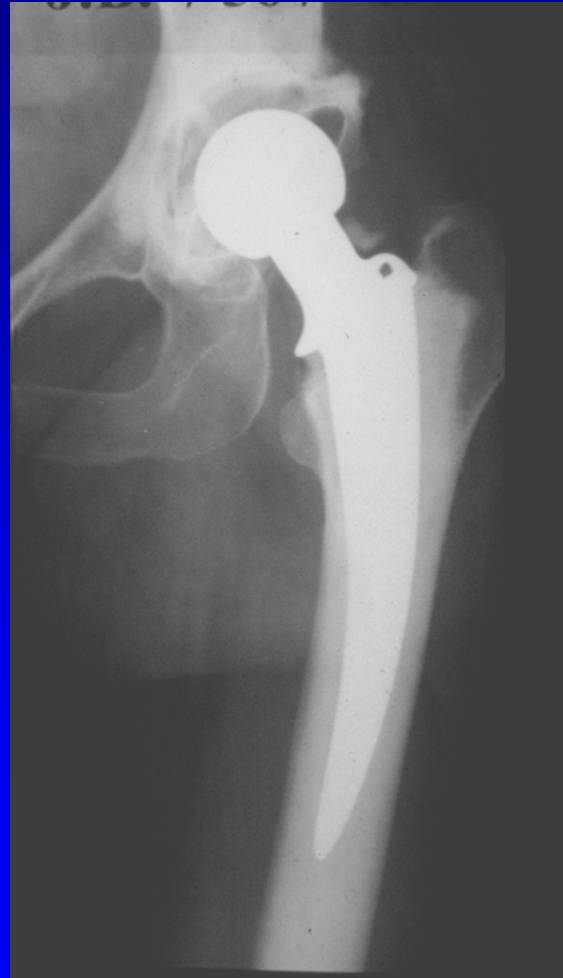Hybrid



Uncemented

Primary THA

Polyethylene cup

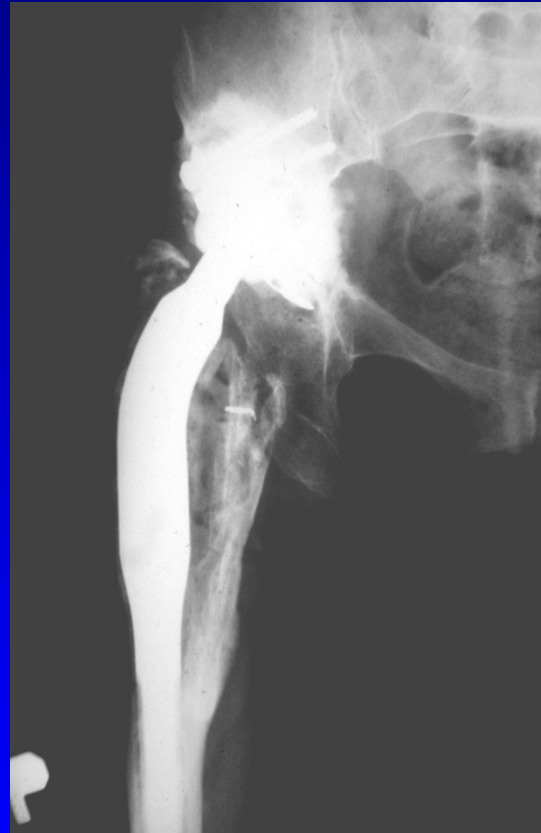
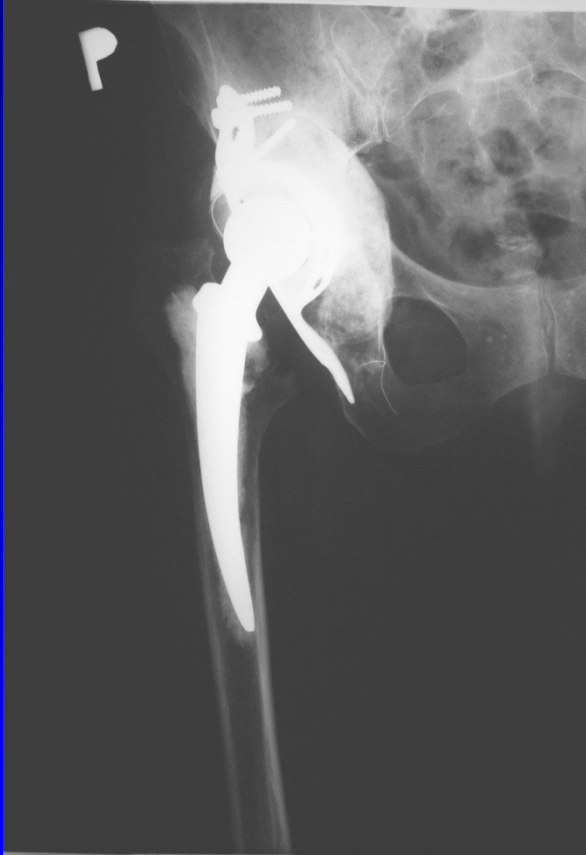
Head

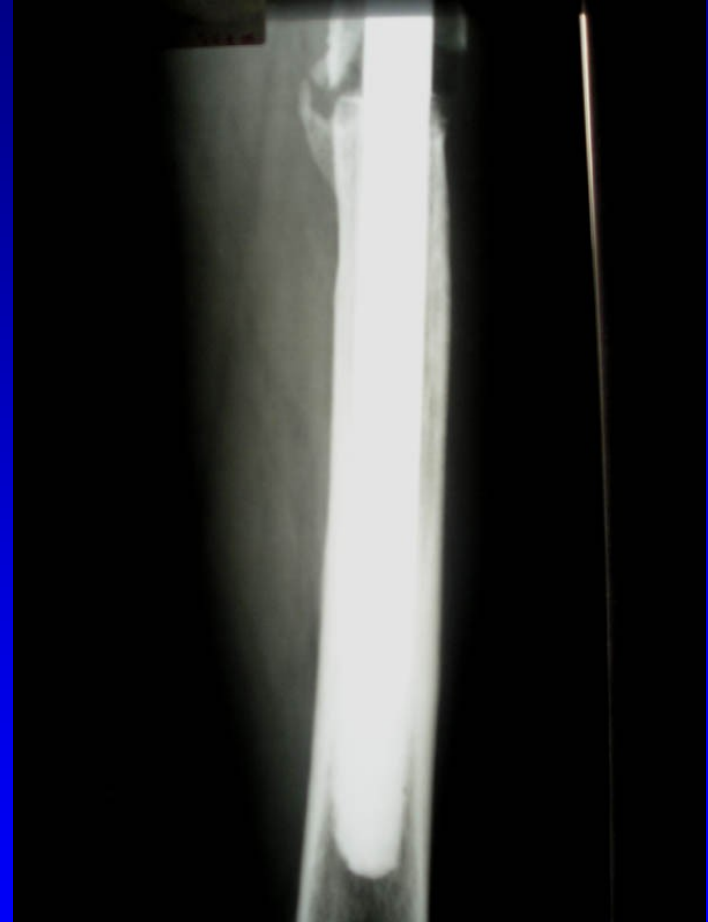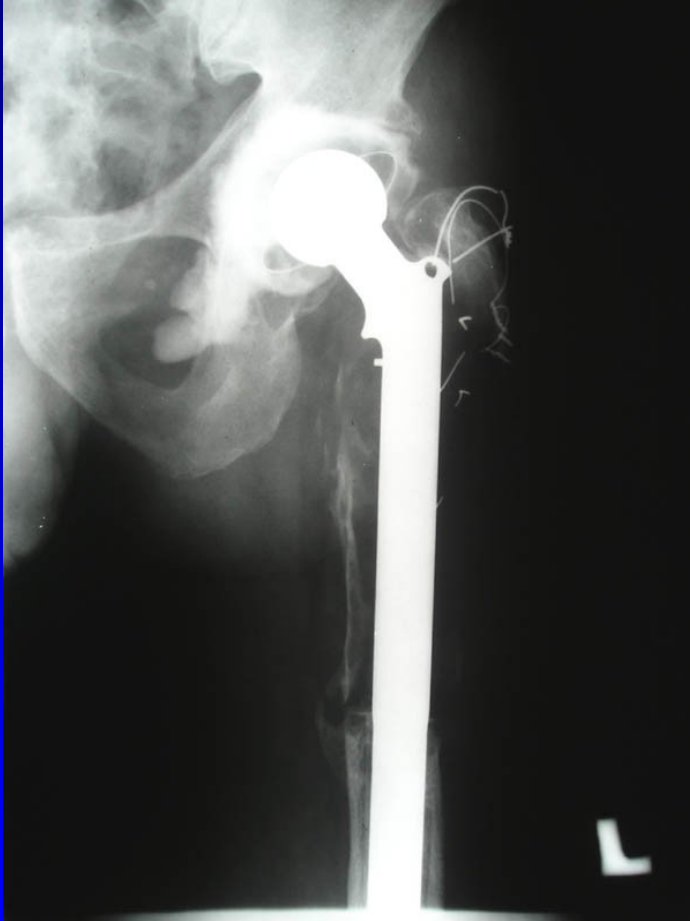Neck

Stem

Revision THA

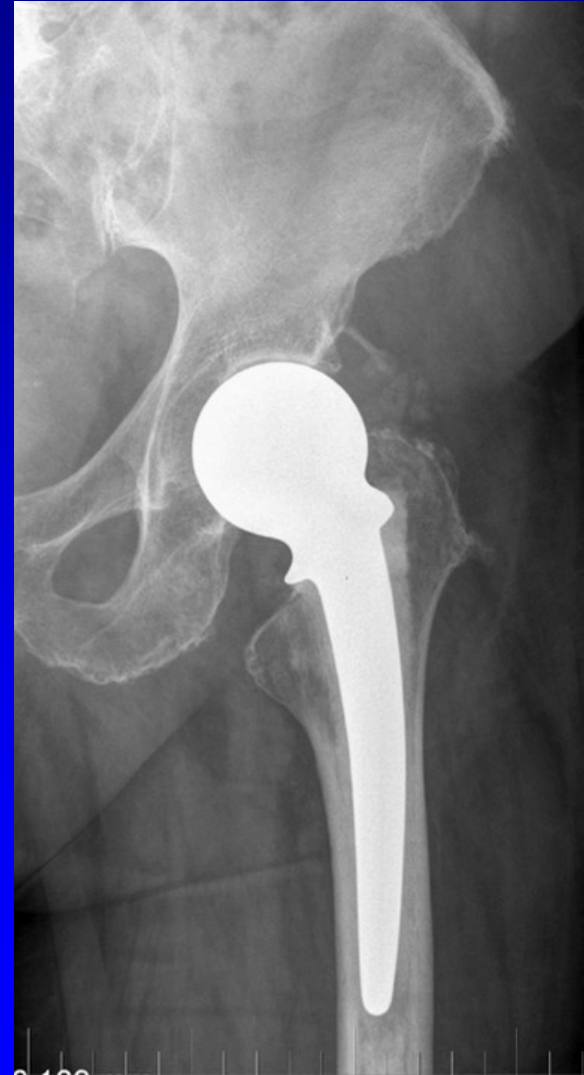
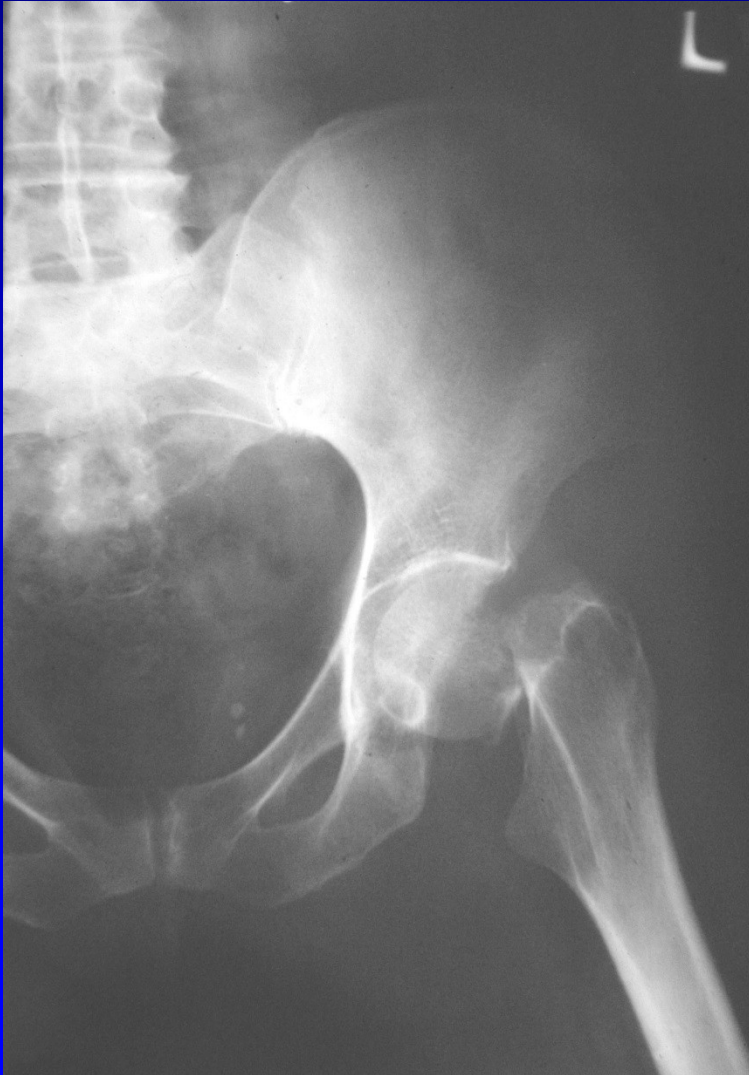
For tumors



Femoral head prosthesis

Thompson



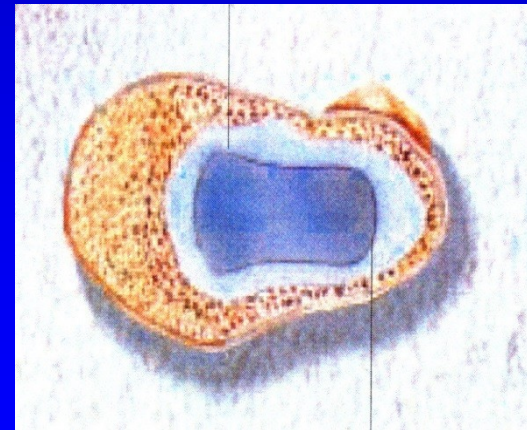
Metal

- Steel
- Cobalt - chromium-molybdenum alloys
- Titanium alloys

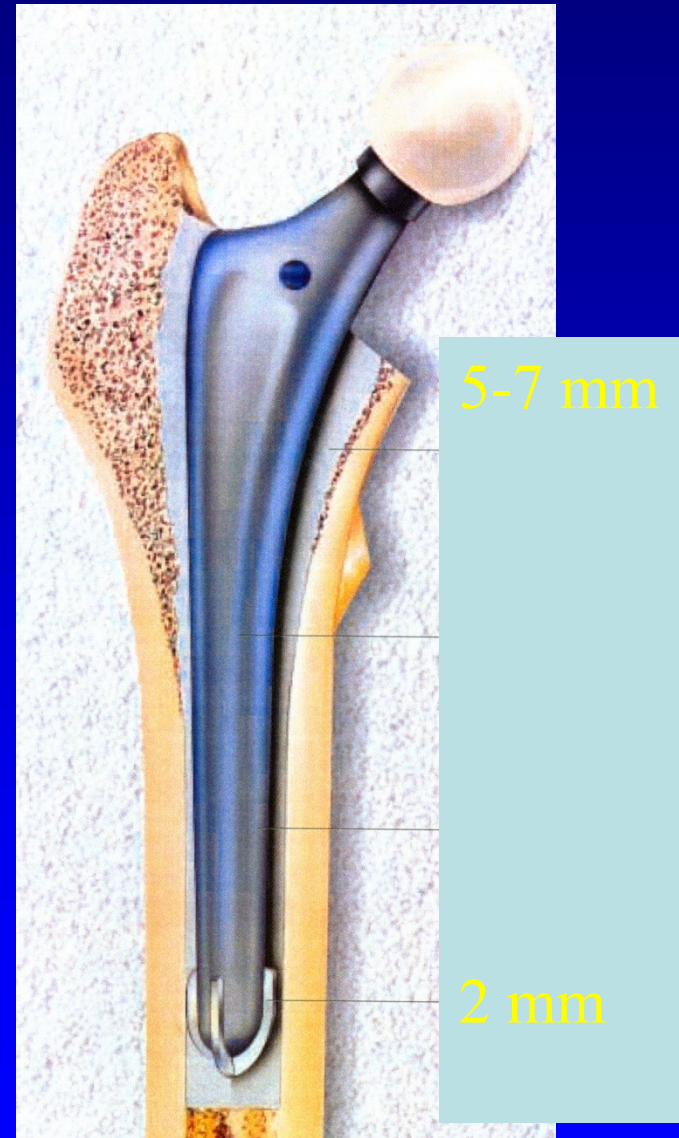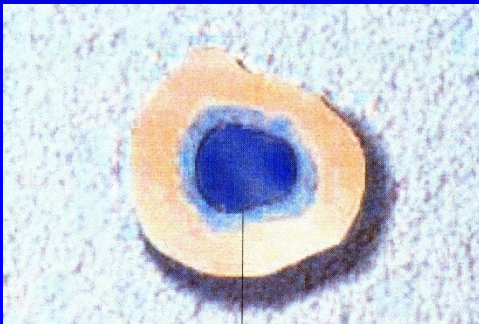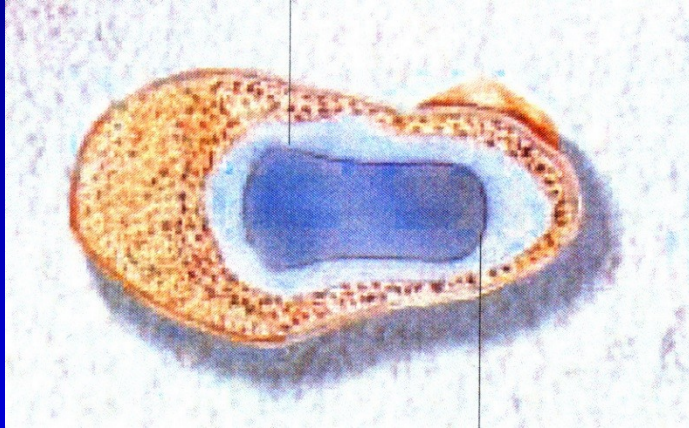


Bone cement

- Polymethyl methacrylate (methyl ester metacrylic acid)
- Powder polymer, liquid monomer
- Exothermic response
- Stabilisation of the implant in 10 minutes
- Cytotoxic effect
- Protein coagulation (thermal + chemical)
- Microembolisation

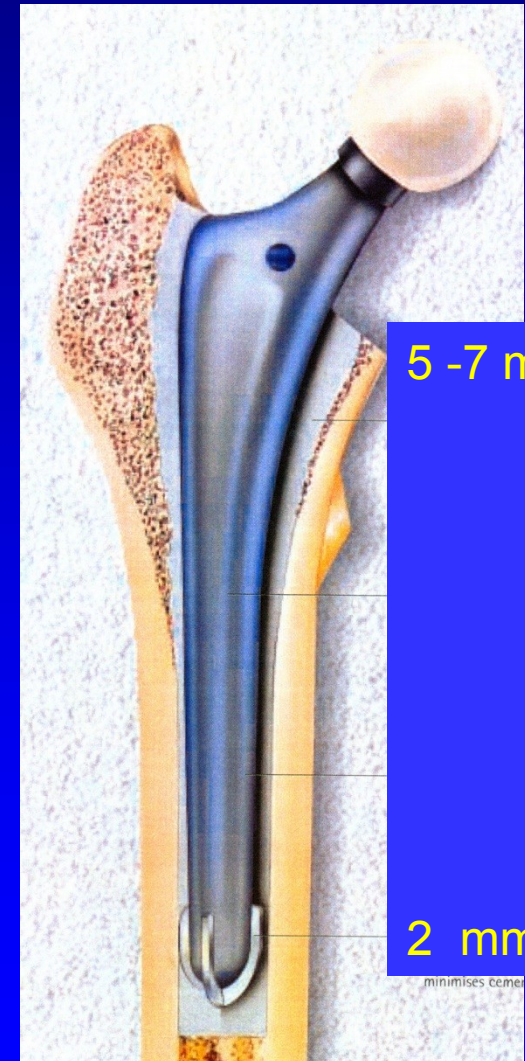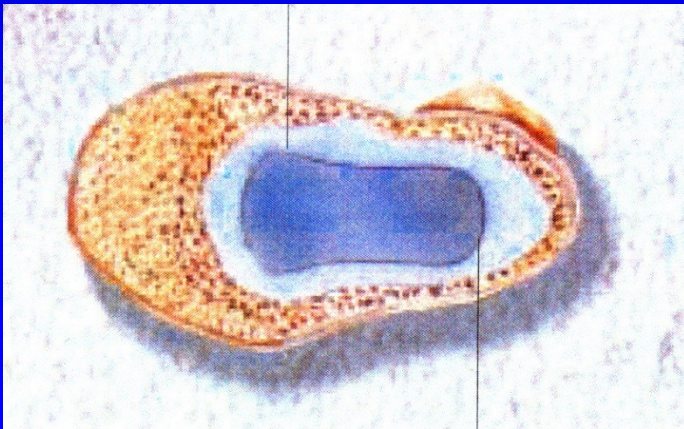


Cemented THA




Cementing technique

- Interdigitation into bone trabeculae
- Regular layer:
 - under the cup 3 mm
 - around the stem 2- 7 mm



Polyethylen

- UHMWPE :
ultra- high- molecular-
weight- polyethylen



PE

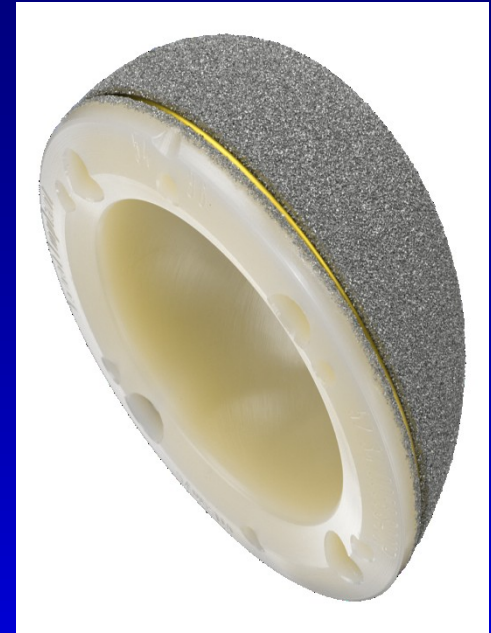
- Polyethylen
 - Longest used material for cup
 - Viscoelastic
 - Plastic deformation (cold flow)
 - Higher wear rate
 - Oxidative degradation



PE

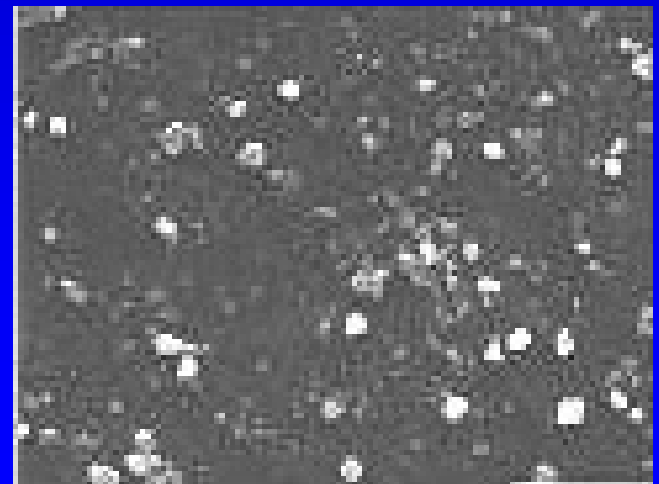

- Polyethylen

- UHLMWH - Ultra high molecular weight polyethylen
- HXLPE – cross - linked
- PE + vit E
- Aim:
 - Wear reduction
 - Oxidative degradation reduction
 - Keeping elasticity modulus



Polyethylen

- Linear wear 0,1 - 0,2 mm / year
- Volumetric wear 0,3 - 10 mg / year
- Cold flow – plastic deformation
- Abrasion and delamination
- Oxidative degradation
- Modern trends:
highly crosslinked polyethylen
- with vitamin E




PE wear particles, 1 um

XPE- highly-cross-linked polyethylen + vitamin E



Antioxidant

Increases mechanical properties
of PE



Ceramic

- Corundum or Zirconium AL_2O_3
- Smooth surface
- Less wear: 0,005 - 0,15 mm / year



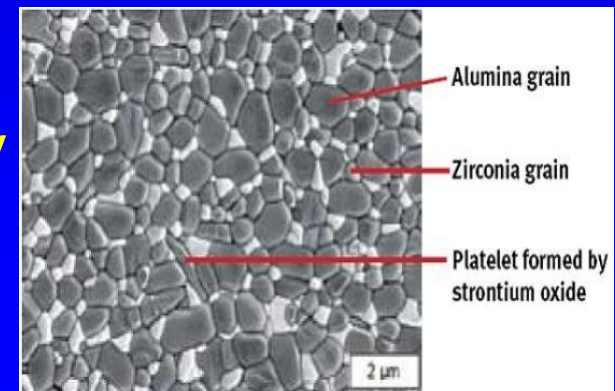
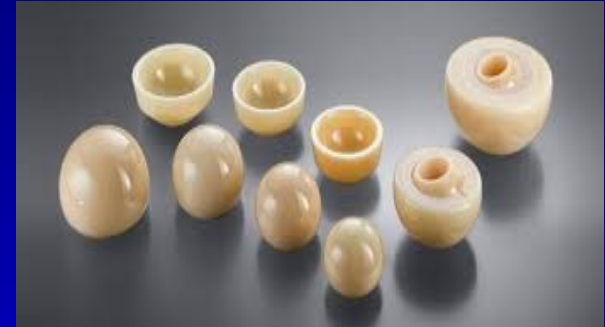Materials – ceramic

- Pure aluminium oxide - Al_2O_3 - corundum
- ZrO_2 – zirconium oxide
- Extremely smooth surface, minimal friction ratio
- An order of magnitude rate compared to metal
- Fragile
- Expensive



Materials – ceramic

- Biolox forte
 - Pure Al_2O_3 (yellow)
- Biolox delta
 - Stronger
 - Lower grain size – even more s
 - More homogenic
 - Pink
 - Al_2O_3
 - ZrO_2
 - Zirconium oxides stabilized by






Materials – Oxinium

- Zirconium oxides
- Combines properties of alloy and ceramic
- 2x harder than ceramic
- Abrasion and scratch resistant
- Fracture resistance
- Trace amount of Ni only (hypoallergenic)
- 20% lighter than CoCr



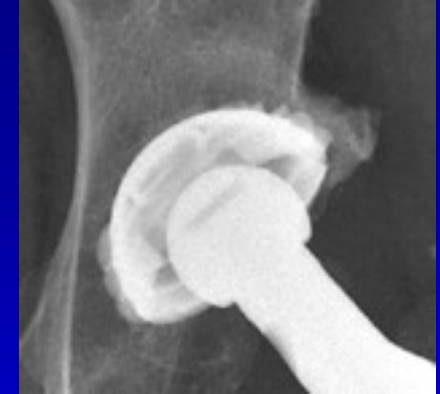Contact : head - cup

- Metal- polyethylen
- Ceramic- polyethylen
- Ceramic -ceramic



Diameter of the head

22, 28, 32, 36, 38, 40 mm

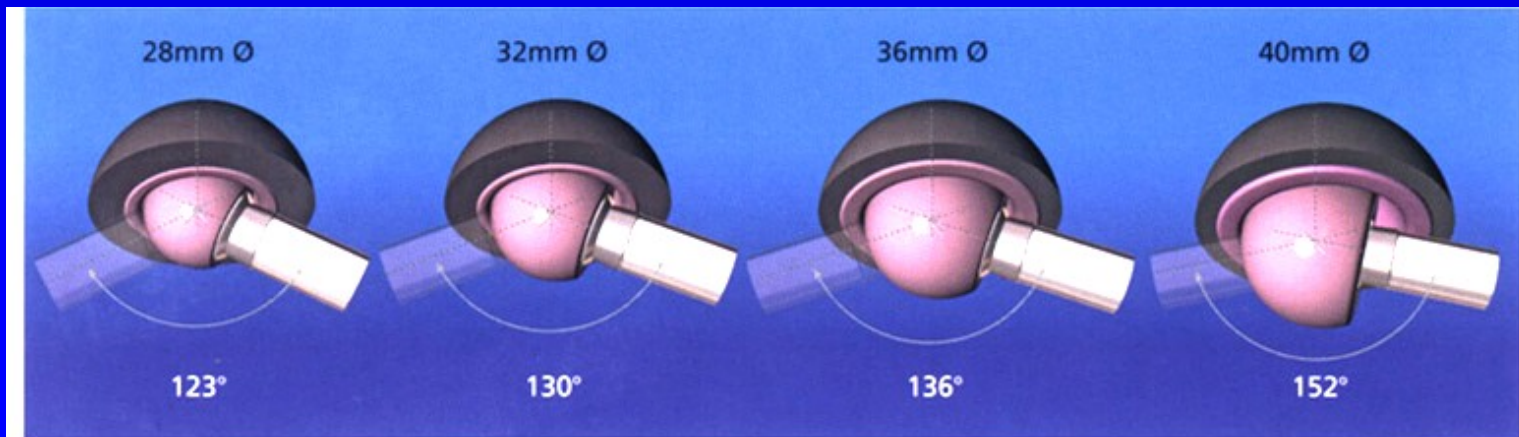


Advantage of 36 mm head:

Higher stability

Greater range of motion

Less impingement neck- edge of the cup



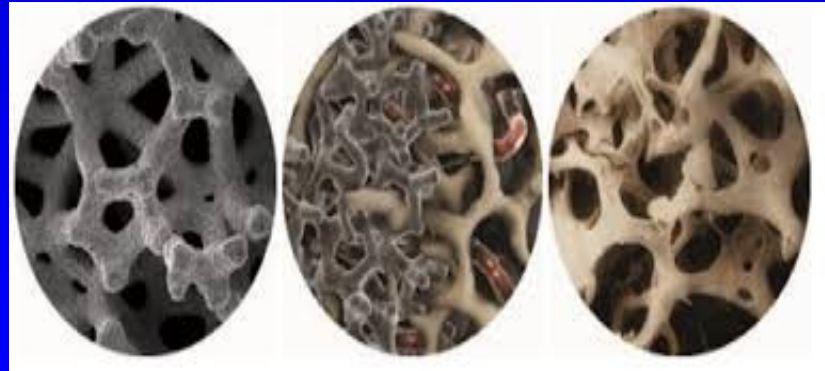
Acetabular component

- Cemented: polyethylen
- Noncemented: metal- backed
with PE insert
with ceramic insert



Materials

- Cementless implants requirements – bone adjacent surface
 - Trabecular titan
 - Trabecular tantal
 - Hydroxyapatite surface



Hydroxyapatite surface

Bioactive

Osteoconductive

Chemical bonds bone- hydroxyapatite



Surface of cementless implant

Macroporosity

Microporosity

Pores on the surface $50\mu\text{m} - 600\mu\text{m}$

Pores above $800\mu\text{m}$ - fibrous tissue

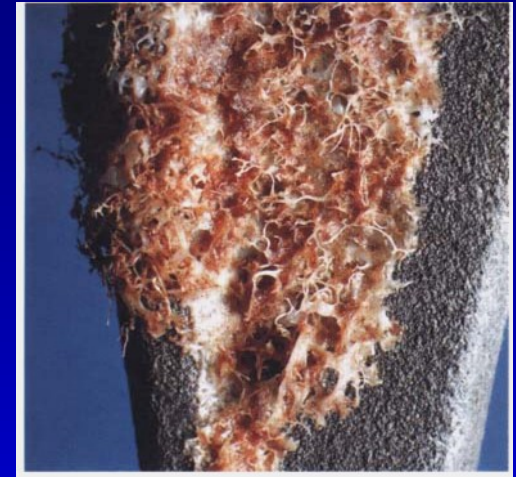Adhesive surfaces:

Trabecular Metal


Trabecular Titan

Pores $300\mu\text{m}$

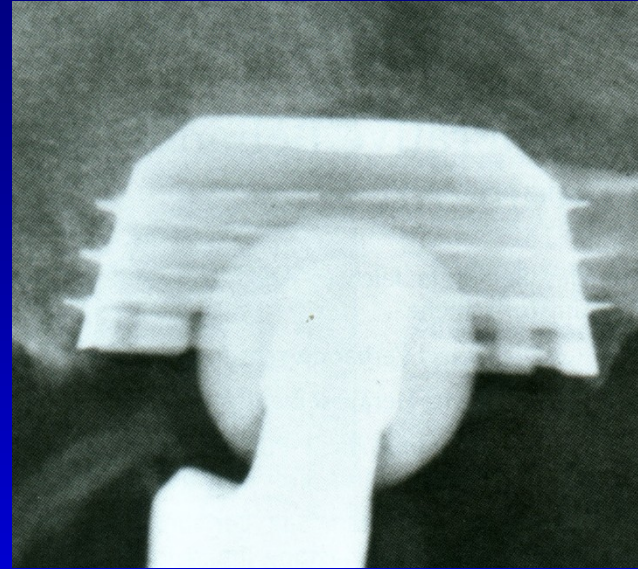
High initial stability



Uncemented cup



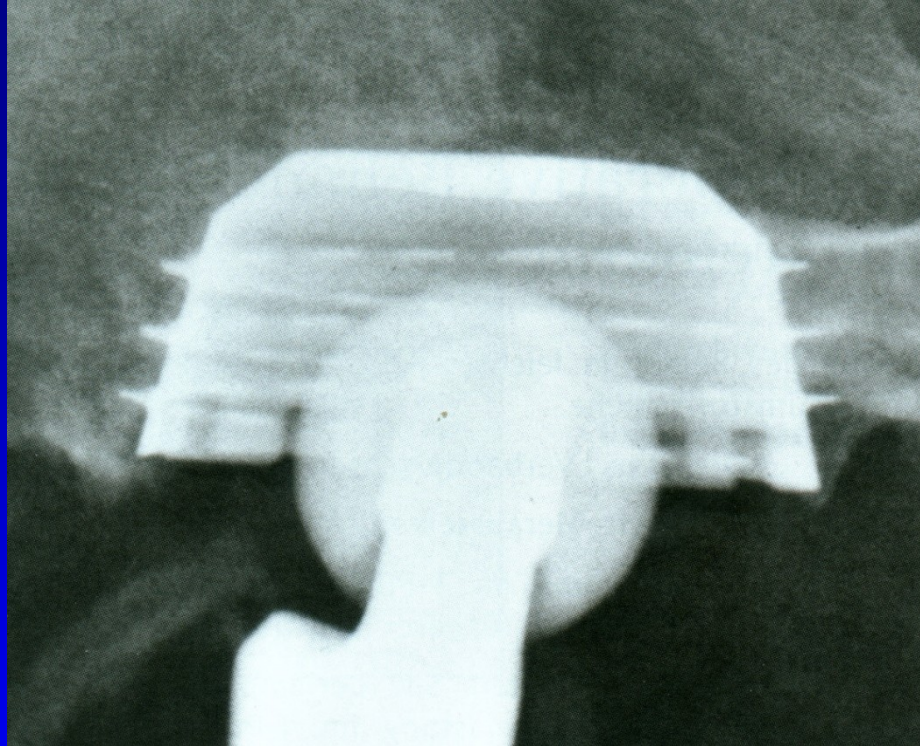
Press - fit



Threaded

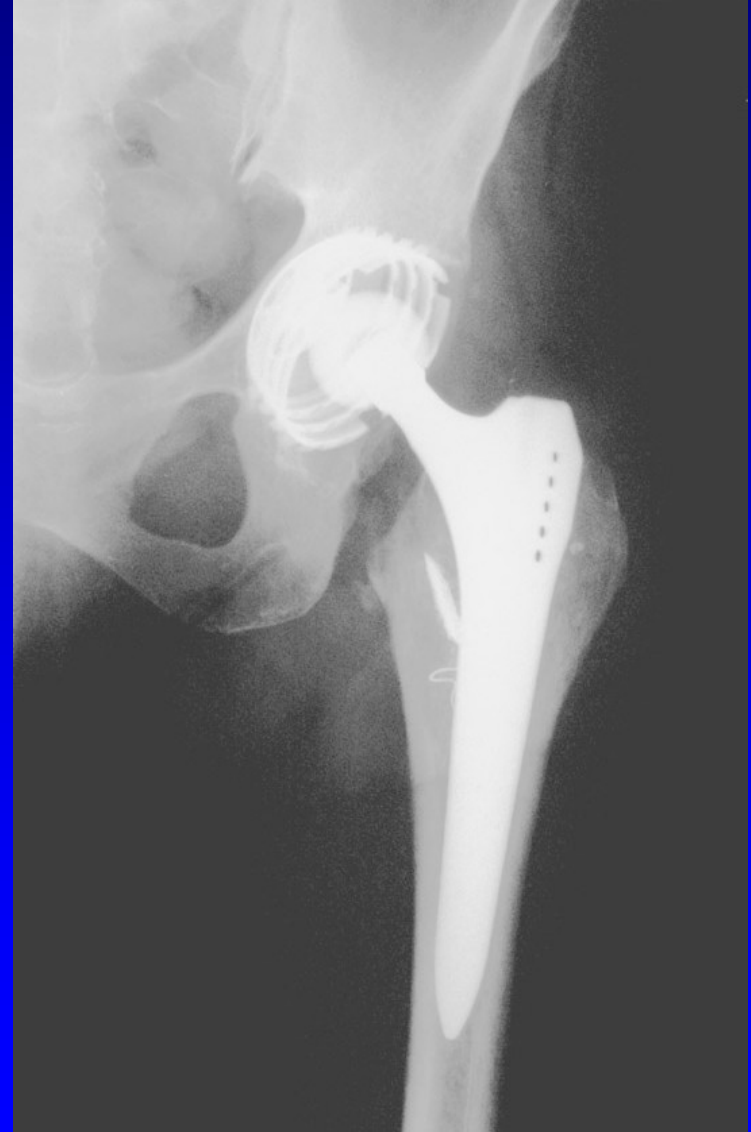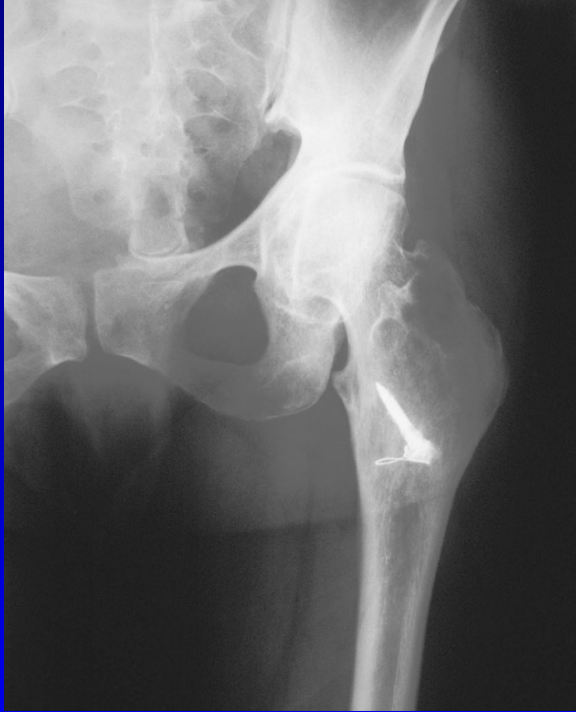Primary fixation: mechanical anchorage in the bone

Uncemented cup



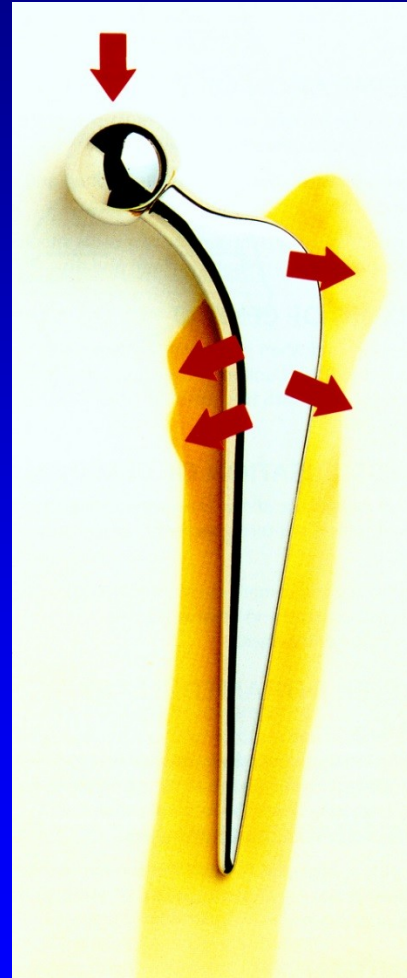
Secondary fixation: osteointegration of the implant on the surface of bone

Bicon – Zweymüller cup

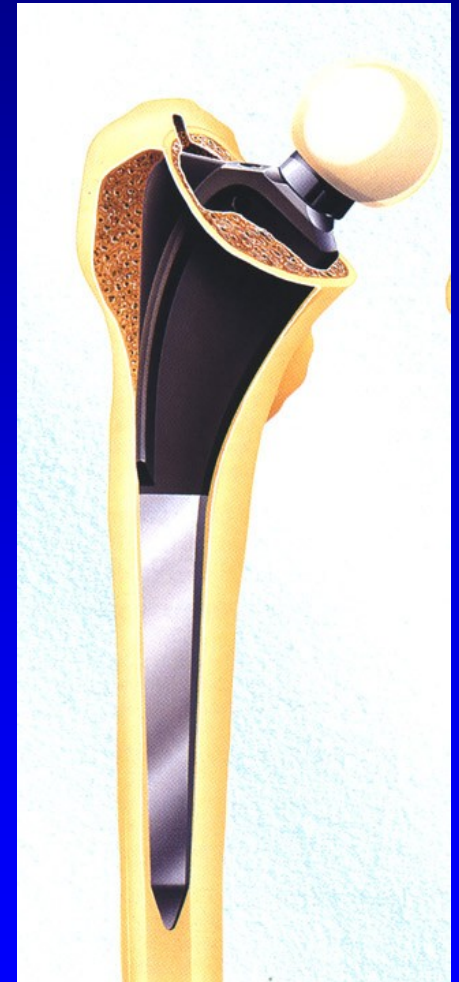

Femoral component

- High polished surface for cementing fixation
- Porous surface for cementless fixation

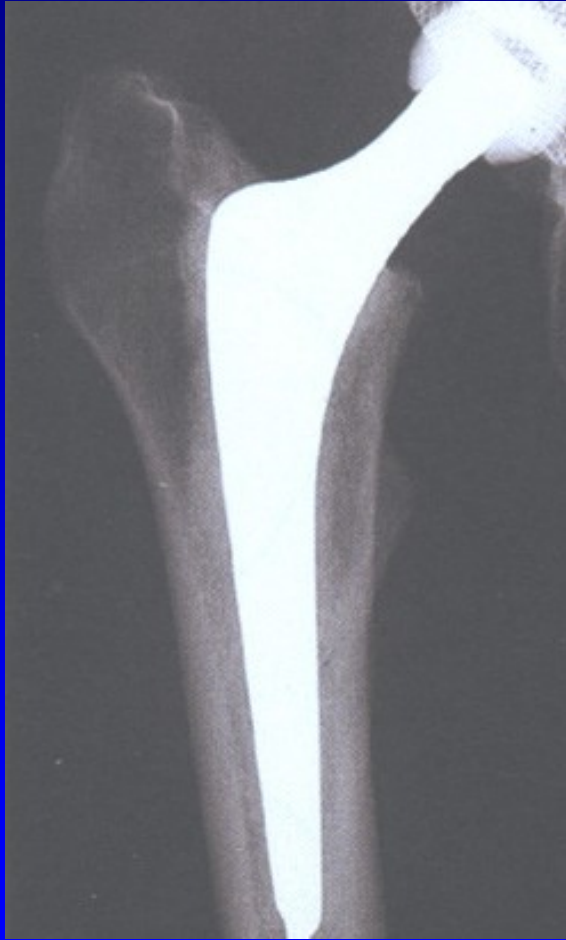


Cemented



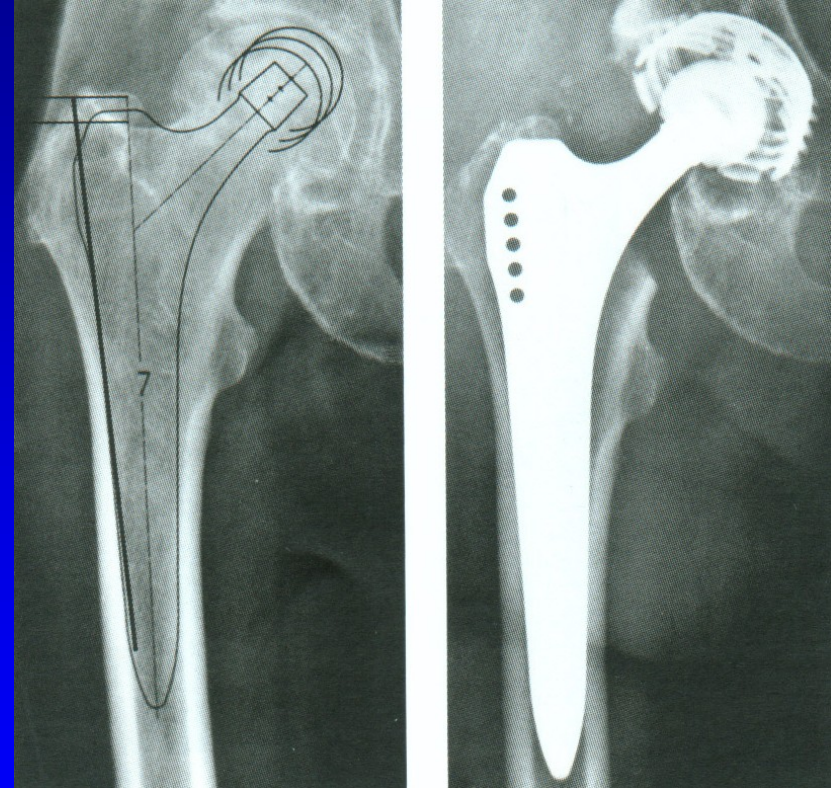
Cementless

Morscher, Spotorno MS – 30 stem cemented

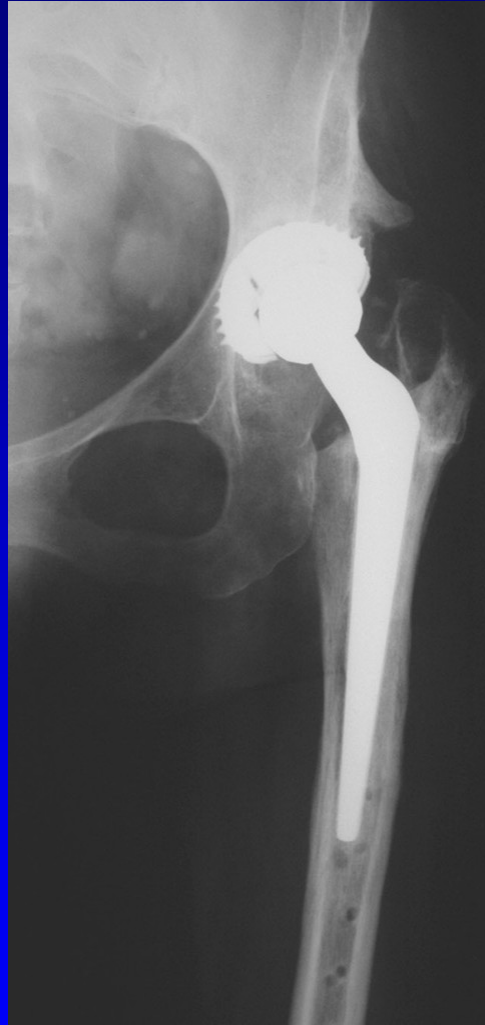


Uncemented stem

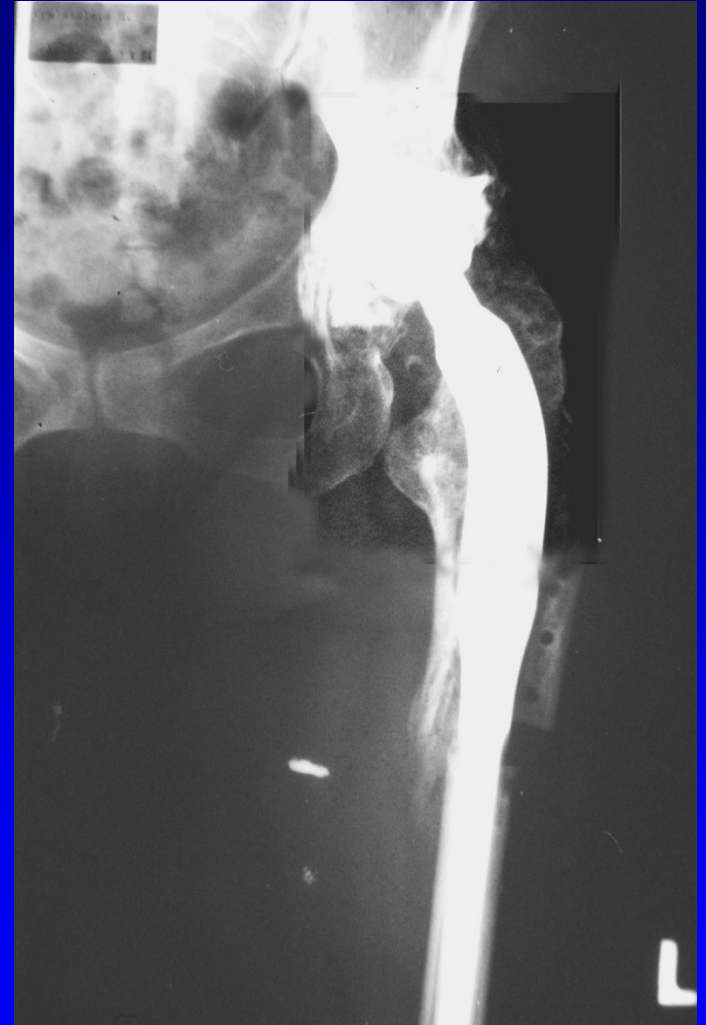- Primary fixation:
- Mechanical anchorage in the bone
- Secondary fixation of the implant on the bone surface



Uncemented stems



Proximal fixed

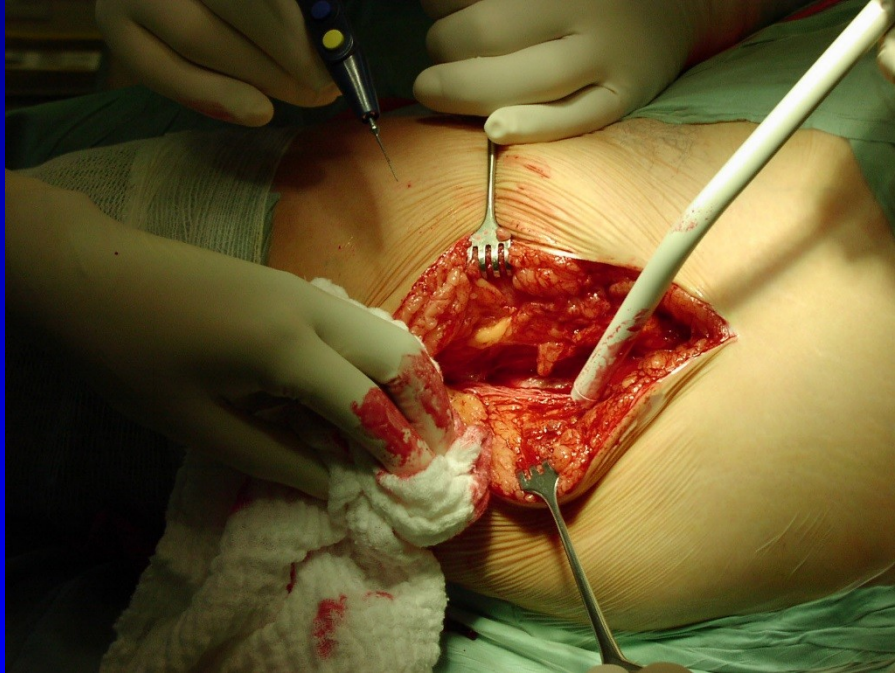


Distal fixed

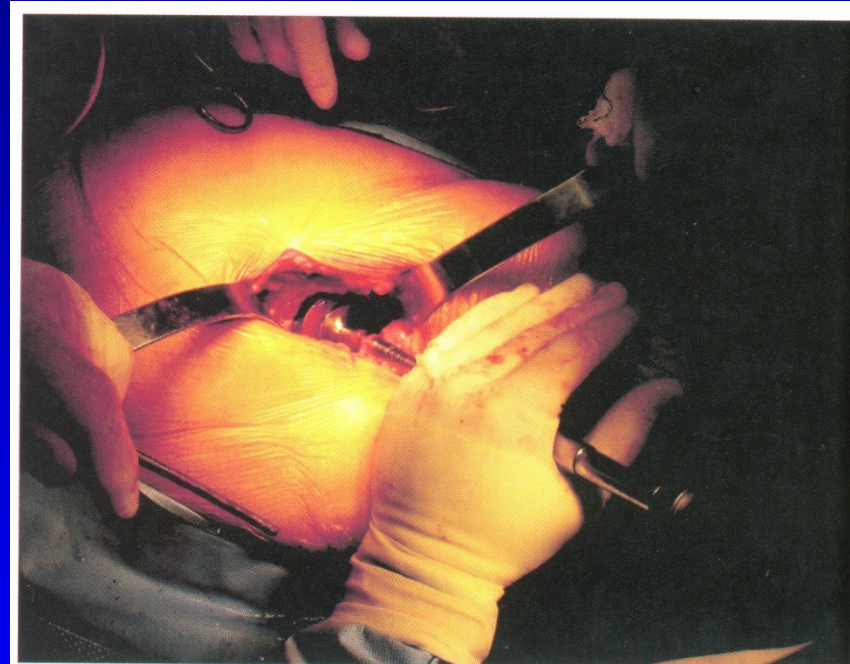
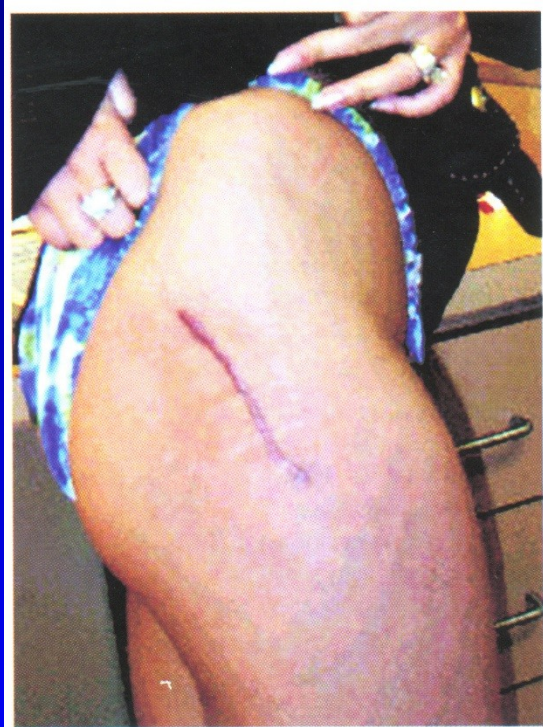Indication scheme

- Uncemented to 60 y.
- Hybrid 61 - 70 y.
- Cemented over 70 y.

Approaches



MIS- mini invasive surgery



Physiotherapy

Day:

1. Sitting, drainage ex
2. - 5. walking
6. + stairs
- 7-21 – in physiotherapy dpt.
- 3 months- spa resort

Full weight bearing. Cemented THA after one month
Uncemented after 12 weeks

Fast track physiotherapy, discharge 3-4 days, home care

Post op. management

- ITU - one day
- Hospitalisation at orthopedic ward for 5 days
- Verticalisation the first post op. day
- Complex rehabilitation protocol, rehabilitation nurse obligatory
- 6. day – transfer to rehabilitation ward
- Spa resort in CZ covered by public health insurance in 3 post op. months
- DVT prevention – 6 weeks
- Prevention of dislocation of THR- no adduction, no deep flexion, no axial extremity traction!
- Modern trends: Shortening of inpatients period (risk of nosocomial infection, economic aspects)
- Fast track physiotherapy
- Outpatient surgery?

Follow up

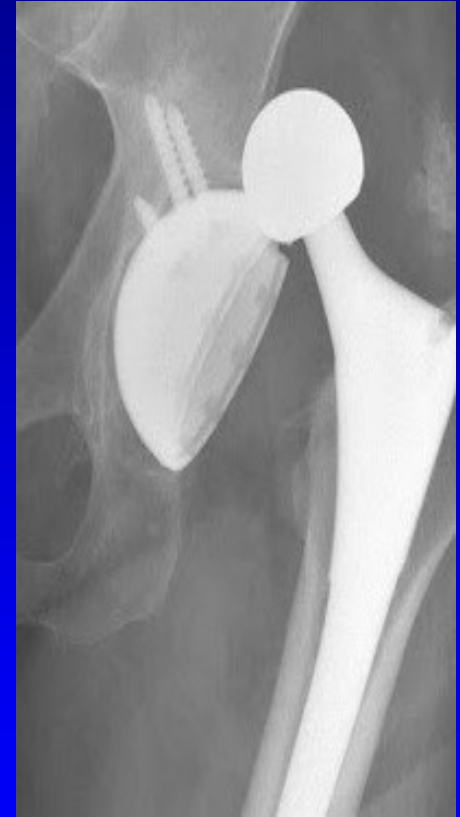- Standardized
- First check up: by orthopedical surgeon in 6 weeks (X ray included)
- Second check up: in 3 months, then 6 month
- Every 2 years (X ray included) if no problem present
- EDUCATION
 - Activity, limitation and régime with THR
 - PJI prevention
 - Urgent check – up if suspected PJI

Complications

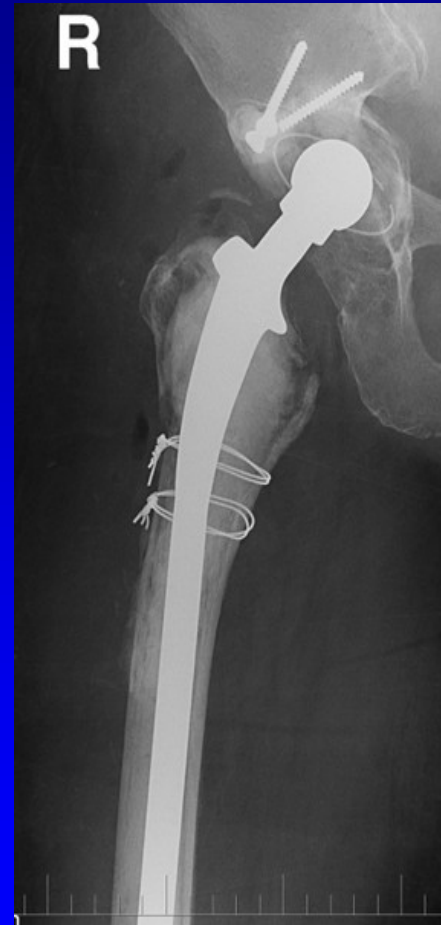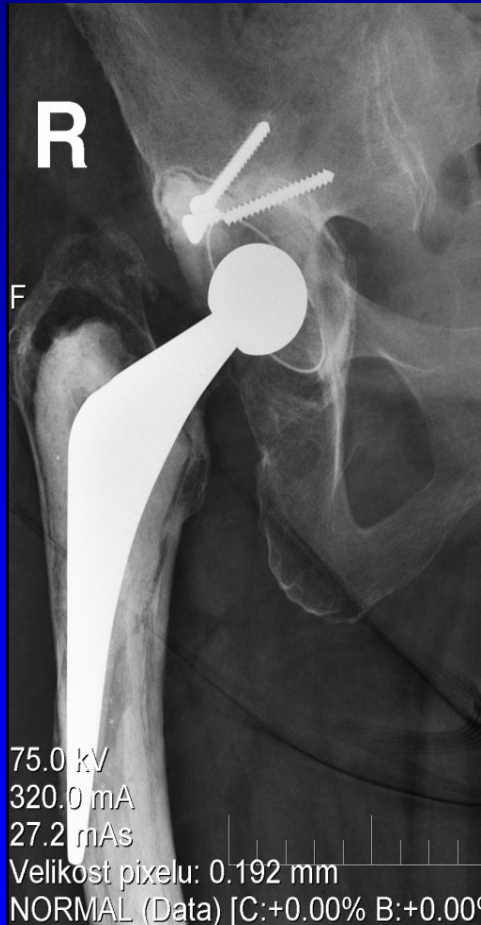
- Peri and early post op. morbidity and mortality
 - Nervous and vascular injury
 - Blood loss
 - Perioperative fracture
 - Hip displacement (luxation)
 - Pulmonary embolism
 - IM
 - General decompensation
 - Development of delirium

Complications

- THR dislocation
 - Shortening and (extra)rotation of extremity, pain, no active hip flexion
 - No active walking and no weight - bearing
 - Therapy:
 - Close hip reduction attempt. Hip orthosis with reduced ROM obligatory
 - Revision, identification of cause, solution
 - Longer head, stabilisation elements
 - Replantation



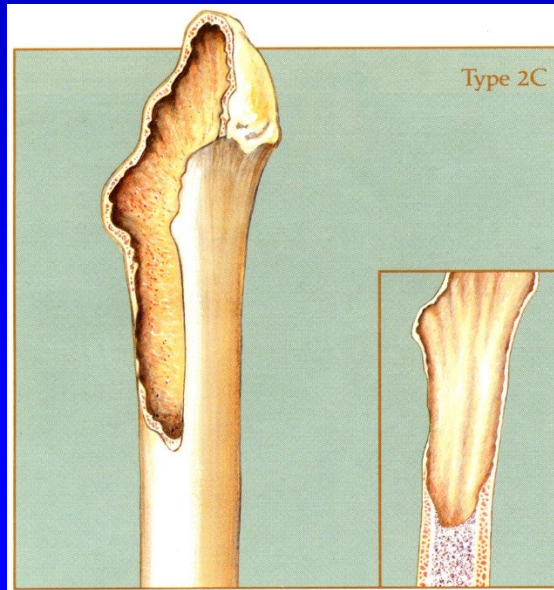
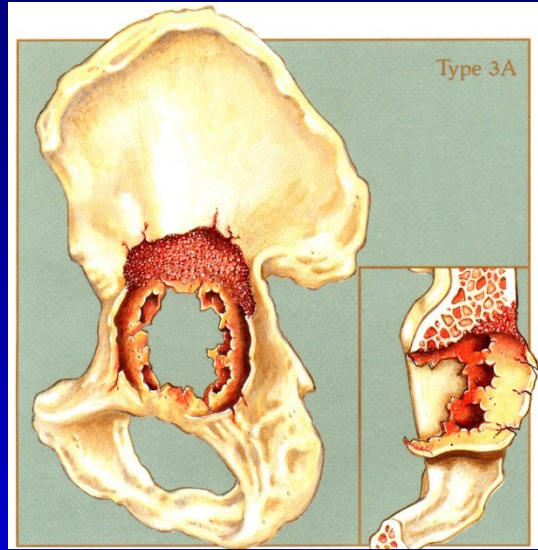
Aseptic loosening - therapy

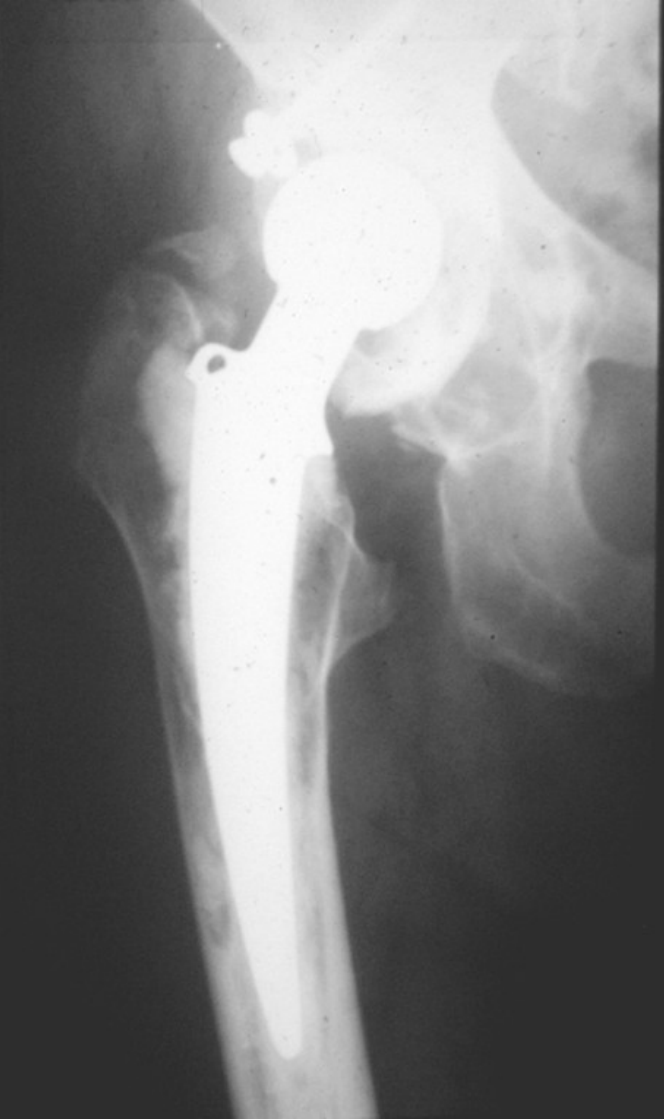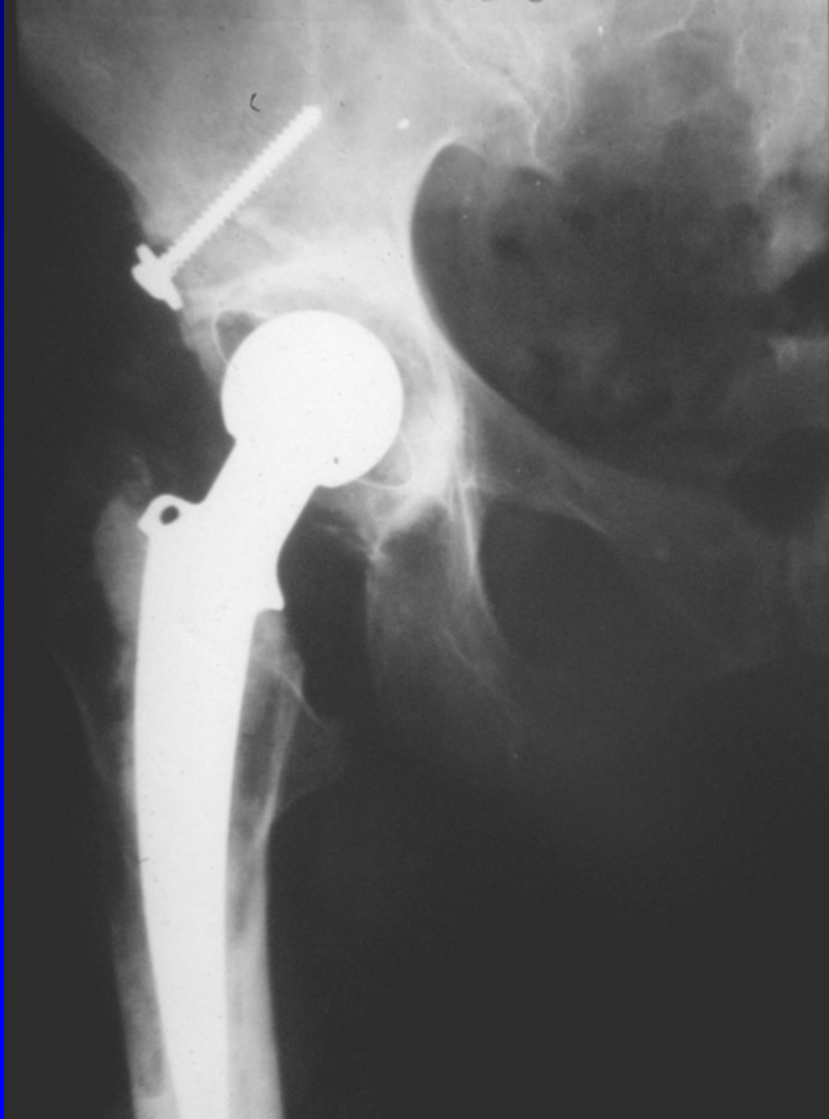


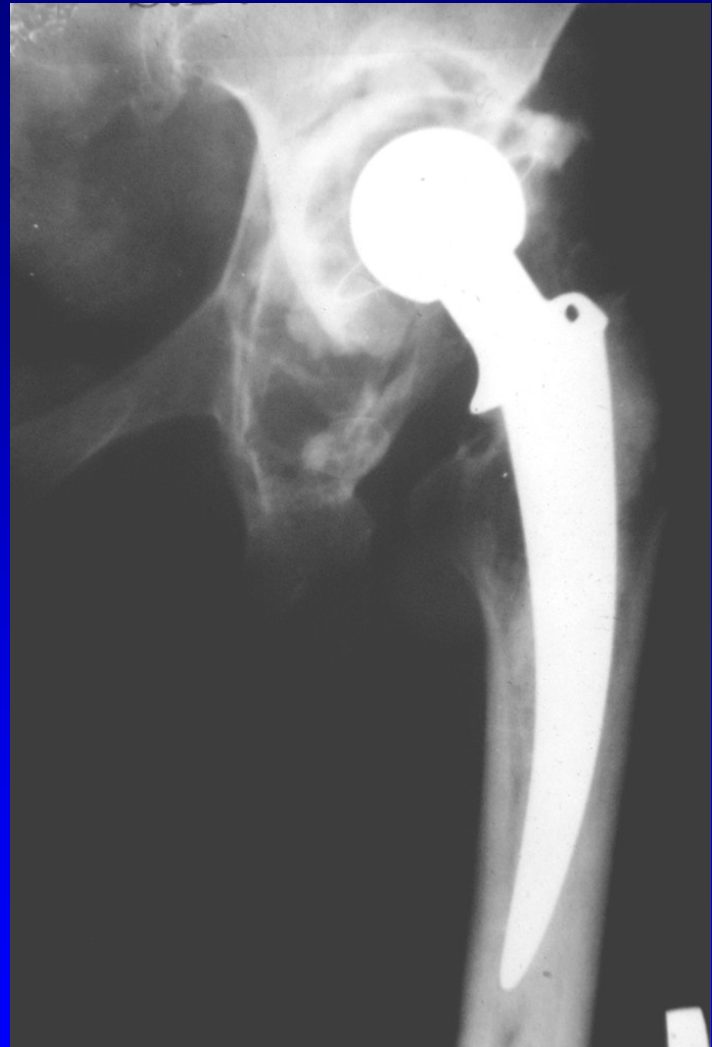
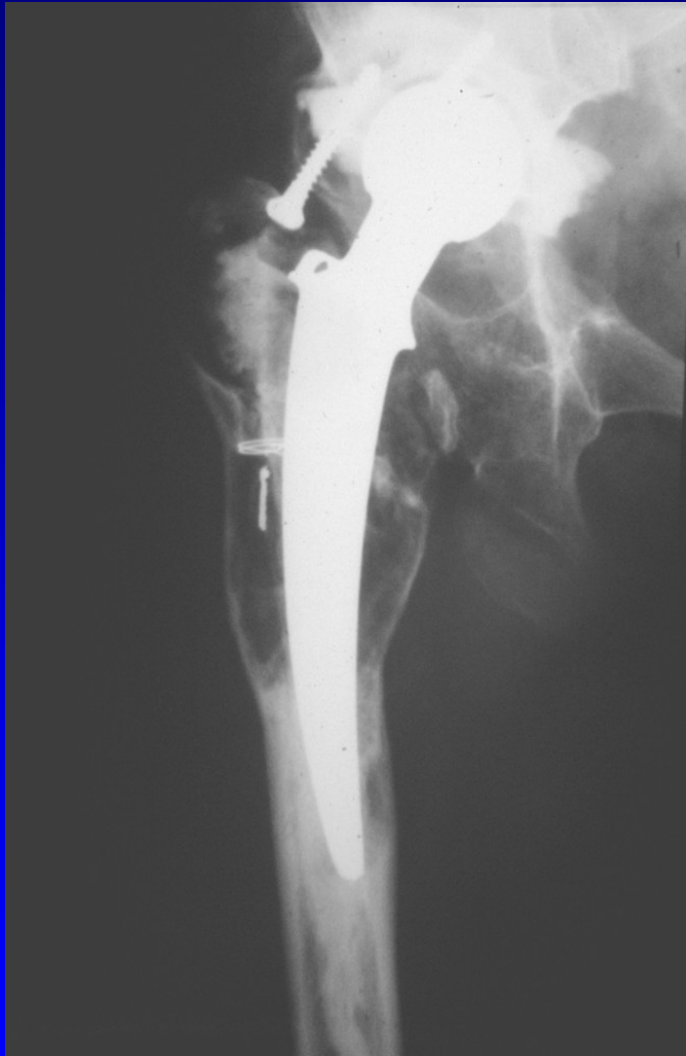Aseptic loosening - therapy

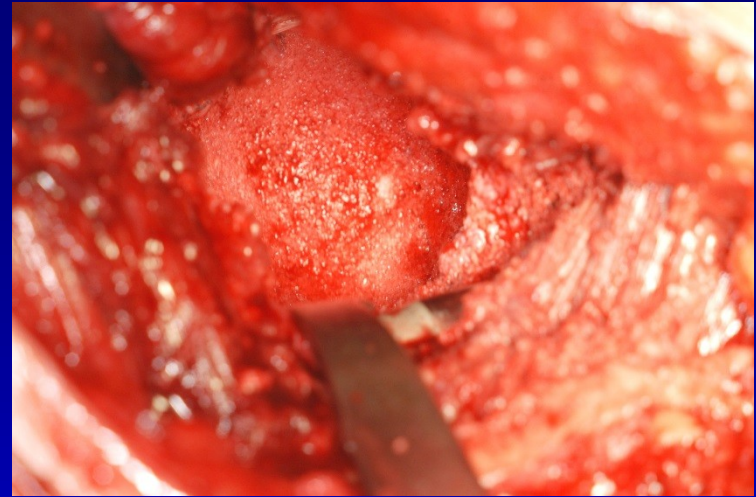
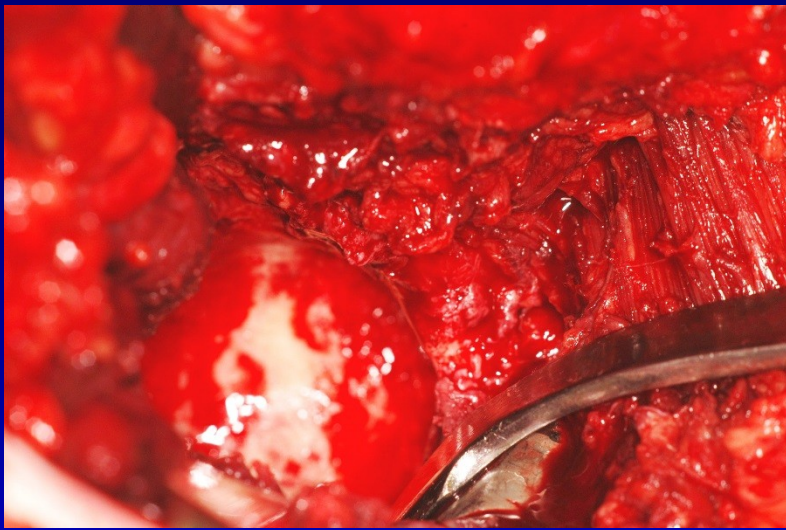
- Revision, reimplantation
- Revision systems, augments, spongionoplasty (allografts)...
- Double ATB combination – higher infection risk
- Higher complication rate
- Inferior outcome
- Lower ROM
- Longer no full weight bearing period (3M)
- Higher mortality
- Higher displacement risk ratio

Revision THA

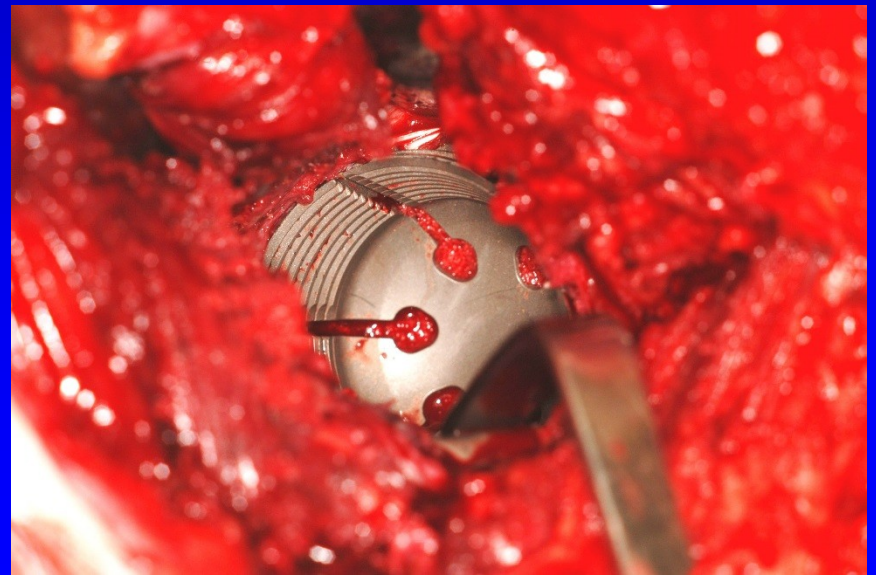
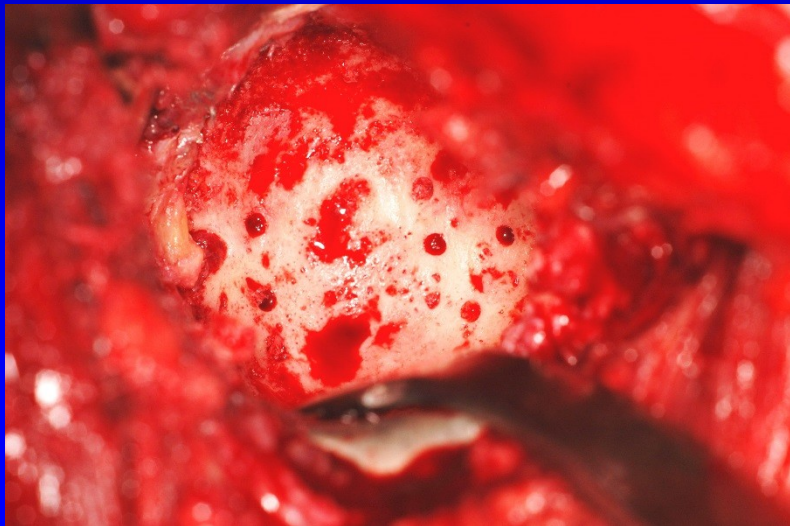




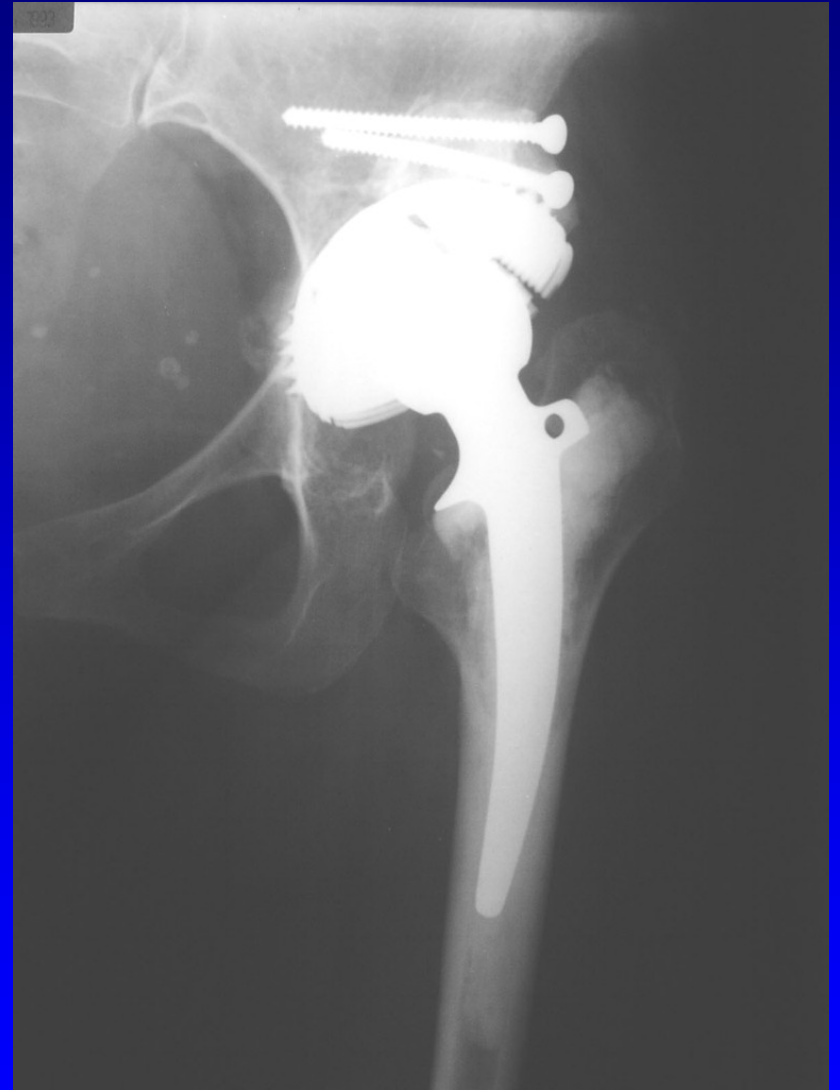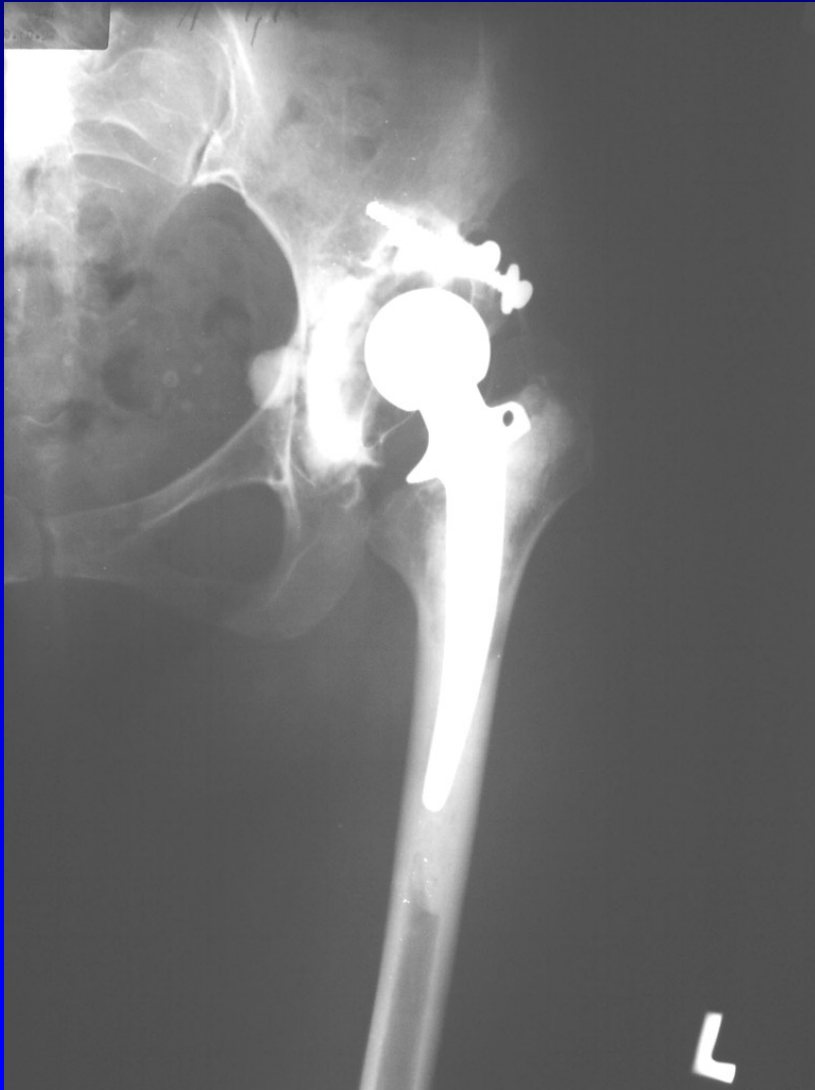


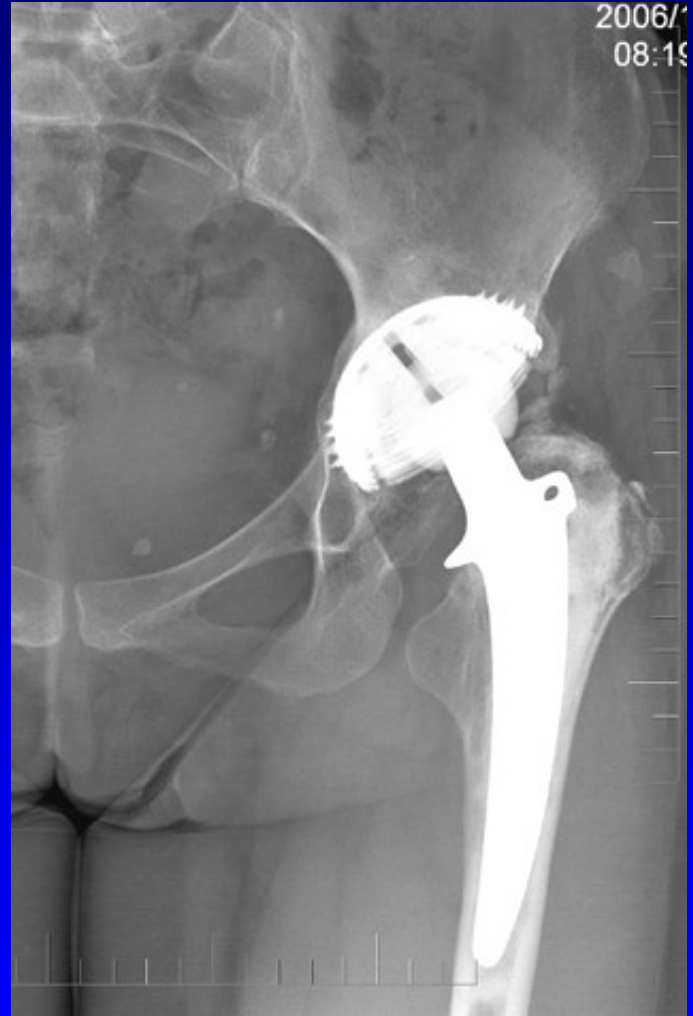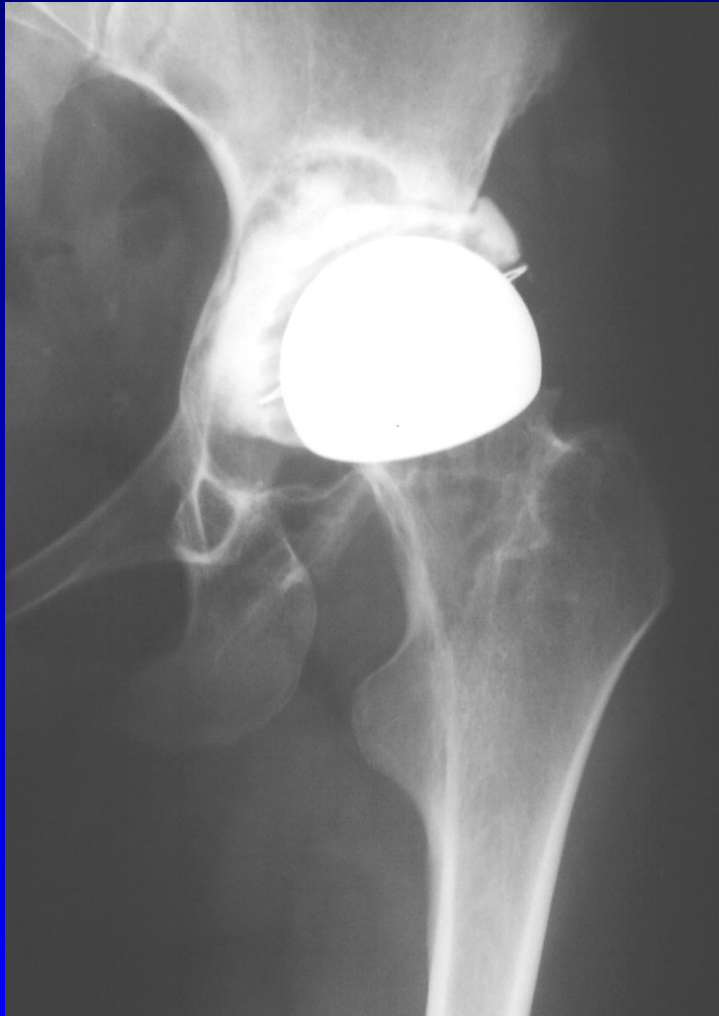


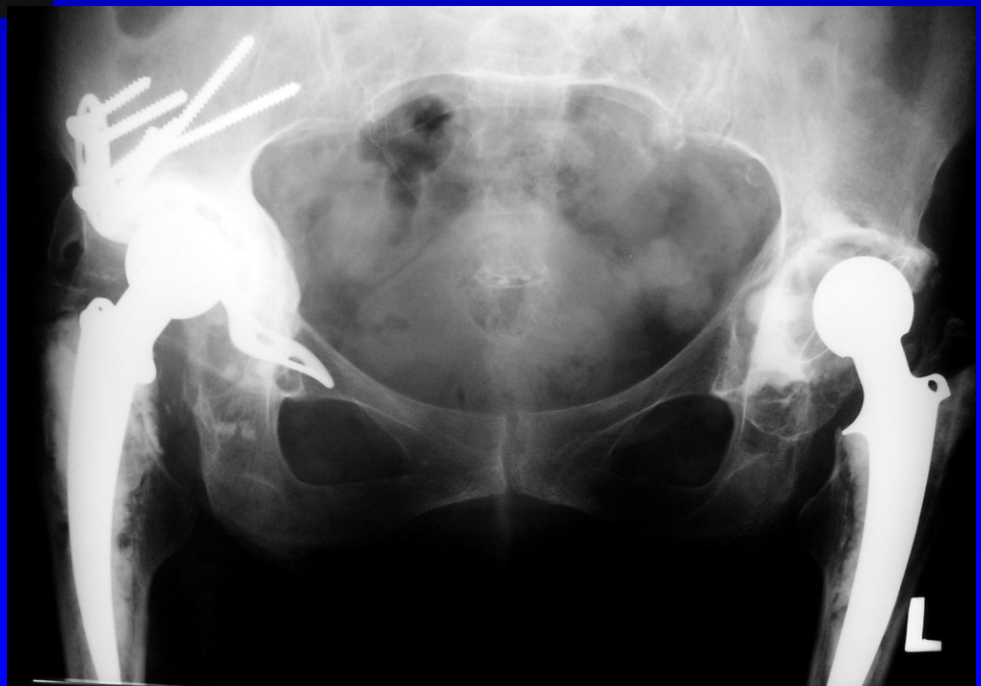
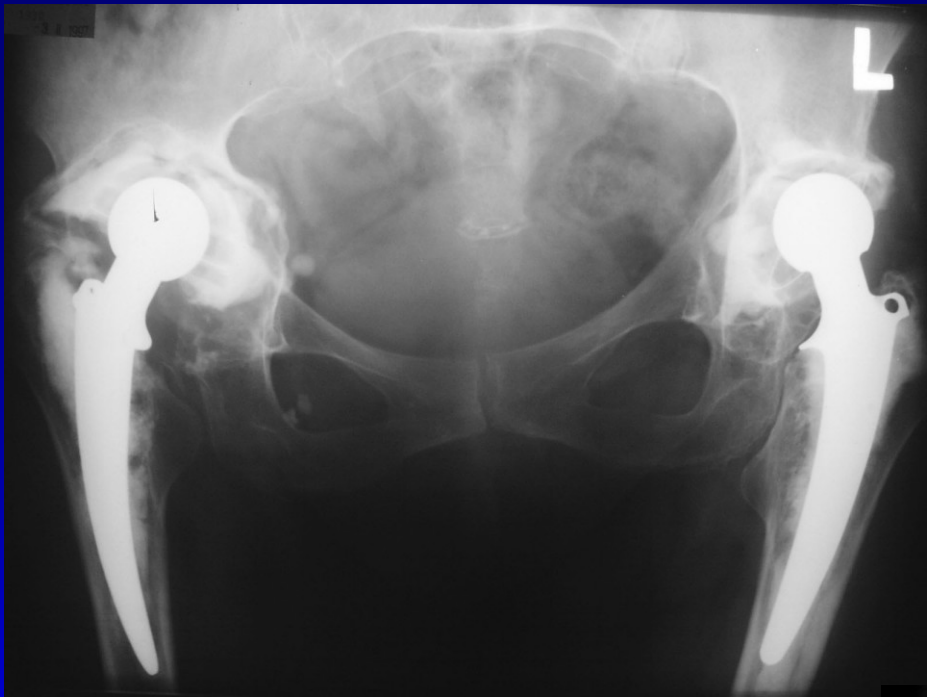Revision of the acetabulum



Revision THA

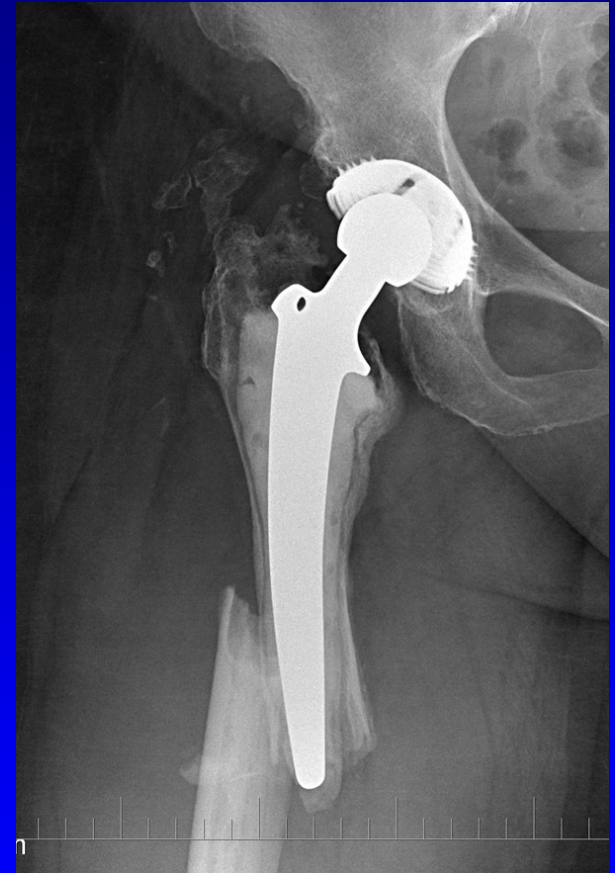





Periprosthetic fracture

- Relatively frequent complication
- Femur in the most cases, acetabulum rarely
- Older patients, worse general condition
- Osteoporosis, poor implant retention
- High mortality and morbidity rate
- High complication rate
- Demanding surgeries (experienced surgeon)

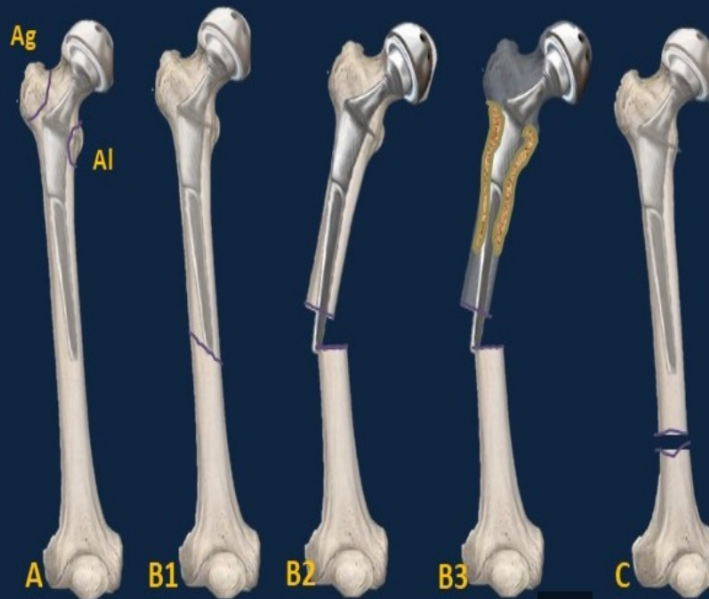


Periprosthetic femoral fracture - classification

Vancouver classification of hip periprosthetic fractures

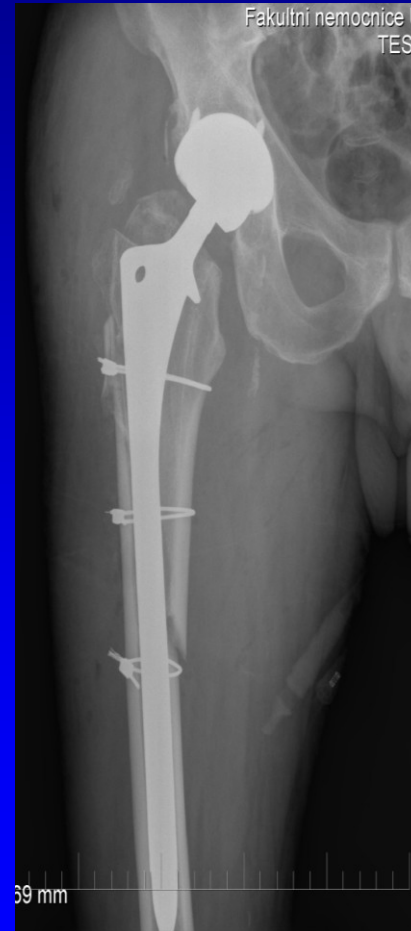
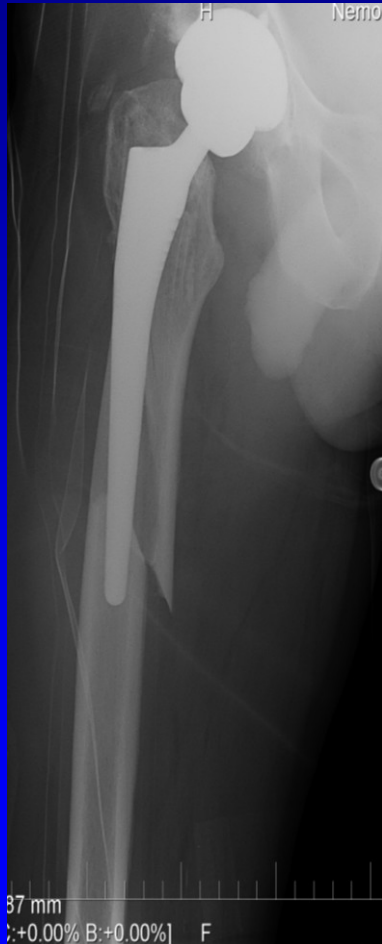
Vancouver classification relies on:

1. The level of the fracture
2. If the prosthesis is stable or not
3. the quality of the bone



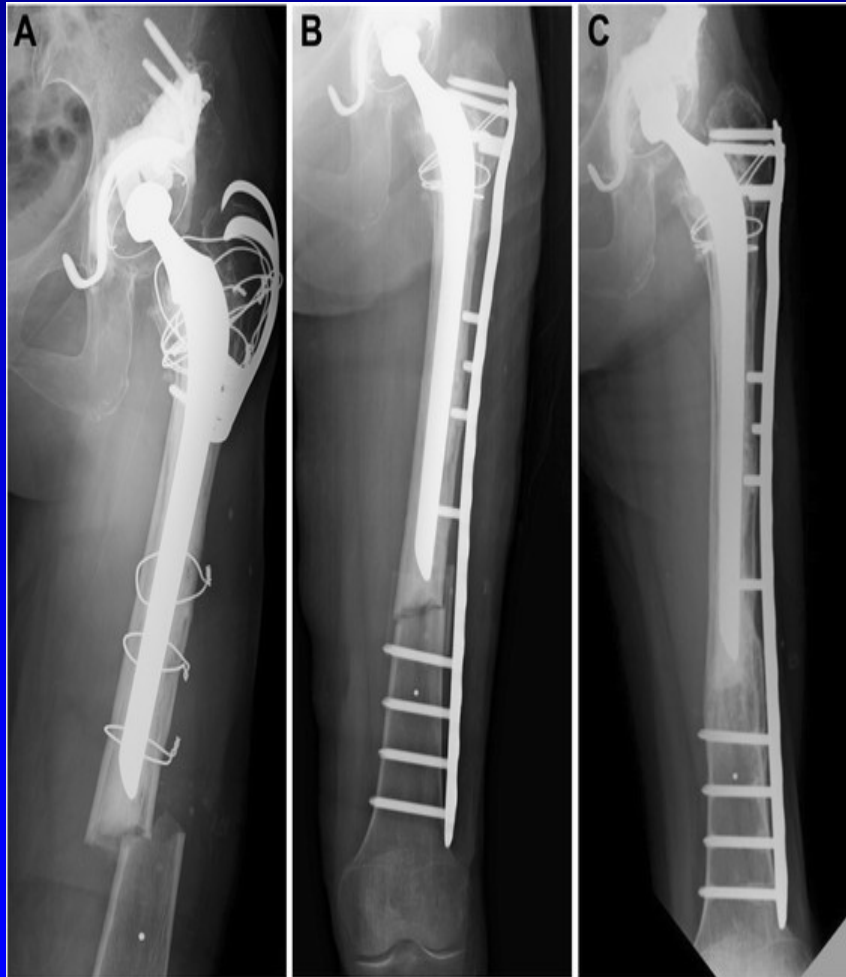Hip periprosthetic fractures	
Type A	Peritrochanteric fractures
	AG: greater trochanter
	AL: lesser trochanter
Type B	Around or just below the tip of the femoral stem
	B1: stable stem
	B2: loose stem
	B3: loose implant with substantial bone loss
Type C	fractures occur well below the implant

Periprosthetic femoral fracture - therapy



Periprosthetic femoral fracture - therapy

- OS (LCP, control cable)



Periprosthetic infection

St. aureus

St. coagulase negative

Streptococci

Enterococci, others

MRSA, MRSE

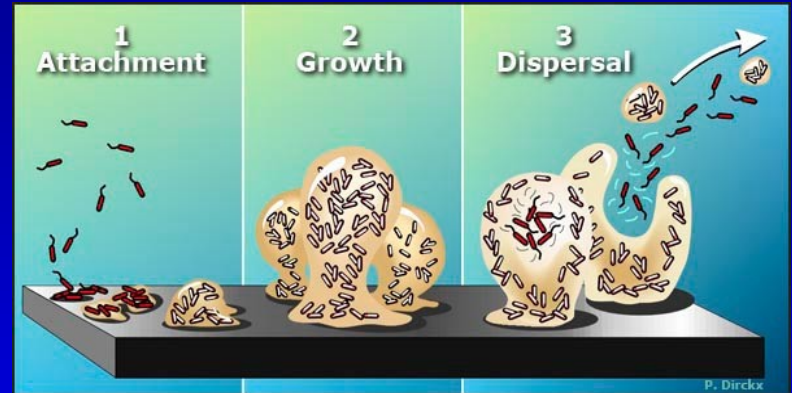Polyresistant G- bacteria

Sessile form and planctonic

Race for surface

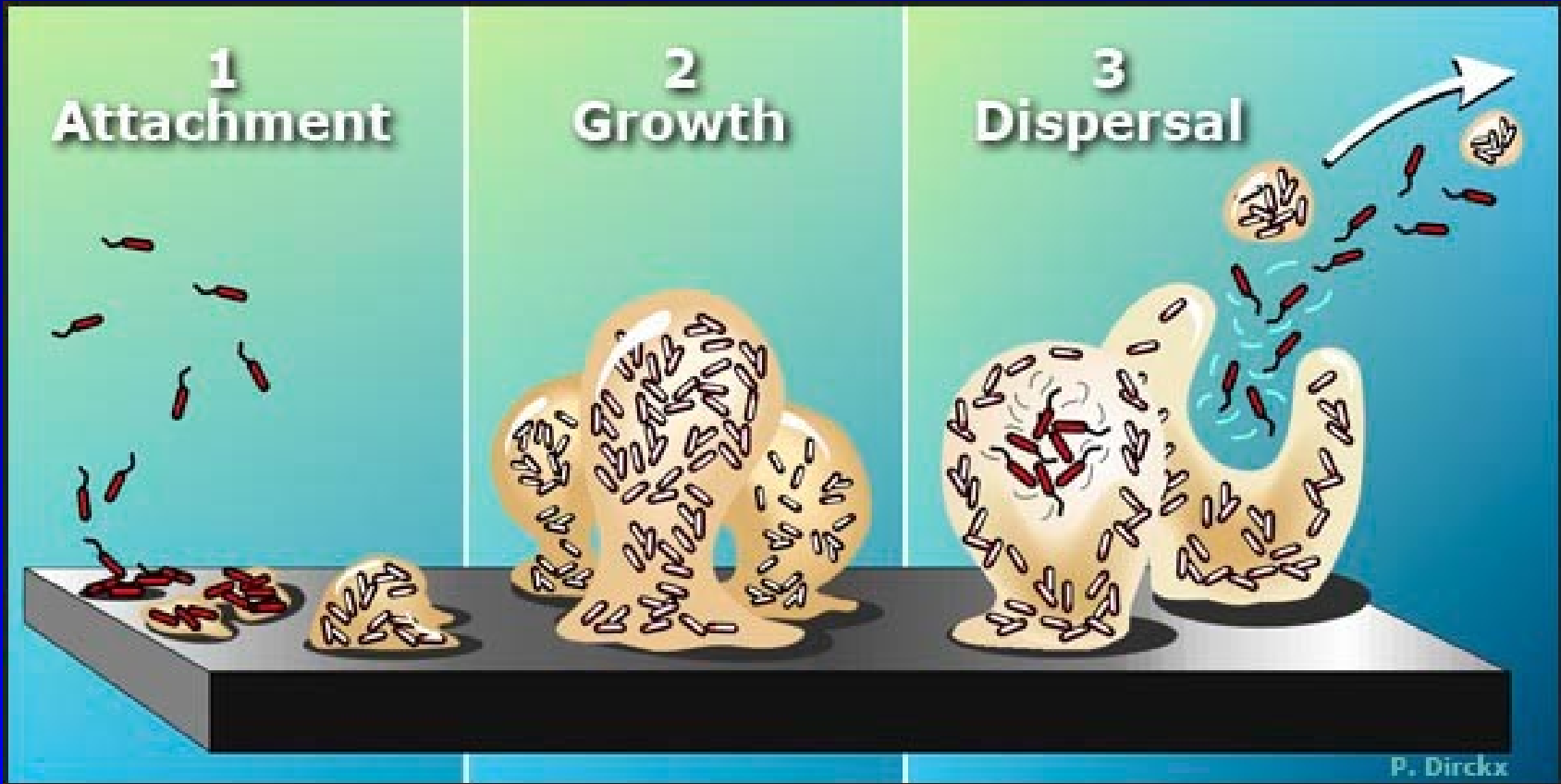
They produce glycocalyx- mucose substance
of glycoproteins

It leads to high resistance
to antibodies and antibiotics



Biofilm

Biofilm



Adhesion of bacteria
- reversible

Exopolymers
- glycolalyx
- extracelular matrix
irreversible

Releas to surrounding
tissue

Periprosthetic infection- diagnostics

Clinicly

Labor: CRP, leu, ESR

aspiration of pus

X-ray- osteolysis, loosening

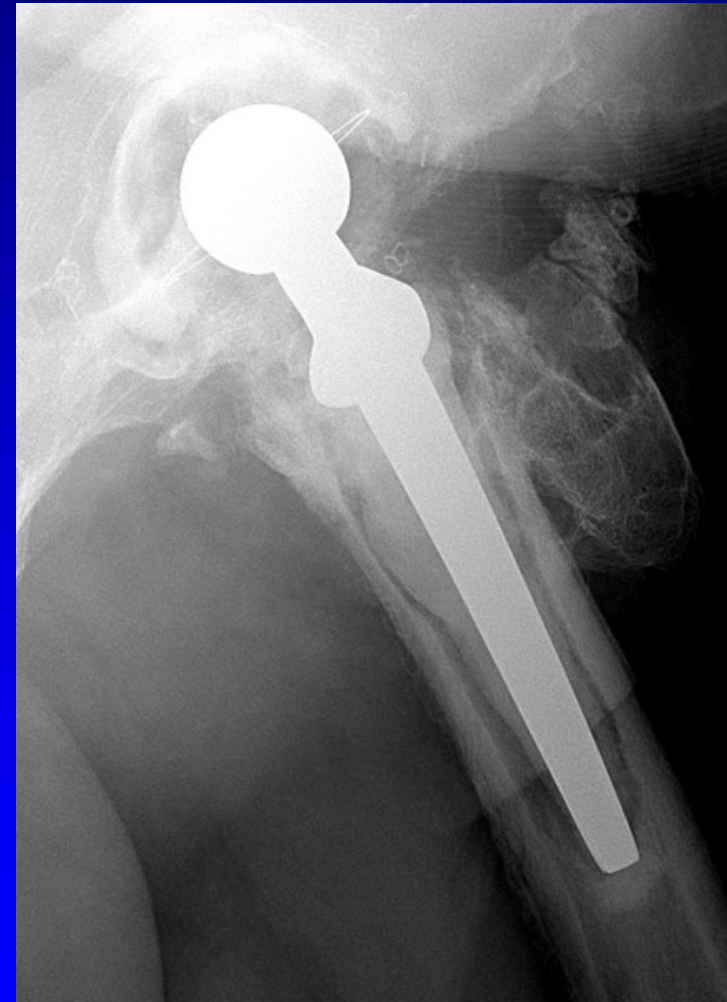USG (abscesus)

Scintigraphy

Sonication of the implant

Bacteriological examination

Long cultivation

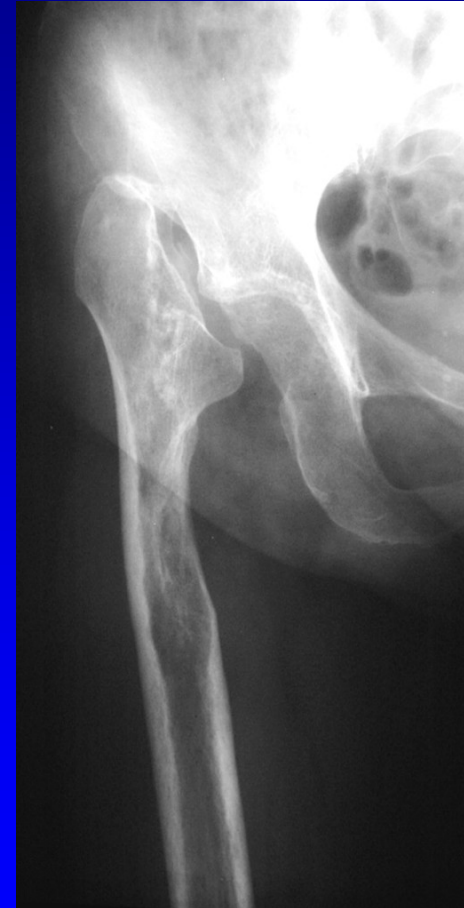

Periprosthetic infection- PPI

Acute PPI

Chronic PPI

Late haematogenous PPI



Management

To start treatment as soon as possible:
10-14 days from the onset of symptoms

Prerequisite: cooperation of the patient
informed physician

Periprosthetic infection-treatment

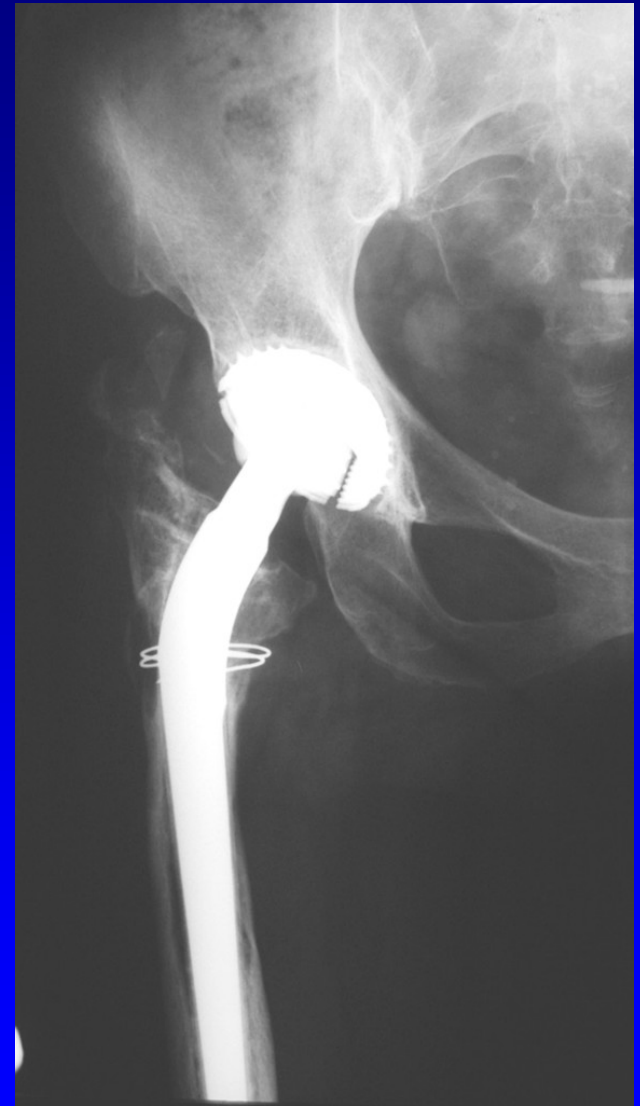
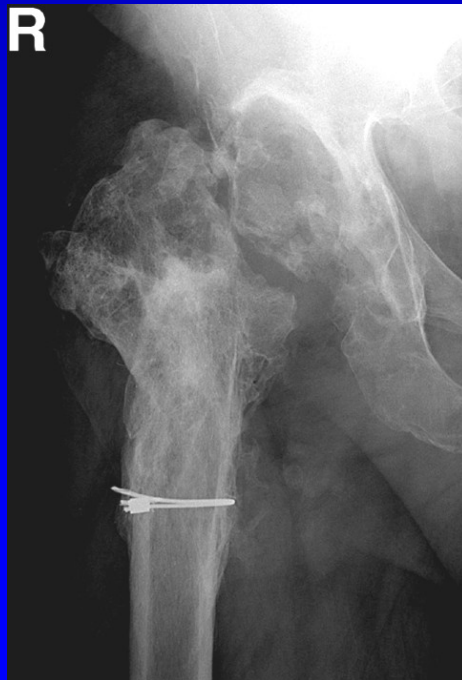Debridement

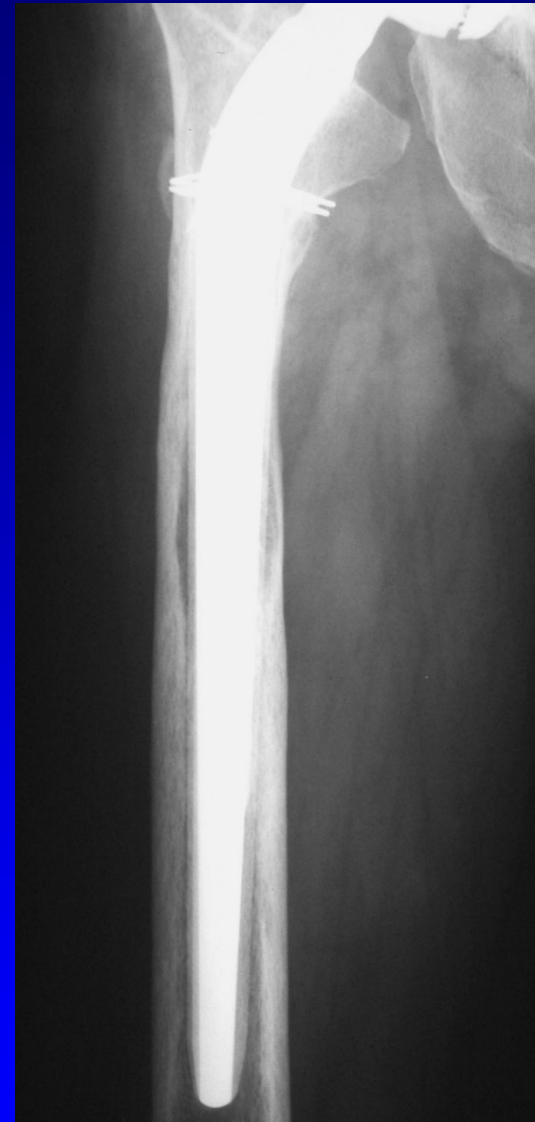
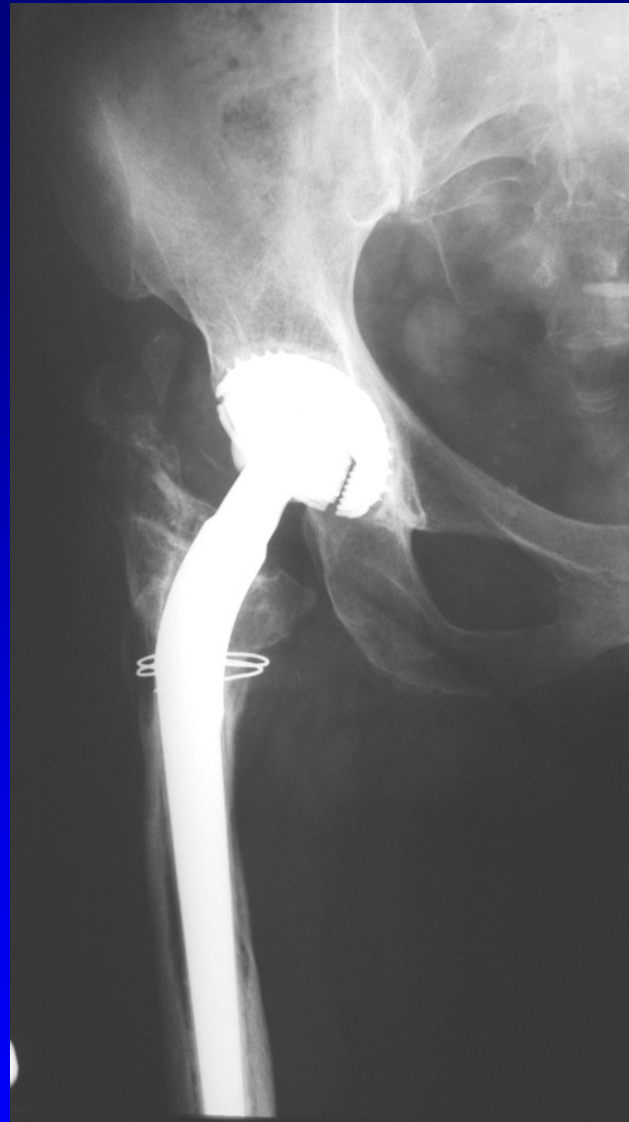
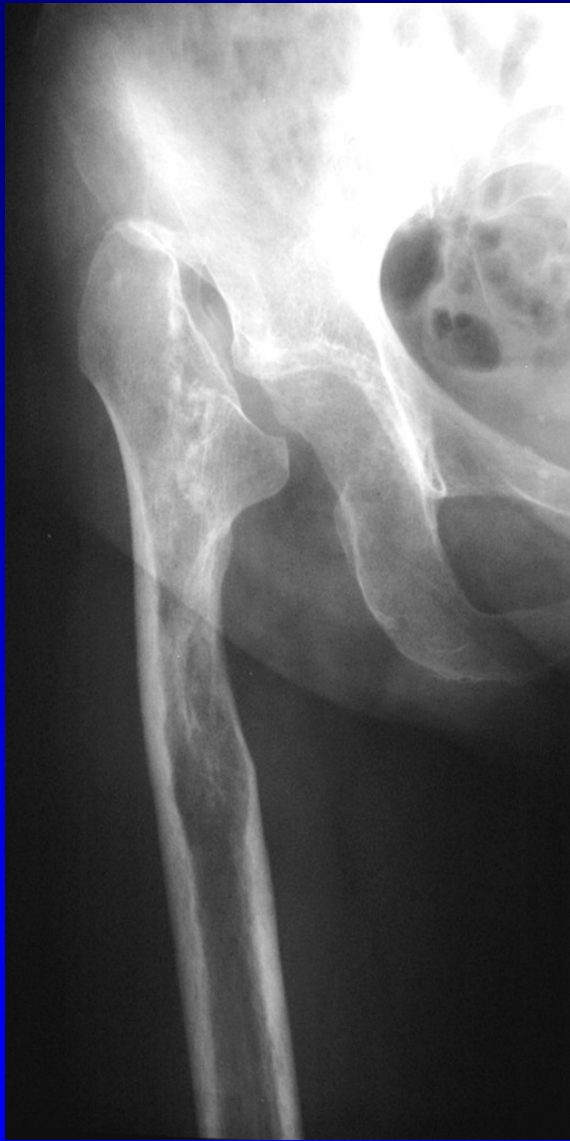One stage surgery

Two stage surgery

Resection arthroplasty

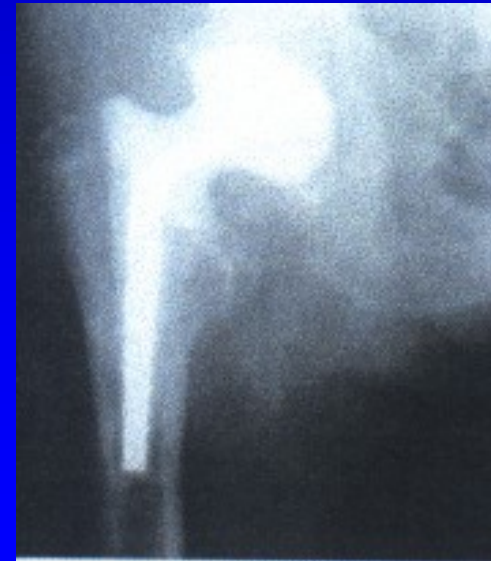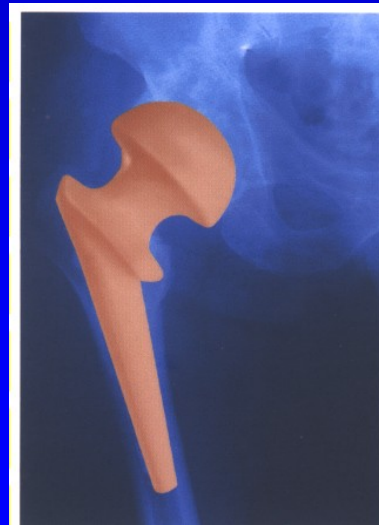
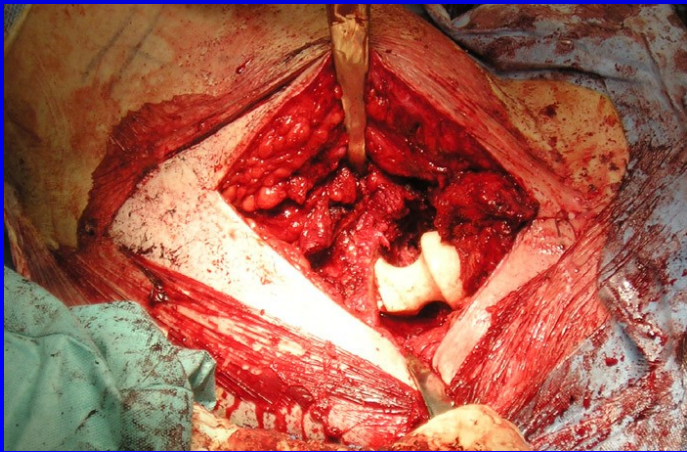
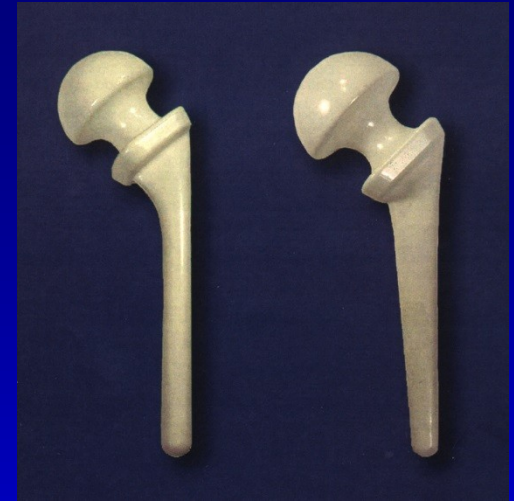Antibiotic suppression





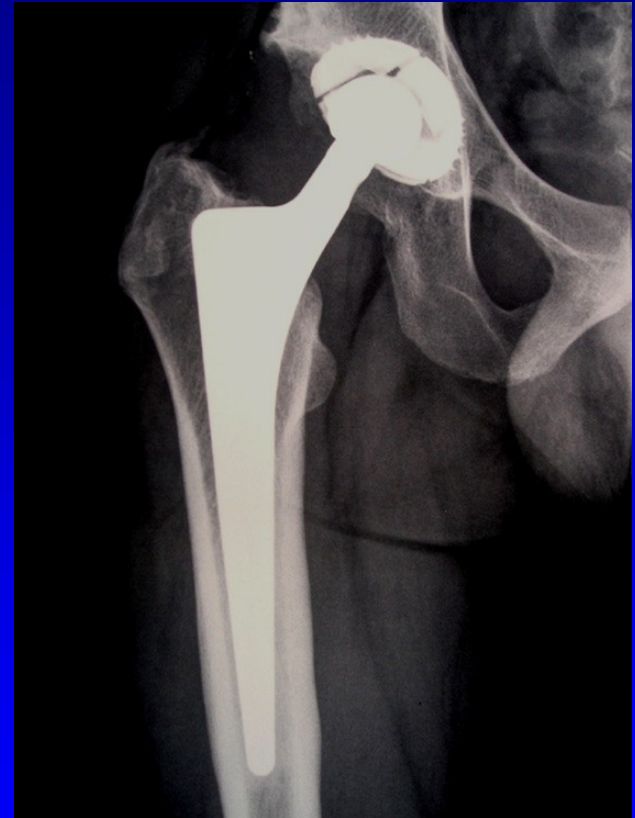
Hip spacers

- Two stage surgery
- Better ROM
- Better walking
- Revision is easier
- Local concentration of antibiotics
 - Gentamycin a Vancomycin
 - Cover 90 % of all pathogens



Prerequisite for good result

Choice of the patient
Preop. examination
Prevention of infection
Choice of the implant
Operative technique
Postop. management
Activity of the patient
Regular follow- up
Prevention of infection
Prevention of aseptic loosening
Long term results
National registries



Daily activity after THA

No lifting and wearing of heavy objects
No strenuous manual labor
Limited running and jumping
No contact sports

Recommended sports:
swimming, bicycle, tennis
tourism, skiing?

