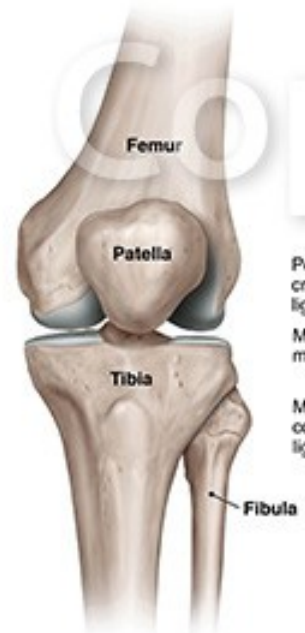



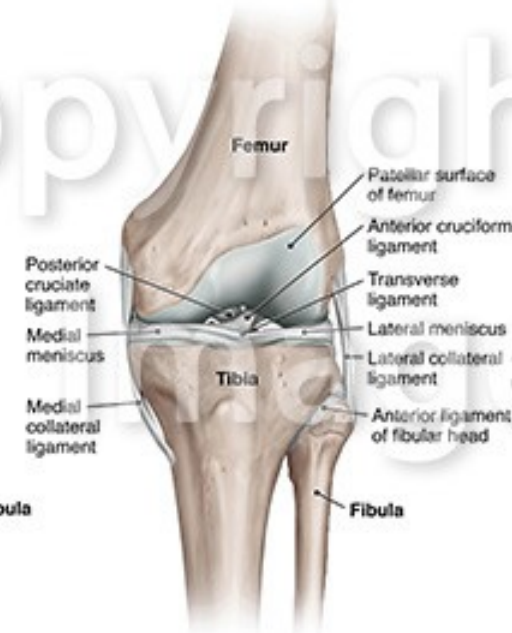MUDR. JAN EMMER, I. ORTOPEDICKÁ KLINIKA FNUSA V BRNĚ

Knee Joint Anatomy

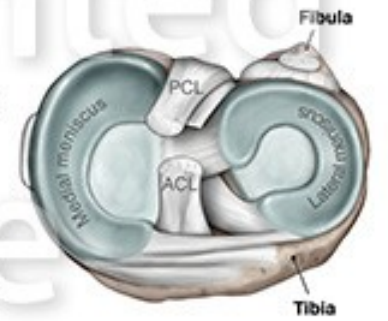**Anterior View of Knee
(Bone Anatomy)**

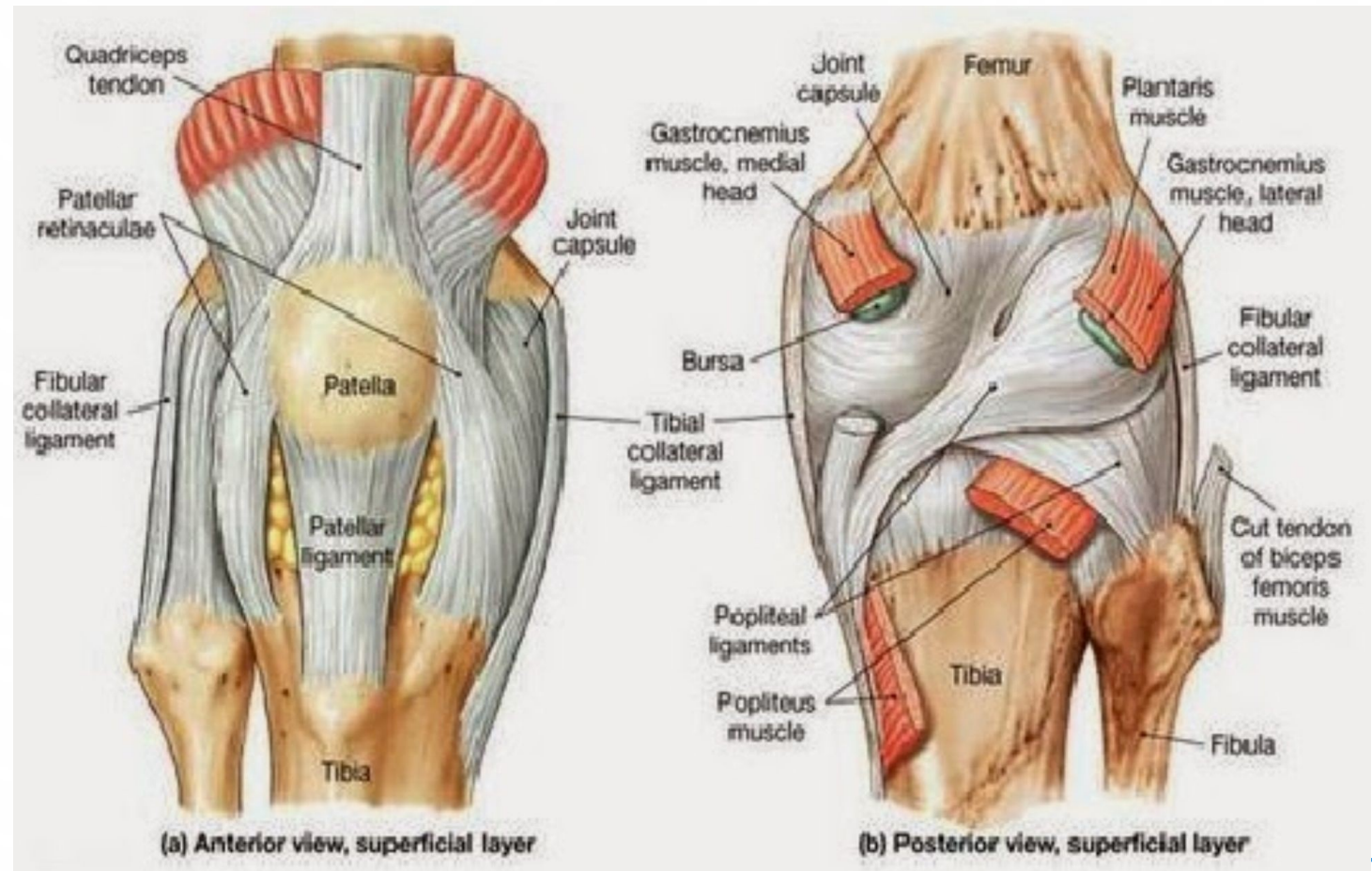


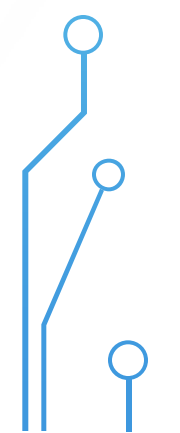

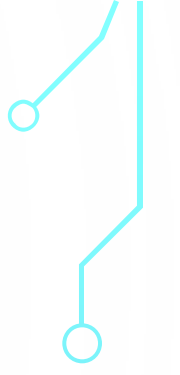
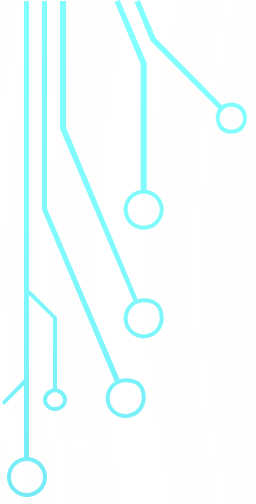
**Anterior View of Knee
(Ligament Anatomy-Patella Removed)**



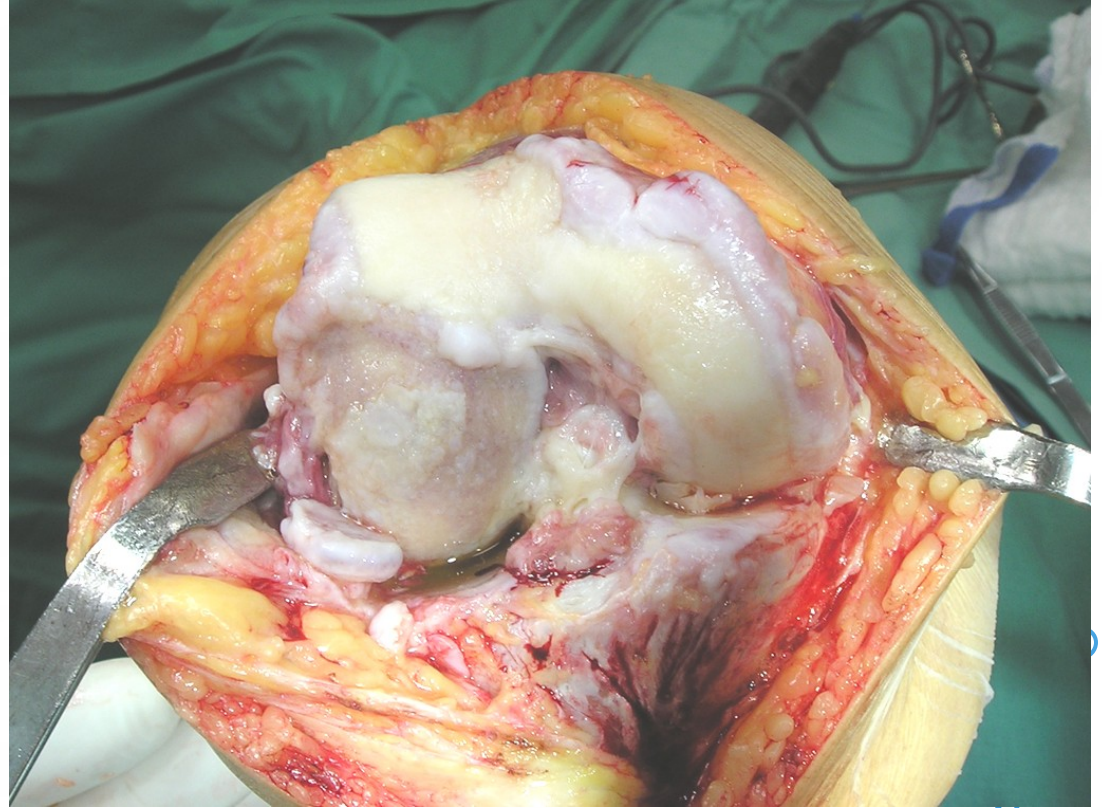
Superior View of Tibial Plateau









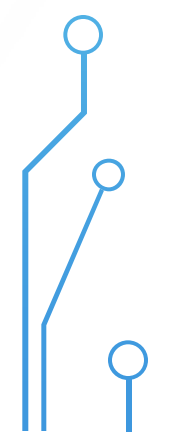

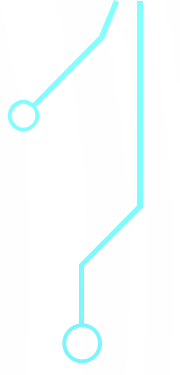
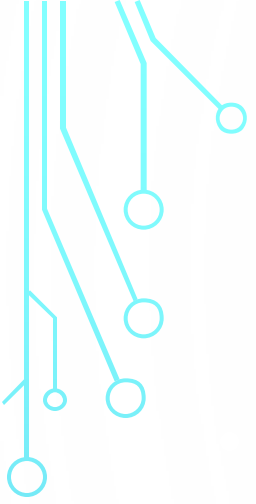



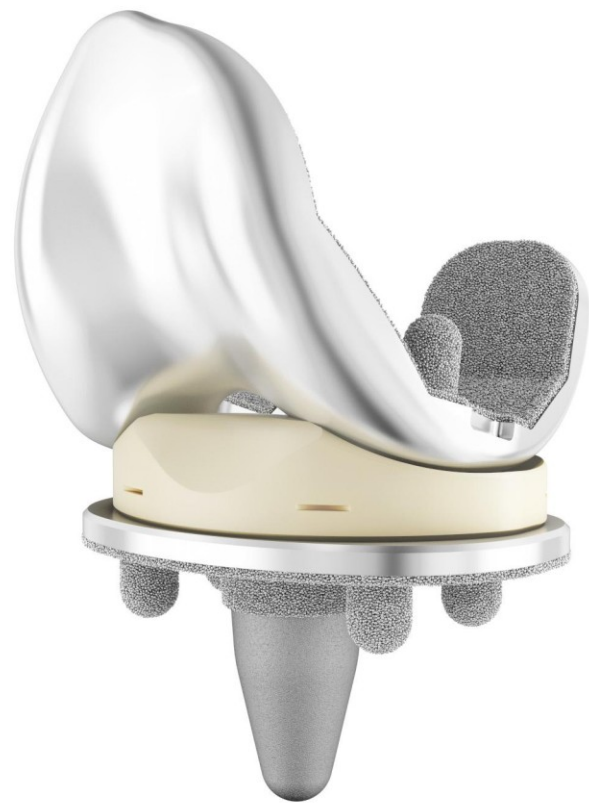


VISIONS

SOLUTIONS





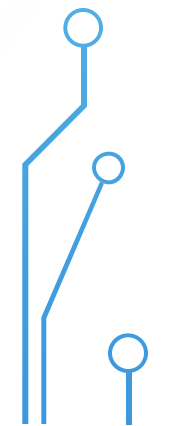
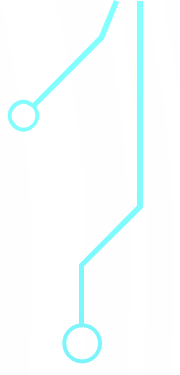
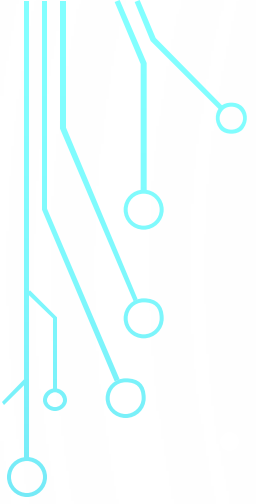


ENERGY

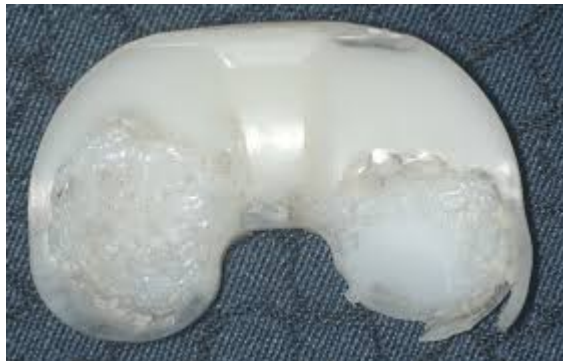






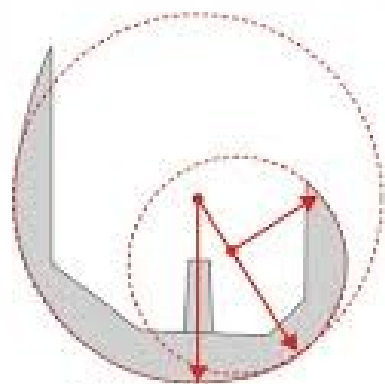




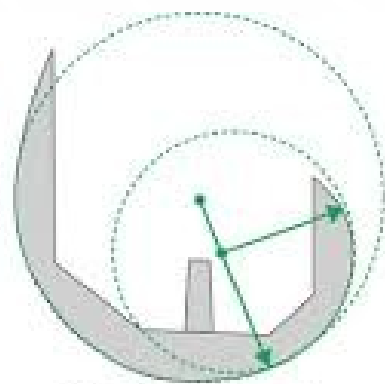









Multi-radii of curvature



"Single" radius of curvature



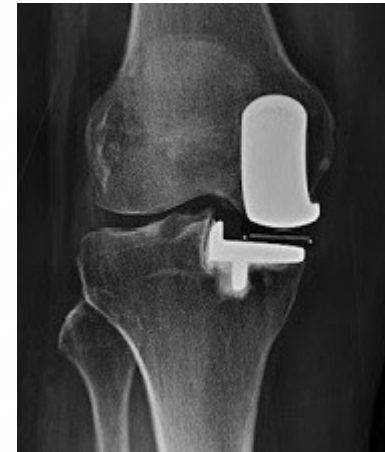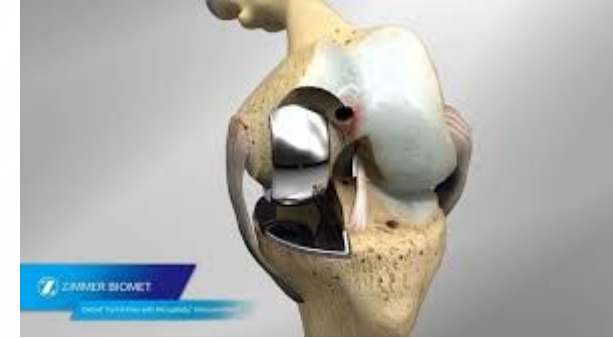ATTUNE GRADIUS™ curve

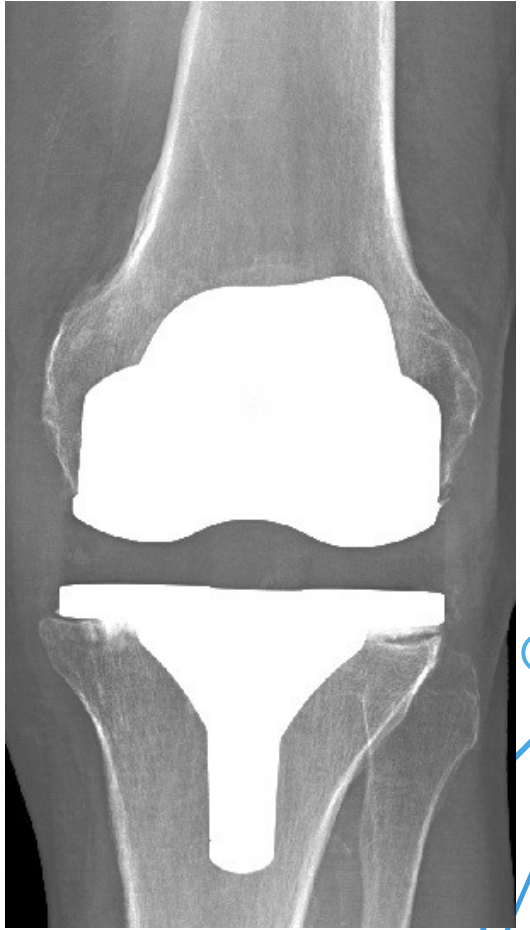
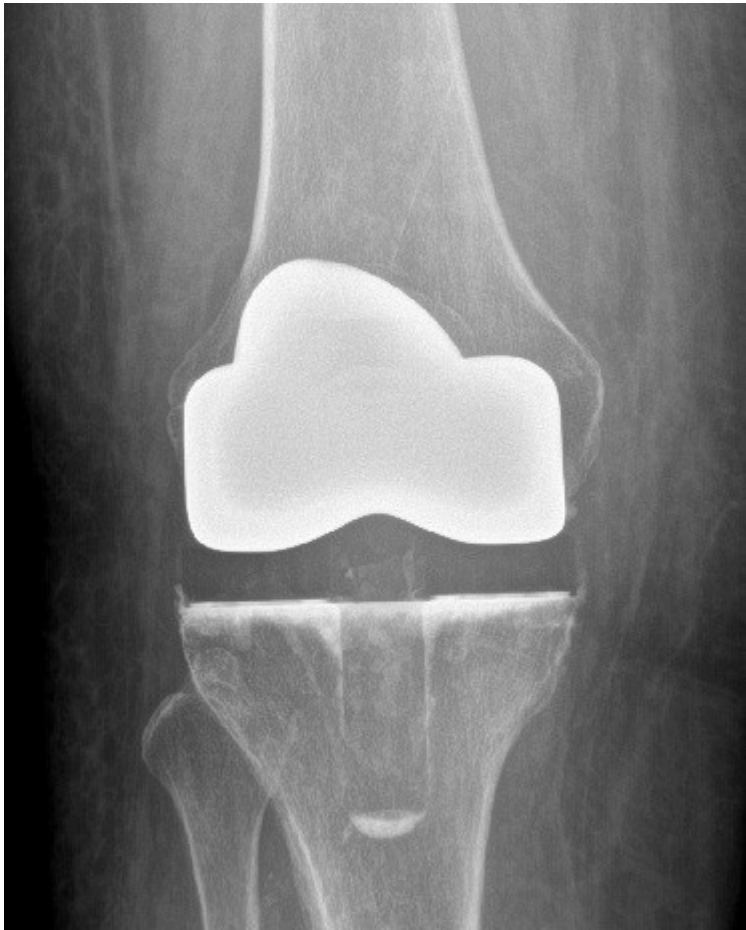

Lateral

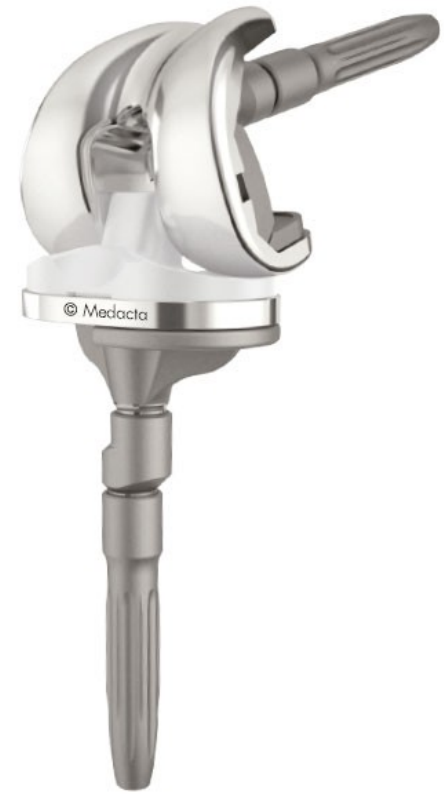Medial

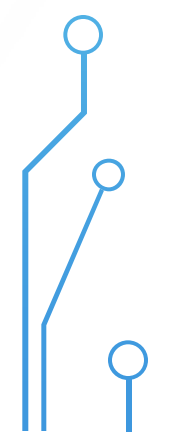

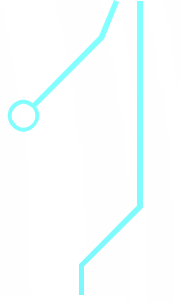
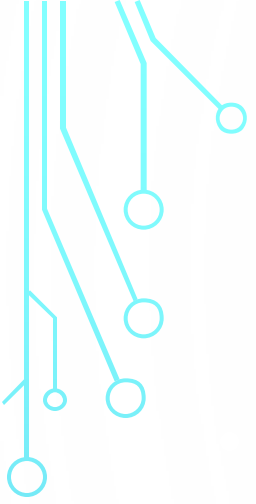
Asymmetric femoral condyles assist in recreating a medial pivot motion.



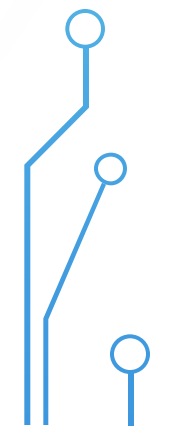
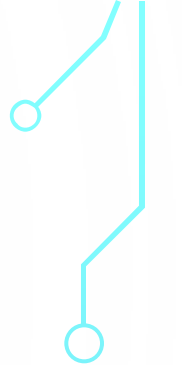
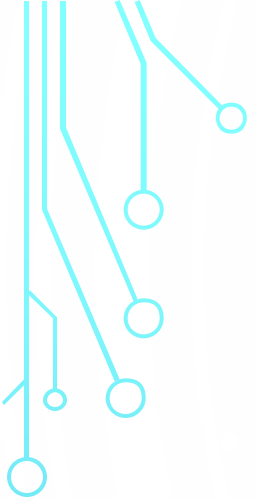


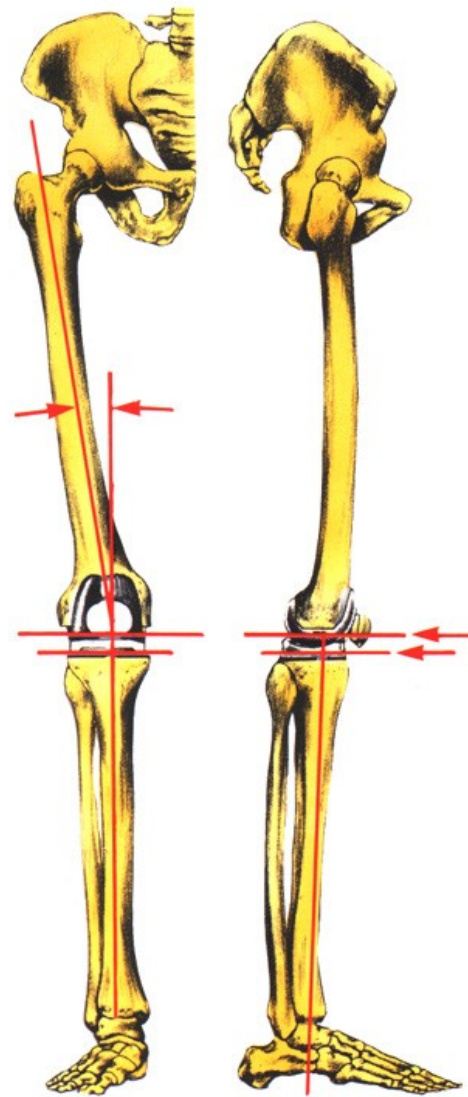
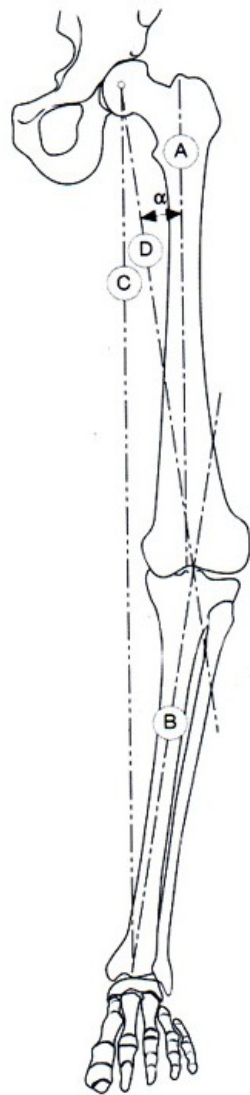
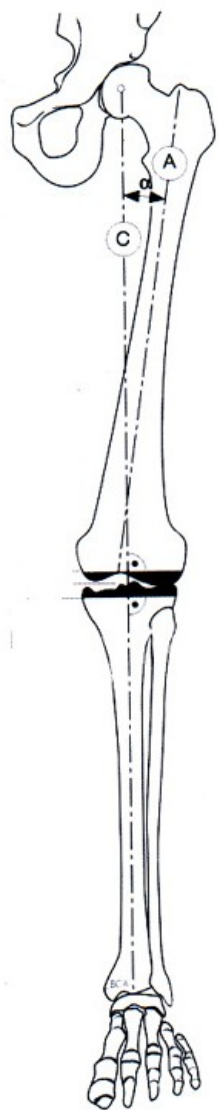


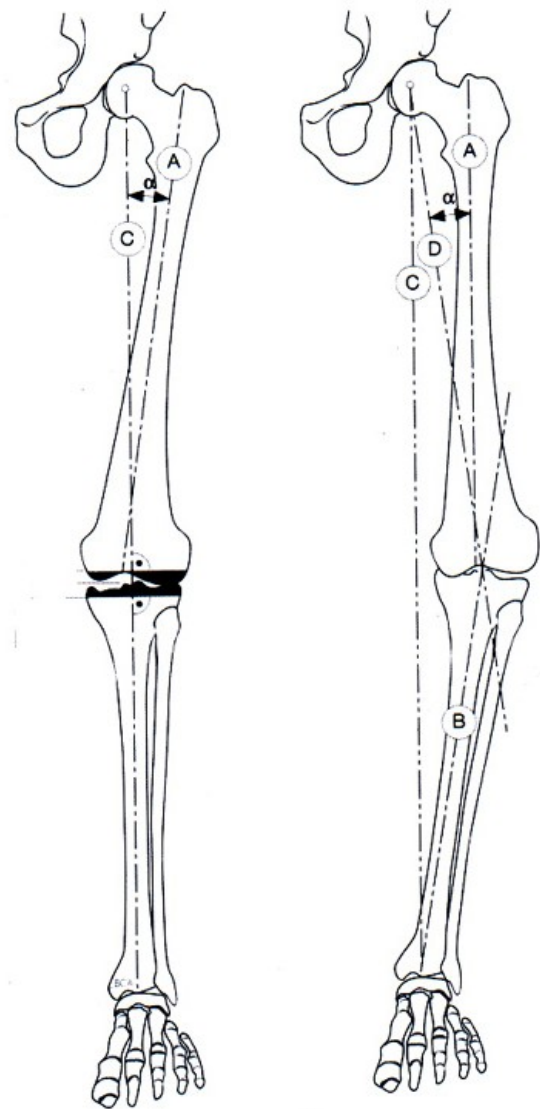


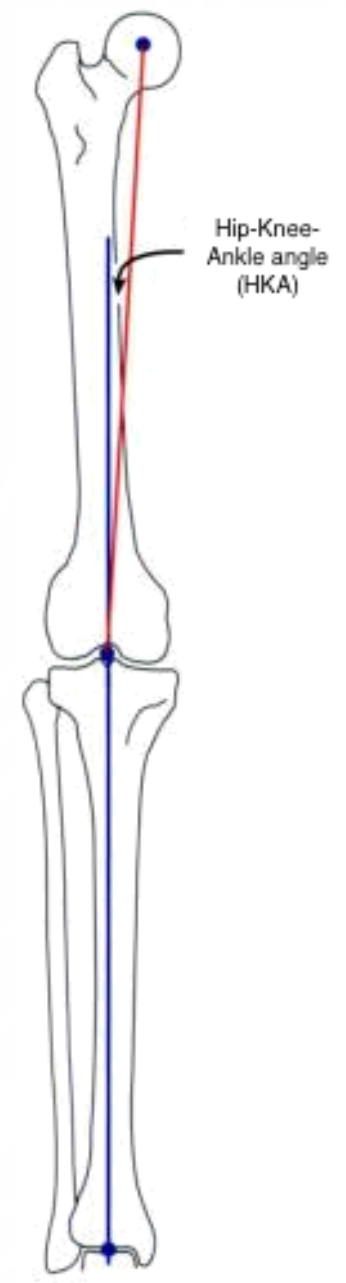


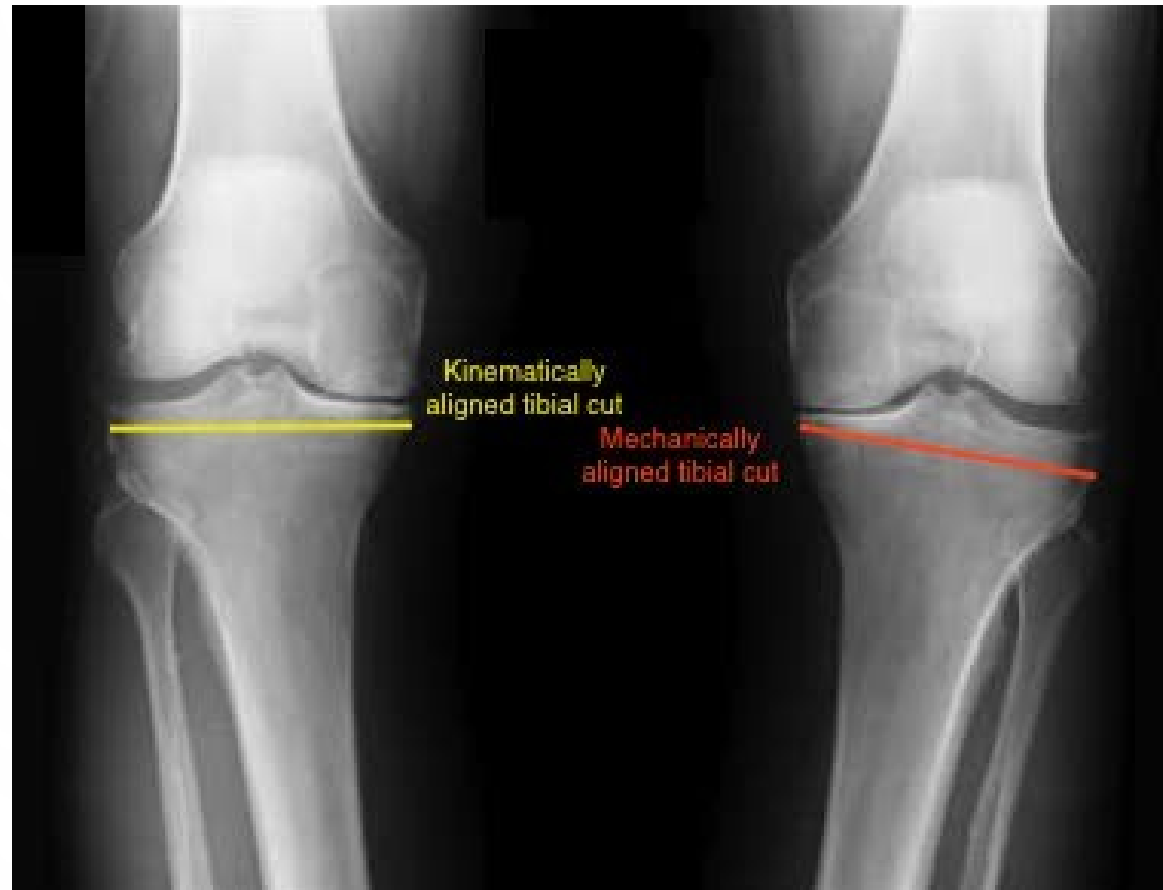©AMINATI.COM

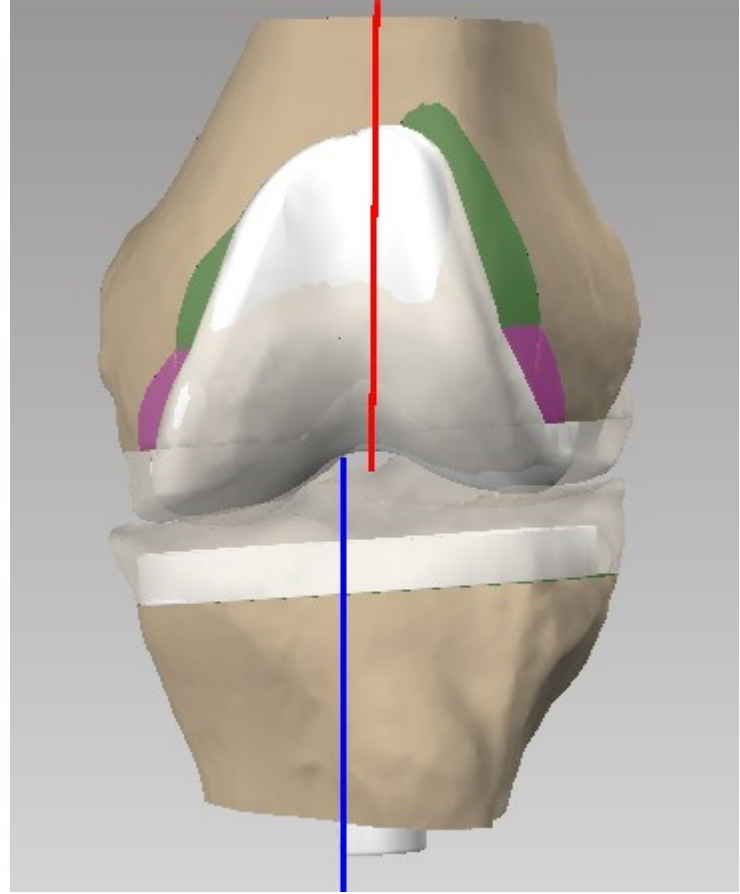
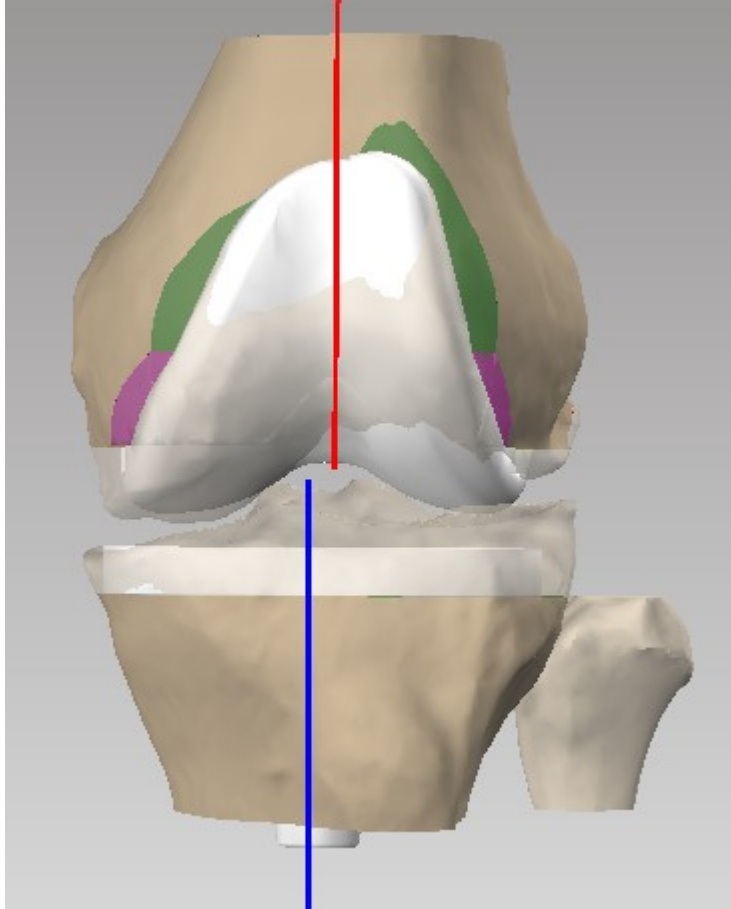


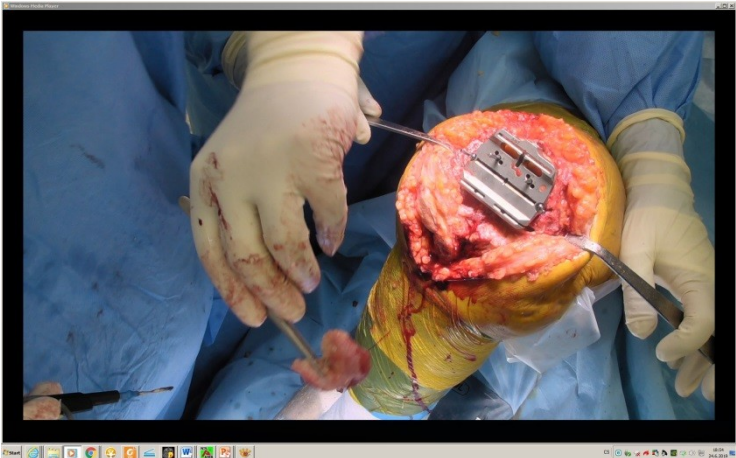
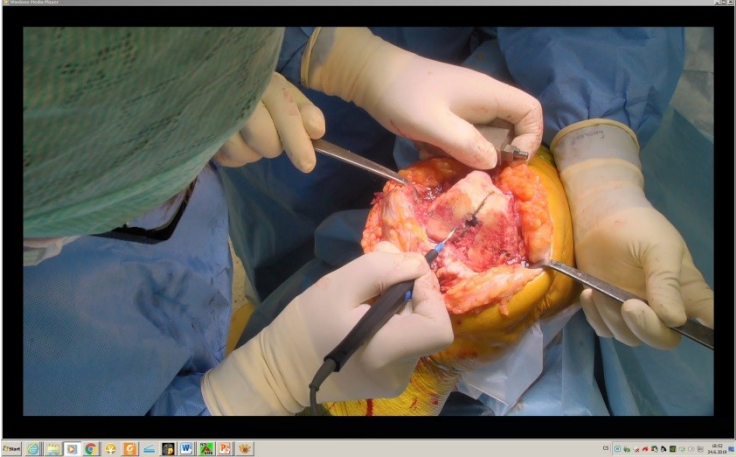


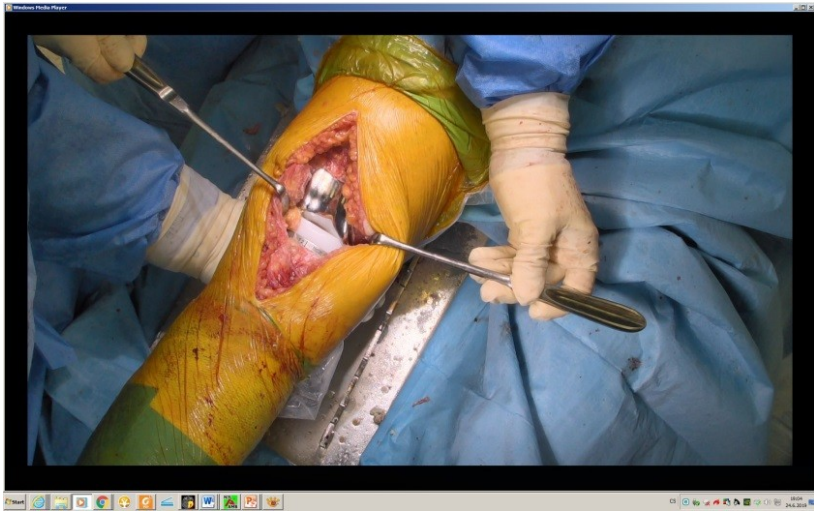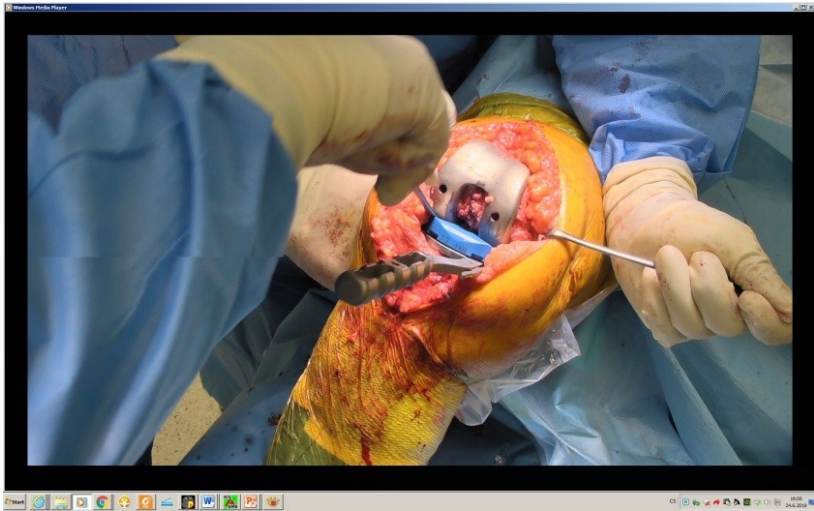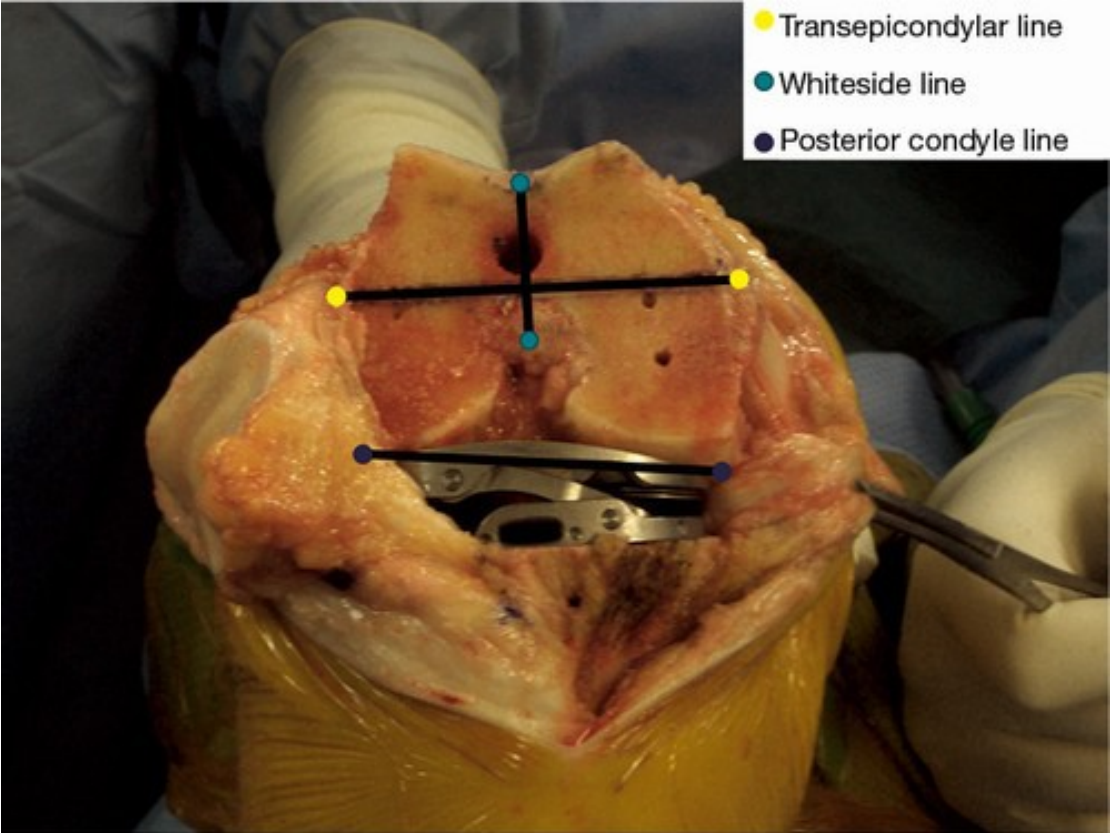




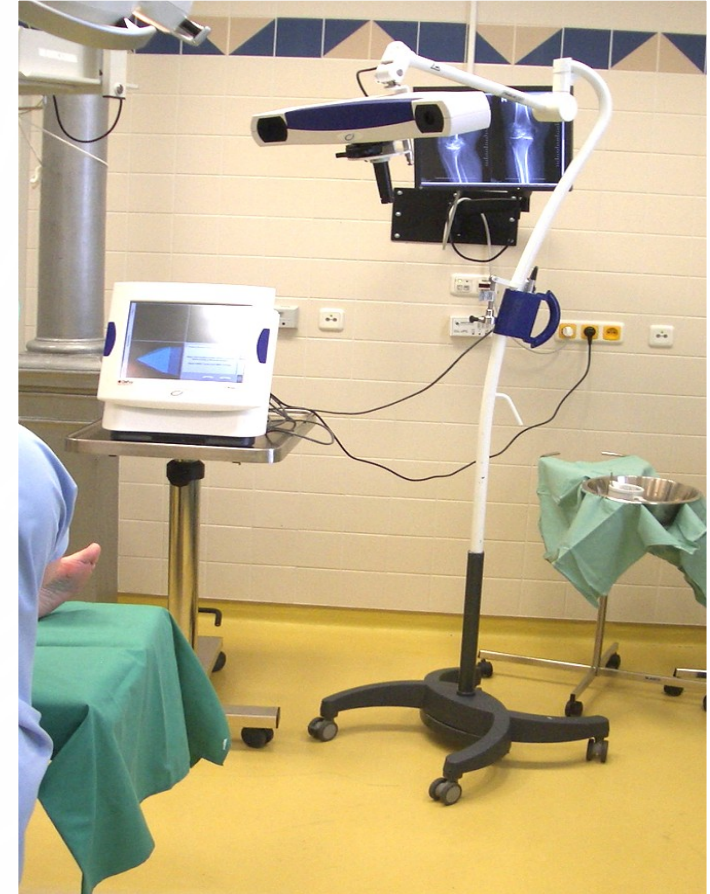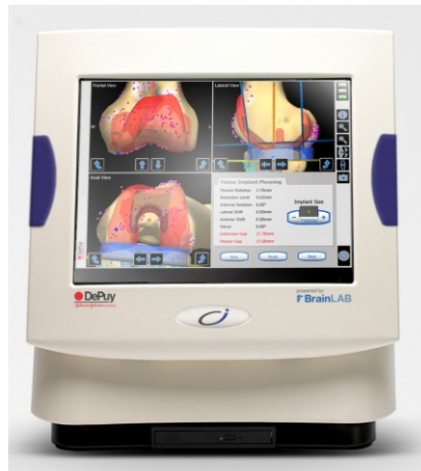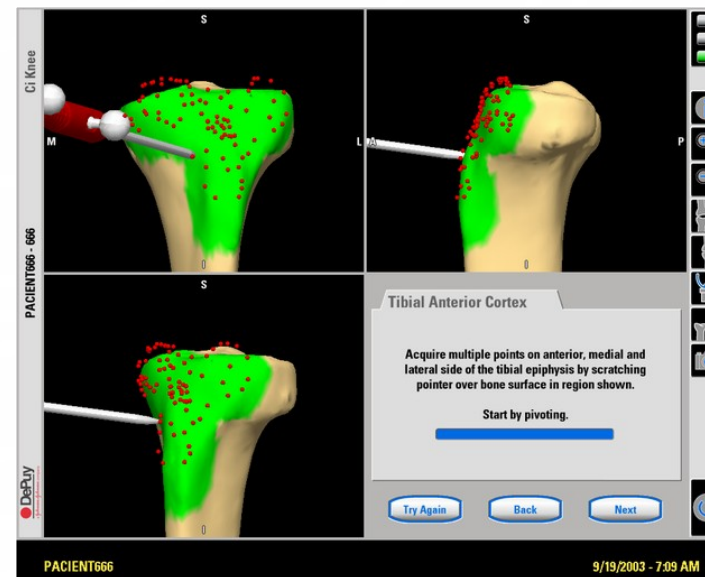
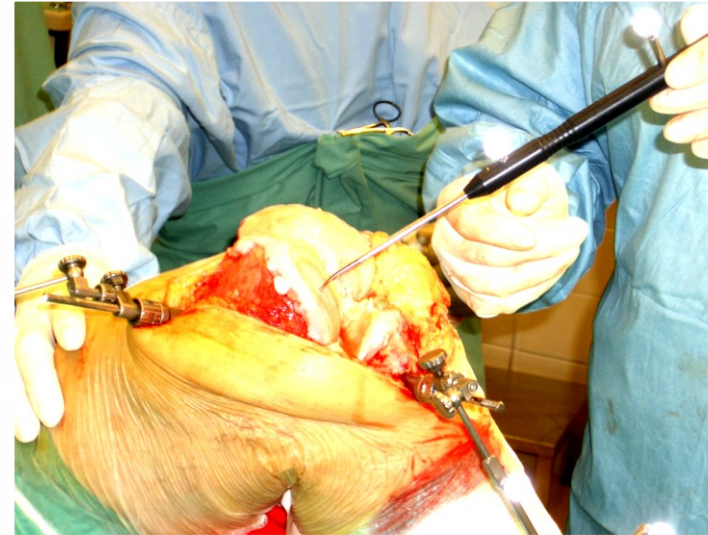


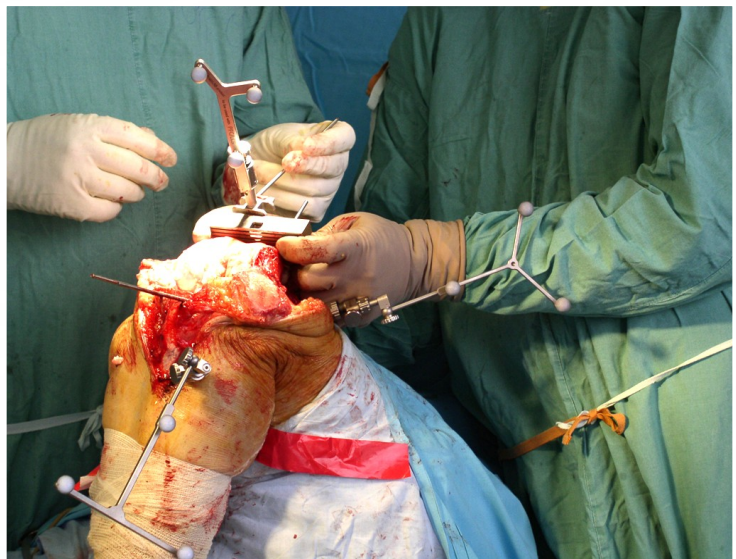
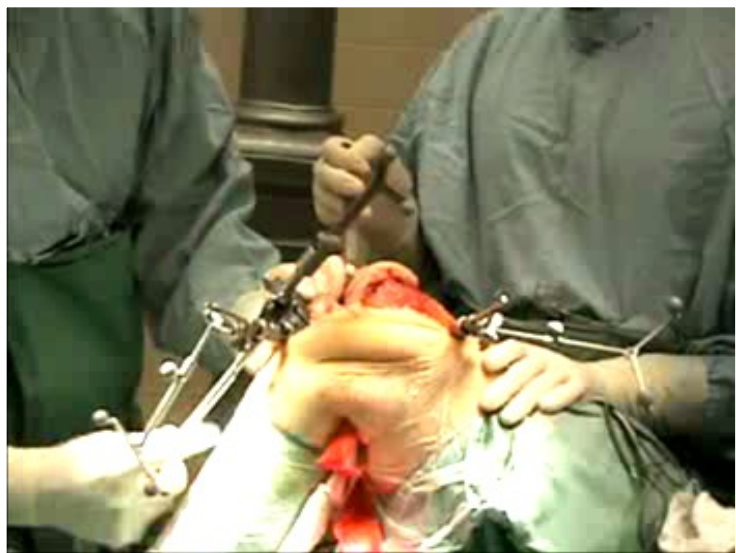


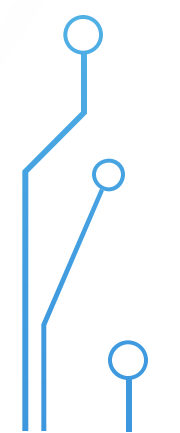
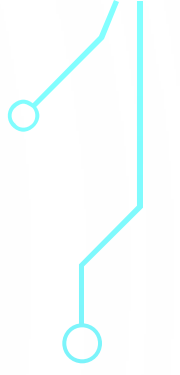
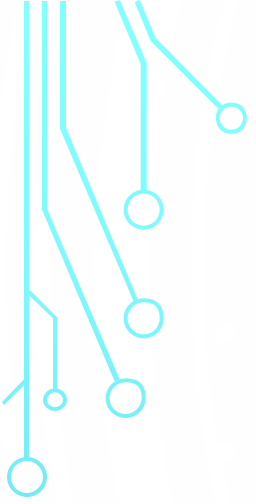


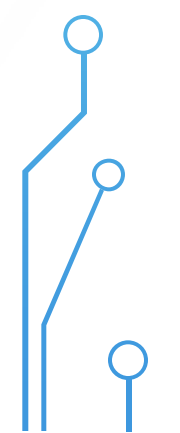

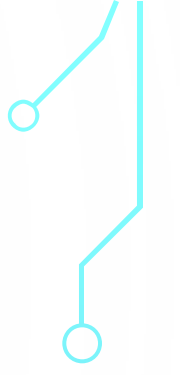
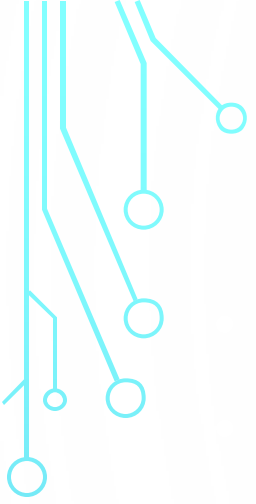


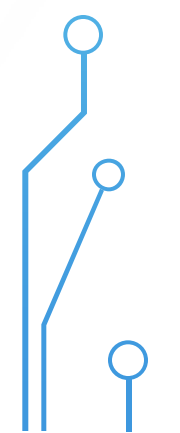
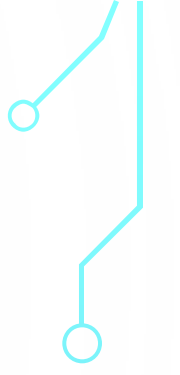
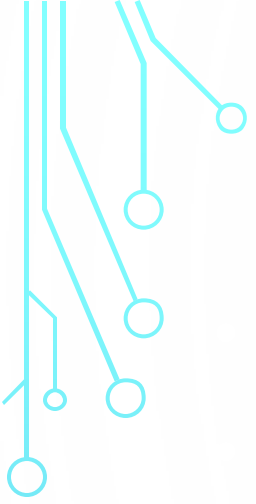









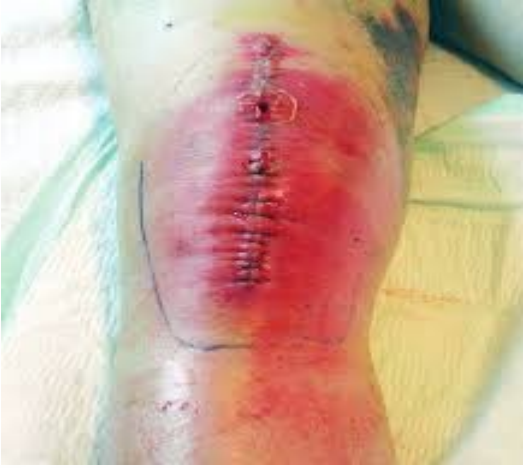
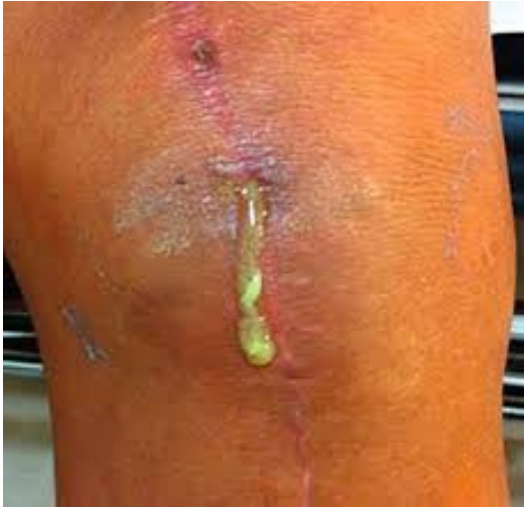

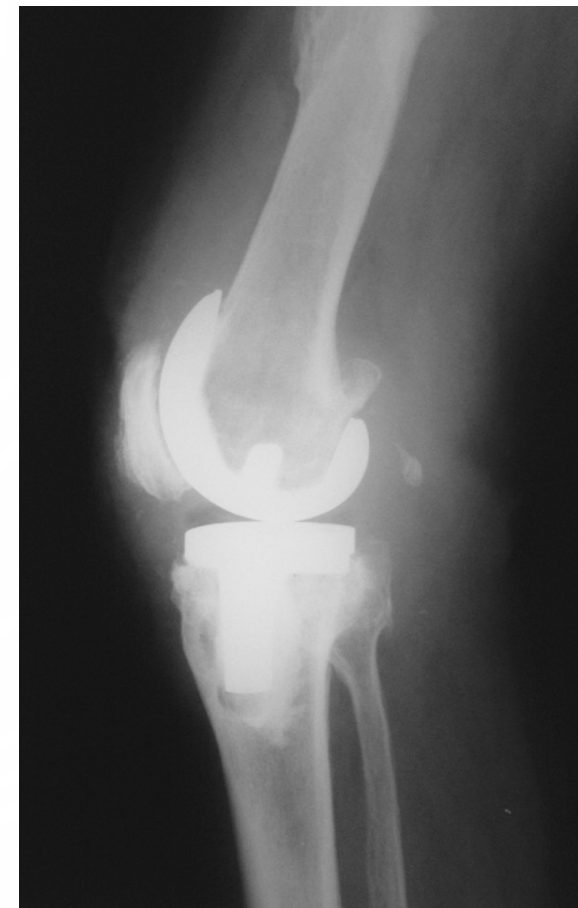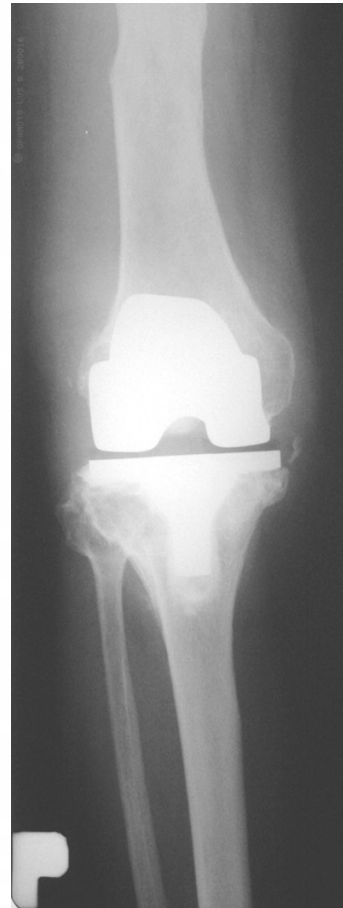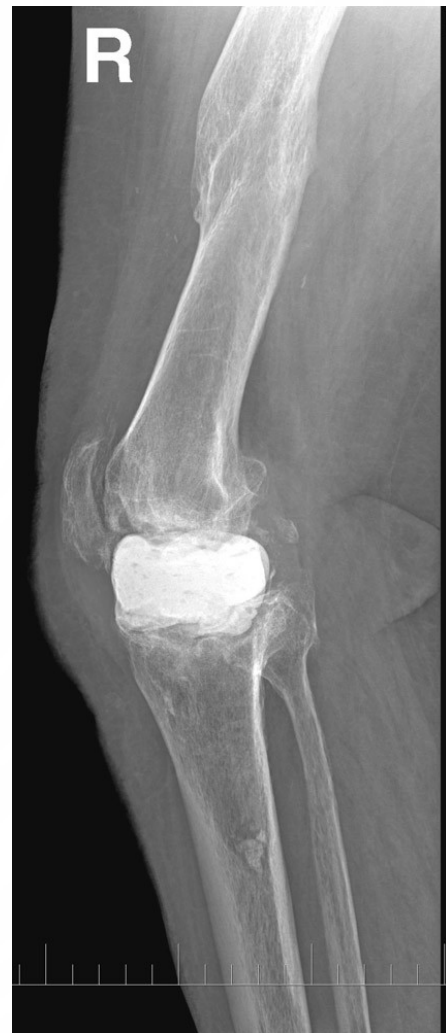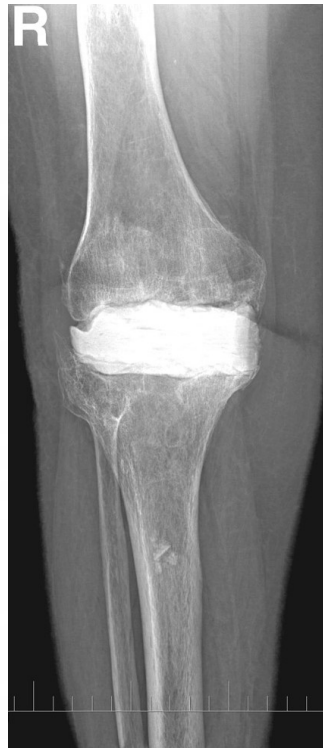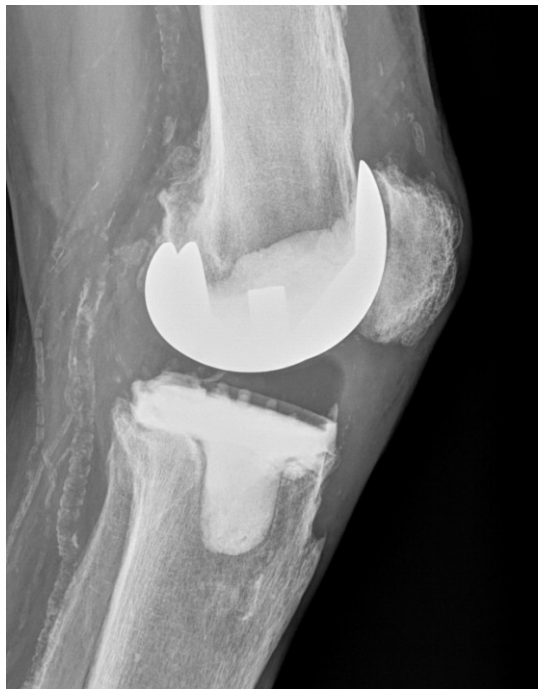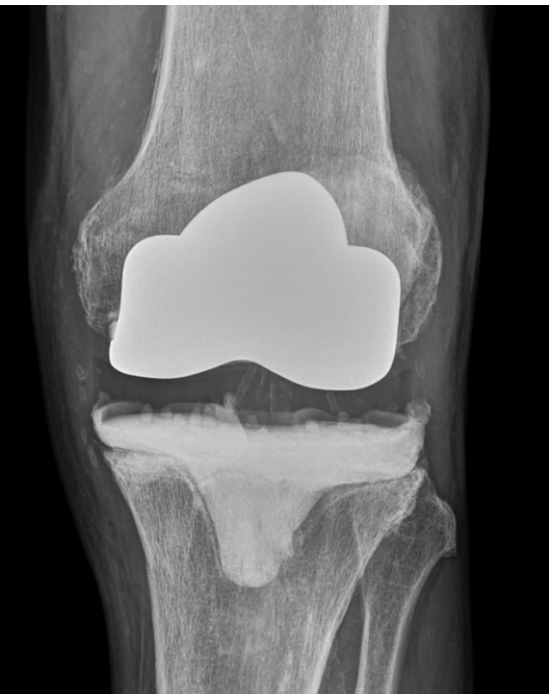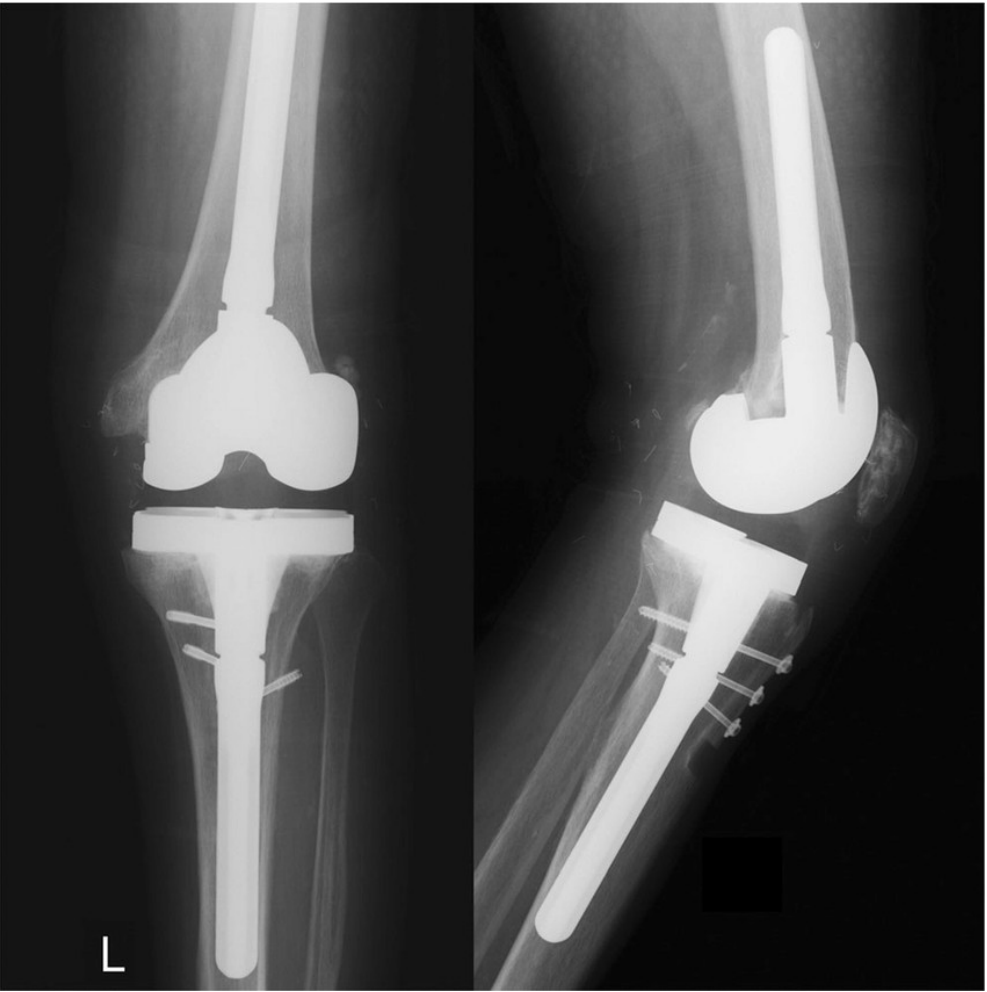








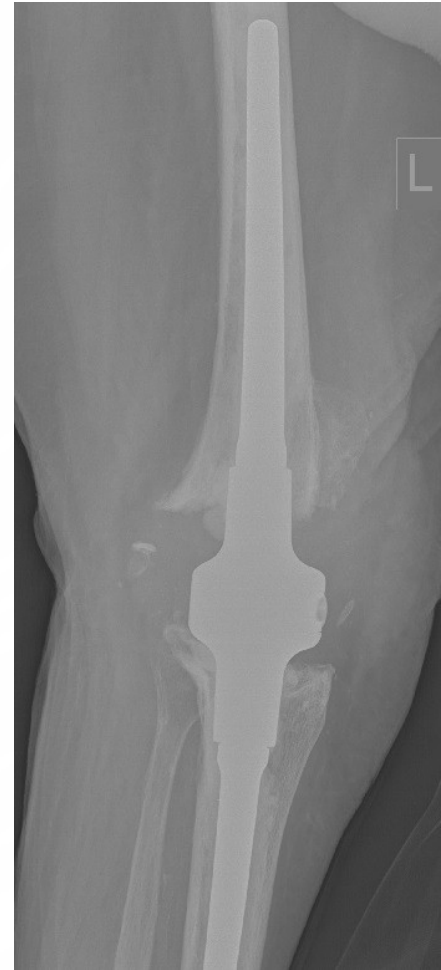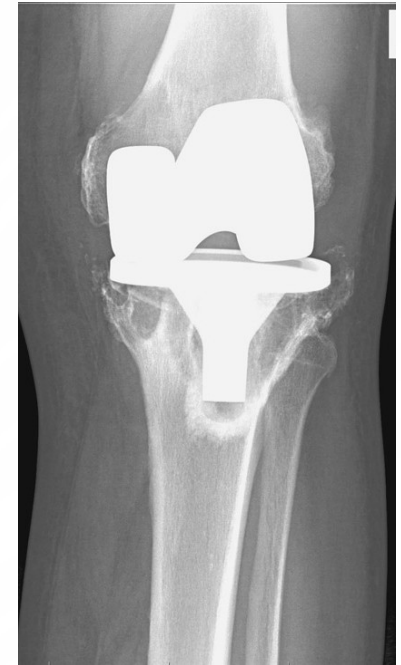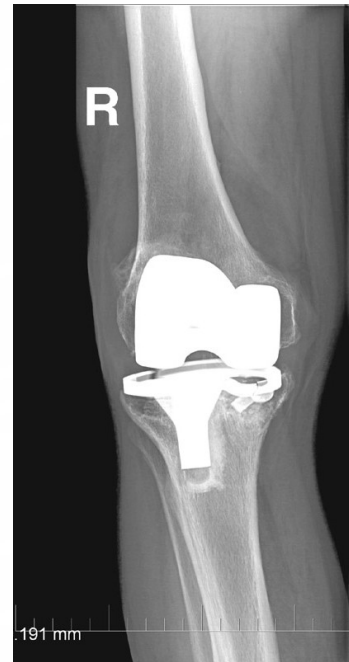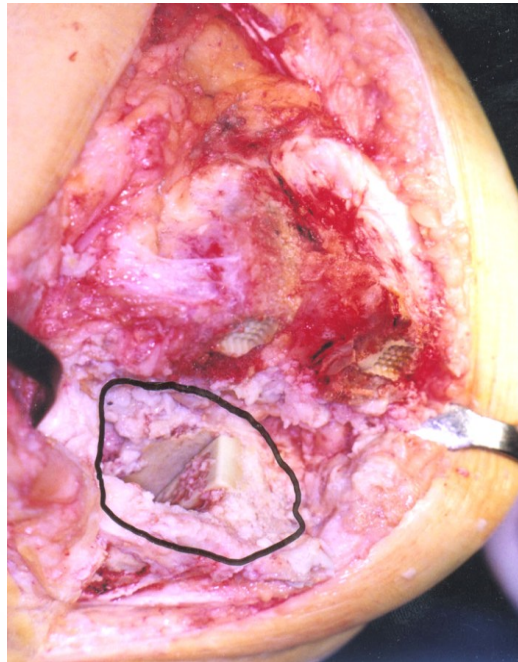






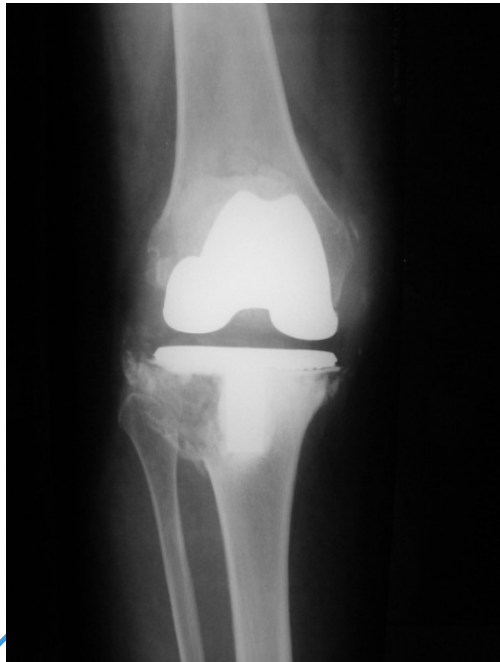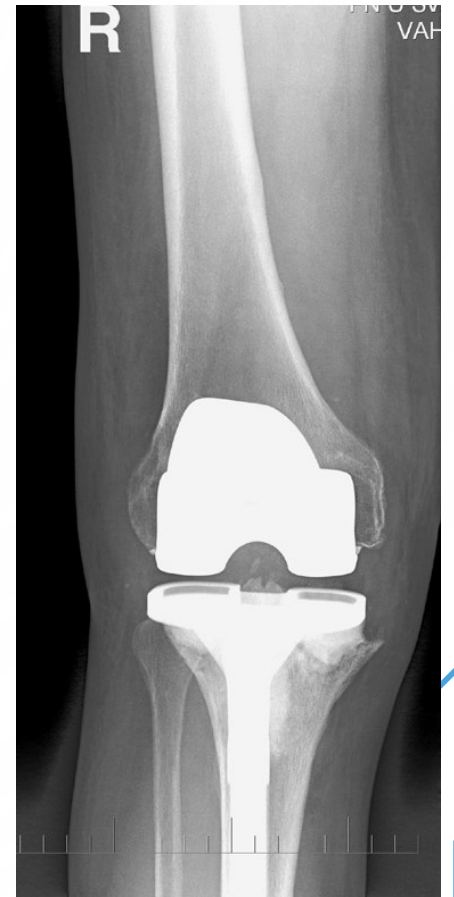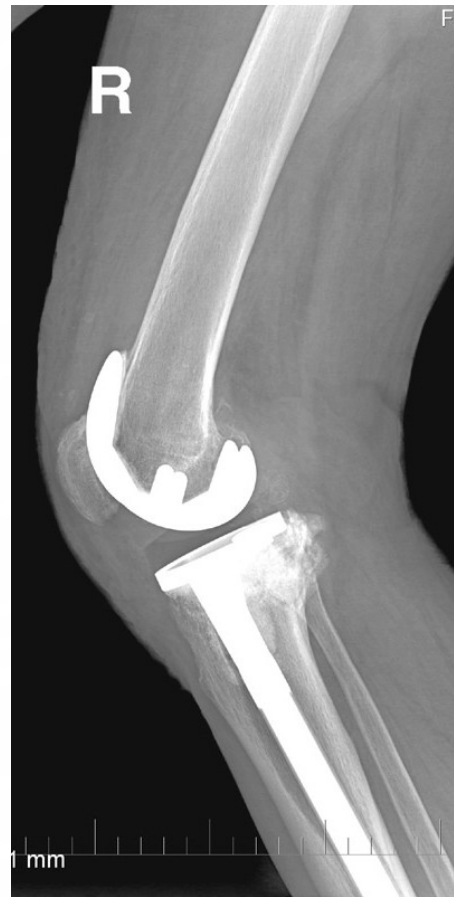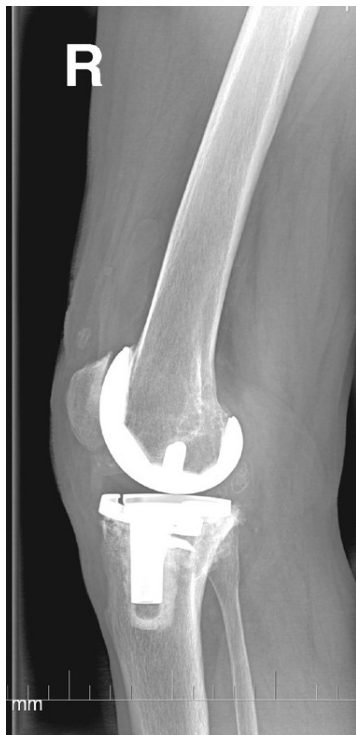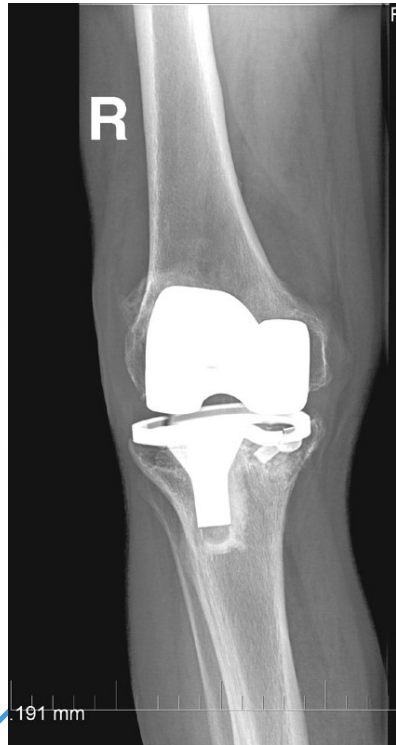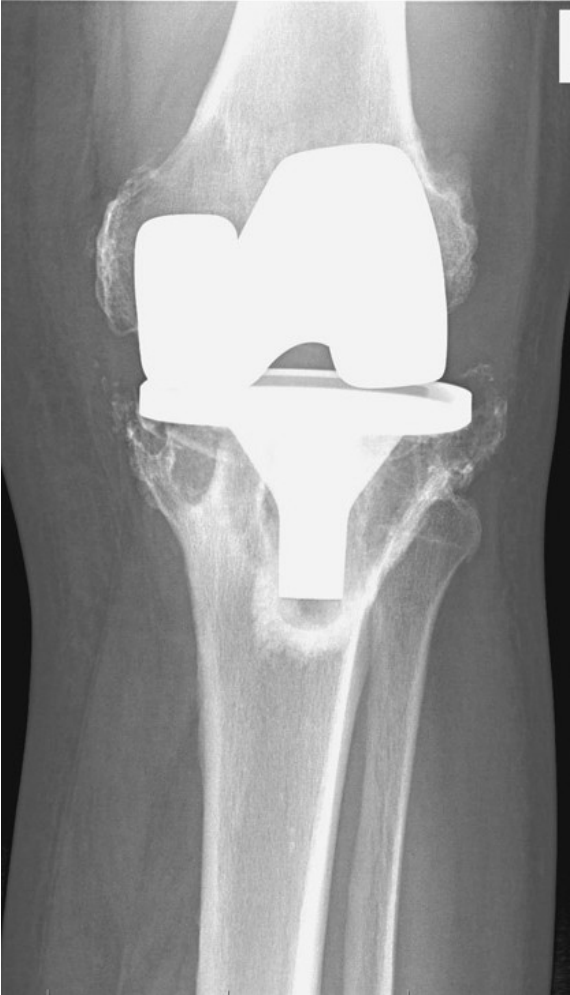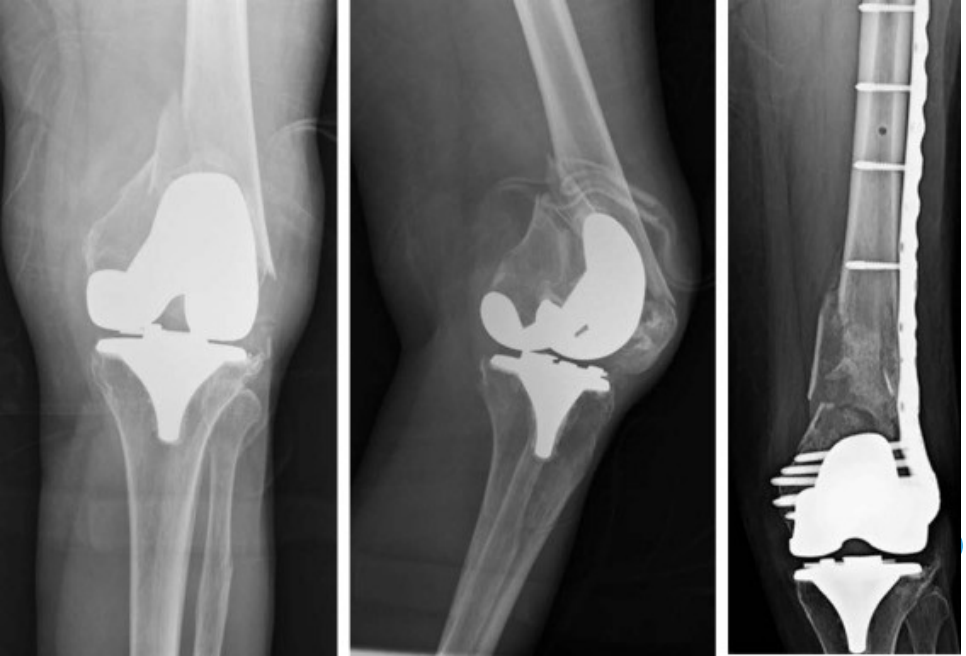© Copyright www.attri.co.za

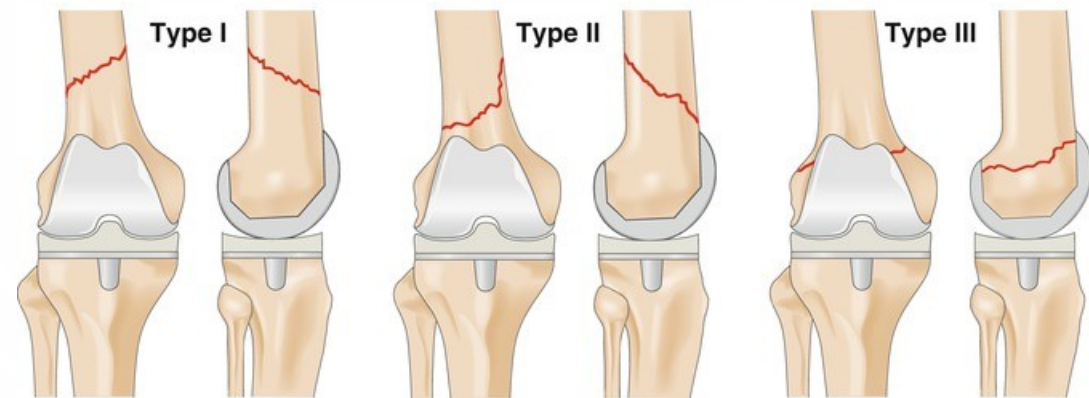


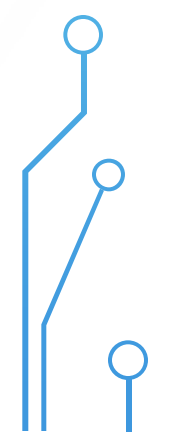

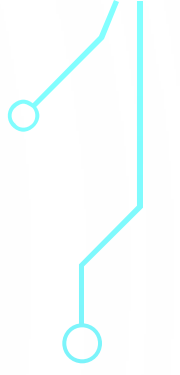
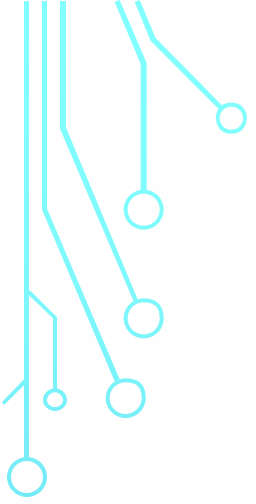












COMPONENTS OF THE BUSINESS PLAN

1. EXECUTIVE SUMMARY

1.1. COMPANY OVERVIEW

1.1.1. COMPANY NAME AND TYPE

1.1.2. BUSINESS MODEL

1.1.3. MARKET POSITION

1.1.4. FINANCIAL SUMMARY

1.1.5. KEY PERSONNEL

1.1.6. CONTACT INFORMATION

1.2. MARKET ANALYSIS

1.2.1. MARKET SIZE AND GROWTH

1.2.2. TARGET MARKET

1.2.3. COMPETITIVE ANALYSIS

1.2.4. SWOT ANALYSIS

