

Spinal Fractures Classification System

an AOSpine Knowledge Forum initiative

- Subaxial Spine Fractures
- Thoracolumbar Spine Fractures
- Sacral Spine Fractures

AOSpine—the leading global academic community for innovative education and research in spine care, inspiring lifelong learning and improving patients' lives.

Spinal Fractures Classification System

an AOSpine Knowledge Forum initiative

CONTENT

- AOSpine Classification and Injury Severity System 04
for Traumatic Fractures of the Subaxial Spine
- AOSpine Classification and Injury Severity System 37
for Traumatic Fractures of the Thoracolumbar Spine
- AOSpine Classification and Injury Severity System 55
for Traumatic Fractures of the Sacral Spine

AOSpine Knowledge Forum

■ AOSpine Classification and Injury Severity System for Traumatic Fractures of the Subaxial Spine

This is the present form of the classification the AOSpine Knowledge Forum (KF) SCI & Trauma is working on. It is the aim of the KF to develop a system, which can in the future be used as a tool for scientific research and a guide for treatment. This system is being subjected to a rigorous scientific assessment.

Project members (in alphabetic order)

Aarabi B, Bellabarba C, Chapman J, Dvorak M, Fehlings M, Kandziora F, Kepler C, Oner C, Rajasekaran S, Reinhold M, Schnake K, Vialle L and Vaccaro A.

Disclaimer

1. Vaccaro, A. R., J. D. Koerner, K. E. Radcliff, F. C. Oner, M. Reinhold, K. J. Schnake, F. Kandziora, M. G. Fehlings, M. F. Dvorak, B. Aarabi, S. Rajasekaran, G. D. Schroeder, C. K. Kepler and L. R. Vialle (2015). "AOSpine subaxial cervical spine injury classification system." Eur Spine J.
2. International validation process to be completed in 2015.
3. Submitted to AOSpine International Board for endorsement as the official AOSpine TL Fractures Classification

Compression injuries

Type		Description
A0	Minor, nonstructural fractures	No bony injury or minor injury such as an isolated lamina fracture or spinous process fracture.
A1	Wedge-compression	Compression fracture involving a single endplate without involvement of the posterior wall of the vertebral body.
A2	Split	Coronal split or pincer fracture involving both endplates without involvement of the posterior wall of the vertebral body.
A3	Incomplete burst	Burst fracture involving a single endplate with involvement of the posterior vertebral wall.
A4	Complete burst	Burst fracture or sagittal split involving both endplates.

Tension band injuries

Type		Description
B1	Posterior tension band injury (bony)	Physical separation through fractured bony structures only.
B2	Posterior tension band injury (bony capsuloligamentous, ligamentous)	Complete disruption of the posterior capsuloligamentous or bony capsuloligamentous structures together with a vertebral body, disk, and/or facet injury.
B3	Anterior tension band injury	Physical disruption or separation of the anterior structures (bone/disk) with tethering of the posterior elements.

Translation injuries

Type	
C	Translational injury in any axis-displacement or translation of one vertebral body relative to another in any direction

Bilateral injuries

Type	
BL	Bilateral injury

Facet injuries

Type		Description
F1	Nondisplaced facet fracture	With fragment <1cm in height, <40% of lateral mass.
F2	Facet fracture with potential for instability	With fragment >1cm, > than 40% lateral mass, or displaced.
F3	Floating lateral mass	
F4	Pathologic subluxation or perched/ dislocated facet	

Neurological status modifier

- Neurologic status at the moment of admission should be scored according to the following scheme:

Type	Description
N0	Neurologically intact
N1	Transient neurologic deficit, resolved
N2	Radiculopathy
N3	Incomplete spinal cord injury
N4	Complete spinal cord injury
NX	Cannot be examined

Case-specific modifiers

- There are four modifiers, which can be used in addition to ad 1 and 2:

Type	Description
M1	Posterior capsuloligamentous complex injury without complete disruption
M2	Critical disk herniation
M3	Stiffening/metabolic bone disease (ie.: DISH, AS, OPLL, OLF)
M4	Vertebral artery abnormality

Classification nomenclature

- Injuries are first classified by their level and primary injury type, either C, B, or A. If there are multiple levels, the most severe level is classified first. The secondary injuries are parenthesized.

For example, a C6-C7 translational injury (C) with a C7 compression fracture (A1) would be classified as:

C6-C7:C
(C7:A1)

And a C5-C6 flexion distraction injury (B2) with a C6 compression fracture (A1) would be classified as:

C5-C6:B2
(C6:A1)

Classification—Facet Injuries

- Included in parenthesis are the remaining subgroups in the order of: facet injuries, neurological status, and any modifiers.
- For bilateral facet injuries, the “BL” modifier is added after the facet injury if the injuries are the same. For example, a C6-C7 flexion distraction injury (B2) with bilateral facet dislocation (F4) would be classified as:

**C6-C7:B2
(F4 BL)**

- When there are different facet injuries to the same level, the right side is listed first, then the left. For example, a C6-C7 flexion distraction injury (B2) with right sided facet dislocation (F4) and a left sided displaced facet fracture (F2) would be classified as:

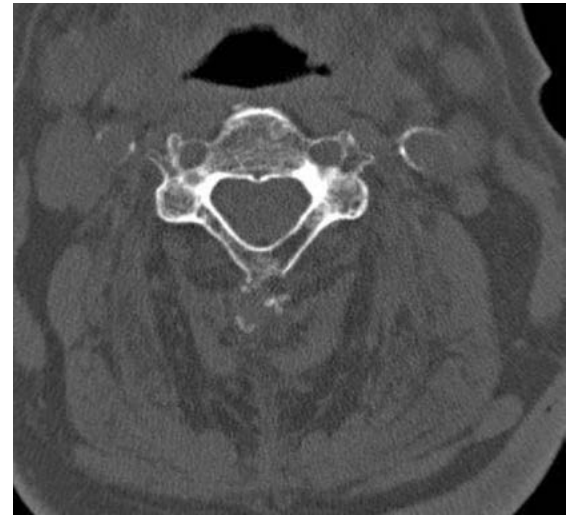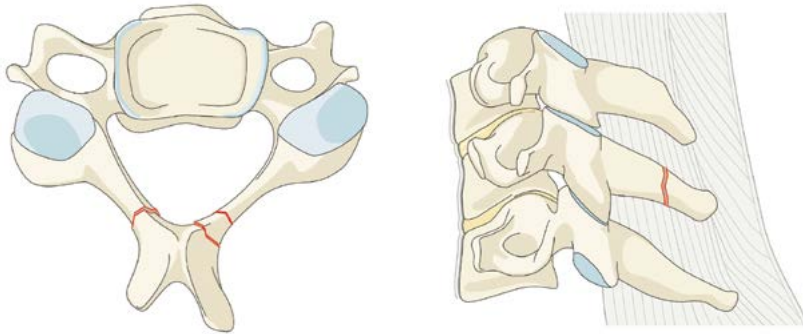
**C6-C7:B2
(F4, F2)**

- If there are multiple injuries to the same facet (For example: small fracture (F1) and dislocation (F4), only the highest level facet injury is classified (F4).
- If only facet injuries are identified (No A, B, or C injury), they are listed first after the level of injury.

Type A: Compression injuries

AO. Minor, nonstructural fractures

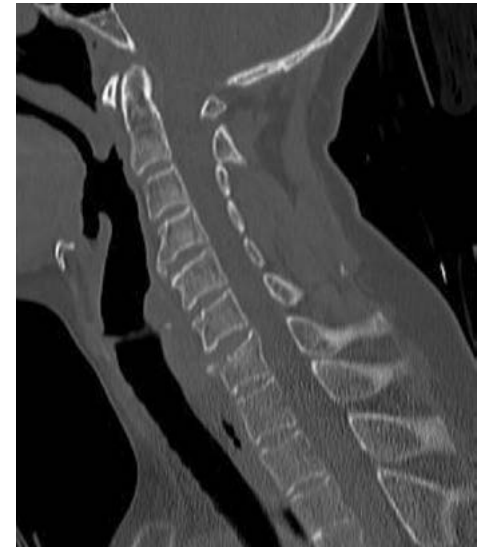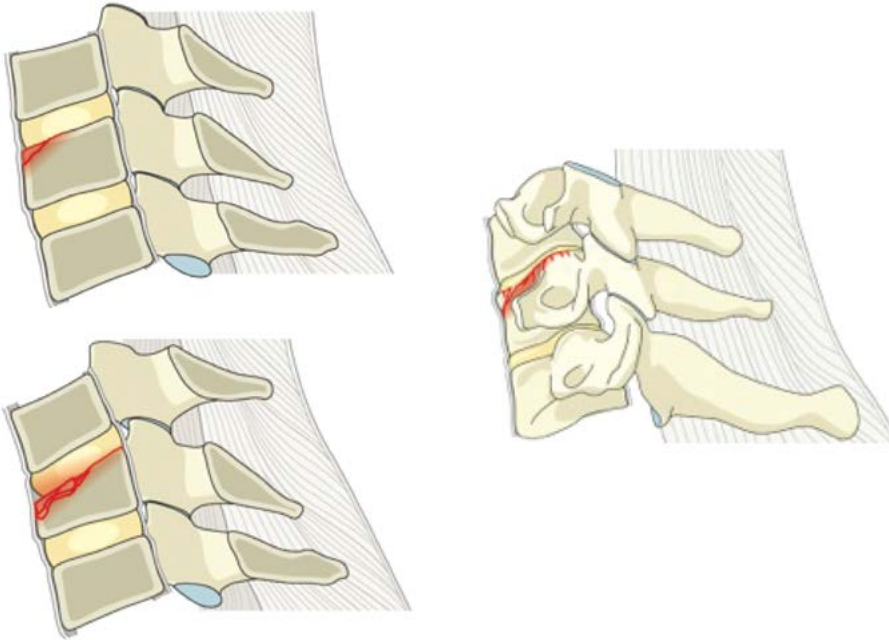
- No bony injury or minor injury such as an isolated lamina fracture or spinous process fracture.



Type A: Compression injuries

A1. Wedge-compression

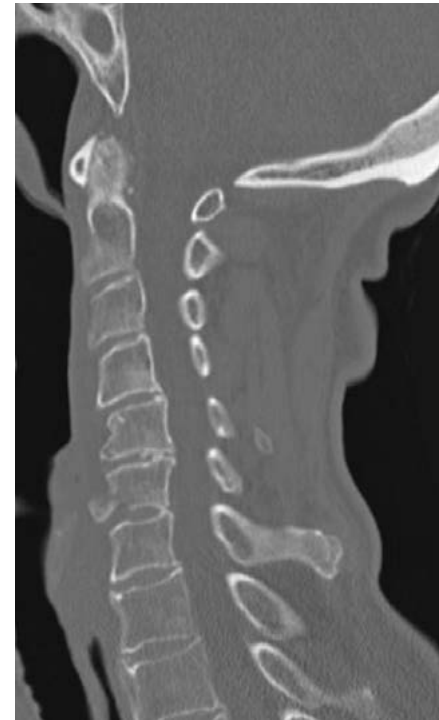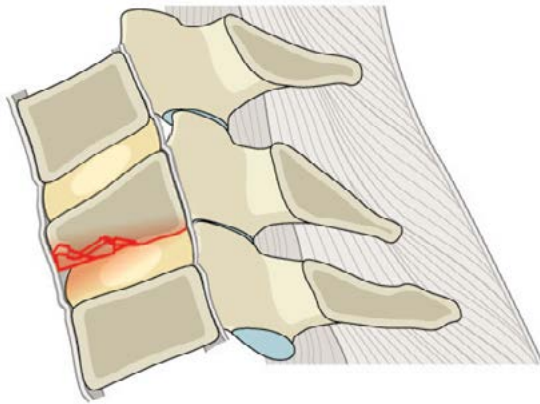
- Compression fracture involving a single endplate without involvement of the posterior wall of the vertebral body.



Type A: Compression injuries

A1. Wedge-compression

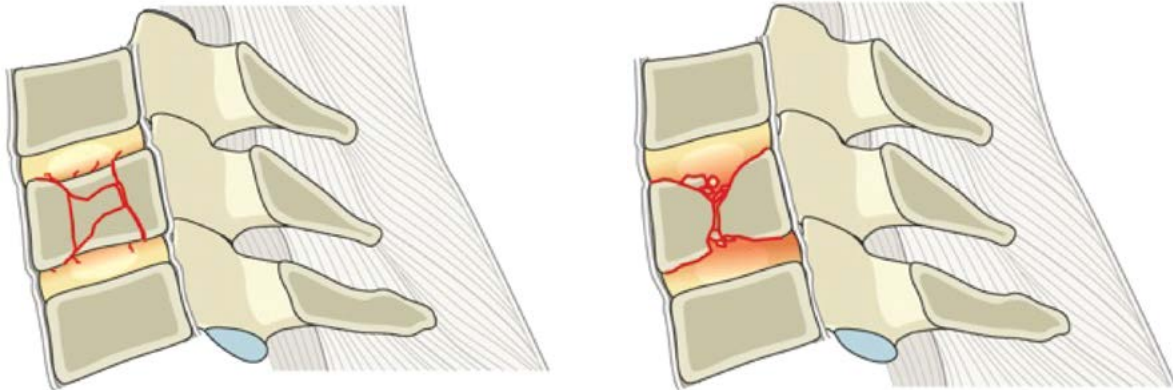
- Compression fracture involving a single endplate without involvement of the posterior wall of the vertebral body.



Type A: Compression injuries

A2. Split

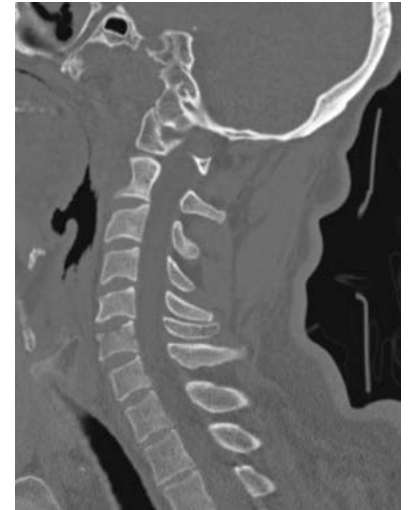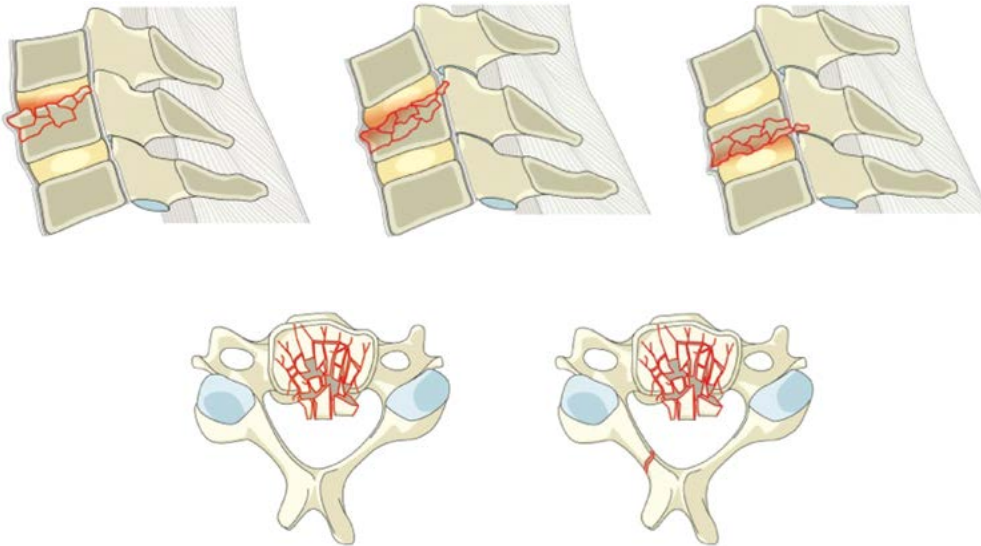
- Coronal split or pincer fracture involving both endplates without involvement of the posterior wall of the vertebral body.



Type A: Compression injuries

A3. Incomplete burst

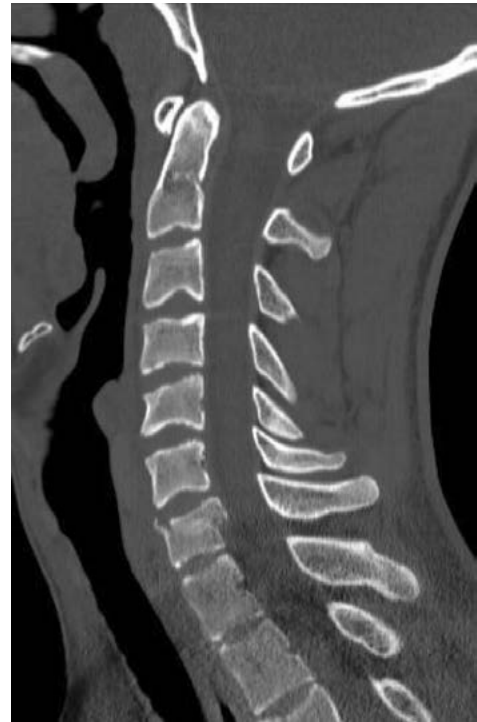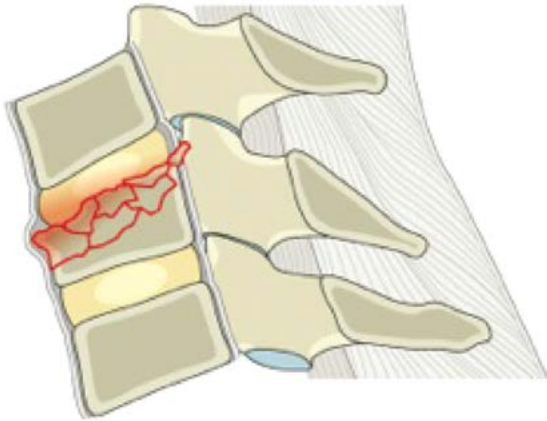
- Burst fracture involving a single endplate with involvement of the posterior vertebral wall.



Type A: Compression injuries

A3. Incomplete burst

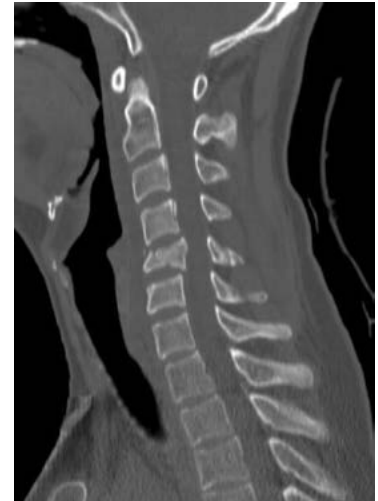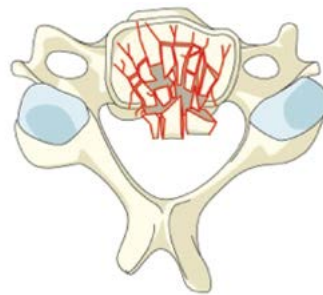
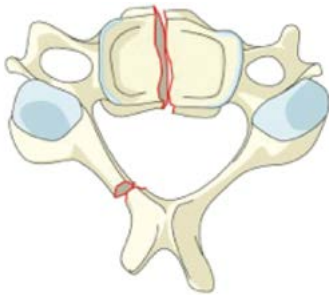
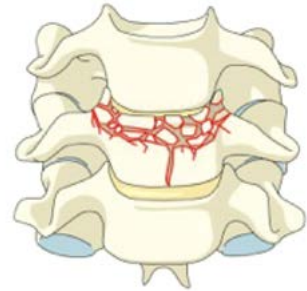
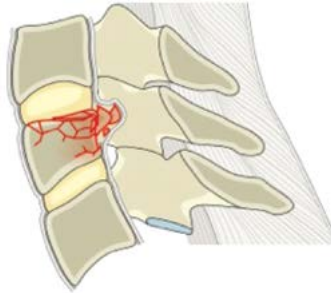
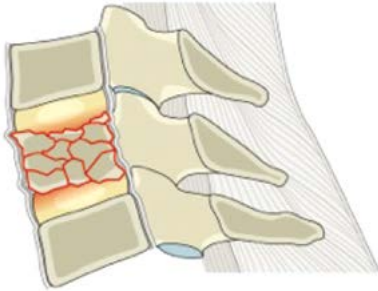
- Burst fracture involving a single endplate with involvement of the posterior vertebral wall.



Type A: Compression injuries

A4. Complete burst

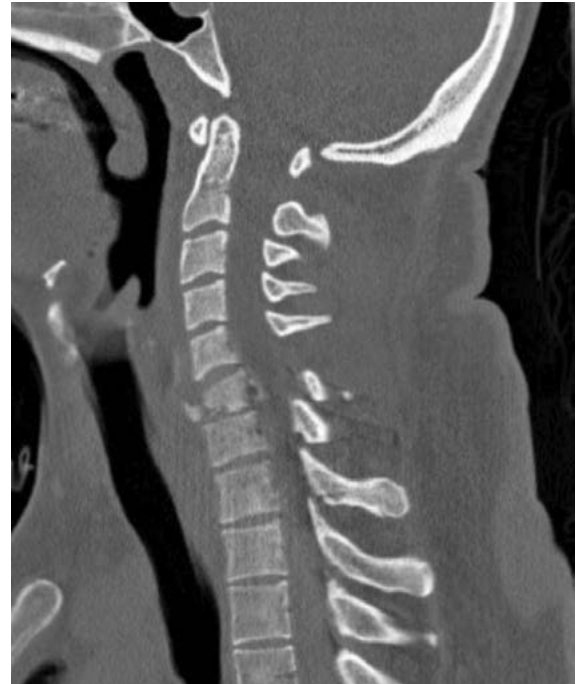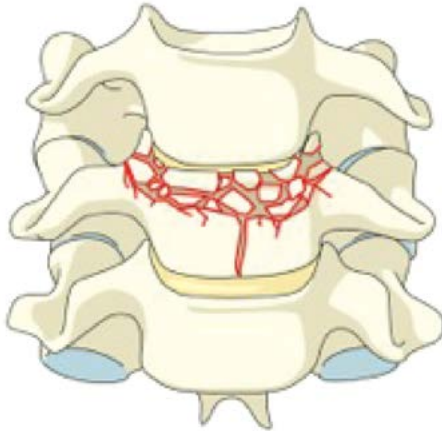
- Burst fracture or sagittal split involving both endplates.



Type A: Compression injuries

A4. Complete burst

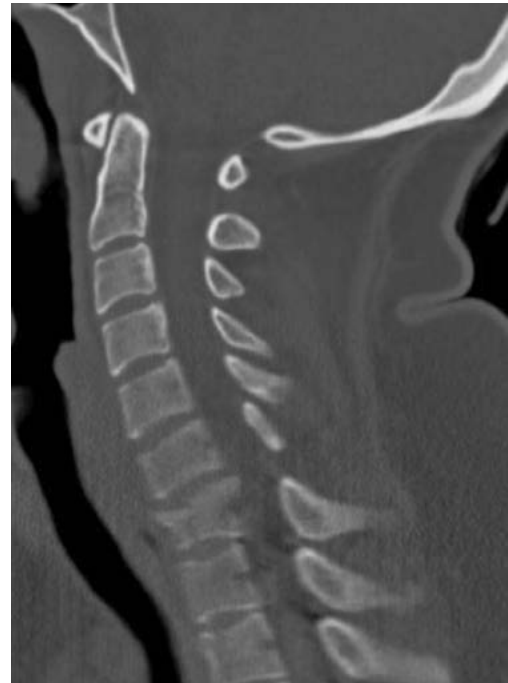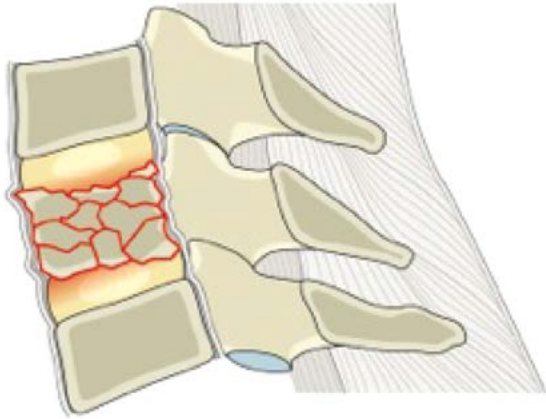
- Burst fracture or sagittal split involving both endplates.



Type A: Compression injuries

A4. Complete burst

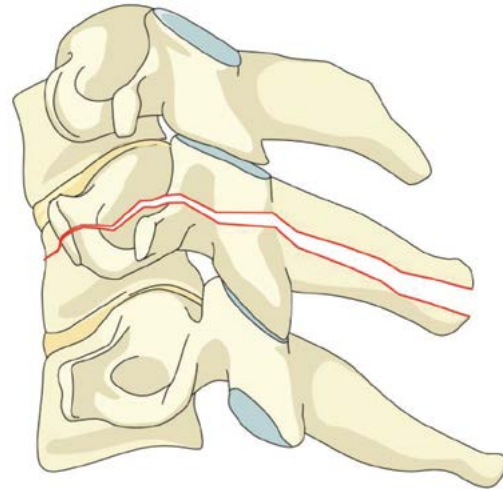
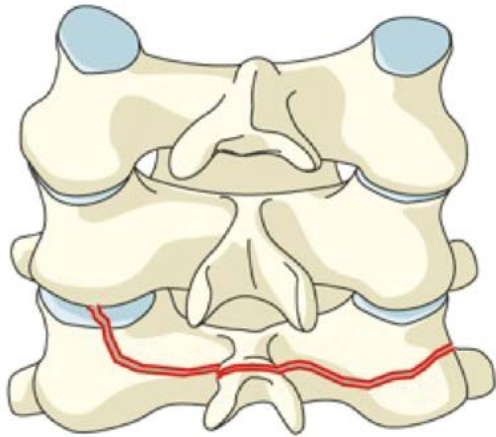
- Burst fracture or sagittal split involving both endplates.



Type B: Tension band injuries

B1. Posterior tension band injury (bony)

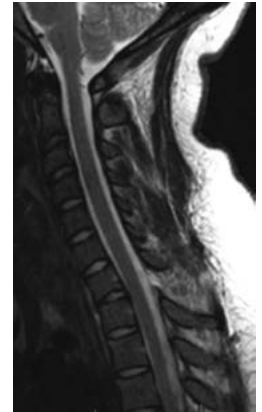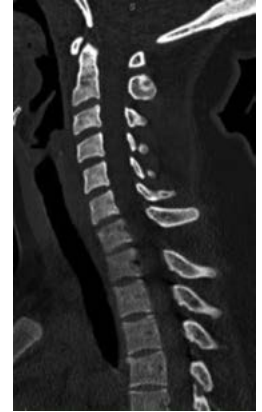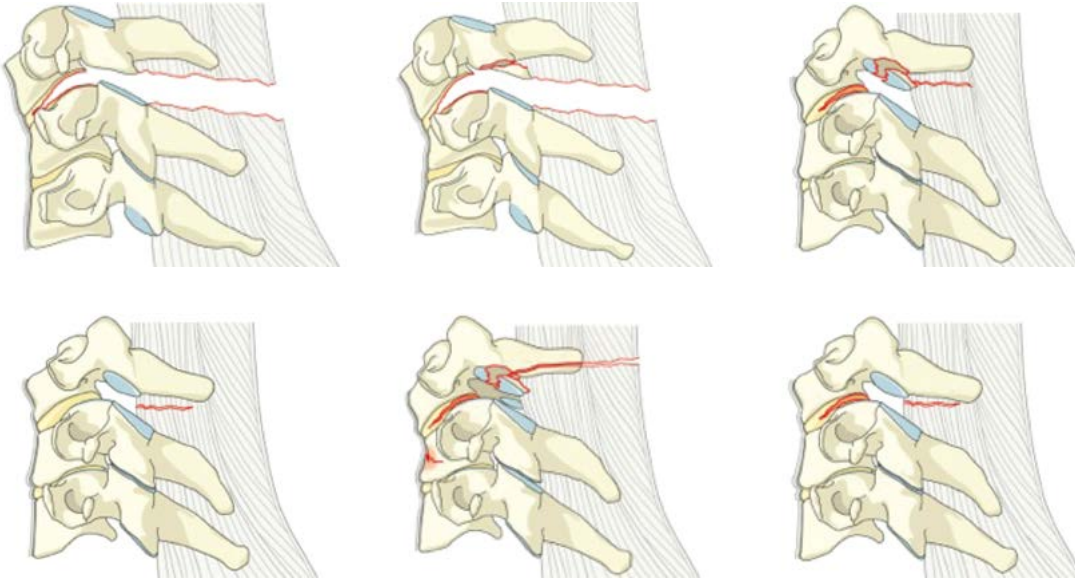
- Physical separation through fractured bony structures only.



Type B: Tension band injuries

B2. Posterior tension band injury (bony capsuloligamentous, ligamentous)

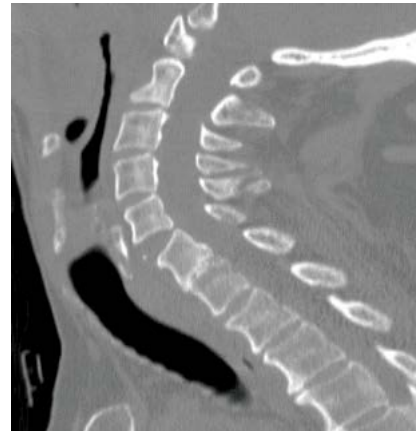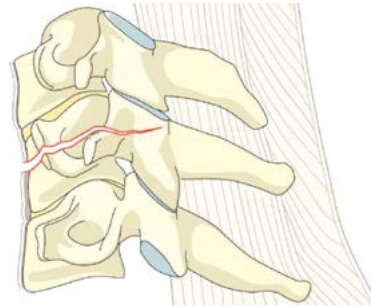
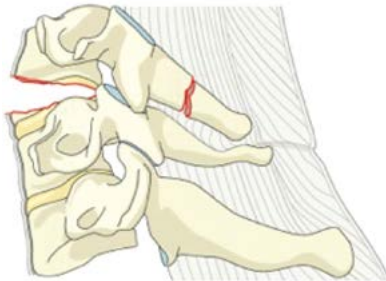
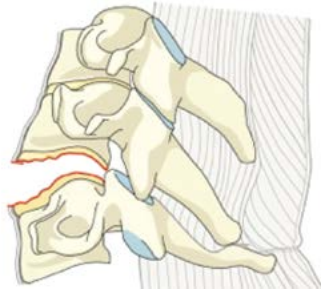
- Complete disruption of the posterior capsuloligamentous or bony capsuloligamentous structures together with a vertebral body, disk, and/or facet injury.



Type B: Tension band injuries

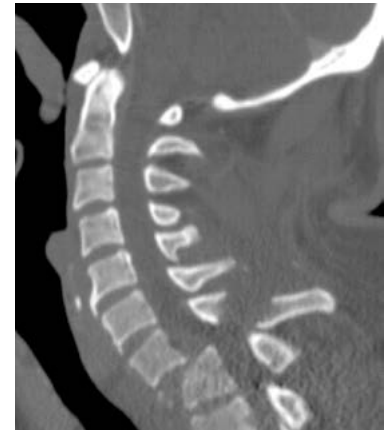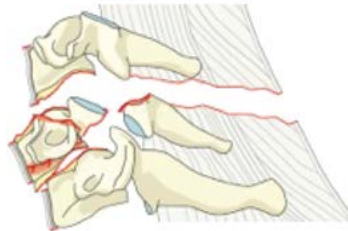
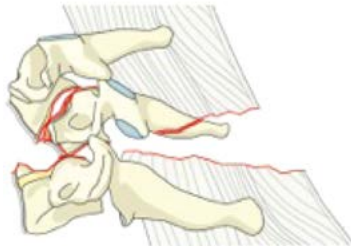
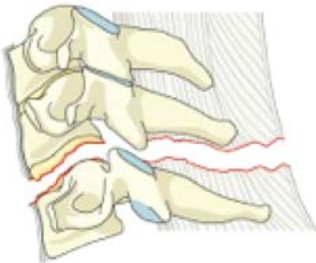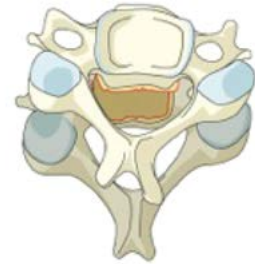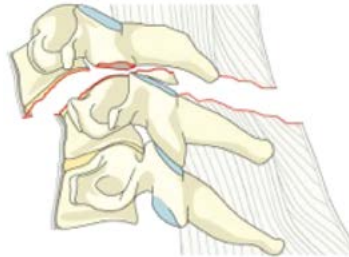
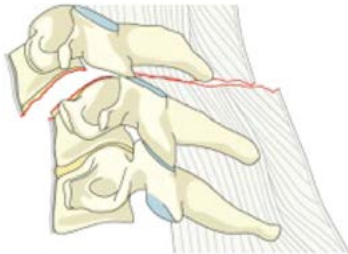
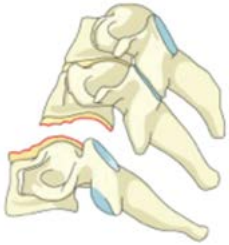
B3. Anterior tension band injury

- Physical disruption or separation of the anterior structures (bone/disk) with tethering of the posterior elements.



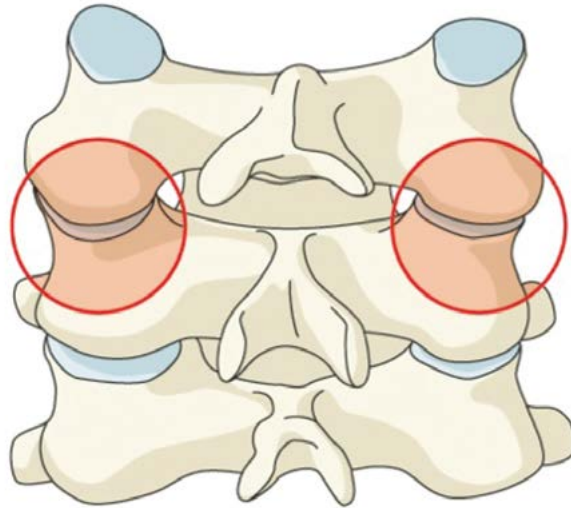
Type C: Translation injuries

C. Translational injury in any axis-displacement or translation of one vertebral body relative to another in any direction



Bilateral injuries

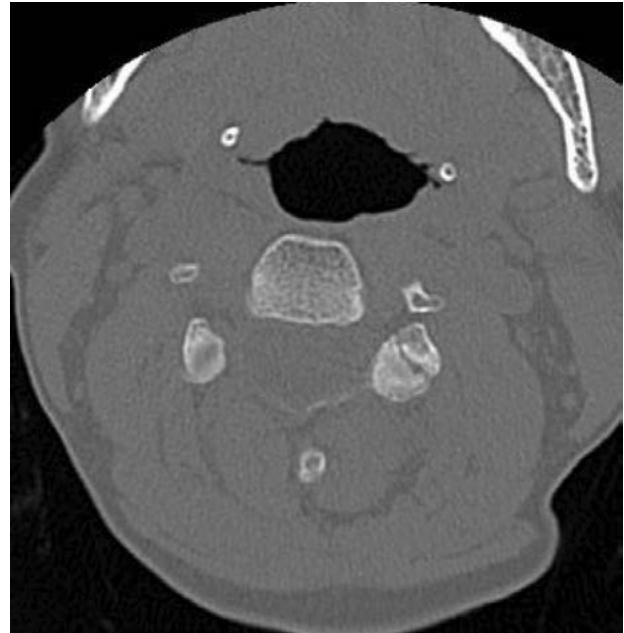
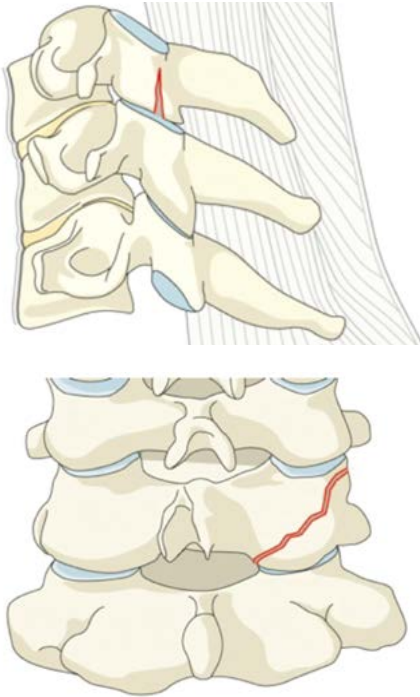
BL. Bilateral injury



Facet injuries

F1. Nondisplaced facet fracture

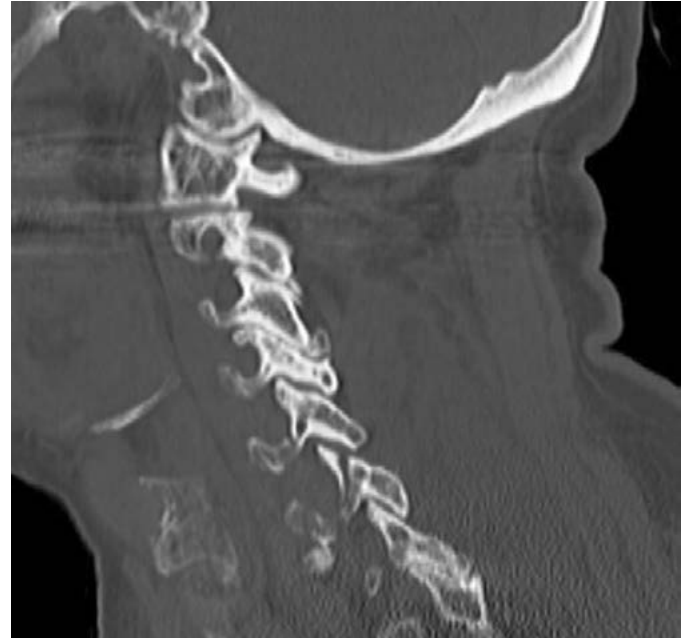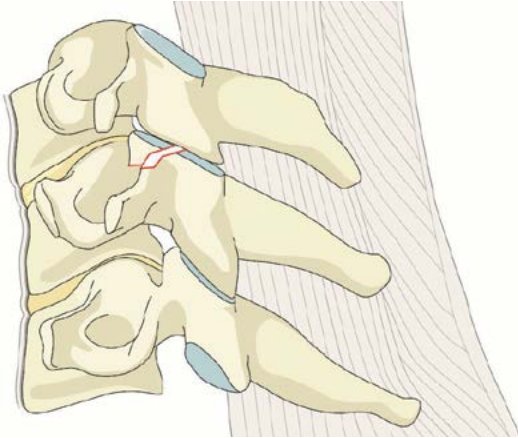
- With fragment <1 cm in height, <40% of lateral mass.



Facet injuries

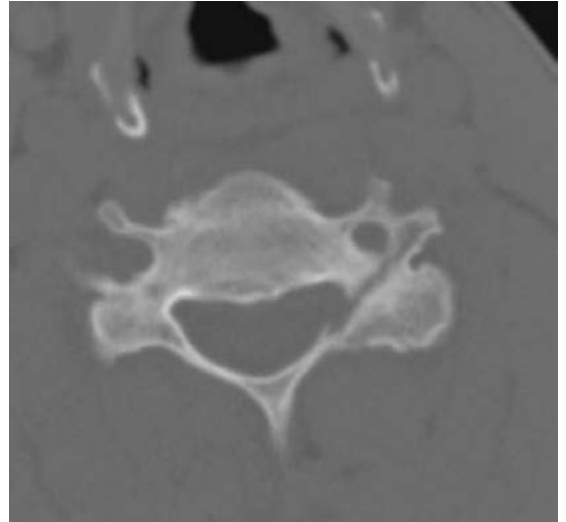
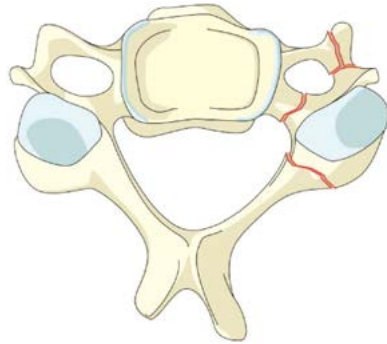
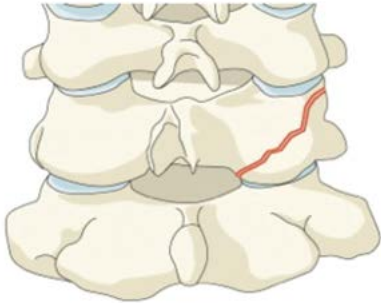
F2. Facet fracture with potential for instability

- With fragment >1 cm, $>$ than 40% lateral mass, or displaced.



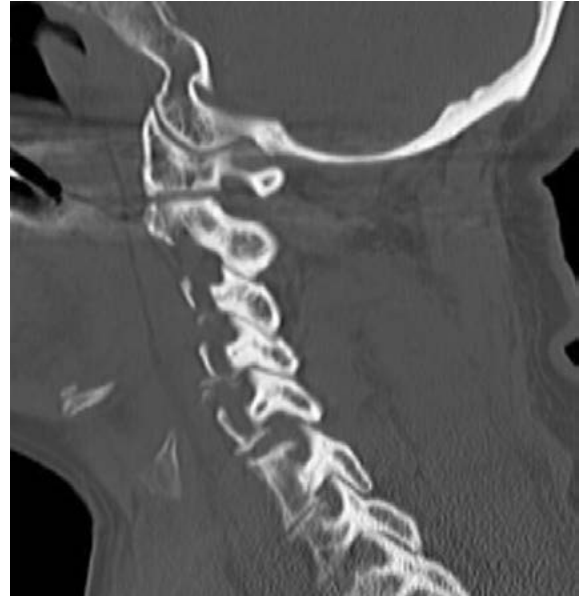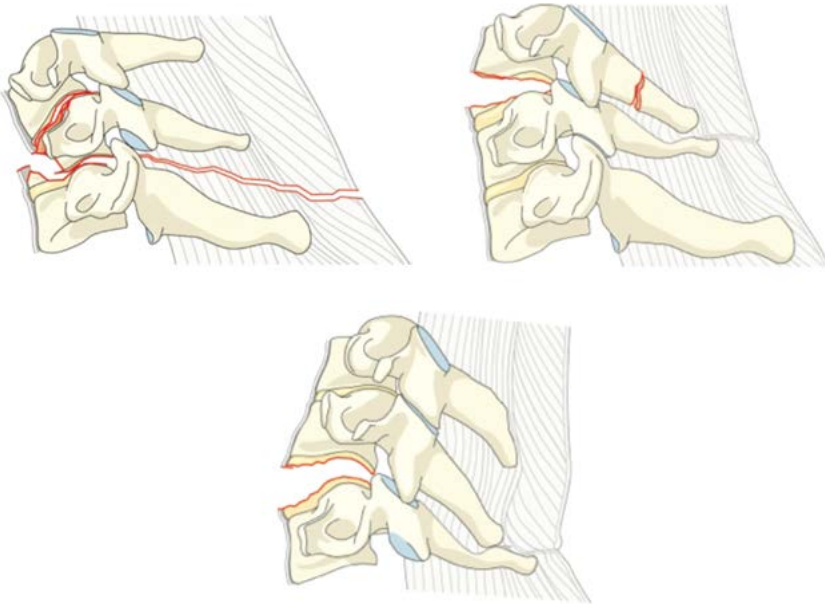
Facet injuries

F3. Floating lateral mass



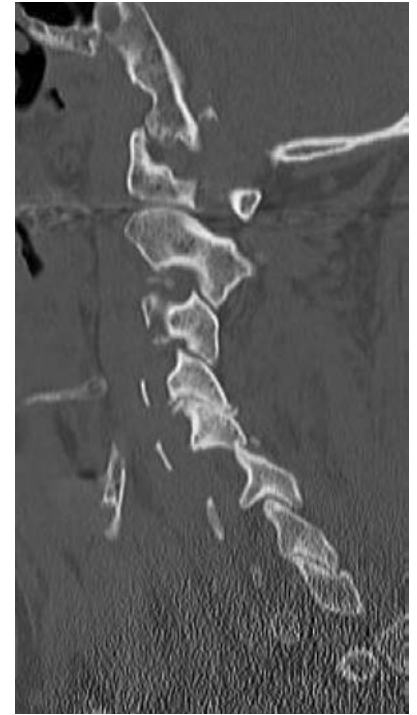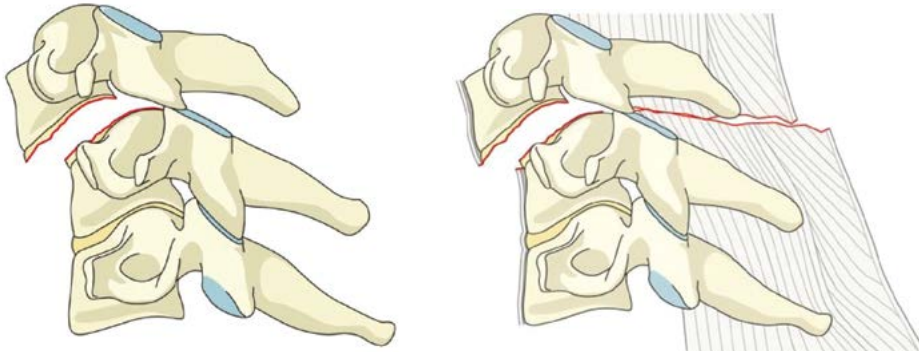
Facet injuries

F4. Pathologic subluxation or perched/dislocated facet



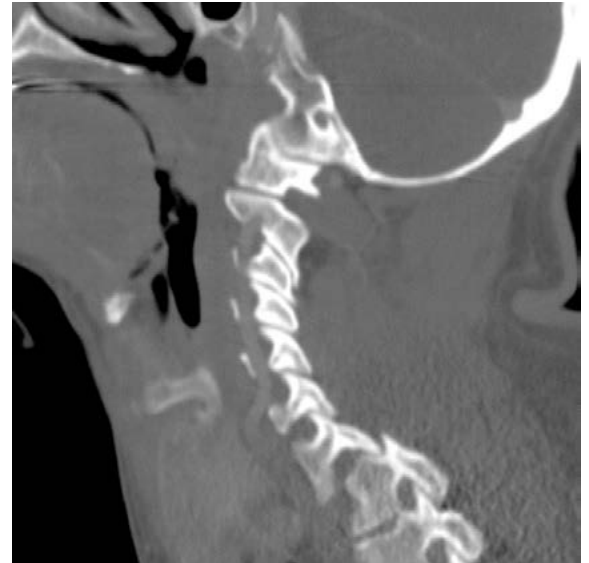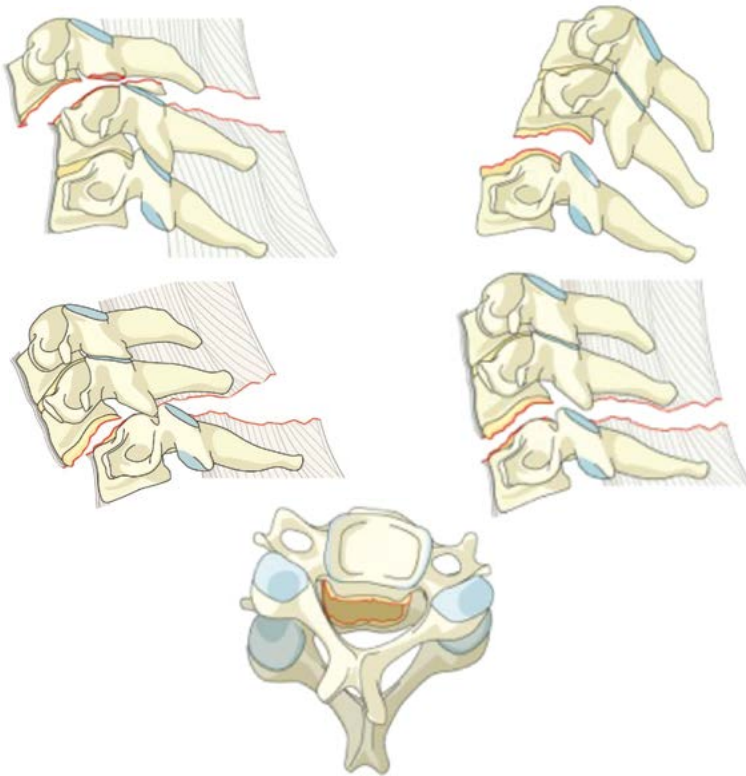
Facet injuries

F4. Pathologic subluxation or perched/dislocated facet



Facet injuries

F4. Pathologic subluxation or perched/dislocated facet



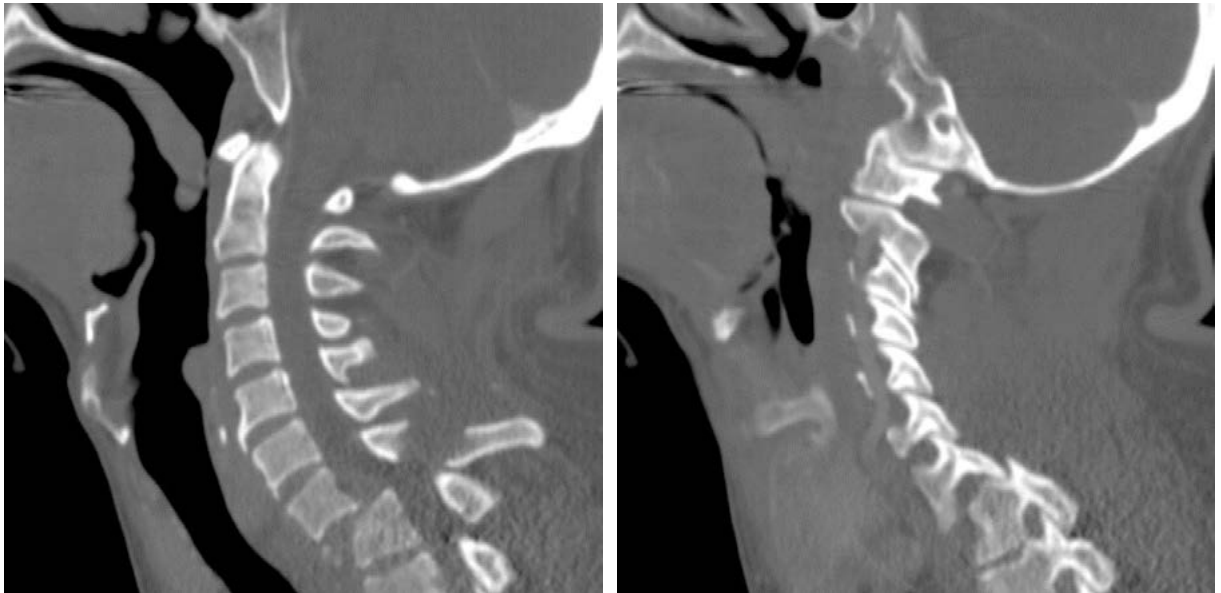Case Example 1.

25 year old male involved in high speed MVA, complete SCI

C7-T1: C

(T1:A1; F4 BL; N4)

(assume bilateral)



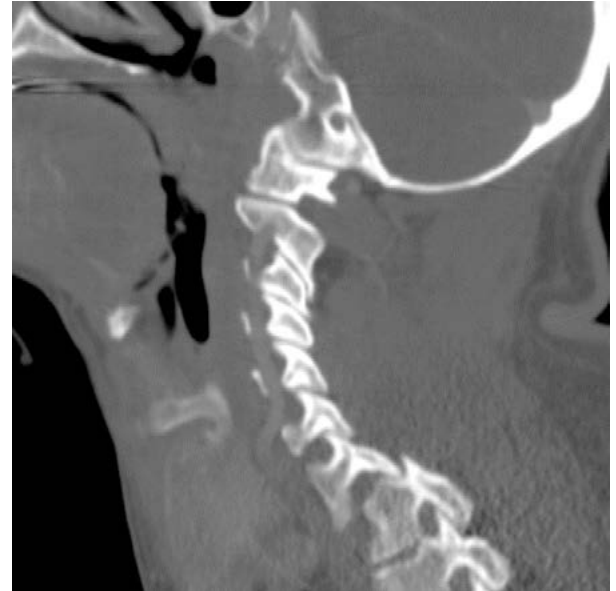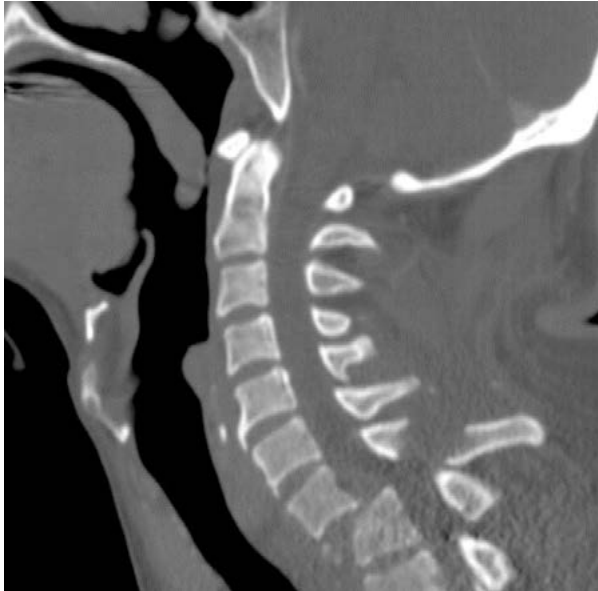
Case Example 1.

25 year old male involved in high speed MVA, complete SCI

C7-T1: C
(T1:A1; F4 BL; N4)

Translational injury (C), with compression fracture at T1 (A1), bilateral facet dislocations (F4 BL), complete SCI (N4)

(assume bilateral)

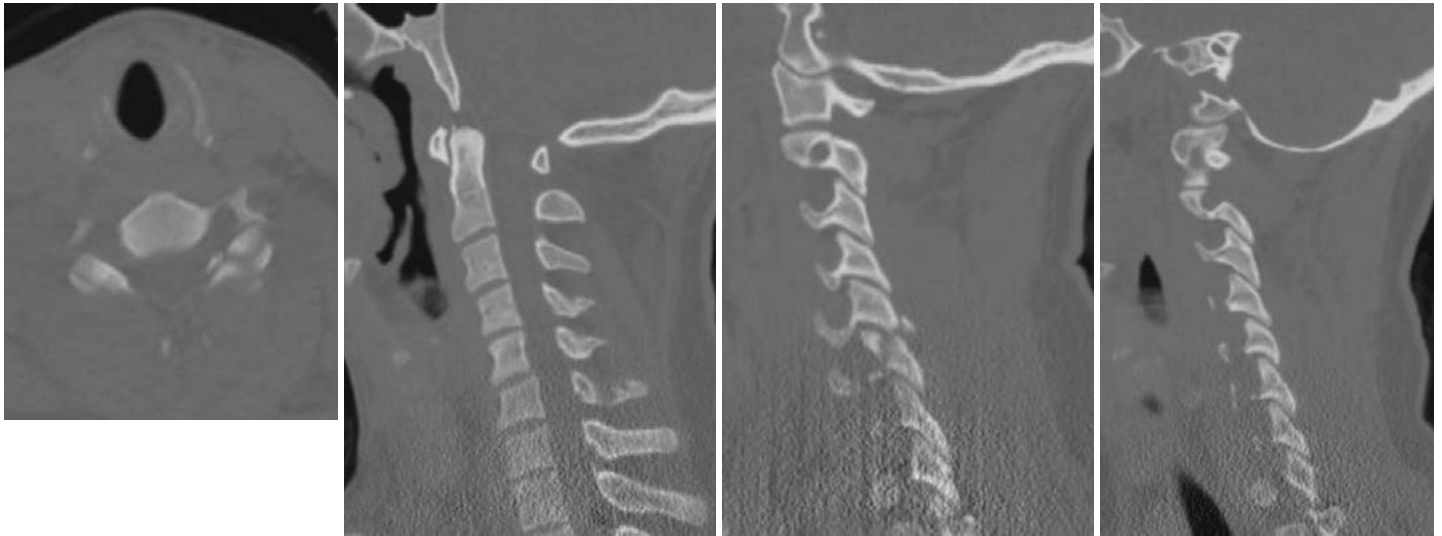

Case Example 2.

42 year old male involved in high speed MVA, radiculopathy

C5: F2, C6: F2

(N2; M1)

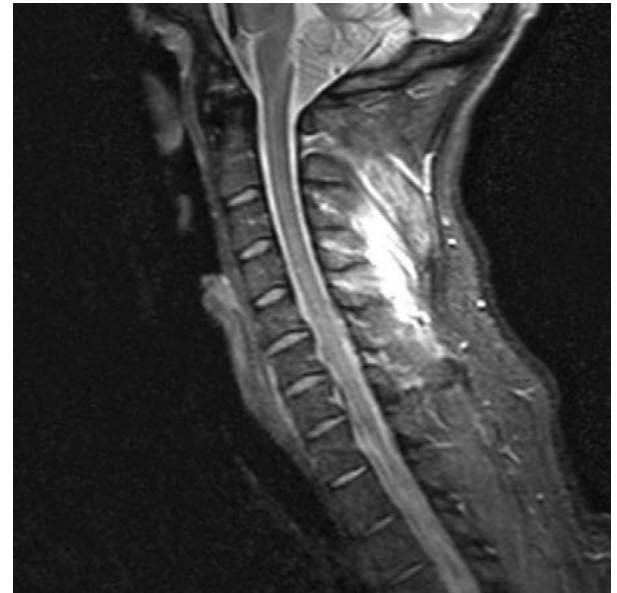
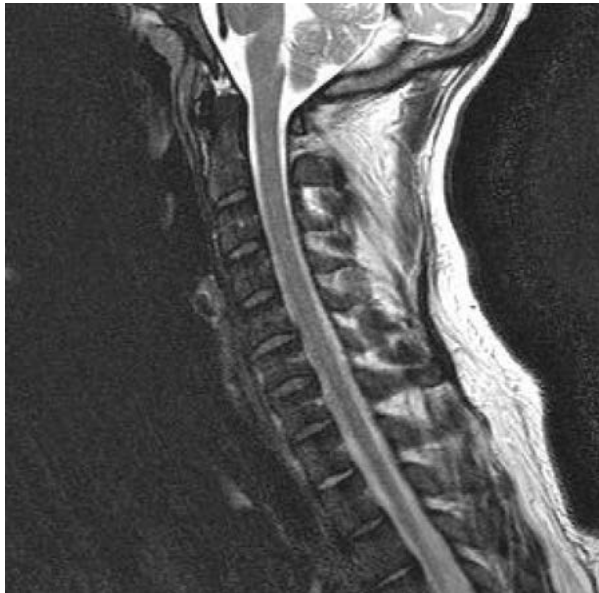


Case Example 2.

42 year old male involved in high speed MVA, radiculopathy

C5: F2, C6: F2
(N2; M1)

C5 and C6 displaced facet fractures (F2),
radiculopathy (N2), posterior capsuloligamentous
complex injury without complete disruption (M1)



AOSpine Knowledge Forum

■ AOSpine Classification and Injury Severity System for Traumatic Fractures of the Thoracolumbar Spine

This is the present form of the classification and injury severity system the AOSpine Knowledge Forum (KF) SCI & Trauma is working on. It is the aim of the KF to develop a system, which can in the future be used as a tool for scientific research and a guide for treatment. This system is being subjected to a rigorous scientific assessment.

Project members (in alphabetic order)

Aarabi B, Bellabarba C, Chapman J, Dvorak M, Fehlings M, Kandziora F, Kepler C, Oner C, Rajasekaran S, Reinhold M, Schnake K, Vialle L and Vaccaro A.

Disclaimer

1. Vaccaro, A. R., C. Oner, C. K. Kepler, M. Dvorak, K. Schnake, C. Bellabarba, M. Reinhold, B. Aarabi, F. Kandziora, J. Chapman, R. Shanmuganathan, M. Fehlings, L. Vialle, A. O. S. C. Injury and F. Trauma Knowledge (2013). "AOSpine thoracolumbar spine injury classification system: fracture description, neurological status, and key modifiers." Spine (Phila Pa 1976) 38(23): 2028-2037.
2. Kepler, C. K., A. R. Vaccaro, J. D. Koerner, M. Dvorak, F. Kandziora, S. Rajasekaran, L. Vialle, M. Fehlings, G. D. Schroeder, M. Reinhold, K. Schnake, C. Bellabarba and C. Oner (2015). "Reliability Analysis of the AOSpine thoracolumbar Spine Injury Classification System by a Worldwide Group of Naïve Spinal Surgeons." European Spine Journal. (in press)
3. Submitted to AOSpine International Board for endorsement as the official AOSpine TL Fractures Classification

Thoracolumbar Fractures—Overview

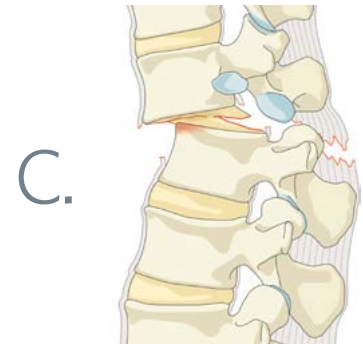
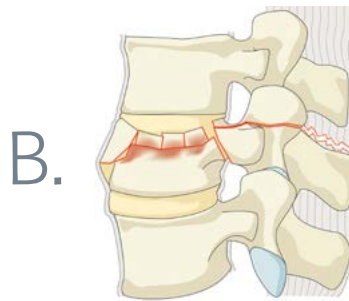
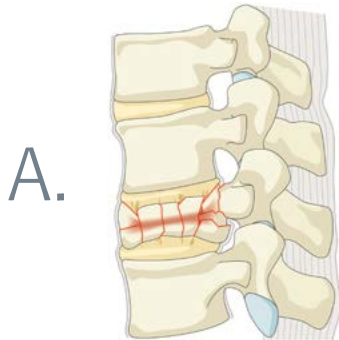
This classification and injury severity system is based on the evaluation of three basic parameters:

- 1. Morphologic classification of the fracture**
- 2. Neurologic injury**
- 3. Clinical modifiers**

1. Morphologic classification

This is based on the Magerl classification modified by the AOSpine Classification Group. For this evaluation radiograms and CT scans with multiplanar reconstructions are essential. In some cases additional MR images might be necessary. Three basic types are identified on the basis of the mode of failure of the spinal column:

- **Type A:** Compression injuries. Failure of anterior structures under compression.
- **Type B:** Failure of the posterior or anterior tension band.
- **Type C:** Failure of all elements leading to dislocation or displacement.



Type A

Describe injury to the vertebral body without tension band (PLC) involvement.

There are five subtypes and no further sub-classification.

These subtypes are also used as description of vertebral body fracture in B and C Types.

Type		Description
A0	Minor, nonstructural fractures	Fractures, which do not compromise the structural integrity of the spinal column such as transverse process or spinous process fractures.
A1	Wedge-compression	Fracture of a single endplate without involvement of the posterior wall of the vertebral body.
A2	Split	Fracture of both endplates without involvement of the posterior wall of the vertebral body.
A3	Incomplete burst	Fracture with any involvement of the posterior wall; only a single endplate fractured. Vertical fracture of the lamina is usually present and does not constitute a tension band failure.
A4	Complete burst	Fracture with any involvement of the posterior wall and both endplates. Vertical fracture of the lamina is usually present and does not constitute a tension band failure.

Type B

Describe the failure of posterior or anterior constraints (in case of TL this is the tension band or PLC / Posterior Ligamentary Complex or the anterior longitudinal ligament).

Is to be combined with subtypes A when appropriate. There are three subtypes:

Type		Description
B1	Transosseous tension band disruption / Chance fracture	Monosegmental pure osseous failure of the posterior tension band. The classical Chance fracture.
B2	Posterior tension band disruption	Bony and/or ligamentary failure of the posterior tension band together with a Type A fracture. Type A fracture should be classified separately.
B3	Hyperextension	Injury through the disk or vertebral body leading to a hyperextended position of the spinal column. Commonly seen in ankylotic disorders. Anterior structures, especially the ALL are ruptured but there is a posterior hinge preventing further displacement.

Type C

Describe displacement or dislocation.

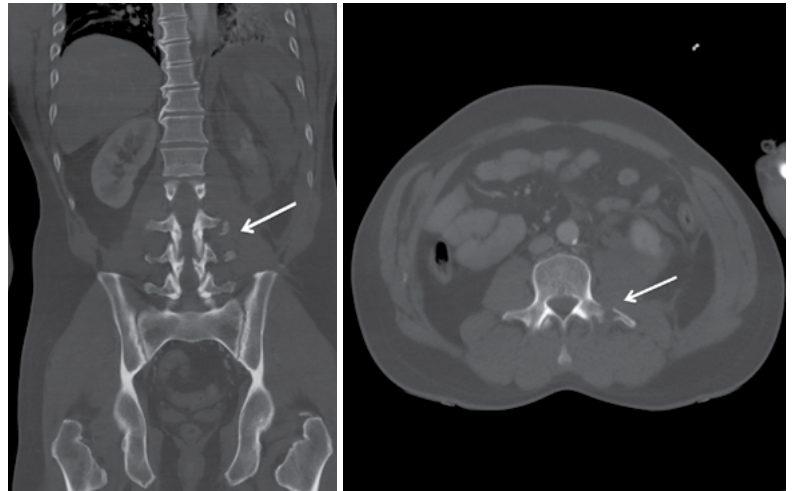
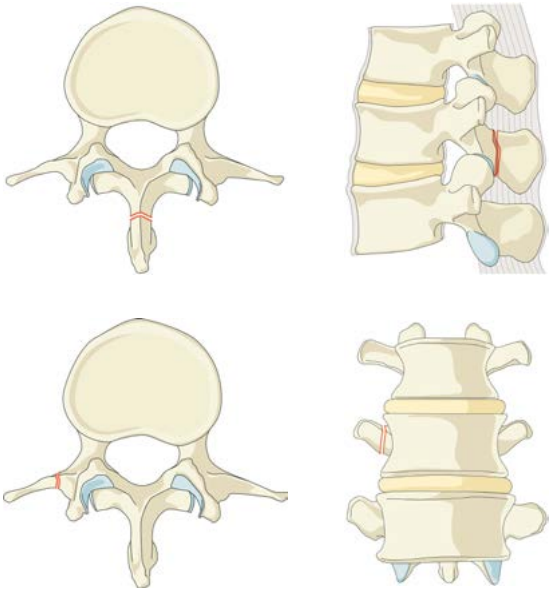
There are no subtypes as because of the dissociation between cranial and caudal segments various configurations are possible in different images.

Is combined with subtypes of A if necessary.

Type A

AO. Minor, nonstructural fractures

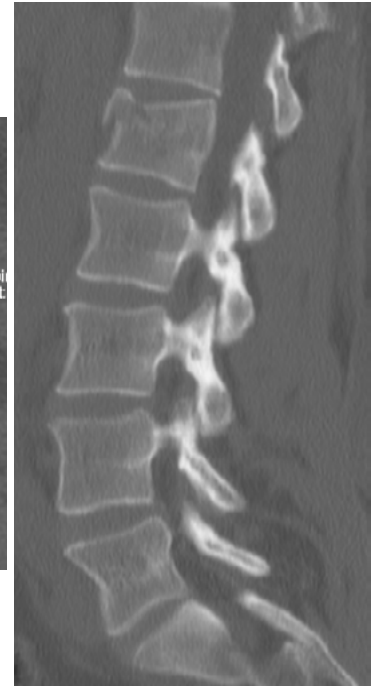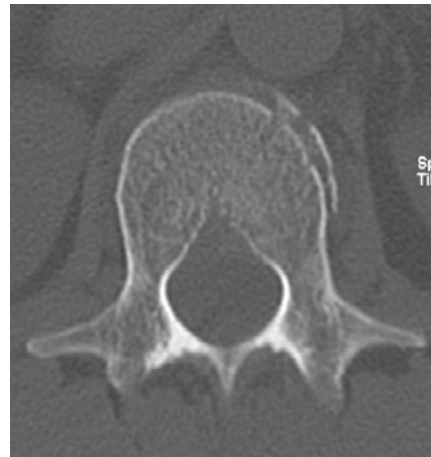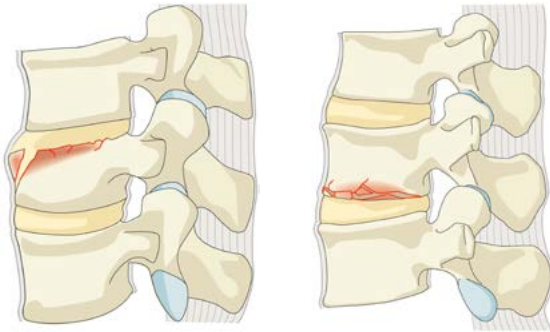
- Fractures, which do not compromise the structural integrity of the spinal column such as transverse process or spinous process fractures.



Type A

A1. Wedge-compression

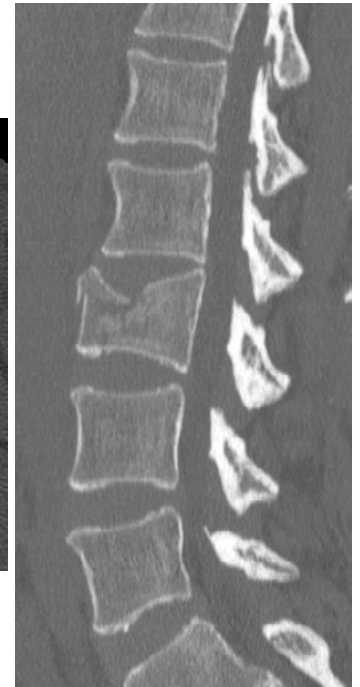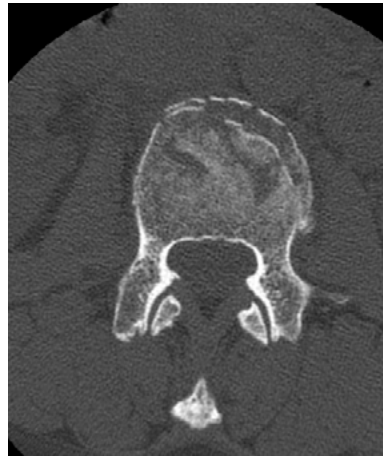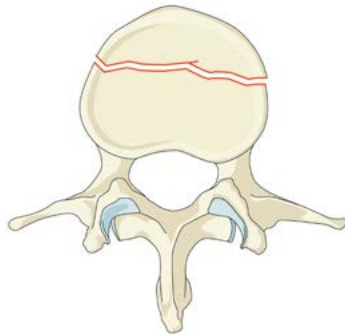
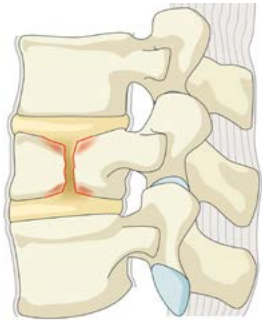
- Fracture of a single endplate without involvement of the posterior wall of the vertebral body.



Type A

A2. Split

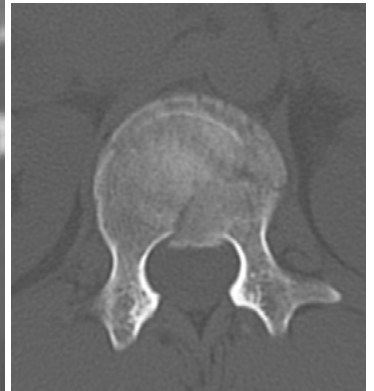
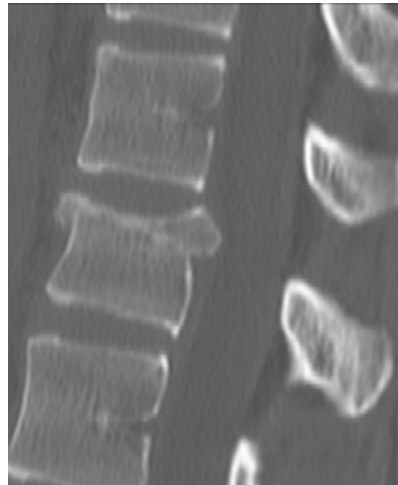
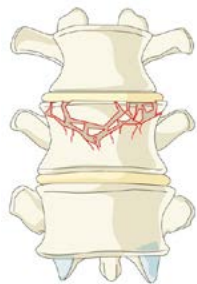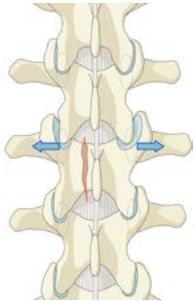
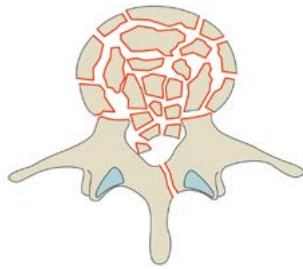
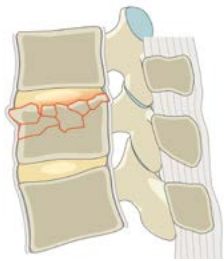- Fracture of both endplates without involvement of the posterior wall of the vertebral body.



Type A

A3. Incomplete burst

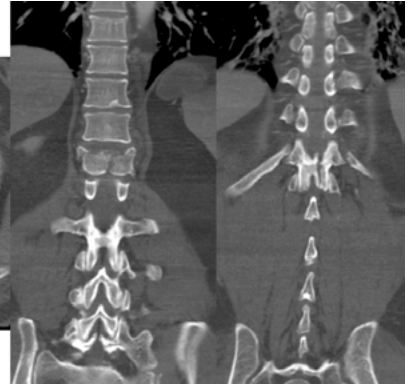
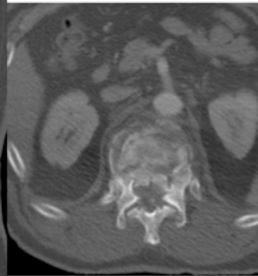
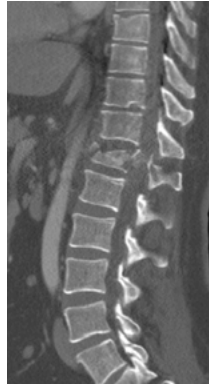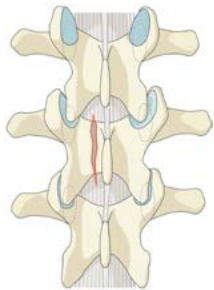
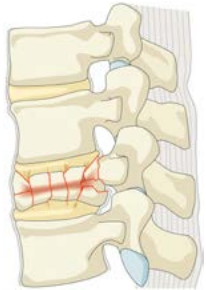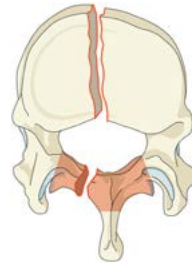
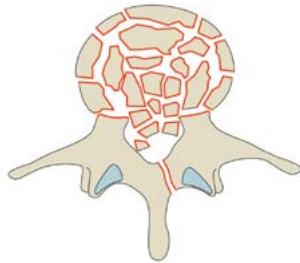
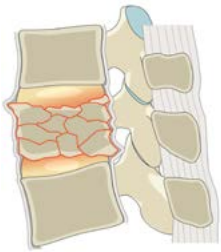- Fracture with any involvement of the posterior wall; only a single endplate fractured.
Vertical fracture of the lamina is usually present and does not constitute a tension band failure.



Type A

A4. Complete burst

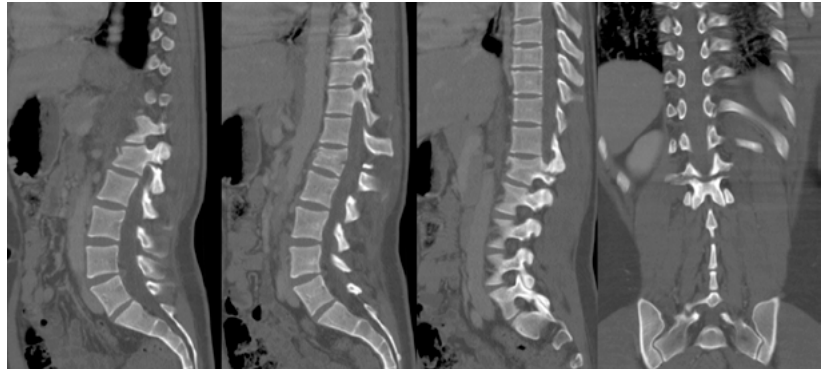
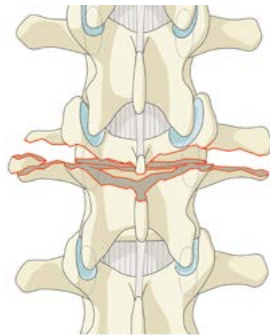
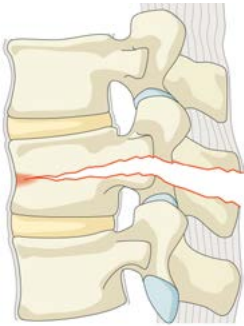- Fracture with any involvement of the posterior wall and both endplates.
Vertical fracture of the lamina is usually present and does not constitute a tension band failure.



Type B

B1. Transosseous tension band disruption/Chance fracture

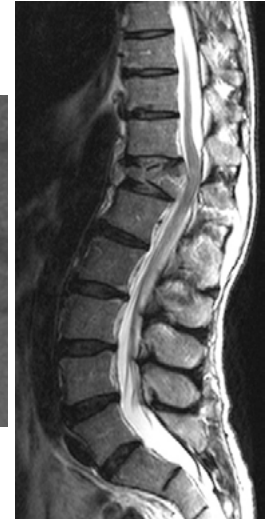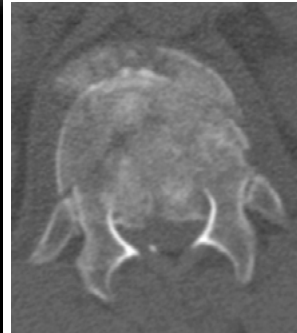
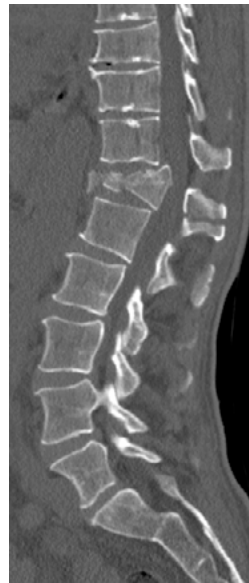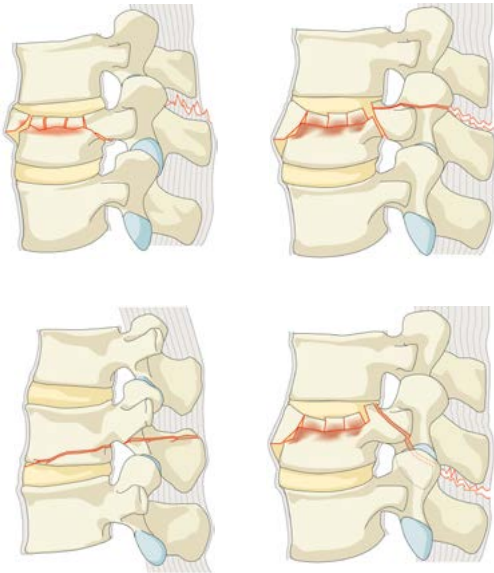
- Monosegmental pure osseous failure of the posterior tension band.
The classical Chance fracture.



Type B

B2. Posterior tension band disruption

- Bony and/or ligamentary failure of the posterior tension band together with a Type A fracture. Type A fracture should be classified separately.

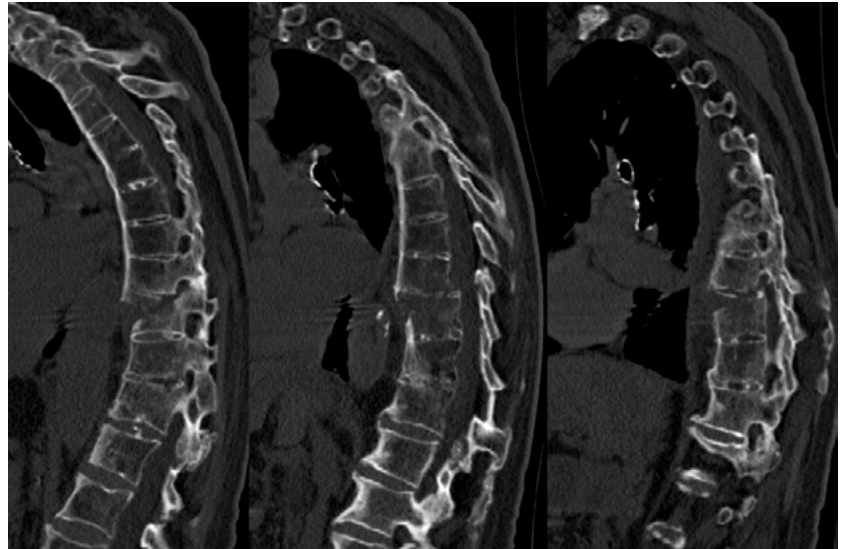
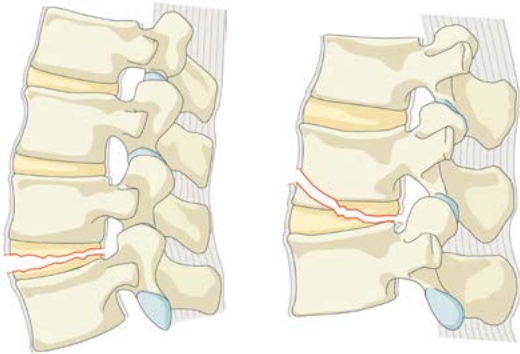


Example: This should be classified as: T12-L1 Type B2 with T12 A4 according to the combination rules.

Type B

B3. Hyperextension

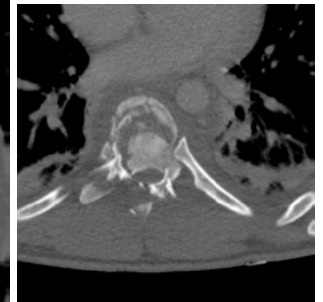
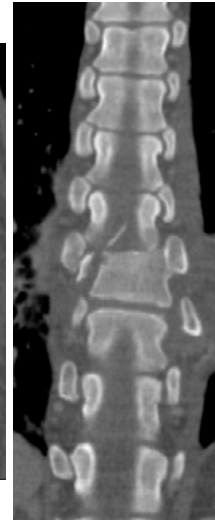
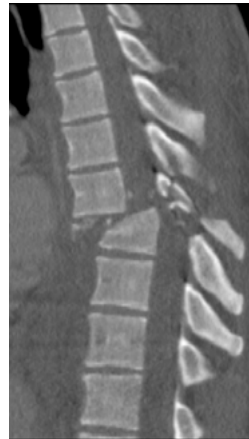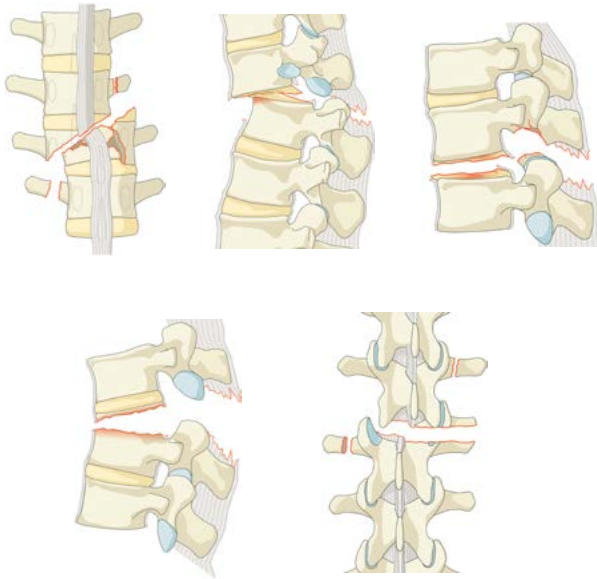
- Injury through the disk or vertebral body leading to a hyperextended position of the spinal column. Commonly seen in ankylosing disorders. Anterior structures, especially the ALL are ruptured but there is a posterior hinge preventing further displacement.



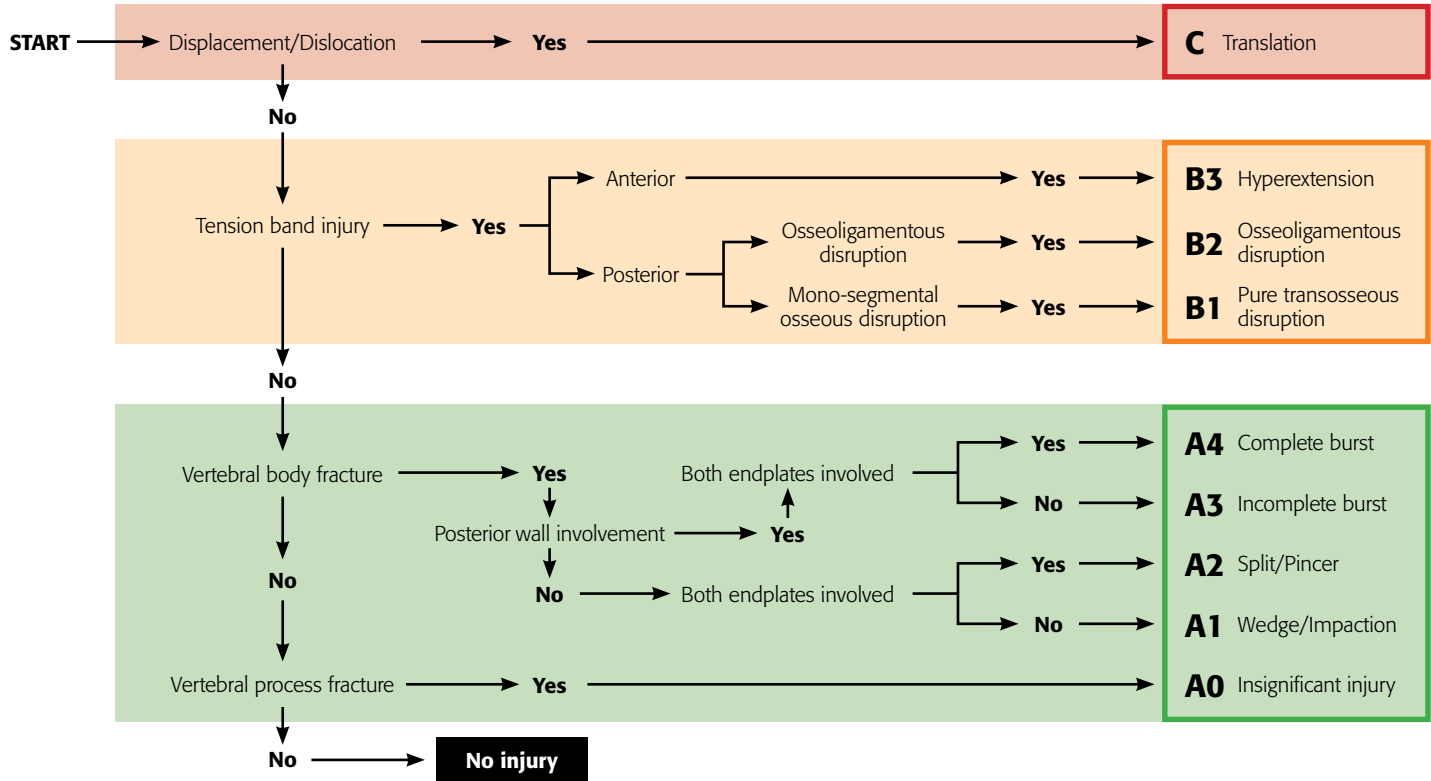
Type C

C. Displacement or dislocation

- There are no subtypes as because of the dissociation between cranial and caudal segments various configurations are possible in different images. Is combined with subtypes of A if necessary.



Algorithm for morphologic classification



2. Neurologic injury

Neurologic status at the moment of admission should be scored according to the following scheme:

Type	Description
N0	Neurologically intact
N1	Transient neurologic deficit, which is no longer present
N2	Radicular symptoms
N3	Incomplete spinal cord injury or any degree of cauda equina injury
N4	Complete spinal cord injury
NX	Neurologic status is unknown due to sedation or head injury

3. Modifiers

There are two modifiers, which can be used in addition to ad 1 and 2:

Type	Description
M1	This modifier is used to designate fractures with an indeterminate injury to the tension band based on spinal imaging with or without MRI. This modifier is important for designating those injuries with stable injuries from a bony standpoint for which ligamentous insufficiency may help determine whether operative stabilization is a consideration.
M2	Is used to designate a patient-specific comorbidity, which might argue either for or against surgery for patients with relative surgical indications. Examples of an M2 modifier include ankylosing spondylitis or burns affecting the skin overlying the injured spine.

AOSpine Knowledge Forum

■ AOSpine Classification and Injury Severity System for Traumatic Fractures of the Sacral Spine

Xxxxx

Project members
(in alphabetic order) | Xxxxx

Disclaimer | 1. Xxxxx

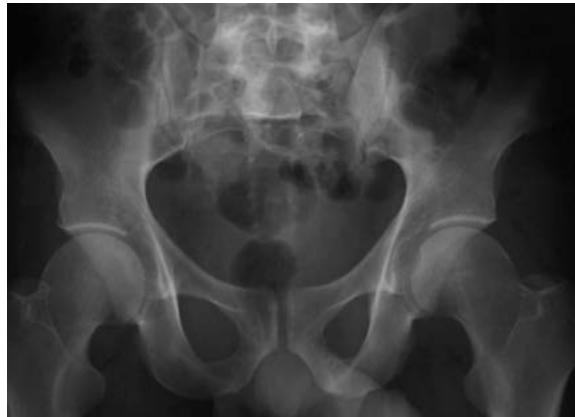Sacral Fractures: Overview

Sacral Fractures

Pelvic Ring Fractures
(Tile, Letournel, AO)

Lumbosacral Dislocation
(Isler)

Sacral Fractures
(Denis, Roy-Camille)



Implications on Prognosis & Treatment

- Degree of instability
 - Broadly correlated with:
 - Energy of injury
 - Amount of displacement

- Type of instability
 - Location of fracture:
 - Lower sacrum (no pelvic or spino-pelvic involvement)
 - Posterior pelvic
 - Spino-pelvic
 - Both posterior pelvic & spino-pelvic

- Neurological injury
 - Broadly correlated with:
 - Energy of injury
 - Amount of displacement

Sacral Fractures—Overview

- Hierarchical system progressing from least to most unstable
- **Type A.** Lower Sacrococcygeal Injuries
 - NO IMPACT ON POSTERIOR PELVIC OR SPINO-PELVIC INSTABILITY
 - Eg. Compression/avulsion fractures/injuries below sacroiliac joints
 - *Higher grade subtypes may be associated with neuro injury
- **Type B.** Posterior Pelvic Injuries
 - PRIMARY IMPACT IS ON POSTERIOR PELVIC STABILITY
 - Unilateral longitudinal (vertical) sacral fractures
 - No impact on spino-pelvic stability
 - Framework is a variation of Denis Zones I through III injuries
- **Type C.** Spino-Pelvic Injuries
 - SPINO-PELVIC INSTABILITY
 - +/- posterior pelvic instability
 - L5-S1 facet involvement, Sacral U variants, bilat longitudinal injuries
 - Subtype severity based on instability & likelihood of neuro injury

Type A–Sacrococcygeal Injuries

■ Definition:

- Injuries below the S-I joint (usually S2)
- No impact on posterior pelvic or spino-pelvic instability
- *May* have impact on neurology

■ Type A1

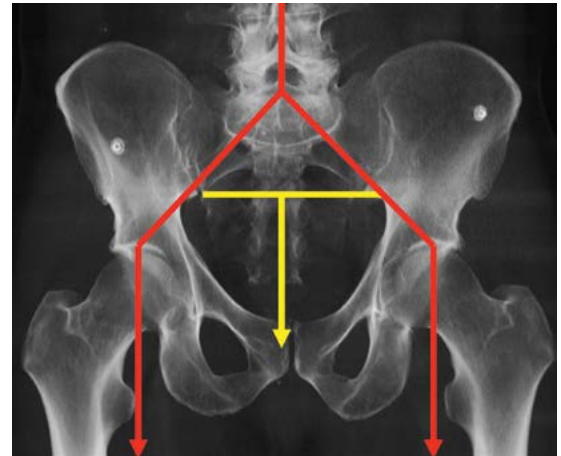
- Coccygeal or compression vs ligamentous avulsion fractures

■ Type A2

- Non-displaced transverse fractures below the S-I joint

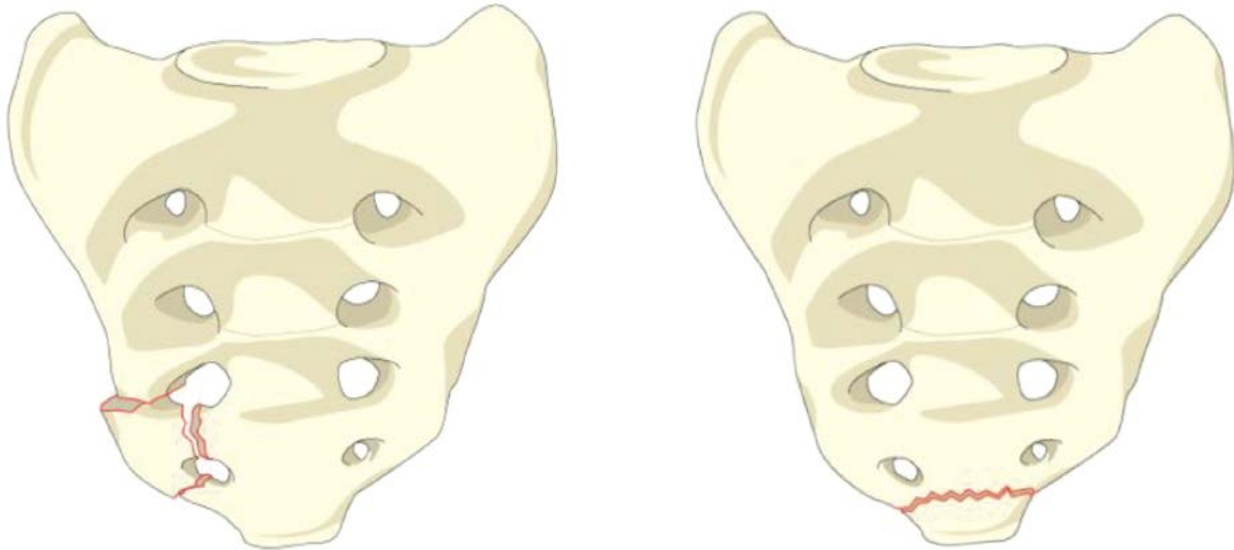
■ Type A3

- Displaced transverse fractures below the S-I joint



Type A

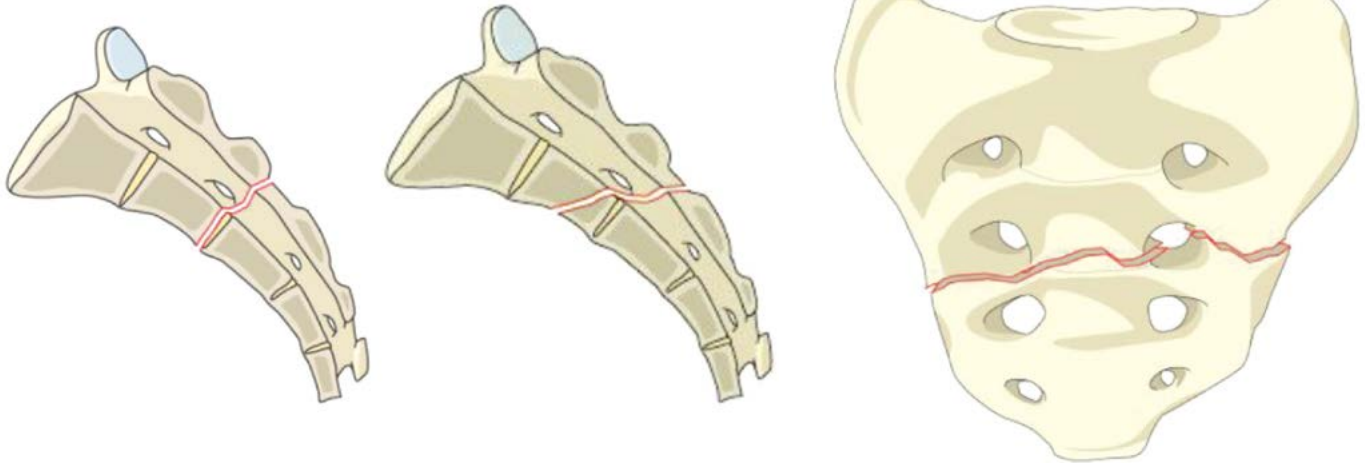
A1. Coccygeal or compression vs ligamentous avulsion fractures



Type A

A2. Non-displaced transverse fractures below the S-I joint

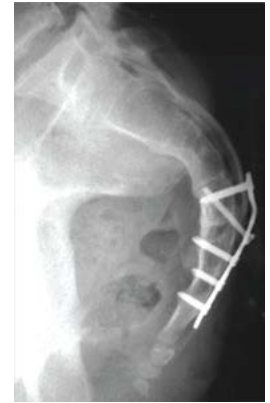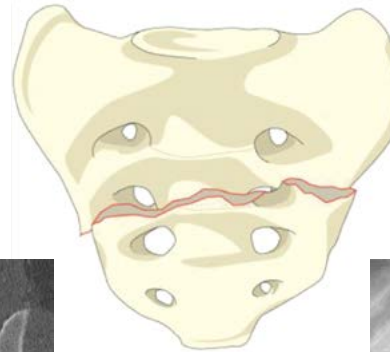
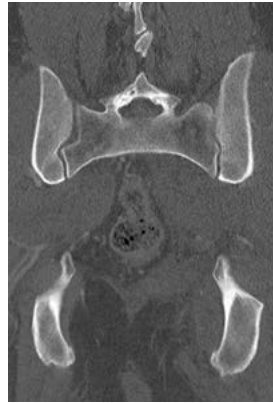
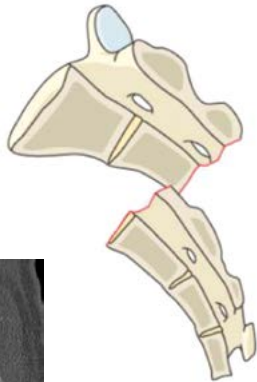
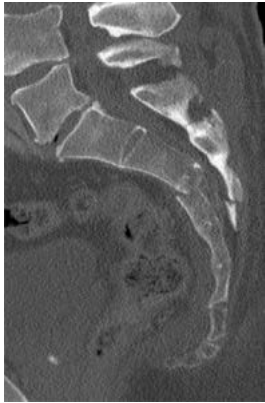
- No implications on stability
- Low likelihood of cauda equina injury



Type A

A3. Displaced transverse fractures below the S-I joint

- Higher likelihood of neuro injury than A1 or A2 (displacement)
- May possibly benefit from reduction & stabilization



Type B—Posterior Pelvic Injuries

■ Definition:

- Unilateral longitudinal sacral fractures
- Primary impact is on posterior pelvic stability
- Minimal to no impact on spino-pelvic stability
- Framework is variation of Denis Zones I through III injuries
- Usually treated with sacroiliac screw fixation

■ Type B1

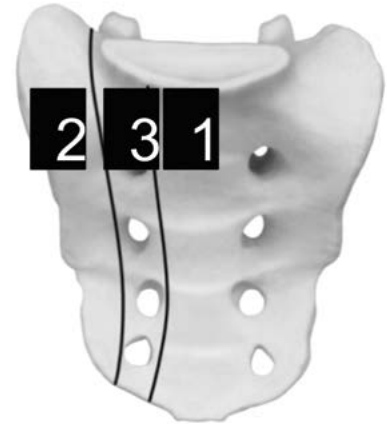- **Central fracture:** Involves spinal canal, but with primarily longitudinal fracture pattern

■ Type B2

- **Transalar fracture:** Does not involve foramina or spinal canal

■ Type B3

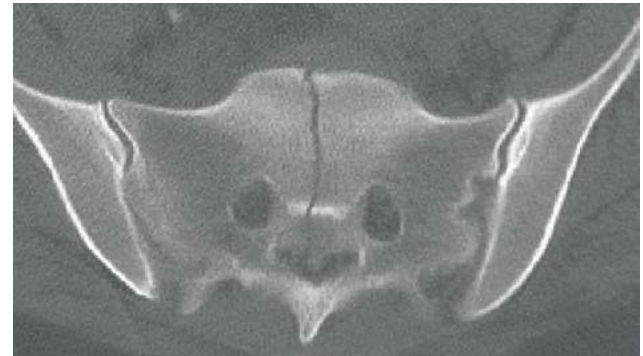
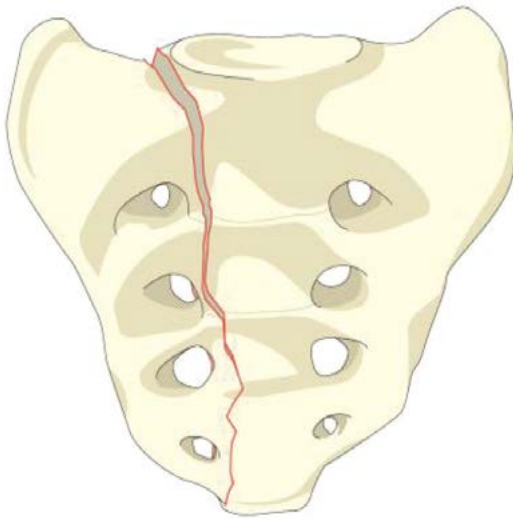
- **Transforaminal fracture:** Involves foramina but not spinal canal



Type B

B1. Central fracture

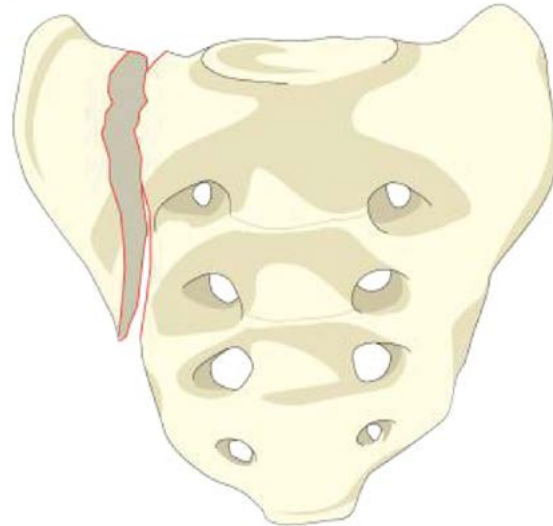
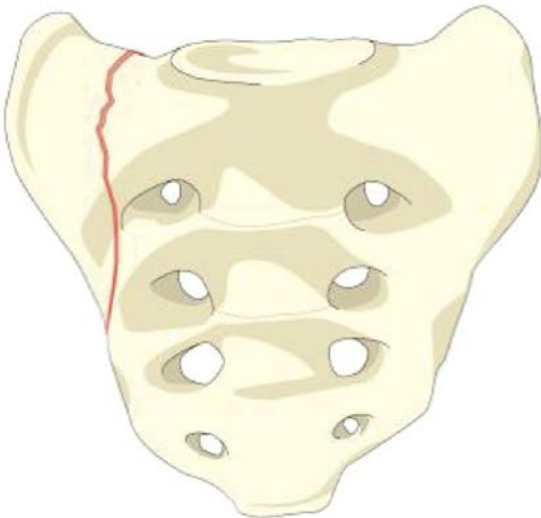
- **Longitudinal** injuries only—rare type of Denis Zone III injuries
- Low likelihood of neurological injury



Type B

B2. Transalar fracture (may extend into the SI joint)

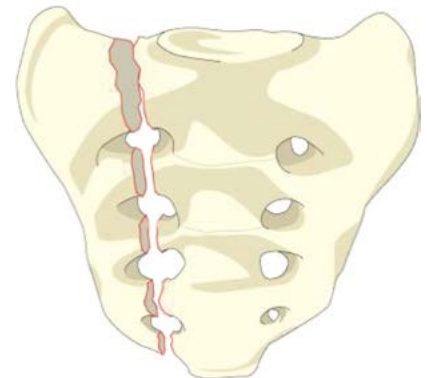
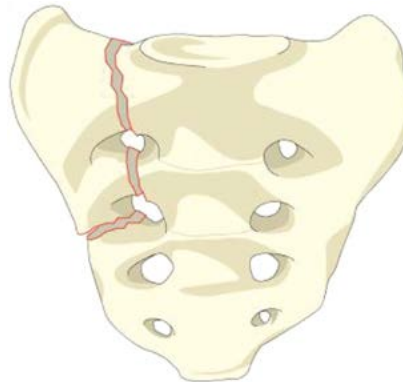
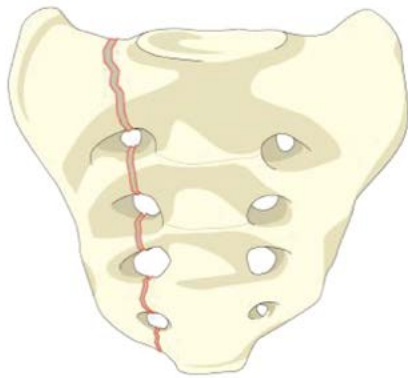
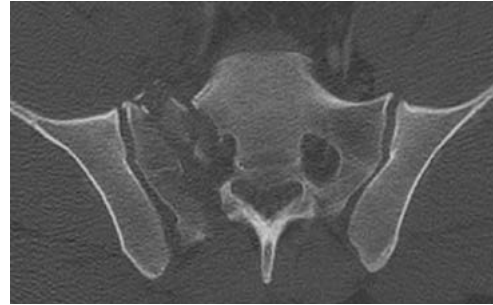- Unilateral Denis Zone I injury



Type B

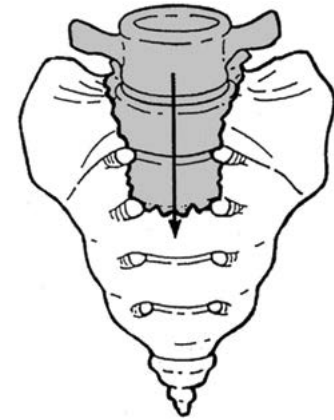
B3. Transforaminal fracture

- Denis Zone II injury



Type C–Spino-Pelvic Injuries

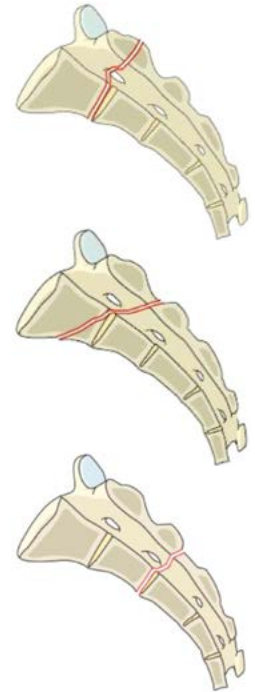
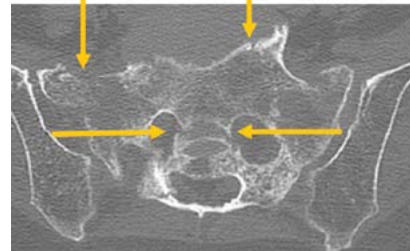
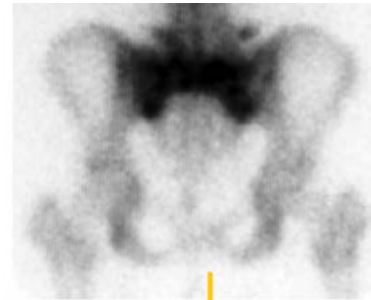
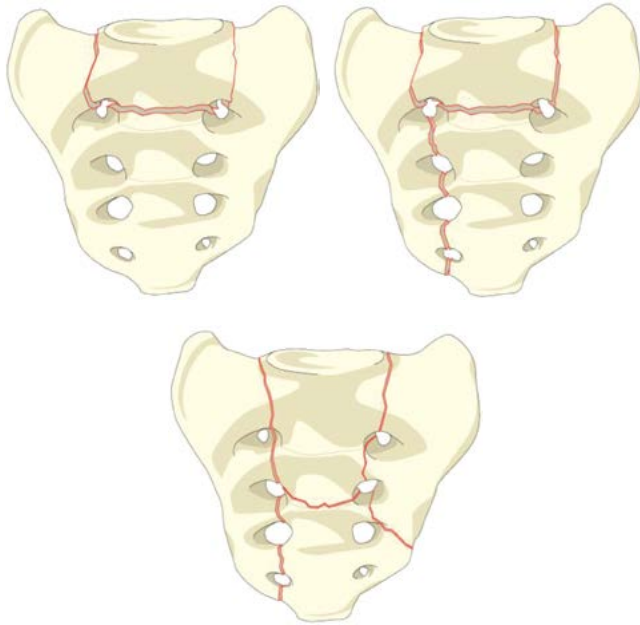
- Definition:
 - Injuries resulting in spino-pelvic instability
- Type C0
 - Nondisplaced sacral U-type variant
- Type C1
 - Alternative–Sacral U-type variant without posterior pelvic instability
- Type C2
 - Bilateral complete Type B injuries without transverse fracture
- Type C3
 - Displaced U-type sacral fracture



Type C

C0. Nondisplaced sacral U-type variant

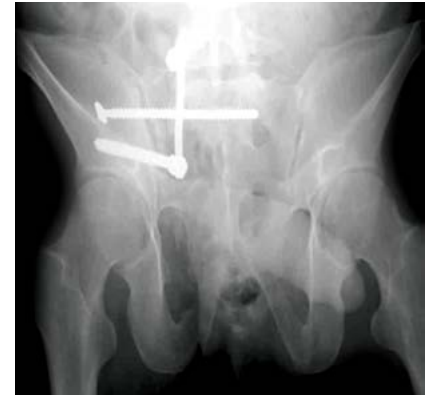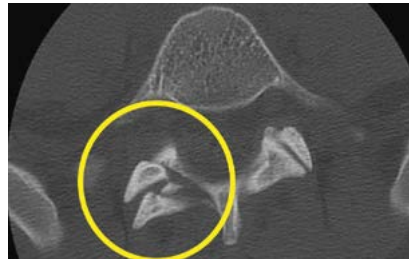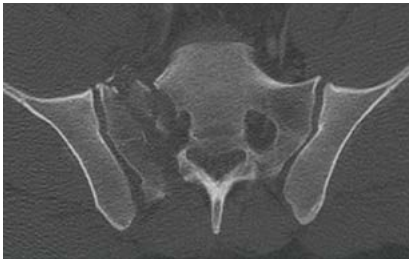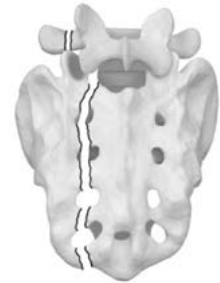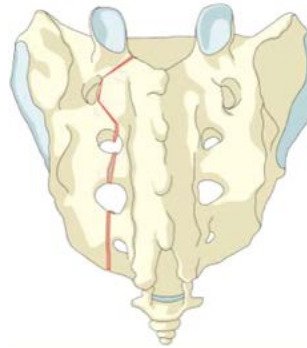
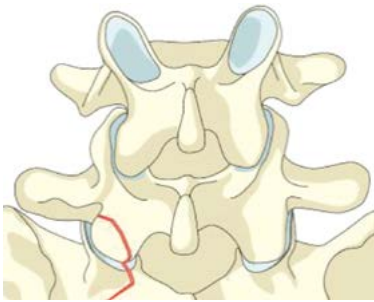
- Commonly seen low-energy insufficiency fracture



Type C

C1. Alternative–Sacral U-type variant without posterior pelvic instability

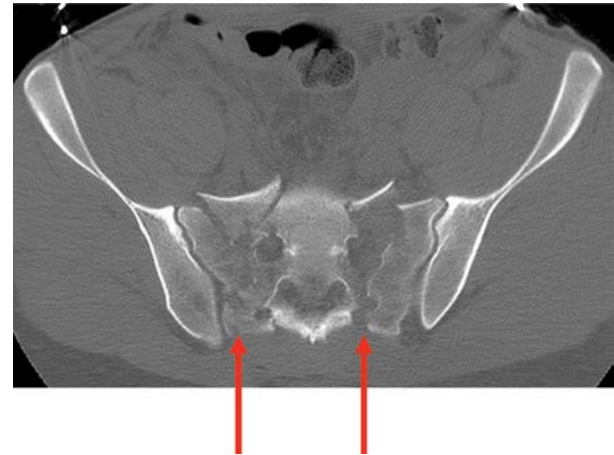
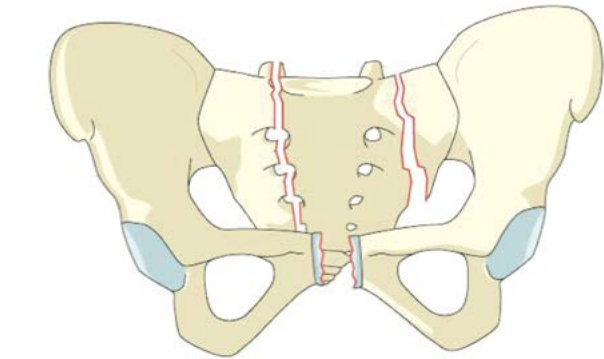
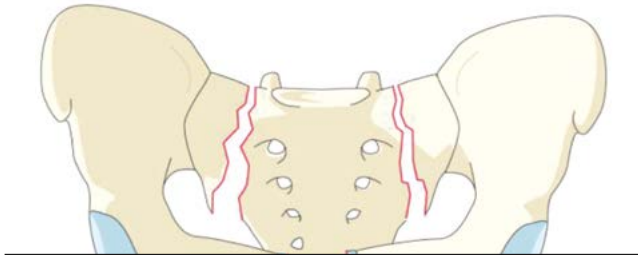
- Any unilateral B-subtype where ipsilateral superior S1 facet is discontinuous with medial part of sacrum
- May impact spino-pelvic stability (Isler)



Type C

C2. Bilateral complete Type B injuries without transverse fracture

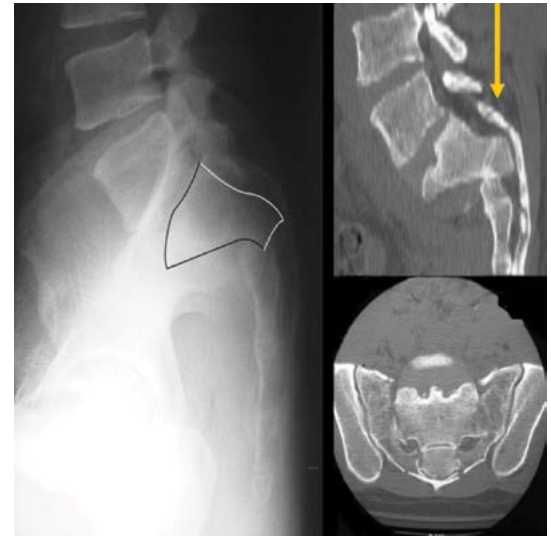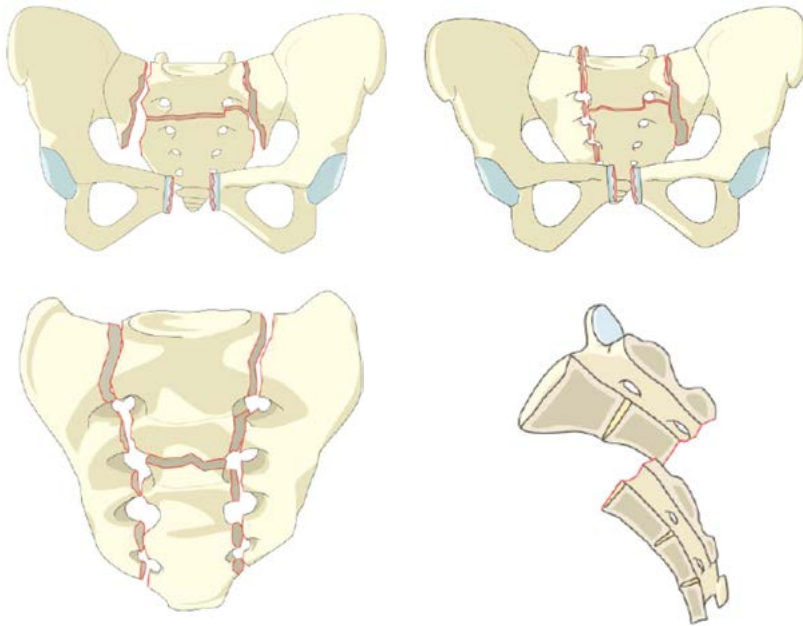
- More unstable and higher likelihood of neuro injury than C1



Type C

C3. Displaced U-type sacral fracture

- Worst combination of instability and likelihood of neuro injury
- Displaced transverse sacral fracture = canal compromise



Neurology

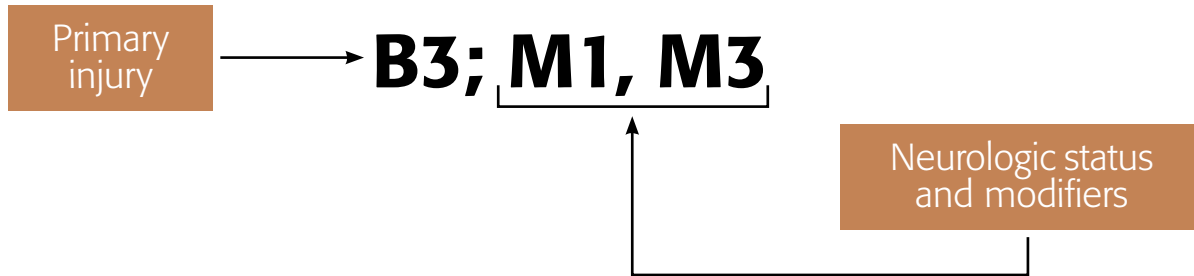
Type	Neurological
Nx	Cannot be examined
NO	No neurological deficits
N1	Transient neurological injury
N2	Nerve root injury
N3	Cauda Equina Syndrome/Incomplete SCI
N4	Complete SCI

Modifiers

Type	Description
M1	Soft tissue injury
M2	Metabolic bone disease
M3	Anterior pelvic ring injury
M4	Sacroiliac joint injury

Classification nomenclature

Transforaminal fracture (B3) high energy injury associated with anterior pelvic ring (M1) and soft tissue injury (M3)



Summary

- Morphological basis for new AOSpine sacral fracture classification
- Neurological Exam
- Modifiers for situations that impact treatment or prognosis



Further information: www.aospine.org/classification



Advancing
spine care
worldwide

AOSpine Latin America
Avenida Silva Jardim, 2042
Cj 1505
80250-200
Curitiba, Brasil

T +55 (41) 3016 4491
F +55 (41) 3016 4491
aosla@aospine.org
www.aospine.org

 AOSpine Latin America
 @AOSpine_Latam