

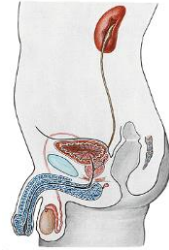## Male genital system

MUDr. Marek Joukal, Ph.D.

Department of Anatomy

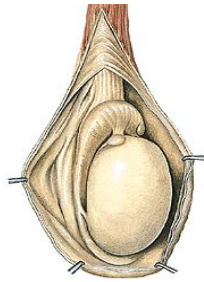
### ORGANA GENITALIA MASCULINA INTERNA

TESTIS  
 EPIDIDYMIS  
 DUCTUS DEFERENS  
 SPERMATIC CORD (FUNICULUS SPERMATICUS)  
 SEMINAL VESICLES (VESICULAE SEMINALES)  
 PROSTATE  
 MALE URETHRA (URETHRA MASCULINA)  
 ORGANA GENITALIA MASCULINA EXTERNA  
 PENIS  
 SCROTUM



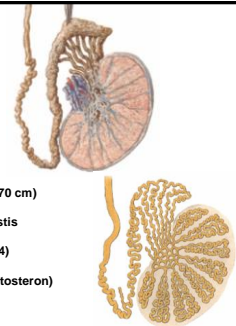
### TESTIS

4-4,5 cm 20-30 g  
 Extremitas superior  
 Extremitas inferior  
 Facies medialis  
 Facies lateralis  
 Margo anterior  
 Margo posterior



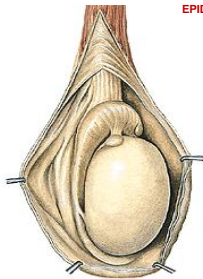
### MORPHOLOGY OF TESTIS

tunica albuginea  
 hilum testis  
 mediastinum testis  
 septula testis  
 lobuli testis (200-300)  
 tubuli seminiferi contorti (50-70 cm)  
 tubuli seminiferi recti, rete testis  
 ductuli efferentes testis (10-14)  
 interstitial Leydig's cells (testosteron)



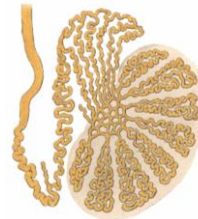
### EPIDIDYMIS

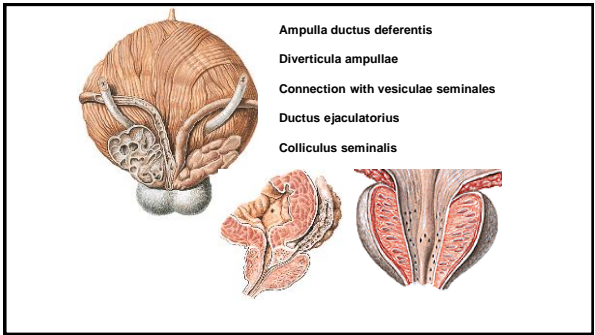
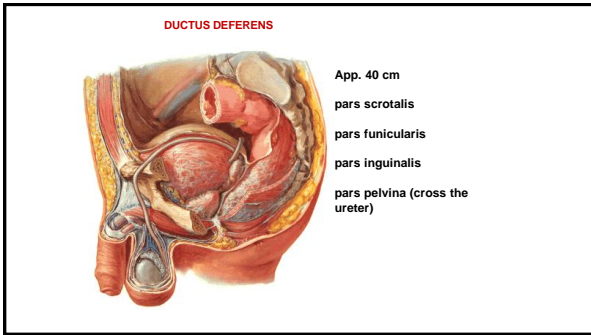
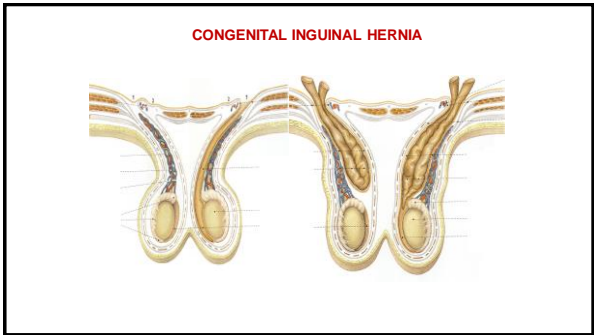
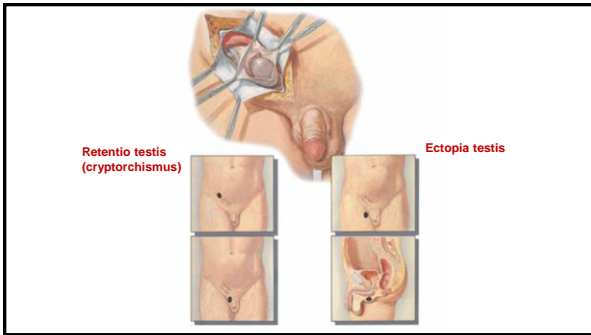
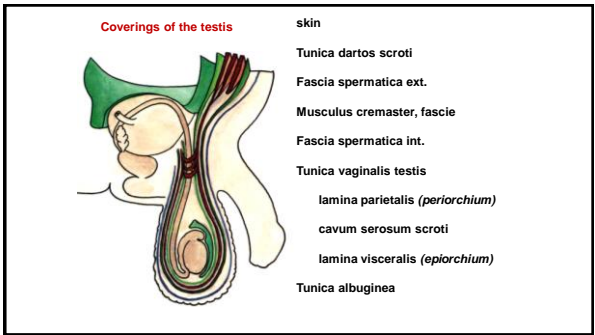
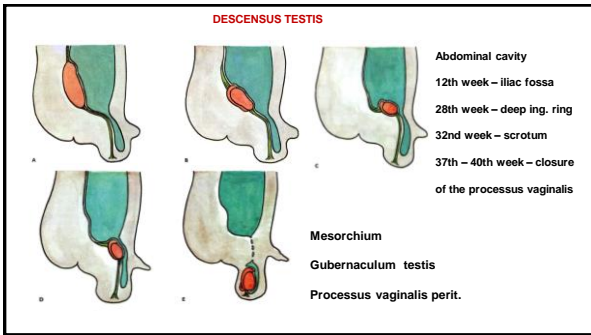
Caput epididymidis  
 Corpus epididymidis  
 Cauda epididymidis  
 Lig. epididymidis sup. et inf.  
 Sinus epididymidis  
 Lig. scrotale (gubernaculum testis)



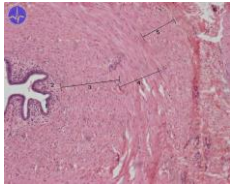
### MORPHOLOGY OF EPIDIDYMIS

Ductuli efferentes testis (12-15)  
 Lobuli epididymidis  
 Ductus epididymidis  
 Ductus deferens



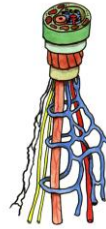


**ULTRASTRUCTURE OF DUCTUS DEFERENS**



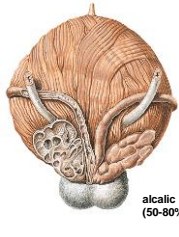
- Mucosa**  
 Columnar epithelium (stereocilia)  
**Muscular layer**  
 longitudinal,  
 circular,  
 longitudinal  
**Adventicia**

**SPERMATIC CORD**

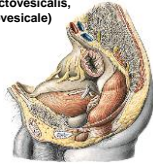

- Ductus deferens  
 Arteria ductus deferentis  
 Plexus deferentialis  
 Arteria testicularis  
 Plexus testicularis  
 Plexus pampiniformis  
 Lymphatic vessels

**SEMINAL VESICLES**



- App. 4-5 cm  
 Laterally from ampulla ductus deferentis  
 subperitoneal  
 (excavatio rectovesicalis, septum rectovesicale)

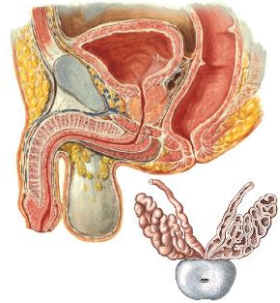


alkalic secret (50-80% ejaculate)

ductus excretorius + ductus deferens = ductus ejaculatorius

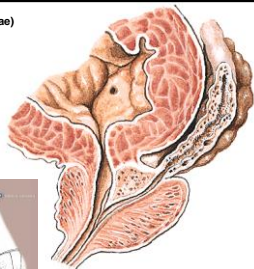
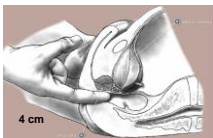
**PROSTATE**

- Basis prostatae (facies vesicalis)  
 Apex prostatae  
 Facies anterior (ligg. puboprostatica)  
 Facies posterior  
 Facies laterales (inferolaterales)

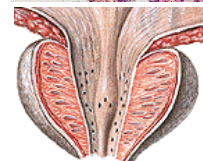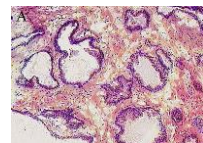


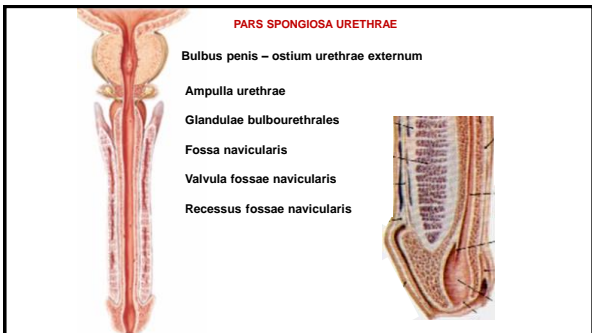
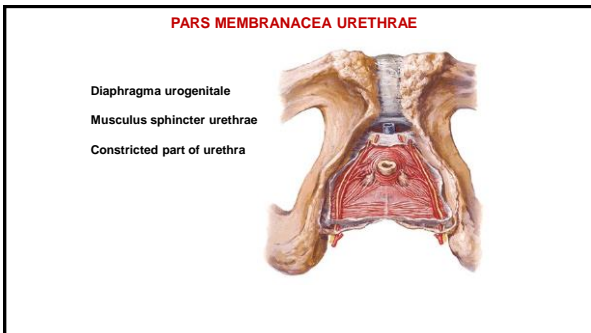
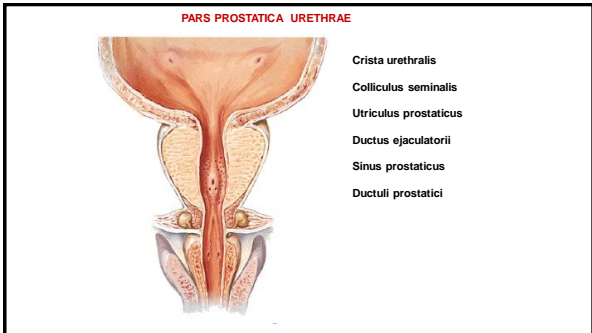
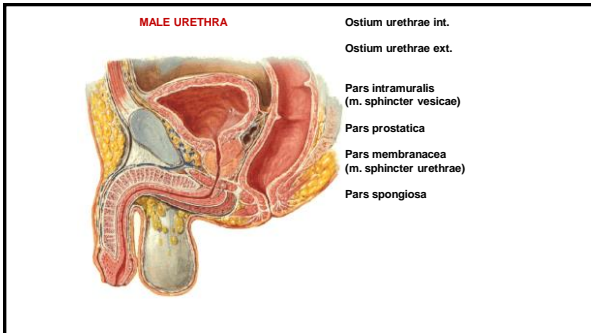
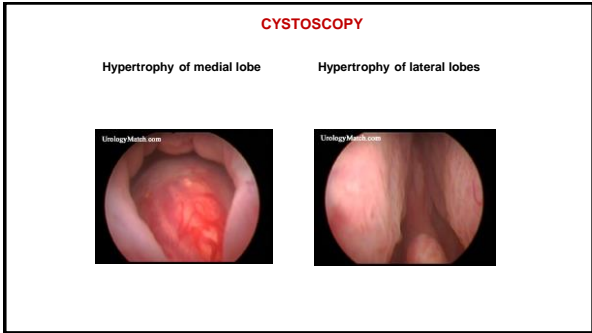
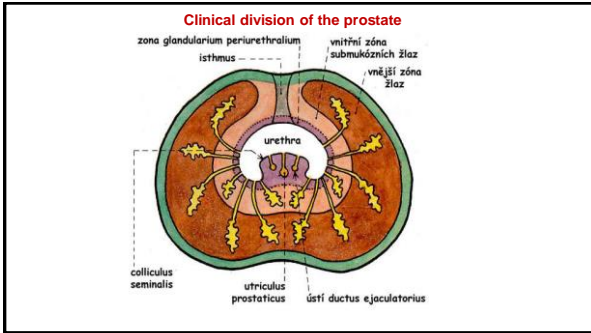
30 - 50 tuboalveolar glands  
 15-30% of ejaculate

- Lobus anterior (isthmus prostatae)  
 Lobus medius  
 Lobus posterior  
 Lobus dexter  
 Lobus sinister



- Capsula periprostatica (visc. sheath of fascia pelvis)  
 Plexus venosus prostaticus  
 Capsula propria  
 Fibromuscular stroma  
 30 - 50 tuboalveolar glands  
 15-30% ejaculate  
 Ductuli prostatici (pars prostatica urethrae)



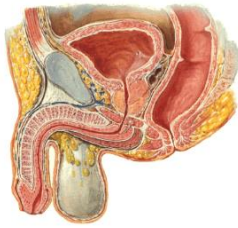


**CURVATURES OF URETHRA:**

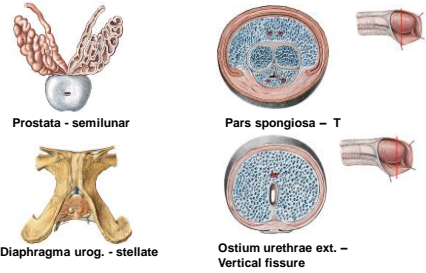
- Curvatura subpubica
- Curvatura praepubica

**CONSTRICTED PARTS OF URETHRA:**

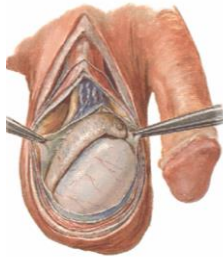
- Ostium urethrae externum
- Between fossa navicularis and ampulla urethrae
- Pars membranacea
- Pars intramuralis



**URETHRA MASCULINA - LUMEN**

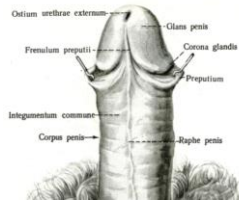


**PENIS**

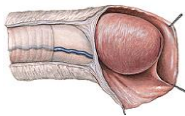


- Radix penis
- Corpus penis
- Glans penis
- Corona glandis
- Collum glandis
- Dorsum penis
- Facies urethralis

**Facies urethralis**

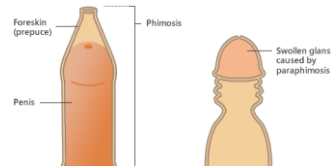


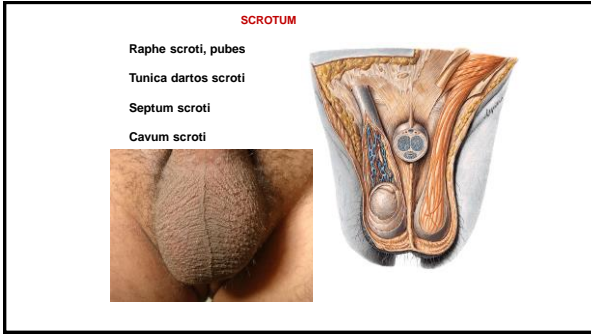
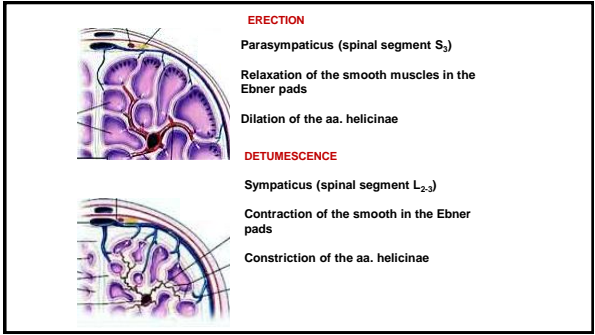
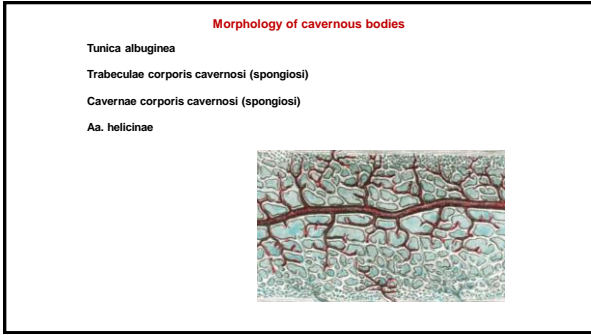
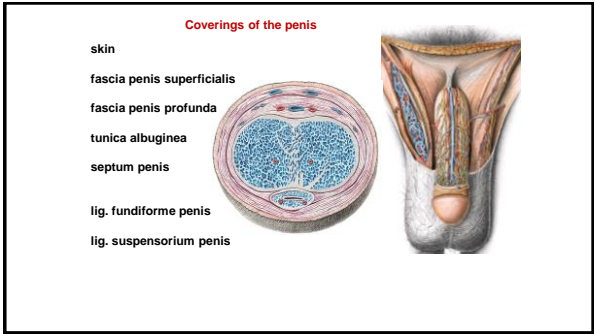
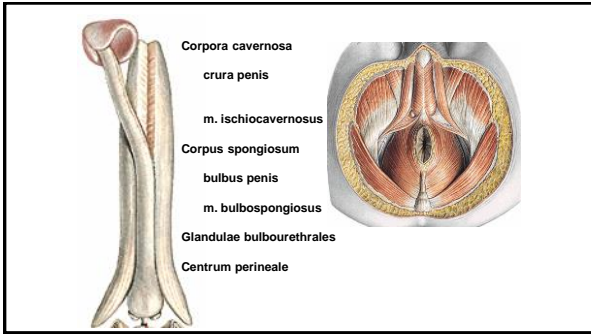
**PRAEPUTIUM**



- Frenulum praeputii
- Ostium (orificium) praeputii
- Glandulae praeputiales
- Smegma praeputii

**Phimosis**





**References:**

Putz, R. (2008):  
 Atlas of Human Anatomy Sobotta. Elsevier Books.

Keith L. Moore, Arthur F. Dalley (2005):  
 Clinically Oriented Anatomy. Williams and Wilkins.

Platzer, W., Kahle, W., Leonhardt H. (1992):  
 Locomotor system. Georg Thieme Verlag, Stuttgart, New York, 4th edition.

Čihák, R. (1987):  
 Anatomie 1. Avicenum, Zdravotnické nakladatelství.

Netter, F. H. (1997):  
 Interactive Atlas of Clinical Anatomy. Novartis, USA.