

REGIONAL ANATOMY OF THE PELVIS

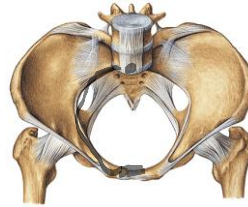
MUDr. Marek Joukal, Ph.D.

Department of Anatomy



Pelvis – inner border

Border between pelvis major et minor = aditus pelvis



Superior:

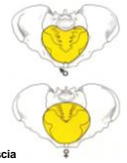promontorium
linea terminalis
superior margine of symphysis

Lateral:

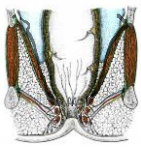
pelvic wall
(m. obturatorius int. + fascia m. piriformis)

Inferior:

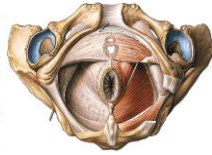
diaphragma pelvis
diaphragma urogenitale



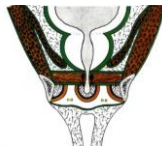Diaphragma pelvis et diaphragma urogenitale



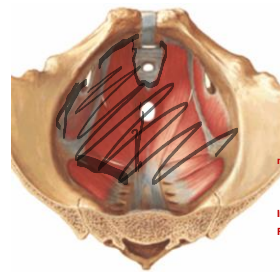
Diaphragma pelvis:
funnel shape
wider around pelvis
narrow around anus
ventral opening – hiatus urogenitalis



Diaphragma urogenitale:
triangular (symphysis, tubera ischiadica)
encloses hiatus urogenitalis (superiorly)



Diaphragma pelvis



musculus levator ani

musculus pubococcygeus (m. levator prostatae)

origo: os pubis near symphysis
encircle hiatus urogenitalis

musculus iliococcygeus

origo: arcus tendineus m. levatoris ani
(fascia obturatoria)

insertio: anus

lig. anococcygeum
os coccygis
os sacrum

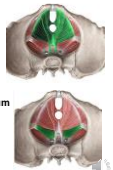
musculus coccygeus (lig. sacrospinale)

origo: spina ischiadica

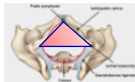
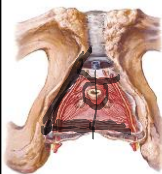insertio: os coccygis, os sacrum

Innervation: plexus sacralis

Fascia diaphragmatis pelvis sup. et inf.



Diaphragma urogenitale



Morphology:

lig. transversum perinei

m. transversus perinei profundus

m. transversus perinei superficialis

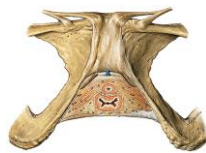m. sphincter urethrae

centrum perineale

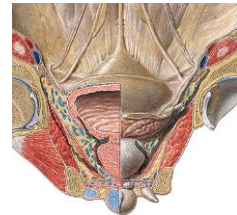
(male: urethra – rectum; female: vagina – rectum)

innervation and blood supply: n. pudendus a vasa pudenda interna

fascia diaphragmatis urogenitalis sup. et inf.



Fascia pelvis



Fascia pelvis parietale

covers the pelvic cavity

its part - fascia diaphragmatis pelvis et urogenitalis sup.

Fascia pelvis visceralis

goes to pelvic organs

Arcus tendineus fasciae pelvis

transition of parietal and visceral fascia

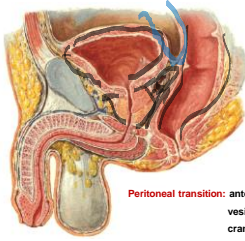
Peritoneum

cavum pelvis **peritoneale**

cavum pelvis **subperitoneale**



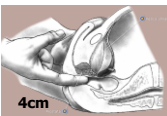

Male pelvis



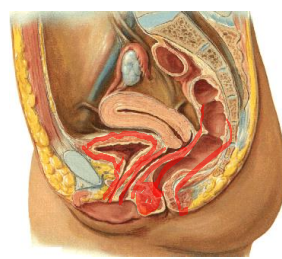
- symphysis + spatium retropubicum
- lig. pubovesicalia
- lig. puboprostatica
- paracystium (fascia vesicoumbilicalis)
- vesica urinaria, vesiculae seminales, ductus deferens,
- prostata
- septum rectovesicale
- rectum

Peritoneal transition: anterior abdominal wall
vesica urinaria
cranial part of vesiculae seminales
rectum (Kohlrusch's fold)

Excavatio rectovesicalis !!!

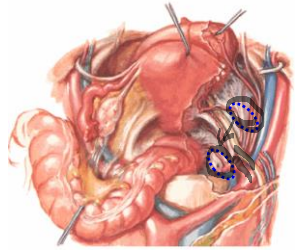
Female pelvis




- symphysis + spatium retropubicum
- lig. pubovesicalia
- paracystium (fascia vesicoumbilicalis)
- vesica urinaria, urethra feminina
- septum urethrovaginale
- vagina
- septum rectovaginale
- centrum perineale
- perineal body
- rectum

Female pelvis – ovary

- Nullipara**
fossa ovarica
(in front of a. iliaca int. and ureter)
- Multipara**
Claudius fossa
(behind a. iliaca int. and ureter)

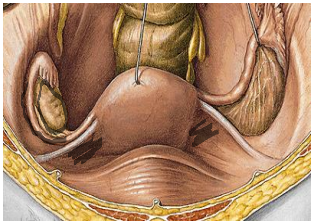


Female pelvis – perimetrium (visceral peritoneum)



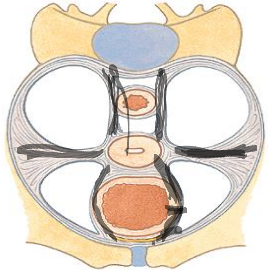
- Round ligament
- Uterine tube
- Mesosalpinx
- Lig. latum uteri
- Uterus
- Ovarian ligament
- Mesovarium
- Ovary

Peritoneal fold:
lig. latum uteri
mesosalpinx
mesovarium



Female pelvis – parametrium

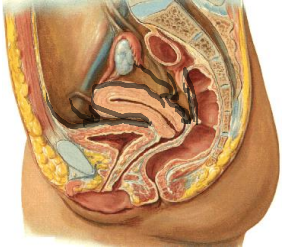
- Lig. pubouterinum**
lig. pubovesicale
lig. vesicouterinum
- Lig. cardinale uteri**
- Lig. sacrouterinum**
plicia sacrouterina
m. rectouterinus
- Lig. teres uteri**

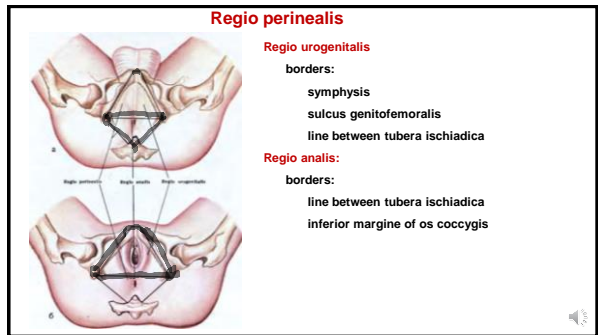
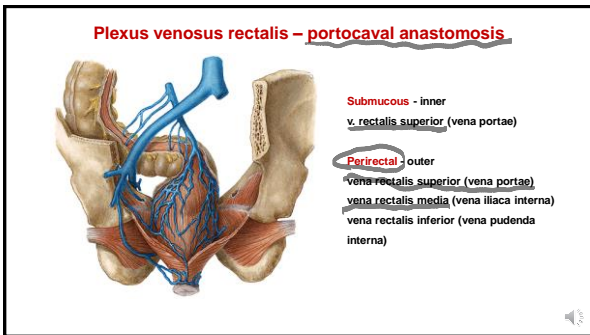
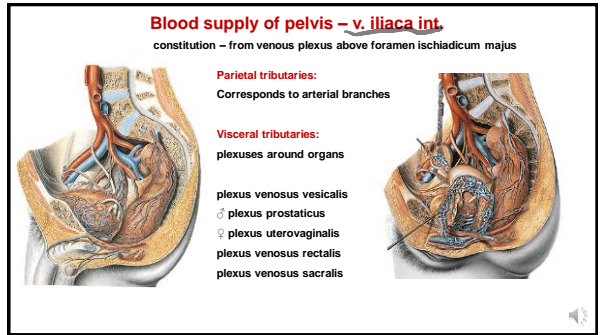
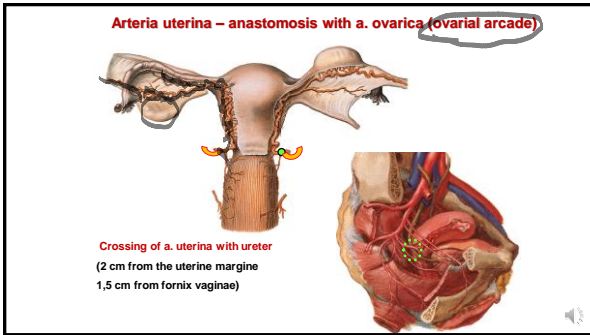
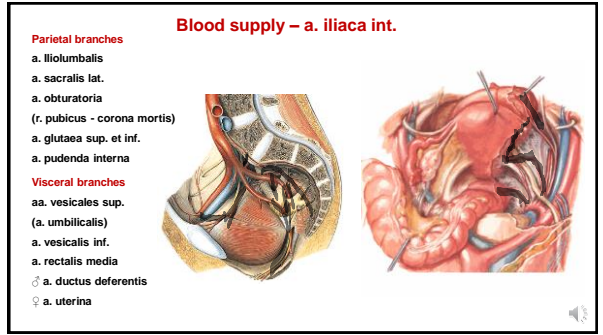
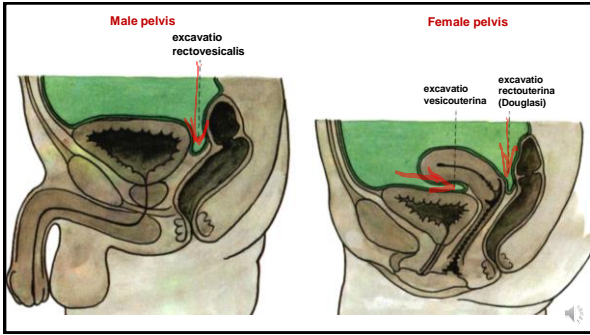


Female pelvis

Transition of peritoneum:
anterior abdominal wall
vesica urinaria
uterus
fornix vaginae post.
rectum (Kohlrusch's fold)

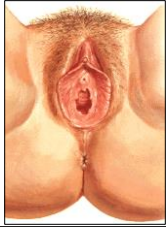
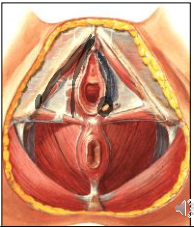
Excavatio vesicouterina
Excavatio rectouterina (cavum Douglasi!!!)





Regio urogenitalis feminina

Content: external genital organs
 spatium perinei spf. (between fascia diaphragmatis urogenitalis inf. + fascia perinei superficialis)
 spatium perinei prof. (between fascia diaphragmatis urogenitalis sup. + inf.)

Spatium perinei spf.
 m. ischiocavernosus
 crura clitoridis
 m. bulbospongiosus
 bulbi vestibuli
 gll. vestibulares majores

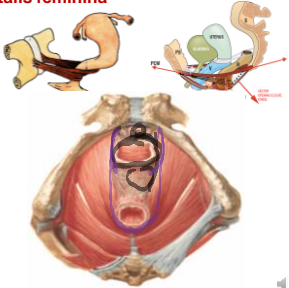
Regio urogenitalis feminina

Spatium perinei prof.
 urethra feminina
 vagina

centrum perineale (between vagina and anus)
 septum rectovaginale
 perineal body

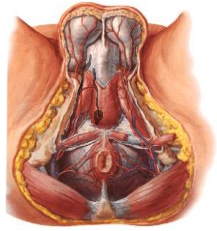
m. sphincter urethrovaginalis
 (from centrum perineale encircles urethra and vagina)

m. compressor vaginae (m. pubovaginalis)
m. compressor urethrae (m. pubourethralis)
 m. puborectalis



Regio urogenitalis masculina

Content: external genital organs
 spatium perinei spf. (between fascia diaphragmatis urogenitalis inf. + fascia perinei superficialis)
 spatium perinei prof. (between fascia diaphragmatis urogenitalis sup. + inf.)



Spatium perinei spf.
 m. ischiocavernosus
 crura penis
 m. bulbospongiosus
 bulbus penis
 gll. bulbourethrales

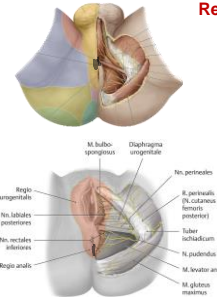
Spatium perinei prof.
 urethra masculina
 m. puboprostaticus

Regio analis

skin:
 anus
 plicae circumanales
 raphe perinei

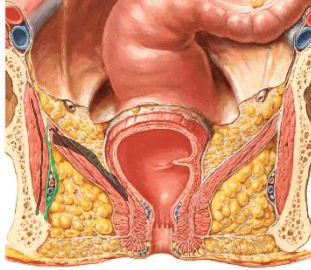
subcutaneous tissue:
 glandulae circumanales
 fatty tissue continues to fossa ischiorectalis

m. sphincter ani externus
centrum tendineum perinei – ventrally from anus
lig. anococcygeum



Fossa ischiorectalis

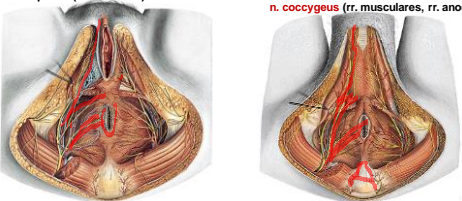
Borders:
mediocranial:
 diaphragma pelvis
lateral:
 m. obturatorius int.
 fascia obturatoria
 canalis pudendalis (n. pudendus, vasa pudenda int.)
ventral:
 recessus pubicus (above diaphragma urogenitale)
dorsal:
 m. gluteus maximus
 lig. sacrotuberale



Regio perinealis – blood supply and innervation

a. + v. pudenda int.
a. + v. rectalis inf.
a. + v. perinealis – rr. scrotales post. (rr. labiales post.)
a. + v. penis (a. clitoridis)

n. pudendus
n. rectalis inf.
n. perinealis – nn. scrotales post. (nn. labiales post.)
n. dorsalis penis (a. clitoridis)
n. coccygeus (rr. musculares, rr. anococcygei)



References:

- Putz, R. et al.: Atlas of Human Anatomy Sobotta. Elsevier Books, (2008).
- Netter, F. H.: Interactive Atlas of Human Anatomy. Windows Version 2.0. (1999).
- Čihák R.: Anatomie 2 (Splanchnologia). Avicenum, zdravotnické nakladatelství, Praha, (1988).
- Čihák, R.: Anatomie 3. Praha, Grada, (2004).
- Platzer, W. et al.: Atlas topografické anatomie. Grada Publishing, (1996).
- Grim, M. a kol.: Základy anatomie. 5. Anatomie krajín těla. Galén, (2002).
- Moore, K. L.: Clinical oriented anatomy. Third edition. Williams & Wilkins, A Waverly Company, (1992).
- Gilroy, A. M. et al.: Atlas of Anatomy. Thieme New York, Stuttgart. (2009).
- Sobotta, J.: Atlas of Human Anatomy Vol 1–2 Munich, Urban und Schwarzenberg, (1993)-
- Willams, P. & Warwick, R.: Gray's Anatomy, 37 ed, Churhill Livingstone, (1996).

