

PARANEOPLASTIC SKIN SYNDROMES

Juraj Hegyi

Paraneoplastic Syndromes (PNS)

- Paraneoplastic syndromes are a heterogeneous group of rare diseases, which are caused by a change in the response of the immune system to the present neoplasm
- Are defined as non-metastatic systemic manifestations, irregularly accompanying cancers
- They are conditioned by the presence of the tumor, but they manifest in the tissue in which the tumor is not present

Paraneoplastic Syndromes (PNS)

- Endocrinological, neurological, cutaneous, GI, hematological, non-specific
- First described PNS 1890 M.Auché
- Skin PNS Helene Ollendorf Curth



Pathophysiology

- Formation of antibodies directed against tumor cells, they cause a cross-reaction against healthy tissue
- Formation and release of physiologically active substances by the tumor itself (hormones, hormonal precursors, enzymes, cytokines)
- Production of embryonic proteins (CEA, AFP, CA19-9....)
- Idiopathic

Epidemiology

- Men 10-15%
- Women 2-20%
- Distribution the same in both sexes regardless of age
- PNS death statistics are not available

Paraneoplastic Syndromes (PNS)

- There is a time coincidence between the onset of the syndrome and cancer
 - At the same time
 - In progress
 - Precedes the manifestation
- There is a parallel relationship between the syndrome and the tumor (regression during successful therapy, flare-up on exacerbation)

Paraneoplastic skin syndromes

- **Obligatory**

- Acanthosis nigricans maligna
- Leser-Trélat sign
- Ichthyosis acquisita
- Hypertrichosis lanuginosa acquisita
- Acrokeratosis paraneoplastica Bazex
- Erythema necrolyticum migrans

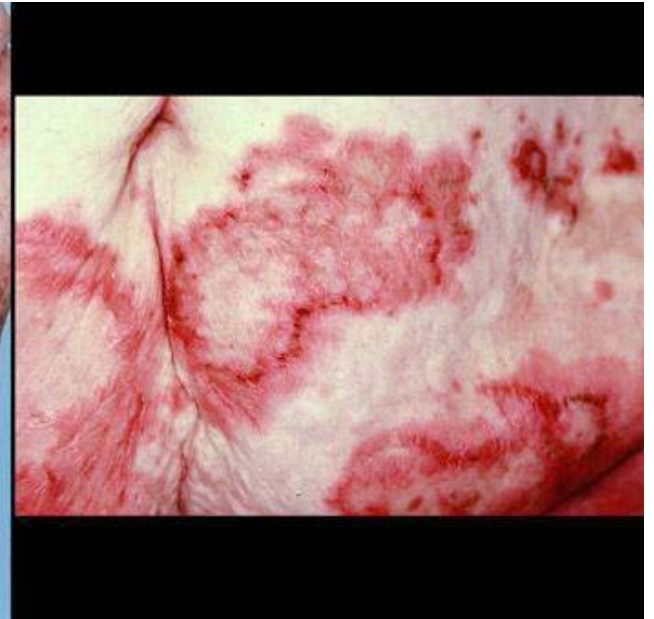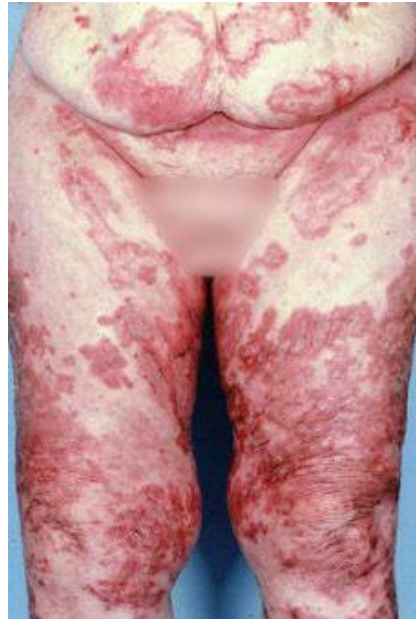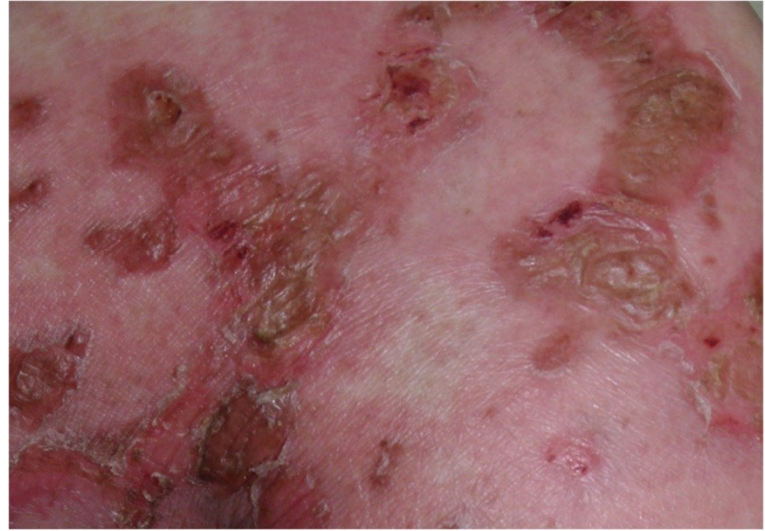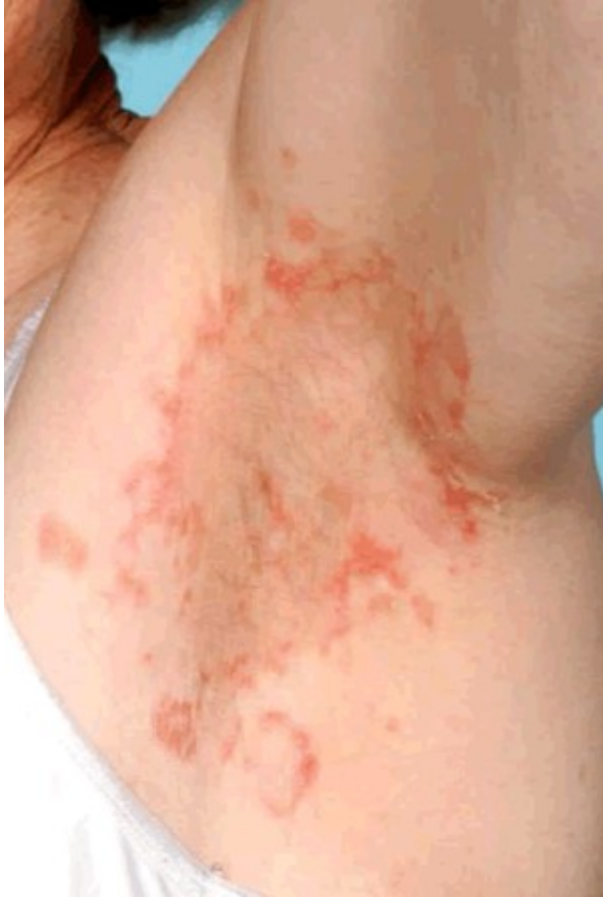- **Facultative**

- Dermatomyositis
- Pemphigus paraneoplasticus
- Sweet syndrom
- Scleromyxoedema
- Livedo reticularis
- Chronic urticaria
- Erythema anulare centrifugum

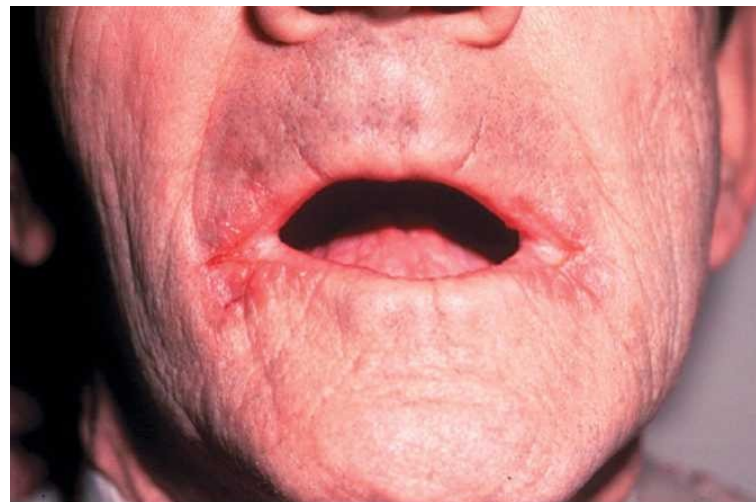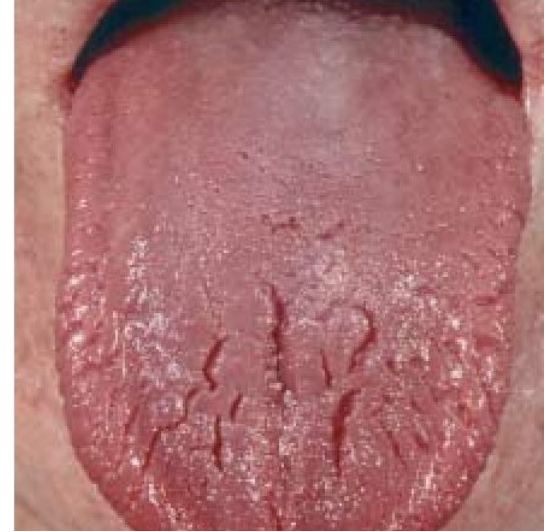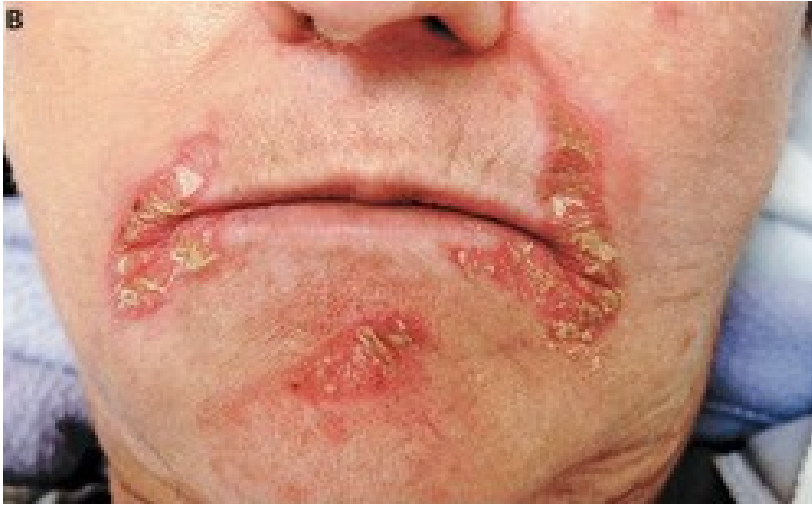Erythema necrolyticum migrans

- Glucagon secreting tumor of the pancreas
- Often preceded by the tumor
- Peripherally spreading erythema, maculopapules and blisters, painful eroded lesions
- Annular and circinary weeping lesions
- Glossitis, stomatitis, DM, anemia, weight loss
- intertriginous areas, face, torso and limbs

Erythema necrolyticum migrans



Erythema necrolyticum migrans



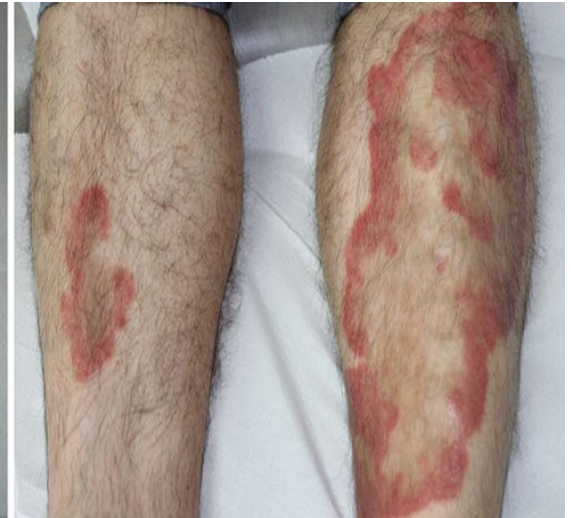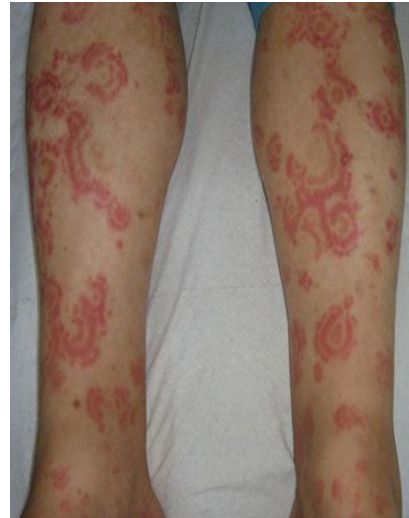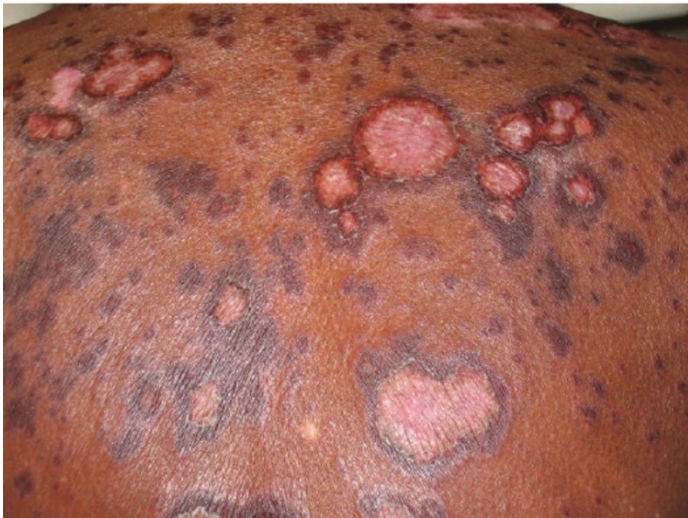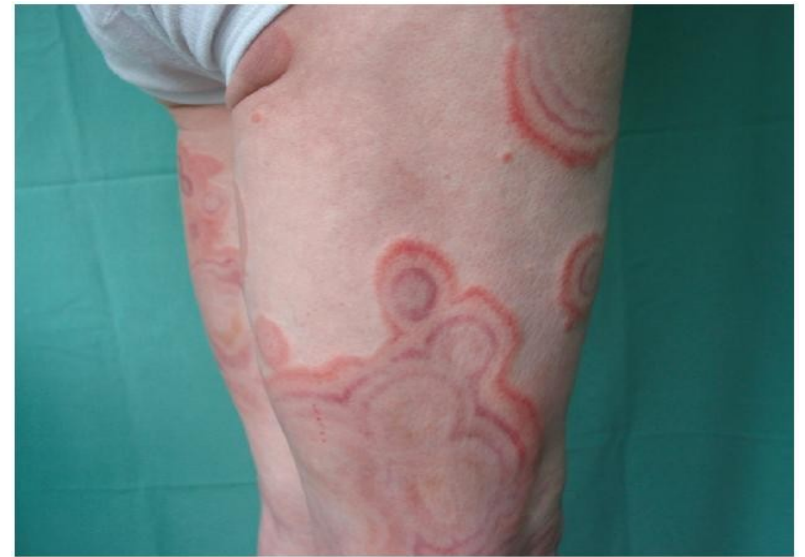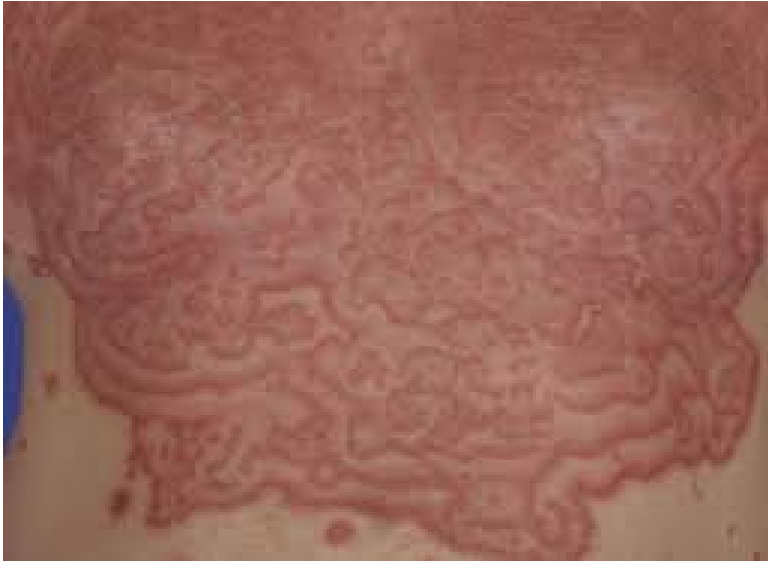Erythema necrolyticum migrans

- Frequent candida or bacterial superinfections
- Differentily sometimes mistaken for candidiasis or intertriginous dermatitis
- Therapy depends on the treatment of underlying disease, otherwise symptomatic

Erythema gyratum repens

- Rapidly spreading, migrating erythema
- Marked to almost debilitating pruritus
- Propagation centrifugally on upper torso and limbs
- Appears a few months before tumor
- Bizarre, tree-like shapes with “Wood graine”
- Tumors of the lung, esophagus, stomach, breast, uterus, prostate
- Disappears several weeks after tumor removal

Erythema gyratum repens



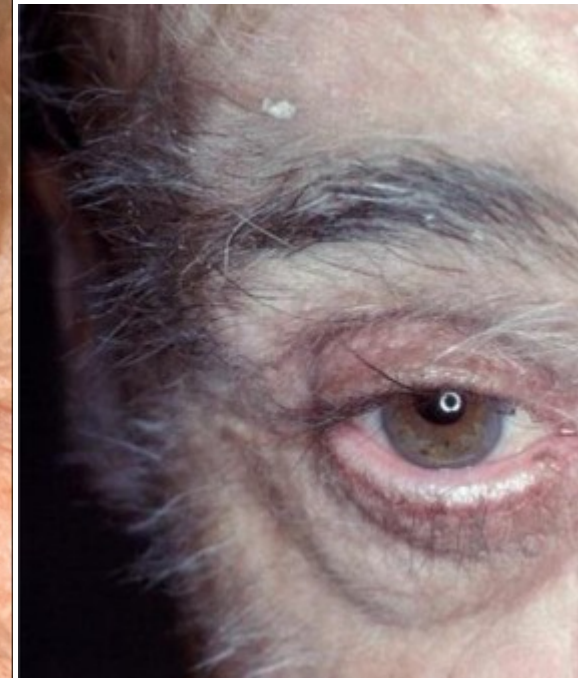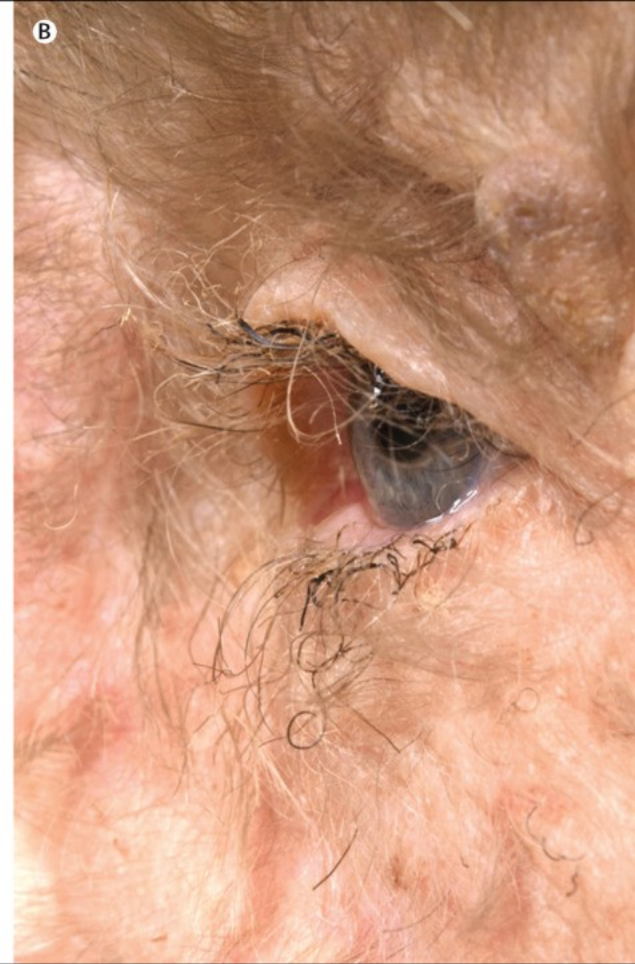
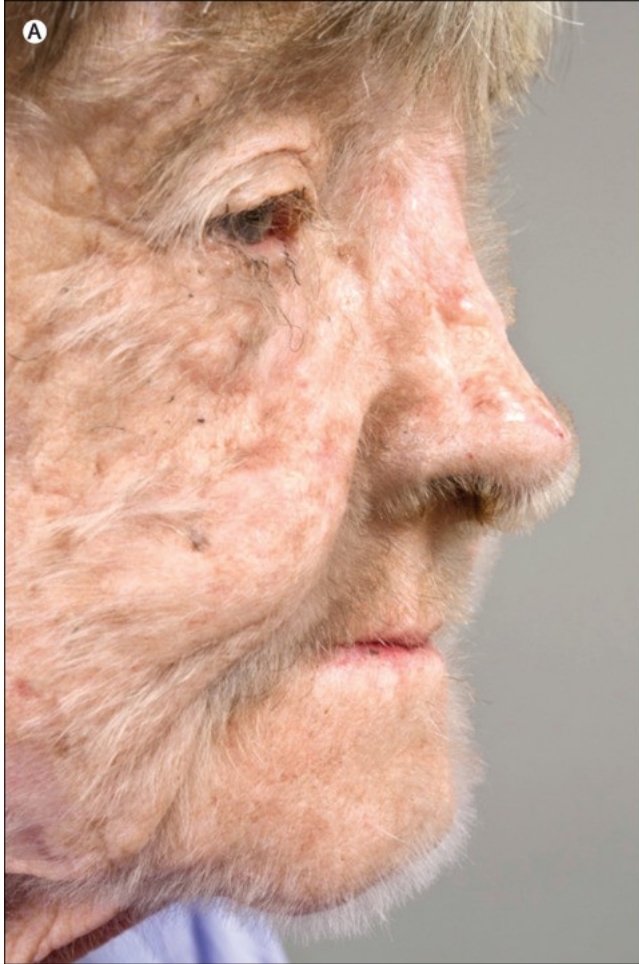Erythema gyratum repens

- Dg. made by clinical image
- non-specific histology, acanthosis, hyperkeratosis, focal parakeratosis, islet spongiosis, perivascular mixed round cell infiltrate
- Neither general nor topical CS have a major effect
- Retinoids also have no significant effect
- Symptomatic alleviation of pruritus, treatment of the underlying disease

Hypertrichosis lanuginosa acquisita

- Rapid formation of fine lanuginous, unpigmented hair
- Glossitis with red tongue
- Tumors of the colon and rectum, stomach, bladder, lungs and breast
- Noticeably more common in women
- diff. other causes of acquired hypertrichosis should be ruled out (porphyria, AIDS)

Hypertrichosis lanuginosa acquisita

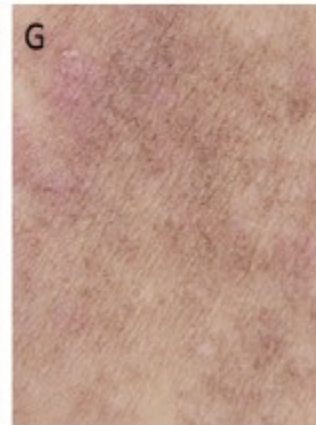
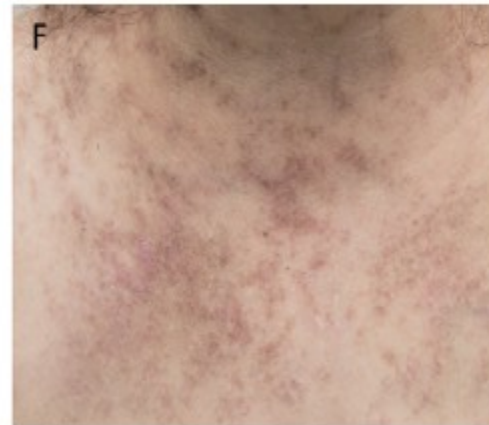
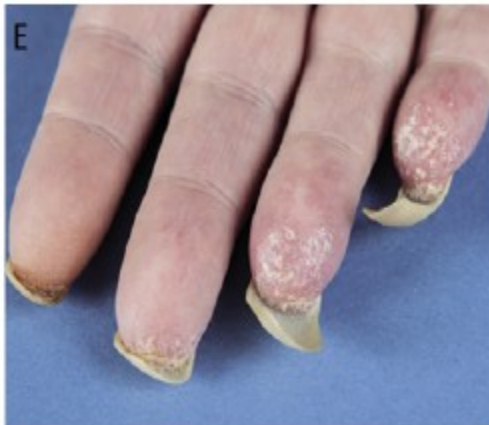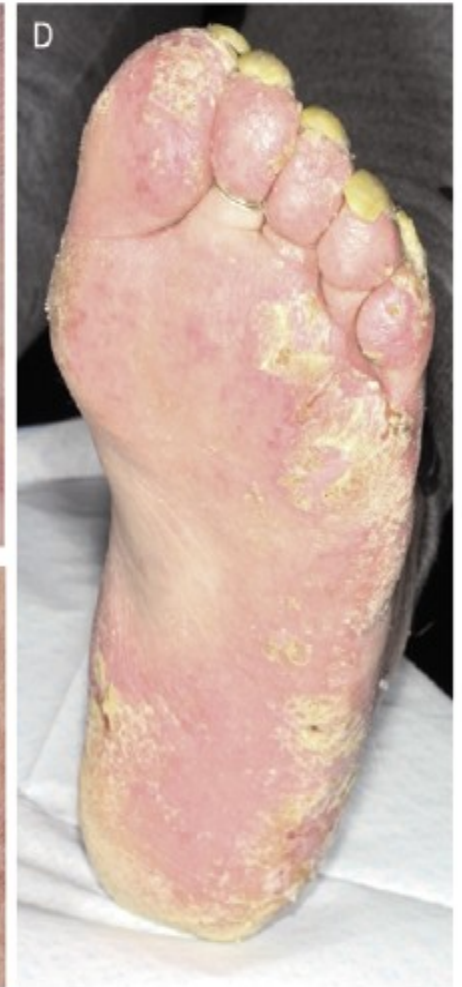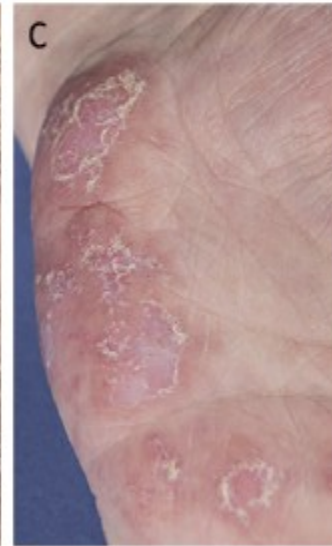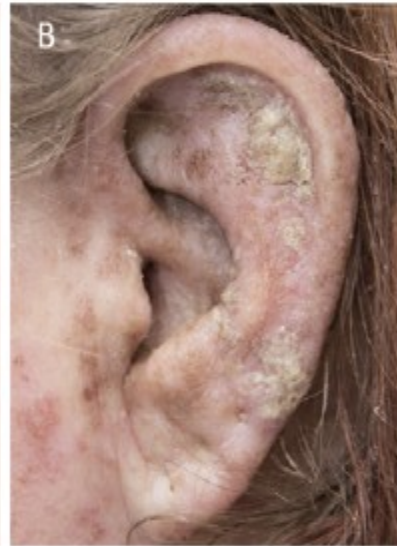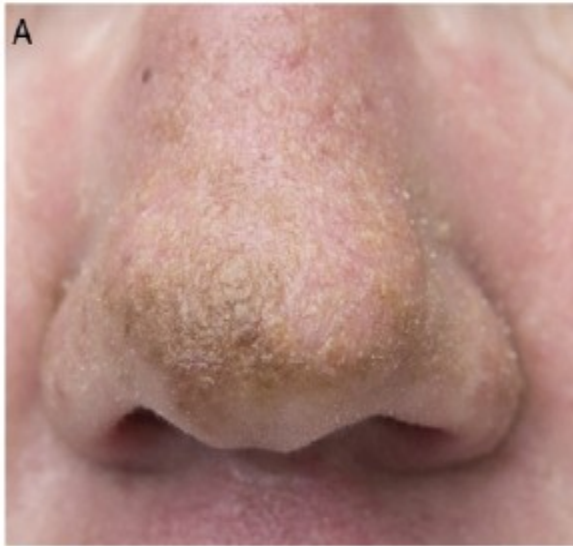Acrokeratosis paraneoplastica

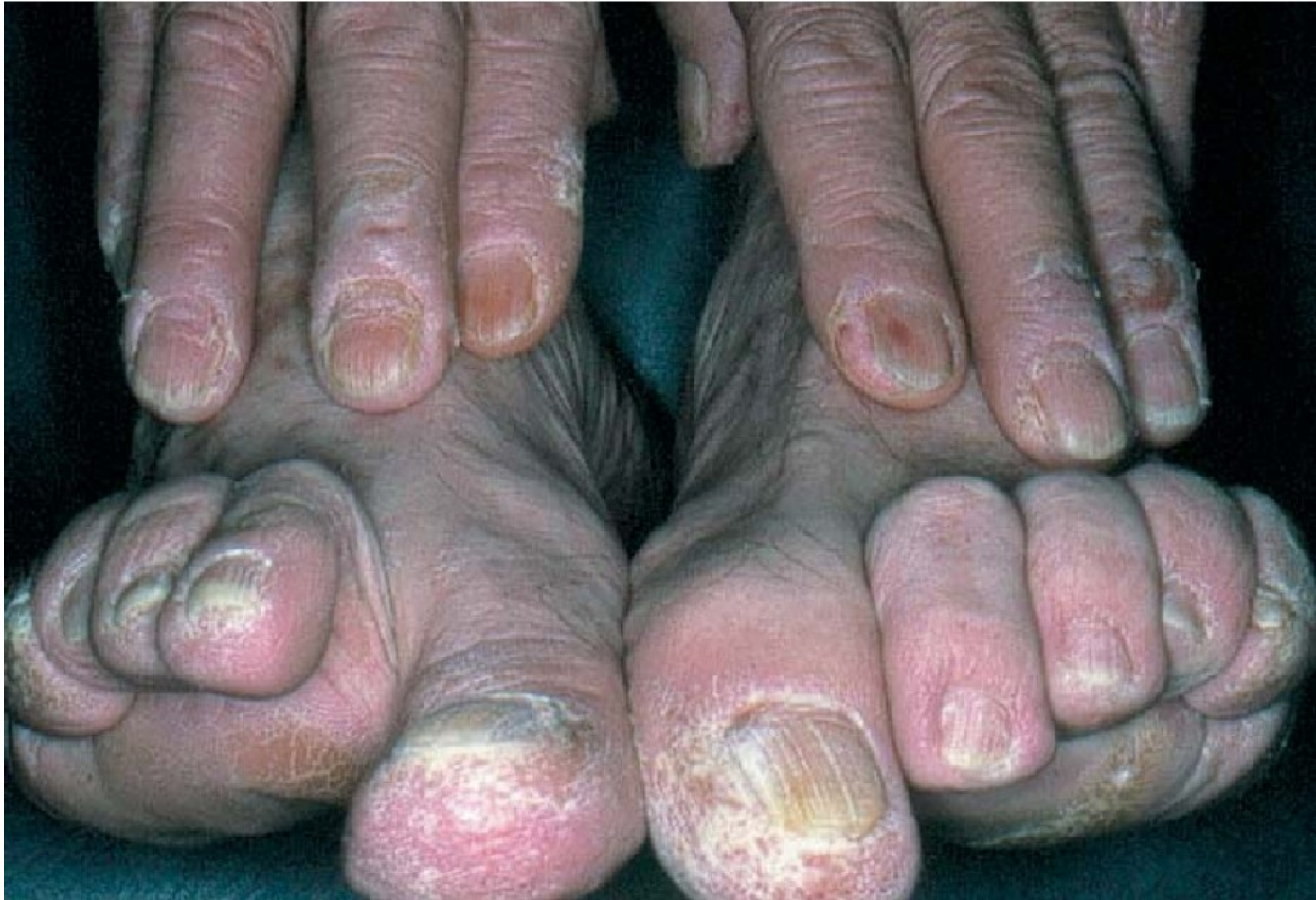Bazex

- Rare dermatosis, typical for men
- Up to 65% precedes the tumor by up to a year!
- Psoriasiform lesions, erythemosquamous
- Hyperkeratotic deposits on the fingers, toes, auricles, tip of nose, elbows and knees
- Gradual development of lesions
- **Dystrophic nail changes**
- Squamous cell carcinomas of the pharynx, esophagus, larynx, lung, urogenital tract, lymphoma

Acrokeratosis paraneoplastica Bazex



Acrokeratosis paraneoplastica Bazex



Acrokeratosis paraneoplastica

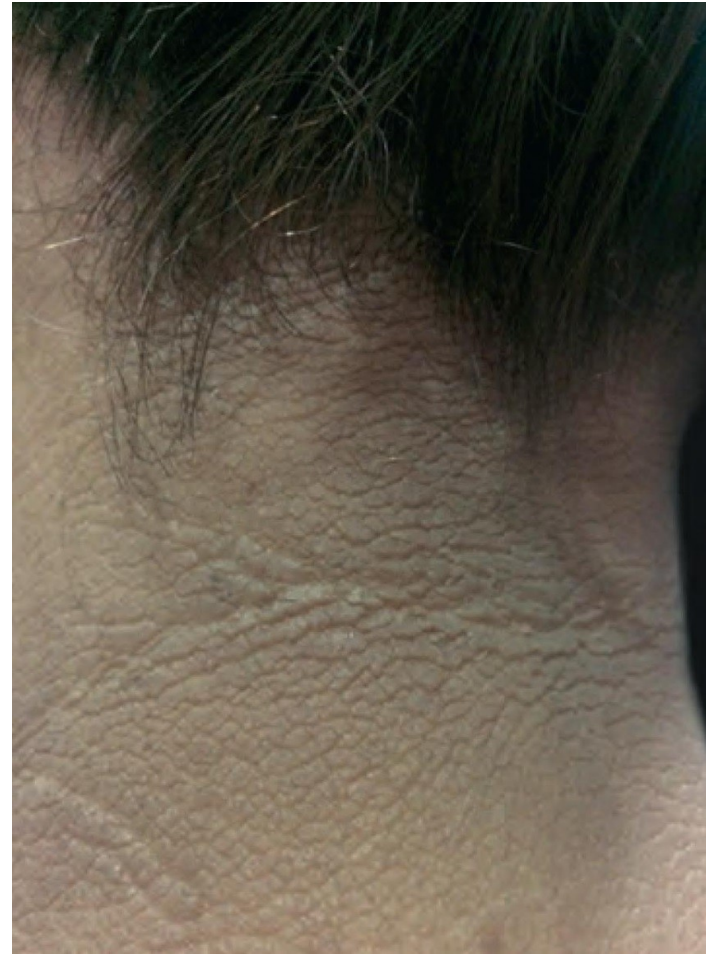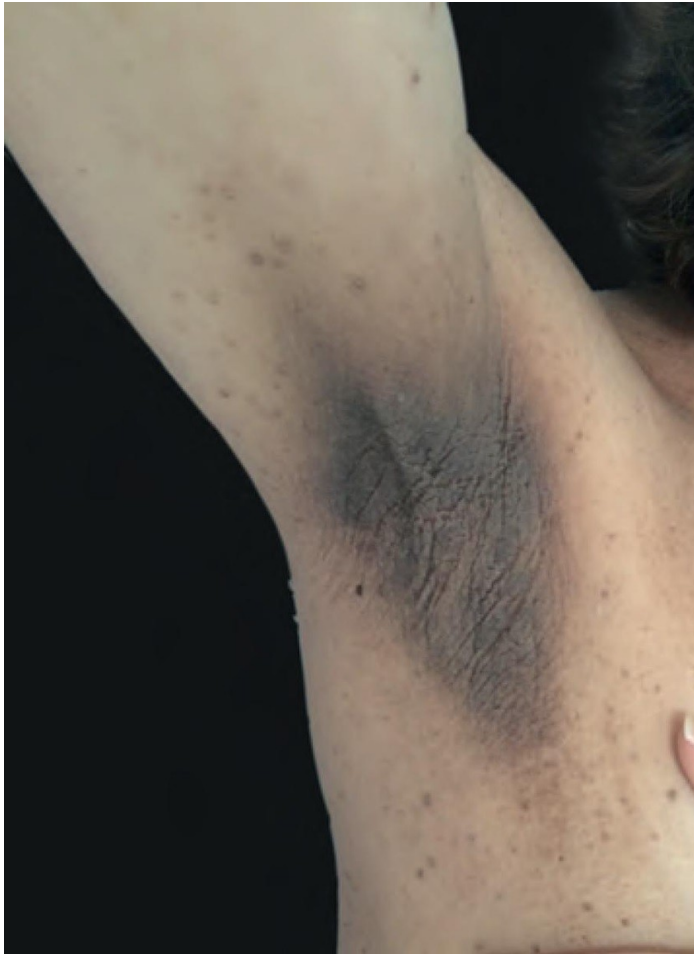Bazex

- Treatment of the underlying disease
- Topical keratolytics, retinoids in combination with CS
- CS in general, retinoids in general, PUVA
- Prognosis depends on the underlying disease
- **Think of dg., look for malignancy!**

Acanthosis nigricans maligna

- Symmetrically thickened velvety skin of yellow-brown to gray-black color with hyperkeratotic papules
- Intertriginous region, neck, extensor surfaces of the limbs, nipples, sometimes on the mucous membranes of the lips and mouth
- **Gastrointestinal adenocarcinomas (70-90%)**, more rarely lung, uterine, ovarian, prostate, lymphoma and sarcoma
- Distinguish the benign form, which arises in childhood most often in the axilla or in adulthood in obese patients with hyperhidrosis and/or diabetes
- Marked pruritus

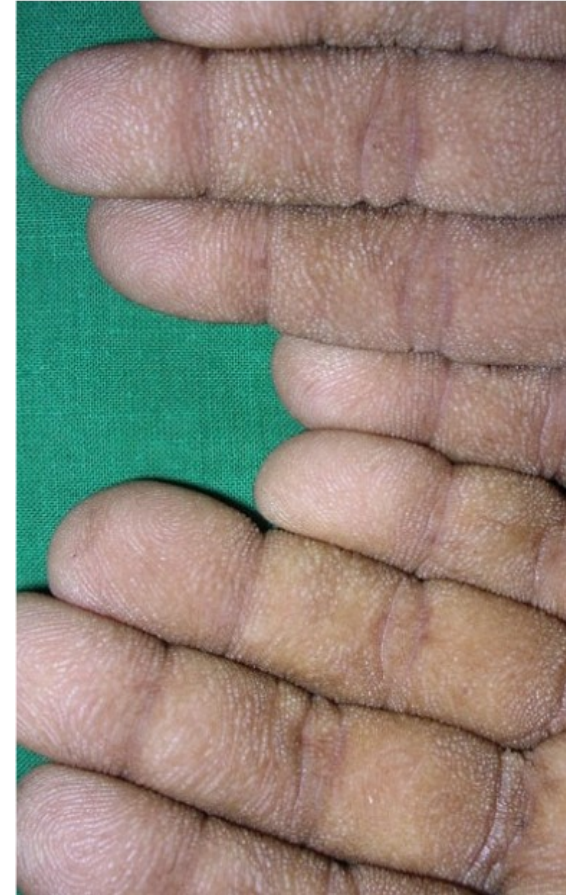
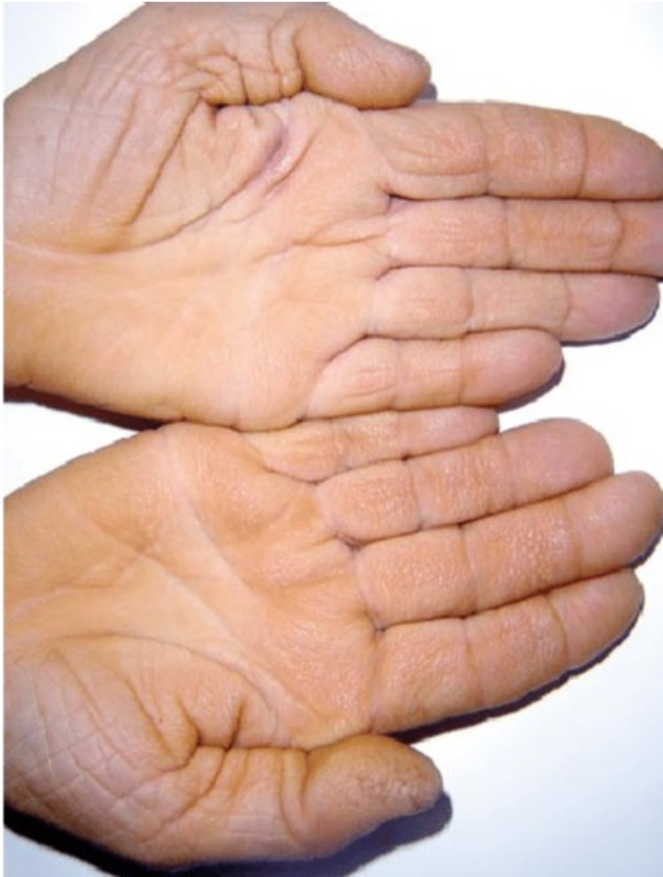Acanthosis nigricans maligna



Acanthosis nigricans palmaris

- Occurs in 75% concomitantly with acanthosis nigricans
- Diffusely thickened rough skin, yellowish color
- Palms with a typically furrowed surface and small hyperkeratotic skin colored papules

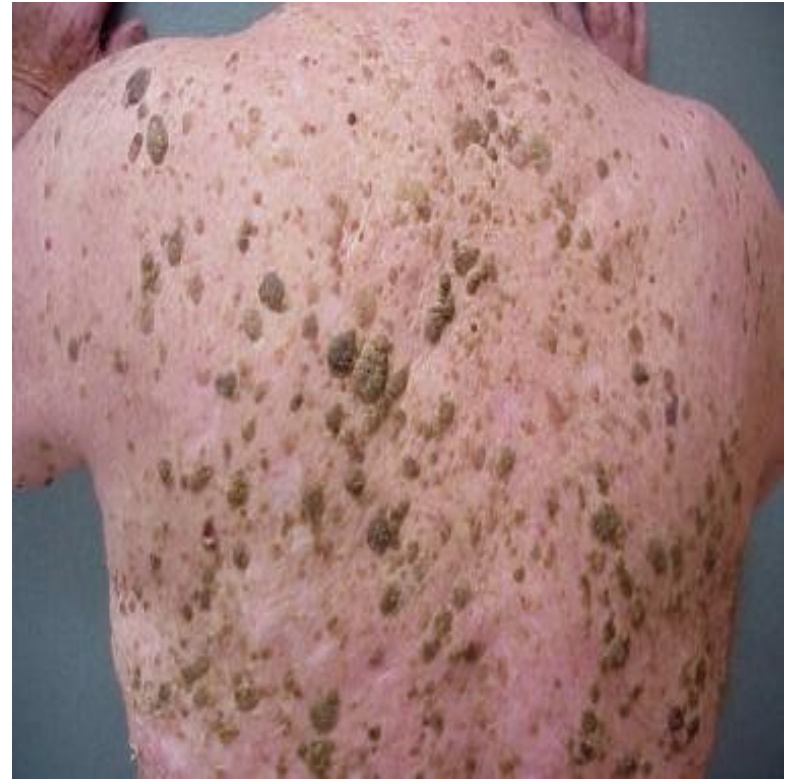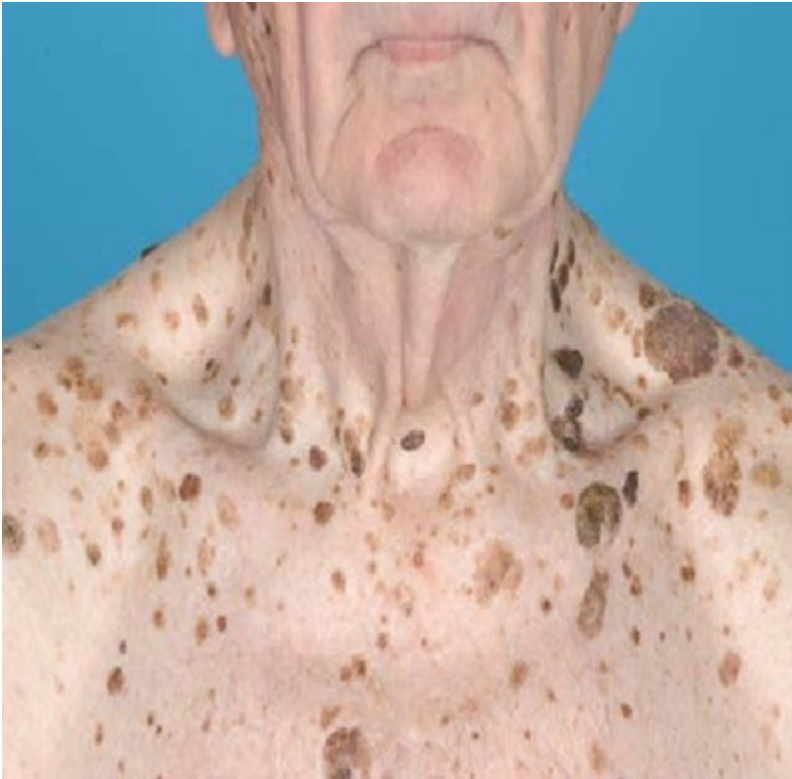Acanthosis nigricans palmaris



Leser - Trélat sign/syndrome

- Characterized by the eruptive emergence of numerous rapidly growing seborrheic warts on the torso, limbs, and later in the face
- Annoying with severe pruritus
- About 20% is associated with acanthosis nigricans
- Leser-Trélate syndrome occurs in tumors of the stomach and colon, breast, lung, ovary, uterus, kidney, liver and pancreas
- Also associated with HIV

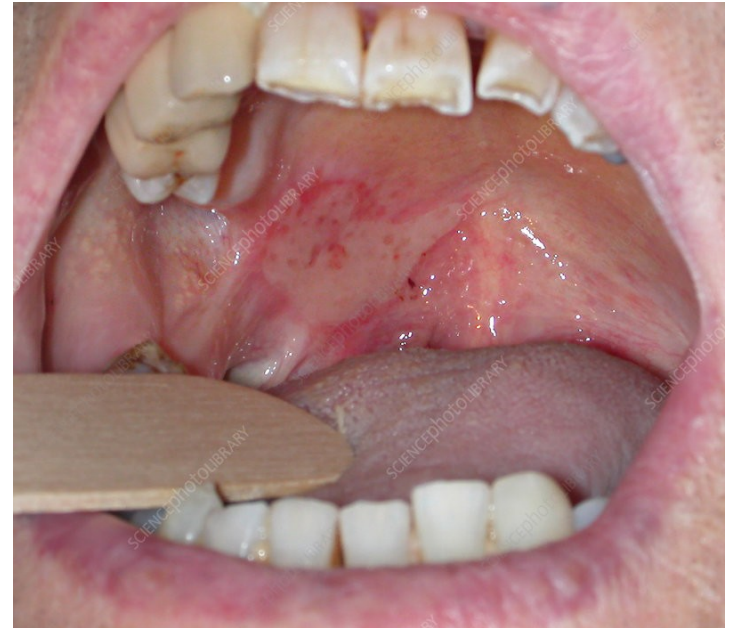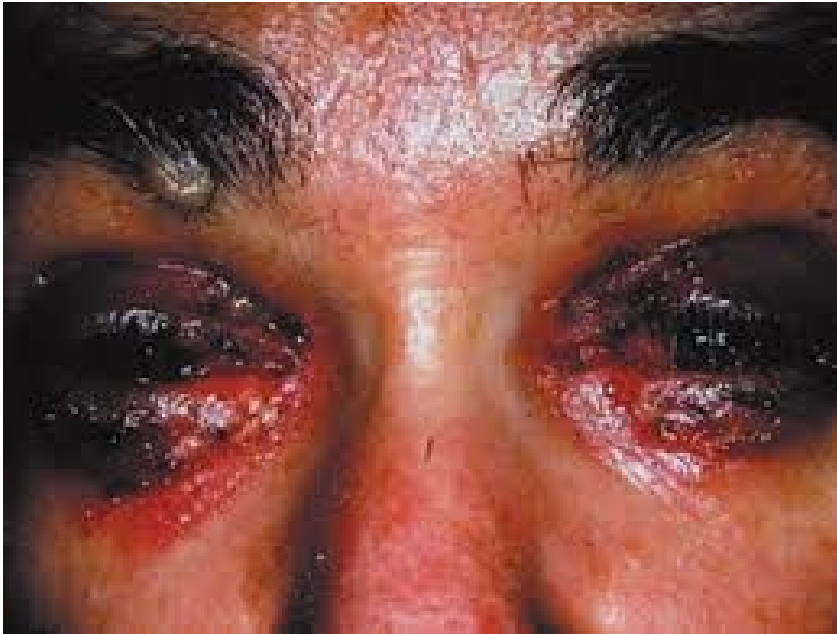Leser - Trélat sign/syndrome



Pemphigus paraneoplasticus

- Severe erosive stomatitis, pharyngitis and conjunctival involvement
- Skin blisters, lichenoid manifestations resembling GVHD
- Multiforme manifestations and palm involvement
- Lung involvement is typical (bronchiolitis obliterans, alveolitis)
- Non-Hodgkin lymphoma, thymomas, sarcomas, Castleman's tumor

Pemphigus paraneoplasticus

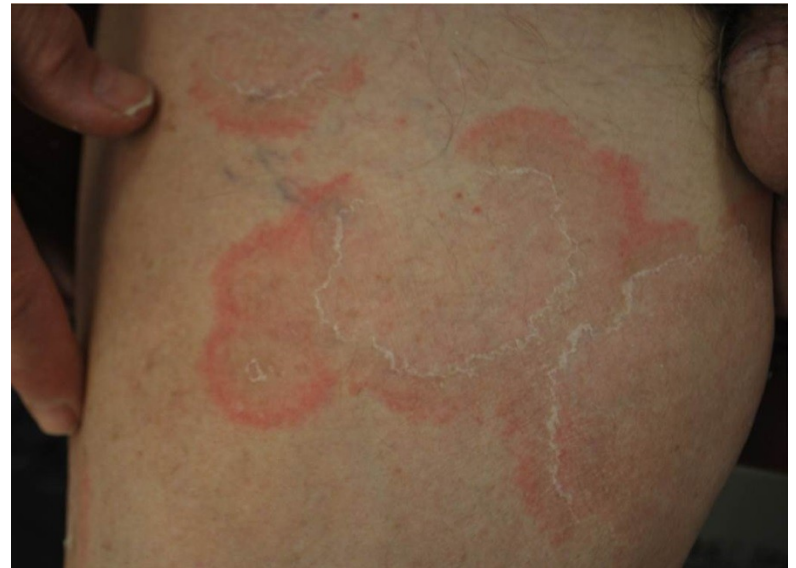
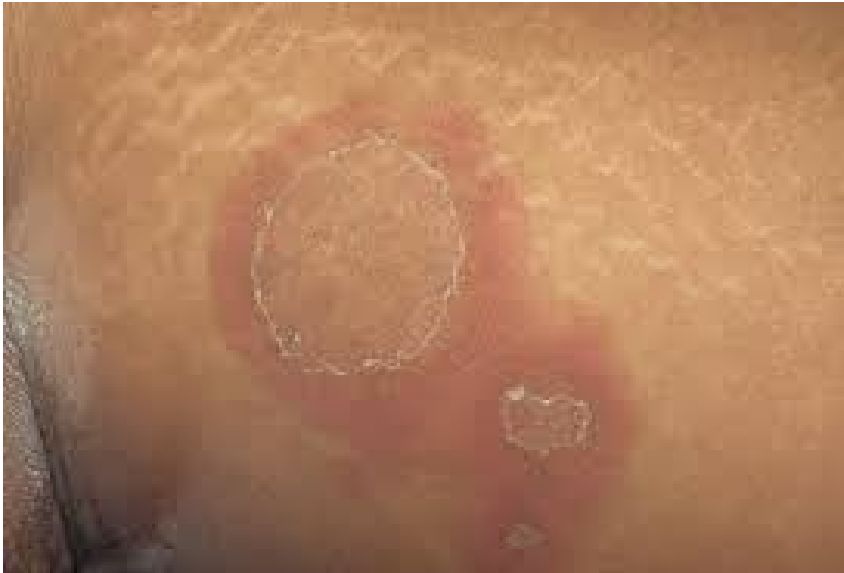
Erythema annulare centrifugum

- Reddish slow-growing deposits with raised edges and a sunken center with collarlike peeling
- Resembles hives
- Has been described in lymphomas, breast, lung and gastrointestinal cancers
- Also infections, infestations, autoimmune diseases

Erythema annulare centrifugum

- Diff. dg. Erythema gyratum repens, erythema necrolyticum migrans, tinea, hives
- Treat underlying diseases, antihistamines, antiphlogistics



Take home message

- Cutaneous paraneoplastic syndromes represent a heterogeneous group of skin diseases, the recognition of which may enable the early detection of an as yet unmanifested malignancy
- Approximately 70% of neoplasias in patients with manifest paraneoplastic syndrome can be detected by a simple clinical examination and basic screening
- Unfortunately, most skin paraneoplastic syndromes are associated with unresponsive cancers and the prognosis is often poor
- **Think about cancer as a possible diagnosis**

BEST
DERMATOLOGIST
YOU ARE

**Good Luck
on the Exam**

