

# Benign skin tumors

I.DVK FNUSA a LF MU

- They grow expansively, so they can apply pressure to surrounding tissue, but they do not grow into it and destroy it
- They keep structural and functional maturity

- **Epithelial**

- Seborrheic keratosis

- **Adnexal**

- Syringoma
- Cylindroma
- Trichoepithelioma

- **Mesenchymal**

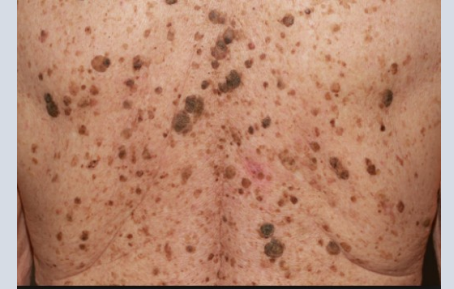- Fibroma
- Hemangioma
- Lipoma
- Keloidal scar
- Dermatofibroma

- **Vessel**

- Hemangioma (capillare, cavernous senile, angiokeratoma)

# 1) Benign epithelial tu = epithelioma

- Seborrheic keratosis (verruca seborrhoica, senile lentigo)

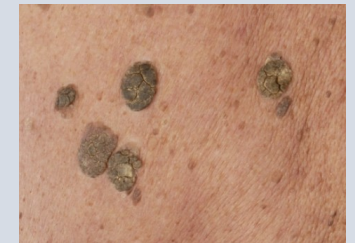

- Is the most common benign skin tumor, almost every elderly person has several

- Are most common on the: trunk (mostly back), head

- They start as well-circumscribed skin-colored or tan

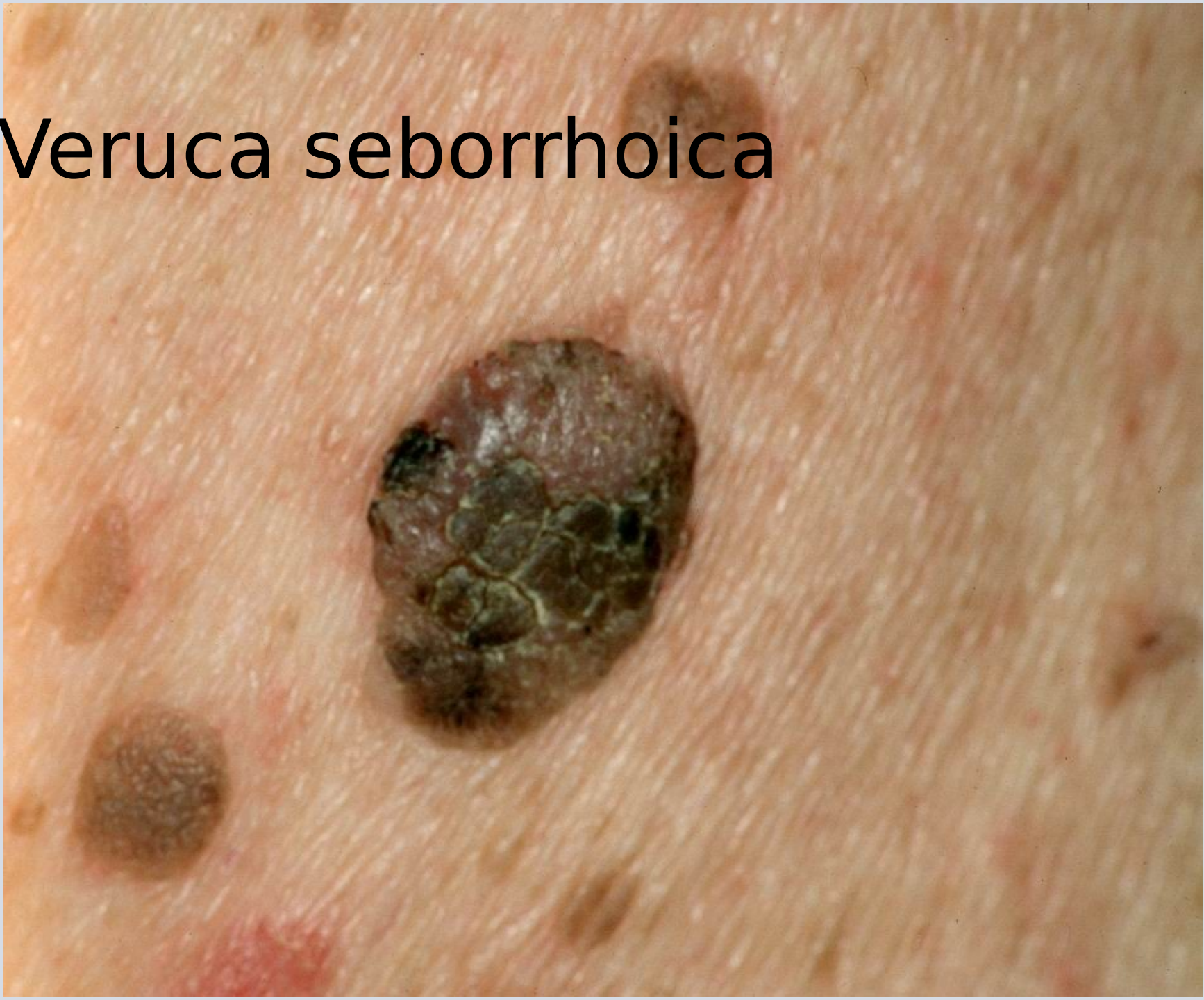maculas, then they slowly become darker, thicker and larger



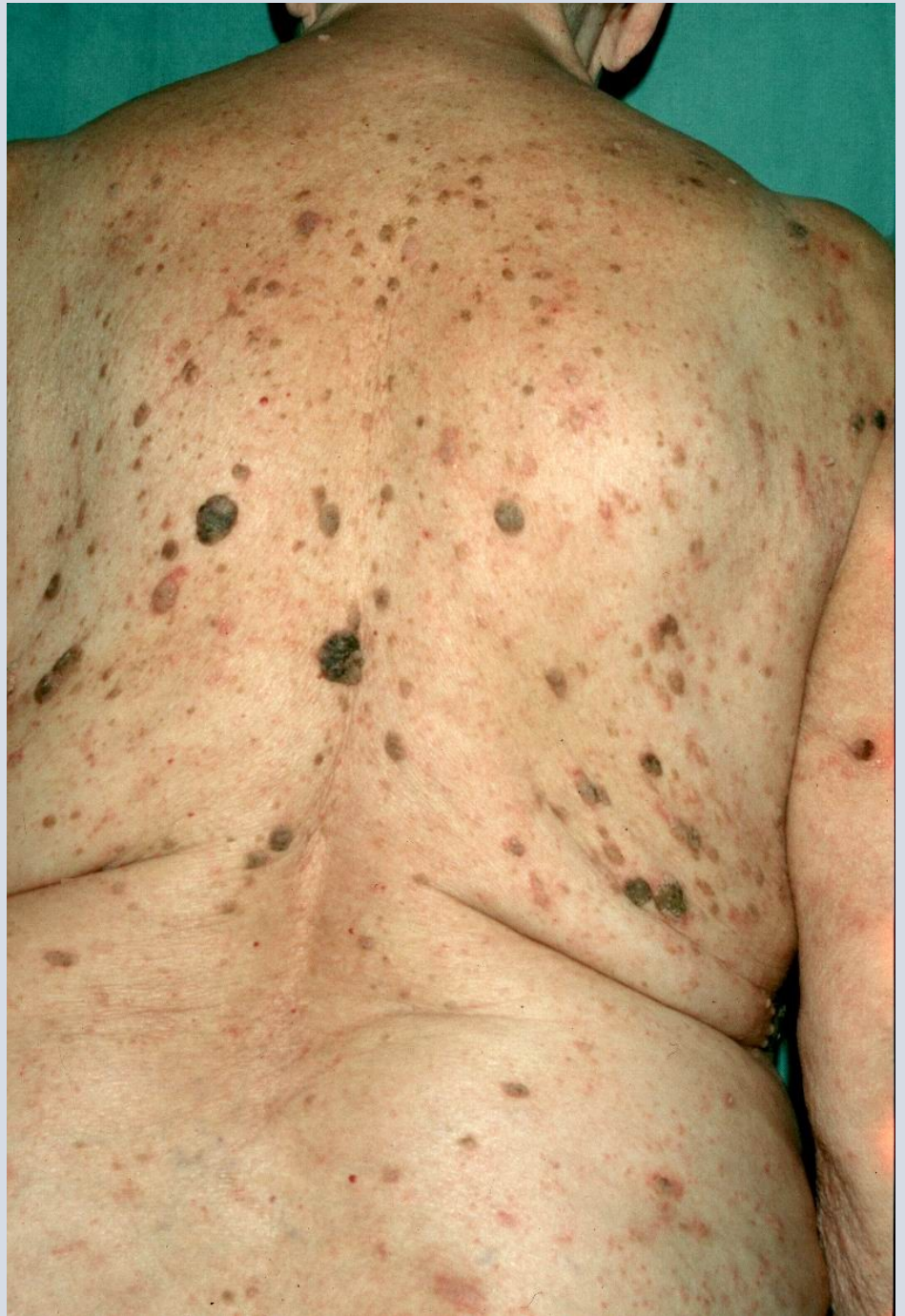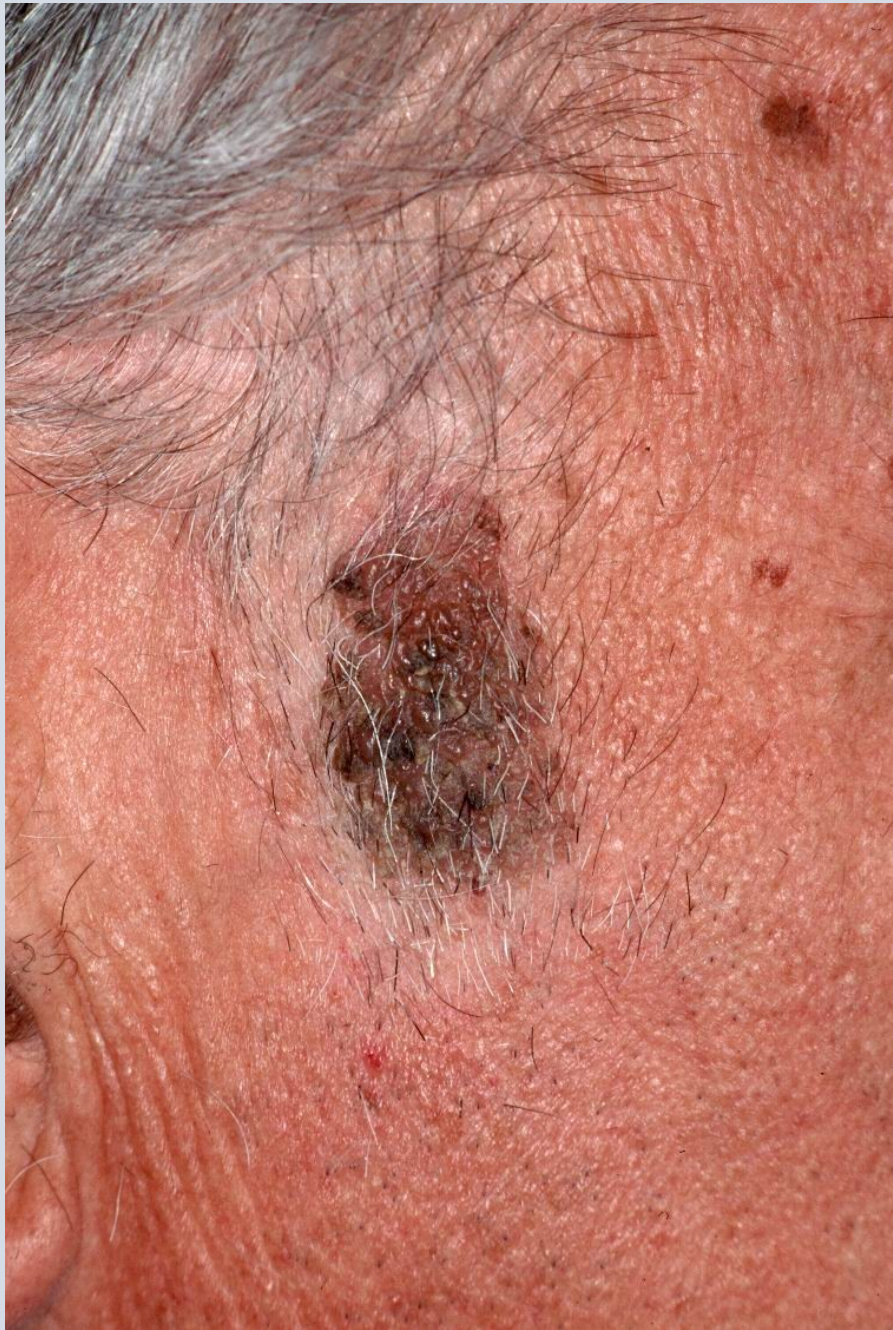- Léser Trelát sign - is sudden eruption of numbers verrucas- can be the sign of malignant tumor of organs (gastrointestinal system, hematopoetic sys.)

- Therapy - no therapy is needed, but patients usually desire removal for cosmetic reasons - curettage or cryotherapy, excision

Veruca seborrhoica







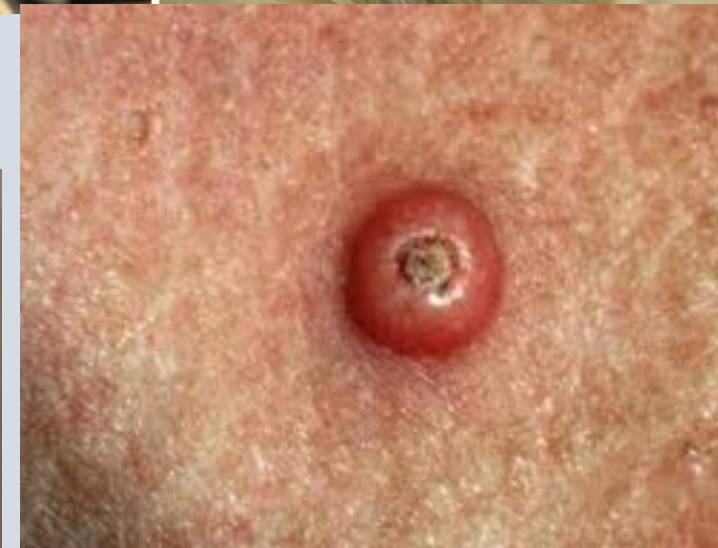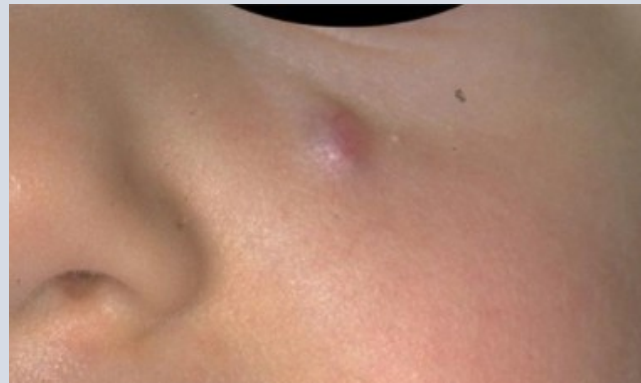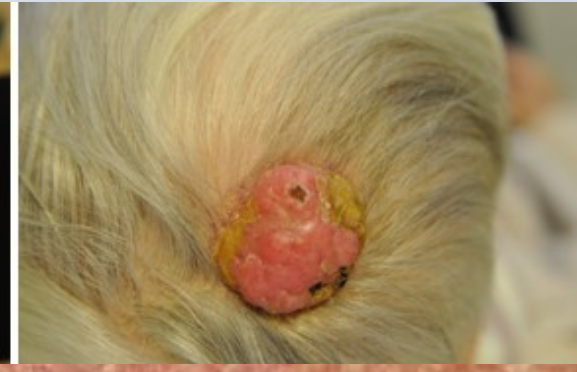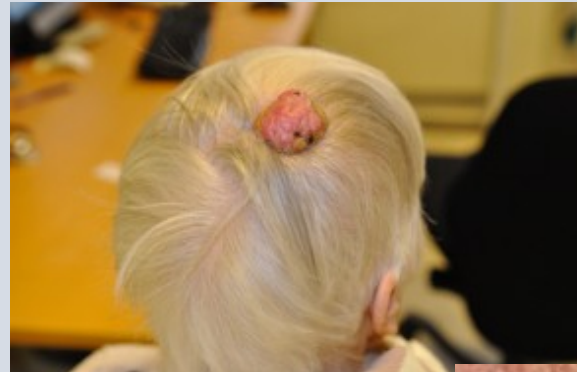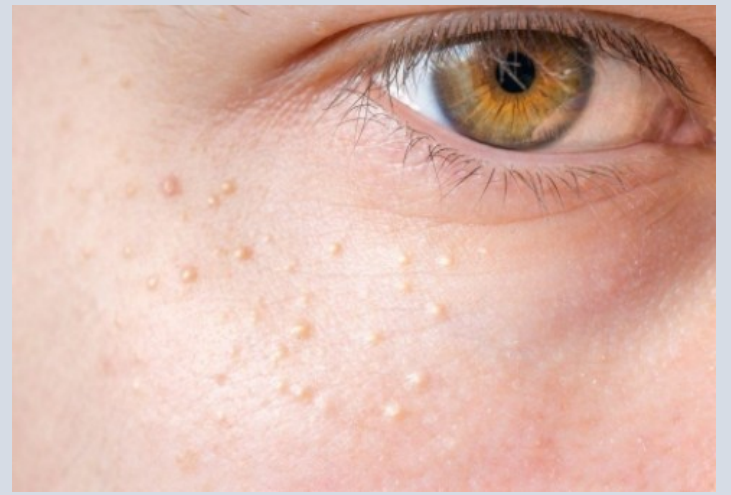## **2) adnexal tumors = adenomas**

- This is large family of tumors with features of eccrine, apocrine, sebaceous, or hair follicle differentiation
- All can be treated by excision



## 2) adnexal

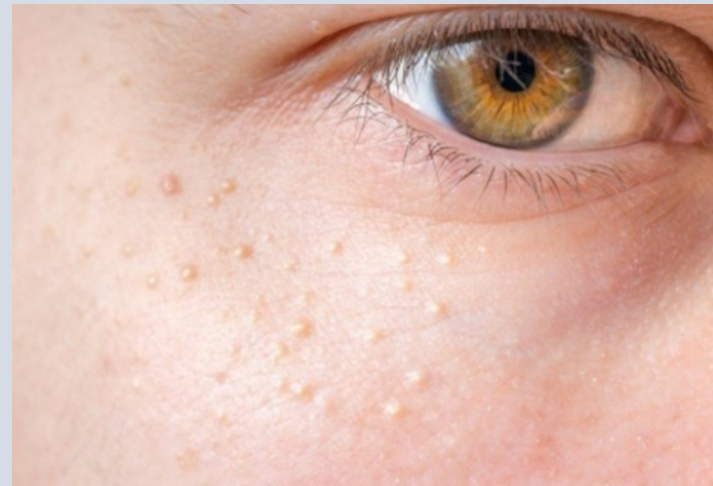- Syringoma
- Cylindroma
- Pilomatrixom
- Kerathoakanthoma





- **Syringoma**

- From the infundibulum of the sweat glands
- 2 forms – usually periorbital, sometimes disseminated
- Clinically – multiple tiny skin-colored papules around the eyes
- Therapy – excision of solitary



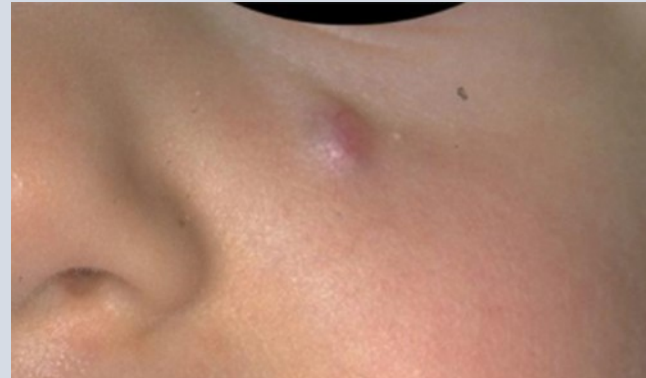- **Cylindroma**

- Epithelioma with apocrine differentiation
- It appears in early adult age, gradually increasing during the time
- Usually occurs on the scalp, at the beginning few papules or nodules skin-colored, or red, gradually increasing the number of nodules, so they can cover whole hair - described as „turban tumour“
- Therapy – surgical excision



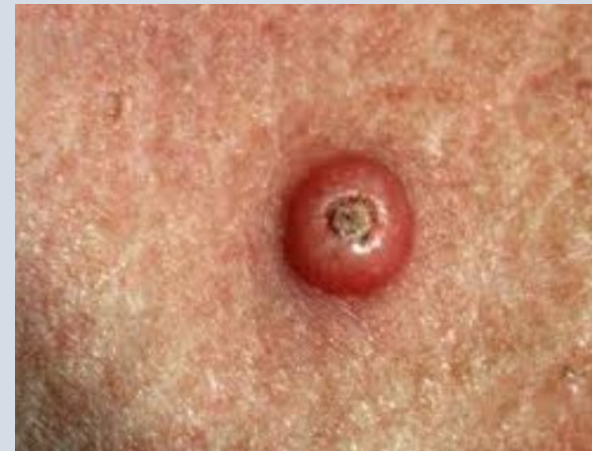- **Pilomatrixom**

- Epithelioma of the hair follicle
- Common cystic childhood tumor
- Usually on the scalp or cheek
- Therapy - excision



- **Kerathoakanthoma**

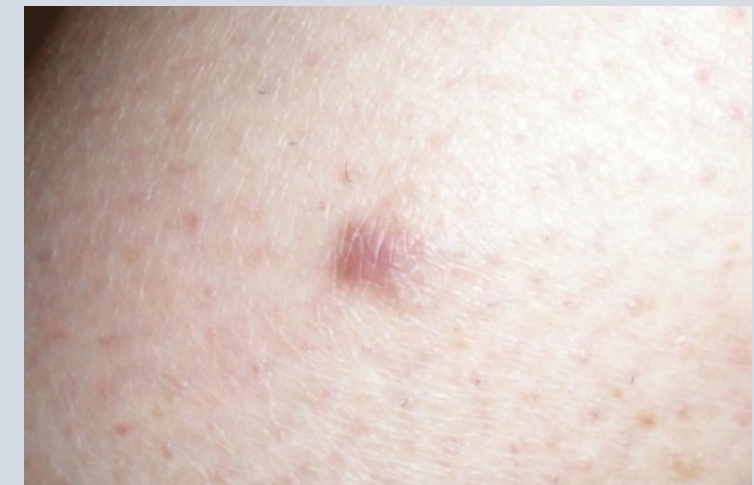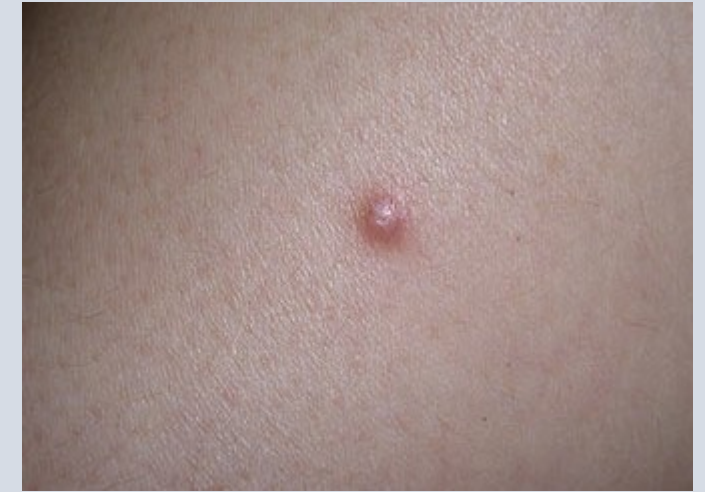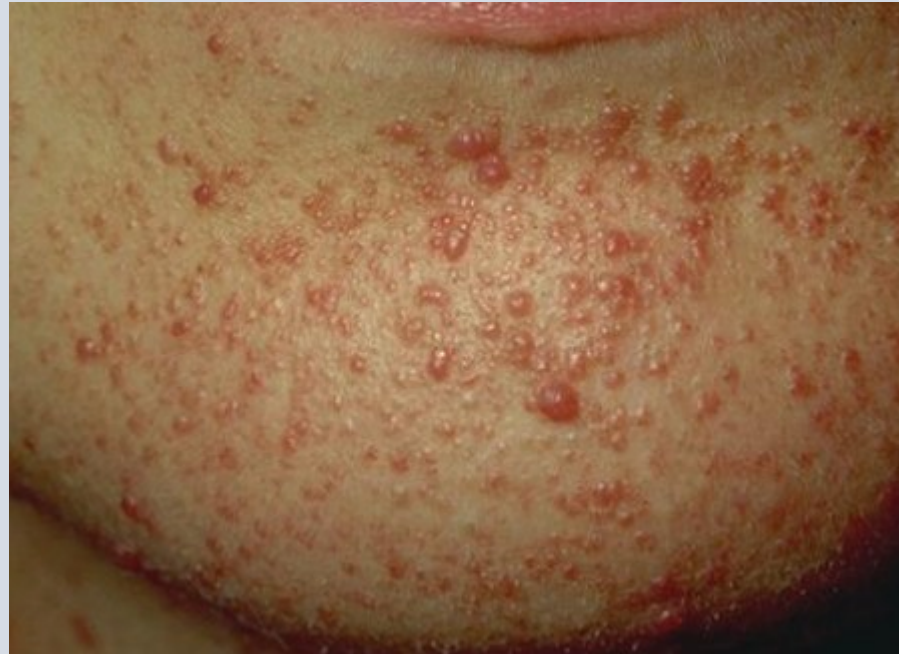- From supraglandular part of hair follicle
- it is formed in sun-exposed parts of the body (face, neck, hands) in people around 60 years, or immunosuppressed people
- fast-growing solitary semicircular nodule reaching up to 2 cm in diameter within a few weeks with bulging edges and a central crater filled with horn
- On the edges there are many teleangiectasias
- It could spontaneously regress with scar
- Therapy - excision

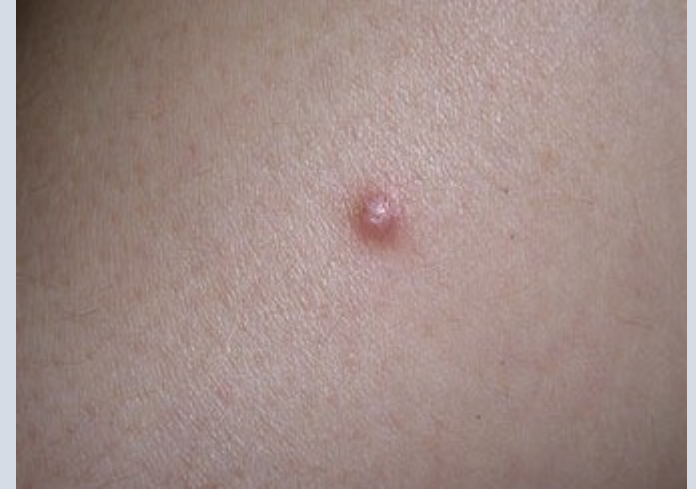



### 3) Mezenchymal tumors

- Histiocytoma, dermatofibroma
- Keloid, hypertrophic scar
- Fibroma molle
- Angiofibroma
- Leiomyoma
- lipoma



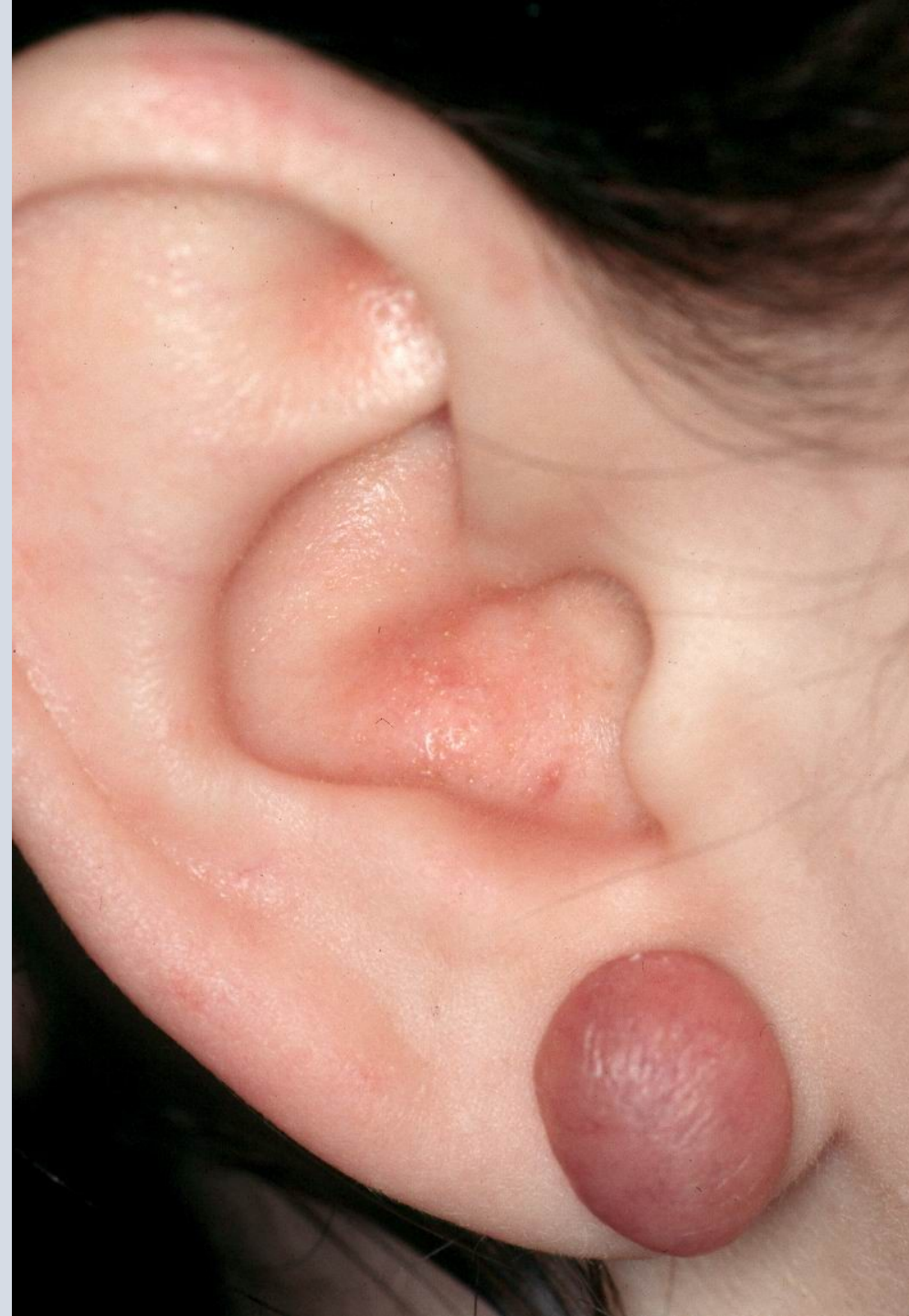

- **Histiocytoma fibrosum, dermatofibroma**
- One of the most common skin tumors
- Mainly appears at younger people on extremities, sometimes on trunk
- It is reactive inflammation after bite of insect or injury
- It looks like solitary flat lesion or small nodule, red-brown
- Therapy isn't needed, but possible is excision

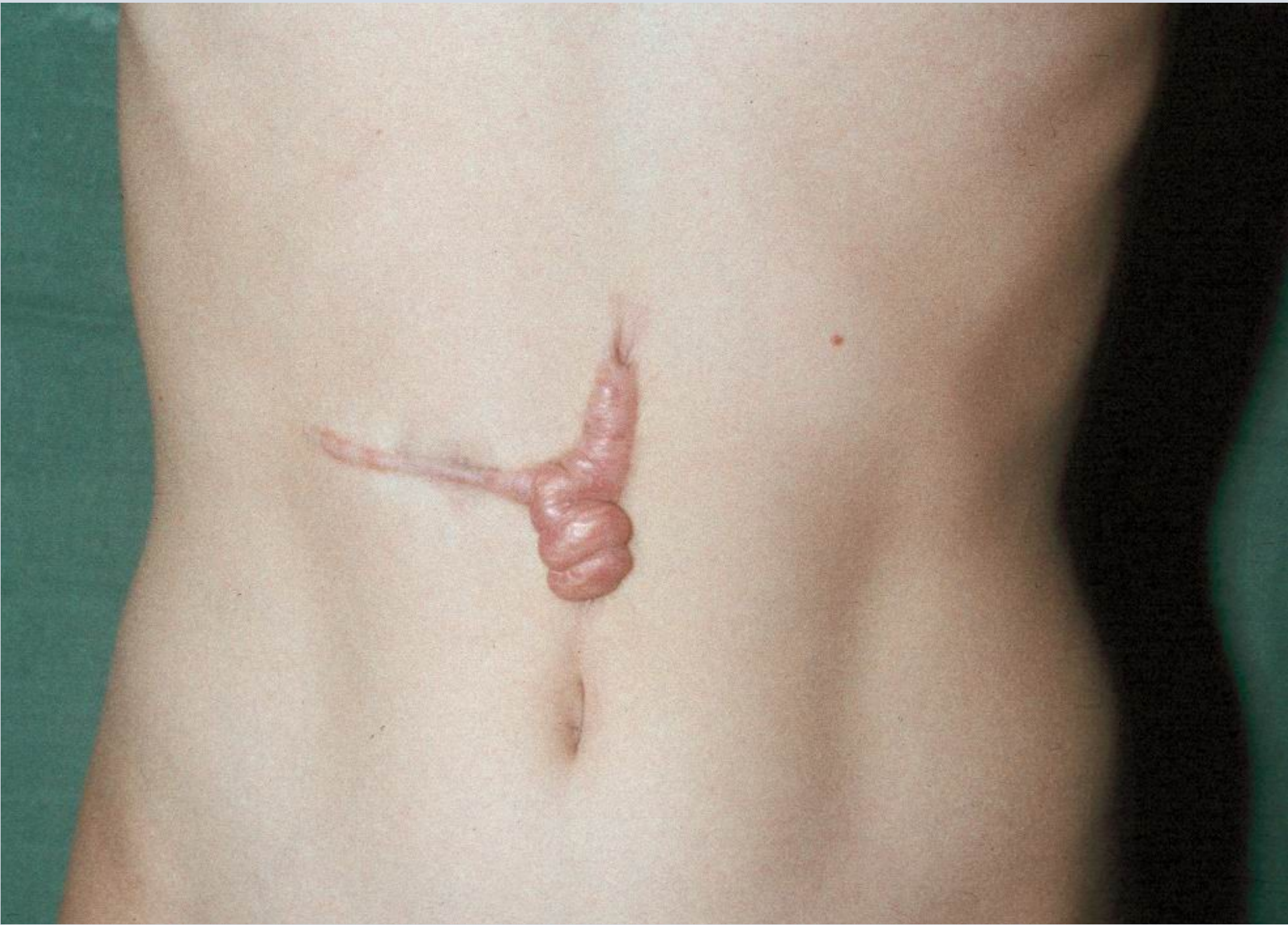
- **Keloid, hypertrophic scar**

- A keloid results when the reparative process extends beyond bounds of the original scar
- Typical are – middle chest, following cardiac surgery or ear lobes after piercing
- Blacks are more likely to develop keloids
- Therapy – treatment is difficult, any manipulation may result in worsening, best results are obtained with shave excision, cryotherapy, interlesional corticosteroids combined with compression
- Hypertrophic scar is confined to the side of the tissue damage

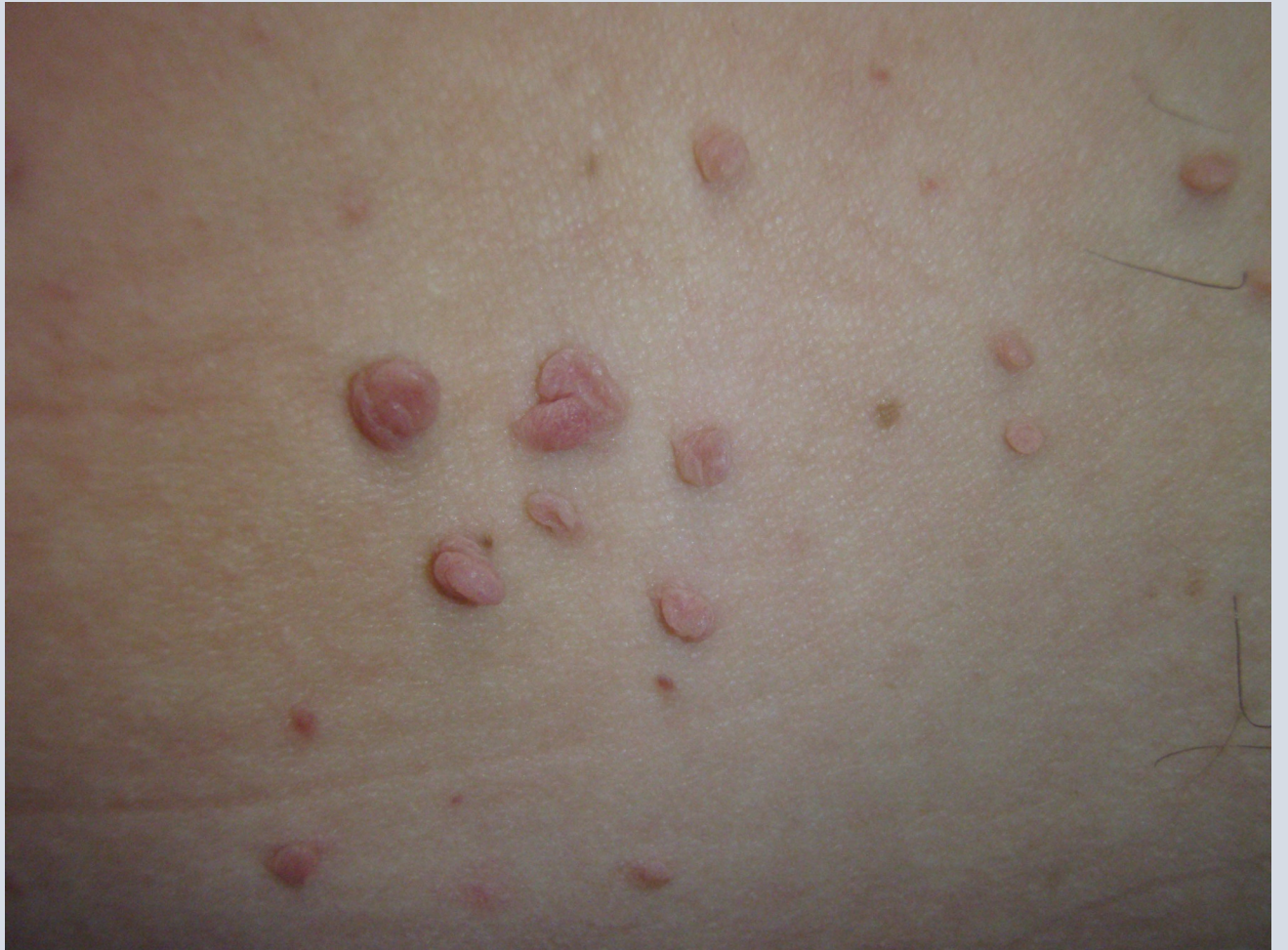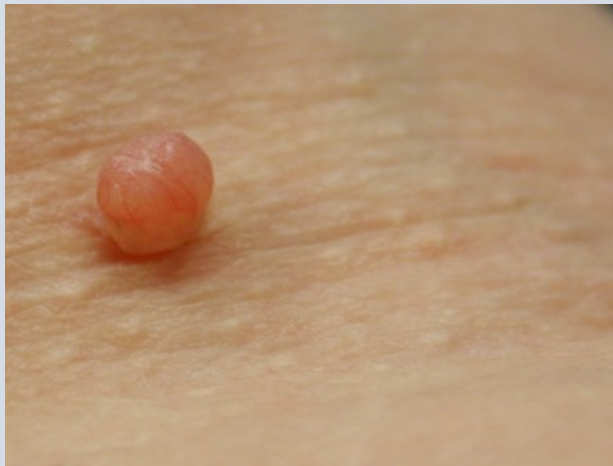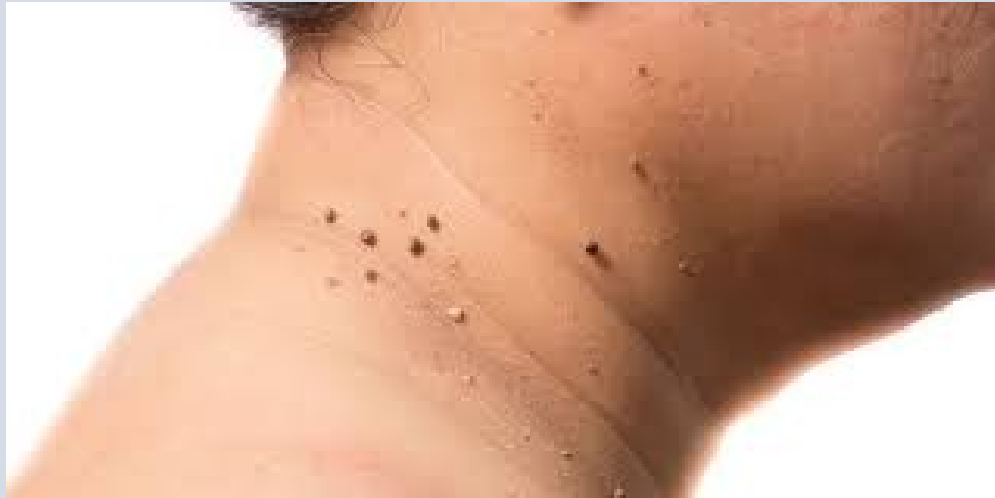# Keloid







- **Skin tags (Fibroma molle)**
- Tinny skin colored or tan papules
- Typicaly on neck, axillae or groin
- More common in overweight and older individuals
- Small lessions can be treated by cauter or excision





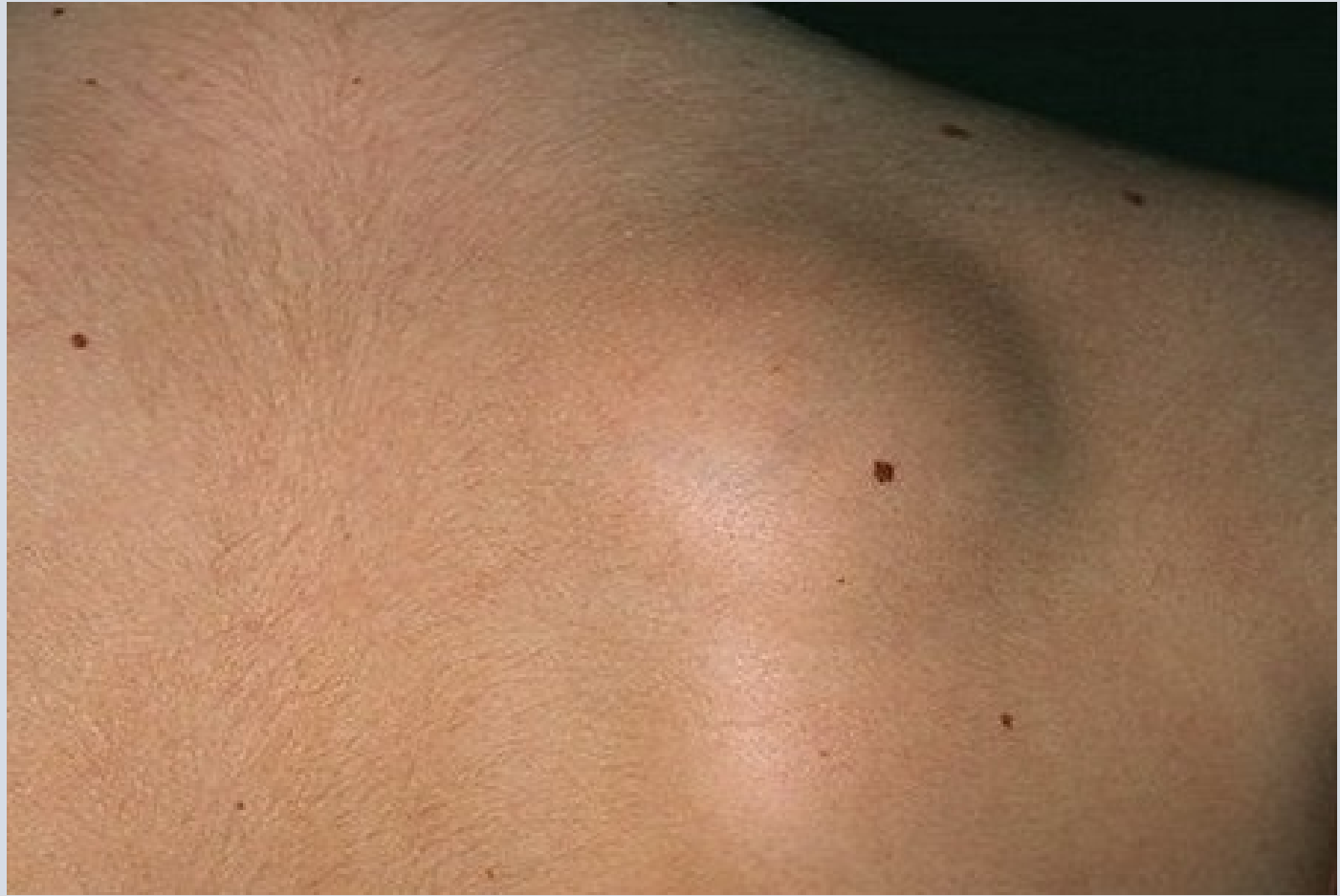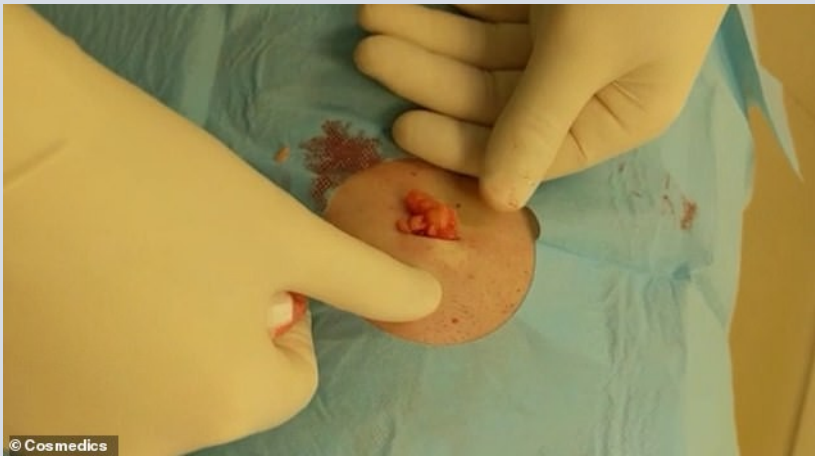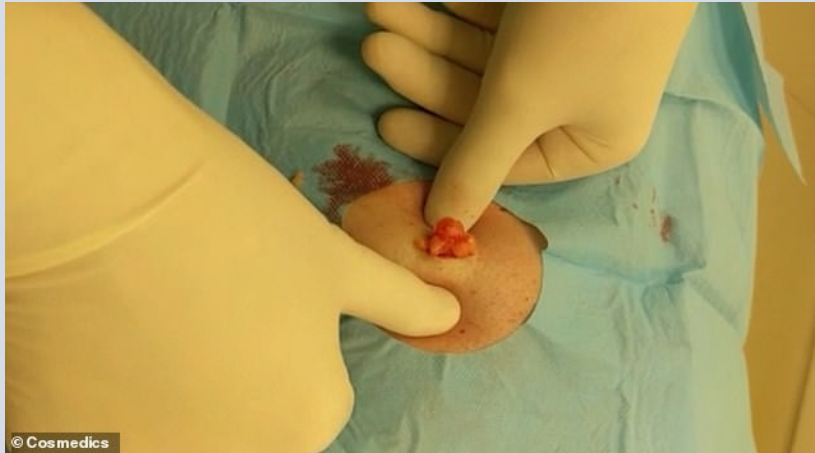- **Angiofibrom**

- Proliferation of small vessels with perivascular fibrosis
- Very often formed from intradermal nevi after regression of pigmentation
- Variants:
  - Fibrous papule of the nose – small solitary inconspicuous nasal papule
  - Tuberous sclerosis – facial papules
- Therapy – excision (solitary), laser (multiple lesions)



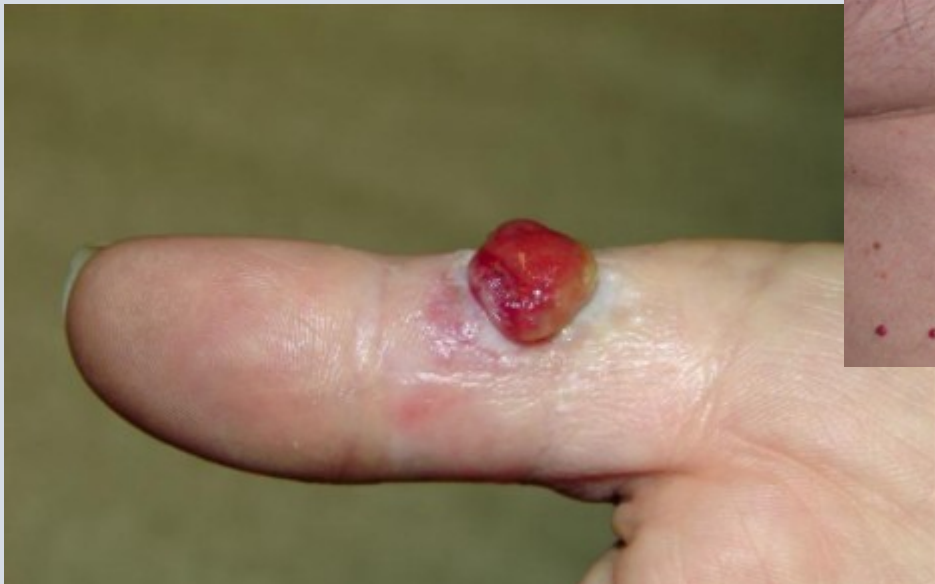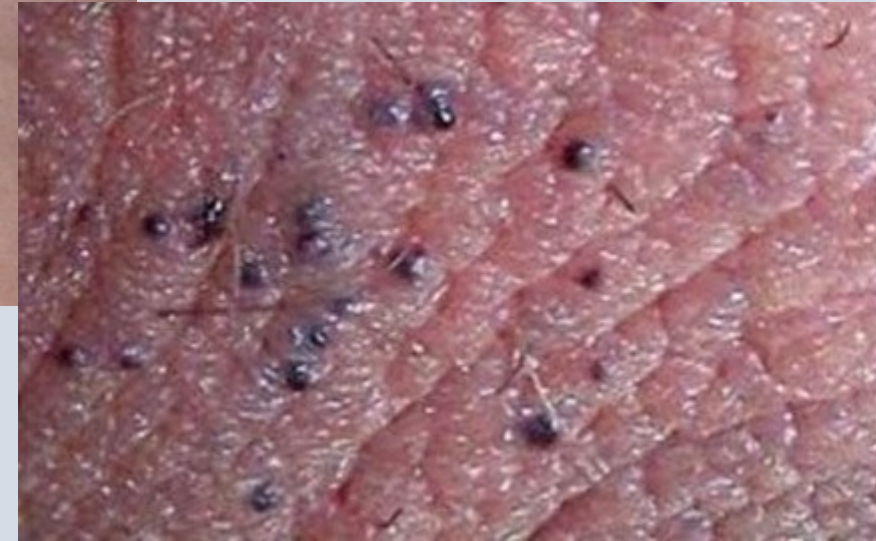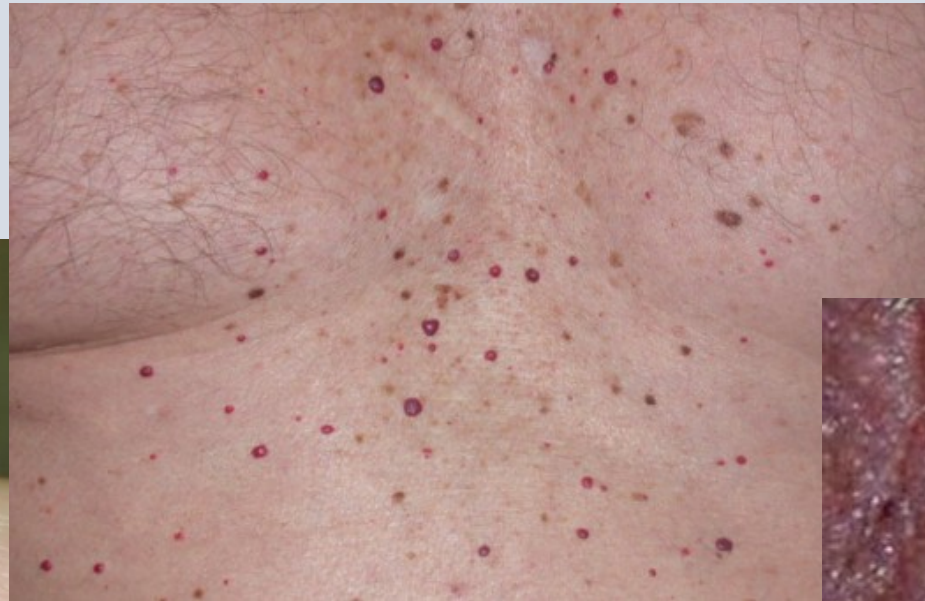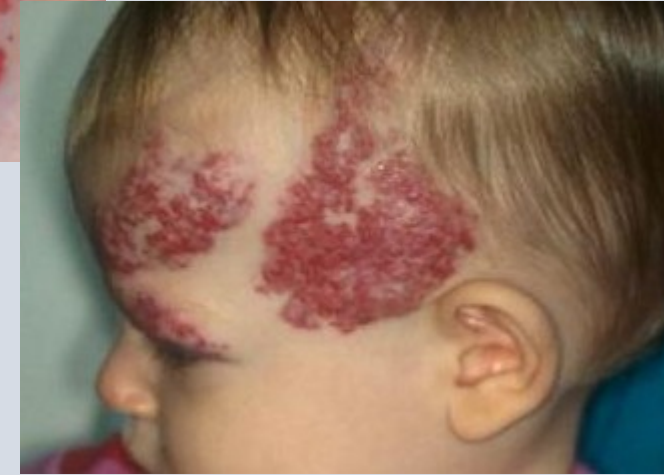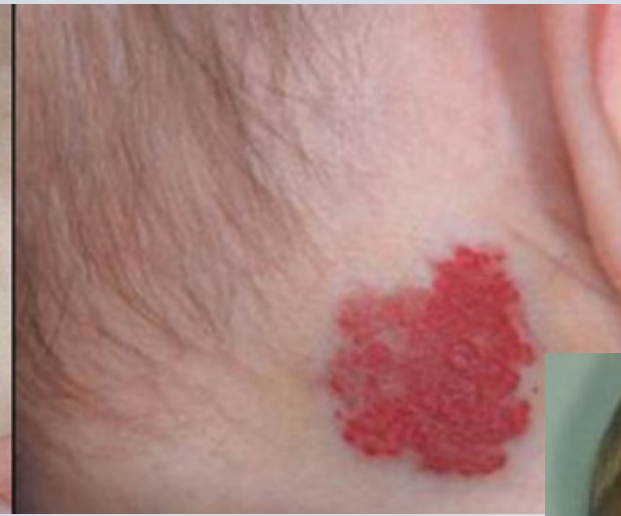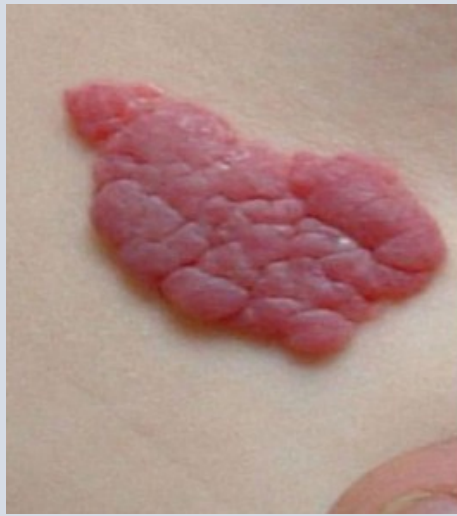- **Lipom**

- Bordered proliferation of subcutis fat tissue
- They are solitary or multiple
- They're located in subcutaneous mass like soft, elastic oval free movable against skin and the base
- It doesn't resolve with weight loss
- Unpainful (normally)
- Therapy – all can be easily excised if they're functionally or cosmeticaly disturbing or painful



## 4) Vascular

- Hemangioma capillare
- Hem. Cavernosum
- Hem. Senile
- Granuloma pyogenicum
- Angiokeratoma
- Lymfangioma



- **Hemangioma capillare**

- This is the most common vascular lesion
- The greatest risk factor is low birth weight, it is present after birth or in first months of life
- The common localization is on head and neck, start as macule with telangiectasia and evolves into rubbery red tumor
- During regression it develops a gray sheen and heals with scarring
- 50% - have resolved by 5 years
- 70% - by 7 years
- Larger takes long to resolve and leave cosmetics defects



- **Hemangioma capillare**

- Complication includes:

- ulceration

- scarring

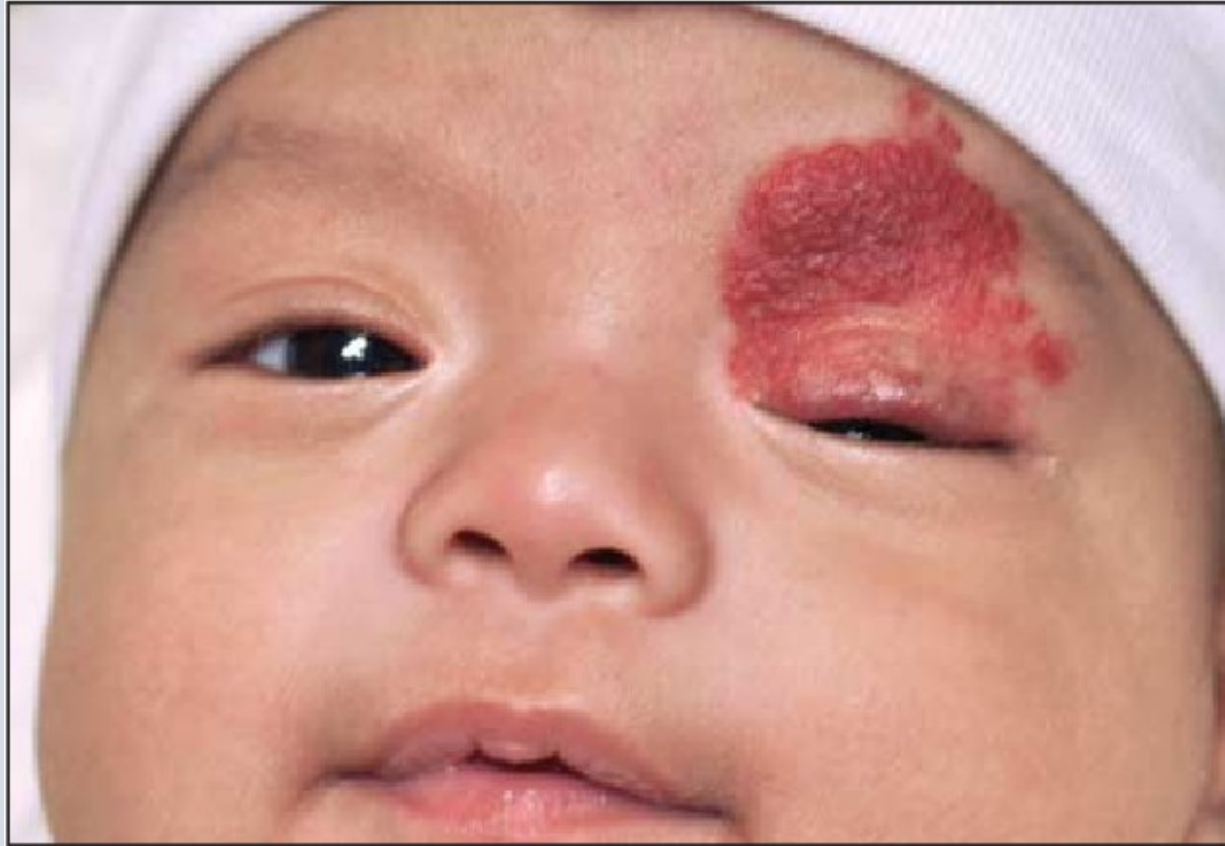- periorbital and periorificial risk of amblyopia sometimes interferes with eating or breathing

- vascular problems risk of shunting and high output cardiac failure

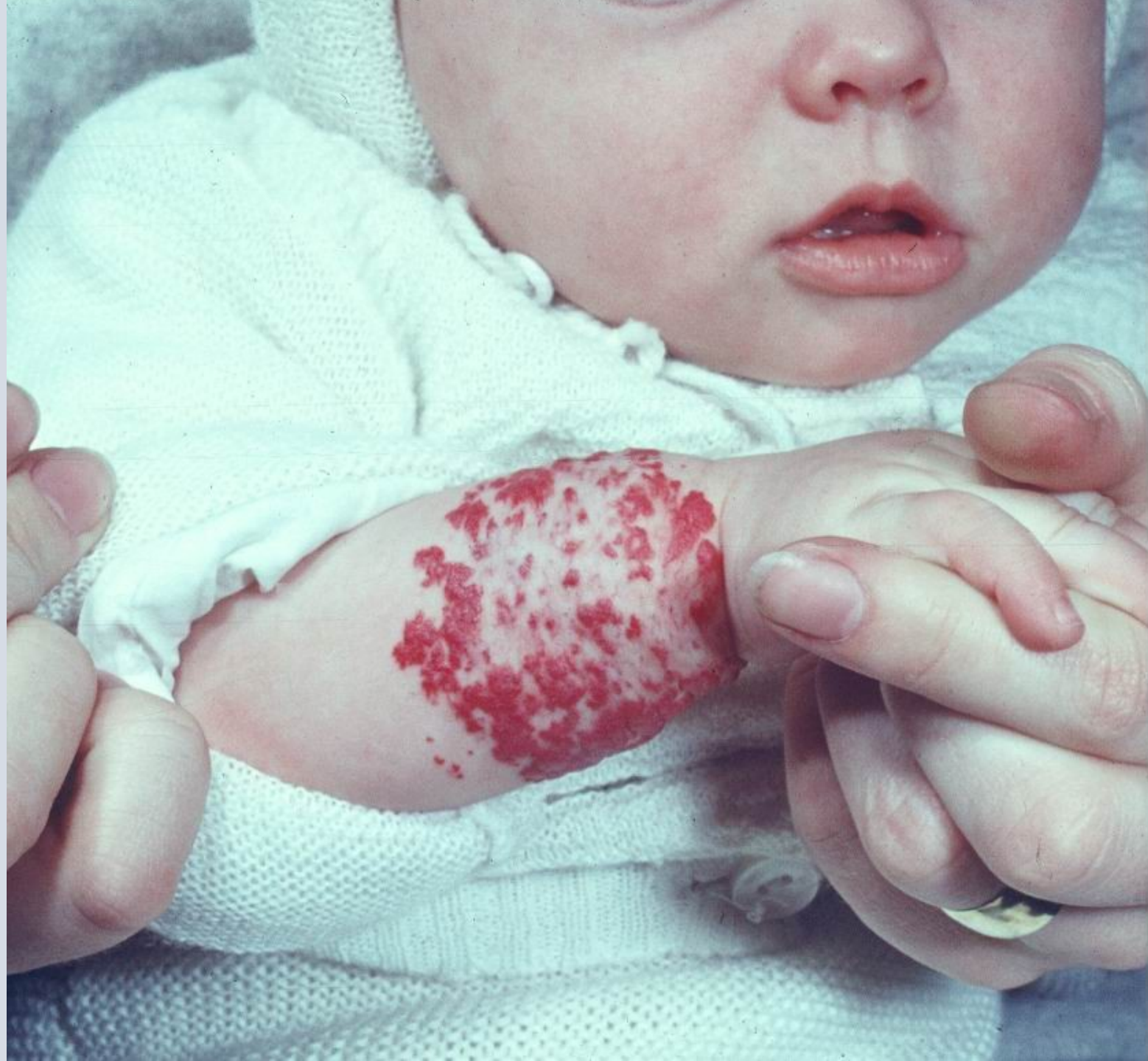- aggressive growth

- **Hemangioma capillare - Therapy**

- observation for low-risk lesion
- Early cryotherapy may induce regression
- Topical or systemic Beta-blockers
- Topical or intralesional corticosteroids and excision or laser
- High risk lesions:
  - Systemic corticosteroids or interferon alpha



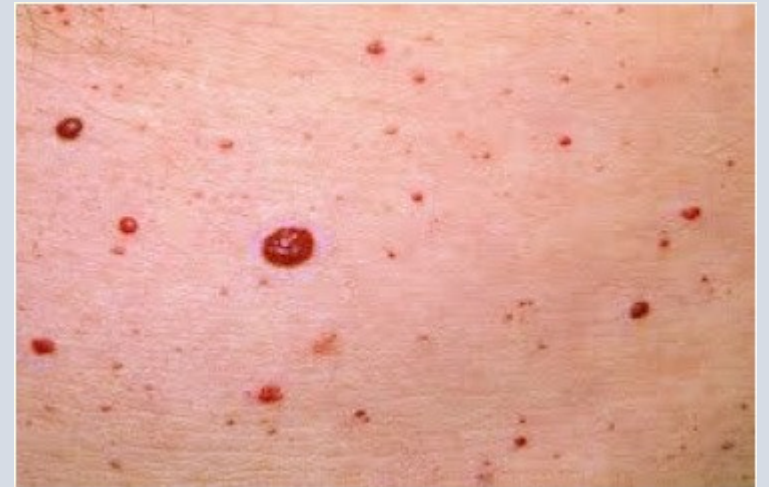**Figure 1.** Before topical treatment, a large capillary hemangioma involved





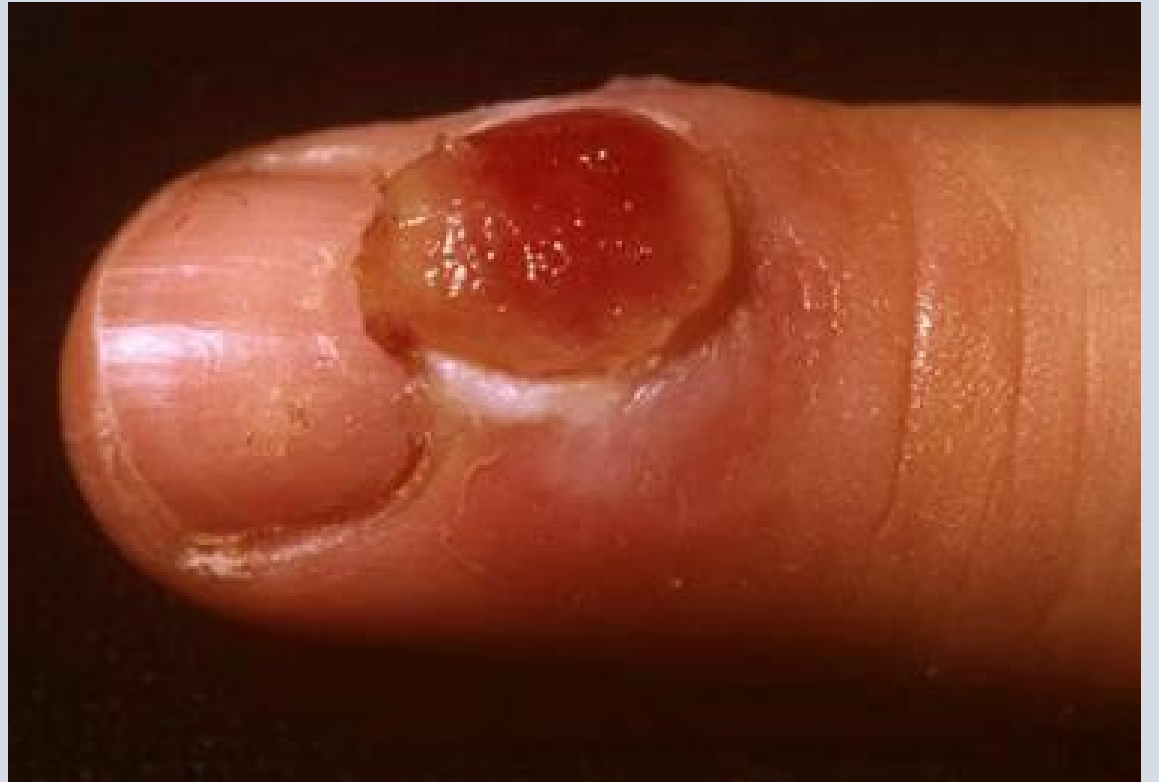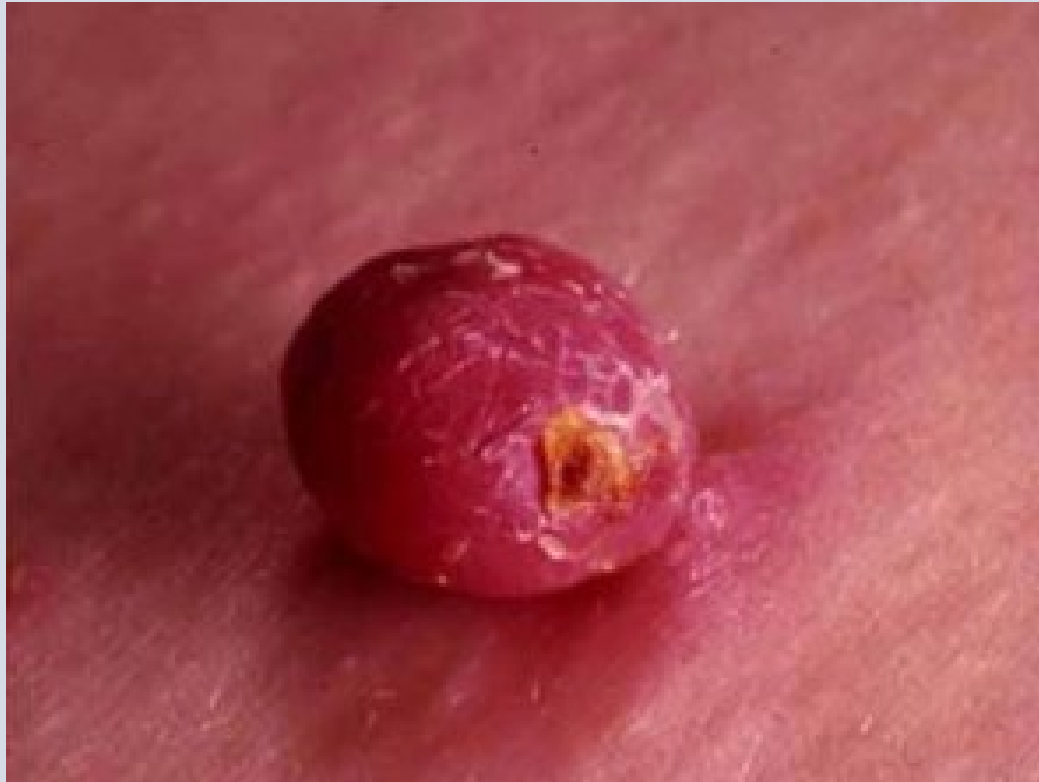- **Hemangioma senile**

- In older age on the trunk
- Dark red papulas with sharp borders (1 - 6 mm)
- Cosmetic problems
- Therapy:
  - Coagulation
  - Laser and cryotherapy



- **Pyogenic granuloma**

- A reactive vascular proliferation in response to trauma
- Characterized by red nodule, that is usually brittle with a bloody surface
- Therapy:
  - Chemical / electrical cauterization
  - Laser destruction



Thank you for your attention