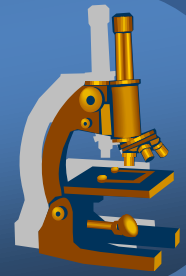
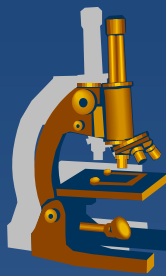


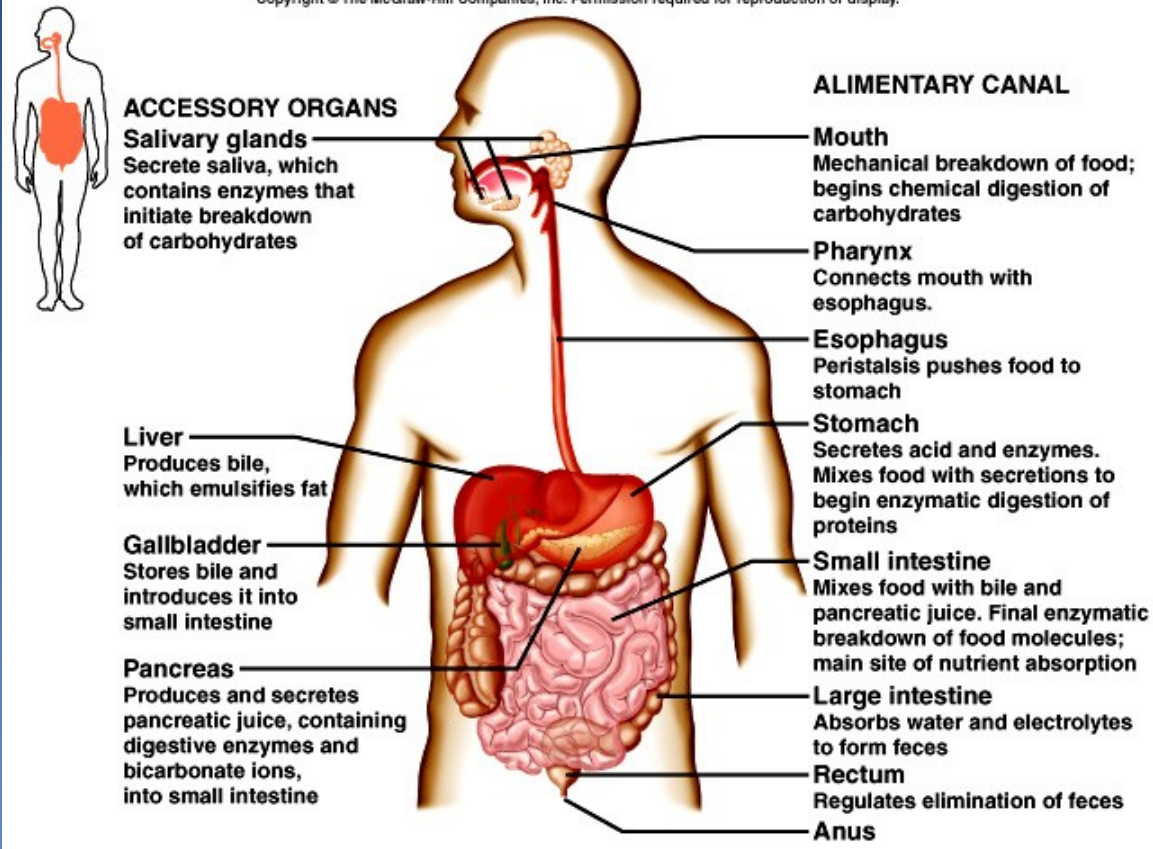
***Systematic pathology  
practice***

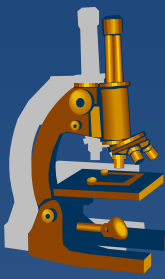


**GIT PATHOLOGY**



Copyright © The McGraw-Hill Companies, Inc. Permission required for reproduction or display.





---

# *ORAL CAVITY*

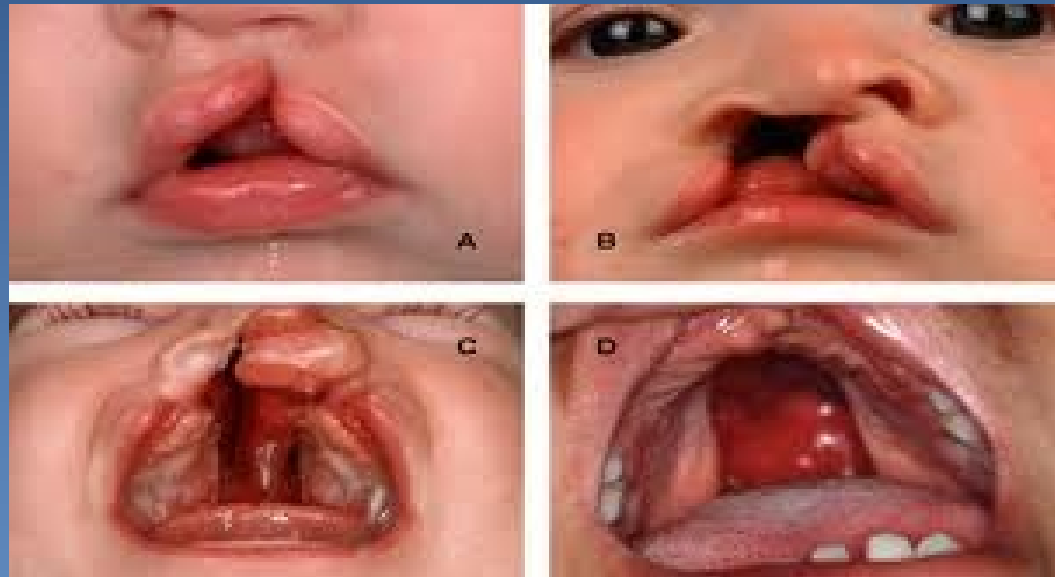# Congenital disorders: hare-lip and cleft palate



- ✗ incidence 1 : 950 newborns
- ✗ lateral cleft – isolated or complete
  - ⇒ *fusion defect* of the first branchial arch –maxilar process with fronto-nasal lateral process
  - genetic x acquired (environmental)
  - unilateral x bilateral
  
  - ⇒ *cheiloschisis (upper lip) – complete/incomplete*
  - ⇒ *gnathoschisis (jaw)*
  - ⇒ *palatoschisis (hard palate)*
  - ⇒ *uranoschisis (soft palate)*
  - ⇒ *staphyloschisis (uvula)*
- ✗ medial, oblique, transverse cleft (rare)



# *Cheilognathopalatoschisis*



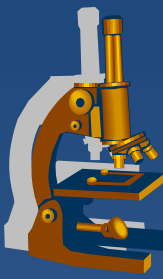
copy

# *Salivary glands*

---

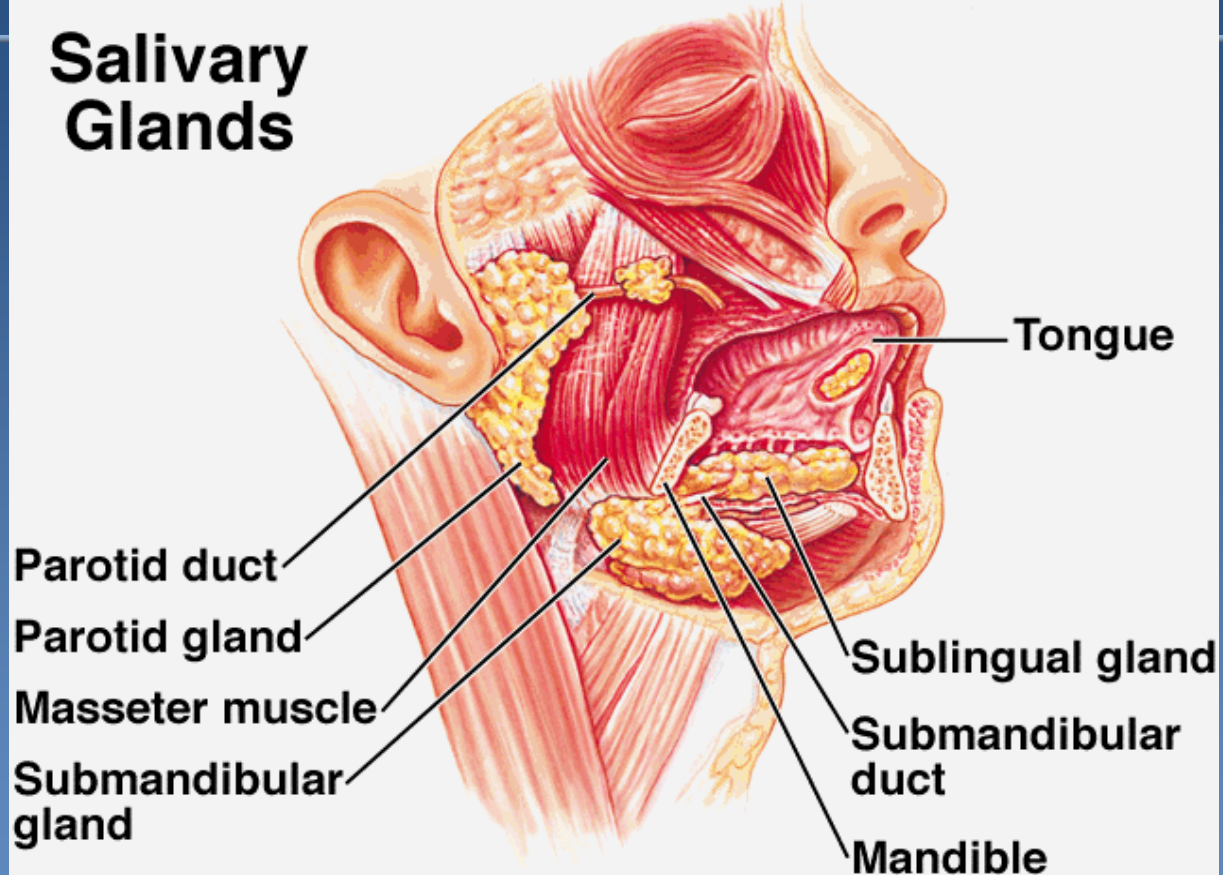


- x 3 pairs of large major salivary glands, numerous small ones
- x serous / mucinous
- x secretory units → glandular ducts
- x double cell layer – external myoepithelia
- x tumors mostly in the parotid gland, in adults usually epithelial tumors

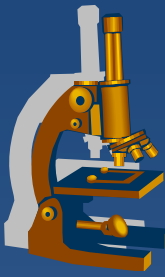


Copyright © The McGraw-Hill Companies, Inc. Permission required for reproduction or display.

# Salivary Glands



# *Salivary gland tumors*



- x parotid**

  - ⇒ *cca 75%, mostly benign (70-85%)*

- x submandibular**

  - ⇒ *40% malignant*

- x minor salivary glands**

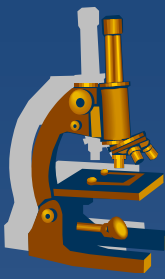
  - ⇒ *50% malignant*

- x sublingual**

  - ⇒ *mostly malignant*

# *Histologic types*

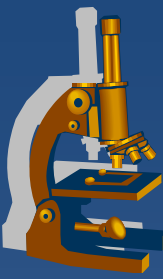
---



## Selected types

- x pleomorphic adenoma (benign mixed tumor)
- x adenolymphoma (Warthin tumor)
- x oncocytoma
- x mucoepidermoid carcinoma
- x adenoid cystic carcinoma
- x malignant mixed tumor

# ***Pleomorphic adenoma (mixed tumor of salivary glands)***



- ✘ former name „myxochondroepithelioma“
- ✘ benign epithelial tumor
- ✘ 80% in the parotid gland, most common parotid tu
- ✘ any age, mostly middle-late adult age
- ✘ slow-growing firm mass
- ✘ well-demarcated, but capsule incomplete
- ✘ frequent recurrences after incomplete resection
- ✘ low risk of malignant transformation (4%), in long duration, recurrences

# *Pleomorphic adenoma*



## **x** *micro:*

⇒ *histologic diversity*

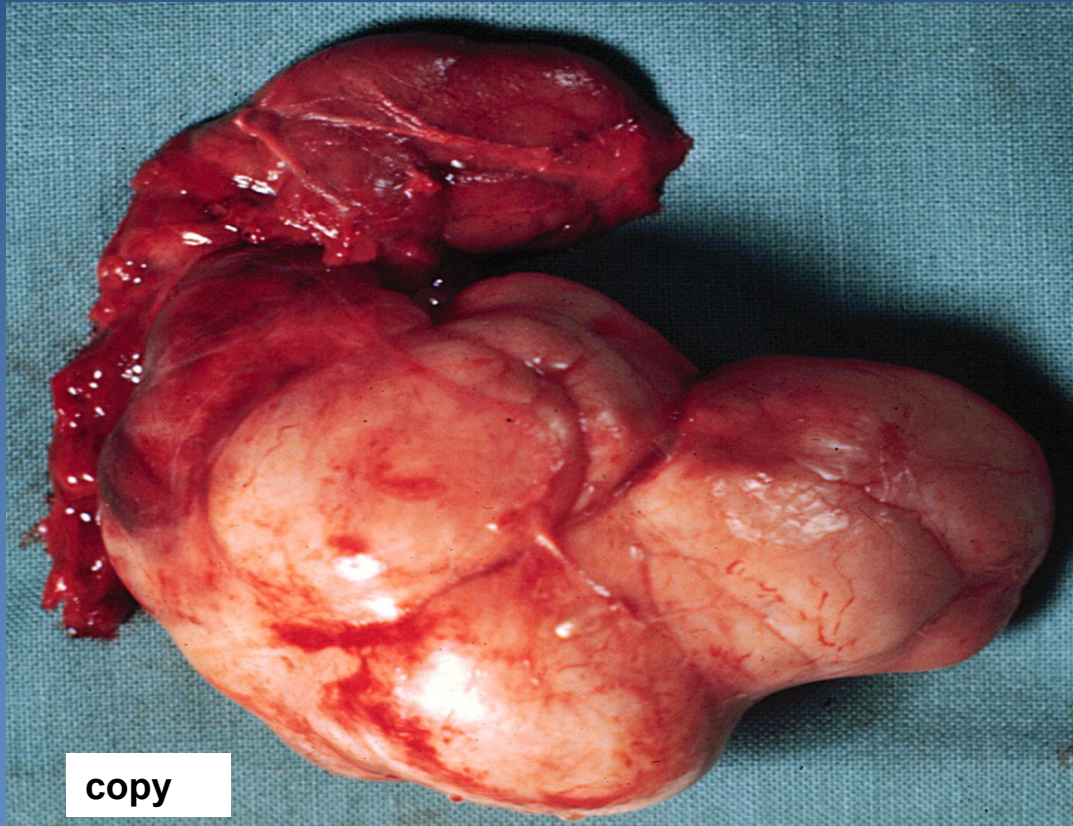
⇒ *ductal and myoepithelial tumor cells*

⇒ *epithelial elements in strands or sheets*

⇒ *myxoid to chondroid stroma produced by myoepithelia*

⇒ *often penetrates the capsule → protuberances*

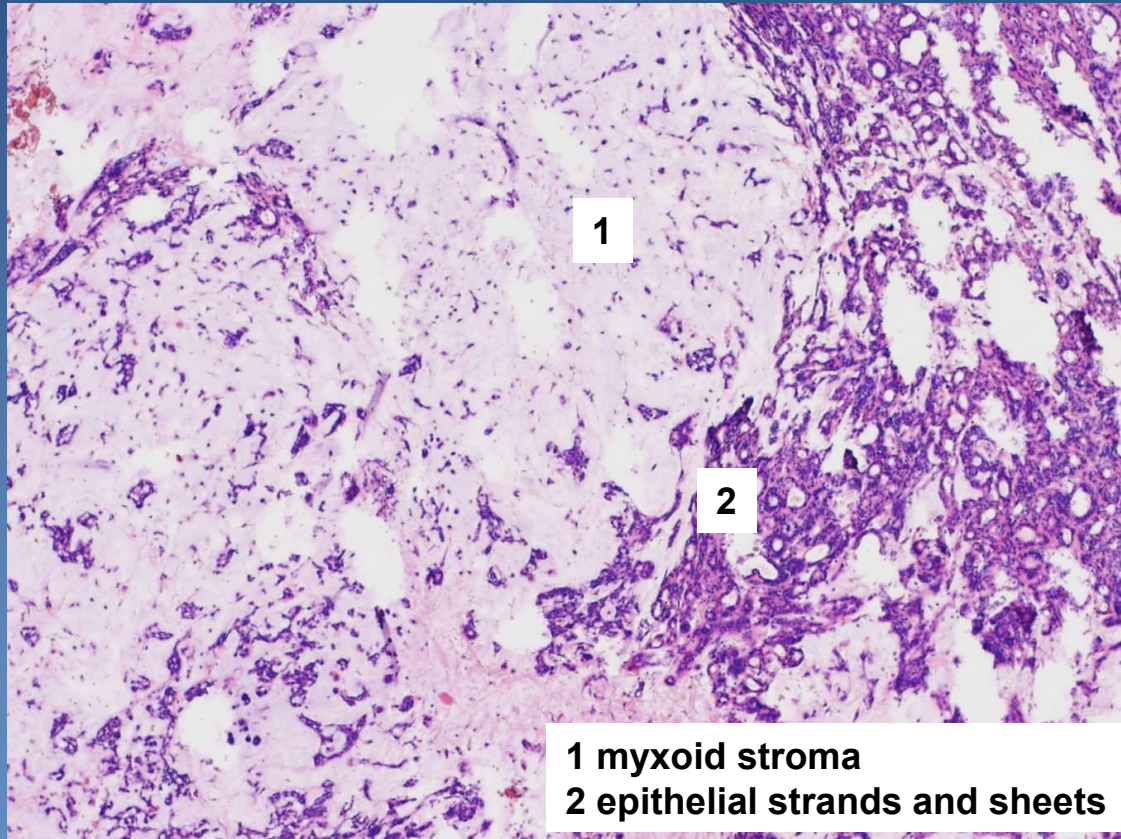
# *Pleomorphic adenoma*



copy



# *Pleomorphic adenoma*



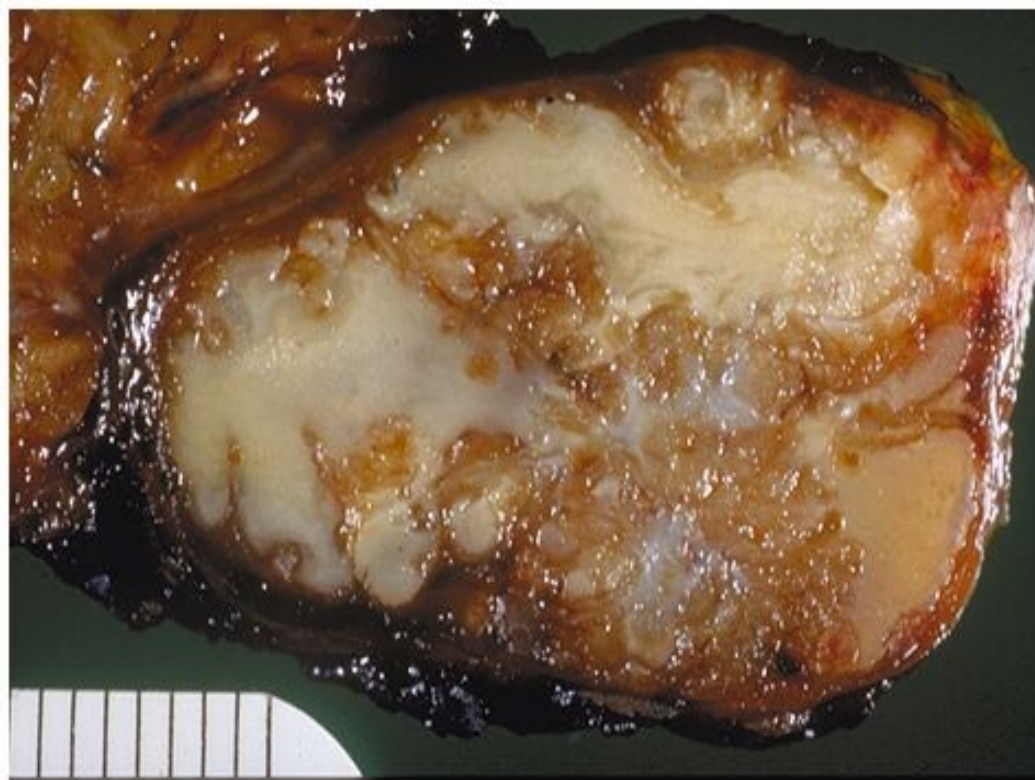**1 myxoid stroma**  
**2 epithelial strands and sheets**

# Warthin's tumor (cystadenolymphoma)



- × 5-10% of total salivary gland tumors, benign
- × M > F, 6th-7th decade
- × lower pole of the parotid gland
- × low recurrence rate, malignant transformation (ca, malignant lymphoma) highly uncommon
- × risk factors:
  - ⇒ *smoking (8x), radiation, EBV*
- × origin? (heterotopic salivary tissue in a LN; reactive epithelial proliferation + lymphocytic infiltration)
- × histology:
  - ⇒ *cystic or cleftlike spaces with double-layered epithelial lining, dense lymphoid stroma (usually + germinal centers)*

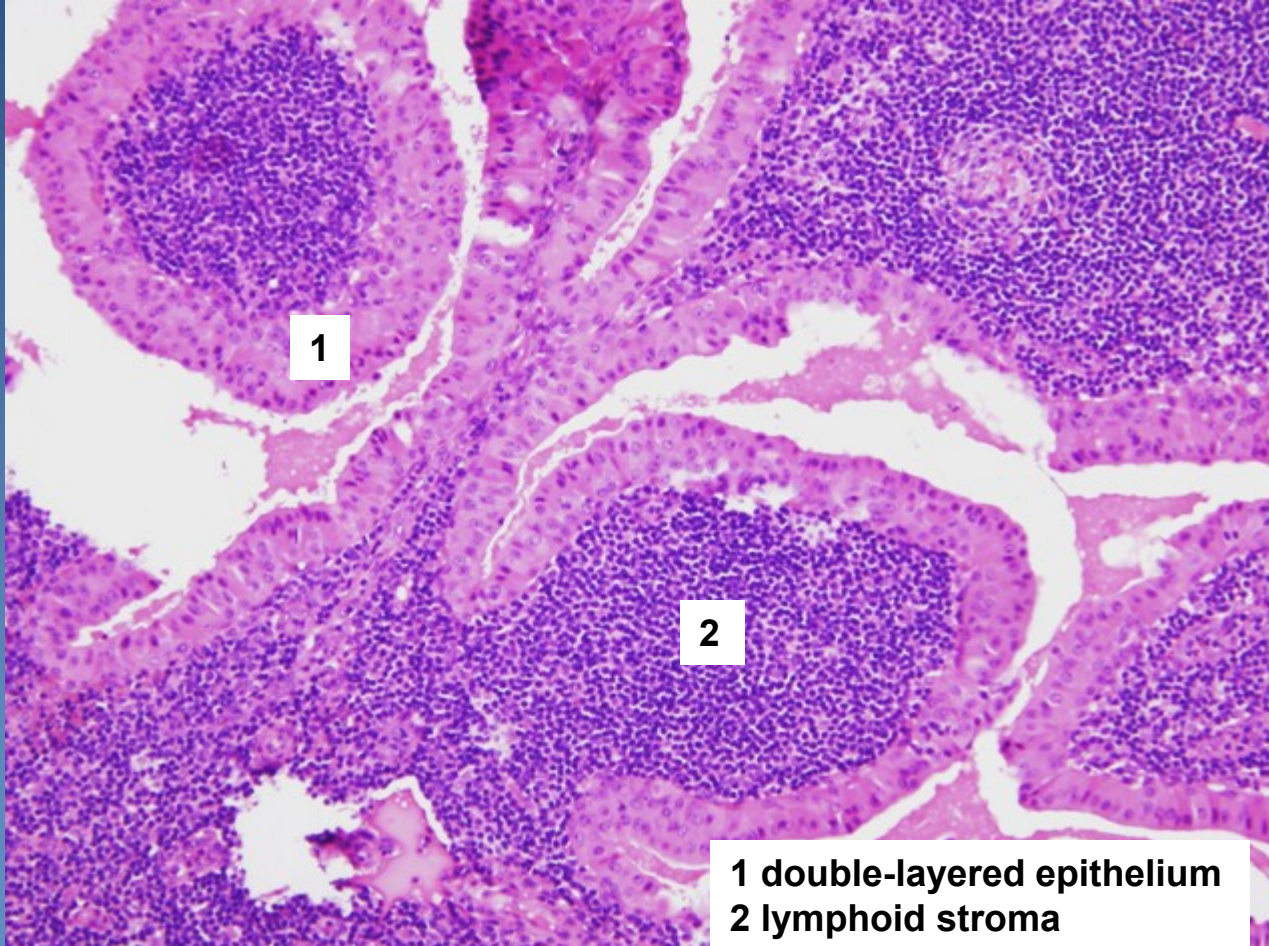
# *Warthin's tumor (cystadenolymphoma)*



Copyright © 2002, Elsevier Science (USA). All rights reserved.



# *Warthin's tumor (cystadenolymphoma)*



1 double-layered epithelium  
2 lymphoid stroma

# *Tonsillitis chronica*



- ✗ recurrent chronic inflammation
- ✗ acute exacerbations - enlarged, red, swollen painful tonsils
- ✗ gross:
  - ⇒ *mostly purulent exudate with necrotic epithelial cells and bacteria in crypts forming semi-firm foul-smelling debris*
  - ⇒ *pseudomembranous tonsillitis (diff. dg. x EBV)*

# Tonsillitis chronica



## × complications: local, distant

⇒ *phlegmonous acute tonsillitis (necrosis and ulceration, penetration of bacteria into the interstitium → inflammation may progress into retrotonsillar stroma)*

⇒ *abscessi (tonsillar, peritonsillar, retropharyngeal) + spread*

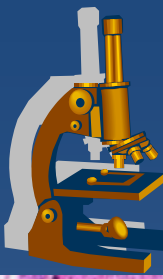
⇒ *distant – rheumatic fever, glomerulonephritis*

## × micro:

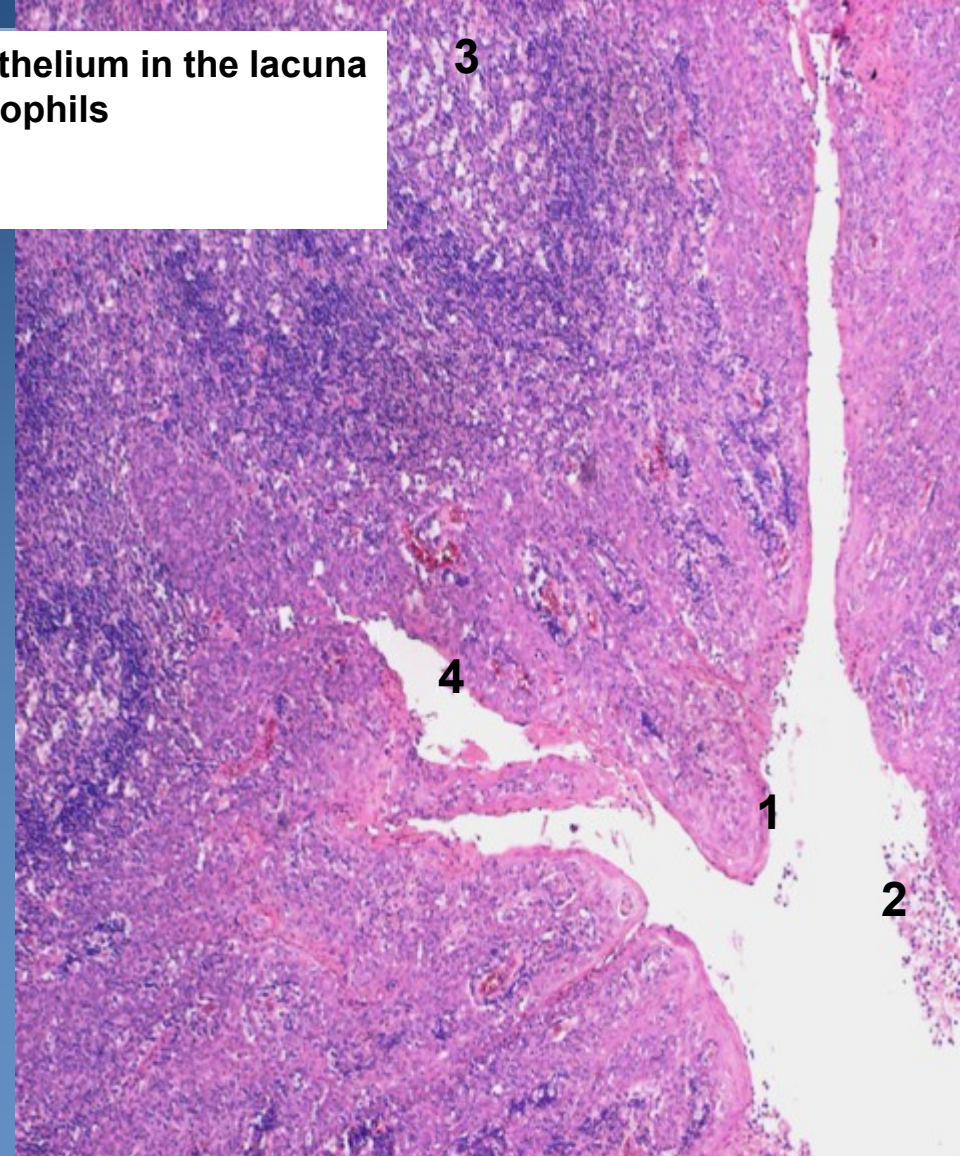
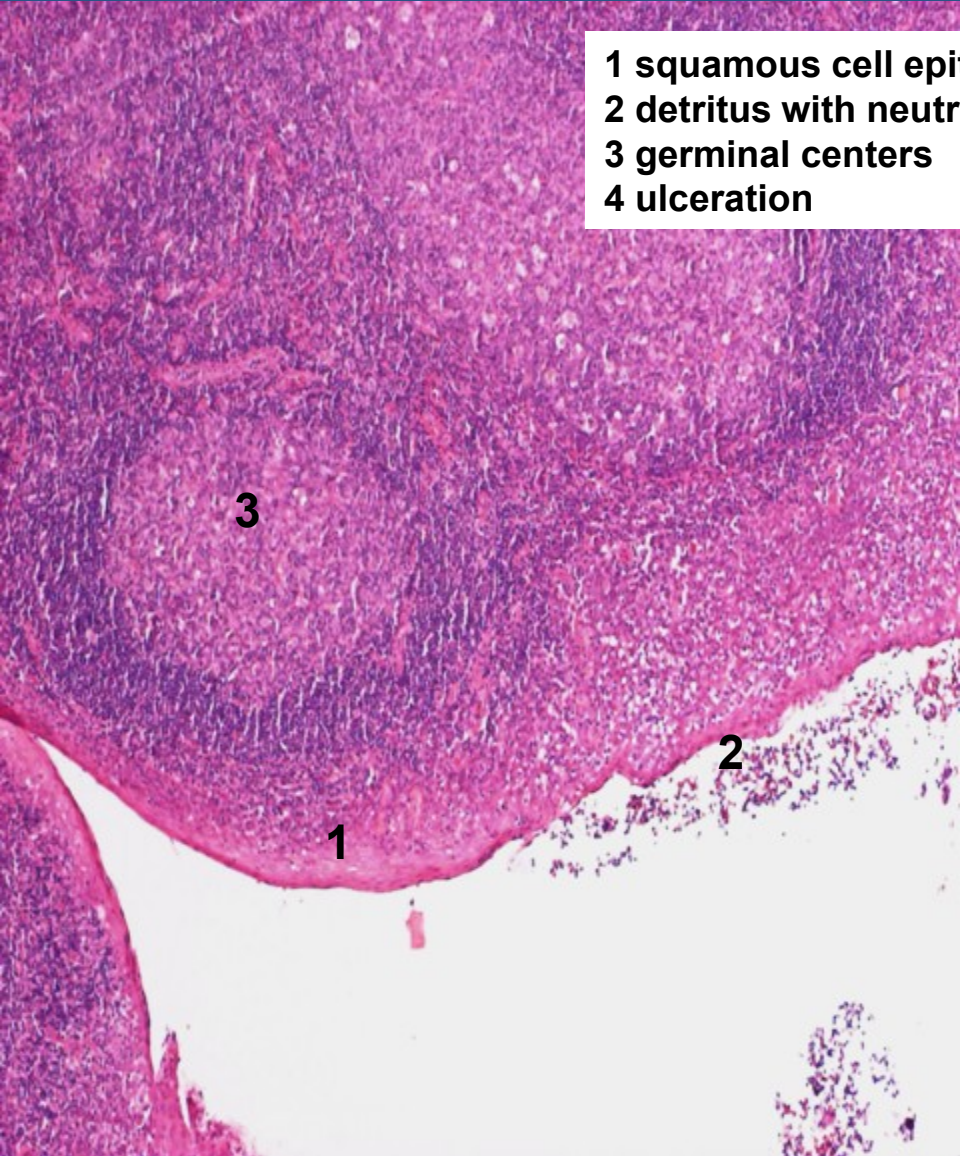
⇒ *reactive hyperplasia of lymphoid tissue, lacunae filled with neutrophils, debris and bacteria, local fibrotisation*



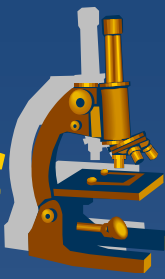
# ***Tonsilla palatina*** ***chronic purulent inflammation***



- 1 squamous cell epithelium in the lacuna
- 2 detritus with neutrophils
- 3 germinal centers
- 4 ulceration



# *Precanceroses and tumors*



- ✗ mostly epithelial, less commonly mesenchymal lesions

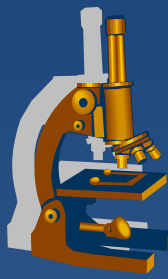
- ✗ sequence

  - ⇒ *normal tissue – hyperplasia – dysplasia – CIS – invasive carcinoma*

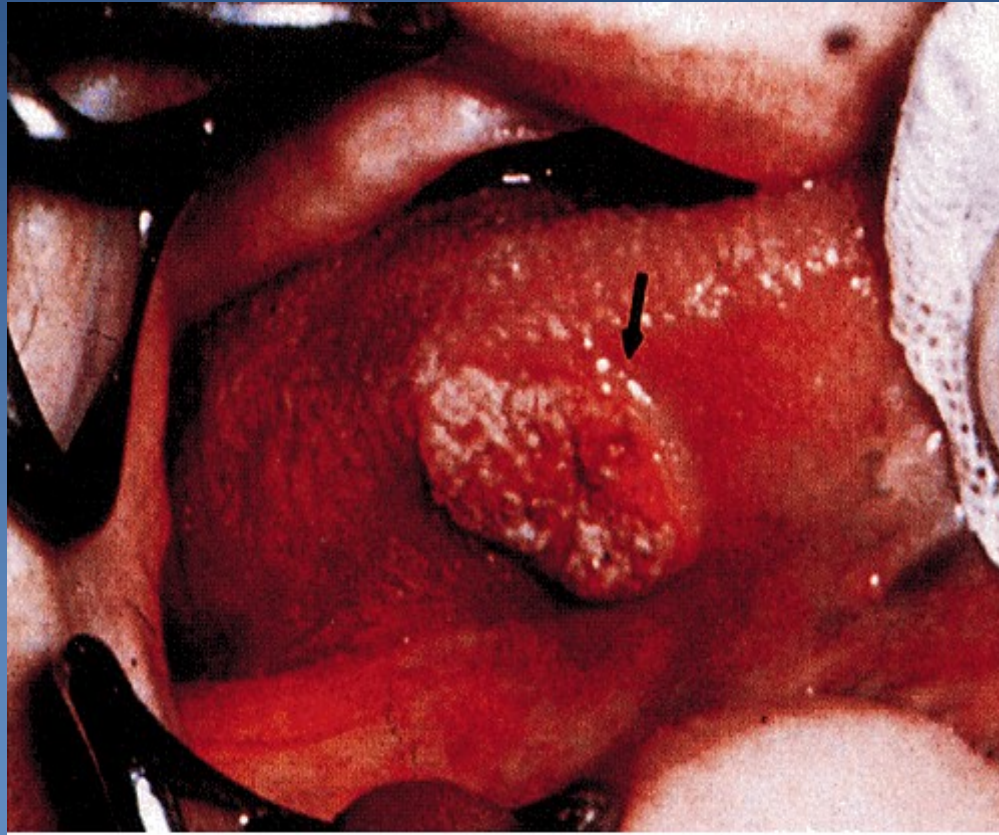
- ✗ risk factors

  - ⇒ *smoking, alcohol, their combination; irradiation, HPV, betel, other chronic irritation*





# ***Squamous cell carcinoma***



***elevated/ulcerated firm lesion***

# Esophageal diverticula



- × **diverticulum** – an acquired outpouching of the esophageal wall involving all the layers of the wall (true diverticulum)
- × Zenker's diverticulum (pharyngoesophageal) - *most common type, located on the posterior wall in the pharyngoesophageal junction, weakening of m. constrictor pharyngis, developed by pulsion (forcible distension of the esophagus) → pulsion diverticulum*
- × Midthoracic diverticulum - *in the mid-chest; developed by traction (external forces pulling on the wall - inflammation with scarring e.g.) → traction diverticulum*
- × Epiphrenic diverticula - *above the diaphragm*
- × Signs: *dysphagia, regurgitation, foetor ex ore*
- × Complications: *putrid inflammation, ulceration, perforation into mediastinum*

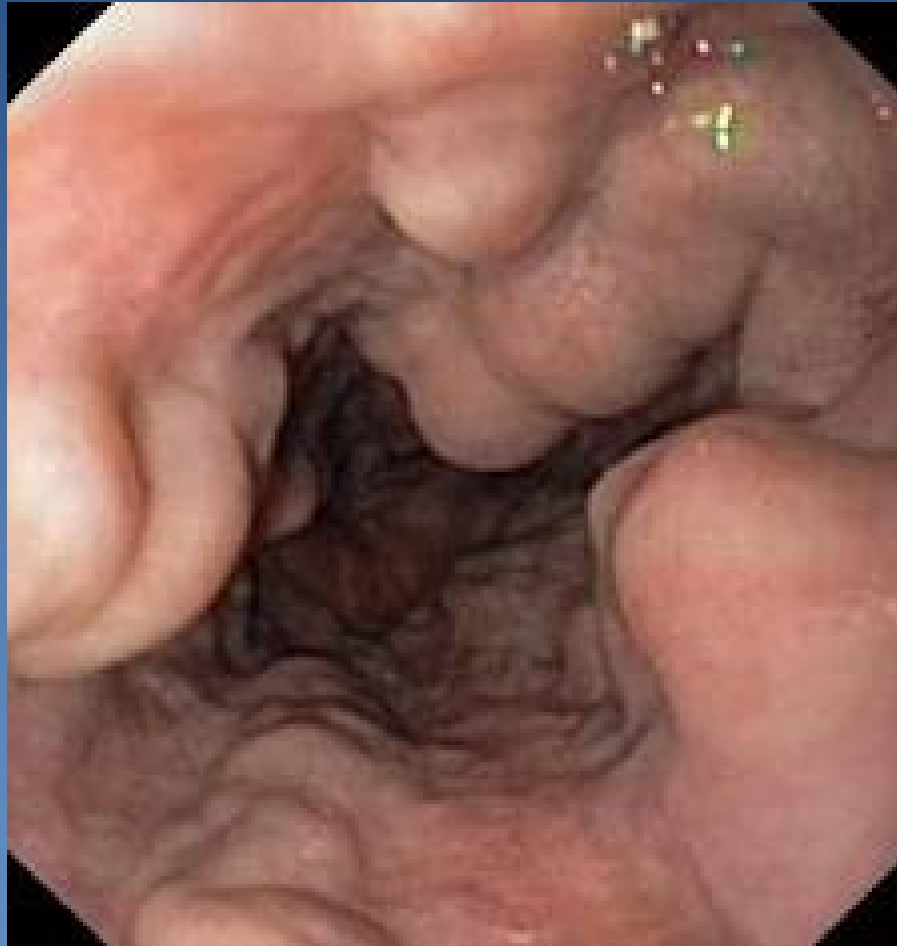# *Esophageal varices*



- x congested and dilated submucosal veins in the distal third of the esophagus
- x in portal hypertension
- x porto-caval anastomoses
- x complications - *rupture with massive hemorrhage into the lumen, haematemesis, haemorrhagic shock*

# *Esophageal varices*

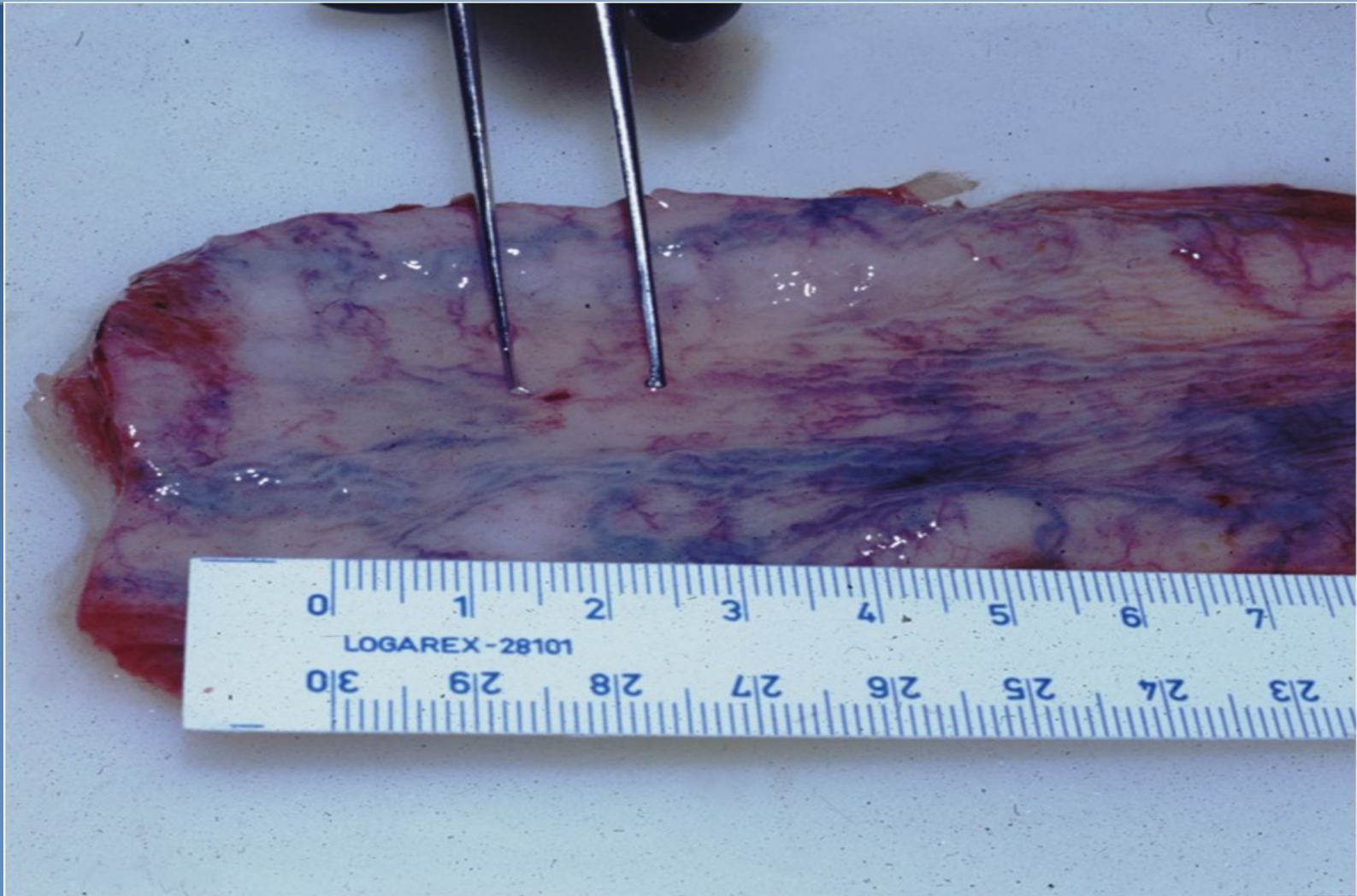
## *- endoscopy*



copy

# *Esophageal varices*

## *gross*

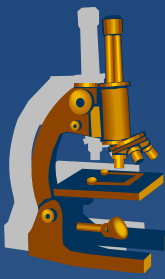


# ***Mycotic oesophagitis***



- x candida, aspergillus, mucor, cryptococcus**
- x superficial form** *low-level immunodeficiency, patients on broad-spectrum ATB or corticosteroids therapy, diabetics, pregnancy...*
- x generalised form + secondary deep mycotic infections** – *high-grade immunodeficiency - AIDS, neoplasia (haemathologic), immunosuppression, debilitated patients*

# *Mycotic oesophagitis*



- ✘ gross:

- ⇒ *white to gray pseudomembranes with hemorrhagic bases after removal*

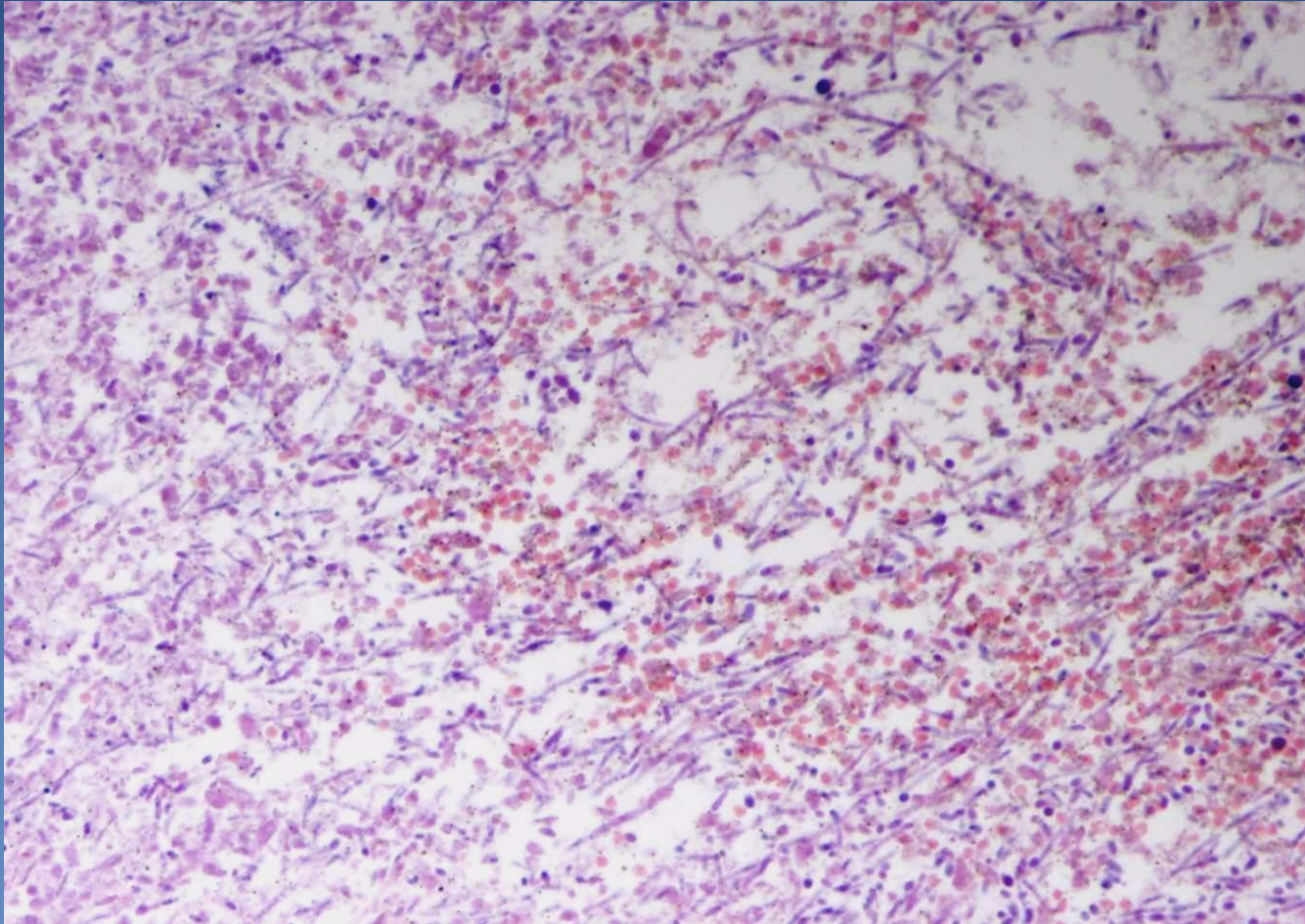
- ✘ micro:

- ⇒ *necrotic mucosa with mixed inflammatory infiltrate, numerous fungal organisms (pseudo/hyphae, yeasts)*

- ✘ special impregnation/staining for detection of the fungi (Groccott, PAS, Giemsa)

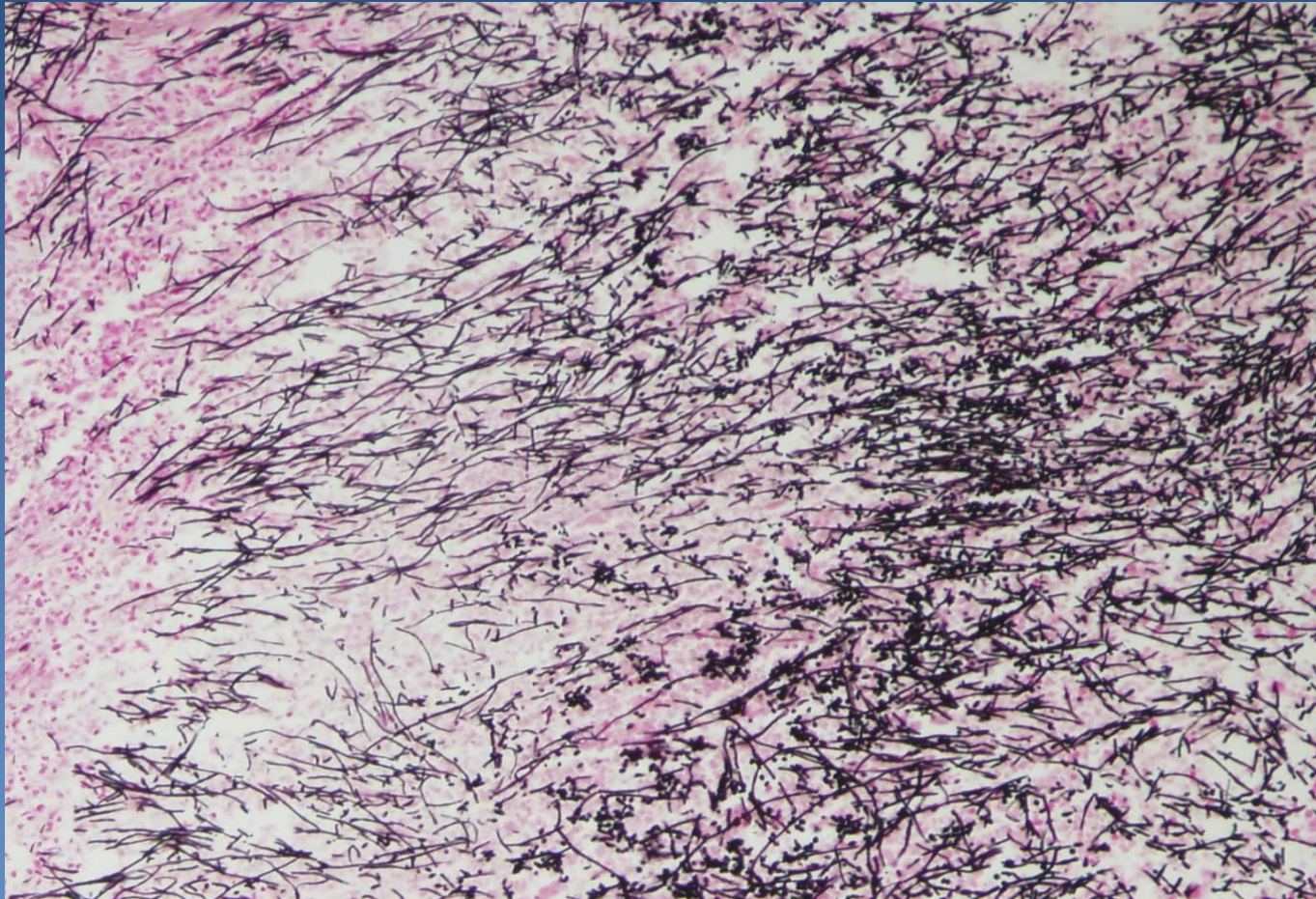


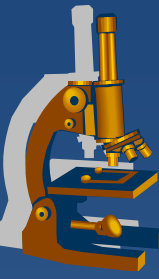
# ***Mycotic oesophagitis***



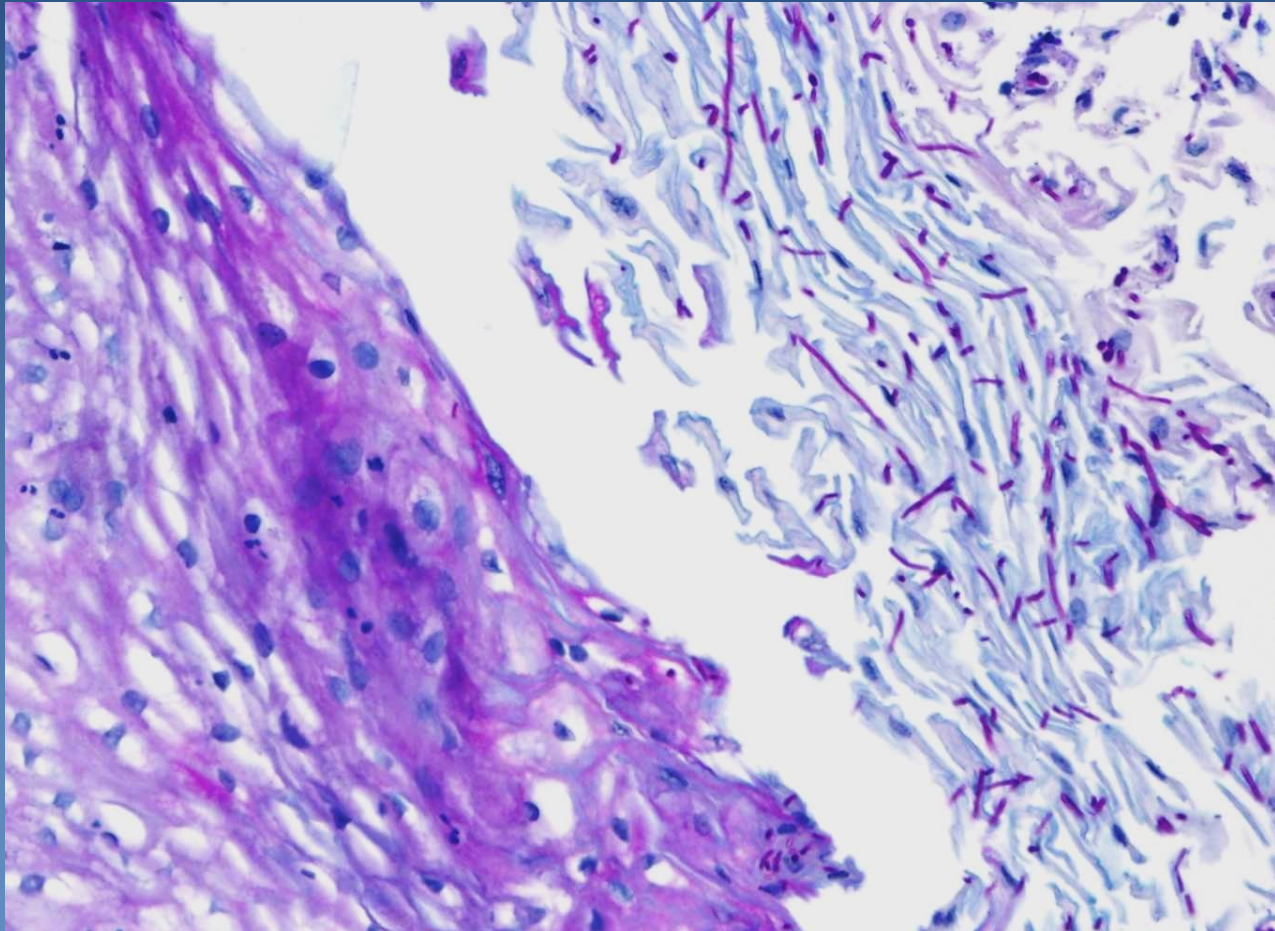


# ***Mycotic oesophagitis*** ***(Groccott silver impregnation)***

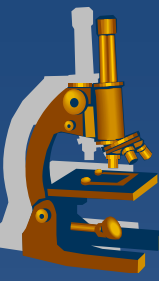




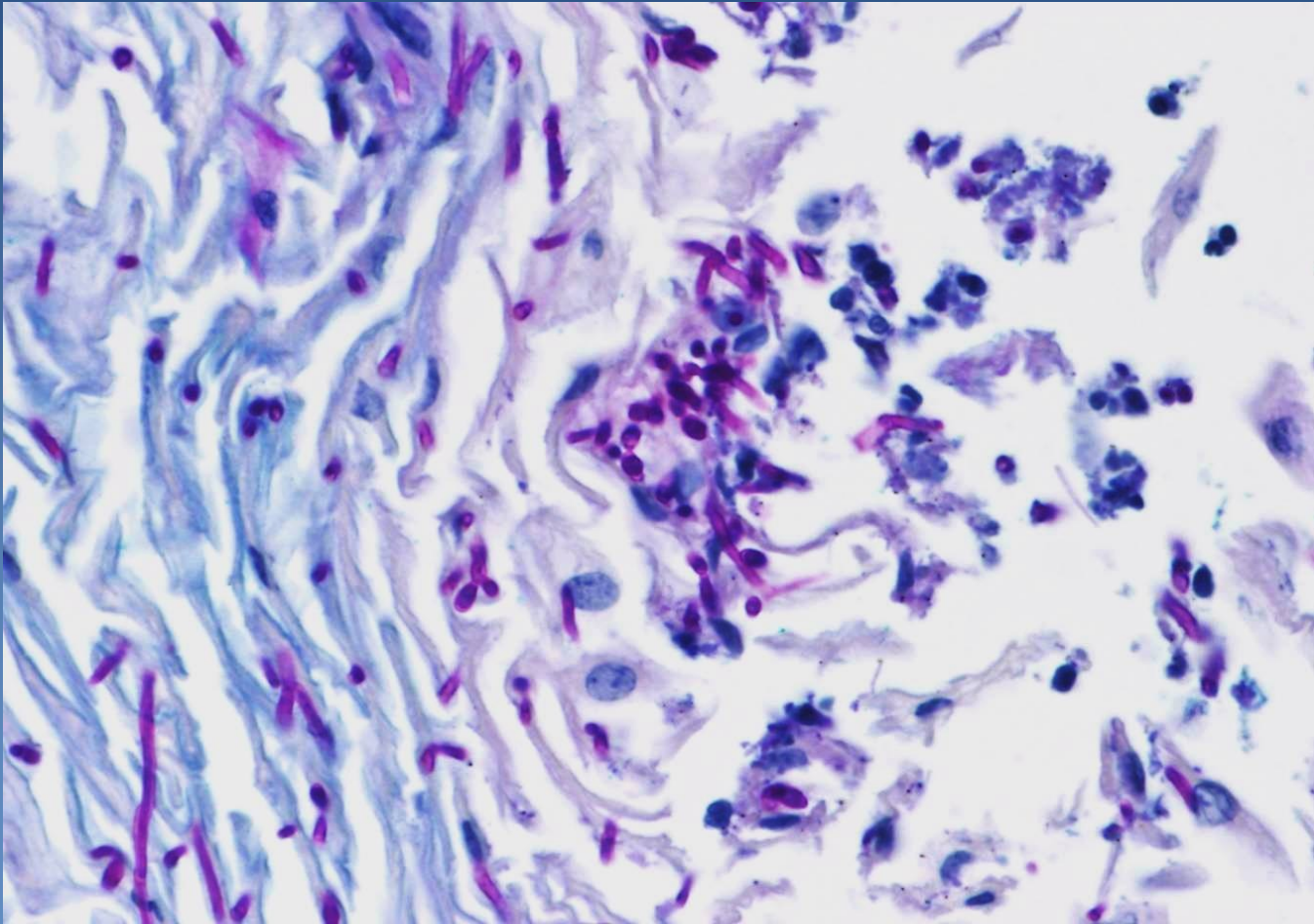
# ***Mycotic oesophagitis - detail*** ***(PAS staining)***







# ***Mycotic oesophagitis - detail*** ***(PAS staining)***



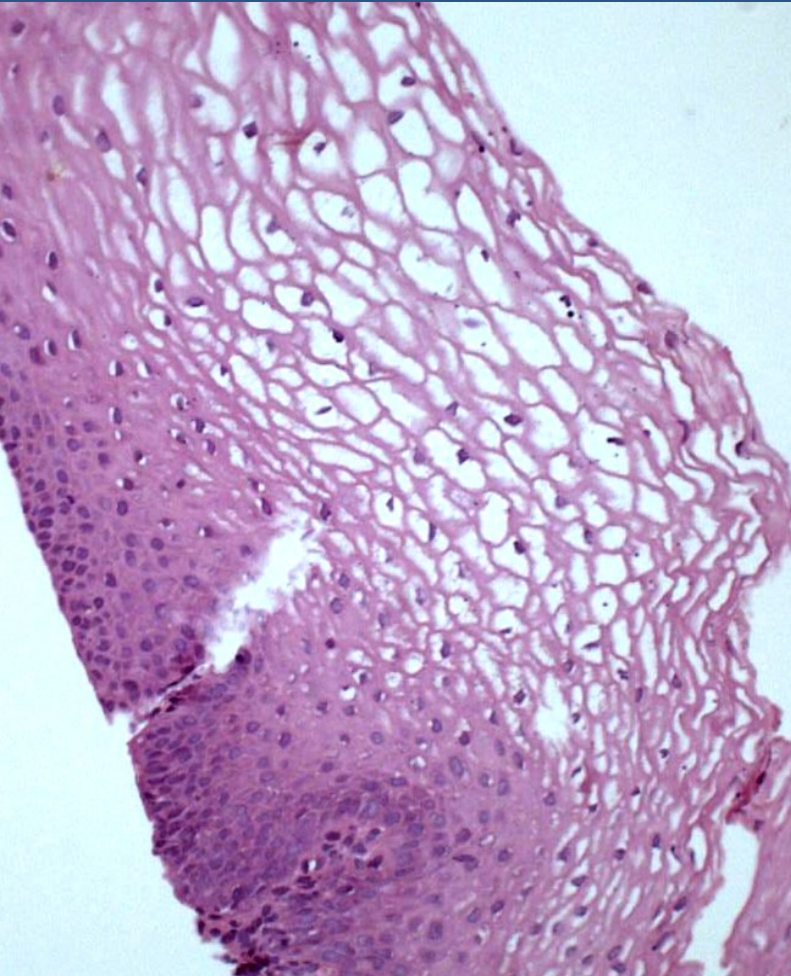
# Reflux oesophagitis



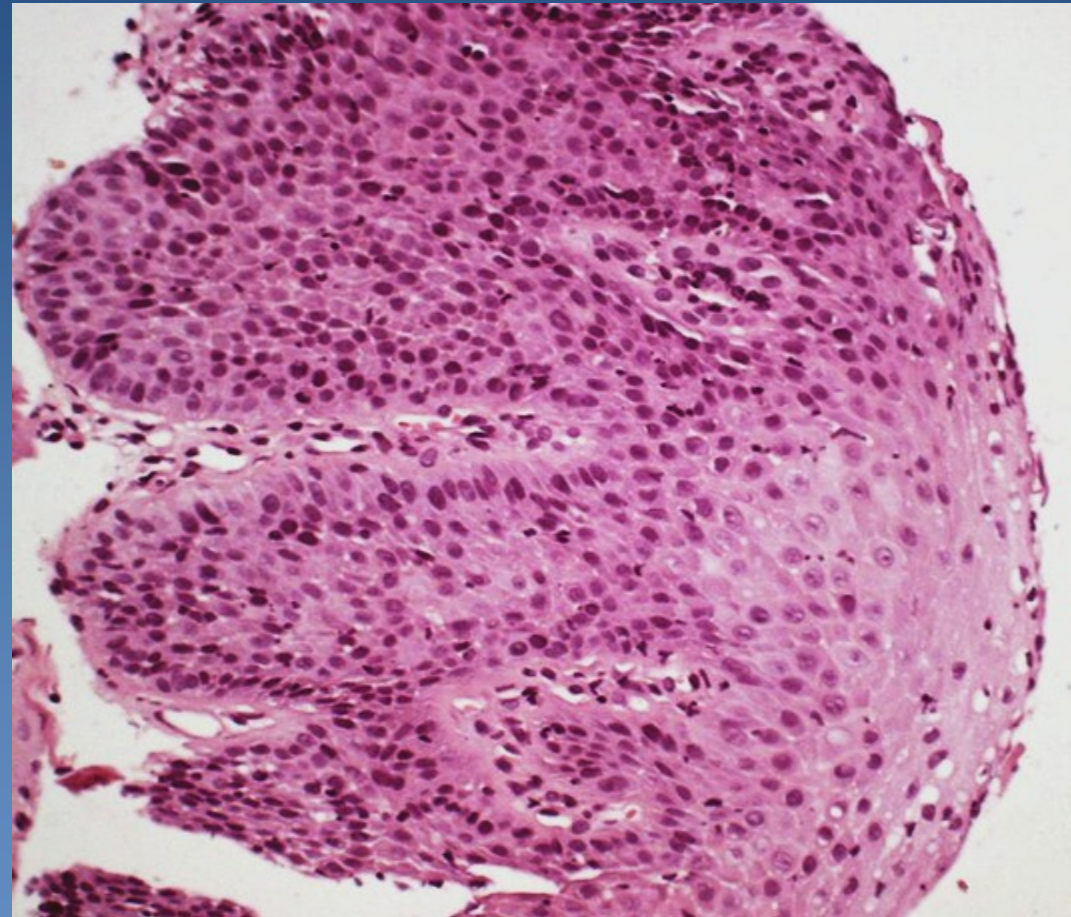
- × chemically caused inflammation in gastro-oesophageal reflux disease (sq. epithelium sensitive to acids)
- × signs x pathology – low correlation
  - ⇒ *heartburn, dysphagia*
- × gross:
  - ⇒ *mucosal hyperemia, epithelial erosions, ulcerations, scarring, stenosis*
- × micro:
  - ⇒ *3 reactive alterations of the squamous cell epithelium: basal zone hyperplasia, elongation of lamina propria papillae, inflammatory infiltrate with eosinophils.*
- × complication: Barrett's oesopagus (predisposition to malignancy)!



# Reflux oesophagitis



**Regular oesophageal epithelium**



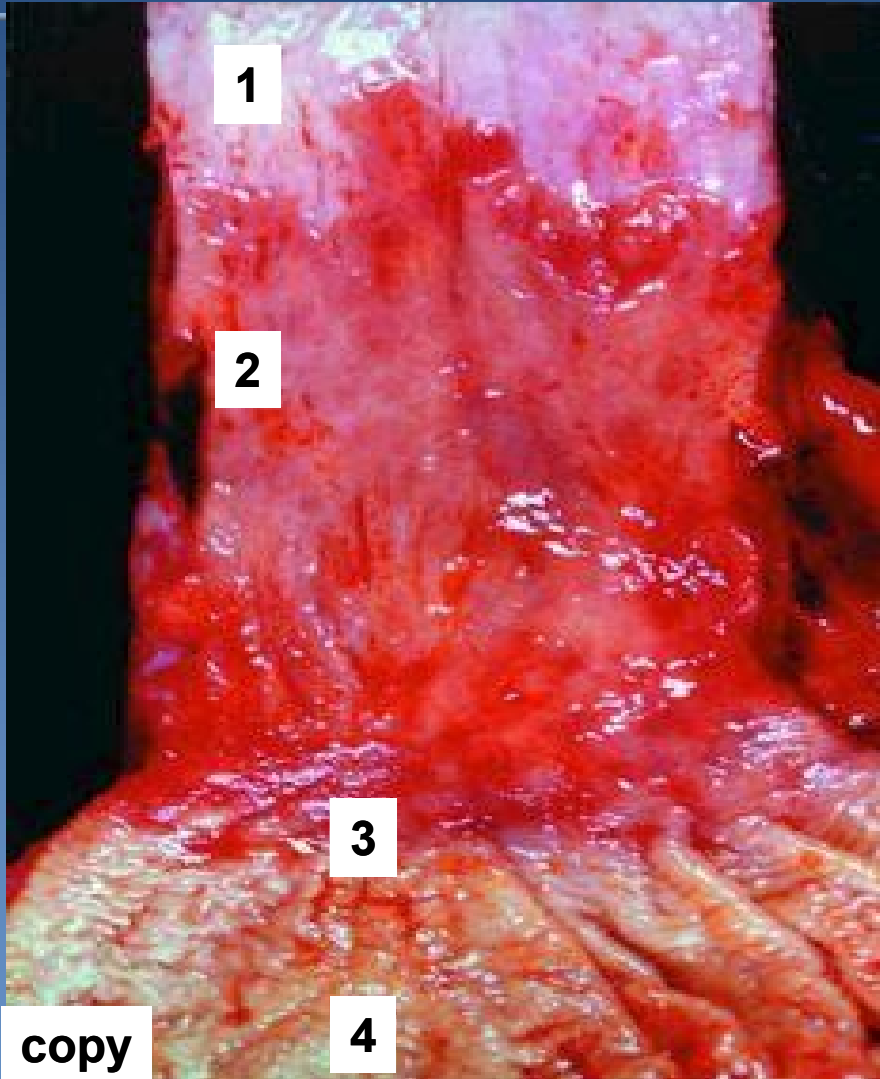
**Reflux oesophagitis:** basal zone hyperplasia (>20%), elongation of lamina propria papillae (into the superficial 1/3)

# *Barrett's oesophagus*



- ✘ complication of reflux oesophagitis
- ✘ risk for the development of adenocarcinoma!
- ✘ replacement of the normal squamous cell epithelium by columnar epithelium with goblet cells (= intestinal metaplasia) → risk of dysplasia
- ✘ → oesophageal adenocarcinoma (so-called Barrett's carcinoma)

# Barrett's oesophagus



1 regular oesophageal mucosa

2 metaplasia

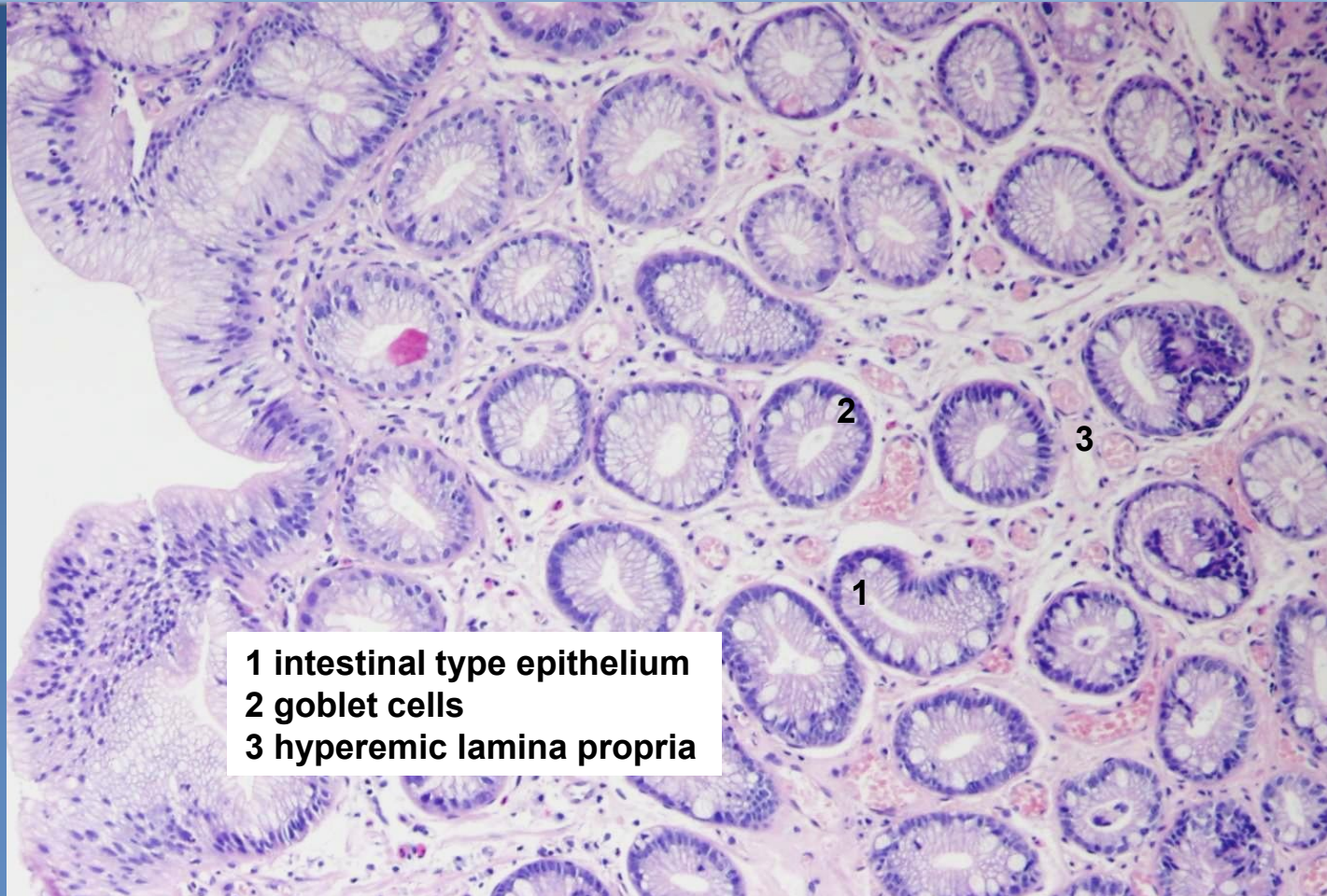3 gastro-oesophageal junction

4 cardia

copy



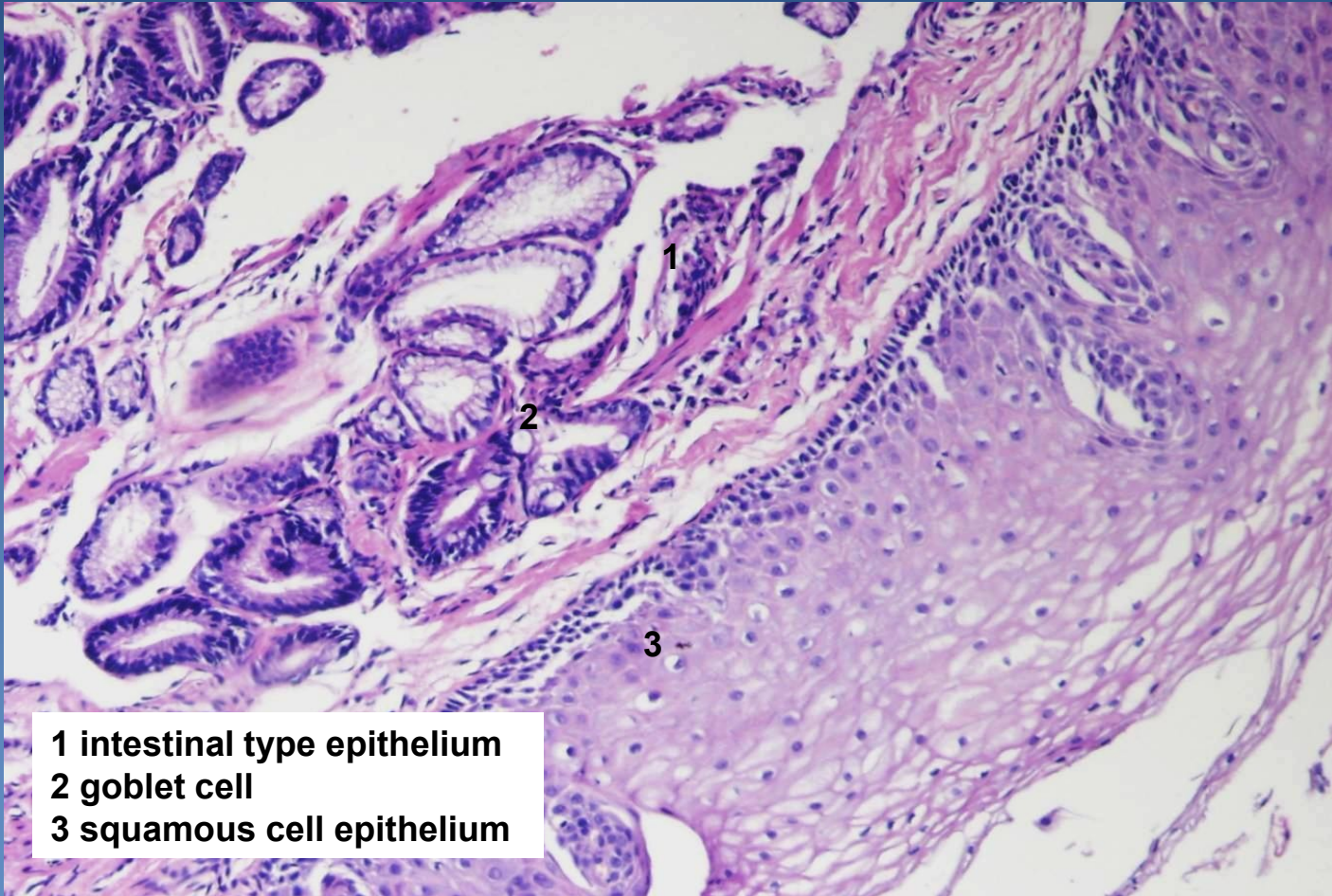
# *Barrett's oesophagus*



- 1 intestinal type epithelium
- 2 goblet cells
- 3 hyperemic lamina propria



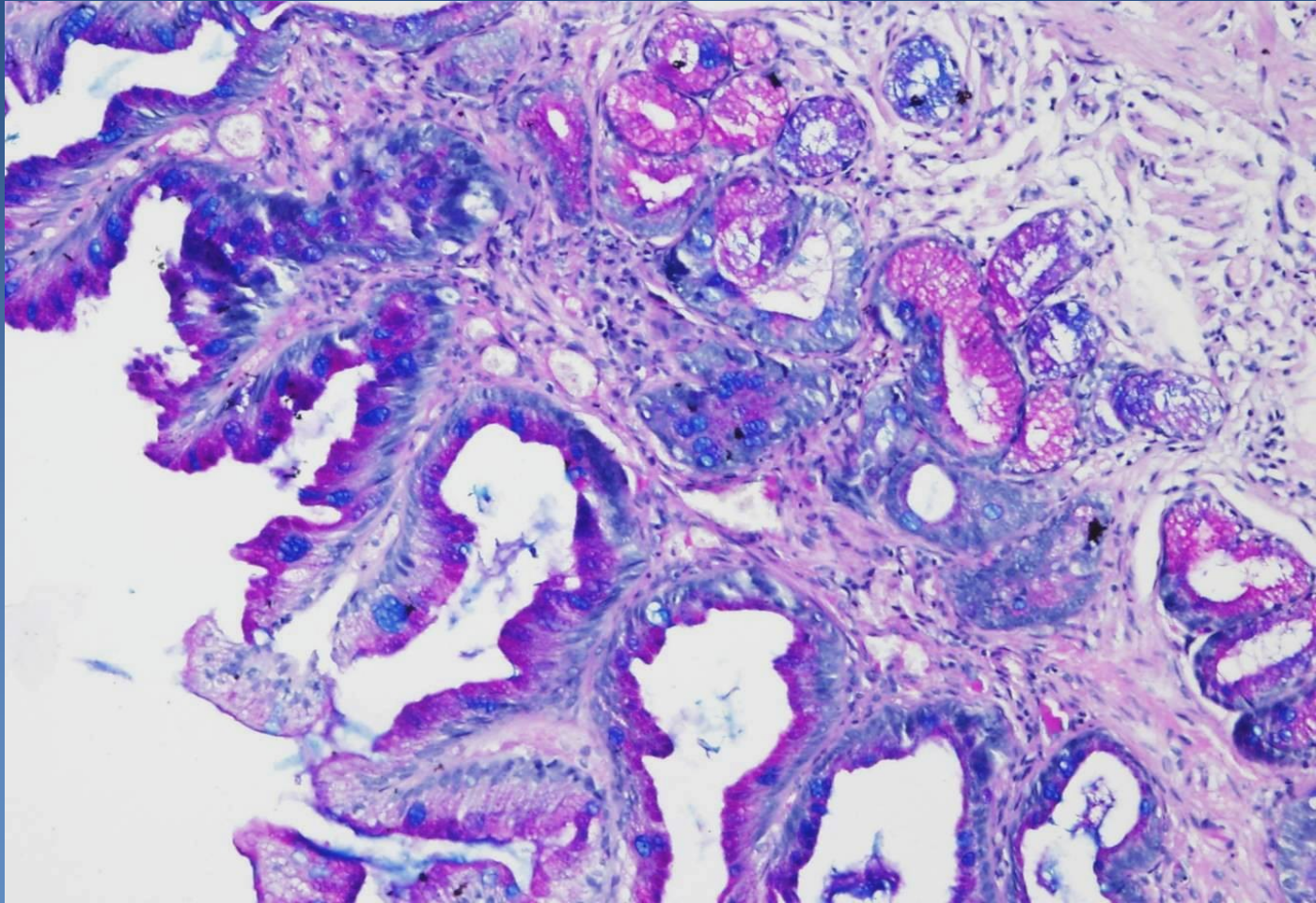
# *Barrett's oesophagus*



- 1 intestinal type epithelium**
- 2 goblet cell**
- 3 squamous cell epithelium**

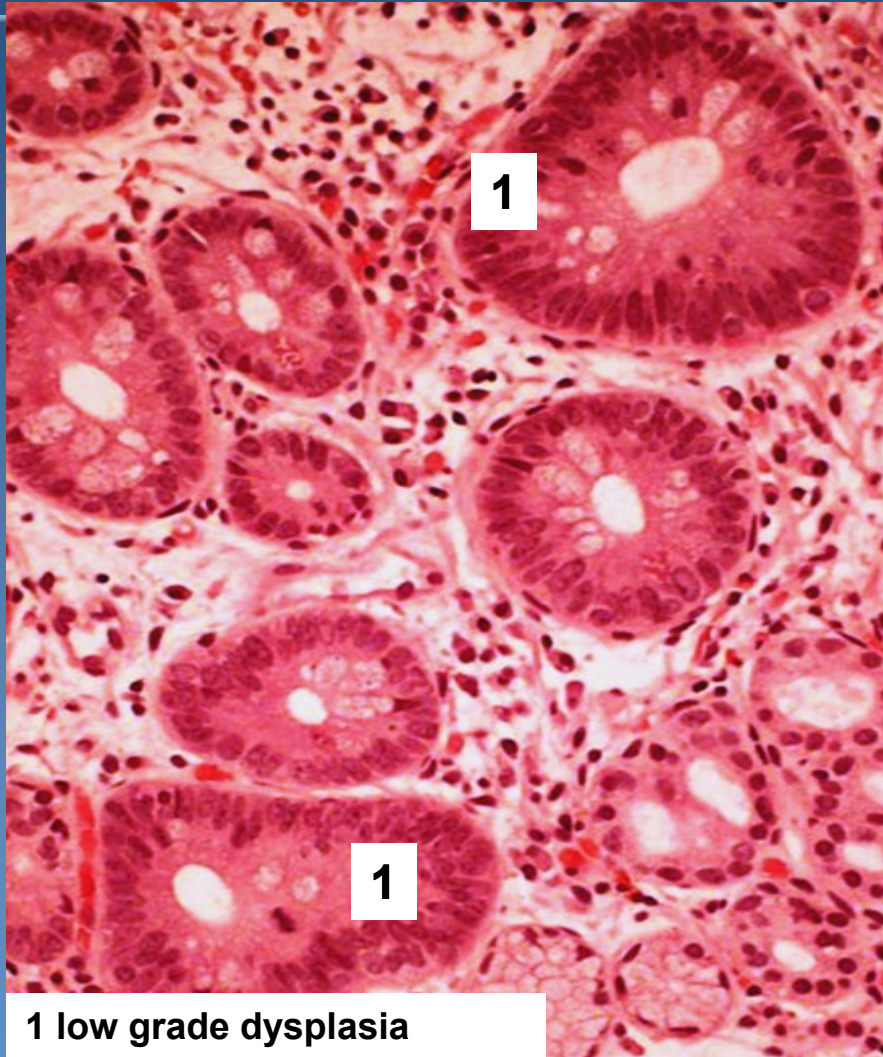
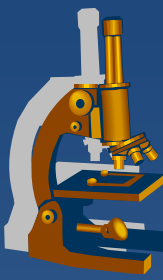
# ***Barrett's oesophagus***

***PAS ALC staining – blue goblet cells***

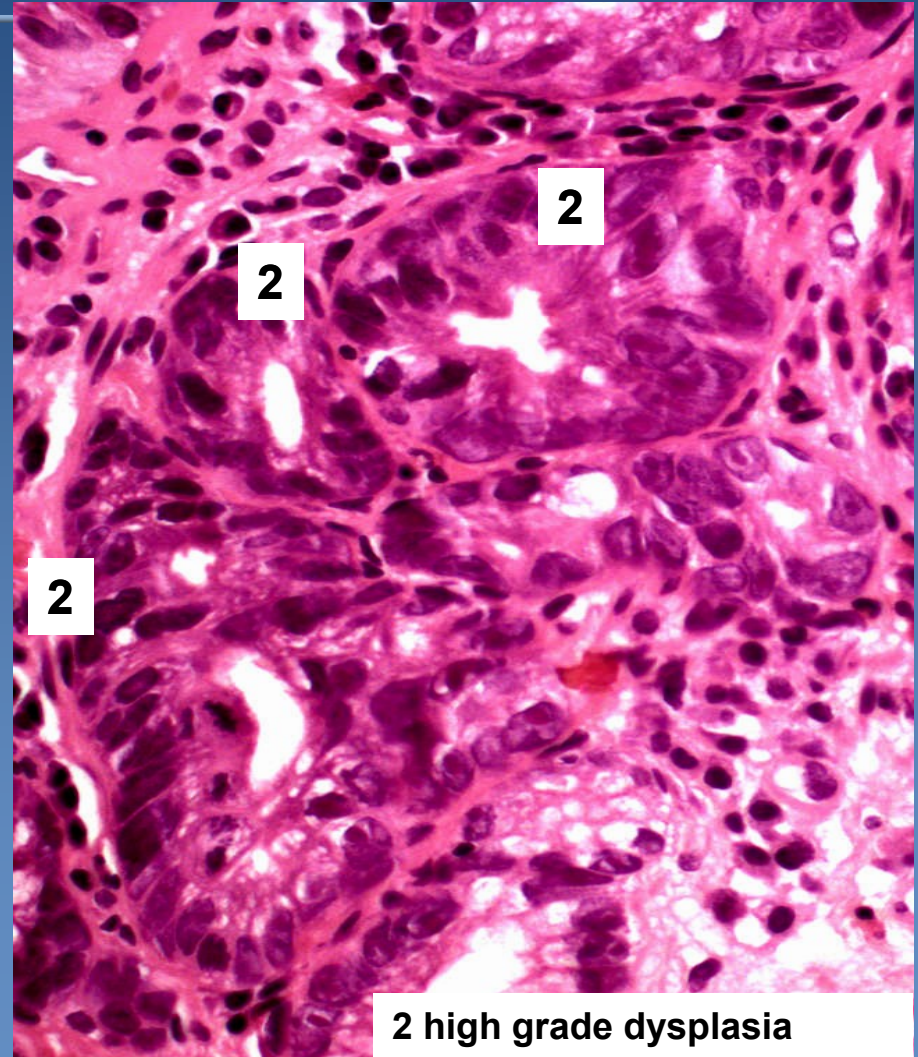




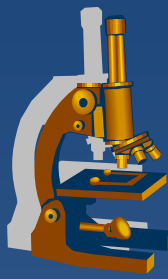
# *Barrett's oesophagus - dysplastic epithelium*



1 low grade dysplasia



2 high grade dysplasia



# *Squamous cell carcinoma of the oesophagus*

---

- ✗ usually in the mid-third of the esophagus
- ✗ M>F, >45 yrs of age
- ✗ Risk factors:
  - ⇒ *carcinogenic substances in food (aflatoxin, nitrosamines), tobacco, alcohol, HPV, very hot beverages, chronic inflammation*
- ✗ Symptoms:
  - ⇒ *dysphagia, weight loss, cachexia*

# ***Squamous cell carcinoma of the oesophagus***

---



**x gross:**

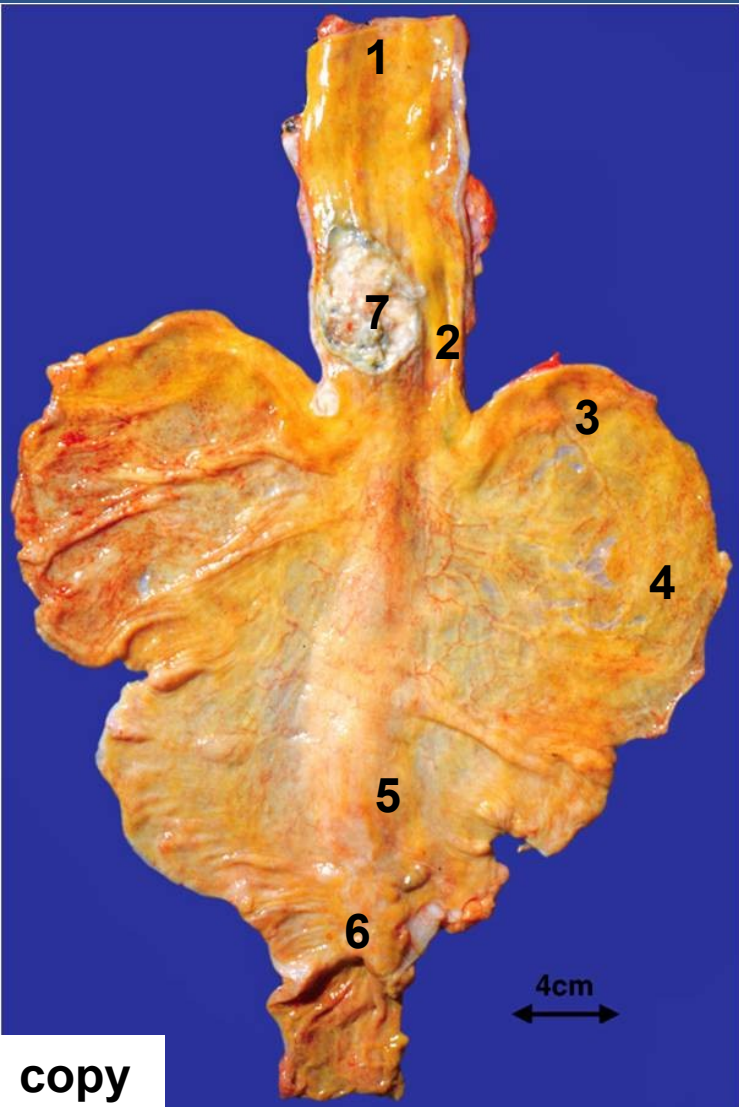
⇒ *polypoid exophytic mass, ulcerative or diffuse infiltrative neoplasm*

**x bad prognosis:**

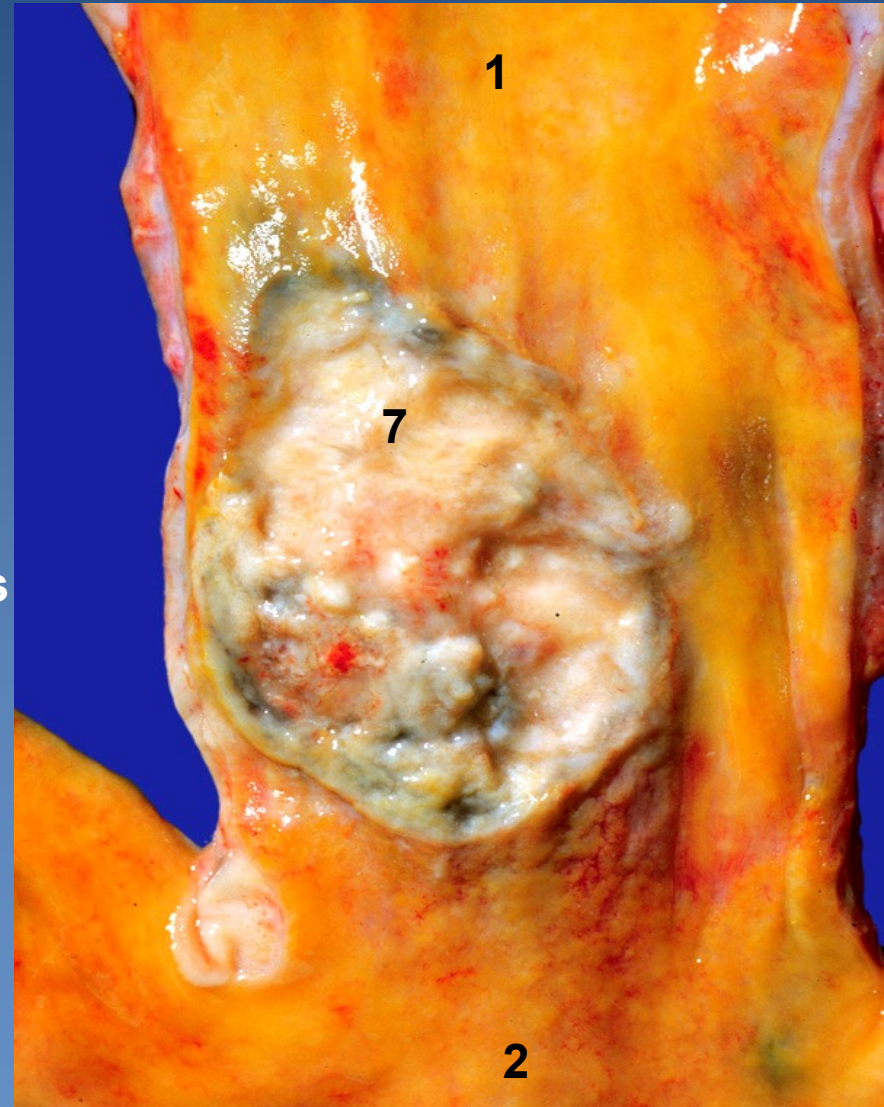
⇒ *tendency to spread through submucosal lymph vessels → distant satellite tumor foci*



# *Squamous cell carcinoma of the oesophagus*



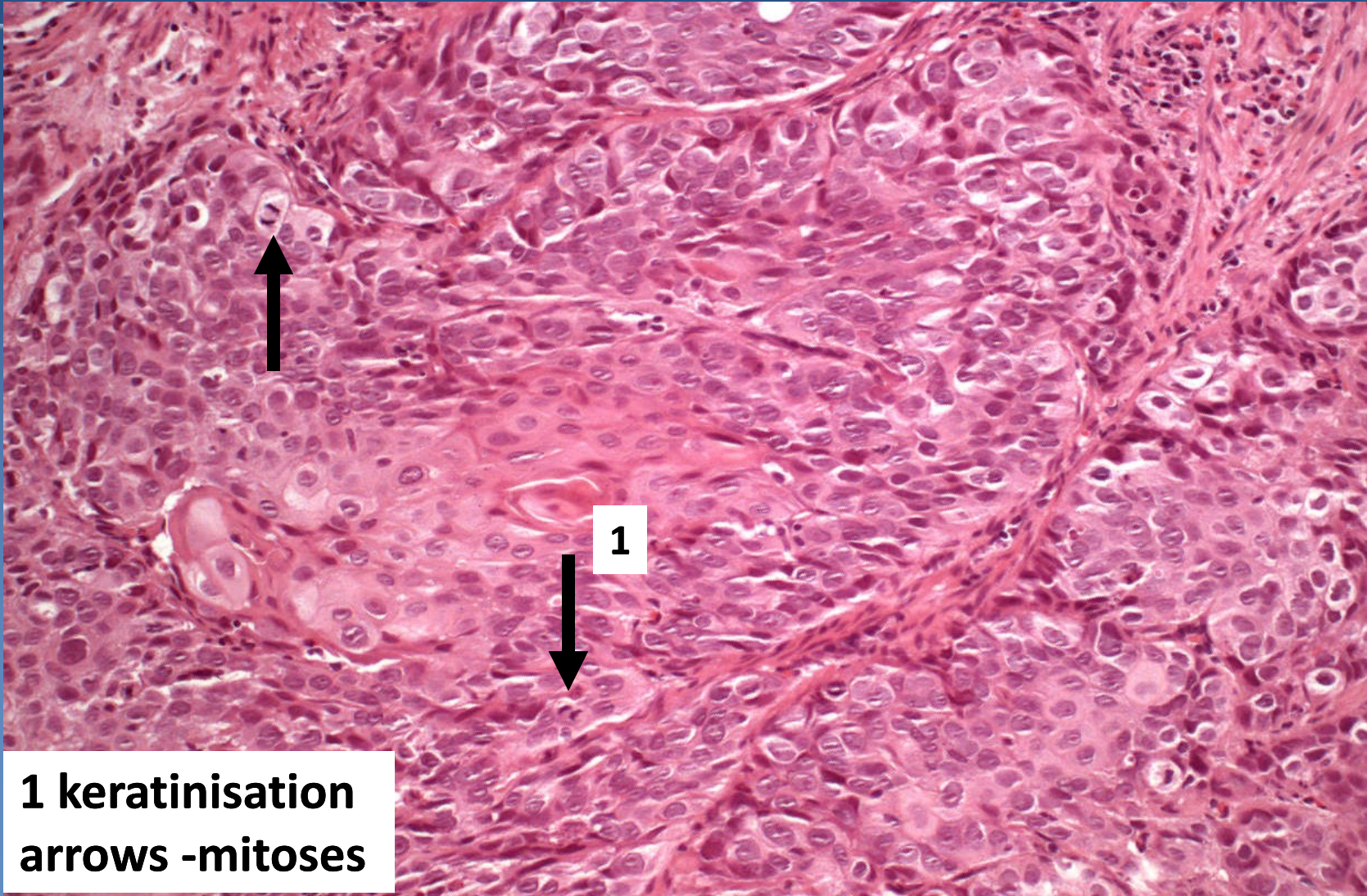
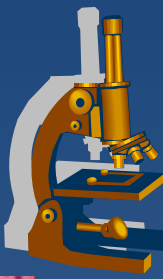
- 1 esophagus
- 2 cardia
- 3 fundus
- 4 body
- 5 antrum
- 6 pylorus
- 7 tumor



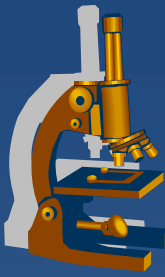
copy



# *Squamous cell carcinoma of the oesophagus*

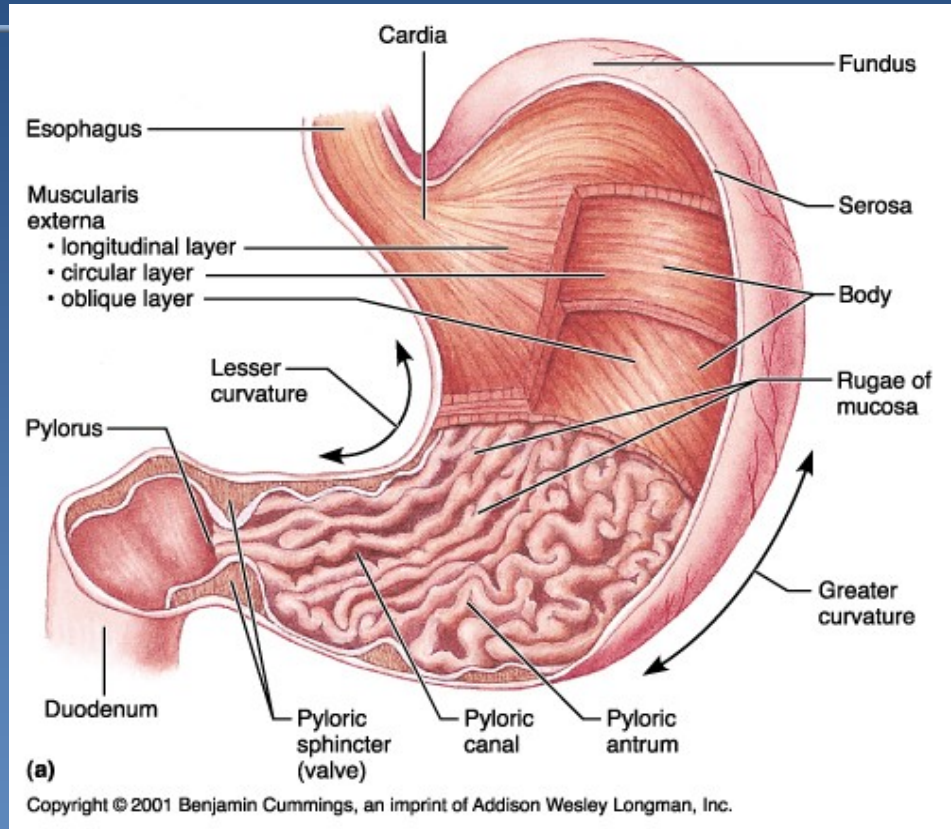
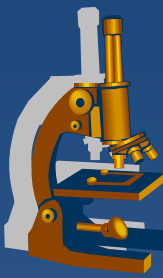


**1 keratinisation  
arrows -mitoses**

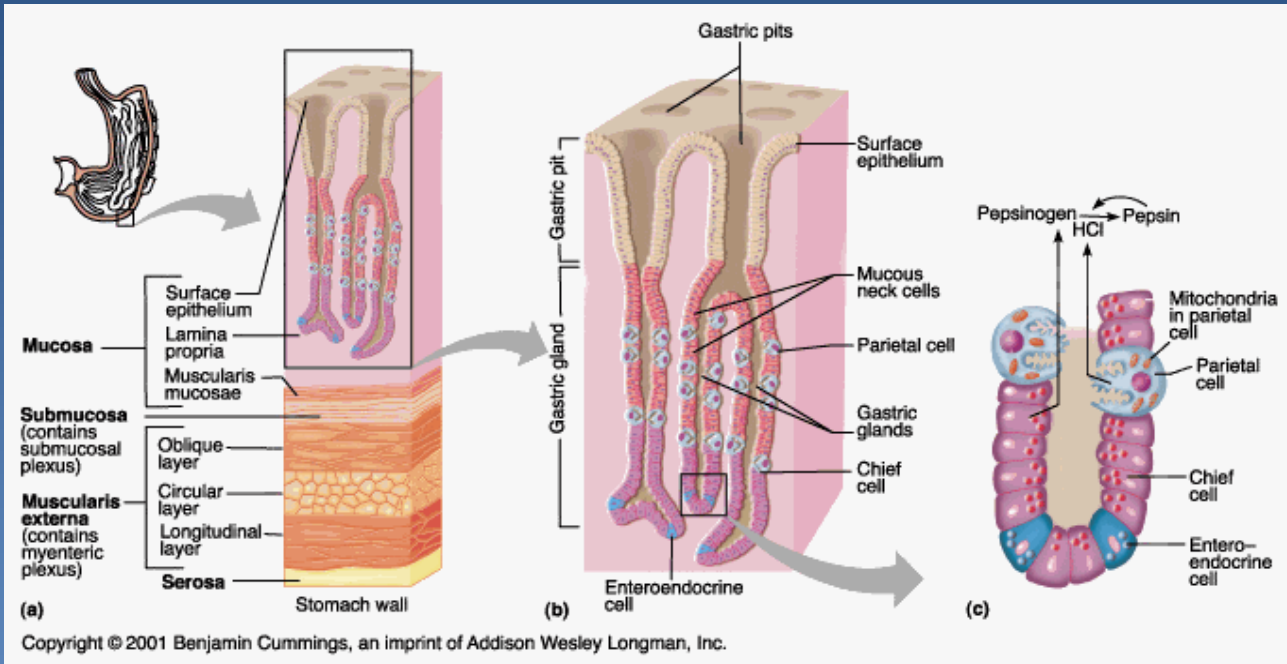
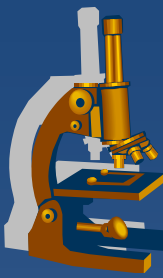


---

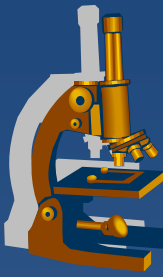
# ***STOMACH***







# Gastritis



× two general types:

⇒ **acute** - *acute mucosal inflammatory process of a transient nature, causes: salt, spices, alcohol, NSAIDs, stress, infection*

- **gross:**

*hyperemic, oedematous mucosa with erosions, haemorrhage*

- **micro:**

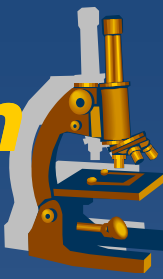*hyperemia, oedema, neutrophilic (foveolar) inflammatory infiltrate, erosions*

# Gastritis



- ⇒ **chronic** - chronic inflammatory changes leading to mucosal atrophy and epithelial metaplasia
- usually associated with *Helicobacter pylori*
  - **micro evaluation:**
    - » inflammatory infiltrate in lamina propria mucosae - lymphoplasmocytic (grade of chronicity) + neutrophils (grade of activity)
    - » presence of HP (+/-) and quantitative analysis
    - » presence of atrophy, intestinal metaplasia (complete, incomplete) and possible dysplasia

# *Clinical-pathological classification of chronic gastritis*



- 1) Chronic non-atrophic gastritis (superficial)  
(„B“)
  
- 2) Chronic atrophic gastritis
  - I. Autoimmune gastritis („A“)
  - II. Chronic multifocal atrophic gastritis
  
- 3) Special forms (chemical - reactive,  
lymphocytic, eosinophilic, granulomatous)



# *Clinical-pathological classification of chronic gastritis*

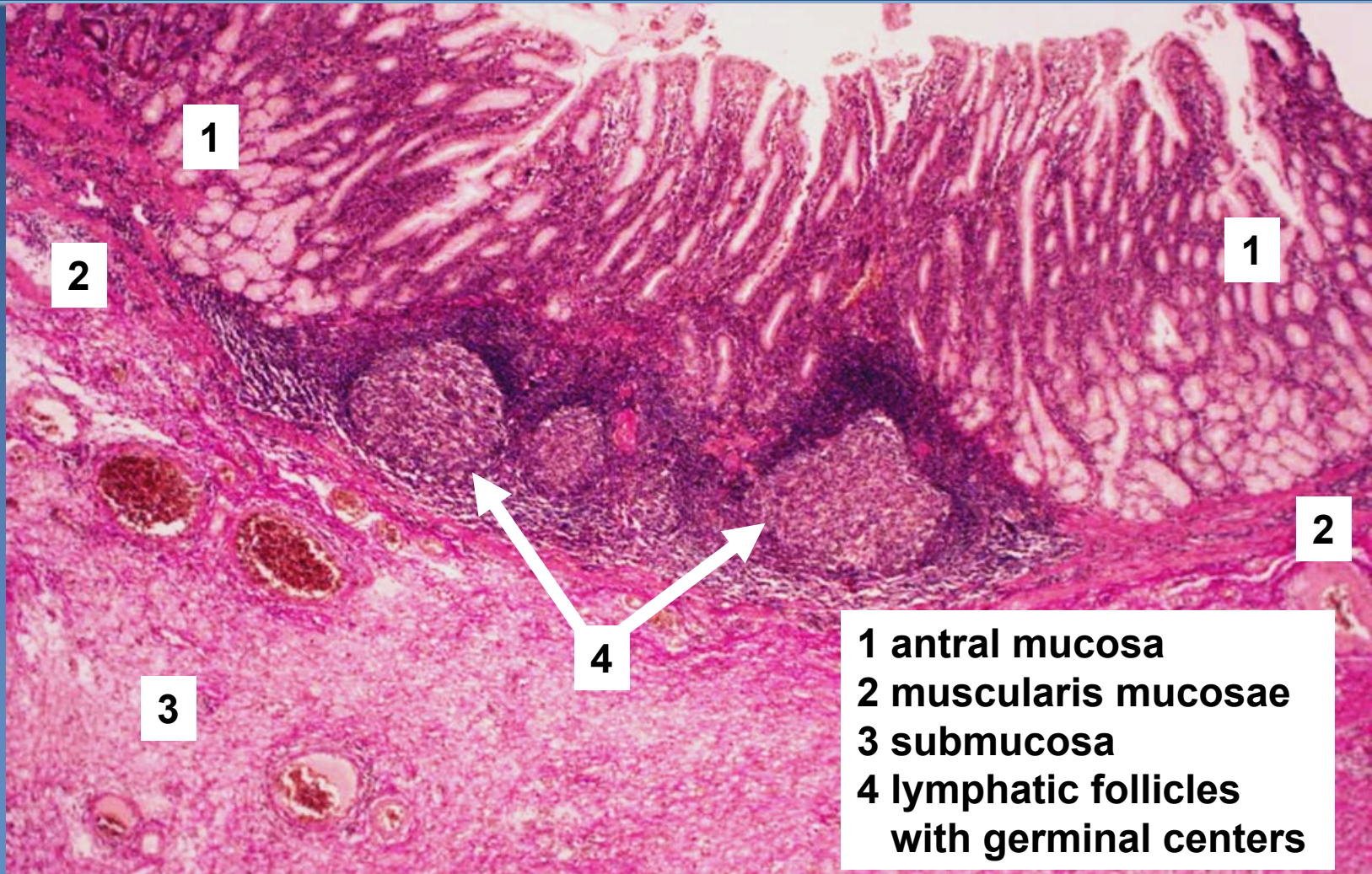


## × **Chronic non-atrophic gastritis (superficial)**

### ⇒ *Helicobacter pylori*

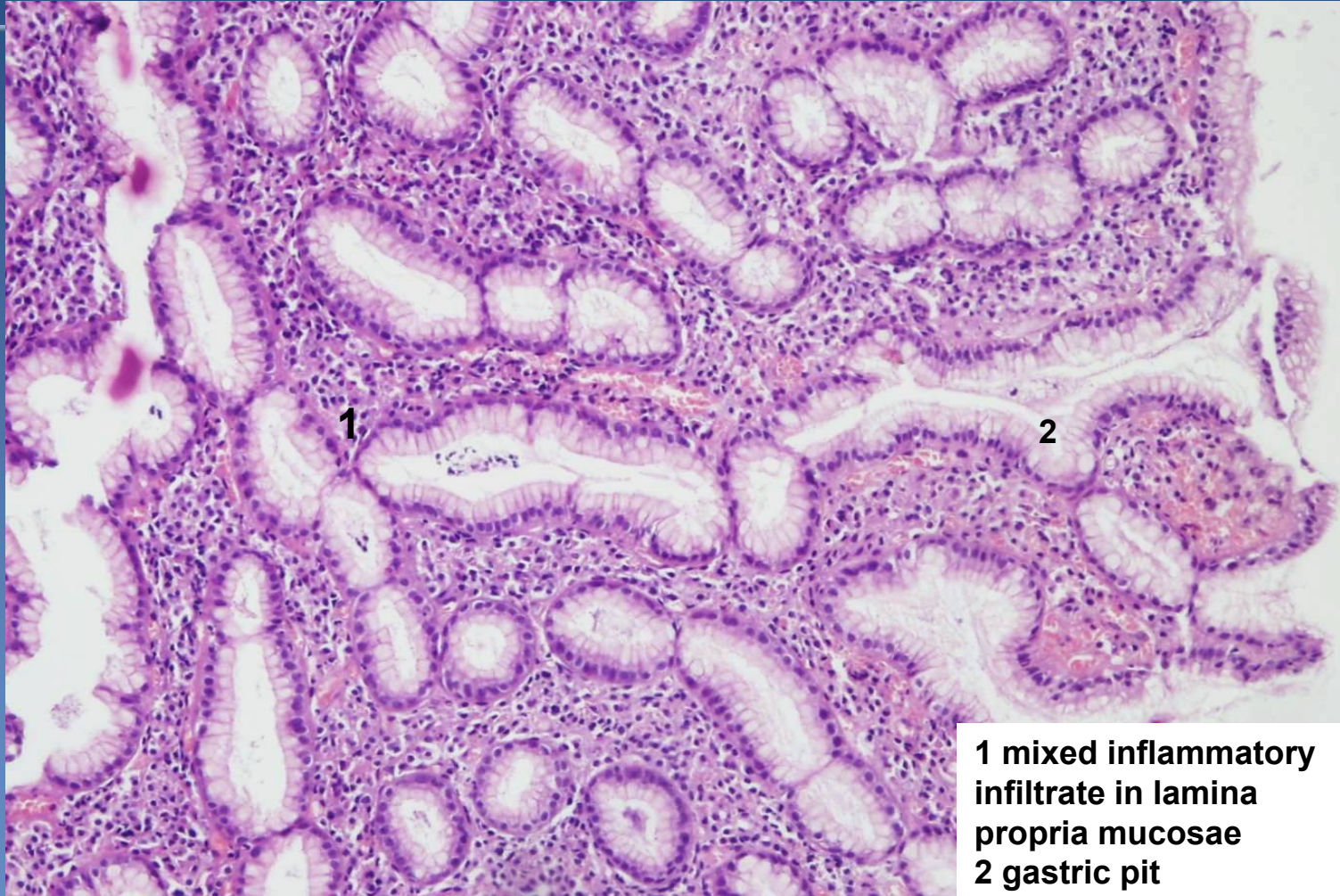
- **gross:** **antrum** and body mucosa
- **micro:** superficial or deep inflammation, active chronic gastritis, lymphocyte and plasma cell response forming lymphatic follicles in the glandular area, final mucosal atrophy
- **higher risk of developing NHL**

# ***Chronic non-atrophic gastritis - follicular***





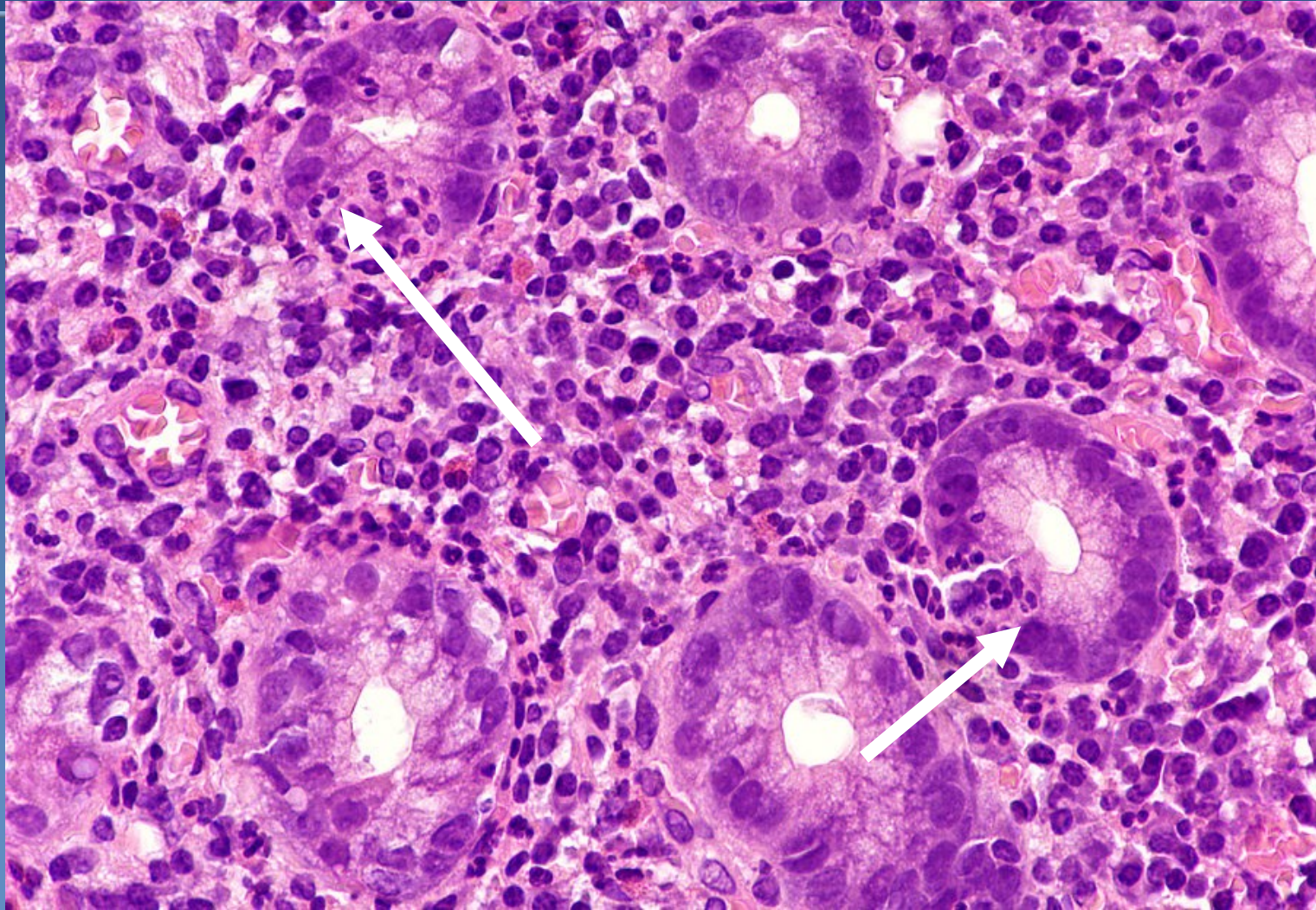
# ***Chronic non-atrophic gastritis*** ***- detail of the mucosa***



**1 mixed inflammatory  
infiltrate in lamina  
propria mucosae**  
**2 gastric pit**



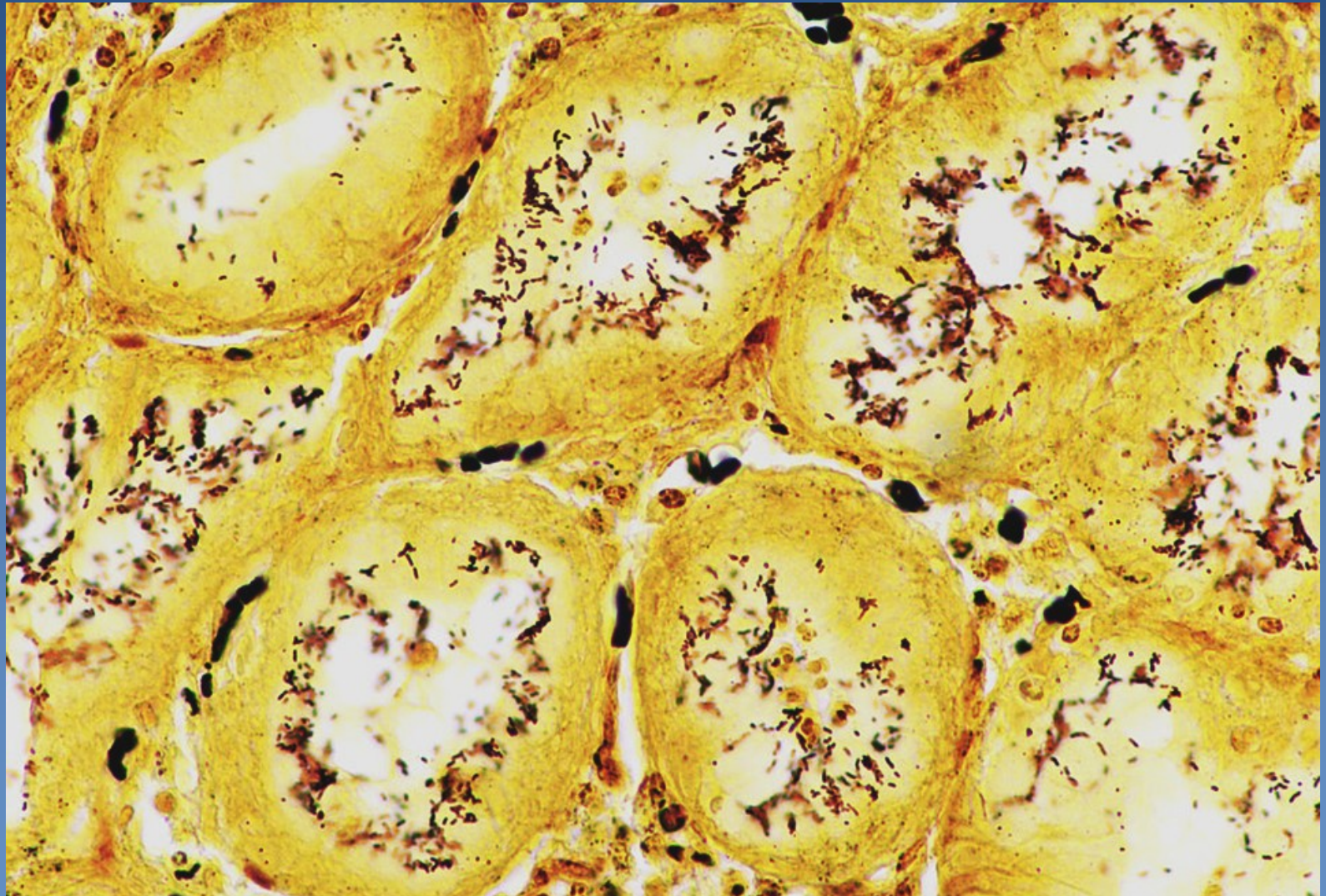
# ***Chronic active gastritis*** ***- grade of activity 2***



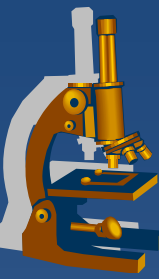
***intraepithelial neutrophils***



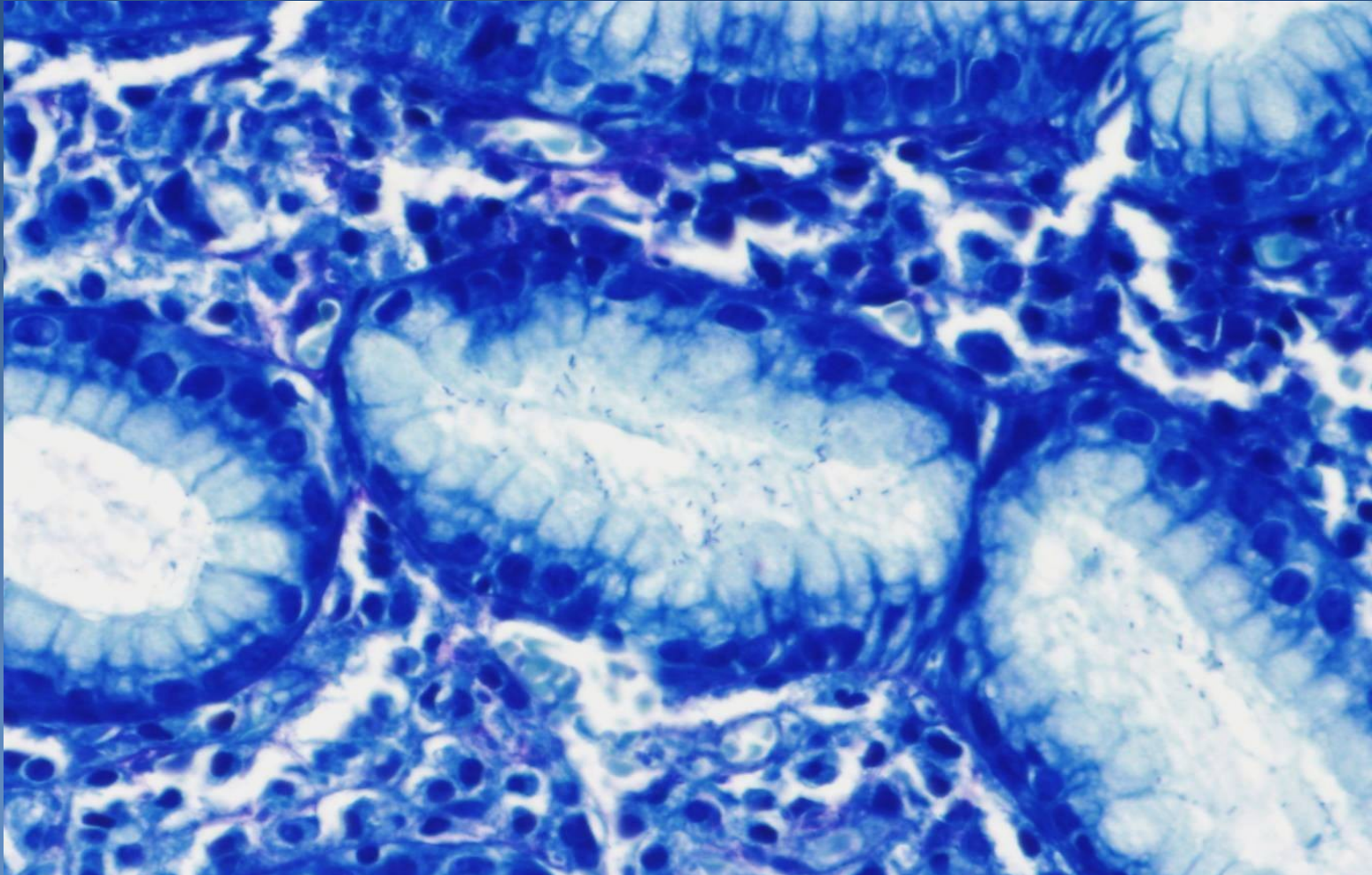
***Chronic non-atrophic gastritis  
Helicobacter pylori (Warthin-Starry)***







***Chronic non-atrophic gastritis  
Helicobacter pylori (Giemsa–Romanowski)***



# Chronic gastritis



## × Chronic atrophic gastritis

### 1/ Autoimmune chronic atrophic gastritis („A“)

⇒ *autoimmune, anti-parietal cell and anti-intrinsic factor antibodies, hypochlorhydria, association with vitamin B12 deficiency and pernicious anemia*

- *gross: mucosa of the gastric **body** and fundus atrophy*
- *micro: chronic non-active gastritis (severe mucosal atrophy with intestinal or pseudopyloric metaplasia, fibrosis)*
- *higher risk of developing adenocarcinoma!*

# Chronic gastritis



× **Chronic atrophic gastritis**

2/ **Chronic multifocal atrophic gastritis (pangastritis)**

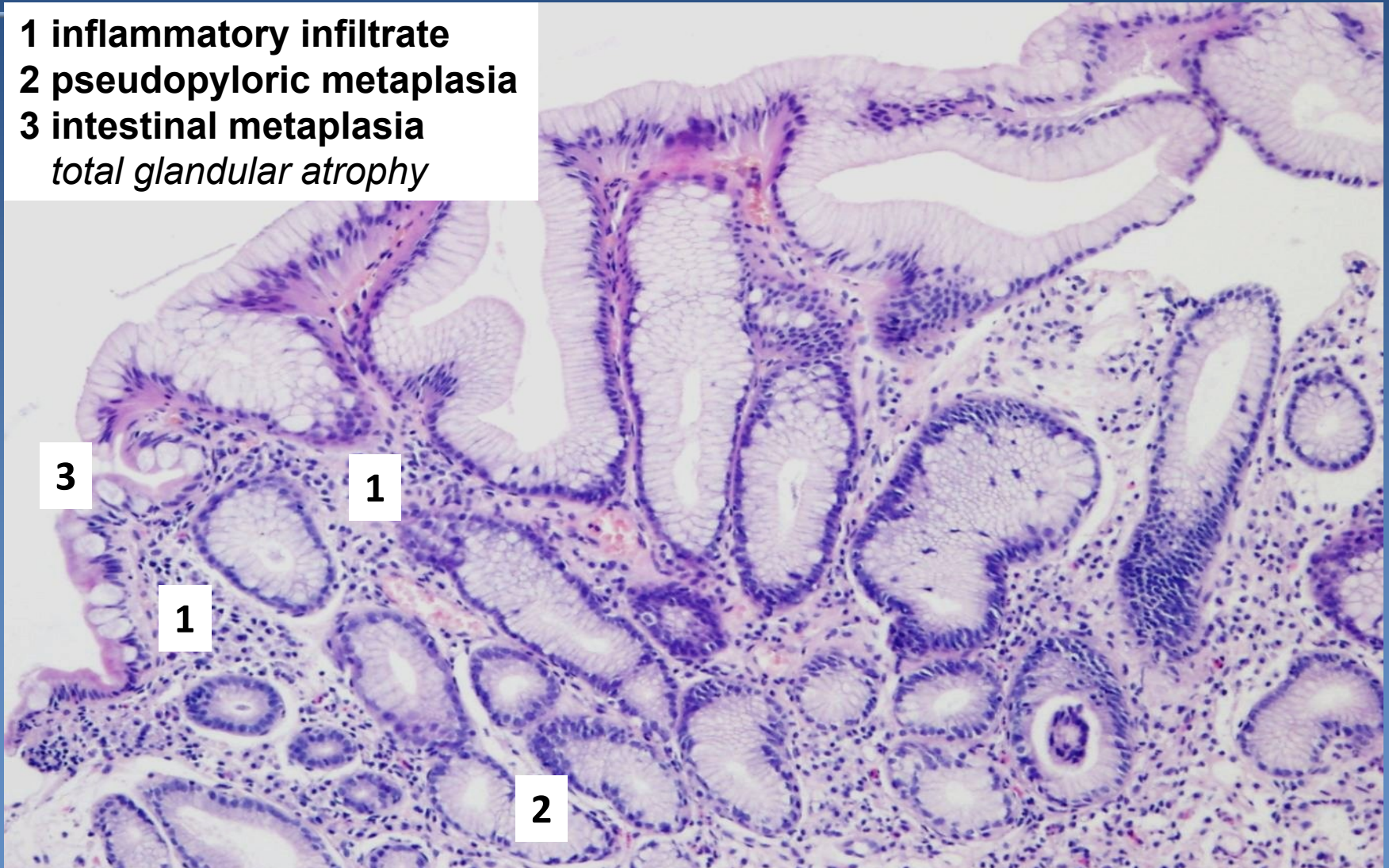
- ⇒ *Helicobacter pylori-associated*
- ⇒ *low grade of inflammation (body + antrum)*
- ⇒ *epithelial reactive changes, erosions*
- ⇒ *uneven distribution of atrophic foci*



# *Chronic atrophic gastritis (gastric body)*

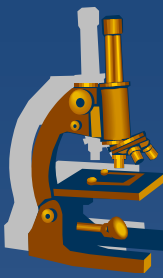


- 1 inflammatory infiltrate
- 2 pseudopyloric metaplasia
- 3 intestinal metaplasia  
*total glandular atrophy*

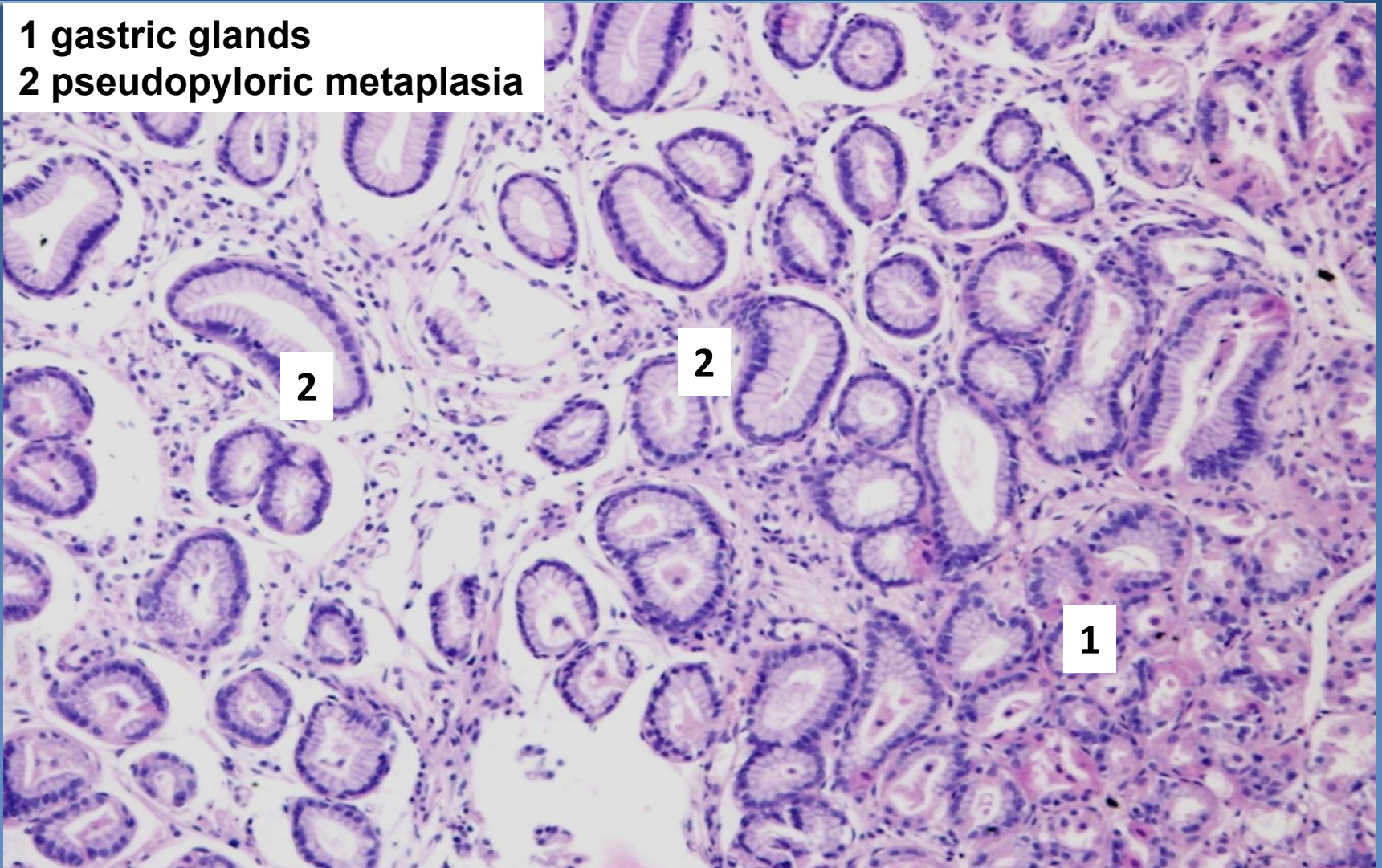




# *Chronic atrophic gastritis (gastric body)*

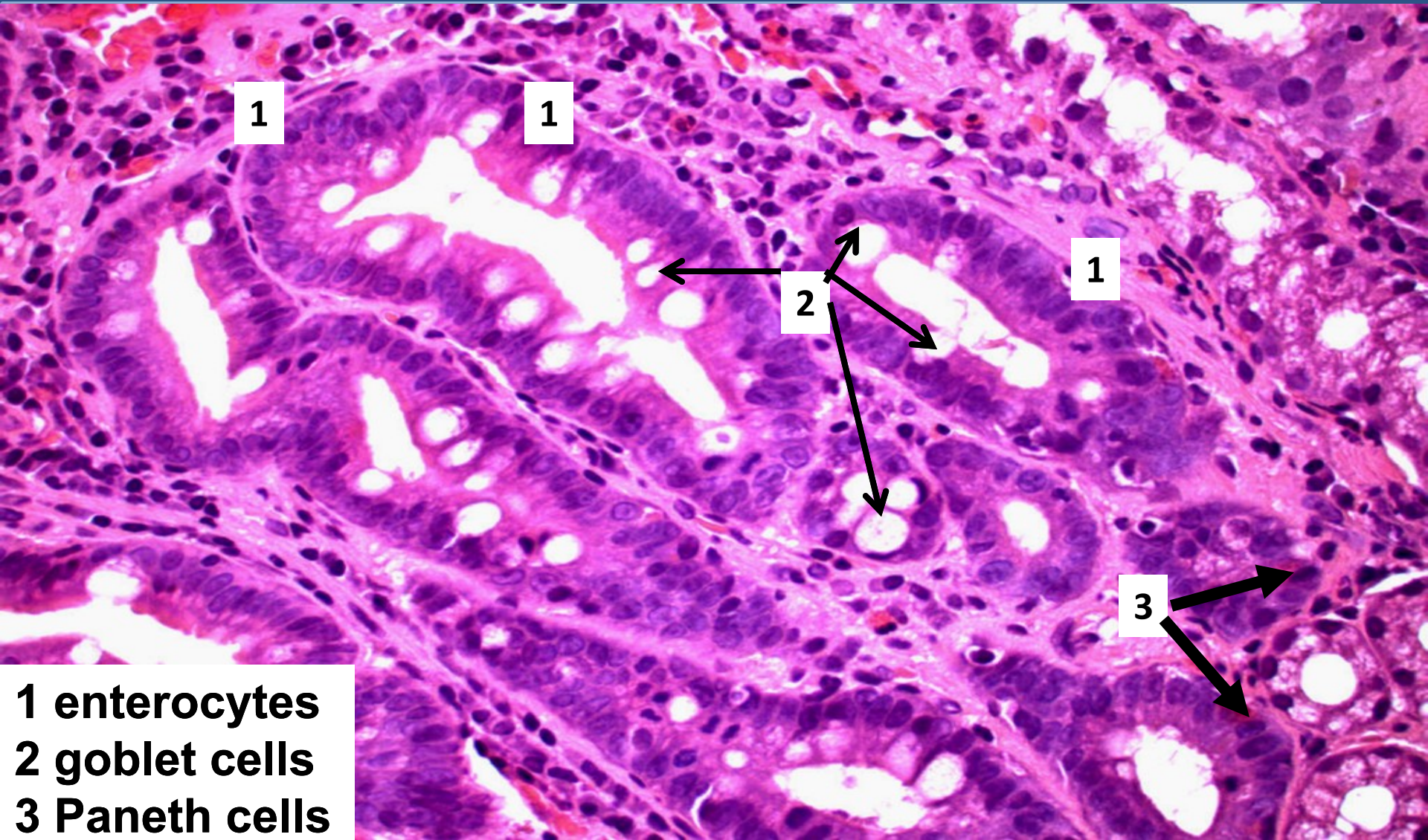


1 gastric glands  
2 pseudopyloric metaplasia





# *Chronic gastritis* *- intestinal metaplasia*



- 1** enterocytes
- 2** goblet cells
- 3** Paneth cells

# Chronic gastritis

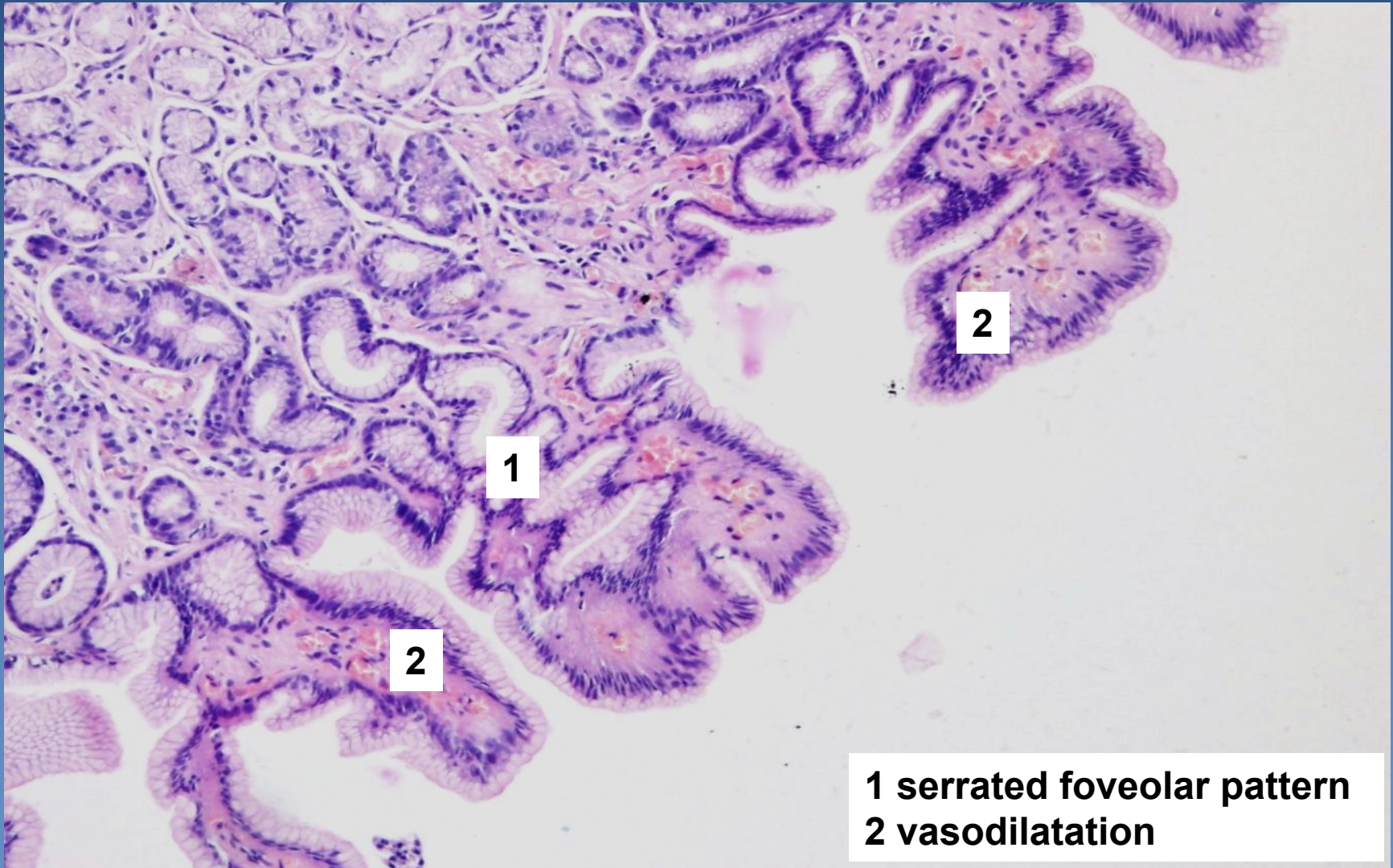
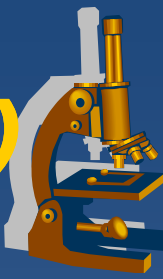

## Special forms:

- × Chemical (reflux) gastritis / reactive gastropathy (former „C“)
  - ⇒ *bile reflux, duodenal reflux after partial gastrectomy, NSAIDs*
  - ⇒ *micro: hyperemic, oedematous mucosa, foveolar hyperplasia, vasodilatation, little inflammatory response*
- × Lymphocytic, eosinophilic, granulomatous...



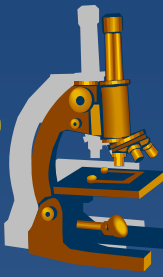
# ***Reactive gastropathy (gastritis C) mild changes***



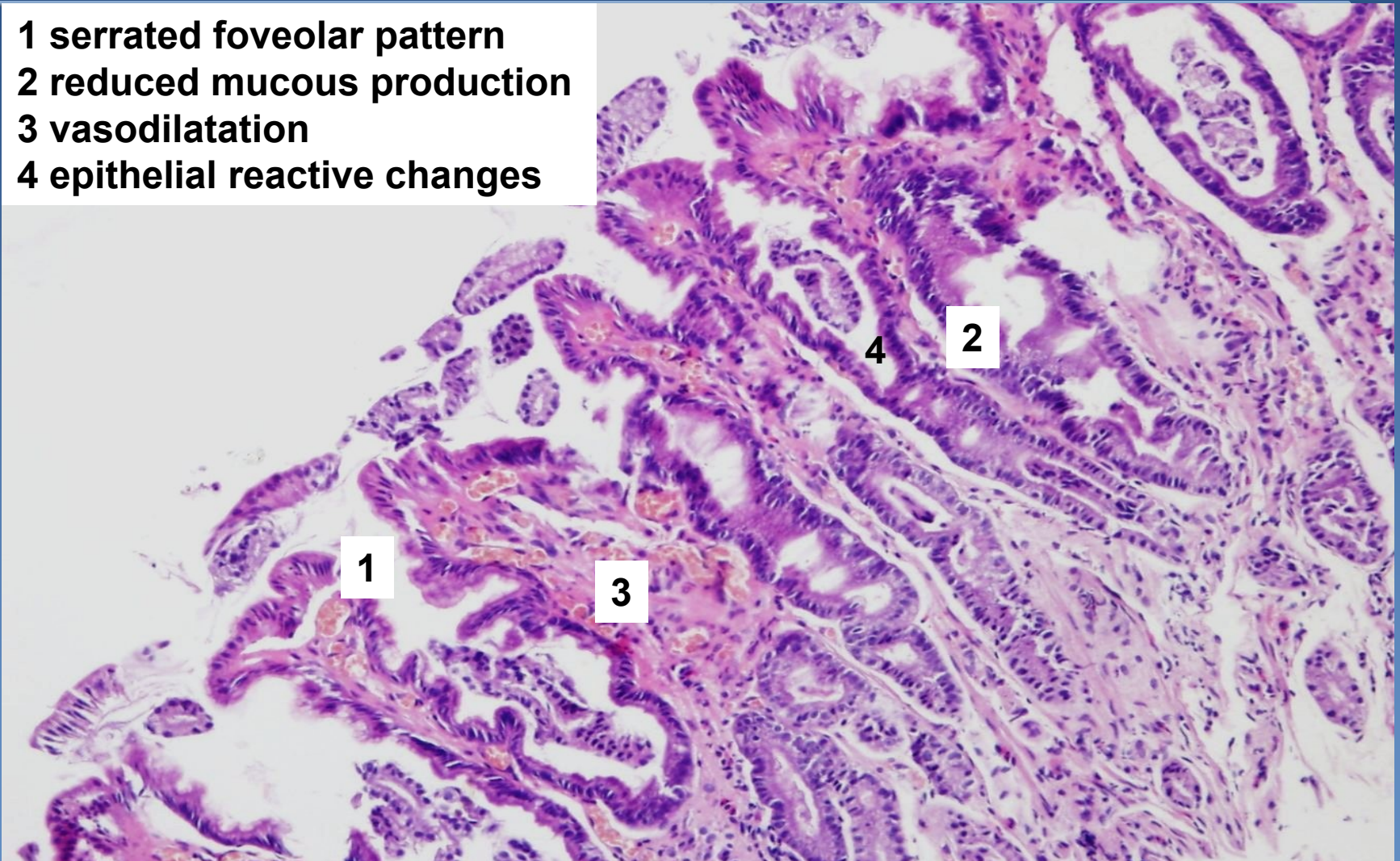
**1 serrated foveolar pattern  
2 vasodilatation**



# ***Reactive gastropathy (gastritis C) severe changes***



- 1 serrated foveolar pattern**
- 2 reduced mucous production**
- 3 vasodilatation**
- 4 epithelial reactive changes**



# Hypertrophic gastropathy



✗ uncommon, large mucosal folds

⇒ *marked epithelial hyperplasia (↑ growth factor release), may mimic a tumor:*

- Ménétrier's disease (hyperplastic hypersecretory gastropathy with protein loss)
- hypersecretory gastropathy (hyperplasia of parietal and chief cells)
- glandular hyperplasia in Zollinger - Ellison syndrome (in neuroendocrine tumors with gastrin production)

# Gastric erosions



- x definition:

- ⇒ *limited by m. mucosae, tiny superficial defects < 3 mm*

- x causes:

- ⇒ *NSAIDs, alcohol, vomiting, stress, burns, infection*

- x localisation:

- ⇒ *antrum and body*

- x microcirculation disorder, capillary rupture

- x complete regeneration within a few days



# Peptic ulceration



- x **Ulcer definition:** *mucosal defect progressing through the m. mucosae **into the submucosa or deeper***
- x **risk factors/causes:**
  - ⇒ *general: genetics, age, stress, alcohol, smoking*
  - ⇒ *local: gastric hyperacidity, HP gastritis, NSAIDs*
- x **localisation:**
  - ⇒ *pylorus, lesser curvature, bulbus duodeni, (Meckel's diverticulum, stomic junction, GE junction)*

# Gastric ulceration



## Acute ulcer:

- ⇒ *sharply demarcated defect 4 - 25mm; acute gastritis, severe stress (shock, trauma, burns), NSAIDs, severe hyperacidity*

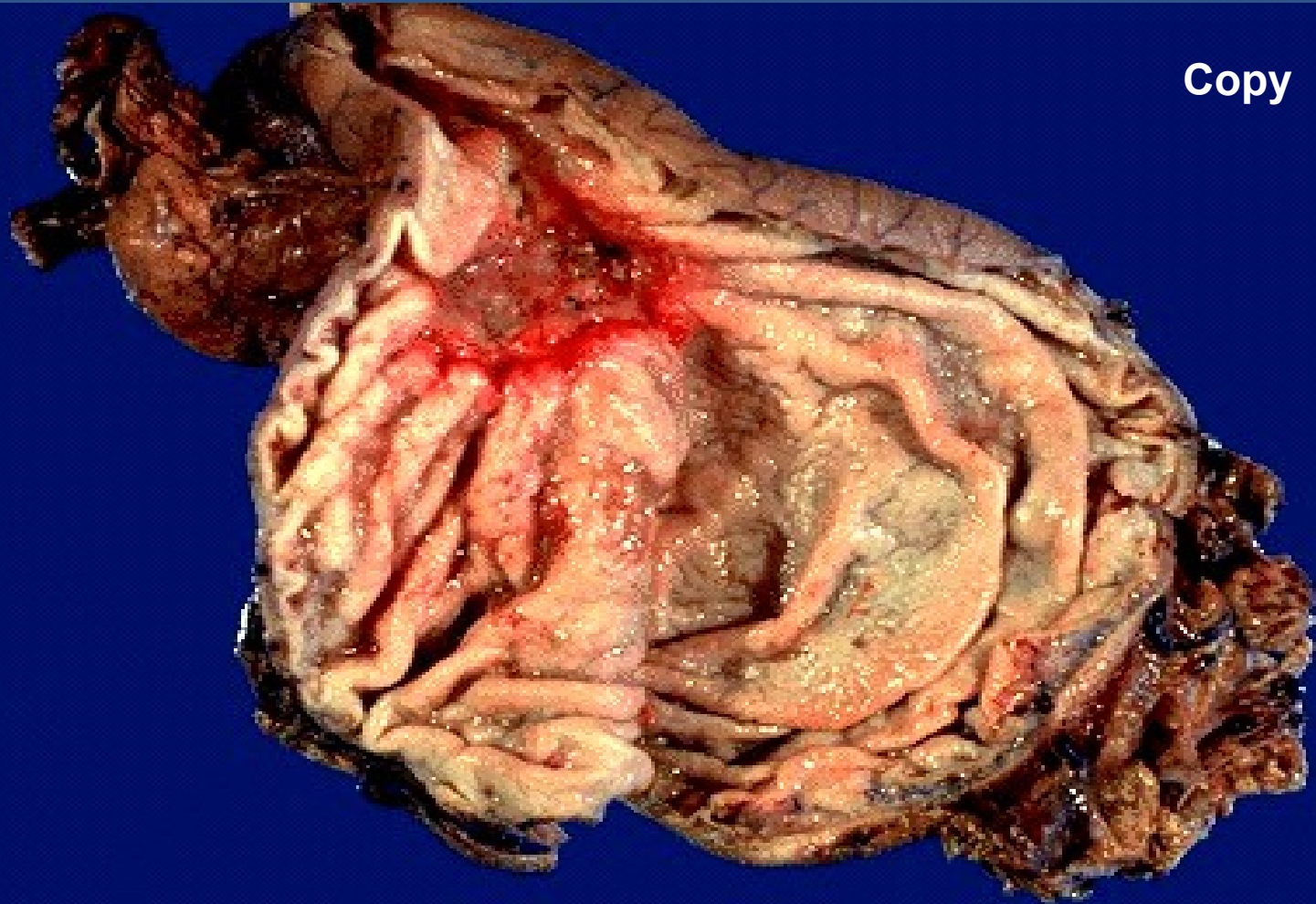
## Chronic ulcer:

- ⇒ *slightly overhanging margins, radial adjacent mucosal folds*
- ⇒ *gross: smooth base*
- ⇒ *4 histologic zones: 1) fibrinoid necrosis and cell debris – active u. 2) mixed inflammatory infiltrate 3) granulation tissue 4) fibrous scar*
- ⇒ *complications: bleeding (overt, occult), penetration, perforation, scarring + obstruction, rare malignant transformation*

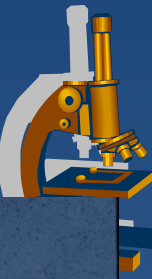
# *Chronic peptic ulcer of the stomach*



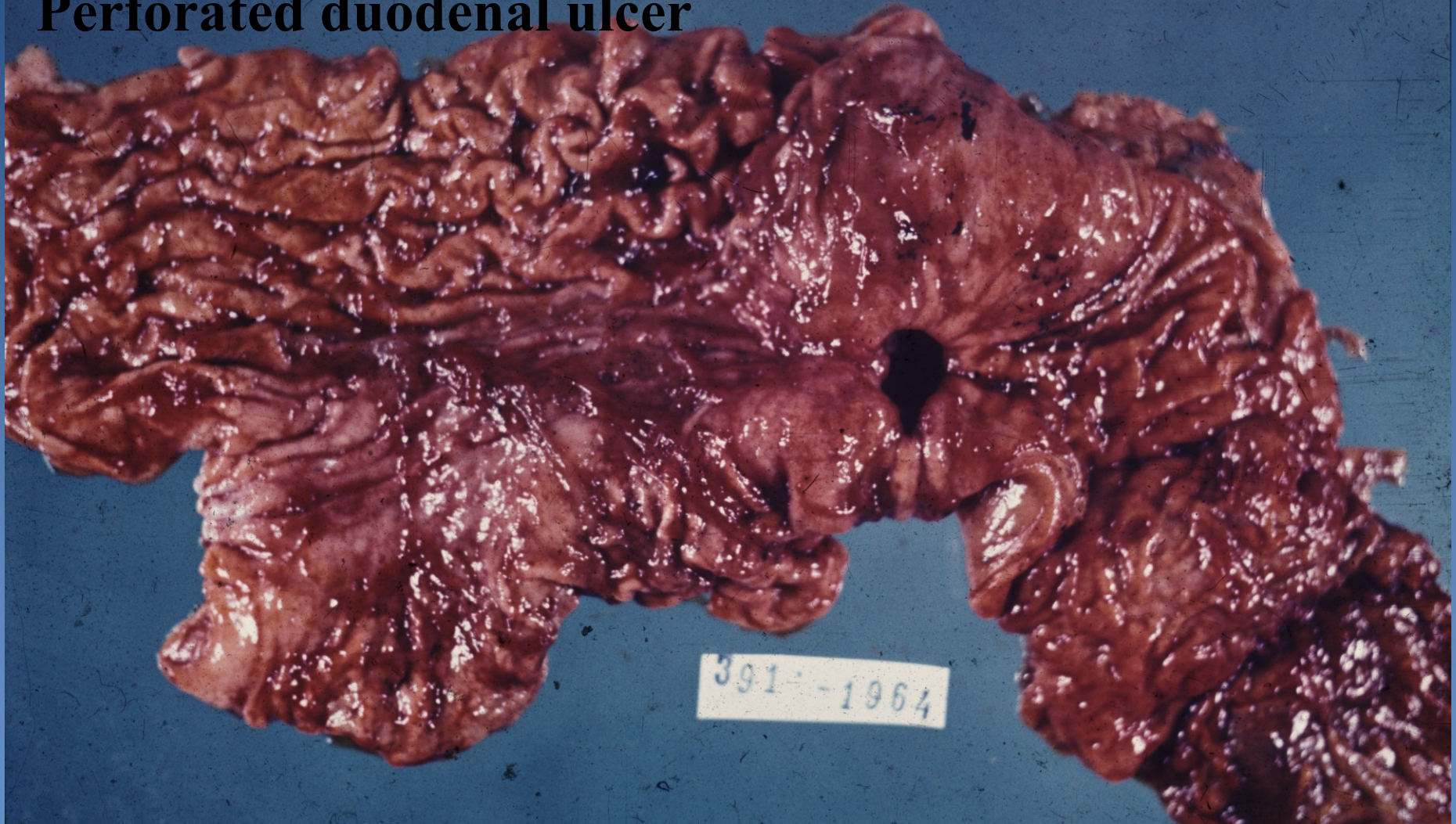Copy



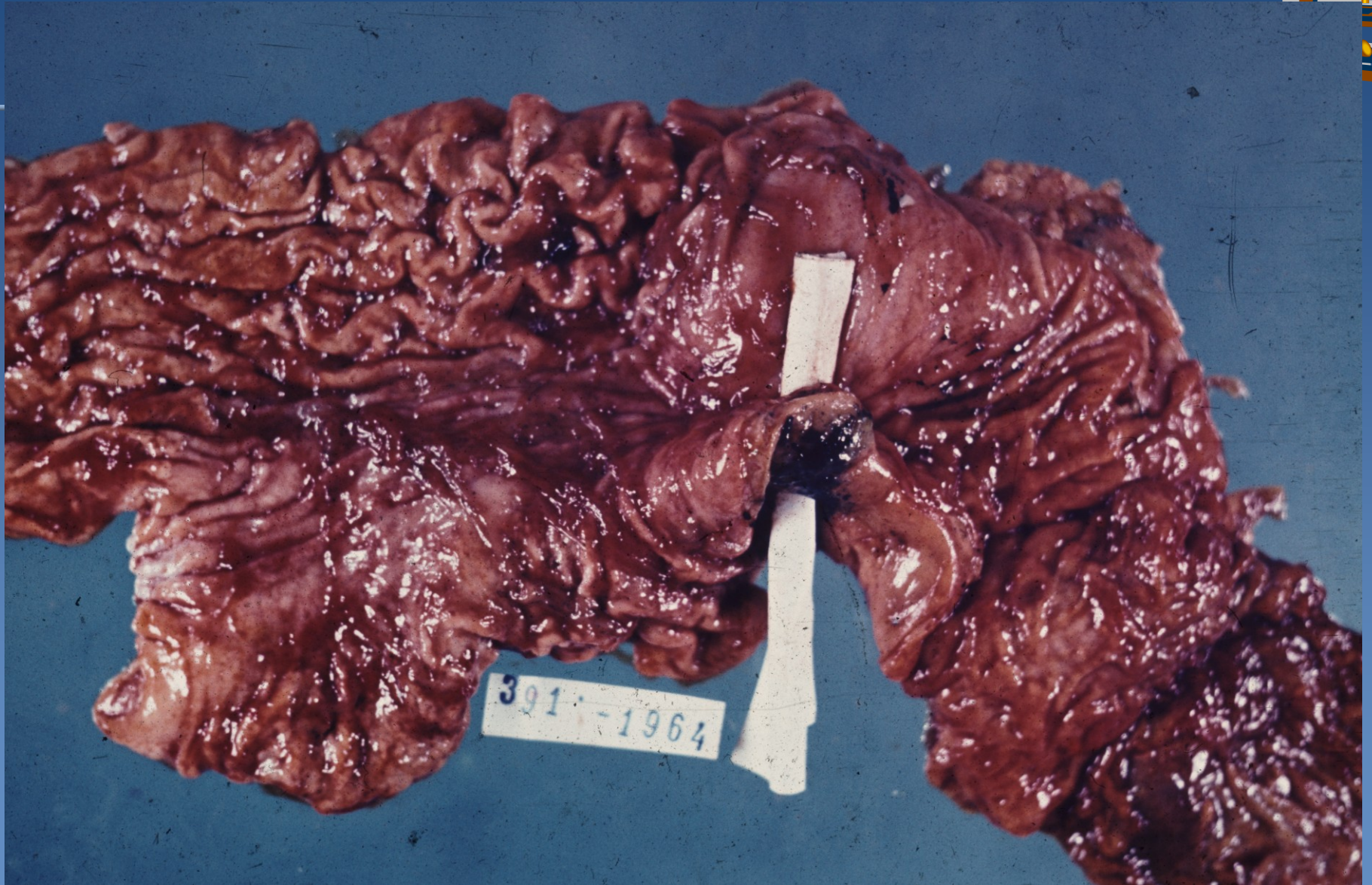
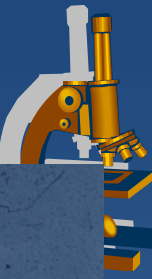




## Perforated duodenal ulcer

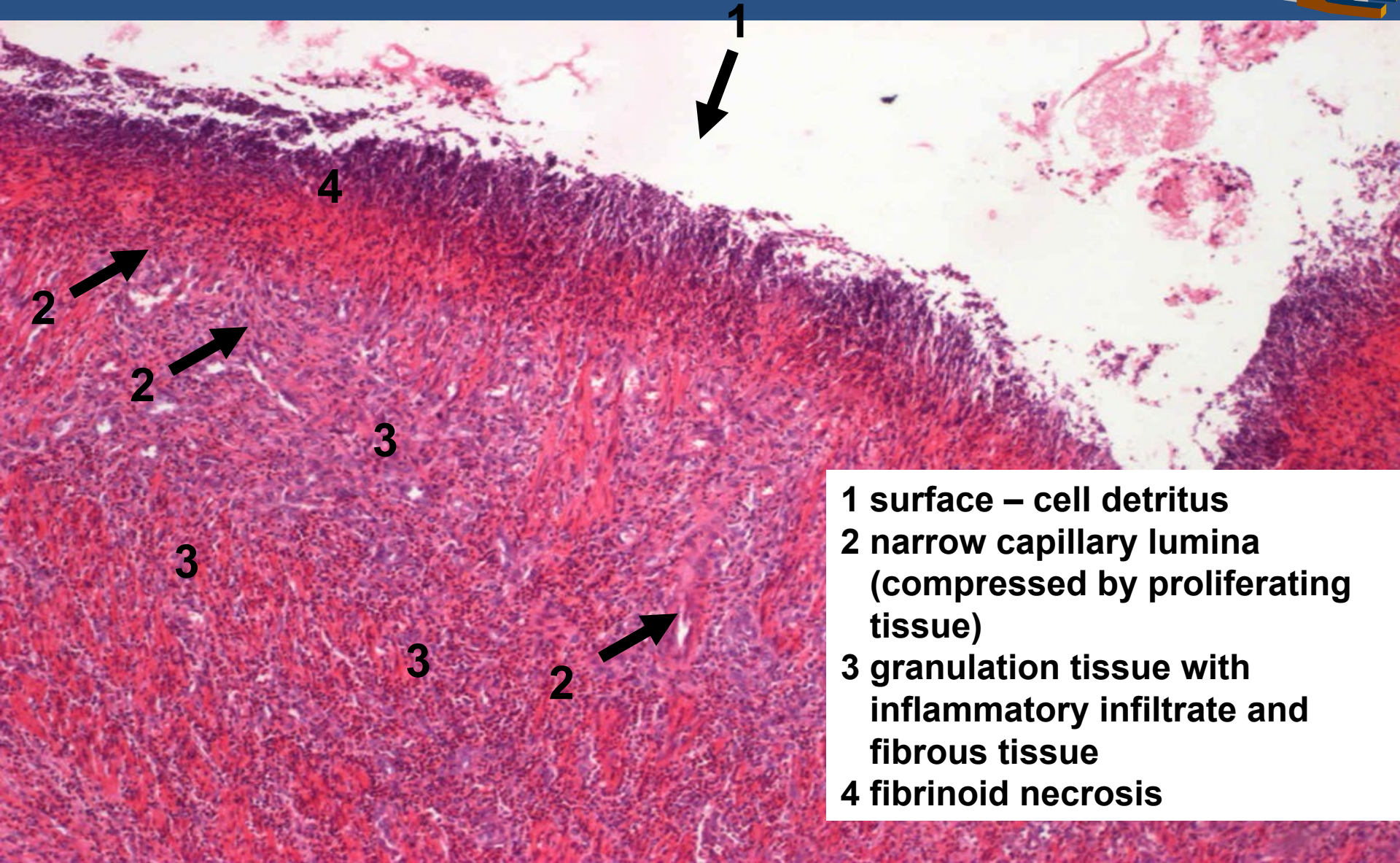
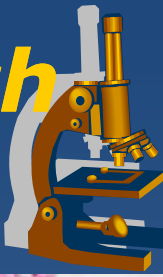







# **Chronic peptic ulcer of the stomach** **- basis**



- 1 surface – cell detritus**
- 2 narrow capillary lumina  
(compressed by proliferating  
tissue)**
- 3 granulation tissue with  
inflammatory infiltrate and  
fibrous tissue**
- 4 fibrinoid necrosis**

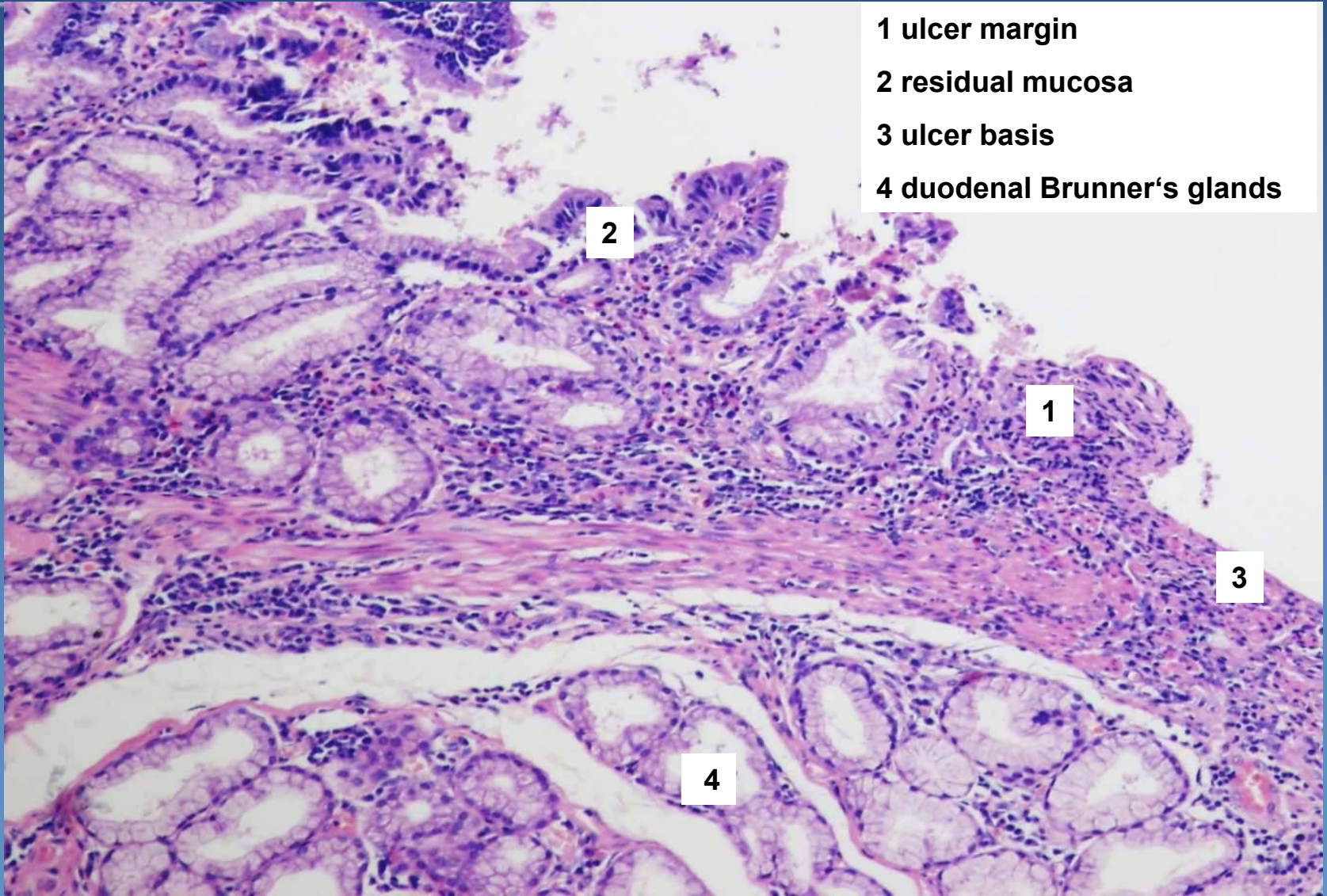


# *Peptic duodenal ulcer*

## *- edges of the ulcer*

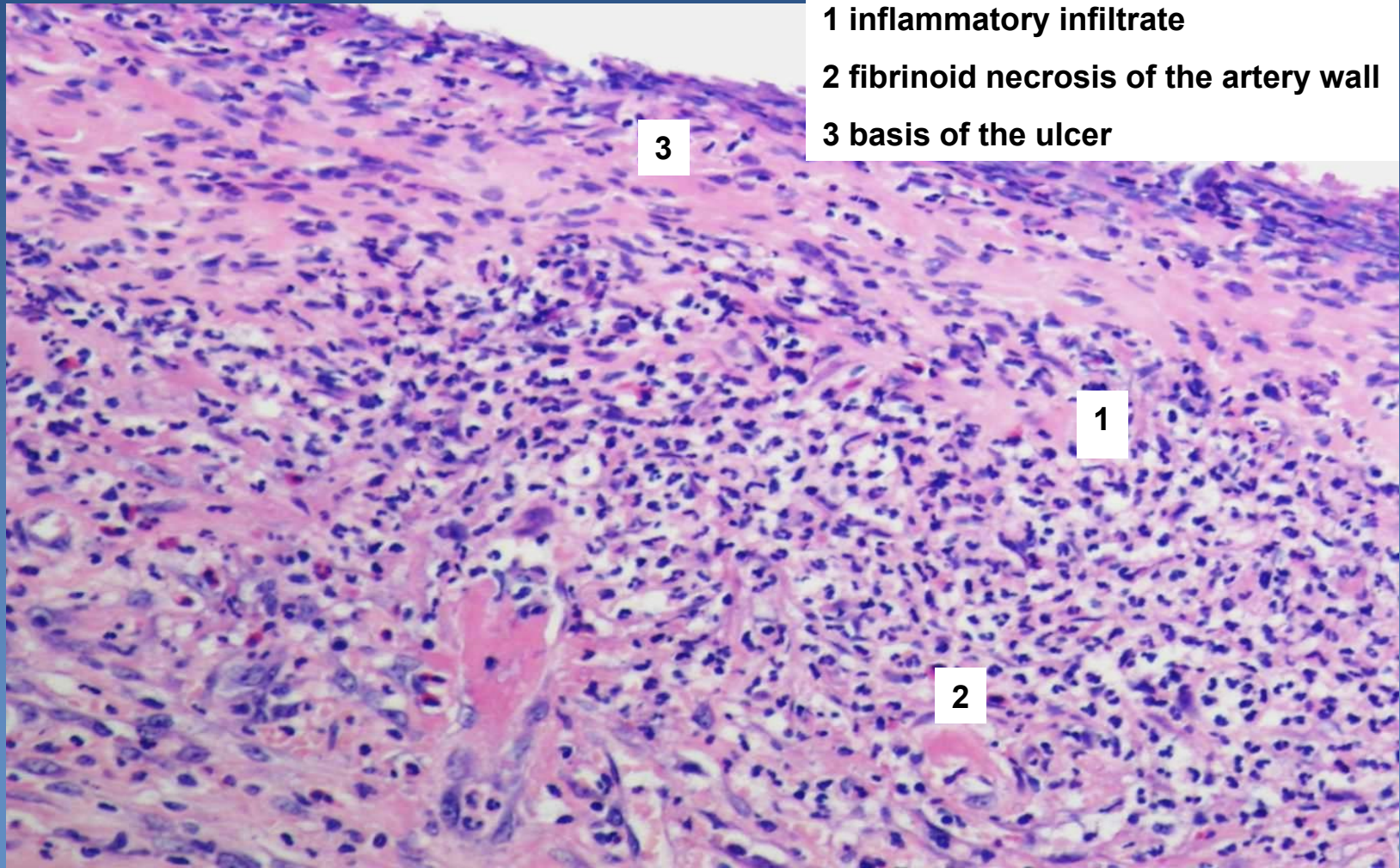
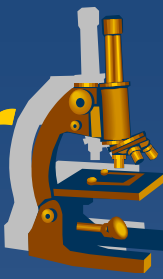


- 1 ulcer margin
- 2 residual mucosa
- 3 ulcer basis
- 4 duodenal Brunner's glands





# ***Chronic peptic duodenal ulcer*** ***- basis of the ulcer***





# *Important gastric tumors*

## **x PSEUDOTUMORS**

⇒ *non-tumorous polyps (inflammatory, hyperplastic, fundic gland polyps)*

## **x EPITHELIAL**

⇒ *adenoma (in the setting of chronic gastritis/intest. metaplasia)*

⇒ *malignant: carcinoma (adenoca, neuroendocrine ca, ...)*

## **x NON-EPITHELIAL**

⇒ *gastrointestinal stromal tumors (GISTs)*

⇒ *lymphomas (NHL: MALT, DLBCL)*



# Gastric carcinoma



- ✗ most common malignant gastric tumor
- ✗ location: antrum, pylorus, lesser curvature
- ✗ risk factors:
  - ⇒ precursor lesions: chronic gastritis with intestinal metaplasia, infection with HP, intraepithelial neoplasia
  - ⇒ EBV, dietary carcinogenes (salted, smoked food), familial
- ✗ clinical features:
  - ⇒ vomiting, abdominal discomfort, weight loss, anorexia
  - Direct spread into adjacent organs/tissues
  - Metastases: LN regional, distant (Troisier's supraclavicular LN), portal circulation (liver), peritoneal dissemination, lung, ovarian **Krukenberg tumor** in females.

# Gastric carcinoma



## Classification:

- ✗ macroscopical:
  - ⇒ *exophytic (polypous)*
  - ⇒ *excavated (ulcerated)*
  - ⇒ *infiltrative (linitis plastica)*
- ✗ depth of invasion:
  - ⇒ **early**: *only in mucosa and submucosa*
  - ⇒ **advanced**: *extended into the muscular wall*
- ✗ histological type

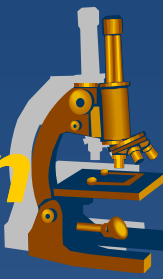
# **WHO** *histological classification of gastric tumors*



- x Tubular
- x Papillary
- x Mucinous
- x Signet-ring cell
- x Adenosquamous
- x Squamous
- x Undifferentiated
- x Neuroendocrine



# Lauren's histological classification



## × Intestinal:

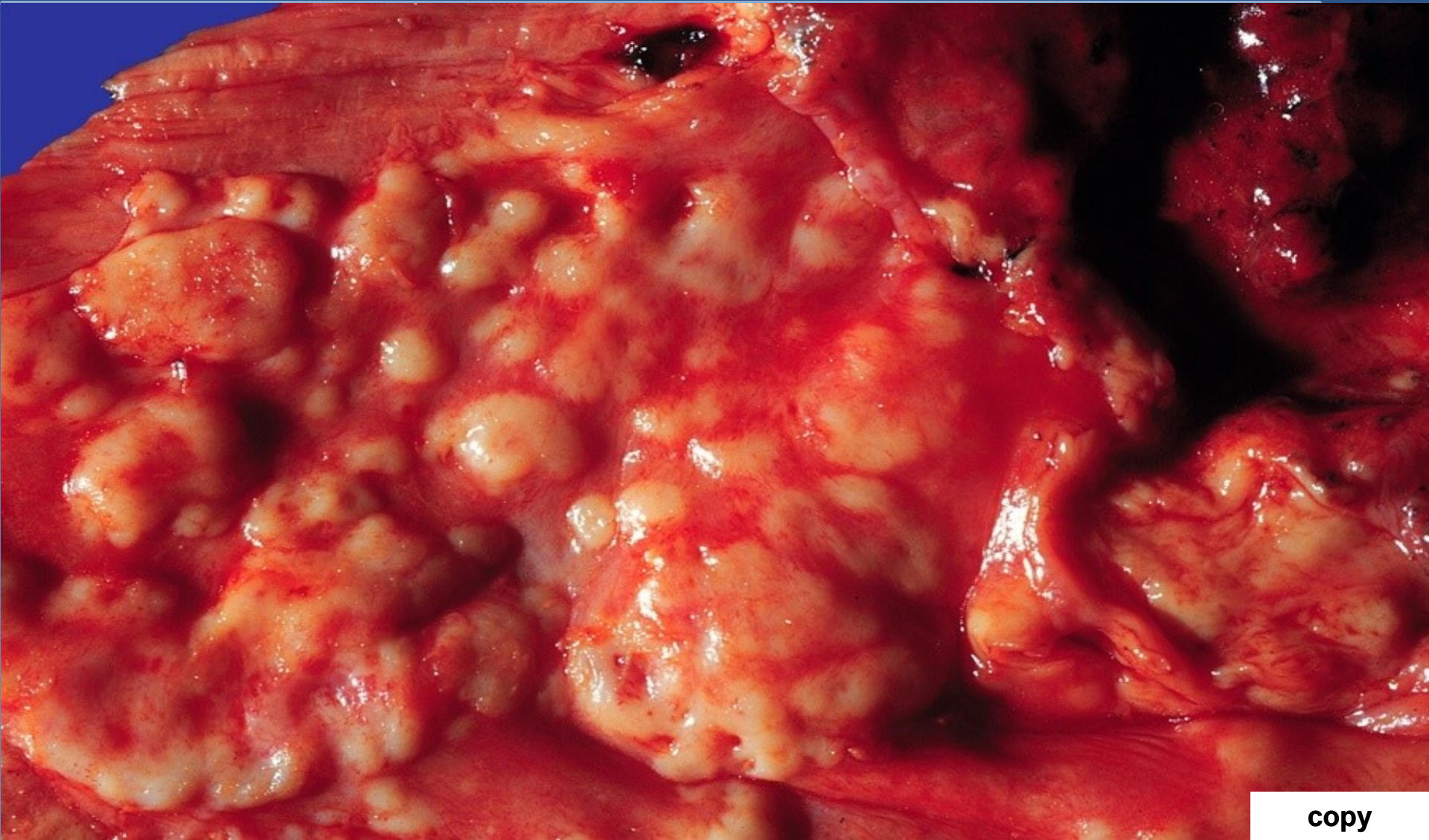
- ⇒ 50%, HP chronic gastritis, ↓ tendency
- ⇒ intestinal metaplasia-connected, neoplastic tubular glands/papillary formations, columnar epithelium, expansive growth
- ⇒ > 50 yrs, M:F 2:1

## × Diffuse:

- ⇒ 30%, ↑ tendency
- ⇒ dissociated cells infiltrating singly / in small clusters into the stomach wall, signet-ring cells possible, reactive desmoplasia - fibrosis (scirrhous)
- ⇒ earlier age, M:F 1:1

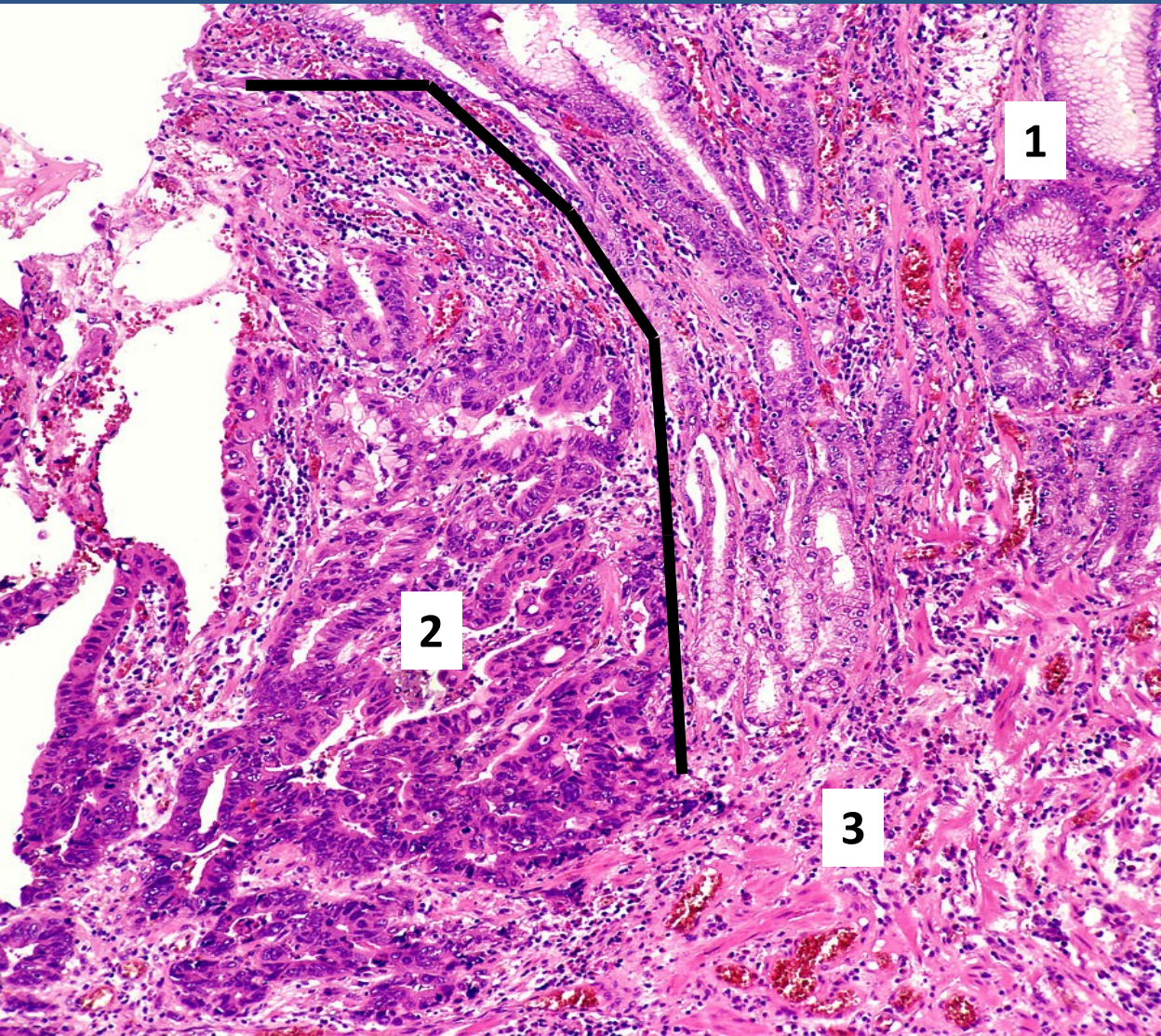
## × Mixed

# ***Gastric adenocarcinoma*** ***- exophytic growth***





# ***Gastric adenocarcinoma*** ***- intestinal type***



**1**

**1 normal gastric mucosa**

**2**

**2 tubopapillary  
adenocarcinoma**

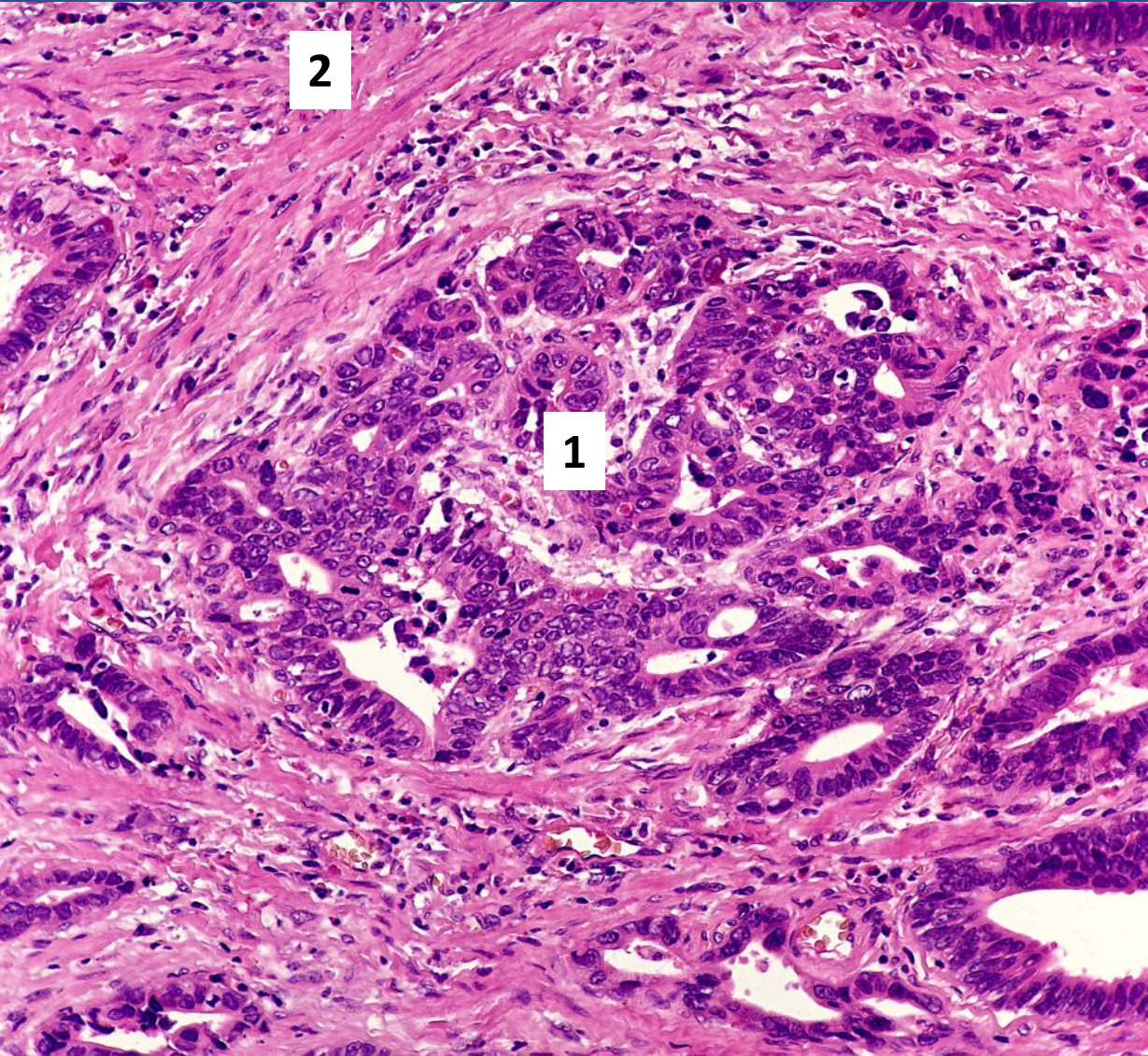
**3**

**3 muscularis mucosae**

**line - sharp demarcation  
of the tumor from  
normal mucosa**



# *Gastric adenocarcinoma (intestinal type) infiltration into lamina muscularis propria*

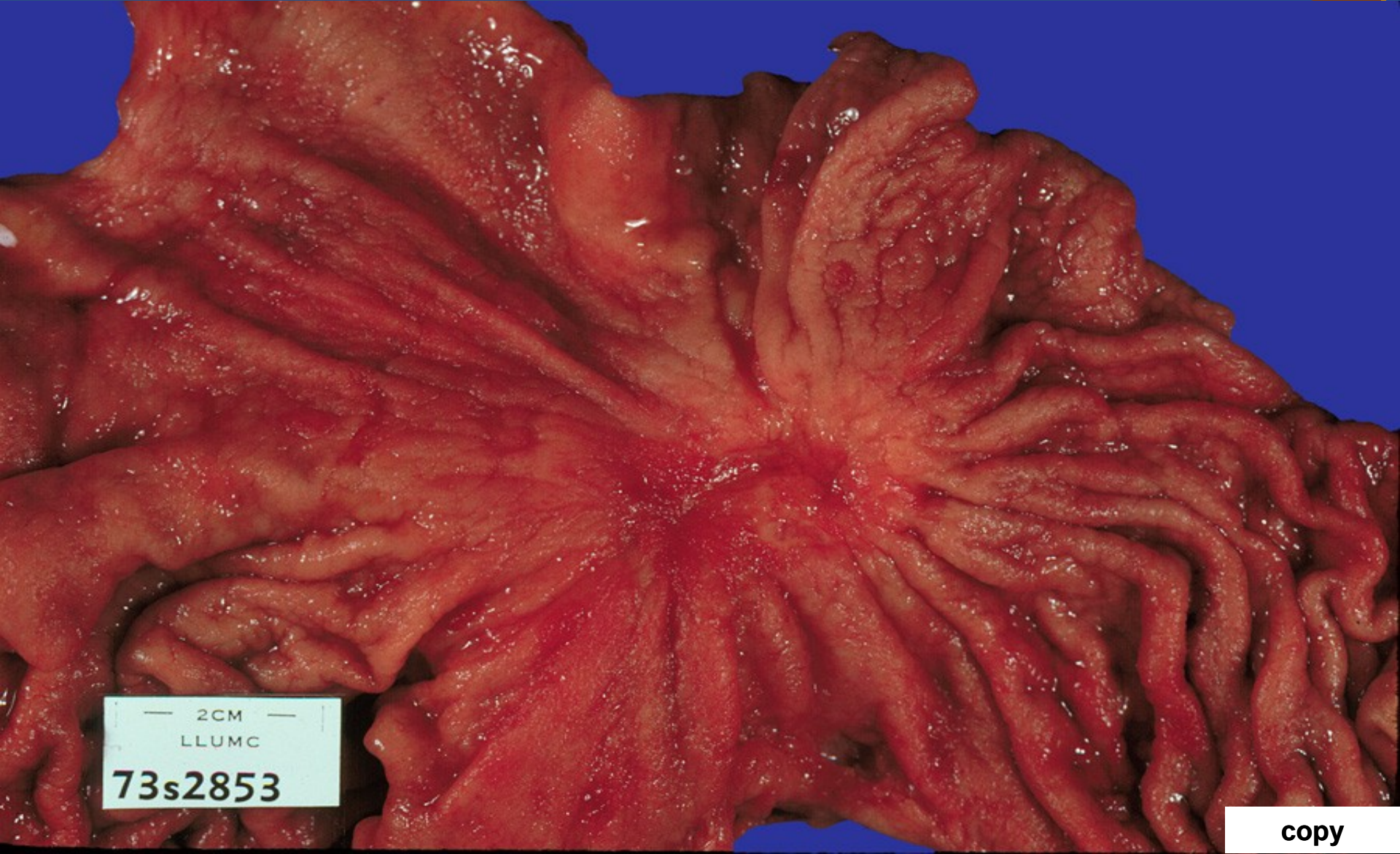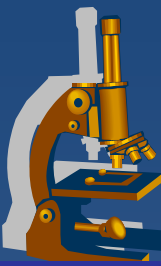


1 tumor cells

2 smooth muscle cells



# ***Gastric adenocarcinoma*** ***- diffuse type***

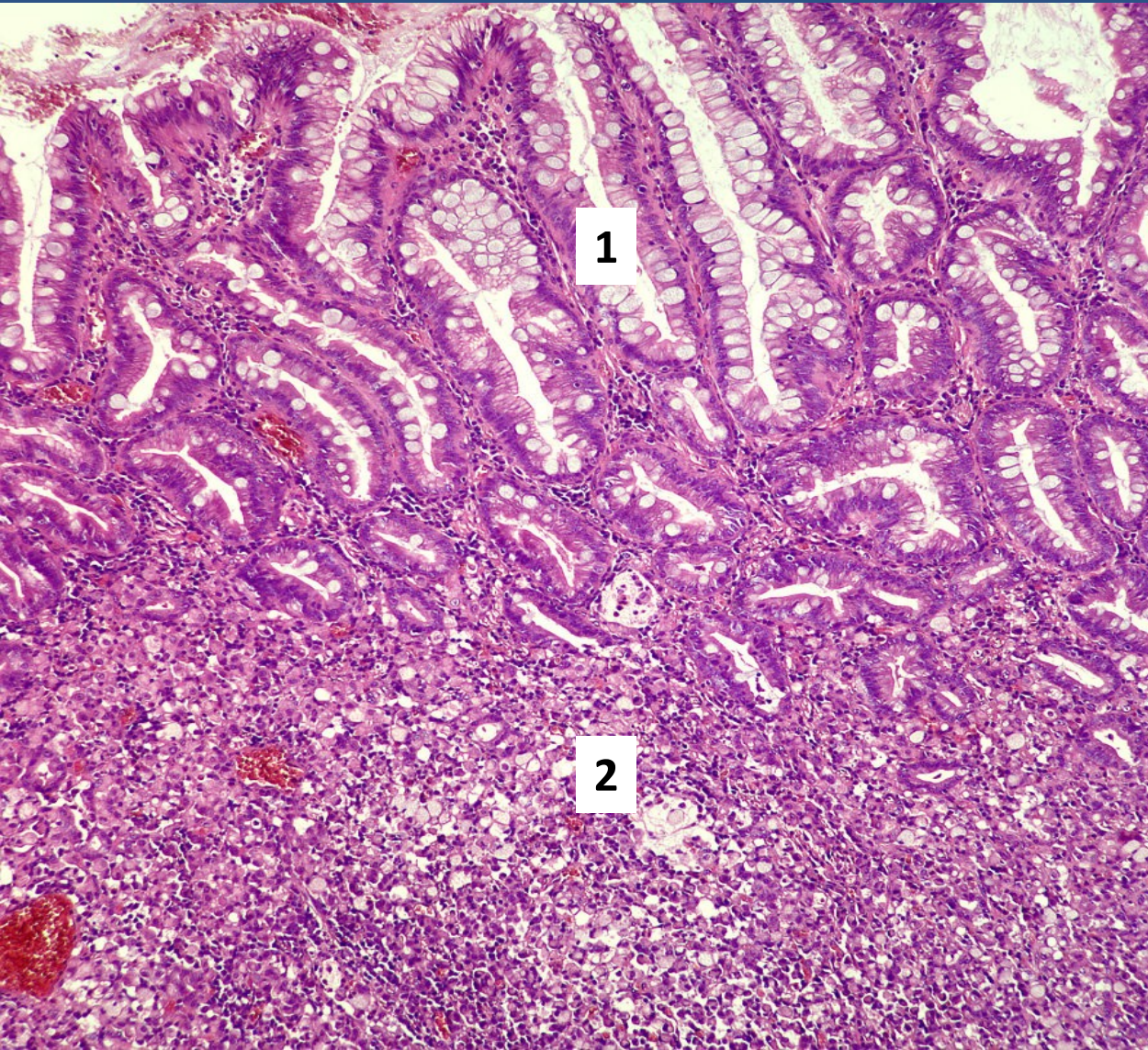


— 2CM —  
LLUMC  
**73s2853**

copy



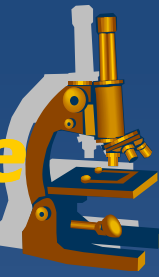
# *Gastric adenocarcinoma* *- diffuse type*



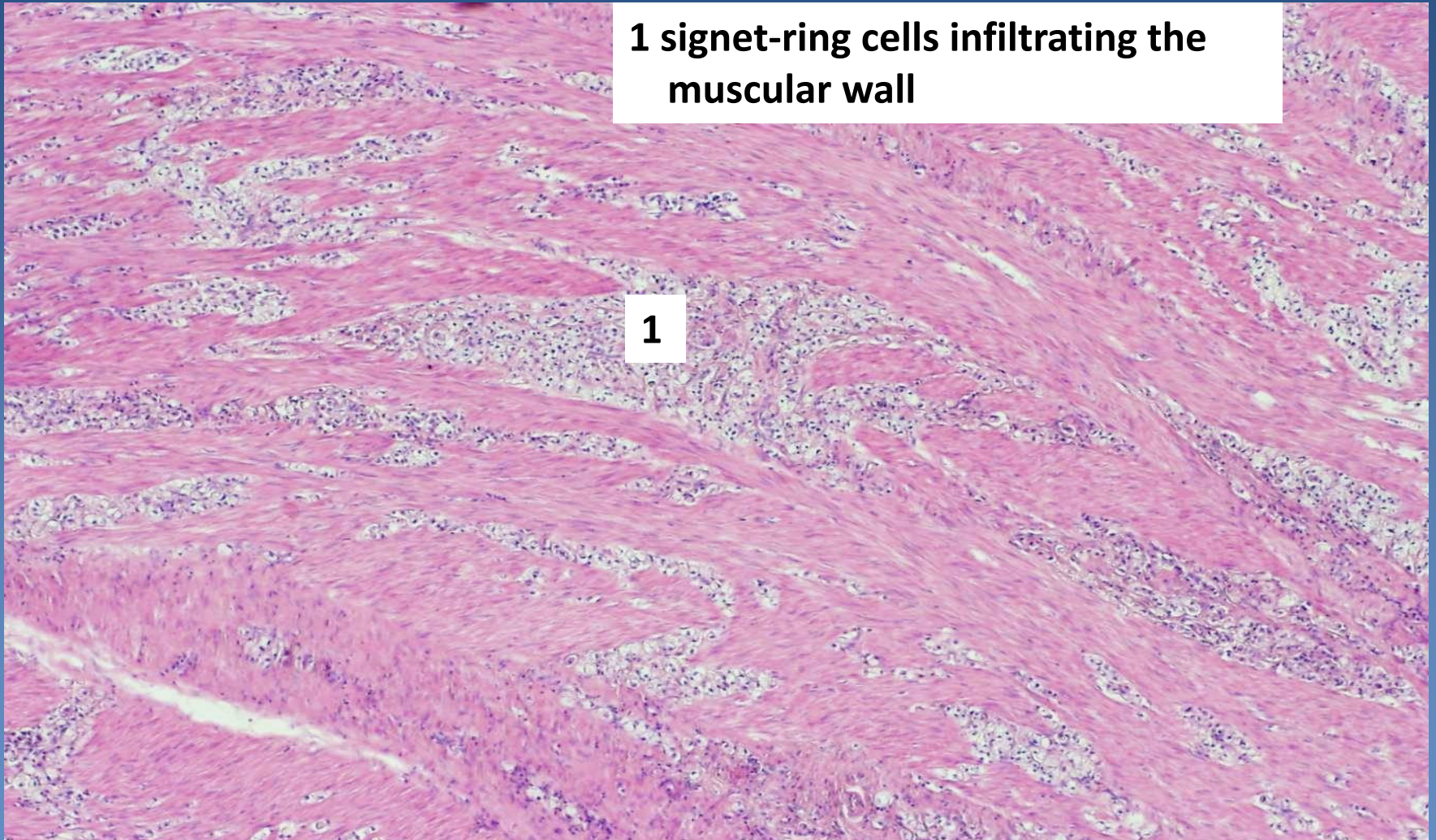
**1** intestinal metaplasia  
of the mucosa

**2** diffuse infiltration with  
signet-ring cells





# ***Gastric adenocarcinoma - diffuse type*** ***- infiltration into lamina muscularis propria***

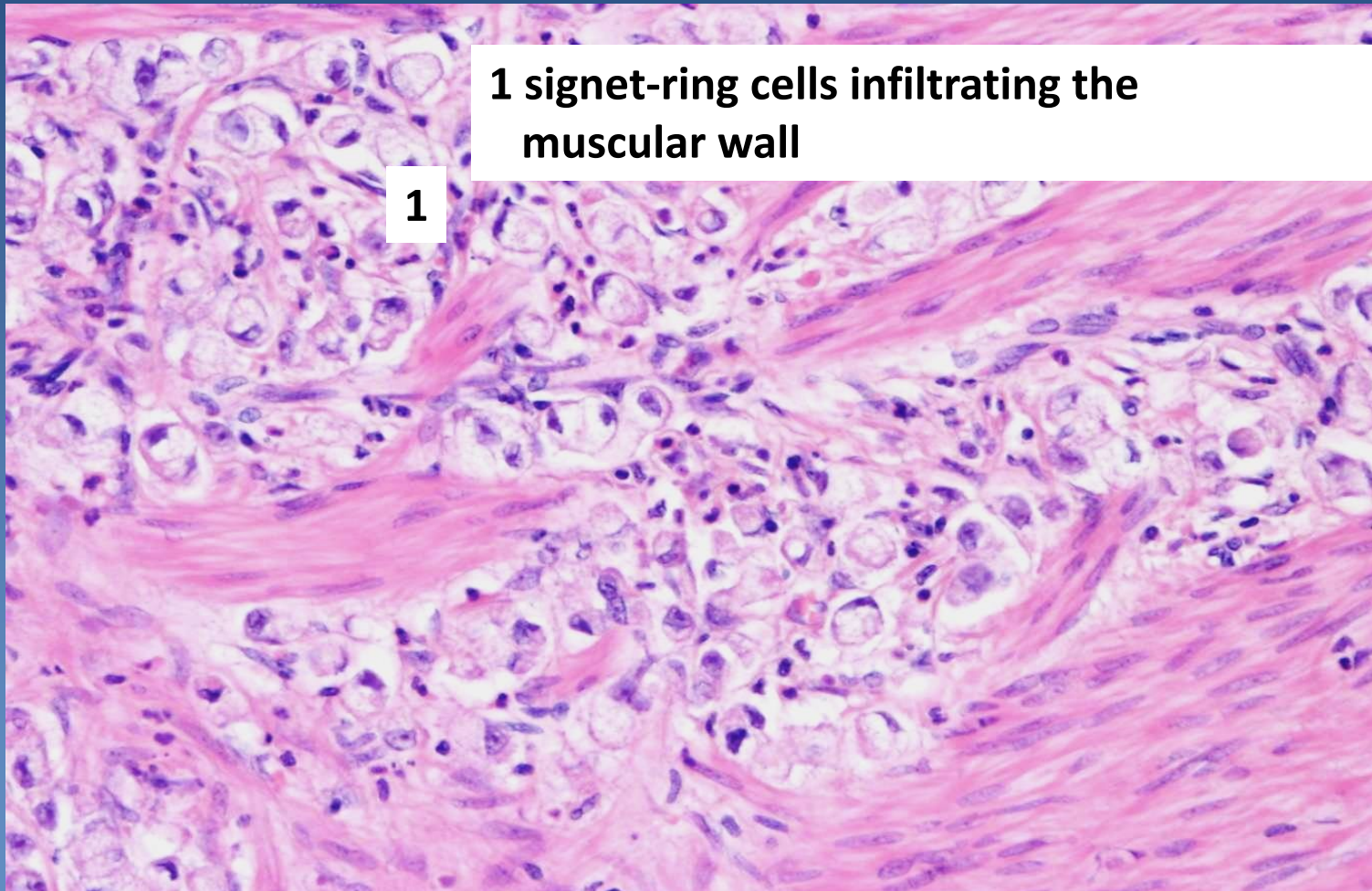
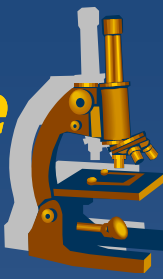


**1 signet-ring cells infiltrating the muscular wall**

**1**



# *Gastric adenocarcinoma - diffuse type detail*

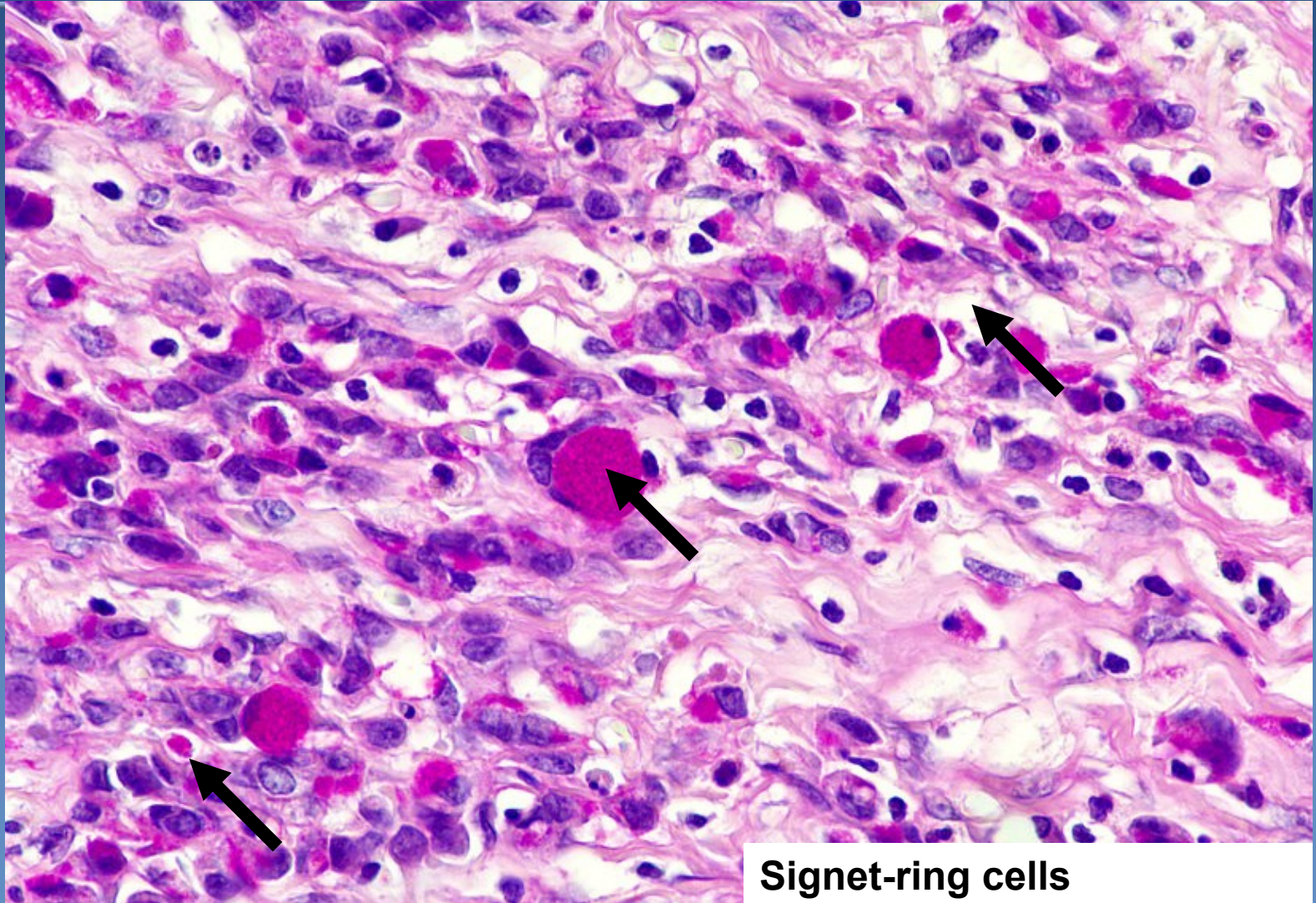
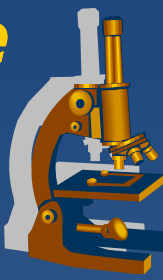


**1 signet-ring cells infiltrating the muscular wall**

**1**



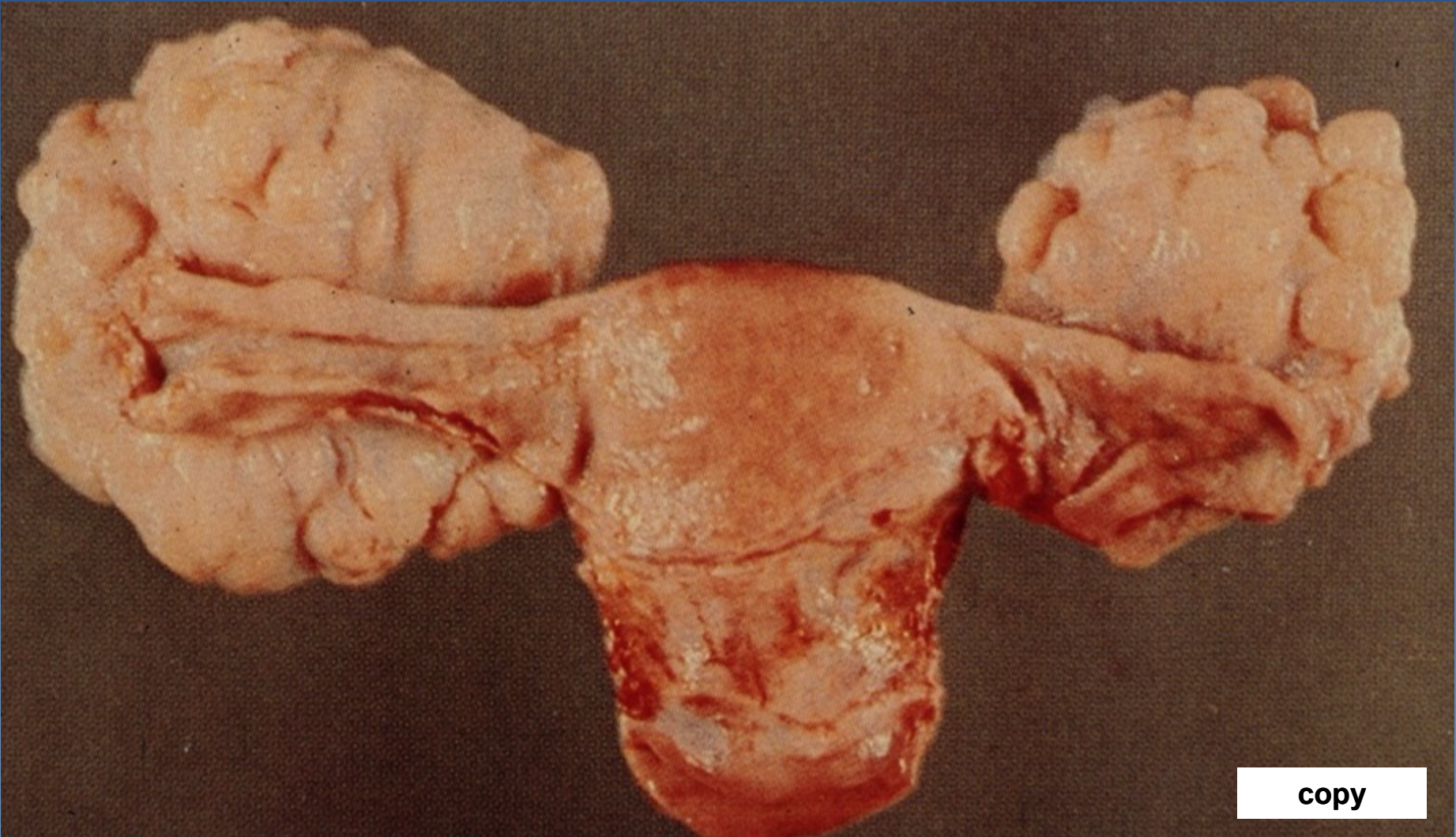
# *Gastric adenocarcinoma - diffuse type detail (PAS)*



**Signet-ring cells**

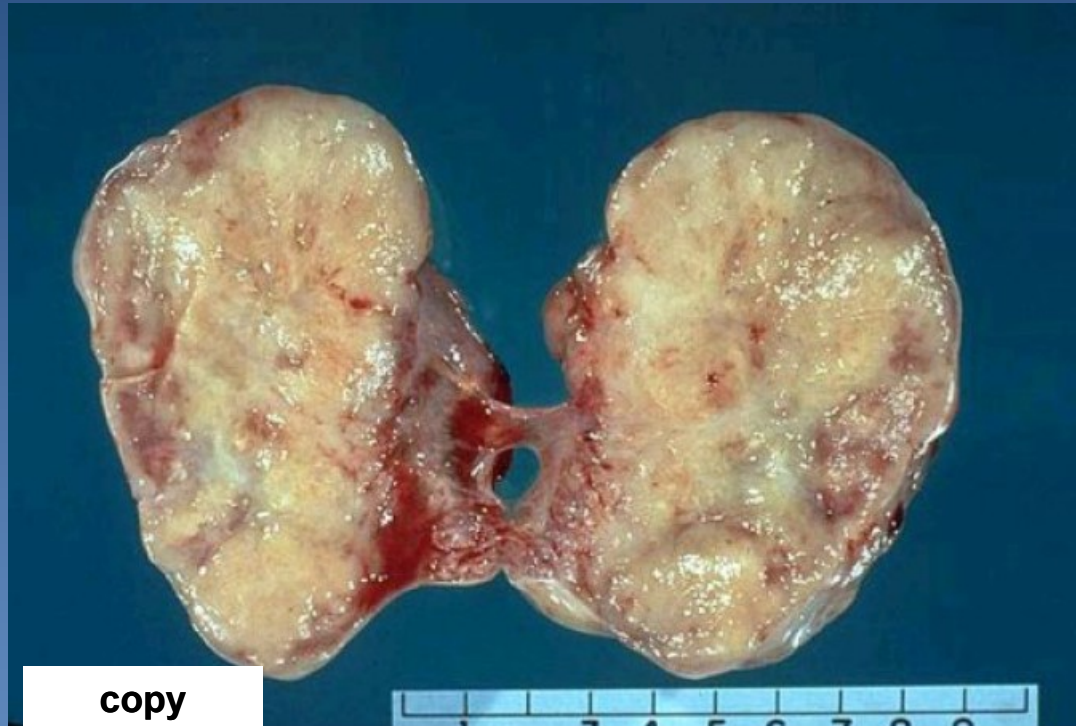


# *Krukenberg tumor*



copy

# *Krukenberg tumor*



copy

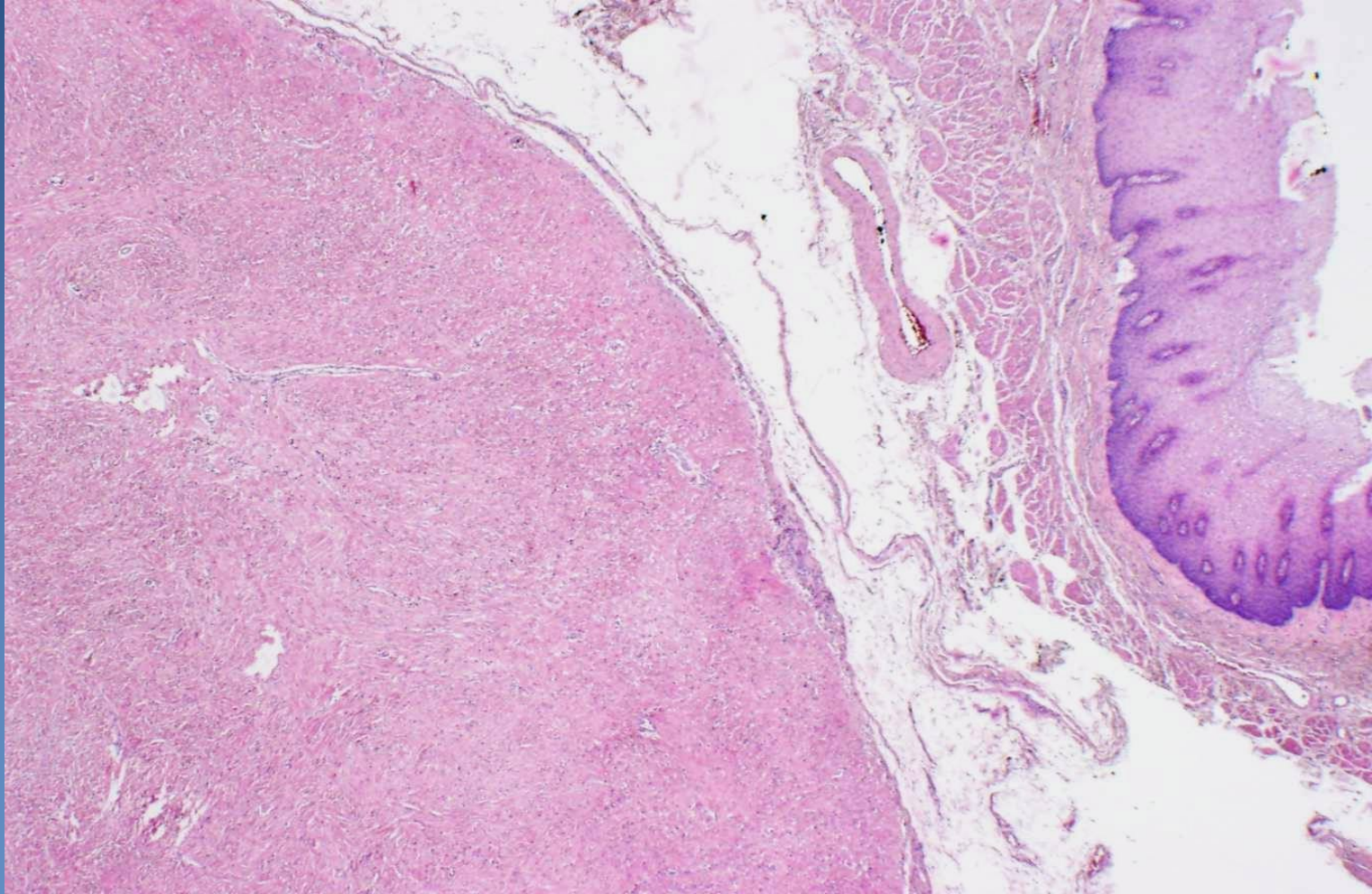
# ***Gastrointestinal stromal tumors (GISTs)***



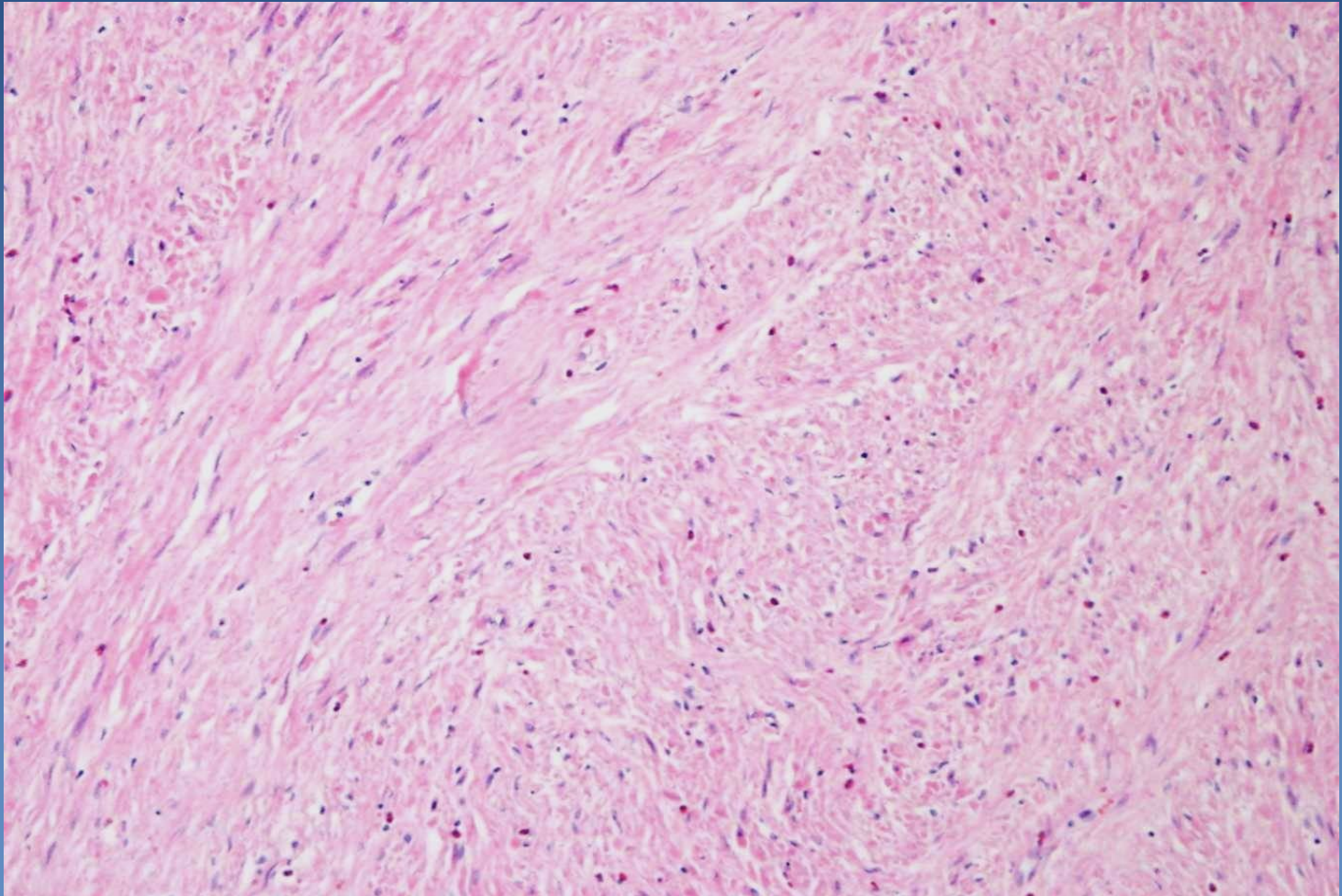
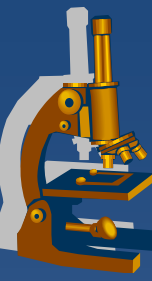
- ✗ mesenchymal tumors
- ✗ arising from intestinal cells of Cajal (pacemaker cells controlling peristalsis)
- ✗ origin anywhere in the GIT: predominantly the stomach and small intestine
- ✗ spindle-like or epitheloid cells, IHC CD117+,
- ✗ biologic behaviour prognosis :
  - ⇒ *according to mitotic rate, size, localization*



# *Oesophageal GIST*

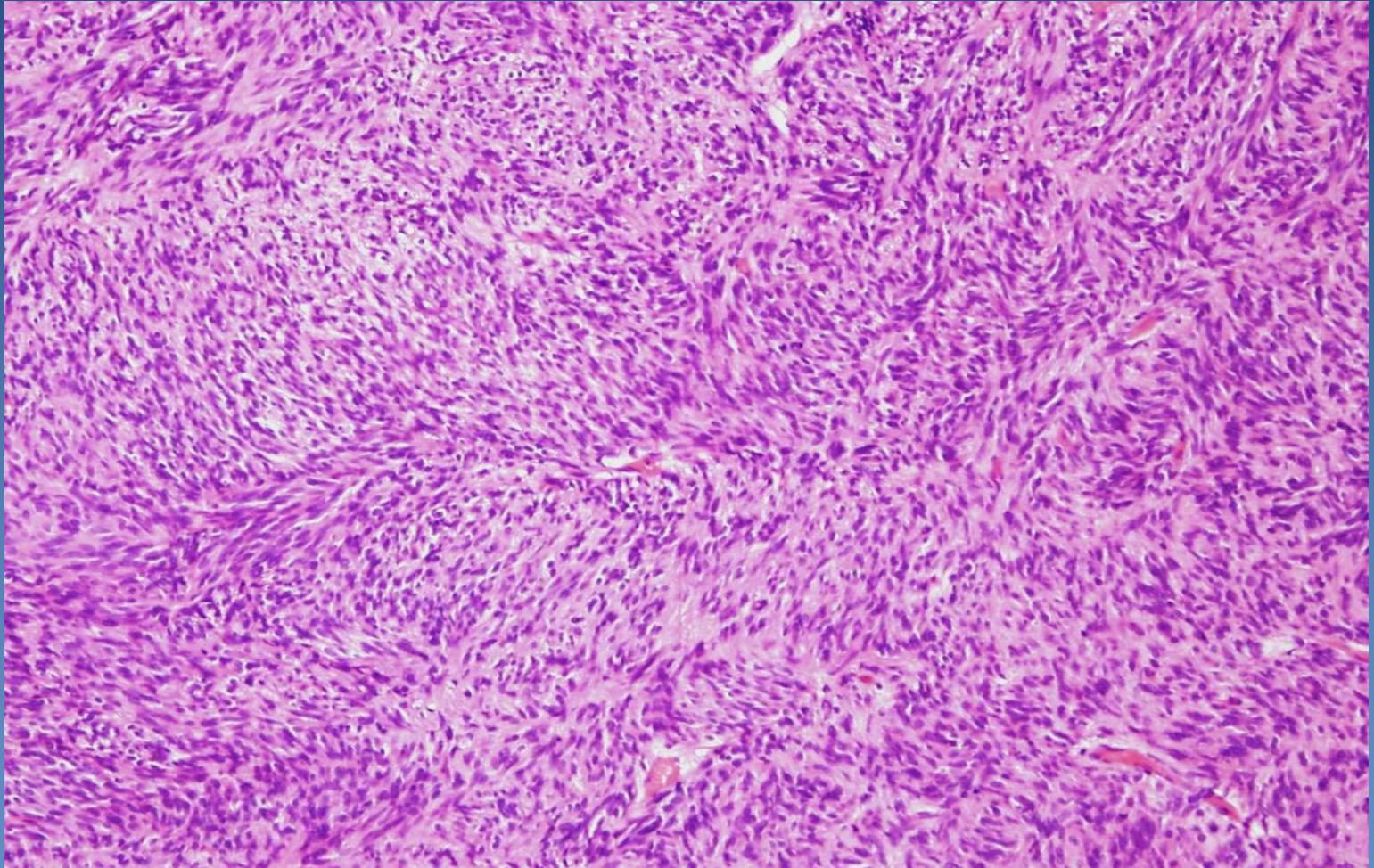
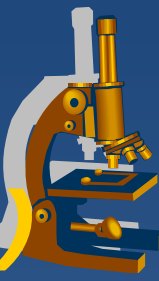


# ***Oesophageal GIST - detail (spindle-like cells, low malignancy)***



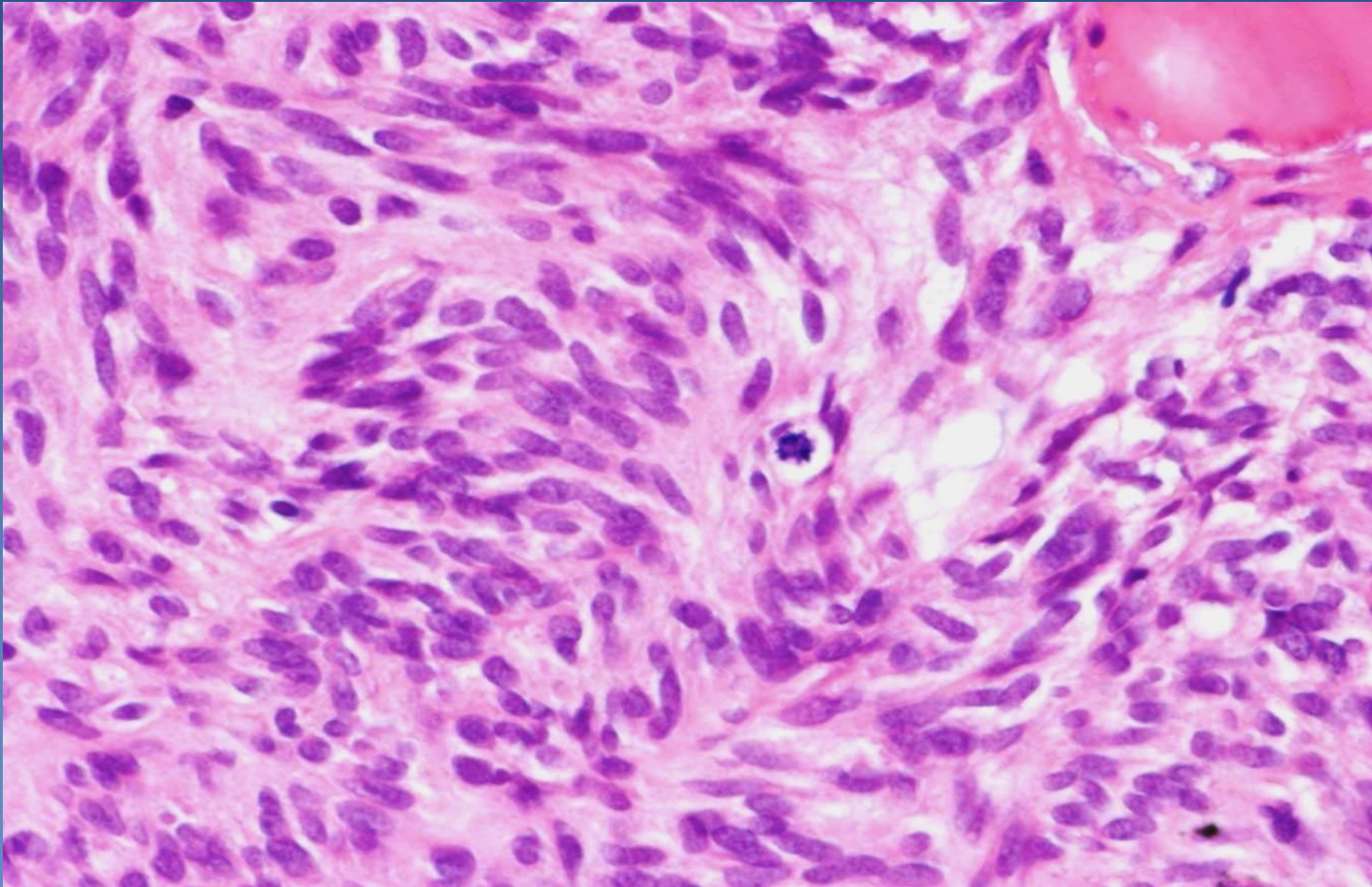


***Oesophageal GIST - detail  
(spindle-like cells, highly malignant)***



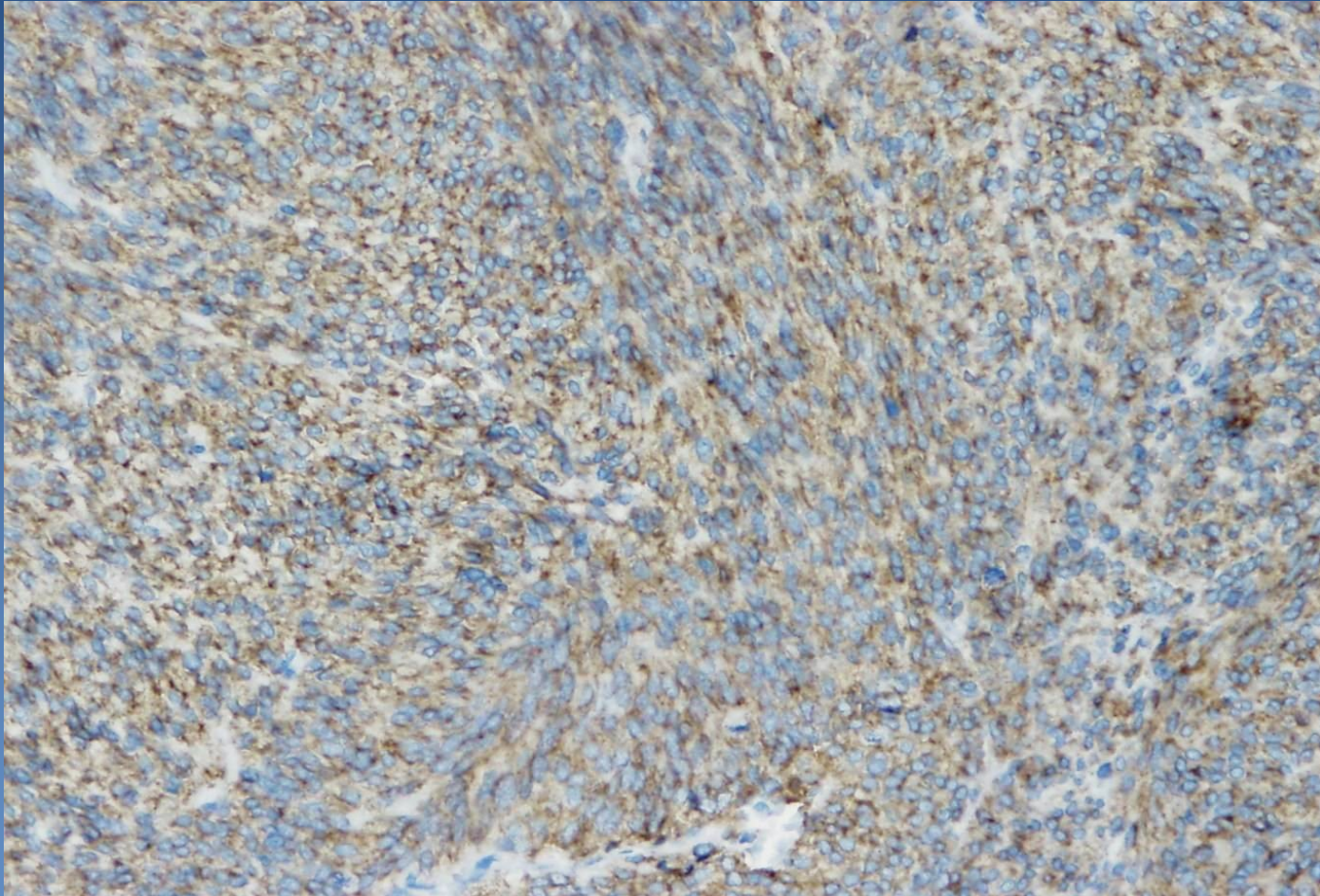
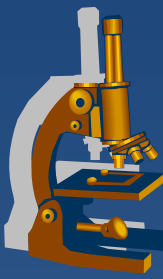


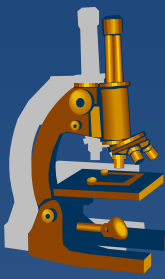
***Intestinal GIST - detail  
(spindle-like cells, highly  
malignant)***



# ***Intestinal GIST***

***IHC CD117 positivity***





---

# ***INTESTINES***



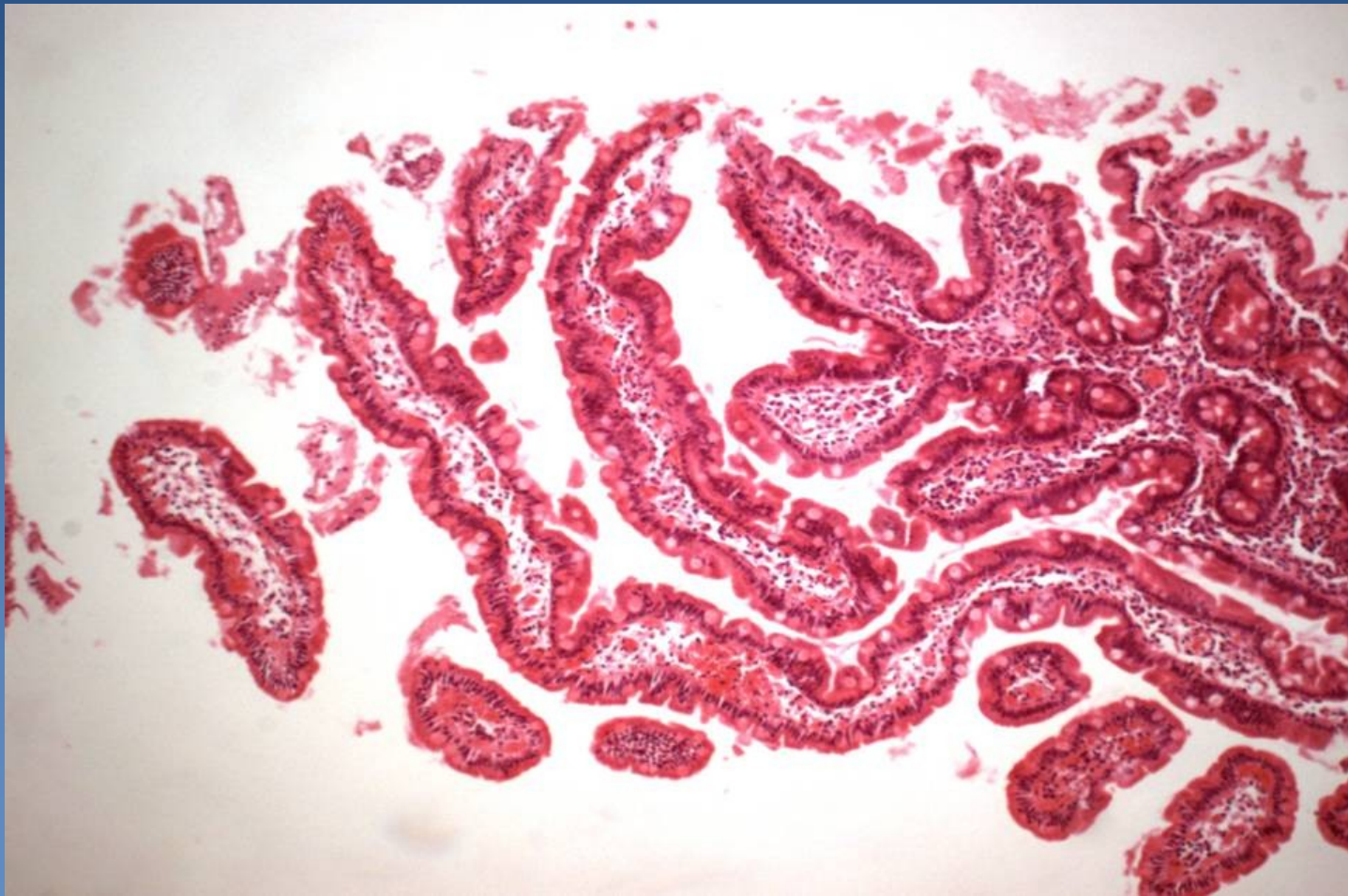# ***Normal mucosa of the small intestine***

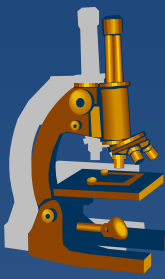
---



- x villi to crypts height ratio 3:1 – 5:1**
- x standard number of intraepithelial lymphocytes: 40 IEL / 100 enterocytes**
  - ⇒ *brush border – microvilli (PAS+, alkaline phosphatase +)*
  - ⇒ *differentiated enterocytes*

# ***Normal villi of the small intestine***





# Malabsorption syndromes

- x a group of symptoms resulting from an alteration in the digestion / absorption of nutrients mostly in the small intestine
- x symptoms:
  - ⇒ *anorexia, diarrhea, steatorrhea, weakness, weight loss, abdominal distention,*
  - ⇒ *growth disturbances, eczema, neurologic/psychologic disturbances, bleeding disorders, anaemia, tetany*
- x disturbance of:
  - ⇒ **digestion** *intraluminal, terminal in the brush border*
  - ⇒ **mucosal absorption** - *enterocytes abnormalities, reduced intestinal surface area*
  - ⇒ *lymphatic transport*





# ***Malabsorption syndromes***

---

- x** Classification

  - ⇒ ***primary*** – enterocytes' disorder (inborn, acquired)

  - ⇒ ***secondary*** – cause apart from enterocytes

- x** commonly mixed causes

# *Defects of mucosal absorption*

---



- × **Brush border enzymatic deficiency** (lactose intolerance – lactase deficiency)
  
- × **Celiac disease** gluten (gliadin)-sensitive enteropathy

# *Celiac disease*



- x prevalence 0,5-1% in Caucasian Europeans
- x associated with dermatitis herpetiformis  
Duhring, DM I., Sjögren sy, etc.
- x immunological sensitivity to gluten (component  
of wheat)
- x antibodies EMA, ARA, TG (non-specific anti-  
gliadin)
- x genetic (HLA), immune, exogenous factors



# Celiac disease



- x gluten-free diet necessary, sm. lifelong
- x risk of malignant disease:
  - ⇒ *malignant lymphomas (T-cell), carcinomas of the small intestine*
- x clinical
  - ⇒ *infancy (6-24 m.), adults 30-60 yrs; silent, latent*
- x symptoms:
  - ⇒ *irritability, diarrhoea, fatigue...*
- x endoscopy:
  - ⇒ *loss of mucosal folds, mosaic mucosal pattern, prominence of the submucosal vessels*

# Celiac disease



- x micro: most changes in the proximal part of the small intestine
- x basic histologic features:
  - ⇒ *increased number of intraepithelial T-cells*
  - ⇒ *inflammatory infiltrate (plasma cells, eosinophils, neutrophils, T-cells) in lamina propria mucosae*
  - ⇒ *villous atrophy*
  - ⇒ *reactive hyperplasia (elongation) of the crypts*

# Marsh classification 0-IV



- ✘ Stage 0: normal mucosa
- ✘ Stage I: infiltrative
  - ⇒ *increased number of IEL*
- ✘ Stage II: hyperplastic
  - ⇒ *proliferation of the crypts*
- ✘ Stage III: destructive
  - ⇒ *villous atrophy*
- ✘ Stage IV: hypoplastic
  - ⇒ *crypt hypoplasia, loss of villi*



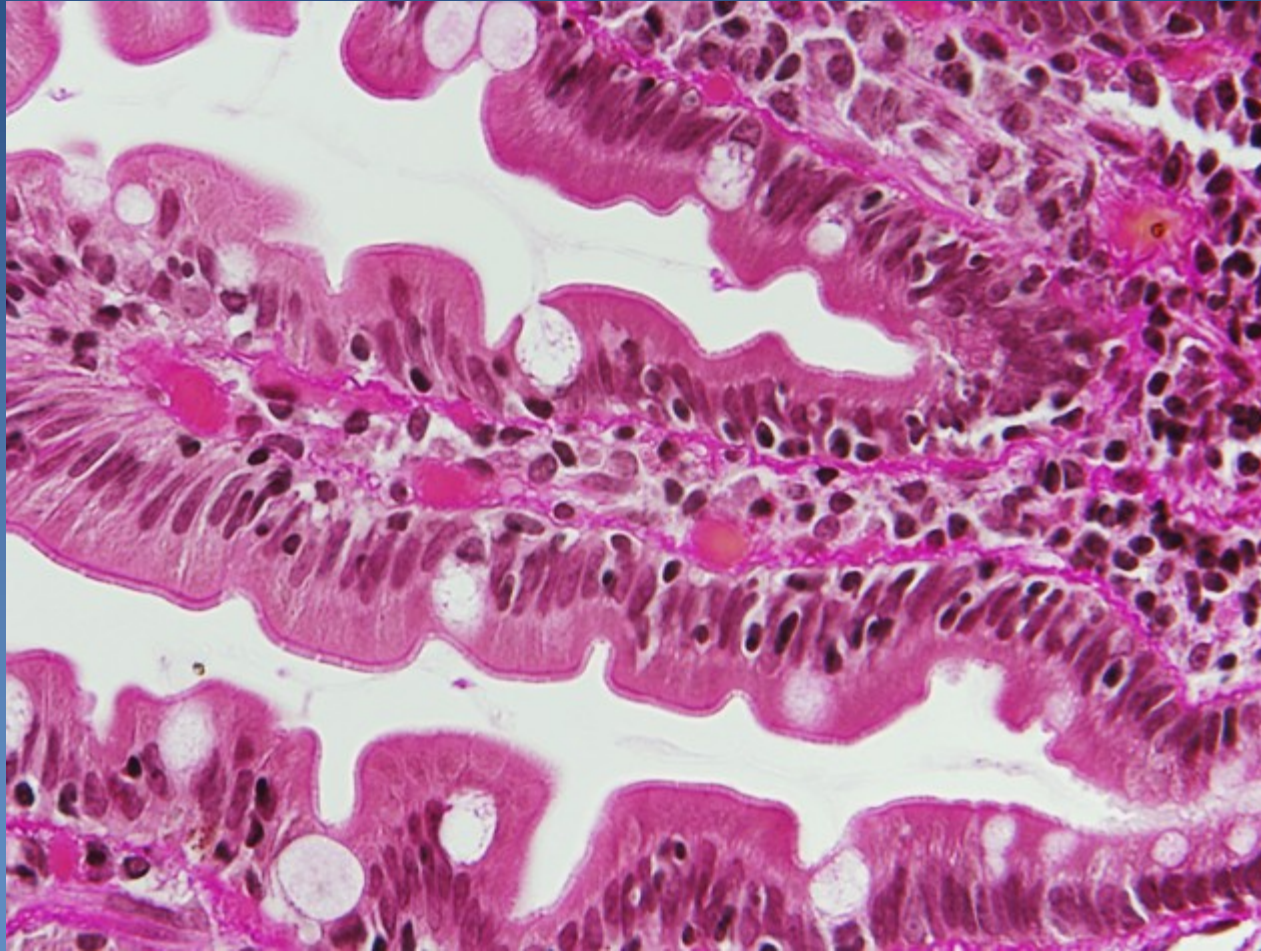
# *Celiac disease*



- ✘ IEL – specific activated CD8+ T-cell subpopulation
- ✘ direct cytotoxic activity – killing of enterocytes
- ✘ increased enterocytes' turnover
- ✘ non-specific histology – diff. dg. alimentary allergies, viral infections, giardiasis, tropical sprue

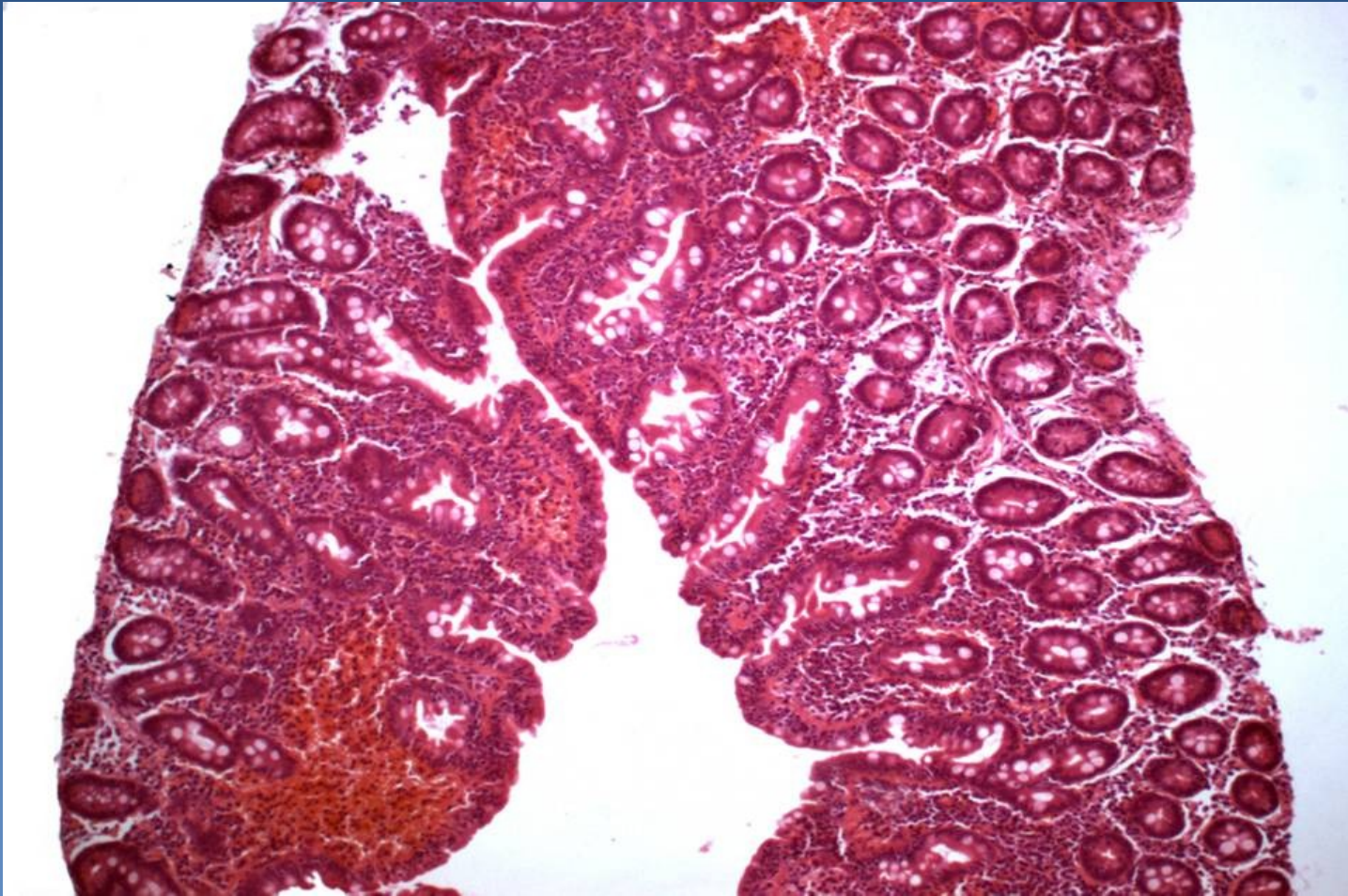
# *Celiac disease*

## *Marsh I*



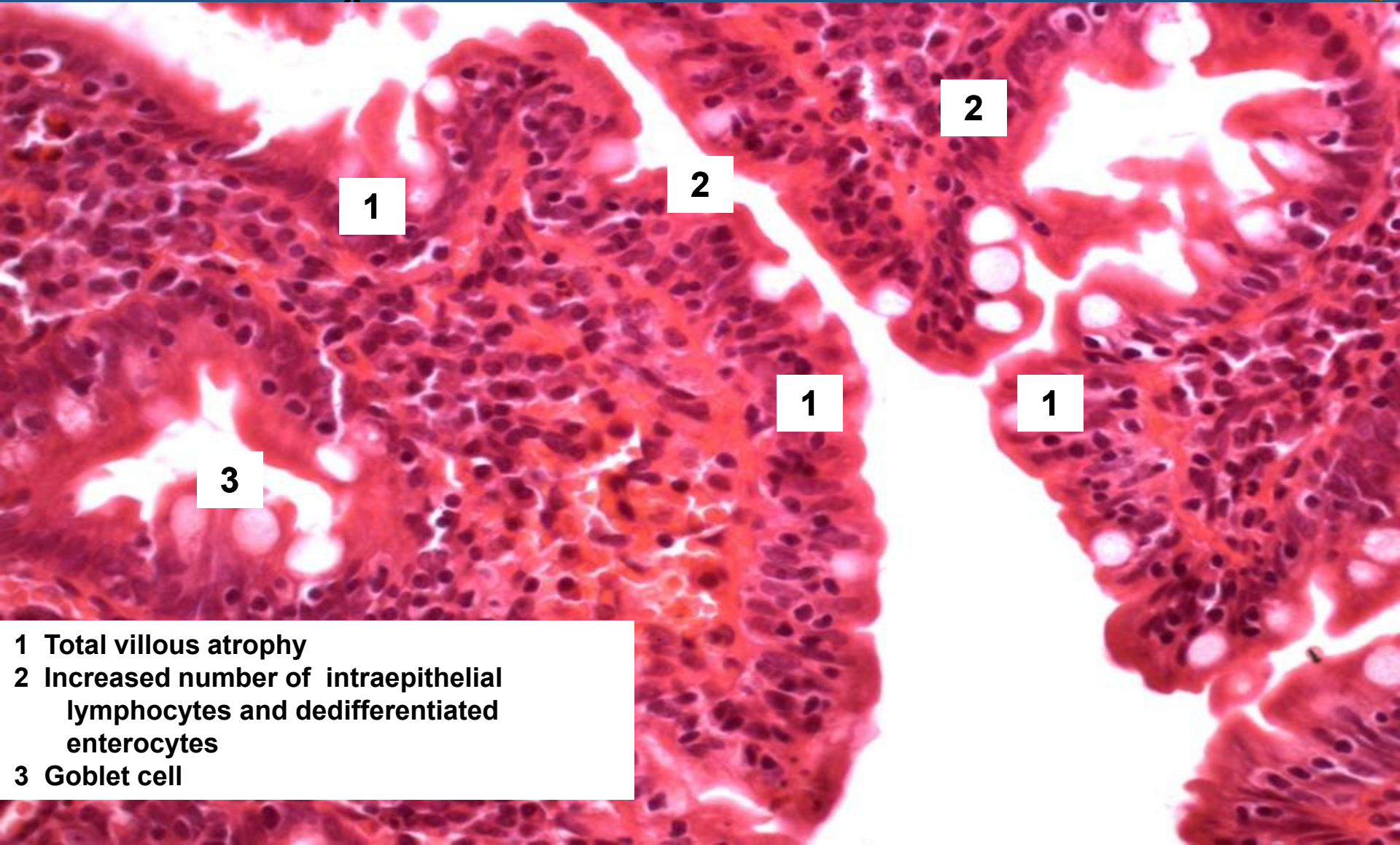
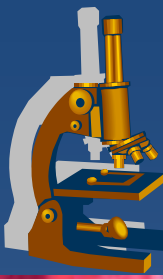
# ***Celiac disease***

## ***Marsh IIIc***





# *Celiac disease atrophic mucosa - detail*



1

2

2

1

1

3

- 1 Total villous atrophy
- 2 Increased number of intraepithelial lymphocytes and dedifferentiated enterocytes
- 3 Goblet cell

# *Inflammatory bowel disease (IBD)*



- ✗ idiopathic, chronic relapsing inflammatory disorders of not completely known origin
- ✗ genetic predisposition, immunologic factors
- ✗ etiology:
  - ⇒ *aberrant local immune response to exogenous stimulus (microbiome) → increased transepithelial permeability → inflammation acceleration*
- ✗ **Crohn disease**
- ✗ **Ulcerative colitis**
- ✗ **Indeterminated colitis (10-15%)**

# ***IBD***



## **x common histologic features:**

- 1) abnormal crypt architecture**
- 2) crypt atrophy**
- 3) dense inflammatory infiltrate in lamina propria, basal plasmacytosis**
- 4) Paneth cell metaplasia in the left colon**



# Crohn's disease



## x Clinical features:

- ⇒ *recurrent attacks of diarrhea, abdominal pain, fever*
- ⇒ *abrupt beginning, lasting days to weeks, symptom-free intervals,*
- ⇒ *common other AI diseases:*
  - iritis, ankylosing spondylitis, erythema nodosum, PSC

## x Gross:

- ⇒ ***terminal ileum**, or anywhere else in the GIT (oral-anus)*
- ⇒ ***sharply demarcated , segmental lesions and skip lesions:***
  - shallow → longitudinal ulcers
  - wall stenosis and thickening, fissuring, fistulae

# Crohn's disease



## x Histology:

- ⇒ **transmural** inflammatory infiltrate
- ⇒ formation of lymphatic follicles/germinal centres
- ⇒ **non-caseating granulomas** (not always present) in submucosa, subserosa and regional lymph nodes
- ⇒ fissuring, ulceration
- ⇒ fibrosis

# *Crohn's disease*

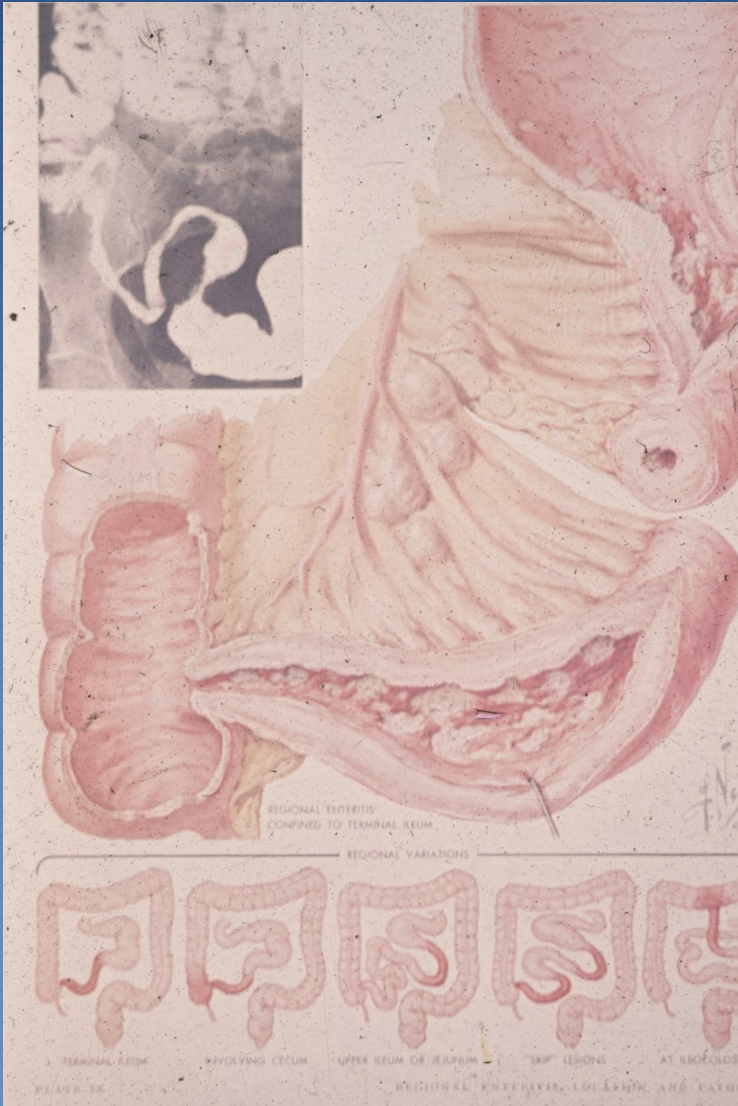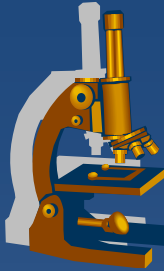


## **x** Complications:

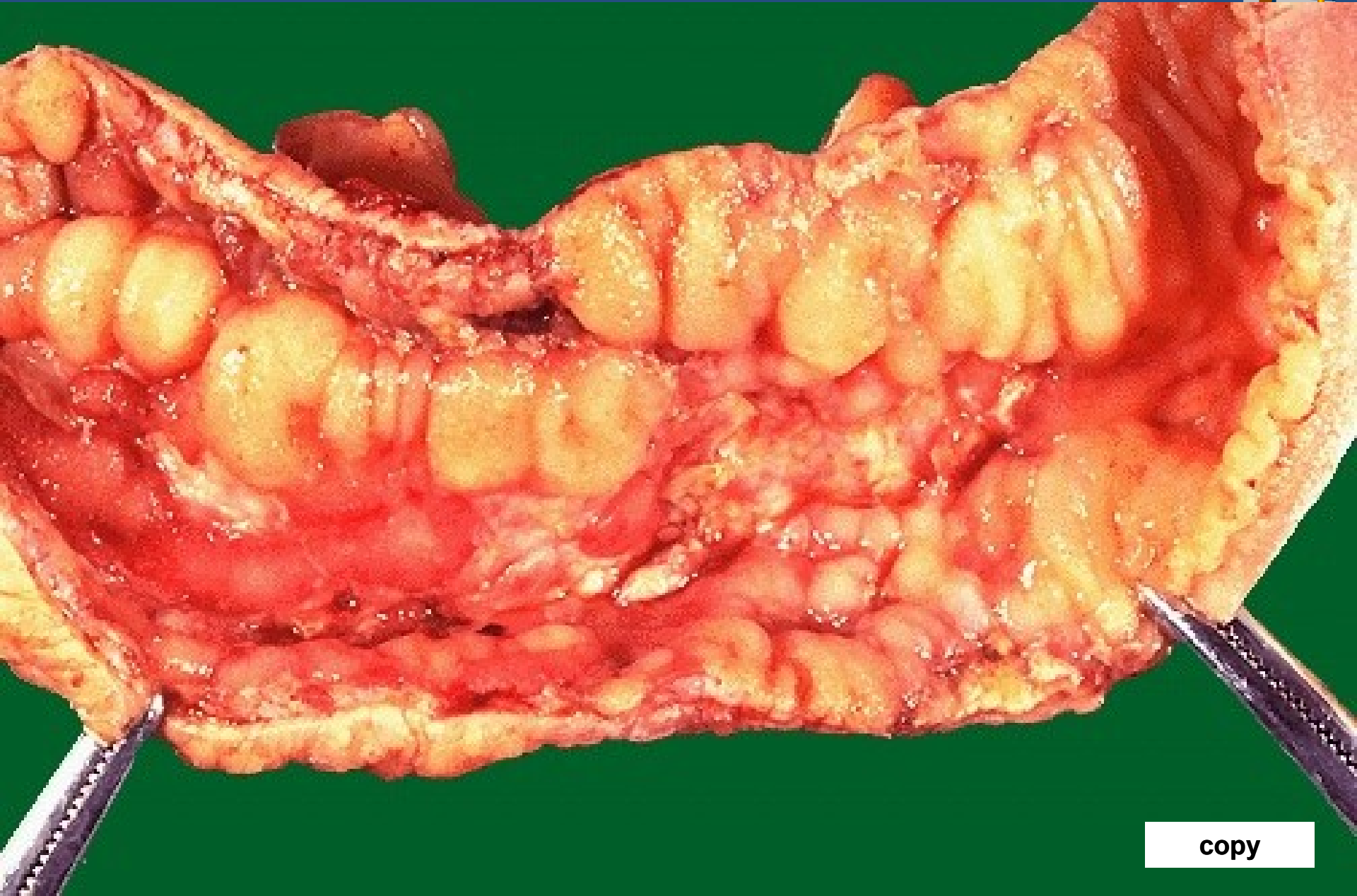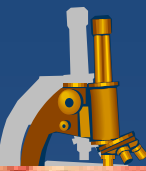
- ⇒ *narrowed lumen, intestinal strictures, obstruction*
- ⇒ *malabsorption, protein loss*
- ⇒ *perforation, peritonitis, fistulae formation*
- ⇒ *hemorrhage*
- ⇒ *systemic AA amyloidosis*
- ⇒ *carcinoma*



# Crohn's disease



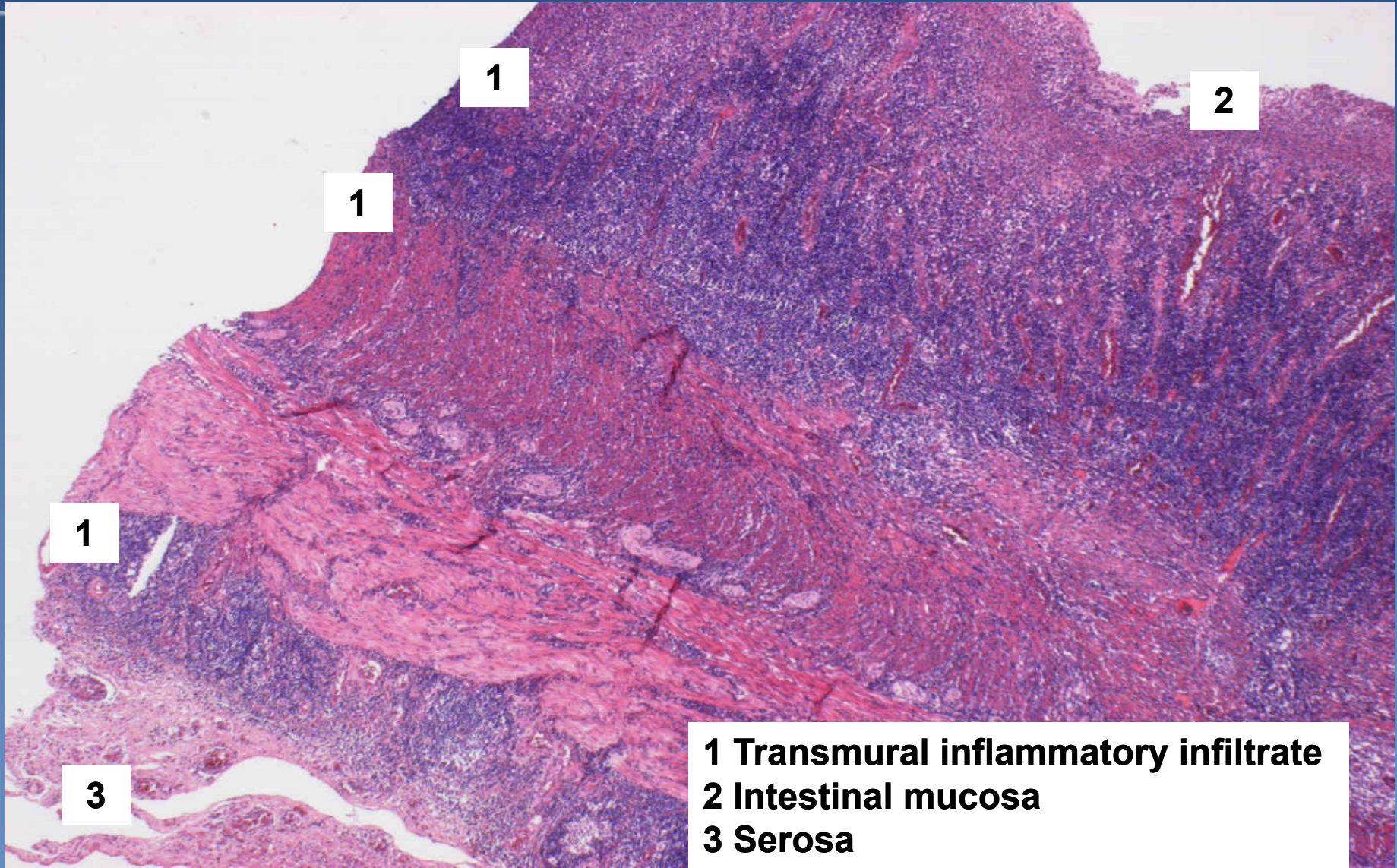
# *Crohn's disease*



copy



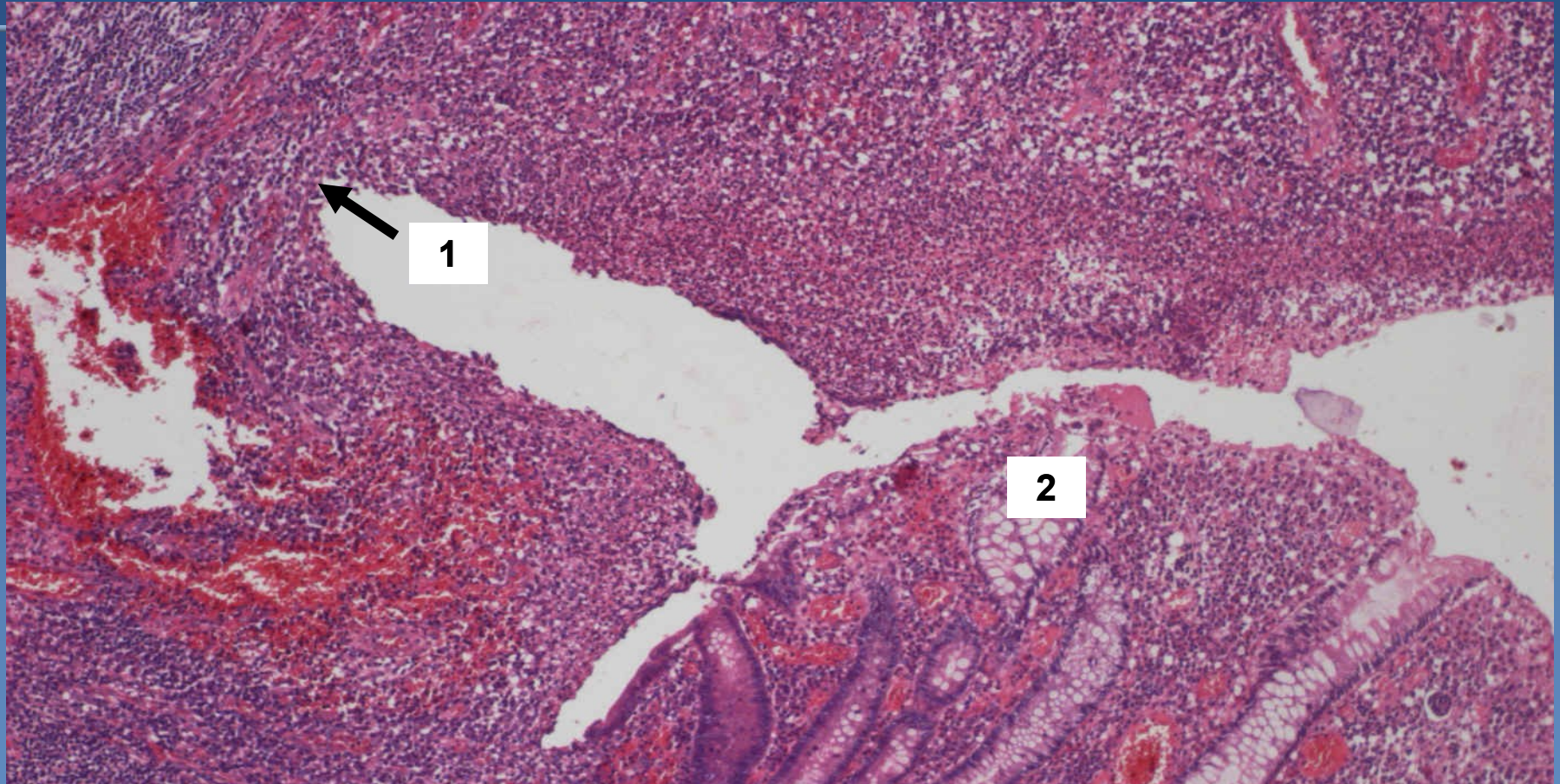
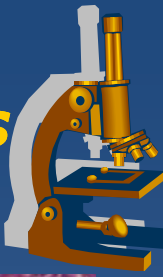# ***Crohn's disease in the colon*** ***(transmural chronic inflammatory infiltrate)***



- 1 Transmural inflammatory infiltrate**
- 2 Intestinal mucosa**
- 3 Serosa**



# ***Crohn's disease - Enteritis regionalis***



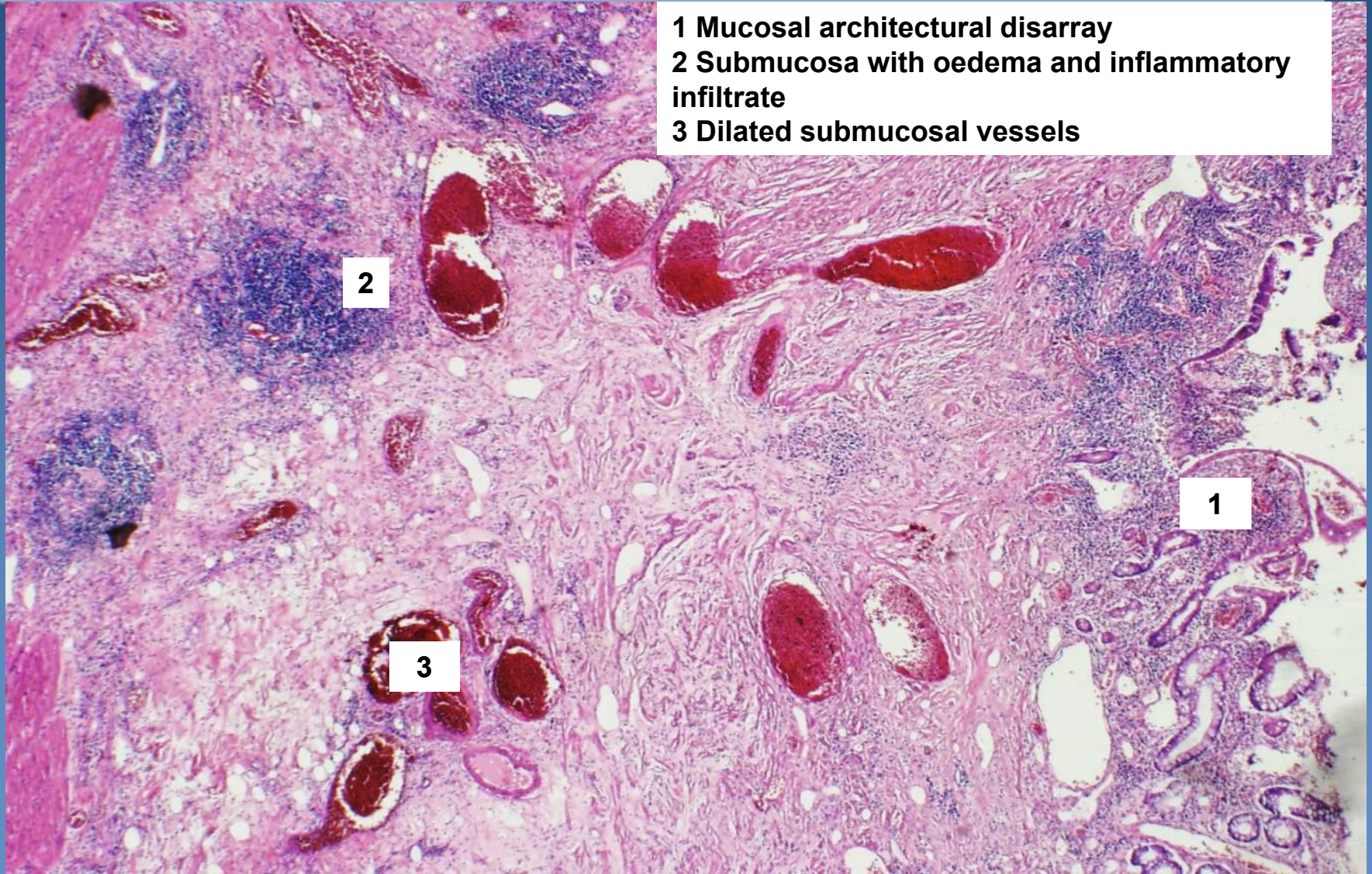
**3**

- 1 Fissure in the mucosa**
- 2 Crypt without dysplastic changes**
- 3 Dense chronic inflammatory infiltrate**



# ***Crohn's disease***

## ***inflammatory infiltrate in the submucosa***



- 1 Mucosal architectural disarray**
- 2 Submucosa with oedema and inflammatory infiltrate**
- 3 Dilated submucosal vessels**

**2**

**1**

**3**

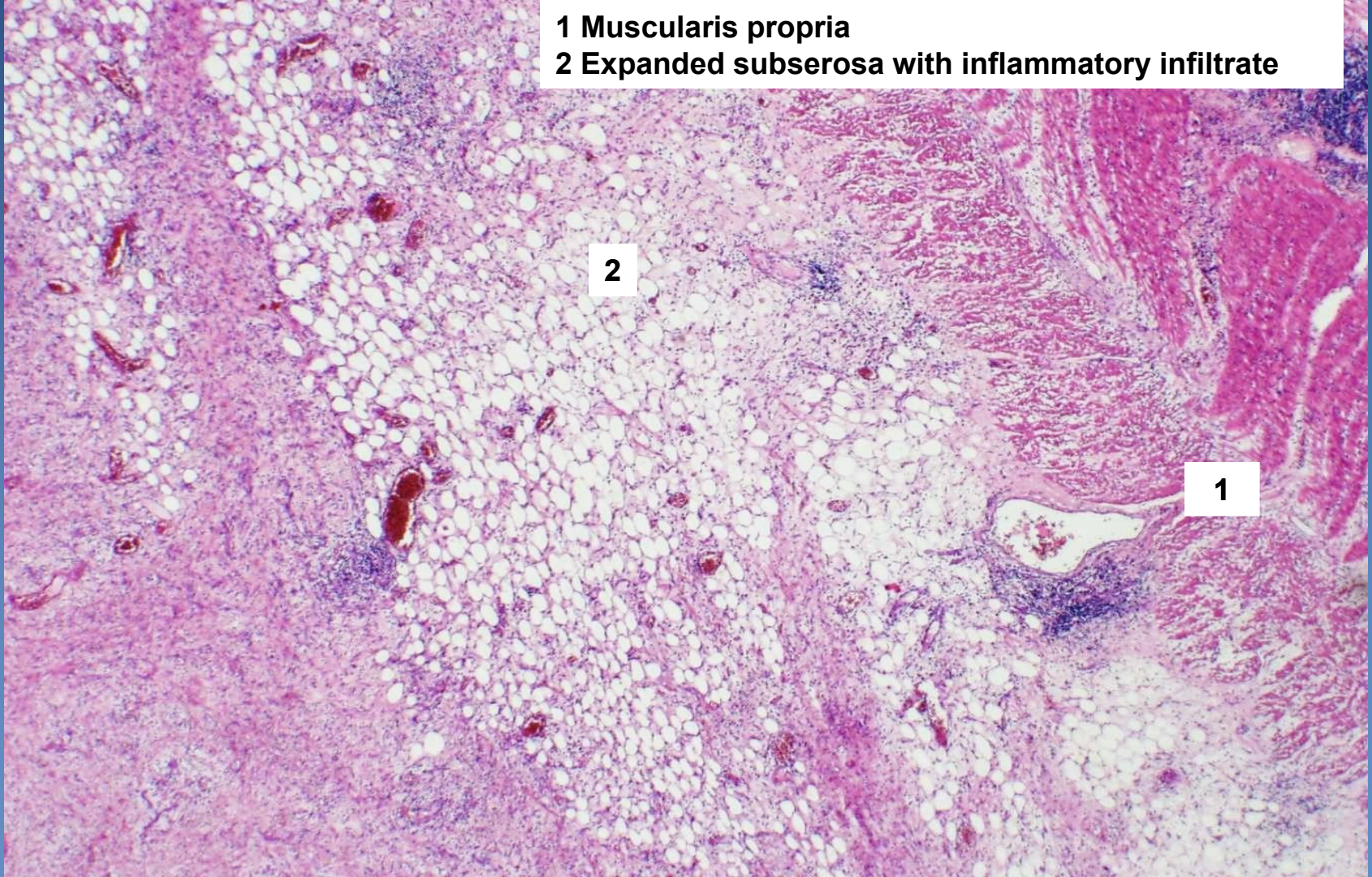


# ***Crohn's disease***

## ***inflammatory infiltrate in the subserosa***



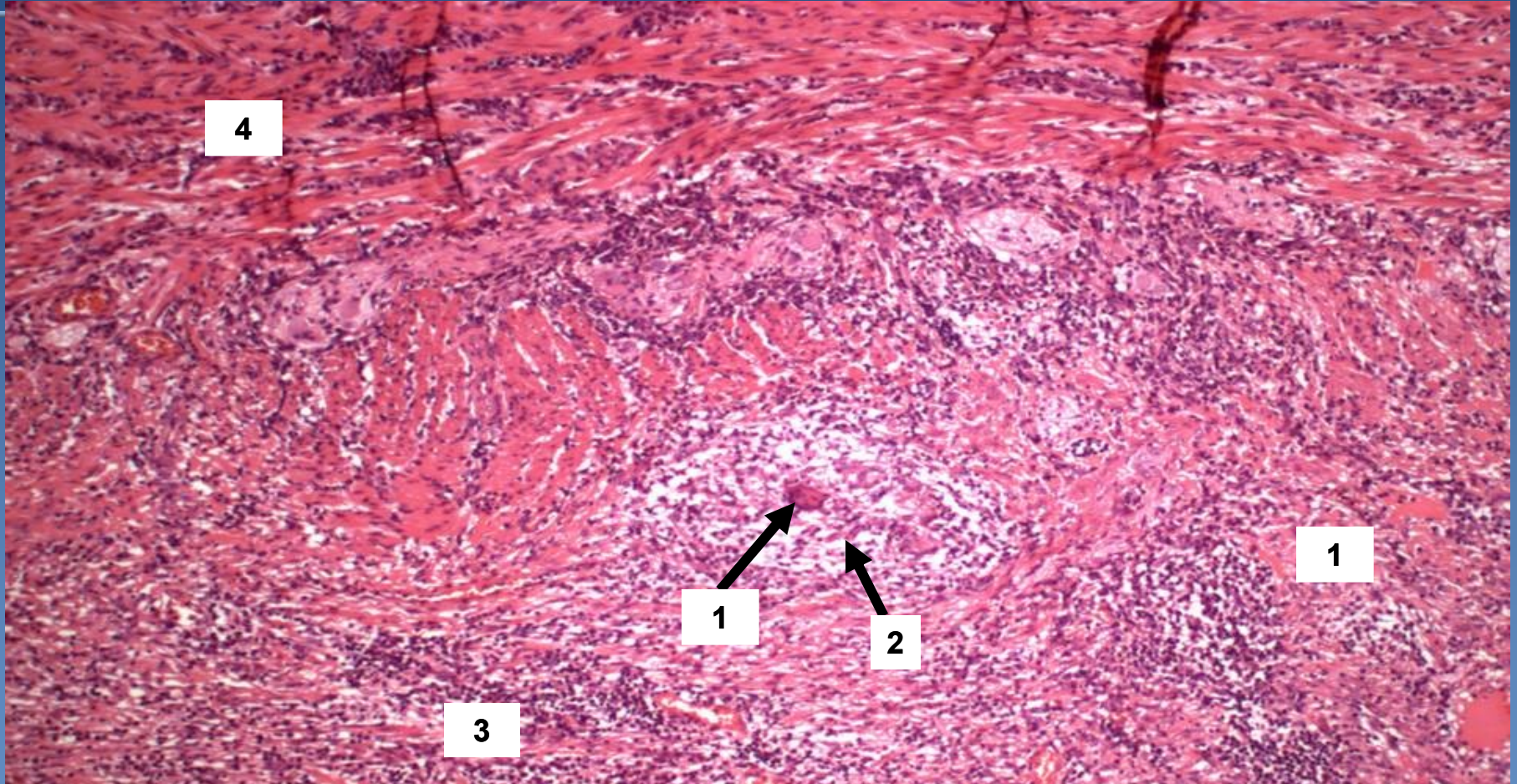
**1 Muscularis propria**  
**2 Expanded subserosa with inflammatory infiltrate**





# ***Crohn's disease***

## ***- granuloma in the submucosa***

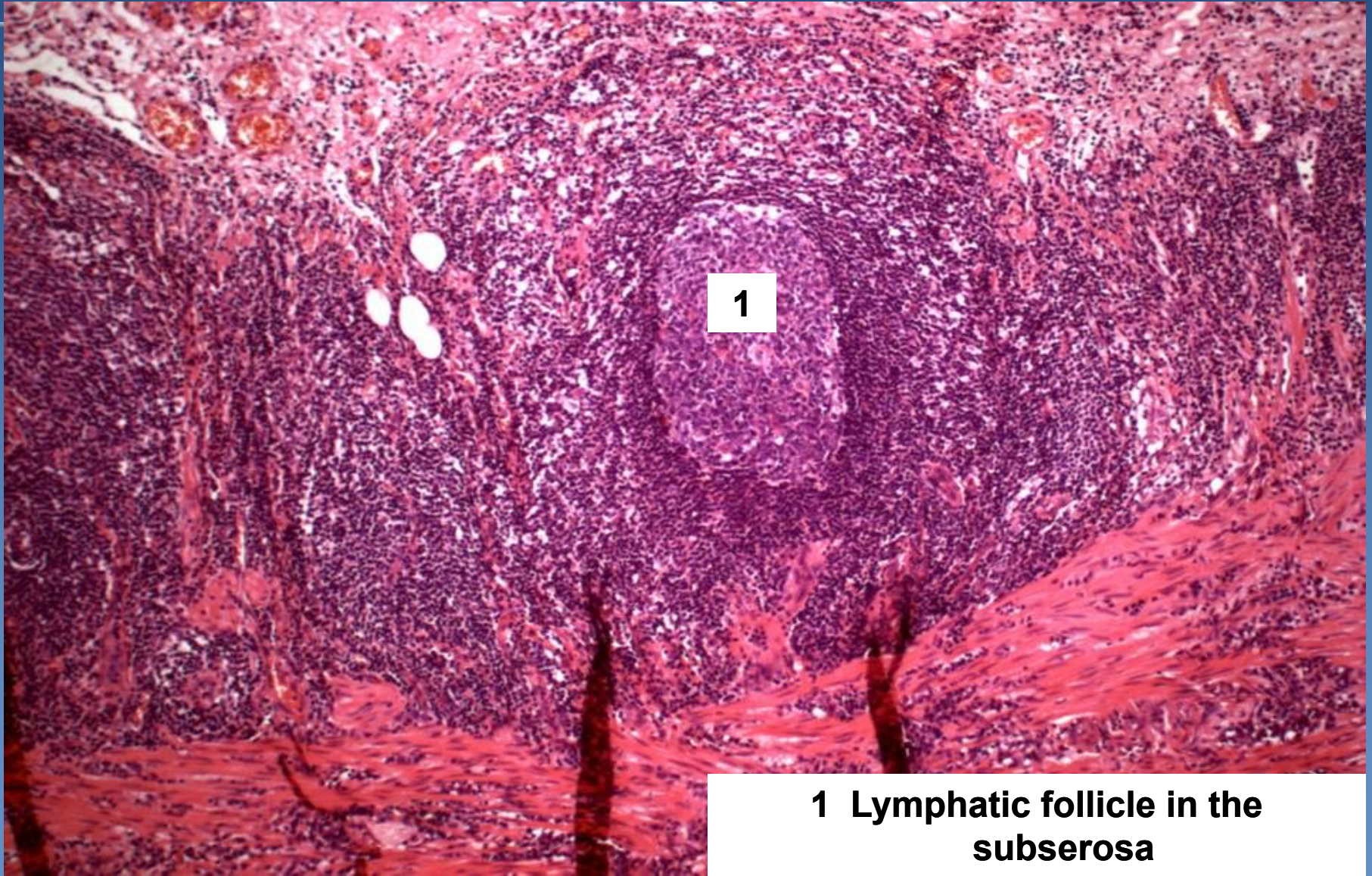
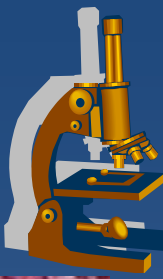


- 1 Multinucleated giant cell
- 2 Granuloma in the submucosa
- 3 Inflammatory infiltrate in the submucosa
- 4 Muscularis propria with inflammatory infiltrate



# ***Crohn's disease***

## ***- inflammatory infiltrate***



**1 Lymphatic follicle in the subserosa**



# ***Ulcerative colitis***

## ***x Clinical features:***

---

- ⇒ relapsing attacks of bloody mucoid diarrhea, cramps, lower abdominal pain***
- ⇒ start - rectum + sigmoid, continuous retrograde extension, may affect the entire **colon** (pancolitis)***
- ⇒ unclear etiology, autoimmune and genetic factors, variable triggers***
- ⇒ associated with systemic disorders (eye, skin, joint, bile tract – primary sclerosing cholangitis)***

## ***x Gross:***

- ⇒ hyperemia, oedema, flat **ulcerations**, regenerative hyperplastic mucosa forming pseudopolyps***



# *Ulcerative colitis*



## **x** Micro:

- ⇒ *non-specific inflammatory infiltrate only in the mucosa and submucosa*
- ⇒ *crypt abscesses, crypt destruction*
- ⇒ *no granulomas, no skip lesions*
- ⇒ *very little fibrosis, no mural thickening*
- ⇒ *high risk of carcinoma development*

# *Ulcerative colitis*



## **x** Microscopic phases of the inflammation:

### ⇒ **1. active**

- hyperemia, mixed inflammatory infiltrate, crypt abscesses

### ⇒ **2. healing**

- less neutrophils, no crypt abscesses, epithelial regeneration

### ⇒ **3. remission**

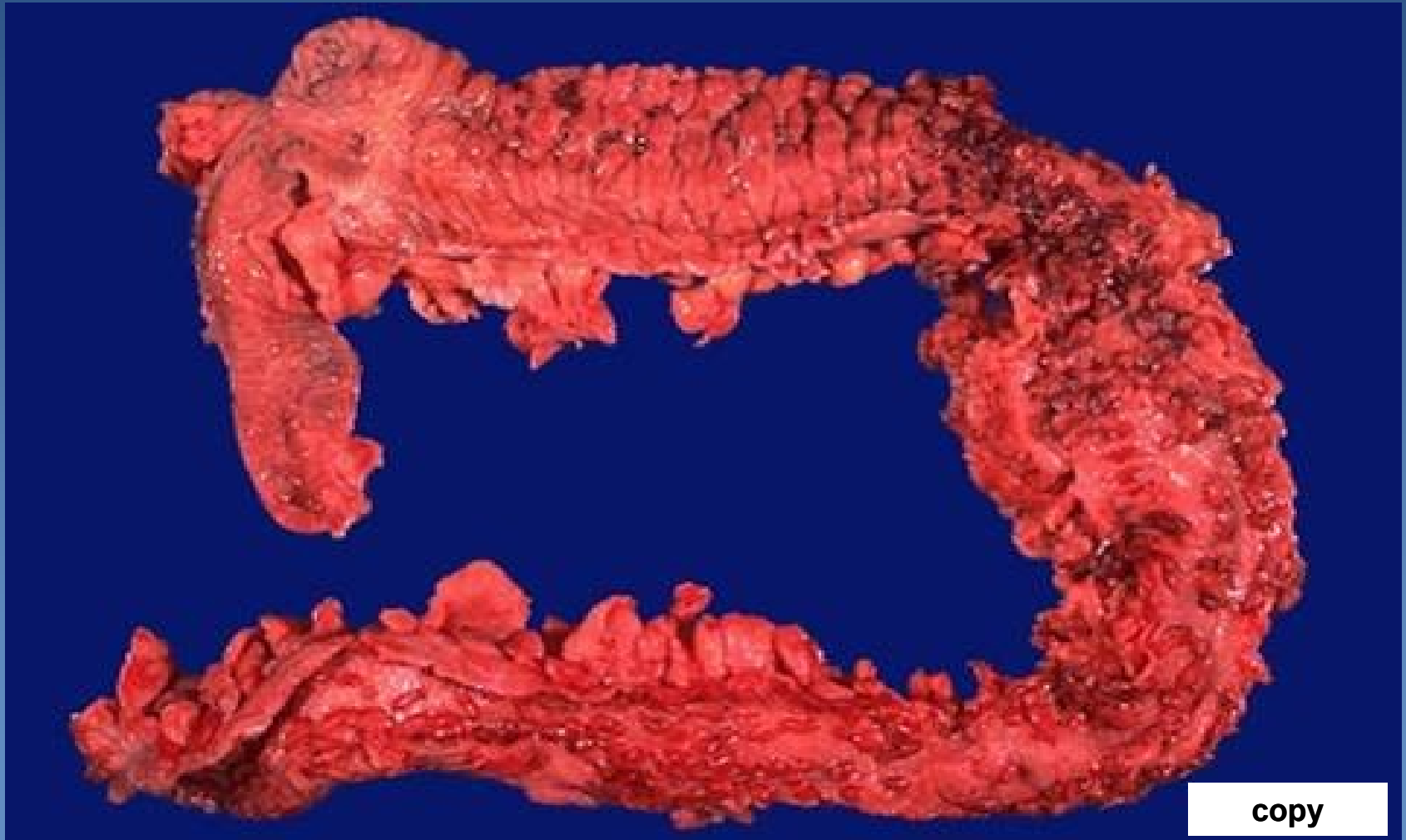
- mucosal architectural disarray, atrophy, inflammatory changes sm.  
only in the **rectum**

## **x** Complications:

- ⇒ *toxic megacolon, hemorrhage, perforation, peritonitis, carcinoma development*

# *Ulcerative colitis*

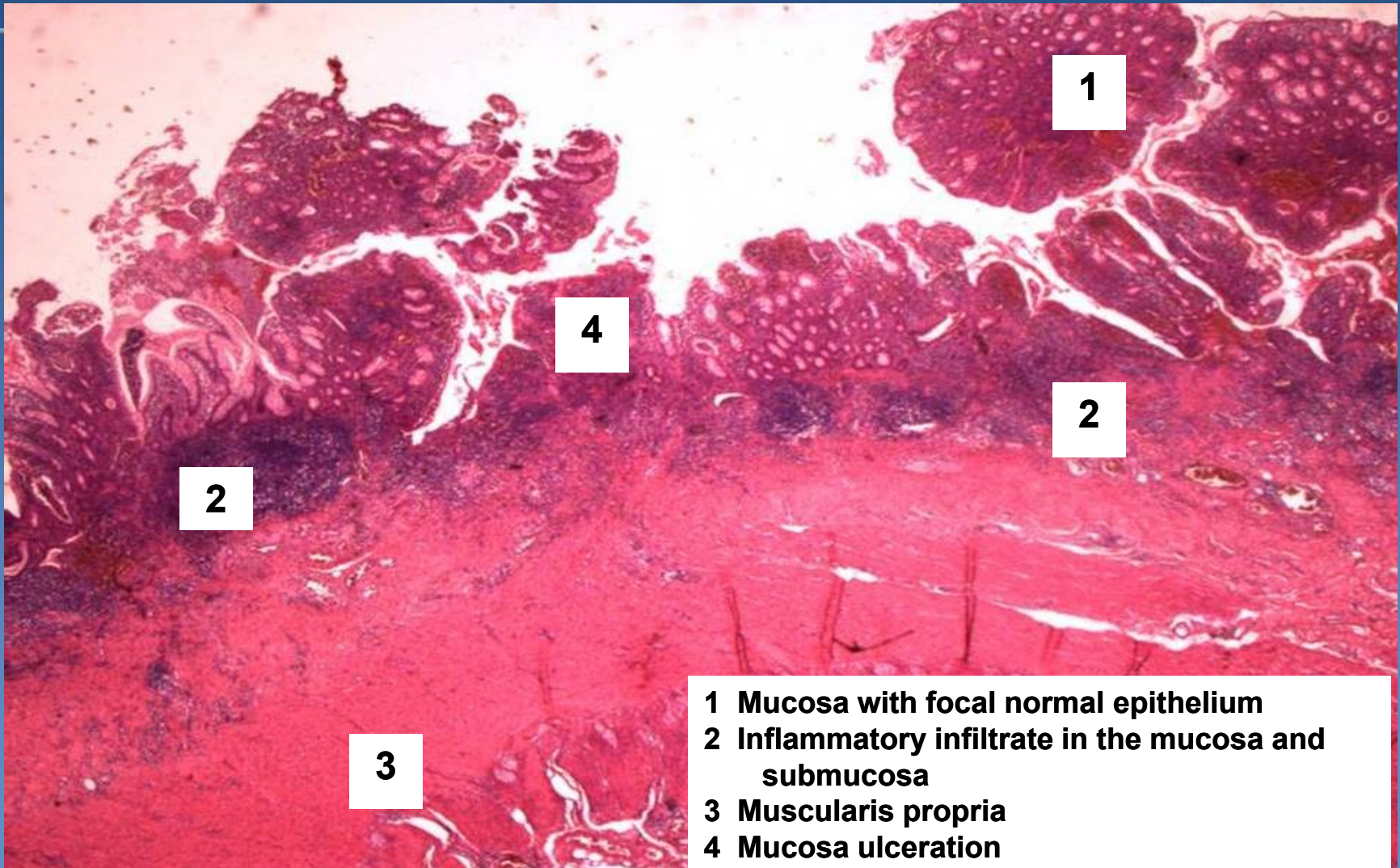
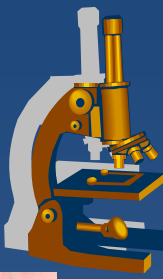
*- gross*



copy



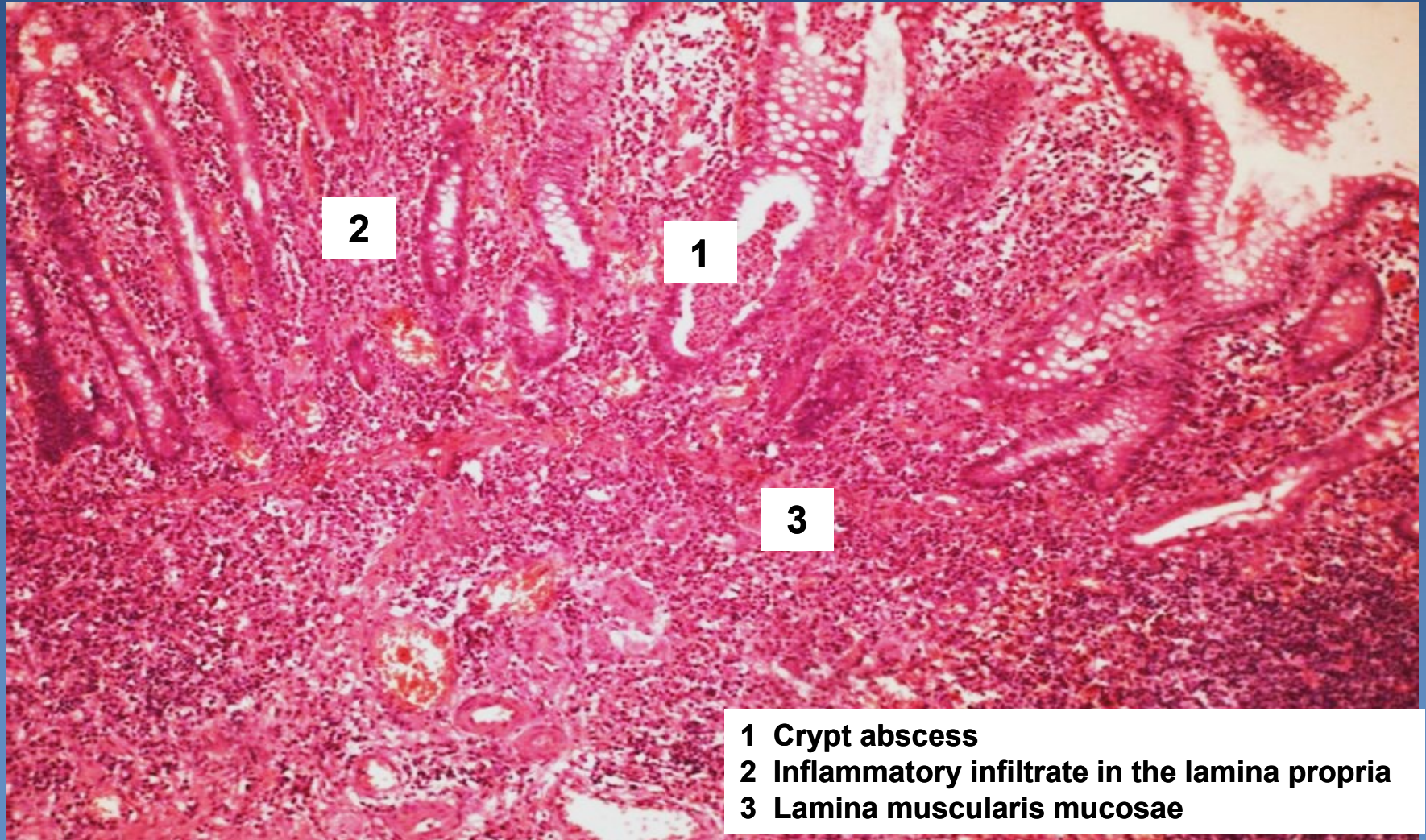
# *Ulcerative colitis* *superficial inflammatory infiltrate*



- 1 Mucosa with focal normal epithelium**
- 2 Inflammatory infiltrate in the mucosa and submucosa**
- 3 Muscularis propria**
- 4 Mucosa ulceration**



# ***Ulcerative colitis - crypt abscess***

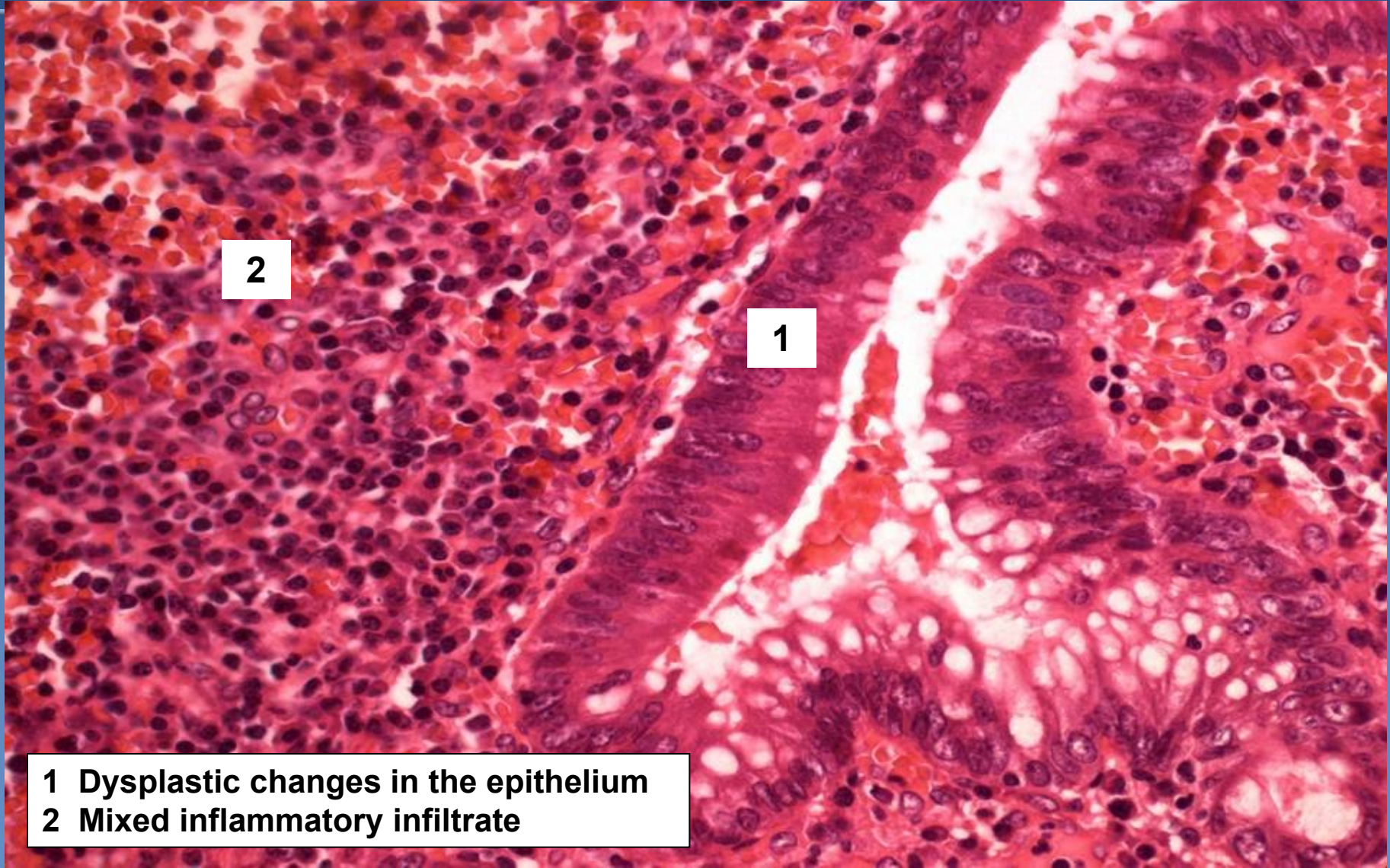
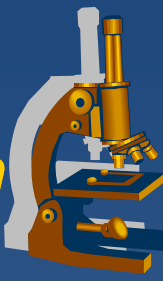


- 1 Crypt abscess**
- 2 Inflammatory infiltrate in the lamina propria**
- 3 Lamina muscularis mucosae**



# *Ulcerative colitis*

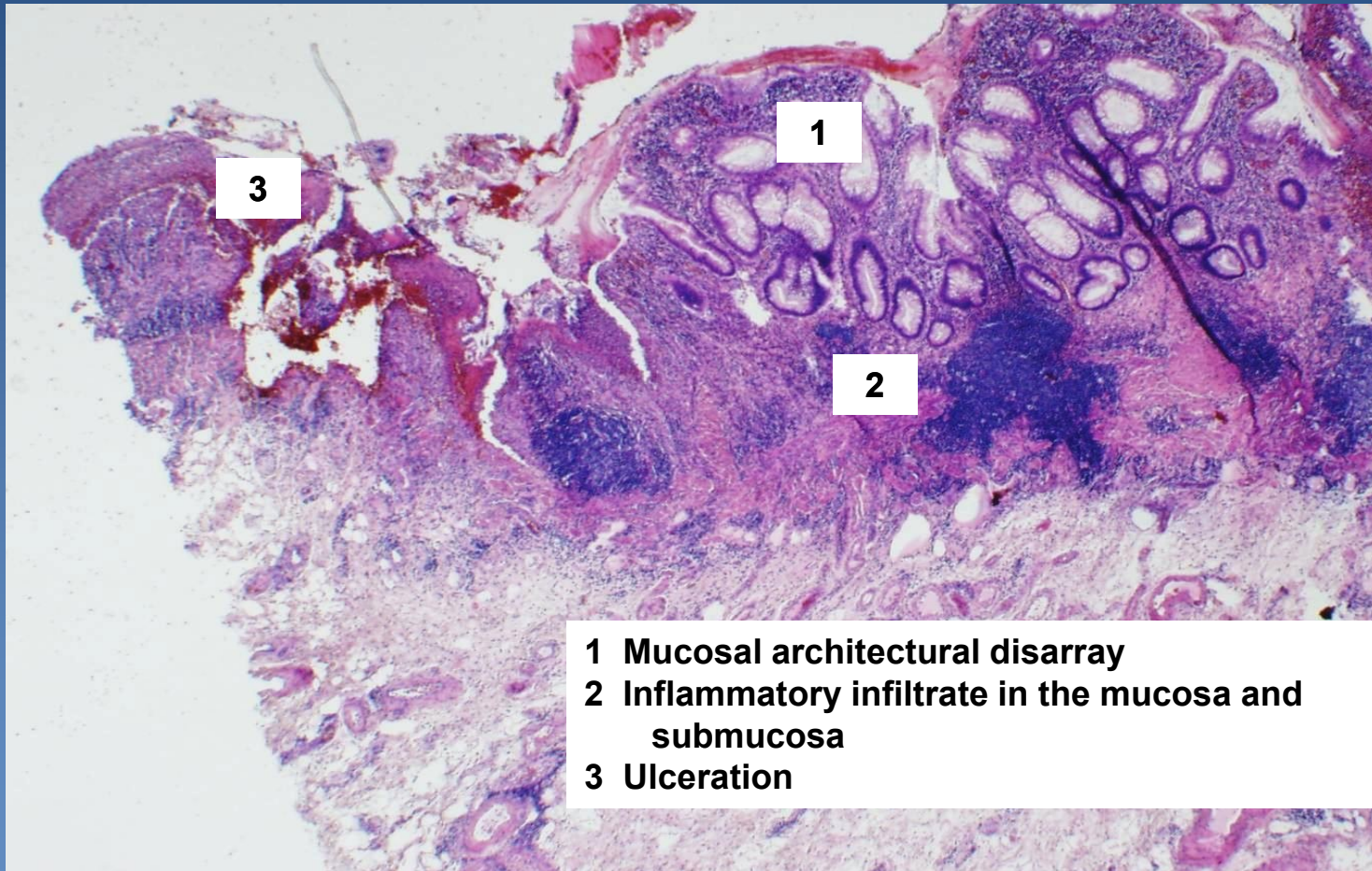
## *- dysplastic changes in the epithelium*



- 1 Dysplastic changes in the epithelium
- 2 Mixed inflammatory infiltrate



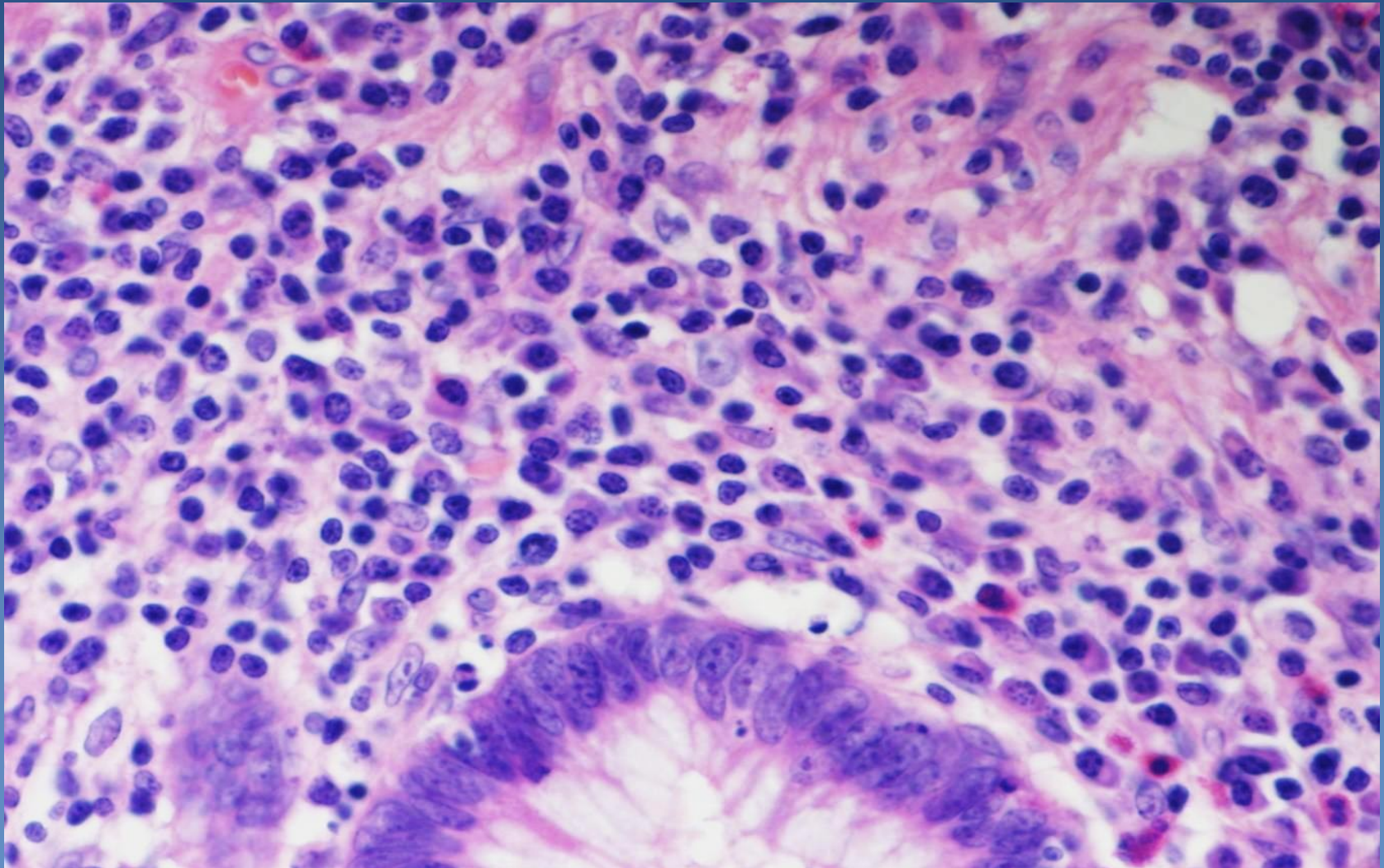
# *Ulcerative colitis*



- 1 Mucosal architectural disarray**
- 2 Inflammatory infiltrate in the mucosa and submucosa**
- 3 Ulceration**

# ***Ulcerative colitis***

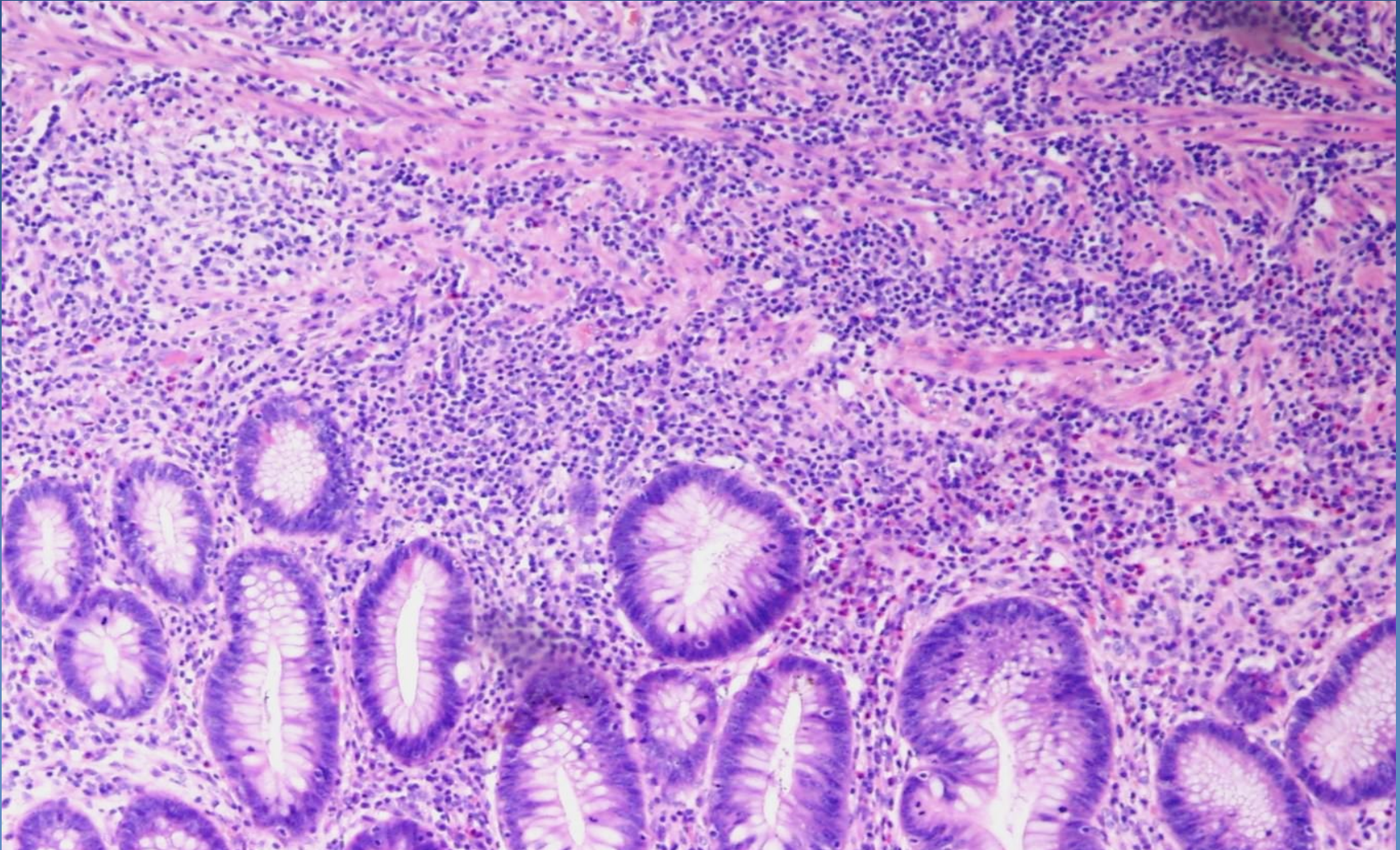
## ***basal plasmacytosis***





# ***Ulcerative colitis***

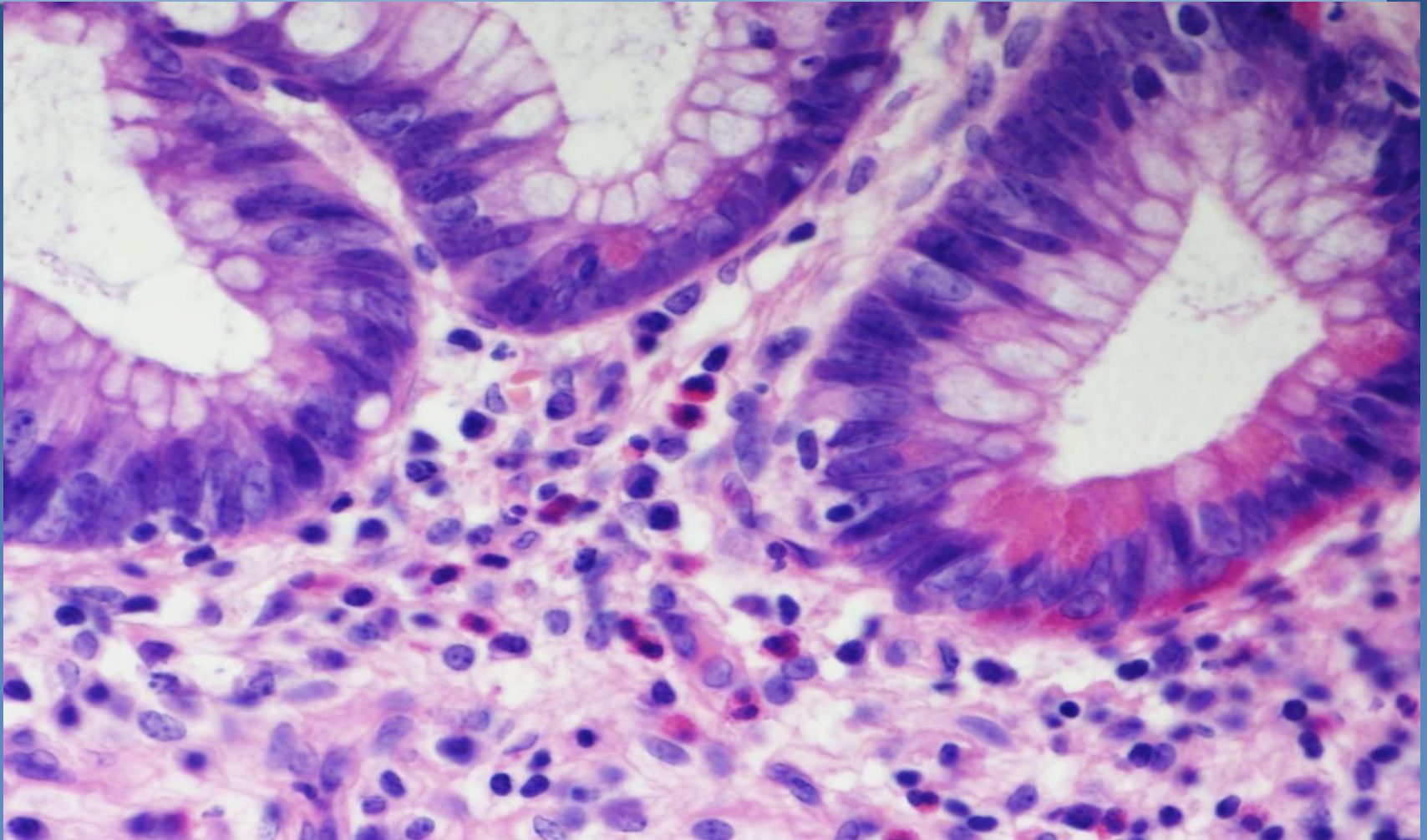
## ***basal plasmacytosis***





# ***Ulcerative colitis***

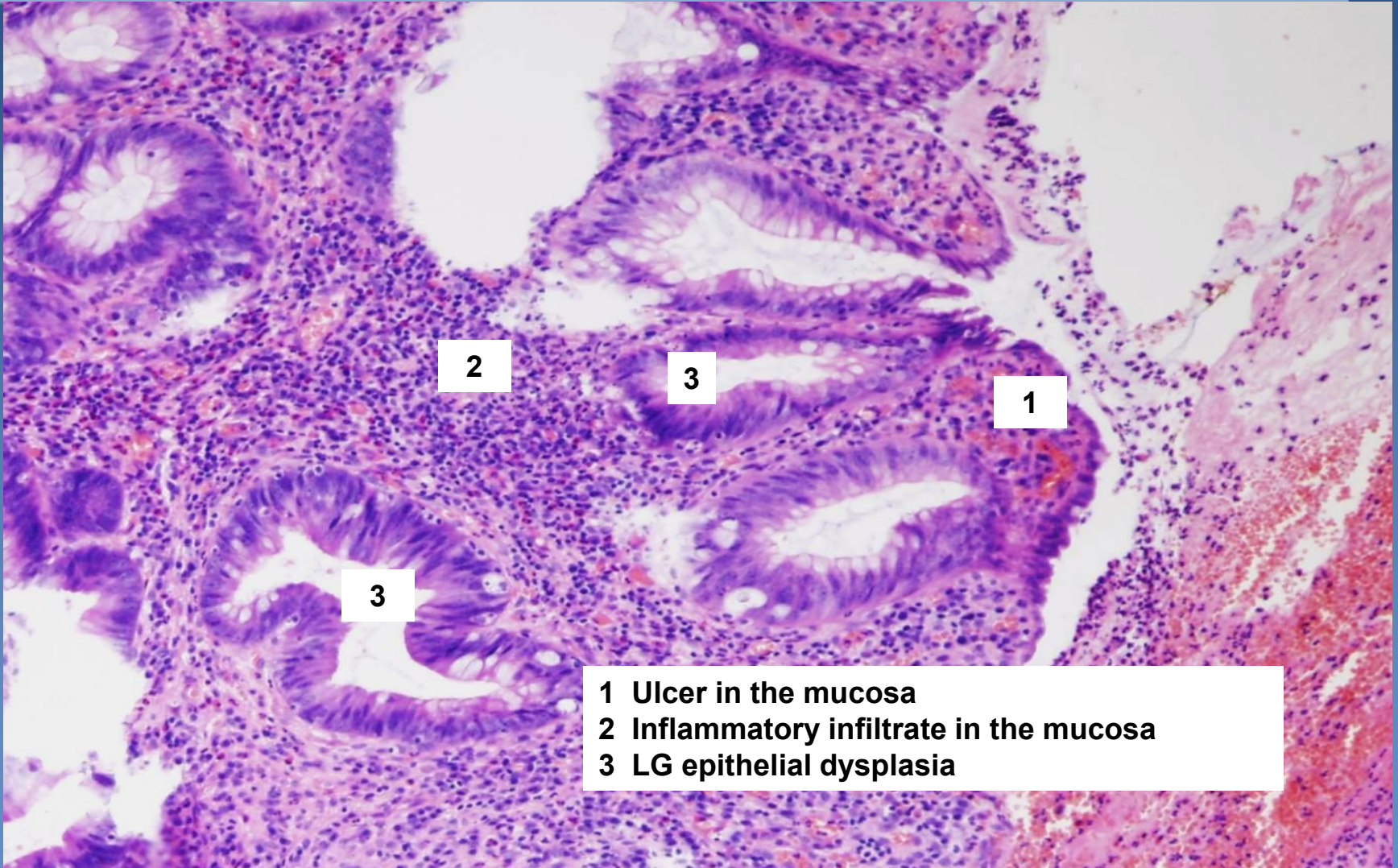
## ***Paneth cell metaplasia in the left colon***





# *Ulcerative colitis*

## *epithelial dysplasia*



- 1 Ulcer in the mucosa
- 2 Inflammatory infiltrate in the mucosa
- 3 LG epithelial dysplasia

# *Further types of enterocolitis*



- x pseudomembranous
- x ischemic
  - ⇒ *short-term decreased blood supply to the intestine (shock, trauma, surgery)*
- x microscopic (collagenous, lymphocytic)
  - ⇒ *chronic watery diarrhea, normal colonoscopy, associated with autoimmune diseases*
- x infectious
- x postradiation
- x others



# *Pseudomembranous colitis*



## **x**etiology:

- ⇒ *infection – bacterial (Clostridium difficile, Salmonella, Staph. aureus)*
- ⇒ *antibiotic-associated*
- ⇒ *uremia*

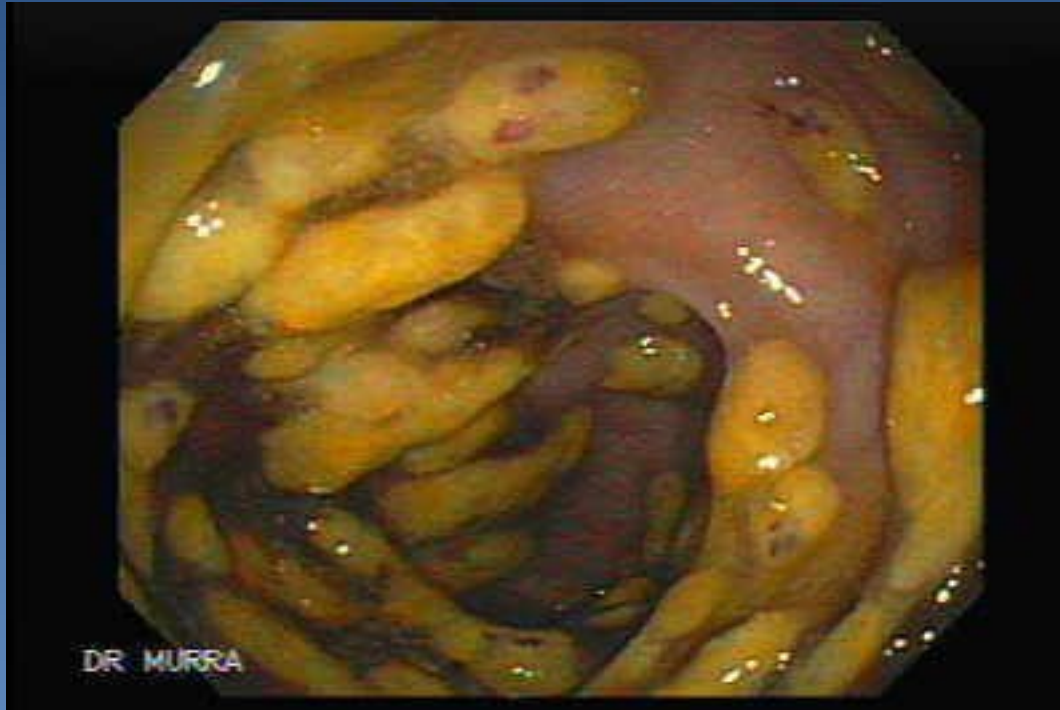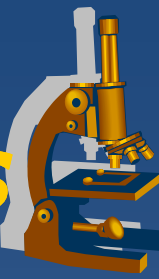
## **x**gross:

- ⇒ *greyish pseudomembranes on the mucosal surface, ulcers*

## **x**micro:

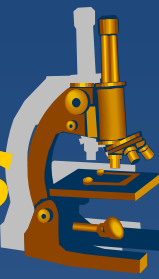
- ⇒ *fibrinous pseudomembrane with neutrophils, bacteria and macrophages, adherent to the necrotic mucosa*

# *Pseudomembranous colitis*

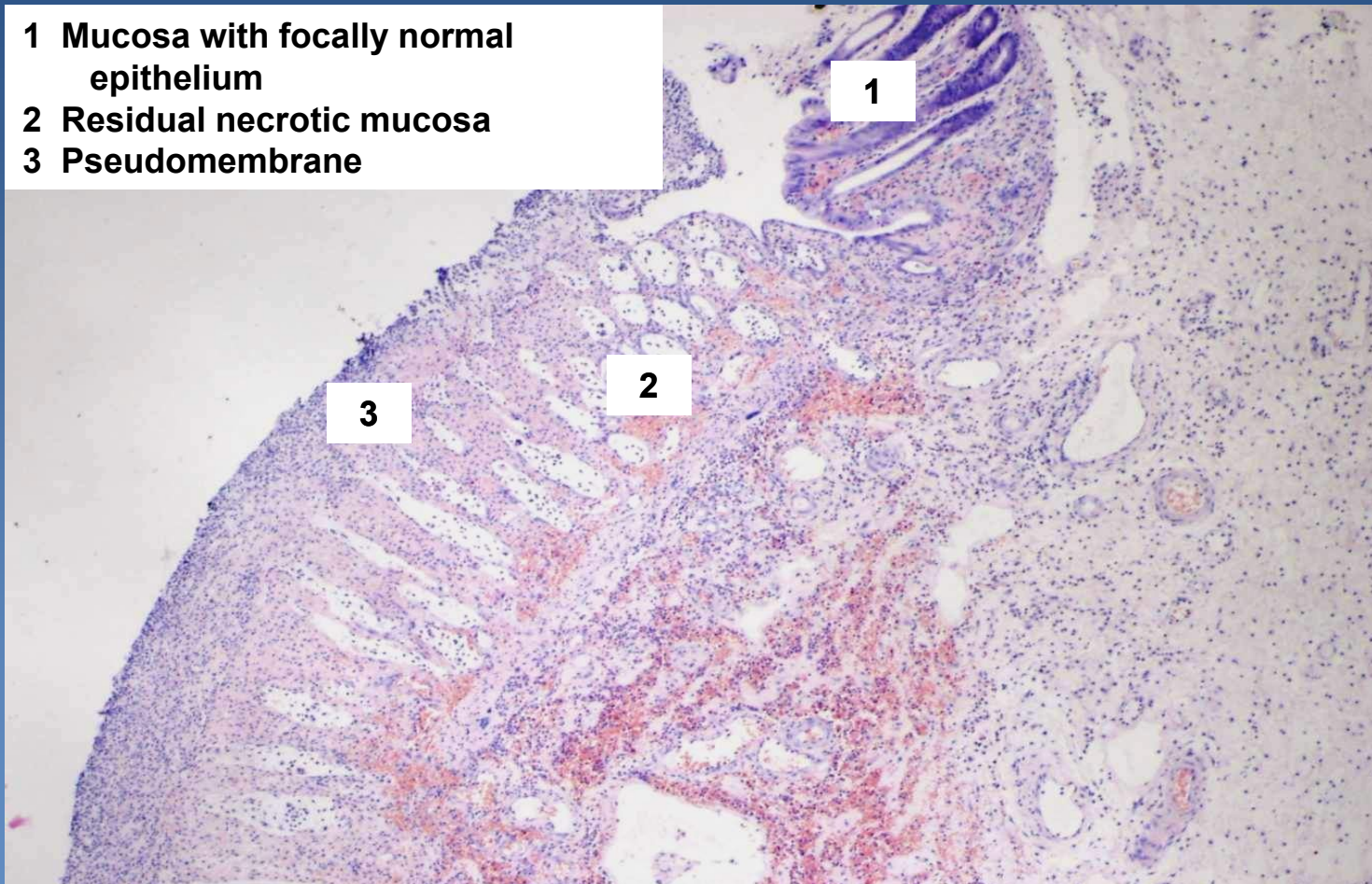


✘ Endoscopy (copy)

# *Pseudomembranous colitis*

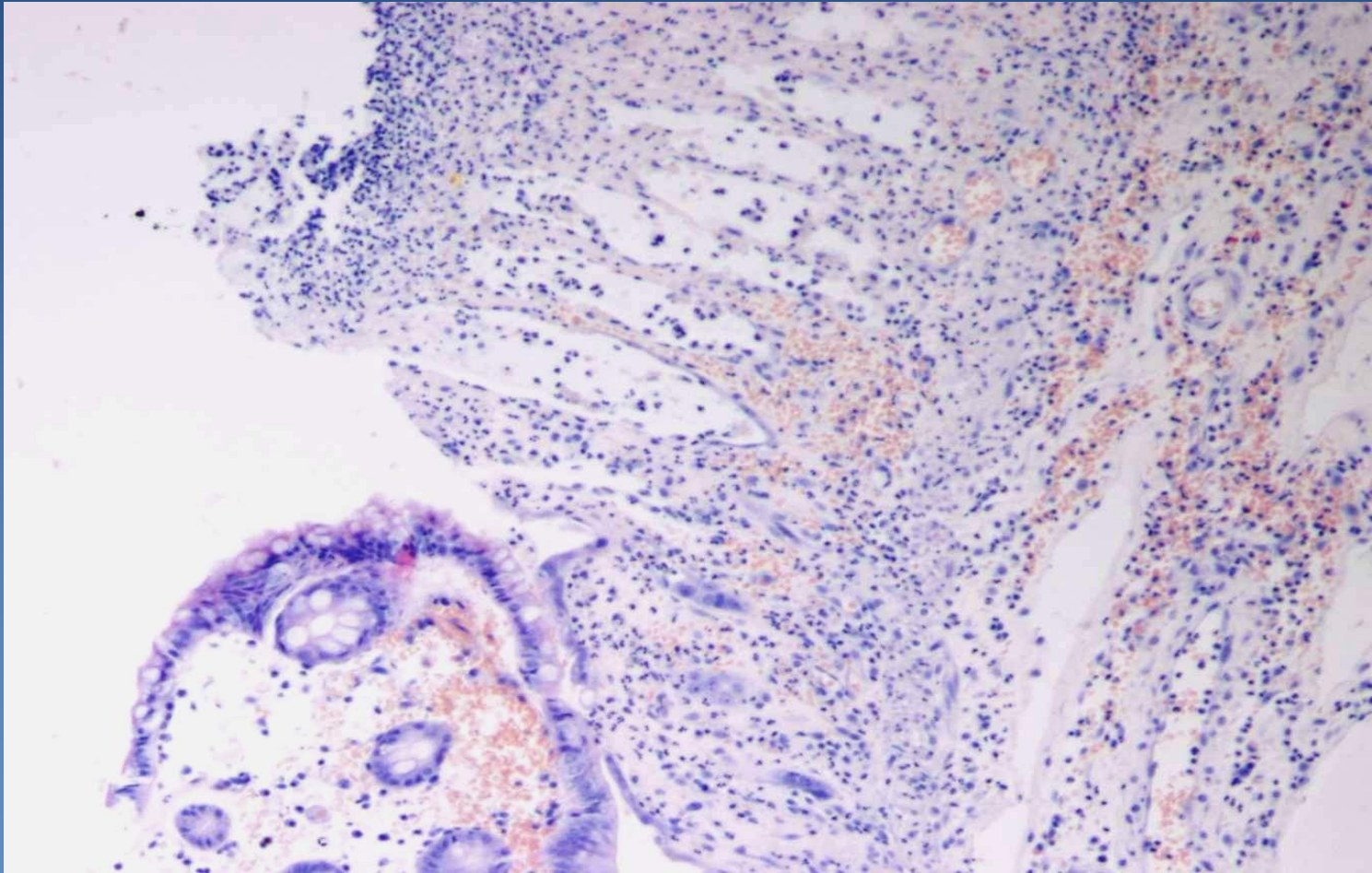


- 1 Mucosa with focally normal epithelium
- 2 Residual necrotic mucosa
- 3 Pseudomembrane





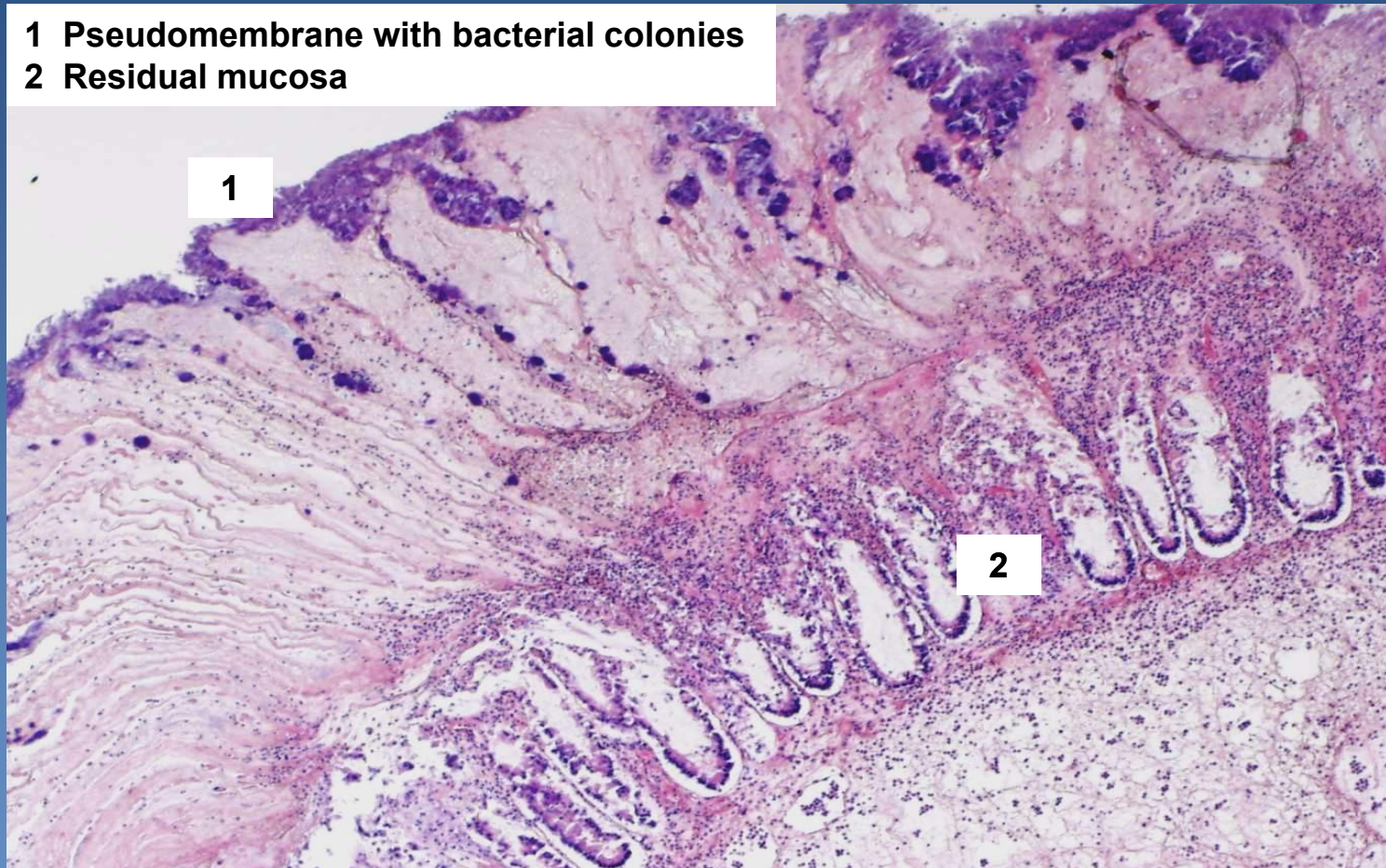
# *Pseudomembranous colitis* *- detail*



# ***Pseudomembranous colitis*** ***(Clostridium difficile etiology)***



- 1 Pseudomembrane with bacterial colonies
- 2 Residual mucosa





# ***Ileus – intestinal obstruction/disruption of the normal motility***



**×mechanic (strangulation, obturation)**

⇒ ***Adhesions***

⇒ ***hernias***

⇒ ***volvulus***

⇒ ***invagination***

⇒ ***tumors***

⇒ ***obstruction (foreign body)***

⇒ ***congenital atresia***

⇒ ***meconial in cystic fibrosis***

**×dynamic**

⇒ ***paralytic: toxic-infective, drugs, peritonitis, post-operative***

⇒ ***vascular: hemorrhagic infarction***

⇒ ***myopathy, neuropathy***

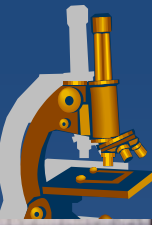
⇒ ***Hirschprung' disease***



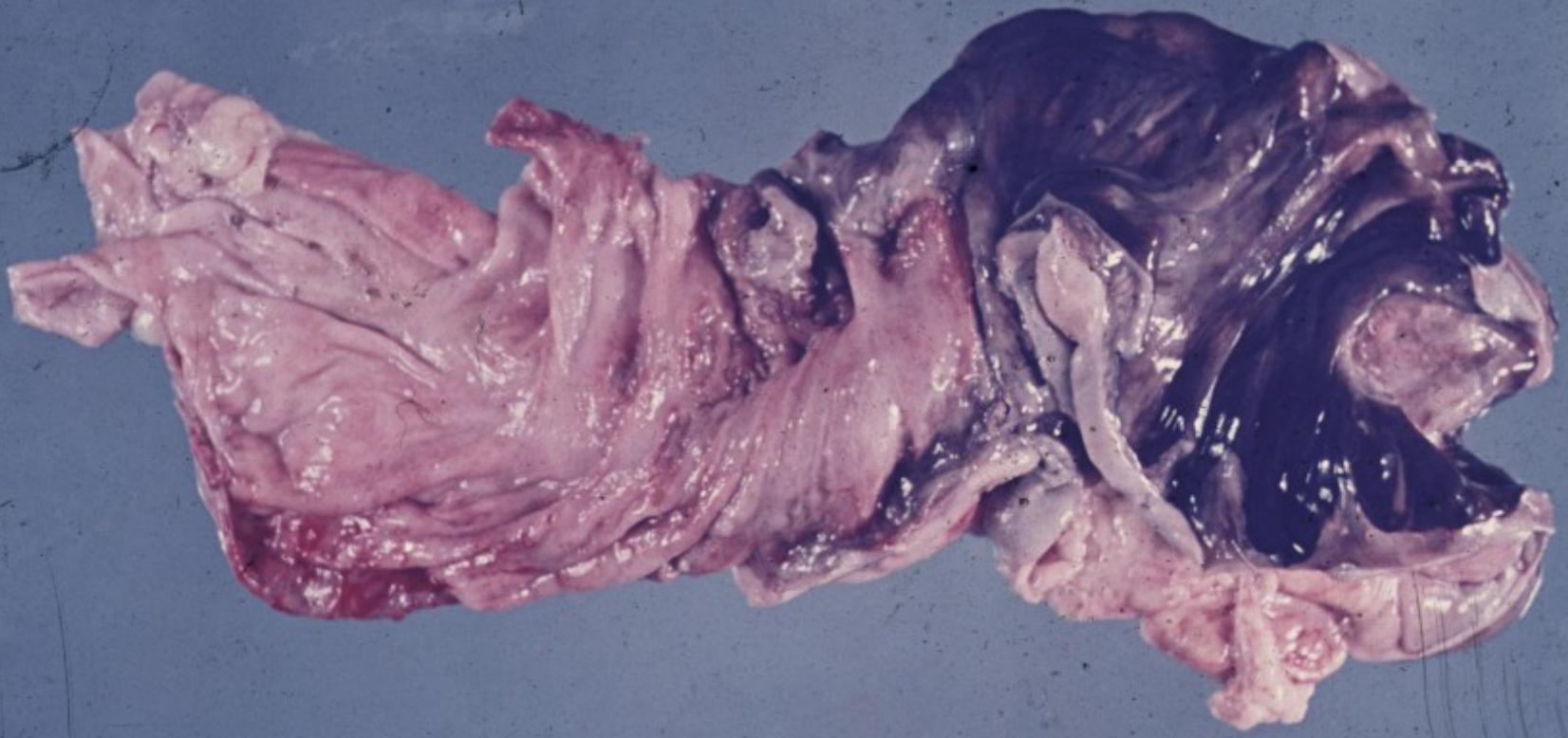# *Ileus*



- ✘ Clinical features: signs of „acute abdomen“ with acute pain, cramps, abdominal distention, nausea and vomiting, stop of the stool/gases passage
- ✘ Type / severity of the signs according to localisation + stage of obstruction
- ✘ Intestinal wall in/above the obstruction:
  - dilatation → inflammation → (peritonitis, sepsis)
  - mural necrosis → perforation → stercoral (fecal) peritonitis

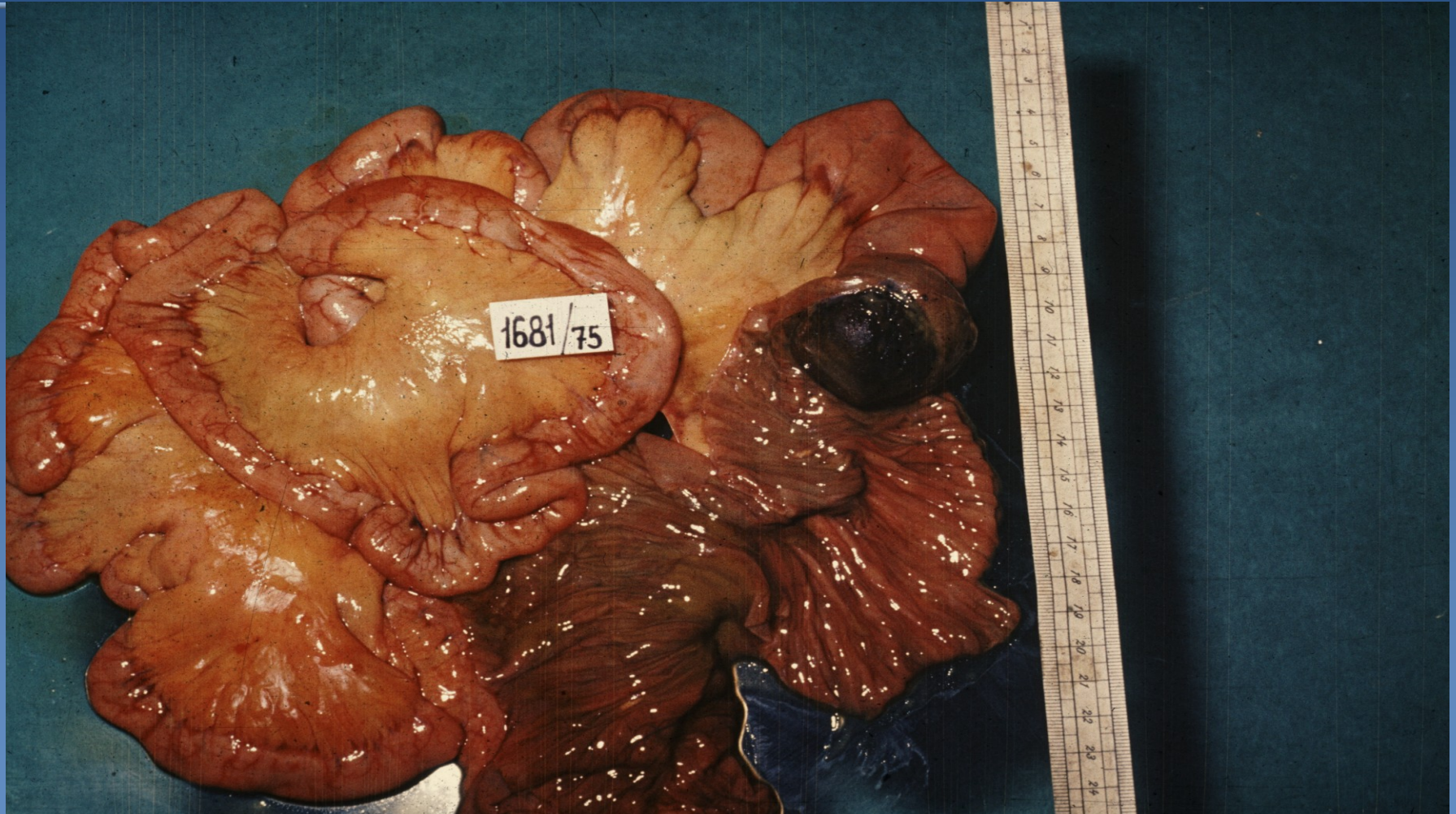

Volvulus, bowel infarction



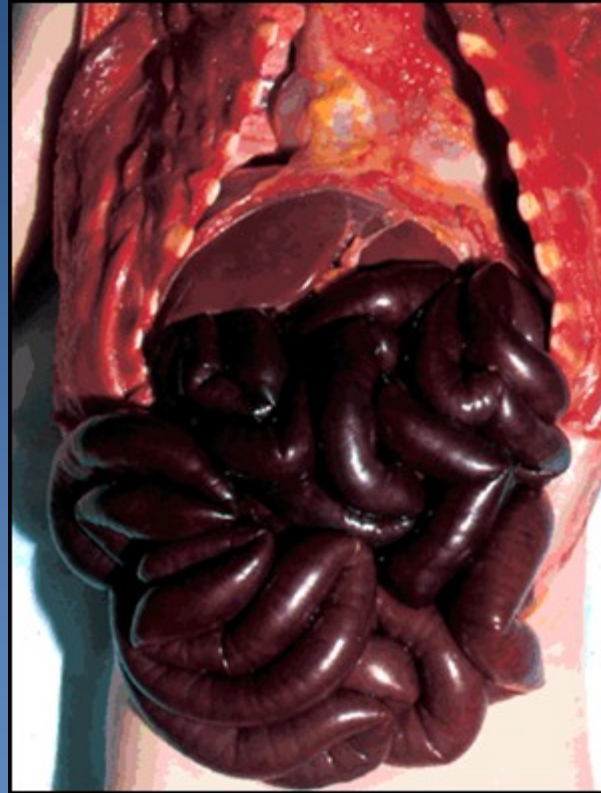


# *Gallstone ileus*





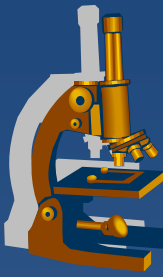
# *Hemorrhagic infarction of the intestine*



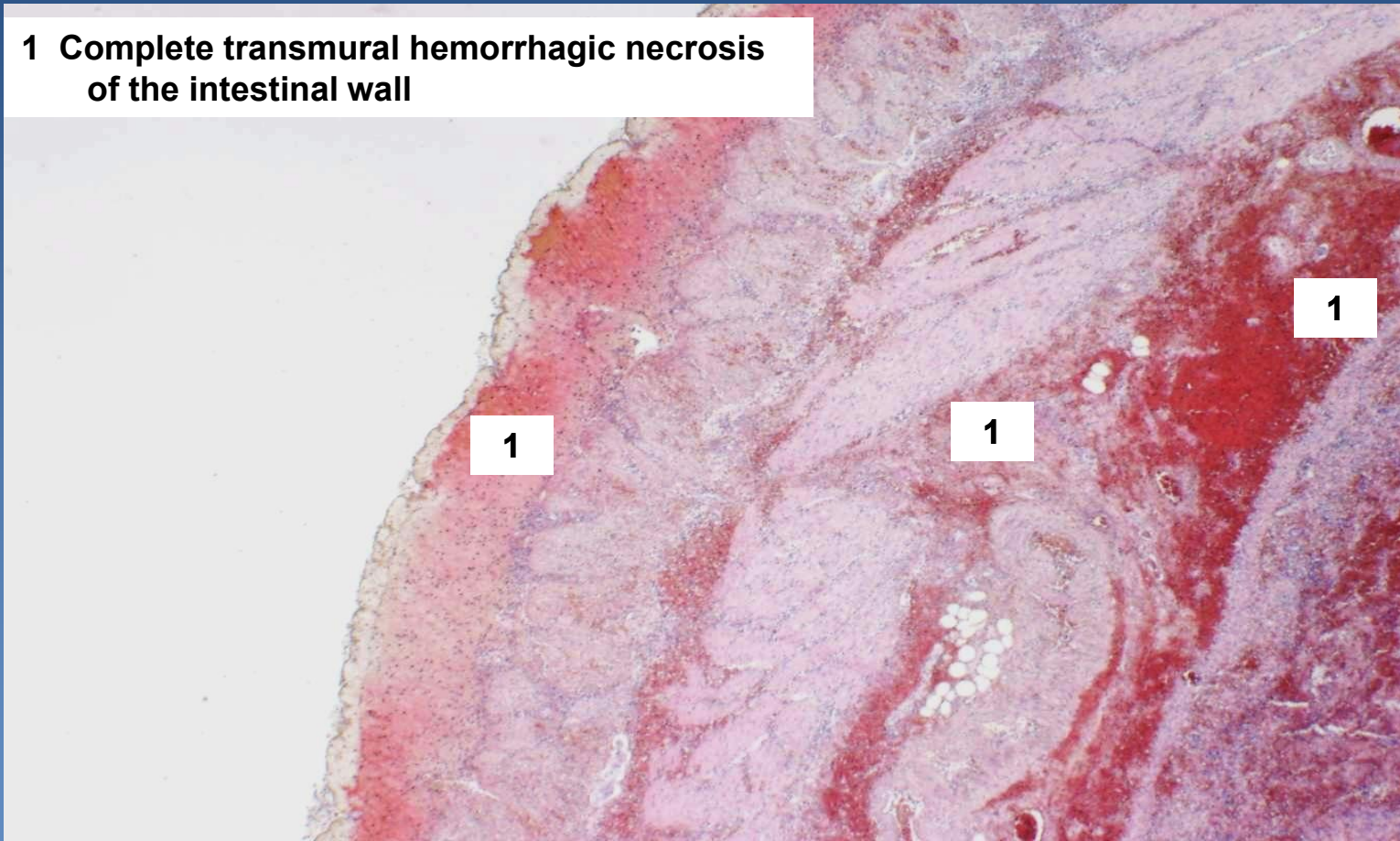
copy

**x** result of intestinal ischemia

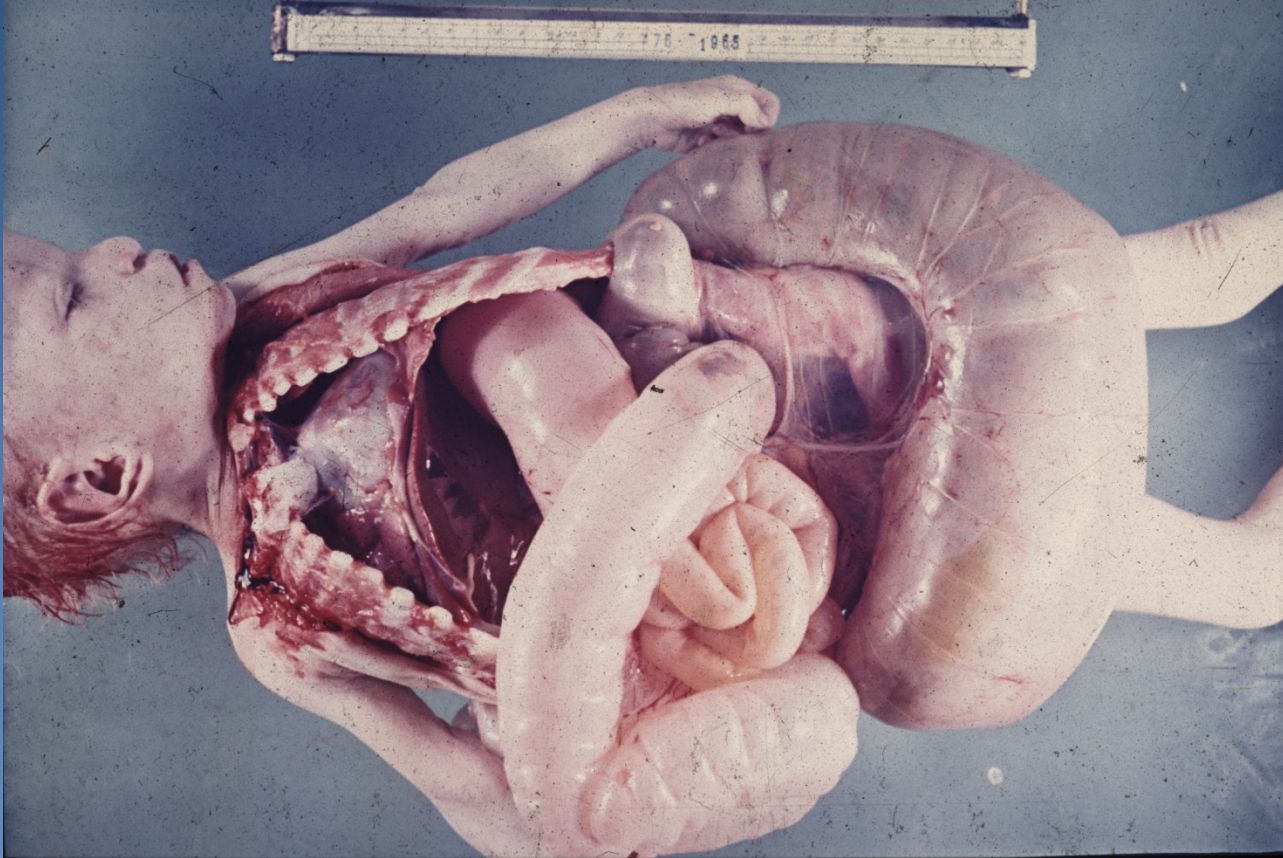
# *Hemorrhagic infarction of the intestine*



**1 Complete transmural hemorrhagic necrosis of the intestinal wall**



# *Hirschprung' disease*





# *Intestinal polyps*



## **x Non-neoplastic polyps**

- ⇒ **hyperplastic polyp** (<5 mm) minimal malignant potential, part of group of serrated lesions
- ⇒ **juvenile polyp** - hamartoma; in children under 5 years, in the rectum, sporadic or part of juvenile polyposis sy (AD, haemorrhage, ↑ risk of ca)
- ⇒ **Peutz - Jeghers** hamartoma polyps + mucocutaneous hyperpigmentation; single/multiple (P-J syndrome - ↑ risk of pancreatic, pulmonary, ovarian, breast cancer)

# *Intestinal polyps*

---



## × Neoplastic sporadic adenomatous polyps

- ⇒ **tubular adenoma** (*smaller, spheric, pedunculated*)
- ⇒ **villous adenoma** (*large, flat, sessile, often HG dysplasia and high malignant potential*)
- ⇒ **tubulovillous adenoma**

# Familial syndromes



## 1/ Familial hereditary polyposis syndromes

### ⇒ familial adenomatous polyposis (FAP):

*AD, mutation of suppressor APC gene, 100-2500 colonic adenomas, teenagers, 100% risk of cancer*

### ⇒ Gardner syndrome: FAP variant, dental anomalies

*extraintestinal tumors: osteomas, gliomas, lipomas, fibromas*

### ⇒ Peutz - Jeghers syndrome :

*melanotic mucosal and cutaneous pigmentation with hamartomatous intestinal polyps*





## 2/ Lynch syndrome

*(hereditary non-polyposis colorectal cancer, AD), DNA mismatch repair defect + increased rate of mutations; younger age, right colon.*

*Increased risk of multiple tumors of the stomach, small intestine, liver, gallbladder tract, urinary tract, brain, skin, prostate.*

# Serrated lesions



- ⇒ *special heterogenous group of polypous lesions, serrated (sawtooth, stellate) morphology, part of intraepithelial neoplasias*
- ⇒ *precursors of perhaps one third of colorectal cancers*
- ⇒ *classification: dysplastic, non-dysplastic*

# ***Classification of serrated lesions/polyps***



## **x Non-dysplastic**

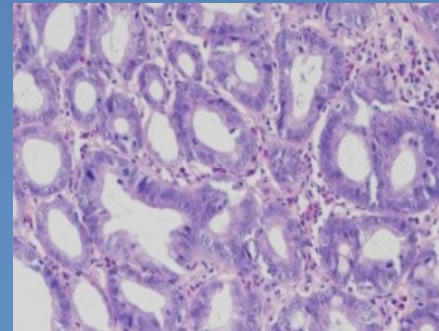
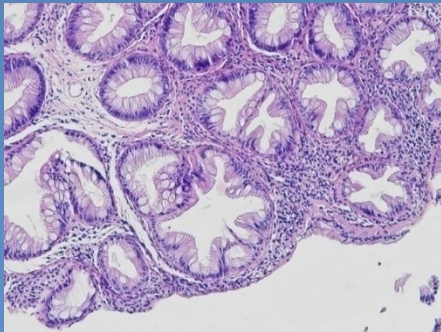
⇒ *hyperplastic polyp*

⇒ *sessile serrated adenoma/polyp*

## **x With dysplasia**

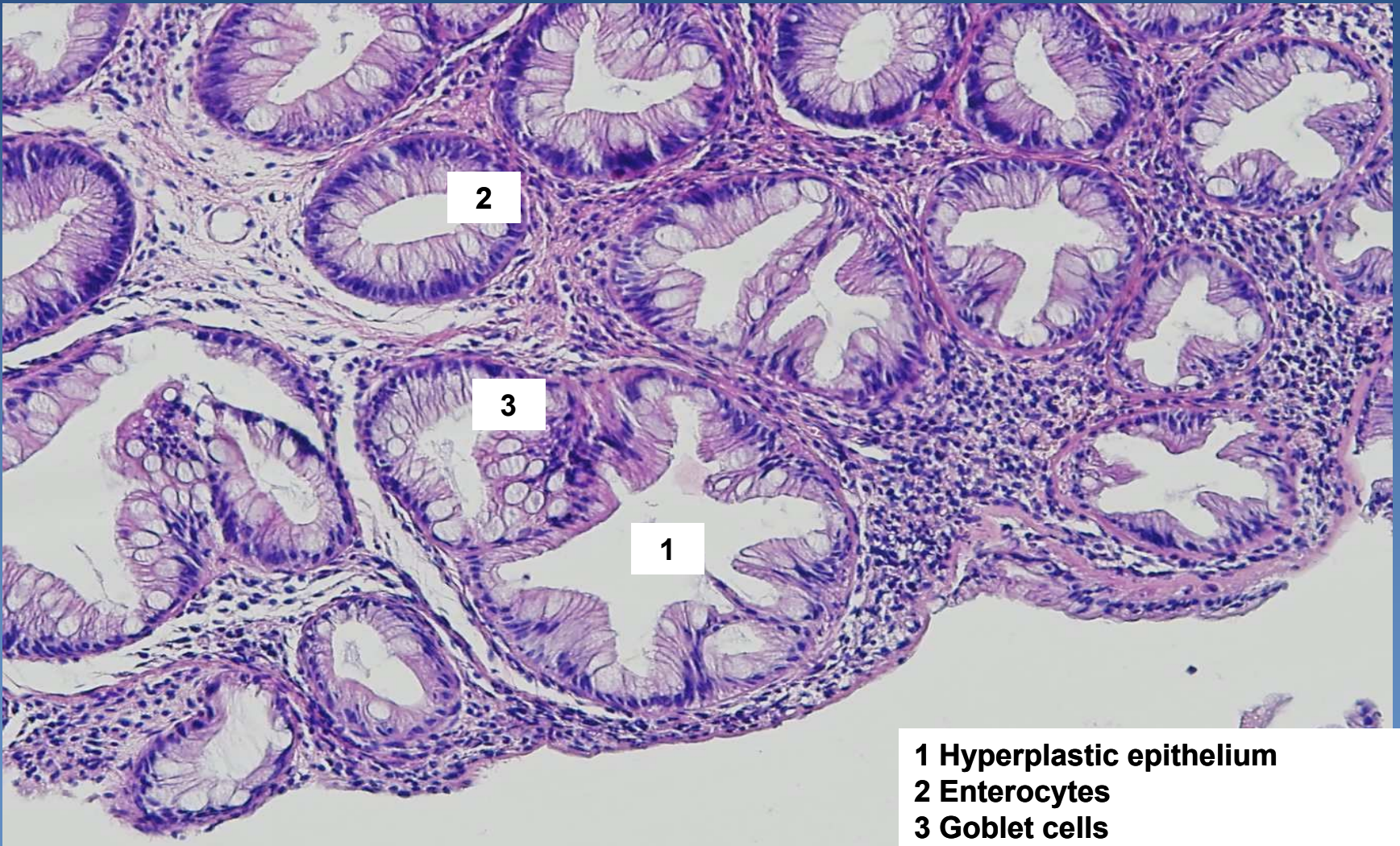
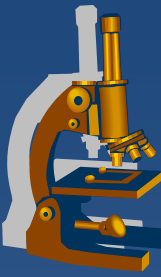
⇒ *sessile serrated adenoma/polyp w. dysplasia*

⇒ *traditional serrated adenoma*





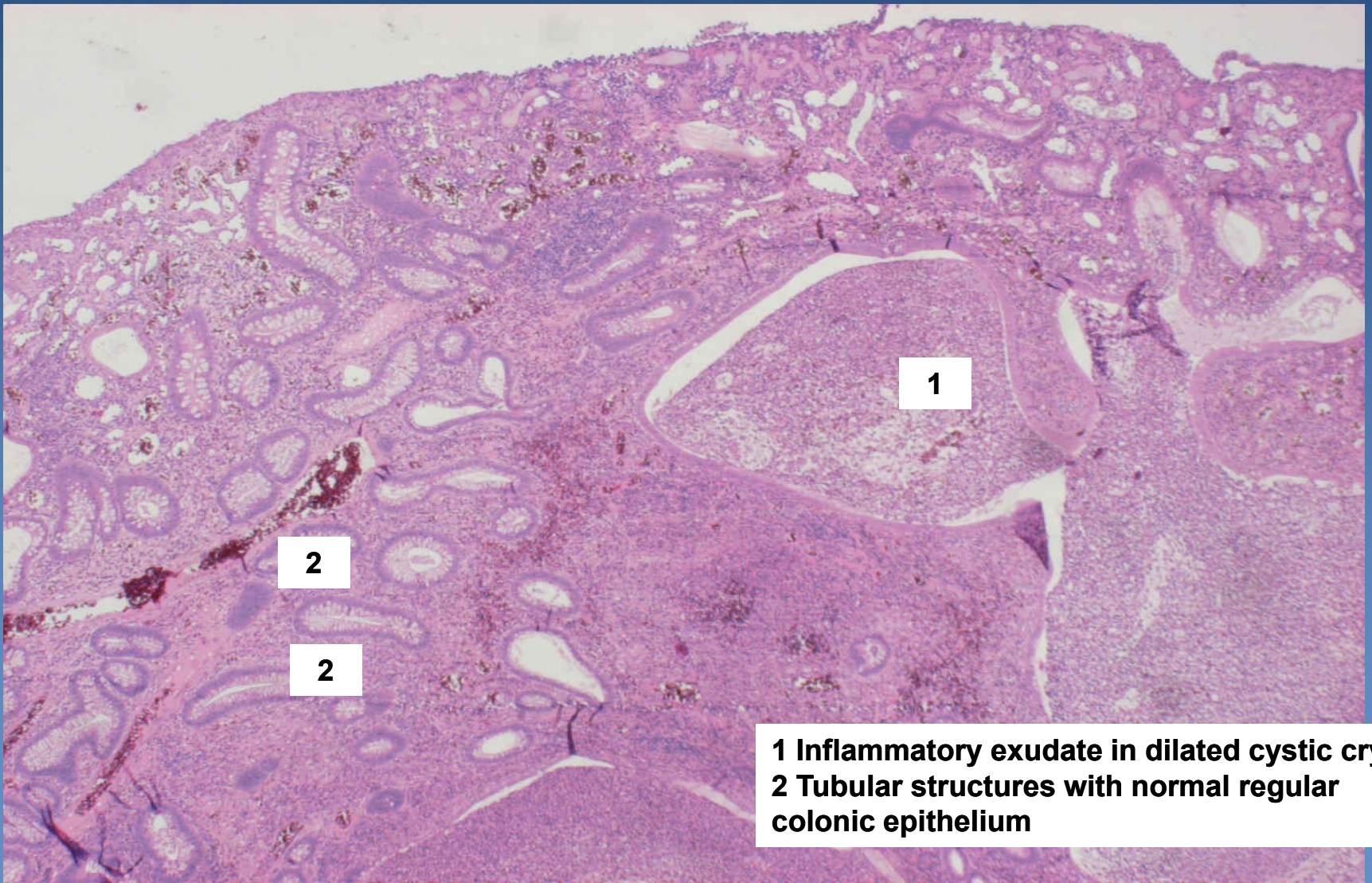
# *Colon – hyperplastic polyp*



**1 Hyperplastic epithelium**  
**2 Enterocytes**  
**3 Goblet cells**



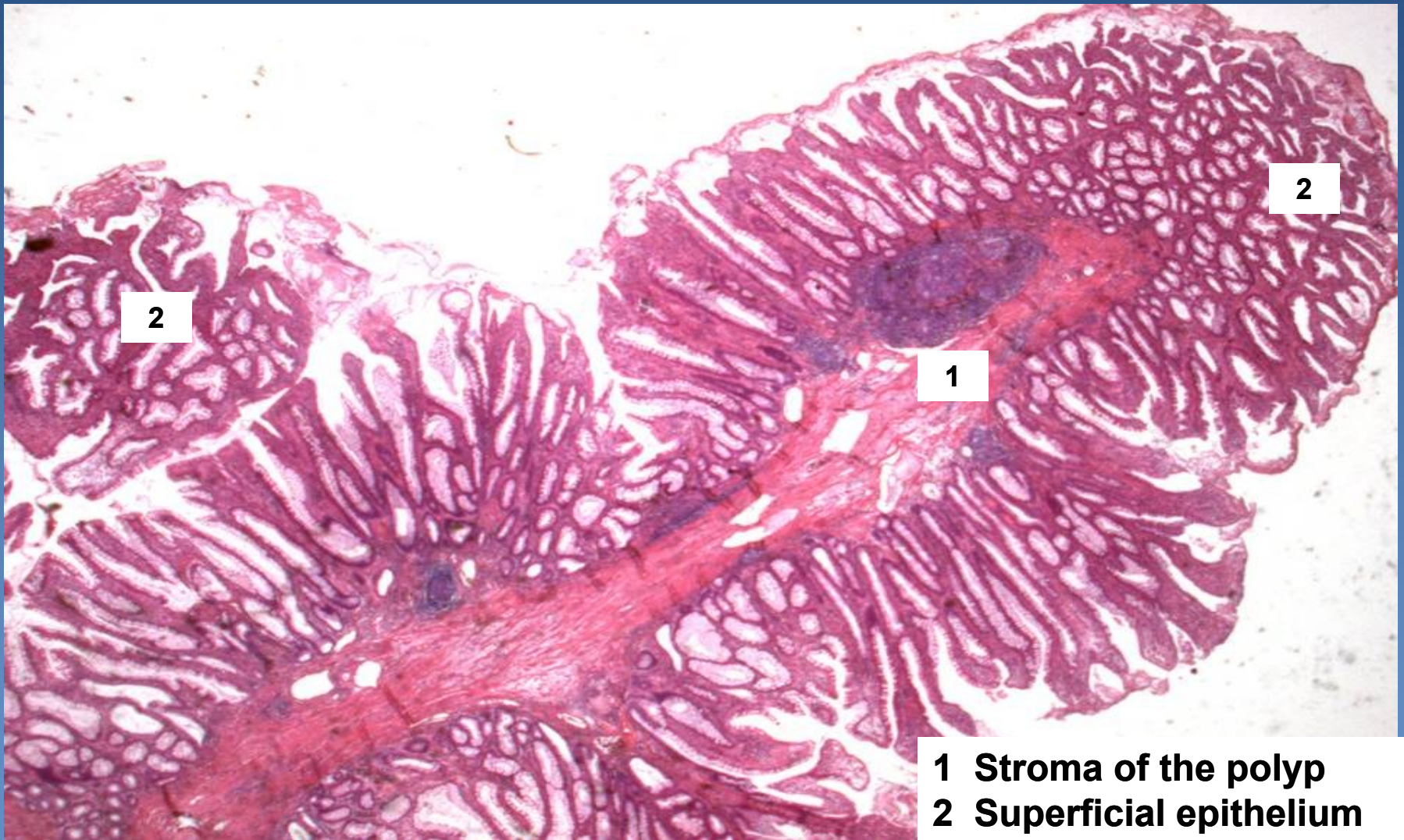
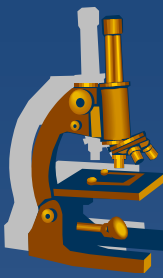
# Colon - juvenile polyp



**1** Inflammatory exudate in dilated cystic crypt  
**2** Tubular structures with normal regular colonic epithelium



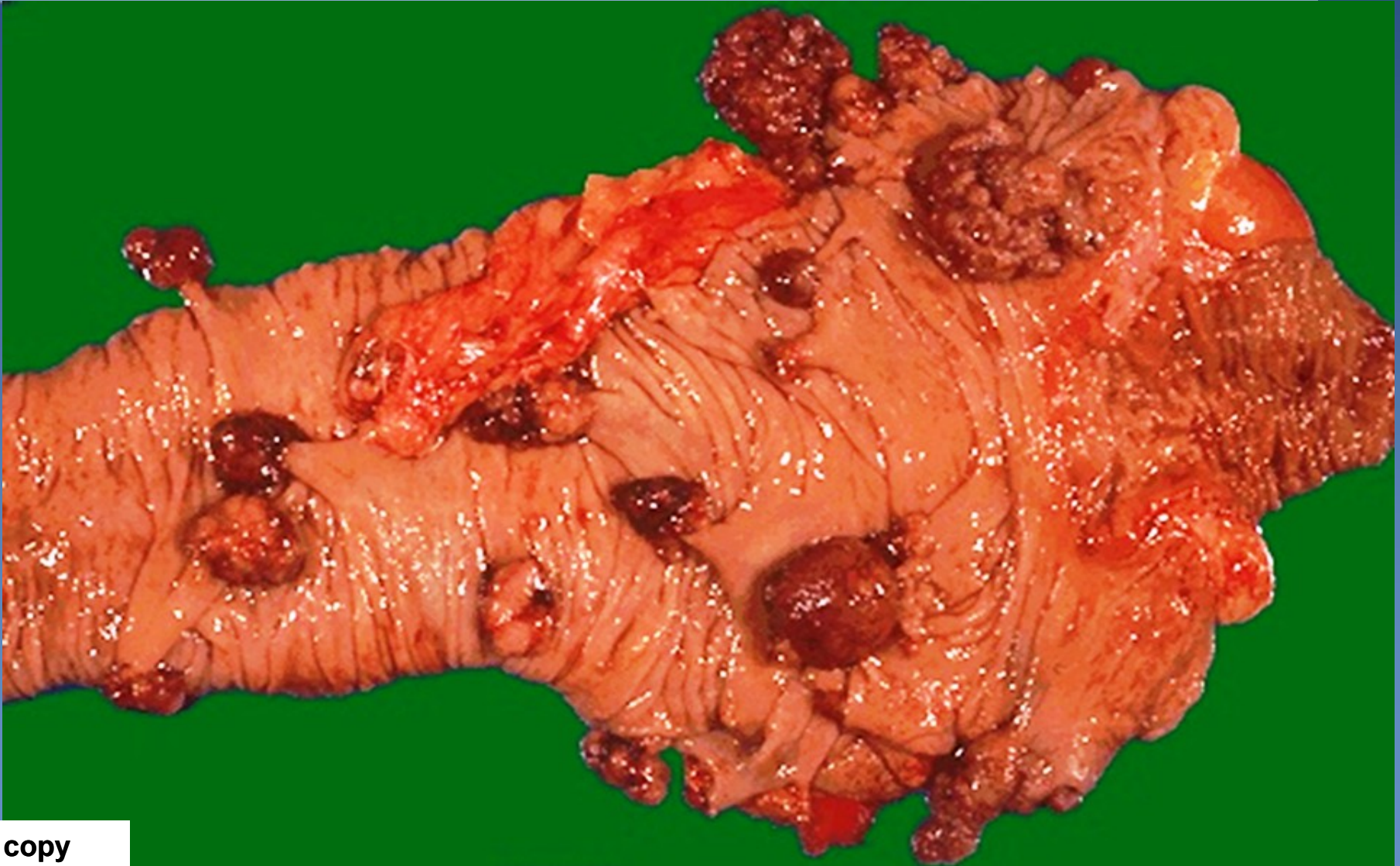
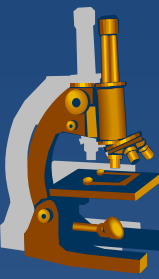
# *Colon - hamartomatous P-J polyp*



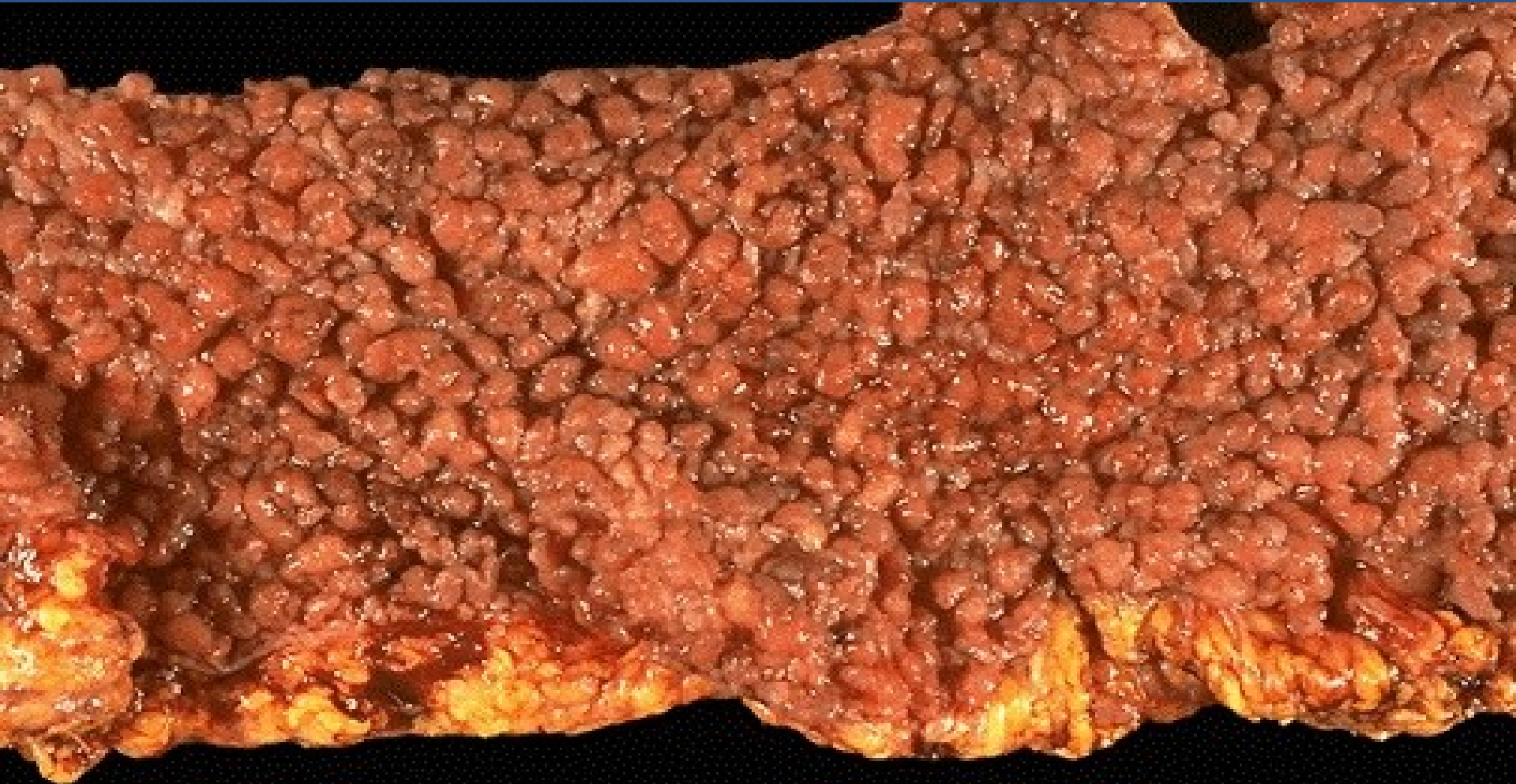
- 1 Stroma of the polyp**
- 2 Superficial epithelium**



# *Adenomas*



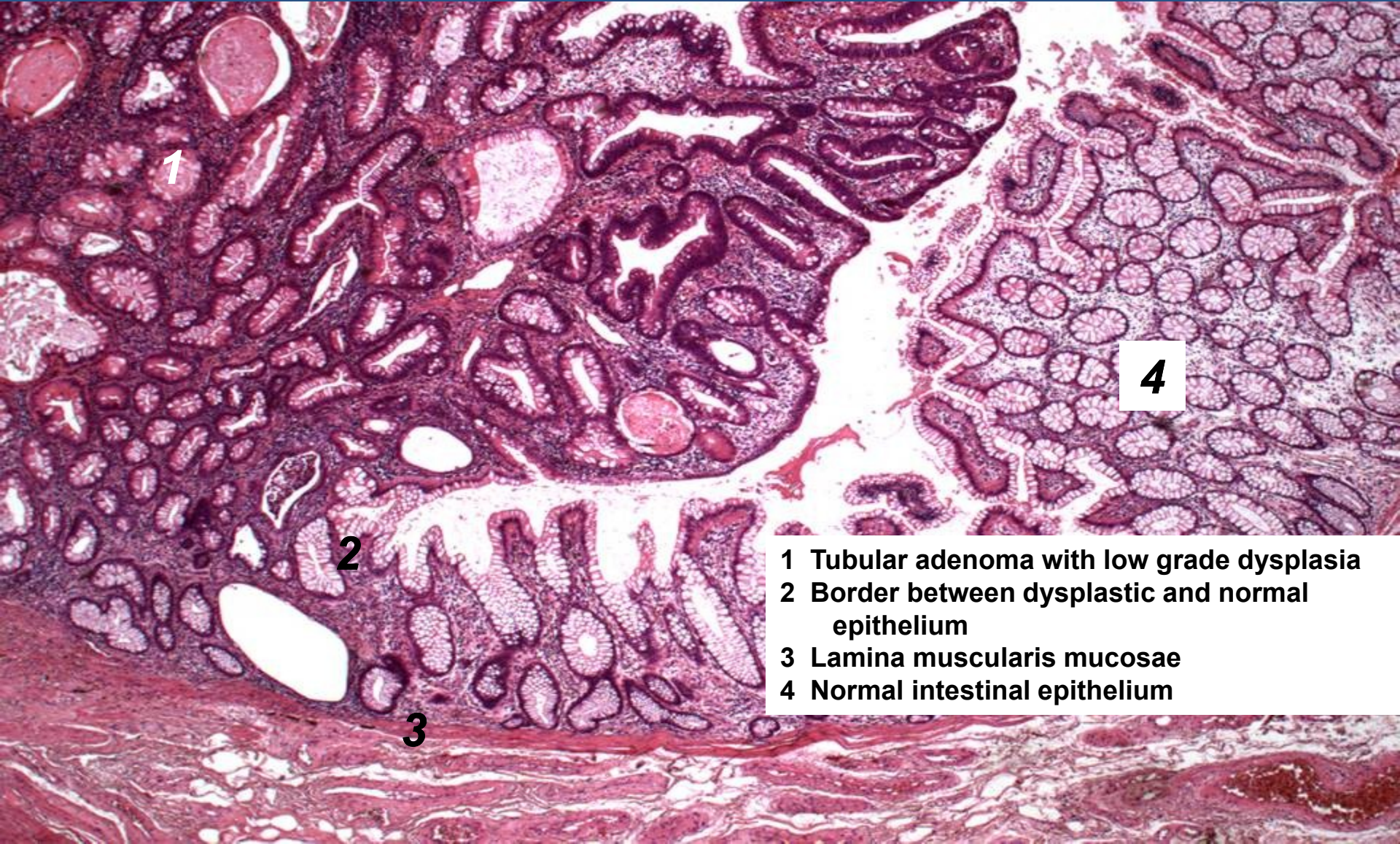
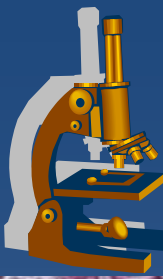
# ***Polyposis of the colon***



**copy**



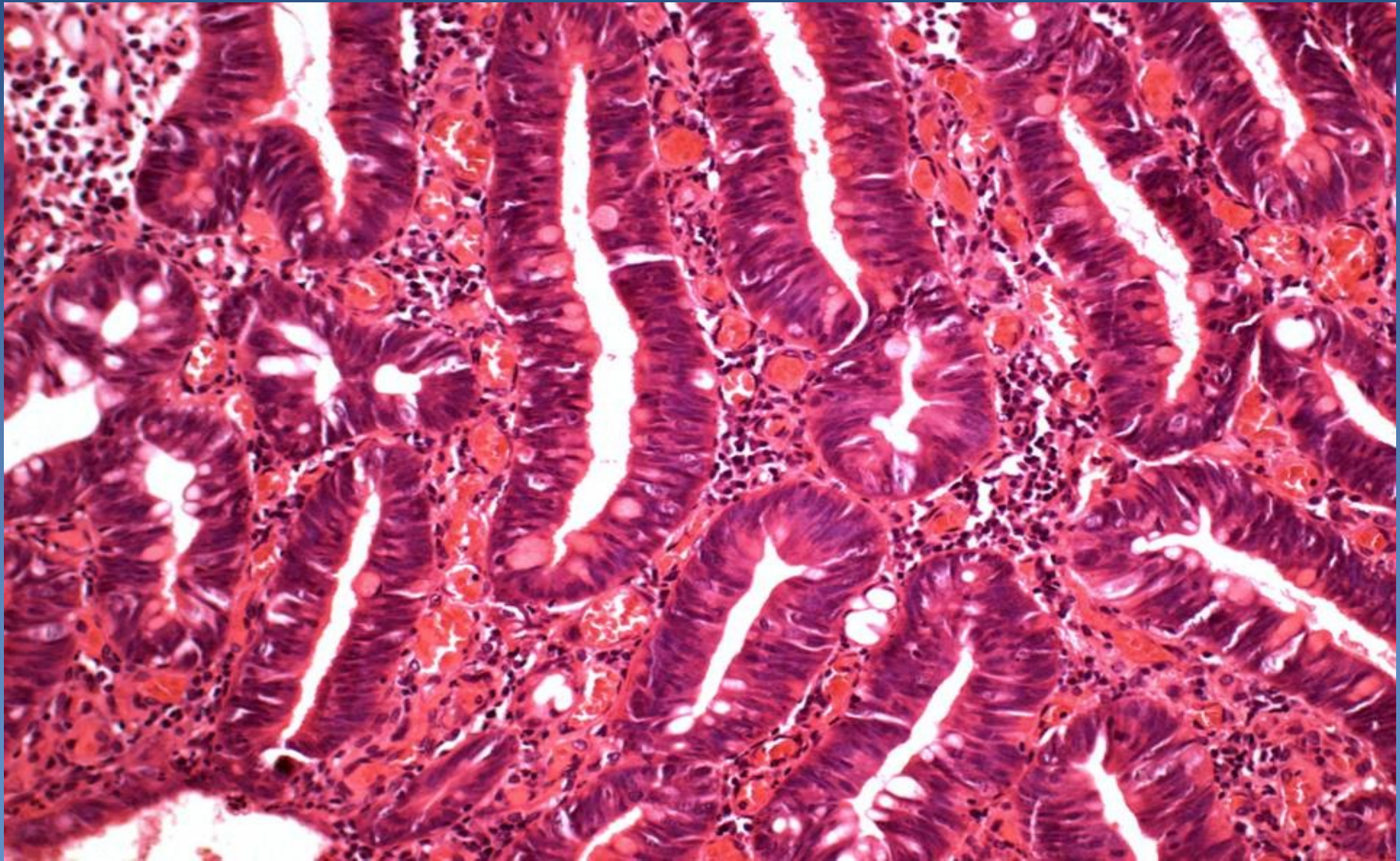
# *Tubular adenoma*



- 1 Tubular adenoma with low grade dysplasia
- 2 Border between dysplastic and normal epithelium
- 3 Lamina muscularis mucosae
- 4 Normal intestinal epithelium

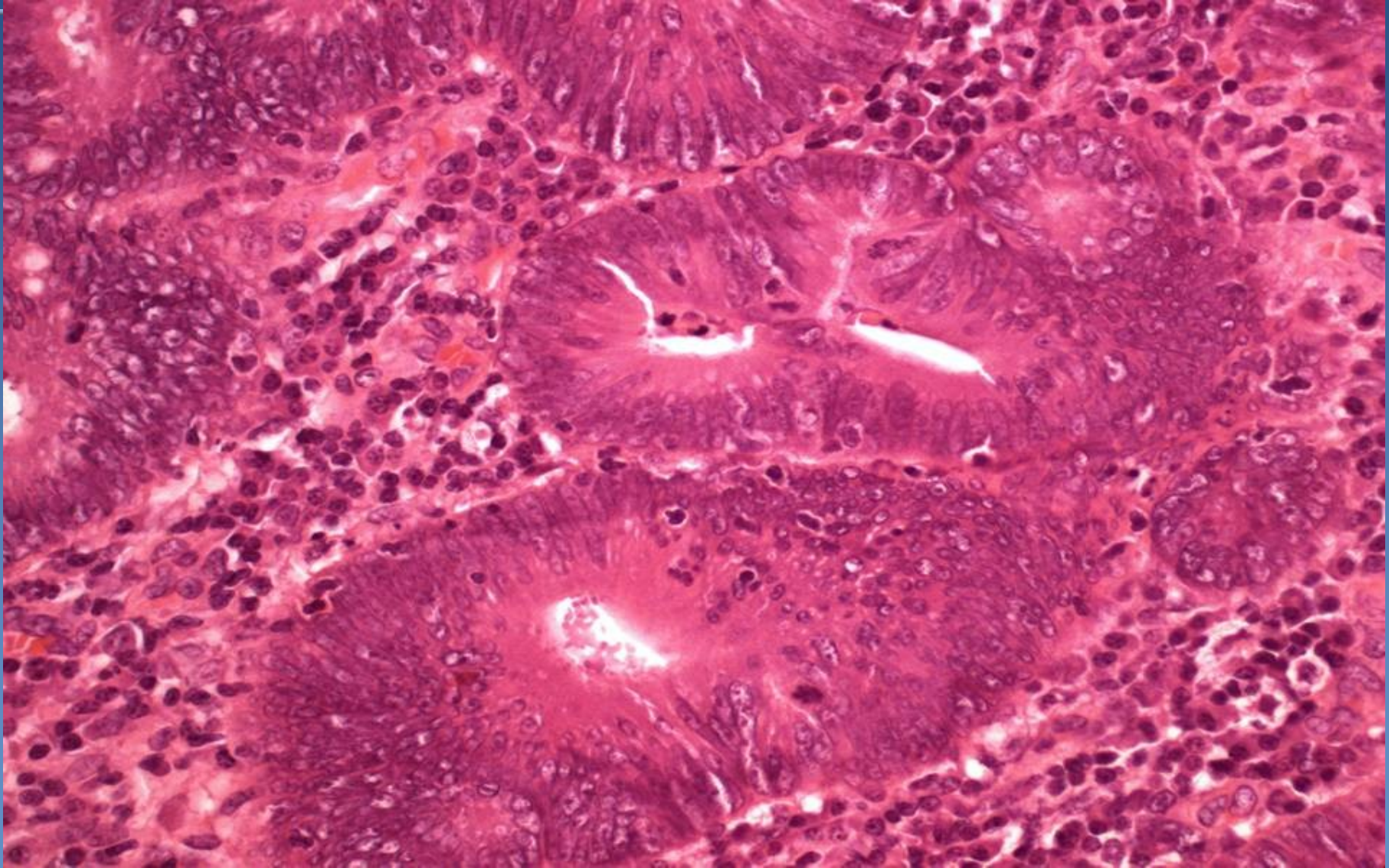


***Tubular adenoma  
– low grade dysplasia***

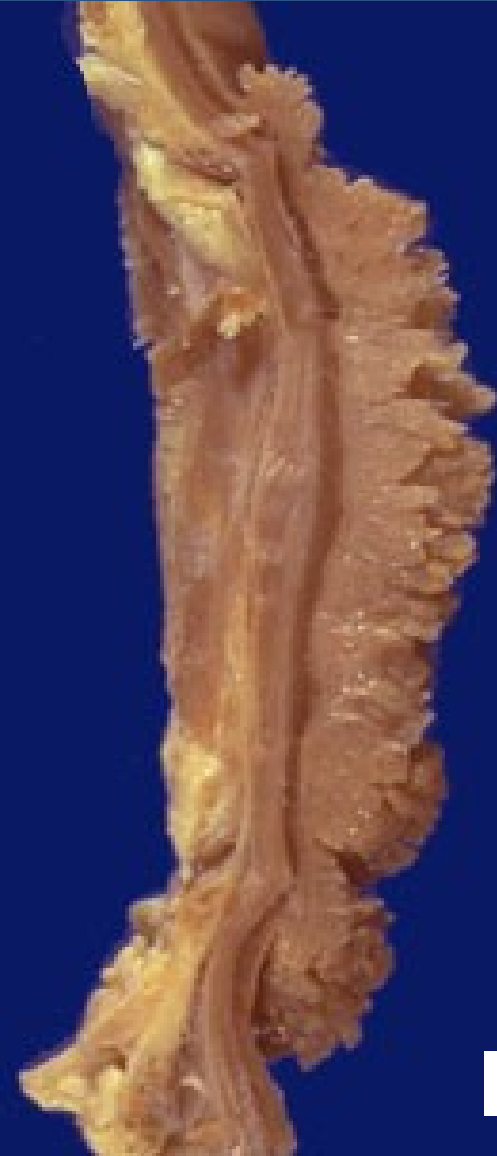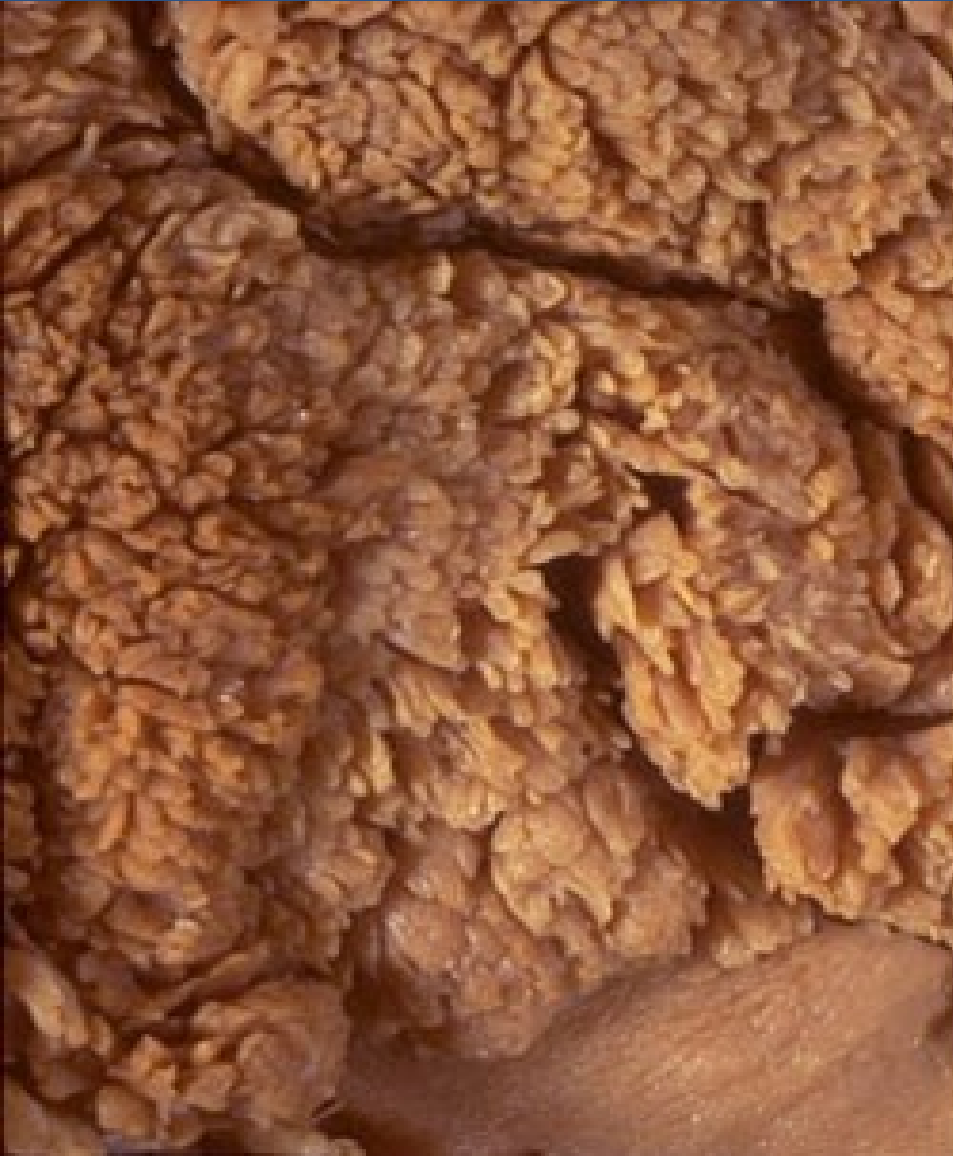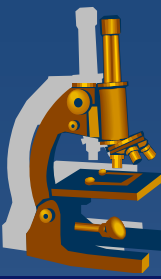




***Tubular adenoma  
– high grade dysplasia***



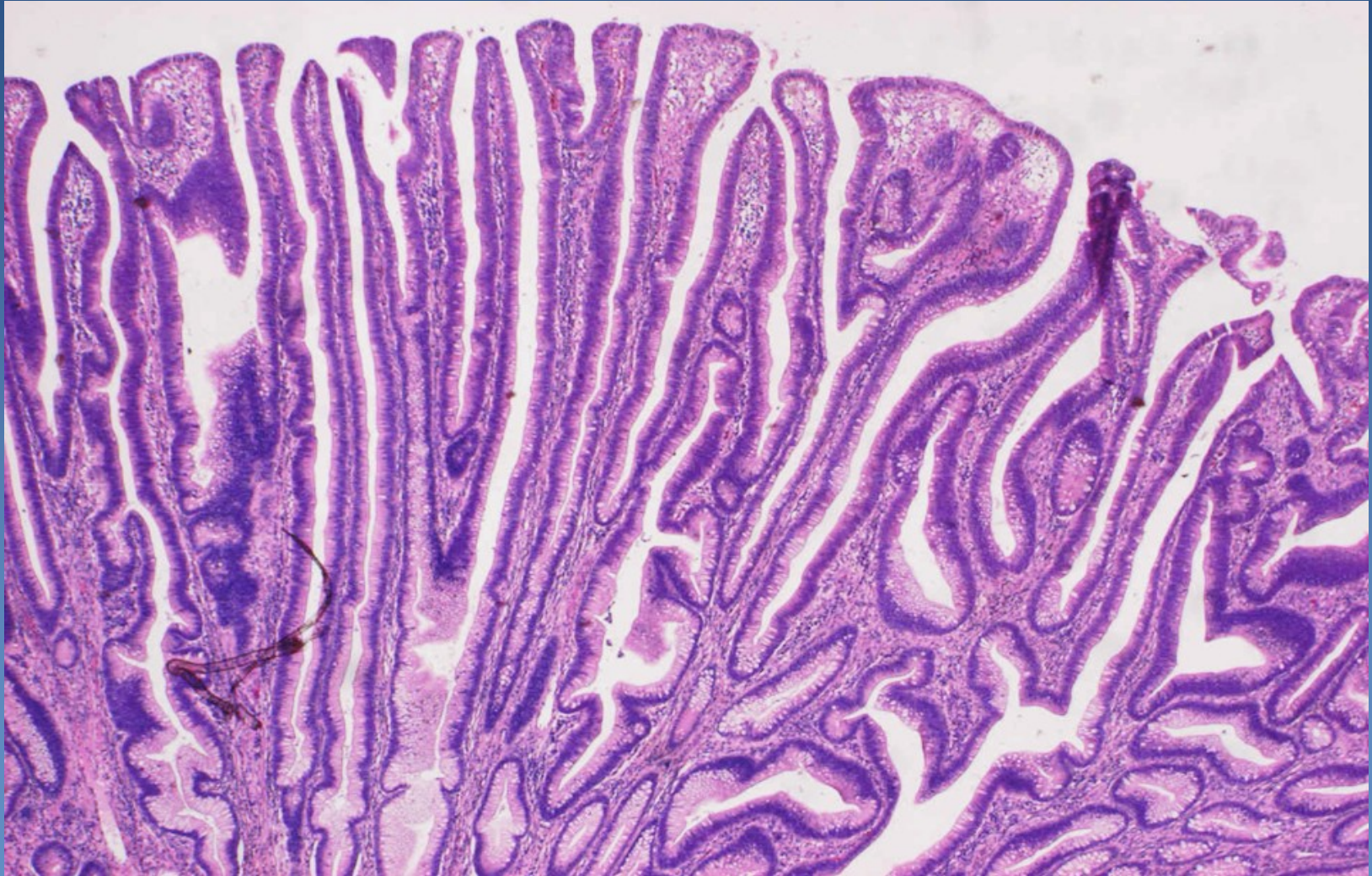
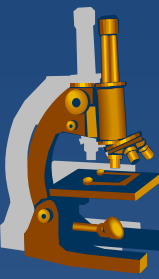
# *Villous adenoma*



copy



# *Villous adenoma*



# Colorectal carcinoma



- ✗ high incidence in the Czech Republic and other developed countries
- ✗ 60 - 70 % in the rectum and sigmoid (50% detectable by per rectum examination)
- ✗ Risk factors: lifestyle + diet, smoking, alcohol
  - ⇒ *high intake: refined carbohydrates, fat, red meat*
  - ⇒ *decreased intake: unabsorbable vegetable fiber, protective micronutrients (vitamins A,C,E)*
- ✗ predisposing factors: genetic
  - ⇒ *polyposis*
  - ⇒ *ulcerative colitis*

# Colorectal carcinoma



## ×Gross:

⇒ *exophytic, polypous*

- proximal colon - long time asymptomatic

⇒ *endophytic, ulcers with heaped-up edges*

- distal colon - early stenosis

⇒ *annular*

- encircling lesions

⇒ *infiltrative*

- rare, linitis plastica type



# Colorectal carcinoma



## ×Micro:

⇒ *tubular adenocarcinoma (most frequently)*

⇒ *other adenocarcinoma types:*

- cribriform comedo-type
- micropapillary
- medullary
- mucinous
- serrated
- signet ring cell

⇒ *adenosquamous, spindle-like, squamous cell, undifferentiated*

# Colorectal carcinoma



- ✘ **TNM classification and tumor progression:**
  - ⇒ *pTis intraepithelial/intramucosal (100% 5-year survival, no metastases)*
  - ⇒ *pT1 submucosa (90% survival)*
  - ⇒ *pT2 into the muscularis propria (+LN metastases possible);*
  - ⇒ *pT3 subserosa (+ metastases common), 35% survival in LN meta - pT3N1*
  - ⇒ *pT4 transperitoneal/invasion into adjacent organ*  
*Distant metastases present - 8% survival.*

# *Colorectal carcinoma*

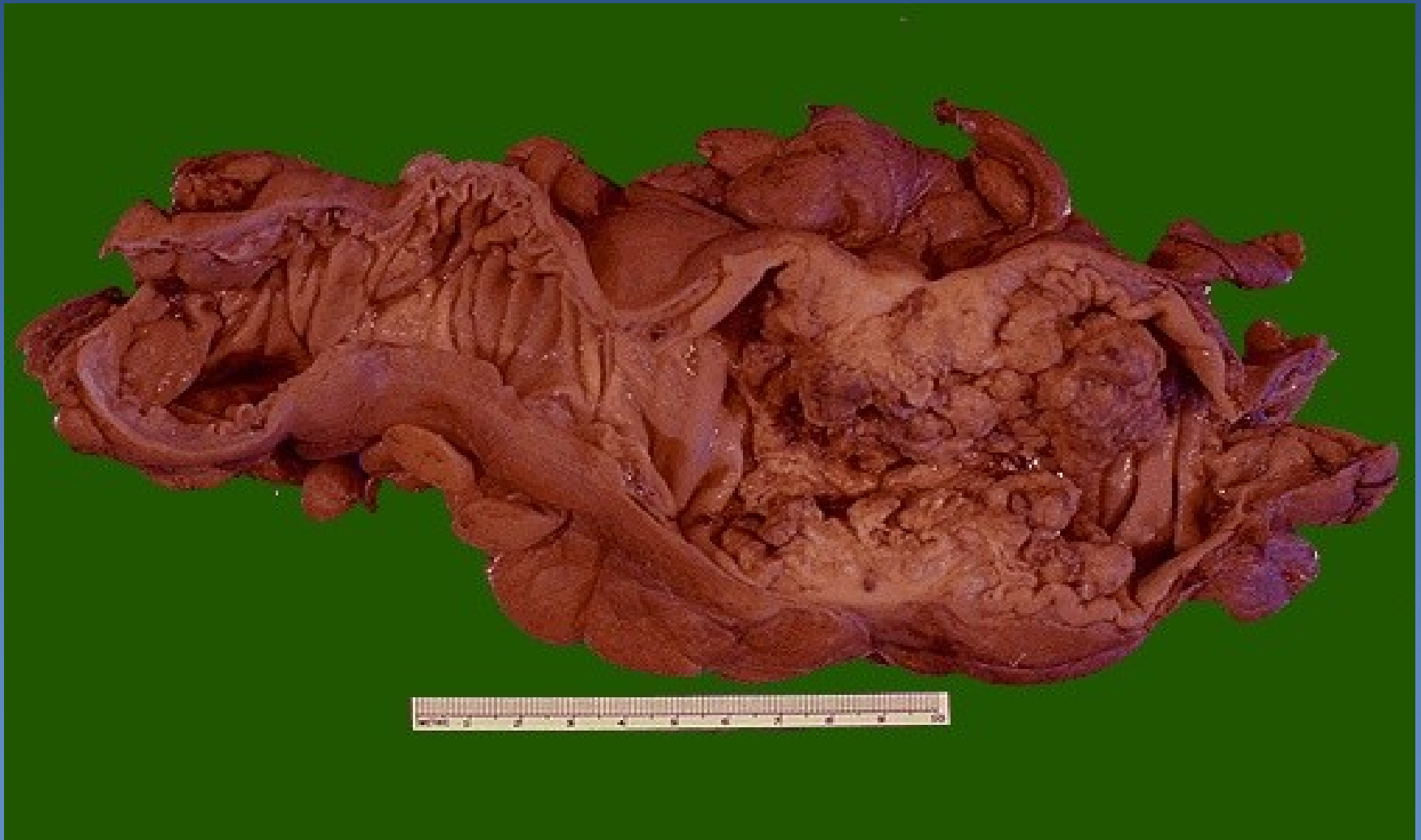

## Staging

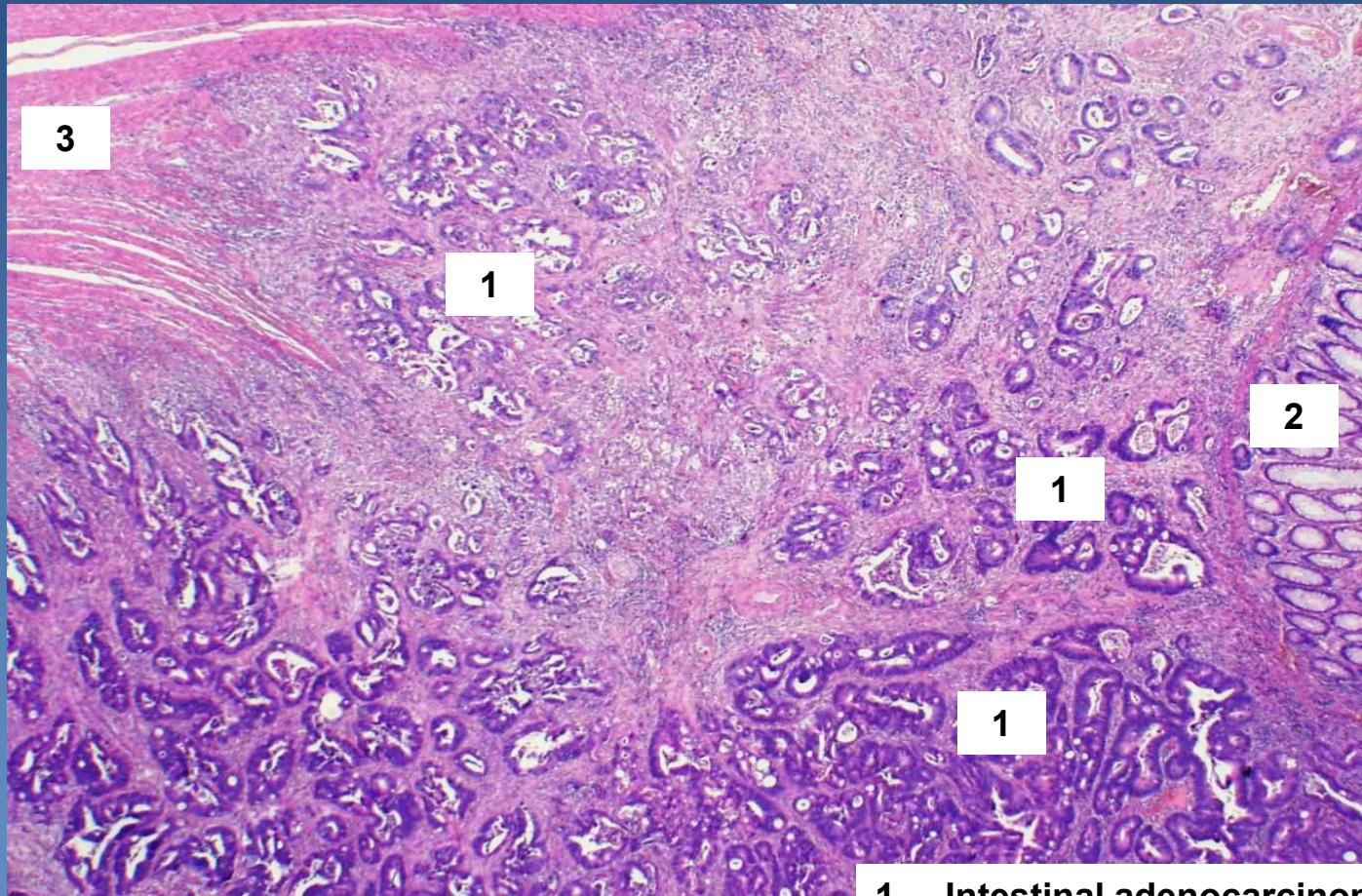
- ✗ stage I: T1, T2, no meta
- ✗ stage II: T3, T4, no meta
- ✗ stage III: any T, LN meta, no distant meta (M0)
- ✗ stage IV: any T, any N, M1



# *Colorectal carcinoma*



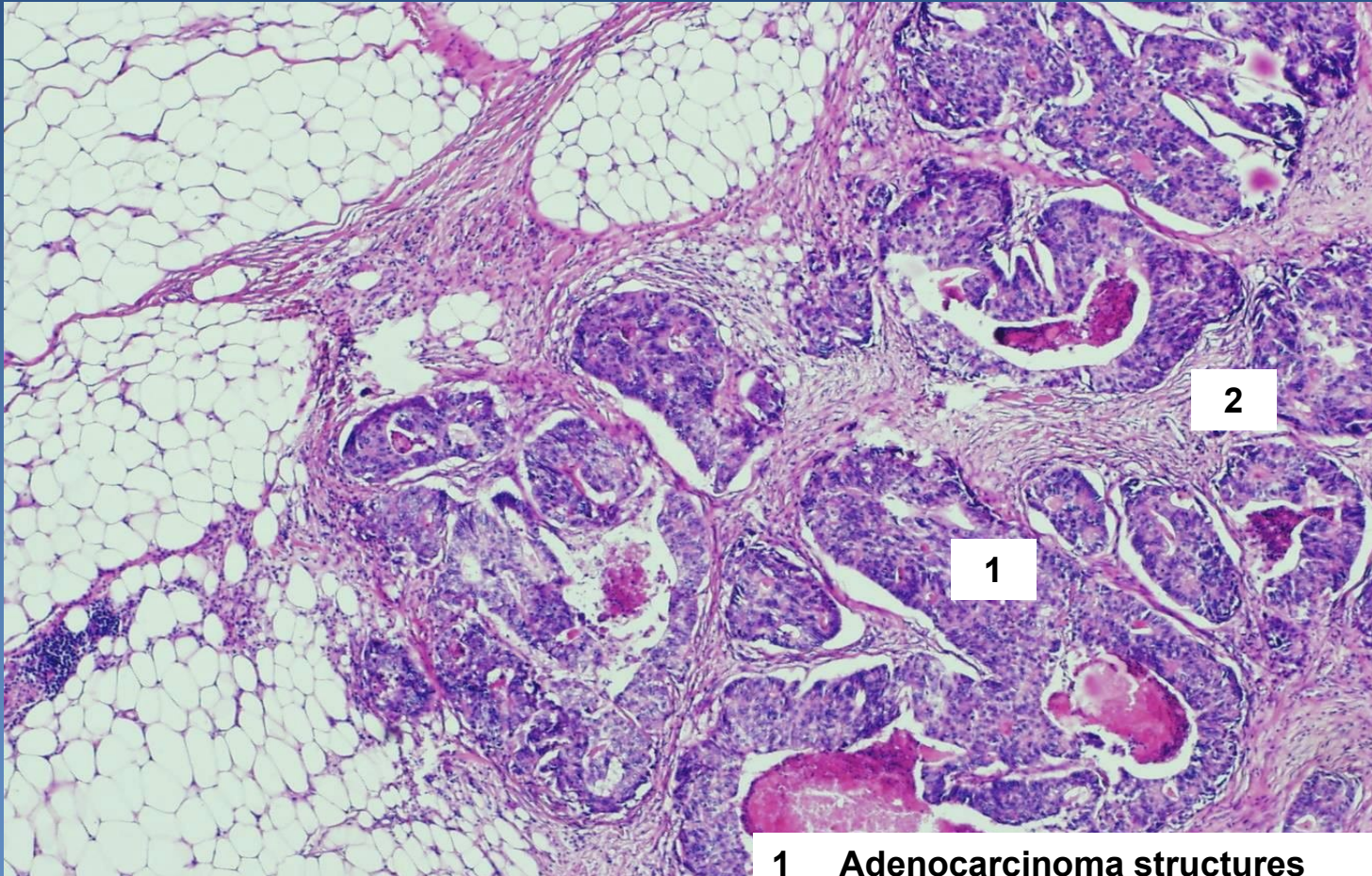
# *Adenocarcinoma of the colon*



- 1** Intestinal adenocarcinoma structures
- 2** Normal colonic epithelium
- 3** Muscularis propria



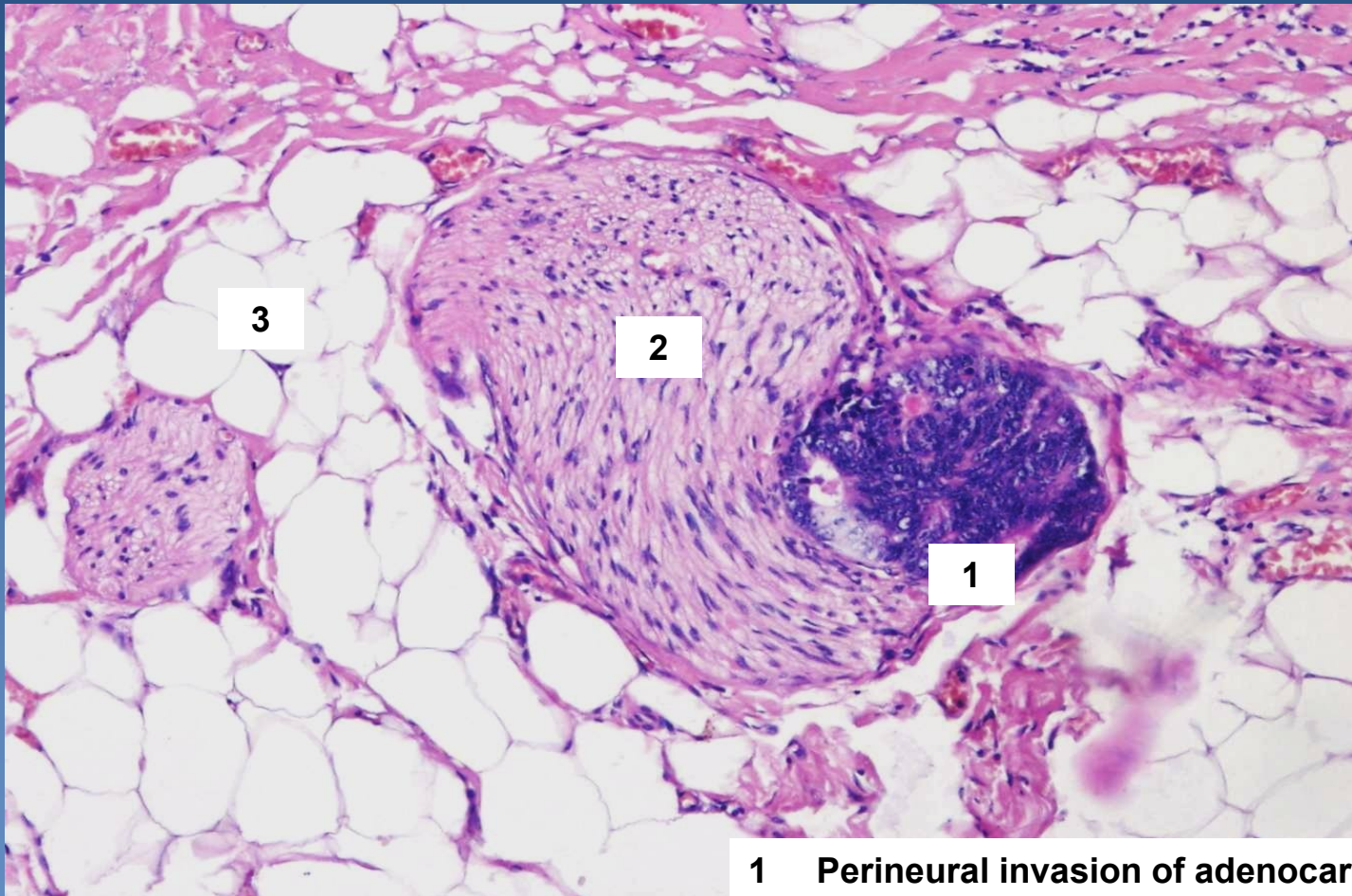
# *Adenocarcinoma of the colon*



- 1 Adenocarcinoma structures**
- 2 Pericolonic fat and fibrous tissue**

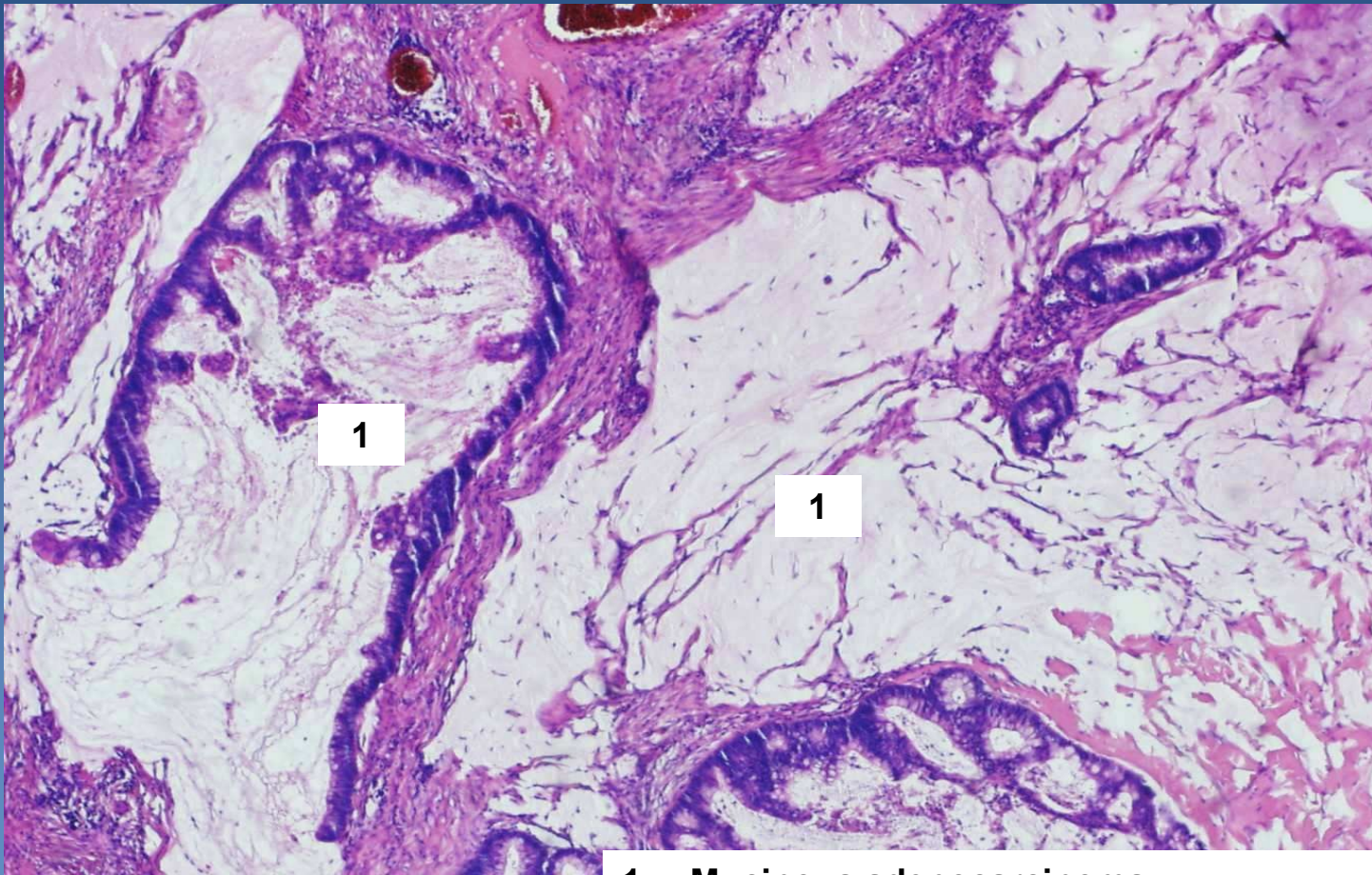


# *Adenocarcinoma of the colon*



- 1** Perineural invasion of adenocarcinoma
- 2** Peripheral nerve
- 3** Pericolonic fat

# *Adenocarcinoma of the colon*



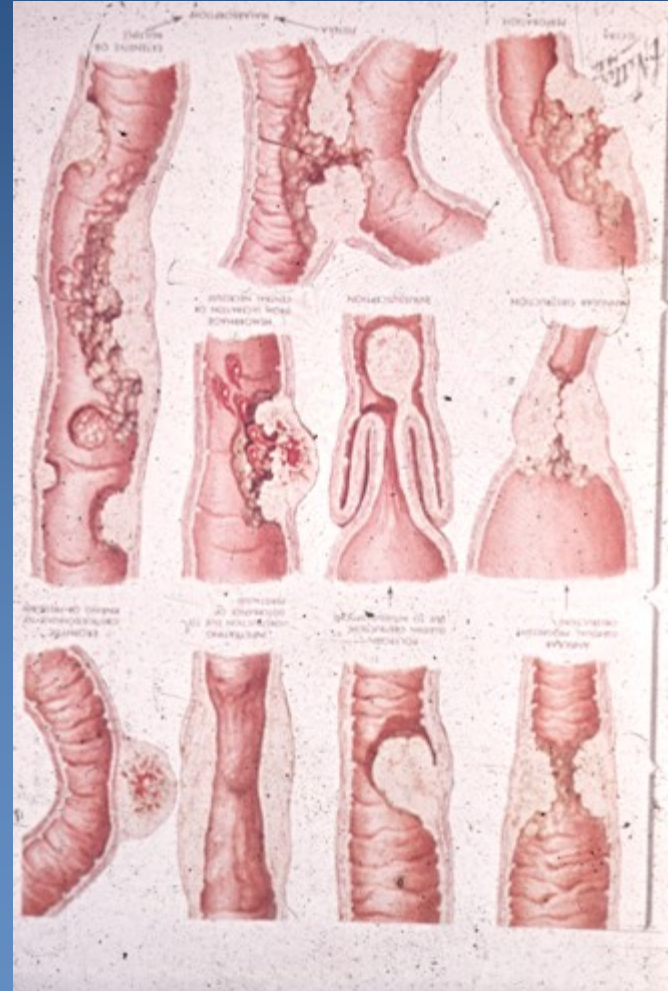**1 Mucinous adenocarcinoma**



# Colorectal carcinoma - complications

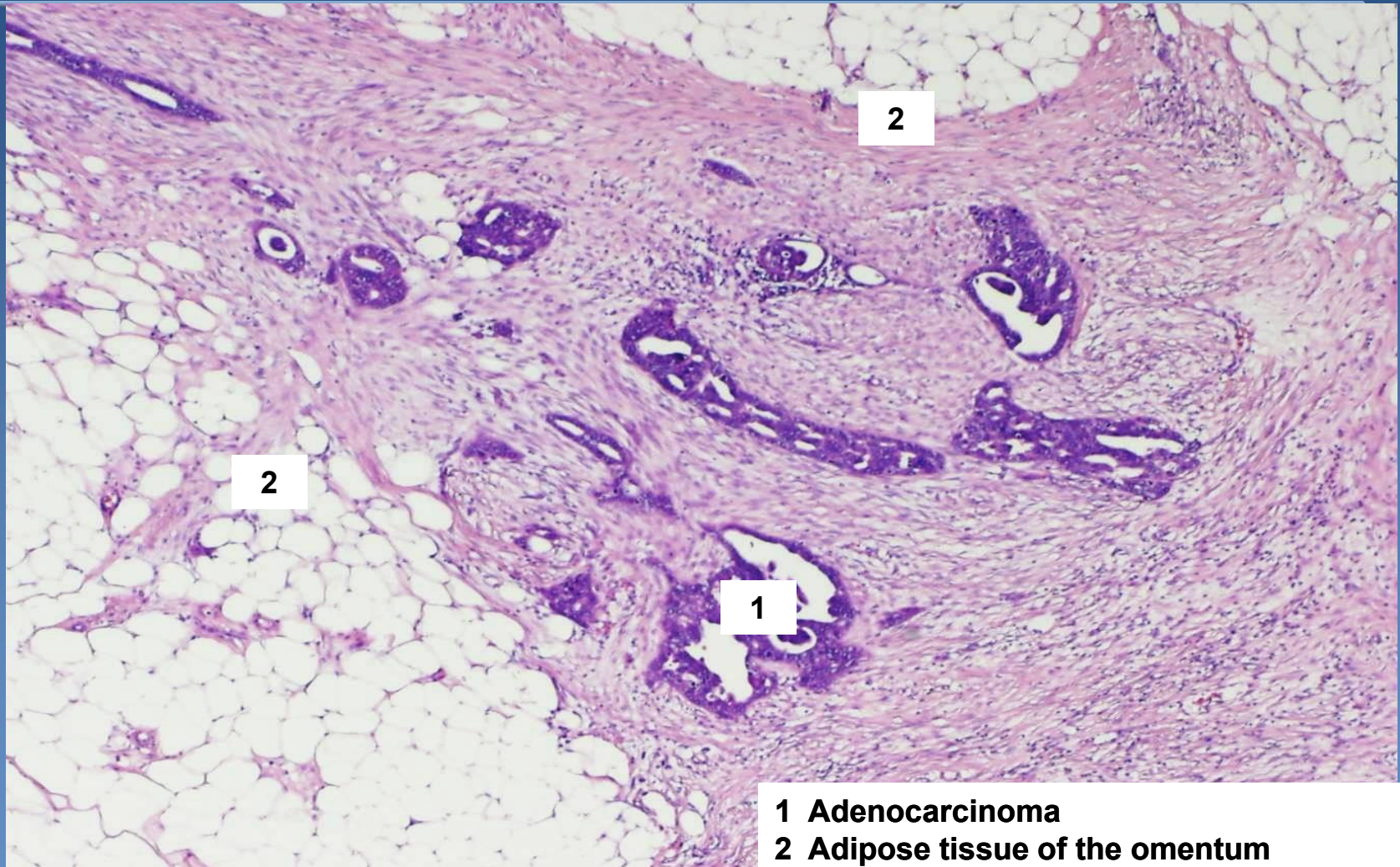


- ✗ stenosis
- ✗ obstructive ileus
- ✗ hemorrhage (occult!, overt)
- ✗ perforation
- ✗ penetration
- ✗ stercoral peritonitis



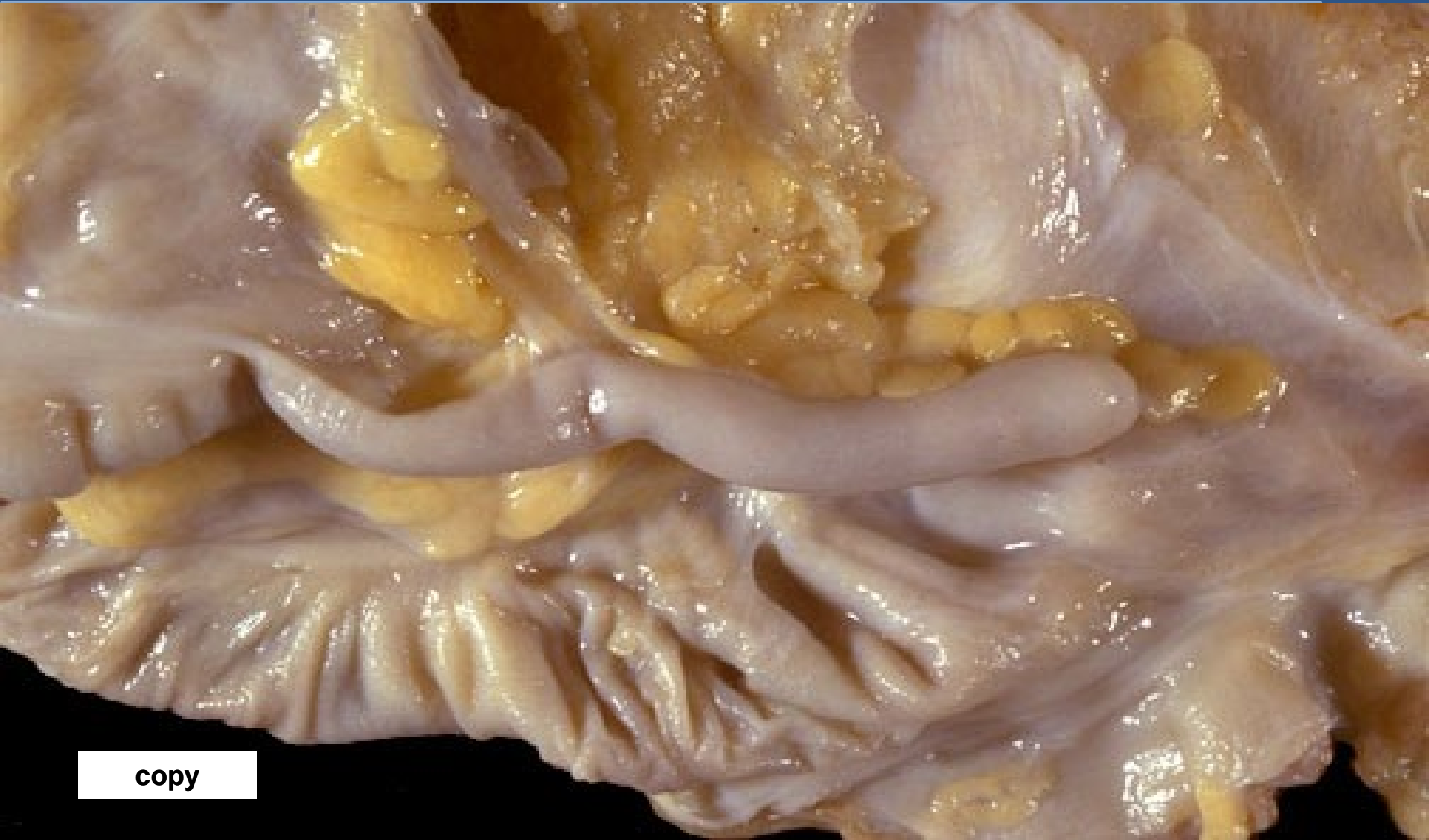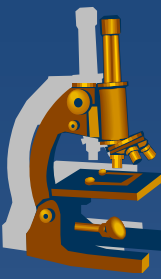


# ***Peritoneal carcinomatosis*** ***widespread metastases in the peritoneum/ omentum***



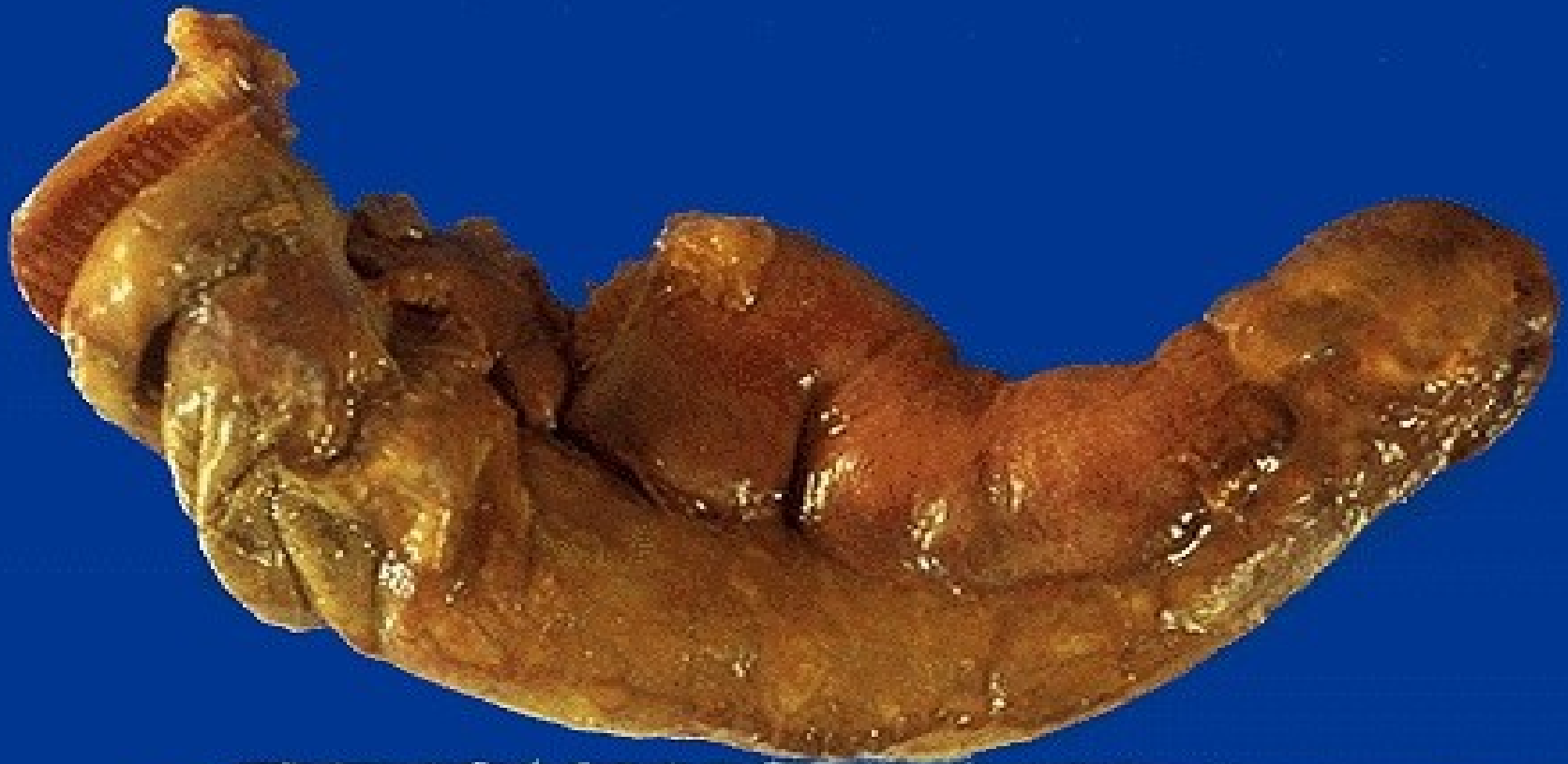**1 Adenocarcinoma**  
**2 Adipose tissue of the omentum**

# *Appendix - normal*



copy

# *Appendix - periappendicitis*



copy

SPECIMEN SP 4778-78 DATE 11/1/78

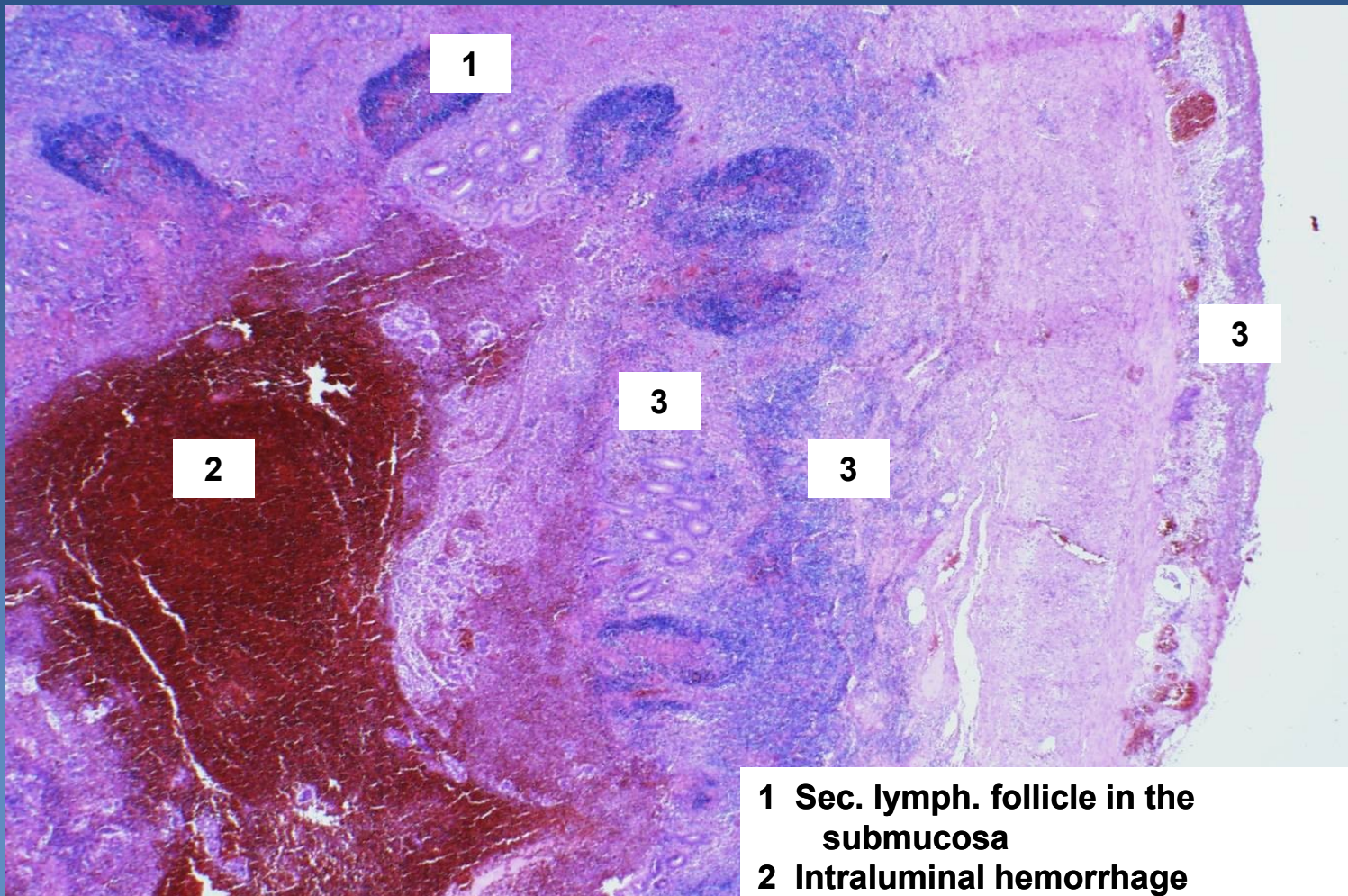


# Appendicitis



- ✘ Causes: ?obstruction, stool stagnation → collapse of the draining veins → ischemia of the wall → bacterial proliferation → inflammation (catarrhal, phlegmonous)
- ✘ Trombosis of mesenteric veins → ischemic necrosis of the appendiceal wall → secondary bacteria invasion → gangrenous inflammation
- ✘ Complications:
  - ⇒ *peritonitis*
  - ⇒ *periappendiceal abscess*
  - ⇒ *portal pyemia*
  - ⇒ *adhesions*

# *Phlegmonous appendicitis*

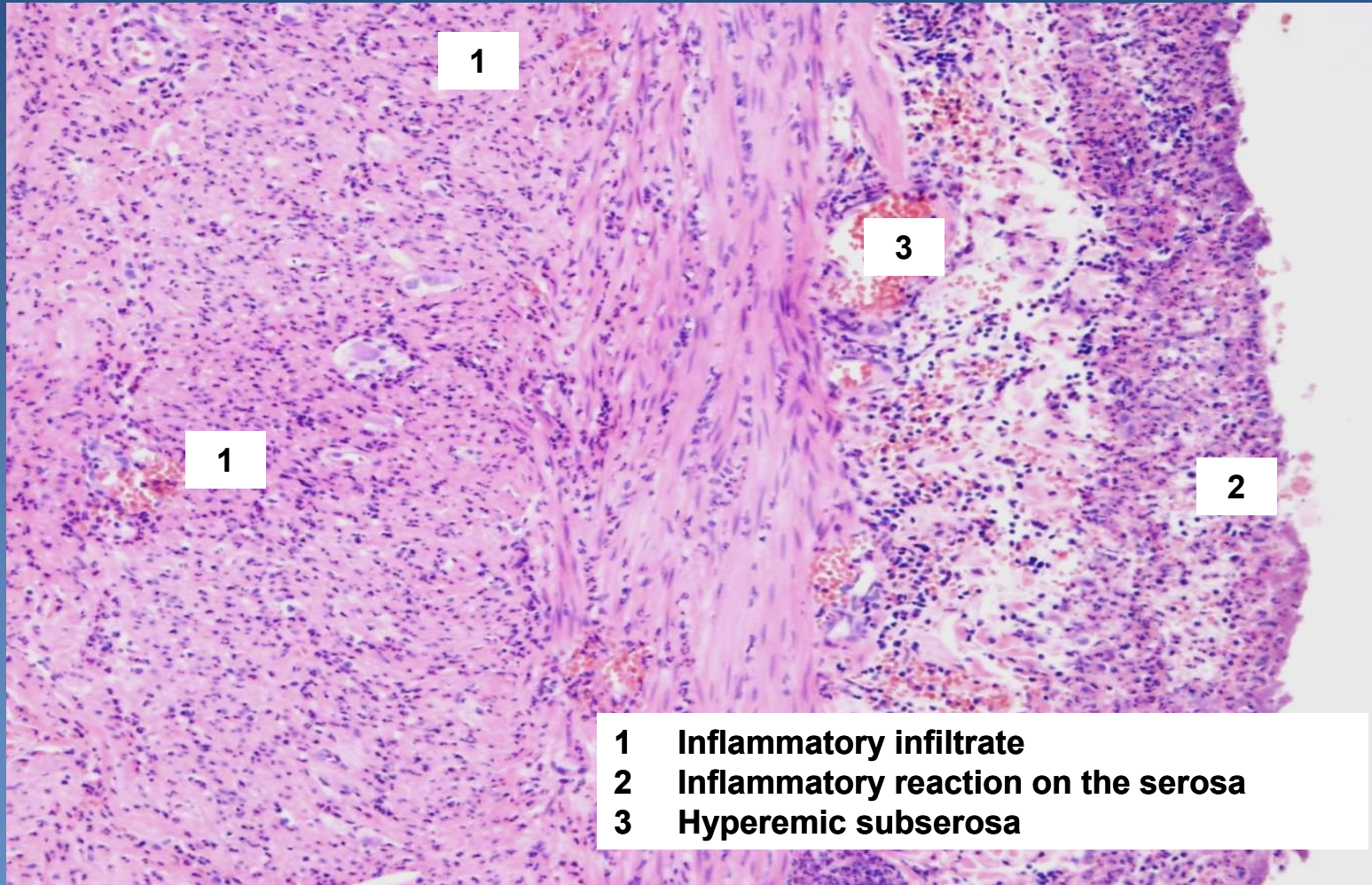


- 1** Sec. lymph. follicle in the submucosa
- 2** Intraluminal hemorrhage
- 3** Inflammatory infiltrate



# *Phlegmonous appendicitis*

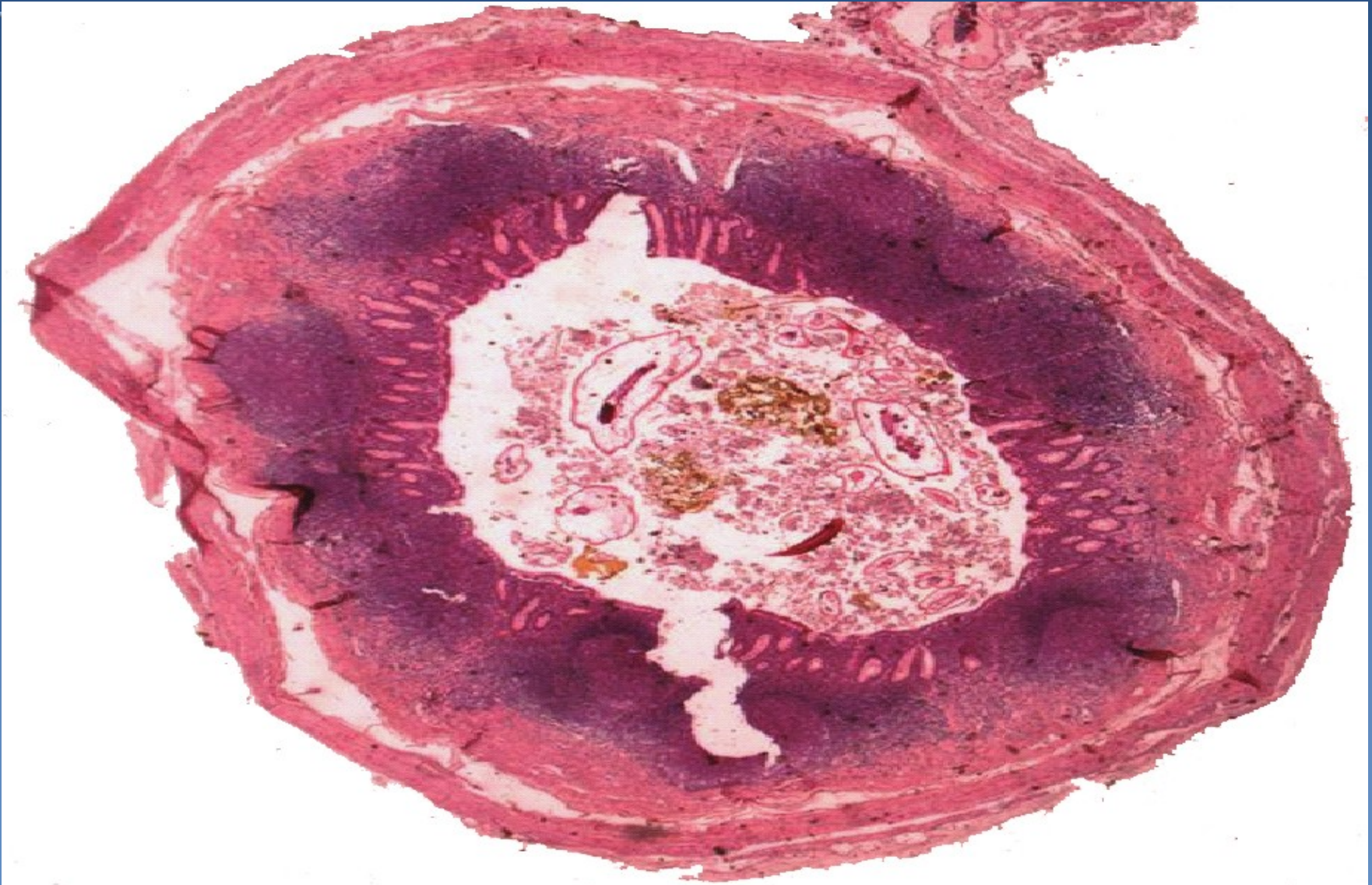
## *- detail*



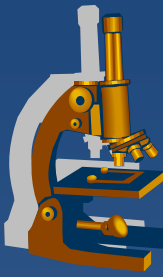
- 1** Inflammatory infiltrate
- 2** Inflammatory reaction on the serosa
- 3** Hyperemic subserosa



***Parasitic appendicitis***  
**- *Oxyuriasis vermicularis* (pinworm)**  
***in the lumen***



# ***Neuroendocrine tumors (NETs)***



**✗ arise from neuroendocrine cells of the gastro-entero-pancreatic system (GEP-NET)**

**✗ histologic classification WHO 2010:**

⇒ ***NET G1 (carcinoid)***

⇒ ***NET G2***

⇒ ***NEC G3 large cell or small cell type***

⇒ ***compound adenoneuroendocrine carcinoma***

# *Neuroendocrine tumors (NET)*

---



- × arise from neuroendocrine or precursor cells of the GIT mucosa
- × mostly in the ileum and appendix (80%)
- × all NETs (except for a very few) **are considered malignant** in various grade



# GEP-NET



**x classification** *depends on:*

⇒ *location*

⇒ *type of the endocrine product*

**x gross:**

⇒ *small, round-shaped, flat nodules of yellowish colour, infiltrating the wall to different depth, superficially ulcerated or covered with normal mucosa, sometimes exophytic*

# GEP-NET



## **x**micro:

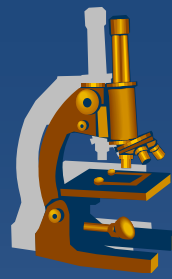
- ⇒ *trabecular, glandular structures - tubules, palisading or compound structure*
- ⇒ *regular cells with clear cytoplasm and round or oval-shaped nucleus; slight nuclear polymorphism*
- ⇒ *low mitotic activity*
- ⇒ *chromogranin A in cytoplasm*

# GEP-NET

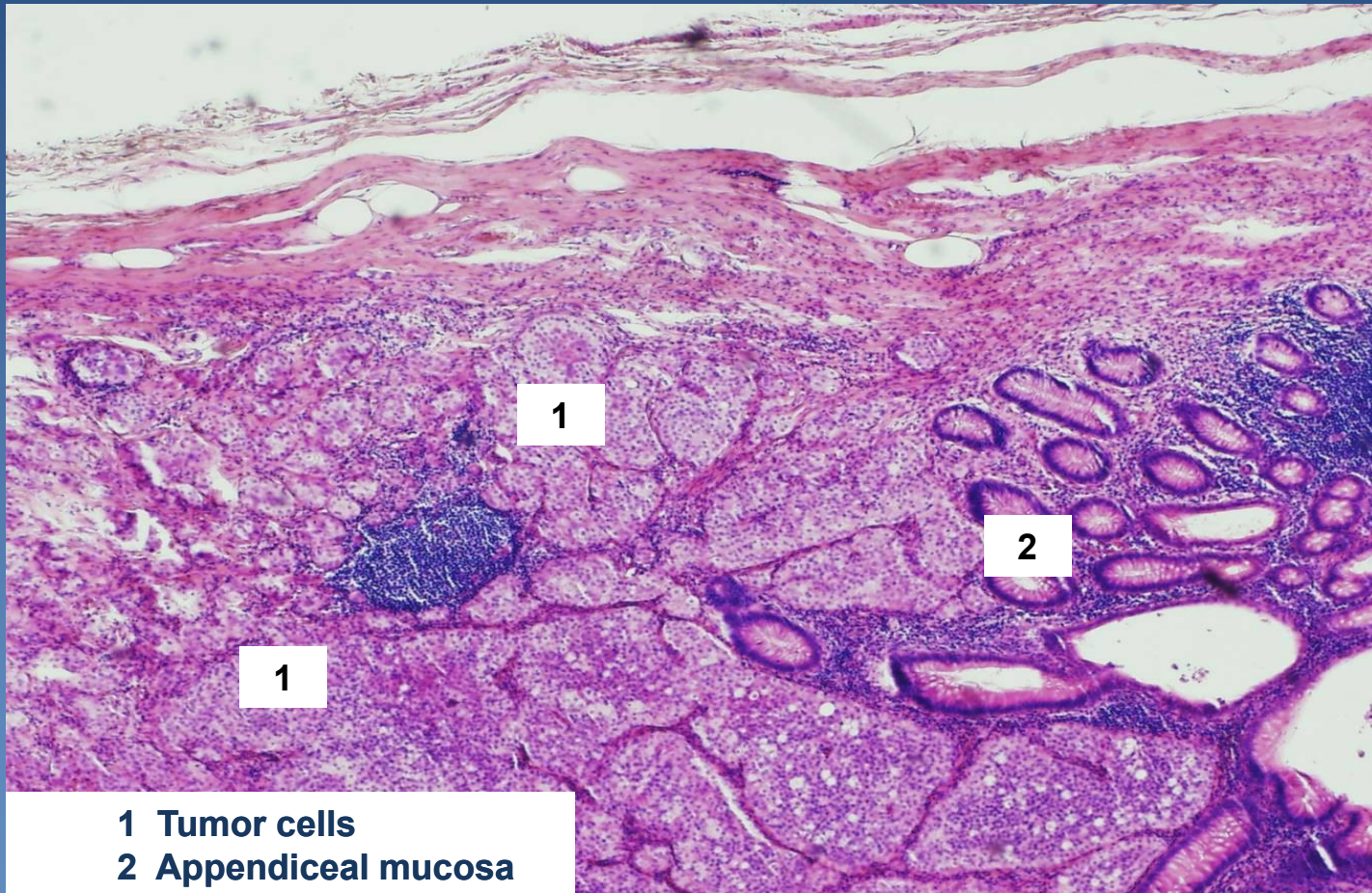


- ✗ possible production of various endocrine substances: serotonin, somatostatin, gastrin
- ✗ *serotonin active only locally in intestine → intestinal hypermotility with diarrhea*
- ✗ **liver metastases → carcinoid syndrome:**  
*cutaneous „flush“ and cyanosis, nausea and vomiting, asthmatic bronchoconstrictive attacks, endocardial fibrosis in right ventricle, hepatomegaly*



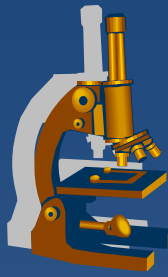


# *Carcinoid of the appendix*

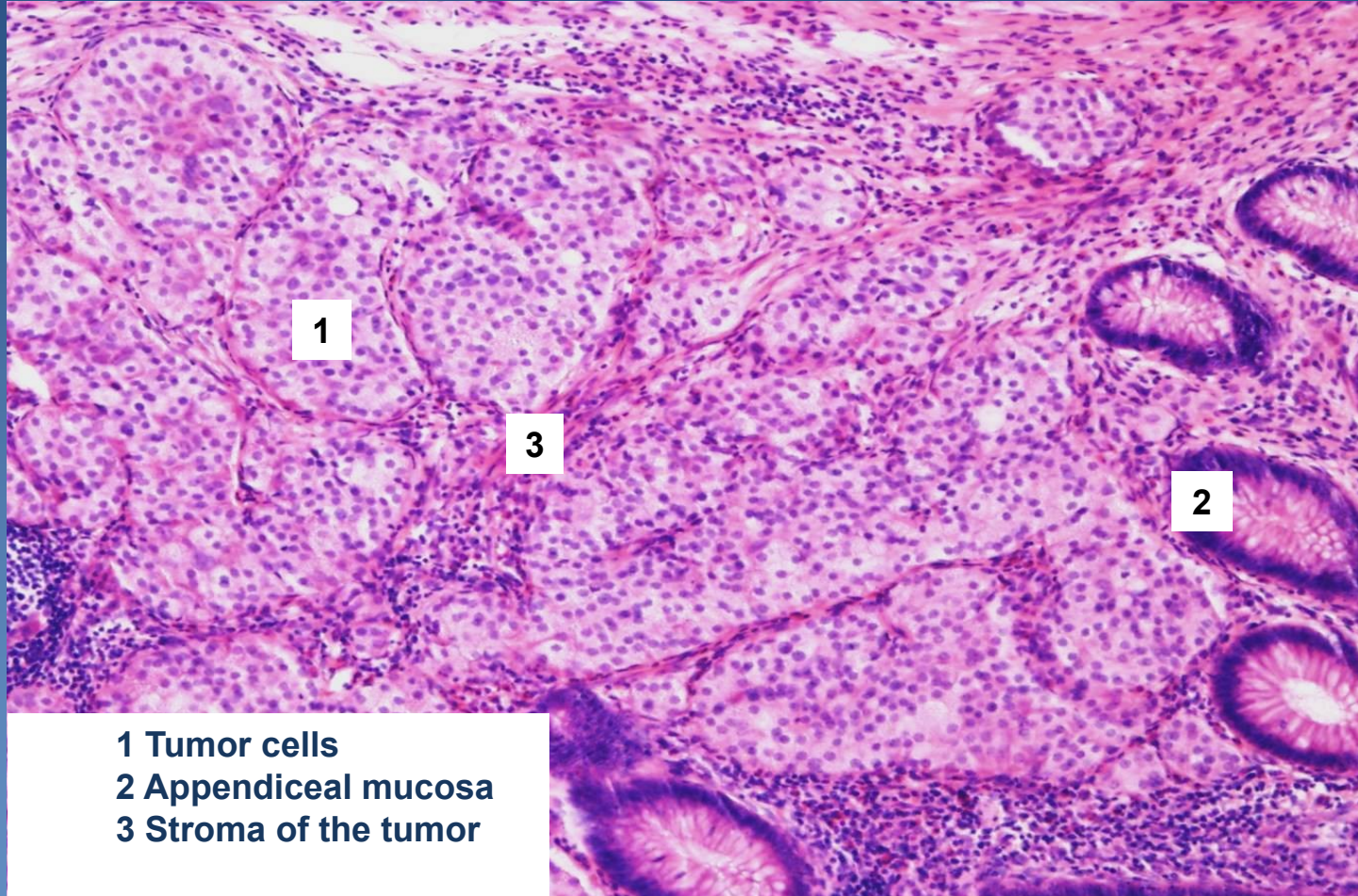


- 1 Tumor cells
- 2 Appendiceal mucosa



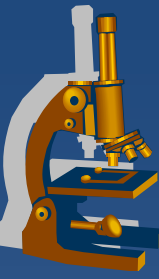


# ***Carcinoid of the appendix*** ***detail***

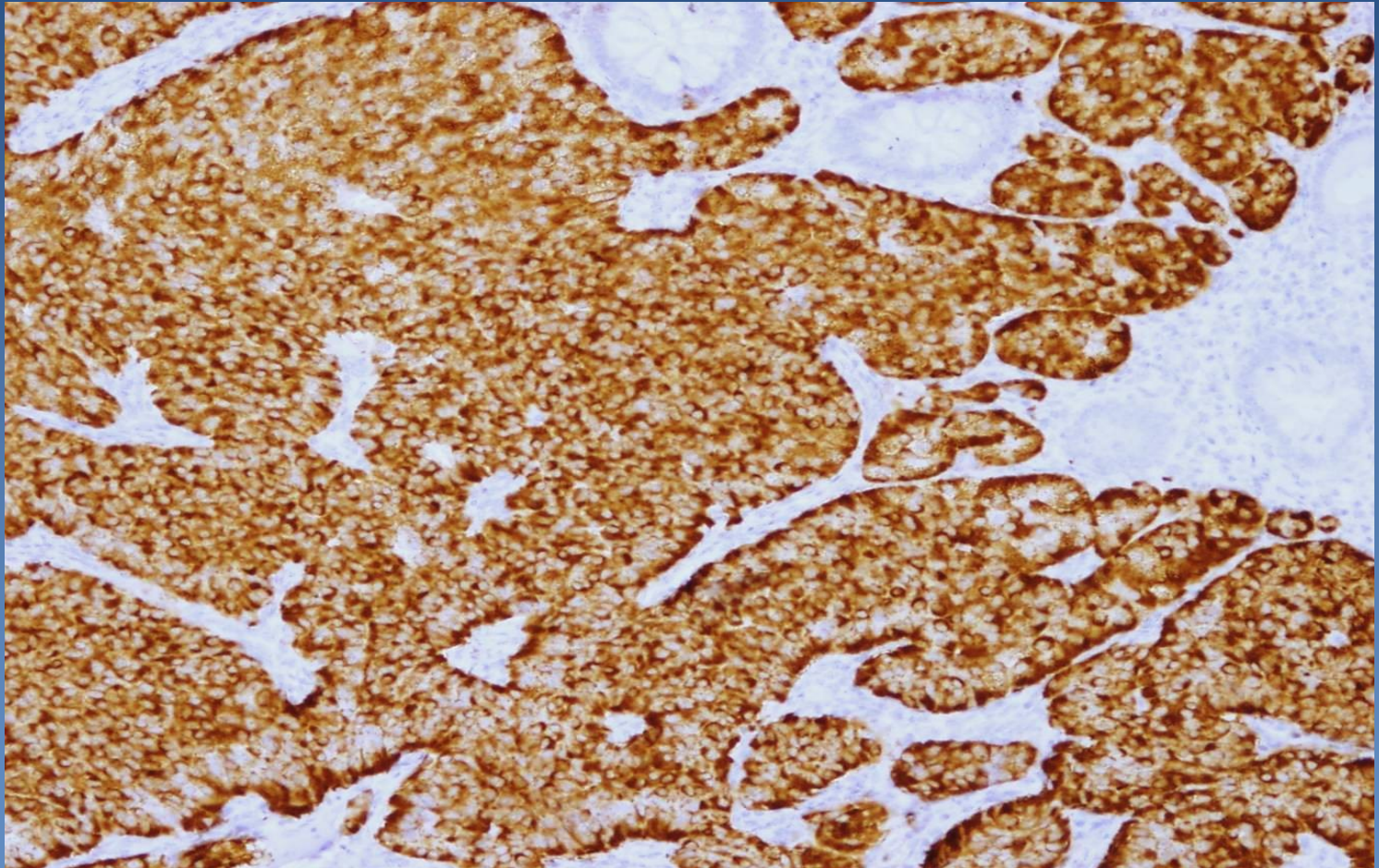


- 1 Tumor cells**
- 2 Appendiceal mucosa**
- 3 Stroma of the tumor**





# ***Carcinoid of the appendix*** ***(IHC chromogranin)***







---

***THANK YOU FOR  
ATTENTION***