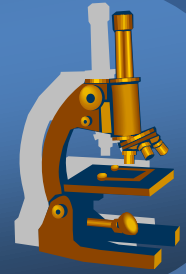


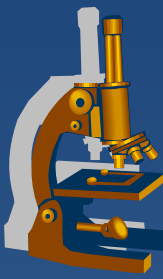
# ***Systemic Pathology***



Hepatobiliary, pancreas, diabetes mellitus, endocrine system

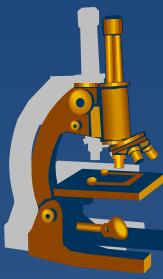
# *Morphology of hepatic injury*

---



- ✗ hepatocyte degeneration and/or pathologic intracellular accumulation (i. e. fatty liver, pigment, ...)
- ✗ hepatocyte necrosis, apoptosis
- ✗ inflammation
- ✗ regeneration
- ✗ fibrosis

# Fatty liver disease - steatosis



## ✗ gross:

⇒ *enlarged, paler, in extreme cases yellow, softer consistency*

## ✗ micro:

⇒ *small or confluent droplets in cytoplasm*

## ✗ causes:

⇒ *alcohol*

⇒ *other toxins (drugs, organic substances)*

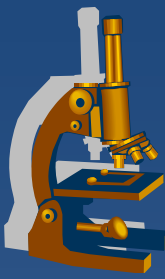
⇒ *diabetes mellitus + metabolic syndrome*

⇒ *excessive fat intake*

⇒ *infection (hepatitis C, ...)*

⇒ *hypoxia*

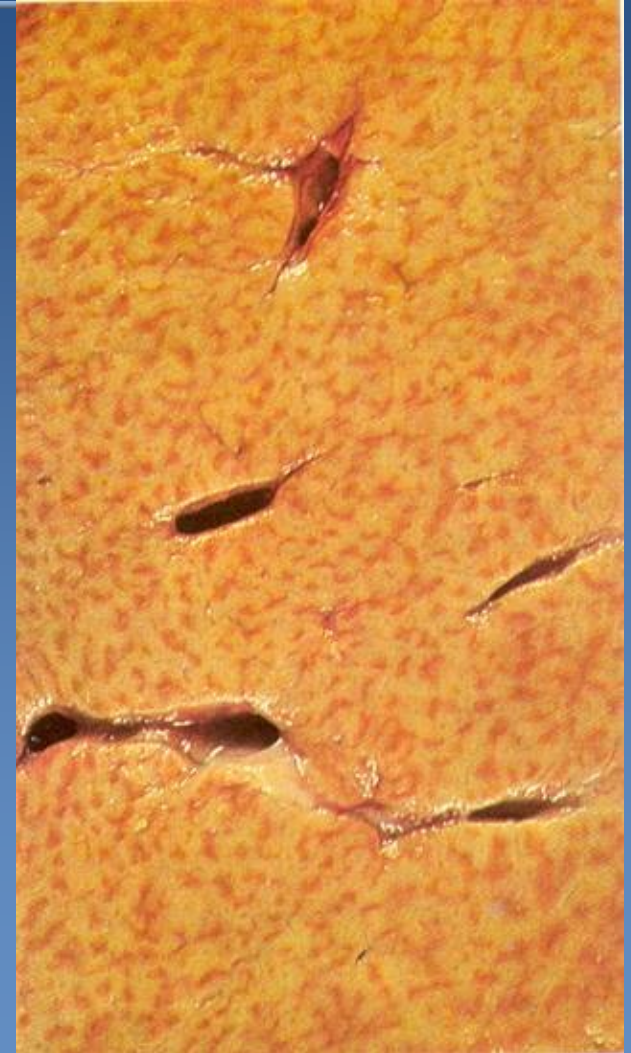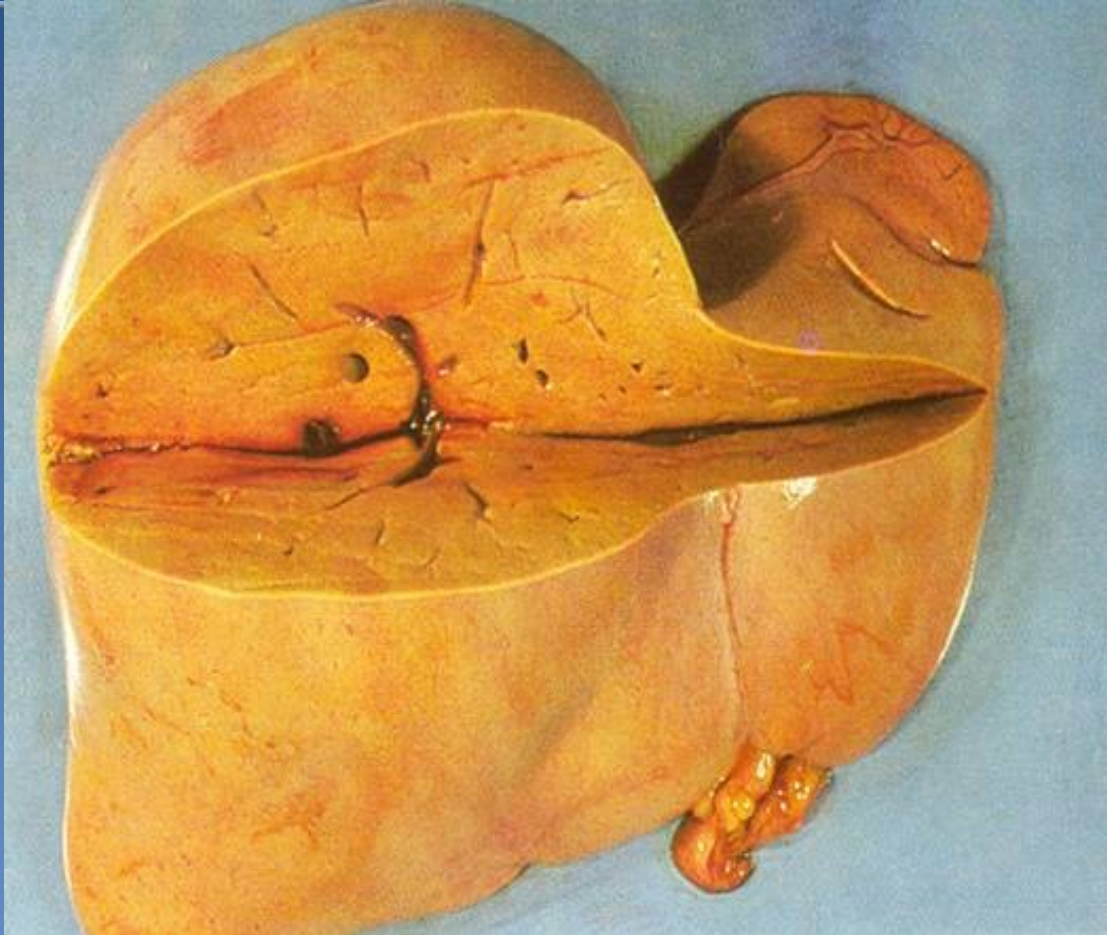
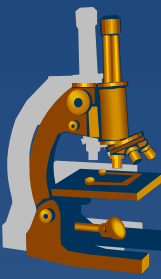
# *Fatty liver - steatosis*



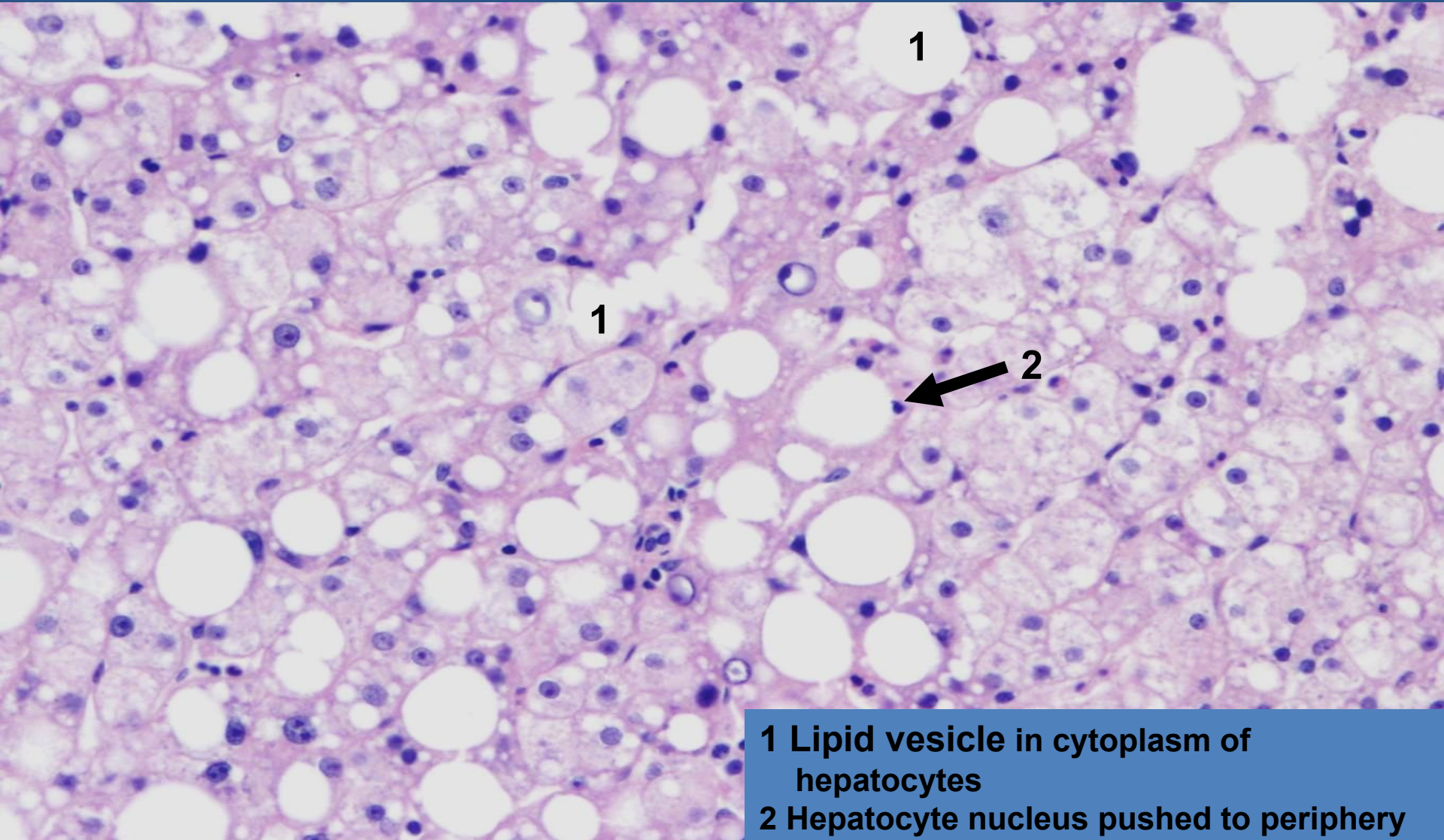
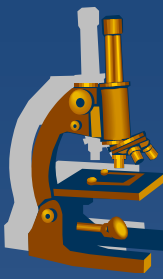
= pathological accumulation of lipids in form of intracytoplasmatic vesicles

- x without inflammatory reaction reversible process
- x with inflammation (steatohepatitis) – possible progression to cirrhosis
- x microvesicular x macrovesicular
  - ⇒ *vesicle < or > than hepatocyte nucleus*
  - ⇒ *variable distribution (diffuse, zonal, focal), may help to the etiological diagnosis*

# *Fatty liver disease - steatosis*



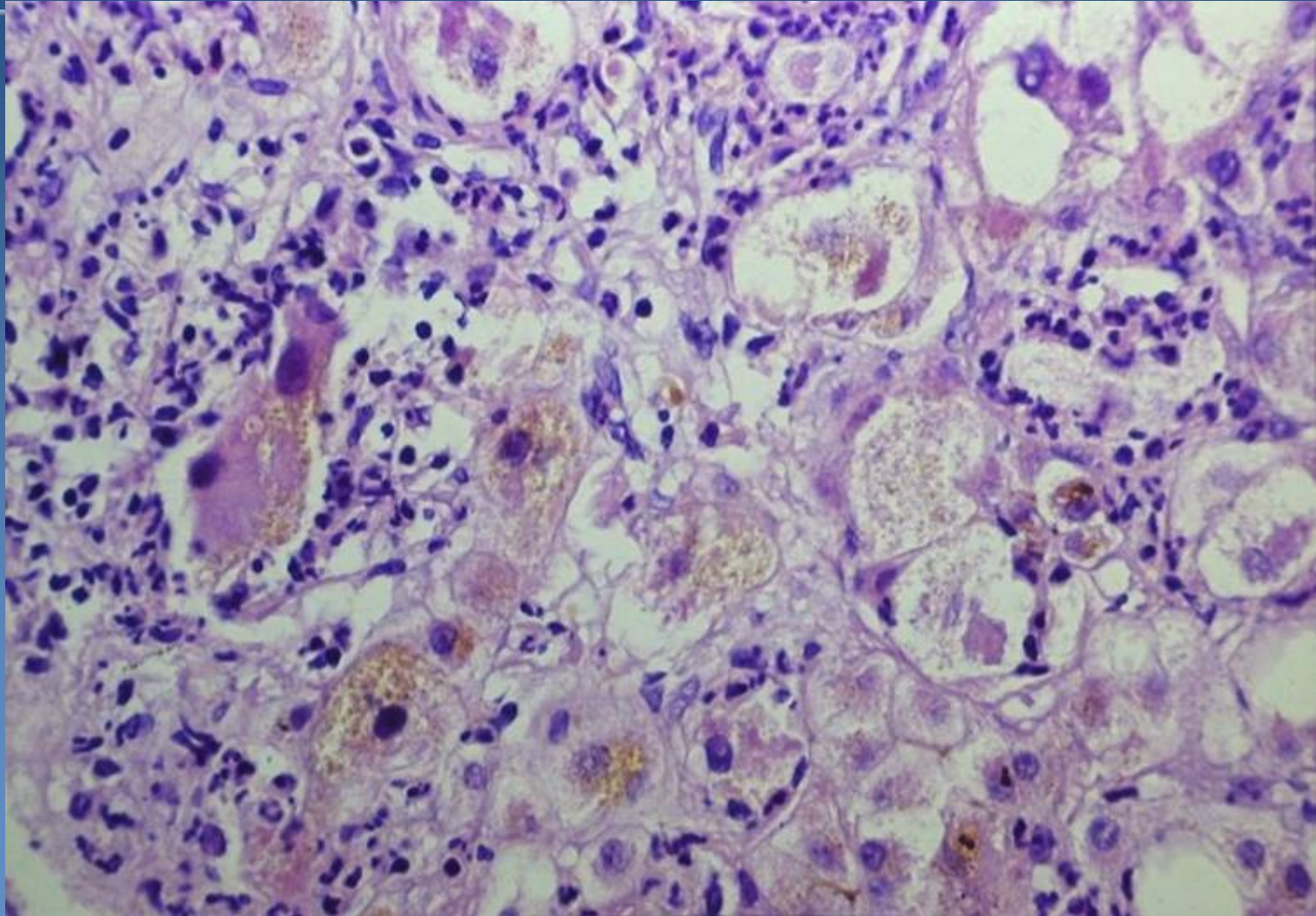
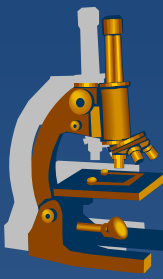
# *Alcoholic fatty liver*



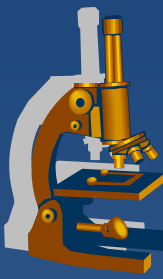
**1** Lipid vesicle in cytoplasm of hepatocytes

**2** Hepatocyte nucleus pushed to periphery

***Alcoholic hepatitis : steatohepatitis,  
cholestasis, Mallory hyaline***



# Cholestasis



## × Causes:

- ⇒ *hepatocellular dysfunction (inborn, acquired)*
- ⇒ *biliary obstruction (intra-, extrahepatic)*

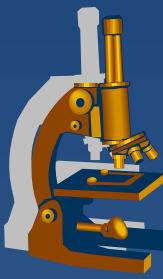
## × Signs:

- ⇒ *pruritus - itching (↑ serum bile acids)*
- ⇒ *hyperlipidemia → skin xanthomas (focal cholesterol accumulation)*
- ⇒ *malabsorption → ↓ fat soluble vitamins (A; D; K)*
- ⇒ *↑ ALP (serum alkaline phosphatase)*



# ***Cholestasis***

## ***MORPHOLOGY***



### **xGross:**

⇒ *green-brown (olive) discoloration*

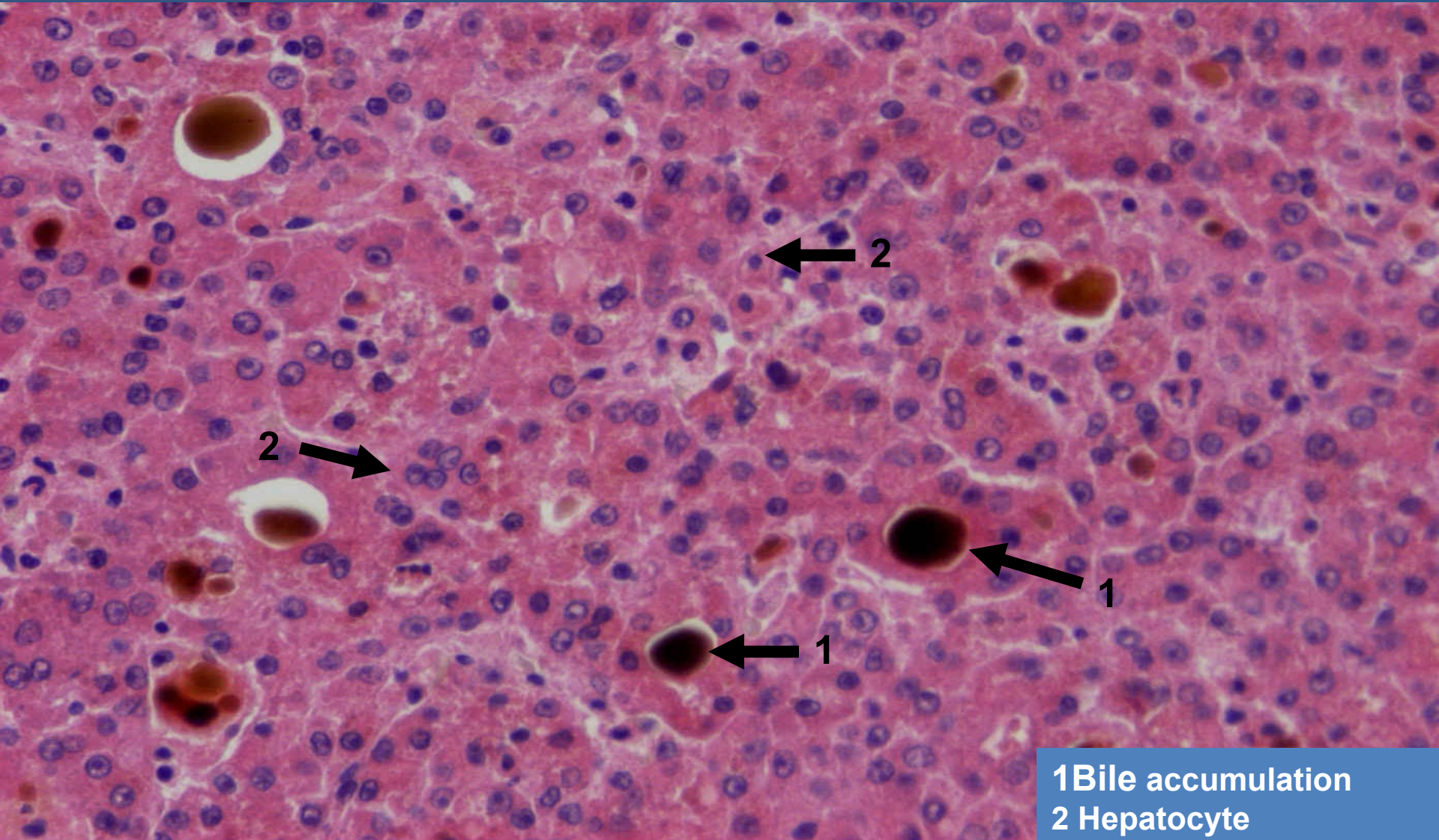
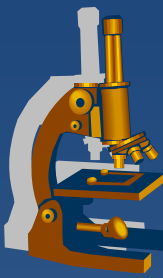
### **xMicro:**

⇒ *bile pigment accumulation in hepatocytes / canaliculi („bile plugs“)*

⇒ *edema, periductal neutrophilic infiltrates in portal spaces*

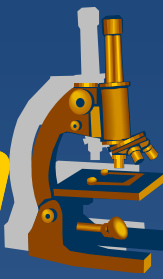
⇒ *chronic obstruction → portal fibrosis → biliary cirrhosis*

# *Cholestasis in HCC*



1 Bile accumulation  
2 Hepatocyte

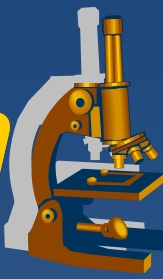
# *Hepatic venous congestion*



## **x** GROSS:

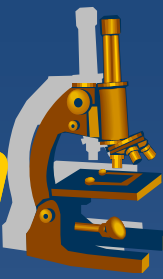
- ⇒ *enlarged, heavy liver*
- ⇒ *dark – reddish brown color*
- ⇒ *cardiac fibrosis (induration)*
- ⇒ *combination with chronic hypoxemic steatosis –  
**nutmeg liver***

# ***Hepatic venous congestion*** ***("nutmeg" liver)***



# *Hepatic venous congestion*

---



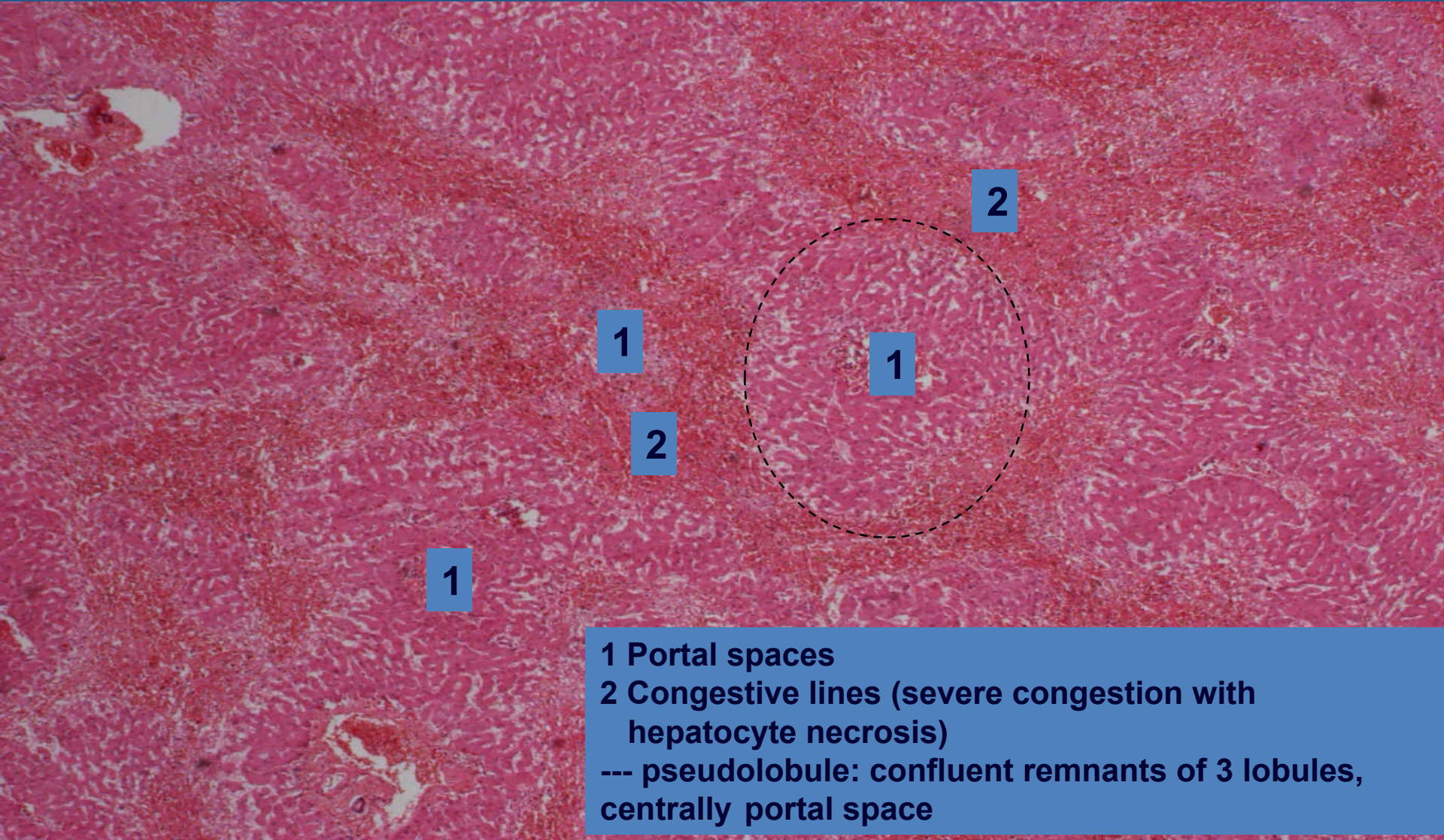
## **x** MICRO:

⇒ *central veins and sinusoidal dilatation*

⇒ *centrolobular hepatocytic atrophy, necrosis*

⇒ *„lines“ of congestion*

# Hepatic venous congestion

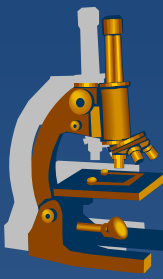


1 Portal spaces

2 Congestive lines (severe congestion with hepatocyte necrosis)

--- pseudolobule: confluent remnants of 3 lobules, centrally portal space

# Hepatitis



## xinfectious

⇒ *acute, chronic*

⇒ *viral*

- most common
- primary hepatotropic - hepatitis viruses
- systemic – EBV, CMV, HSV, yellow fever, enteroviruses, ...

⇒ *bacterial*

- pyogenic bacteria, TBC, salmonella – typhoid fever, leptospirosis,...

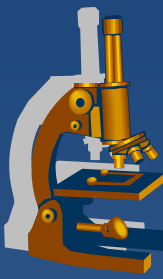
⇒ *parasitic*

- echinococcus, schistosoma, ...

⇒ *protozoal*

- amebiasis

# Hepatitis



## Non-infectious

(acute, chronic)

⇒ *autoimmune (AIH)*

⇒ *metabolic*

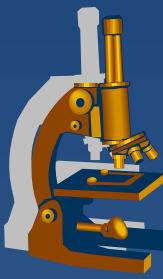
- hemochromatosis, NASH

⇒ *toxic/drug induced*

⇒ *cryptogenic*

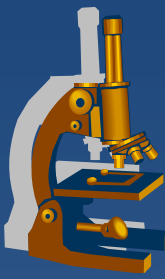


# Chronic hepatitis



- ✗ Asymptomatic / clinical symptoms
- ✗ Laboratory signs of progressive/relapsing liver disease (> 6 months, 12 months in HCV)
- ✗ Etiology:
  - ⇒ *Viruses*
    - HBV, HBV+HDV, HCV
  - ⇒ *AIH*
  - ⇒ *metabolic (inborn, NASH)*
  - ⇒ *toxic/ drug induced (alcoholic)*
  - ⇒ *cryptogenic*

# Chronic hepatitis - pathology



## x Gross:

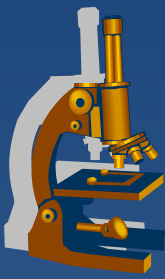
⇒ *non-characteristic, commonly enlarged liver of firmer consistency*

## x Micro:

⇒ *Disease activity: grade of necroinflammatory changes in portal spaces and lobules (interface activity; type, grade and localisation of necrosis; grade of inflammatory infiltrate)*

# Chronic hepatitis - pathology

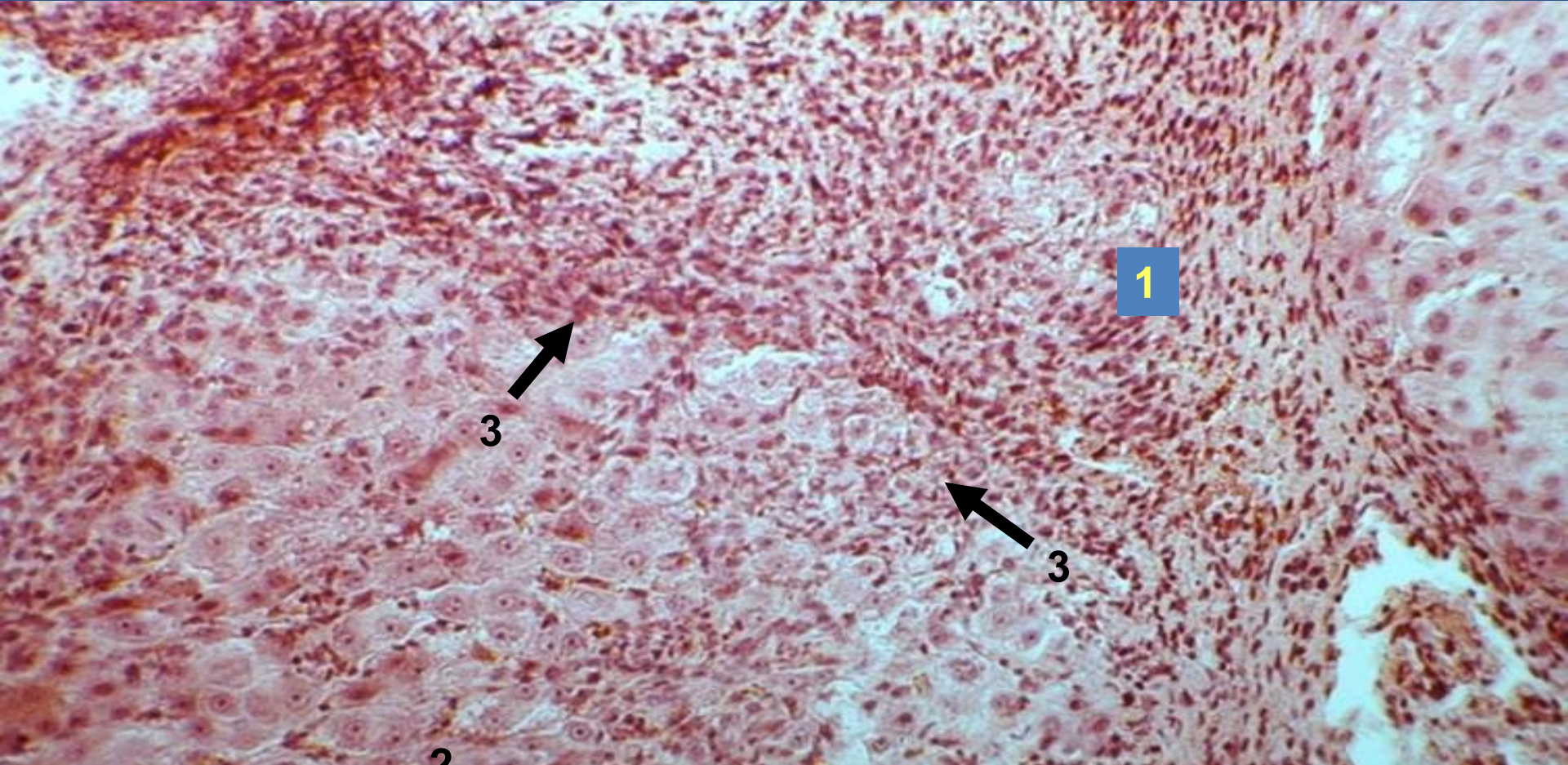
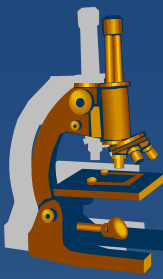
---



✘ Disease stage:

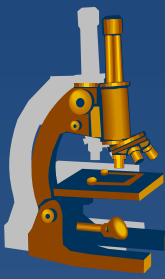
⇒ stage of fibrosis and architectural changes (portal fibrotic expansion, bridging fibrosis, nodularity → cirrhosis)

# *Chronic hepatitis*



- 1 Portal spaces with inflammatory infiltrate
- 2 Hepatocytes
- 3 Interface activity

# ***NASH: non-alcoholic steatohepatitis***



## **x Spreading silent epidemics:**

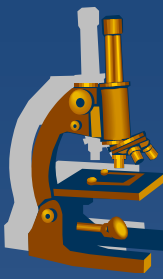
### **Patients with metabolic syndrome:**

„male-type“ obesity (intraabdominal fat  
accumulation – waist size)

hyperlipidemia

DM of II type, hyperglycaemia

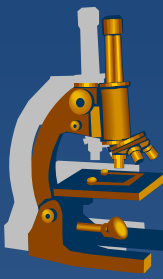
# Liver fibrosis



- × Response to inflammation
- × Mostly irreversible
  - ⇒ *(under favorable conditions reversible to some extent)*
- × Deposition of collagen
  - ⇒ → *effects on hepatic metabolism and blood flow*
- × Begins around portal tracts or central veins → spreads → links other regions (bridging fibrosis)
- × Basic lobular architecture partially preserved

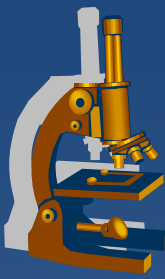
# ***Advanced liver disease (cirrhosis)***

---



- ✘ Complete loss of original architecture
  - ⇒ *Regenerating groups of hepatocytes surrounded by fibrotic scar tissue*
  - ⇒ *Reorganisation of vascular architecture*
  - ⇒ *Intrahepatic biliary tract changes, incl. ductular hyperplasia*
  
- ✘ Due to continued parenchymal injury and fibrosis
- ✘ Advanced stage of liver disease, may be partially reversible

# ***Advanced liver disease (cirrhosis)***



## **x Etiology:**

⇒ ***massive acute necrosis***

⇒ ***chronic hepatitis***

⇒ ***biliary diseases:***

- inborn (atresia)

- acquired:

- autoimmune (primary biliary cirrhosis, prim. sclerosing cholangitis),  
secondary biliary cirrhosis (chronic obstruction)

⇒ ***cryptogenic cirrhosis***

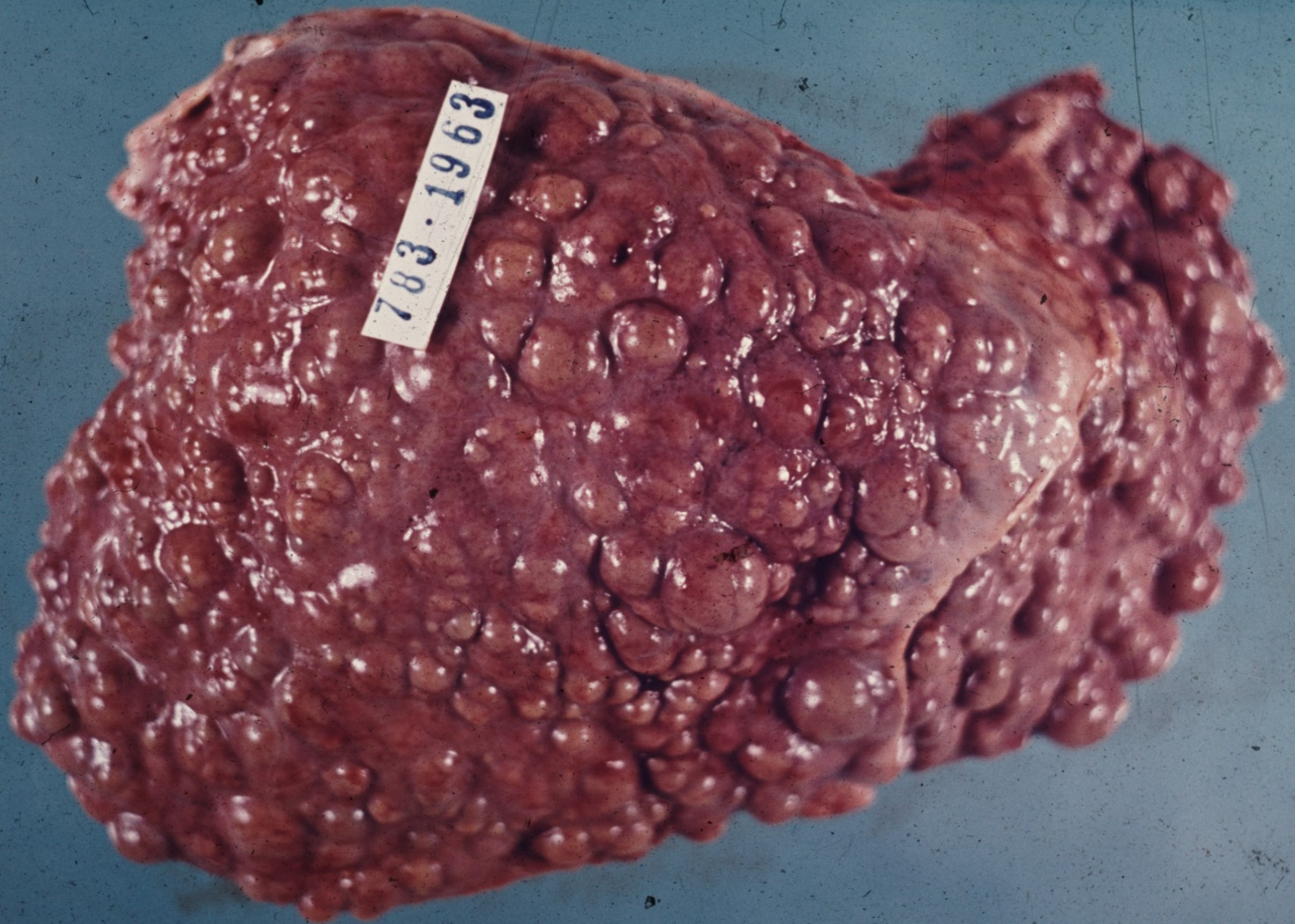
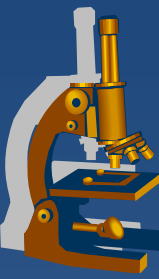
## **x Gross: liver usually diminished in size**

⇒ ***micronodular***

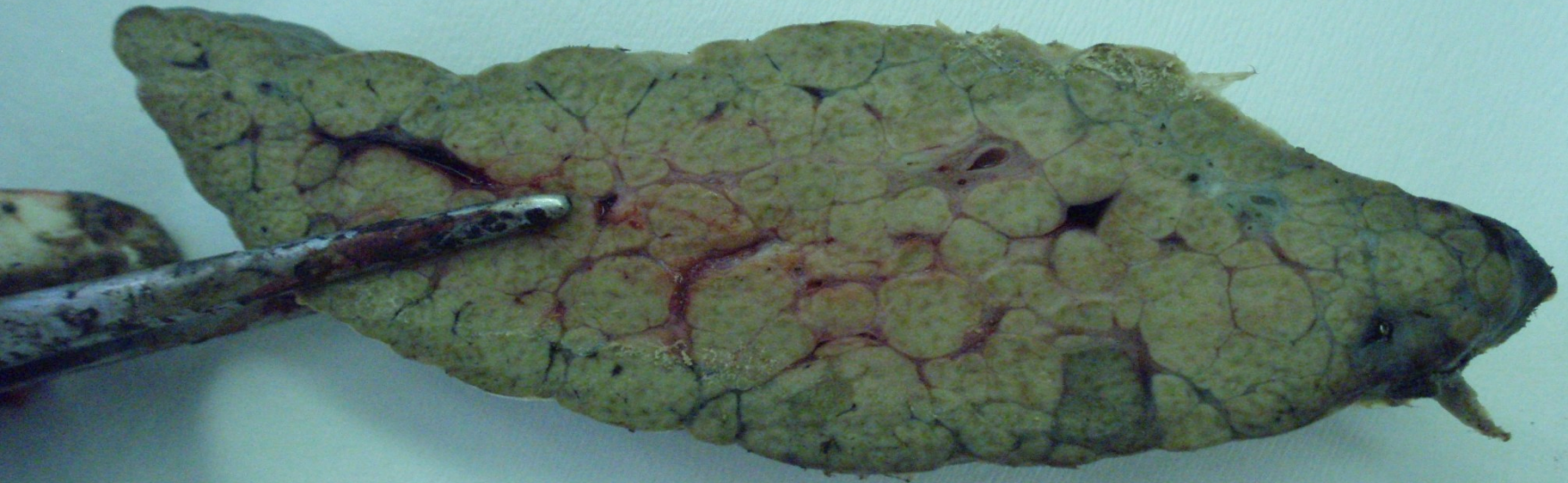
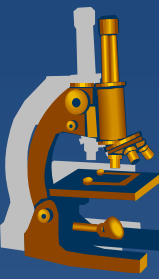
⇒ ***macronodular***



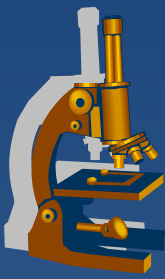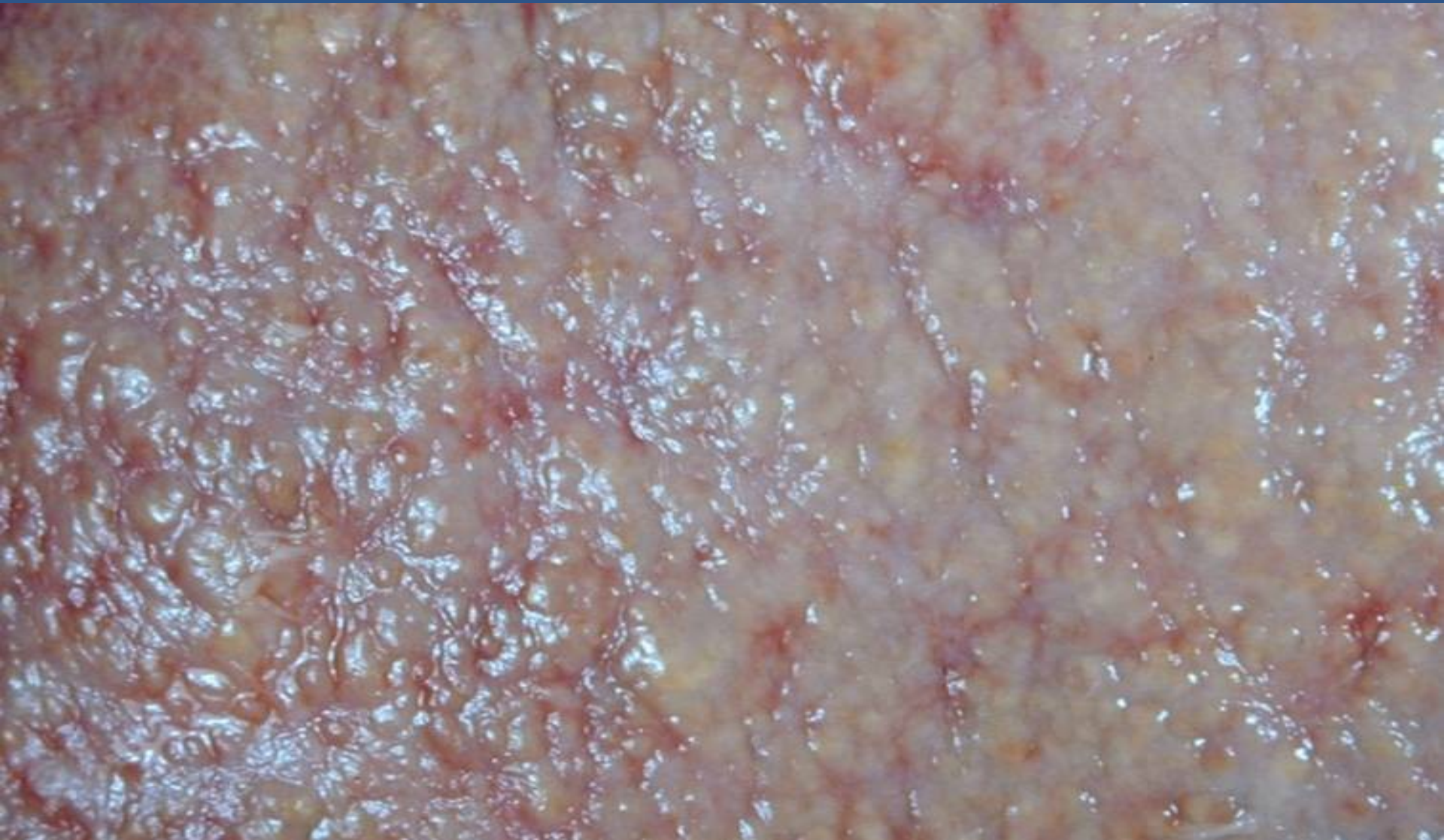
# *Cirrhosis - macronodular*



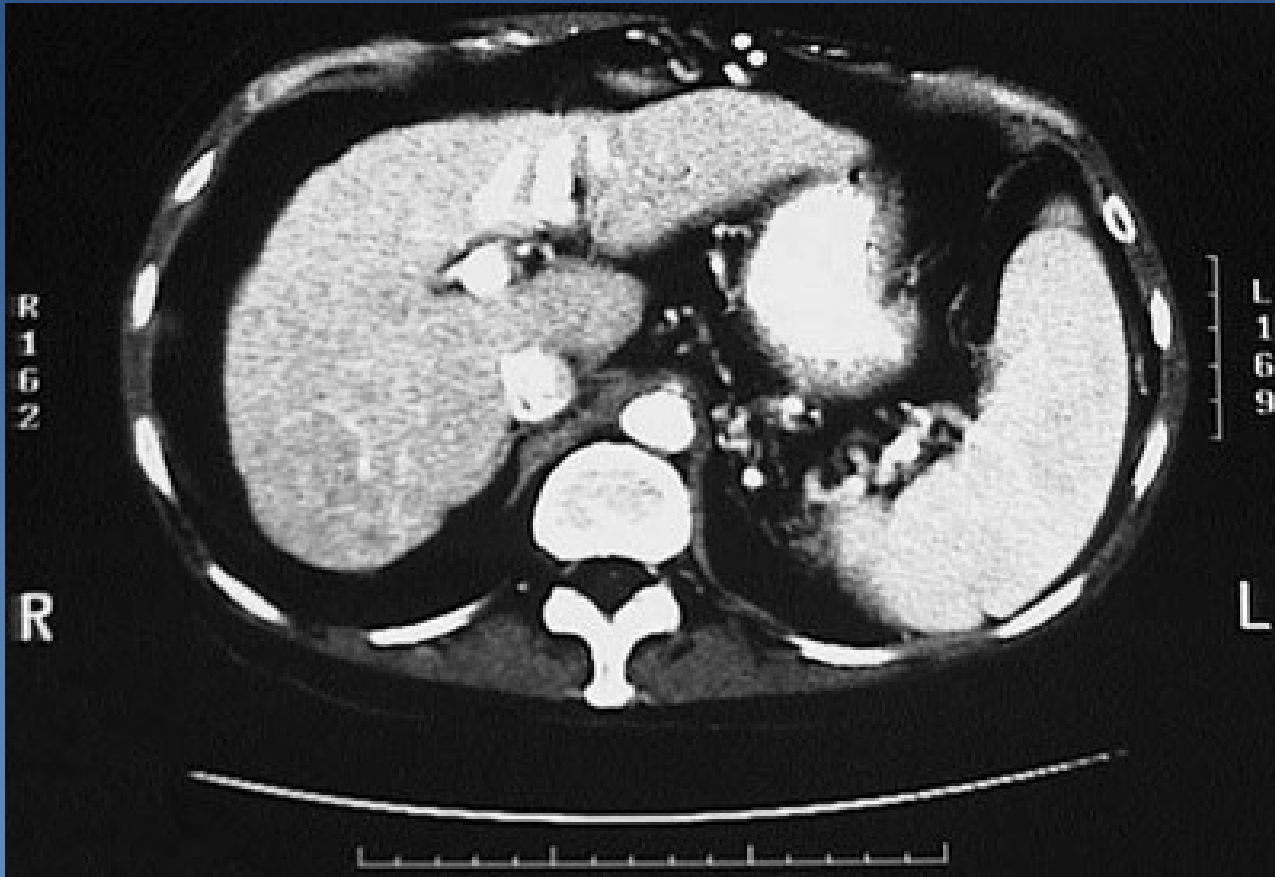
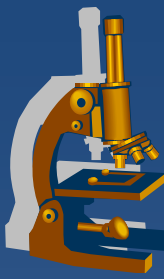
# *Cirrhosis - micronodular*



# ***Advanced liver disease (cirrhosis)***

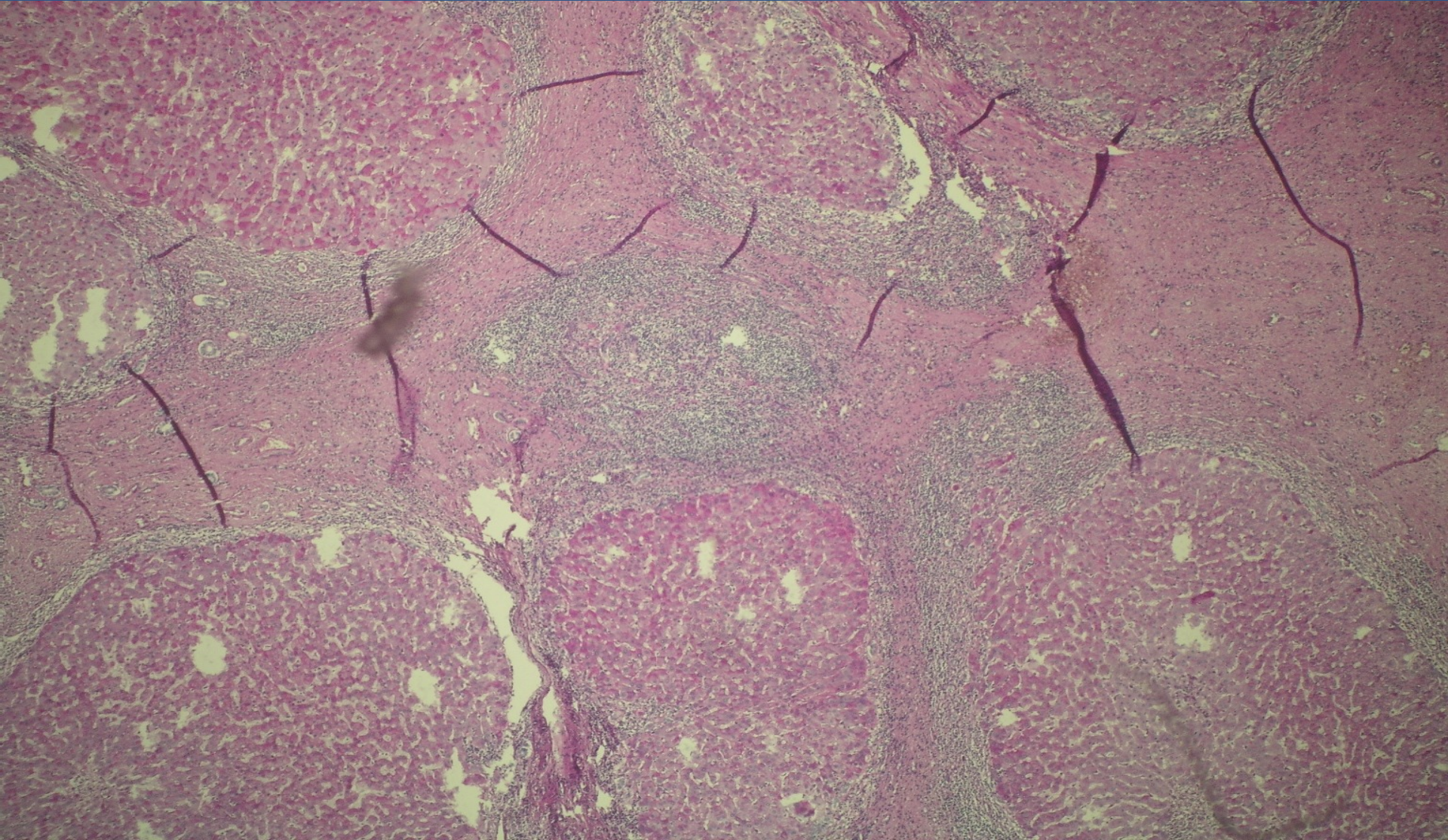
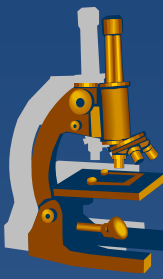


# Advanced liver disease (cirrhosis)

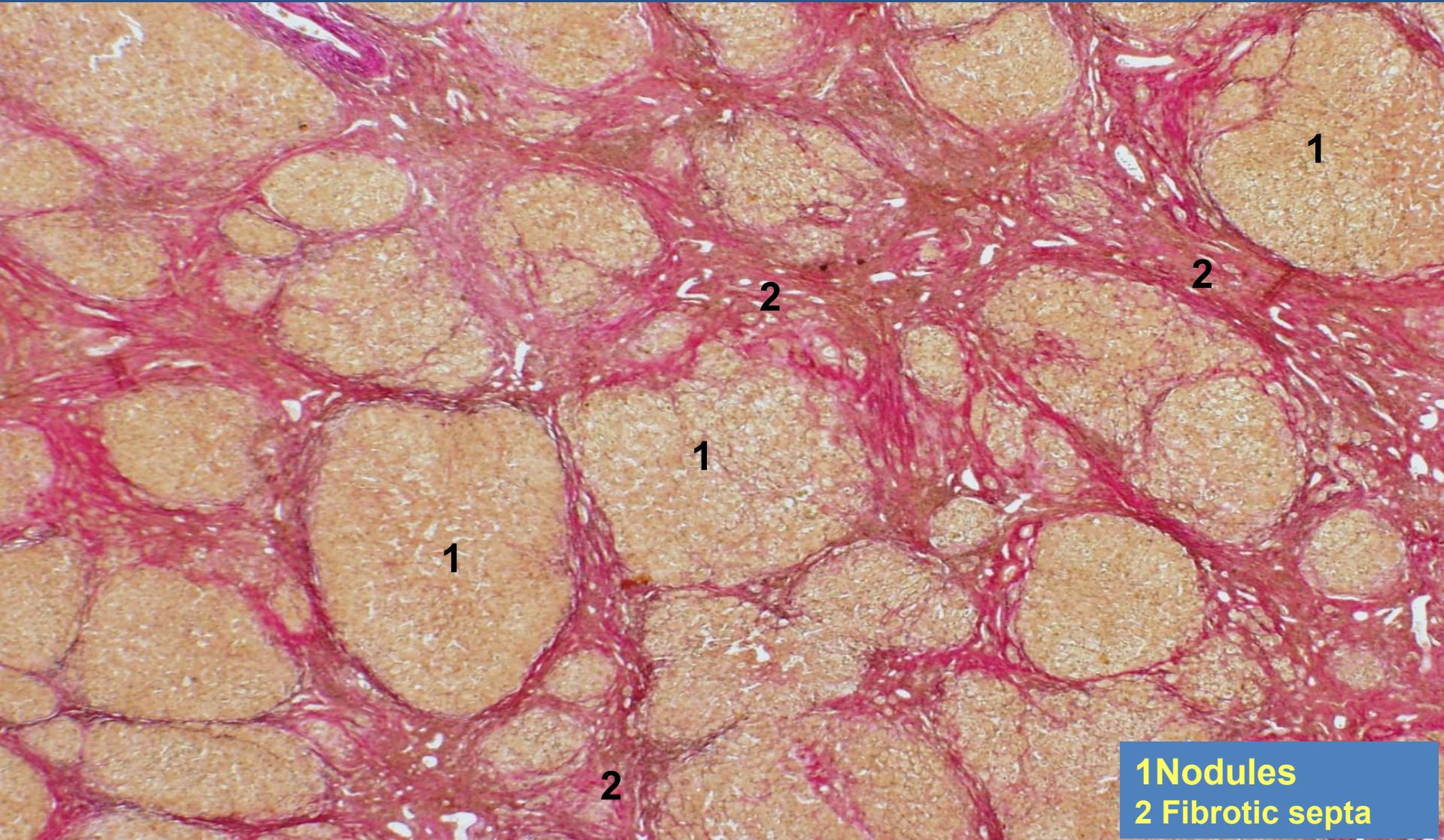
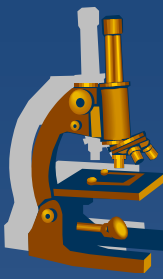


CT scan with contrast of the abdomen in transverse view demonstrates a **small liver with cirrhosis**. The spleen is enlarged from portal hypertension

# ***Advanced liver disease (cirrhosis)***

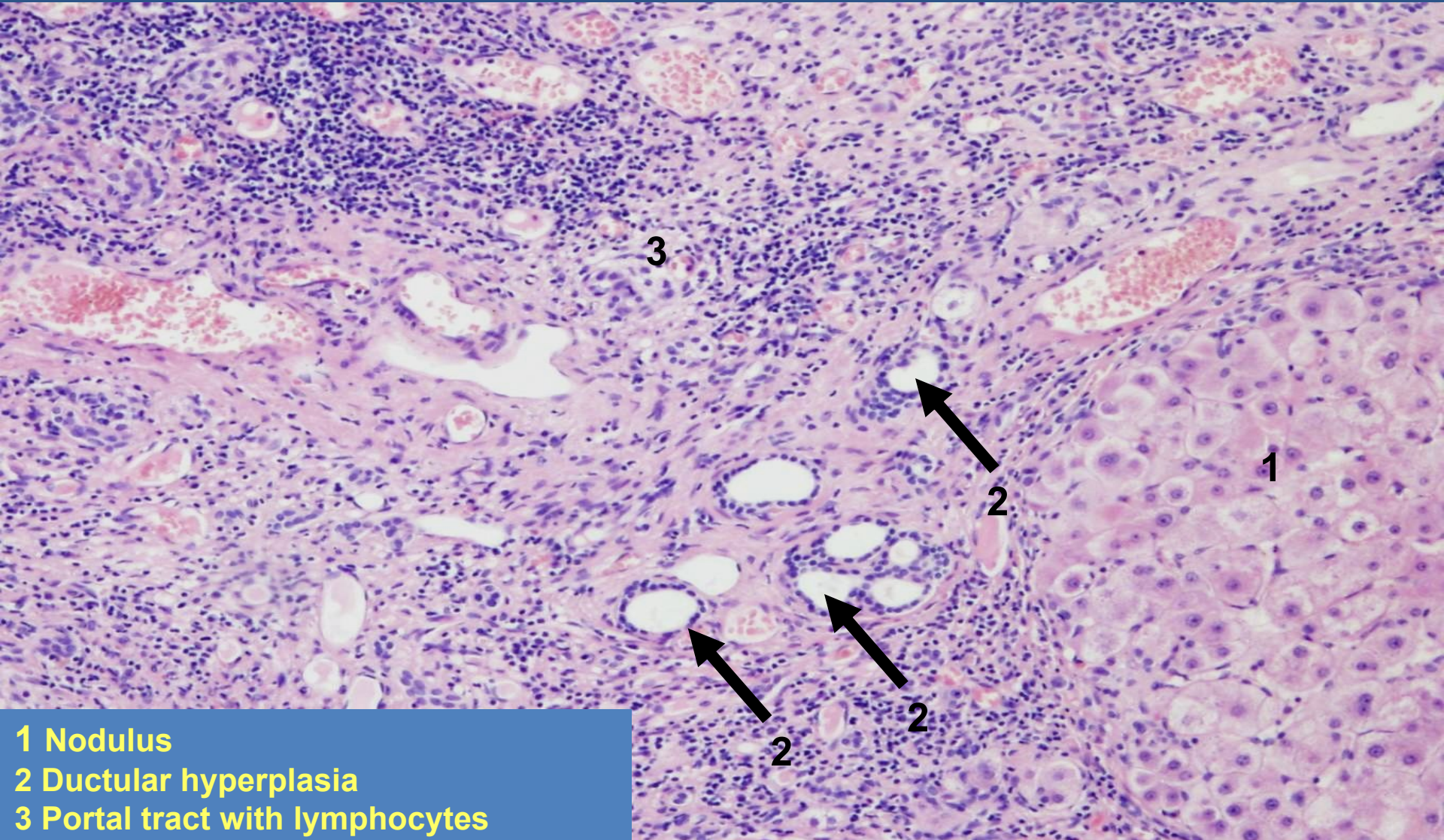
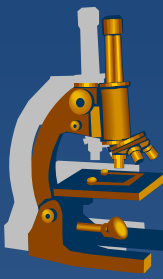


# ***Cirrhosis – fibrotic septa*** ***(Van Gieson staining)***



**1** Nodules  
**2** Fibrotic septa

# *Cirrhosis - ductules*



3

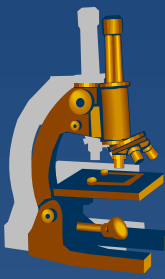
1

2

2

2

- 1 Nodulus
- 2 Ductular hyperplasia
- 3 Portal tract with lymphocytes



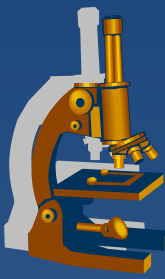
# Complications of cirrhosis

- ✘ **Insufficiency of liver functions:**
  - ⇒ ↓ *synthesis (proteins incl. clotting factors etc.)*
  - ⇒ ↓ *detoxication – hepatic coma*
  - ⇒ ↓ *Kupffer cells function*
  
- ✘ **Portal hypertension:**
  - ⇒ *splenomegaly, intestinal venous congestion (! infarsation, inflammation)*
  - ⇒ *ascites (! peritonitis)*
  - ⇒ *portocaval anastomoses (oesophageal varices)*
  
- ✘ **Carcinoma**
  - ⇒ *mostly hepatocellular*



# ***Focal lesions and tumors***

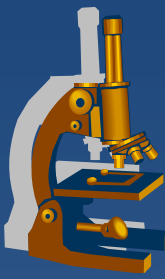
---



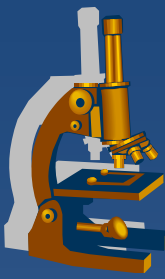
- x Tumor-like lesions**
- x Benign tumors**
- x Malignant tumors:**
  - ⇒ *primary, secondary*

# *Tumor-like lesions*

---



- × Focal nodular hyperplasia
- × Nodular regenerative hyperplasia  
(lack of fibrosis)
- × Cysts
- × Biliary hamartoma (von Meyenburg complex)

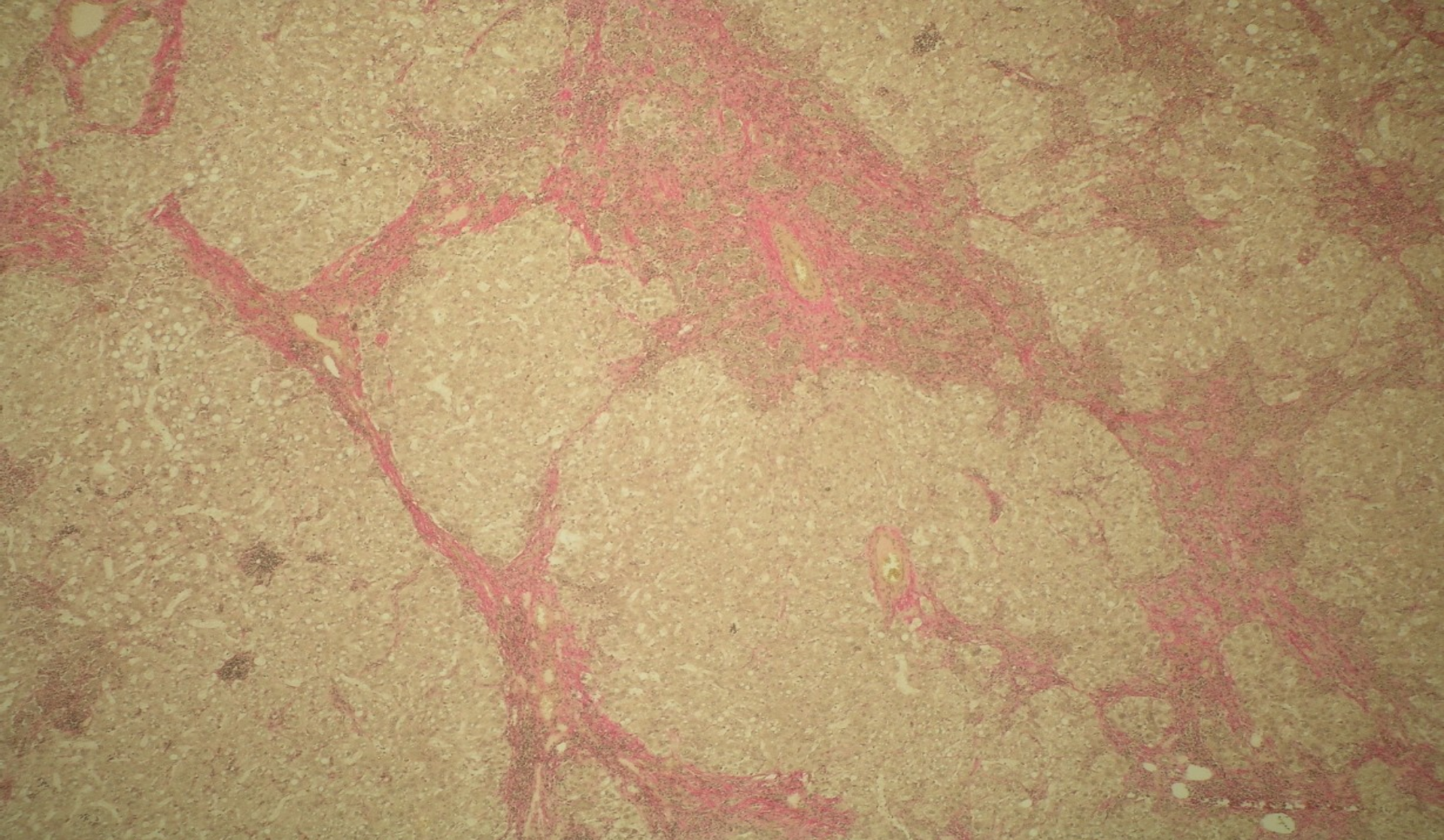
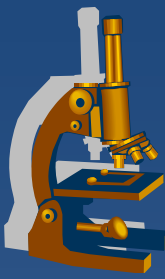


# ***Focal nodular hyperplasia***

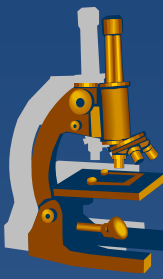
---

- ✘ Localized benign hepatocellular nodules with central stellate fibrous scar
- ✘ Single or multiple
- ✘ More common in females, oral contraceptives – estrogens
- ✘ Diff. dg. x tumors

# ***FNH – fibrotic scar***



# Benign tumors



## Adenoma

---

### ×hepatocellular

⇒ *lack of portal tracts, regular trabeculae*

### ×cholangiocellular

⇒ *biliary, accumulation of regular ducts, lack of bile production, less than 1cm, subcapsular*

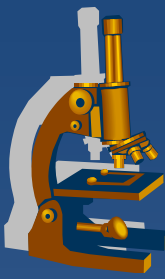
### ×cystadenoma

⇒ *mucinous, rare*

## Haemangioma

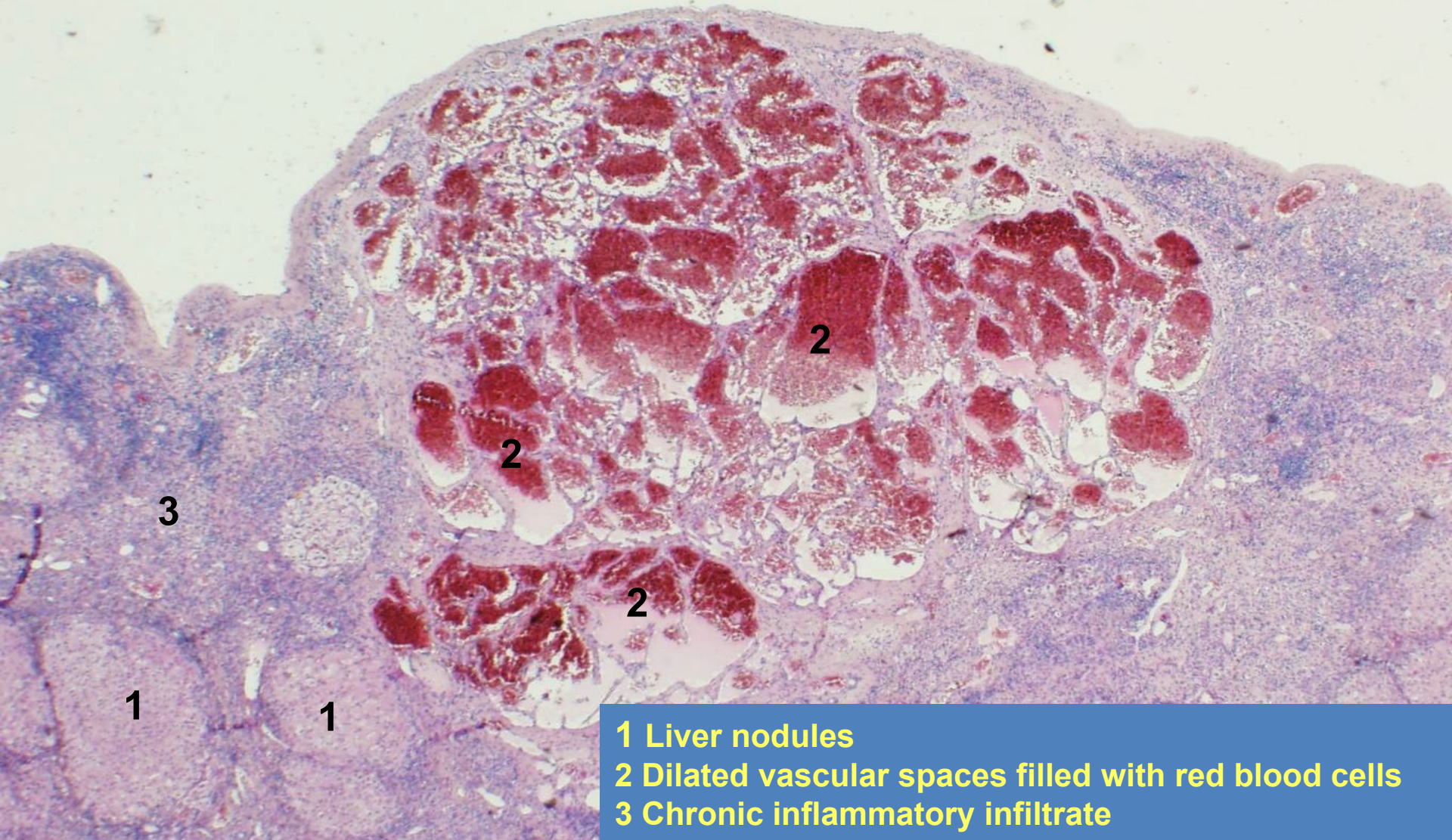
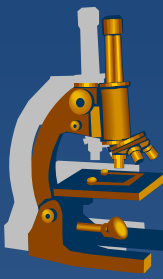
### ×cavernous

# *Cavernous haemangioma*



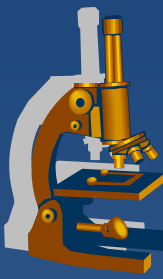
- x hamartoma, commonly multiple
- x 2 mm – 15 cm
- x risk of rupture + bleeding, consumption coagulopathy
- x common regressive changes – atypical US, CT, dif. dg. x malignancy
- x dark spongiotic demarcated focus
- x fibrous septa + vascular spaces

# ***Cavernous haemangioma (in micronodular liver cirrhosis)***

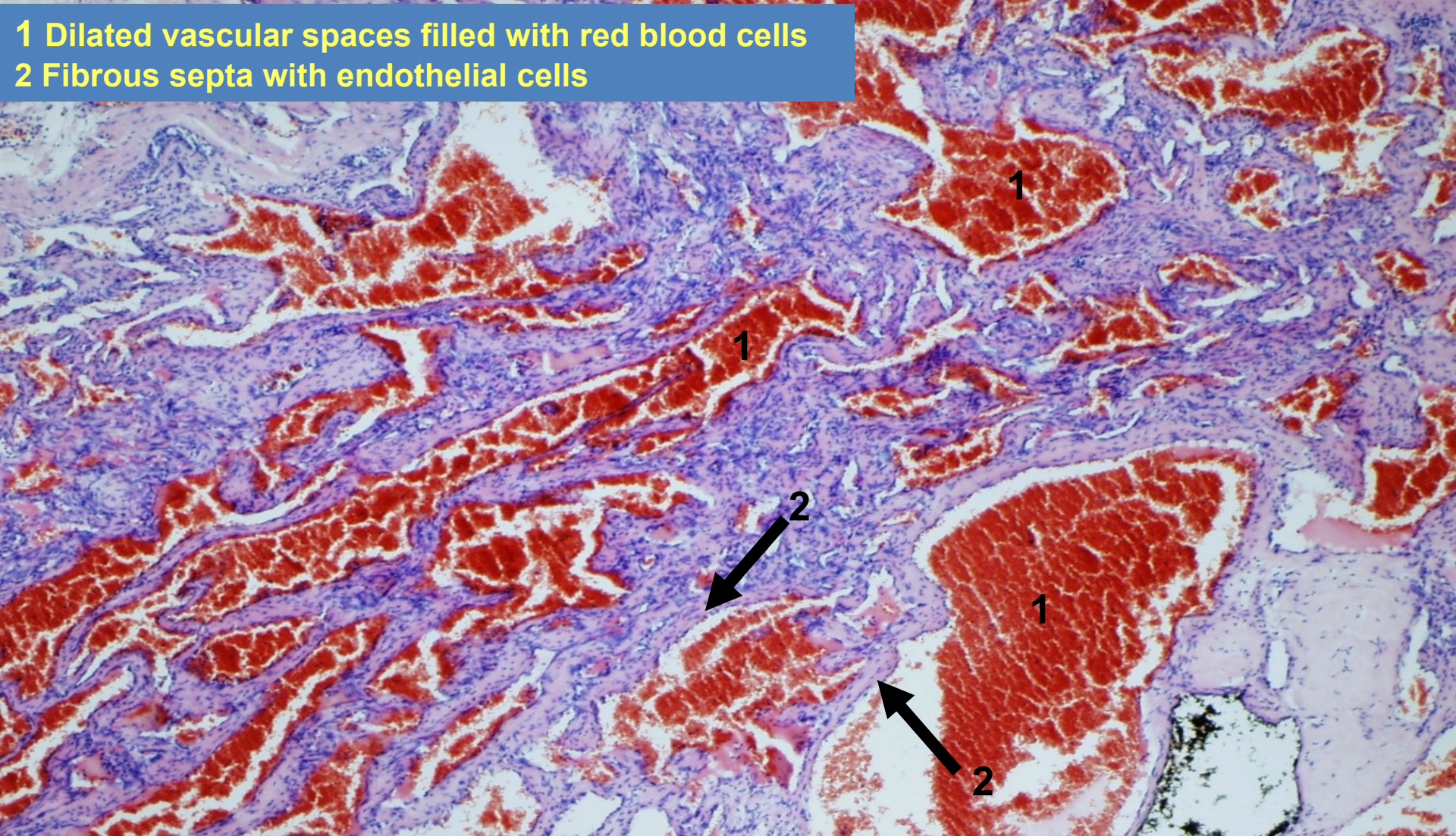


- 1 Liver nodules**
- 2 Dilated vascular spaces filled with red blood cells**
- 3 Chronic inflammatory infiltrate**

# *Cavernous haemangioma*

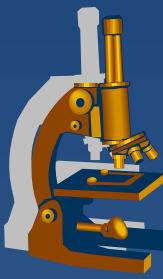


1 Dilated vascular spaces filled with red blood cells  
2 Fibrous septa with endothelial cells





# ***Malignant tumors***



## **x Primary**

⇒ *Hepatocellular carcinoma (90%)*

⇒ *Cholangiocarcinoma*

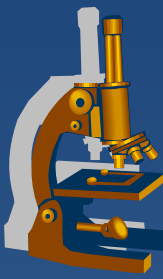
⇒ *Hepatoblastoma*

- children

⇒ *Angiosarcoma*

- associated with vinyl chloride, arsenic, or Thorotrast exposure

# ***Malignant tumors***



## **xSecondary**

### ⇒ ***Metastatic carcinomas***

- most common liver malignancy (GIT, lung, breast, kidney,...)

### ⇒ ***Direct spread of adjacent malignant tumors***

- gall bladder, pancreas

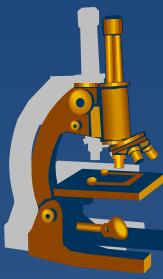
### ⇒ ***Other metastasing tumors***

- melanoma, sarcomas etc.

### ⇒ ***Haemopoetic neoplasms***

- leukemia infiltrates, lymphomas

# Preneoplastic changes



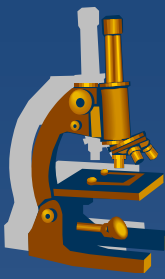
## x Liver cell dysplasia

⇒ *low grade, high grade*

⇒ *usually in cirrhosis*

⇒ *small foci or nodules, microcellular – smaller cells with less cytoplasm + bigger nuclei*

Diff. dg. x well diff. HCC

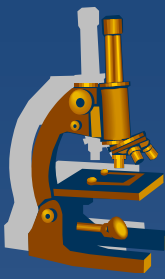


# *Hepatocellular carcinoma*

- ✗ World-wide 5th most common malignancy in males, 8th in females
- ✗ Possible primary prevention
- ✗ Different incidence due to geography / cause

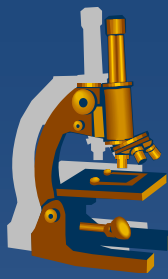
*High-income countries: now lower incidence, usually in cirrhosis (alcohol), ↑ (NASH, HCV)*

*Eastern Asia (HBV) + Africa (aflatoxin) – 80% of cases*



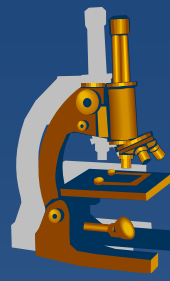
# *Hepatocellular carcinoma*

- x** Single or more nodules different from adjacent tissue
  - ⇒ *multifocal start or intrahepatic metastases*
- x** Micro
  - ⇒ *trabecular, acinar +/- pseudoglandular, solid*
  - ⇒ *enlarged nuclei + nucleoli, ↑ mitotic activity, atypias; eosinophilic – pale cytoplasm*
- x** Possible steatosis, bile production

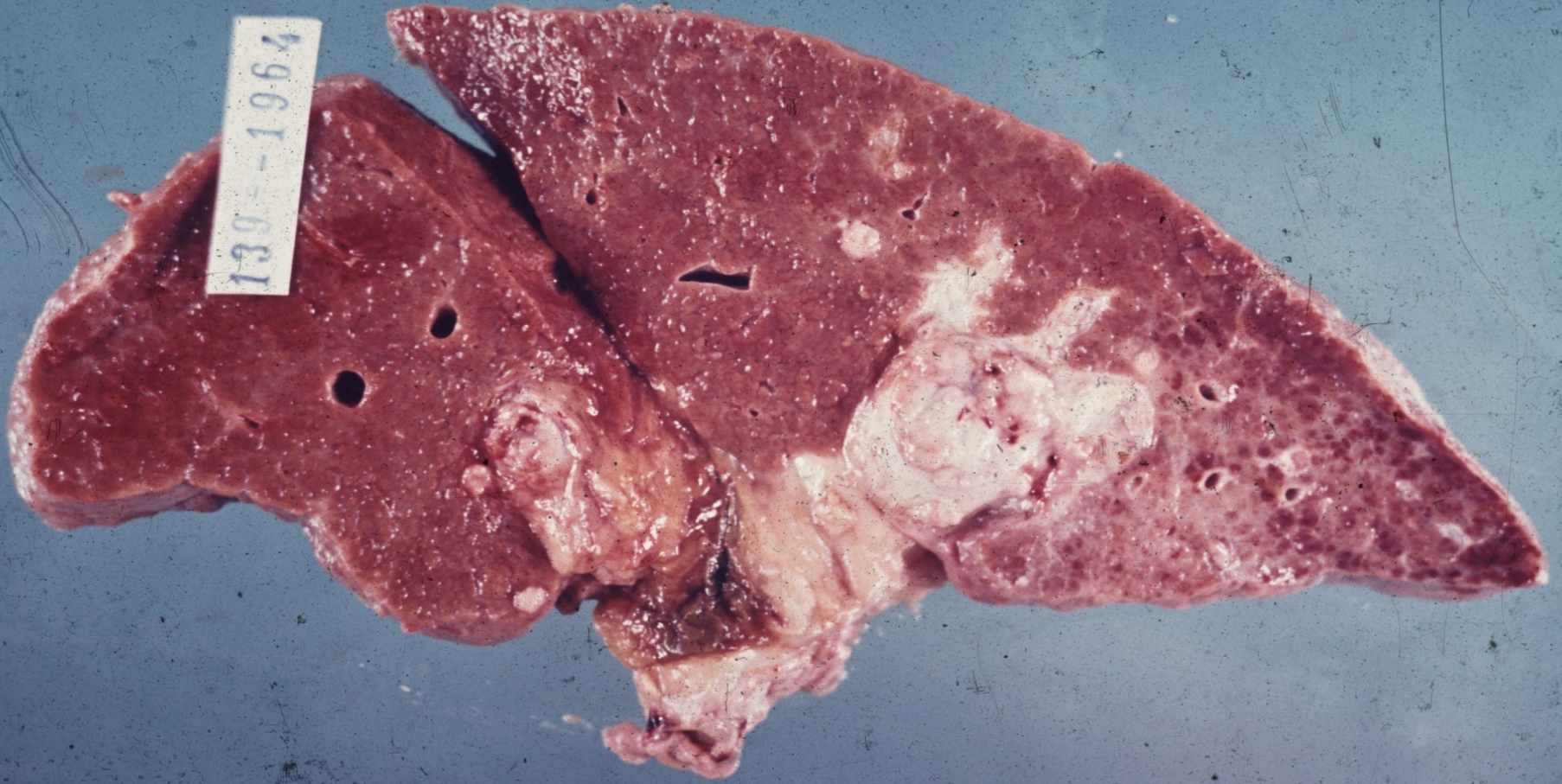


# *Hepatocellular carcinoma*

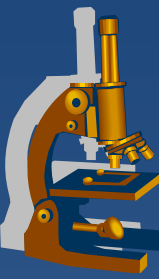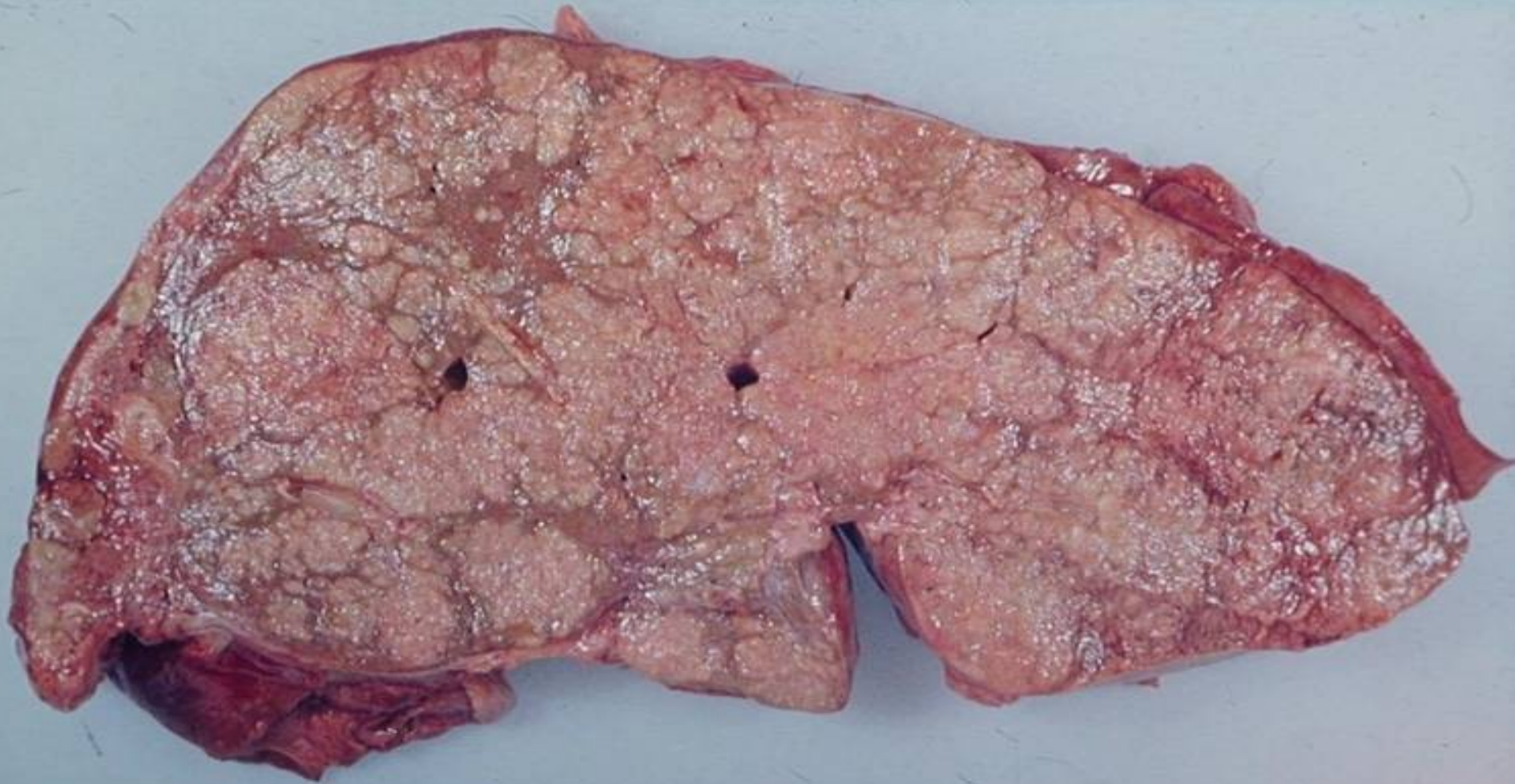
- x** angioinvasion
  - ⇒ *mostly venous*
- x** metastases
  - ⇒ *lung, bones, LN*
- x** small solitary (→3) focus
  - ⇒ *excision, transplantation*
- x** large, multiple
  - ⇒ *ablation, bad prognosis*
- x** secondary prevention
  - ⇒ *regular check-up of cirrhotic patients*



# *Hepatocellular carcinoma*



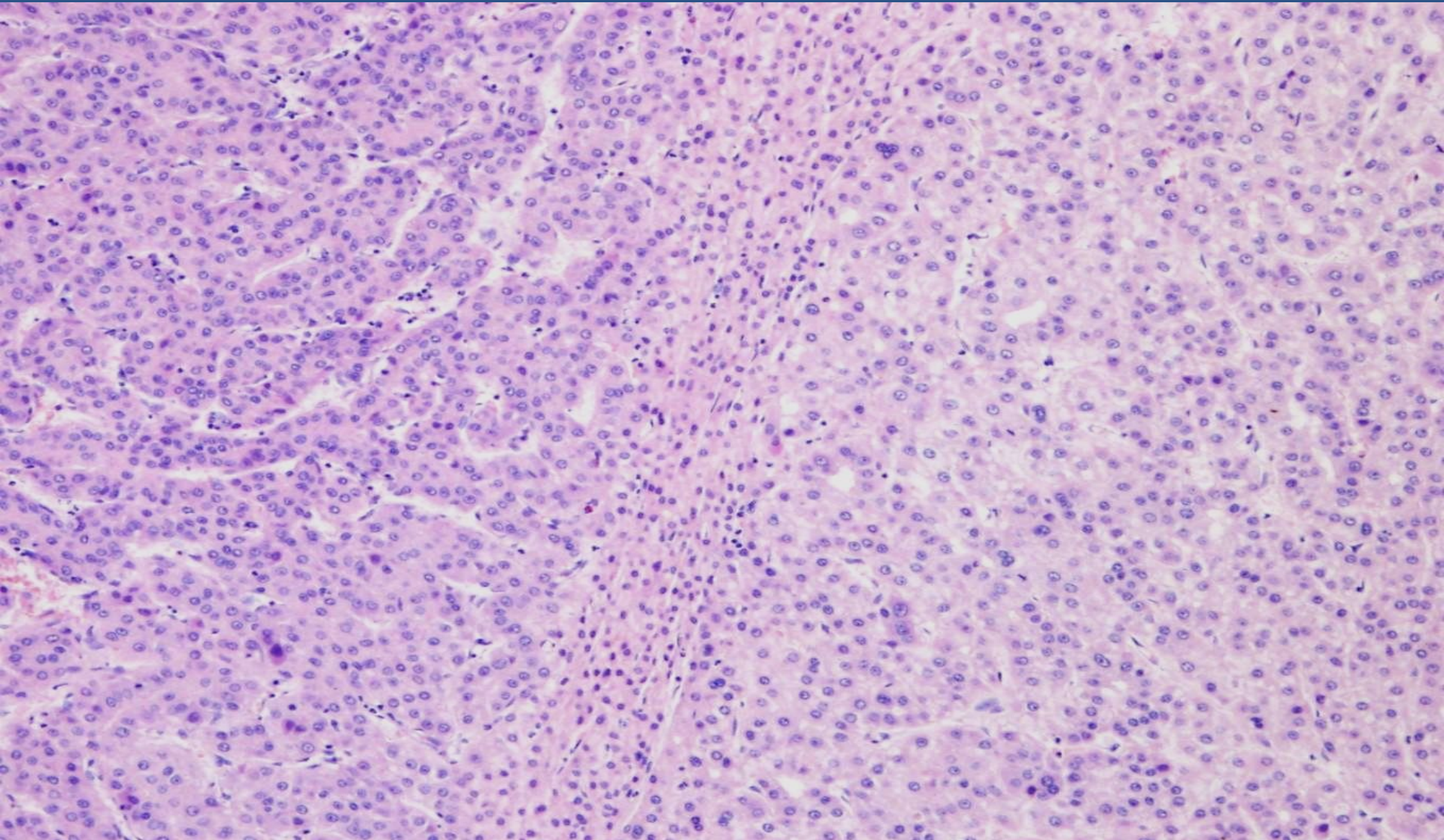
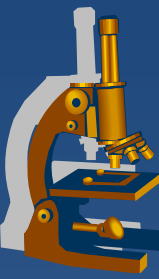
# HCC



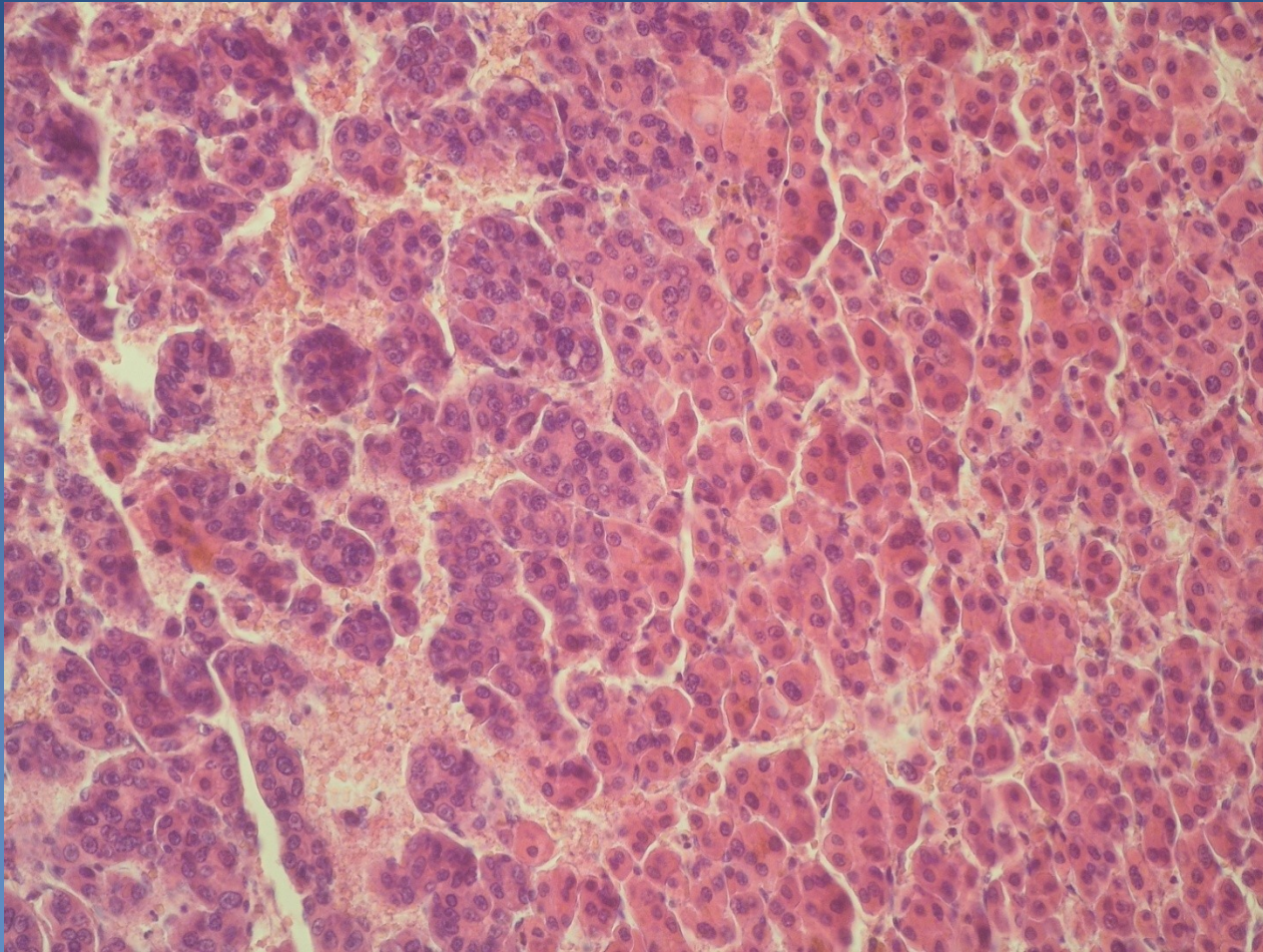
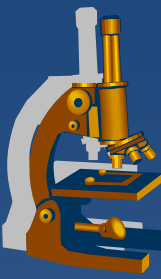
P 400/72



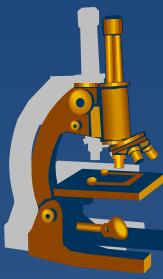
# HCC



# HCC

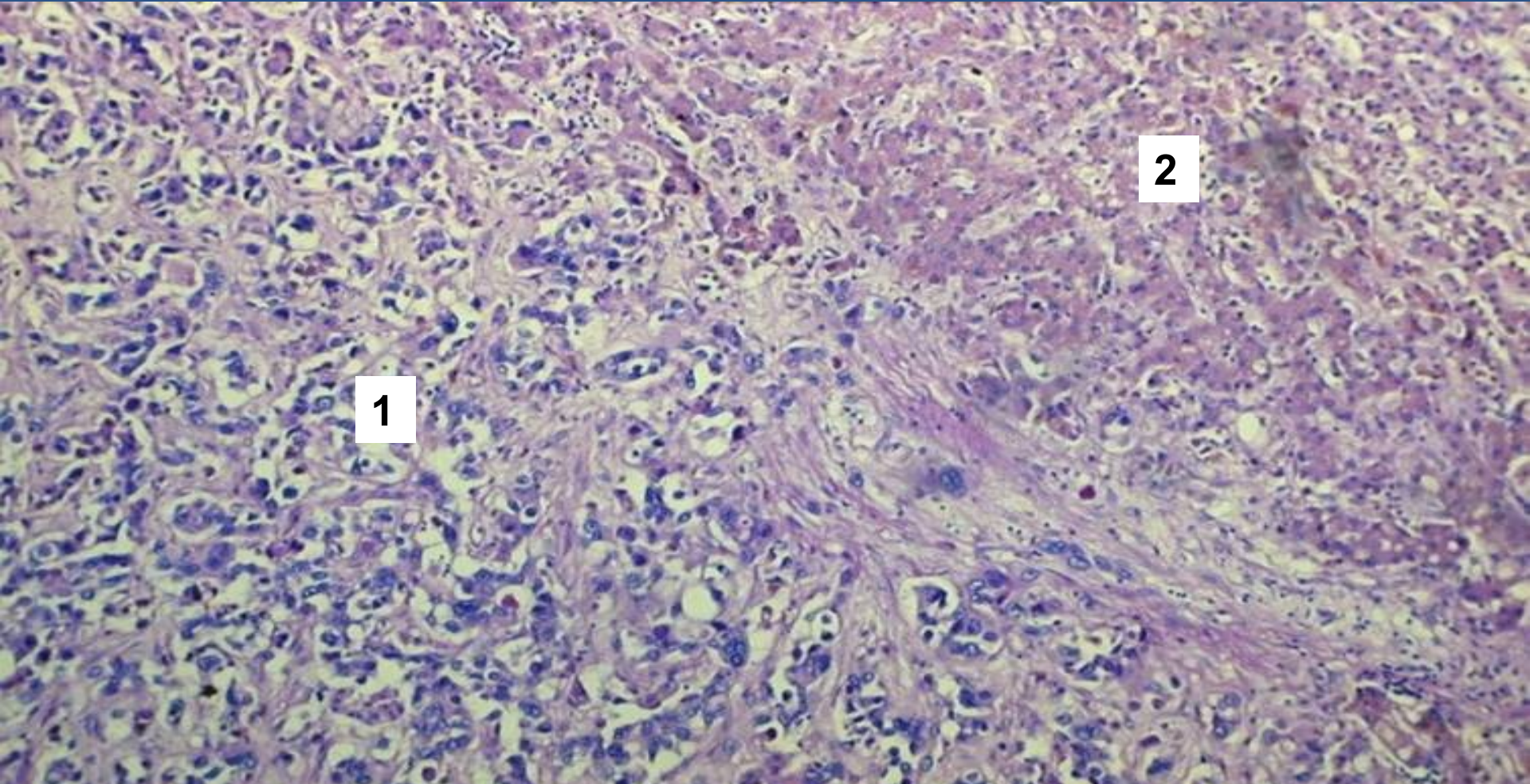
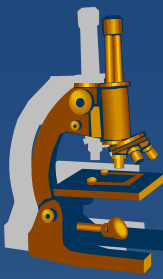


# ***Cholangiocarcinoma***



- × From intrahepatic biliary ducts
- × ↑ risk in PSC, HCV cirrhosis, ...
- × mucin secretion, no bilirubin pigment
- × irregular ducts, strands of cells
- × diff. dg. × metastatic or direct spread –  
gallbladder, pancreas, colorectal ca
- × mostly bad prognosis

# ***Cholangiocarcinoma***

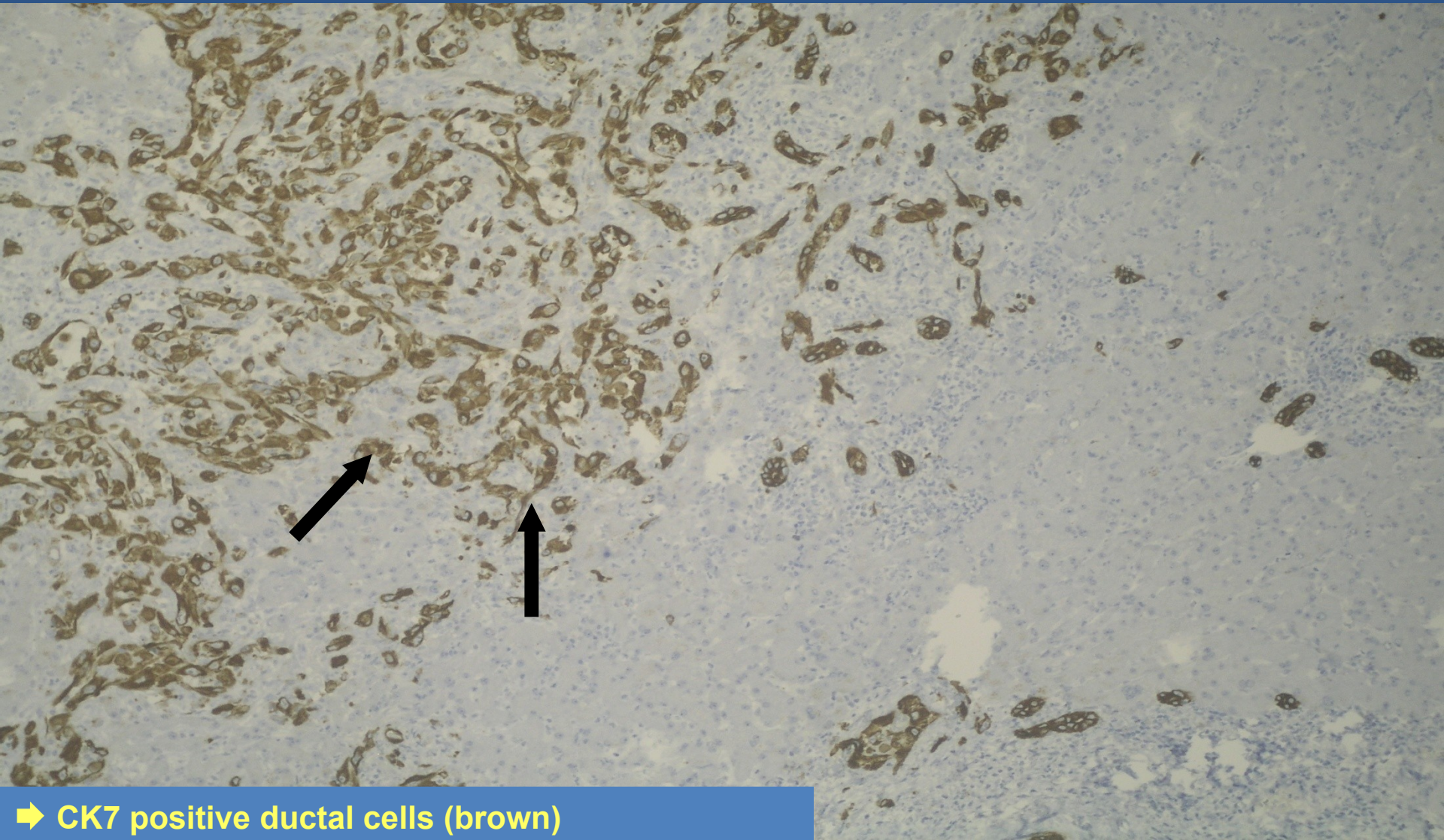
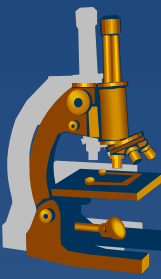


**1**

**2**

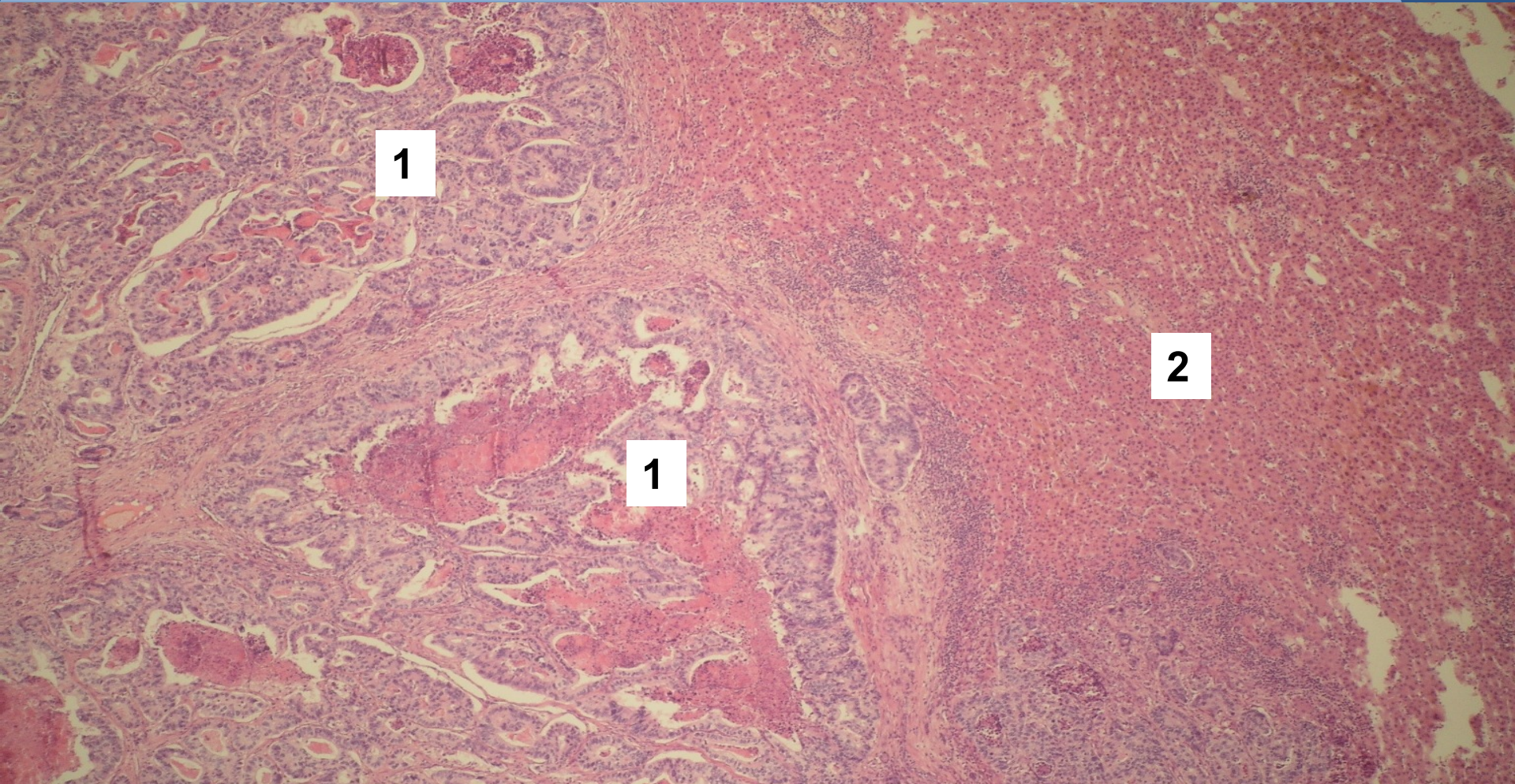
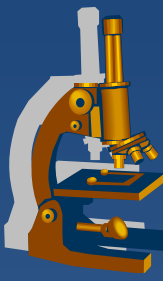
**1 Cholangiocarcinoma**  
**2 Liver parenchyma**

# ***Cholangiocarcinoma*** ***(IHC CK7)***



➡ CK7 positive ductal cells (brown)

# *Colorectal ca metastasis*



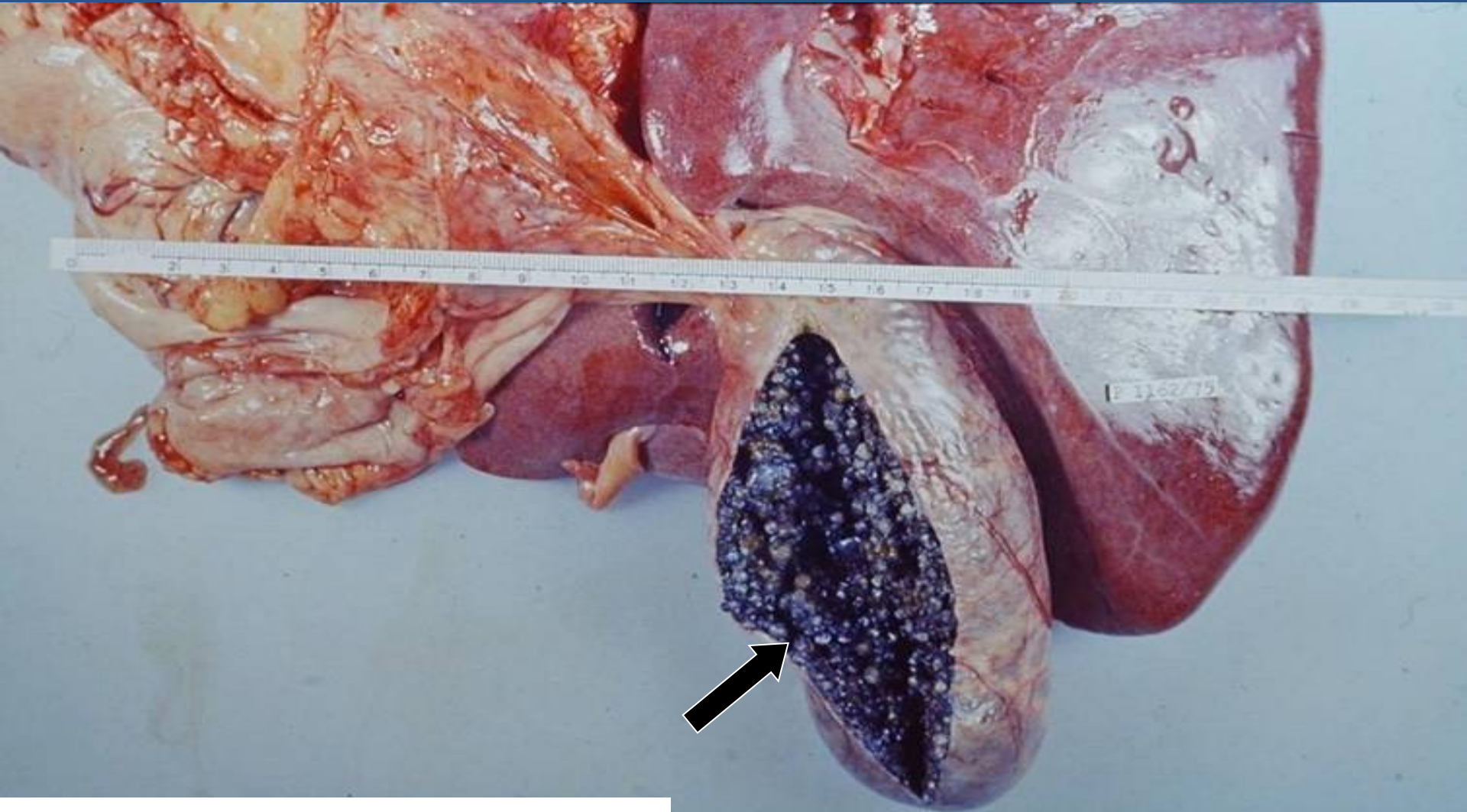
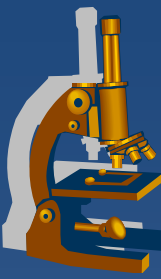
1

1

2

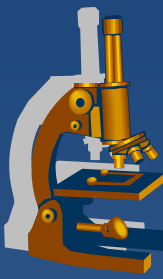
1 Tubular formations of colorectal adenocarcinoma  
2 Liver parenchyma

# *Cholecystolithiasis*



➡ Gallbladder filled with stones

# Cholecystitis



## **x** Acute calculous

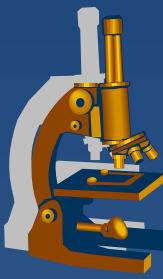
- ⇒ *Obstruction of GB neck or cystic duct*
- ⇒ *Local pain radiating to right shoulder*
- ⇒ *Fever, nausea, leukocytosis*
- ⇒ *Potential surgical emergency*

empyema of gallbladder

gangrenous cholecystitis



# Cholecystitis



## × Acute acalculous

⇒ *less common, ischemic (postoperative, trauma, burns, sepsis,...)*

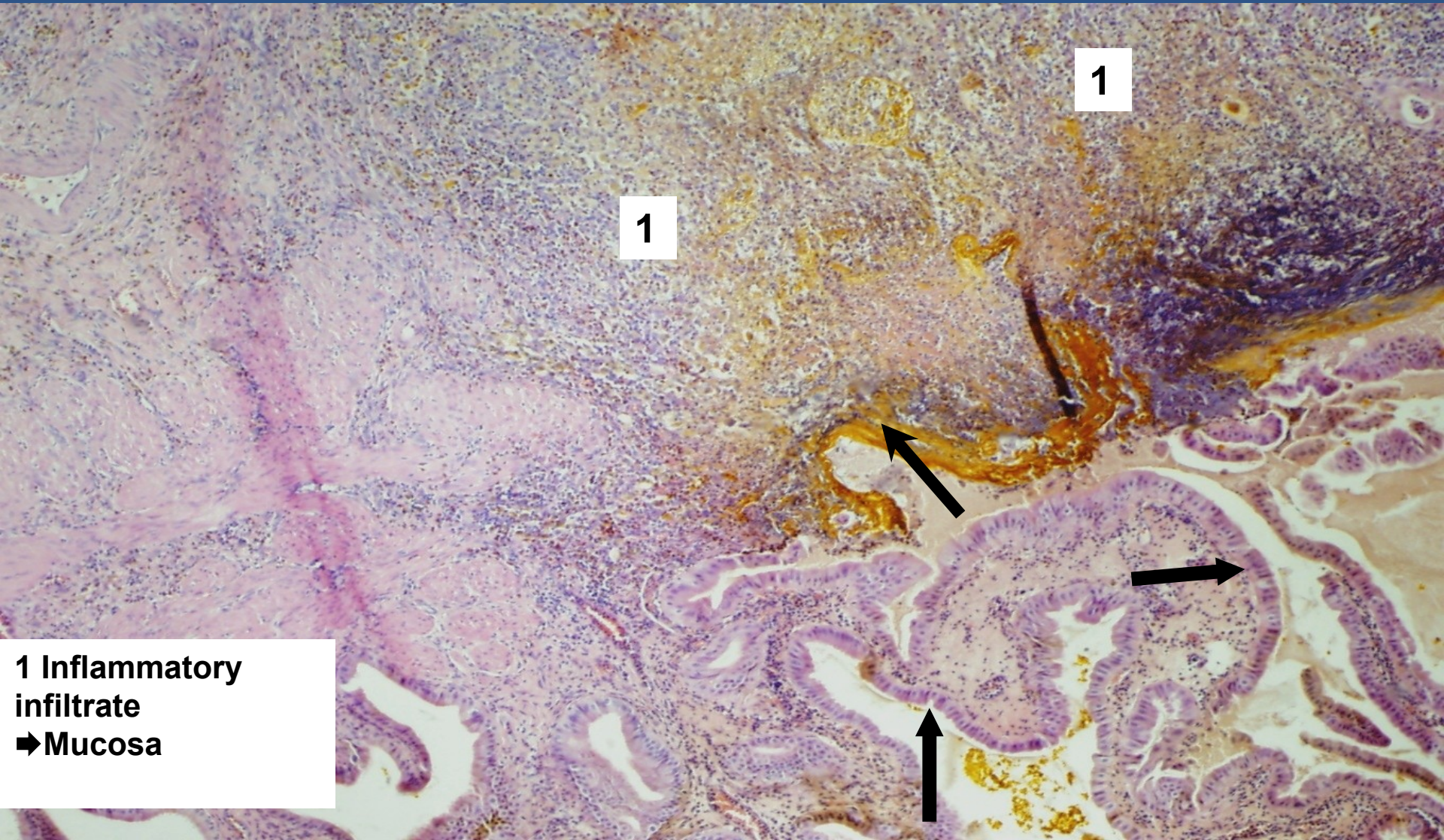
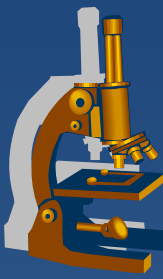
## × Chronic

⇒ *Recurrent attacks of pain*

⇒ *Nausea and vomiting*

⇒ *Associated with fatty meals*

# Cholecystitis

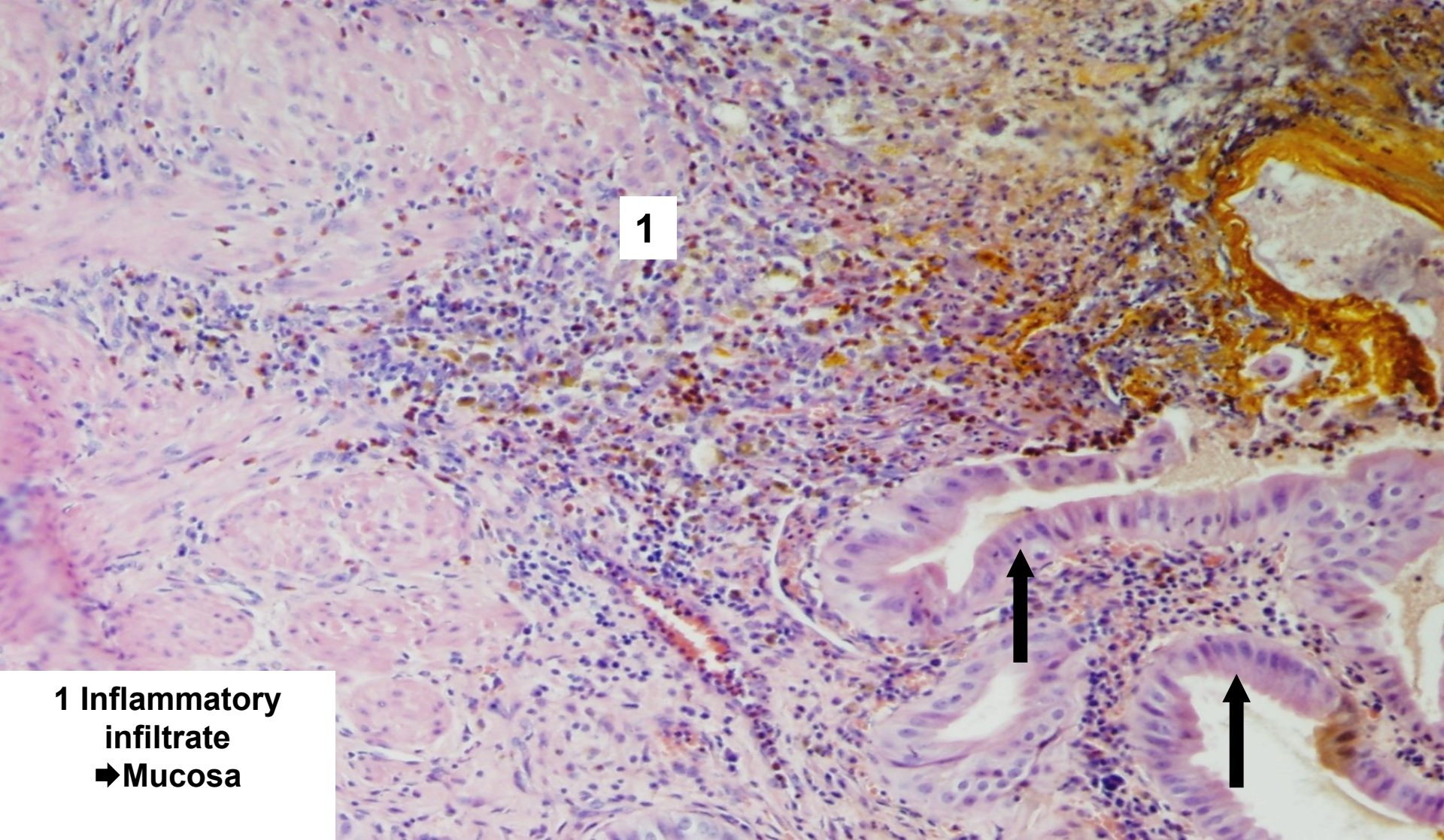
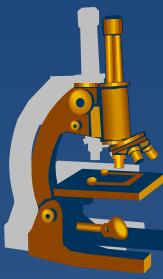


1

1

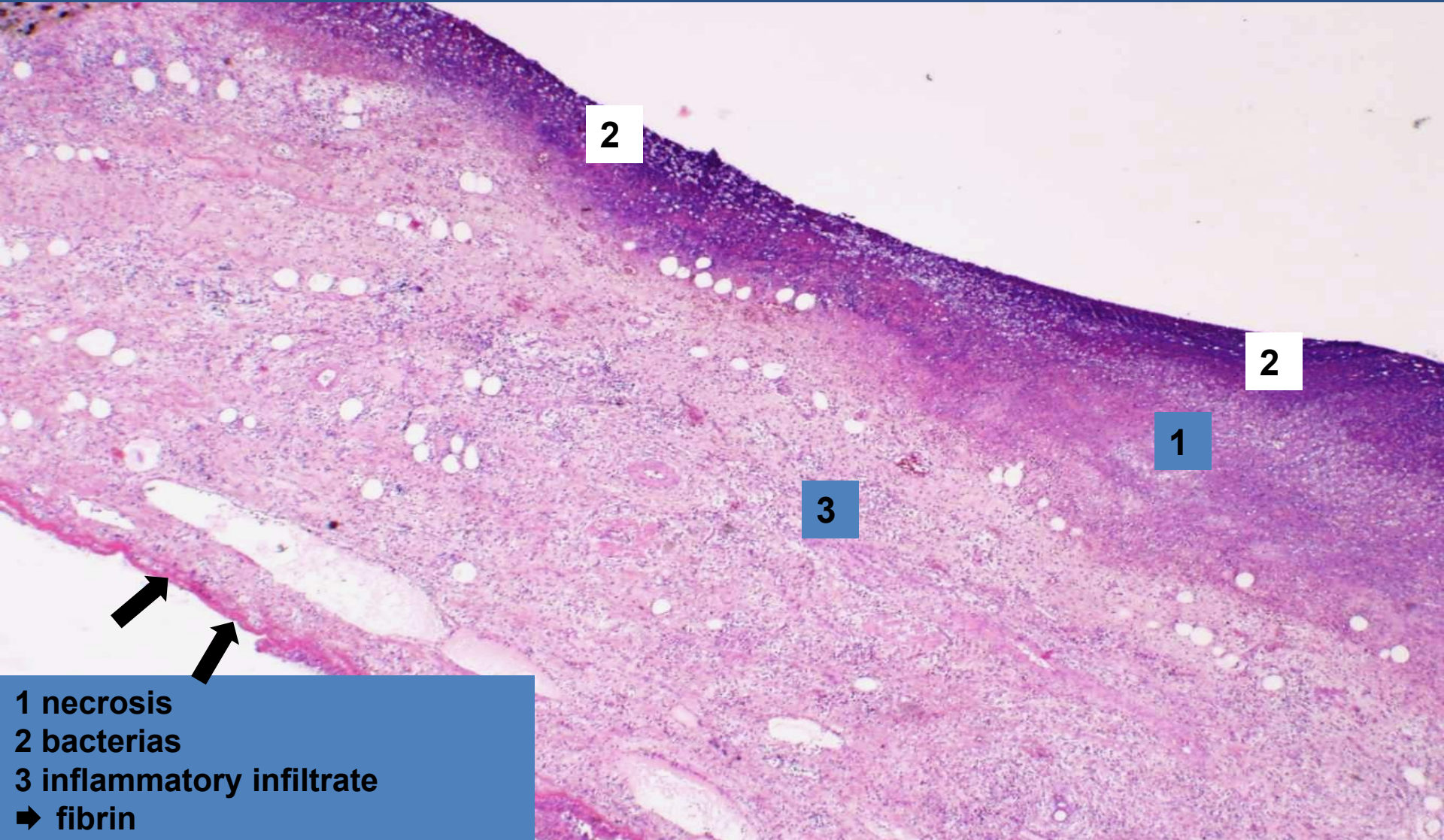
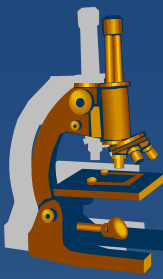
1 Inflammatory infiltrate  
➔ Mucosa

# *Cholecystitis*



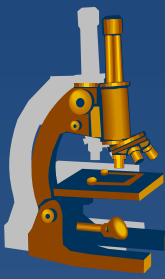
**1 Inflammatory  
infiltrate  
➔ Mucosa**

# Gangrenous cholecystitis



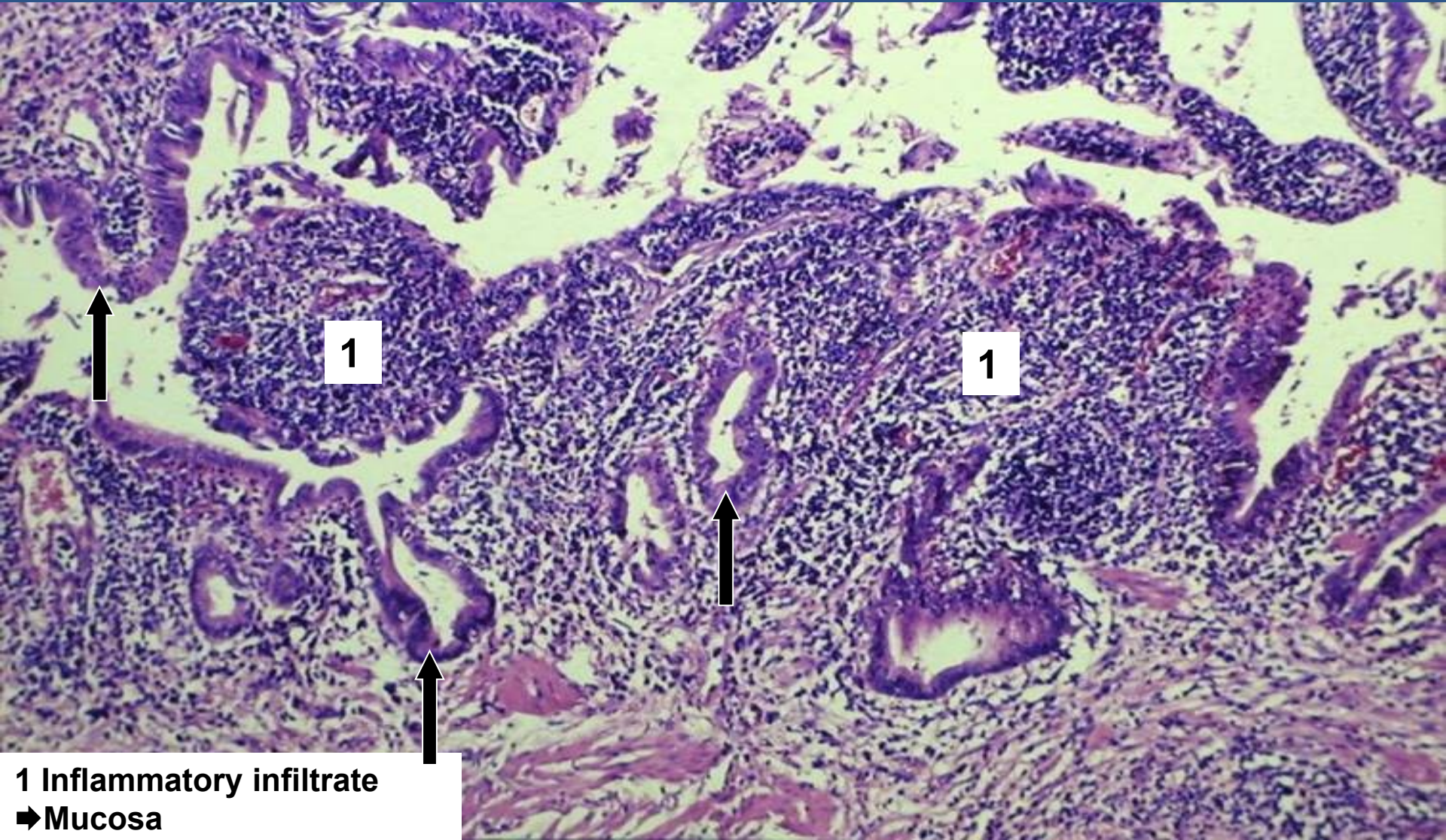
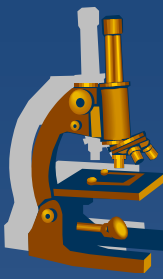
1 necrosis  
2 bacterias  
3 inflammatory infiltrate  
➔ fibrin

# Chronic cholecystitis



- ✗ Fibroproduction
  - ⇒ *thickening of the wall, adhesion, diff. dg. x ca*
- ✗ Chronic inflammation
- ✗ Reactive epithelial atypias and metaplasia
  - Possible dysplasia
    - ⇒ ↑ *ca risk*
- ✗ Dystrophic calcification
- ✗ Gallbladder hydrops

# *Chronic cholecystitis*

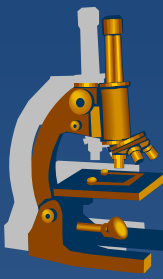


1

1

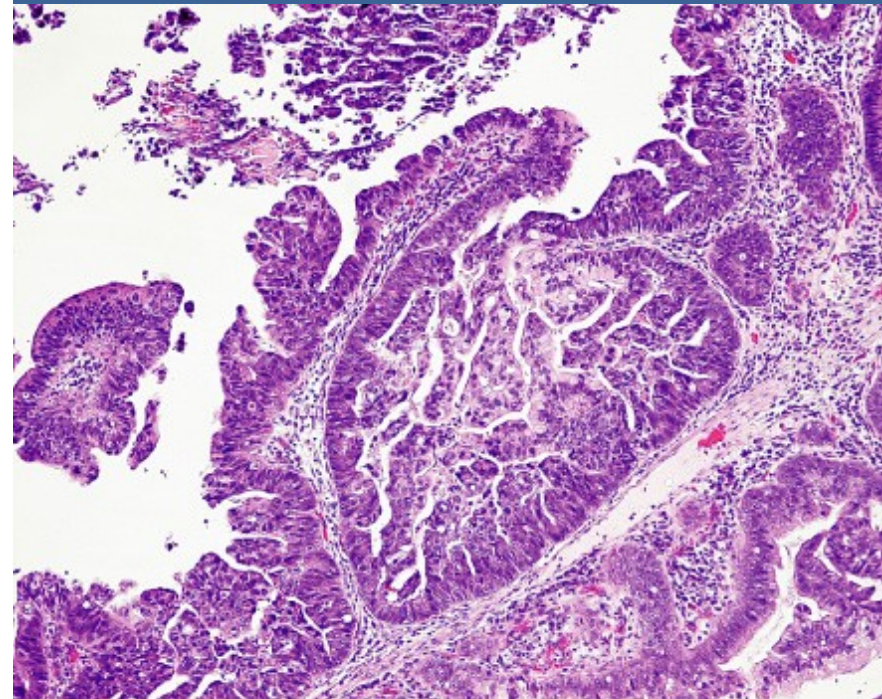
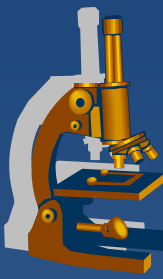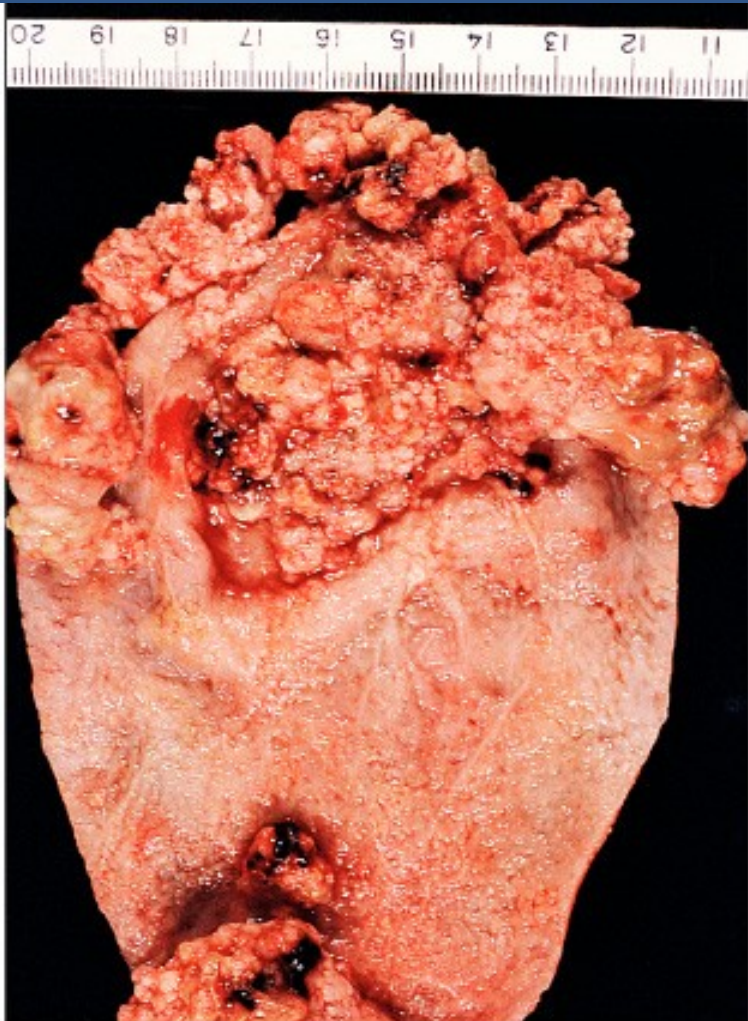
1 Inflammatory infiltrate  
➔ Mucosa

# *Gallbladder carcinoma*



- ✘ Seventh decade
- ✘ F > M
- ✘ Discovered at late stage, usually accidental
- ✘ Adenocarcinoma, other types
- ✘ Local extension into liver, cystic duct, portal LN
- ✘ Mean 5 yrs survival 1%
  - ⇒ *better prognosis if accidental finding in CHCE in incipient stage*

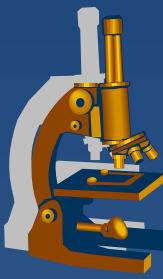
# Gallbladder carcinoma



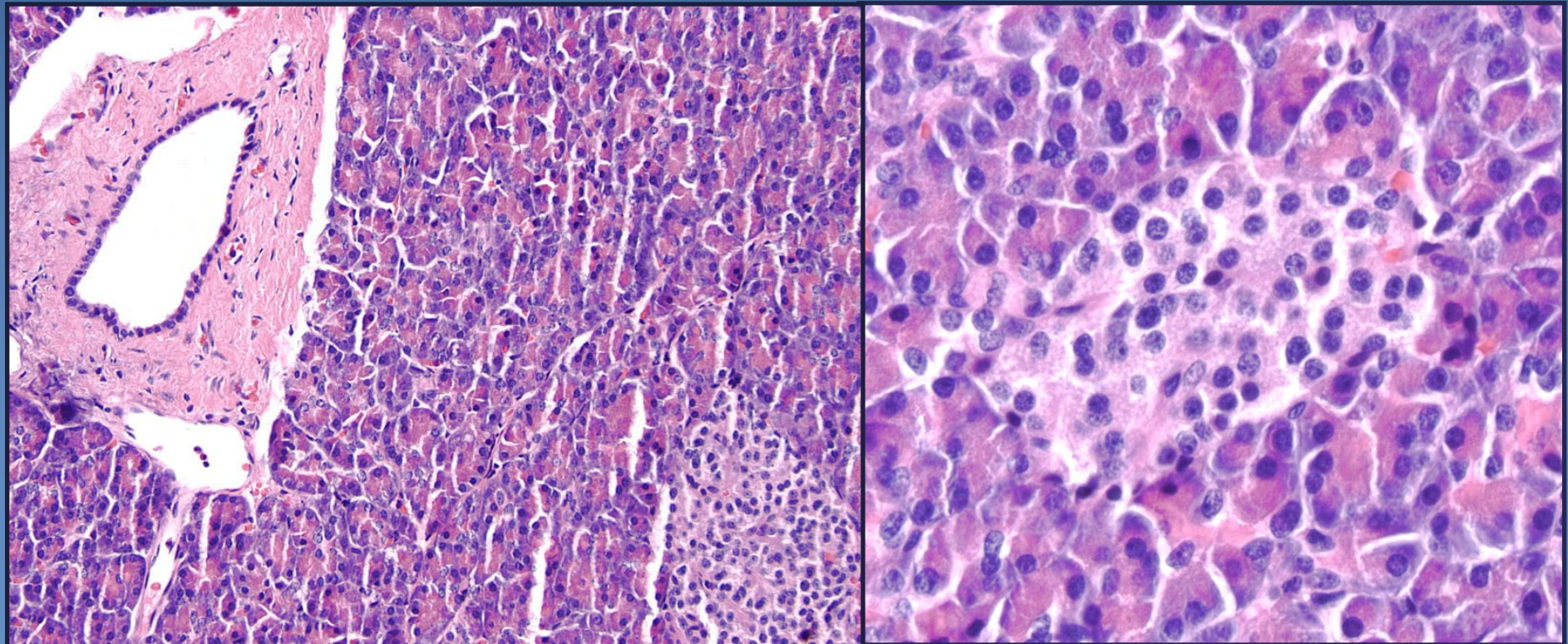
© Elsevier Inc 2004 Rosai and Ackerman's Surgical Pathology 9e



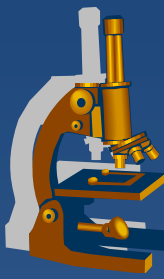
# *Pathology of pancreas*



- ✘ Exocrine
- ✘ Endocrine



# Acute pancreatitis



## × etiological factors:

### ⇒ **Metabolic**

- Alcohol
- Hyperlipoproteinemia (type I and V)
- Hypercalcemia (hyperparathyroidism)
- Drugs
- Genetics

### ⇒ **Mechanic**

- Obstruction (lithiasis), spasms
- Iatrogenic damage (ERCP, perioperative)

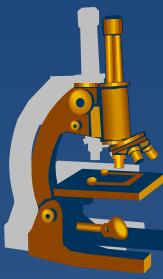
### ⇒ **Vascular, ischemic**

- Shock, thrombosis, embolia
- Vasculitis – polyarteriitis nodosa

### ⇒ **Infections**

- mumps
- Coxsackieviruses
- Mycoplasma pneumoniae

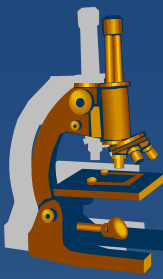
# Acute pancreatitis



## x clinical features:

- ⇒ *severe abdominal (epigastric) pain, nausea and vomiting – acute abdomen*
- ⇒ *DIC*
- ⇒ *shock, multiorgan failure, ARDS, renal failure*
- ⇒ *elevation of serum amylases, lipases, hypocalcaemia*
- ⇒ *infective complications*
- ⇒ *pseudocysts*

# *Acute pancreatitis*



## **x** Morphology:

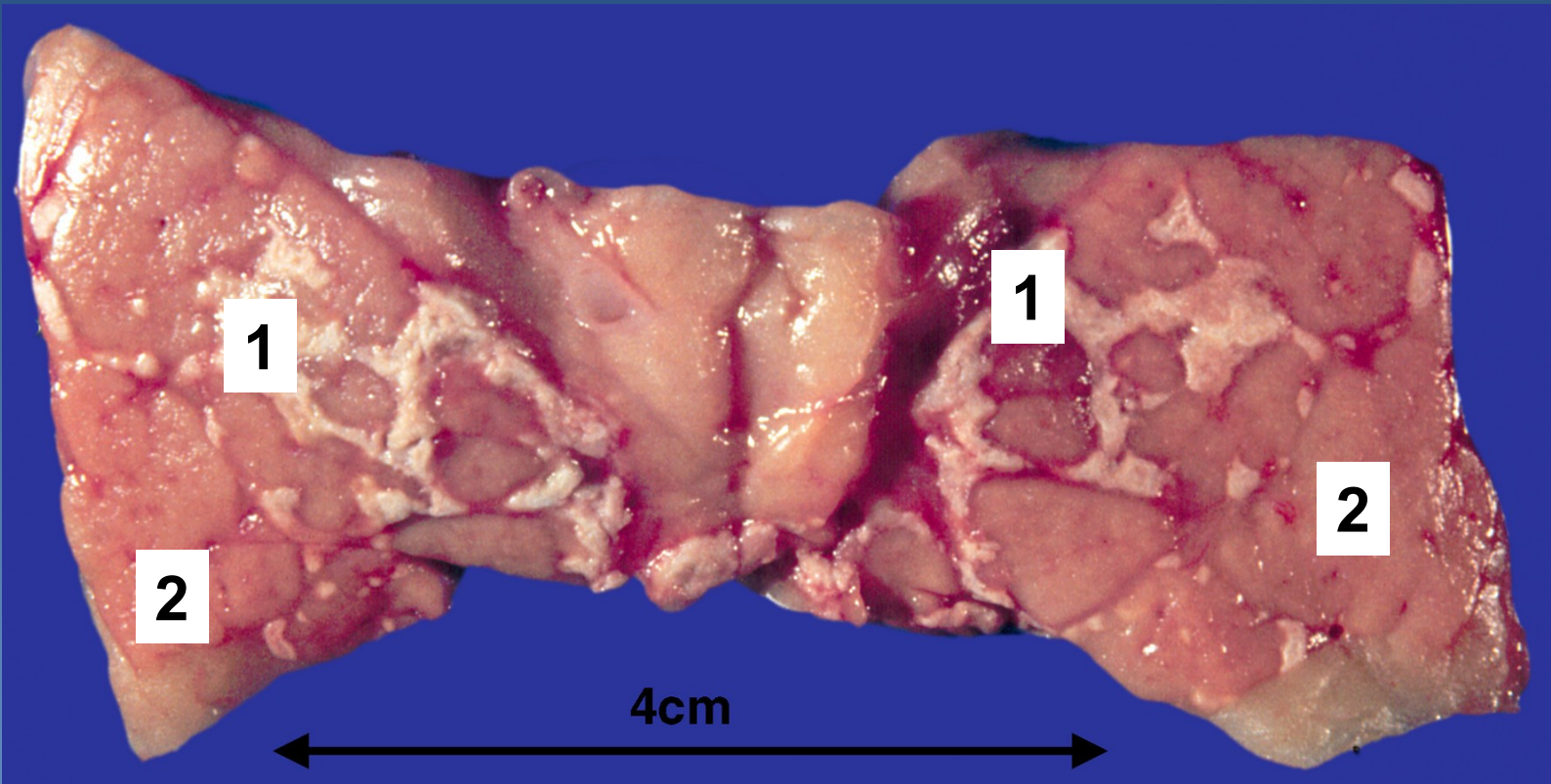
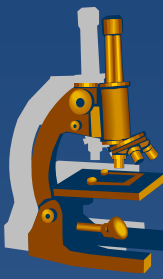
⇒ *serous and haemorrhagic exsudate in the peritoneal cavity*

⇒ *swollen pancreas*

⇒ *necroses, colliquation, haemorrhages*

⇒ *Balzer's fat necroses*

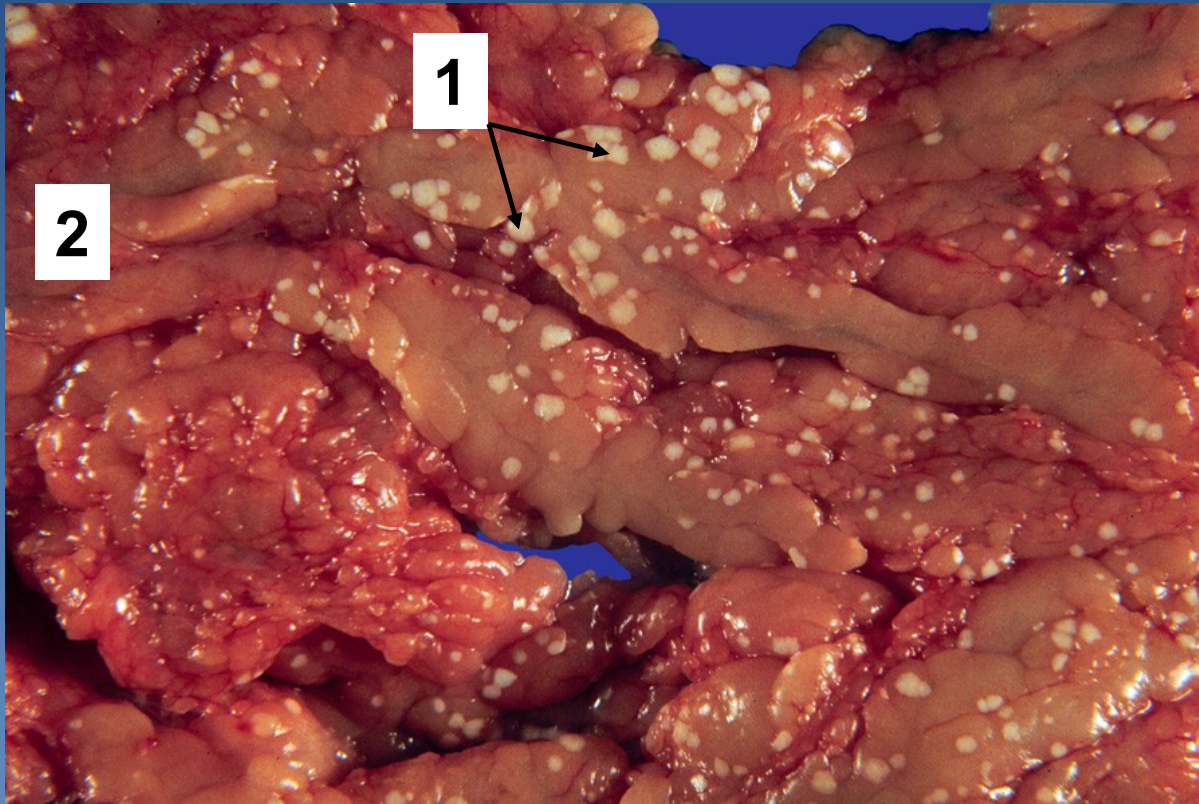
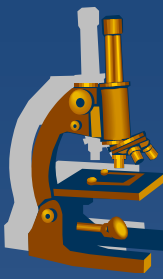
# Acute pancreatitis



1. Fatty necroses with haemorrhagic rim

2. Adjacent pancreatic parenchyma

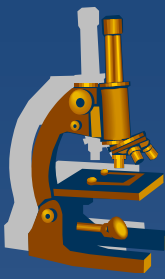
# *Balzer's fat necroses*



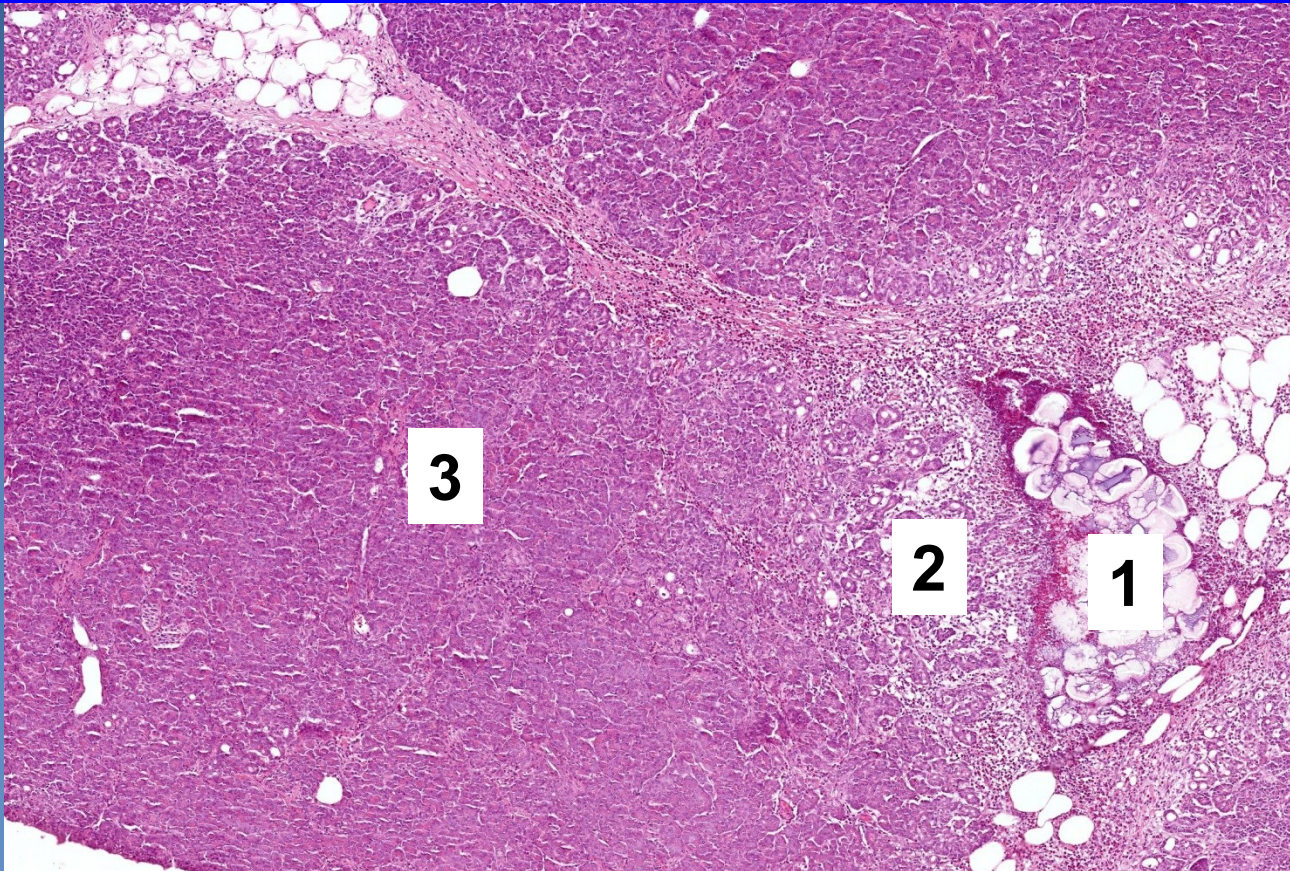
*1. Balzer's fat necrosis in the omentum*

*2. Surrounding fatty tissue*

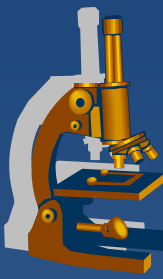
# Acute pancreatitis



1. Necrosis
2. Demarcation/leucocytes
3. Adjacent pancreatic tissue

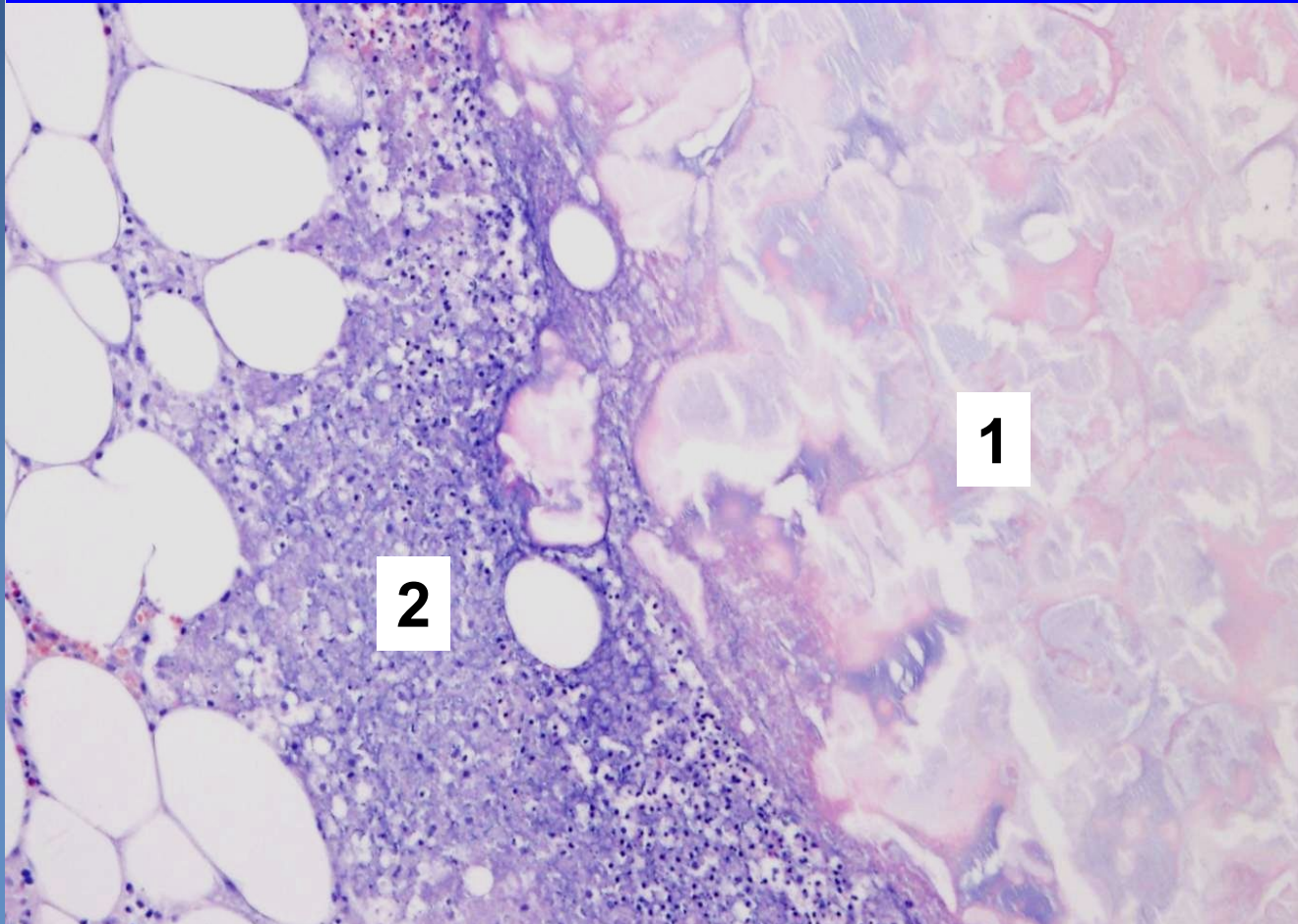


# *Acute pancreatitis*



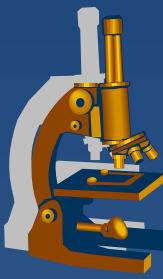
*1. Necrosis*

*2. Demarcation/leucocytes*





# *Chronic pancreatitis*



- × TIGAR-O classification (2001):

- ⇒ *Toxic/metabolic (alcohol, uremia, drugs)*

- ⇒ *Idiopathic*

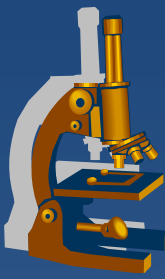
- ⇒ *Genetic (hereditary)*

- ⇒ *Autoimmune*

- ⇒ *Recurrent acute*

- ⇒ *Obstructive*

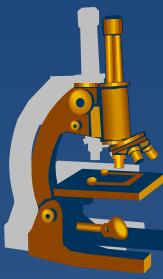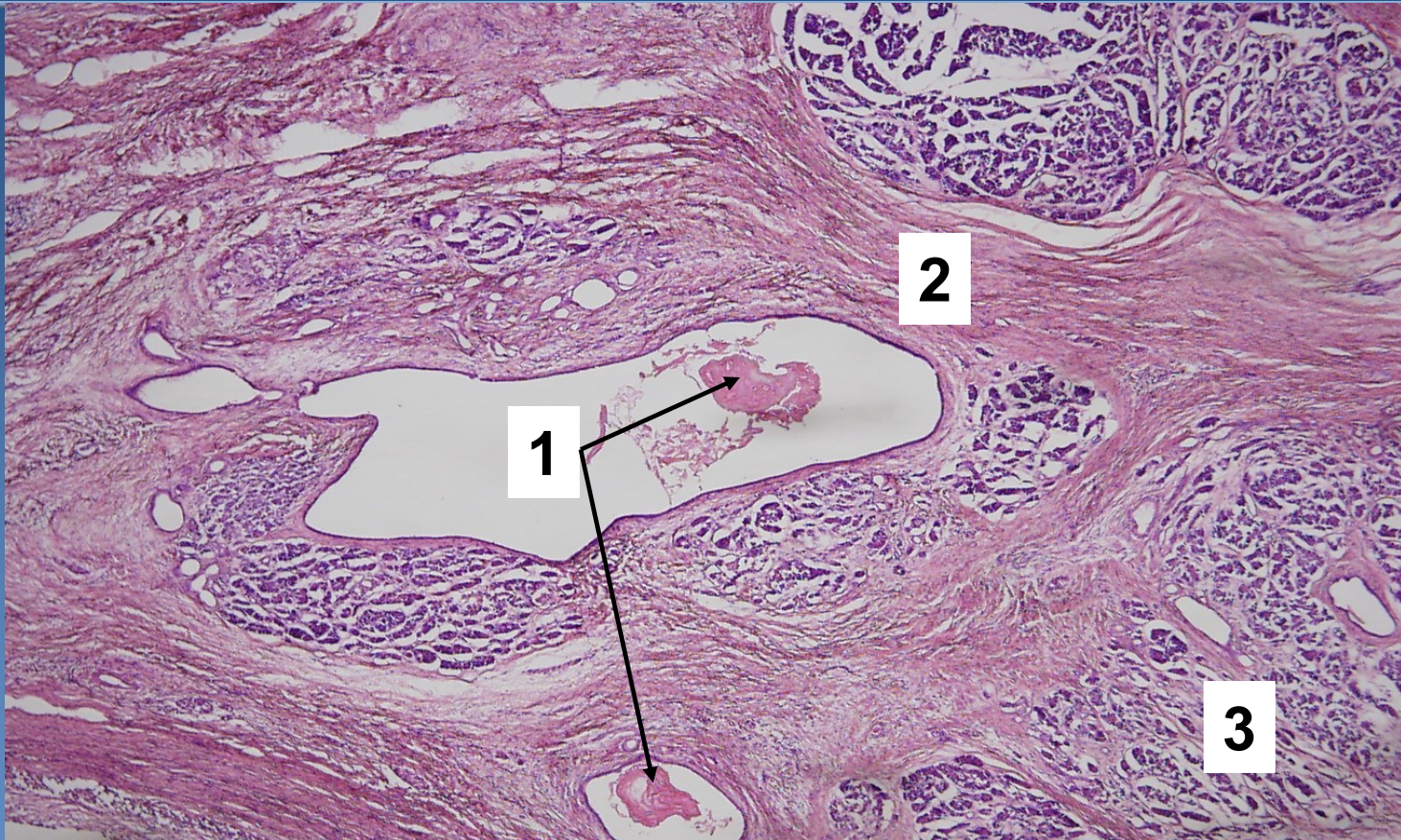
# *Alcoholic pancreatitis*



## **x** histologic features:

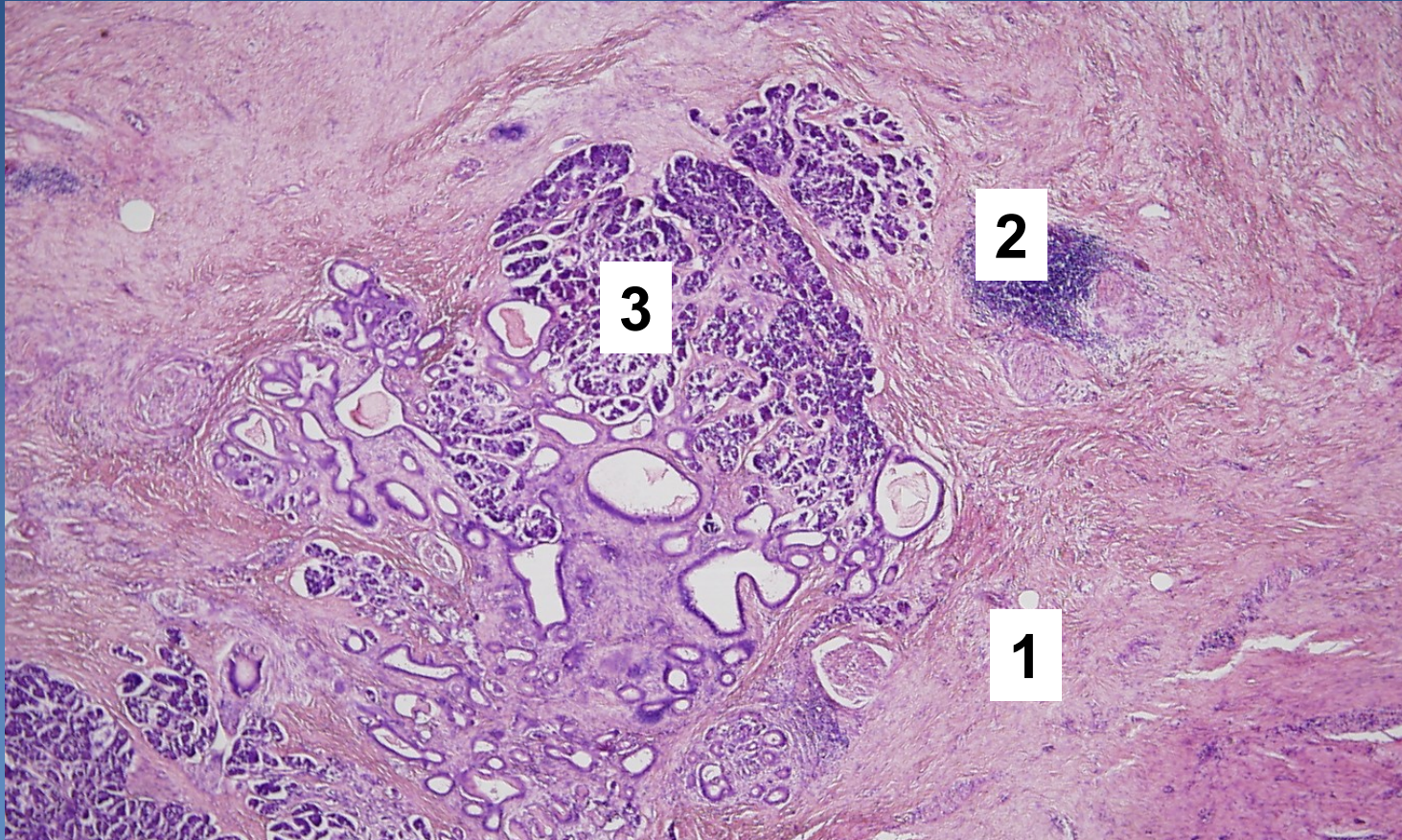
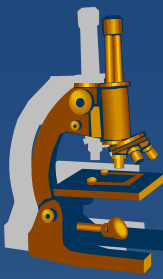
- ⇒ *chronic calcifying pancreatitis*
- ⇒ *fibrotisation of pancreas, mostly perilobular*
- ⇒ *autodigestive necroses and postmaltatic pseudocysts*
- ⇒ *dilated and irregular ducts*
- ⇒ *protein plugs in ducts, calcifications*
- ⇒ *hyperplasia and metaplasia of ductal epithelium*
- ⇒ *increased risk of pancreatic cancer in chronic pancreatitis*

# *Alcoholic pancreatitis*



- 1. Dilated ducts, protein plugs in ducts*
- 2. Perilobular fibrotisation*
- 3. Lobular architecture of pancreas*

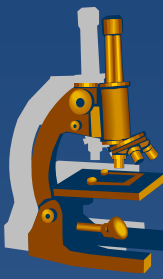
# Alcoholic pancreatitis



- 1. Perilobular fibrotisation*
- 2. lympho-plasmocellular inflammatory infiltration*
- 3. Lobular architecture of the pancreas*

# ***Autoimmune pancreatitis***

---



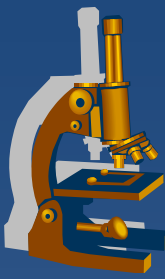
**x adults affected**

⇒ *rare in 2nd and 3rd decade*

**x M>F**

**x clinical and radiological features mimic pancreatic cancer**

**x associated with other autoimmune disorders**

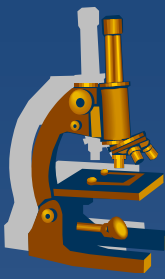


# ***Obstructive pancreatitis***

- x** **Obstructive pancreatitis – histological features:**
  - ⇒ *diffuse perilobular and intralobular fibrosis*
  - ⇒ *dilated ducts without obstruction, irregularities or signs of destruction of ductal epithelium*
  - ⇒ *no protein plugs or calcifications in ducts*
  - ⇒ *hyperplasia of ductal epithelium*
  - ⇒ *necroses and pseudocysts absent*

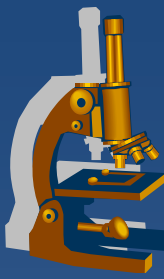
# *Tumours of the pancreas*

---



- x epithelial
- x non-epithelial
- x secondary - metastatic

# Epithelial tumours



## × *classified according to biological behavior:*

### ⇒ **benign:**

- serous cystadenoma
- acinar cell cystadenoma

### ⇒ **Premalignant lesion:**

- pancreatic intraepithelial neoplasia grade 3 (PanIN-3)
- mucinous cystic neoplasm with low- or intermediate grade dysplasia
- mucinous cystic neoplasm with high grade dysplasia
- intraductal papillary mucinous neoplasm with low- or intermediate grade dysplasia
- intraductal papillary mucinous neoplasm with high grade dysplasia
- intraductal tubulopapillary neoplasm

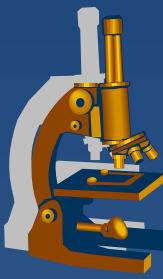
### ⇒ **malignant:**

- **Ductal adenocarcinoma !! (PDAC)**
- mucinous cystic neoplasm associated with invasive carcinoma
- intraductal papillary mucinous neoplasm associated with invasive carcinoma
- acinar cell carcinoma
- acinar cell cystadenocarcinoma
- serous cystadenocarcinoma
- pancreatoblastoma
- solid-pseudopapillary neoplasm
- mixed acinar-ductal carcinoma
- mixed acinar-neuroendocrine carcinoma
- mixed acinar-neuroendocrine-ductal carcinoma
- mixed neuroendocrine-ductal carcinoma



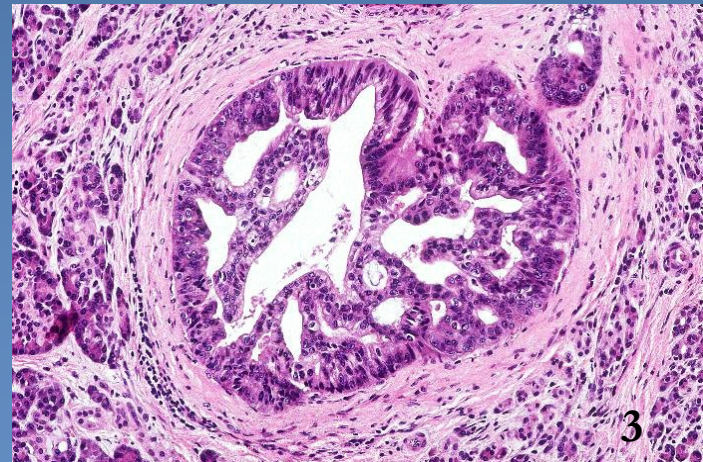
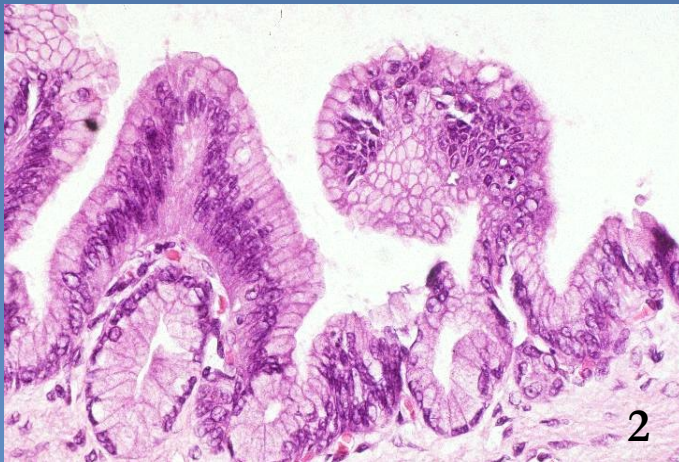
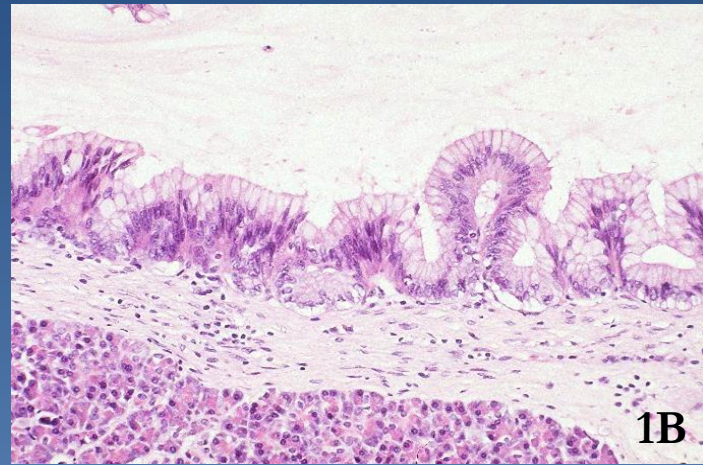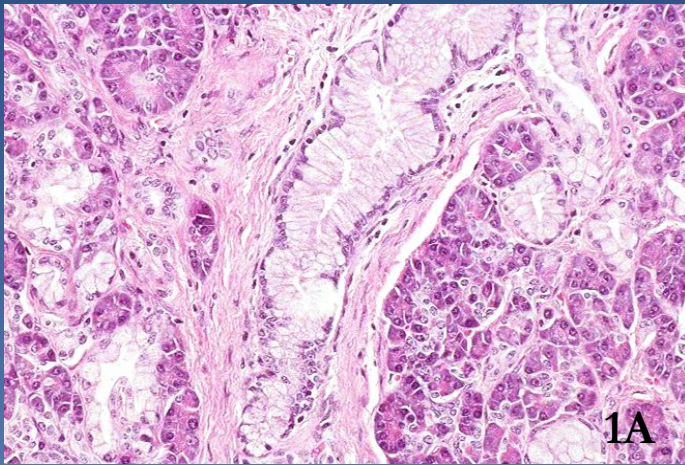
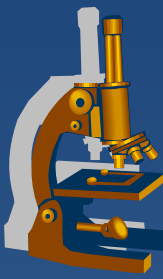
# ***Precursor lesions of invasive pancreatic cancer***

---

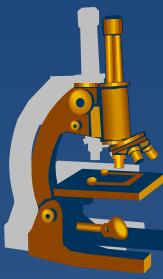


- x Pancreatic intraepithelial neoplasia (PanIN)**
  - ⇒ *microscopic precursor of PDAC*
- x Mucinous cystic neoplasm (MCN)**
- x Intraductal papillary mucinous neoplasm (IPMN)**
  - ⇒ *gross cystic precursor lesions*

# *Pancreatic intraepithelial neoplasia (PanIN)*

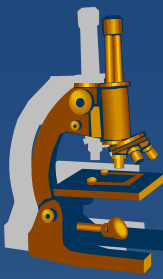


# Ductal adenocarcinoma



- × *ductal adenocarcinoma* - 85-90% of all pancreatic neoplasias
  
- × 5th most frequent cancer-related death
  - ⇒ *in GIT 2nd after colorectal cancer*
  
- × **risk factors:**
  - ⇒ *higher age*
  - ⇒ *genetic factors*
  - ⇒ *environmental factors:*
    - **smoking, high fat diet, obesity and low physical activity, chemicals**
  - ⇒ *chronic pancreatitis (both hereditary and sporadic); (CP)*
  - ⇒ *diabetes mellitus*
  - ⇒ *alcohol (indirectly, induces CP)*

# ***Ductal adenocarcinoma***



## **x Clinical features:**

⇒ ***60-70 % in the pancreatic head***

⇒ ***abdominal and back pain***

⇒ ***weight loss***

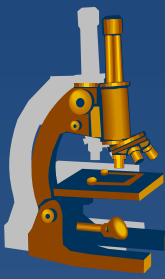
⇒ ***icterus, pruritus, diabetes mellitus***

⇒ ***migratory thrombophlebitis***

⇒ ***symptoms related to liver metastasis and/or invasion of adjacent organs***

# Ductal adenocarcinoma

---



- × biological behavior

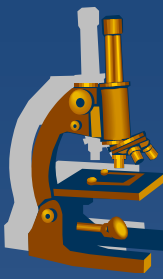
- ⇒ *lymphogenous metastasis (regional lymph nodes)*

- ⇒ *haematogenous metastasis (liver, lungs, bones)*

- ⇒ *carcinomatosis of peritoneum*

- ⇒ *perineural spreading*

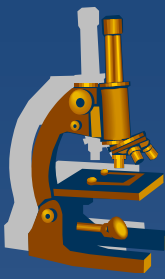
# Ductal adenocarcinoma



## x Gross:

- ⇒ *usually solid mass in the pancreatic head*
- ⇒ *mean diameter 2-3 cm*
- ⇒ *common bile duct and/or main pancreatic duct stenosis*
- ⇒ *necrosis rare*
- ⇒ *absence of calcifications and pseudocysts*

# Ductal adenocarcinoma

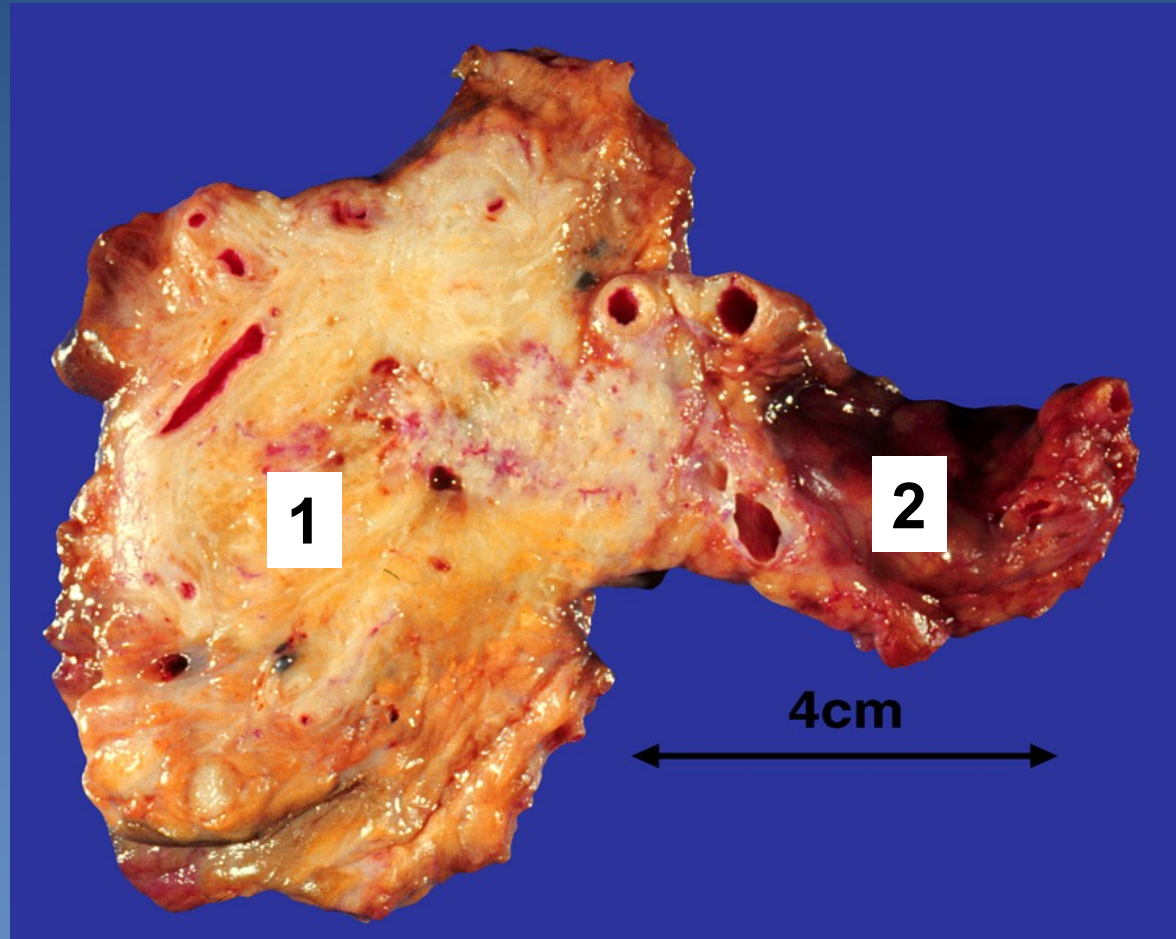
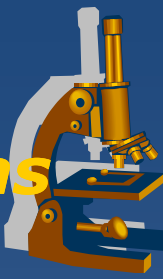


## × Micro:

### ⇒ *grade of differentiation:*

- **grade 1: well differentiated**
  - ductal and tubular formation in desmoplastic stroma, columnar mucin producing cell, distinct small nucleoli, low mitotic activity, low degree of pleomorphism/atypia
- **grade 2: moderately differentiated**
  - ductal, tubular, microglandular, cribriform formation, desmoplasia, irregular mucin production, prominent nucleoli, higher pleomorphism
- **grade 3: poorly differentiated**
  - irregular glandular structure, solid aggregates, squamoid foci, spindle cells, anaplastic, pleomorphic structures, mitotic activity

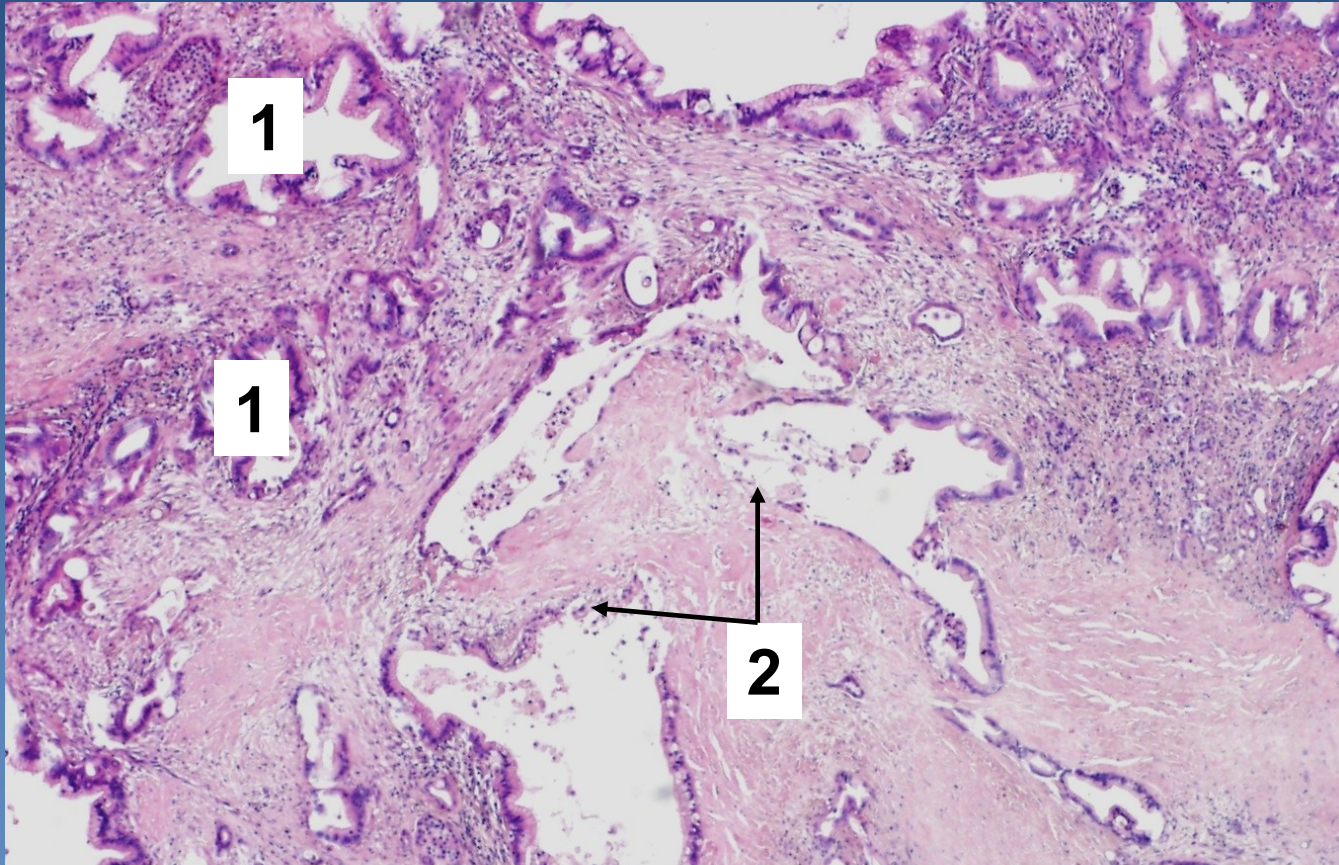
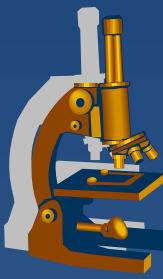
# *Ductal adenocarcinoma in the head of pancreas*



- 1. Carcinoma of pancreatic head*
- 2. Pancreatic body and tail*



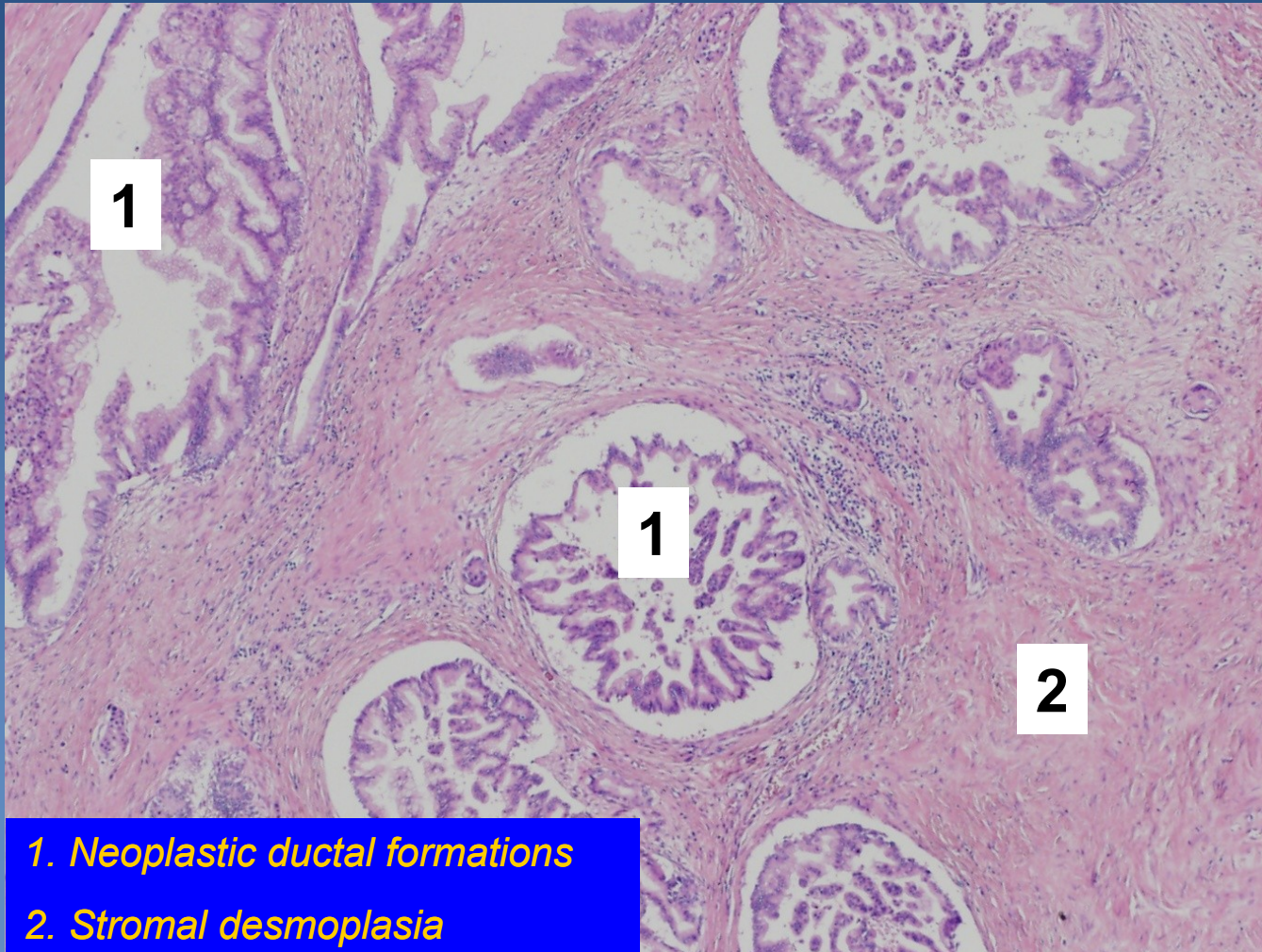
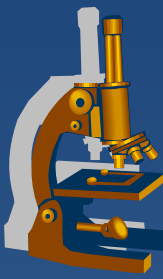
# Ductal adenocarcinoma



*1. Neoplastic ductal formations*

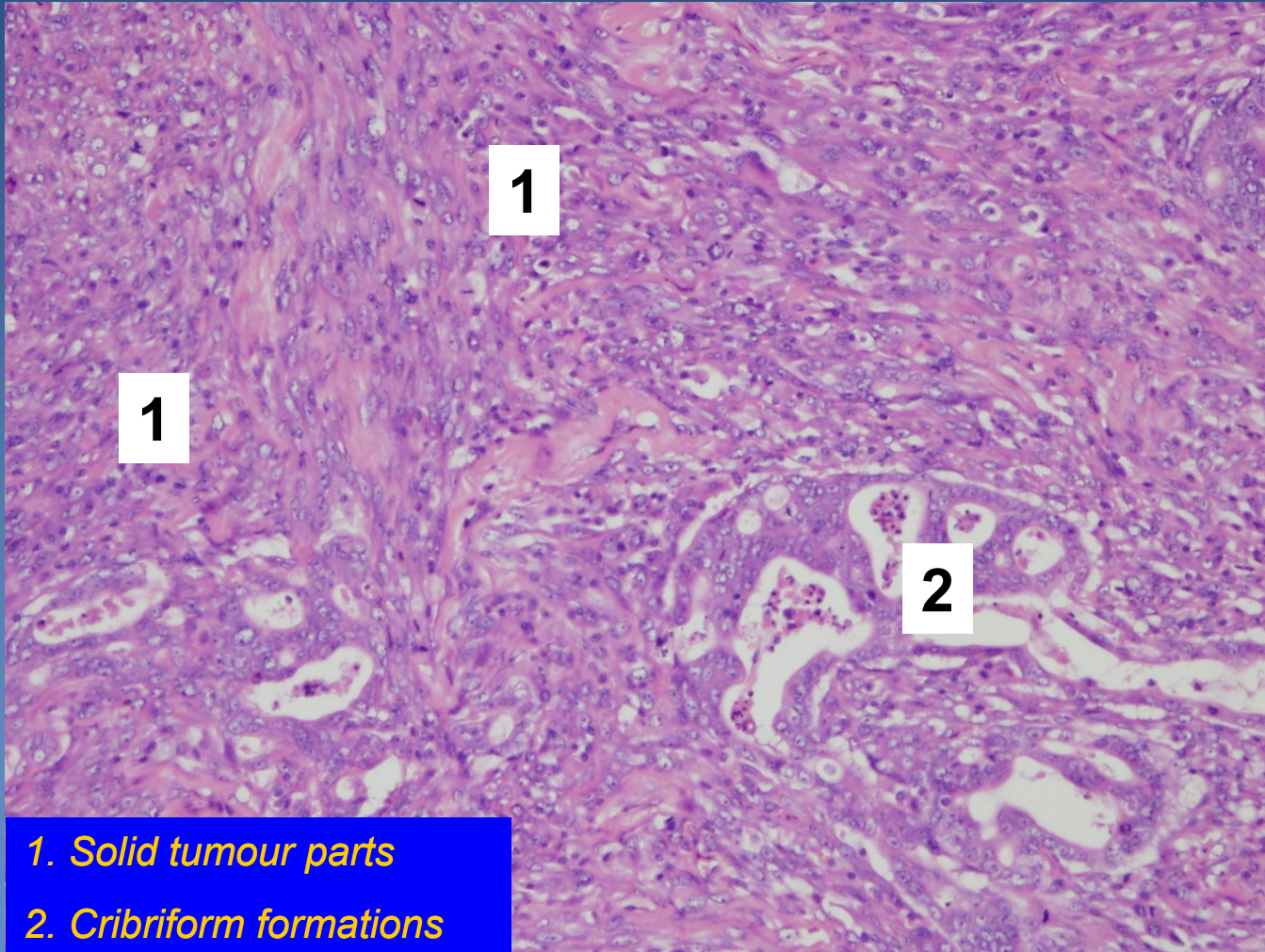
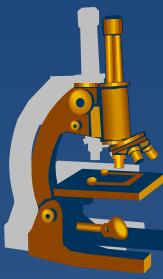
*2. Focal duct ruptures with macrophages and detritus intraluminally*

# *Ductal adenocarcinoma – well differentiated (G1)*



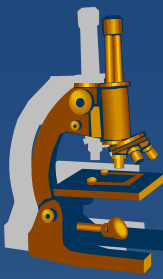
- 1. Neoplastic ductal formations*
- 2. Stromal desmoplasia*

# *Ductal adenocarcinoma – poorly differentiated (G3)*



- 1. Solid tumour parts*
- 2. Cribriform formations*

# ***Differential diagnosis of ductal adenocarcinoma and chronic pancreatitis – clinical features***



## **x Adenocarcinoma:**

⇒ *older patients*

- rare under 40

⇒ *no pancreatitis and alcoholism in medical history*

⇒ *sudden painless icterus*

## **x Chronic pancreatitis:**

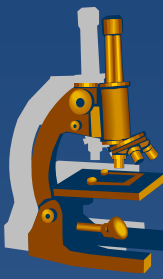
⇒ *often in younger patients*

⇒ *medical history:*

- long term
  - recurrent acute pancreatitis
- alcohol abuse

⇒ *icterus after long term duration of disease*

# ***Differential diagnosis of ductal adenocarcinoma and chronic pancreatitis – gross features***



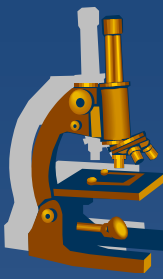
## **x Adenocarcinoma:**

- ⇒ *solid mass in the pancreatic head, mean diameter 2-3 cm*
- ⇒ *common bile duct stenosis*
- ⇒ *usually without necrosis, calcifications, pseudocysts*

## **x Chronic pancreatitis:**

- ⇒ *more diffuse*
- ⇒ *Alternation of lobular parenchyma and areas of fibrosis*
- ⇒ *protein plugs and calcifications in ducts*
- ⇒ *extrapancreatic pseudocysts*

# Differential diagnosis of ductal adenocarcinoma and chronic pancreatitis – microscopic features



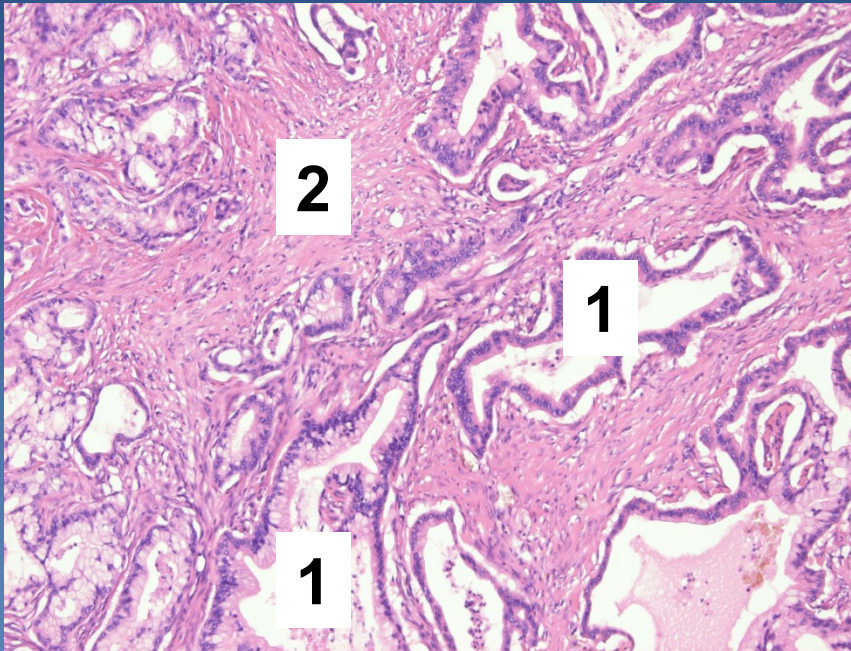
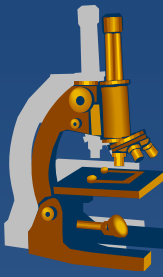
## × Adenocarcinoma:

- ⇒ haphazard distribution of irregular ductal structures
- ⇒ ducts perineurally, in extrapancreatic fatty tissue
- ⇒ hypercellular condensation of stroma around neoplastic ducts, stromal desmoplasia
- ⇒ enlarged nuclei, pleomorphism, hyperchromasia, mitoses, prominent nucleoli, loss of nuclear polarity
- ⇒ dense acidophilic cytoplasm, apical condensation of cytoplasm

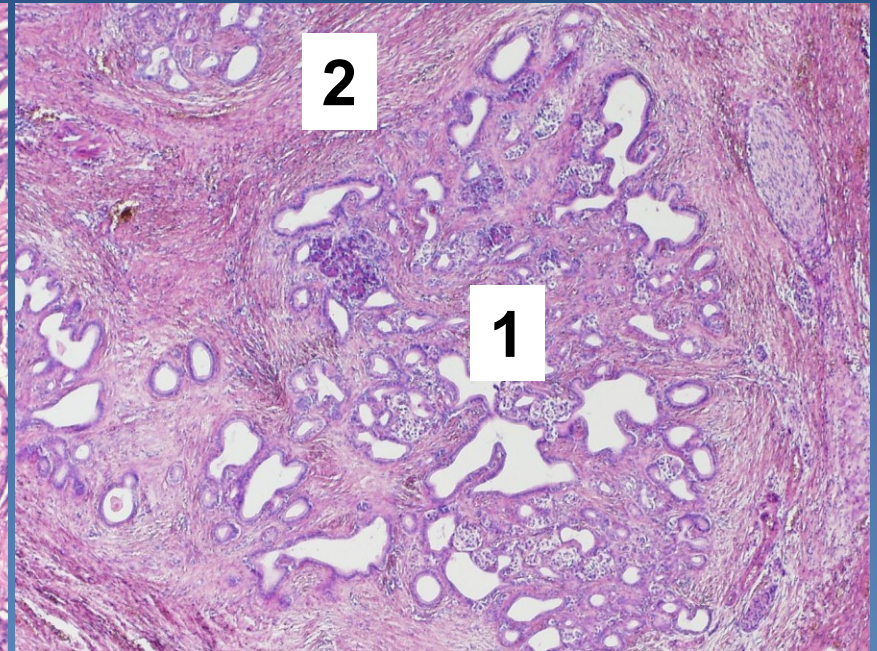
## × Chronic pancreatitis

- ⇒ (organoid) lobular arrangement
- ⇒ ducts intrapancreatically
- ⇒ smooth contours of the ducts, round/oval lumens
- ⇒ dense hyalinized stroma
- ⇒ uniform nuclei, inconspicuous nucleoli, no mitoses
- ⇒ cytoplasm normochromophilic, absence of apical condensation

# **Differential diagnosis of ductal adenocarcinoma and chronic pancreatitis – microscopic features**

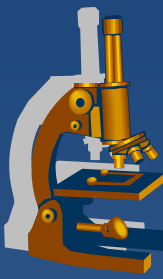


1. Haphazard distribution of irregular ducts
2. Stromal desmoplasia



1. Lobular arrangement
2. Dense hyalinized stroma

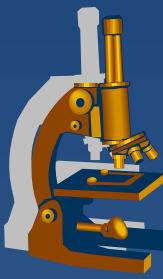
# Neuroendocrine neoplasms of the pancreas



- ✘ synonyms: pancreatic NETs, islet cell tumor, APUDoma
- ✘ 1 – 2 % of all pancreatic tumors
- ✘ 3rd-6th decade
- ✘ classification:
  - ⇒ *neuroendocrine tumour (NET)*
    - nonfunctional NET (NET G1, G2)
    - NET G1
    - NET G2
  
  - ⇒ *neuroendocrine carcinoma (NEC)*
    - large cell NEC
    - small cell NEC



# Neuroendocrine neoplasms of pancreas



- × Functional (hormonally active)
  - ⇒ *insulinoma*
  - ⇒ *glucagonoma*
  - ⇒ *somatostatinoma*
  - ⇒ *gastrinoma*
  - ⇒ *VIPoma*
  - ⇒ *serotonin producing NET*
  - ⇒ *others – with ectopic hormone production (ACTH, calcitonin,...)*
  
- × Nonfunctional (with no association with hormonal syndrome)
  
- × Pancreatic neuroendocrine microadenomas
  - ⇒ *<0,5 cm*
  - ⇒ *usually clinically silent*

# ***Neuroendocrine neoplasms of pancreas***

---



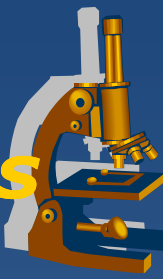## **xGross:**

⇒ *partially or totally circumscribed/encapsulated; usually solitary*

⇒ *white, yellow or pink-brown*

⇒ *haemorrhages, necrosis can occur; cystic tumors rare*

# ***Neuroendocrine neoplasms of pancreas***



## **x Micro:**

⇒ *nesting, trabecular, glandular, acinar, tubuloacinar, pseudorosette, ...arrangements of their cells*

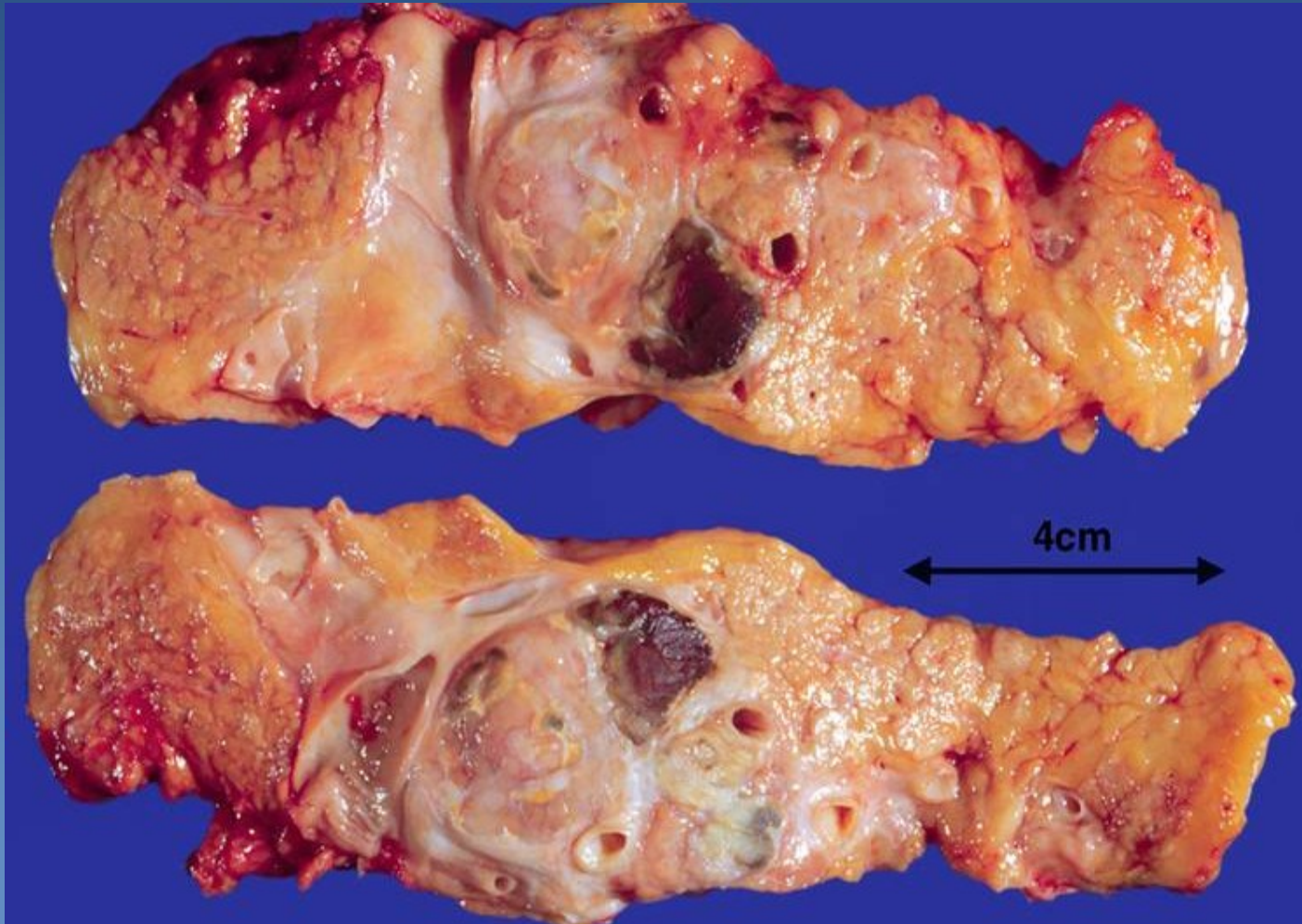
⇒ *cells uniform, round, finely granular amphophilic to eosinophilic cytoplasm, coarsely clump chromatin („salt and pepper“)*

⇒ *Variable amount of stroma*

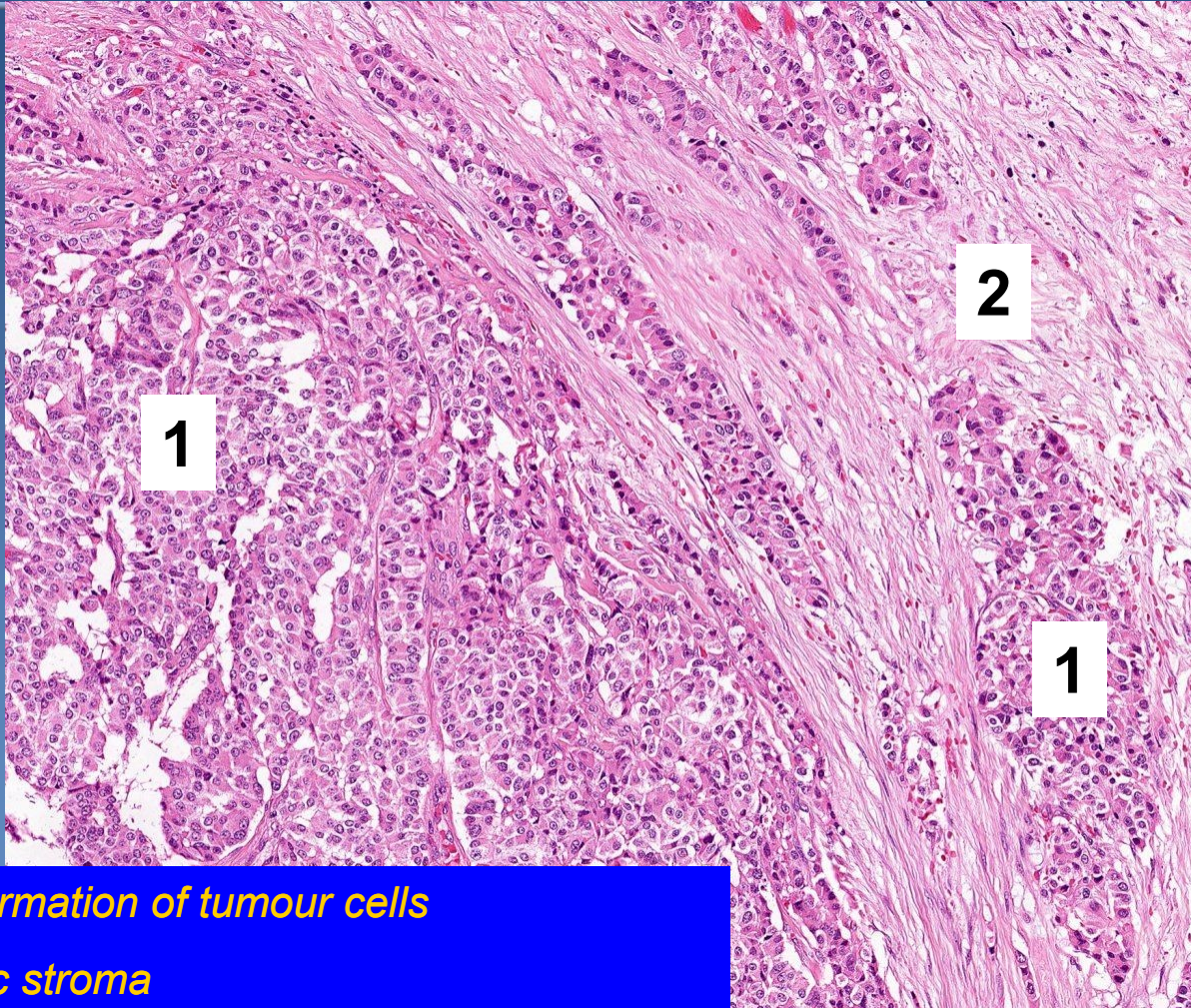
⇒ **IHC:**

- CEA, synaptophysin, chromogranin, NSE, CD56
- peptide hormones:
  - insulin, glucagon, serotonin, somatostatin, gastrin

# *Neuroendocrine neoplasms of pancreas*



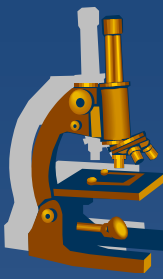
# *Neuroendocrine neoplasms of pancreas*



*1. Trabecular formation of tumour cells*

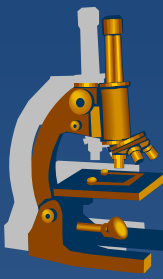
*2. Dense fibrotic stroma*

# Diabetes mellitus



- ✗ Group of complex metabolic lesions
- ✗ Multifactorial etiology
- ✗ Common sign:
  - ⇒ *glucose metabolism dysregulation* → *glucose intolerance* - **hyperglycaemia**
- ✗ Causes:
  - ⇒ *insulin secretion disorders*
  - ⇒ *disorders of insulin action / response to insulin*
  - ⇒ *combination of both*

# *Diabetes mellitus*



## **x** Other metabolic disorders:

### ⇒ *lipolysis*

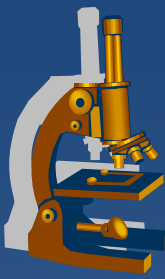
- hyperlipidaemia (loss of weight), ketoacidosis

### ⇒ *hyperglycaemia*

- osmotic diuresis (polyuria, dehydration, thirst)

### ⇒ *diminished protein synthesis*

# *Diabetes mellitus - classification*



## **x Primary DM:**

### ⇒ *DM type 1*

- insulin-dependent
- destruction of  $\beta$ -cells, autoimmune, idiopathic

### ⇒ *DM type 2*

- non-insulin dependent

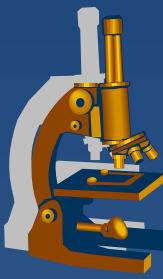
### ⇒ *Genetic defects of $\beta$ -cells function*

- MODY – maturity-onset diabetes of the young, etc.

## **x Now possible 5 DM types**



# ***Diabetes mellitus - classification***



## **× Secondary DM:**

### ⇒ ***Exocrine pancreas defects***

- (chron. pancreatitis, cystic fibrosis, hemochromatosis, tumor)

### ⇒ ***Endocrinopathies***

- (Cushing sy, hyperthyreosis, acromegaly, etc.)

### ⇒ ***Infections***

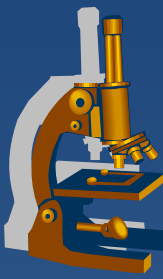
- (CMV, coxsackie B, congenital rubella)

### ⇒ ***Drugs***

- (glucocorticoids, proteases inhibitors, ...)

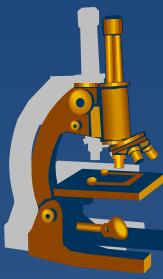
## **× Gestational DM**

# Diabetes mellitus



- ✘ Atypical glucose bond on proteins
  - ⇒ *glycation* → change of normal characteristics/functions, i.e. in vessels BM; monitoring - glycosylated hemoglobin HbA1c
- ✘ Polyol pathways
  - ⇒ *atypical metabolism* of glucose by reductases to sorbitol + fructose i.e. in kidneys, nerves, eye lens → oedema and cell damage
- ✘ Free radicals formation
  - ⇒ *oxidative stress*

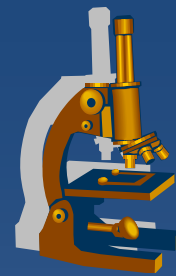
# ***Diabetes mellitus - complications***



Long-term consequences similar in all types:

- ⇒ *microangiopathy (neuropathy, retinopathy)*
- ⇒ *diabetic glomerulosclerosis*
- ⇒ *accelerated atherosclerosis*
- ⇒ *immune defect, mostly nonspecific (bacterias, fungi)*
- ⇒ *diabetic ketoacidosis, hyperosmolar coma*
- ⇒ *hypoglycaemia/coma due to insulin overdose*

# ***Diabetes mellitus – morphology***



## **Pancreas**

### **x DM type1**

⇒ *more specific changes*

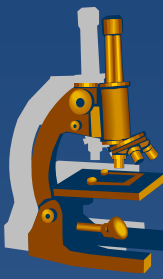
⇒ *insulinitis with lymphocytic infiltration of islets + ↓ of their size and number*

### **x DM type 2**

⇒ *possible amyloid deposition or islet fibrotisation*

# *Diabetes mellitus – morphology*

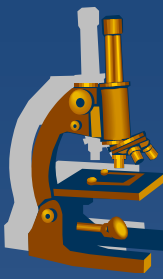
---



## Large vessels

- ✘ AS, changes non-specific
- ✘ AS complications (MI, gangrene) sooner and more often
- ✘ accelerated hyaline arteriolosclerosis and hypertension → intracerebral haemorrhage, nephrosclerosis

# *Diabetes mellitus – morphology*



## Small vessels

- ✘ Microangiopathy

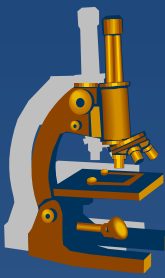
  - ⇒ *diffuse thickening of BM, but BM more leaky for proteins*

- ✘ Nephropathy

- ✘ Retinopathy

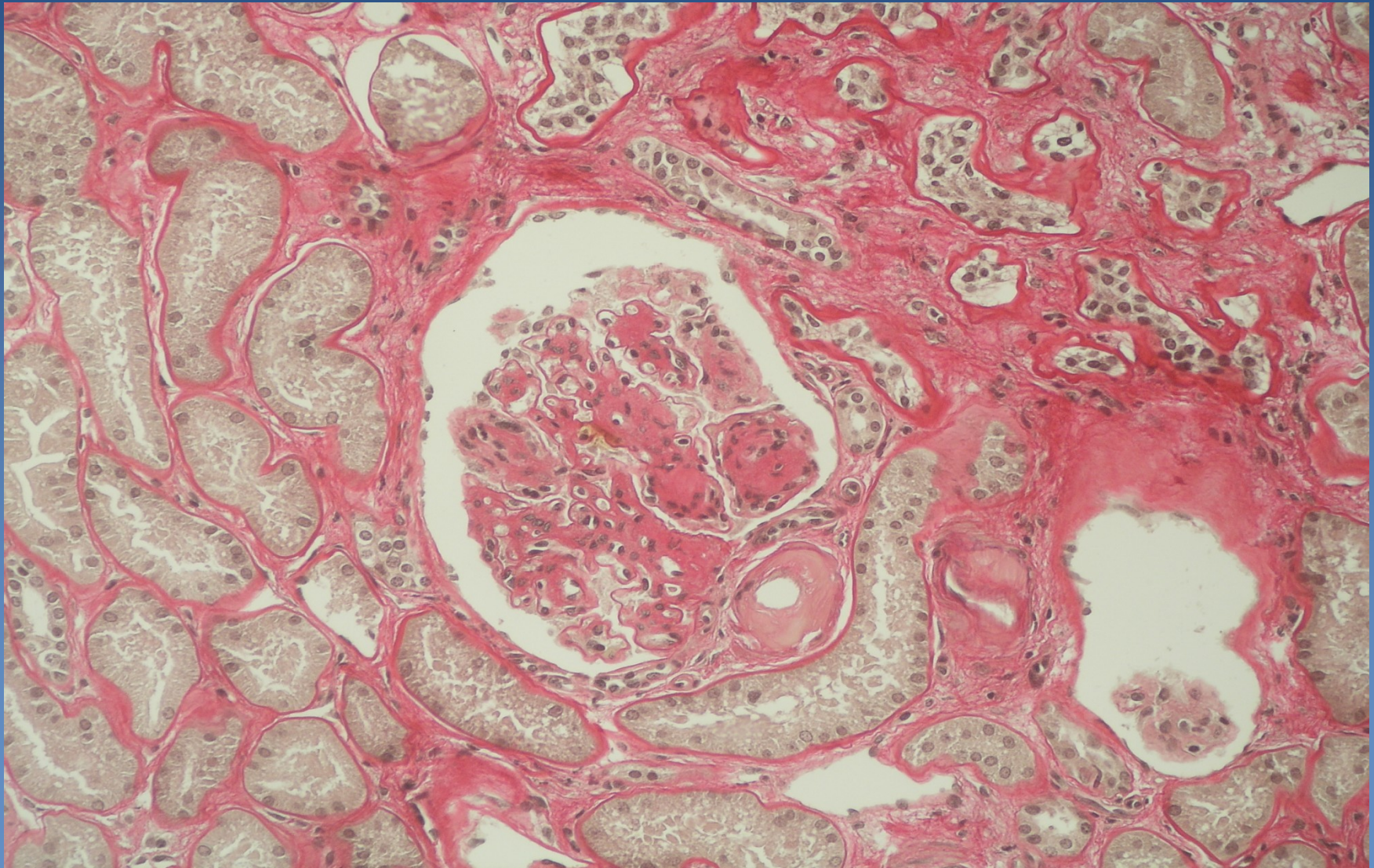
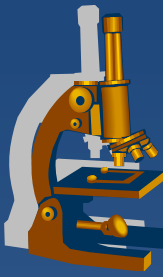
- ✘ Neuropathy

# Diabetic nephropathy



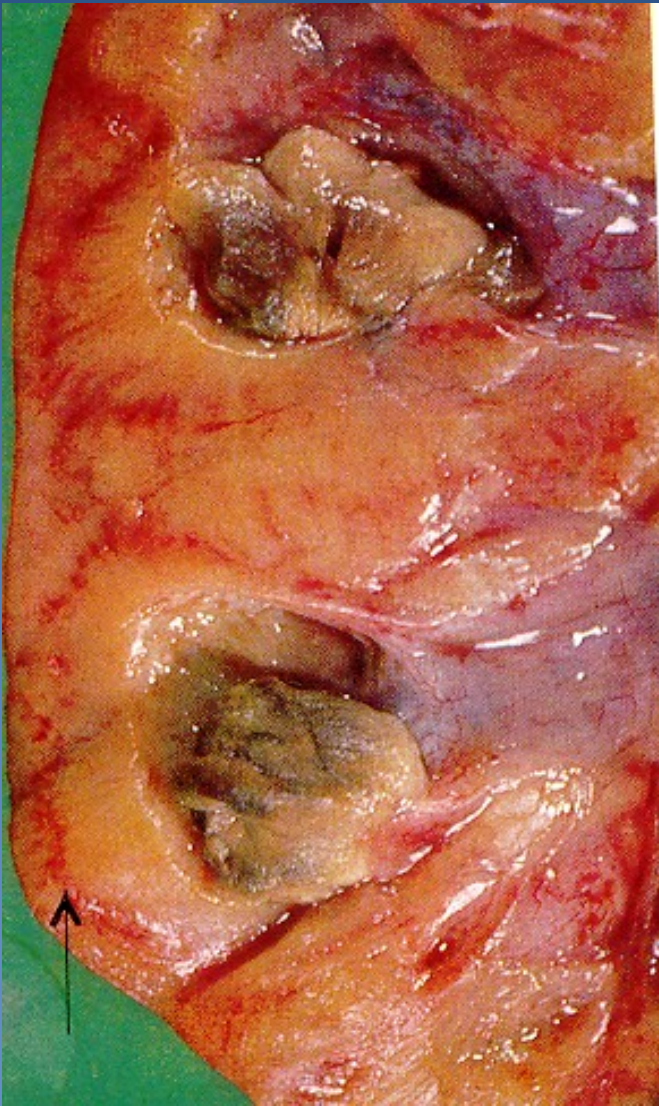
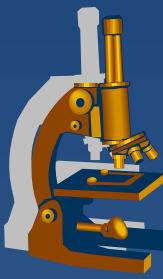
- ✘ Diabetic glomerulosclerosis
  - ⇒ *diffuse x nodular*
- ✘ Renal vascular lesions
  - ⇒ *arteriosclerosis*
- ✘ Pyelonephritis incl. papillary necrosis
- ✘ Common progression to renal insufficiency

# ***Glomerulosclerosis + arteriolosclerosis***





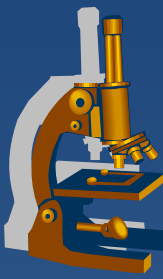
# *Papillary necrosis*



- ✘ Acute necrotizing papillitis in the setting of focal ischaemia

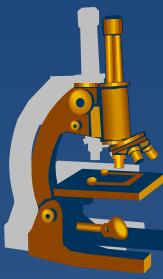
# ***Diabetes mellitus – morphology***

---



- x Ocular lesions:**
  - ⇒ *retinopathy (neovascularization)*
  - ⇒ *cataract formation (opaque lens)*
  - ⇒ *glaucoma (intra-ocular hypertension)*

# ***Diabetes mellitus – morphology***



## **x Neuropathy**

segmental demyelination

### ⇒ ***distal polyneuropathy***

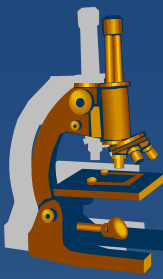
- mostly motoric + sensitive in lower extremities – incl. ↓ pain perception (→ ulceration)

### ⇒ ***autonomic neuropathy***

- functional disorders of intestines, bladder, sexual

# ***Diabetes mellitus – morphology***

---

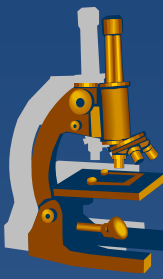


## **x Skin**

- ⇒ *increased susceptibility to infections incl. protracted mycotic i., gangrene*
- ⇒ *granuloma annulare (foci of collagen degeneration + inflammatory infiltrate)*
- ⇒ *necrobiosis lipoidica*

# ***Diabetes mellitus – morphology***

---



## **x Pregnancy**

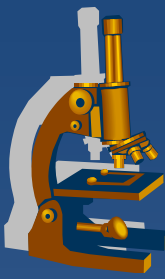
⇒ *pre-eclampsia*

⇒ *large babies (already in utero)*

⇒ *neonatal hypoglycaemia*

# *Metabolic syndrome*

---



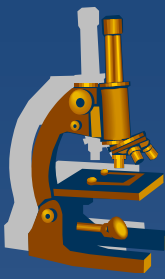
- x abdominal obesity („male type“)
- x insulin resistance
- x hyperlipidemia + abnormal lipid spectrum

## Consequences

- x cardiovascular lesions
- x non-alcoholic steatohepatitis

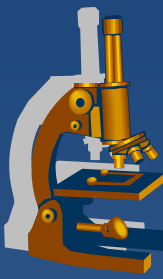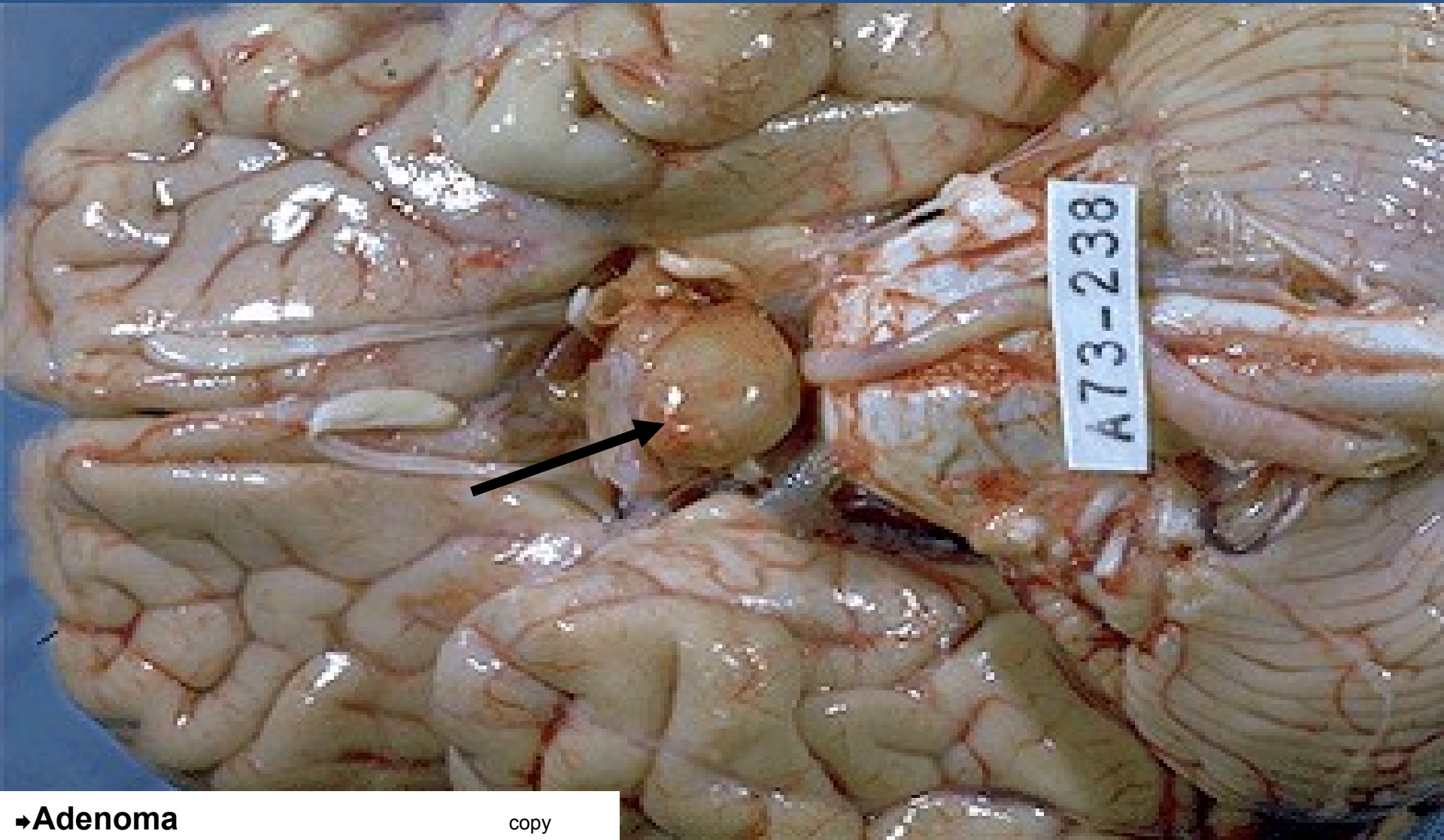
# *Pathology of other endocrine organs (selected)*

---



- x Hyperfunction
- x Hypofunction
- x Neoplasia (+ event. functional changes)

# *Pituitary adenoma*

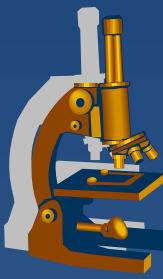


→ Adenoma

copy



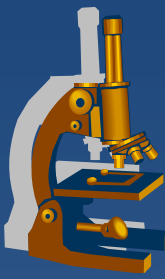
# Thyroid gland



## HYPERTHYROIDISM - thyrotoxicosis

- ✗ overproduction, ↑ release into the blood, extrathyroidal secretion
- ✗ hyperplasia
  - ⇒ *Graves-Basedow disease, nodular goitre*
- ✗ hyperfunctional tumor
  - ⇒ *adenoma, ca*
- ✗ incipient autoimmune thyroiditis
- ✗ endocrine axis dysregulation

# *Thyroid gland*

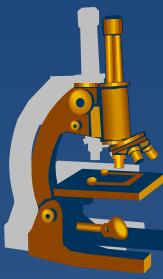


## Thyrotoxicosis

hypermetabolic state + overactivity of sympathetic nervous system

- ✗ Exophthalmos
- ✗ Weight loss, diarrhoea, tremor, anxiety, insomnia
- ✗ Tachycardia, palpitations, arrhythmia - atrial fibrillation → thyrotoxic cardiomyopathy, hypertension
- ✗ Sweating, heat intolerance
- ✗ Osteoporosis
- ✗ Possible thyroid storm, heart failure

# Thyroid gland

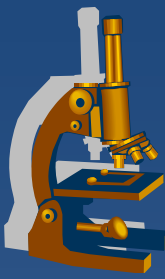


## HYPOTHYROIDISM

✗ congenital (cretinism),

- ⇒ *geographic iodine deficiency (endemic cretinism), individual factors (hypoplasia, ectopy, genetic /metabolic defects)*
- ⇒ *thyroid hormones necessary to fetal brain development → severe neurologic defects incl. mental retardation*
- ⇒ *coarse facial features + hypomimia, protruding tongue, disorders of dentition + growth, sexual retardation*


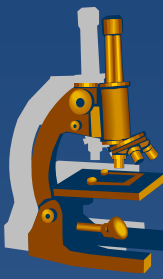
# *Thyroid gland*



## MYXEDEMA

- ✗ hypothyroidism developing in older child/adult
- ✗ **M:F 1:10**
- ✗ slowing of physical/mental activity
- ✗ accumulation of mucoid matrix substances in dermis, myocardium, vessels, ...), hypercholesterolemia, AS acceleration
- ✗ cool skin, cold intolerance, constipation + overweight, fatigue, dyspnoea, decreased exercise capacity
- ✗ secondary oligo- amenorrhoea
- ✗ cardiovascular insufficiency

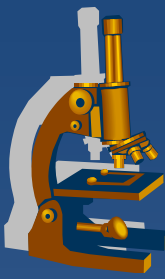
# Thyroid gland - scintigraphy



radioactive iodine uptake

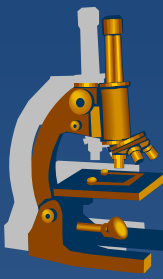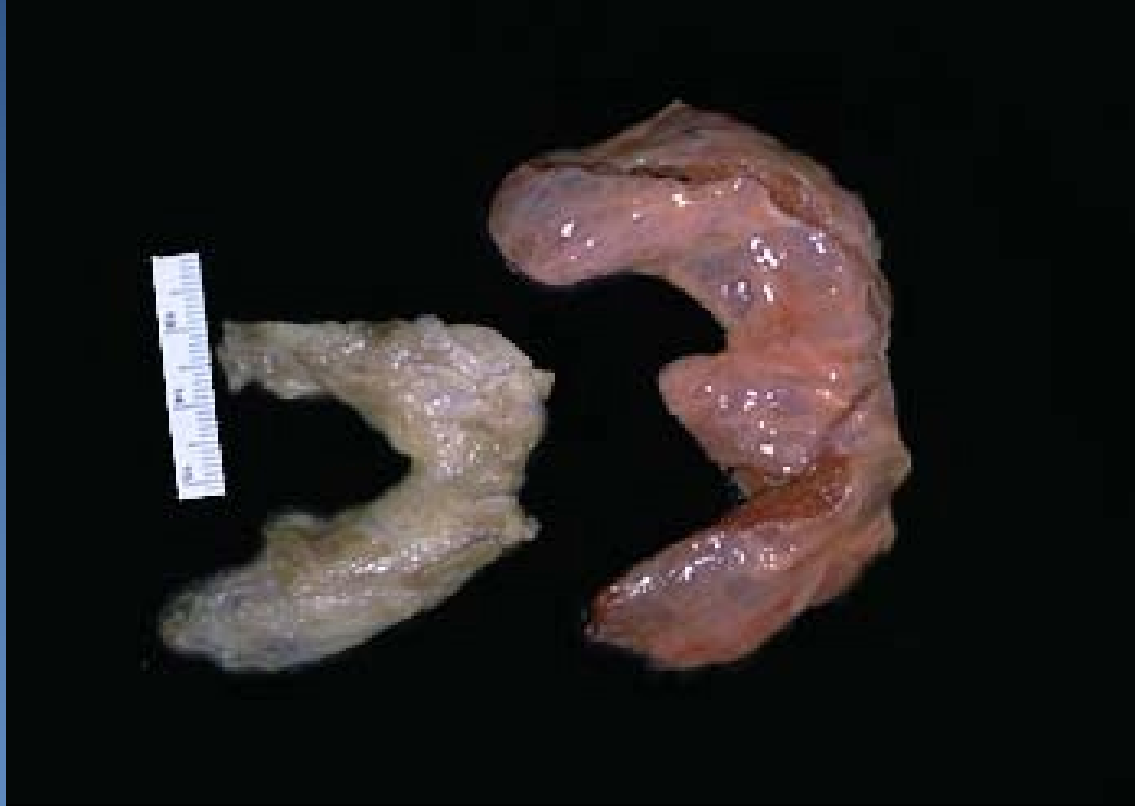
1. norm
2. diffuse hyperplasia
3. „hot“ nodule – usually adenoma
4. „ cold“ nodule - ca

# Thyroiditis

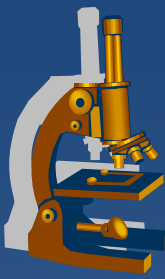


- × Acute inflammations uncommon
  - purulent bacterial (abscess), tbc*
- × Subacute granulomatous – giant cell thyroiditis (de Quervain's) ?viral
  - ⇒ *painful enlargement, micro mixed inflammatory infiltrate + giant cell reaction*
- × Chronic sclerosing t. (Riedel's)
  - ⇒ *dense fibrotisatin, diff. dg. x ca*

# *Chronic thyroiditis*



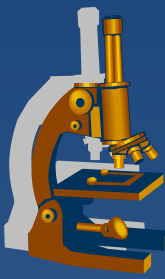
# Hashimoto's thyroiditis



- ✗ organ-specific autoimmune inflammation
- ✗ variable auto-antibodies
  - ⇒ *x peroxidase, thyroglobulin, etc.*
- ✗ early stage - enlargement + hyperfunction
- ✗ later hypofunction
- ✗ ↑ risk of other autoimmune diseases (DM, SLE,..)
- ✗ ↑ risk of malignancies
  - ⇒ *MALT lymphomas, papillary thyroid carcinoma*



# Hashimoto's thyroiditis



## × Gross:

⇒ *non-homogenous, firm, small paler foci*

## × Micro:

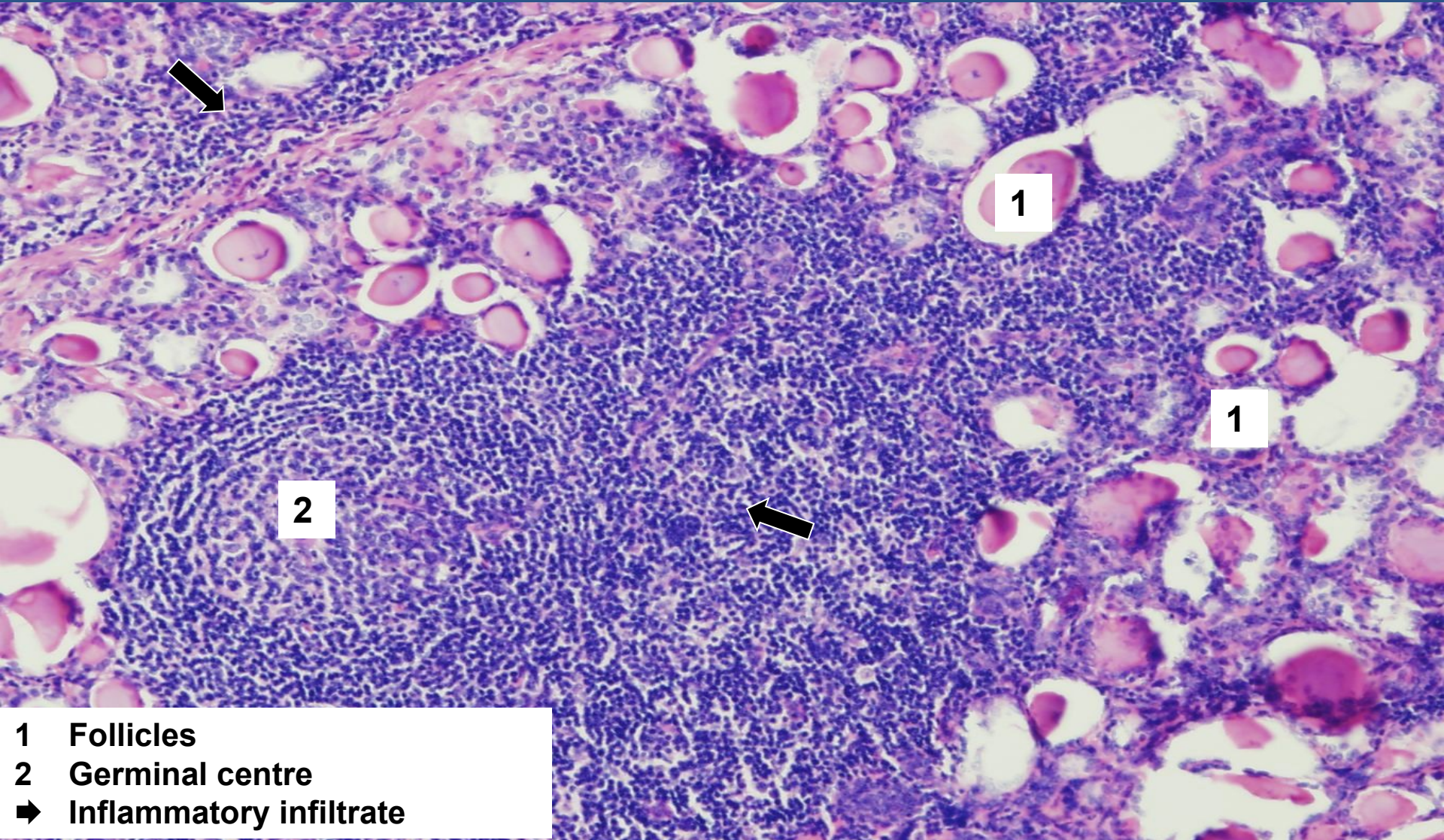
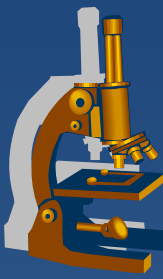
⇒ *dense lymphoplasmocellular infiltrate, incl. germinal centres*

⇒ *thyroid follicles atrophy, onkocytic transformation of follicular epithelium (Hürtle cells)*

- eosinophilic cytoplasm, enlarged nucleus, distinctive nucleolus

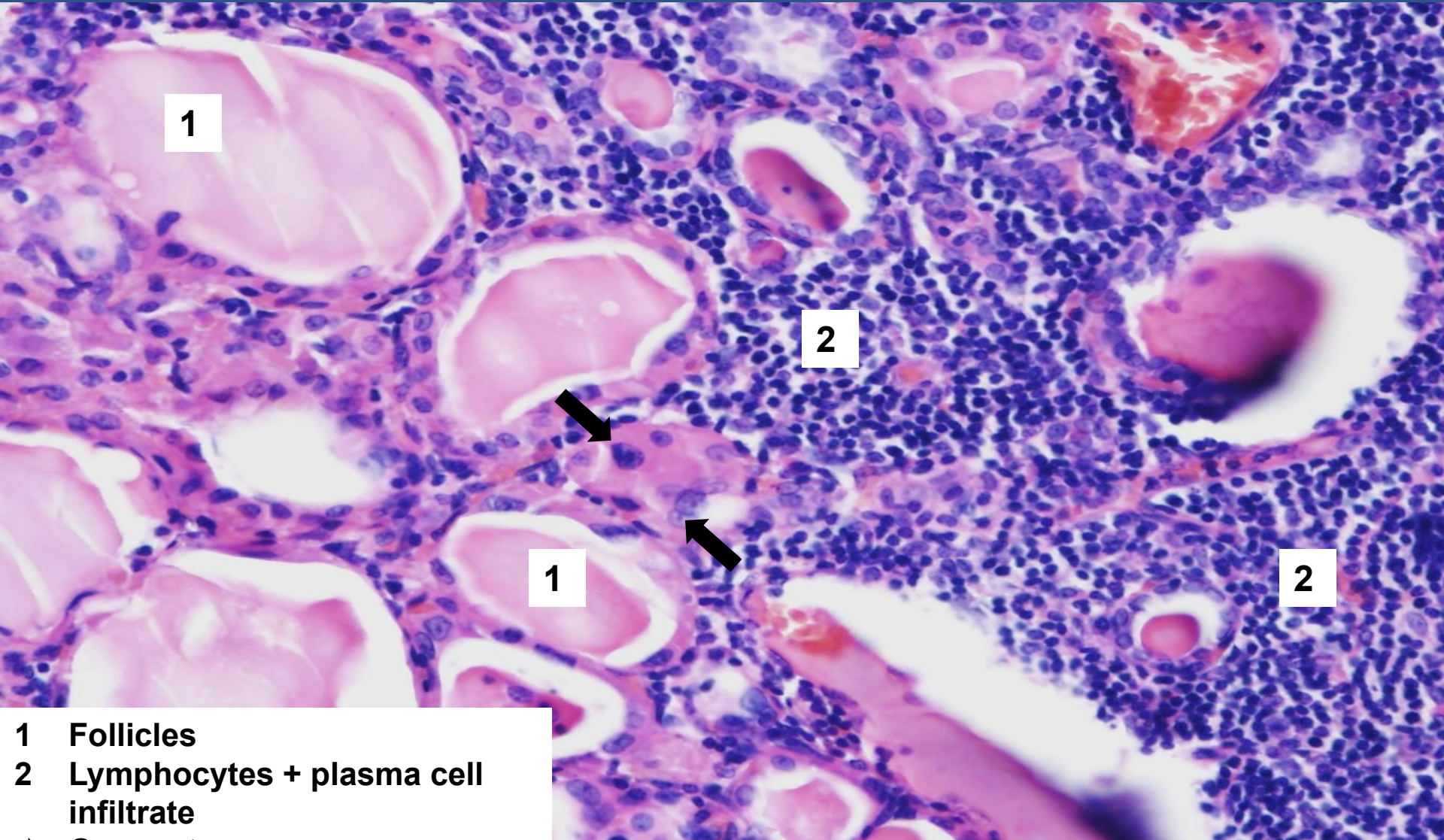
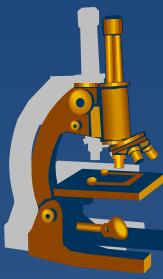
⇒ *variable grade of fibrosis*

# Hashimoto's thyroiditis



- 1 Follicles
- 2 Germinal centre
- ➡ Inflammatory infiltrate

# *Hashimoto's thyroiditis*



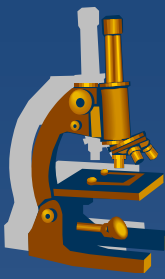
1

2

1

2

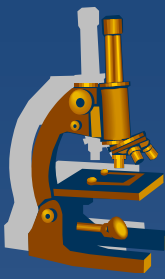
- 1 Follicles
- 2 Lymphocytes + plasma cell infiltrate



# ***Thyroid gland hyperplasia***

---

- x** Autoimmune Graves-Basedow disease
- x** Diffuse parenchymatous thyrotoxic goiter (> 60g)  
+ exophthalmos
- x** IgG auto-antibody to the TSH receptor – LATS  
(long-acting thyroid stimulator)
- x** Adenomatoid nodules
  - ⇒ *in the setting of nodular goiter, unencapsulated, diff. dg. x true adenoma may be difficult*



# ***Thyroid gland hyperplasia***

---

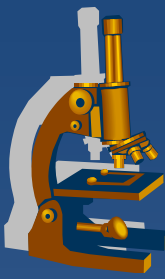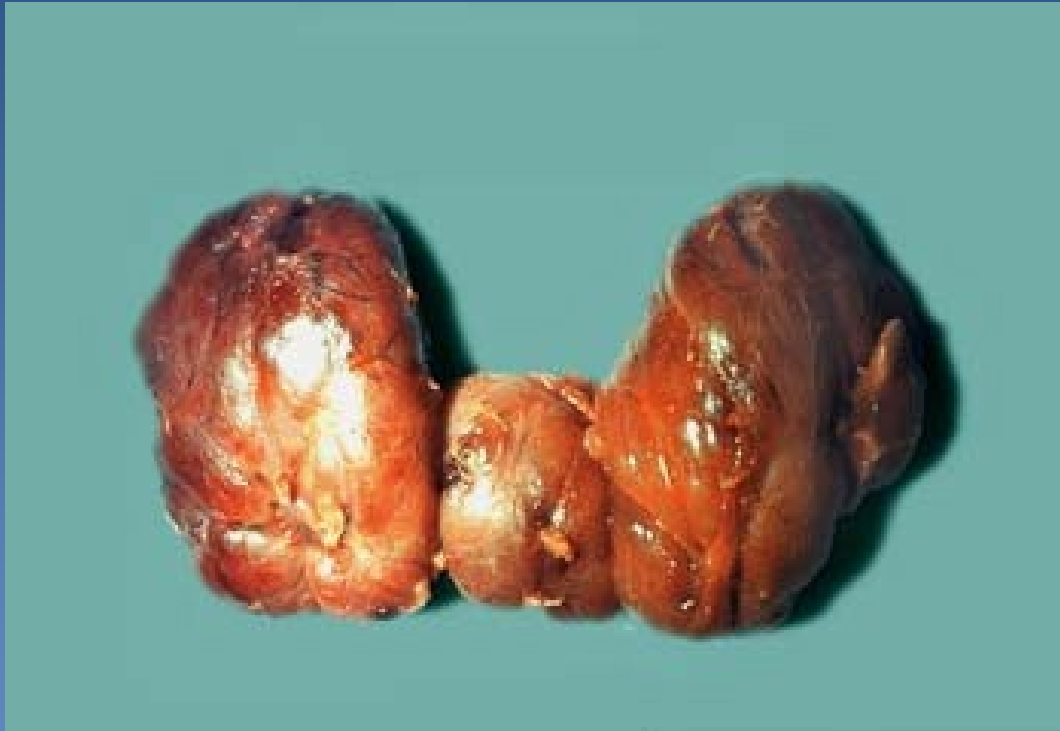
## **x Gross:**

⇒ *symmetric diffuse enlargement, red-brown, „fleshy“*

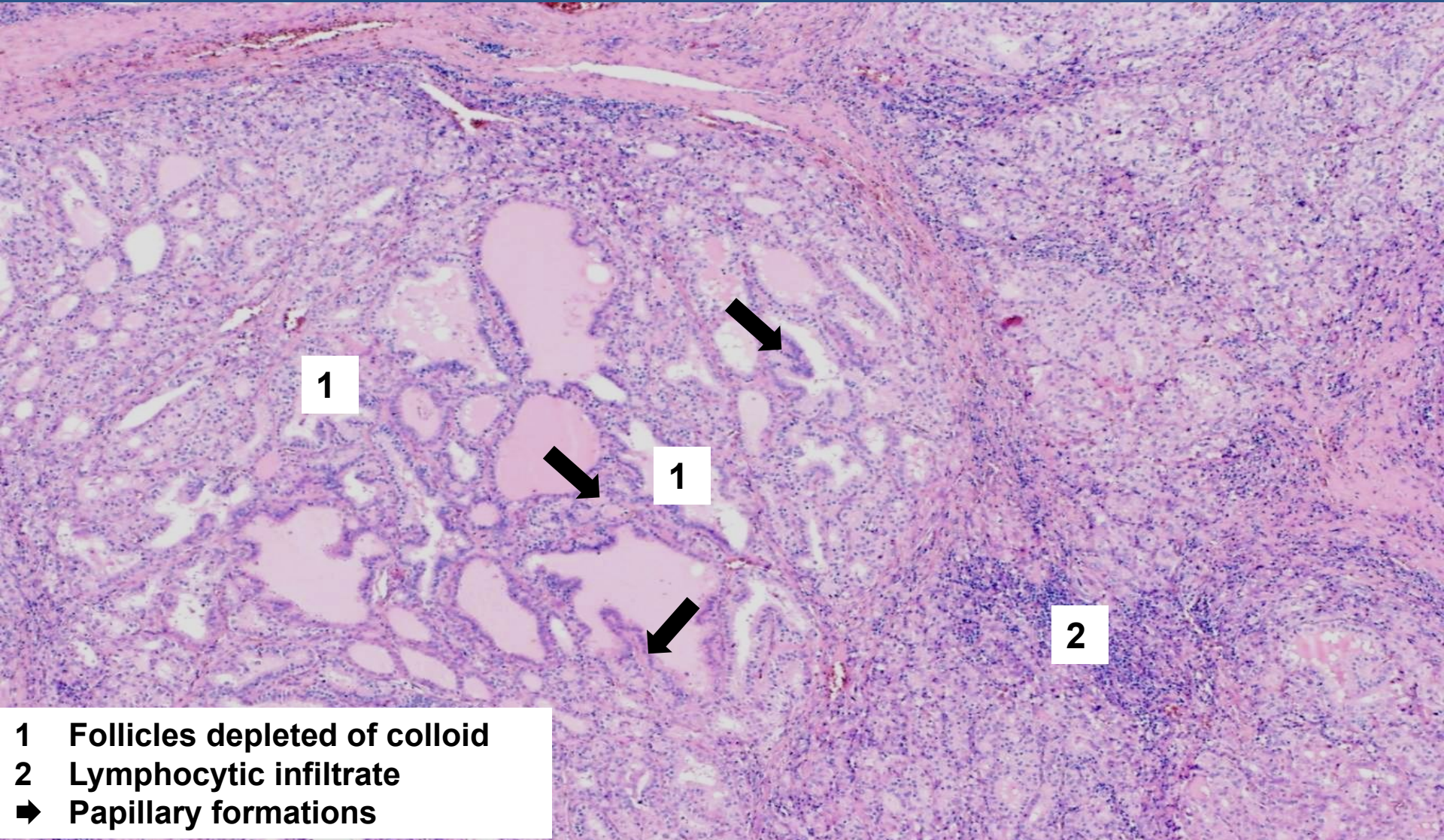
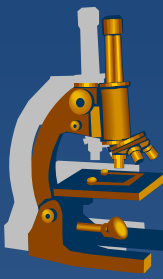
## **x Micro:**

⇒ *tall hyperplastic follicular cells, papillary formations, ↓ amount of colloid, numerous resorptive vacuoles, focal lymphocytic infiltration*

# *Thyroid hyperplasia*



# *Thyroid hyperplasia*



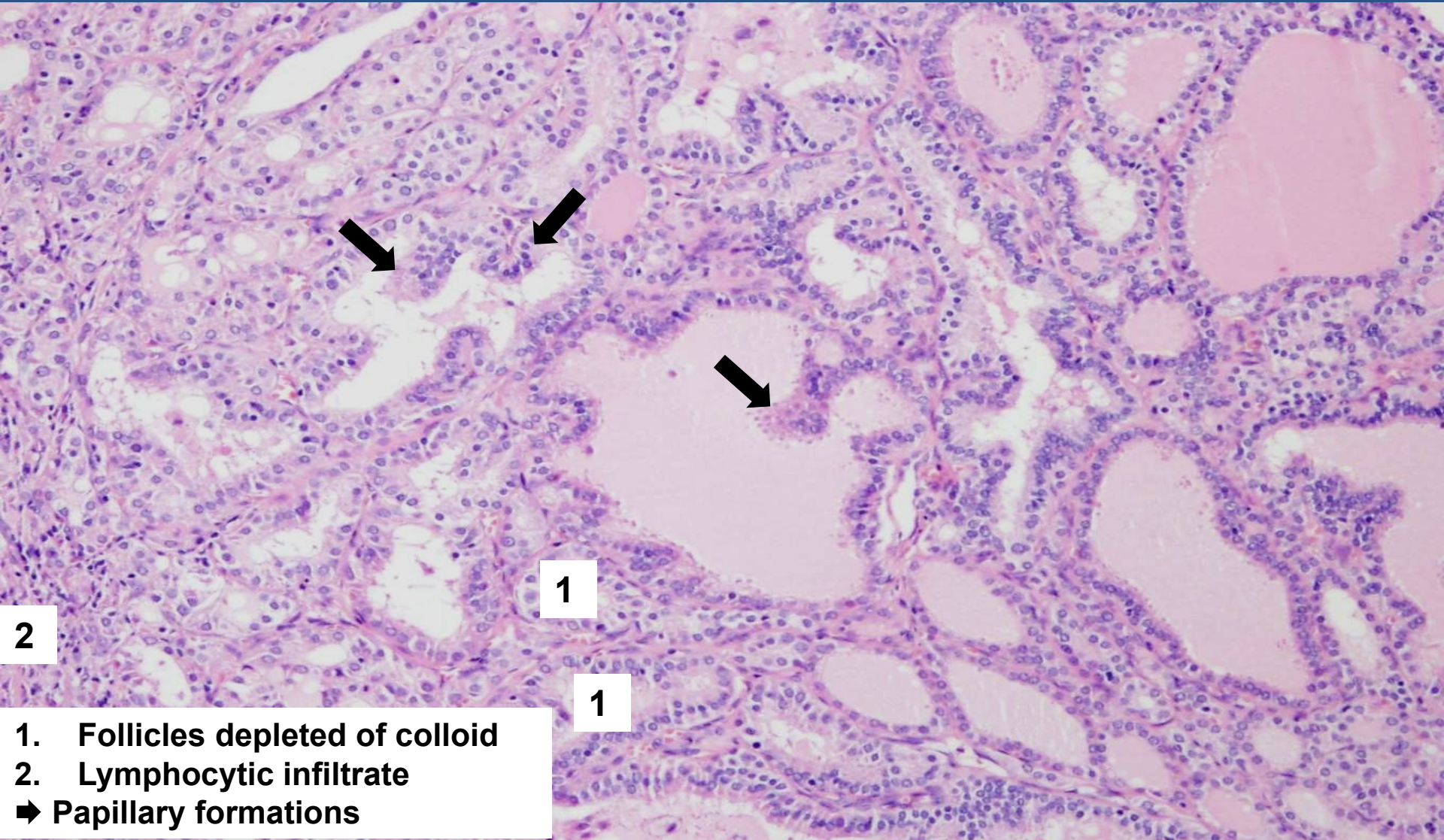
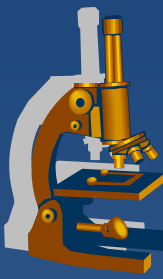
1

1

2

- 1 Follicles depleted of colloid
- 2 Lymphocytic infiltrate
- ➔ Papillary formations

# *Thyroid hyperplasia*



1

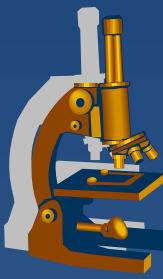
1

2

- 1. Follicles depleted of colloid
  - 2. Lymphocytic infiltrate
- ➔ Papillary formations

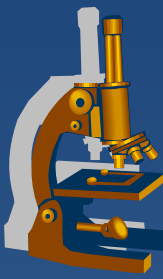


# *Nontoxic goitre*



- ✘ Iodine deficiency, goitrogens etc. → impaired synthesis of thyroid hormones → activation of hypothalamus-pituitary-thyroidal axis - ↑TSH
- ✘ Irregular activation, hyperplastic phase, colloid involution, reactive and regressive changes
- ✘ Nodular transformation – multinodular goitre
- ✘ Mostly euthyroid or low-level of hypothyroidism

# *Multinodular goitre*



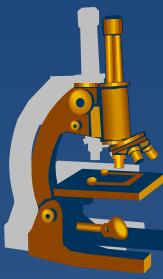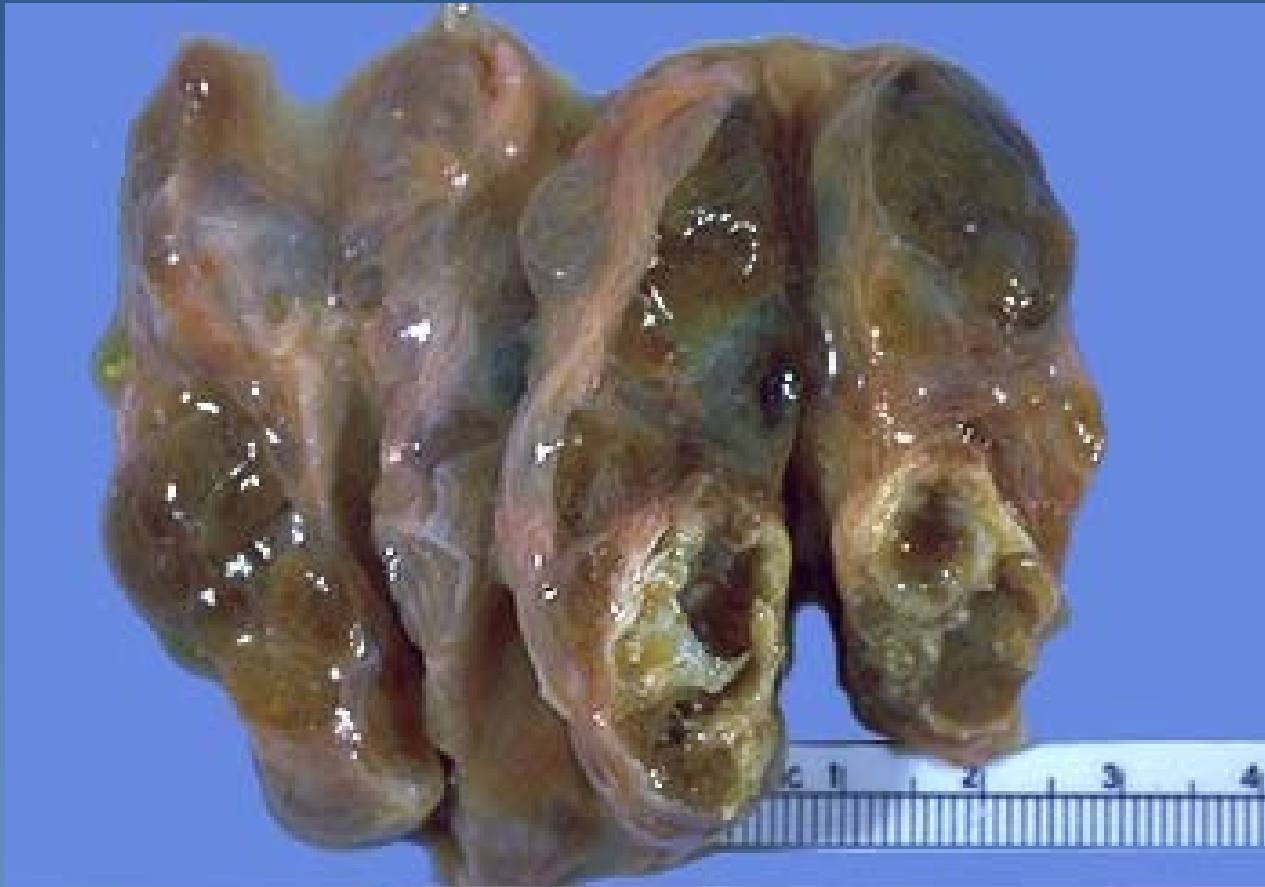
## *x Gross:*

- ⇒ irregular nodules, granular, yellow-brown (colloid goitre)*
- ⇒ common regressive changes – haemorrhage, cysts, fibrosis, calcification*

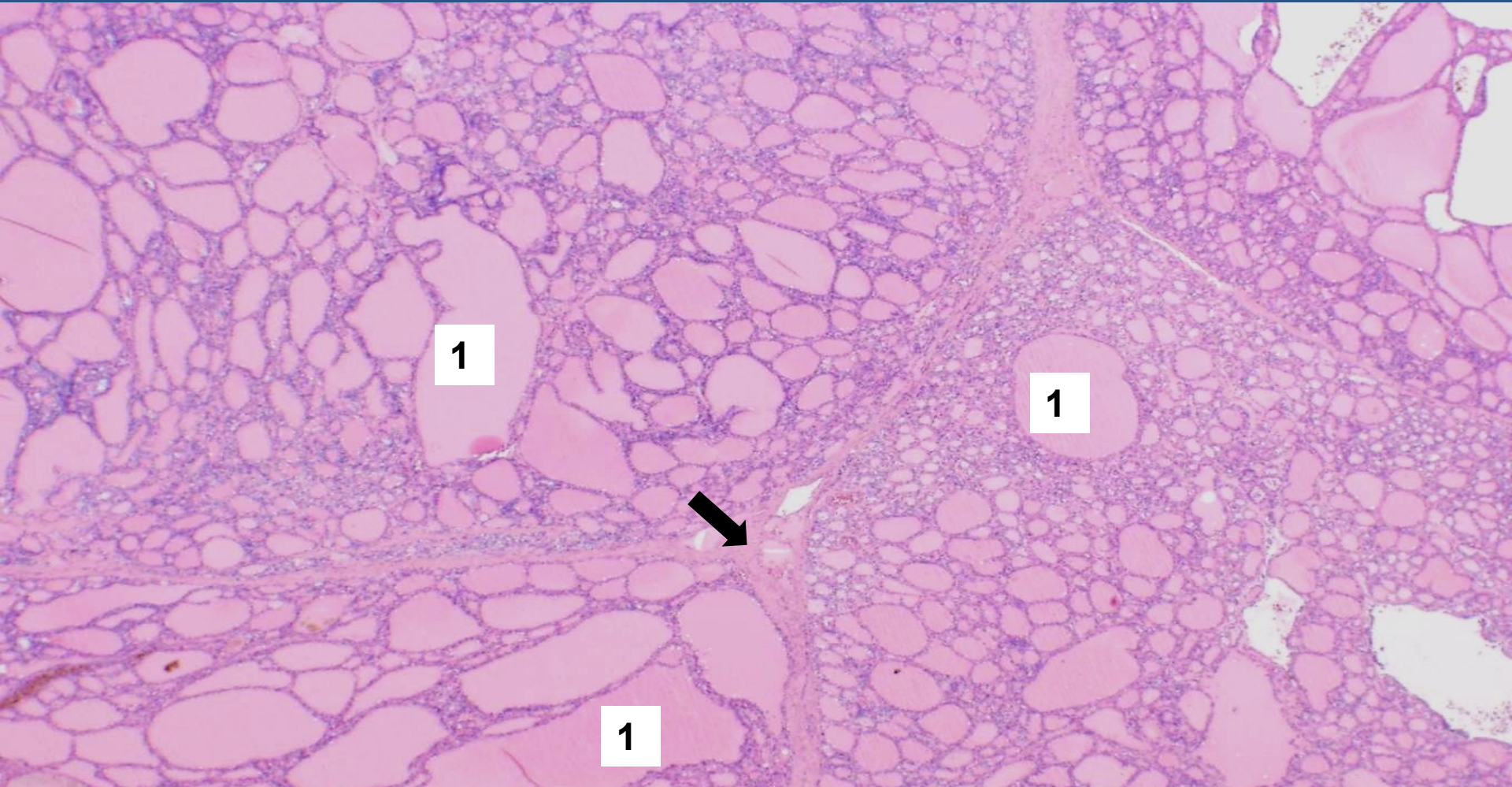
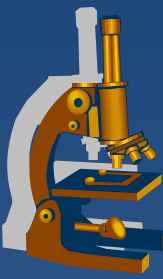
## *x Micro:*

- ⇒ dilated follicles filled with colloid, sparse resorptive vacuoles, flat epithelial cells*

# *Multinodular goitre*

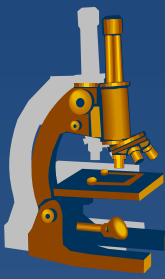


# *Multinodular goitre*



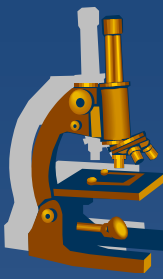
**1** Follicles  
**➡** Fibrous septa

# *Thyroid tumors*



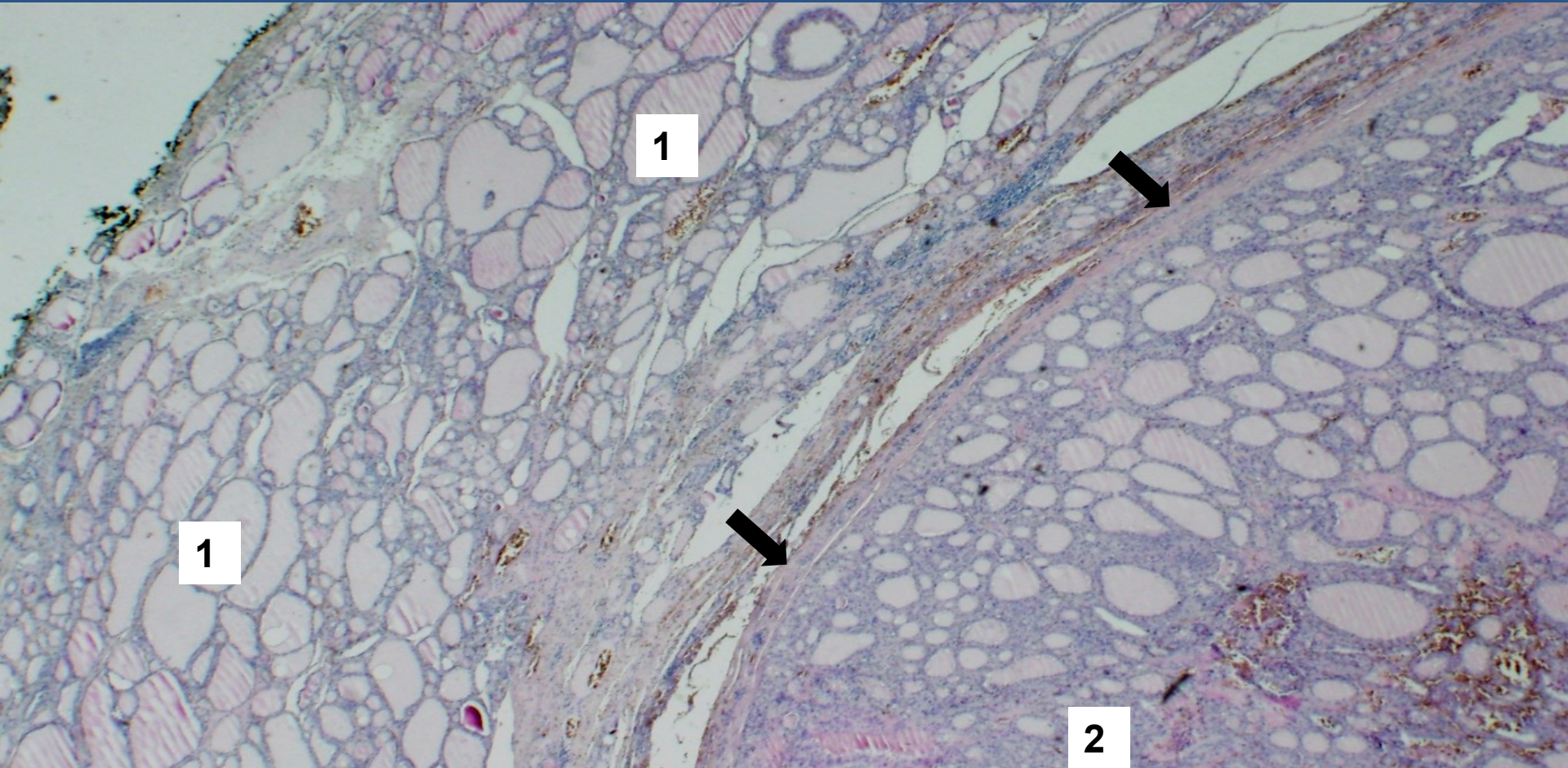
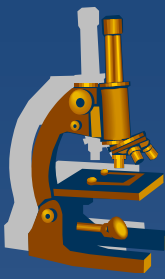
- × Adenomas with variable structure
  - ⇒ *follicular, oncocytic, etc.*
- × Carcinomas
  - ⇒ *papillary, follicular, medullary – parafollicular C-cells, anaplastic*
- × Malignant lymphomas, secondary tu, etc.

# *Follicular adenoma*



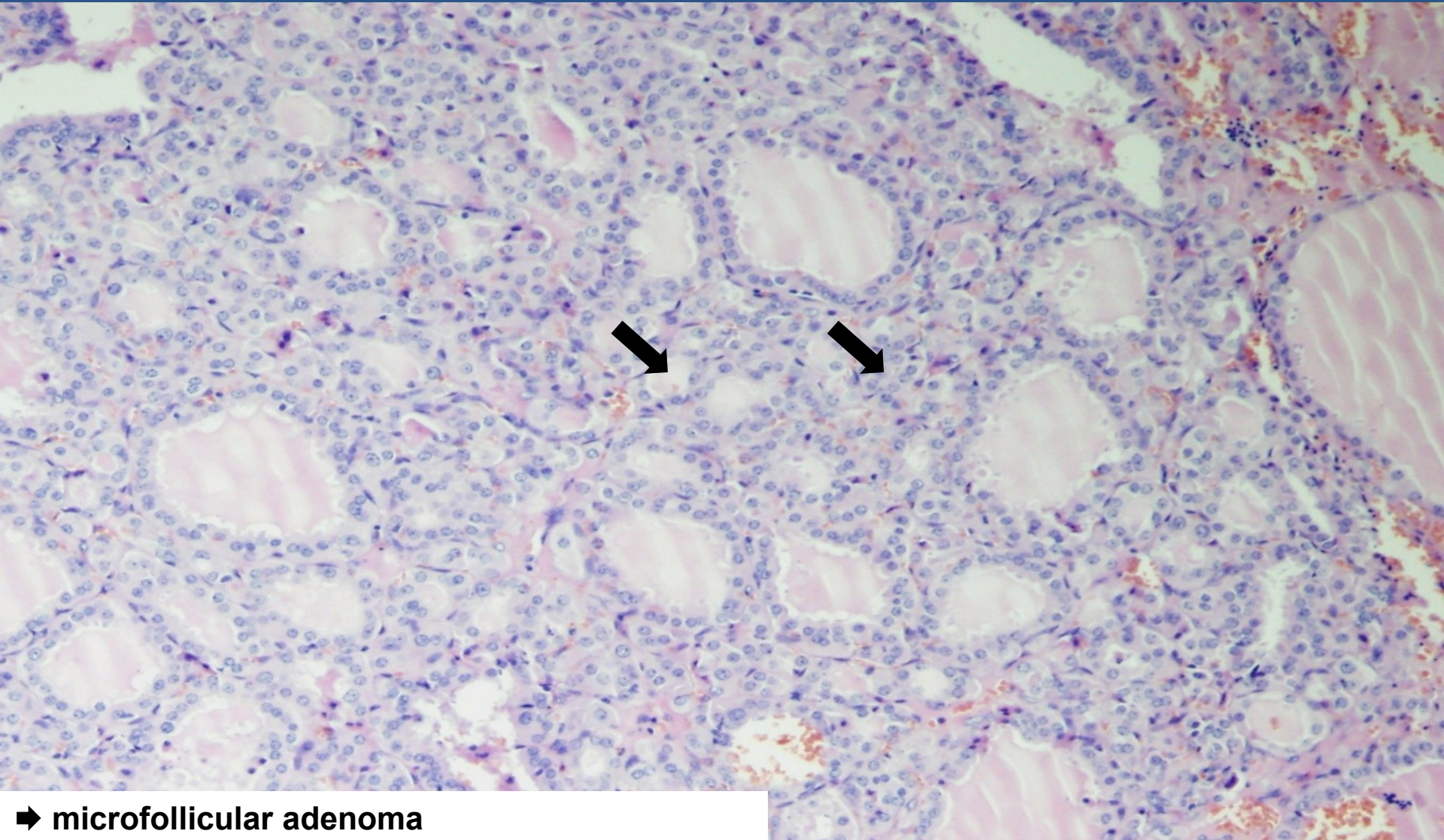
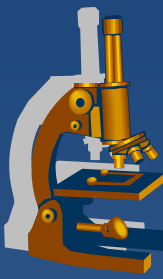
- ✗ Mostly solitary
- ✗ Encapsulated
- ✗ Pressure atrophy of adjacent parenchyma
- ✗ Diff. dg. ✗ follicular carcinoma
  - ⇒ *similar histologic structure, transcapsular invasion into surrounding thyroid tissue and/or angioinvasion necessary for ca diagnosis*
- ✗ Diagnosis possible only with complete biopsy
- ✗ Cytology – well differentiated follicular neoplasia

# *Follicular adenoma*



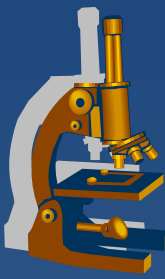
- 1 Thyroid parenchyma with follicles
- 2 Adenoma
- ➔ Fibrotic capsule (adenoma demarcation)

# *Follicular adenoma*



➡ microfollicular adenoma



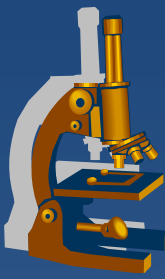


# *Papillary adenocarcinoma*

---

- ✗ Most common thyroid malignancy
- ✗ F 25-50 yrs, M less common, possible in children, adolescent
- ✗ ↑ incidence (better diagnostics)
- ✗ Solitary / multifocal
- ✗ Subtypes according histological structure
  - ⇒ *papillary, follicular, diffuse sclerosing, etc.*
- ✗ Diagnosis based on cytologic morphology

# *Papillary adenocarcinoma*



## **x** Gross:

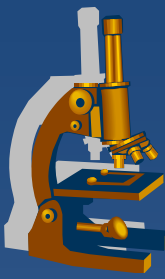
⇒ *pale focus*

## **x** Micro:

⇒ *ground-glass nuclei*

- clear nuclei, grooved nuclei, excentric nucleolus („Orphan Annie“), nuclear superposition

⇒ *papillary formations with disp. microcalcification*

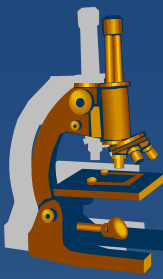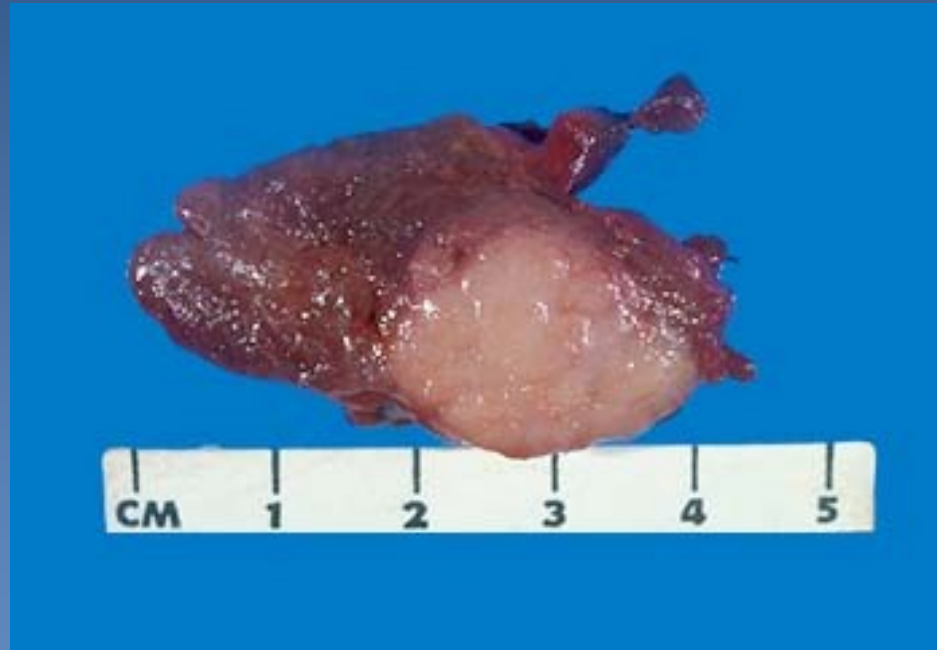


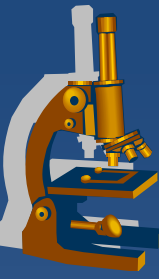
# *Papillary adenocarcinoma*

---

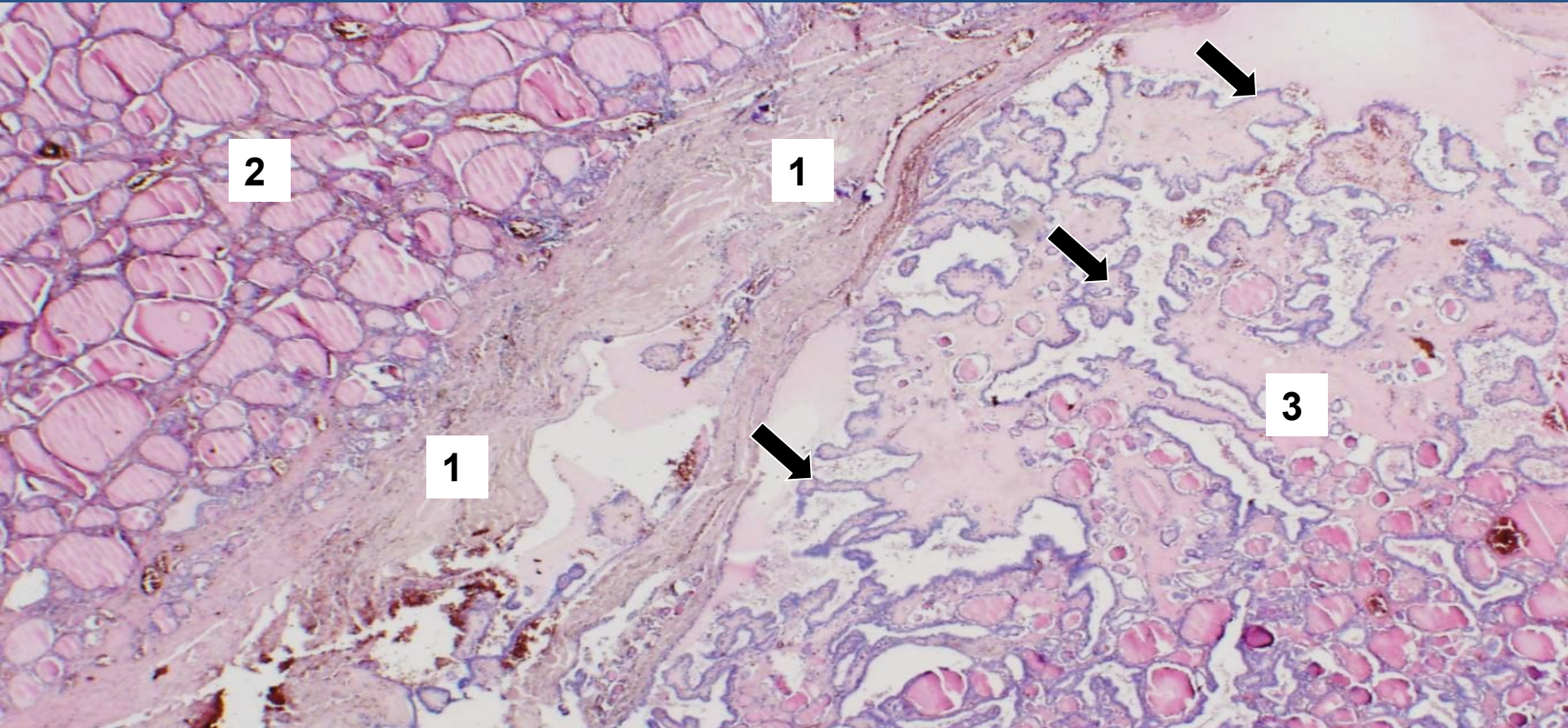
- ✘ Microcarcinoma
  - ⇒ *incidental finding, < 1 cm, very good prognosis*
- ✘ Worse prognosis in males, older people, ca with extrathyroidal extension
- ✘ Metastases into regional LN, lungs

# *Papillary adenocarcinoma*

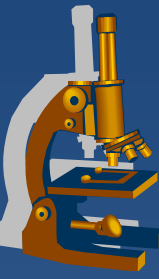




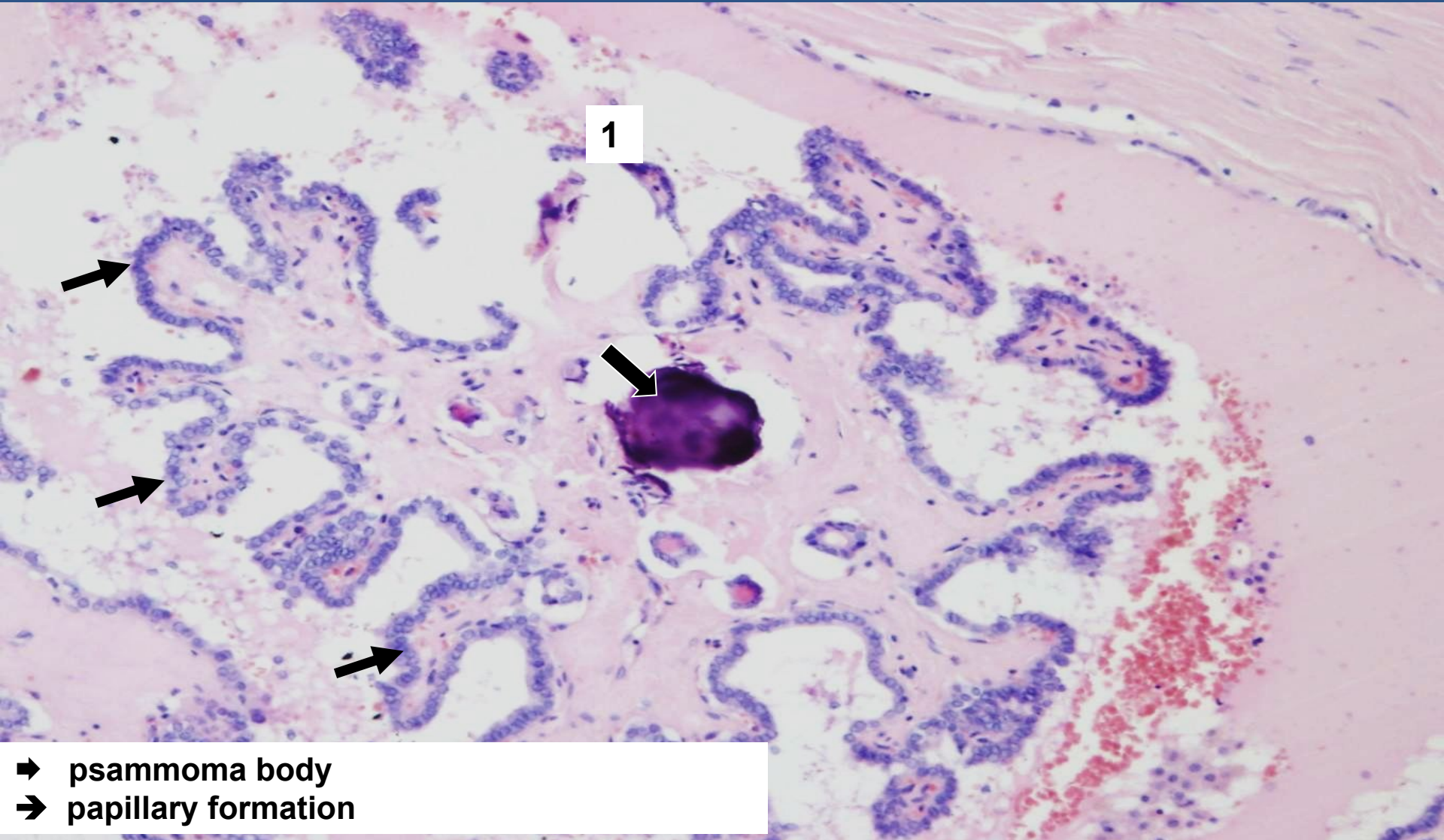
# *Papillary adenocarcinoma*



- 1 fibrotic capsule
- 2 normal thyroid parenchyma
- 3 adenocarcinoma
- ➔ papillary formations

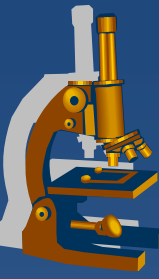


# *Papillary adenocarcinoma*

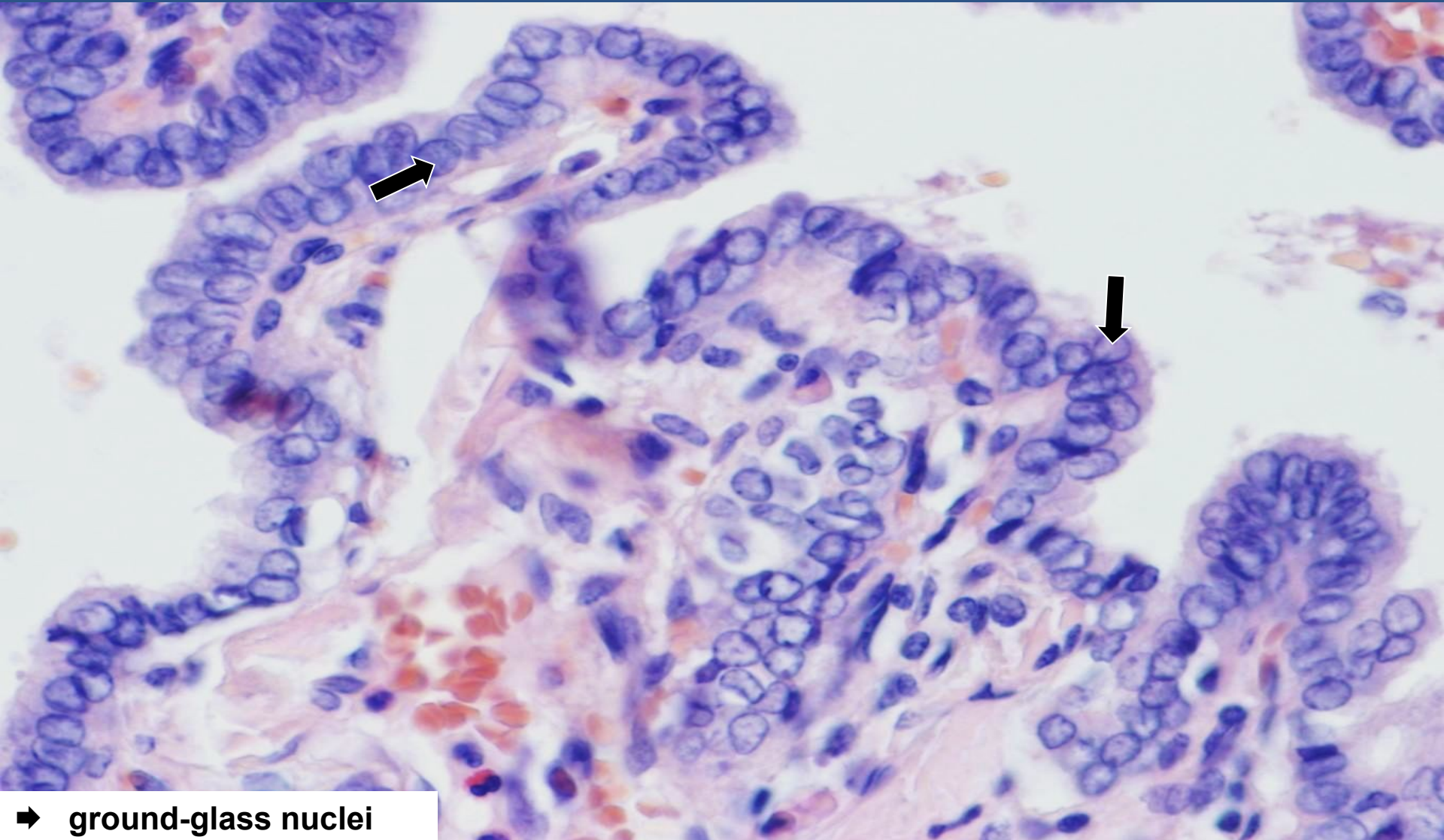


1

- ➔ psammoma body
- ➔ papillary formation

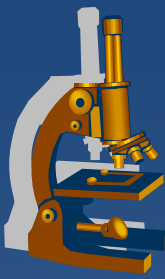


# *Papillary adenocarcinoma*



➔ ground-glass nuclei

# *Pathology of adrenals*



## **x** Adrenal medulla pathology

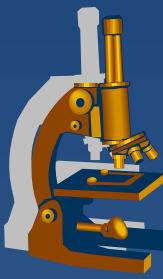
⇒ *Hyperplasia ( MEN sy)*

⇒ *Tumors*

- Neuroblastoma
- Ganglioneuroma
- Pheochromocytoma

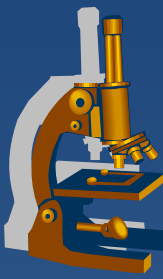


# *Pheochromocytoma*



- ✘ Chromaffin cells of adrenal medulla (paraganglioma), extraadrenal site possible
- ✘ Catecholamines synthesis
- ✘ Hypertension (incl. paroxysmal), tachycardia, sweating, tremor, headache
- ✘ Risk of brain haemorrhage
- ✘ More common 4.-5. decade, possible in children
- ✘ 90% benign behaviour

# Pheochromocytoma



## × Gross:

⇒ *demarcated paler lesion of variable size (g-kg), possible regressive changes (haemorrhage, necrosis)*

## × Micro:

⇒ *fine capillarized stroma*

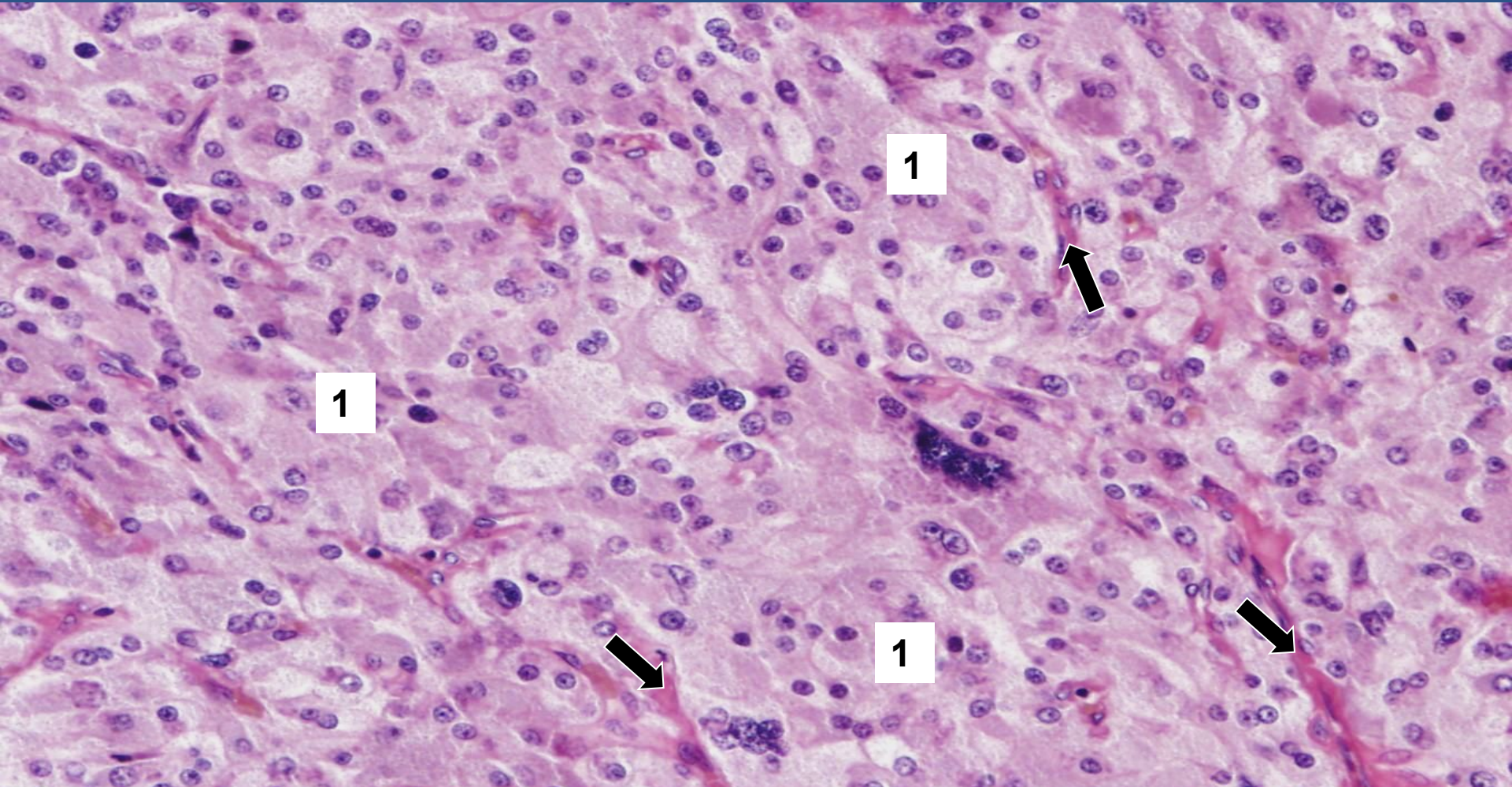
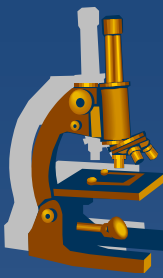
⇒ *trabeculae, solid alveoli*

⇒ *large cells, granulated cytoplasm, neurosecretory granules*

⇒ *nuclear atypias are not a sign of malignancy*

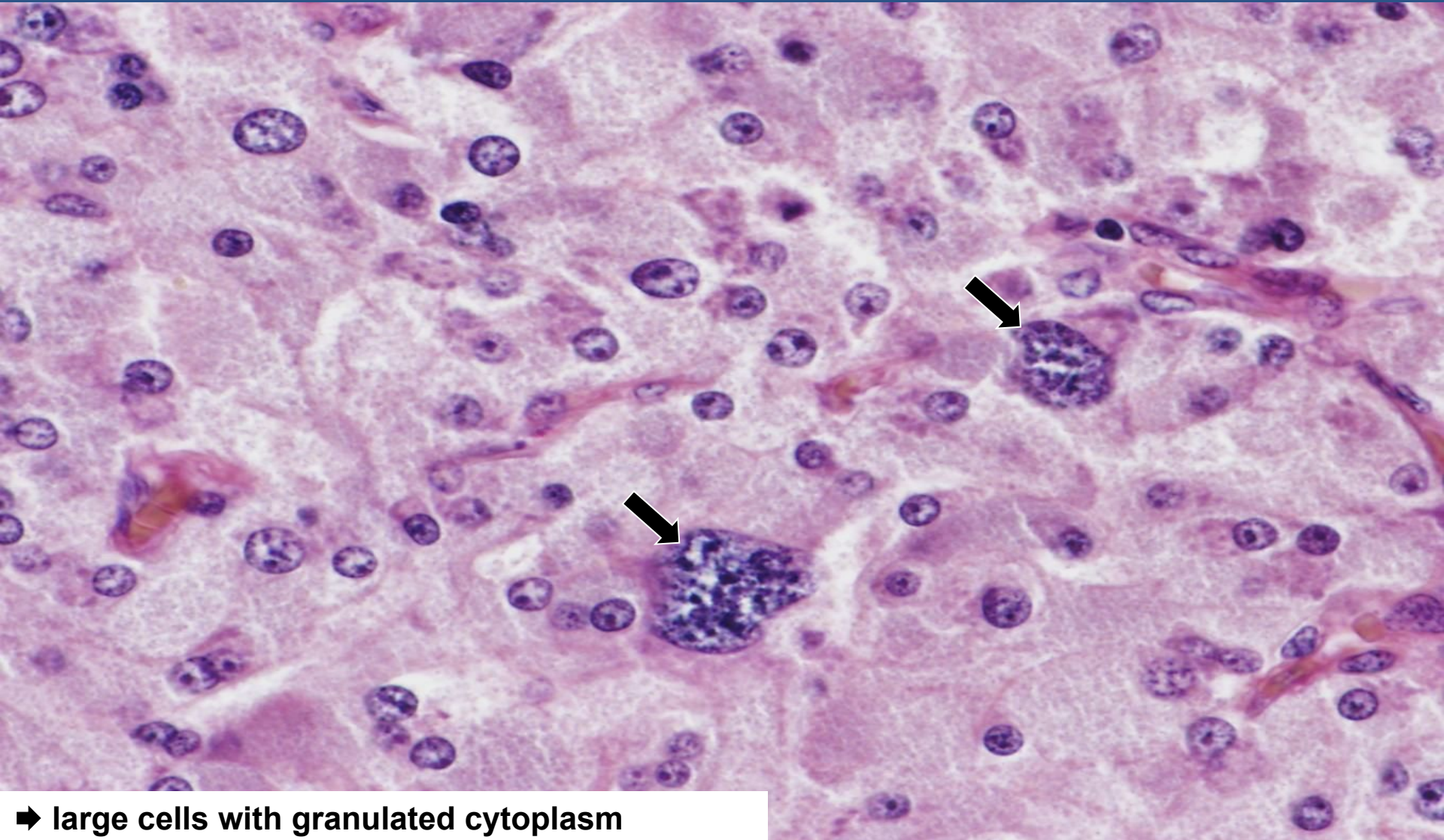
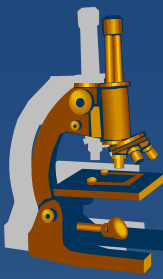
× Definitive diagnosis of malignancy based exclusively on finding of metastases

# *Pheochromocytoma*



**1** solid alveoli  
**➔** capillarized stroma

# *Pheochromocytoma*



➔ large cells with granulated cytoplasm