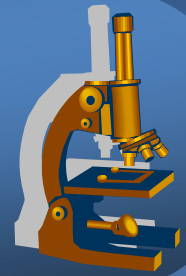


***8th special
pathology practice***



Bones

Soft tissue

Skin



BONES

Osteomyelitis



- × purulent – tendency to chronicity

 - ⇒ *staphylococcus, E. coli, Klebsiella, salmonella, gonococcus, ...*

- × entry of infection:

 - ⇒ *hematogenous (bacteriemia, sepsis)*

 - ⇒ *from adjacent tissues (ORL, teeth)*

 - ⇒ *direct implantation (orthopedic surgery, trauma)*

- × difficult healing

 - ⇒ *slow diffusion of ATB into bones... surgical drainage necessary*

- × complications

 - ⇒ *pathological fracture, sepsis, purulent arthritis*

Osteomyelitis



× acute stage:

- × flegmonous intertrabecular inflammation, necrosis
- × subperiosteal abscess → bone ischemia, skin draining sinus possible

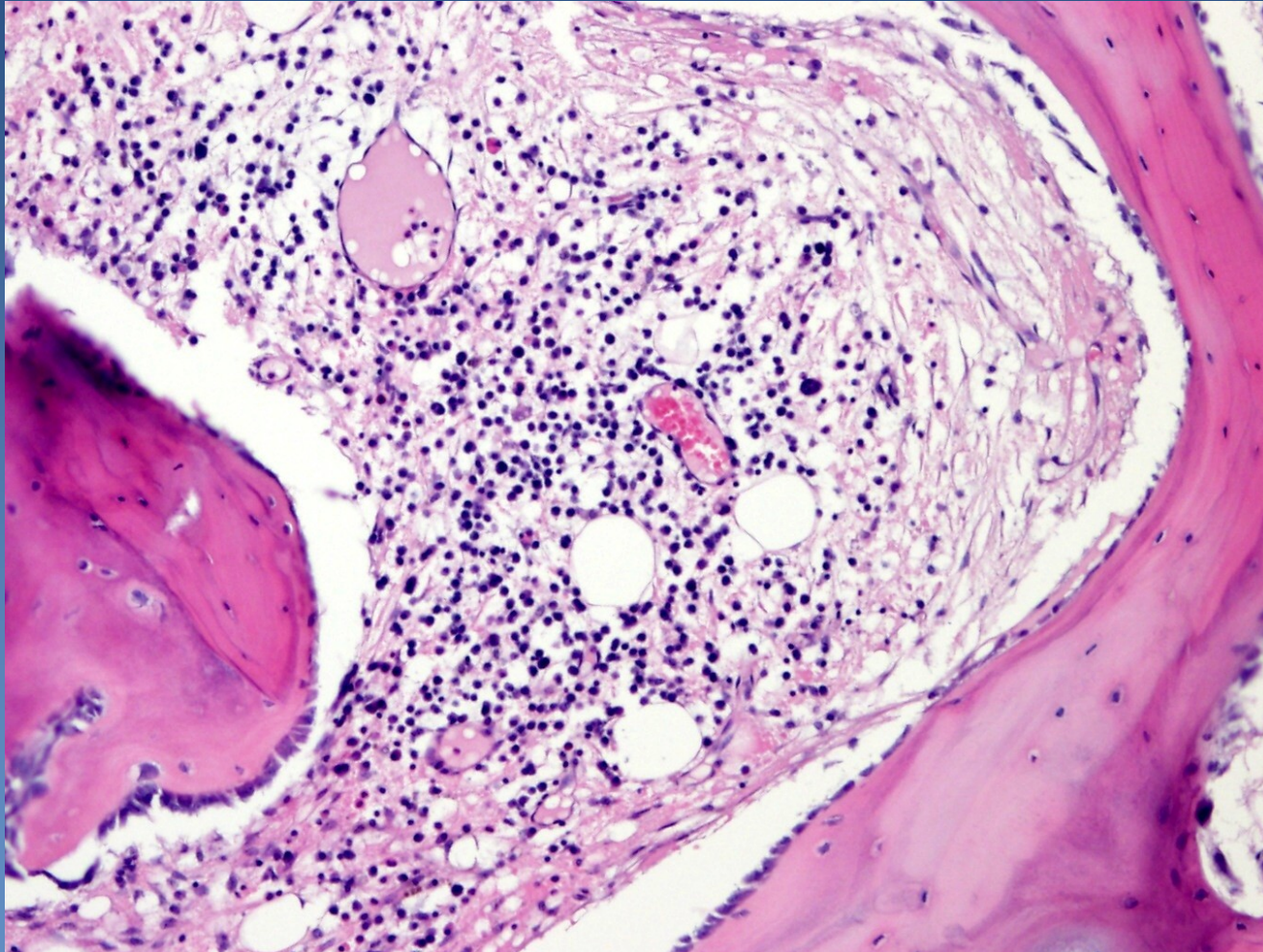
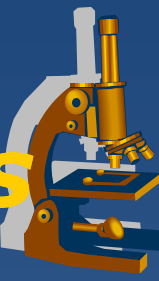× subacute and chronic stage:

⇒ *separation of necrotic parts of the bone as sequestrum*

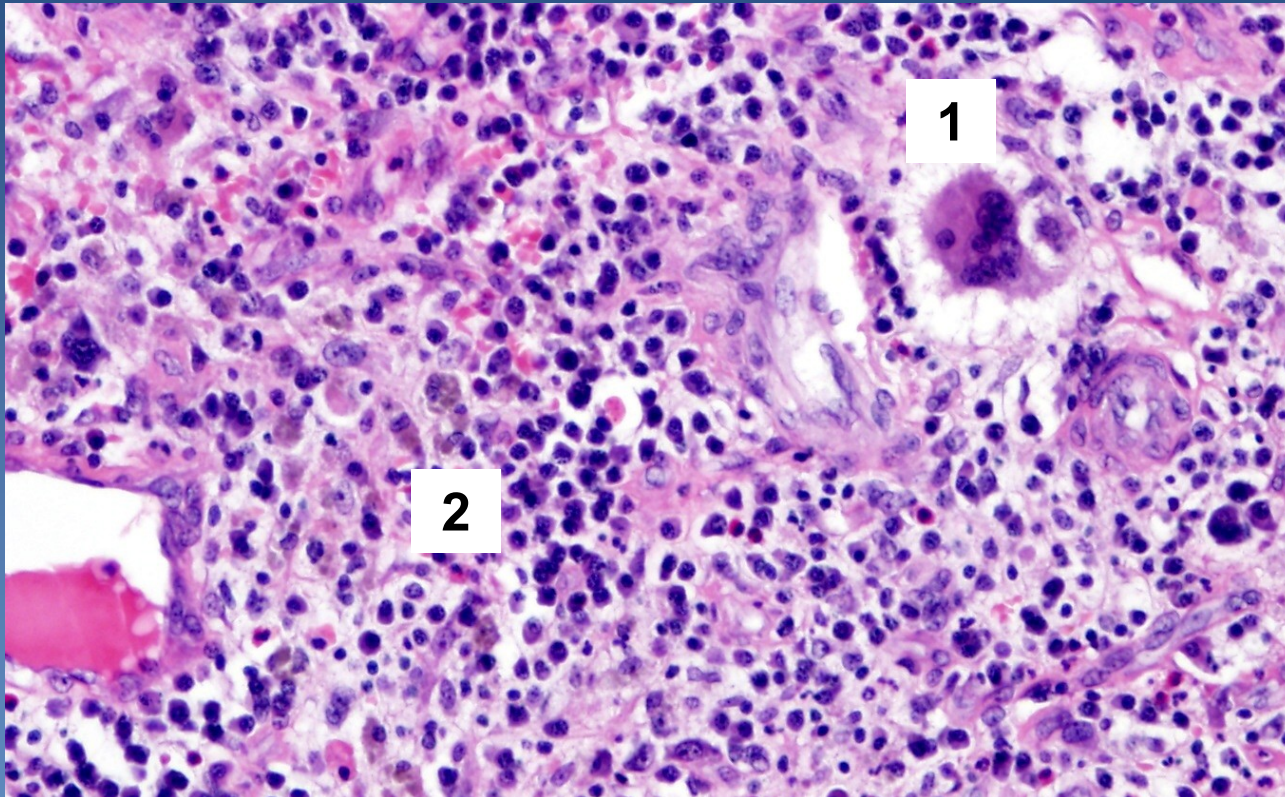
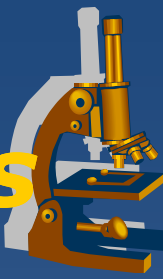
- free foreign bodies eliminated through sinus
- sequestrum may be surrounded by reactive new bone growth – involucrum, persistent infection

× ***tbc ostitis***: immunosuppressed, endemic regions; spine,

Chronic purulent osteomyelitis



Chronic purulent osteomyelitis



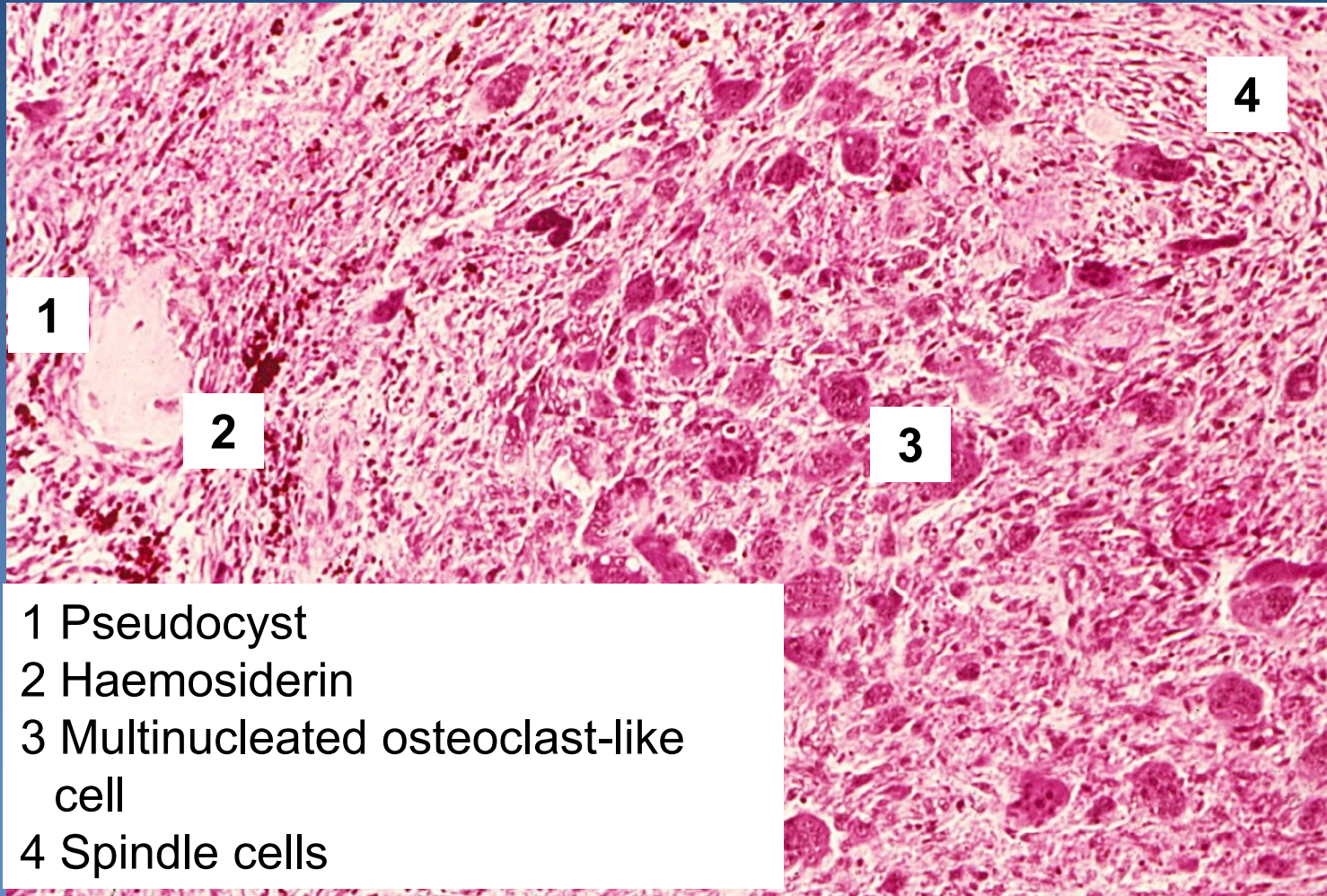
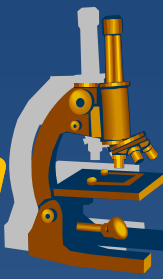
- 1 Osteoclast**
- 2 Inflammatory infiltrate (mainly plasma cells, neutrophils)**

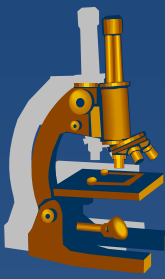
Osteitis fibrosa cystica



- ✗ von Recklinghausen`s disease, now rare
- ✗ primary or secondary hyperparathyreoidism →
↑osteoclastic bone resorption→ pathological fractures, „brown tumor“
- ✗ stage:
 - ⇒ *osteoclastic resorption*
 - ⇒ *fibrous phase*
 - ⇒ *cystic phase* – *pseudocysts due to resorbed haematomas*

Brown tumor – osteitis fibrosa cystica





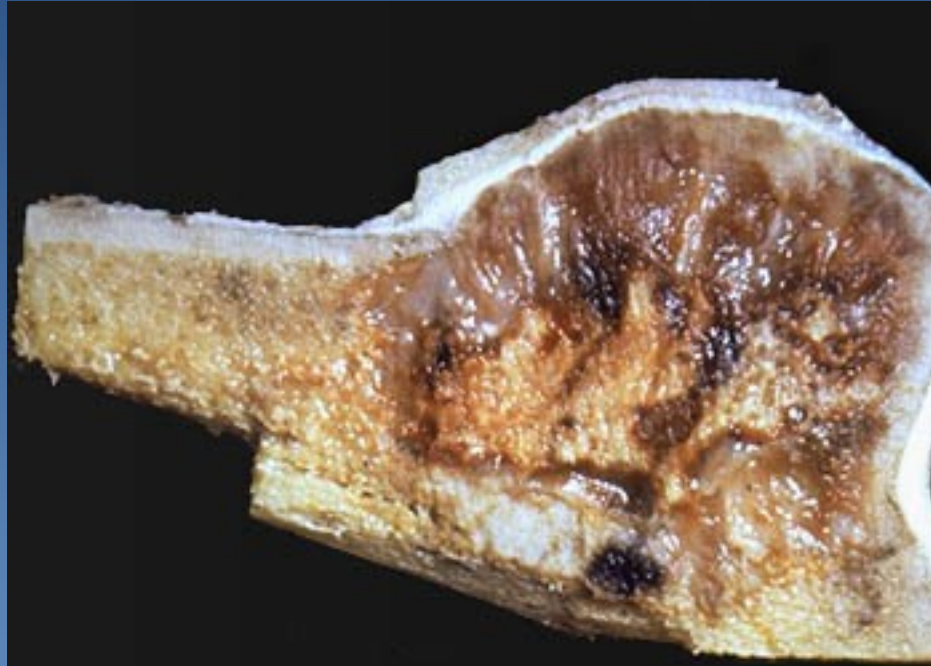
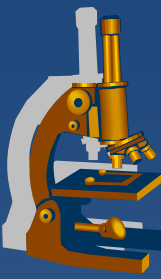
Selected BONE TUMORS



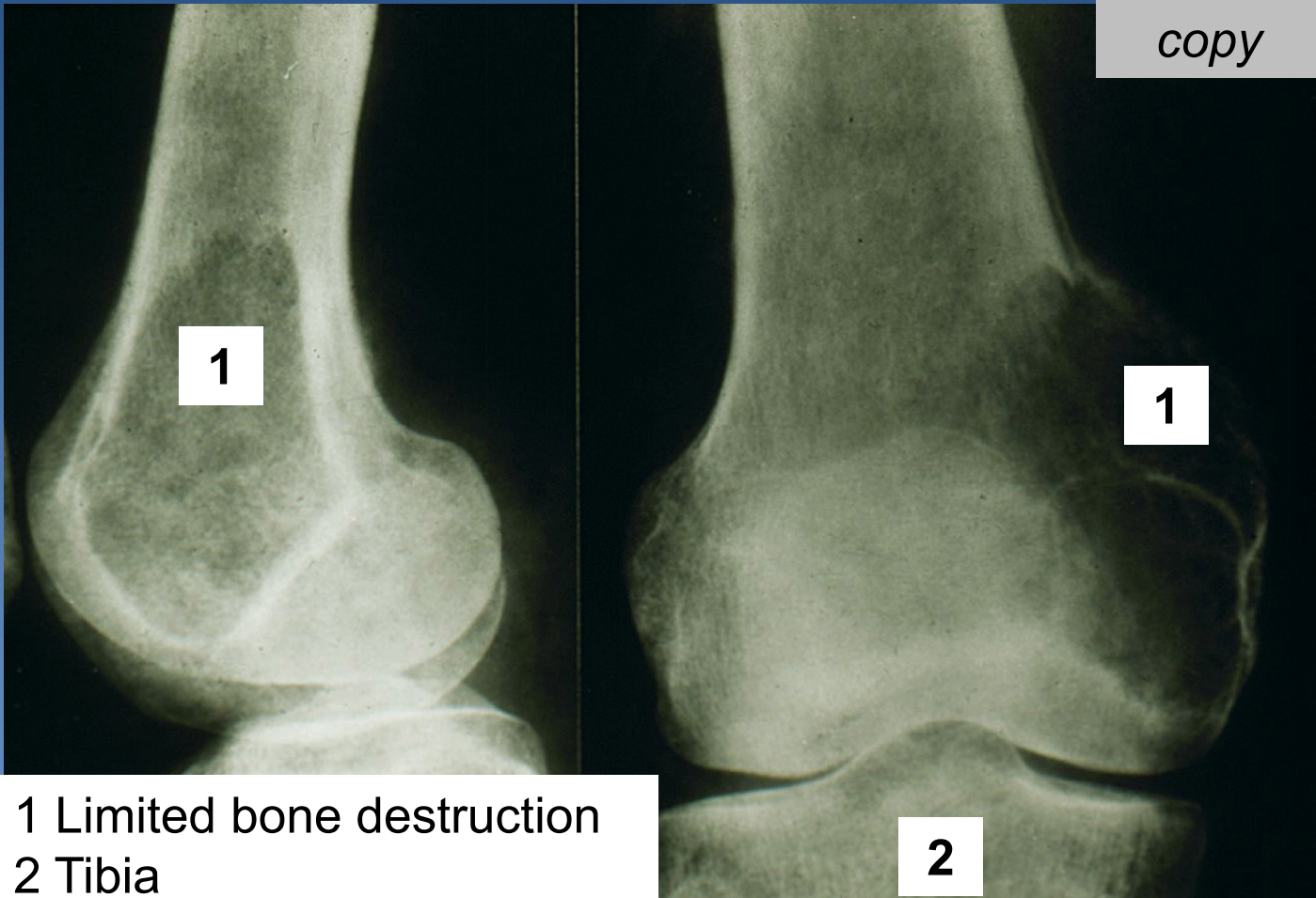
Giant-cell tumor of the bone

- x histogenesis (?? undifferentiated mesenchymal cells, marrow stromal cell)**
- x characteristic X-ray, localization**
 - ⇒ poorly demarcated bone destructive (osteolytic) lesion in the meta- or epiphysis of a long bone at the age of 20-40.*
- x Gross:**
 - ⇒ soft brown-red tumor, often with central hemorrhage*
 - ⇒ locally destructive growth, metastases in 10% (lungs)*

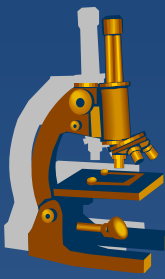
Giant cell bone tumor



Giant-cell tumor of the bone femur



1 Limited bone destruction
2 Tibia



Giant-cell tumor of the bone

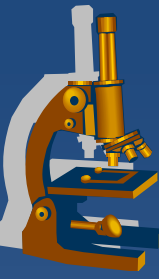
x micro:

⇒ *2 cell types:*

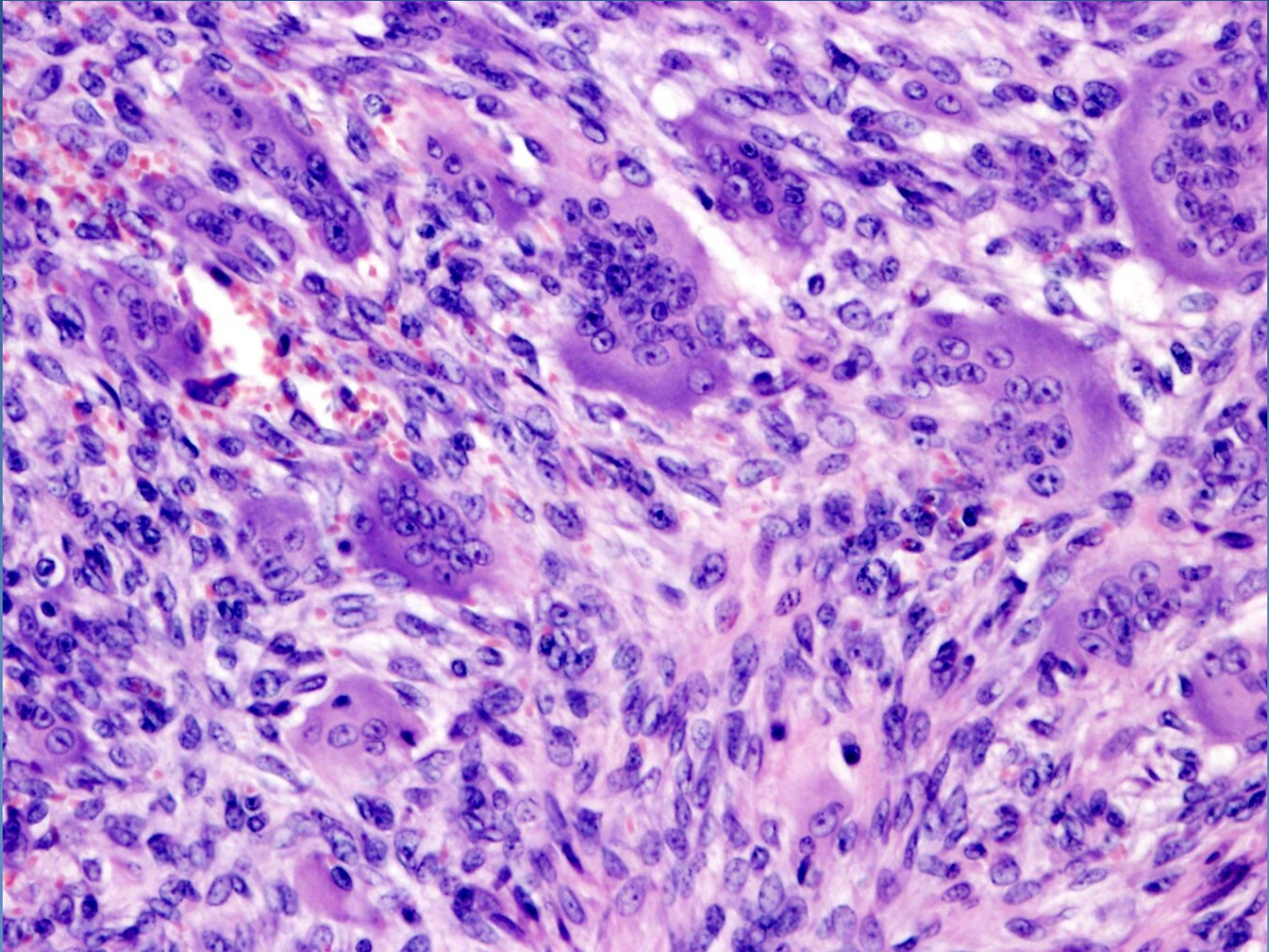
- uniform population of **mononuclear cells** - proliferating.
- **giant multinucleated cells** – osteoclast-like (100 nuclei)

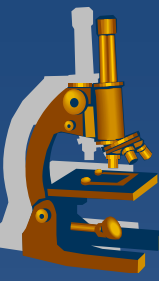
⇒ *often hemorrhage, fibrosis and necrosis*

- diff.dg.: „brown tumor“ in osteitis fibrosa cystica

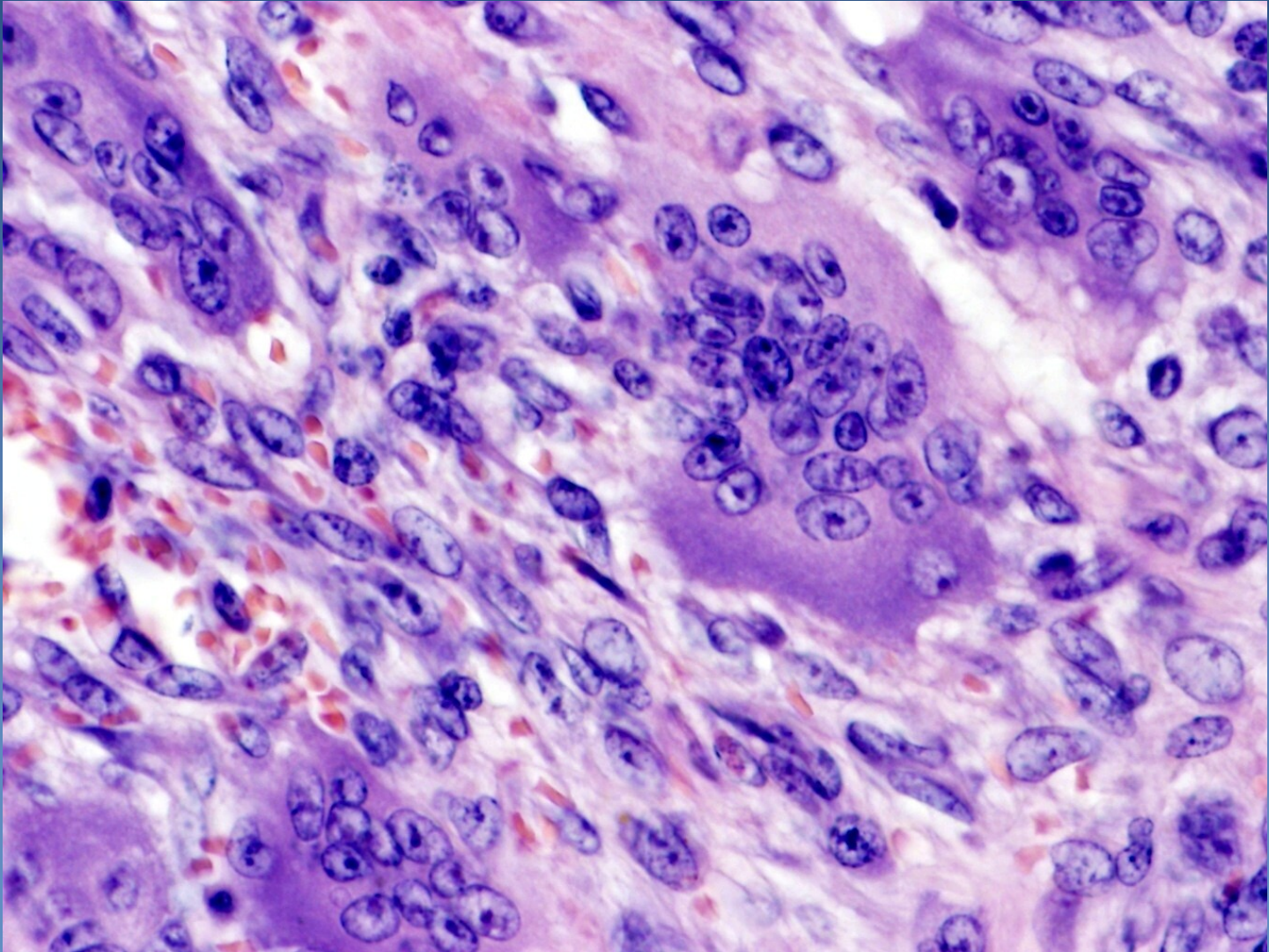


Giant-cell tumor of the bone





Giant-cell tumor of the bone

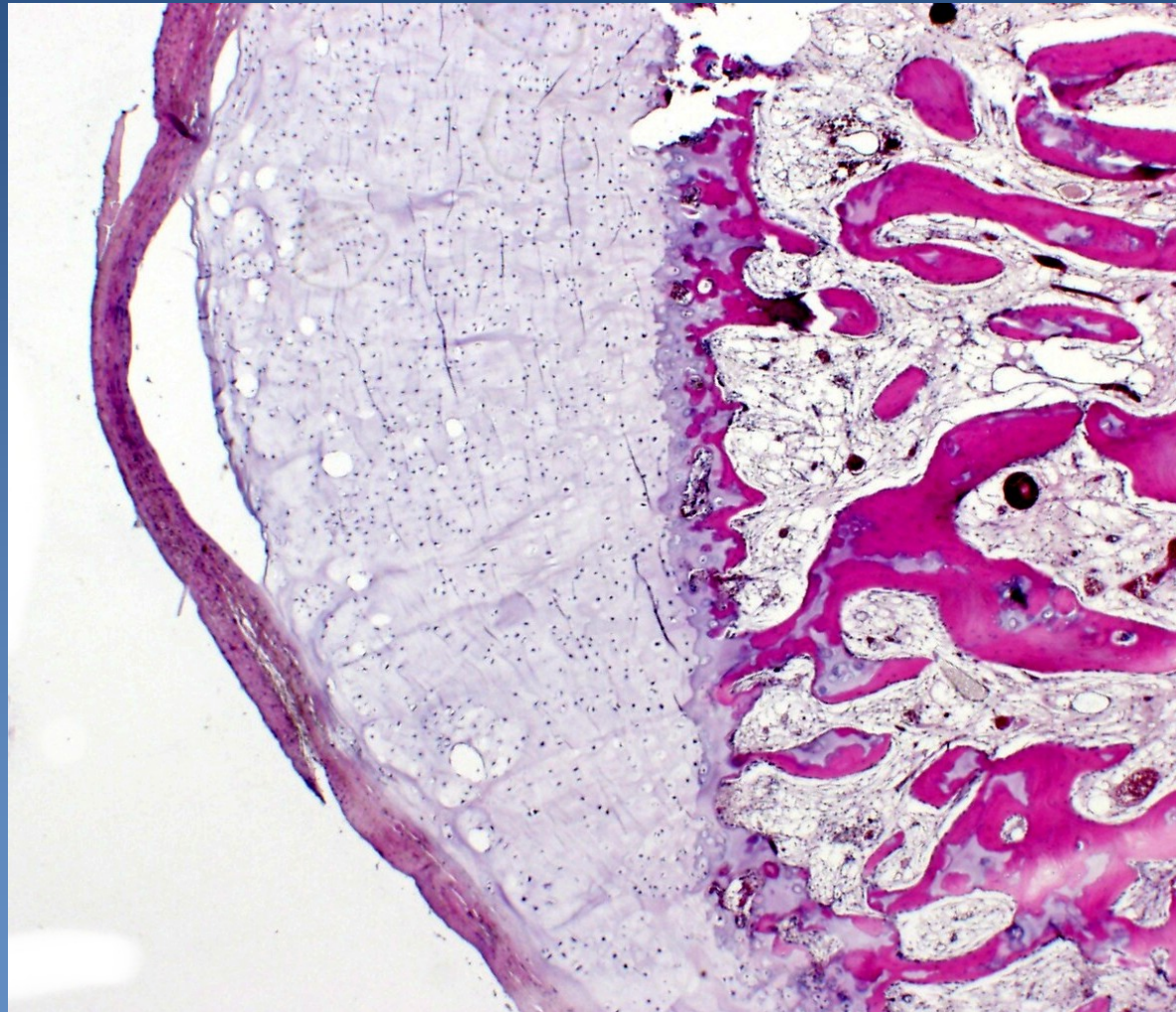


Osteochondroma

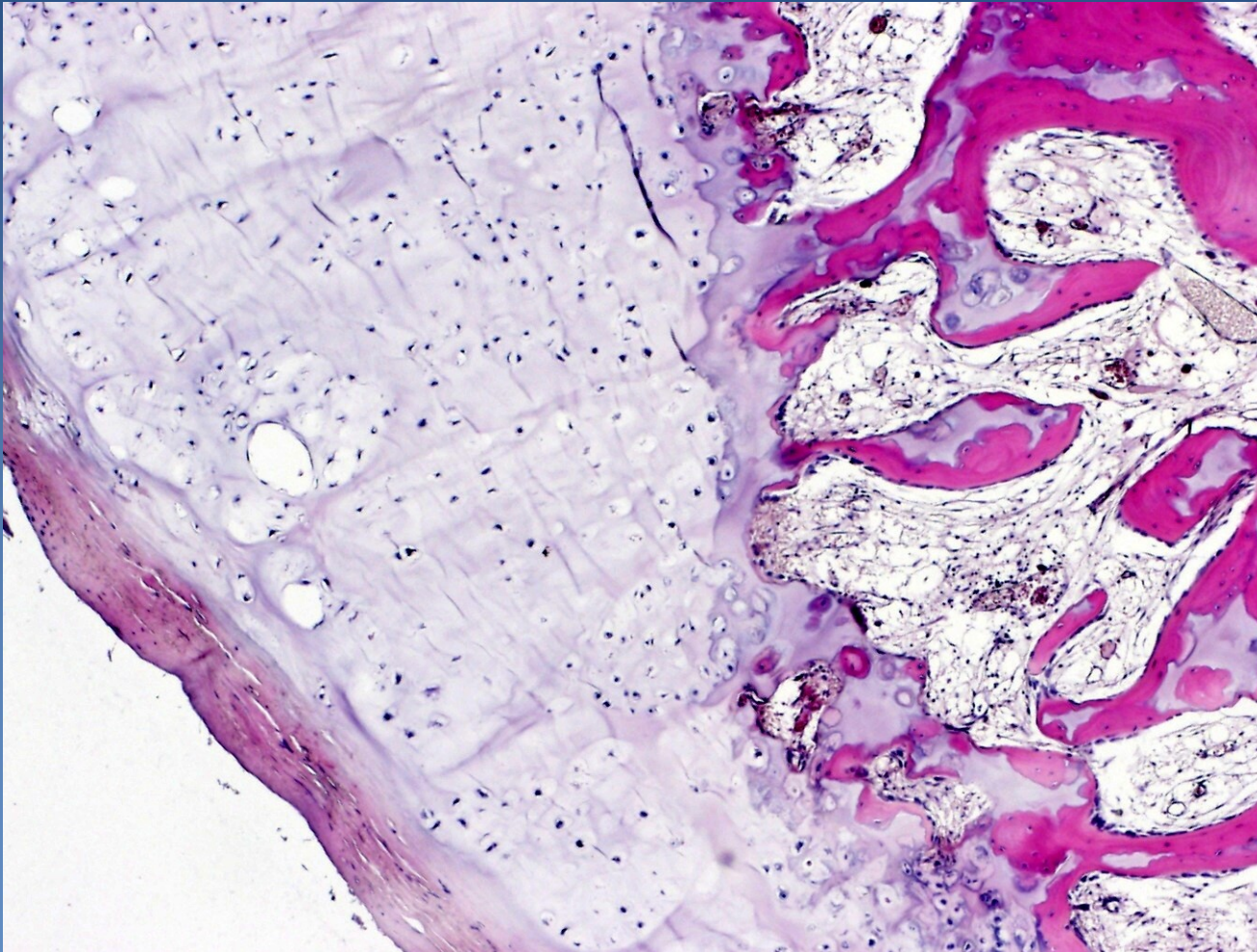


- ✗ „exostosis“
- ✗ on the metaphysis of the long/flat bones
- ✗ often during the period of skeletal growth
- ✗ gross:
 - ✗ bone prominence covered with cartilage – growthplate-like
- ✗ micro:
 - ⇒ *benign hyaline cartilage on the surface → enchondral ossification and lamellar bone formation*
 - ⇒ *intertrabecular bone marrow (adipous, haematopoetic)*

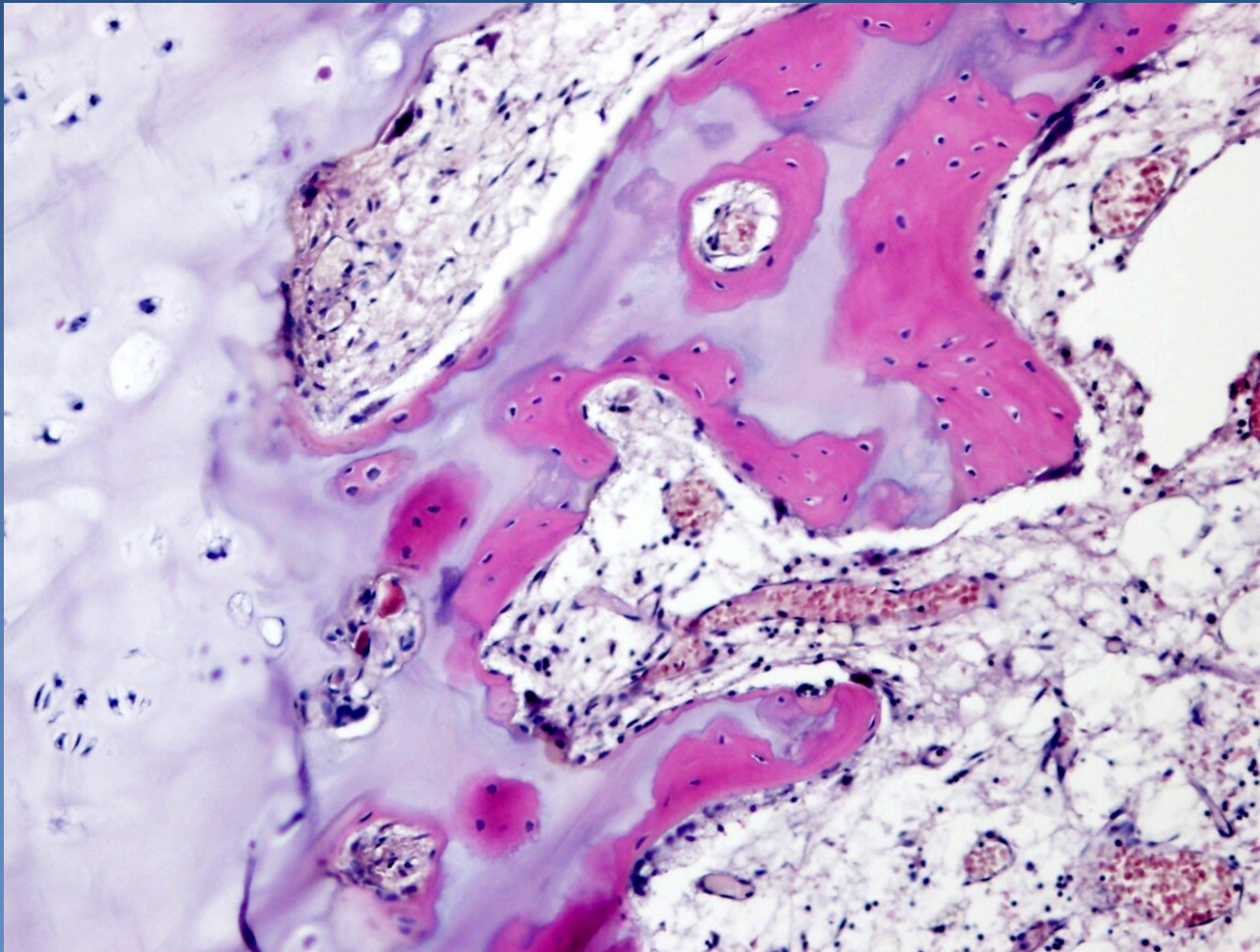
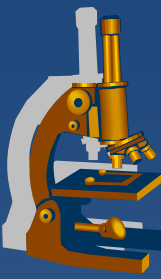
Osteochondroma



Osteochondroma



Osteochondroma



Osteosarcoma (OSA)

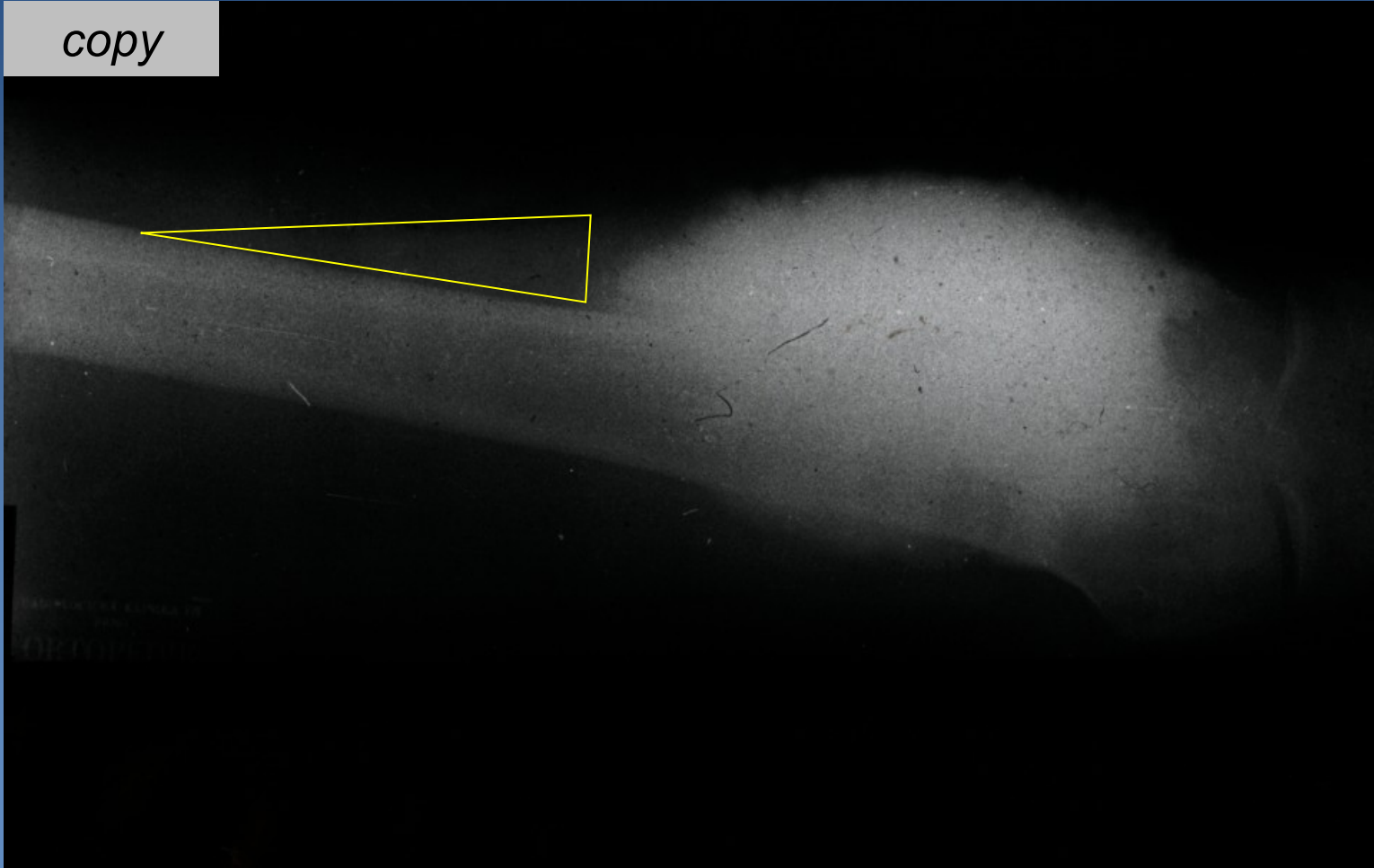


- × bone matrix producing malignant cells
- × primary: typically in **childhood - adolescence**
 - ⇒ *mostly during accelerated skeletal growth period*
- × secondary osteosarcoma possible in Paget disease, post-radiation
- × **localization**
 - ⇒ *long bone metaphyses (femur, tibia, humerus), especially in knee region (Codmann`s triangle on the X-ray)*
- × **divided according to their biological behavior**
 - ⇒ *low-grade (LG) – more commonly peripheral growth*
 - ⇒ *high-grade (HG) – more commonly central growth*

Osteosarcoma – Codman`s triangle



copy



HG OSA



× **micro:**

⇒ *irregular atypical osteoblasts* → **tumorous osteoid**

⇒ *frequent mitoses*

⇒ *significantly dilated vascular spaces*

⇒ *possible presence of cartilage or fibrous bone elements*

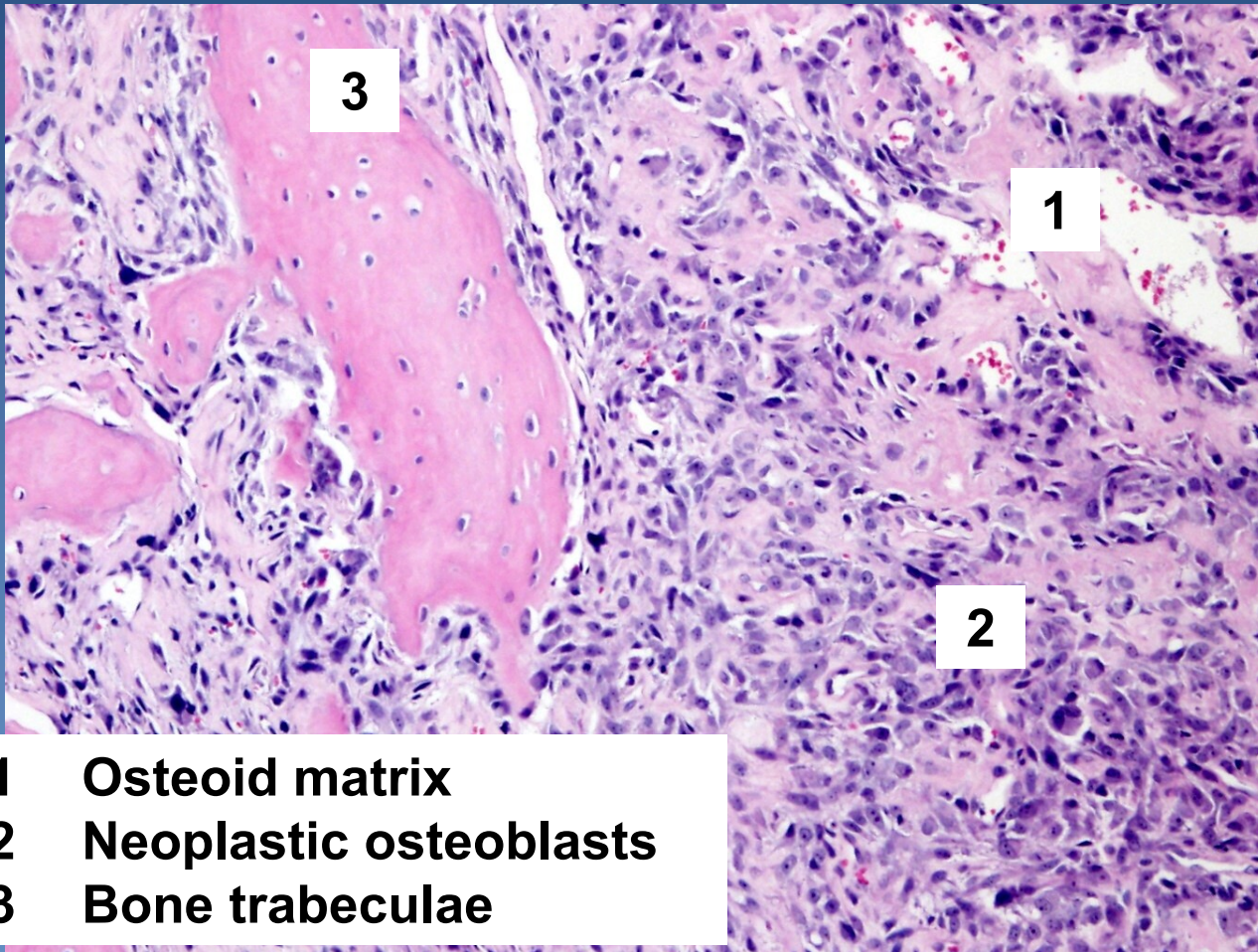
- osteoblastic, chondroblastic, fibroblastic variant

× **blood-borne micrometastases often present at the time of diagnosis (bones, lungs)**

⇒ *poor prognosis without treatment, with overt meta, recurrent*

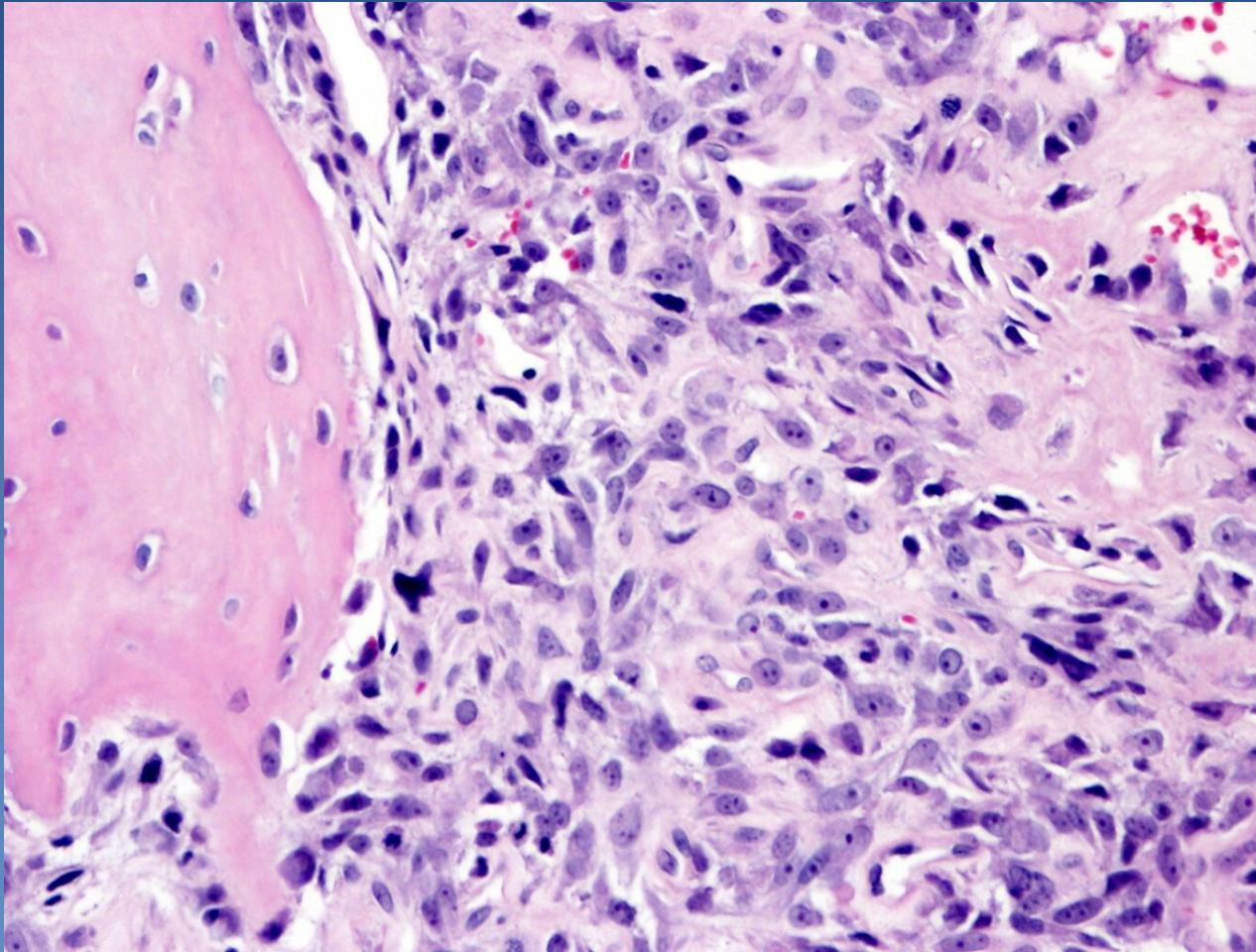
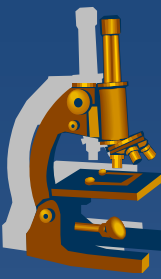
⇒ *chemotherapy + surgery (avoiding amputation)*

Osteosarcoma

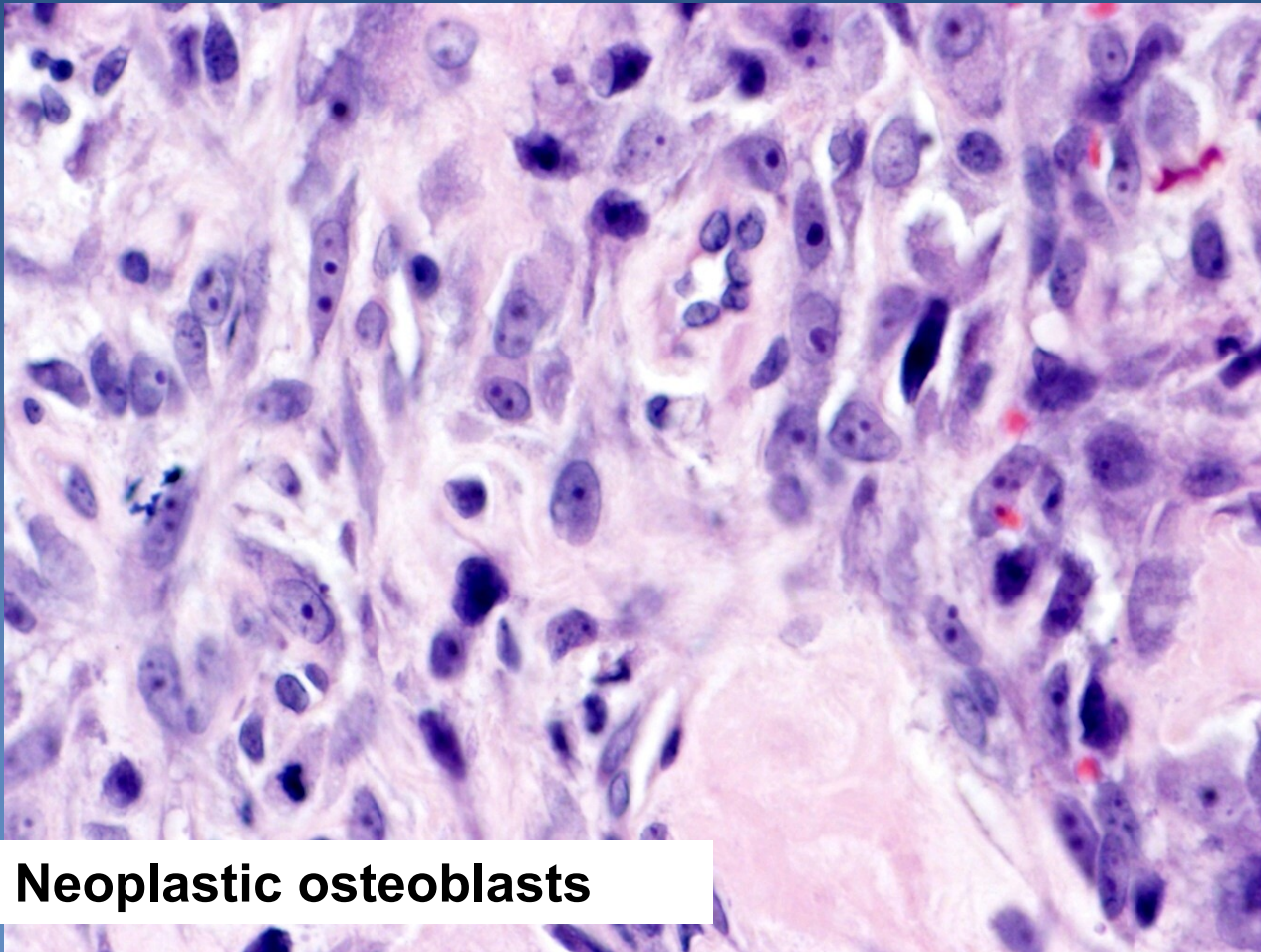


- 1 Osteoid matrix**
- 2 Neoplastic osteoblasts**
- 3 Bone trabeculae**

Osteosarcoma



Osteosarcoma



Neoplastic osteoblasts

Chondrosarcoma



- × typically in **adulthood** (after age of 20, mostly in 4th-6th decade)

- × **localization**

 - ⇒ *pelvis, femur, shoulder region*

- × **micro**

 - ⇒ *nodules of neoplastic cartilaginous tissue*

 - ⇒ *neoplastic chondroblasts with anisonucleosis, hyperchromasia, binucleate*

 - ⇒ *calcification, necrosis common*

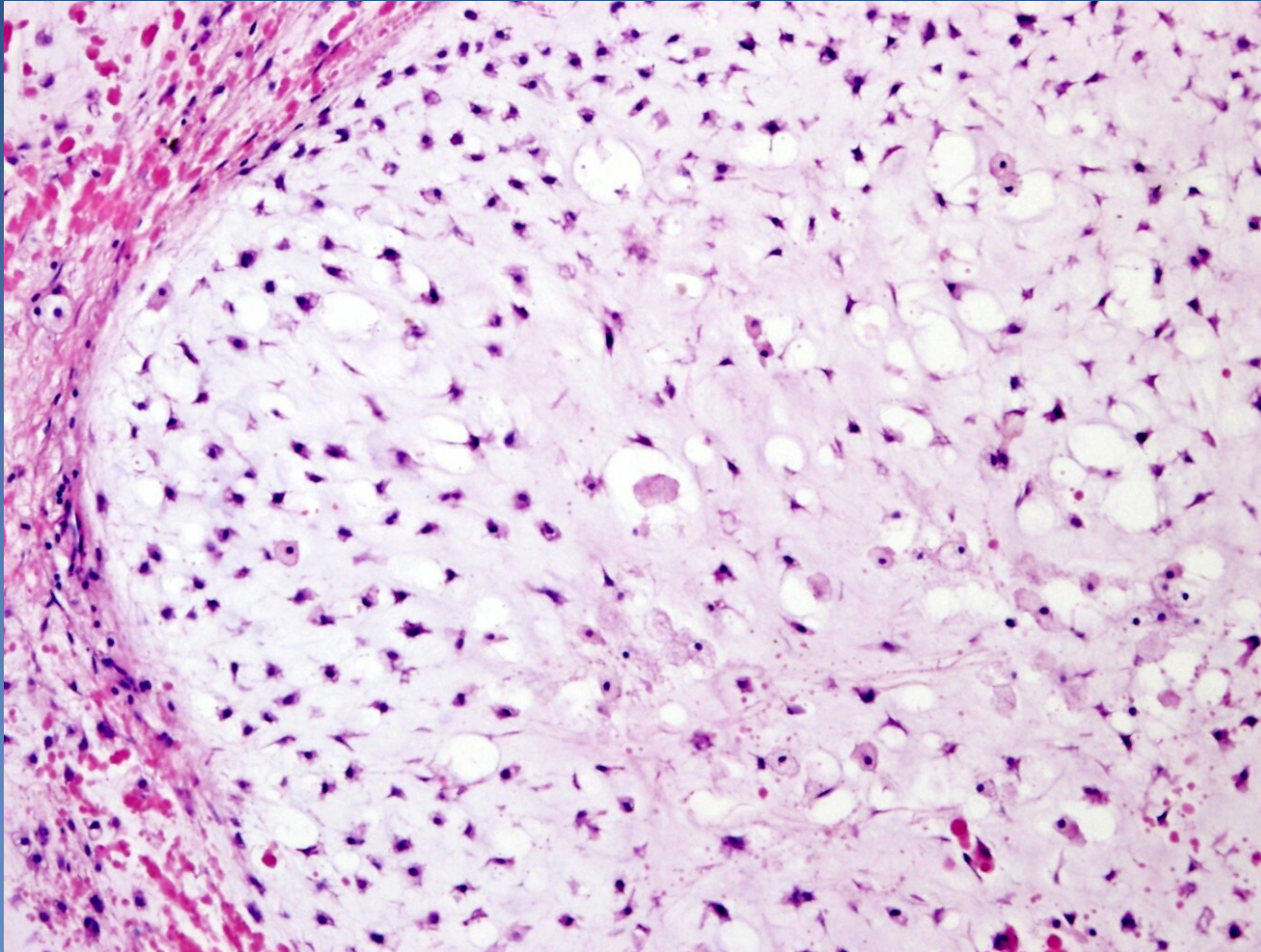
 - ⇒ *myxoid change of cartilaginous matrix possible*

- × **prognosis**

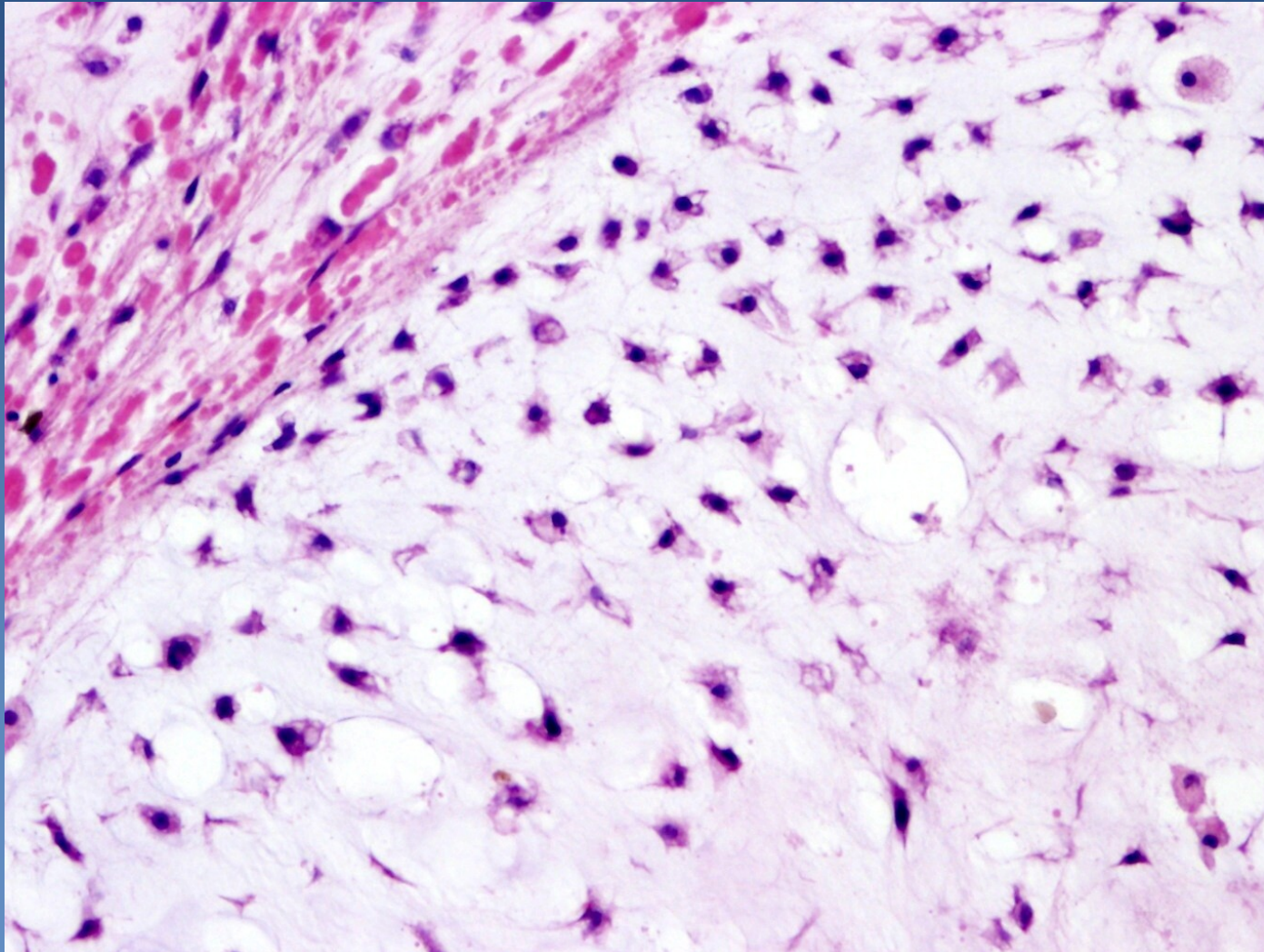
 - ⇒ *better than HG OSA*

 - ⇒ *slow proliferative activity common (surgery mostly)*

Chondrosarcoma



Chondrosarcoma



Ewing's sarcoma/PNET



- x group of small blue round-cell sarcomas, with detectable specific chromosome translocation**
 - ⇒ *improved prognosis thanks to aggressive CHT*
 - ⇒ *5-year survival for metastatic disease (lungs, bones) is only 25%*
- x typical in children and young adults**
- x most often localized in bone marrow, but any other localization possible**
- x molecular genetic changes:**
 - ⇒ *balanced translocation of EWSR1 (localized on 22nd chromosome) and ETS gene family → fusion genes → abnormal cell proliferation + survival*
 - **t(11;22)/ EWSR1-FLI** – the most common (90%)
 - **t(21;22)/EWSR1-ERG** – in 5-9%

Ewing's sarcoma/PNET



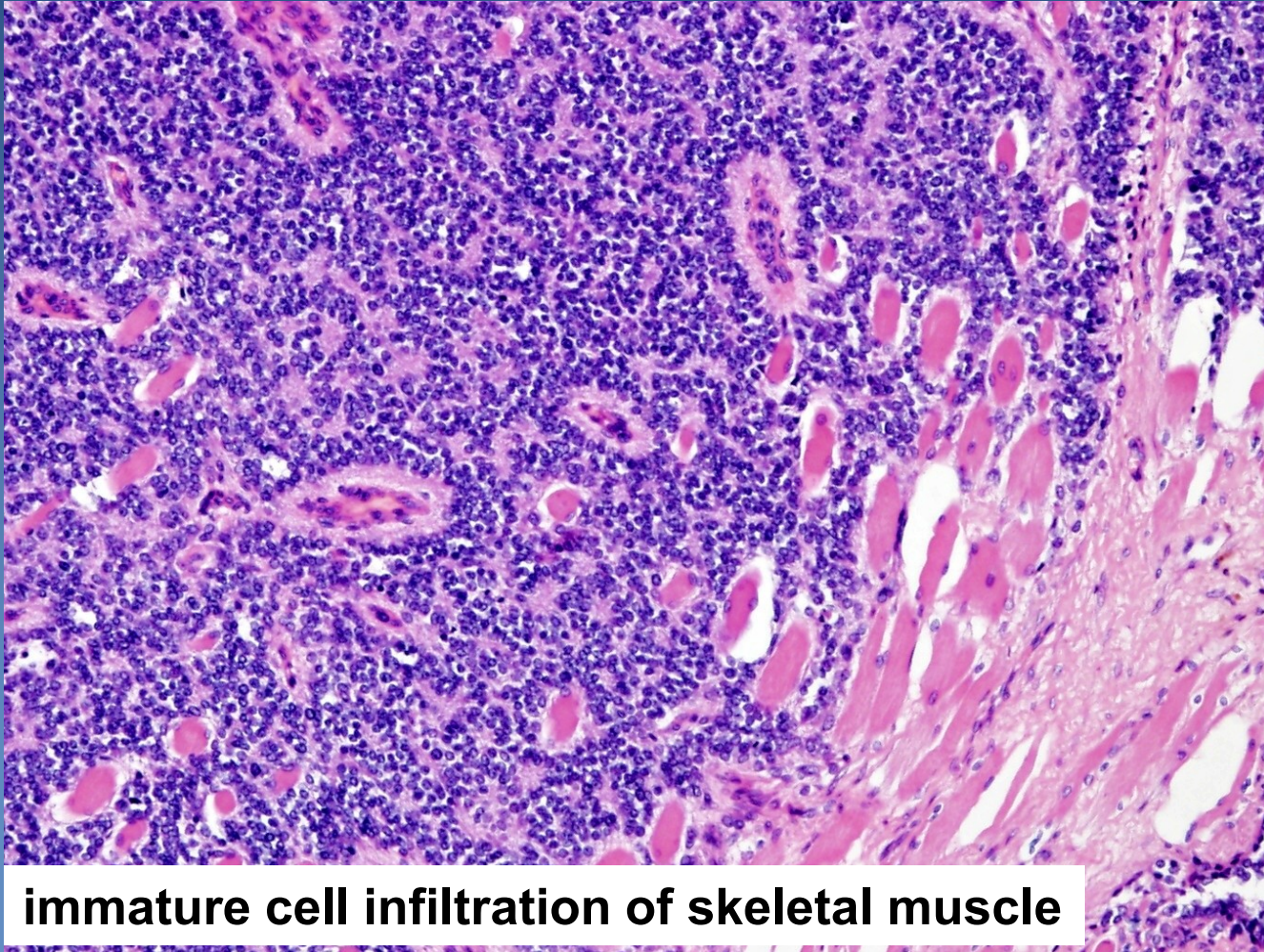
x gross:

- ⇒ *X-ray: osteolytic destructive lesion localized in diaphysis of a long bone + lamelated or “onion skin” type periosteal reaction*
- ⇒ *whitish necrotic focus – may resemble purulent osteomyelitis*
- ⇒ *fragile, necrotic, hemorrhagic tumor in soft tissues and in affected organs*

x micro:

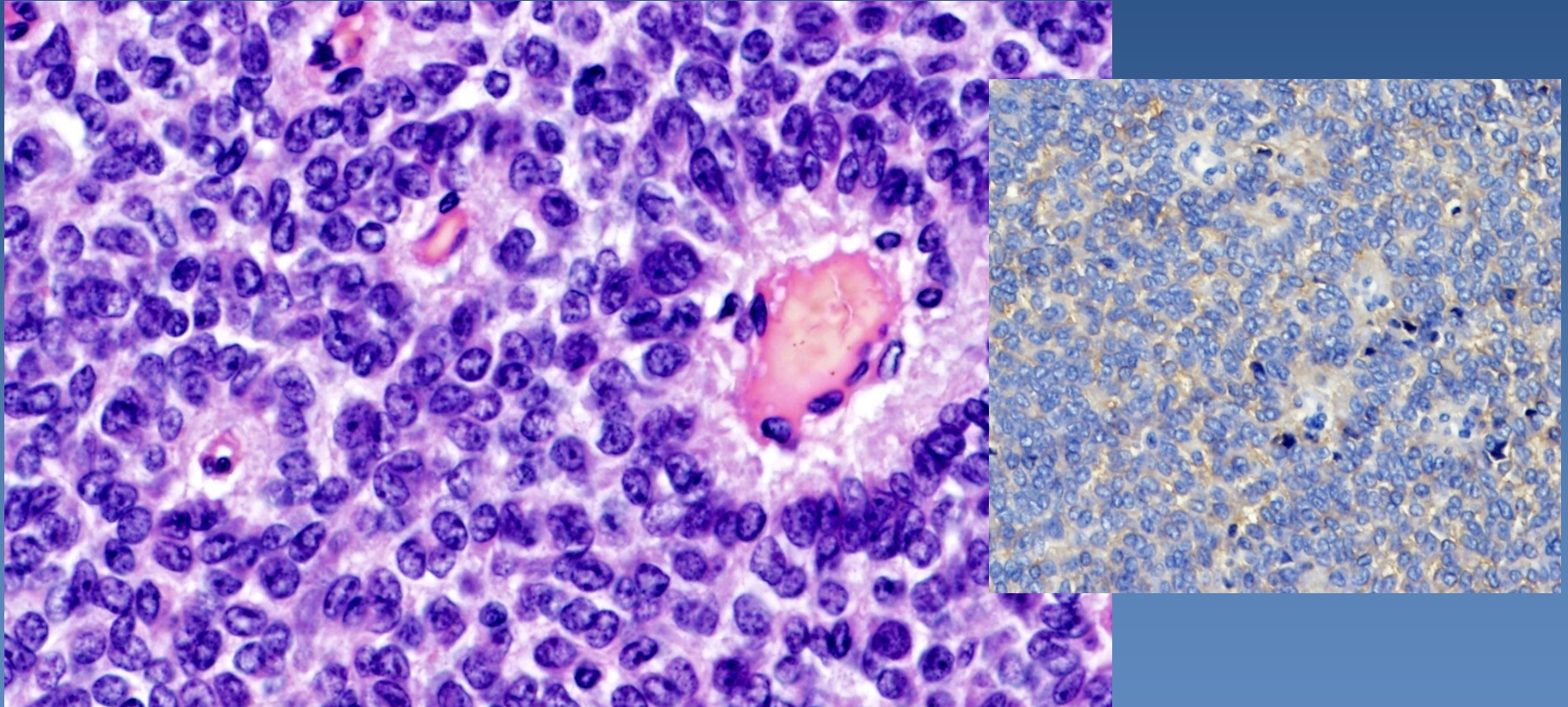
- ⇒ *uniform round cells*
- ⇒ *formation of rosettes, pseudorosettes*
- ⇒ *necrosis*
- ⇒ *mitoses*

Ewing's sarcoma



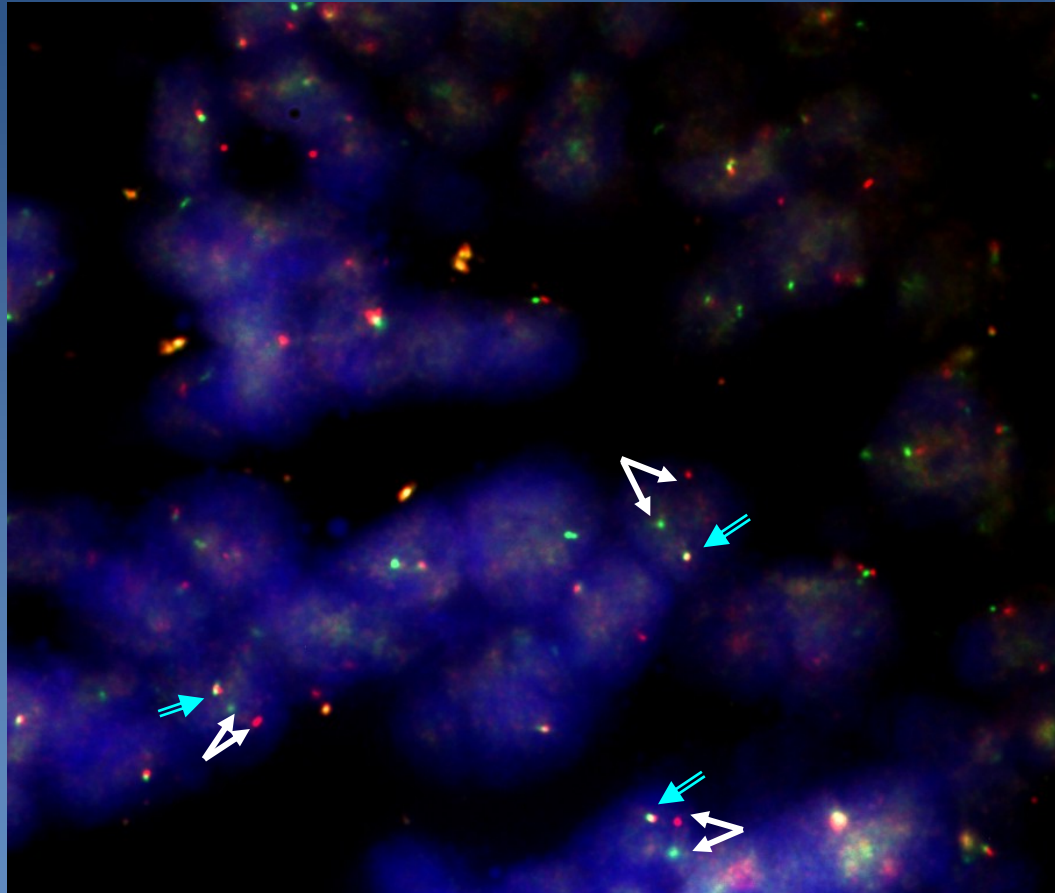
immature cell infiltration of skeletal muscle

Ewing's sarcoma



Tumor cell nuclei with dispersed chromatin
Right: anti-CD99

Ewing's sarcoma



FISH: split () *EWSR1* gene on chromosome 22, normal locus EWS (↗)



JOINTS, SOFT TISSUES

Arthritis uratica - gout



× defective uric acid metabolism

⇒ *monosodium urate crystals*

- in joint cartilage, in synovial membrane, in soft tissues surrounding joint (big toe joints...)

× acute gouty arthritis

⇒ *acute synovial membrane inflammation*

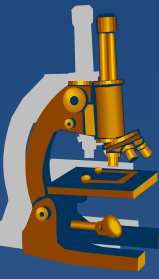
- neutrophils, free oxygen radicals, inflammatory synovial membrane damage...

× chronic gouty arthritis

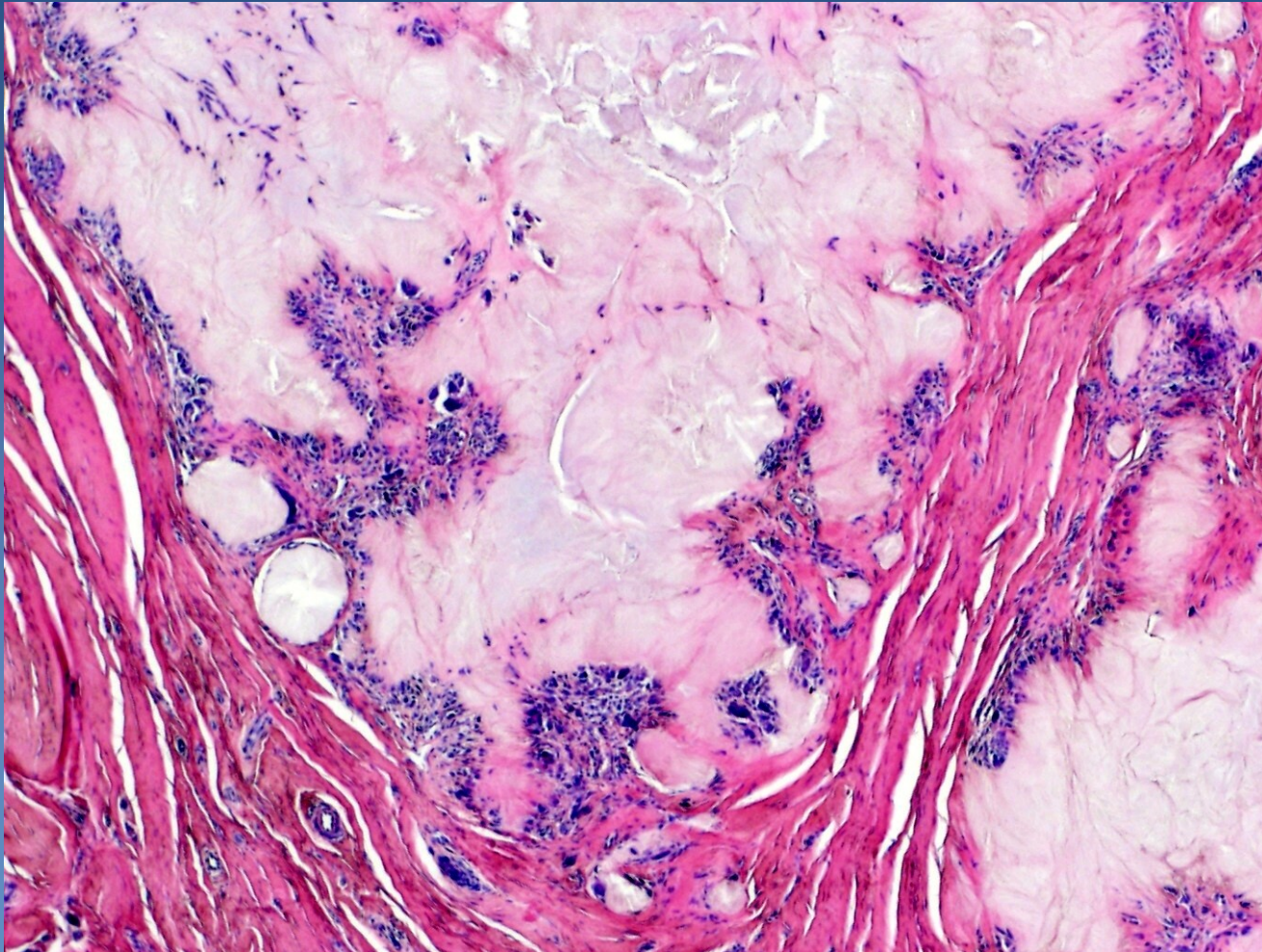
⇒ *after repeated acute attacks*

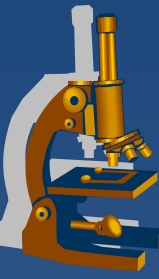
⇒ ***tophus***

- aggregates of urate crystals surrounded by giant cell granuloma

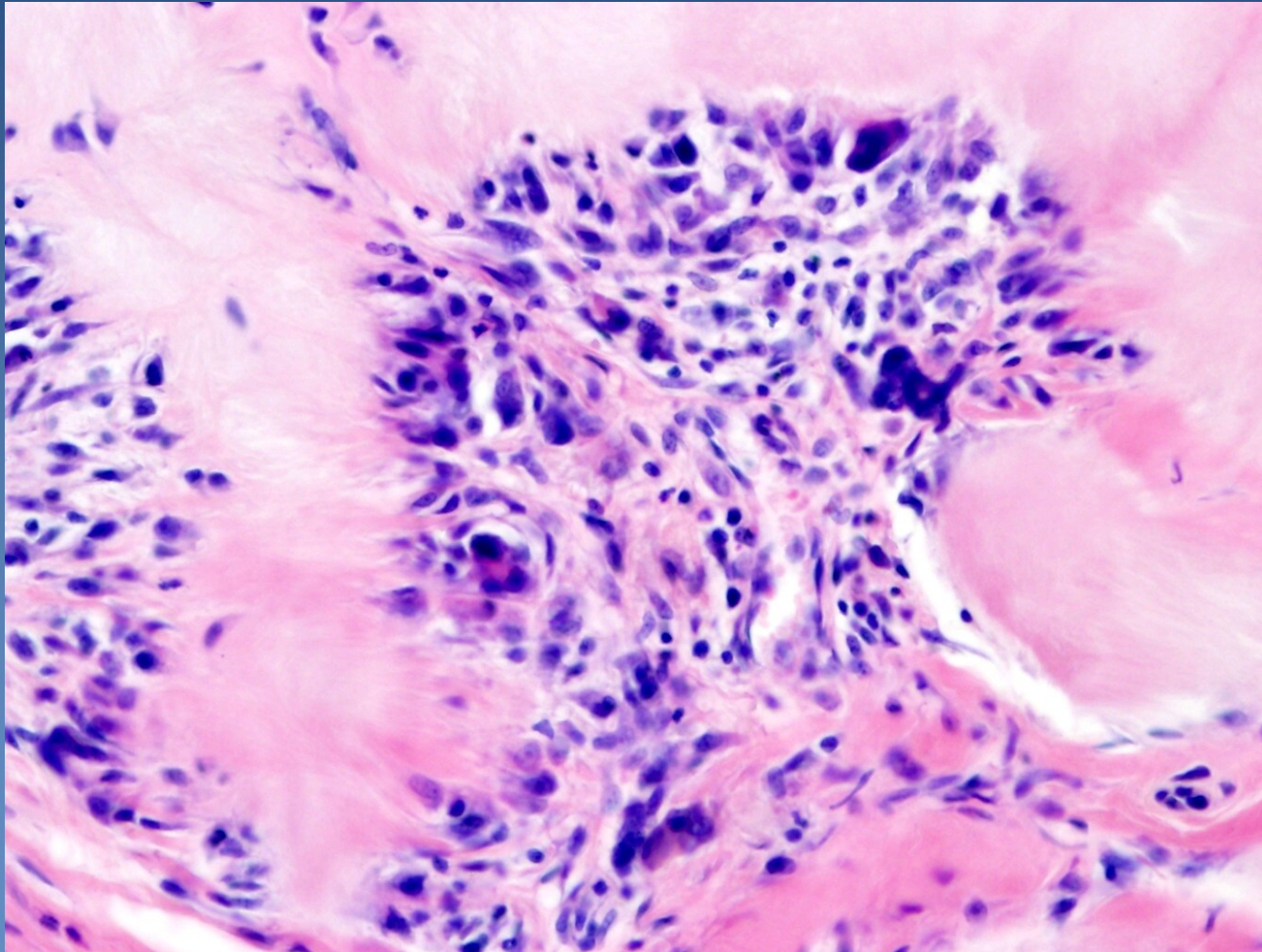


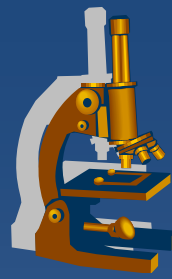
Arthritis uratica – tophus



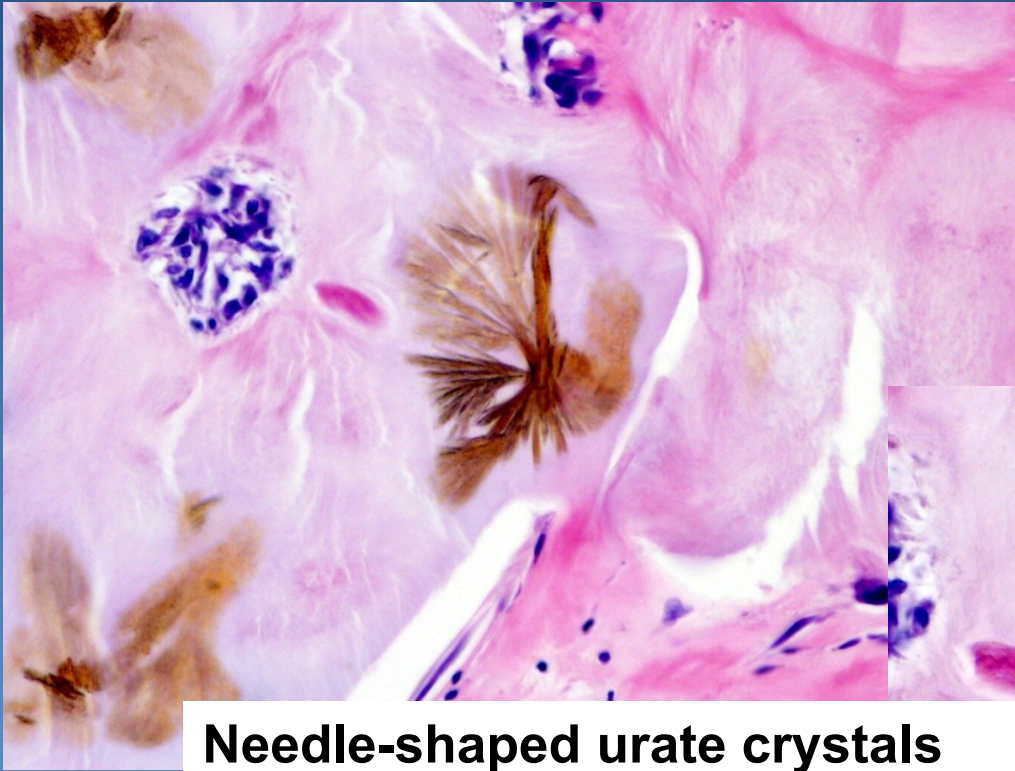


Arthritis uratica – tophus

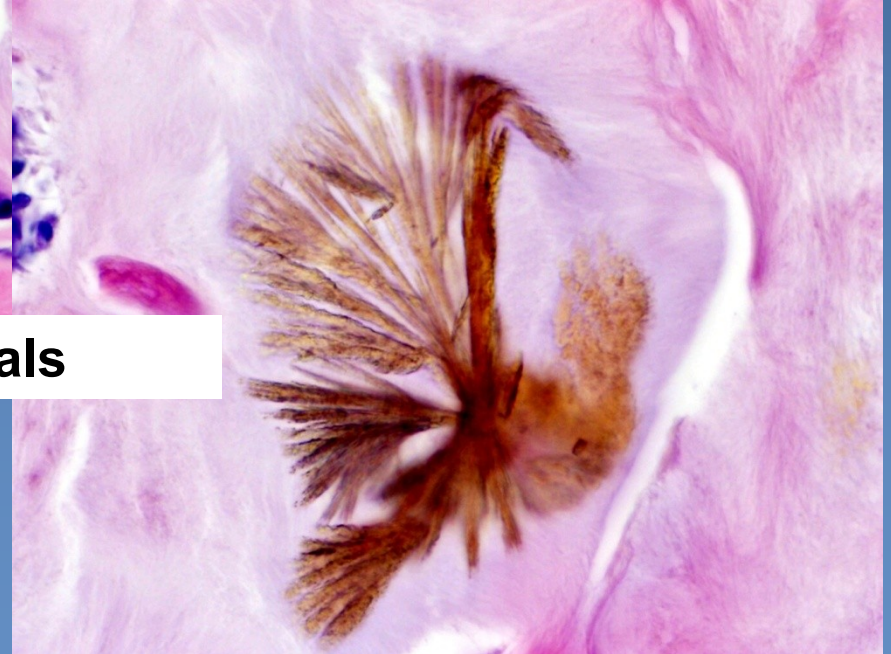



Arthritis uratica – tophus



Needle-shaped urate crystals



Myositis ossificans

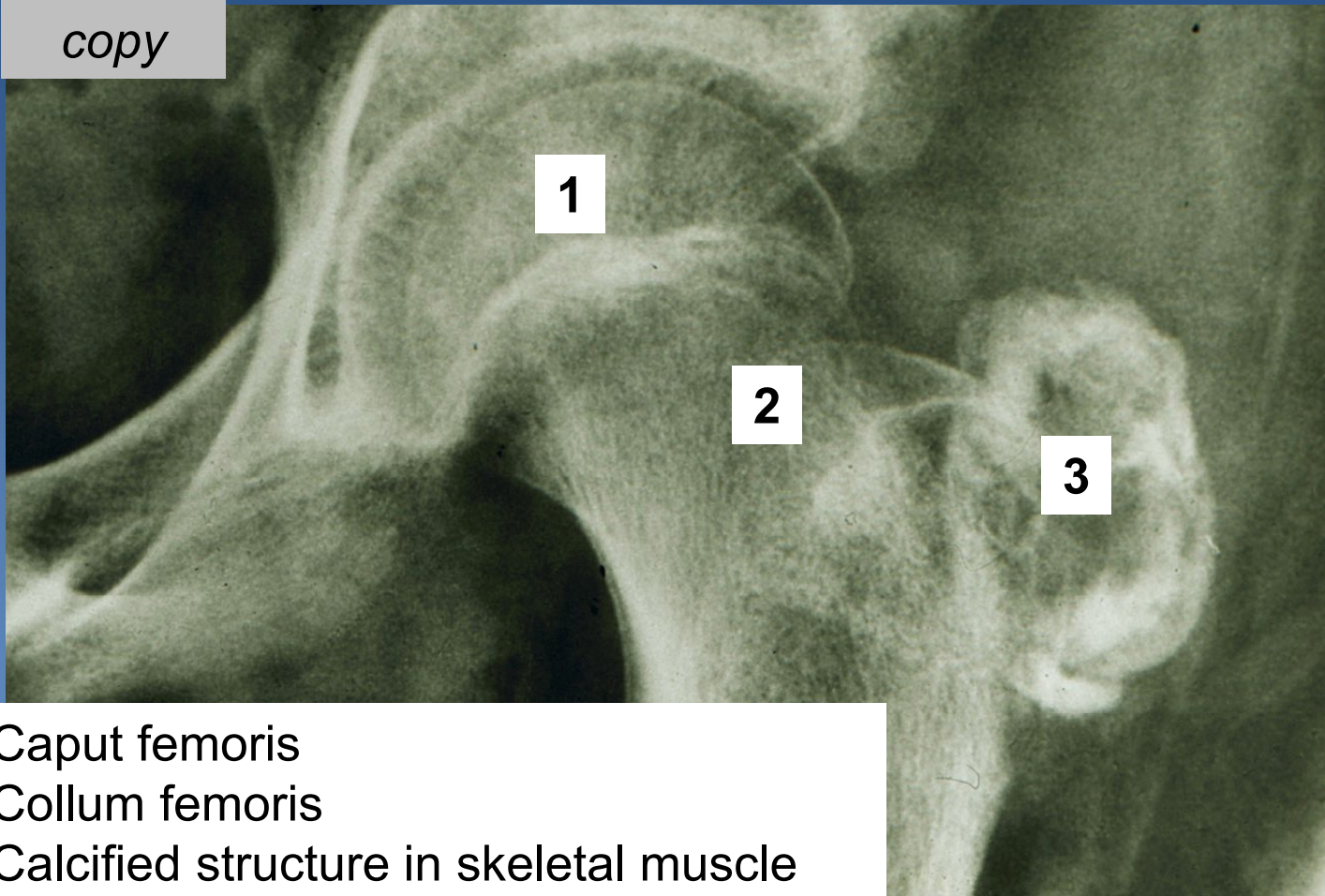


- × tumor-like reactive nodular fibroblastic lesion
- × metaplastic ossification of skeletal muscle following inflammation (diff.dg. x extraskeletal osteosarcoma)
- × mostly in young sportsmen, proximal limbs
- × often trauma anamnesis (→ deep haematoma)
- × X-Ray: central clearing with ossified border
- × micro:
 - ⇒ *central fibroblastic proliferation + hemosiderin*
 - ⇒ *metaplastic ossification and regressive muscle changes in the periphery*

Myositis ossificans

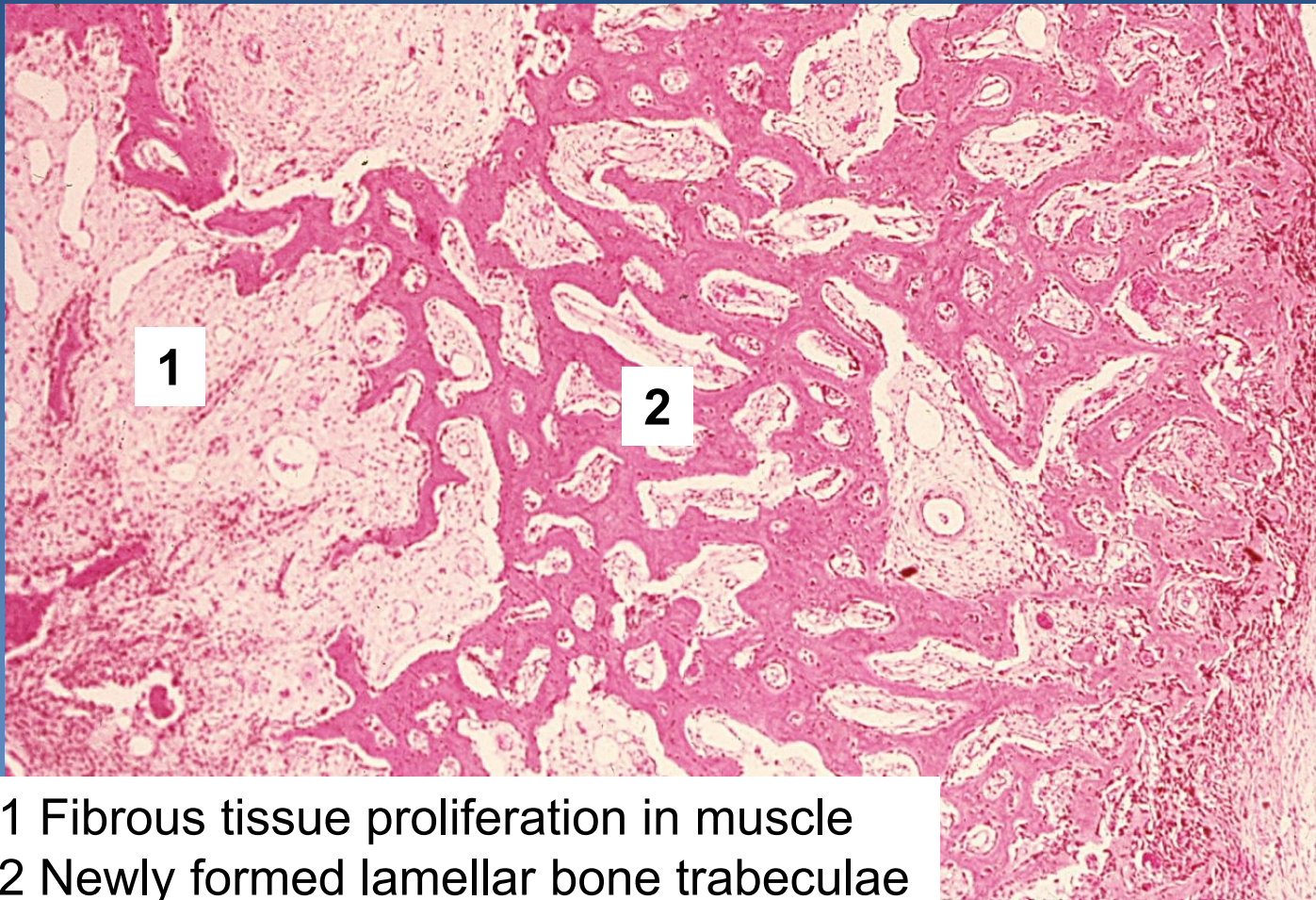


copy



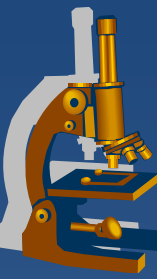
- 1 Caput femoris
- 2 Collum femoris
- 3 Calcified structure in skeletal muscle

Myositis ossificans



- 1 Fibrous tissue proliferation in muscle
- 2 Newly formed lamellar bone trabeculae

Undifferentiated pleomorphic sarcoma **(Malignant fibrous histiocytoma, MFH)**



- × high-grade sarcoma
- × 30% of all soft tissue sarcomas
 - ⇒ *may occur in dermis and subcutaneous tissue*
- × often in the thigh region
- × mostly in older males
- × diagnosis *per exclusionem*
 - ⇒ *after elimination of any other poorly differentiated mesenchymal or neuroectodermal tumor*

„MFH“



x gross:

⇒ *whitish tumor, „ fish-flesh“ appearance on cut section*

x micro:

⇒ *excessive pleomorphism of tumor cells and cellular architectonics*

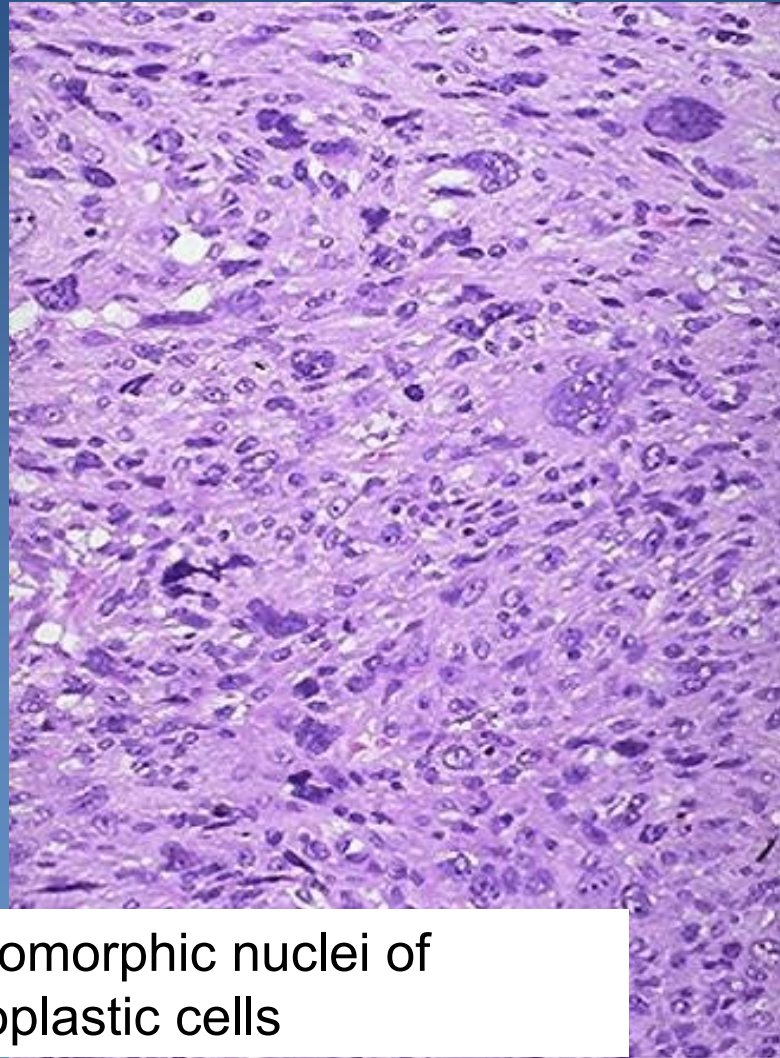
⇒ *bizarre multinucleate cells*

⇒ *frequent mitotic activity, necrosis*

⇒ *variants:*

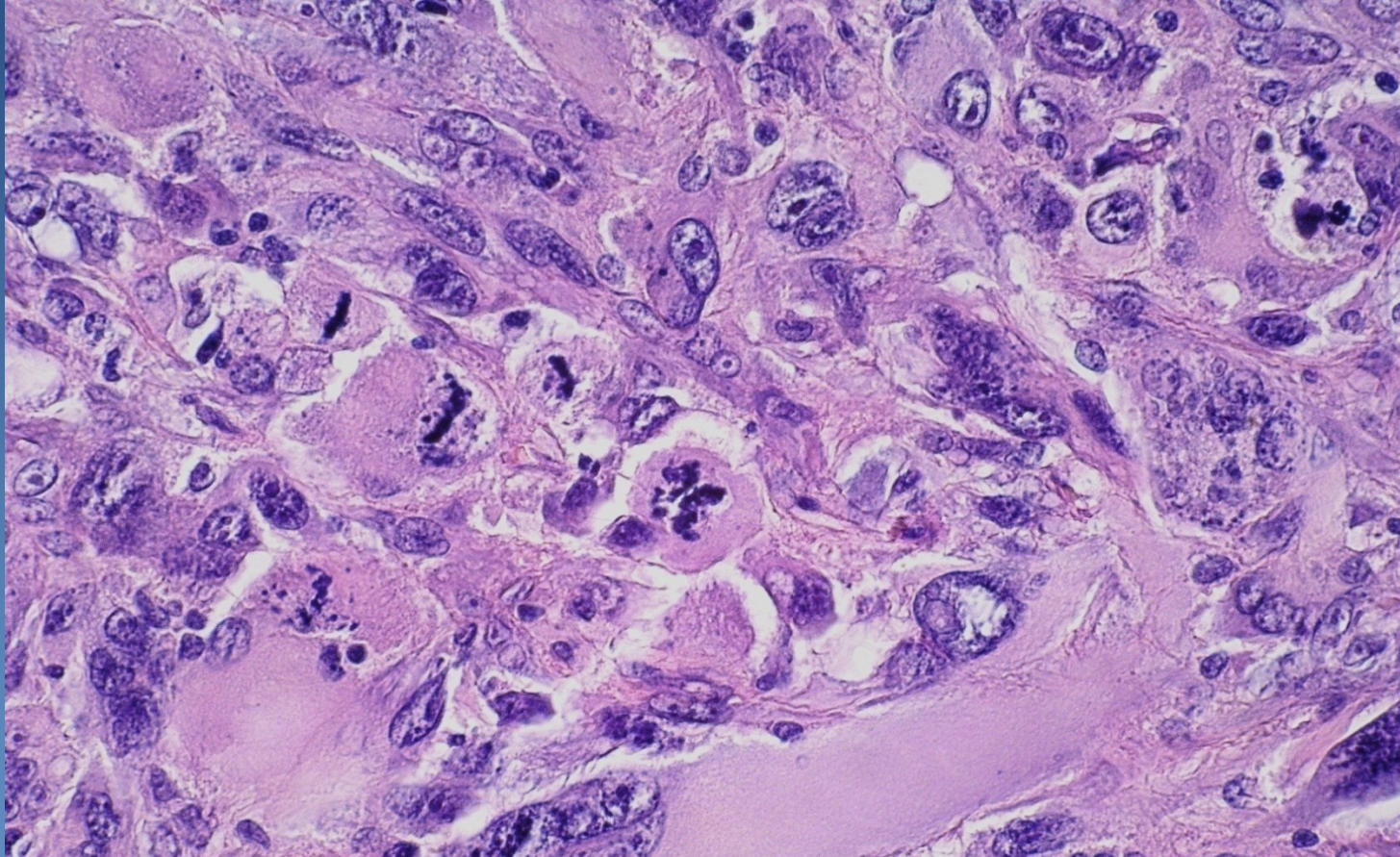
- pleomorphic
- inflammatory
- giant-cell

MFH – high grade undifferentiated pleomorphic sarcoma



Pleomorphic nuclei of neoplastic cells

MFH – high grade undifferentiated pleomorphic sarcoma



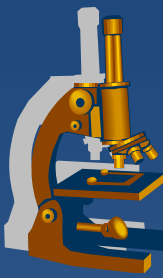
Pleomorphic nuclei of neoplastic cells,
frequent mitotic activity (atypical mitoses)

Synovial sarcoma



- × in fact not from synovial cells – original cell unclear
- × usually balanced translocation $t(X;18)$
- × typical in adolescents and young adults (15 – 40s)
- × mostly in deep soft tissues of upper or lower limbs

Synovial sarcoma



x therapy:

⇒ *resection + CHT, RT*

x aggressive tumor

⇒ *lung, bones metastases*

⇒ *5-year survival 25 – 85 %*

x micro:

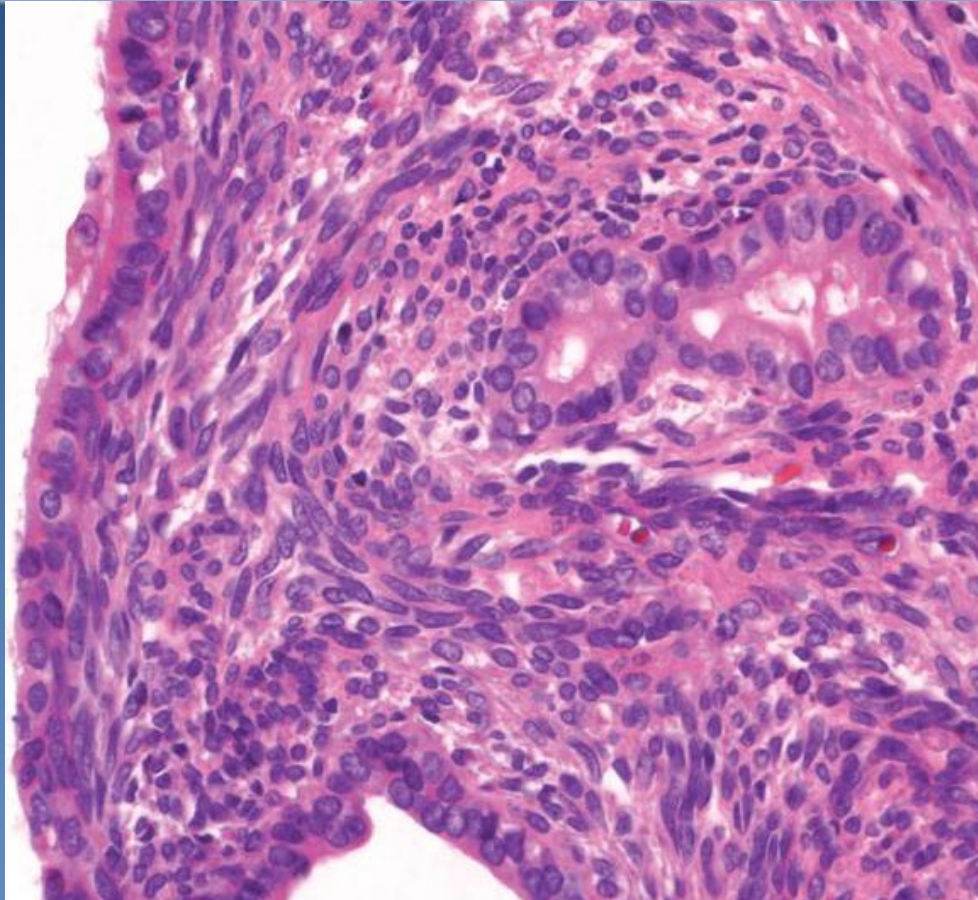
⇒ *Biphasic variant*

- spindle cells + epithelial component (glandular formations, strands of epithelial cells)

⇒ *Monophasic variant*

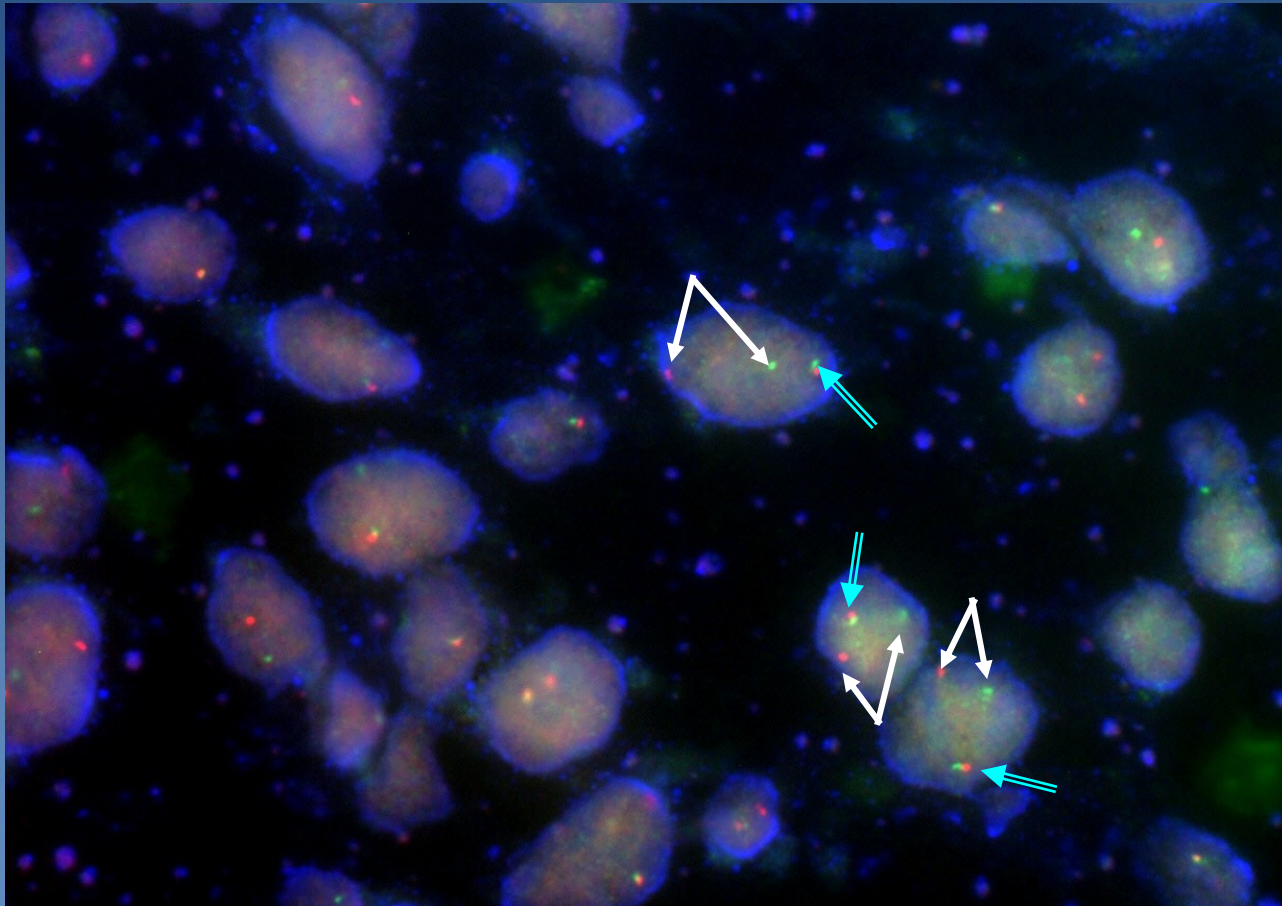
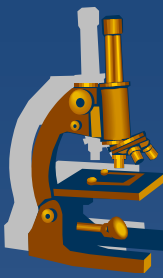
- spindle cells

Synovial sarcoma



Biphasic variant:
spindle cells + glandular
formations

Synovial sarcoma



FISH: split () gene SS18, normal locus SS18() ↗



SKIN - INFLAMMATION

Skin changes - terms



x hyperkeratosis

⇒ *thickened stratum corneum, often associated with marked stratum granulosum*

x parakeratosis

⇒ *imperfect keratinization characterized by retention of the nuclear remnants in the stratum corneum, stratum granulosum often missing*

x dyskeratosis

⇒ *abnormal monocellular keratinization (disordered or premature) occurring within individual cells or groups of cells below the stratum granulosum – intraepidermal keratin foci*

x acanthosis

⇒ *hyperplasia of the stratum spinosum*

x papillomatosis

⇒ *hyperplasia of papillary dermis with elongation of the dermal papillae*

Psoriasis



x chronic inflammatory dermatosis (epidermal hyperproliferation) genetic susceptibility (HLA) + unknown trigger factor; T-cell mediated, TNF, increased epidermal cell proliferation and turnover

x typical localizations:

⇒ *elbows, knees, extensor surfaces of the skin*

⇒ *generalization possible*

x sometimes associated with arthropathy, myopathy, enteropathy, etc.

Psoriasis



x gross:

⇒ *well demarcated pink to red plaques*

⇒ *covered by silvery parakeratotic scales*

x micro:

⇒ *hyperkeratosis, parakeratosis*

- *stratum granulosum thinned or absent*

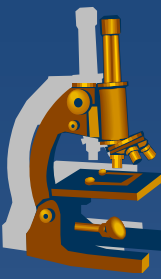
⇒ *acanthosis*

- *thinned suprapapillary layer of dermis, papillary oedema*

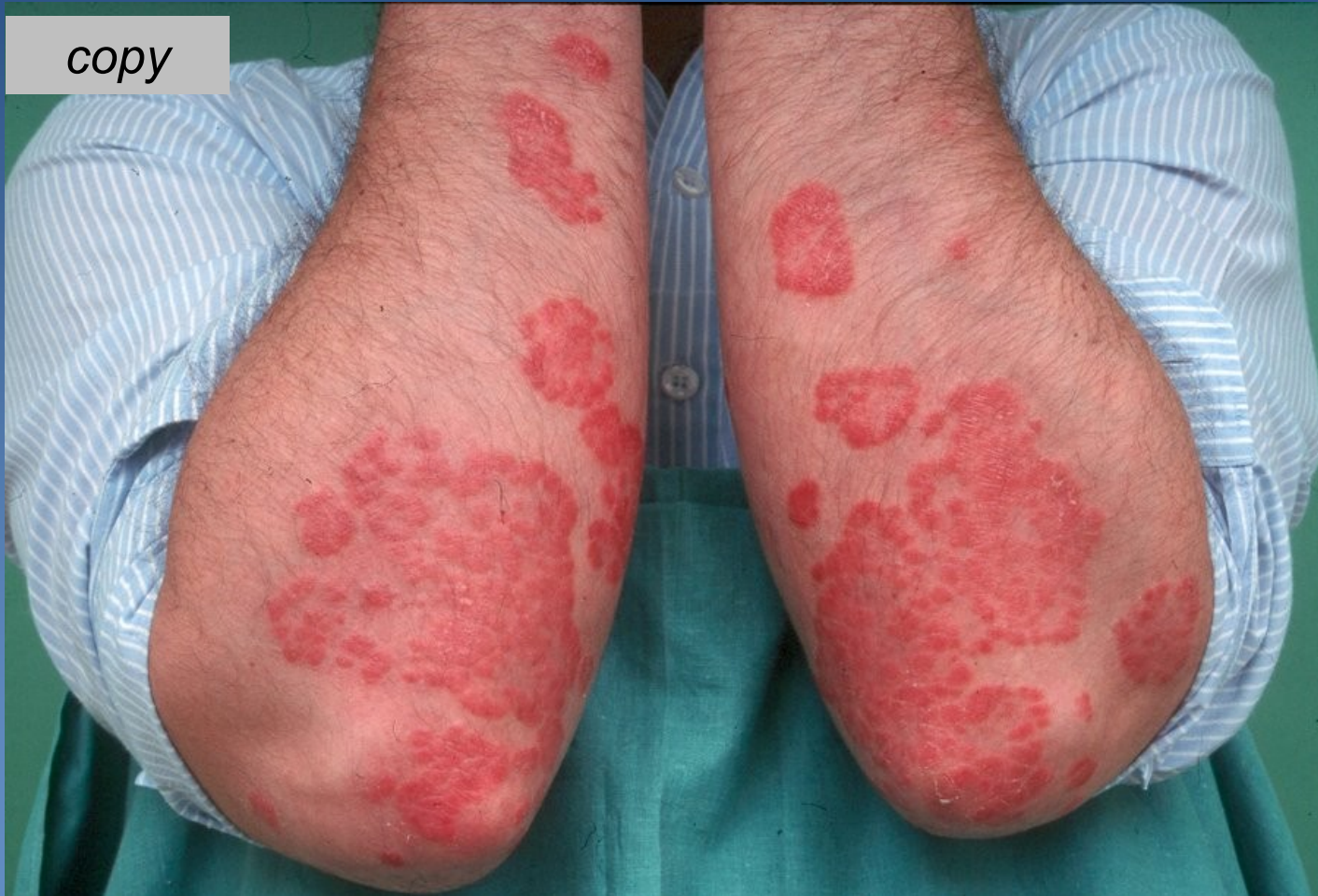⇒ *neutrophils in the stratum corneum – **microabscesses***

⇒ *chronic dermal inflammatory infiltrate*

Psoriasis



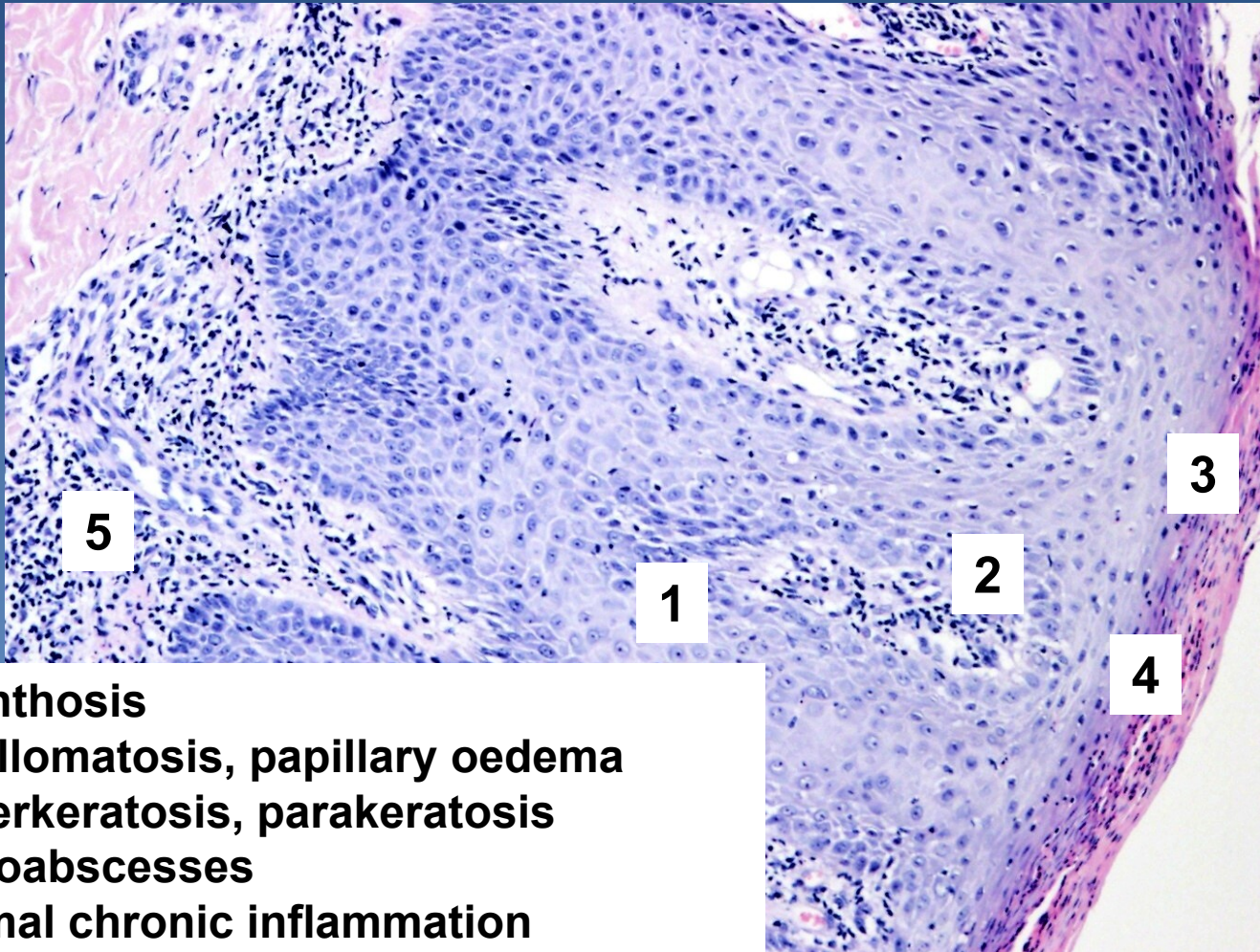
copy



Psoriasis

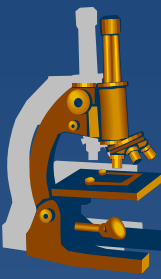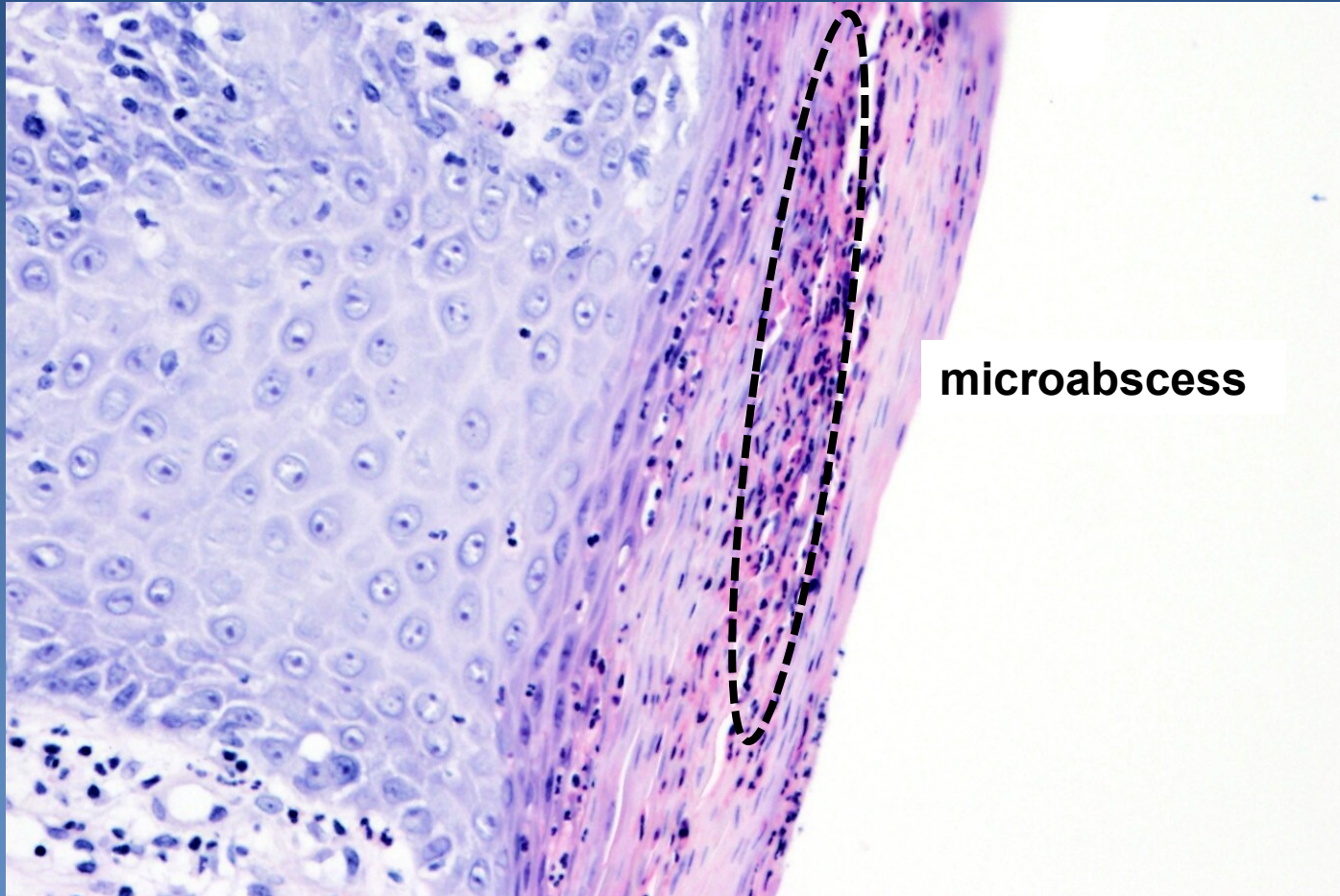


Psoriasis



- 1 Acanthosis
- 2 Papillomatosis, papillary oedema
- 3 Hyperkeratosis, parakeratosis
- 4 Microabscesses
- 5 Dermal chronic inflammation

Psoriasis



Lichen ruber planus



x chronic disease of skin and mucous membranes

x localization

⇒ *wrist, volar side of forearm, lower leg (crus)*

x gross

⇒ *pruritic skin-colored polygonal shaped flat-topped papulae*

⇒ *may fuse to form purple plaques*

⇒ *oral – white reticular lesions*

Lichen ruber planus



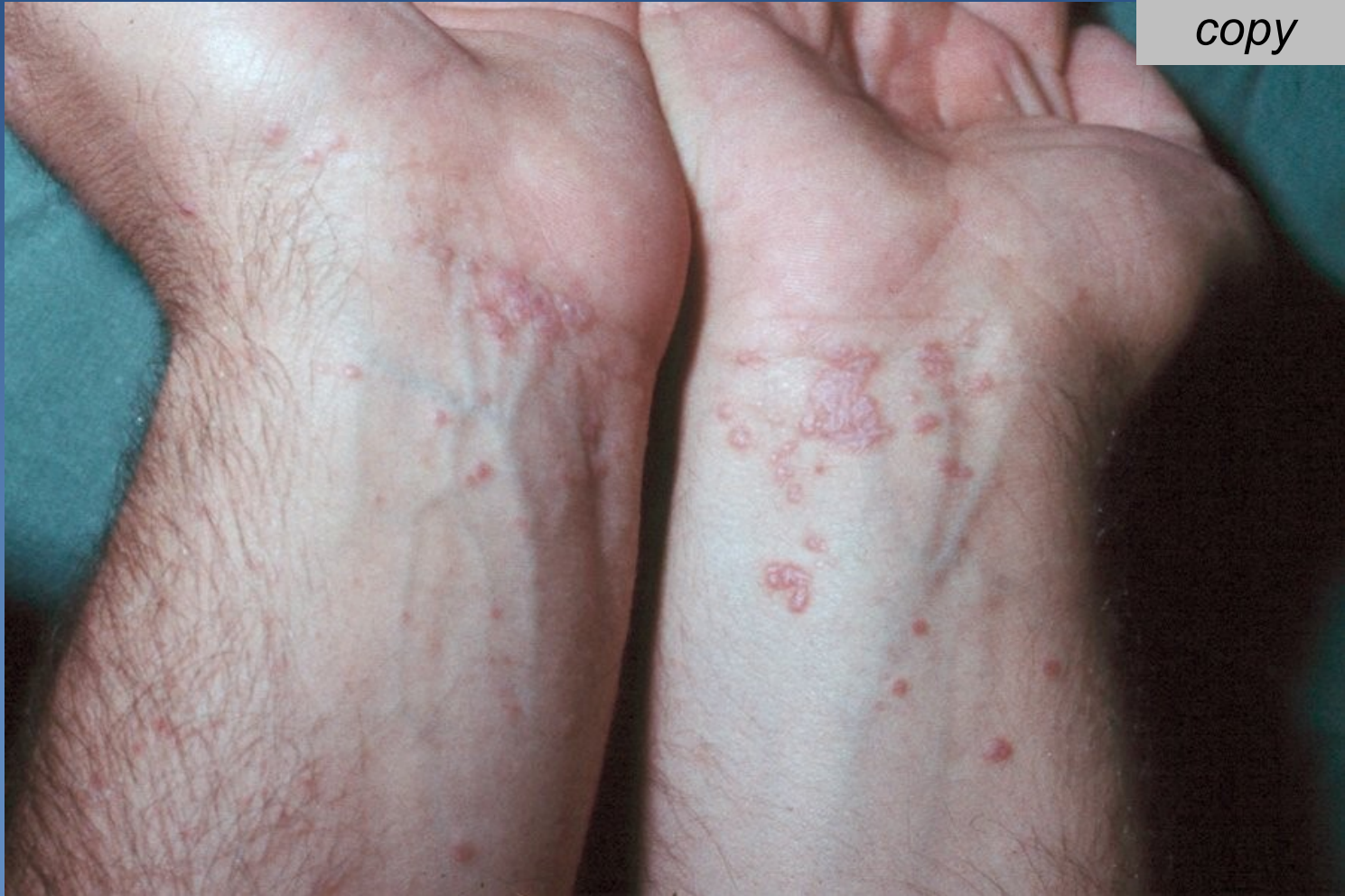x micro:

- ⇒ *hyperkeratosis* without *parakeratosis*, thickened stratum granulosum
- ⇒ *irregular acanthosis*, disperse necrotic keratinocytes
- ⇒ *interface dermatitis* – cell-mediated cytotoxic immune reaction – degeneration + destruction of basal keratinocytes, saw-tooth profile
- ⇒ *dense infiltrate of lymphocytes along the dermoepidermal junction + melanin incontinence* (pigment in melanophages)
- ⇒ *x lichenoid infiltrate*

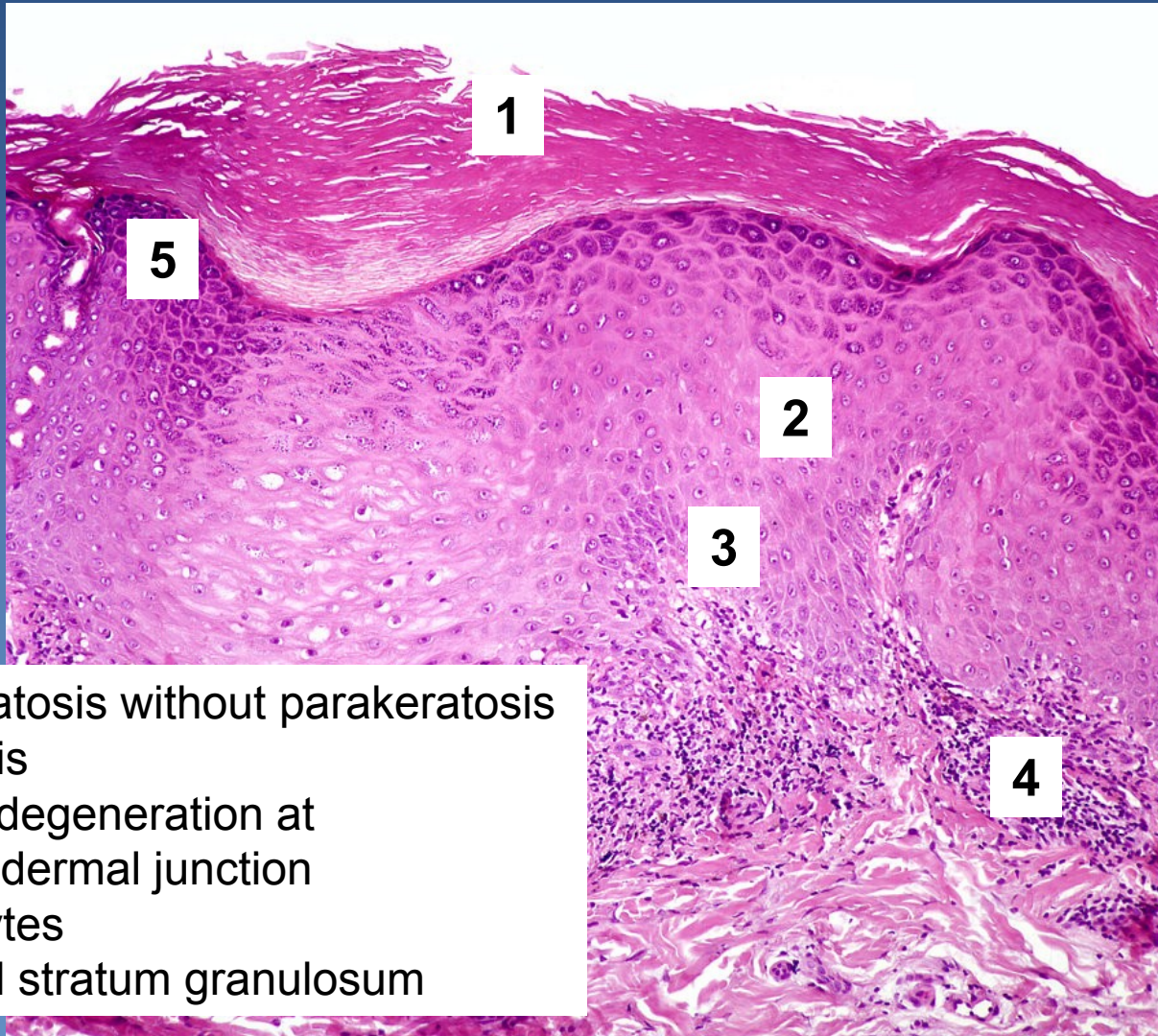
Lichen ruber planus



copy



Lichen ruber planus



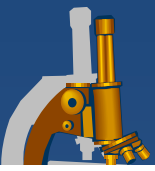
- 1 hyperkeratosis without parakeratosis
- 2 acanthosis
- 3 vacuolar degeneration at dermoepidermal junction
- 4 lymphocytes
- 5 thickened stratum granulosum

Urticaria (hives)

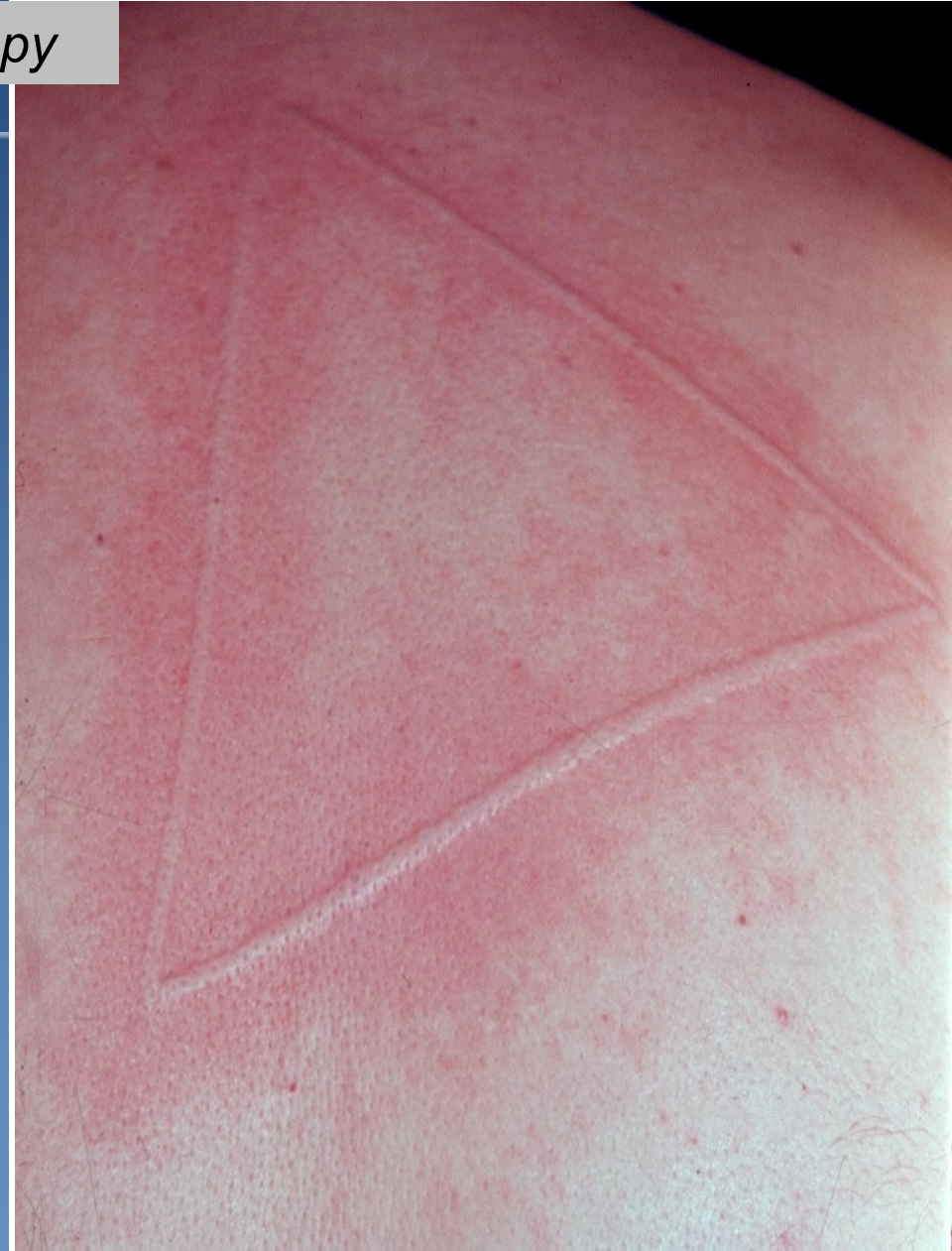
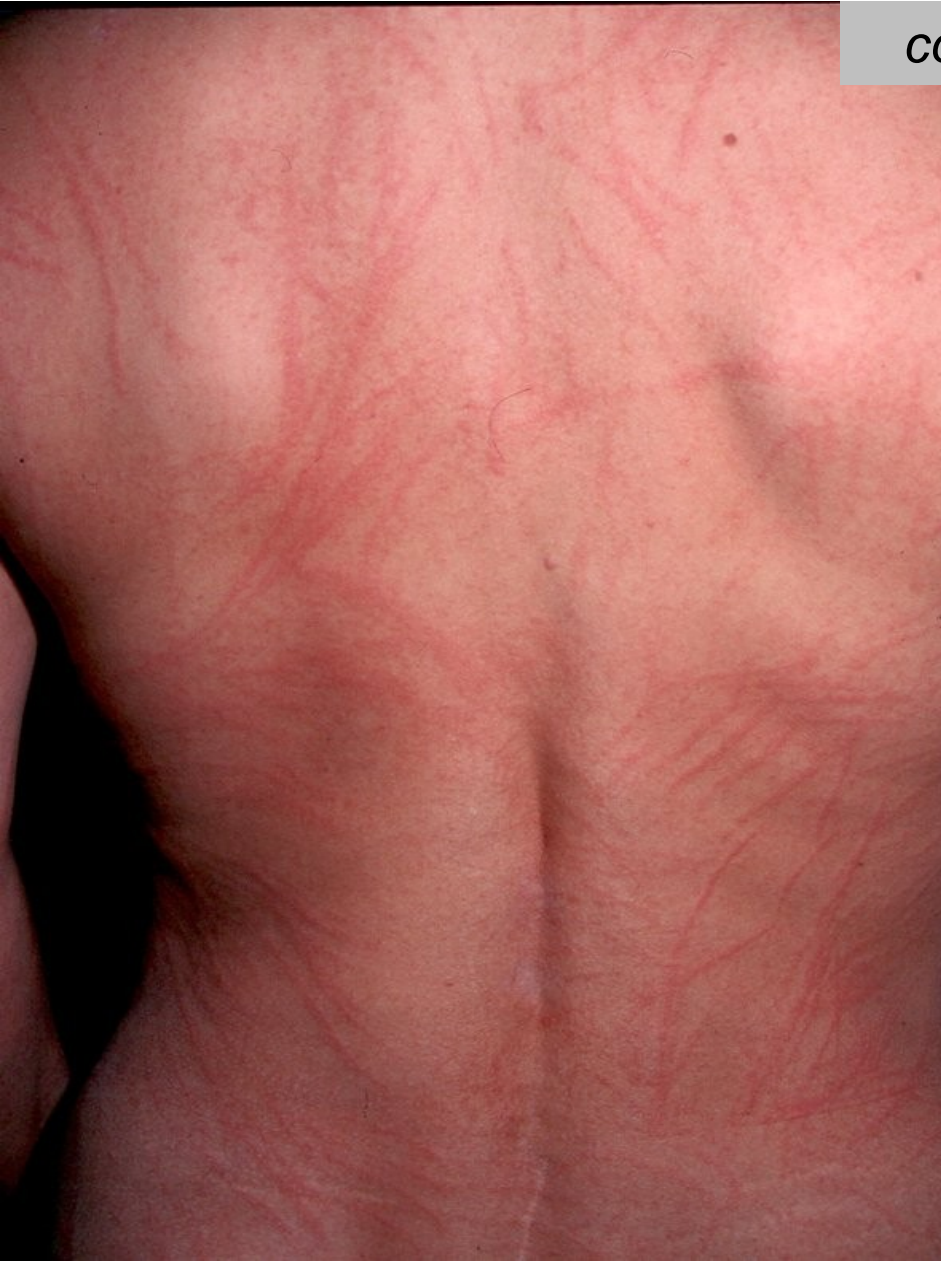
- × dermal (interstitial) edema
- × very sparse superficial perivascular and interstitial infiltrate consisting of mononuclear cells with neutrophils and sometimes with eosinophils
- × dermographism

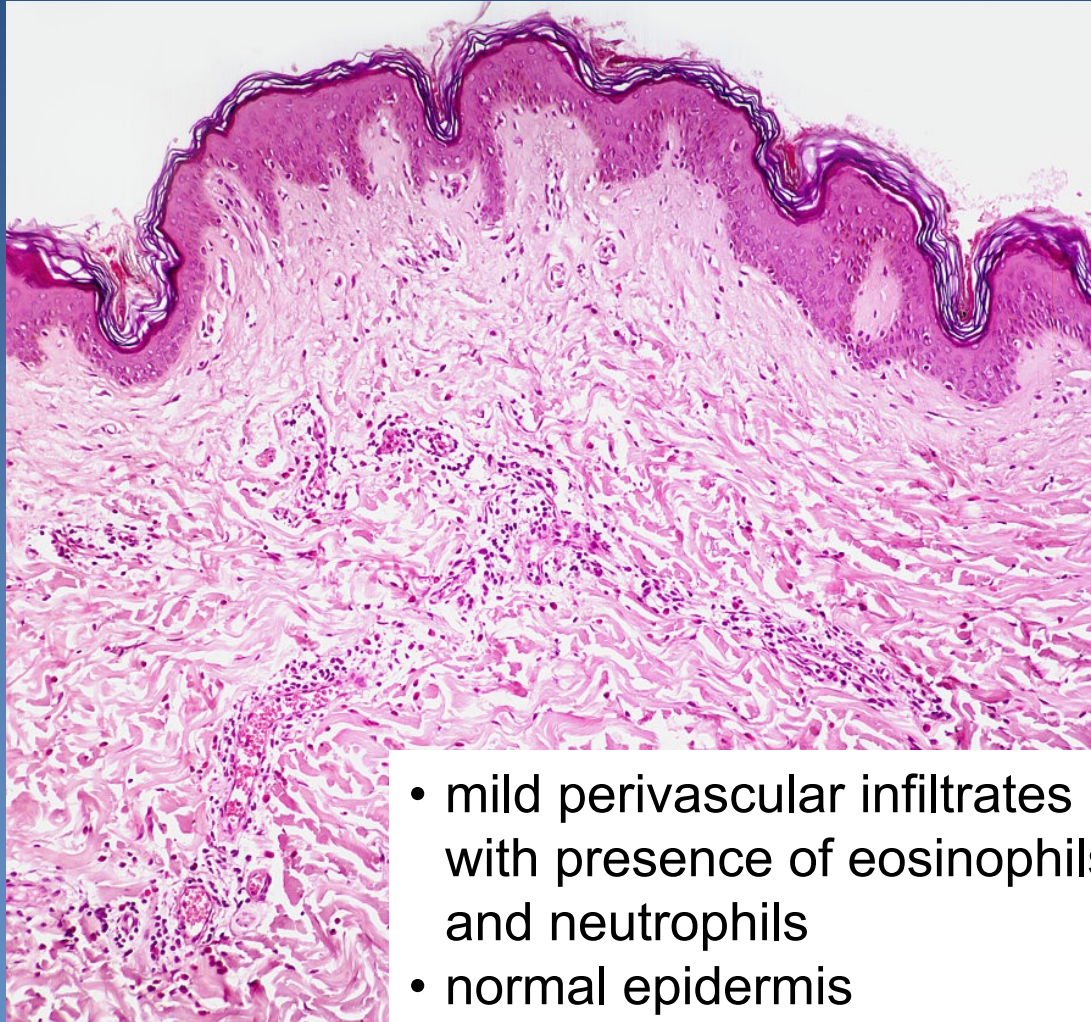
Urticaria (dermographism)



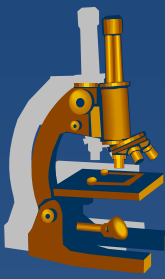
copy



Urticaria



- mild perivascular infiltrates with presence of eosinophils and neutrophils
- normal epidermis



Blistering (bullous) diseases

x sites of blister formation:

- ⇒ *subcorneal*
- ⇒ *suprabasal*
- ⇒ *subepidermal*

x causes:

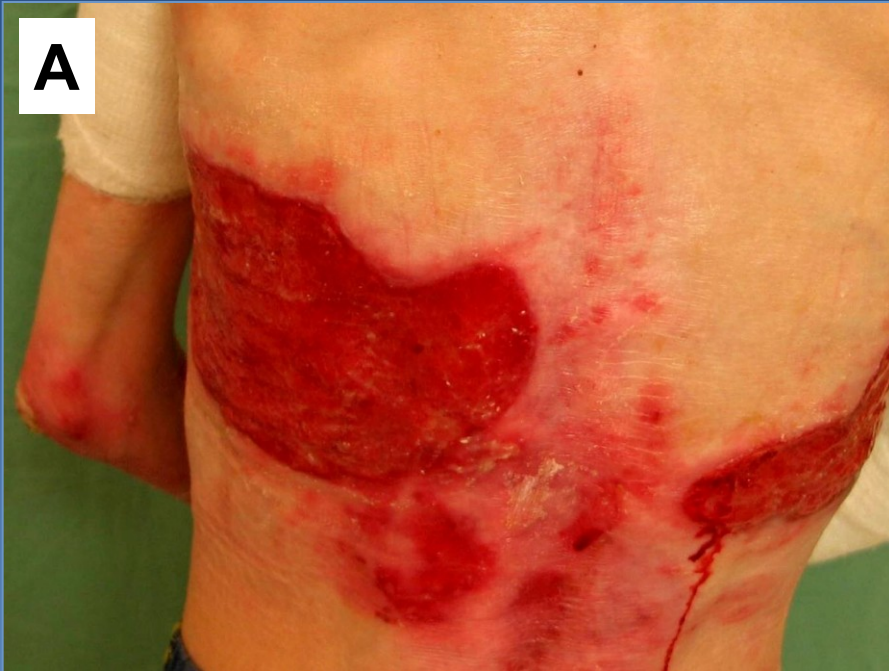- ⇒ *acantholysis* (dissolution of the intercellular bonds of the stratum spinosum)
- ⇒ *spongiosis* (intercellular edema of the epidermis)
- ⇒ *ballooning and reticular degeneration*
- ⇒ *cellular vacuolization of the basal cell layer*
- ⇒ *necrotic blisters*

Epidermolysis bullosa

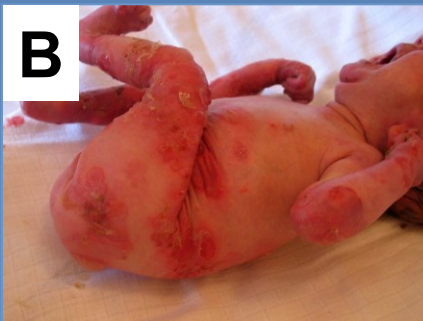

- ✗ group of non-inflammatory blistering disorders
- ✗ inherited defects in structural proteins lending mechanical stability to the skin
- ✗ blisters on the skin + mucosal membranes due to minimal trauma (pressure, rubbing)
- ✗ dg.
 - ⇒ *IF*
 - ⇒ *ELMI*
 - ⇒ *molecular-genetic methods*

Epidermolysis bullosa



A

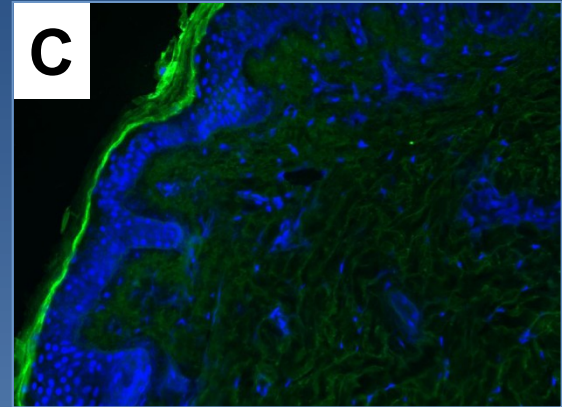


B

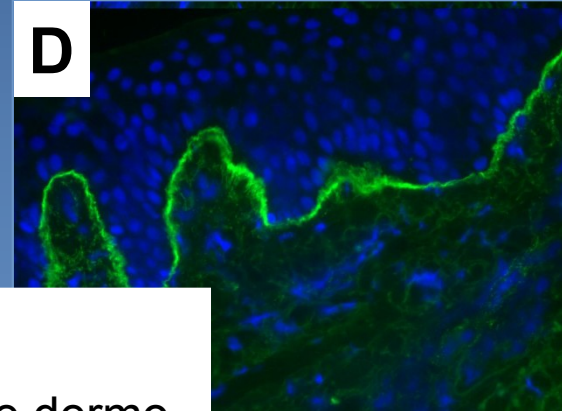
A, B: large erosions

C: collagen VII absence in the dermo-epidermal junction (IF)

D: collagen VII - positive control (IF)

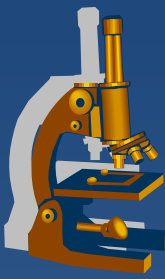


C



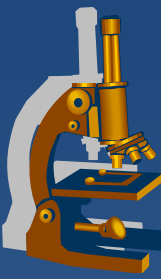
D

Pemphigus vulgaris

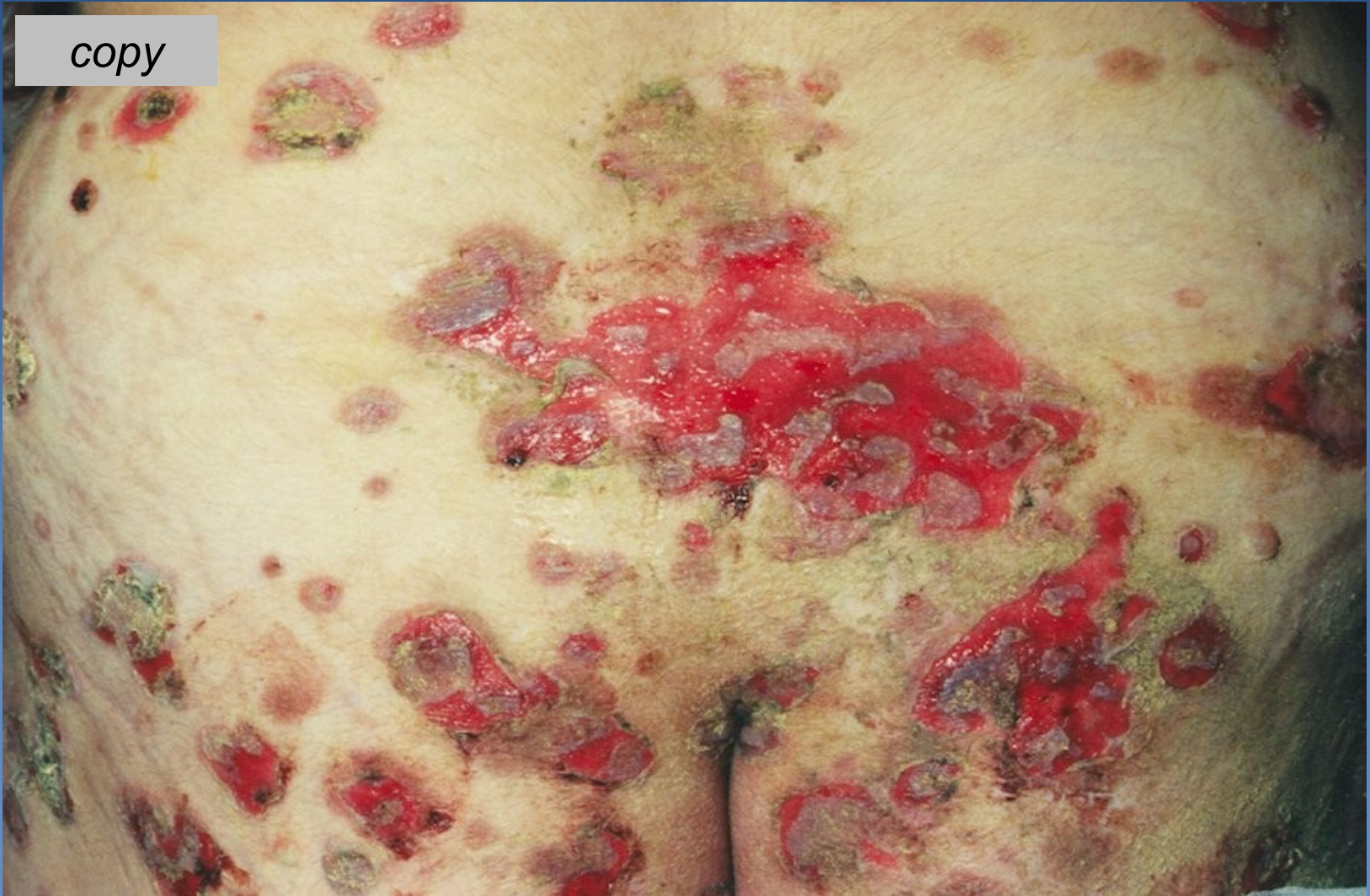


- × **life threatening disease, may start at any age (more common 4-6th decade)**
- × **repeated attacks**
- × **acantholysis → large blisters formation**
 - **loss of fluids, proteins; secondary infection**
- × **auto-antibodies → dissolution of desmosomes**
- × **suprabasal blisters (skin+mucosa – oral), frequent eosinophils**
- × **immunofluorescence**
 - ⇒ *intercellular IgG deposits between keratinocytes*

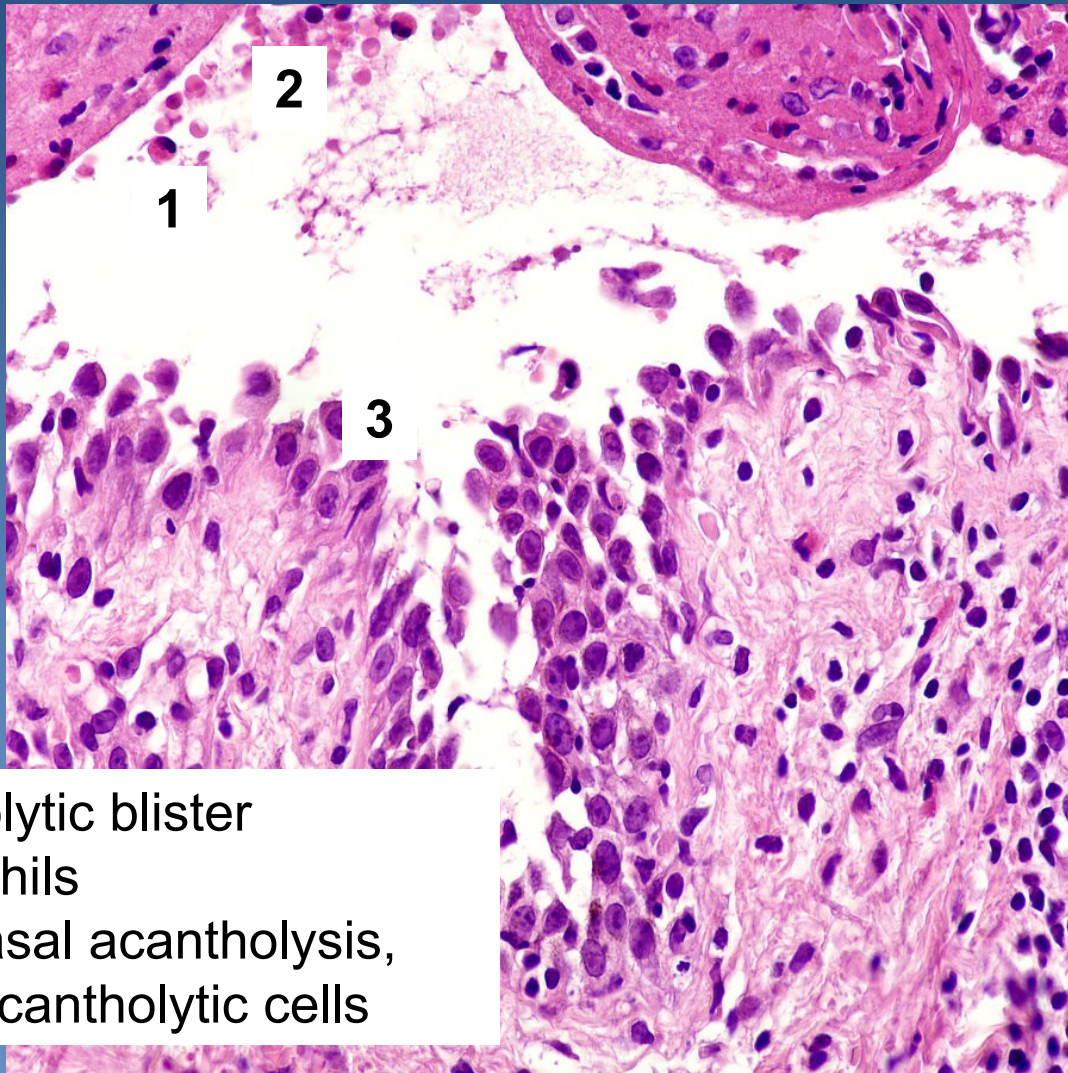
Pemphigus vulgaris



copy

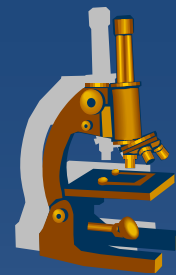


Pemphigus vulgaris



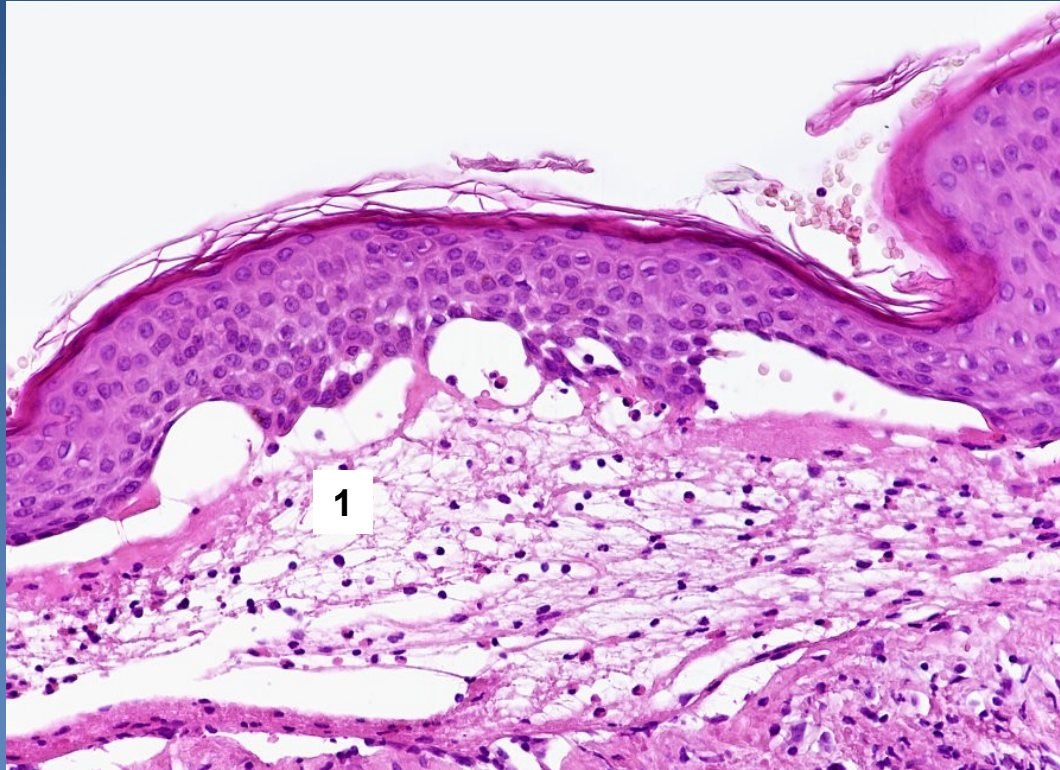
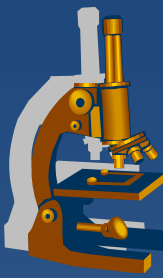
- 1 acantholytic blister
- 2 eosinophils
- 3 suprabasal acantholysis,
round acantholytic cells

Bullous pemphigoid



- ✗ chronic skin disease
- ✗ **benign affection** (x pemphigus vulgaris)
- ✗ patients mostly over 60 years; skin +/- mucosa
- ✗ **subepidermal** tense nonacantholytic blister,
numerous eosinophils (better healing)
- ✗ immunofluorescence: deposits of Ig, C3 along
the basement membrane, fibrin

Bullous pemphigoid



1 subepidermal blister – basal layer vacuolization
fibrin and eosinophils

2 inflammatory infiltrate (presence of
eosinophils)

Herpes simplex



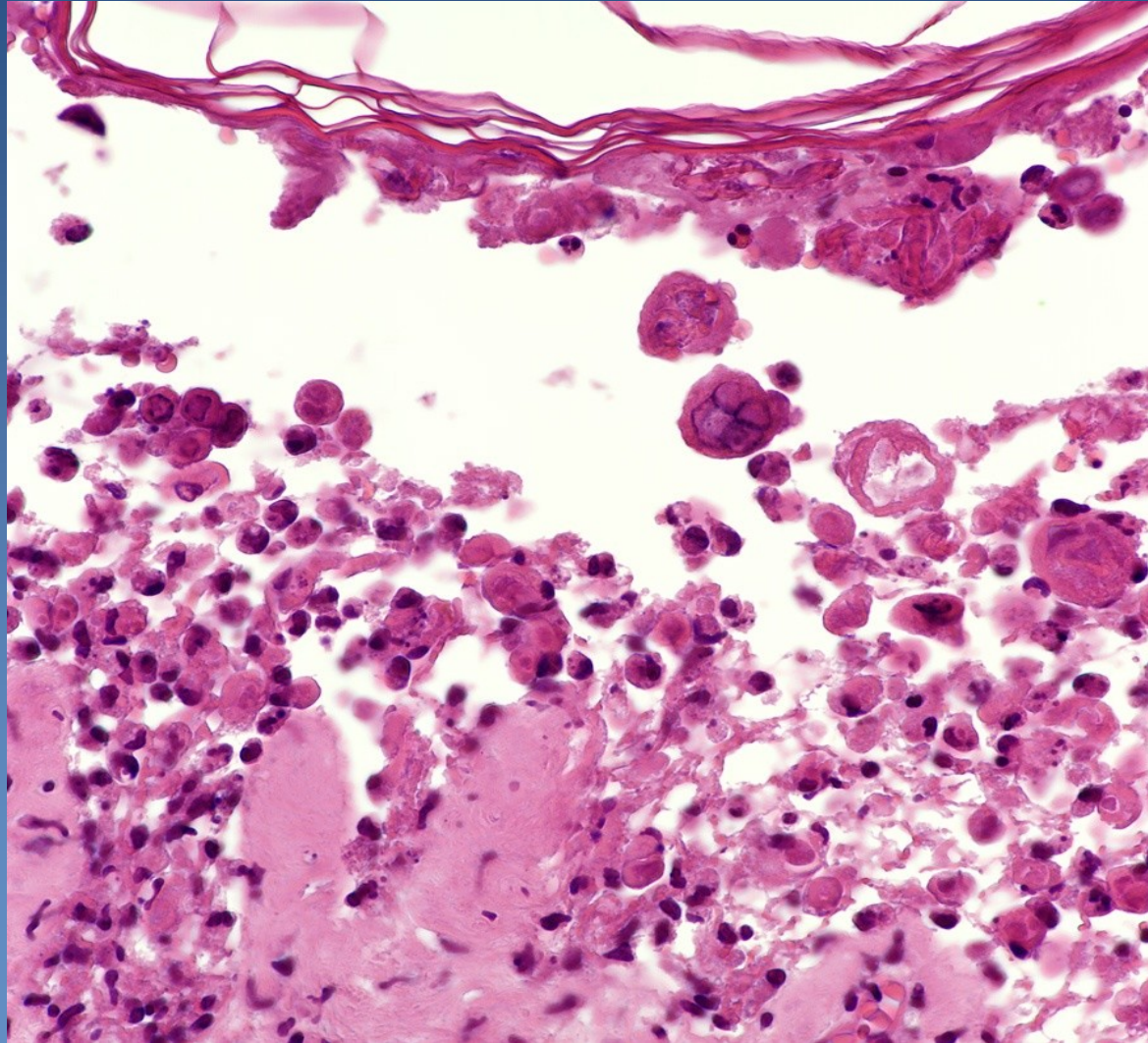
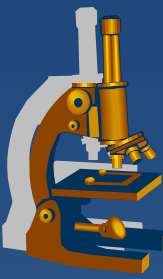
x recurrent disease, painful erythematous vesicles, often erosive

x localization

⇒ *lip border*

⇒ *anogenital region*

Herpes simplex



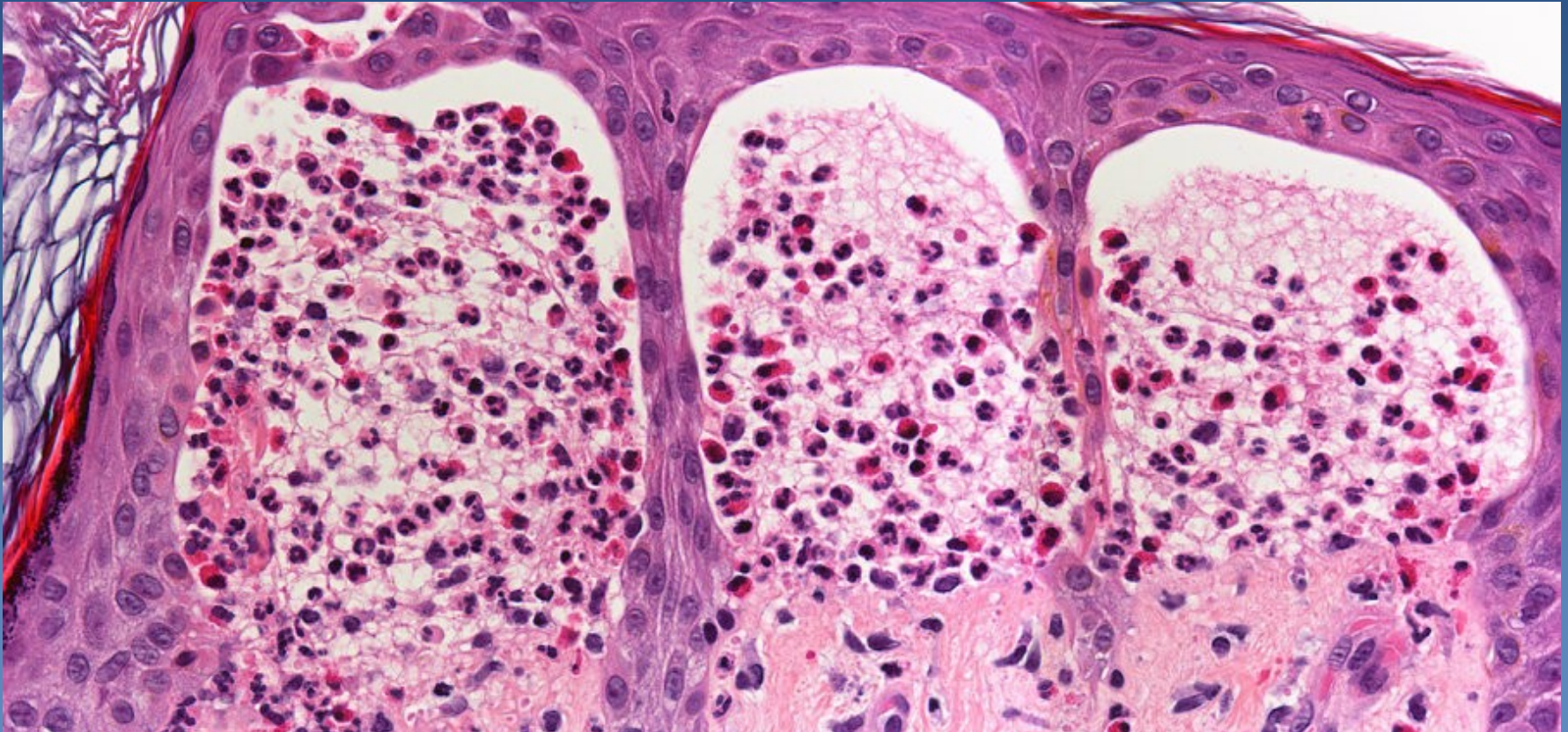
Dermatitis herpetiformis

Duhring



- ✗ chronic skin disease, urticaria + groups of vesicles
- ✗ **dietary gluten hypersensitivity**
(possible association with **celiac disease**)
- ✗ extreme **pruritus** (+ scratching excoriations)
- ✗ intrapapillary edema, subepidermal blister
- ✗ **numerous neutrophils** (at the tips of dermal papillae)
- ✗ immunofluorescence:
 - ⇒ *subepidermal IgA deposition*

Dermatitis herpetiformis



Intrapapillary edema and neutrophilic accumulation (small subepidermal vesicles)

Granulomas



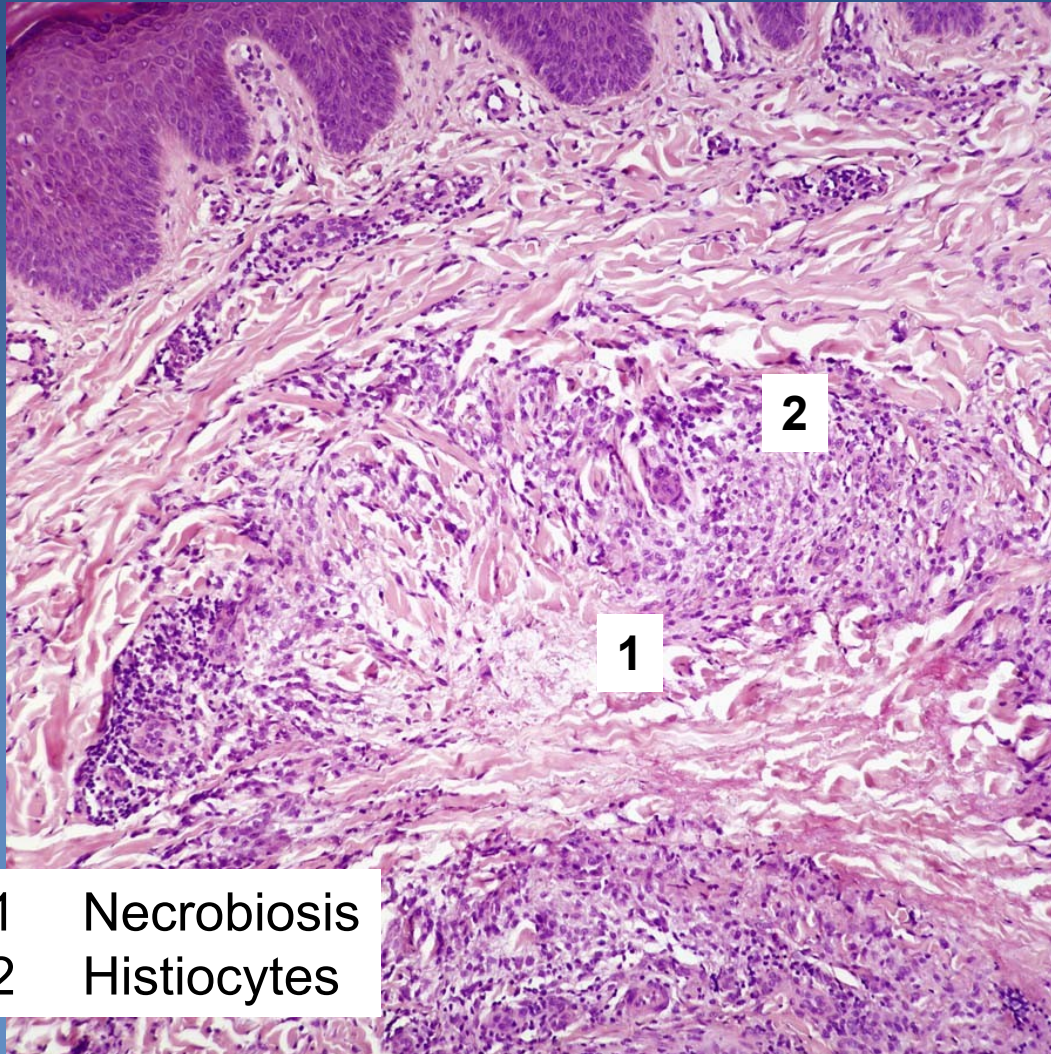
- ✗ chronic skin disease
- ✗ **dense accumulation of modified histiocytes in dermis**
- ✗ **histology:**
 - epitheloid granulomas
 - palisading granulomas
 - inflammatory granulomas
- **aetiology:**
 - ⇒ *infectious: mycobacteria, fungi*
 - ⇒ *non-infectious: foreign body*
 - ⇒ *uncertain immune-mediated origin*

Granuloma annulare



- ✗ **acquired** chronic skin disease of unknown aetiology
- ✗ **usually self-limited** (even spontaneously)
- ✗ **multiple round lesions with elevated borders**
- ✗ **micro:**
 - ⇒ ***palisading granuloma in the dermis***
 - poorly demarcated
 - centered to foci of necrobiosis (degenerated collagen)

Granuloma annulare



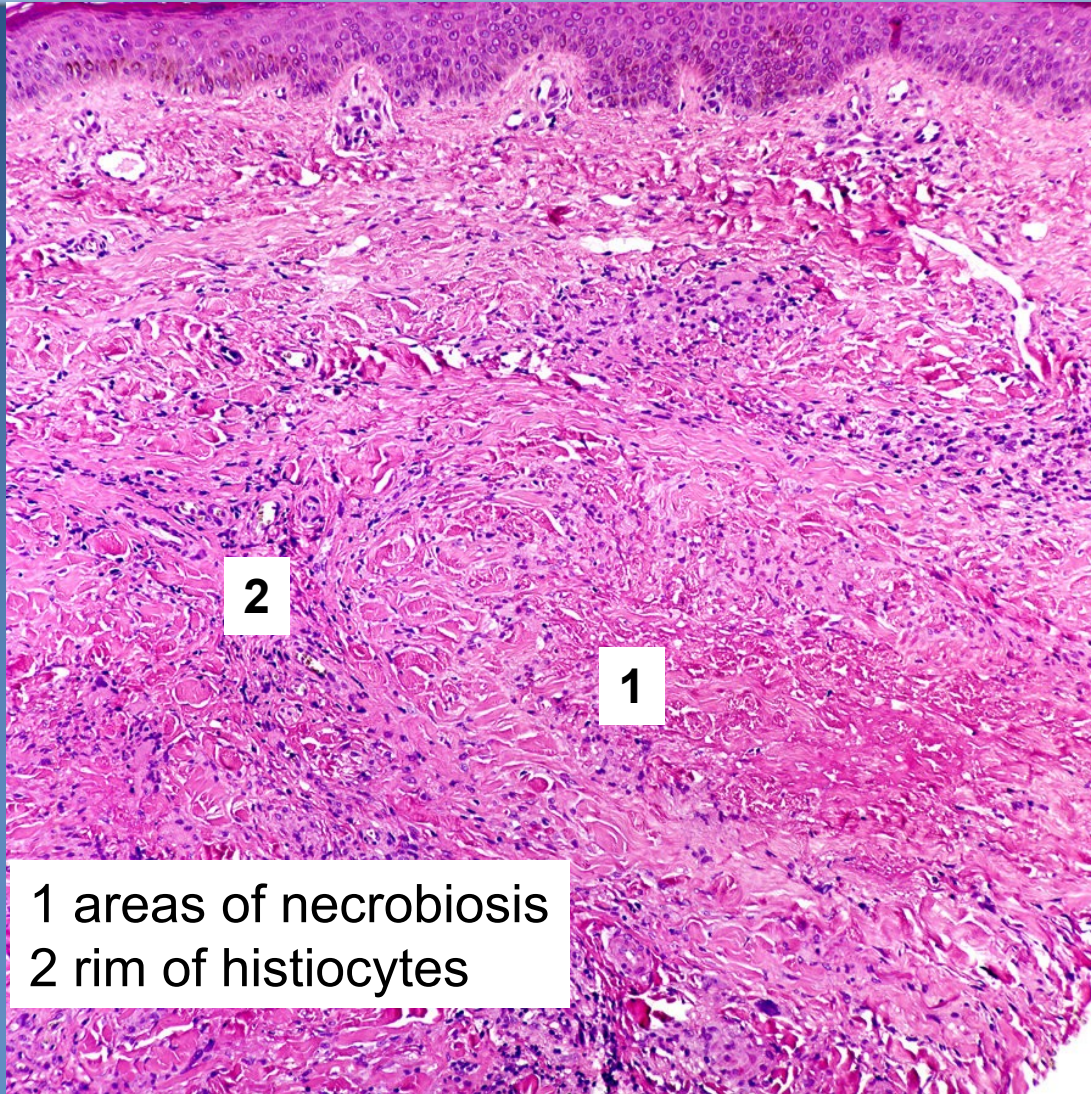
- 1 Necrobiosis
- 2 Histiocytes

Necrobiosis lipoidica



- ✗ **acquired** chronic skin disease
- ✗ often associated with **diabetes mellitus**, females
- ✗ **localization:**
 - ⇒ *crural region of legs*
- ✗ **micro:**
 - ⇒ *large areas of necrobiosis*
 - ⇒ *surrounding rim of histiocytes*
 - ⇒ *positive lipid stain*

Necrobiosis lipoidica



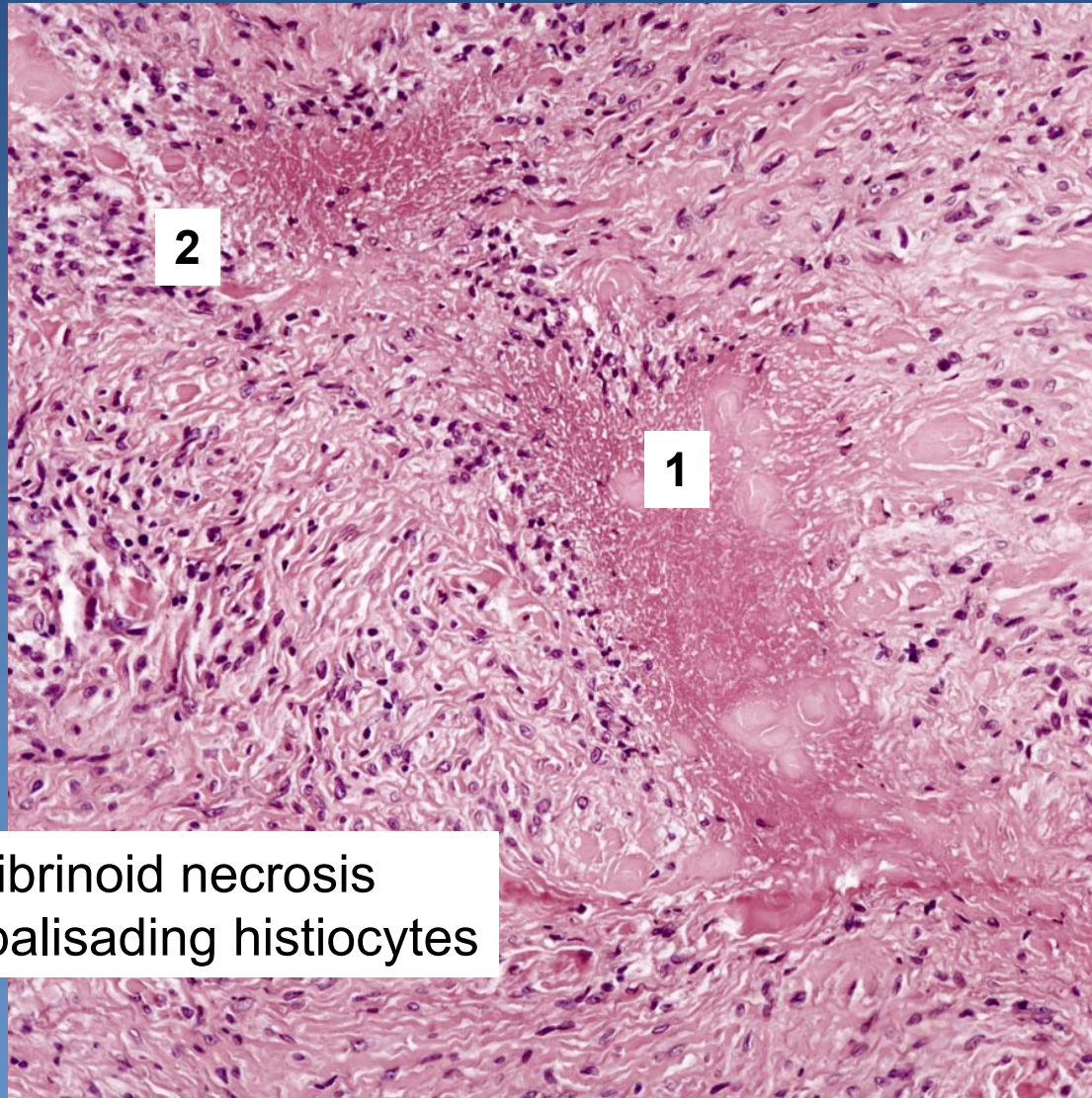
1 areas of necrobiosis
2 rim of histiocytes

Rheumatoid nodules



- × **patients with rheumatoid arthritis**
- × **localization:**
 - ⇒ *mostly extensor sites of limbs, but it can occur elsewhere (+ extracutaneous localization – diff. dg. x tumors)*
- × **nodules (mm-5cm) localized deep in dermis**
- × **micro:**
 - ⇒ *large palisading granulomas around fibrinoid necrosis*

Rheumatoid nodules

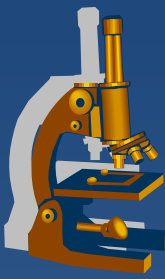


2

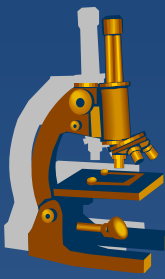
1

1 fibrinoid necrosis
2 palisading histiocytes

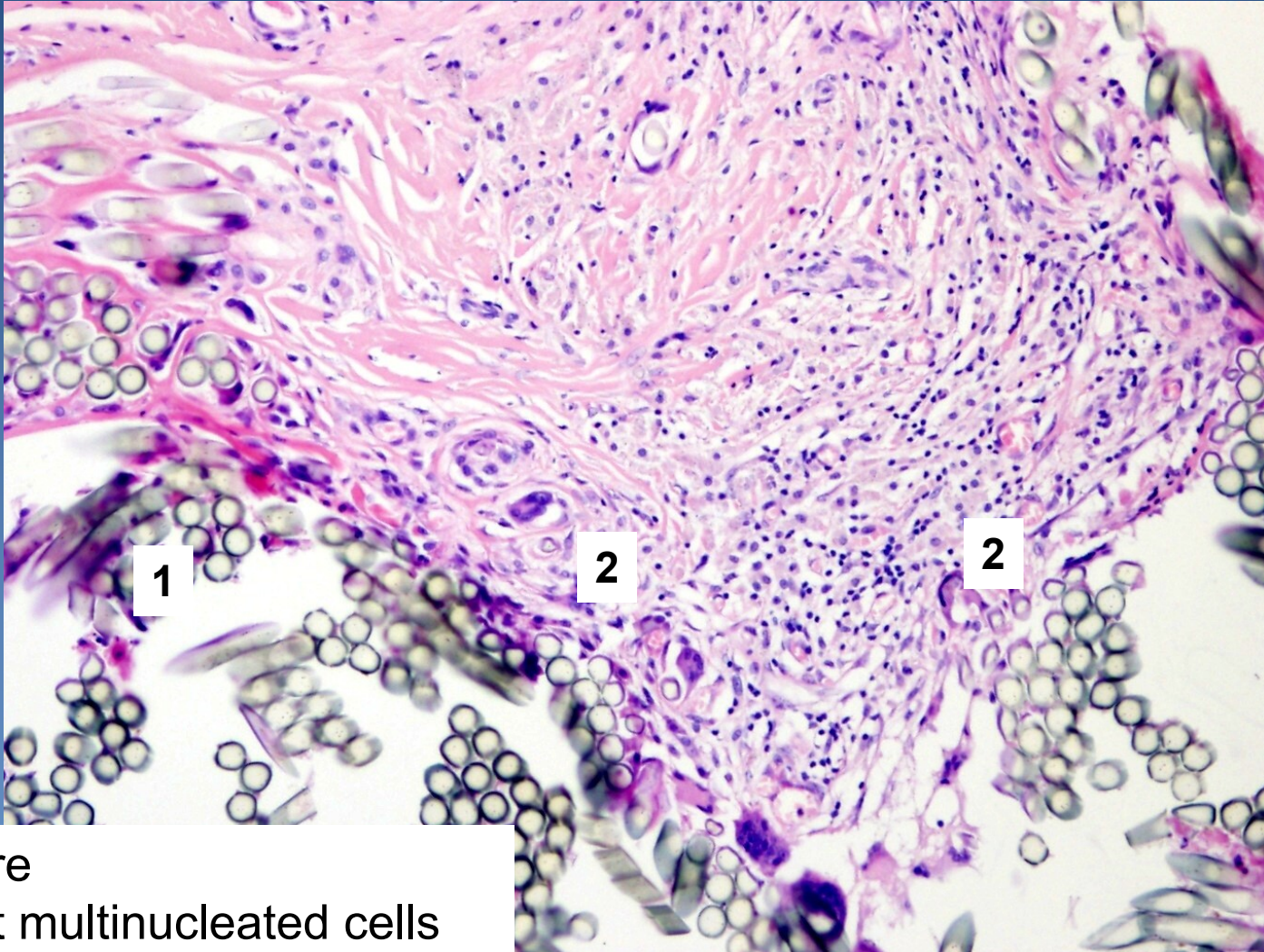
Foreign body granuloma



- × **epithelioid granulomas surrounding** foreign material
- × **multinucleated giant cells**
- × foreign material can often be visualized by **polarized light**
- × process often **associated with purulent inflammation**
- × **example:**
 - ⇒ *Schloffer`s pseudotumor around suture material*



Schloffer`s pseudotumor

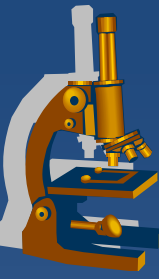


1

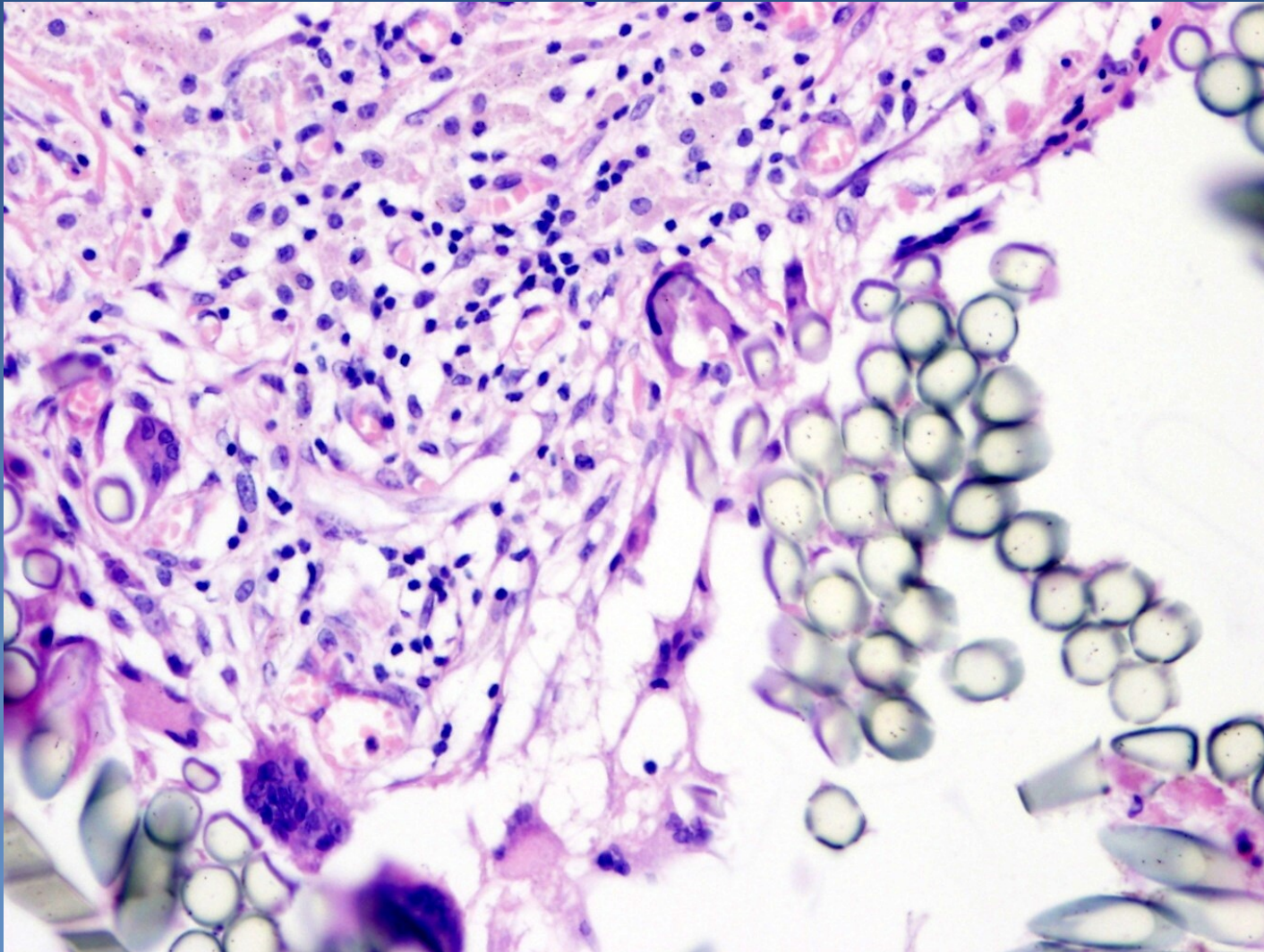
2

2

- 1 Suture
- 2 Giant multinucleated cells



Schloffer`s pseudotumor



Lupus erythematosus

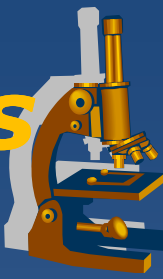

- × chronic **autoimmune** multisystem disease
 - ⇒ *kidney, skin, joints, lungs, heart, serosal membranes, mucous membranes, CNS*

- × clinic:
 - ⇒ *acute onset*
 - ⇒ *subacute*
 - ⇒ *chronic (insidious onset)*

Systemic lupus erythematosus

SLE



x etiology:

- ⇒ *failure of the self-tolerance mechanism*
- ⇒ *genetic predisposition + unknown trigger*
- ⇒ *CMV?, EBV?, hereditary factors, female hormones?*

x clinic:

- ⇒ *remitting, relapsing disease*
- ⇒ *fever, muscle pain, arthralgia – diff. dg. x **sepsis!***
- ⇒ *seizures- diff. dg. x **epilepsy!***
- ⇒ *antinuclear and antiphospholipid antibodies, anemia, leukopenia, thrombocytopenia*

SLE



x skin:

- ⇒ *involved in 80% of patients*
- ⇒ specific: *maculopapular exanthema in face (“butterfly pattern”); UV-sensitive*
- ⇒ nonspecific: *chronic skin ulcers*

x heart:

- ⇒ *pericarditis, myocarditis*
- ⇒ *Libman-Sacks verrucous non-bacterial endocarditis*

x lungs:

- ⇒ *pleuritis, lupus pneumonitis*

SLE



- × **kidney:**

 - ⇒ *lupus nephritis*

- × **CNS involvement**

 - ⇒ *various symptoms*

- × **hematologic disorders:**

 - ⇒ *anemia, leukocytopenia, lymphocytopenia, thrombocytopenia, antiphospholipid antibodies*

- × **joint involvement**

 - ⇒ *arthralgia, migrating polyarthritits, joint deformity, diff. dg. x rheumatoid arthritis*

SLE



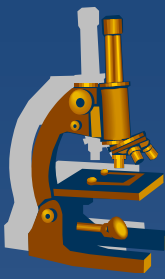
x micro:

⇒ *hyperkeratosis*

⇒ *atrophy of the basal epidermal layer*

⇒ *dermal edema*

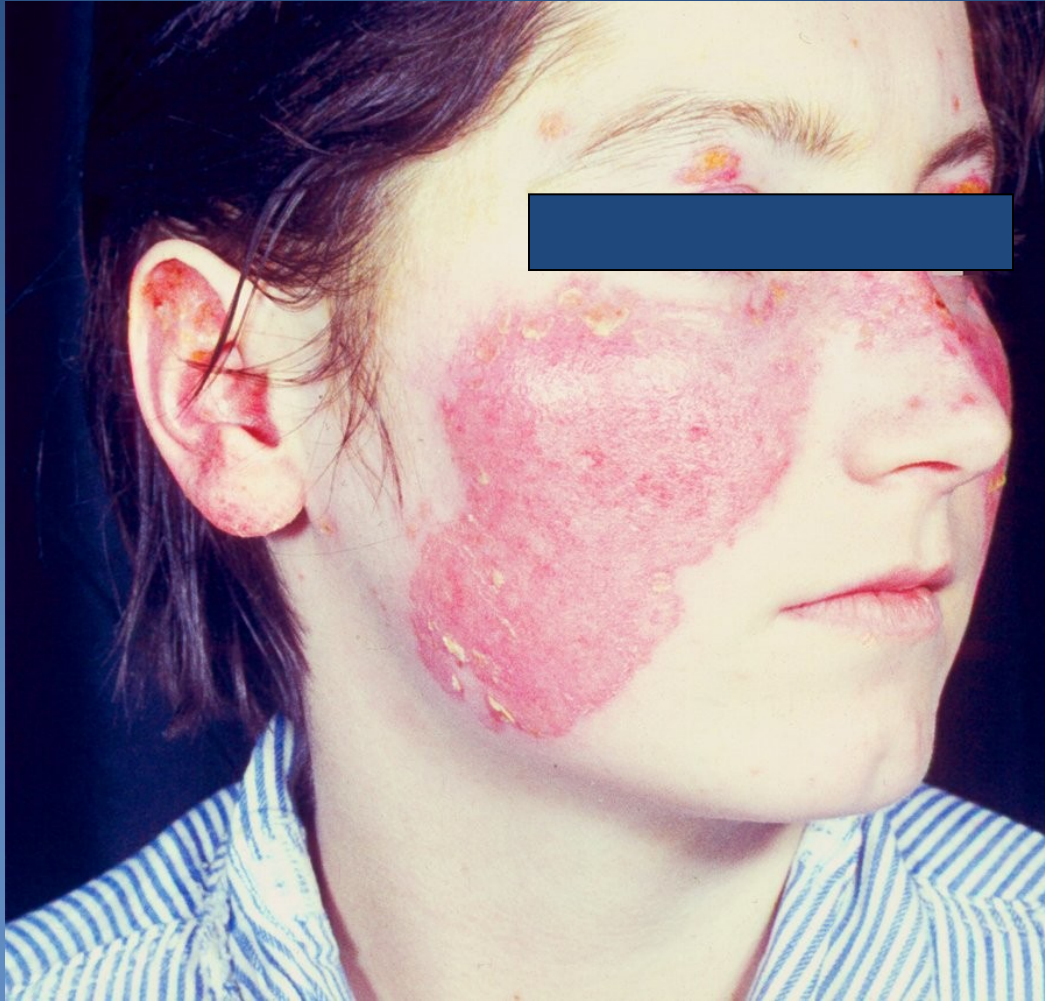⇒ *periadnexal lymphocytic infiltrate*



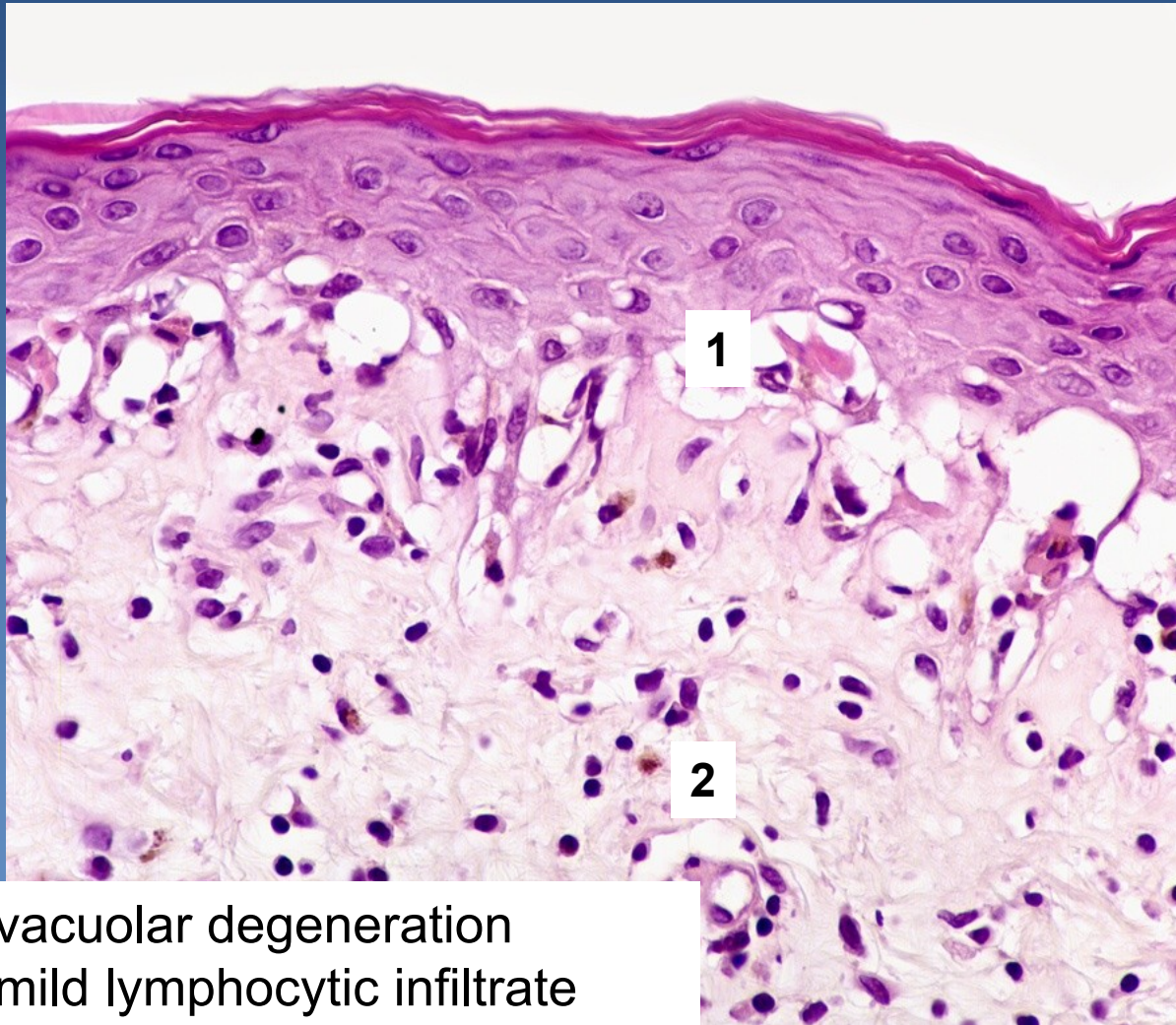
Discoid lupus erythematosus

- x form of lupus limited to the skin**
- x** antinuclear antibody positivity in 70%
 - ⇒ ***negative SLE specific antibodies***
- x clinic:**
 - ⇒ ***chronic disease, relapsing and remitting***
 - ⇒ ***transform in systemic form in 5-10% of patients (after 10-20 years)***

SLE – exanthema ("butterfly pattern")

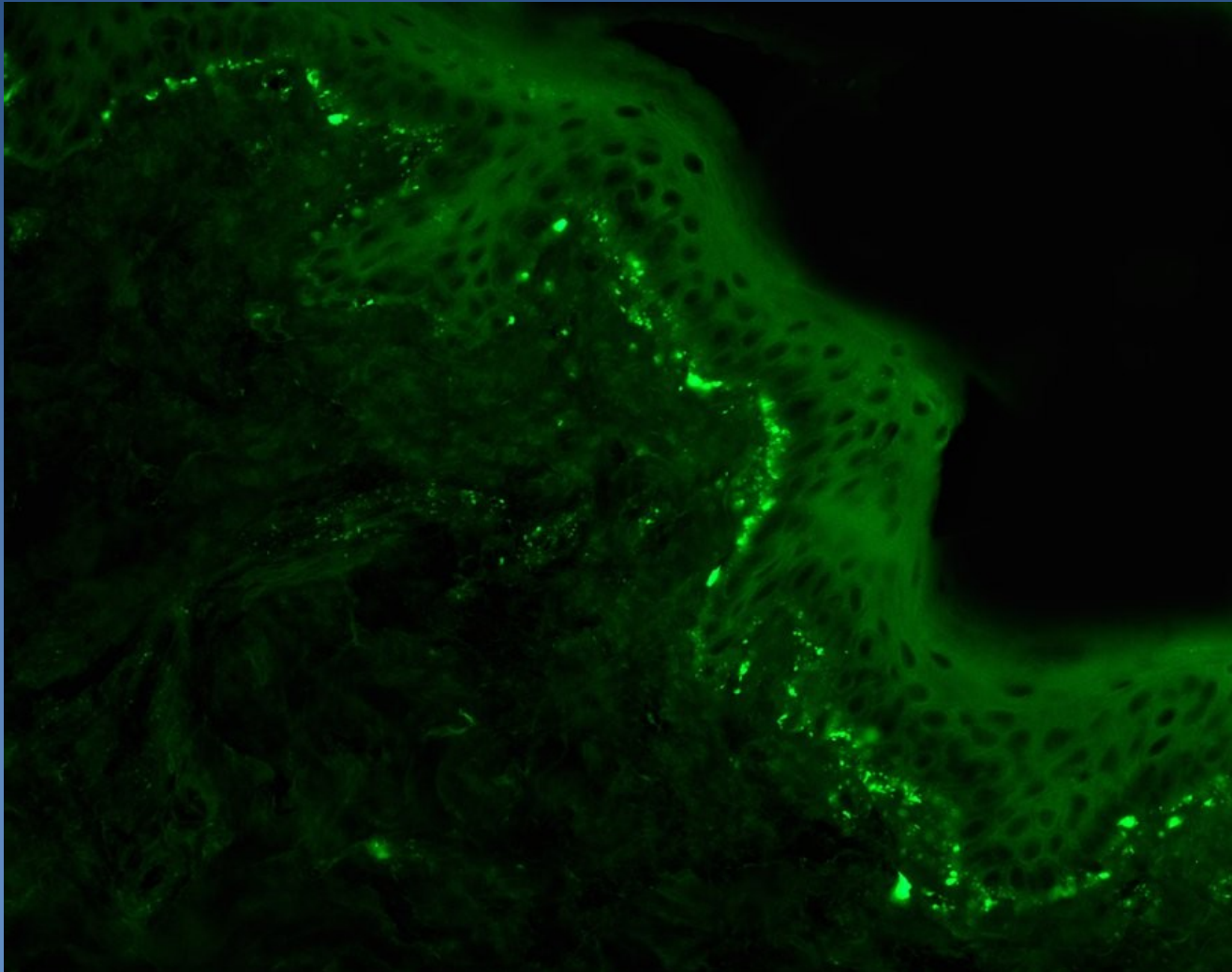


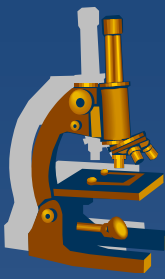
SLE – acute form



- 1 vacuolar degeneration
- 2 mild lymphocytic infiltrate

SLE – Immunofluorescence (lupus band)





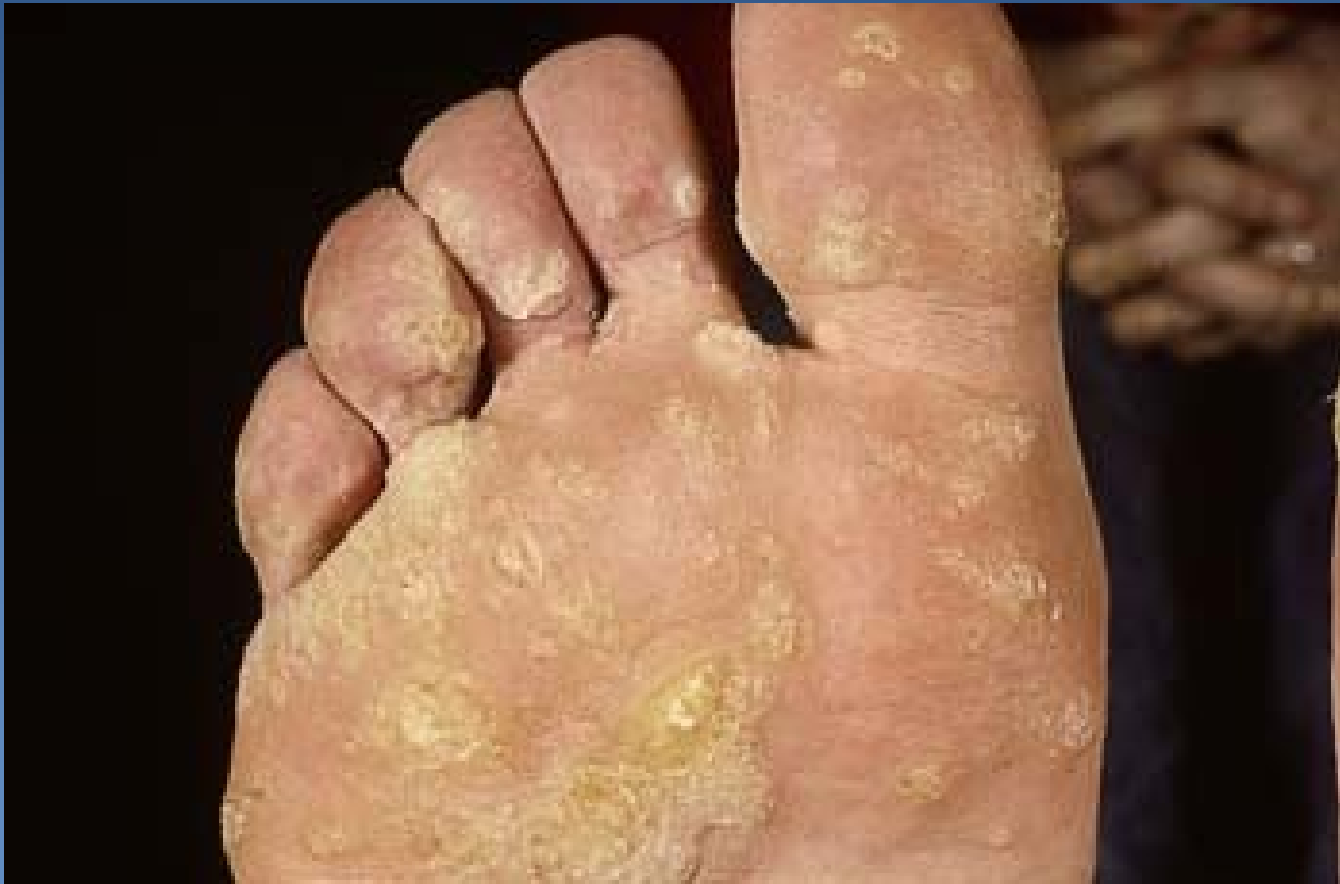SKIN - TUMORS

Verruca vulgaris

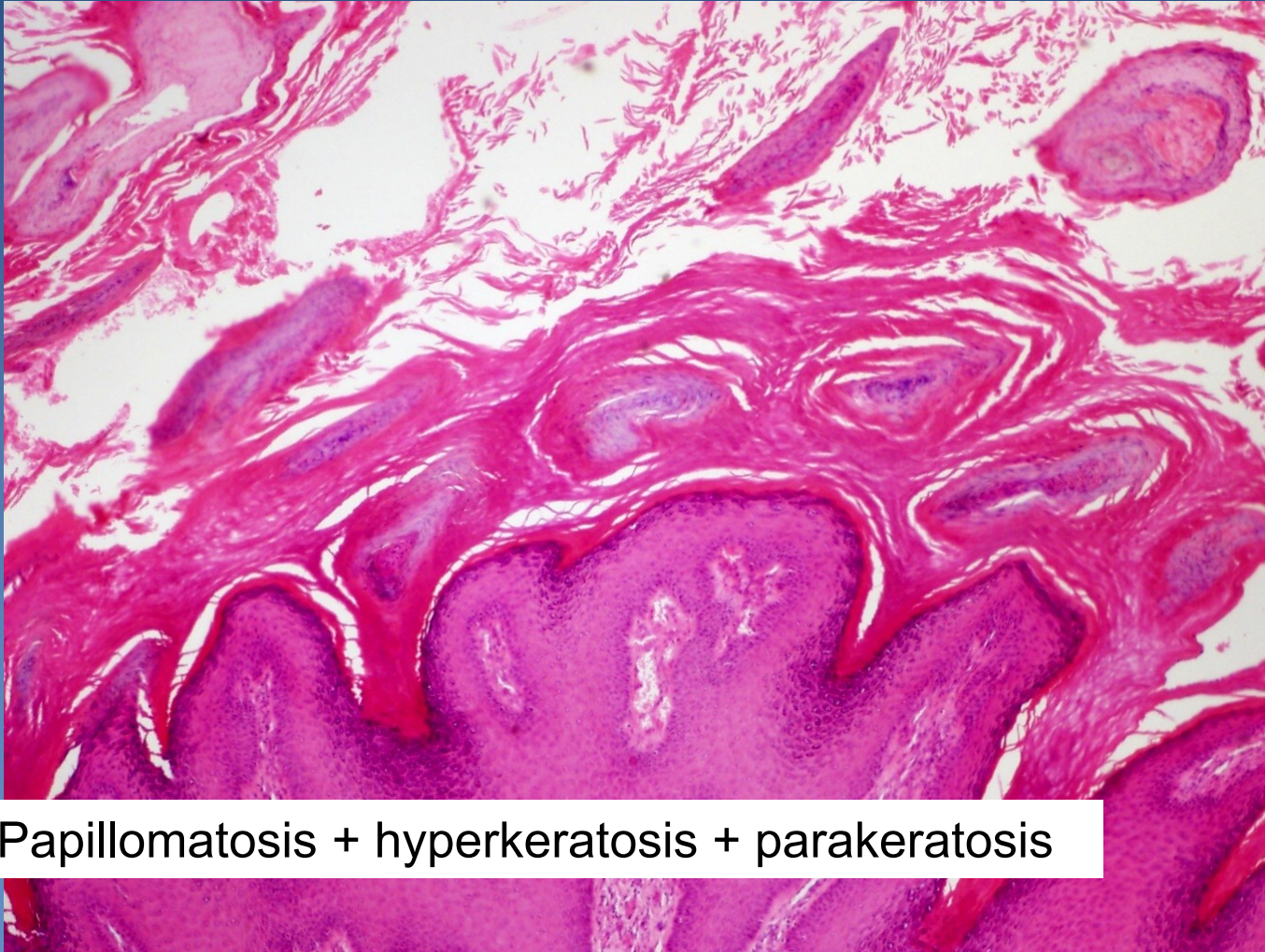


- × caused by **HPV** (type 2, less often type 1, 4, 7...)
- × **transmission**: direct contact, autoinoculation
- × **most frequent localization**: fingers, feet
- × **gross**:
 - ⇒ *warty papule with a rough surface , gray-white to tan, skin color*
- × **micro**:
 - ⇒ *papillomatous (verrucous) epidermal hyperplasia with **acanthosis**, **hyperkeratosis** and **parakeratosis***
 - ⇒ *intracytoplasmatic viral inclusions*
 - ⇒ *reactive mononuclear infiltrate in dermis and interstitium*

Plantar verruca

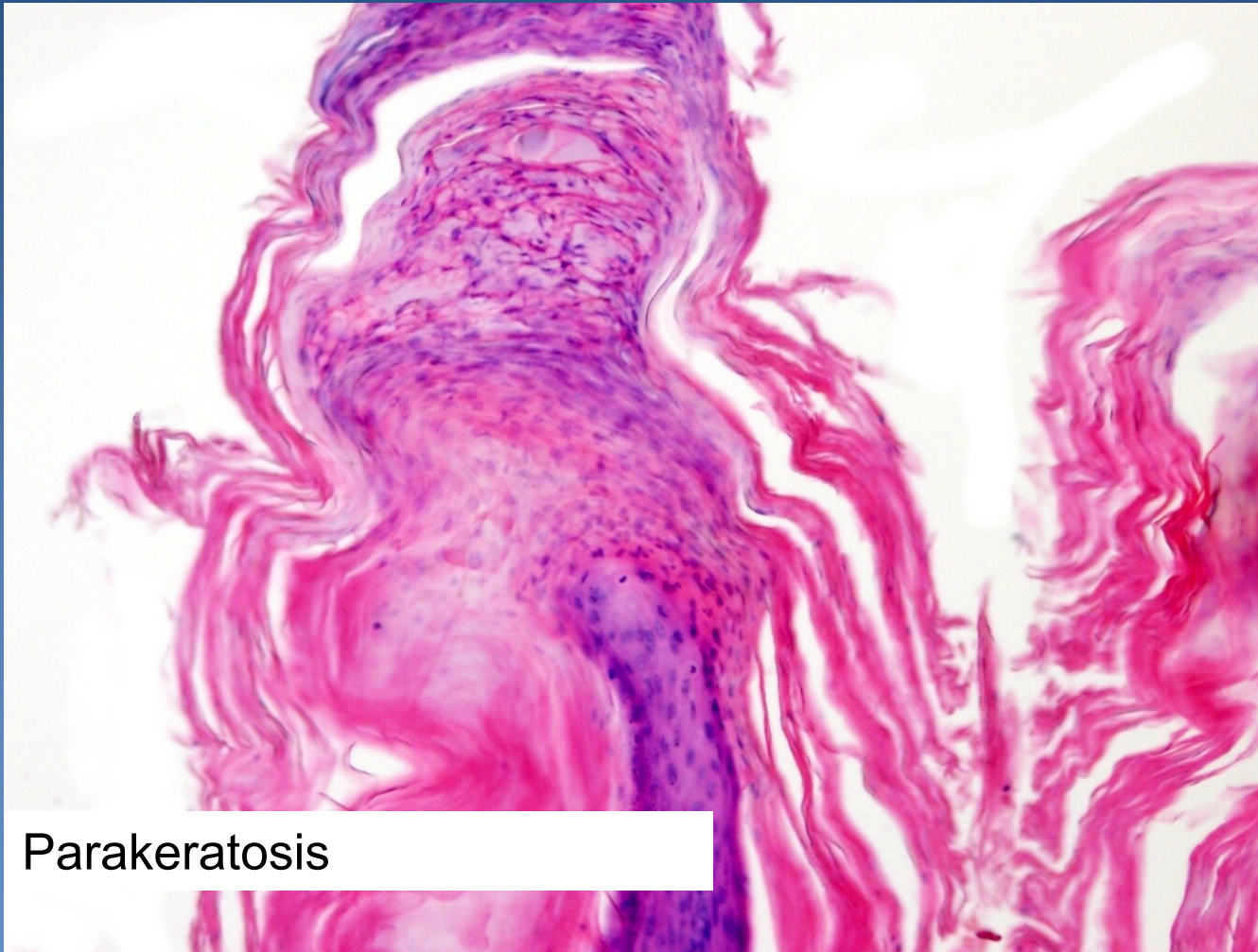
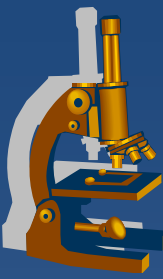


Verruca vulgaris



Papillomatosis + hyperkeratosis + parakeratosis

Verruca vulgaris



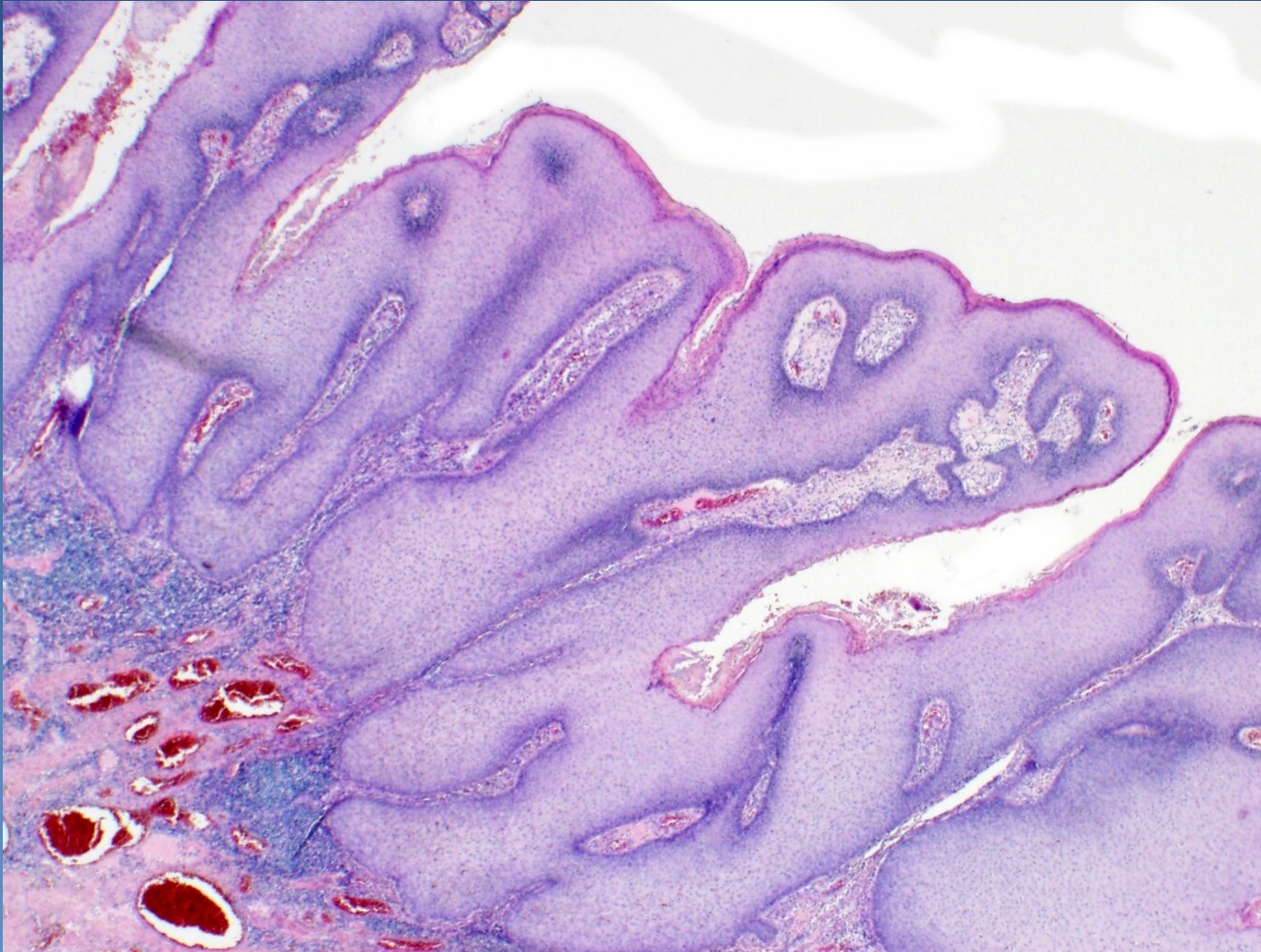
Parakeratosis

Condyloma accuminatum

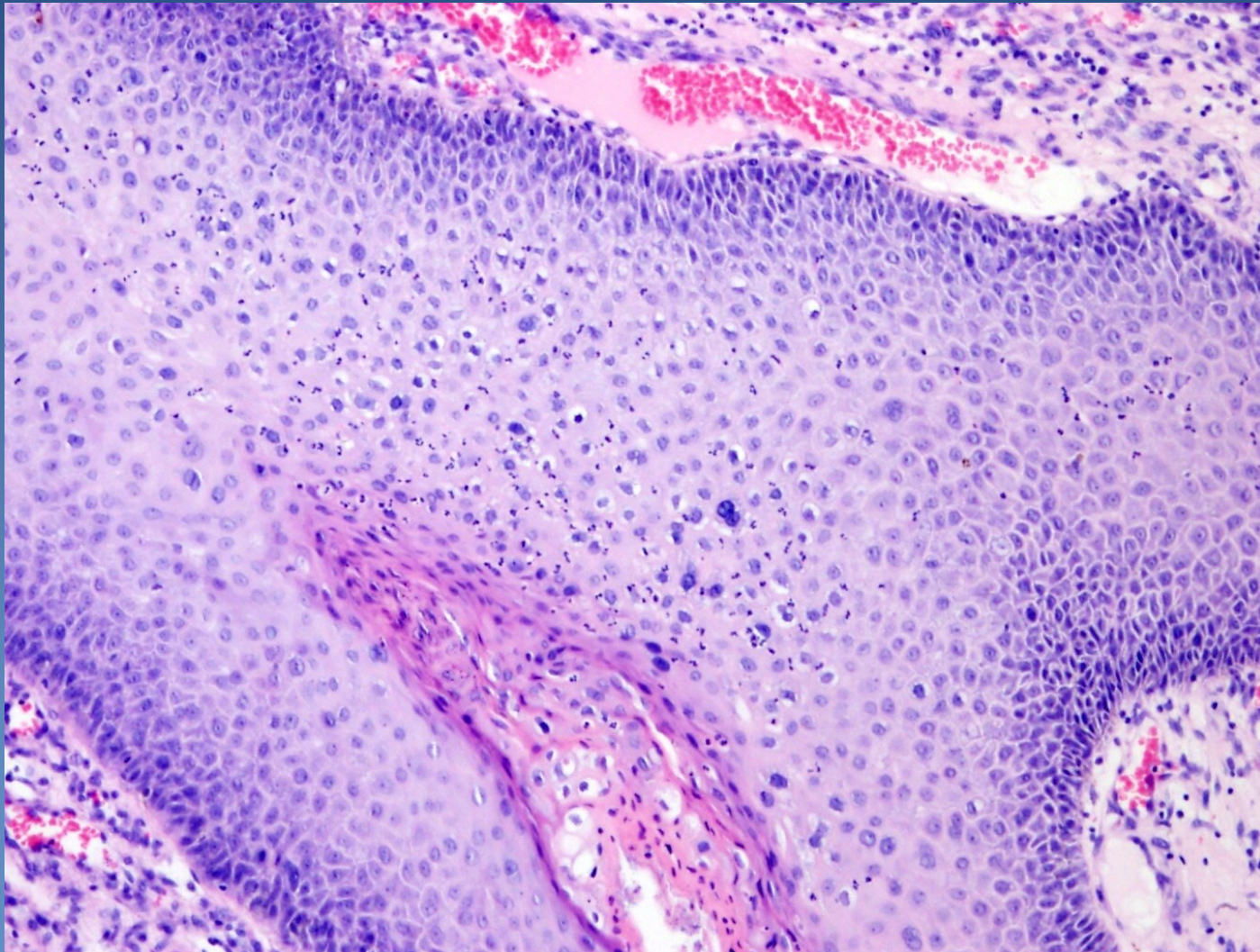


- ✗ caused by **HPV**, mainly type **6,11** etc. - localized in **anogenital region**
- ✗ **sexually transmitted disease**
 - ⇒ *venereal wart, incubation time 2-3 months*
- ✗ **gross:**
 - ⇒ *wart-like (often multiple) lesion in typical localization*
- ✗ **micro:**
 - ⇒ *koilocytes*
 - cells with shrank dark nuclei surrounded with empty “halo”, bi- or multinucleated cells
 - ⇒ *hyper-, para- and dyskeratosis*

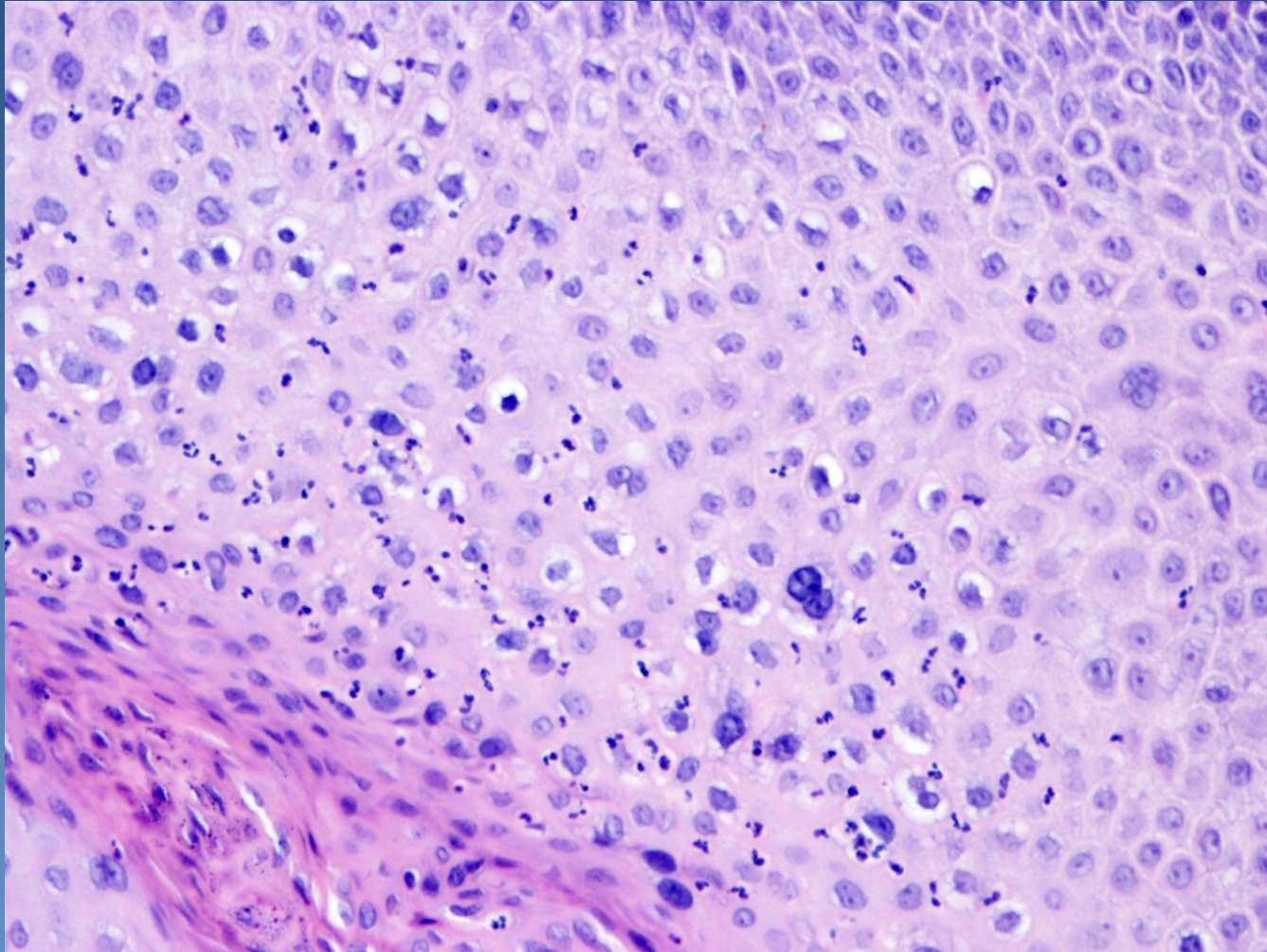
Condyloma accuminatum



Condyloma accuminatum



Condyloma accuminatum

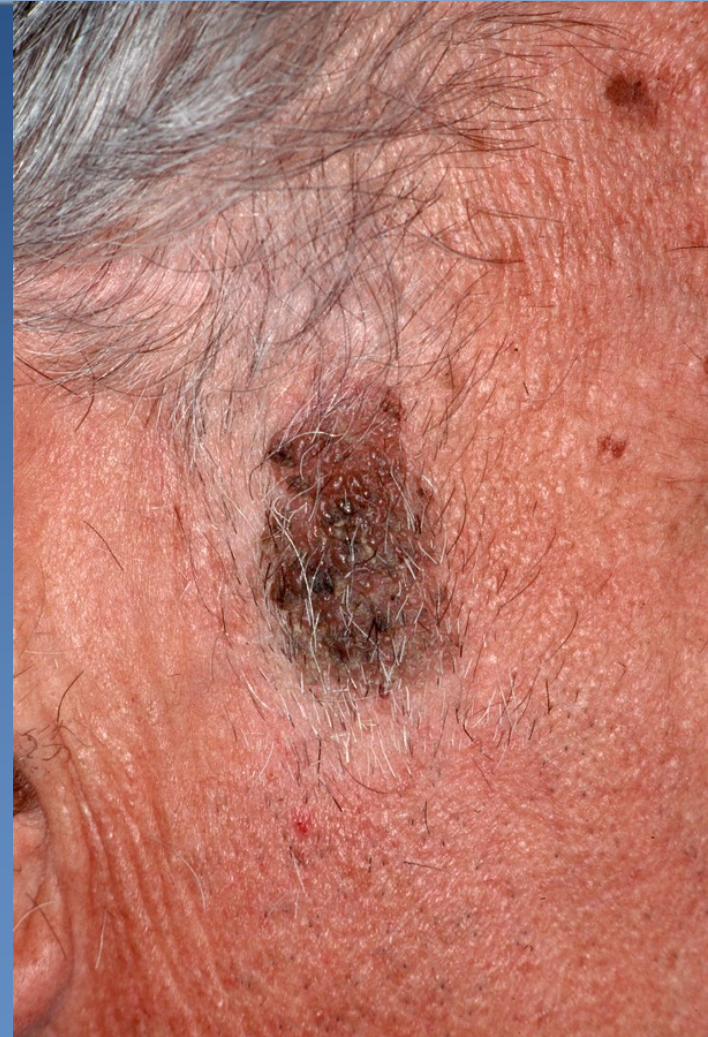
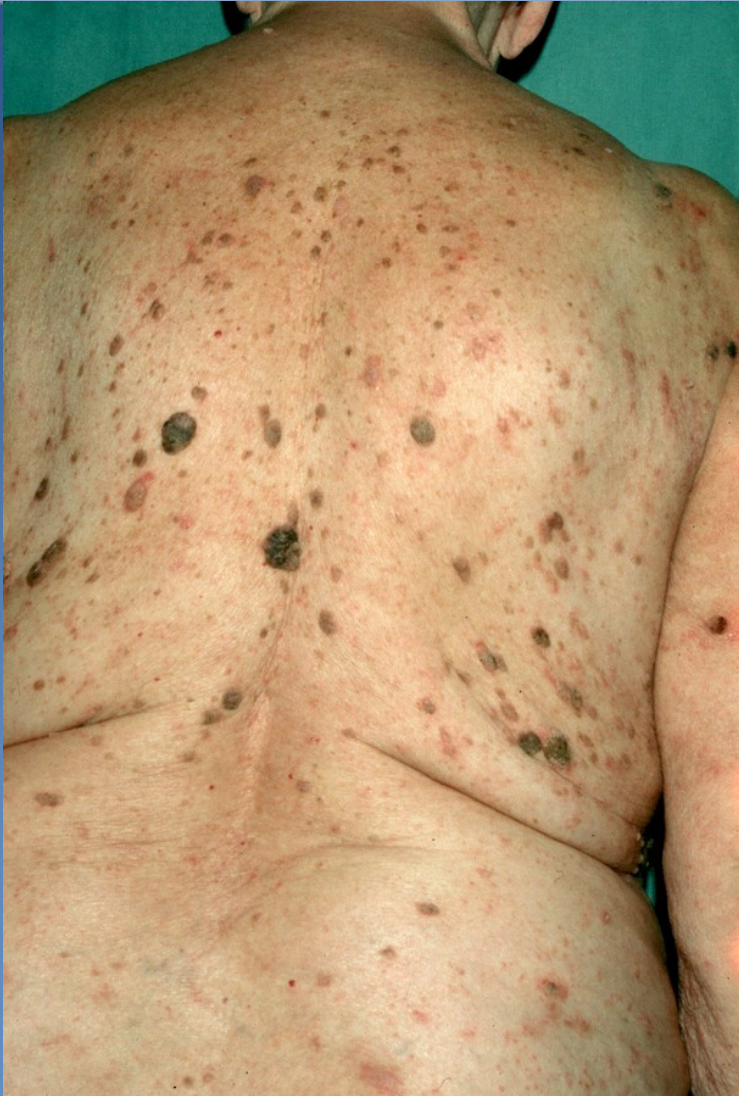
Seborrheic keratosis

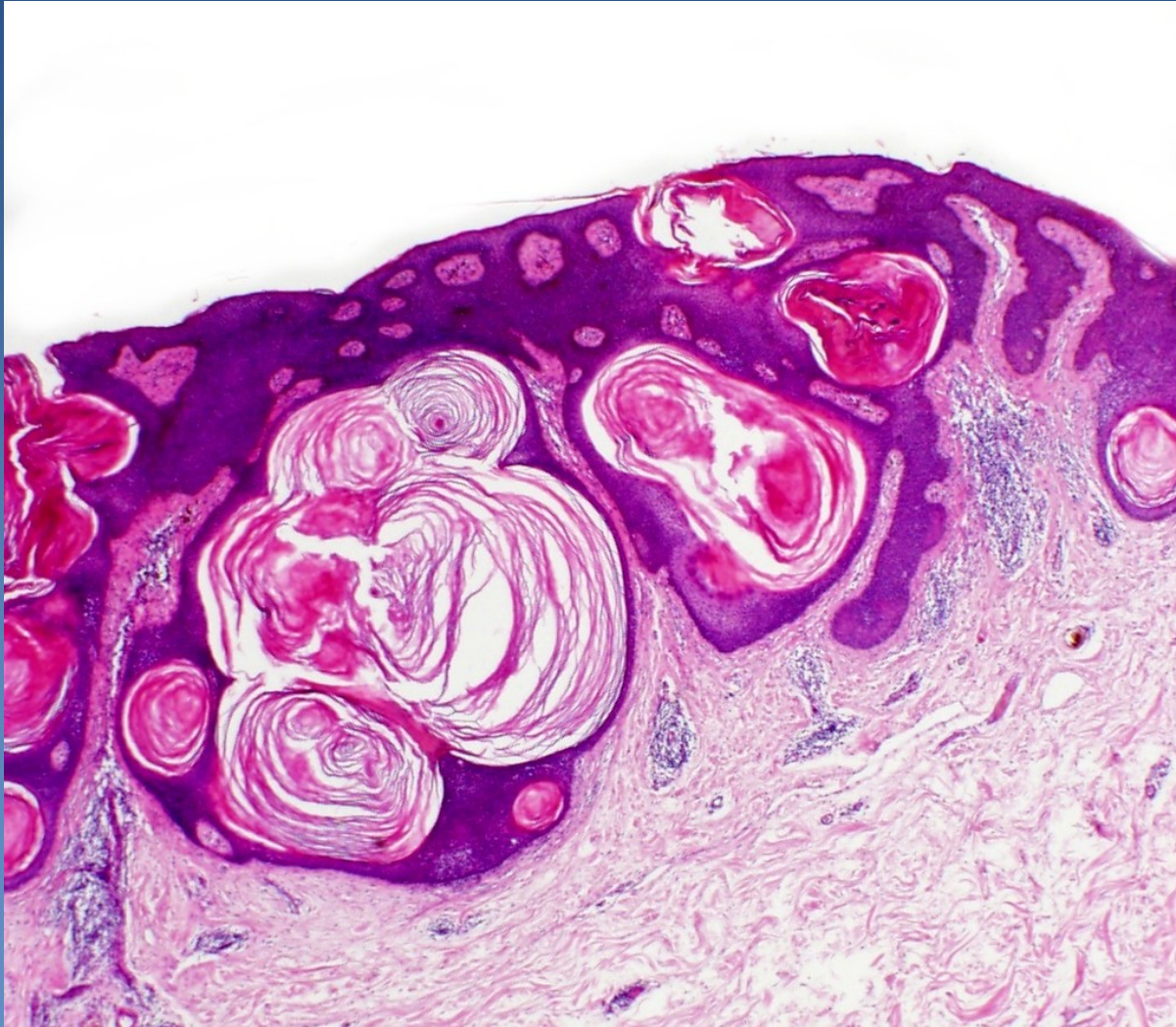


- × **common benign cutaneous tumor**
- × **gross:**
 - ⇒ *well demarcated hyperpigmented papule of “greasy waxy appearance”*
- × **micro:**
 - ⇒ *hyperkeratosis, papillomatosis, acanthosis*
 - ⇒ *formation of „horn“ cysts filled with keratin lamellae*
 - ⇒ *variable melanin pigmentation often present*

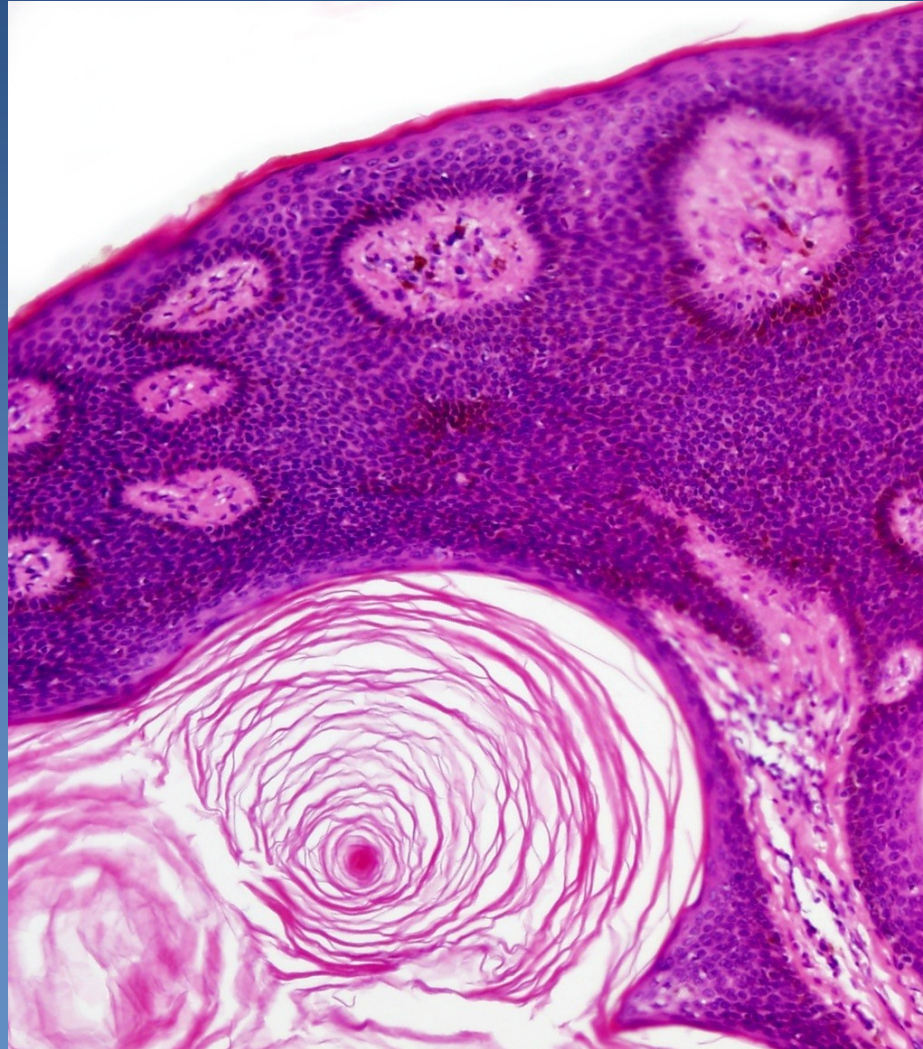
Seborrheic keratosis



Seborrheic keratosis



Seborrheic keratosis

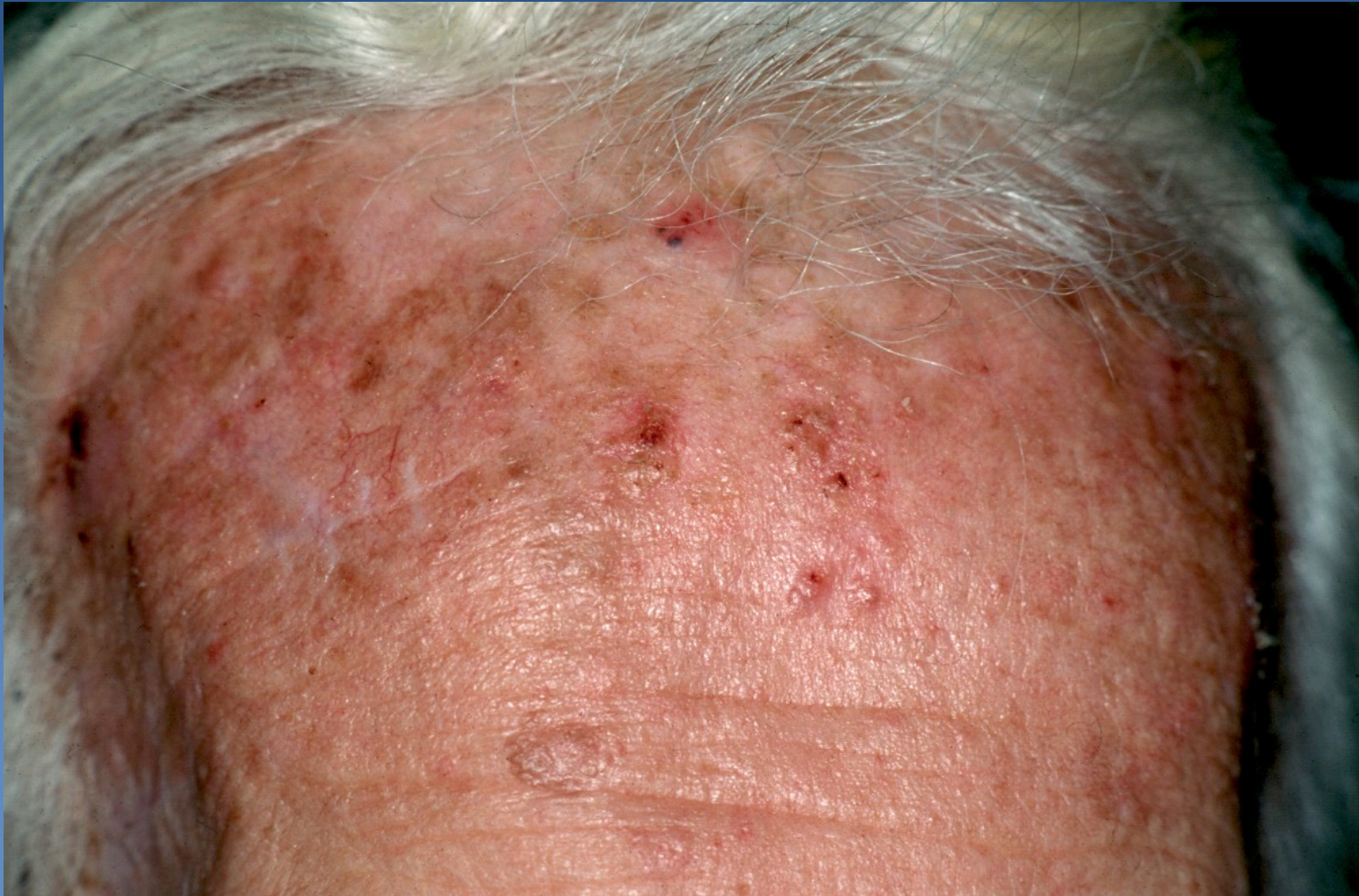

Actinic keratosis

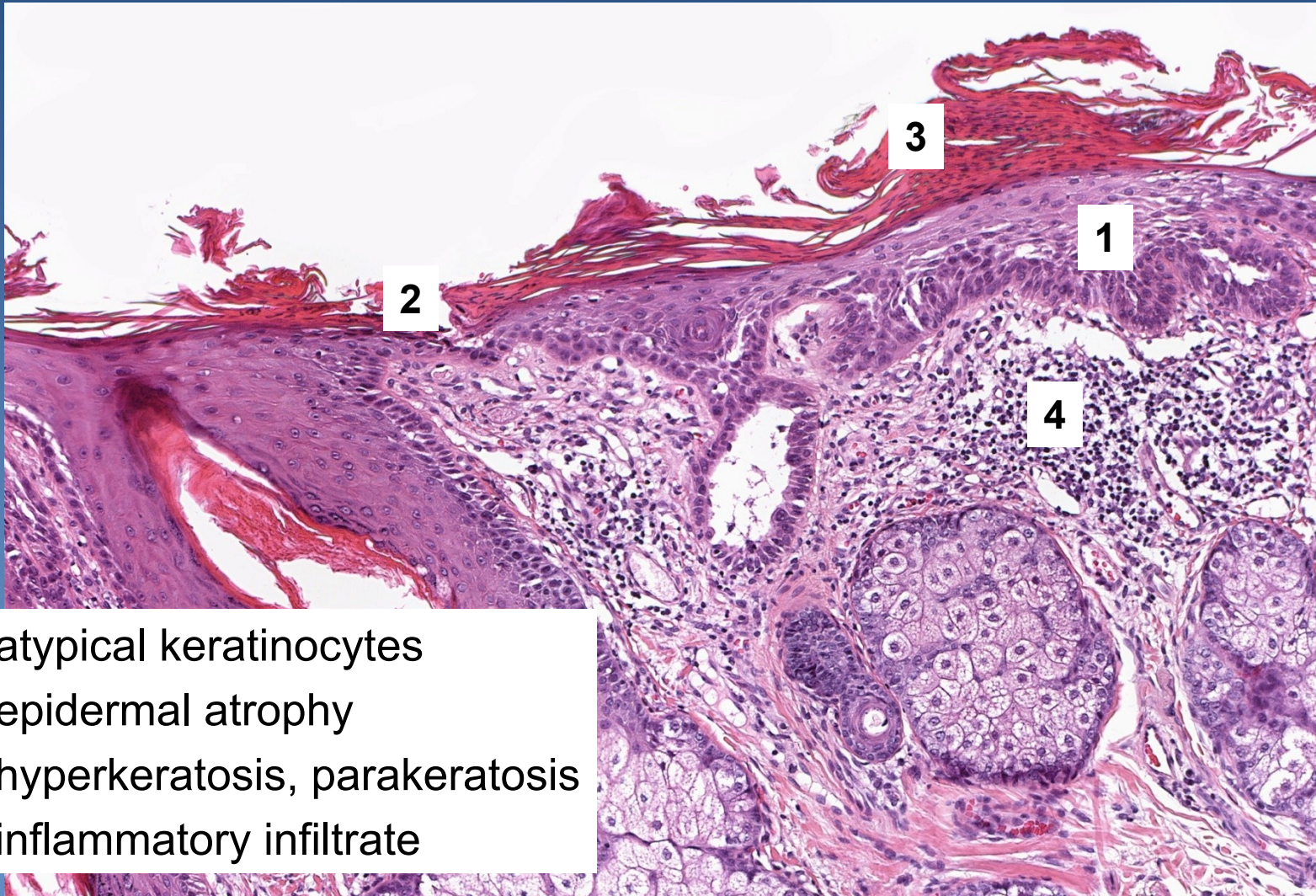


- **intraepidermal dysplasia - precancerosis**
- **occurs at sites of chronic sun exposure**
(head, neck, shoulder...)
- **gross:**
 - *areas of thickened, rough skin + small excoriations, atrophy*
- **micro:**
 - *dysplasia up to variable layer of the epidermis (starts at basal layer)*
 - *atrophy + hyperkeratosis, parakeratosis + dense chronic inflammatory infiltrate in superficial dermis*

Actinic keratosis



Actinic keratosis



- 1 atypical keratinocytes
- 2 epidermal atrophy
- 3 hyperkeratosis, parakeratosis
- 4 inflammatory infiltrate

Basal cell carcinoma



- × **locally aggressive carcinoma** (rarely metastasize)
- × **typically at the sites of chronic sun exposure**

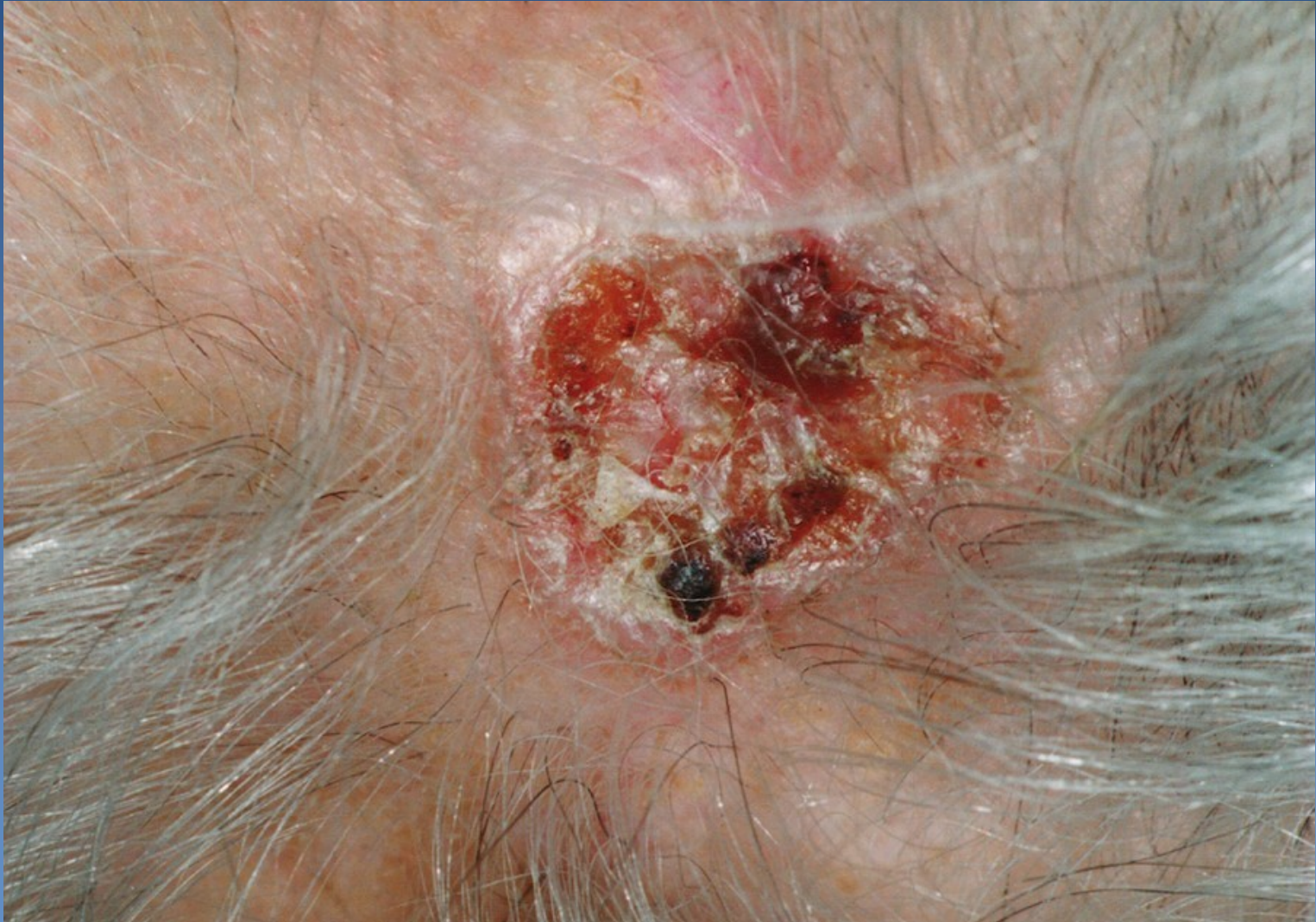× **gross:**

- ⇒ *flat / nodular lesion of skin color; erythematous plaque (superficial BCC)*
- ⇒ *may contain melanin pigment*
- ⇒ *often central ulceration*

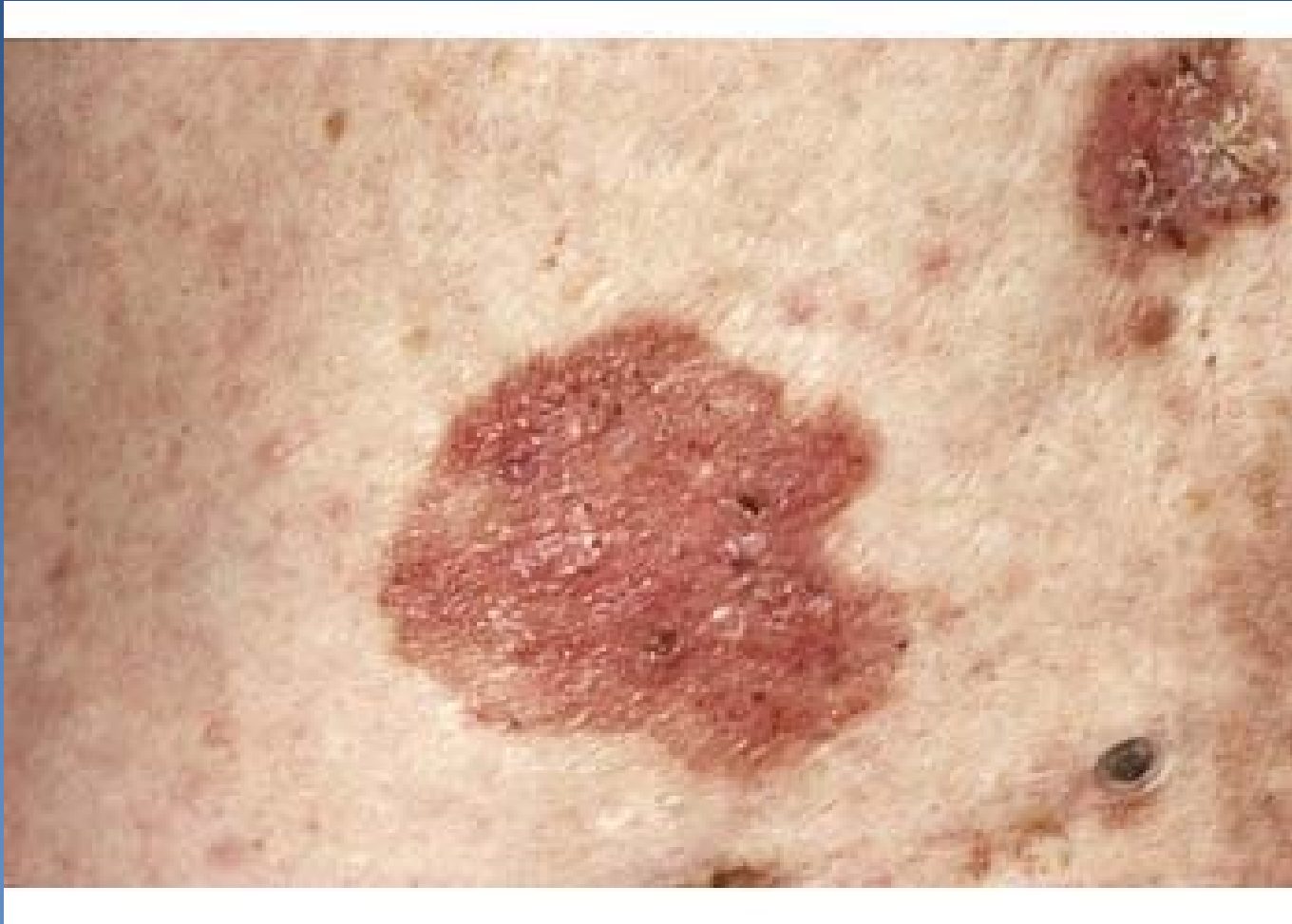
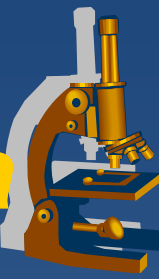
× **micro:**

- ⇒ *hyperchromatic dark basaloid cell nests*
- ⇒ *peripheral palisading*
- ⇒ *mitoses frequent,*
- ⇒ *stroma shrinks away from the tumor nests, creating clefts or separation artifacts*

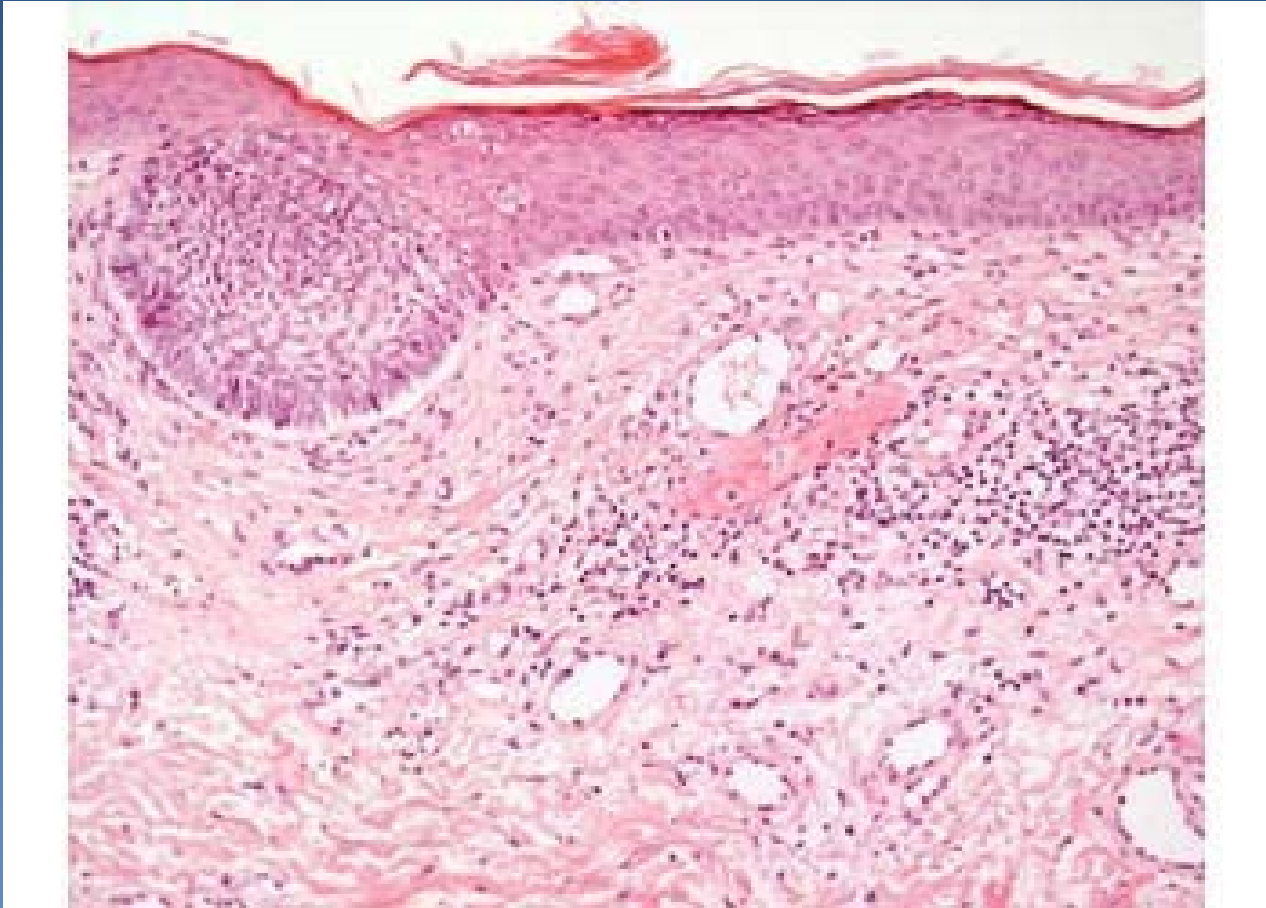
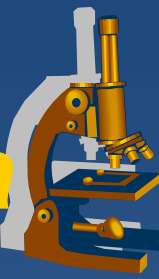
Basal cell carcinoma



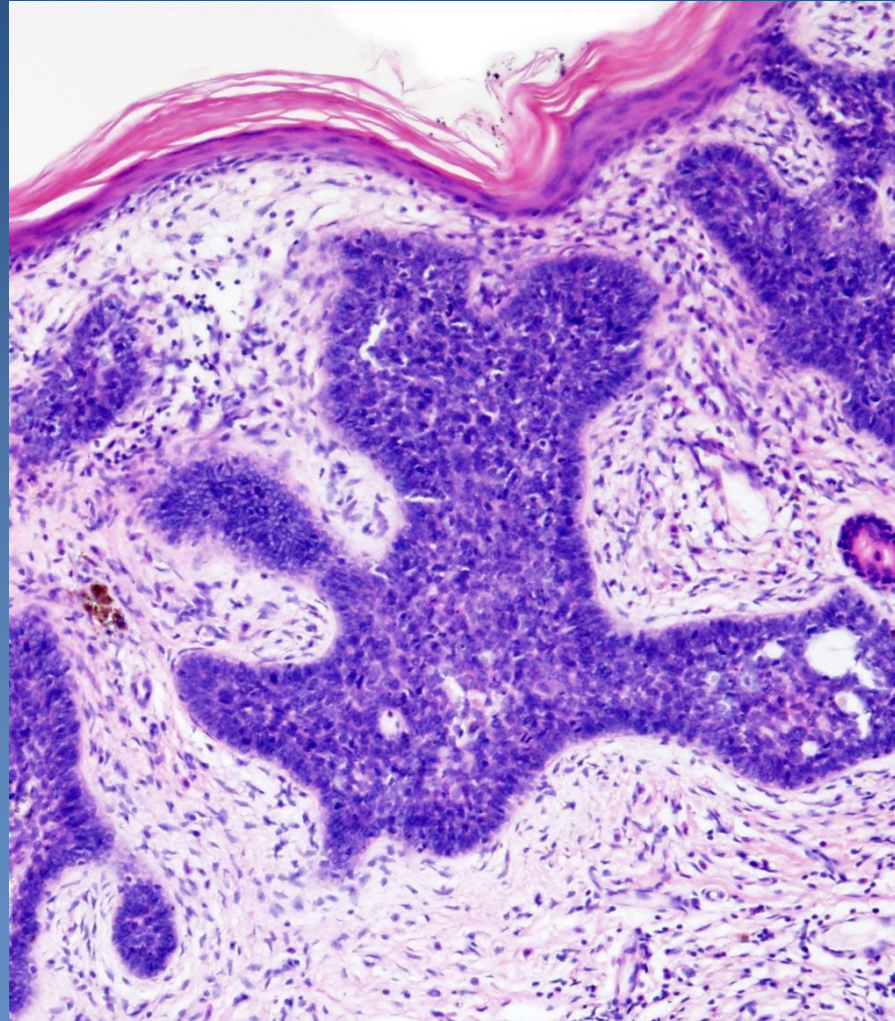
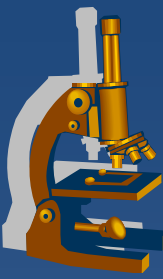
Superficial basal cell carcinoma



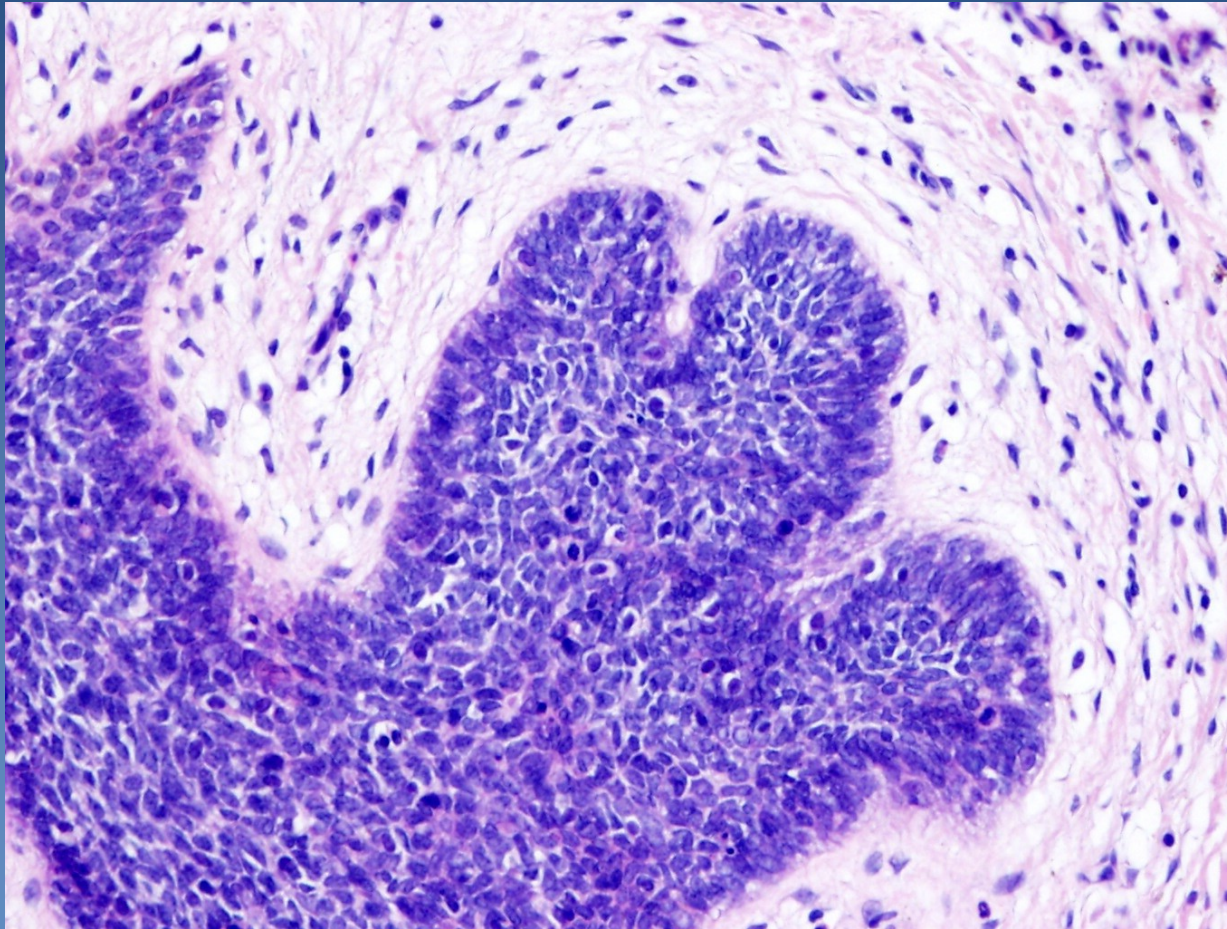
Superficial basal cell carcinoma

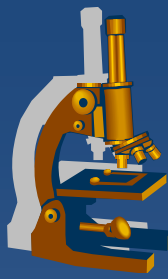


Basal cell carcinoma



Basal cell carcinoma





Squamous cell carcinoma

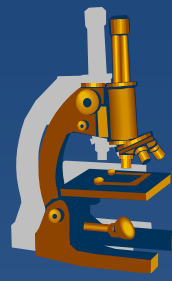
× UV light, HPV, chronic ulcers + wounds, chemical carcinogenes

× **gross:**

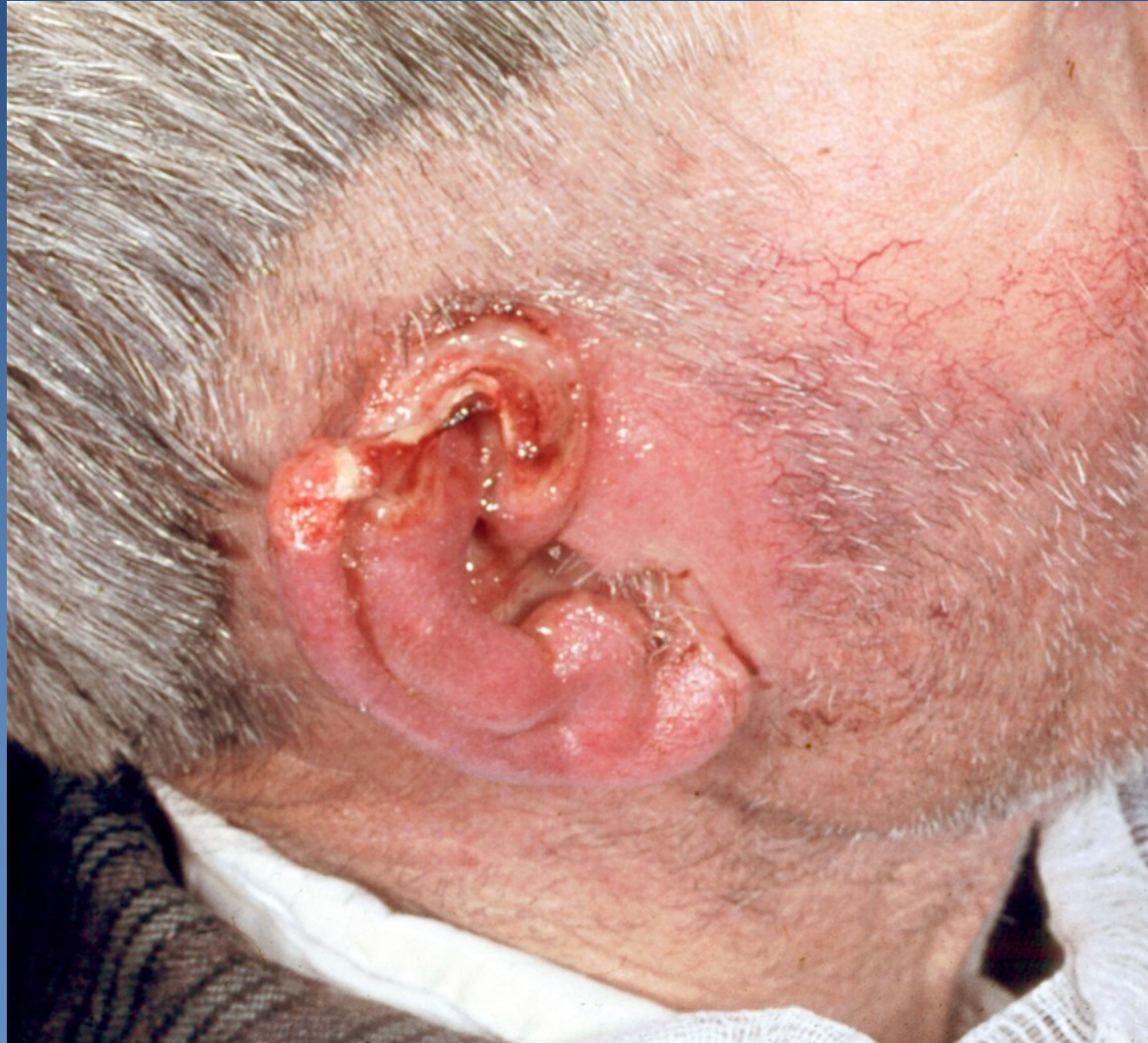- ⇒ *sharply demarcated scaling plaques, sm. elevated or nodular lesion of firm consistency*
- ⇒ *possible ulceration*

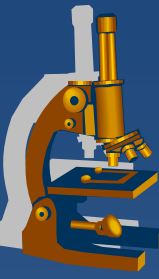
× **micro:**

- ⇒ *tumor cells arranged in **ords and nests***
 - cells on the edge of nests smaller, to the centre increased cytoplasmic volume (~ stratum spinosum)
 - atypical mitoses at all levels of epidermis
 - **variabler keratinization, dyskeratosis, keratine pearls**
 - **intercellular bridges**

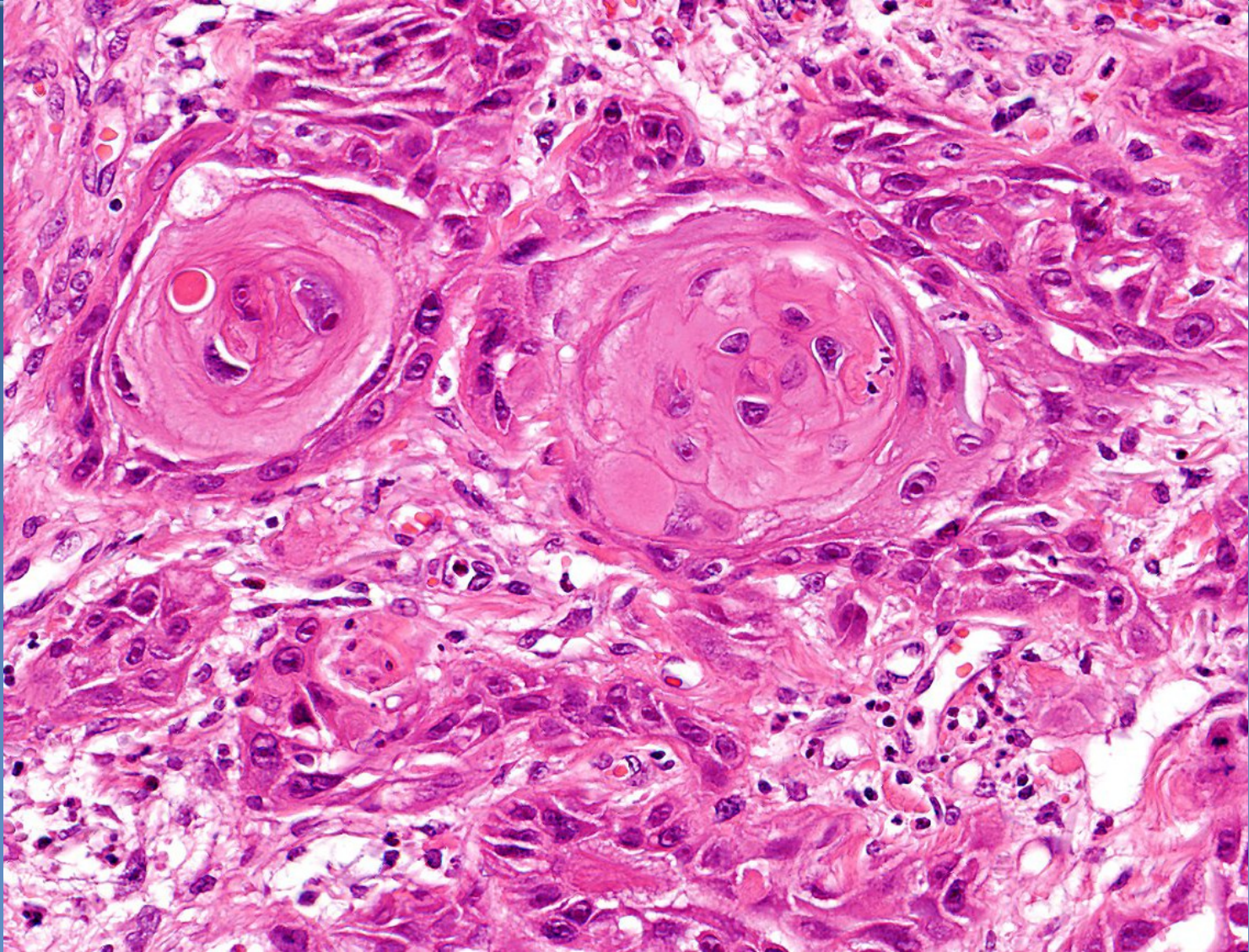


Squamous cell carcinoma





Squamous cell carcinoma



Melanocytic lesions



x Benign:

- ⇒ *freckles (ephelides)*
- ⇒ *benign lentigo*
- ⇒ *pigmented nevus*
- ⇒ *spindle and epitheloid cell nevus (Spitz nevus)*
- ⇒ *atypical (dysplastic) nevus*

x Malignant melanoma:

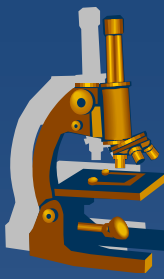
- ⇒ *lentigo maligna*
- ⇒ *superficial spreading melanoma*
- ⇒ *nodular melanoma*
- ⇒ *acral lentiginous melanoma*

Pigmented nevus

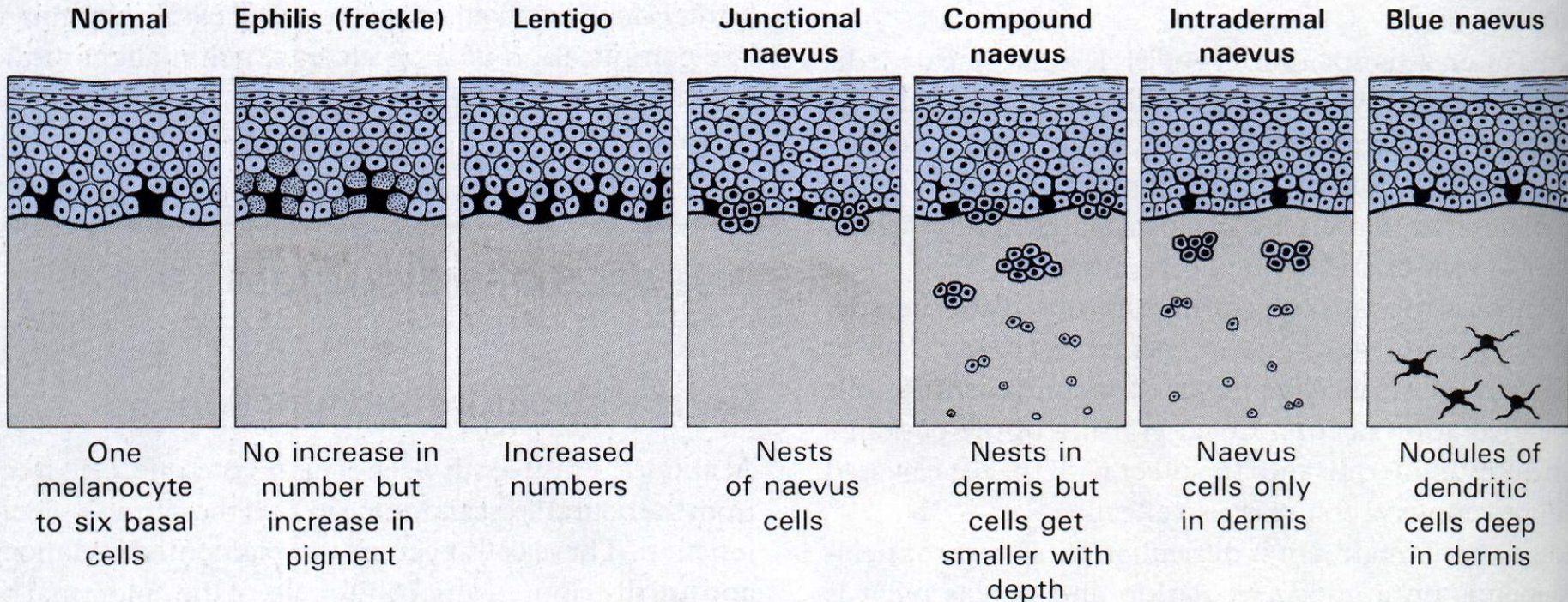


- ✗ benign tumor, congenital or acquired
- ✗ congenital nevus usually larger (esthetic surgery)
- ✗ micro:
 - ⇒ ***junctional nevi***
 - groups of pigmented cells (= nests) grow in dermoepidermal junction
 - ⇒ ***compound nevi***
 - nests grow in junction zone and into the underlying dermis (in dermis arranged also in cords)
 - ⇒ ***intradermal nevi***
 - nests/cords only in the dermis

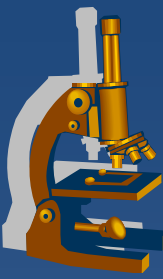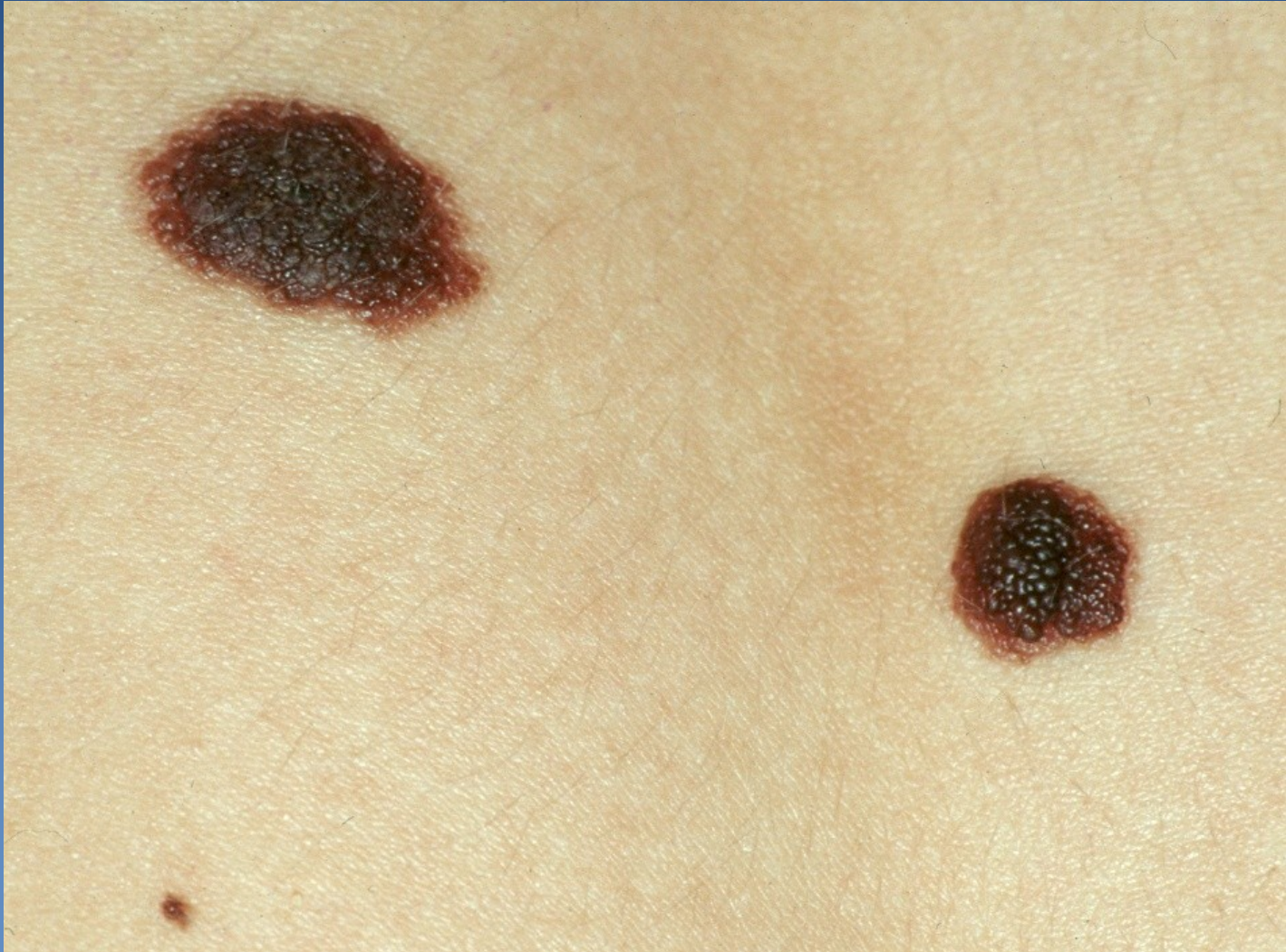
Melanocytic lesions



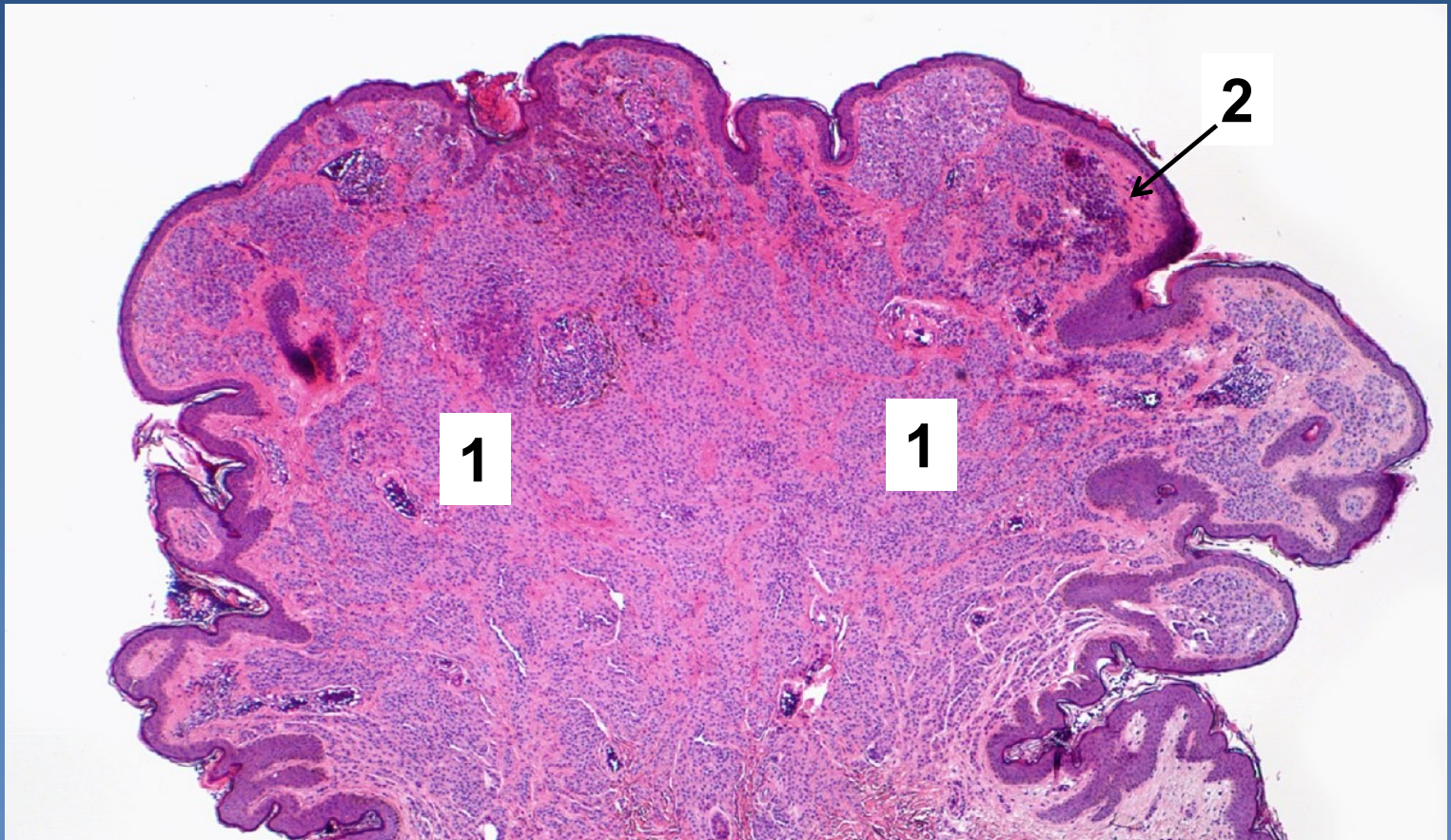
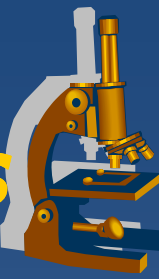
copy



Pigmented nevus



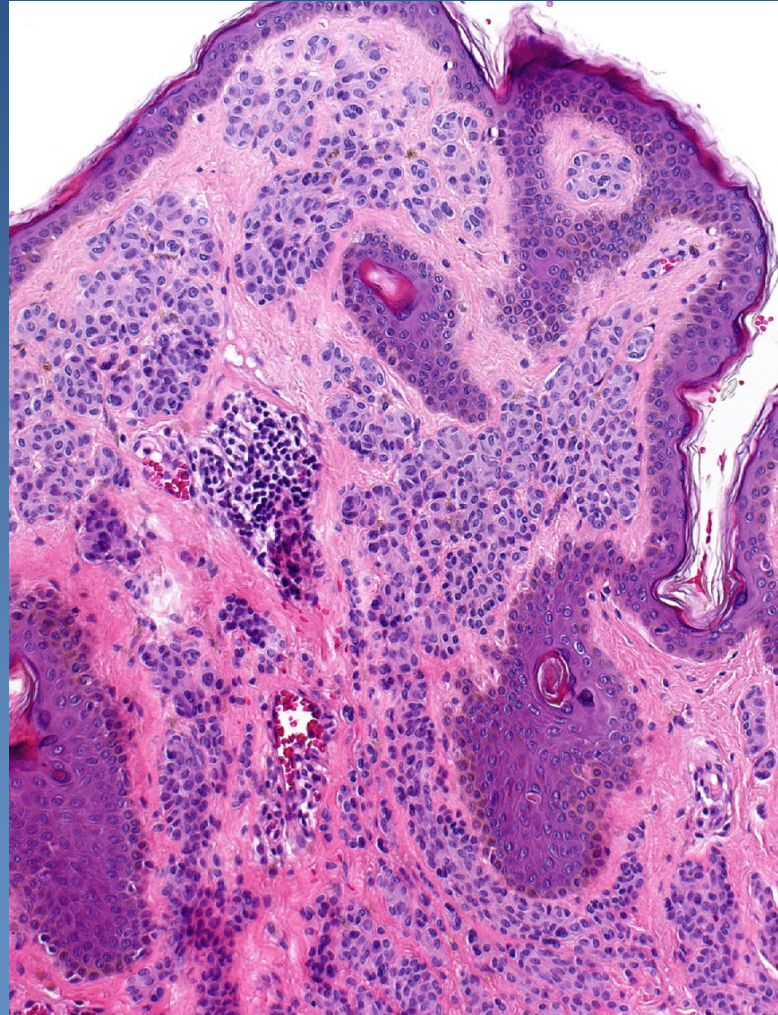
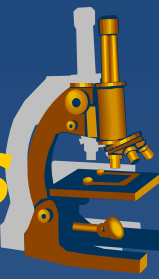
Intradermal pigmented nevus

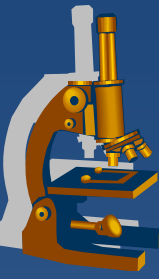


1. Melanocytes

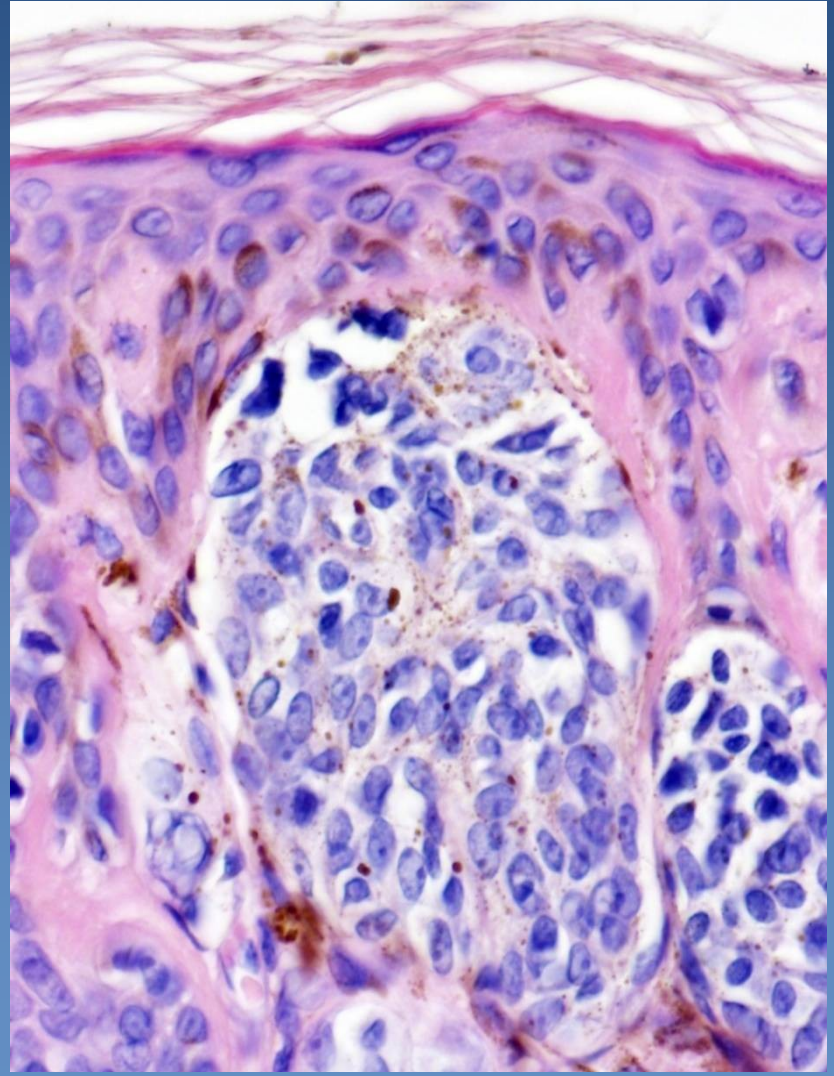
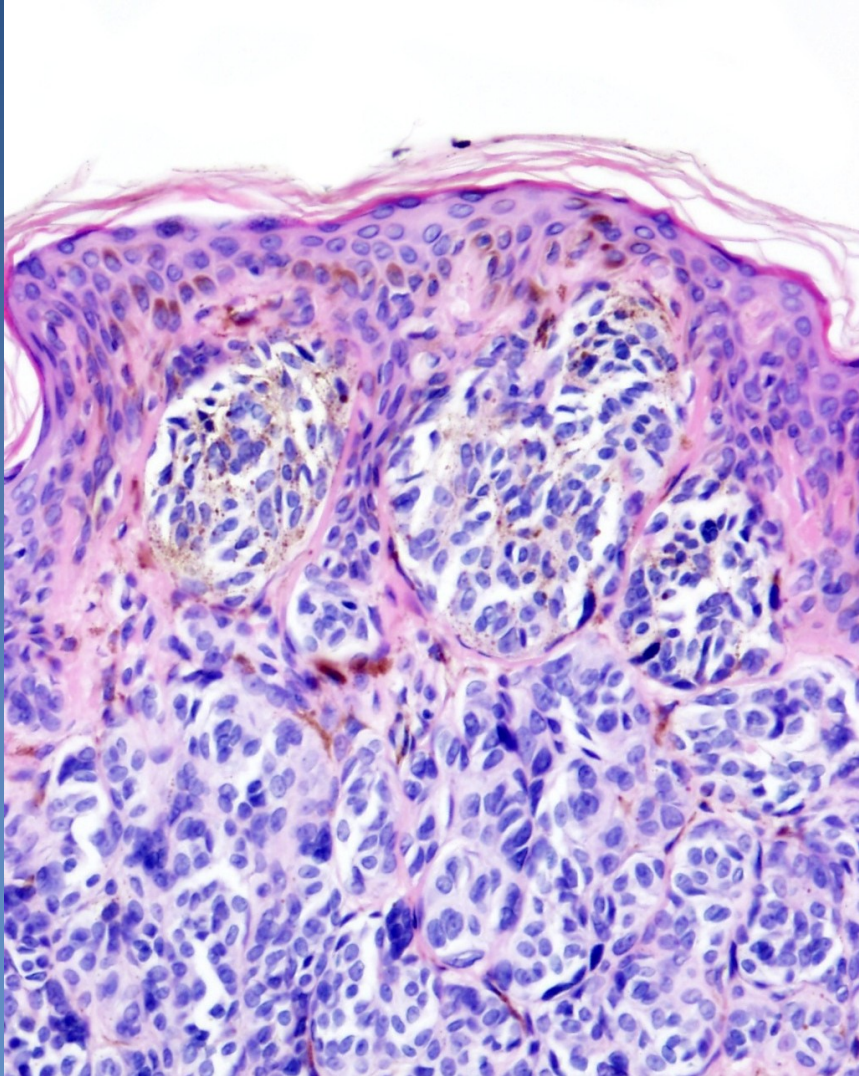
2. Papillary dermis separating nests of melanocytes and epidermis

Intradermal pigmented nevus





Compound pigmented nevus



Malignant melanoma



x origin:

⇒ *malignization of preexisting nevi*

⇒ *de novo*

x localization:

⇒ *skin*

⇒ *mucous membranes*

⇒ *meninges*

⇒ *eye*

Malignant melanoma



x gross:

- ⇒ *similarity to congenital nevus at early stage*
- ⇒ *irregular borders*
- ⇒ *variegation of color within a pigmented lesion*
- ⇒ *ulceration, darkening, bleeding at late stages*

⇒ *clinic ABCD rule*

- **A**ssymetry
- irregular **B**order
- uneven **C**olour
- **D**iameter > 6mm

Malignant melanoma



x micro:

⇒ *assymetry*

⇒ *atypical pleomorphic epitheloid or spindle cells*

⇒ *large hyperchromatic nuclei with prominent **nucleoli***

⇒ ***mitoses** (atypically localized)*

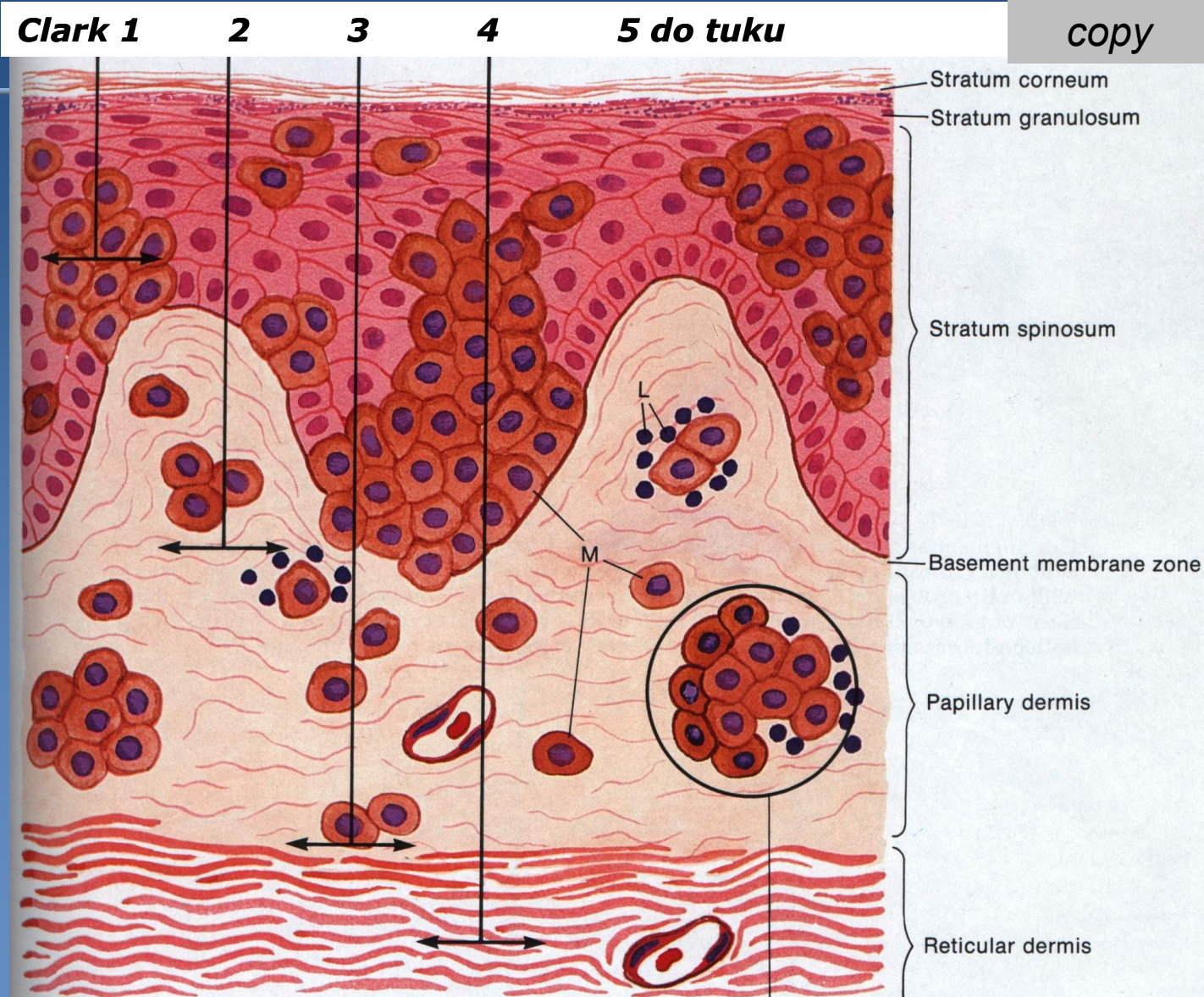
⇒ *irregular rough granular pigmentation*

- forms with complete absence of pigment possible

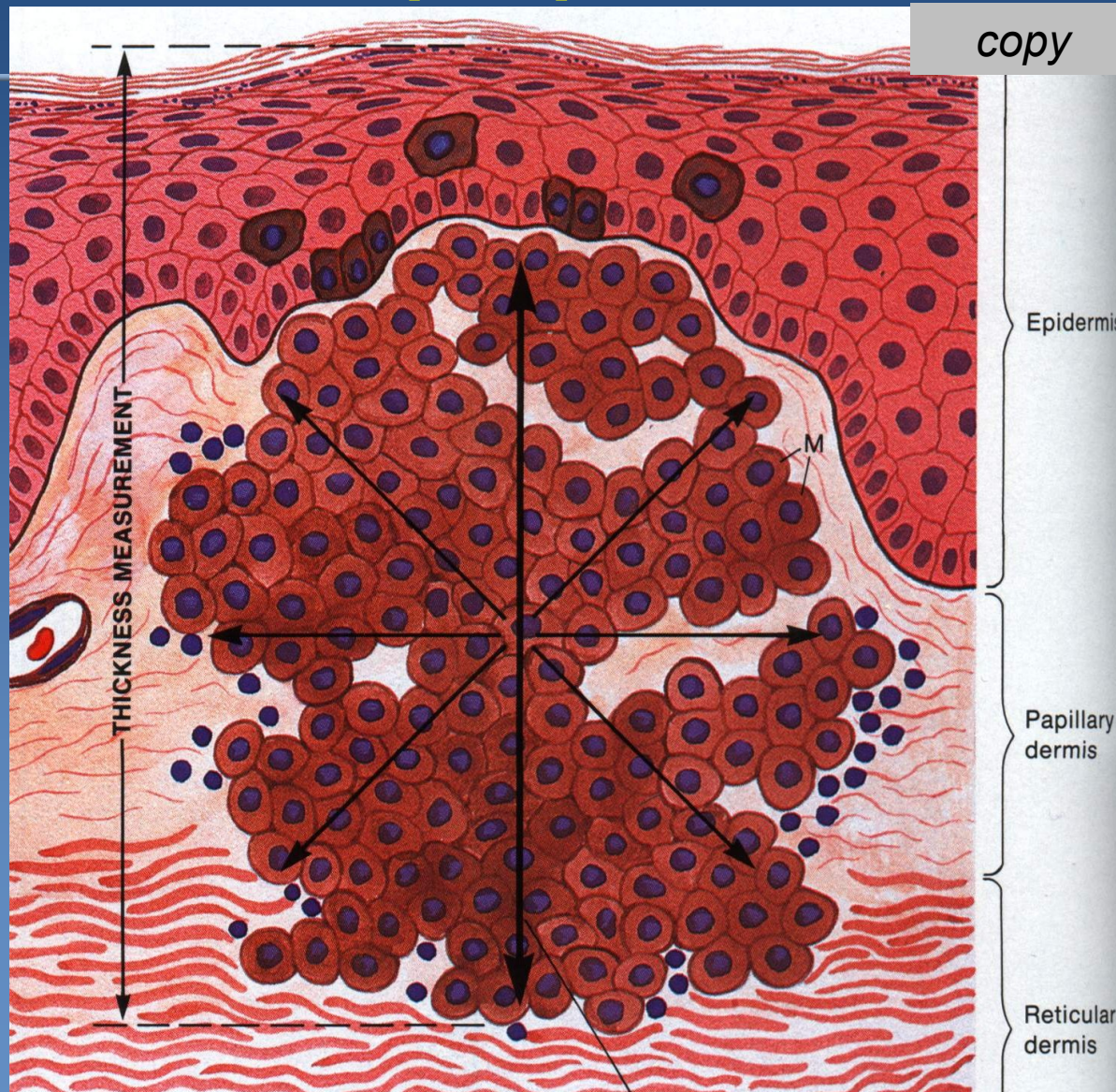
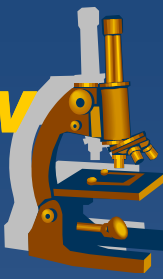⇒ *immunoprofile:*

- melan A, HMB-45, S-100

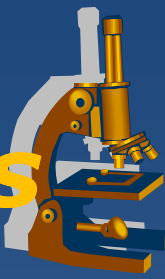Depth of melanoma invasion by Clark



Depth of melanoma invasion by Breslow (mm)



Melanoma – prognostic factors



- × thickness of lesion by **Breslow** (groups of 1-2-4 mm)
- × depth of invasion by **Clark** (in TNM)
- × ulceration
- × mitotic rate
- × partial regression (worse prognosis)
- × presence of tumor-infiltrating lymphocytes
- × lymphovascular invasion
- × **females** - longer survival
- × longer survival by localization on limbs
 - ⇒ *except of subungual and plantar form (acral lentiginous melanoma – worse prognosis)*

Malignant melanoma



x 3 growth phases:

⇒ ***melanoma in situ (intraepidermal phase)***

⇒ ***radial growth phase - superficial MM***

- superficial growth within epidermal layers associated with invasion into the papillary dermis

⇒ ***vertical growth phase – nodular MM***

- downward invasion into the reticular dermis
- clone of cells with metastatic potential

Lentigo maligna



- × **severe intraepidermal melanocytic dysplasia**
– melanoma in situ; may progress – lentigo maligna melanoma

- × **gross:**

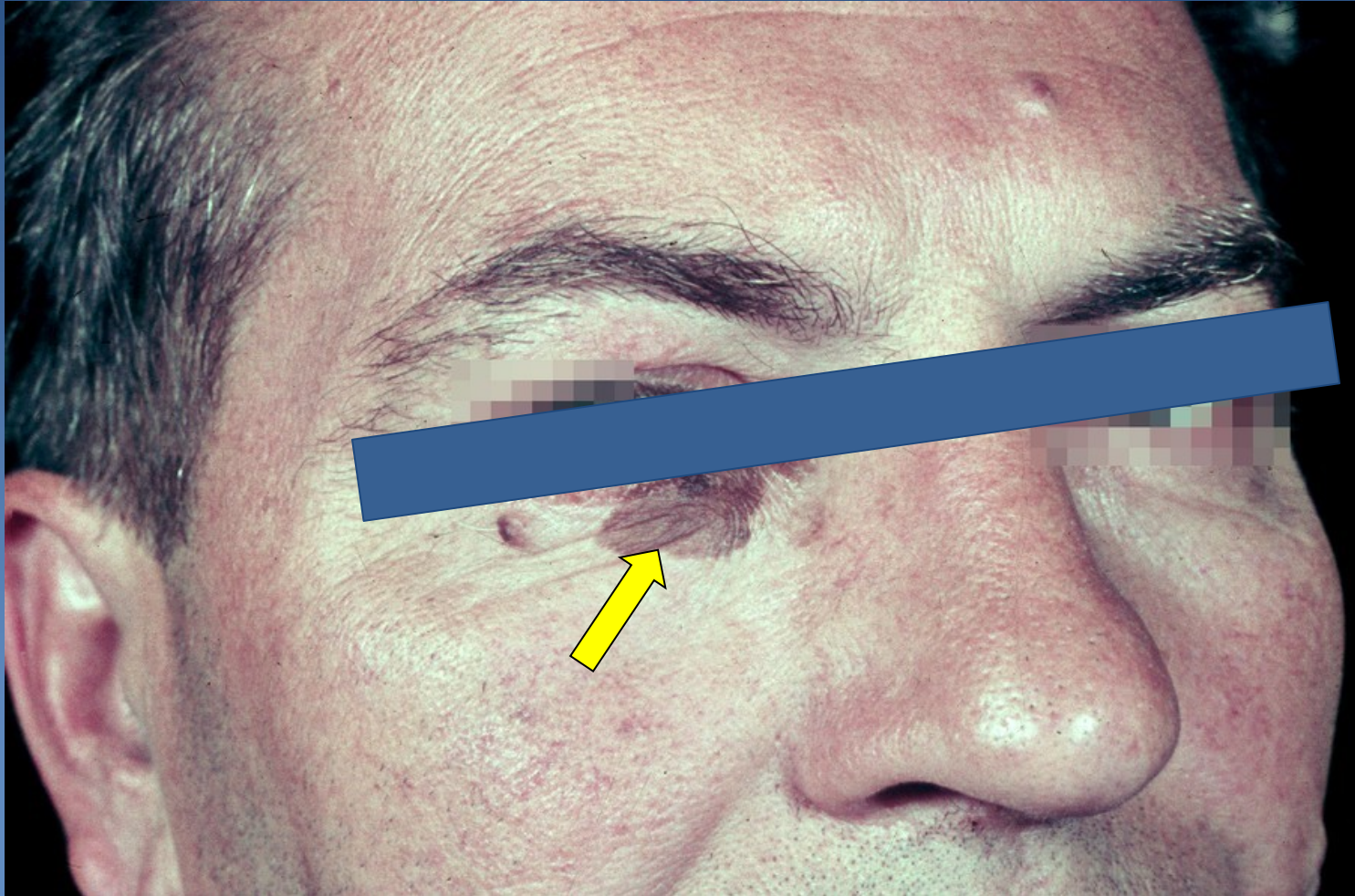- ⇒ *irregular pigmented lesion, mostly localized on the face*

- × **micro:**

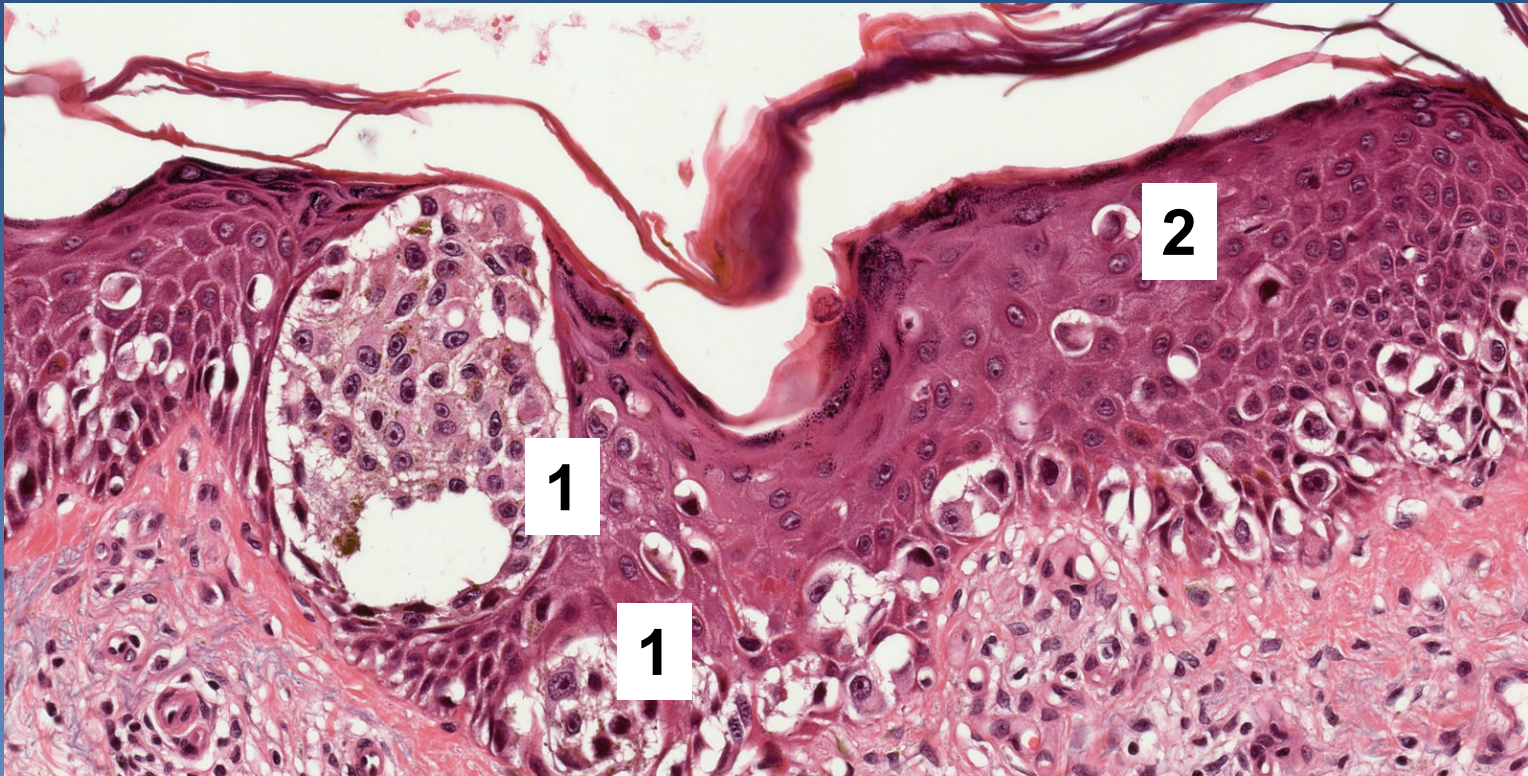
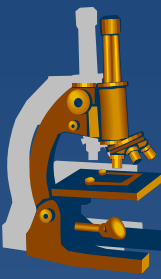
- ⇒ *atypical melanocytes **single in dermoepidermal junction and in all layers of the epidermis***

- ⇒ *epidermal atrophy and basophilic collagen degeneration*

Lentigo maligna melanoma



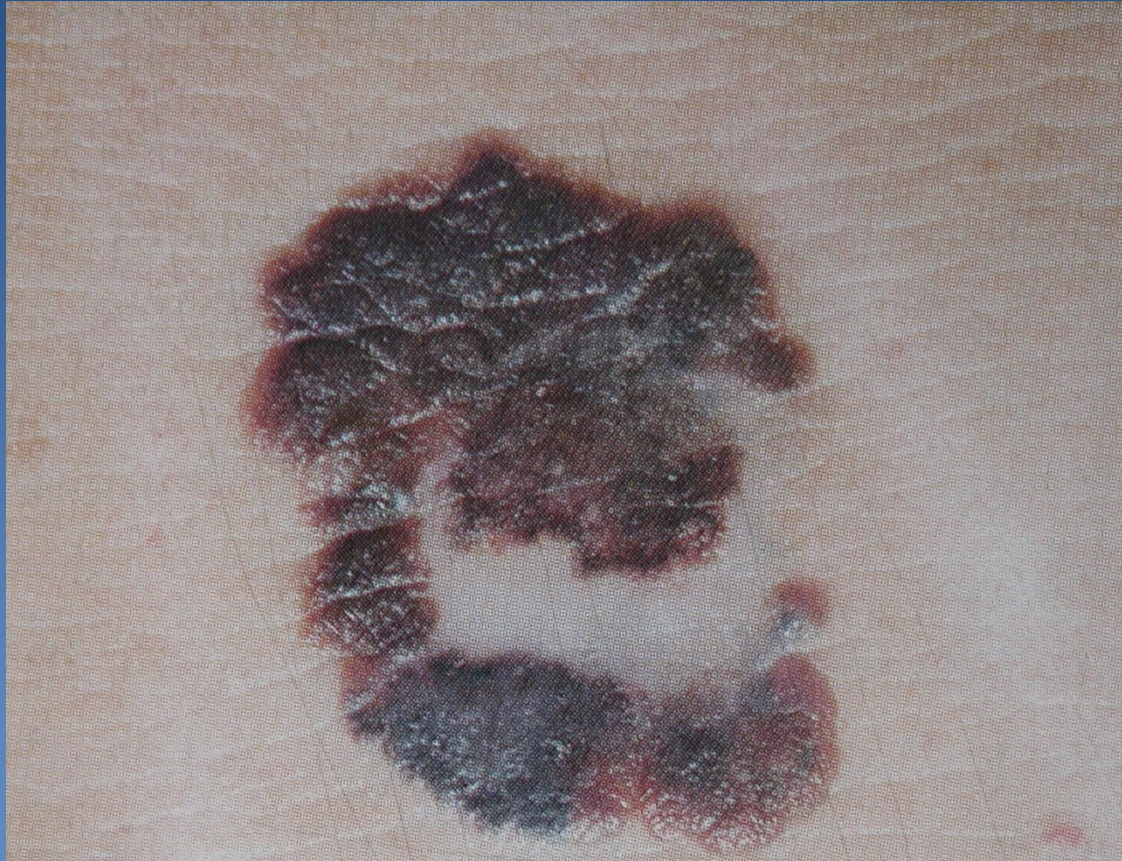Lentigo maligna melanoma



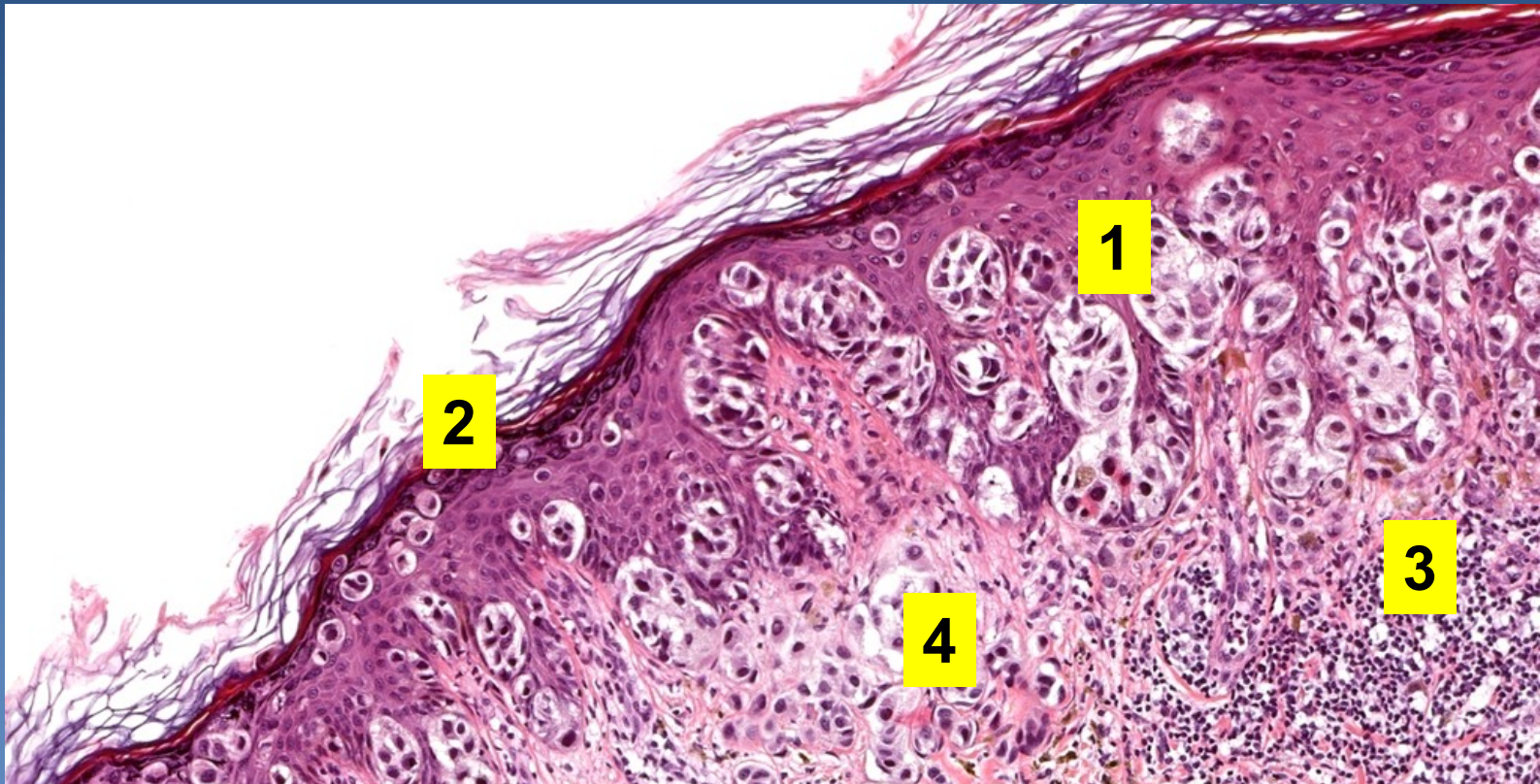
1 irregular nests in the junction zone

2 melanocytes in all epidermal layers (pagetoid spread)

Malignant melanoma radial growth phase - SSM



Malignant melanoma radial growth phase - SSM



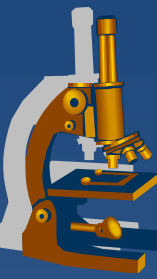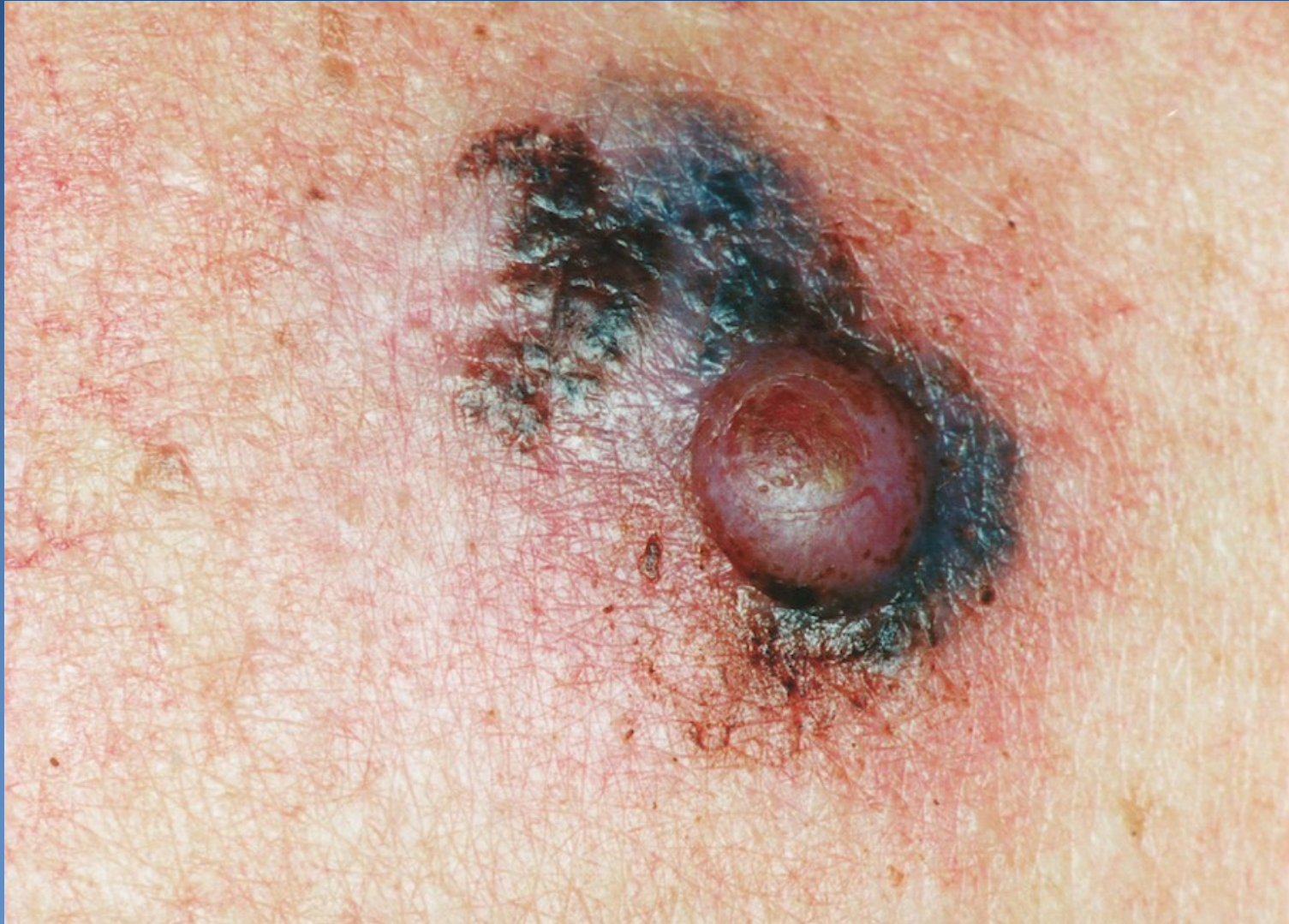
1. Irregularly distributed nests in junction zone
2. Single melanocytes in upper epidermal layers
3. Lymphocytic infiltrate
4. Invasion into papillary dermis (Clark 3)

Malignant melanoma vertical growth phase



- x** SSM + nodular clone of melanoblasts with vertical growth
- x** worse prognosis
- x** gross:
 - ⇒ *irregular variably pigmented macule + prominent nodule*
- x** micro: SSM + different neoplastic clone, bigger nest with vertical growth

***Malignant melanoma
vertical growth phase with nodularity***

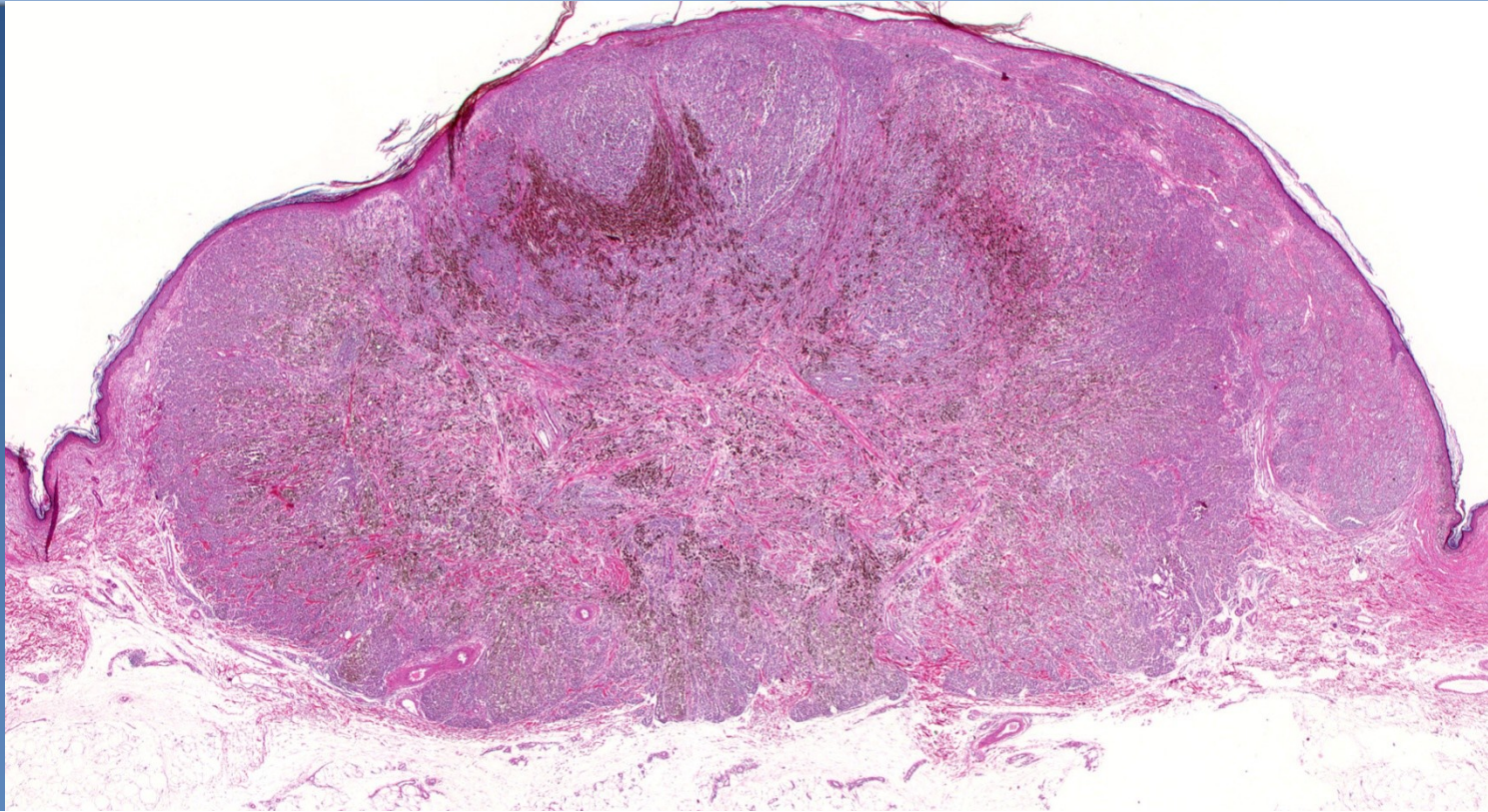


Malignant melanoma – nodular MM



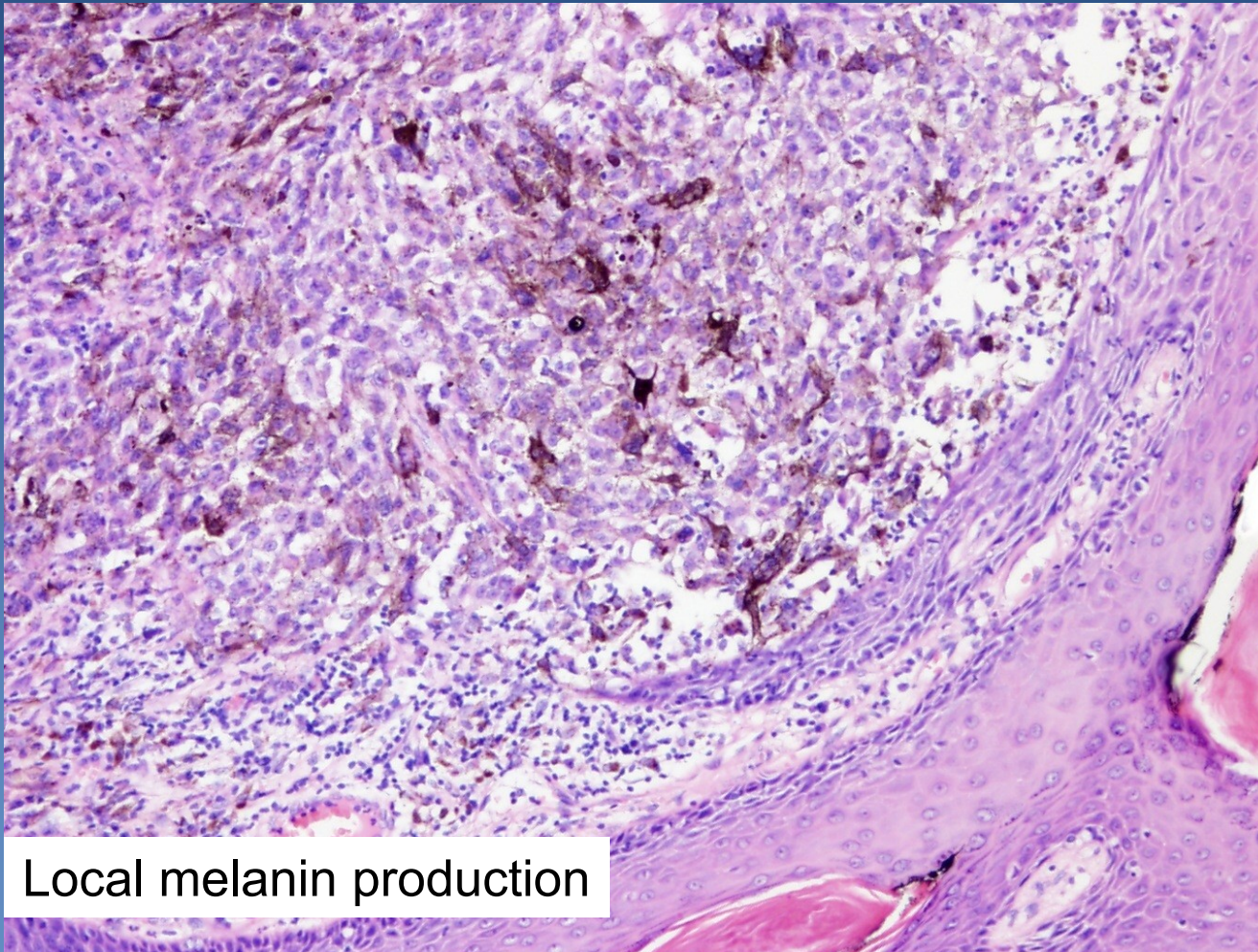
- x growth zone in the dermis**
- x metastasizes**, depends on prognostic factors
 - ⇒ *first into lymph nodes, later hematogenous spreading into literally any organ/tissue*
 - ⇒ *radical excision*
- x gross:**
 - ⇒ *odule of various color*
- x micro:**
 - ⇒ *tumorous melanocytes forming nodule of various size in the dermis*
 - tumor cells differ from radial growth component (new tumorous clone) – most often epitheloid appearance
 - maturation to the base of the lesion absent

Malignant melanoma – nodular MM



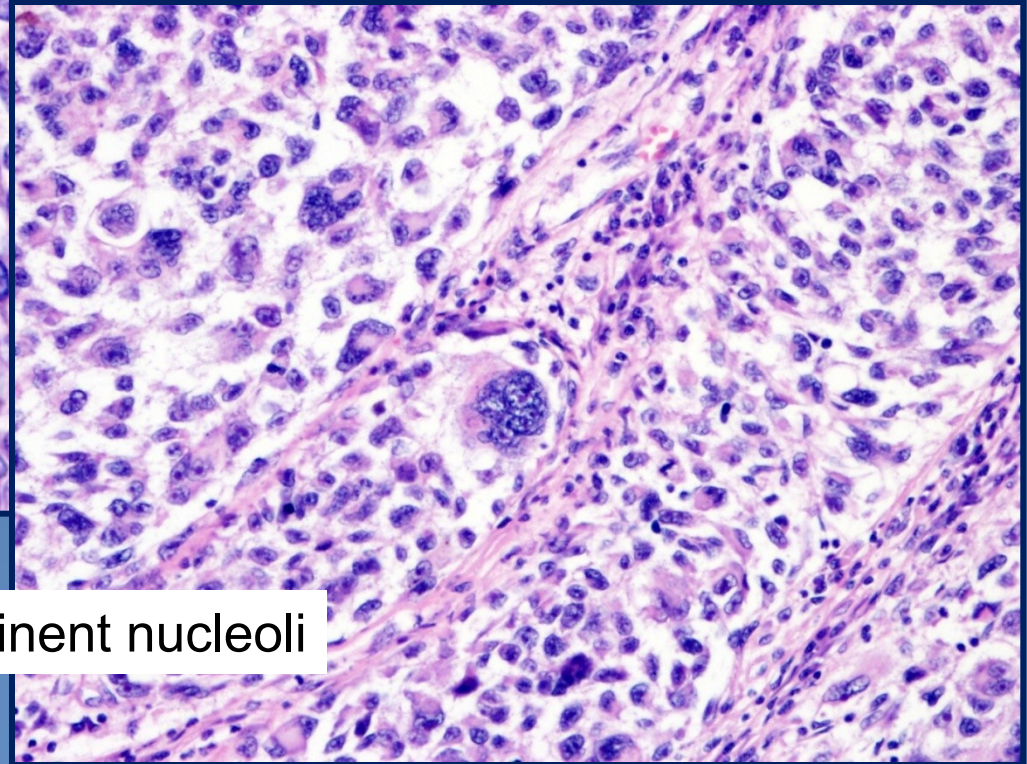
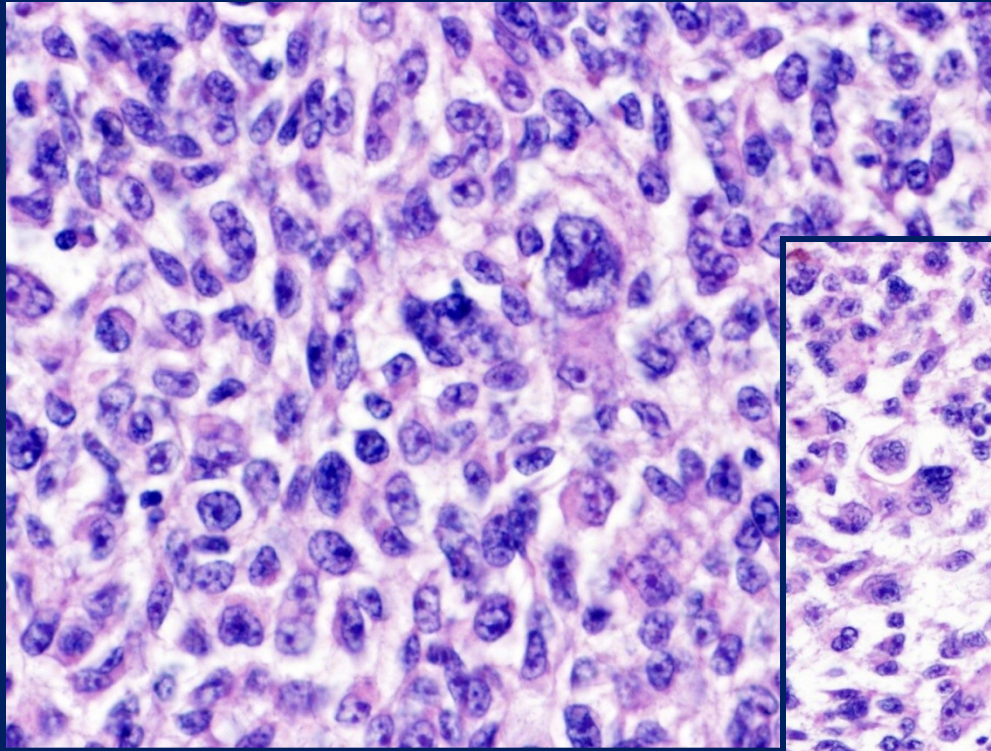
Large tumor infiltrating fat tissue, without horizontal growth component;
local enormous melanin production

Malignant melanoma vertical growth phase – nodular MM



Local melanin production

Malignant melanoma nodular MM



Atypical melanoblasts, prominent nucleoli

Malignant melanoma liver metastases



