

# Urinary tract diseases

## Male genital system

V. Žampachová  
I. ÚP

# Congenital anomalies

- **Extrophy of the bladder** – non-closure of anterior wall (bladder +/- abdominal, symphysis pubis; infections incl. pyelonephritis; ↑ risk of ca)
- **Congenital stenosis** – ureteropelvic junction, double/bifid ureter → hydronephrosis
- **vesicoureteral / ureteropelvic** reflux



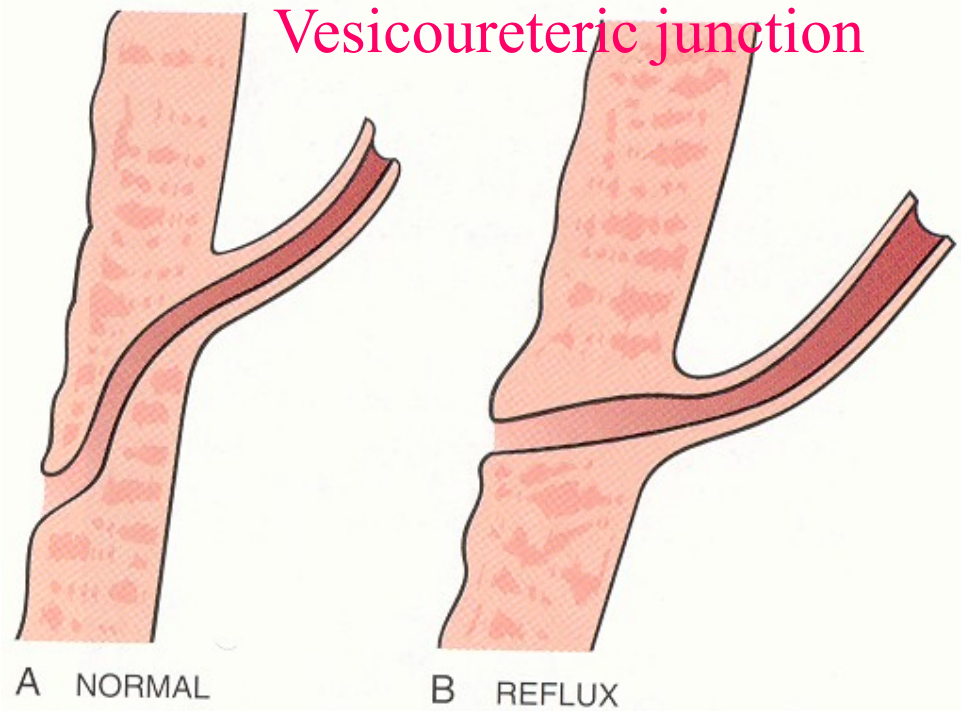
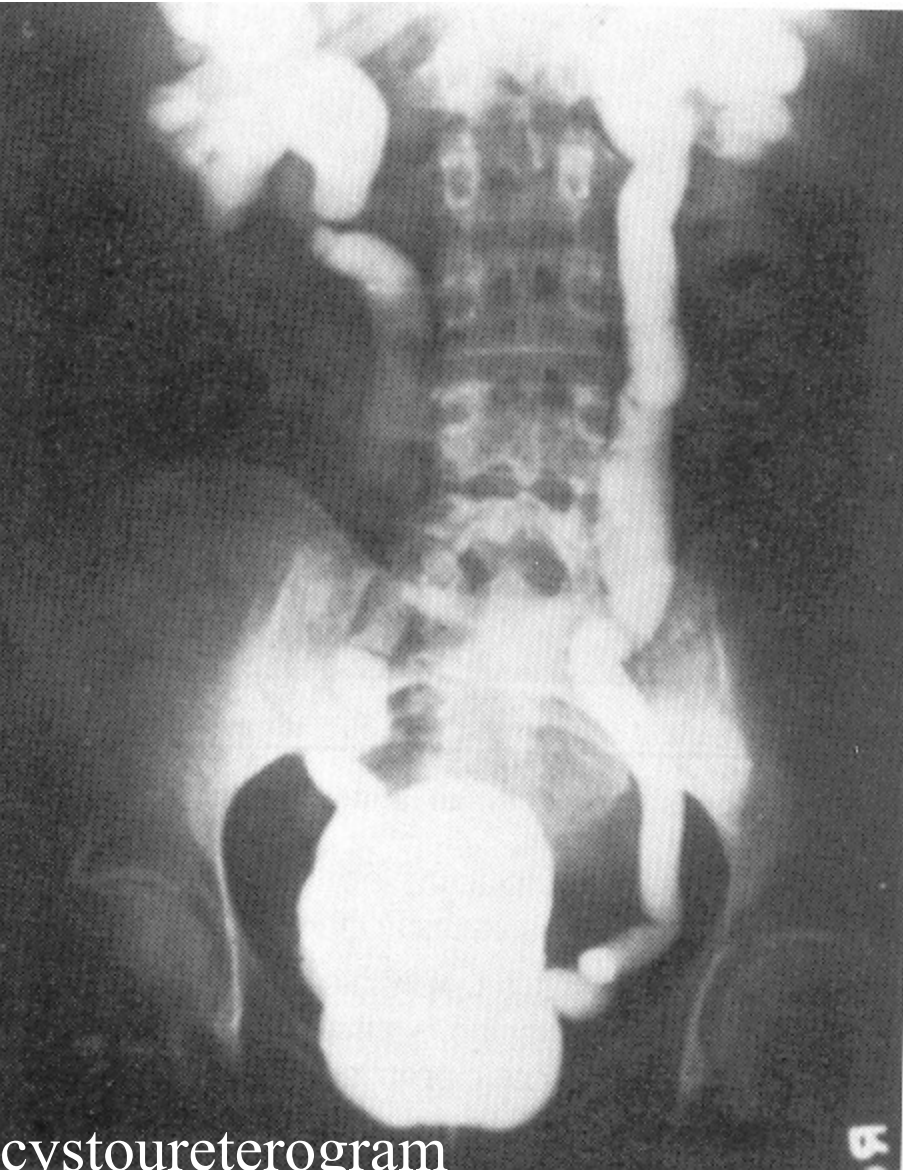
# Urinary tract obstruction

- increased susceptibility to urolithiasis
- increased susceptibility to infection
- risk of hydronephrosis
  
- Combination of inborn + acquired risk factors

# Vesico-ureteric reflux

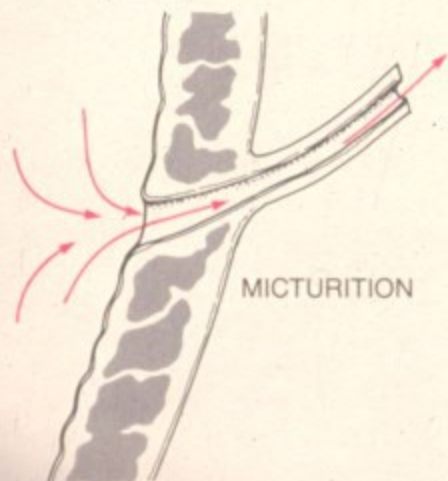
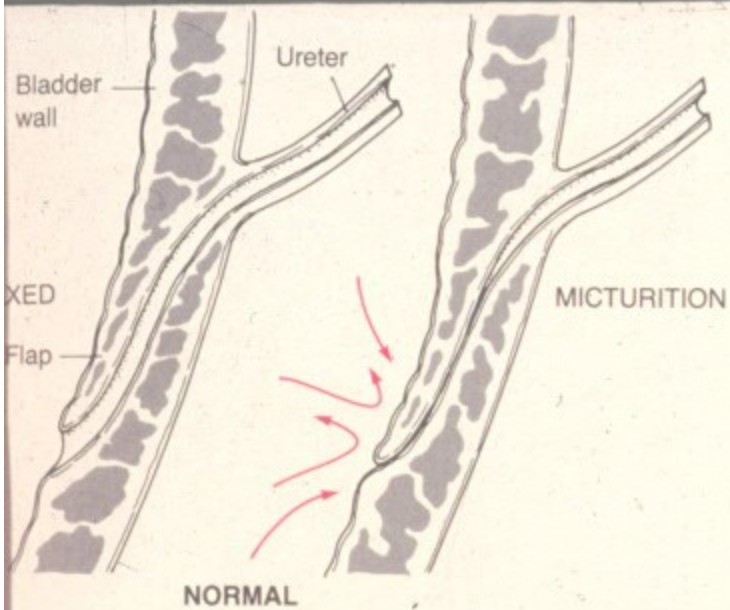
- Incompetence of the vesico-ureteral valve
- Combination of congenital defect (short intravesical part of ureter, 1-2% of children)
- ↓ ureteral contractility in infection
- acquired in bladder atonia (spinal cord injury)

# Vesico-ureteric reflux

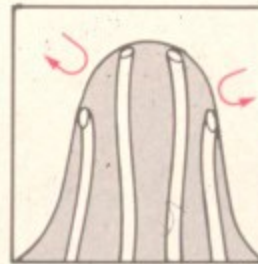
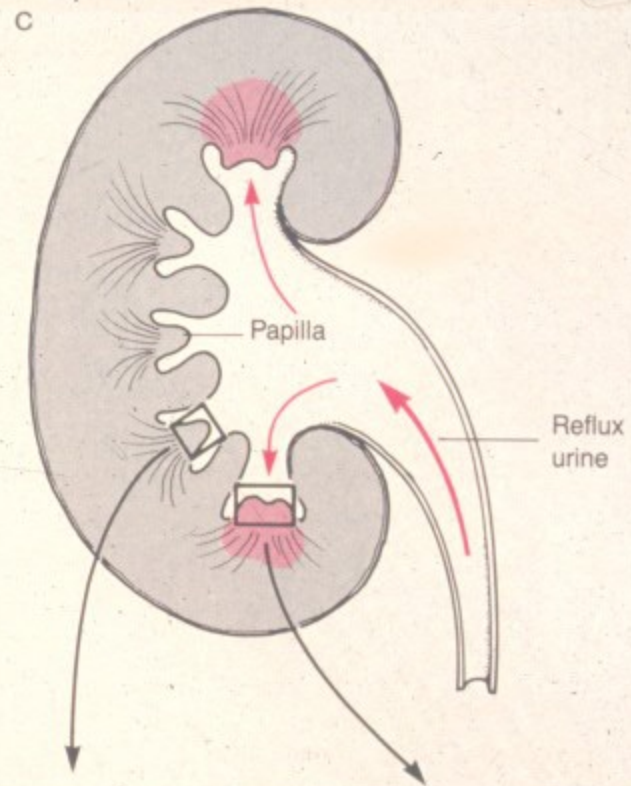


# Intrarenal reflux

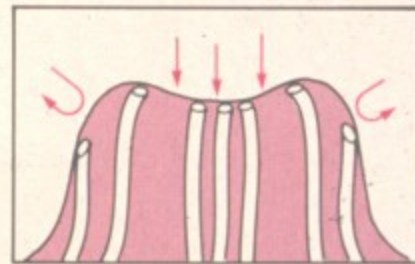
- Upper and/or lower renal papillae
- Progression of infection into the kidney tissue
- No reflux – usually no ascending infection



SHORT INTRAVESICAL URETER



SIMPLE PAPILLA



COMPOUND PAPILLA

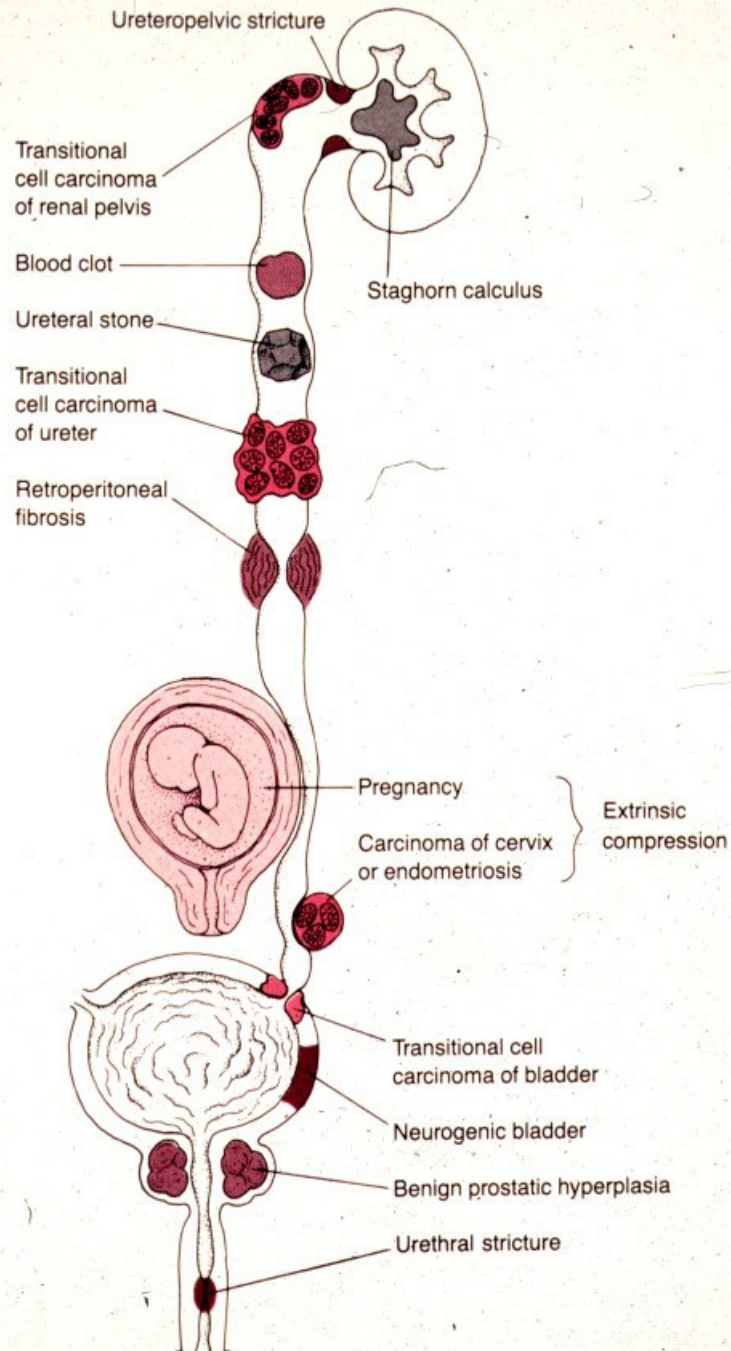
# Obstruction causes

- **Intrinsic** – luminal obstruction (stone, blood clot, necrotic papilla, tumor or its part)
- **Wall stenosis or dysfunction** (inborn, inflammation, postinflammatory, tumor, ...)
- **Extrinsic** – external compression, some causes common for both sexes, some different

# Obstruction causes

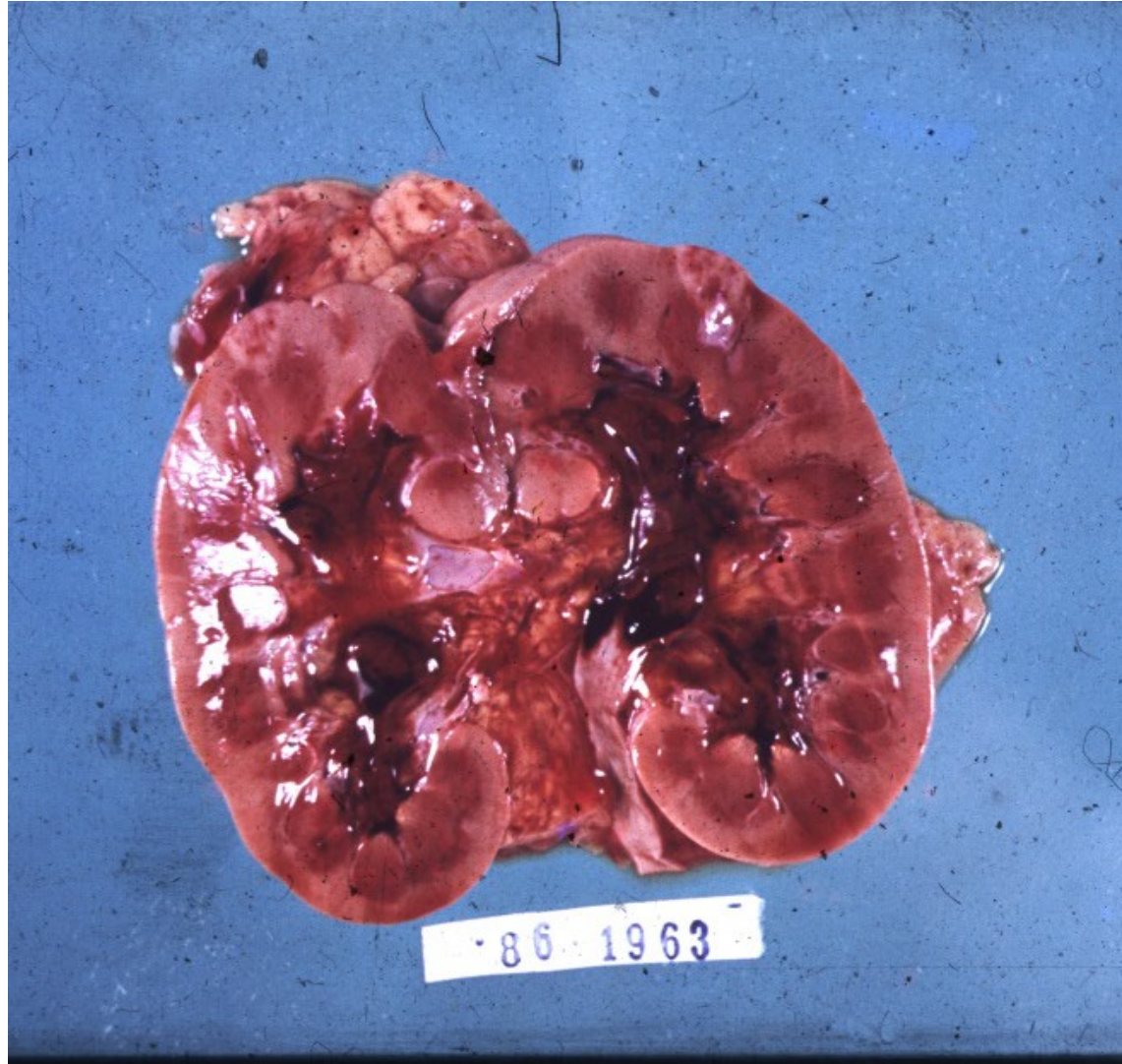
- **In males:** prostatic hyperplasia, prostatic ca, urethral stenosis, phimosis + complications
- **In females:** pregnancy, cervical ca (+ therapy), uterine myoma, ovarian tumor, uterine prolapse
- **in both:** chronic inflammation/fibrosis (retroperitoneal fibrosis), tumor (colorectal ca, LN,...), aortic aneurysm







Massive hematuria from renal calculi,  
tumors, or papillary necrosis



# Urinary calculi

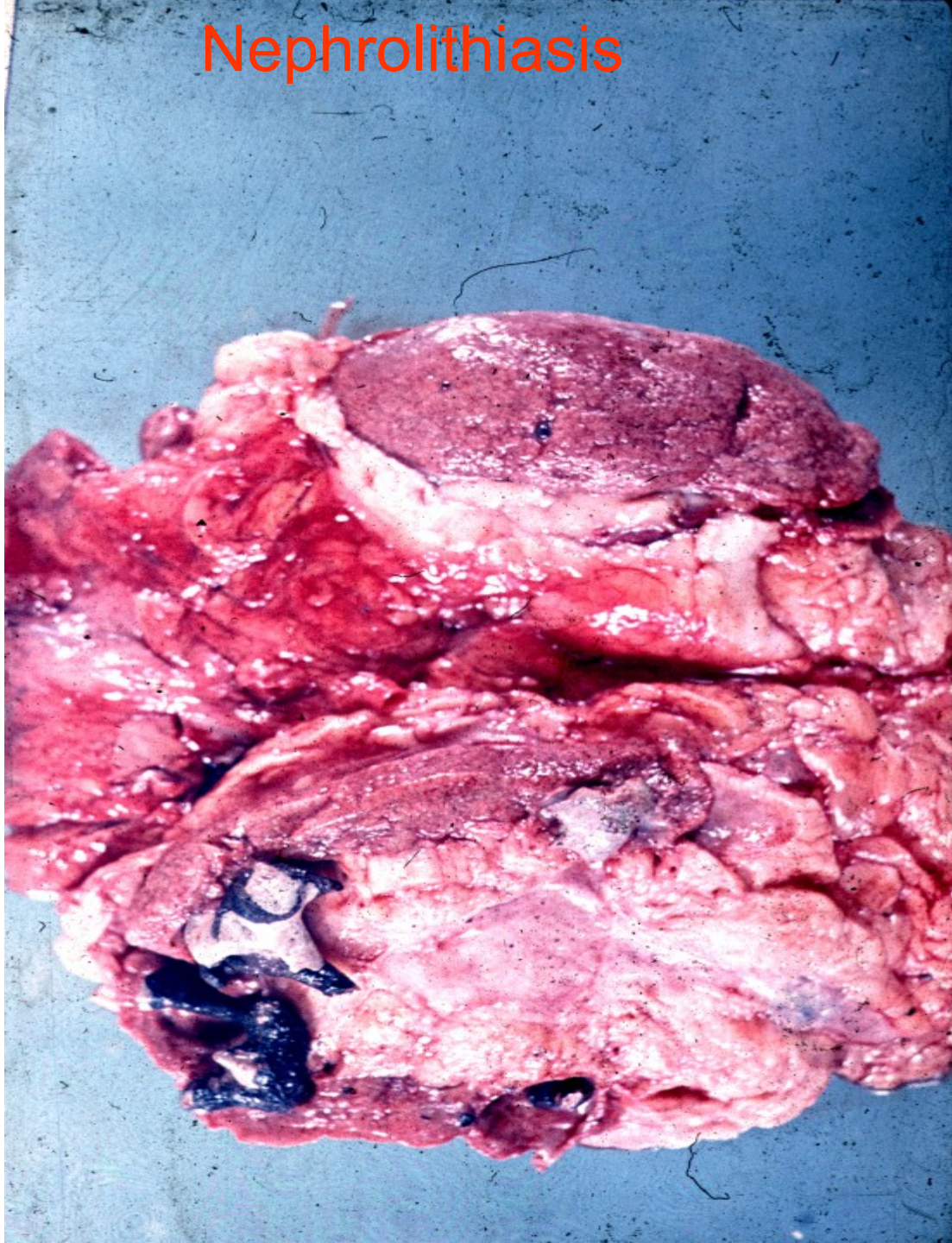
- Usually of renal origin
- Stones  $> 5$  mm cannot pass into ureter
- Renal colic – pain + spasms during the passage of a stone along the ureter
- Chronic dull pain lumbal – lower pelvic region
- $\uparrow$  risk of obstruction
- Repeated infection
- Epithelial transformation: squamous metaplasia

# Urinary calculi

- **Calcium** containing stones: commonest, laid down in an acid urine.
- **Complex triple phosphate** stones: often associated with urinary infection, in an alkaline urine.
- **Mixture of uric acid and urate-uric acid** stones, 20% of patients with gout, in an acid urine. Pure uric acid stones radiolucent.
- **Cystine** stones: in primary cystinuria, important in childhood.

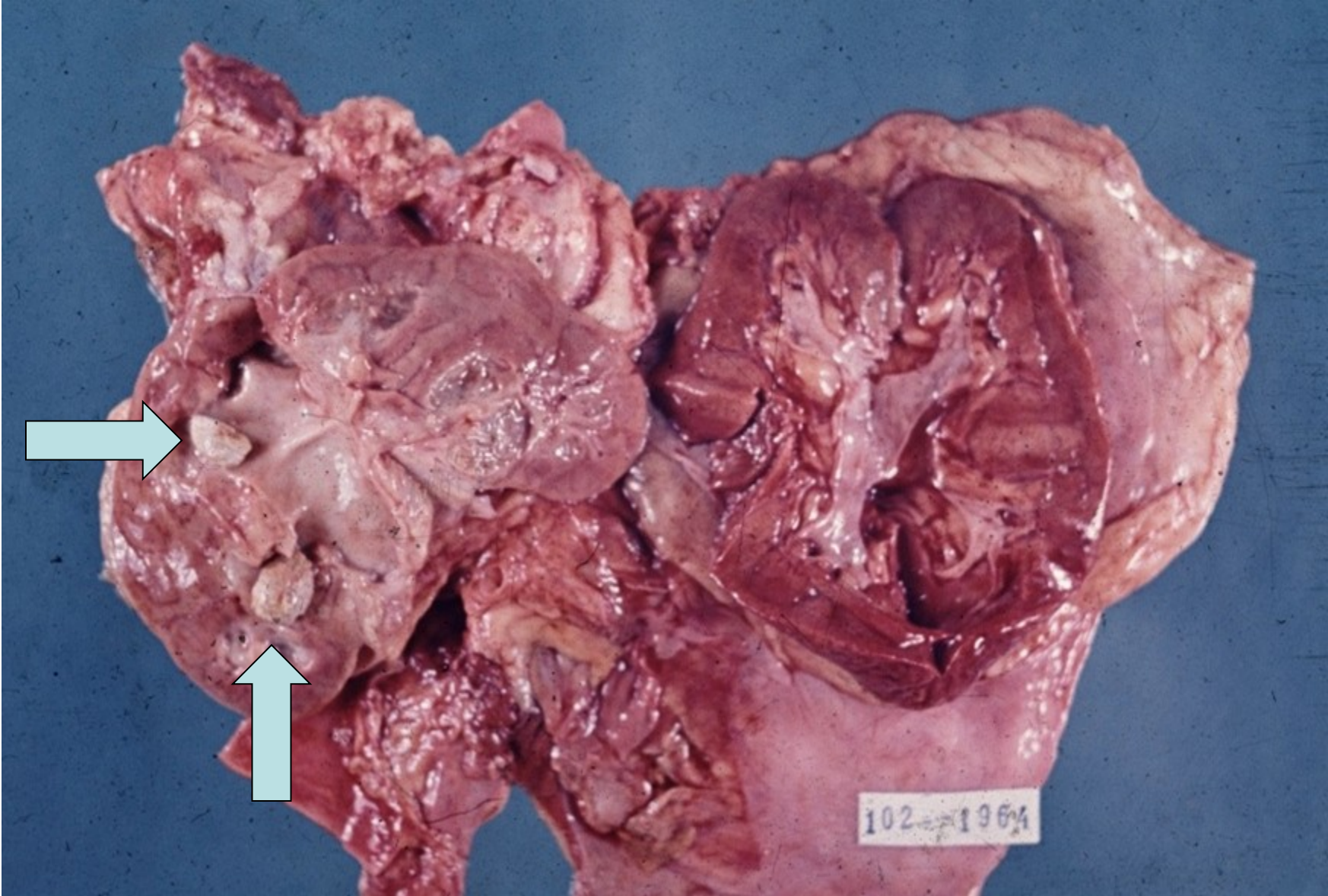


# Nephrolithiasis

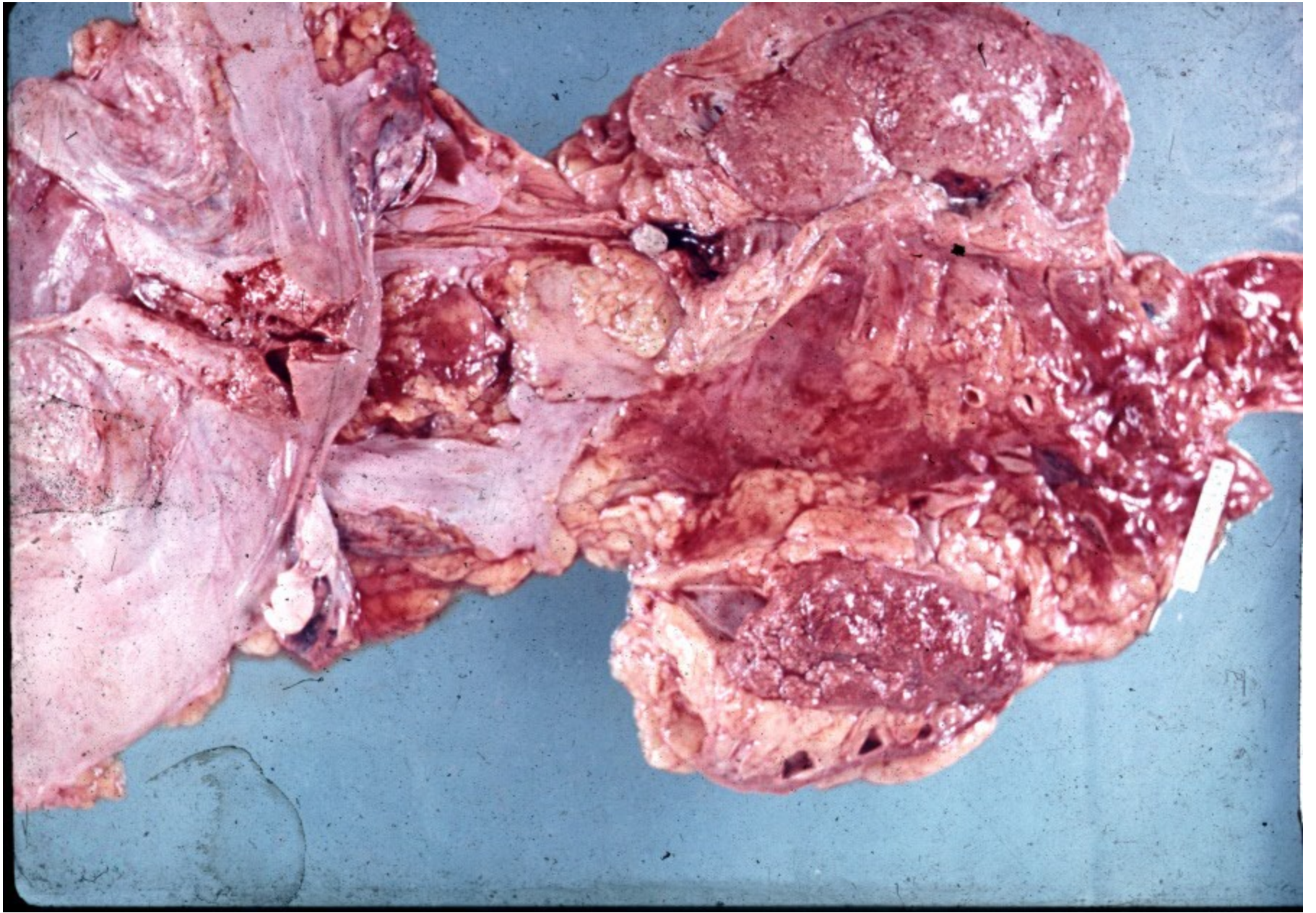




# Pyelolithiasis in situ

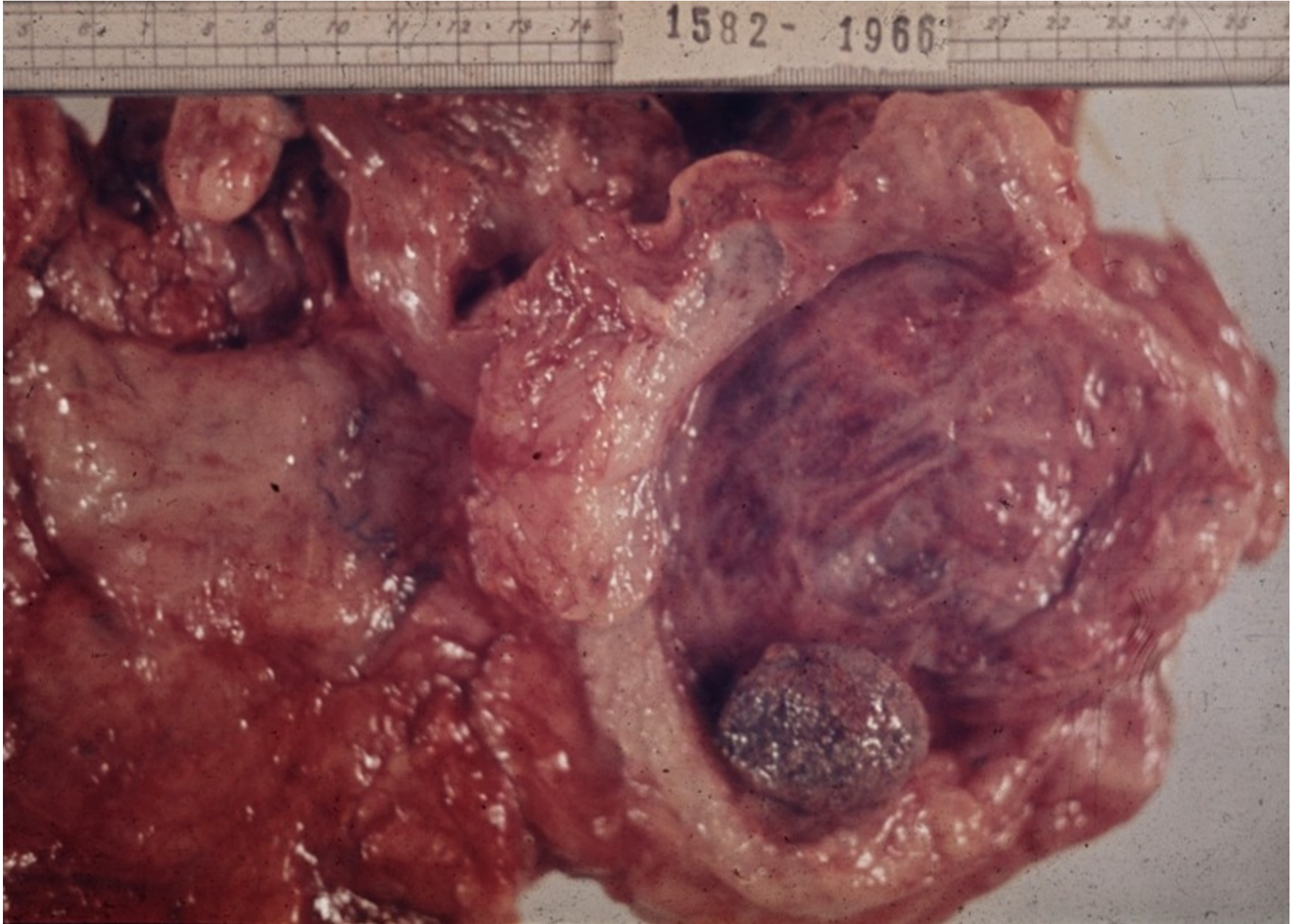







# Urocytolithiasis

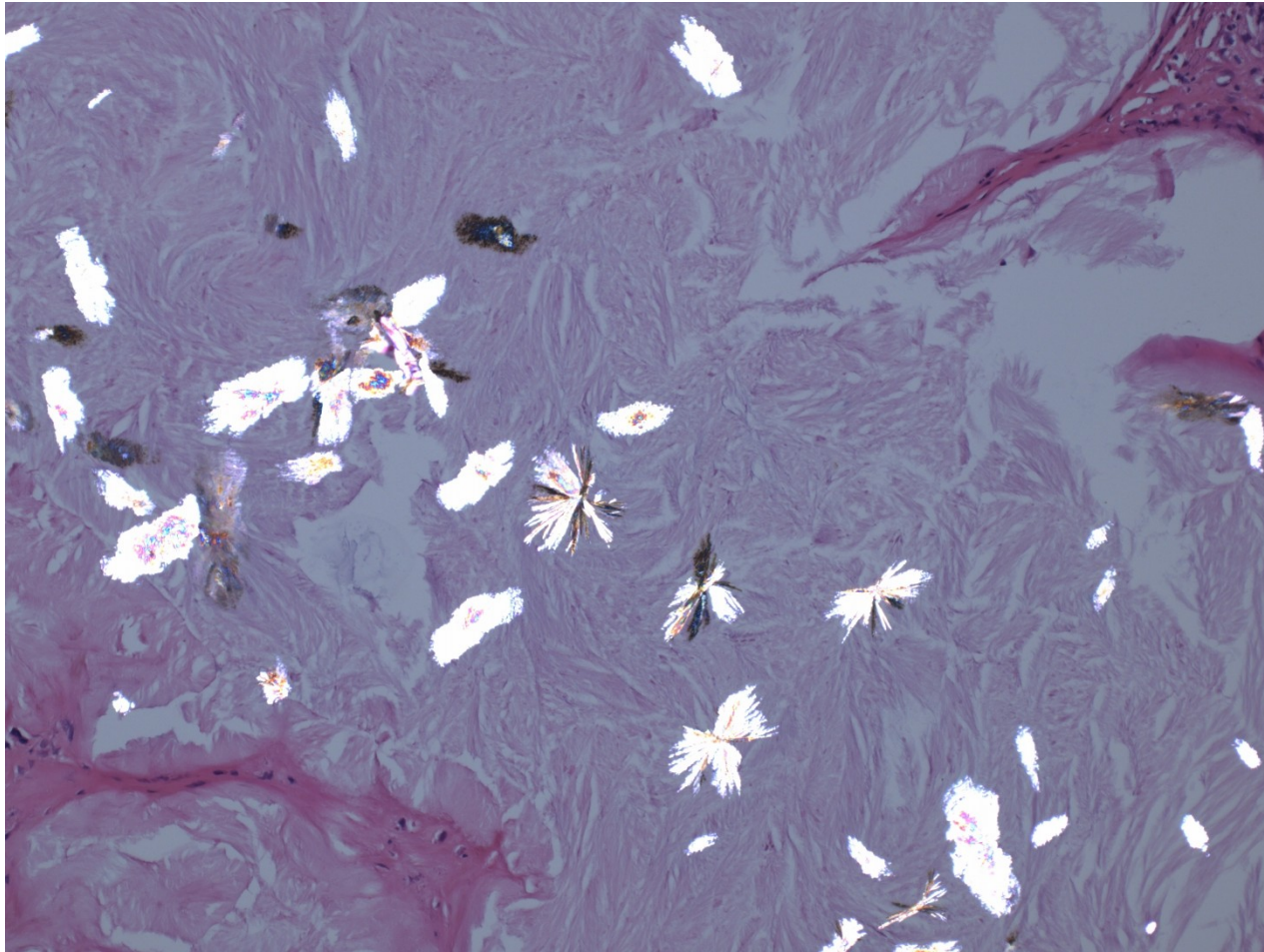


# Urate nephropathy


- Hyperuricemic disorders (urate crystals formation) may lead to 3 forms of injury:
- **Acute urate nephropathy** in patients with haematologic malignancies, commonly during chemotherapy (extensive cell breakdown – release of nucleic acids – urate crystals in tubules – acute renal failure
- **Chronic urate nephropathy** – in gout. Urate crystals surrounded by foreign body giant cells, tubulo-interstitial nephritis
- **Urate stones**



# Urate crystals



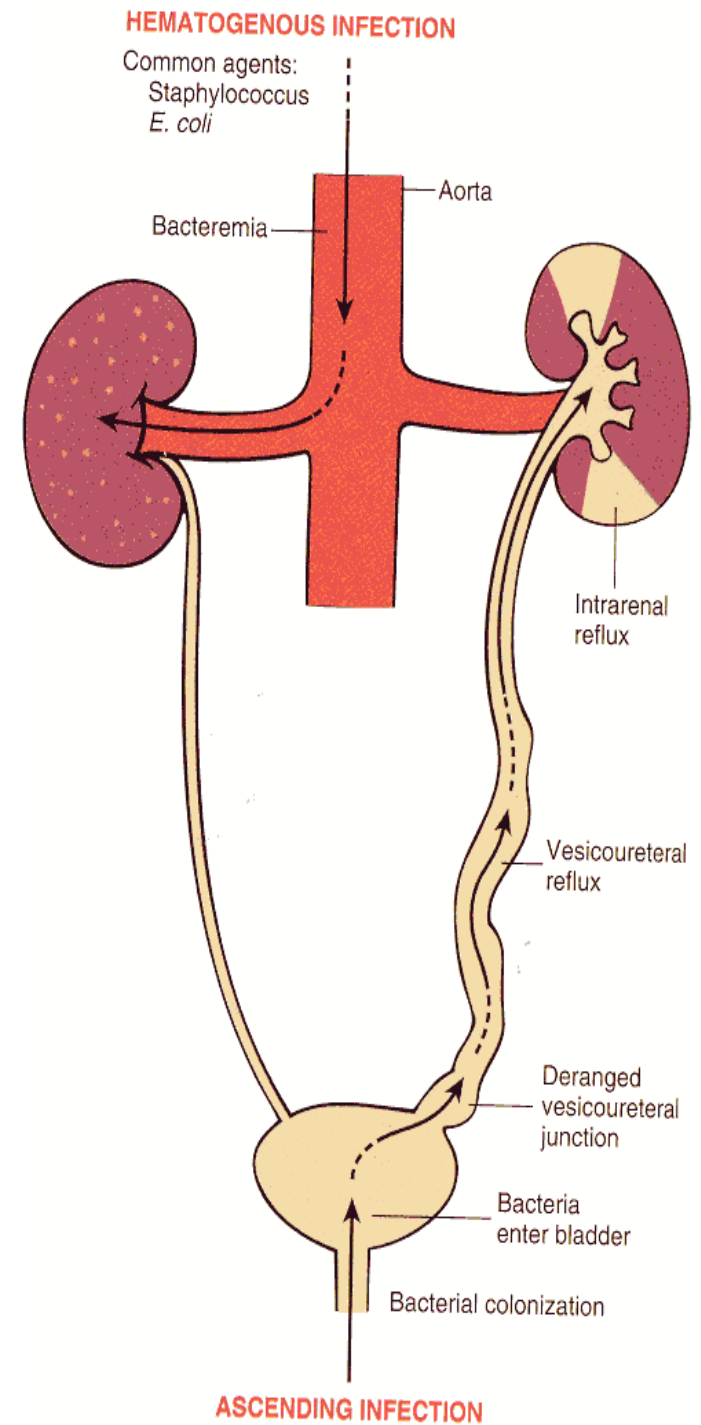
# Urate crystals - polarization



# Acute pyelonephritis

- Common purulent renal inflammation, bacterial infection by *Escherichia coli*, *Proteus*, *Klebsiella*, *Enterobakter*
- **Ascending** infection by urine reflux in urinary tract inflammation
- **Descending (haematogenous)** infection in septicaemia, rare

# Acute pyelonephritis

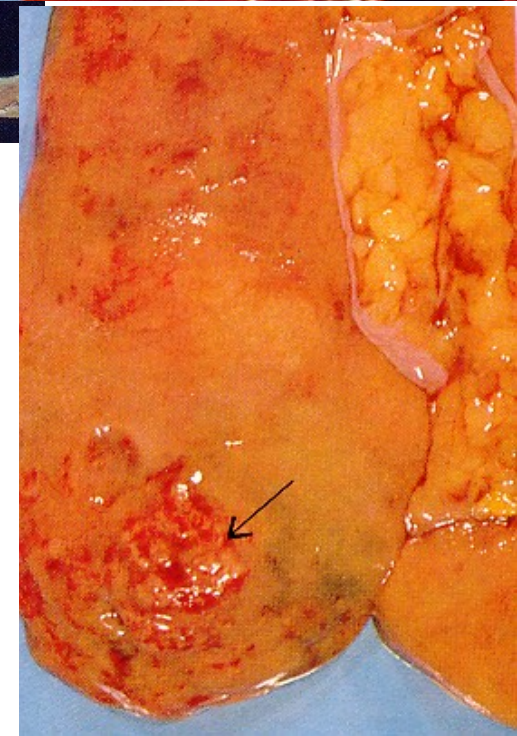
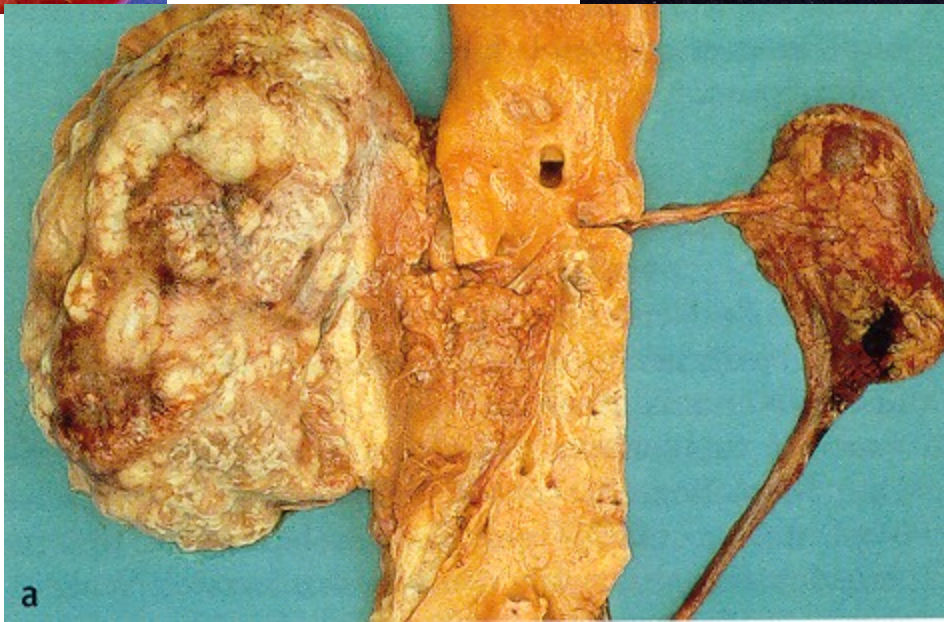
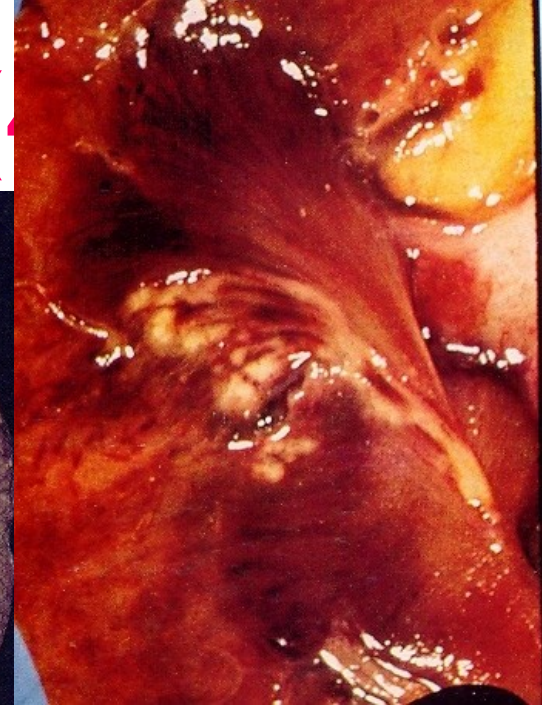
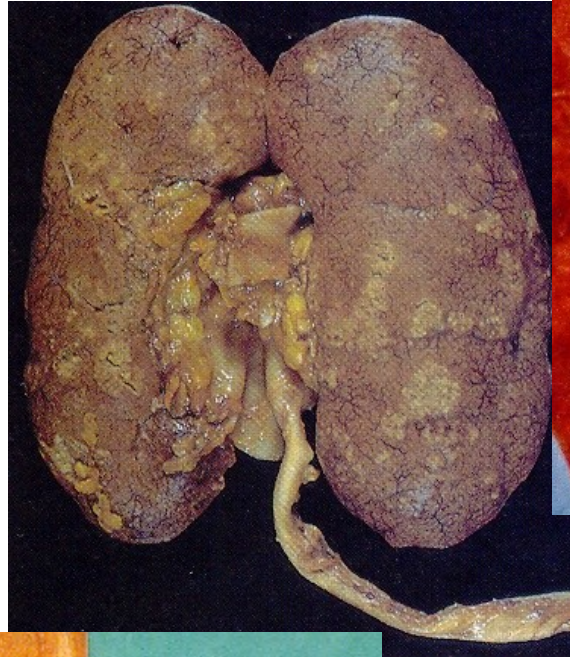
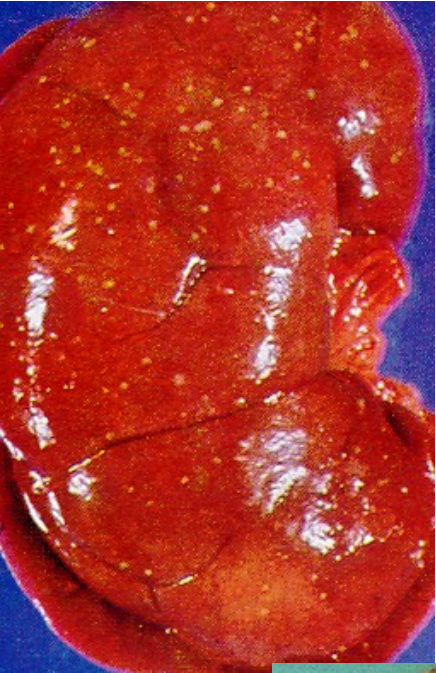
# Acute pyelonephritis

- Facilitated by DM, gout, all causes of obstructive uropathy (e.g. nephrolithiasis, tumors, urinary tract anomalies incl. vesicoureteric and intrarenal reflux)
- Instrumental interventions (cathetrization, cystoscopy)
- GROSS: enlarged kidney, cortical and medullary abscesses
- MICRO: purulent neutrophilic exudate in tubules and interstitium, oedema

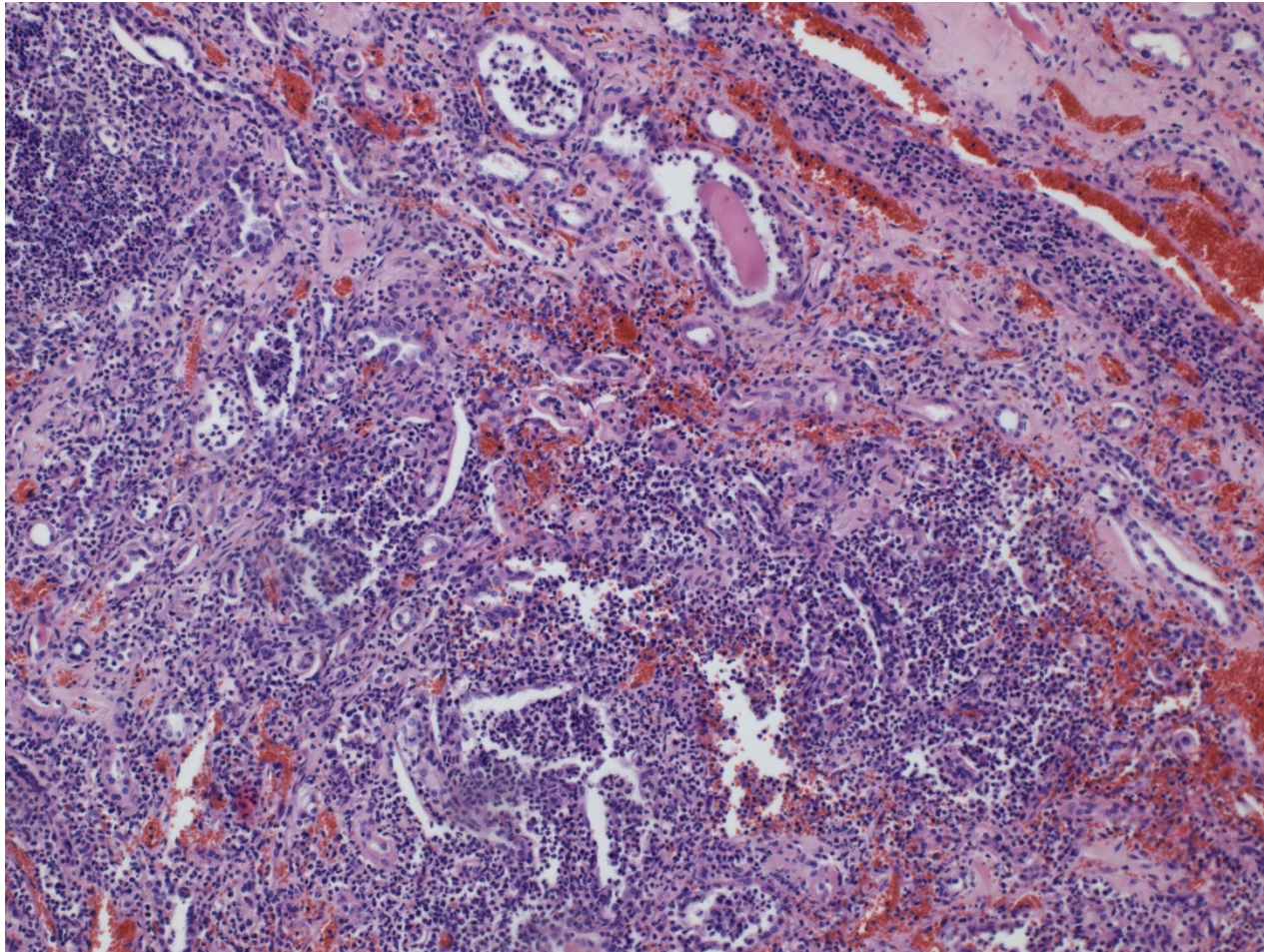


# Acute pyelonephritis (A)





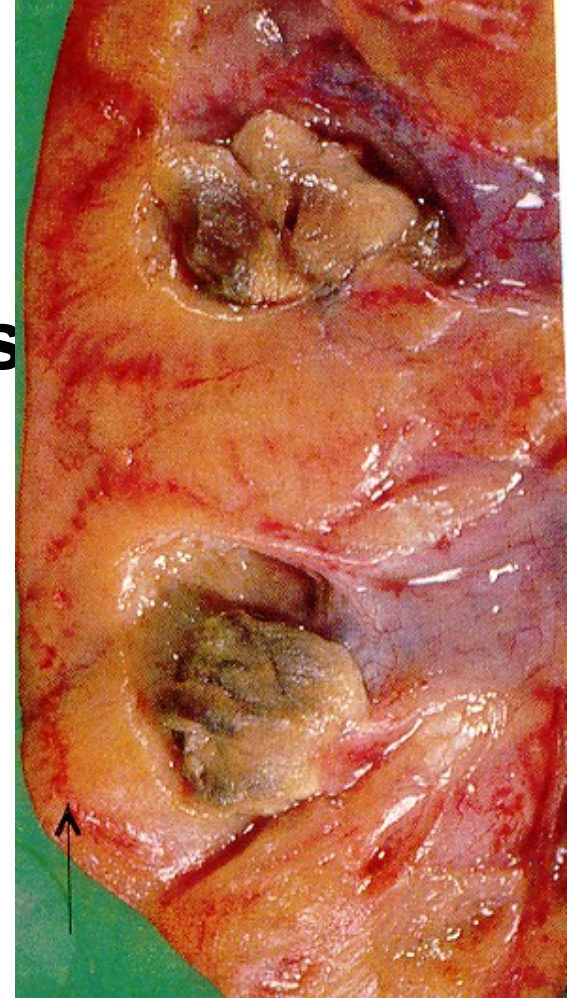
# Acute pyelonephritis



# Acute pyelonephritis

- **Pyonephros**
- **Papillary necrosis** in diabetics
- **Peri- and paranephritic abscess**

**Papillary  
necrosis**

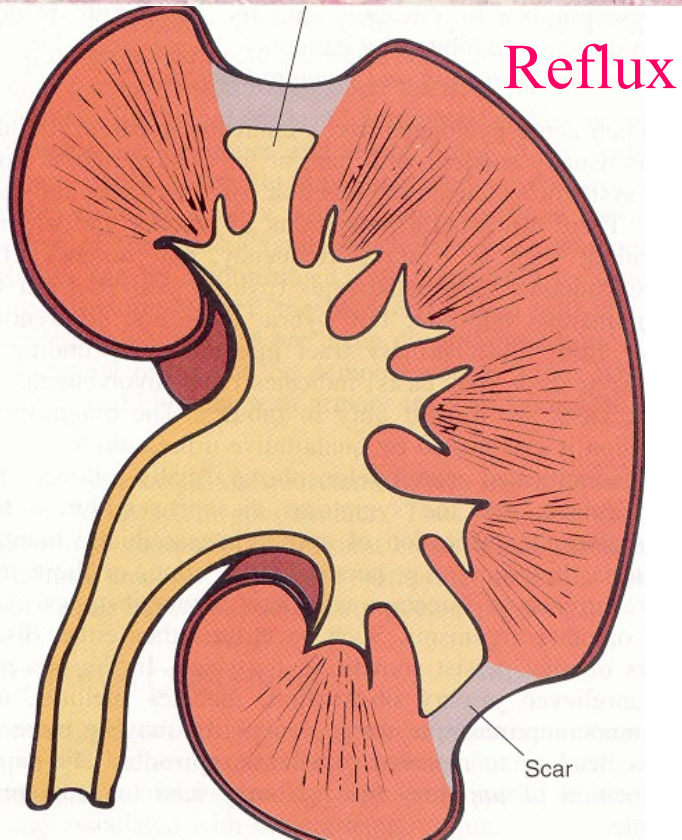
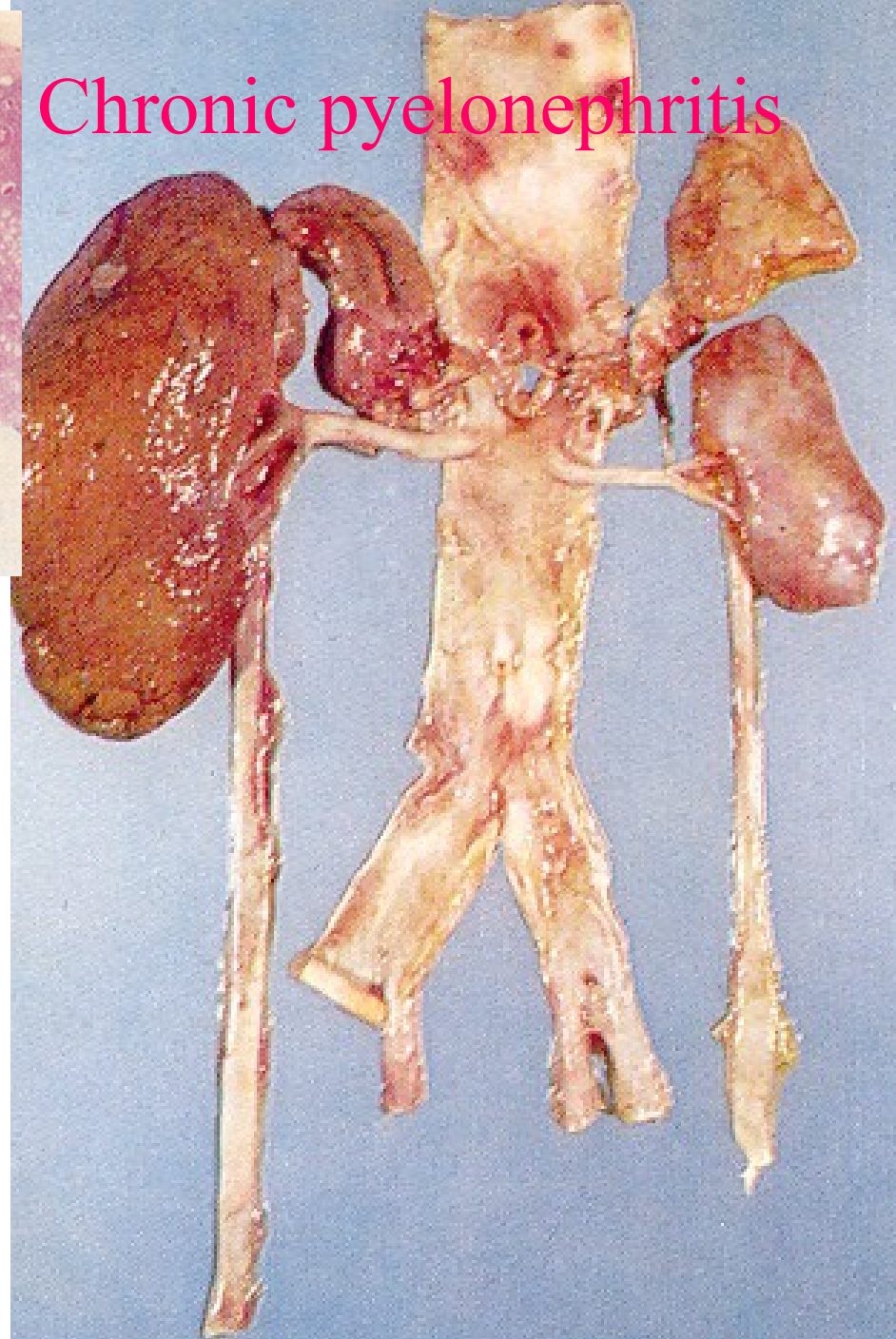
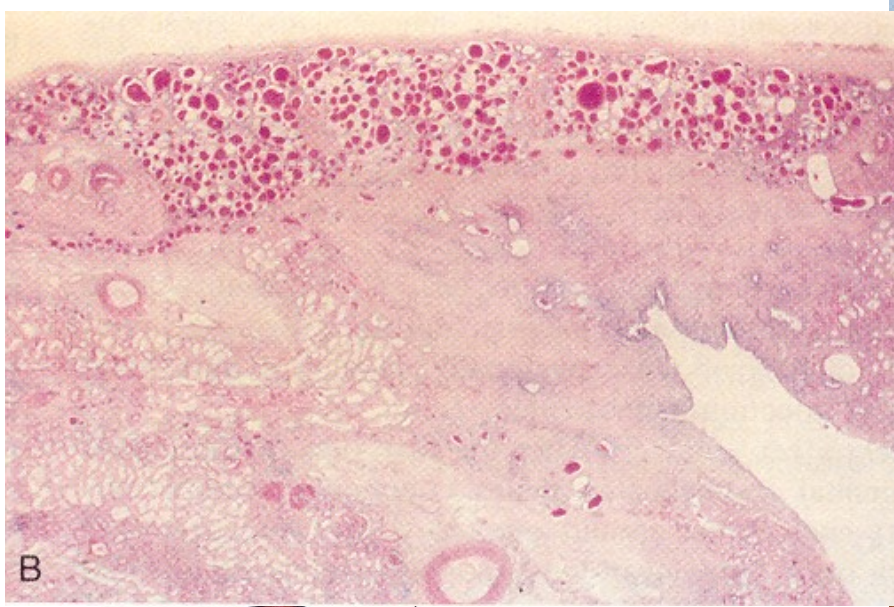




# Chronic pyelonephritis

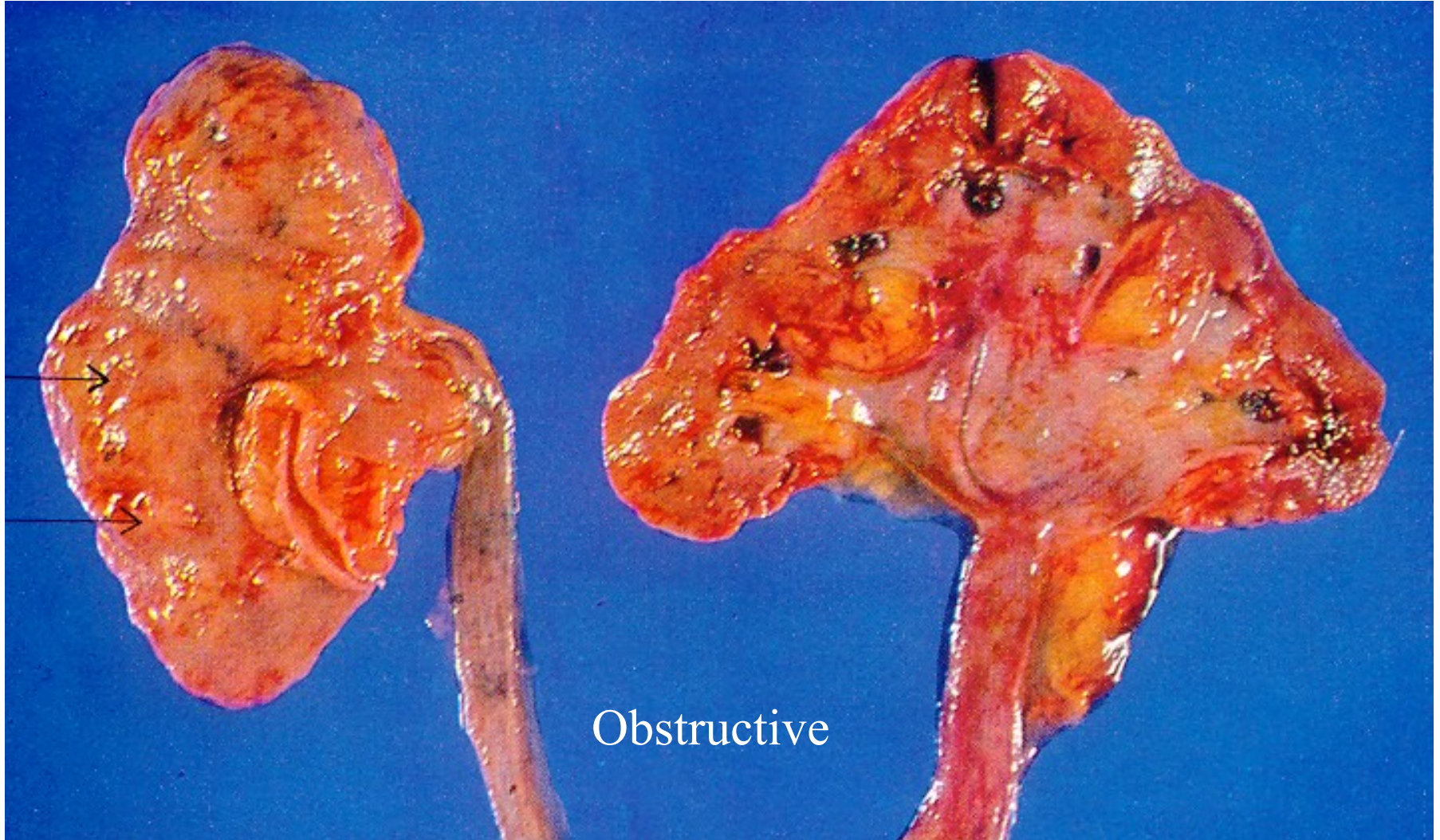- Uni- or bilateral chron. tubulointerstitial renal inflammation with scarring
- 10-20% end-stage kidney
- **Obstructive PN** - repeated infections
- **Reflux nephropathy –vesicoureteric and/or pelveorenal reflux** (from lower and upper pole calyces into renal parenchyme)

# Chronic pyelonephritis



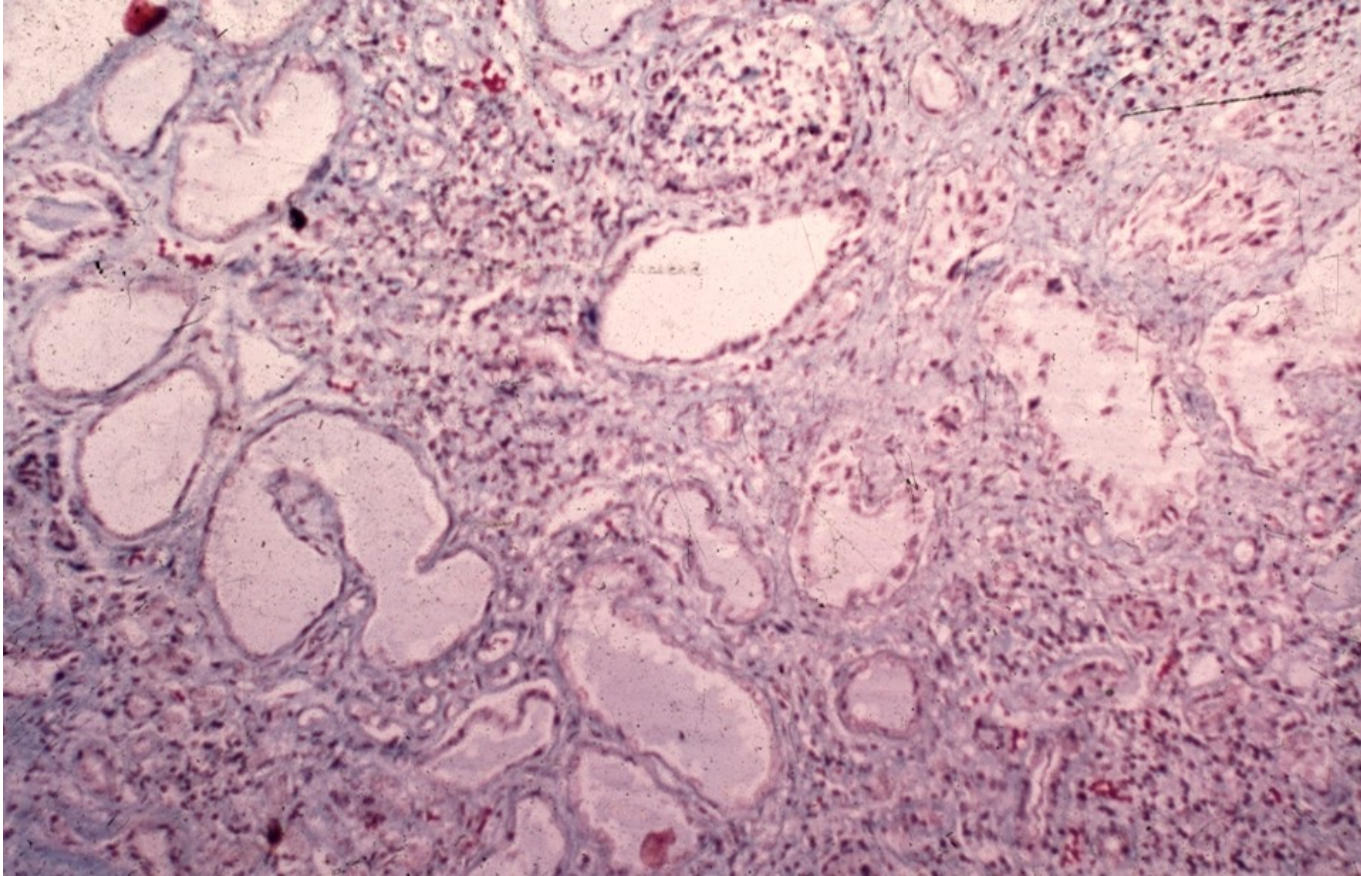


# Chronic pyelonephritis

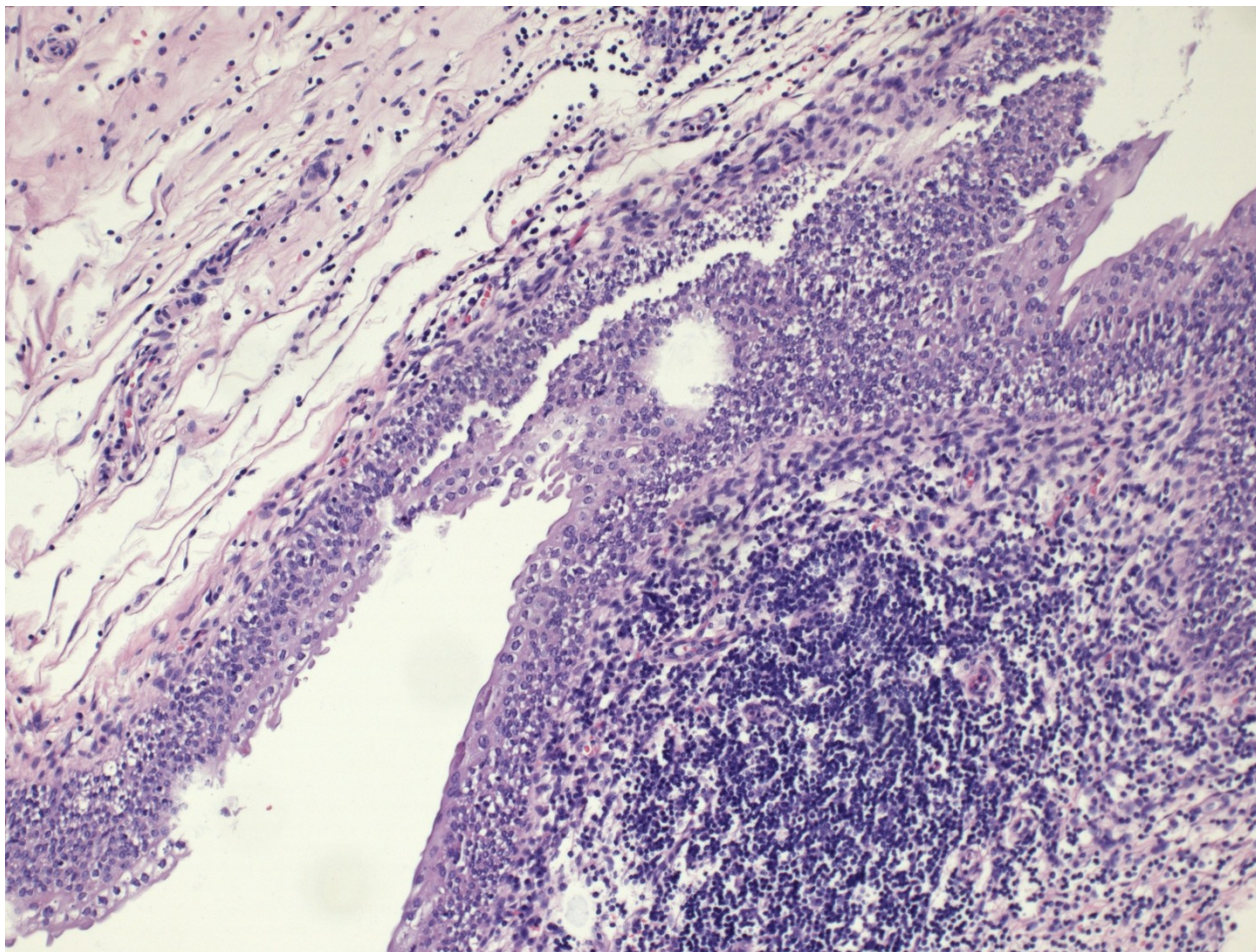




# Chronic pyelonephritis

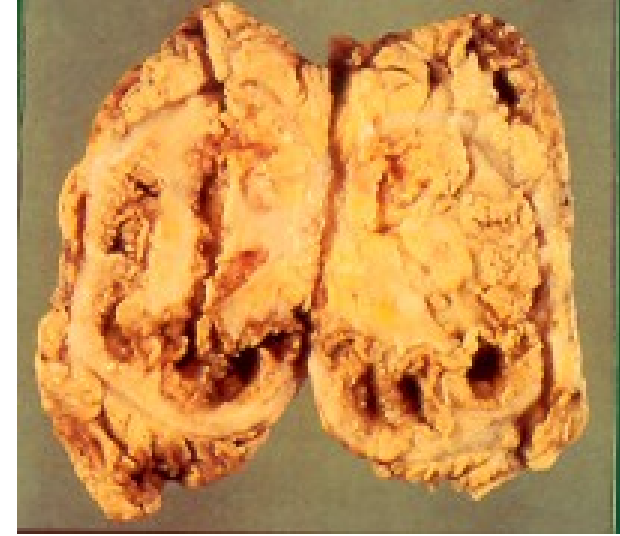

# Chronic pyelitis





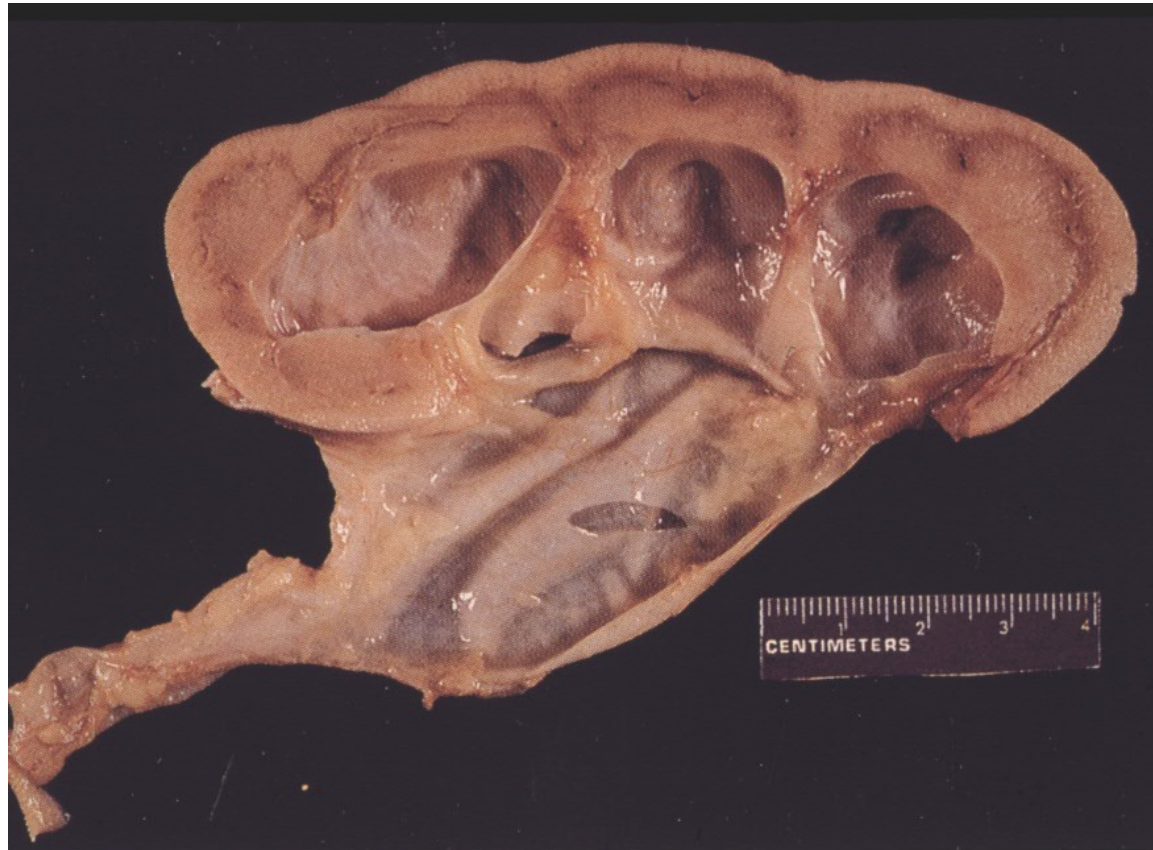# Xanthogranulomatous pyelonephritis



- Uncommon form of chronic pyelonephritis with accumulation of foamy macrophages in interstitium
- Yellowish focal lesions in macroscopy, diff. dg. x renal carcinoma

# Hydronephrosis, hydroureter

Renal tissue atrophy, renal insufficiency



# Tumors of the renal pelvis

**Primary:** transitional cell neoplasia, mostly papillary transitional cell carcinoma (invasive, non-invasive)  
Rarely other types of carcinoma (squamous cell, neuroendocrine, adenocarcinoma)  
Other types (mesenchymal, melanoma, ...)

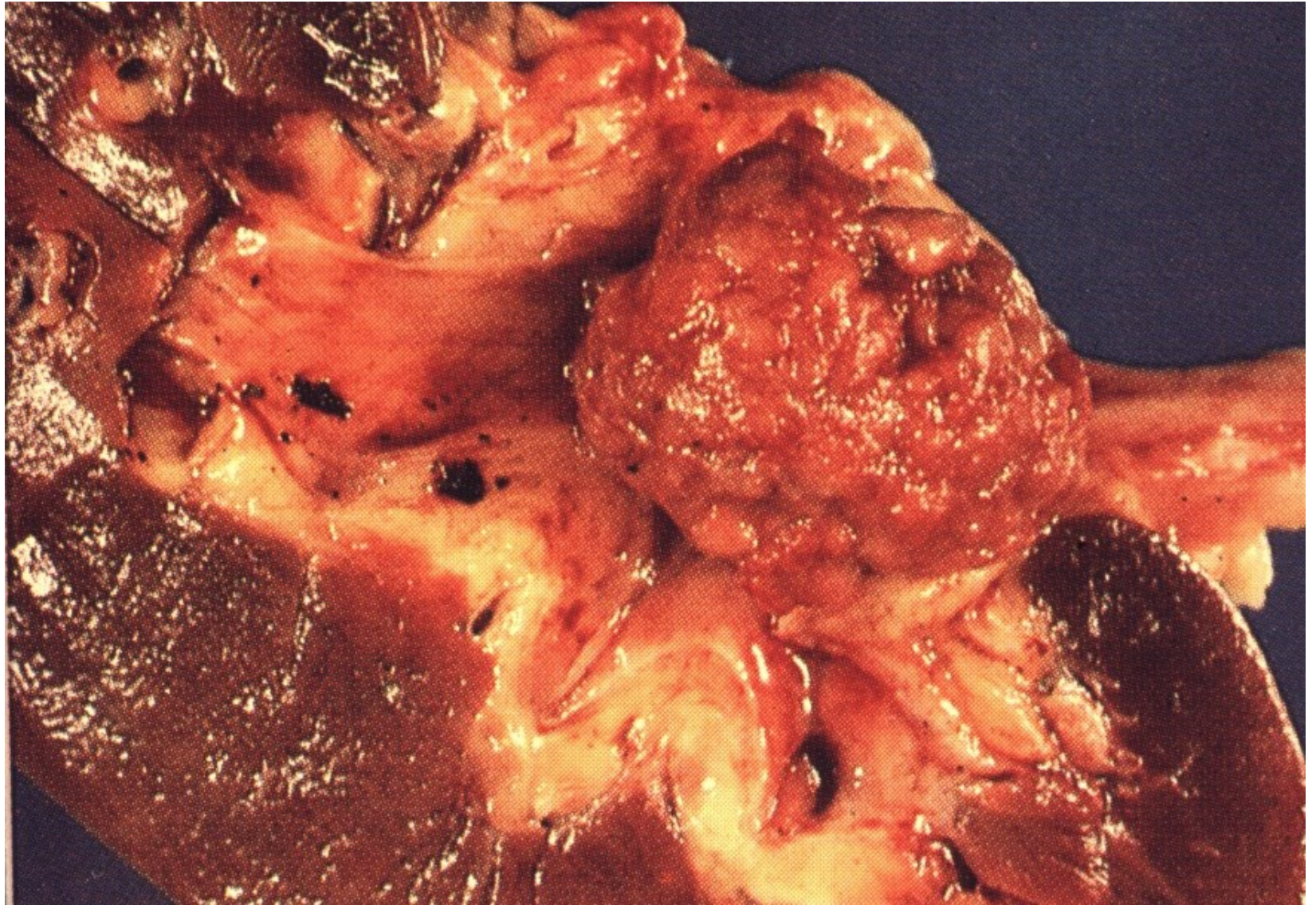
**Secondary:** local progression from the kidney  
metastasis



# Transitional cell ca

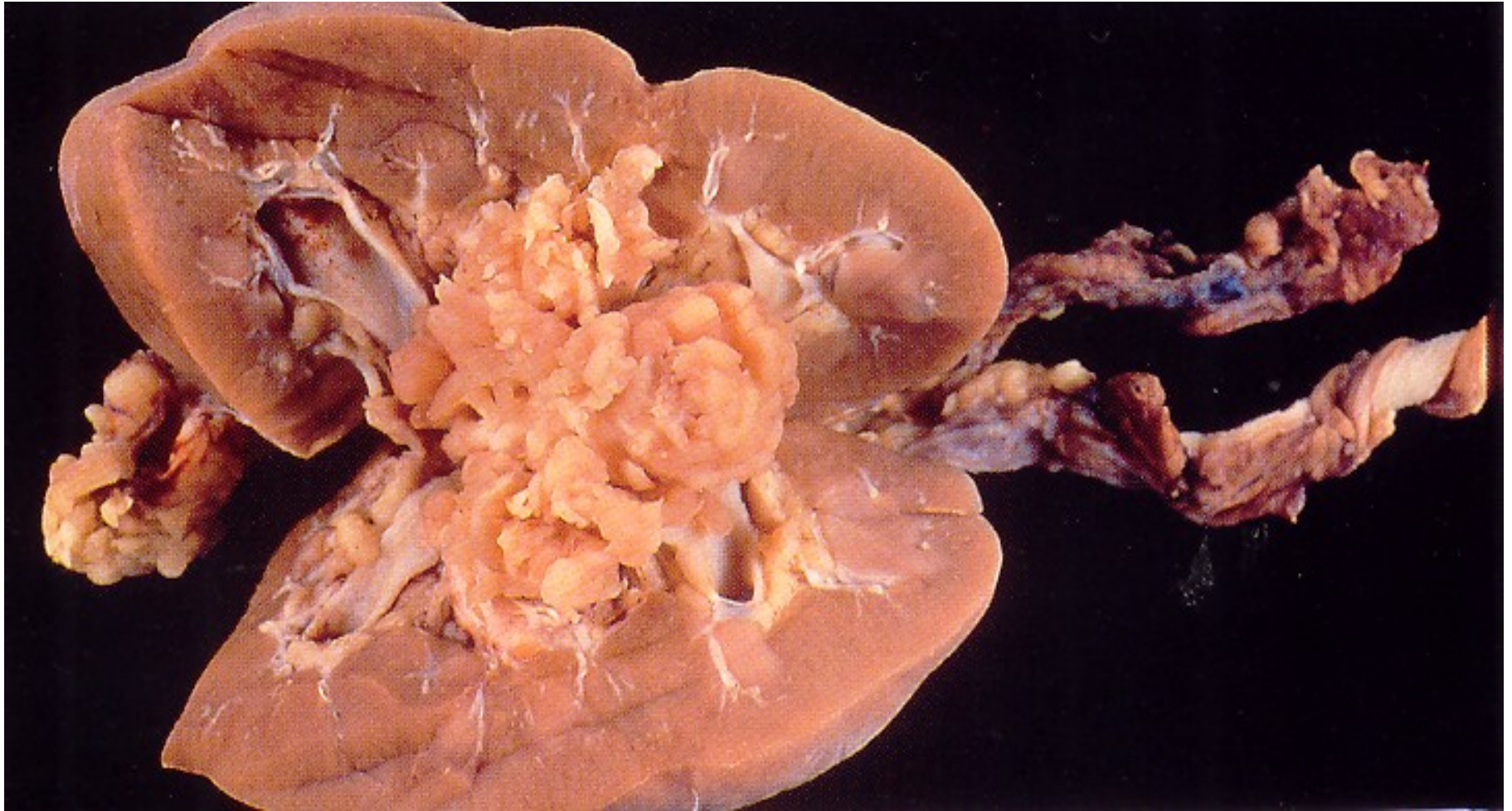
- in pelvis or ureter less common than bladder
- possible multiple dysplastic foci
- histopathology similar to bladder ca
- possible perigenous seeding
- invasion into kidney and surrounding tissues
- diff. dg. x renal cell ca

## Invasive urothelial carcinoma – renal pelvis

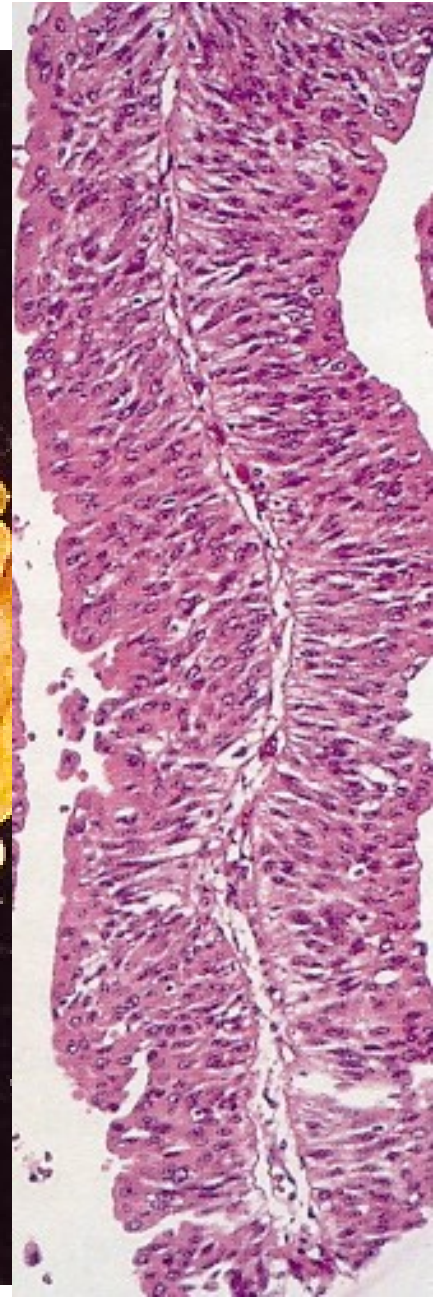
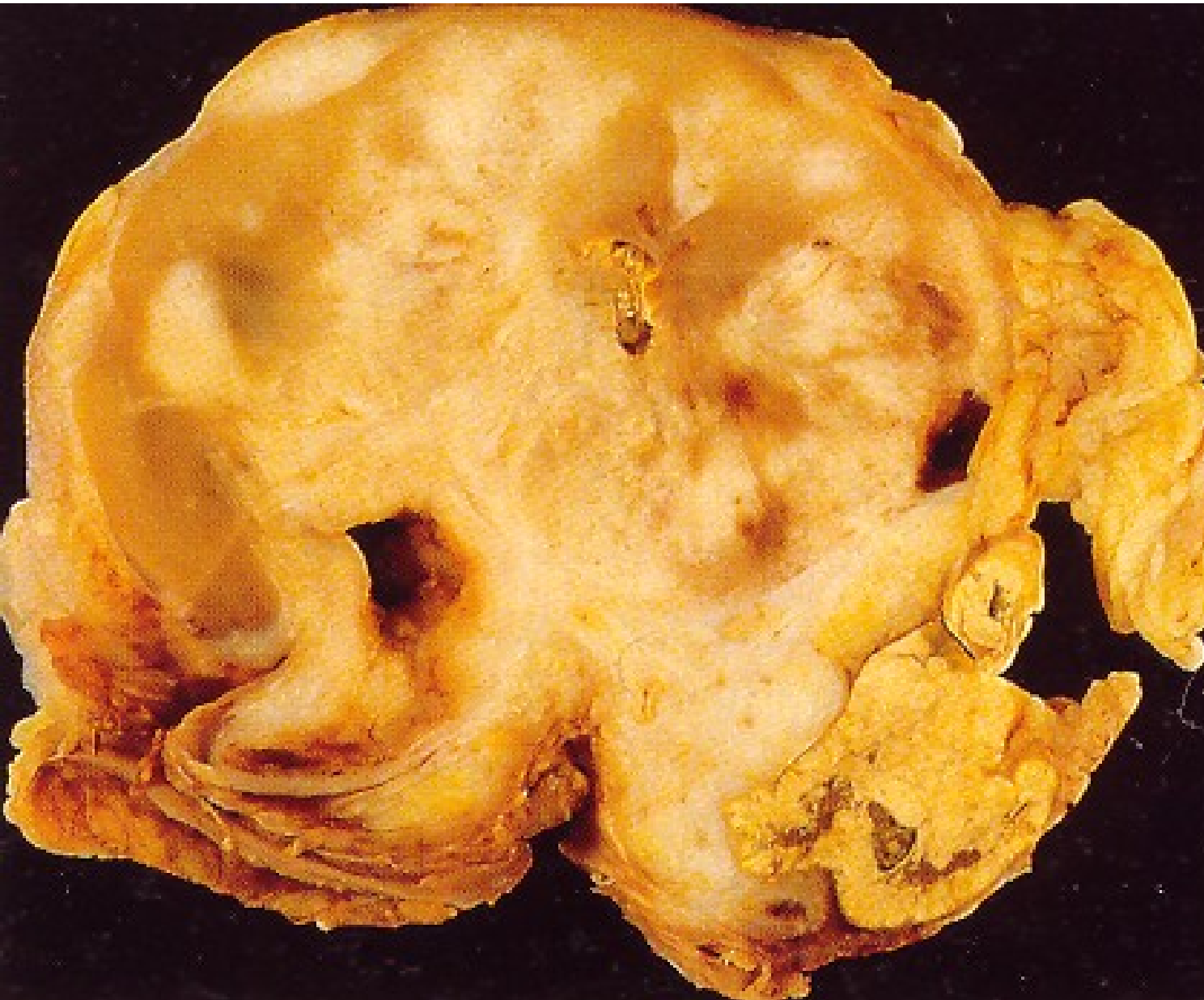



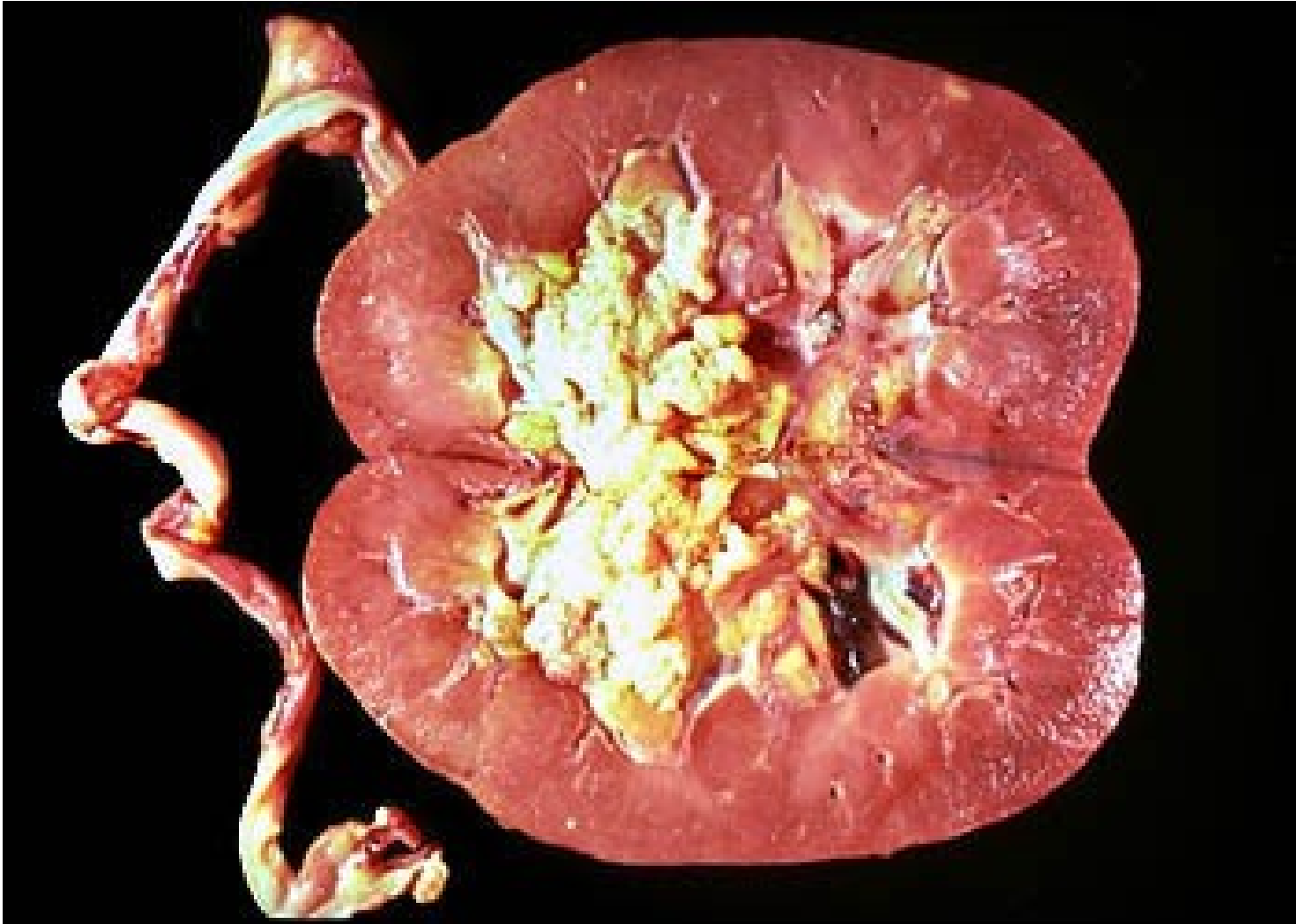# Transitional cell ca of the renal pelvis



# Transitional cell ca of the renal pelvis



Concurrent urothelial ca of pelvis + bladder possible



# Ureter

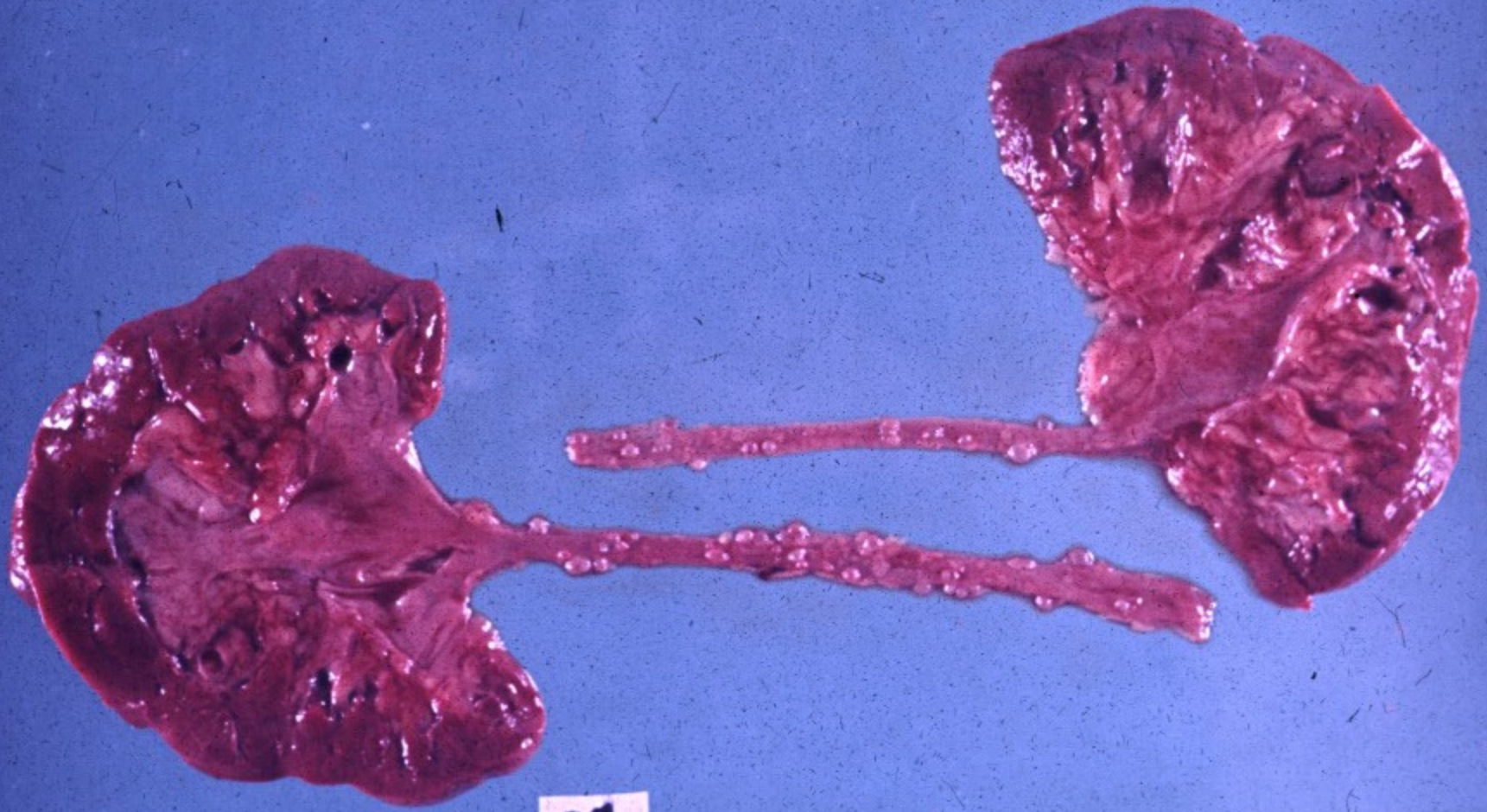
- **congenital anomalies** (double/bifid ureter, obstruction of the ureteropelvic junction, lesion of the vesicoureteric junction, diverticula)
- **obstruction**
- **inflammation** (acute, chronic incl. ureteritis cystica - preneoplastic)
- **neoplasia and pseudotumorous lesions** (transitional cell tu, squamous cell ca, fibroepithelial polyp, etc.)

# Ureteritis cystica

- Special form of chronic ureteritis
- Numerous cysts in the ureteral mucosa, solid or cystic nests of transitional or metaplastic glandular epithelium.
- Terminal stage of chronic inflammations
- ↑ risk of ca

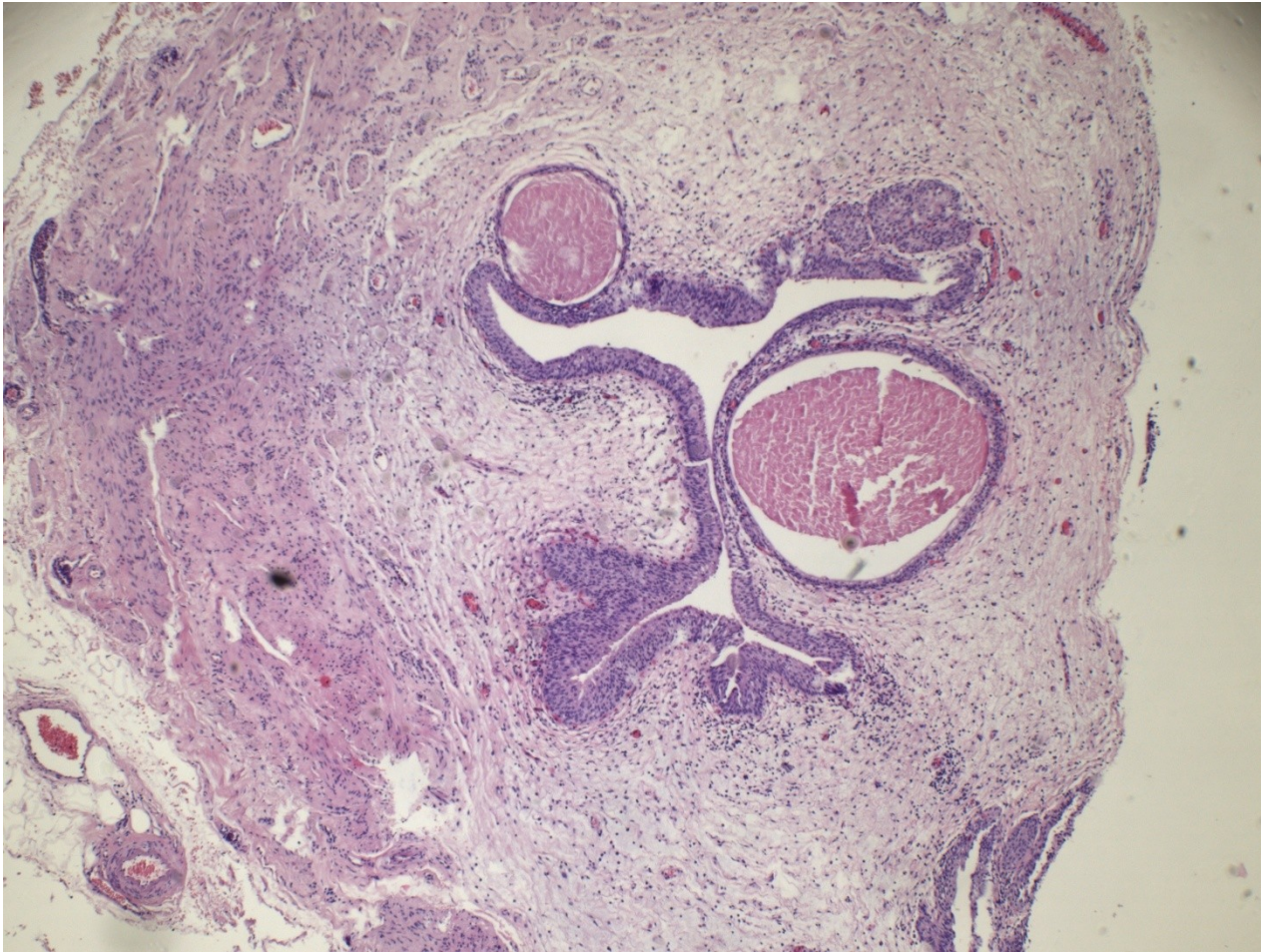

# Chronic ureteritis cystica

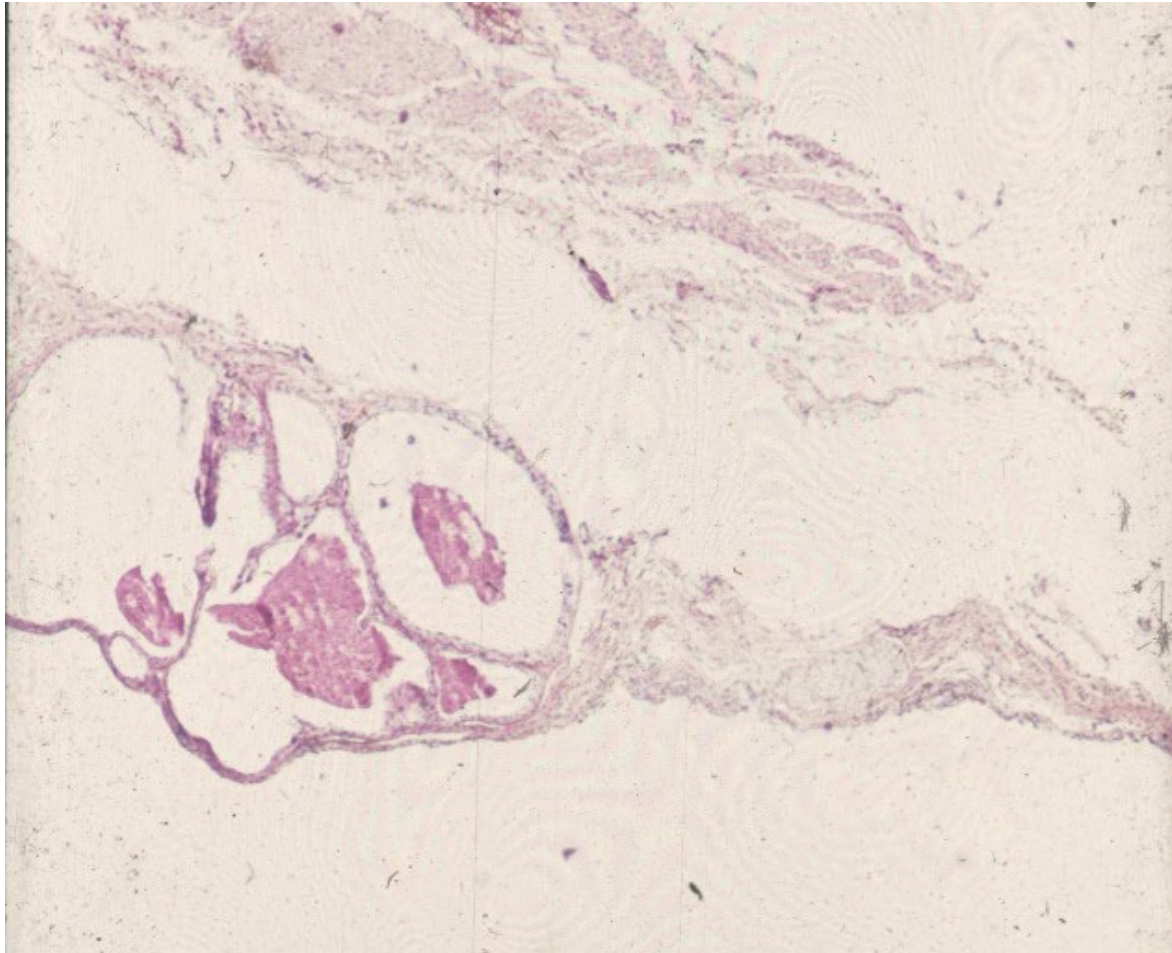




# Cystic ureteritis



# Cystic ureteritis

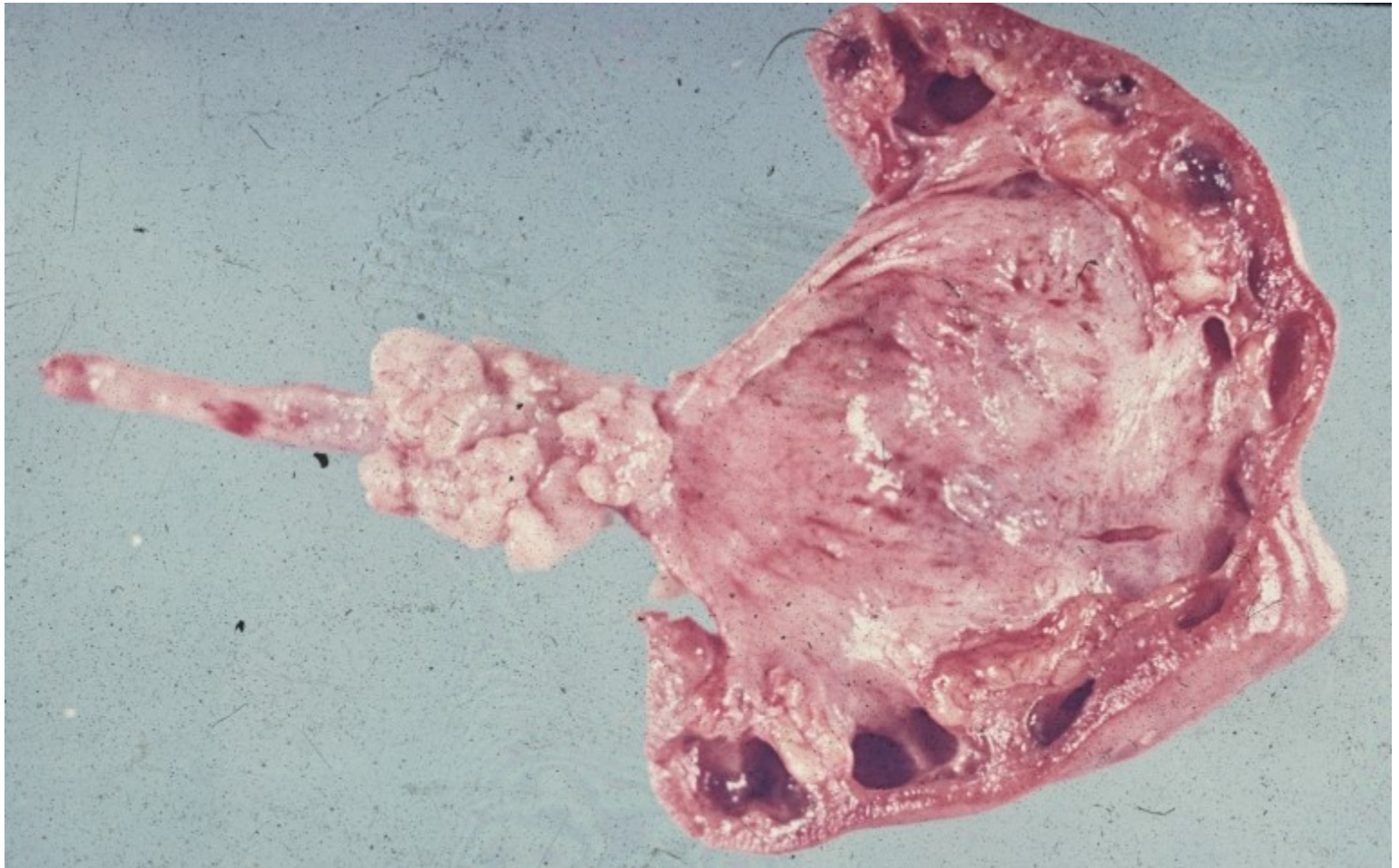




# Tumors, tumor-like lesions

- **Fibroepithelial polyp**: small, loose stroma + epithelium
- **Benign**: rare, mesenchymal tumors
- **Malignant**: transitionall cell carcinoma  
progression of malignancy from surrounding tissues

# Transitional cell carcinoma of the ureter



# Urinary bladder

- **congenital anomalies** (exstrophy, diverticula, persistent urachus)
- **cystitis** (acute, chronic, special forms – malakoplakia, tbc, schistosomiasis, etc.)
- **metaplasia** – usually in cystitis (c. cystica, c. glandularis), squamous m.- leukoplakia
- **tumors and pseudotumorous lesions**
- **miscellaneous** (calculi, fistulae, prolapse)



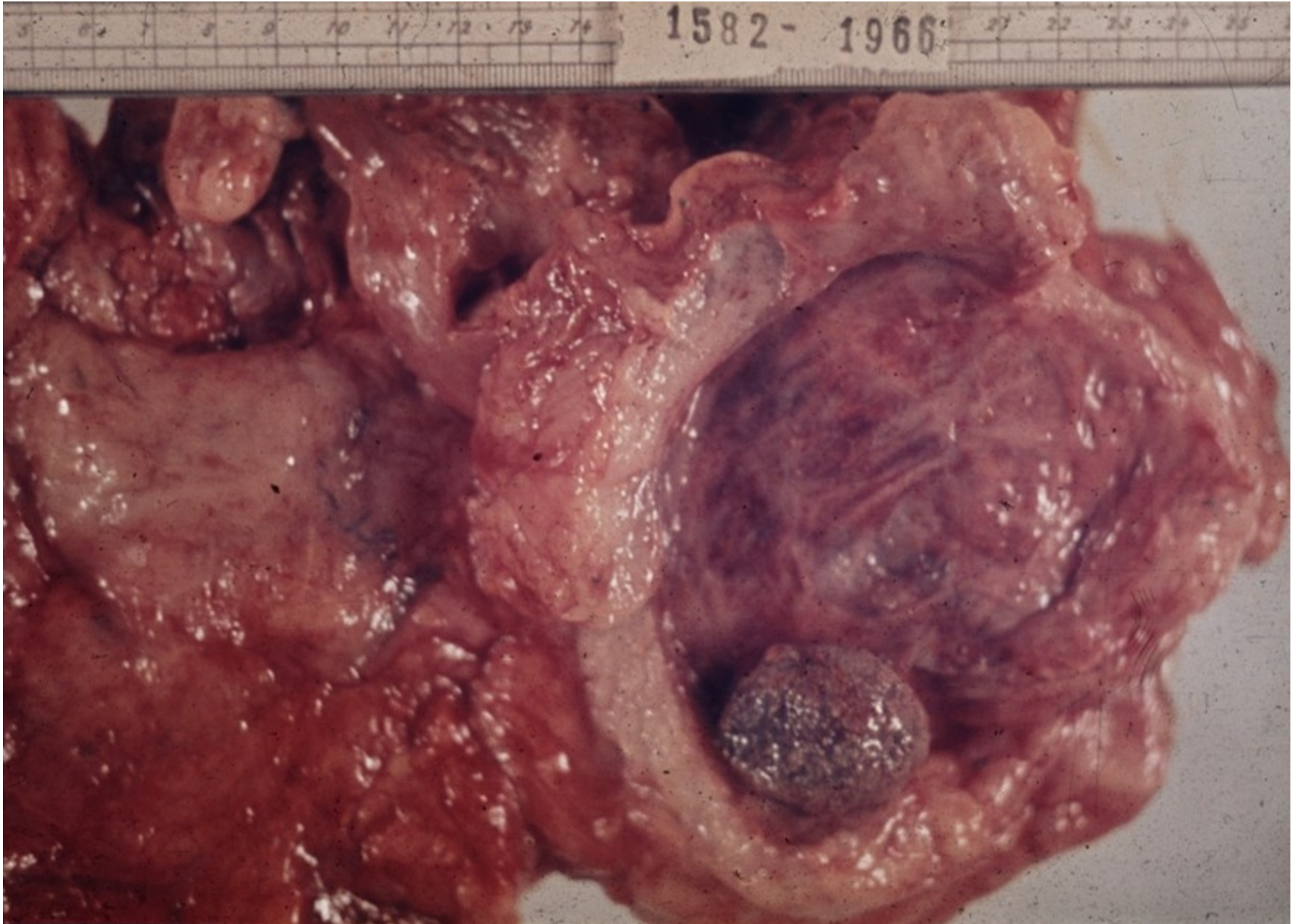# Exstrophy

- nonclosure of anterior bladder + abdominal wall incl. missing layers
- bladder may be opened to the outside
- ascending renal infection
- epithelial metaplasia, ↑ risk of ca
- commonly in combination with other congenital anomalies

# Diverticula

- **Congenital**: uncommon, solitary. Wall defect; intrauterine urinary obstruction
- **Acquired**: multiple. Most common in prostatic hyperplasia, concurrent with cystitis
- ↑ risk of infection, stones, perforation

# Urocystolithiasis + chronic cystitis + diverticula

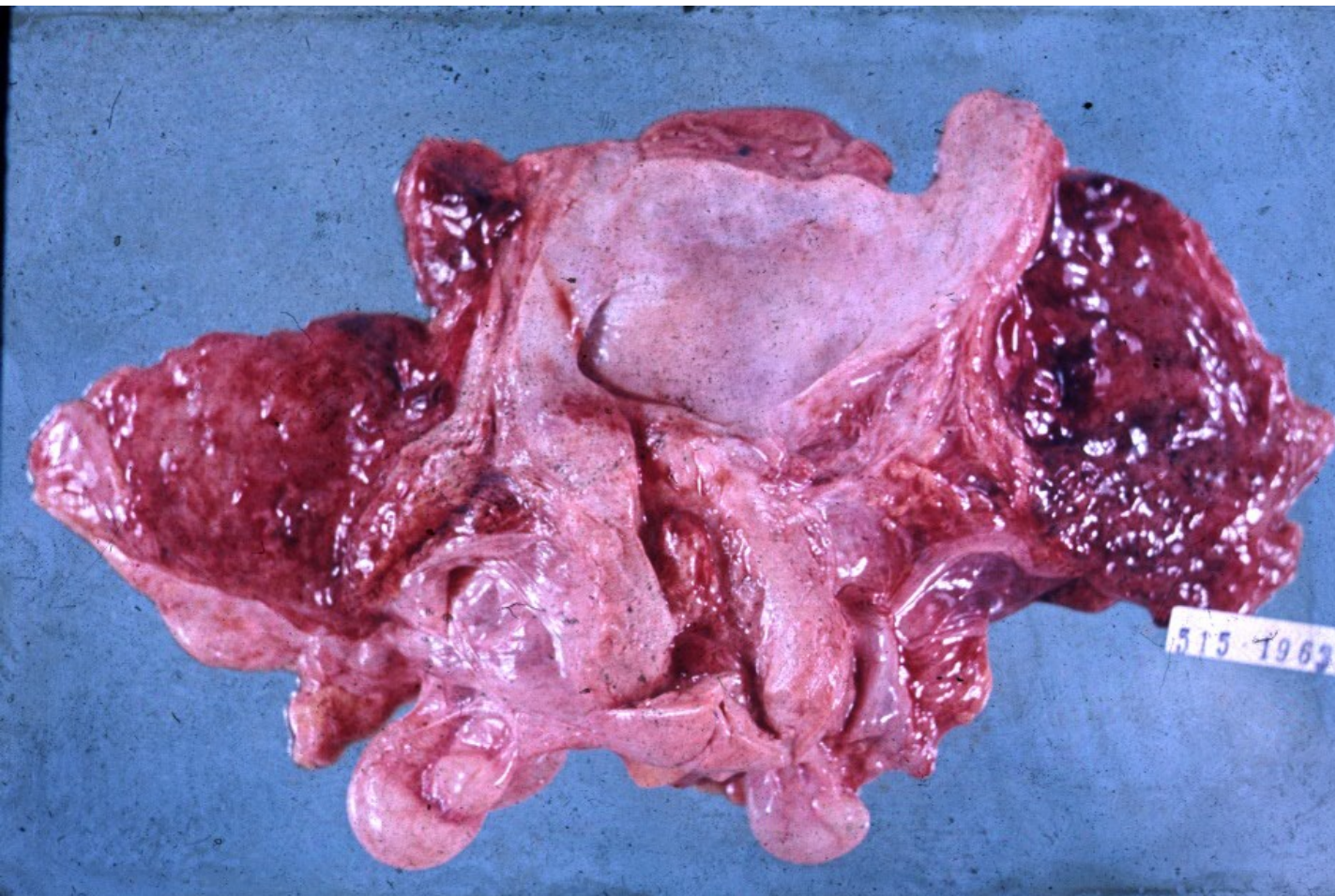




# Acute cystitis

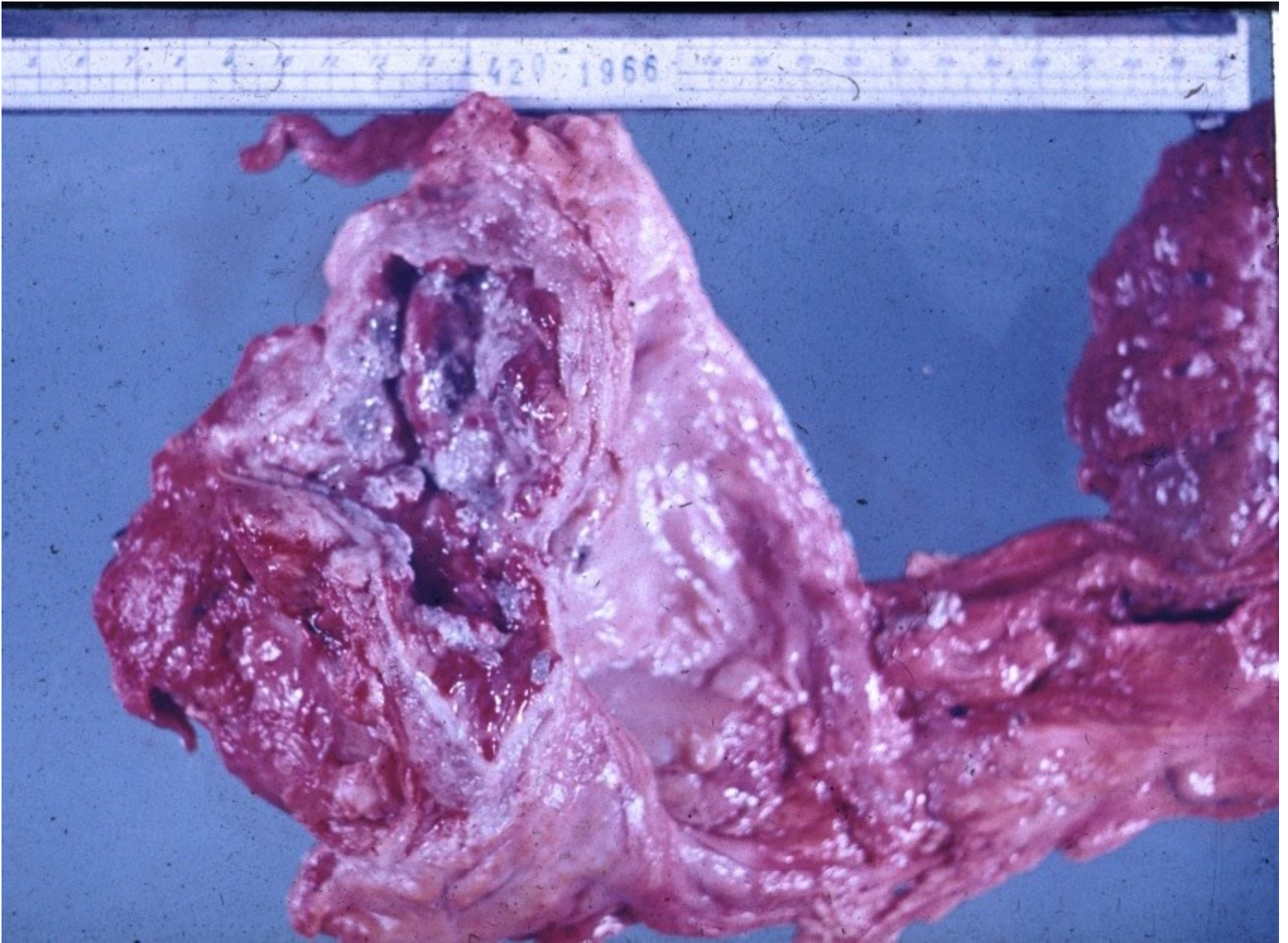
- highly common in females (short urethra, perineal connection with anus)
- mostly fecal bacteria, mixed flora
- risk factors – urine pH, hormonal status, iatrogenic
- usually purulent (leucocytes, blood in urine), urging, pain; may have systemic signs
- complications – ureteral spread, ulcers, rare phlegmona, pseudomembranous infl.

# Haemorrhagic cystitis





# Ulcerative cystitis

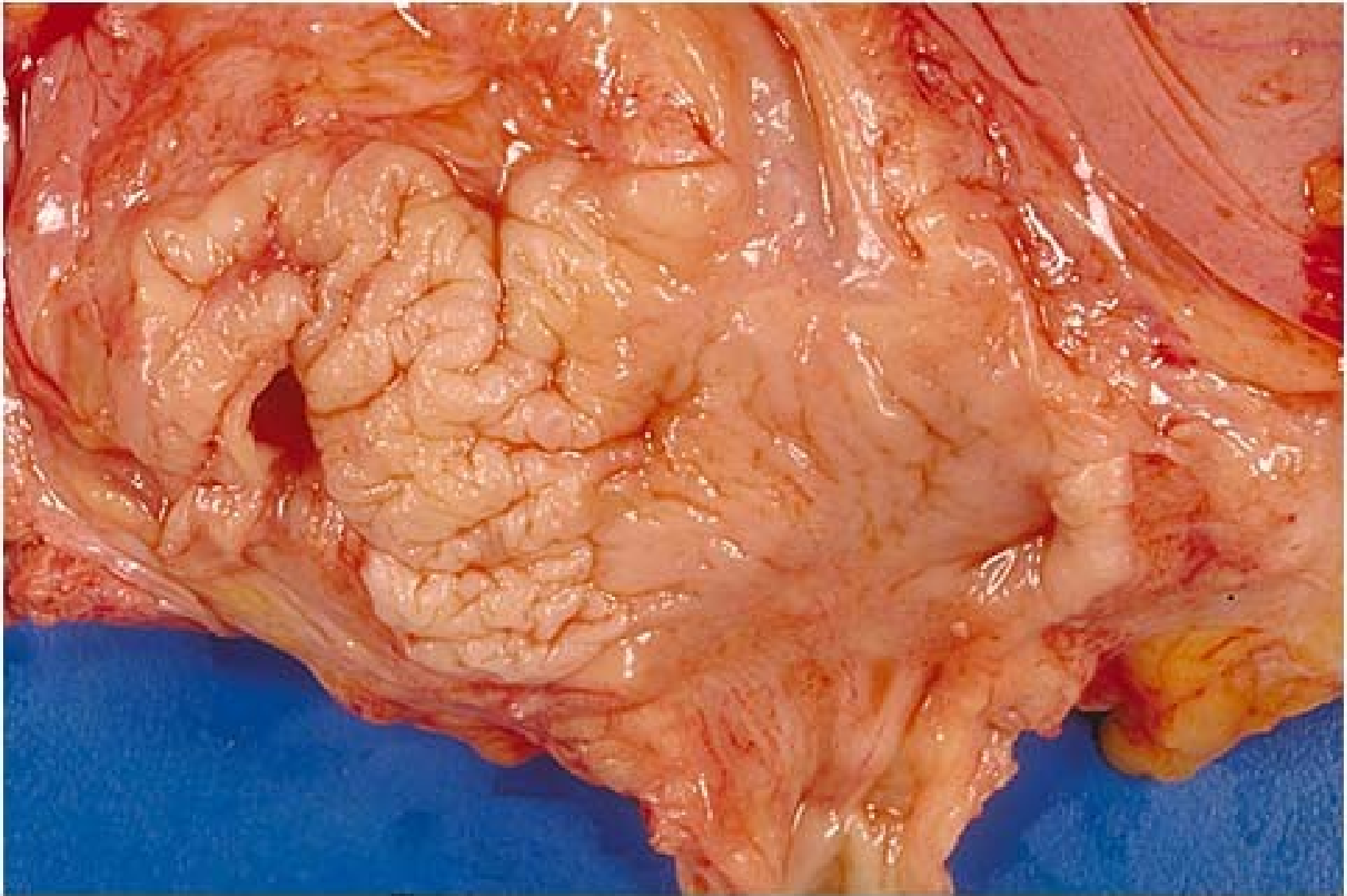




# Chronic cystitis

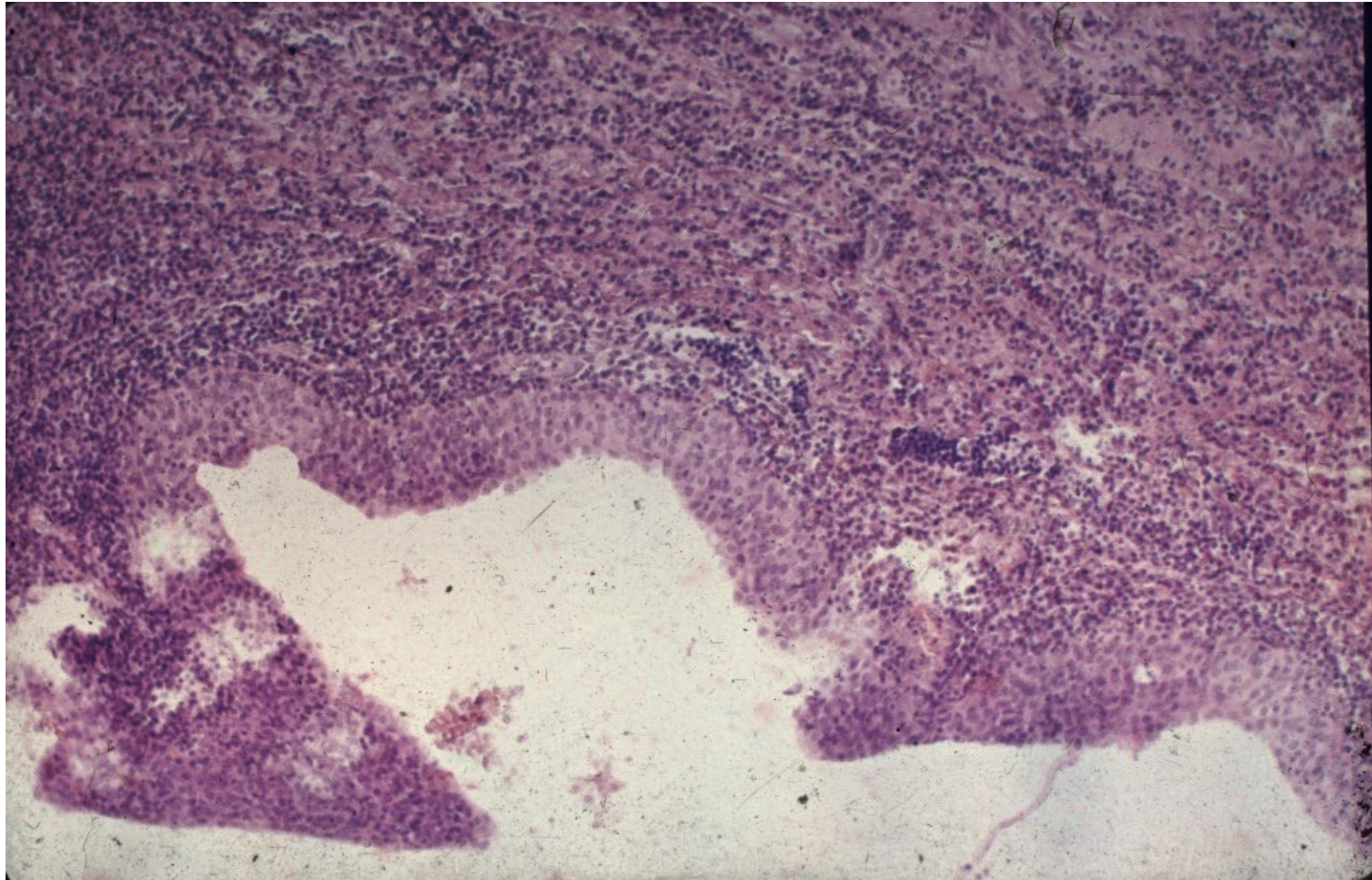
- epithelial transformations – polyps, epithelial hyperplasia (Brunn's nests, reactive atypia – x neoplastic), metaplasia (squamous - leukoplakia, glandular)
- neoformation of lymphatic follicles in stroma
- in obstruction + muscular hyperplasia, diverticuli
- acute exacerbations, stone formation
- may be risk factor for neoplasia
- diff. dg. x neoplasia

# Leukoplakia



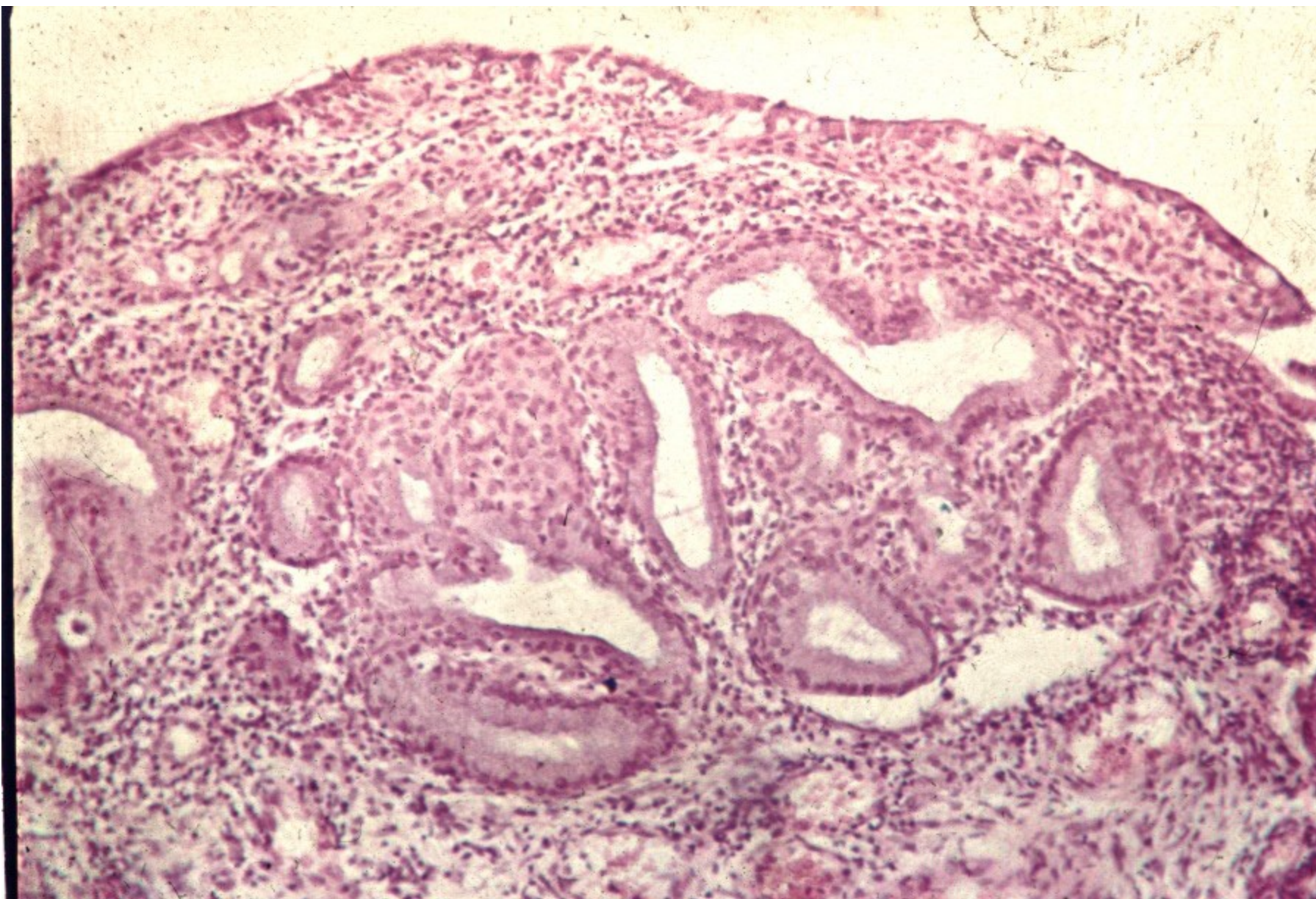
Copyright © 2002, Elsevier Science (USA). All rights reserved.

# Chronic cystitis with squamous metaplasia





# Glandular cystitis

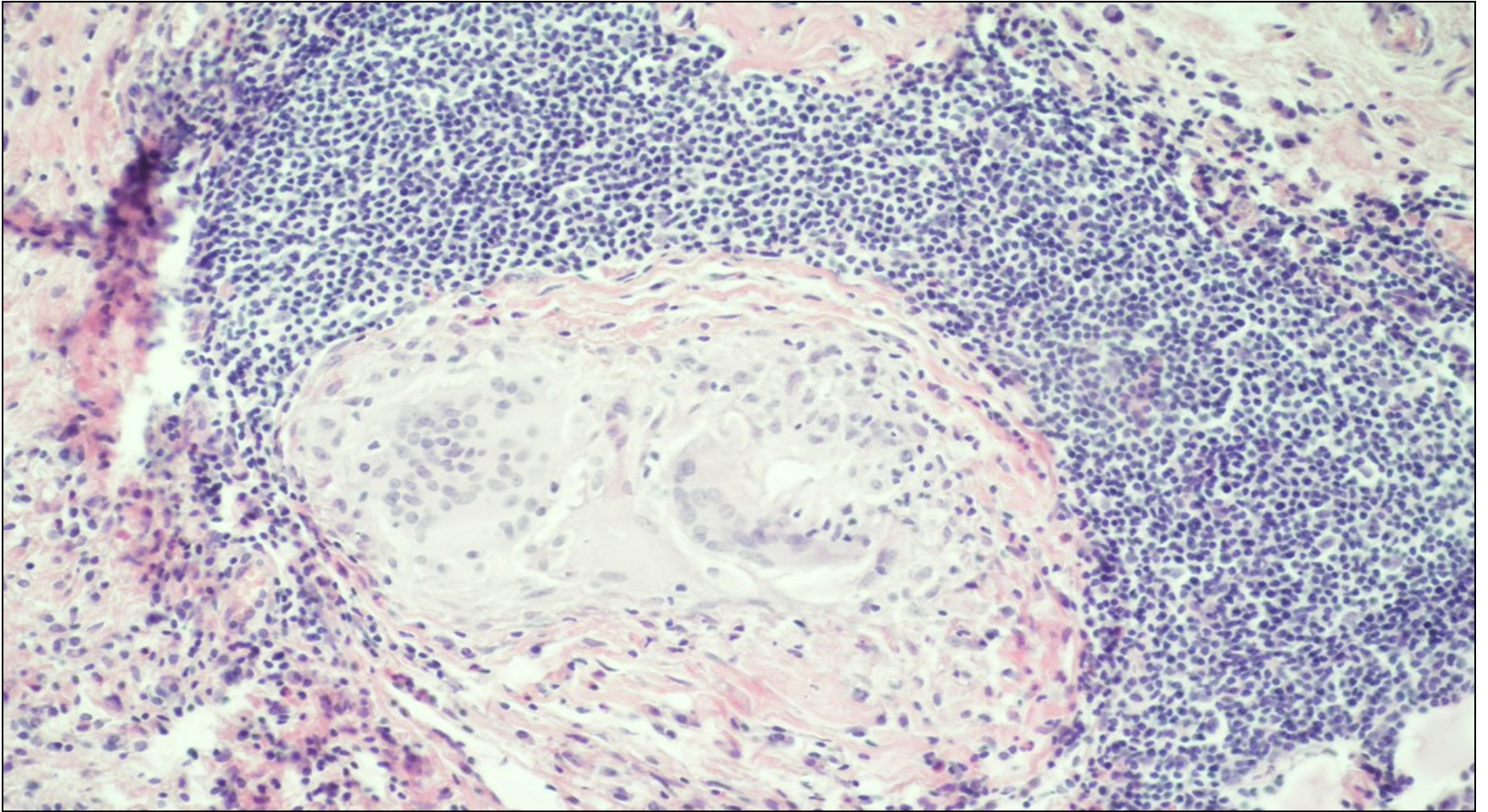


# Granulomatous cystitis

- **specific**
  - parasites
  - TB, incl. BCG vaccine as treatment for bladder ca
  - other
- **nonspecific**
  - foreign body reaction, incl. post-treatment (endoresection)



# Granulomatous cystitis

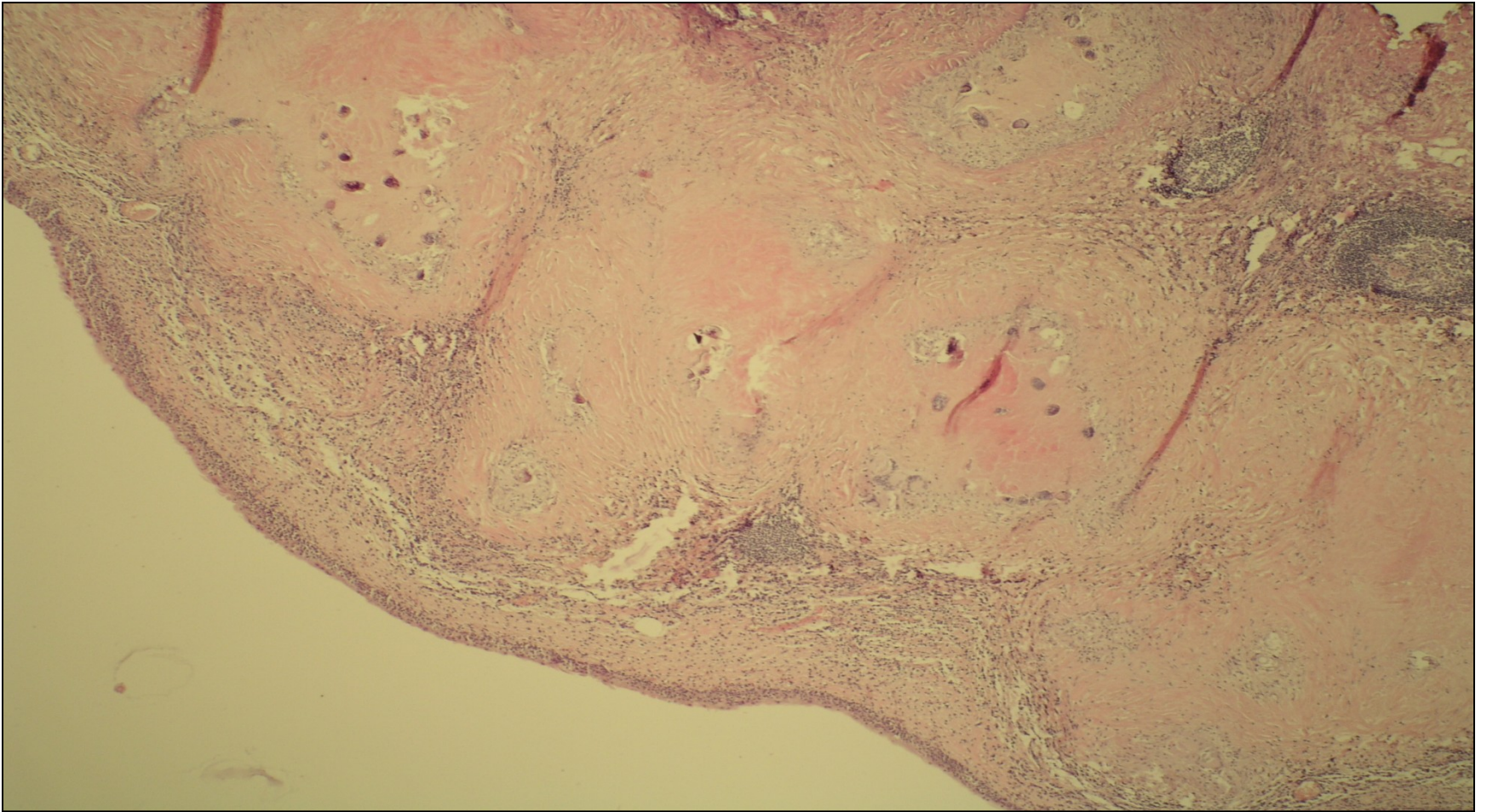




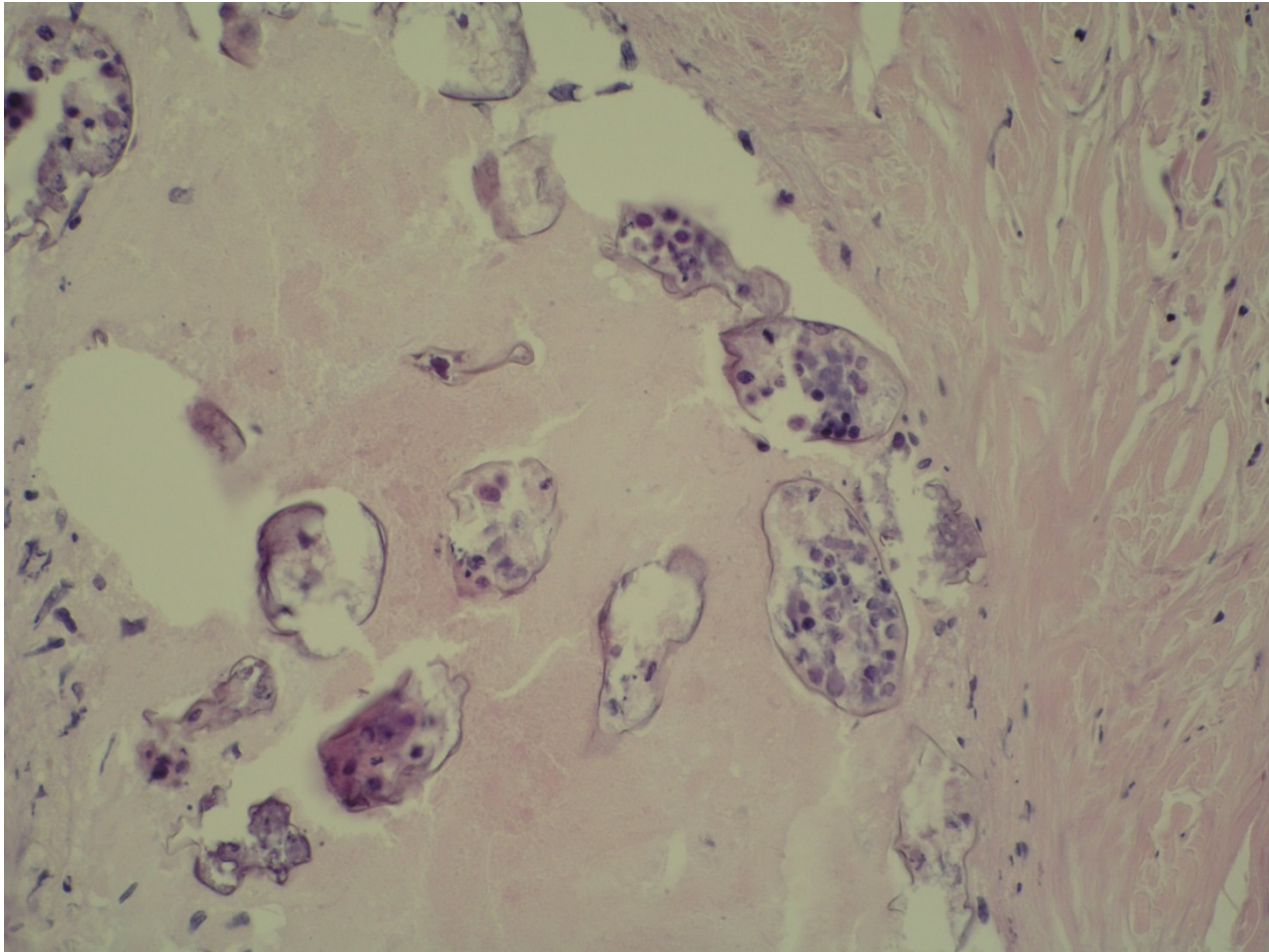
# Schistosomiasis

- chronic parasitic inflammation
- endemic in Africa, Middle East
- possible traveller infection, worm lives for up to 20 years
- granulomatous reaction to eggs + fibrosis
- strictures, squamous metaplasia
- ↑ ↑ risk of squamous ca

# Schistosomiasis



# Schistosomiasis





# Transitional cell (urothelial) tumors

## exophytic:

- papilloma (benign), inverted papilloma
- papillary urothelial neoplasm of low malignant potential (PUNLMP)
- non-invasive papillary urothelial carcinoma – low grade, high grade
- invasive urothelial carcinoma – low grade, high grade

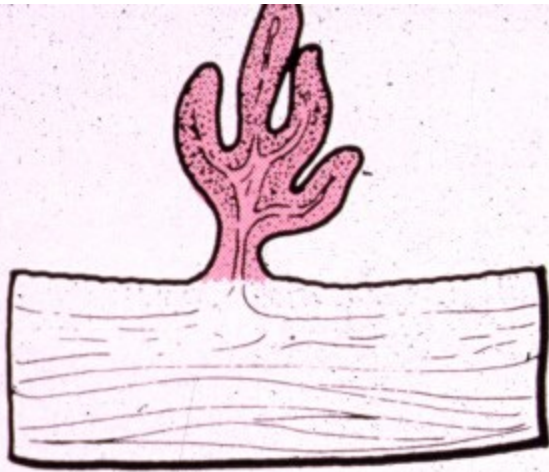
# Transitional cell (urothelial) tumors

- **Flat lesions**

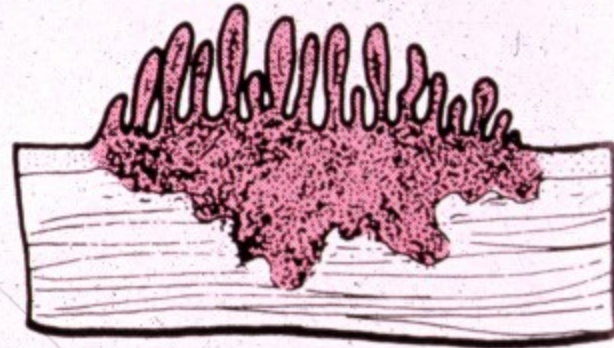
## **Intraepithelial neoplasia**

- dysplasia
- carcinoma in situ (CIS)

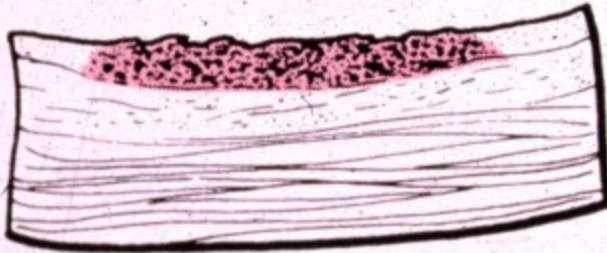## **Invasive carcinoma**



Papilloma-  
papillary carcinoma



Invasive papillary  
carcinoma



Flat noninvasive  
carcinoma



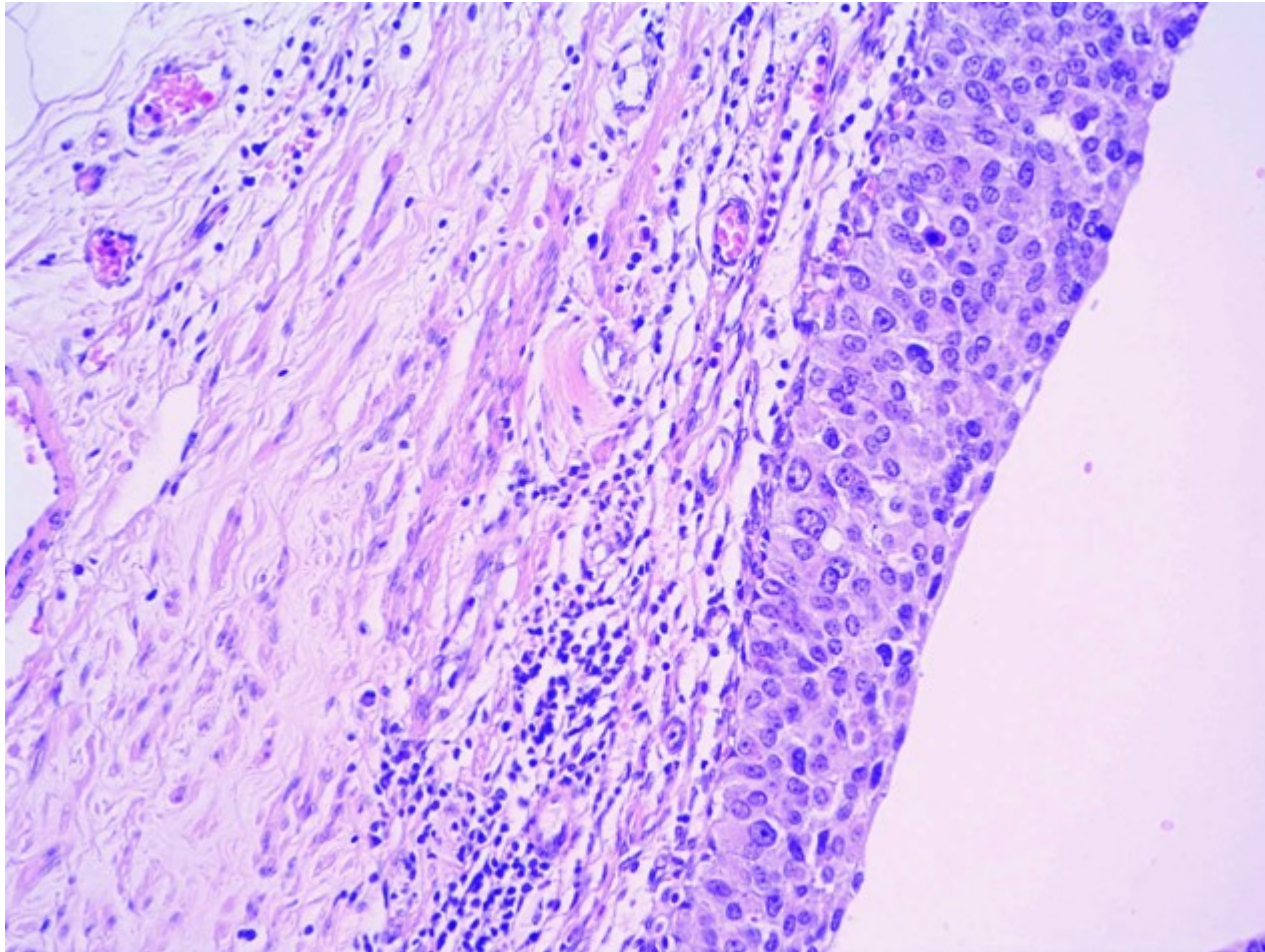
Flat invasive  
carcinoma

**Figure 21-9. Four morphologic patterns of bladder tumors.**

from Robbins' Pathology of Diseases



# Urothelial ca in situ



# Urothelial papilloma

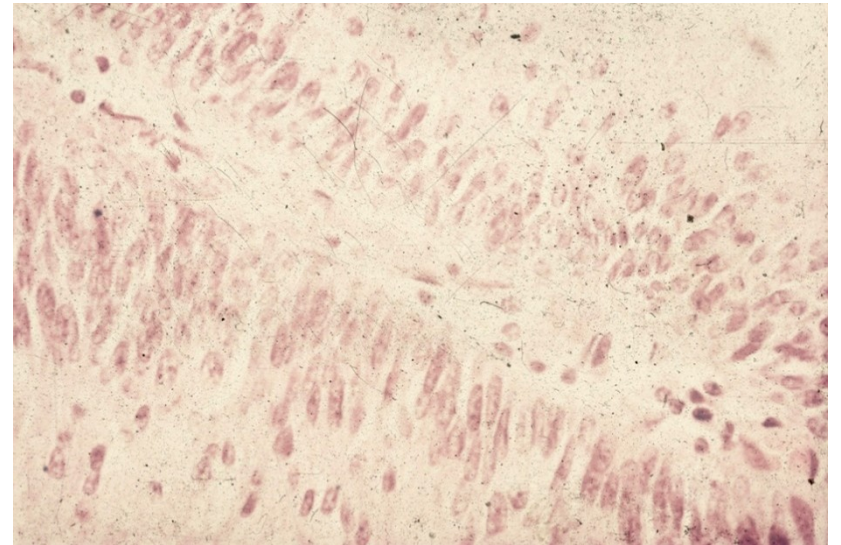
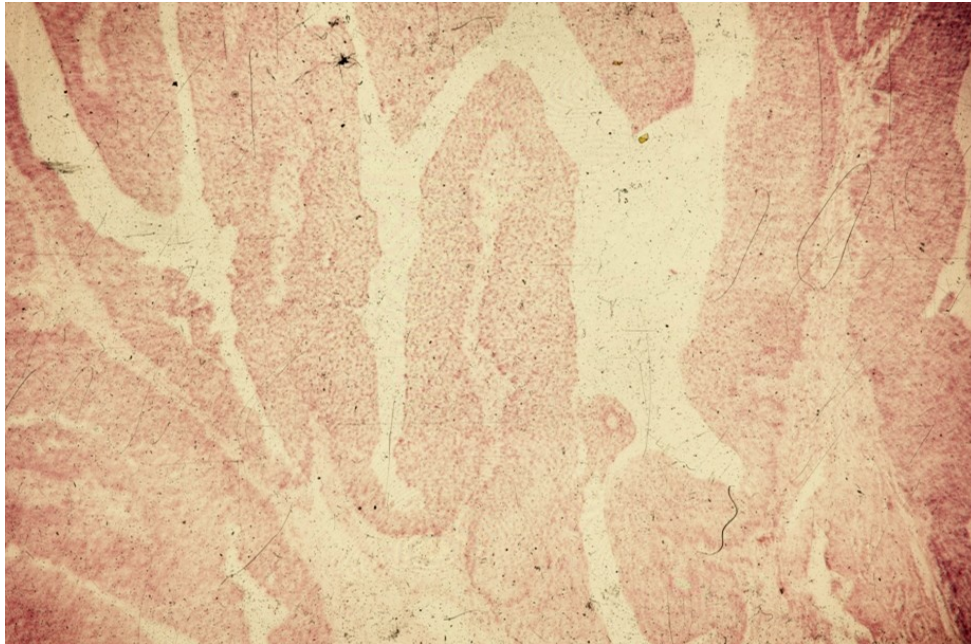
- Rare
- Solitary
- Exophytic / endophytic (inverted)
- Normal urothelium – no atypia, usual number of layers, superficial differentiation of umbrella cells

# Papillary urothelial neoplasm of low malignant potential

- Slight increase in the number of cell layers, normal stratification, minimal increase in nuclear size and density
- Basal sporadic mitotic activity
- Risk of recurrence, possible progression into ca



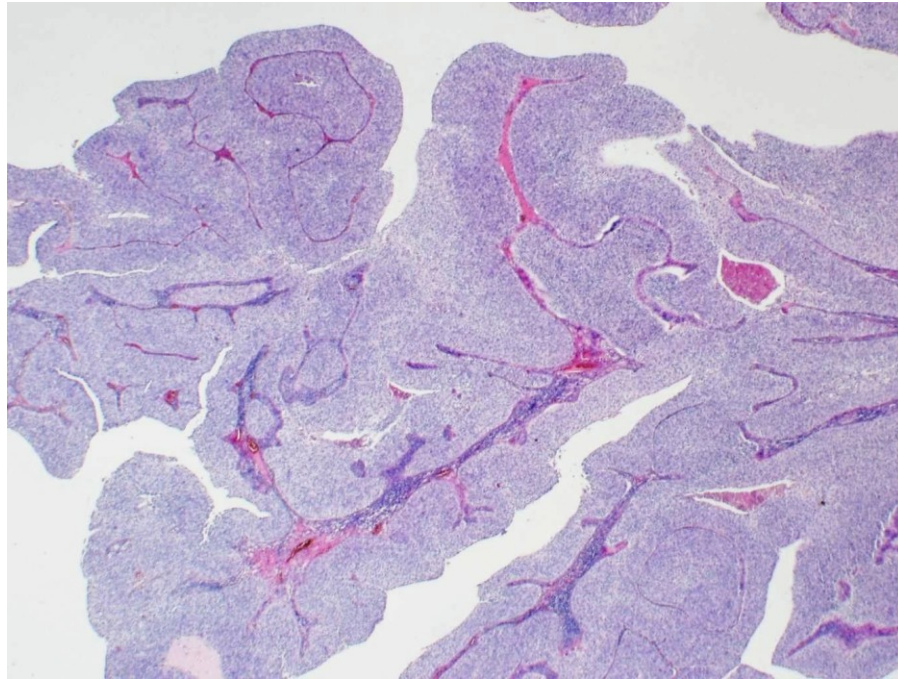
# Papillary urothelial neoplasm of low malignant potential



# Non-invasive papillary urothelial carcinoma

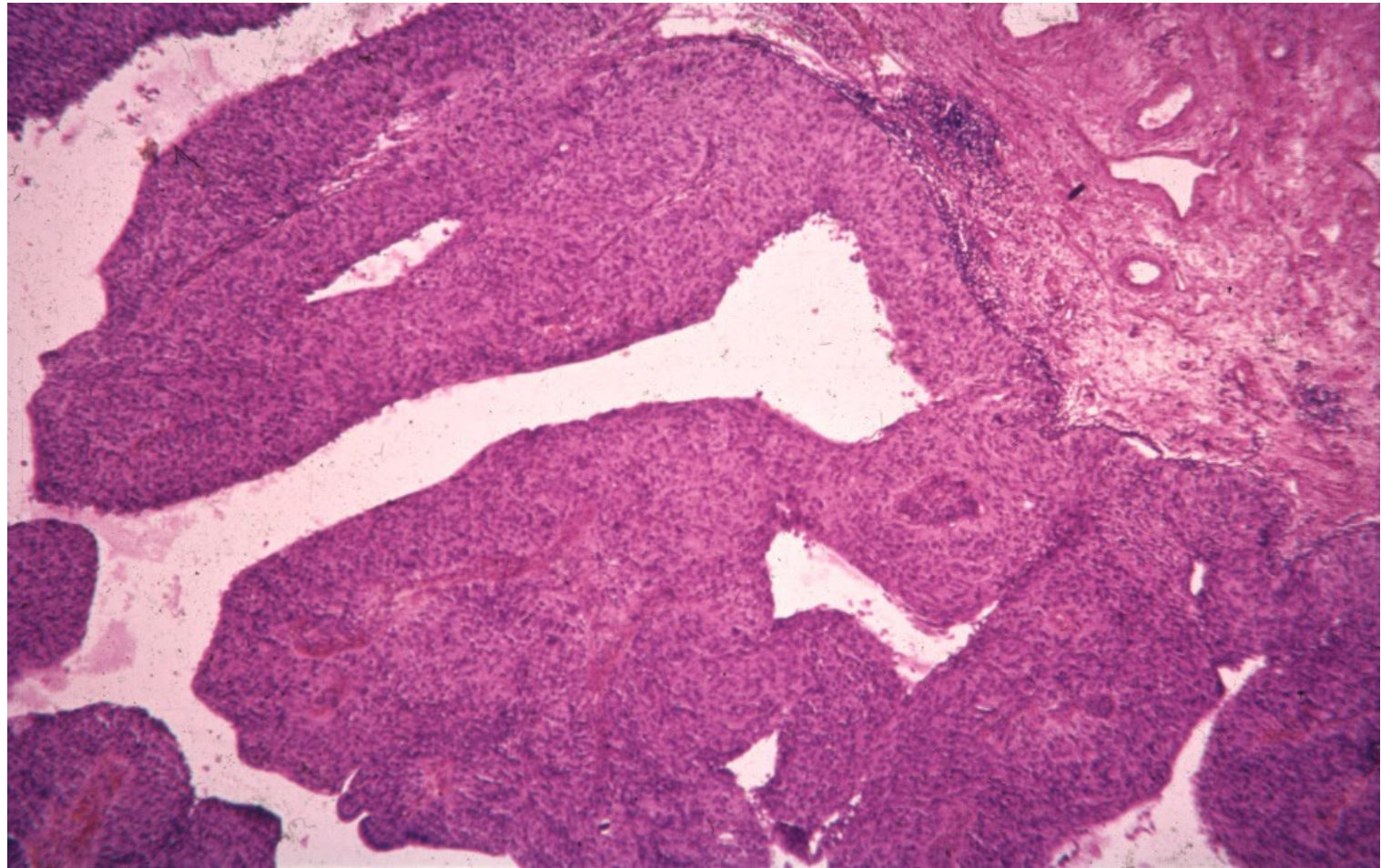
- low grade
- high grade
- cytonuclear atypias of a carcinoma
- no stromal invasion
- histological code of a ca in situ (8130/2)

# Non-invasive papillary urothelial carcinoma, low grade

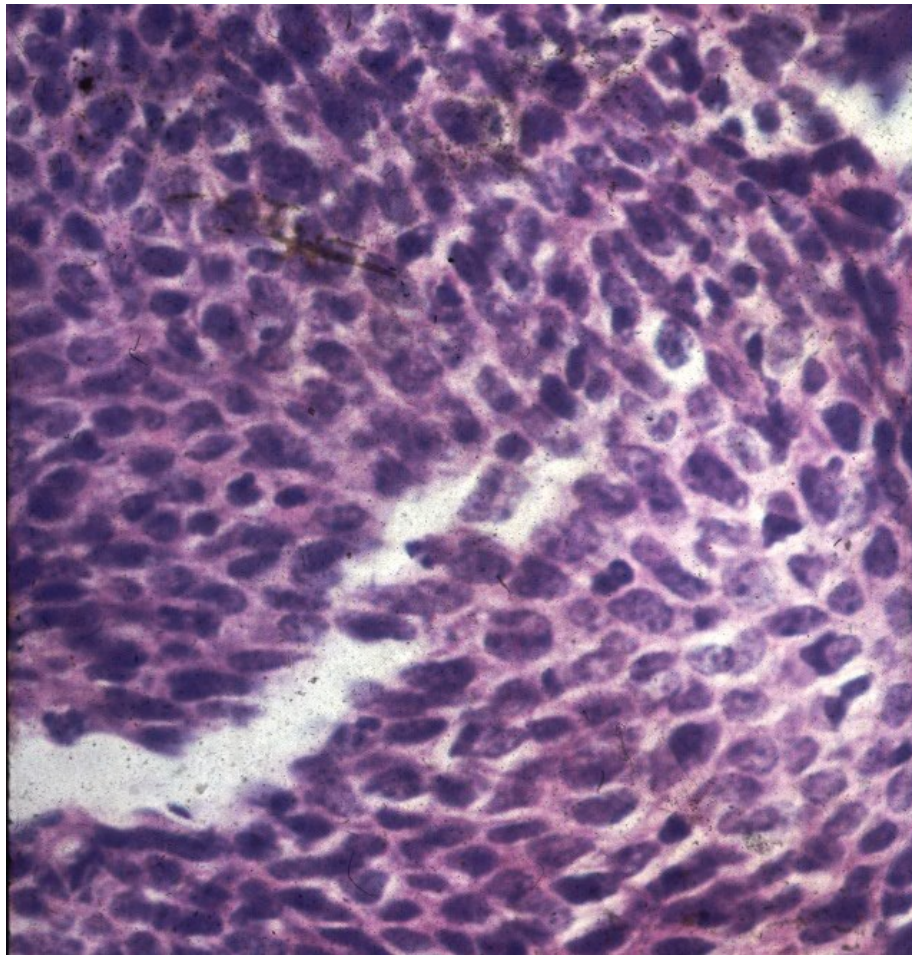




# Non-invasive papillary urothelial carcinoma, high grade



# Non-invasive papillary urothelial carcinoma, high grade



# Invasive urothelial carcinoma

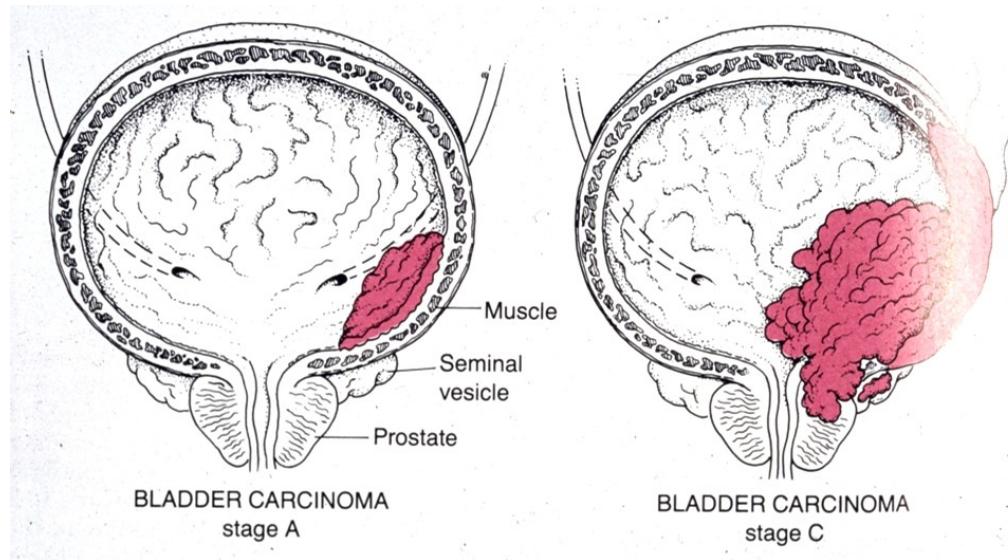
- ex flat urothelial ca in situ
- ex non-invasive papillary urothelial ca (papillary component commonly present)
- variable grade
- invasion into deep bladder structures (muscle layer), adjacent tissues/organs (fat, ureters, prostate gland, ...)



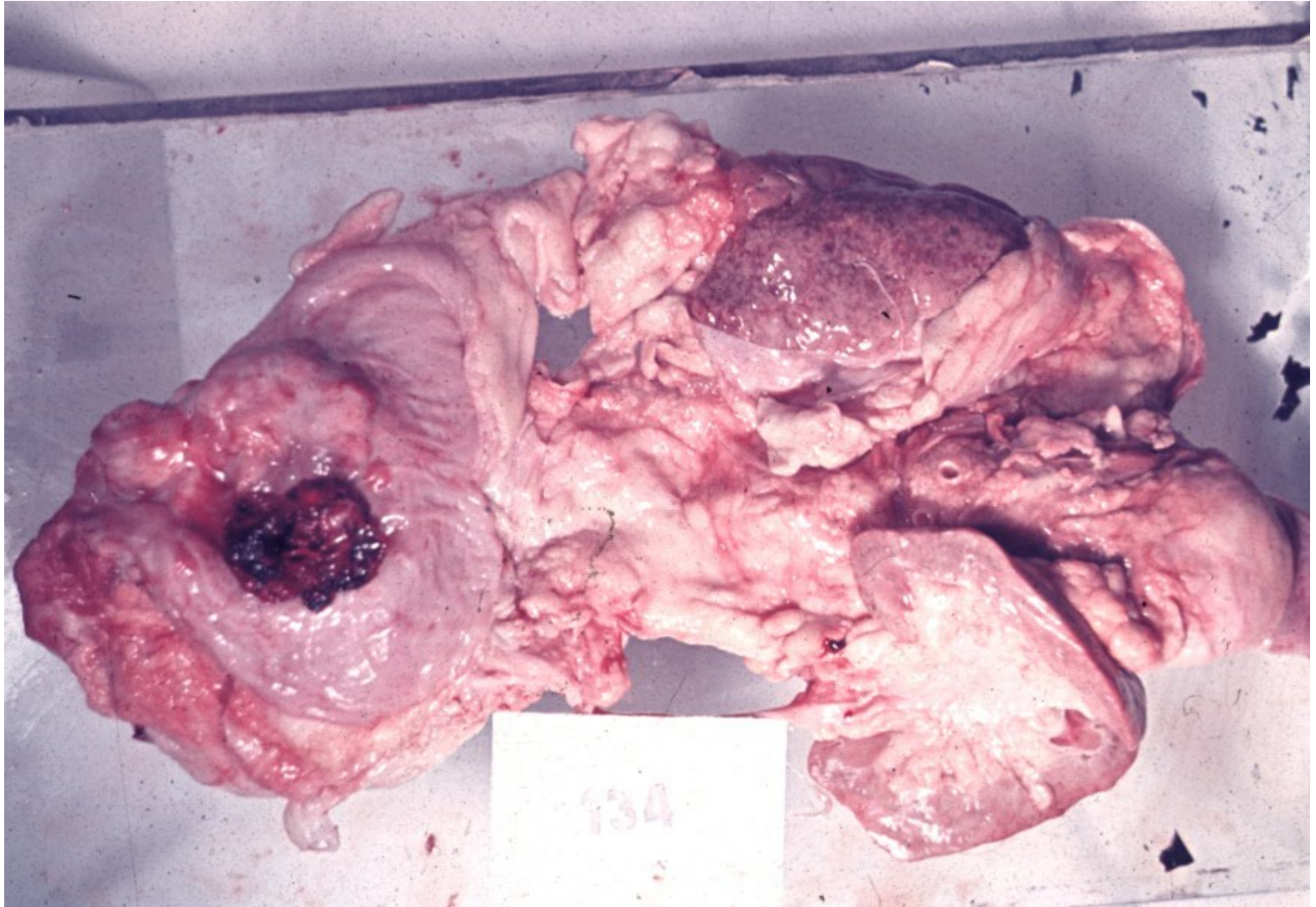
# Invasive urothelial carcinoma

- 90% ca in the bladder (rare squamous cell ca or adenocarcinomas), mostly in 50 – 80 yrs old
- etiology: smokers, professional (anilin dyes, plastics industry), analgesic abuse, irradiation. Sq. cell ca in chronic inflammation (schistosomiasis)
- Differentiation grade G1 – G3
- asymptomatic, possible haematuria

# Invasive urothelial carcinoma - staging

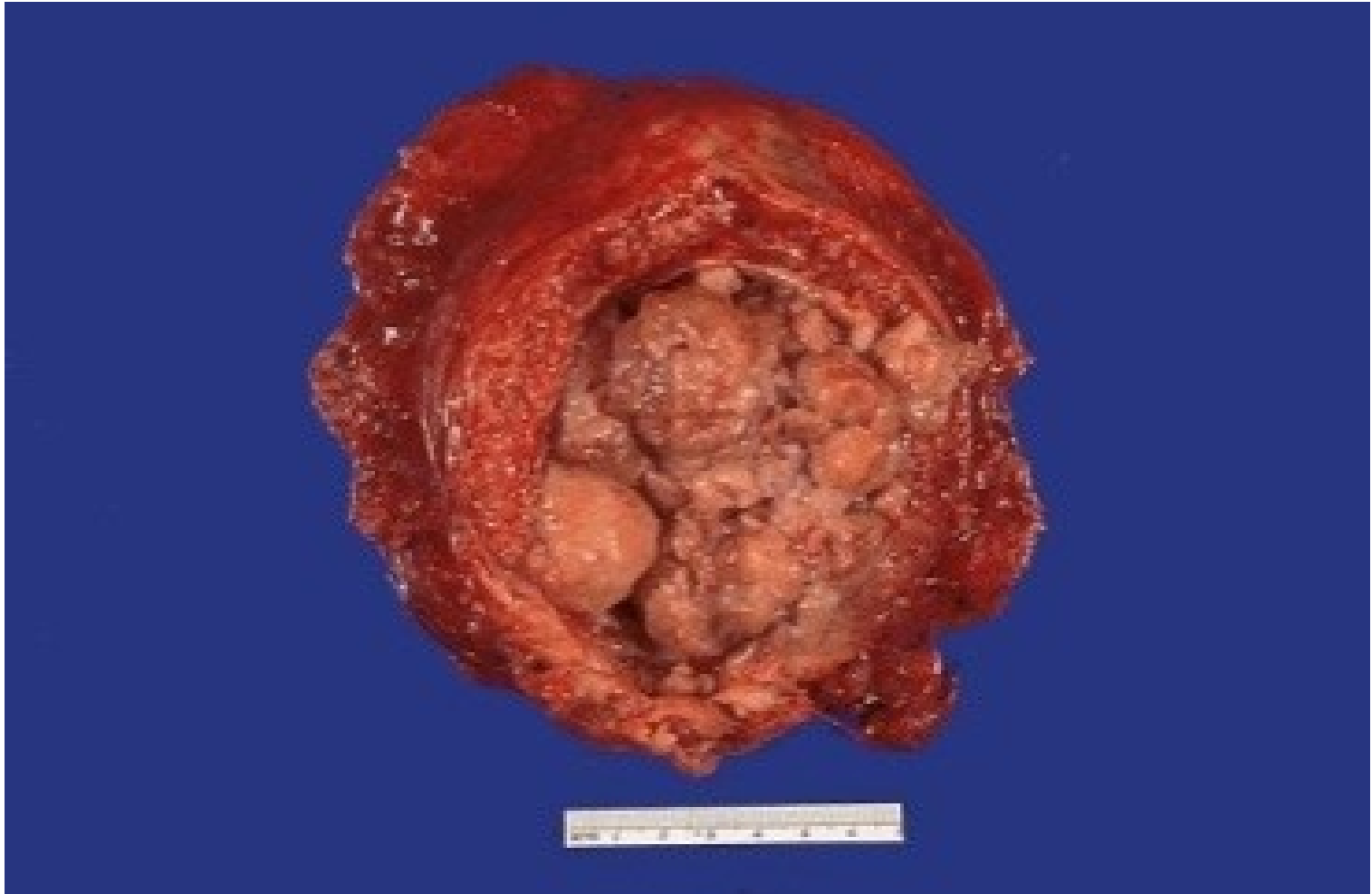

# Bladder carcinoma

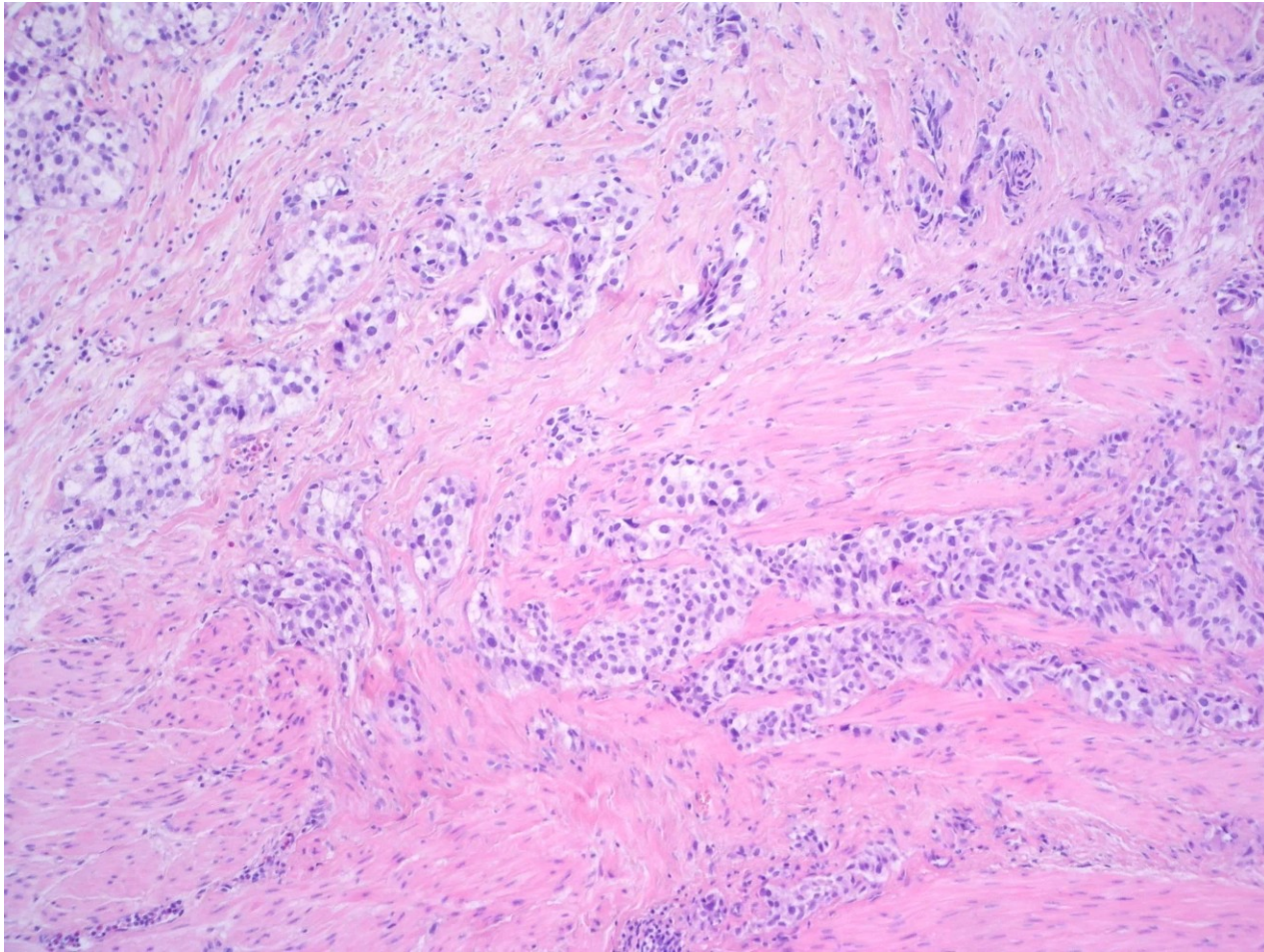




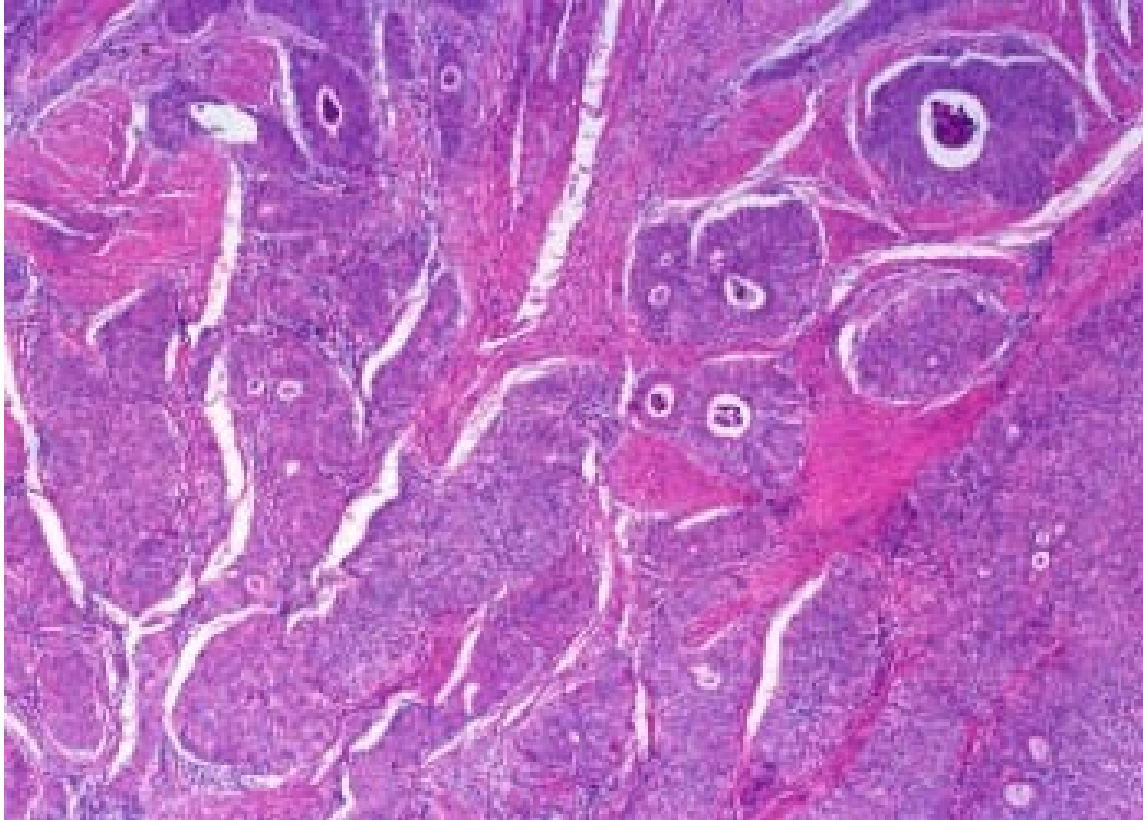
# Bladder carcinoma



# Invasive urothelial carcinoma

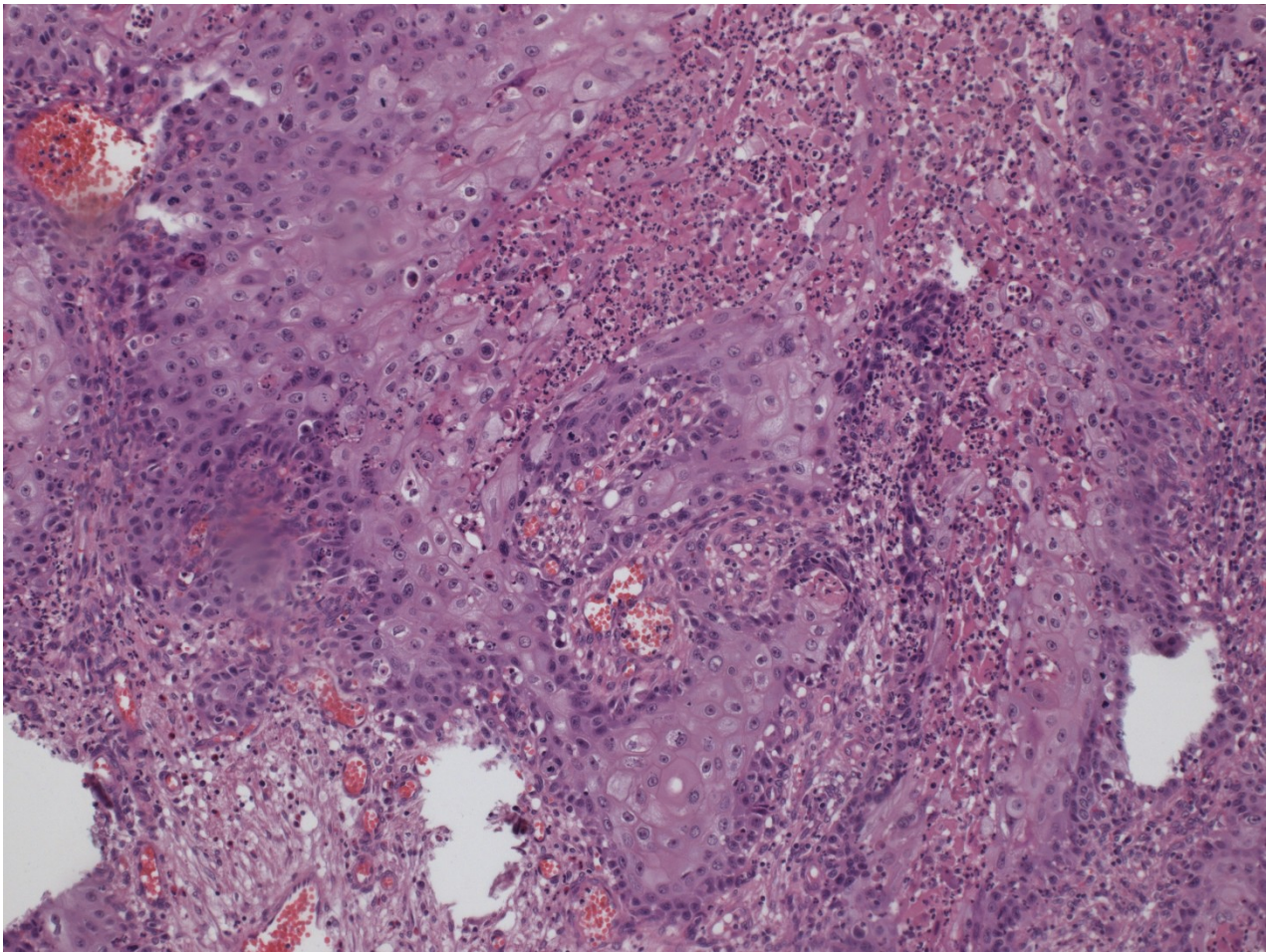


# Carcinoma with glandular transformation



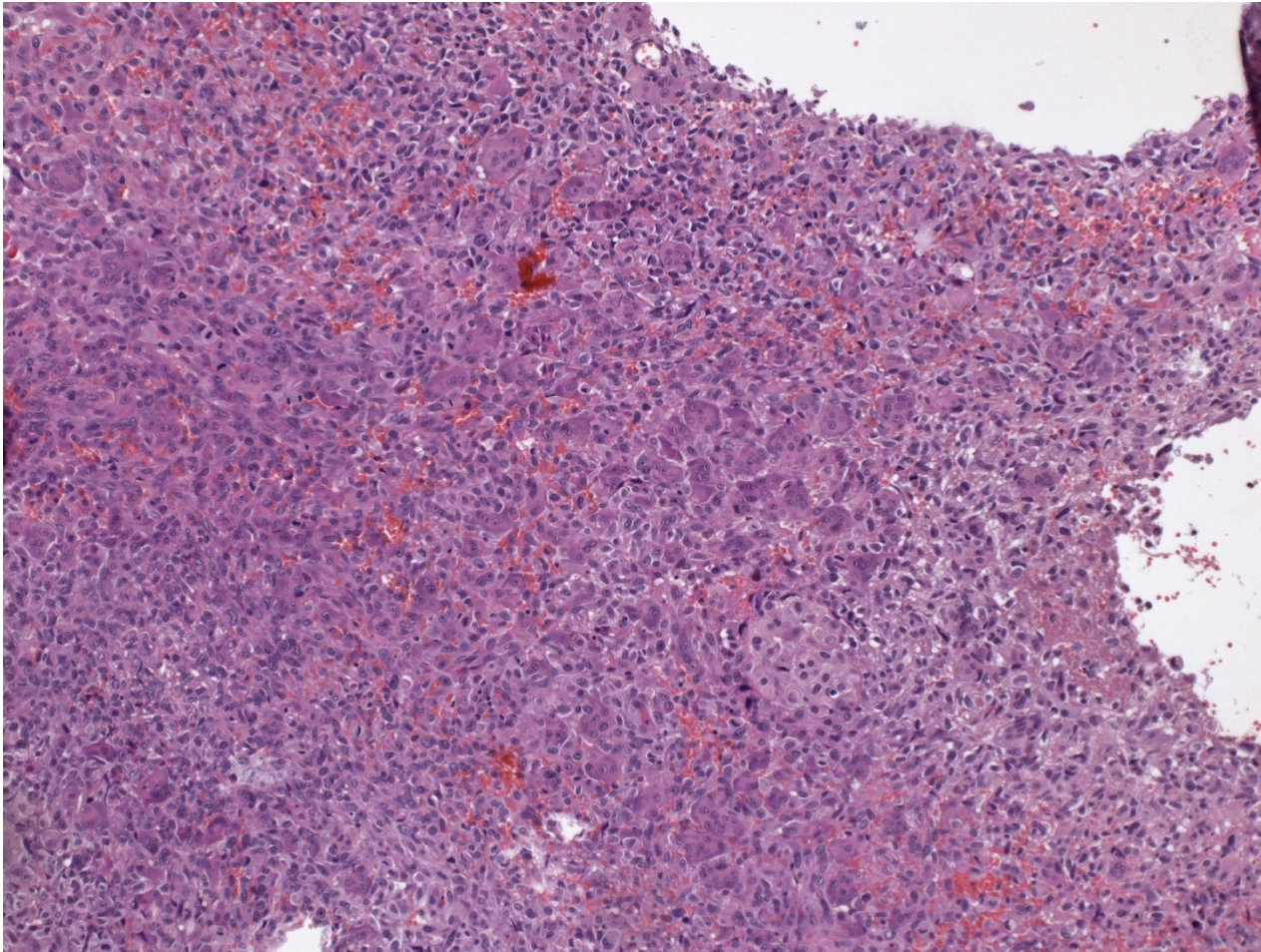


# HG ca w. squamous transformation





# HG sarcomatoid ca

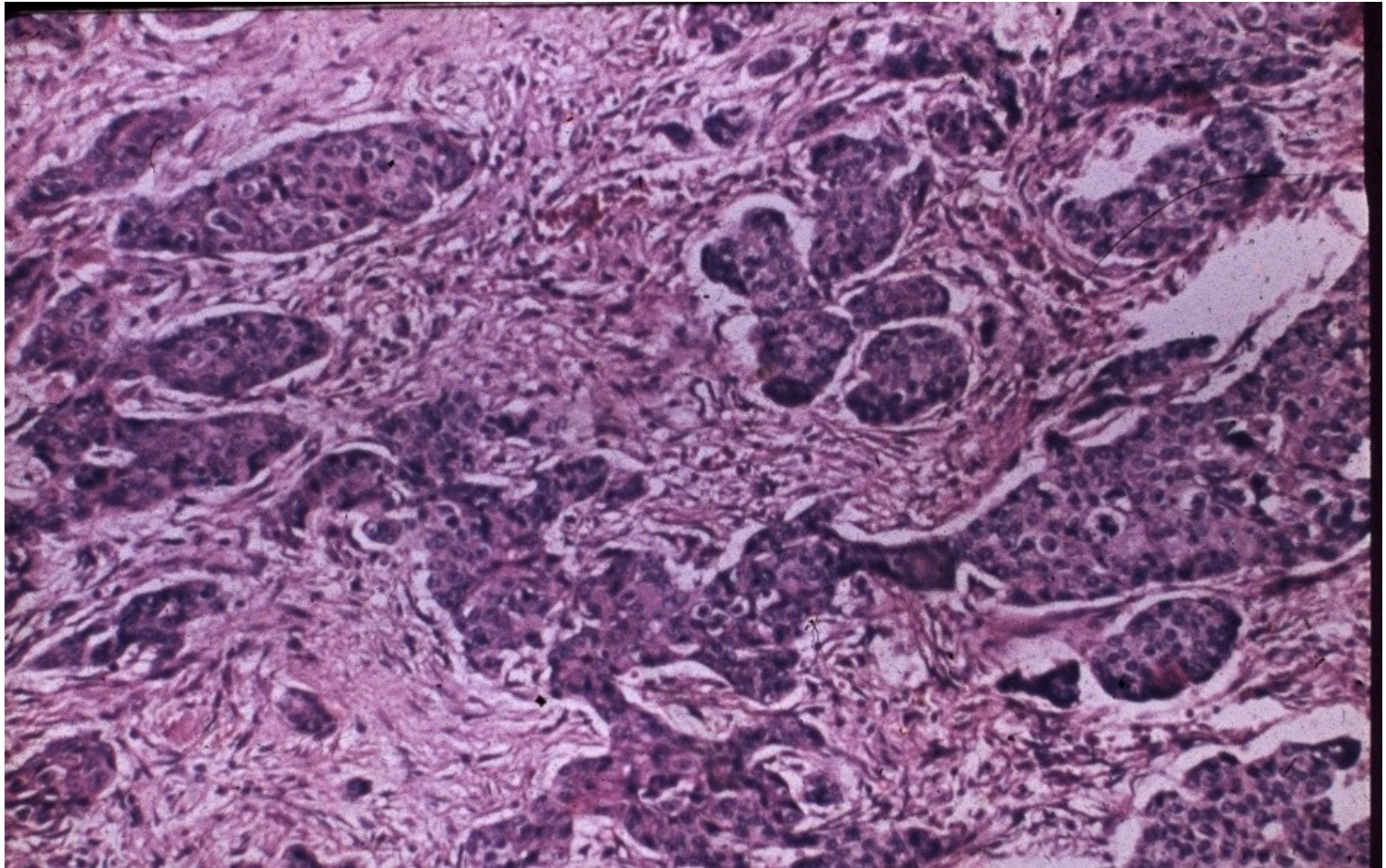


# Bladder epithelial tumors - other

- squamous cell carcinoma
- adenocarcinoma
- small cell carcinoma (neuroendocrine ca)
- mixed ca
- secondary tumors – prostatic ca, cervical ca, rectal ca

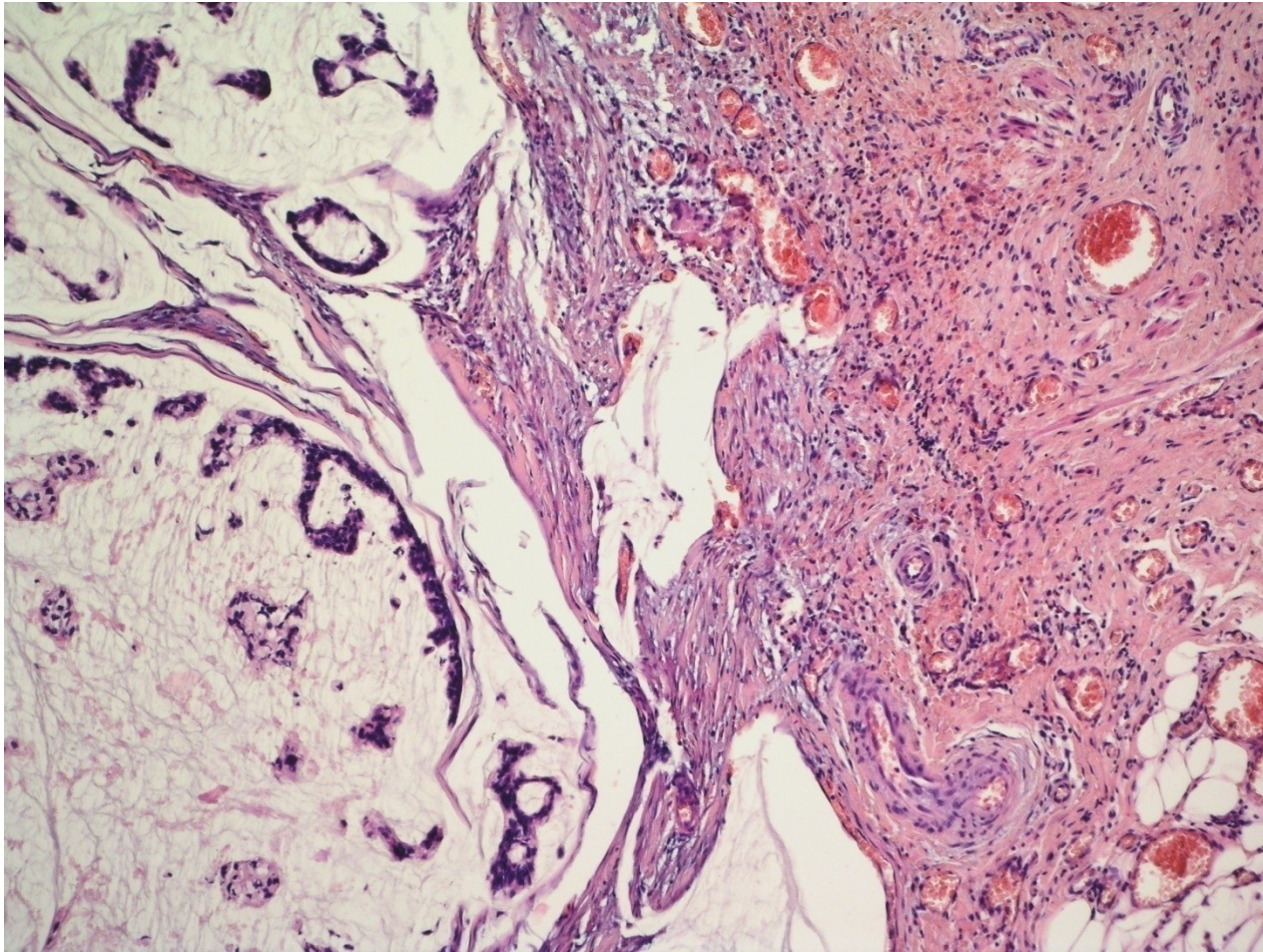


# Squamous cell carcinoma





# Mucinous adenocarcinoma

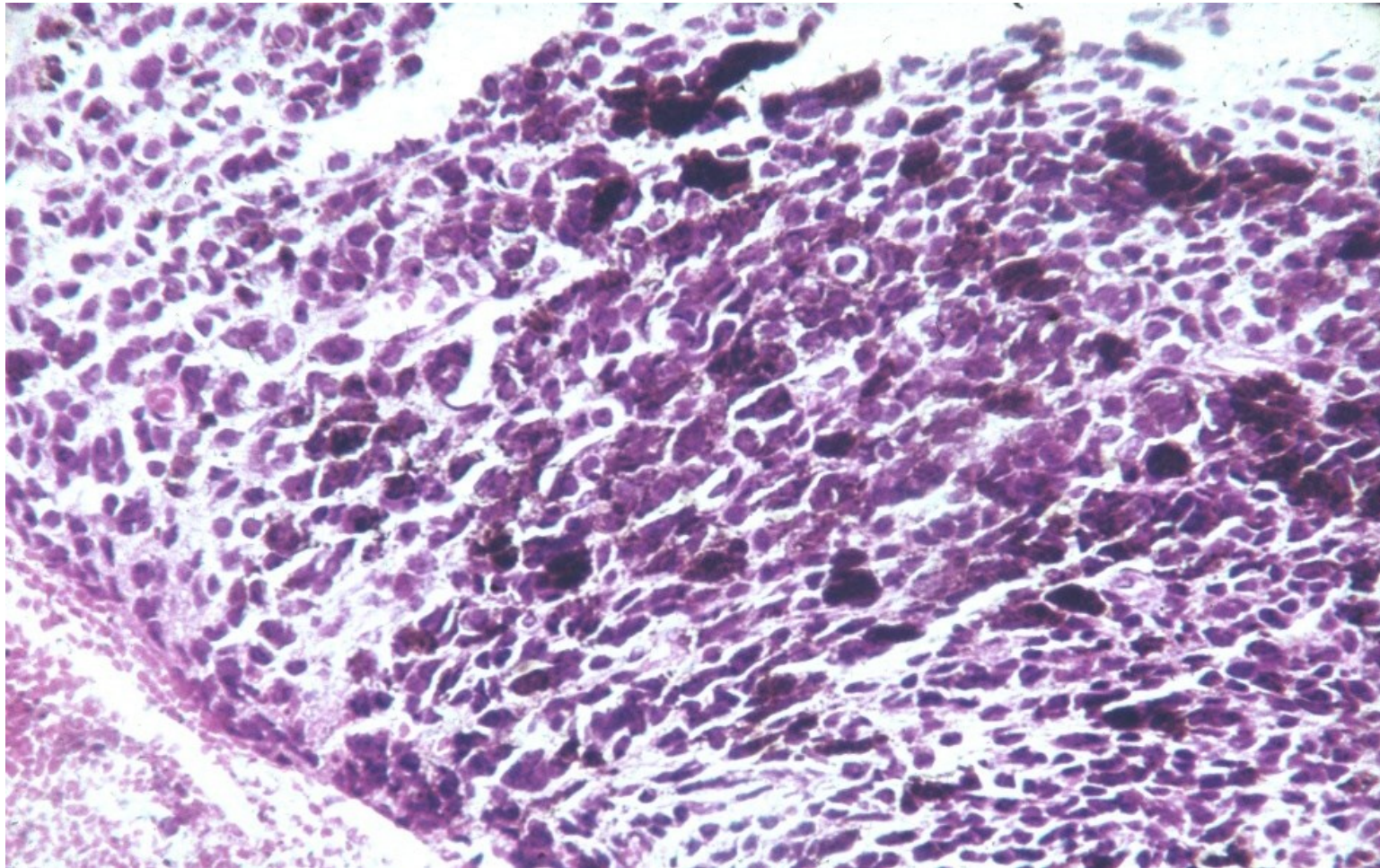


# Bladder non-epithelial tumors

- Melanocytic
- Mesenchymal (benign, malignant sarcomas)
- Other



## Malignant melanoma in the bladder



# MALE GENITAL SYSTEM

Penis, scrotum



# Congenital lesions

- **Epispadia**: less common, incomplete fusion of urethra, dorsal opening, may be a part of bladder exstrophy
- **Hypospadia**: more common, opening on inferior part of penis (glans, shaft, perineum)
- **Phimosis**: diminished size of prepuce opening, rare inborn, more common acquired – inflammation, scarring, ! ca

# Circulatory disorders

- **Edema**
- **corpora cavernosa thrombosis,**
- **gangrene (uncommon)**

# Balanoposthitis

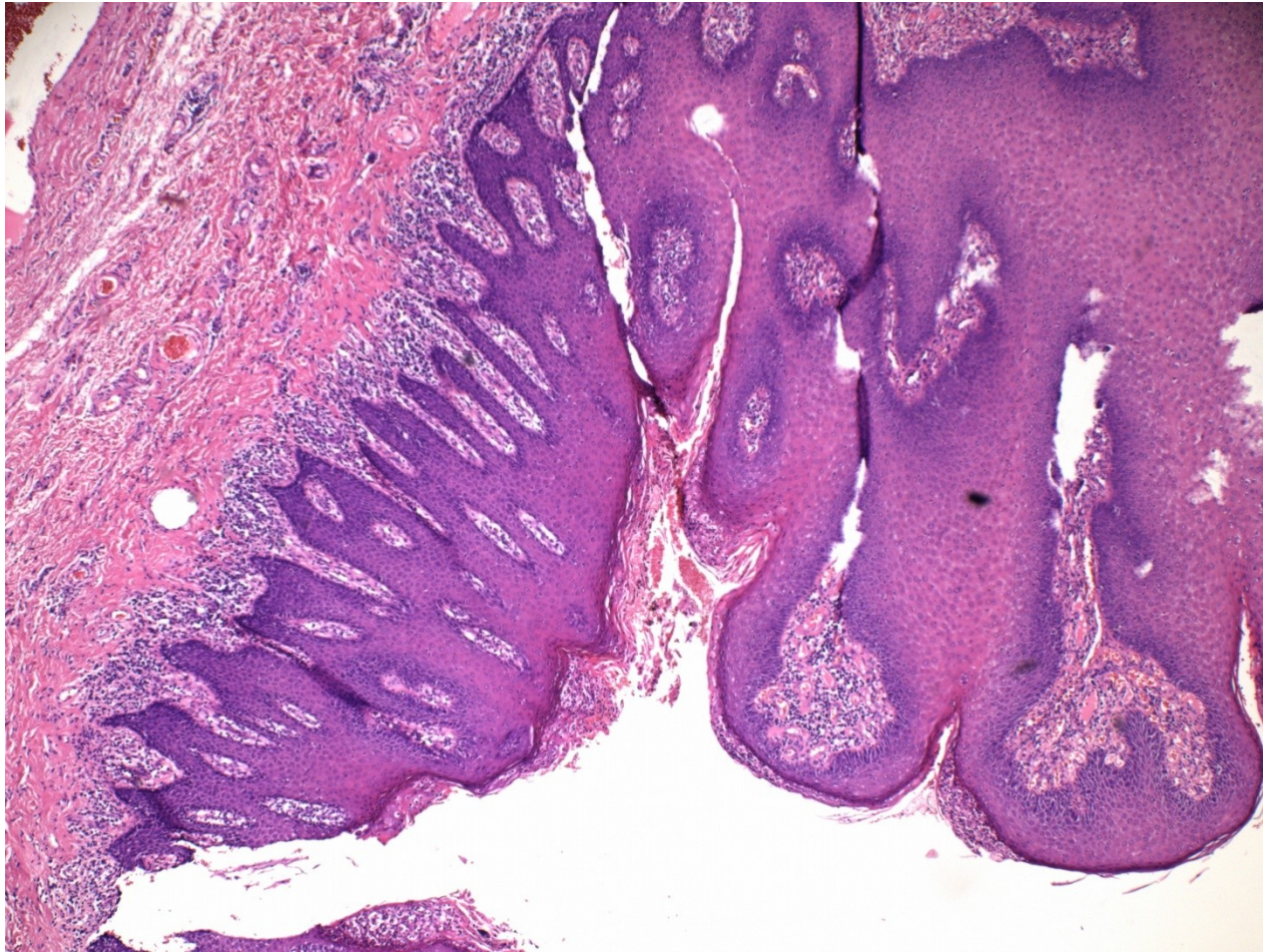
- Glans + prepuce
- Sexually transmitted diseases – STD: syphilis, gonorrhoea, chancroid, herpes
- Non-specific infection: candida, pyogenic bacteria, anaerobic bacteria
- Poor hygiene – repeated infection
- Phimosis, chronic irritation



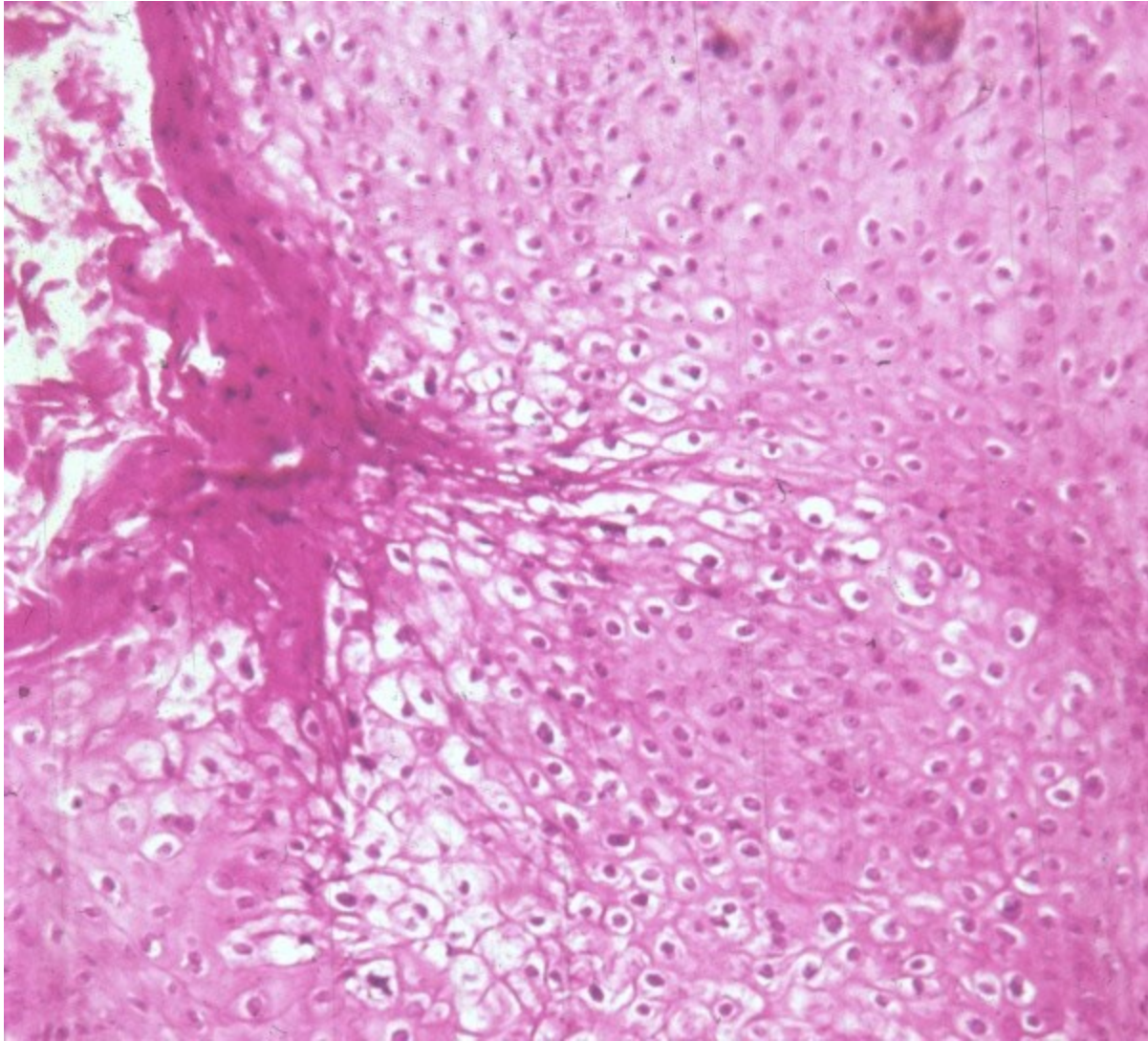
# Viral infections

- inflammation +/- pseudotumorous lesion (molluscum contagiosum)
- benign tumors: **condyloma accuminatum** – HPV 6, 11) squamous cell papilloma
- preneoplastic lesion/intraepithelial neoplasia incl. carcinoma in situ
- HPV risk factor – HPV-associated neoplasia

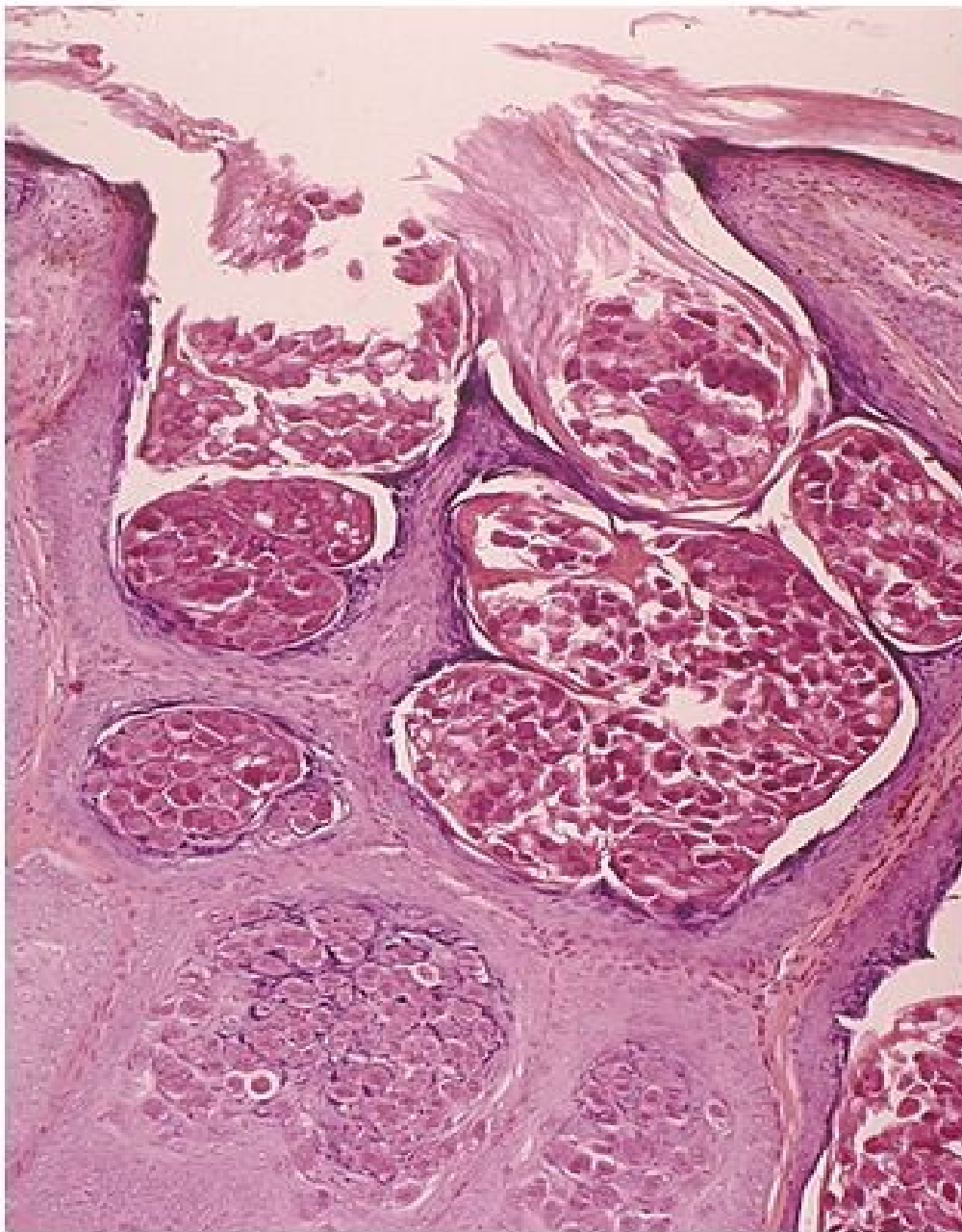
# Penile condyloma + psoriasis



# condyloma accuminatum - HPV







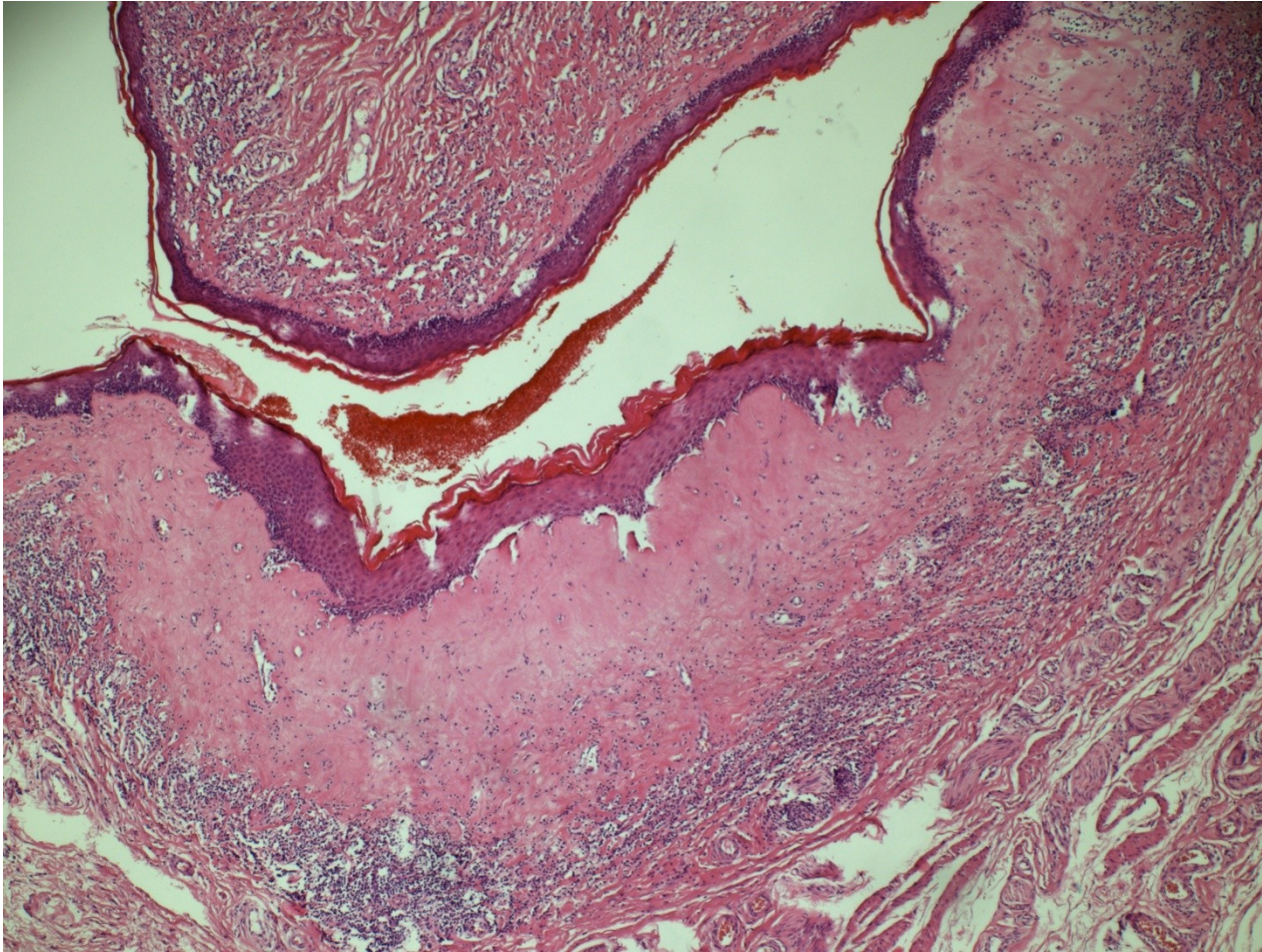
## Molluscum contagiosum

Copyright © 2002, Elsevier Science (USA). All rights reserved.

# Balanitis xerotica obliterans - lichen sclerosus

- chronic inflammatory disorder
- epithelial hyperkeratosis, atrophy, inflammatory infiltrate
- risky terrain for ca

# Lichen sclerosus





# Tumorous lesions

- Fibromatosis (Peyronie's disease) – deformation possible
- Pseudotumor - fibroepithelial polyp
- Benign tumors – HPV papilloma, adenoma

# Malignant tumors

- Skin tumors (squamous cell carcinoma, melanoma)
- Mucosa tumors (various types of squamous cell carcinoma incl. exophytic verrucous ca)
- Urethral tumors
- Other primary tumors
- Secondary tumors

# Penile intraepithelial neoplasia

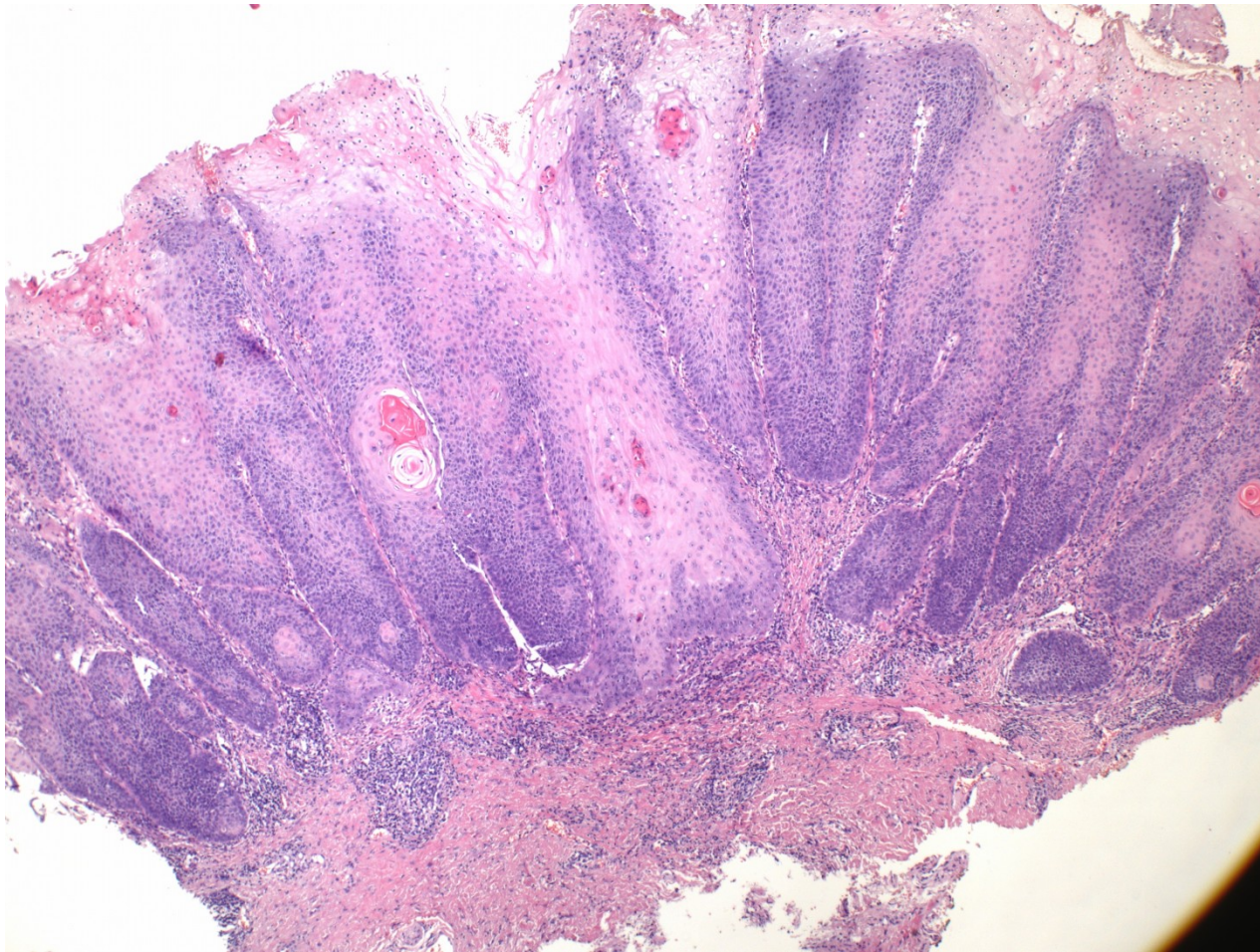
- penile intraepithelial neoplasia
  - HPV-associated
    - low grade PeIN
    - high grade PeIN
  - differentiated PeIN, HPV independent
    - associated w. chronic inflammation – lichen sclerosus, smoking, trauma
    - always high grade



# HPV-associated PeIN

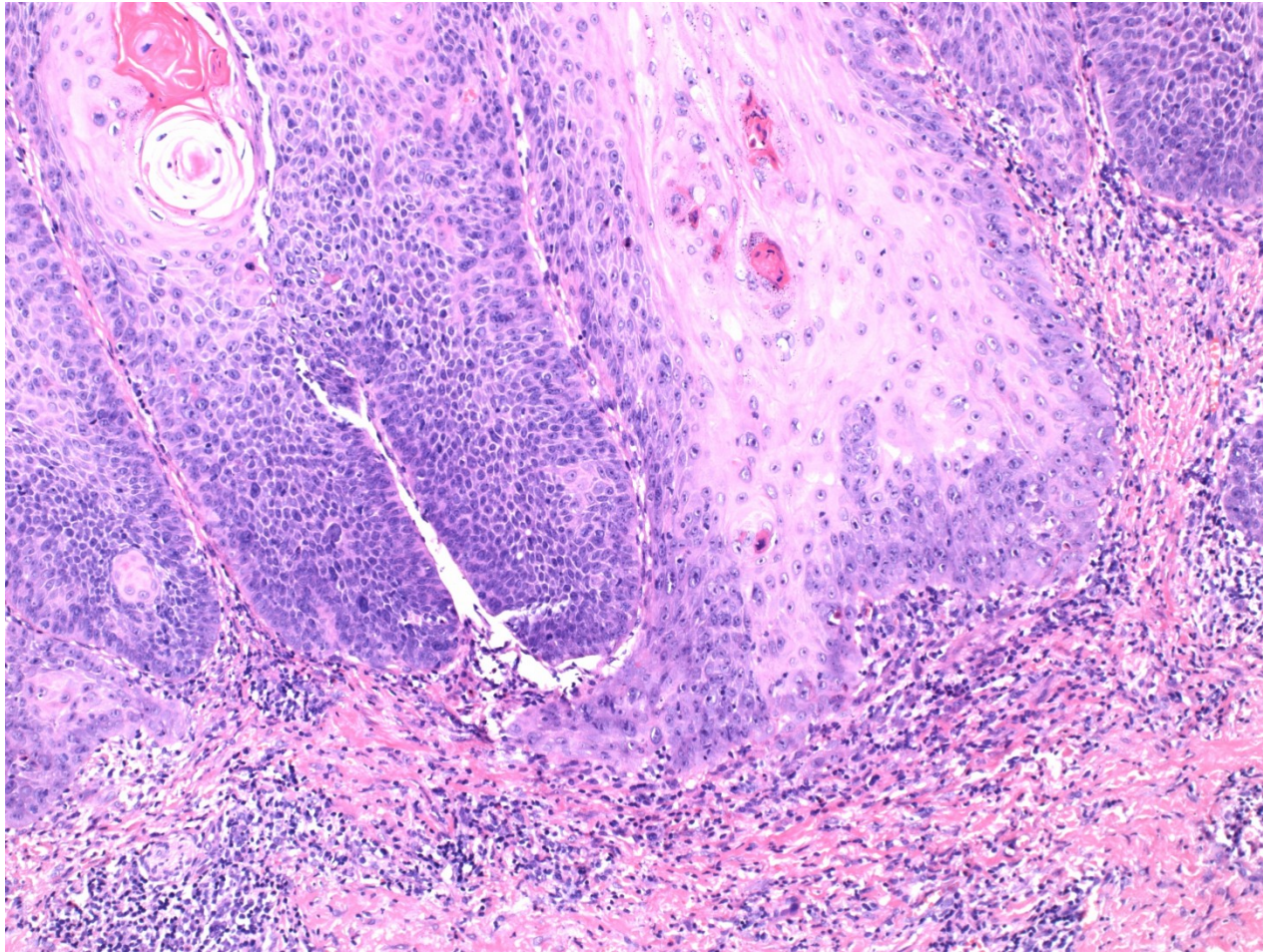
- 80 % of PeIN
- Bowen's disease – clinical term for PeIN on the shaft (skin)
- erythroplasia of Queyrat - clinical term for PeIN on on the glans/foreskin - red focus on the mucosa

# Penile intraepithelial neoplasia - SCC





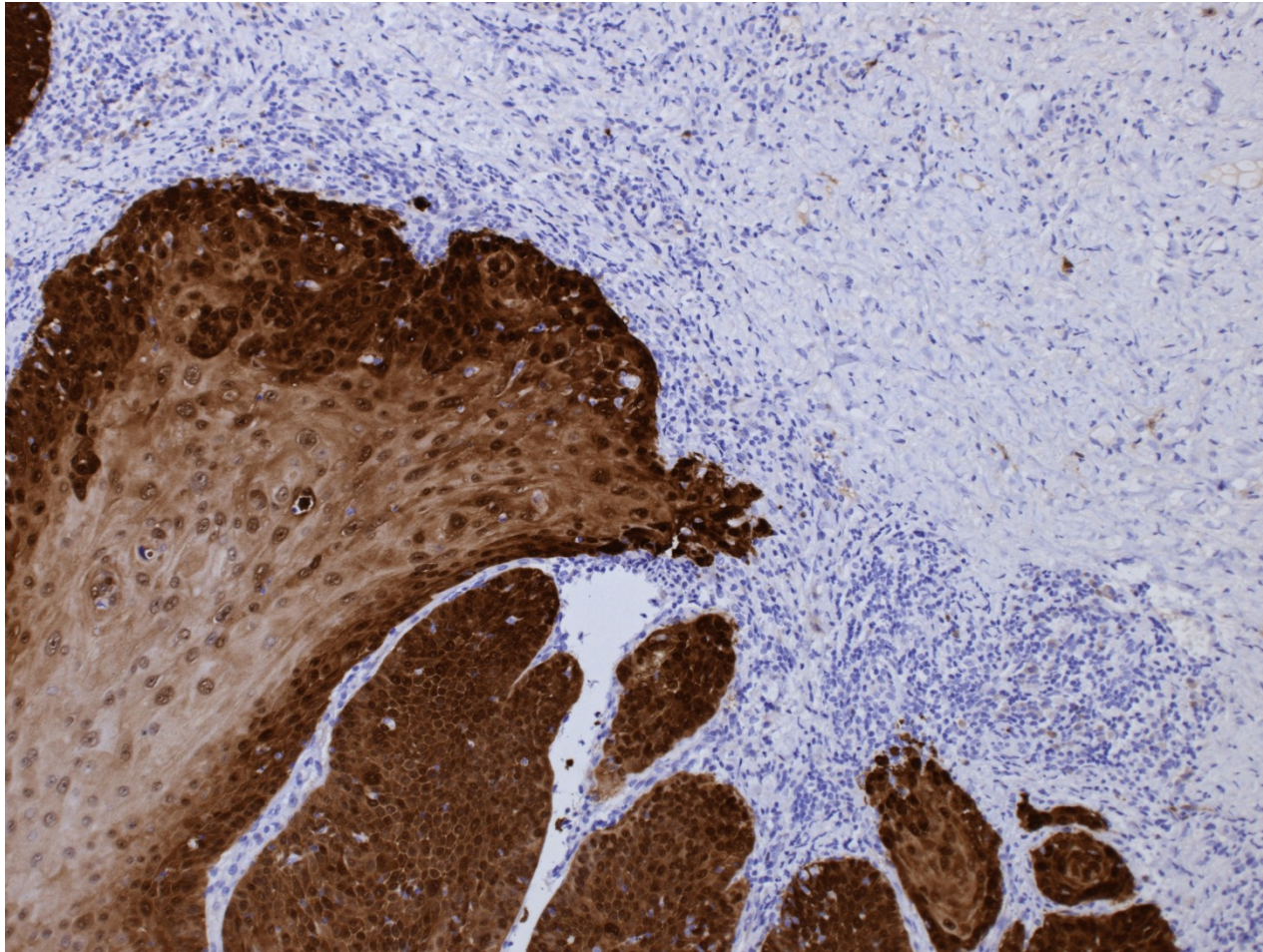
# Penile intraepithelial neoplasia - SCC





# Penile intraepithelial neoplasia – SCC

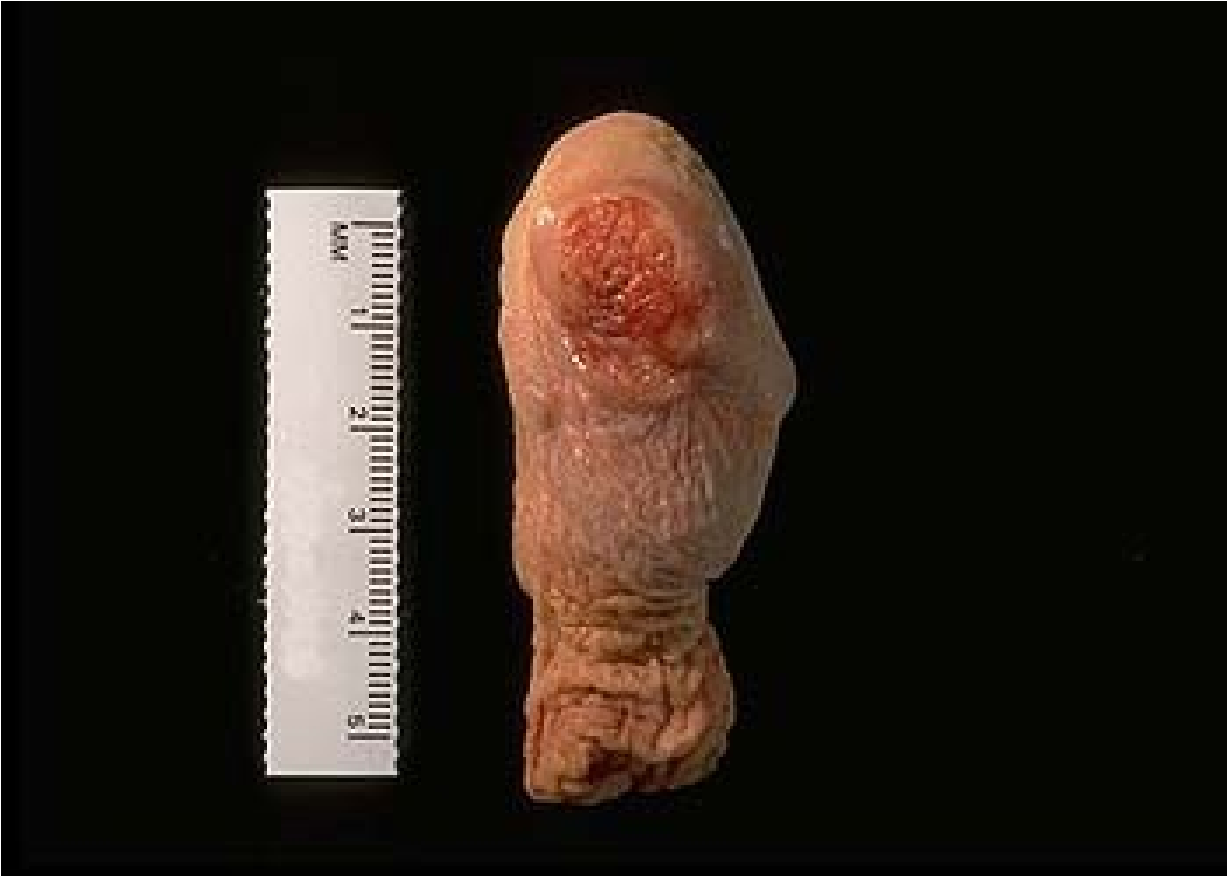IHC p16



# Invasive squamous cell ca

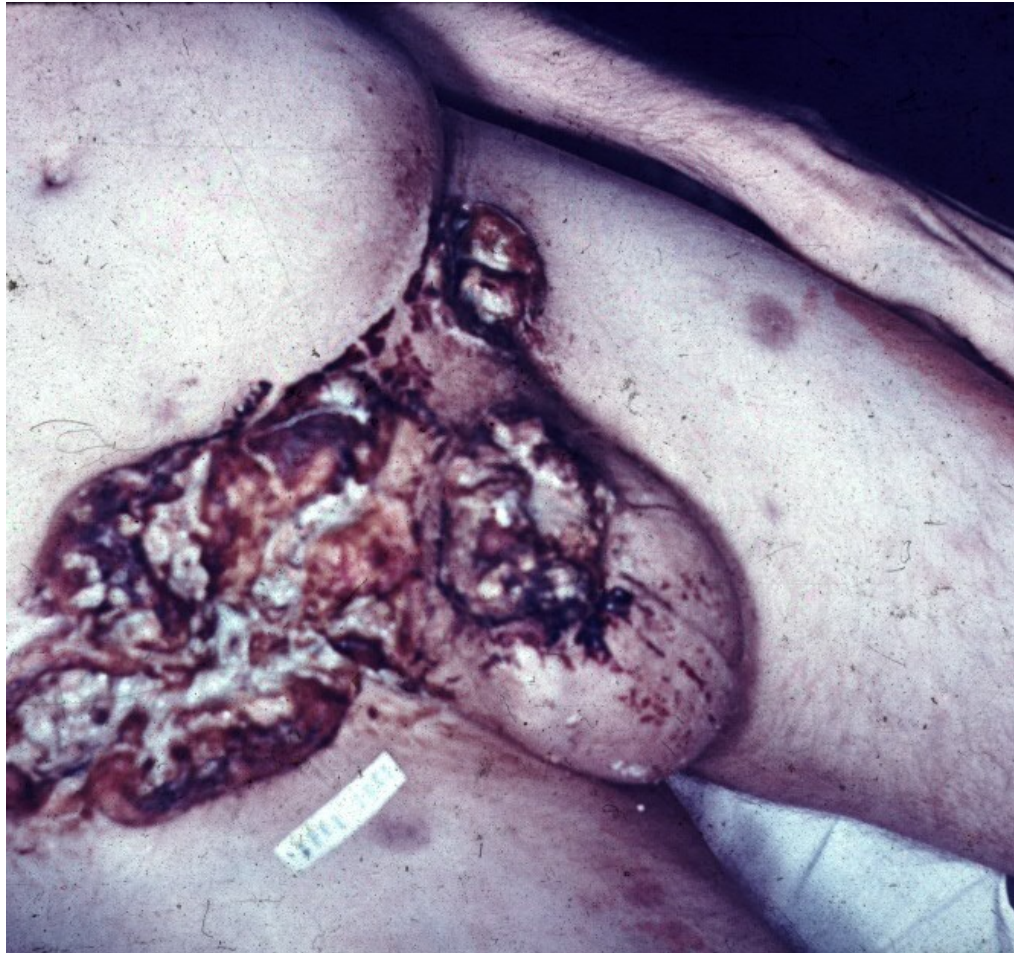- geography (Latin America, East Asia)
- circumcision - protective factor (↓HPV, carcinogenes in smegma)
- risk factors – smoking, occupational (mineral oil, tar)
- gross – ulcer, non-healing lesion
- micro – sq. ca of variable type/grade
- HPV-associated
- HPV-independent

# Carcinoma of the penis

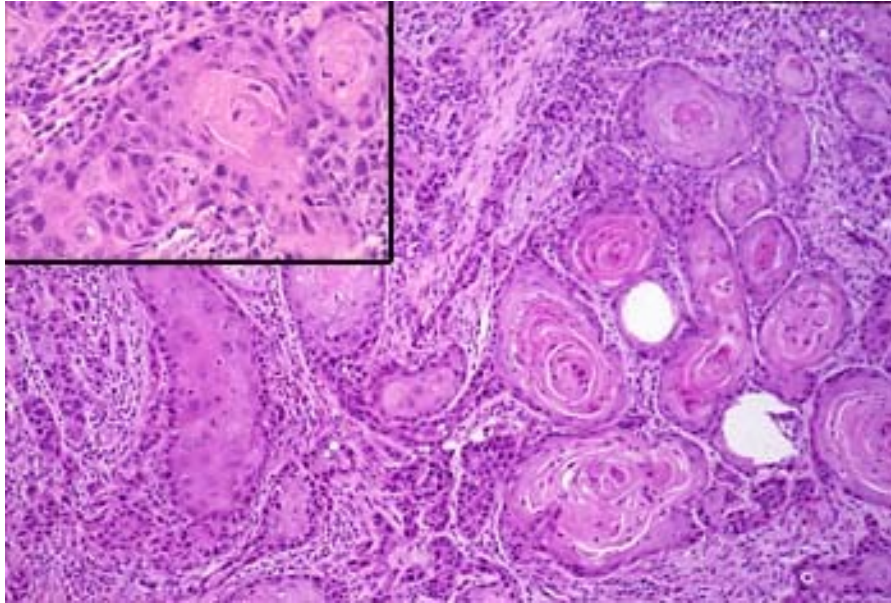




# Carcinoma of the penis



# Squamous cell carcinoma of the penis



# Prostate gland

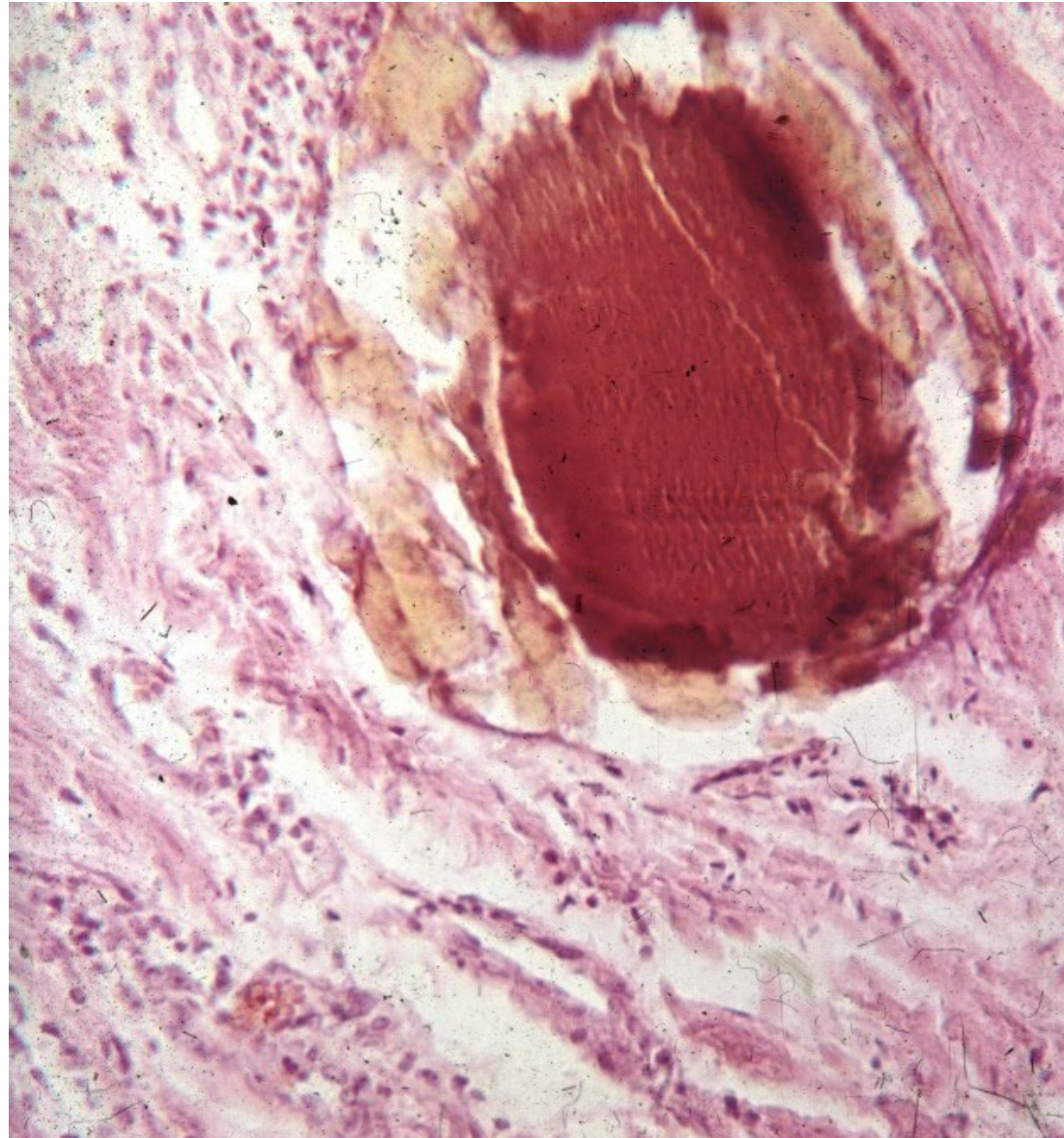
- **infarction** (usually in hyperplastic prostate, repair with sq. cell metaplasia may mimic ca)
- **inflammation** (acute/chronic, a/bacterial, granulomatous)
- **benign nodular hyperplasia (adenomyomatous)** + related lesions
- **precancerous lesions, tumors** (PIN, adenocarcinoma, other)



# Inflammation

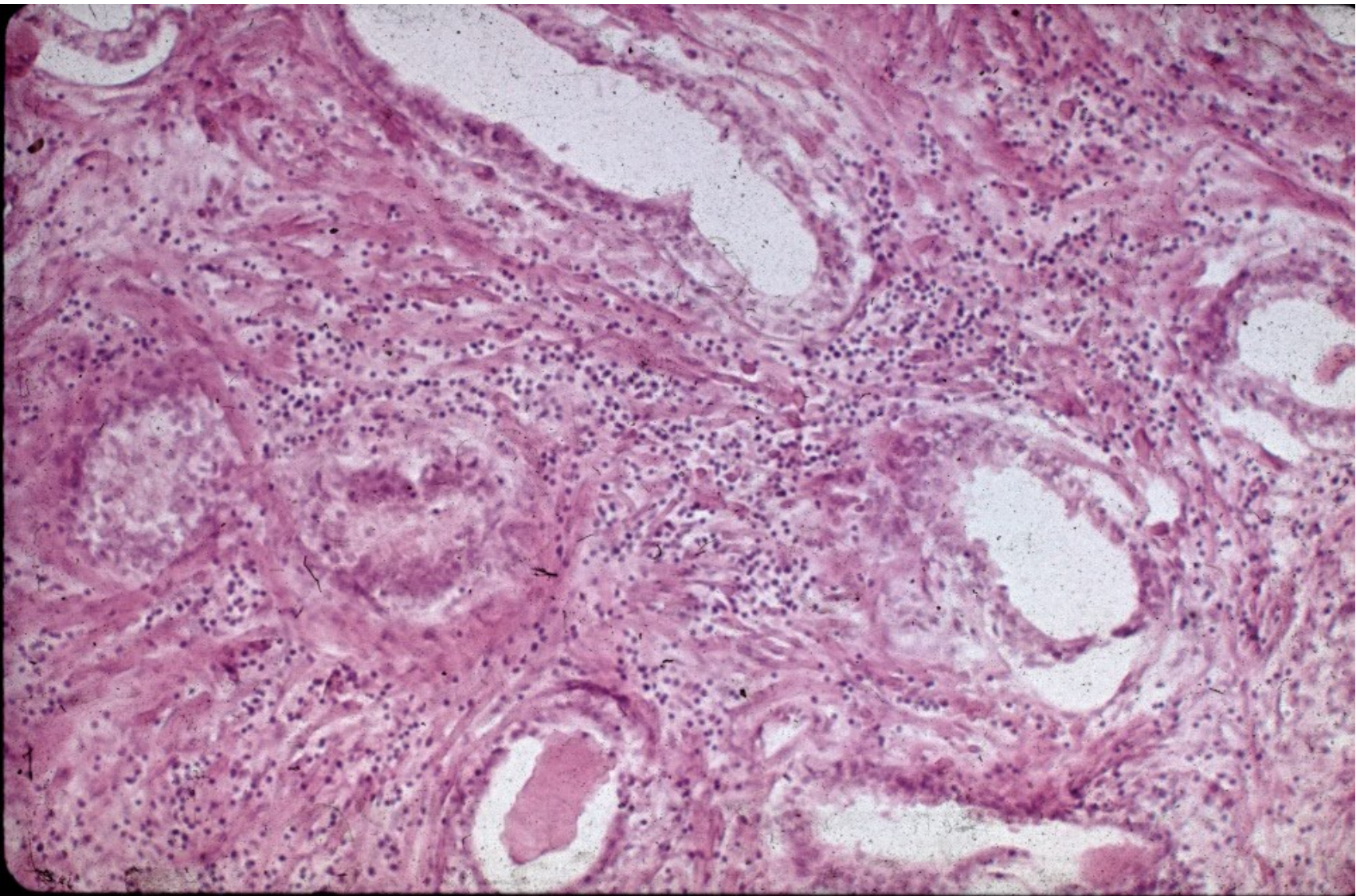
- **Acute bacterial**: ~ UTI, intraprostatic reflux of urine, iatrogenic – catheterization, cystoscopy, surgery. Pain, dysuria, fever.
- **Chronic bacterial**: repeated UTI, non-specific symptoms. Difficult to treat.
- **Chronic abacterial**: most common, no UTI, negative bacterial culture, reactive (+ prostatolithiasis), Chlamydia, ureaplasma
- **Granulomatous**: specific: Tb, BCG used for bladder ca; reactive

# Prostatolithiasis





# Chronic prostatitis



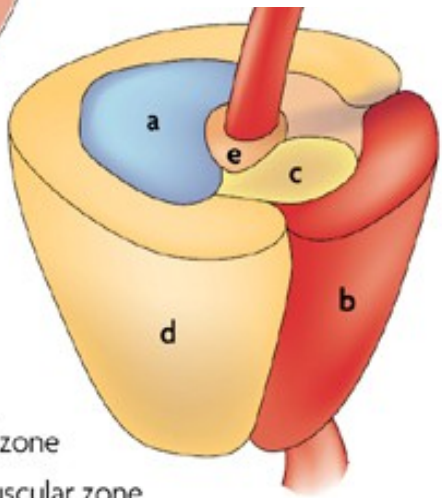
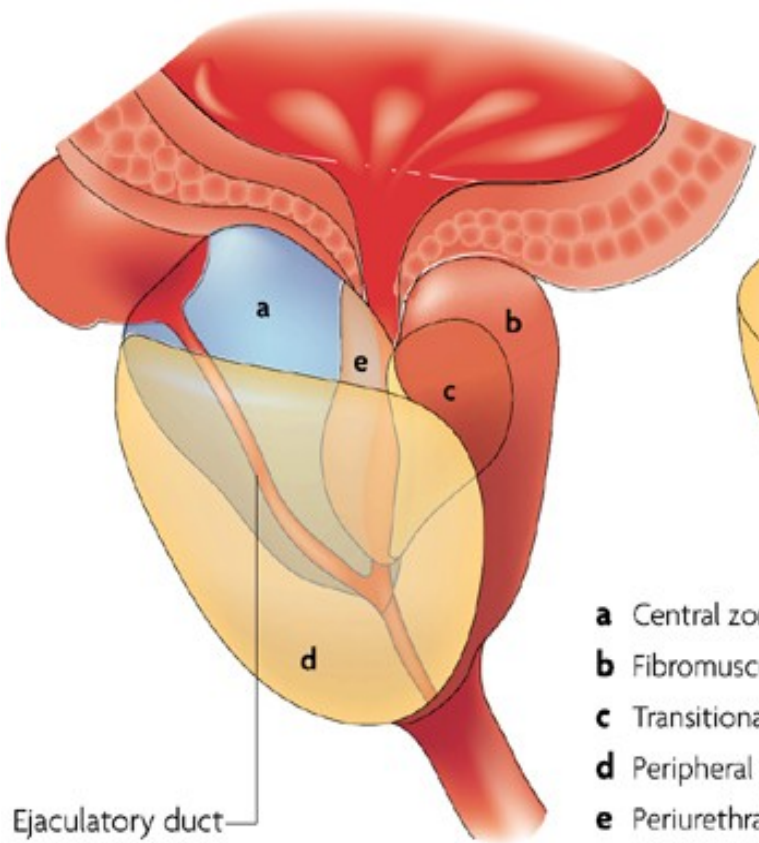


# Zonal predisposition of prostate diseases

	Prostate zone		
	Peripheral	Transition	Central
Focal atrophy	Medium-high prevalence	Medium-high prevalence	Low prevalence
Acute inflammation	Low prevalence	Low prevalence	None
Chronic inflammation	Medium-high prevalence	Medium-high prevalence	Low prevalence
Benign prostatic hyperplasia	None	High prevalence	Low prevalence
High-grade PIN	Medium-high prevalence	Low prevalence	Low prevalence
Carcinoma	Medium-high prevalence	Low prevalence	None

■ High prevalence      □ Low prevalence  
■ Medium-high prevalence      □ None

Prostate zones



- a** Central zone
- b** Fibromuscular zone
- c** Transitional zone
- d** Peripheral zone
- e** Periurethral gland region

# Benign prostatic hyperplasia

- Common in older men, high incidence > 60 yrs
- Adenomyomatous hyperplasia – stromal (smooth muscle, fibrotic tissue) + glandular, alternating with atrophy, cystic and regressive changes. Two cellular layers – outer myoepithelial, inner secretory
- Gross: enlarged, nodular, tougher.
- Main changes in central (periurethral) region

# Benign prostatic hyperplasia

- **Outcome:** partial → complete urethra obstruction, urinary residuum, risk of infection (+ ascending – pyelonephritis), bladder trabecular hypertrophy, hydronephrosis.
- Benign, but setting for possible preneoplastic changes
- Th: surgery, drugs



# Benign prostatic hyperplasia

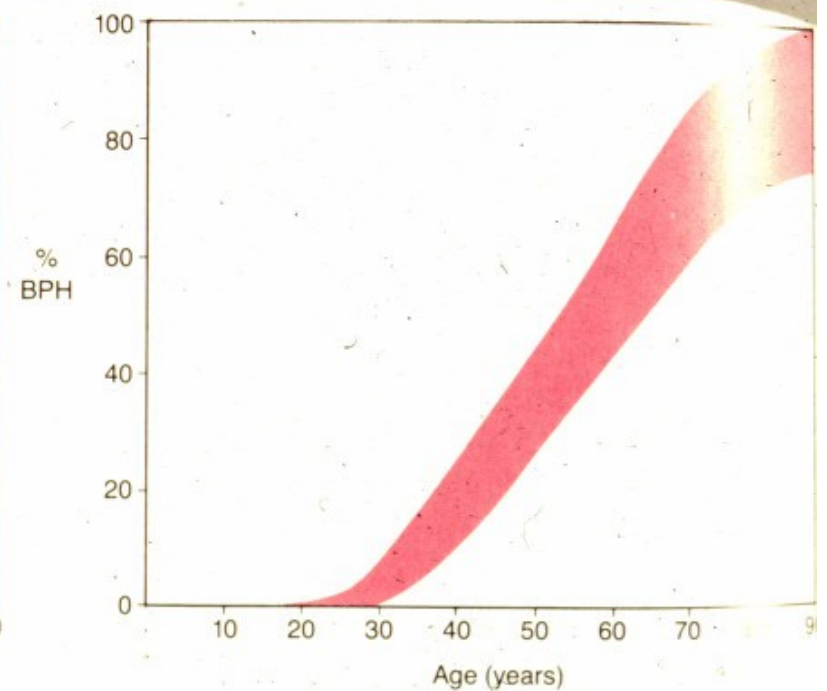
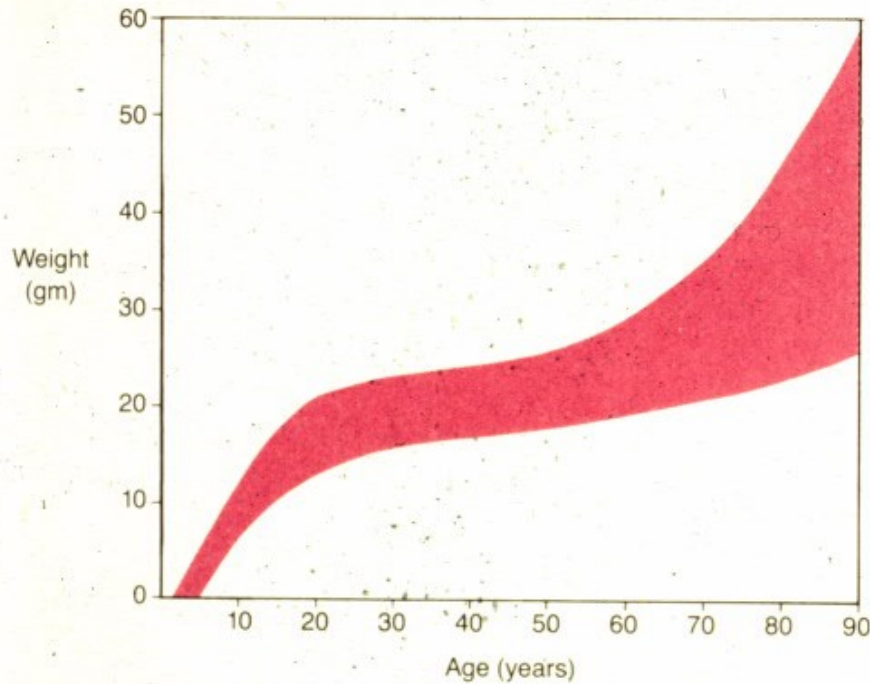
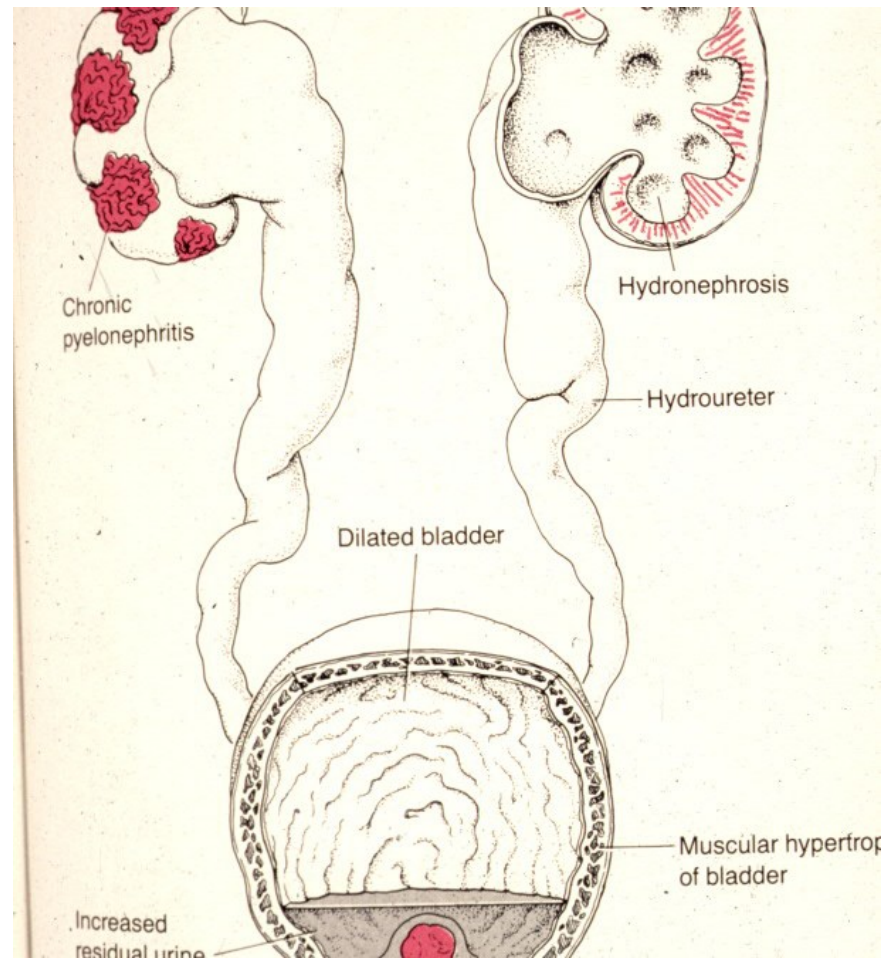
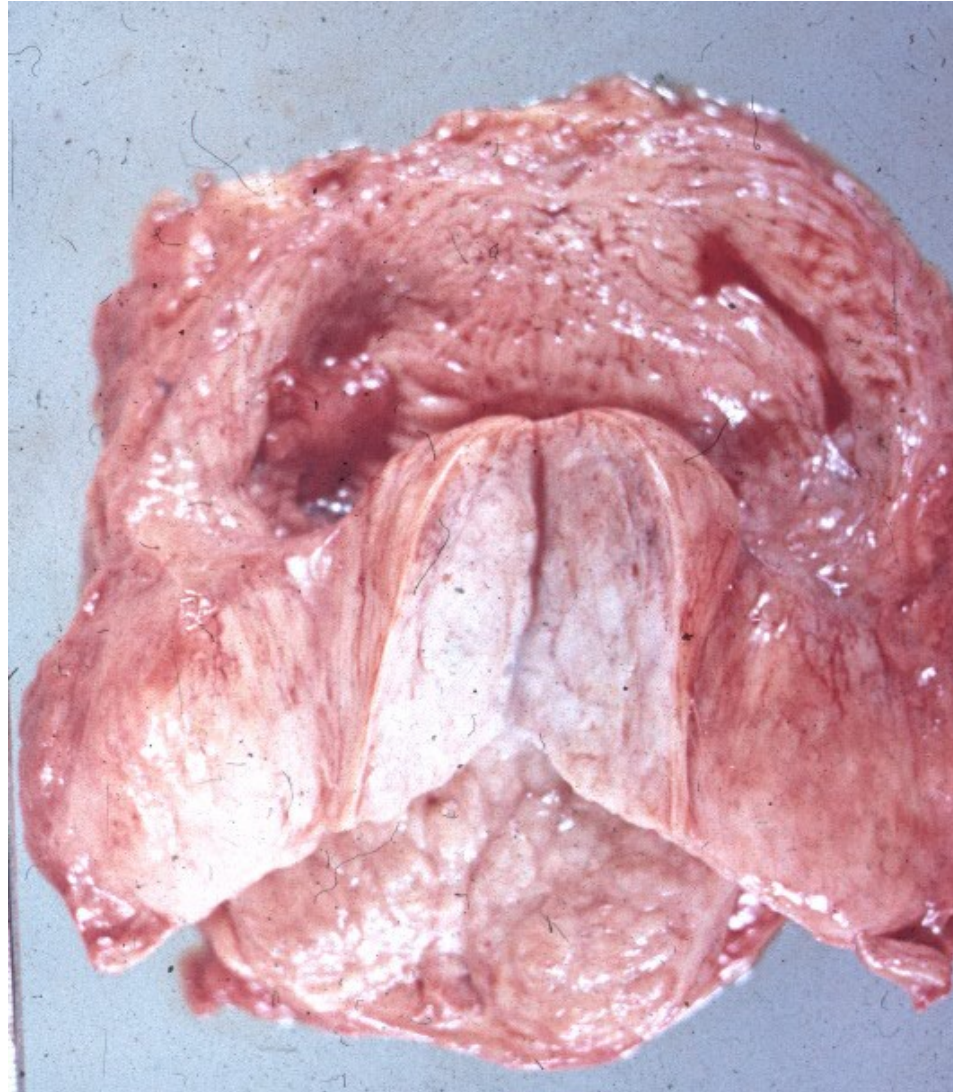


FIGURE 17-34  
Growth of the prostate (*left*) and frequency of nodular hyperplasia (*right*). By 80 years of age, most men have benign prostatic hyperplasia.

# Benign prostatic hyperplasia - complications

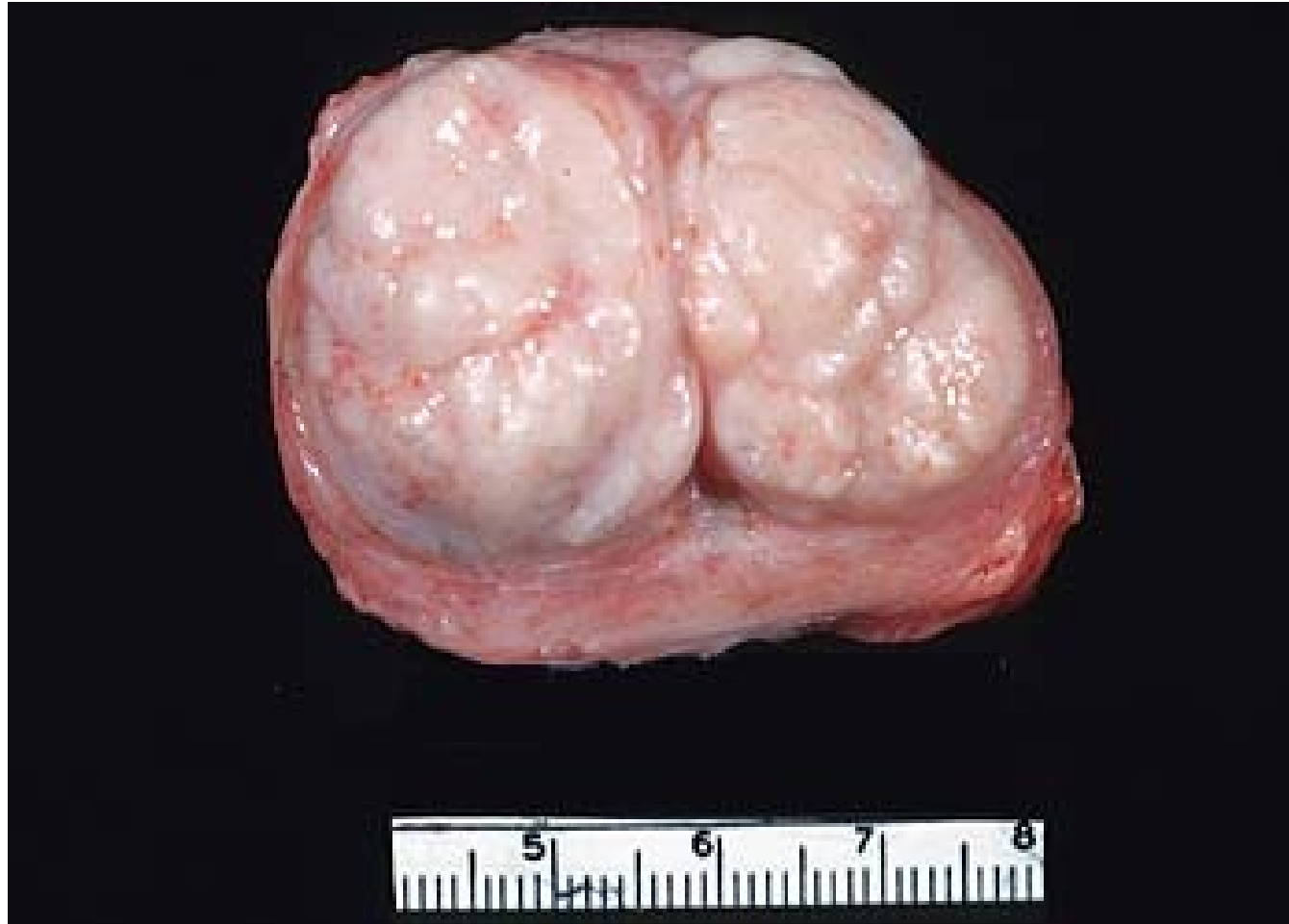

# Benign prostatic hyperplasia

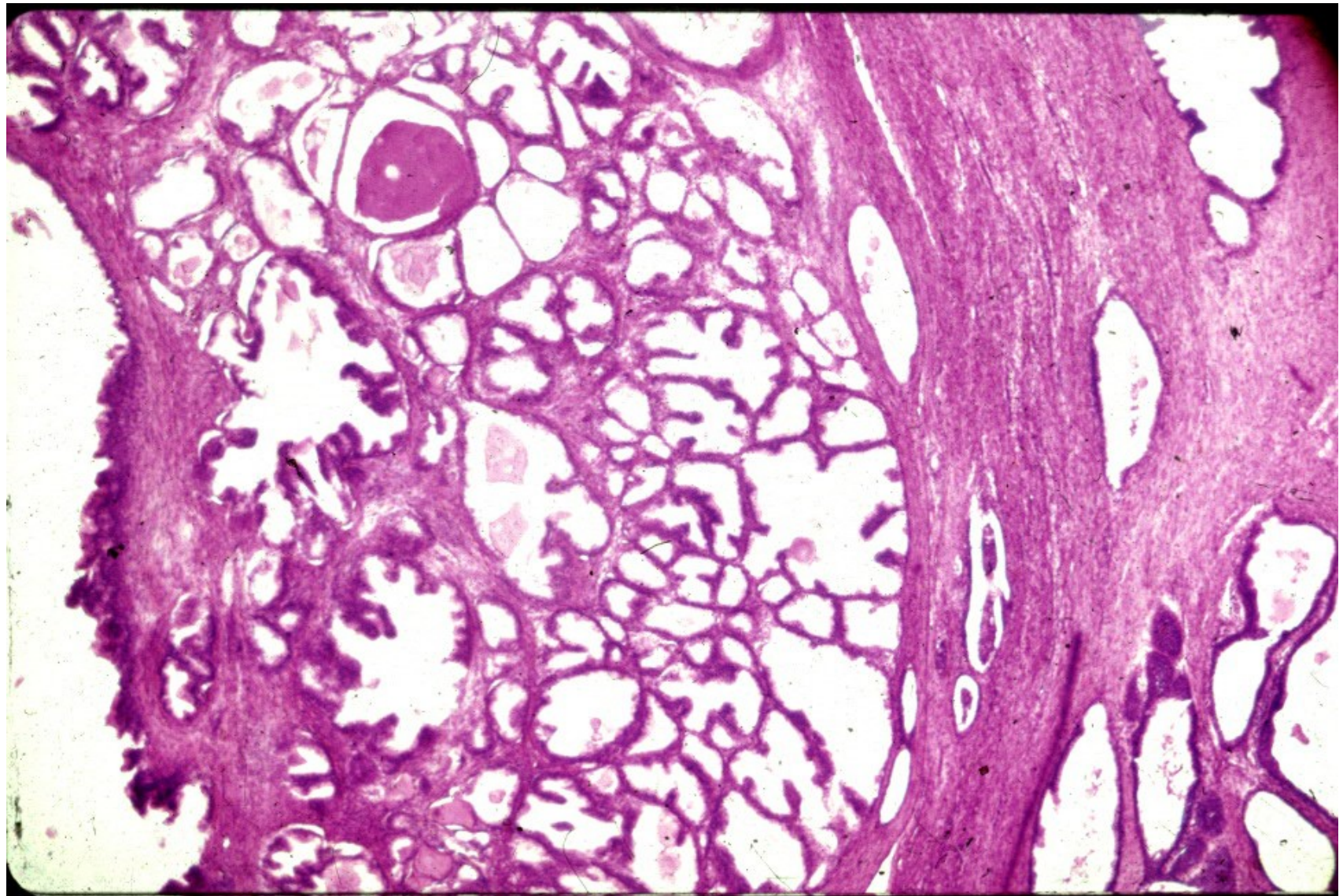




## Benign prostatic hyperplasia

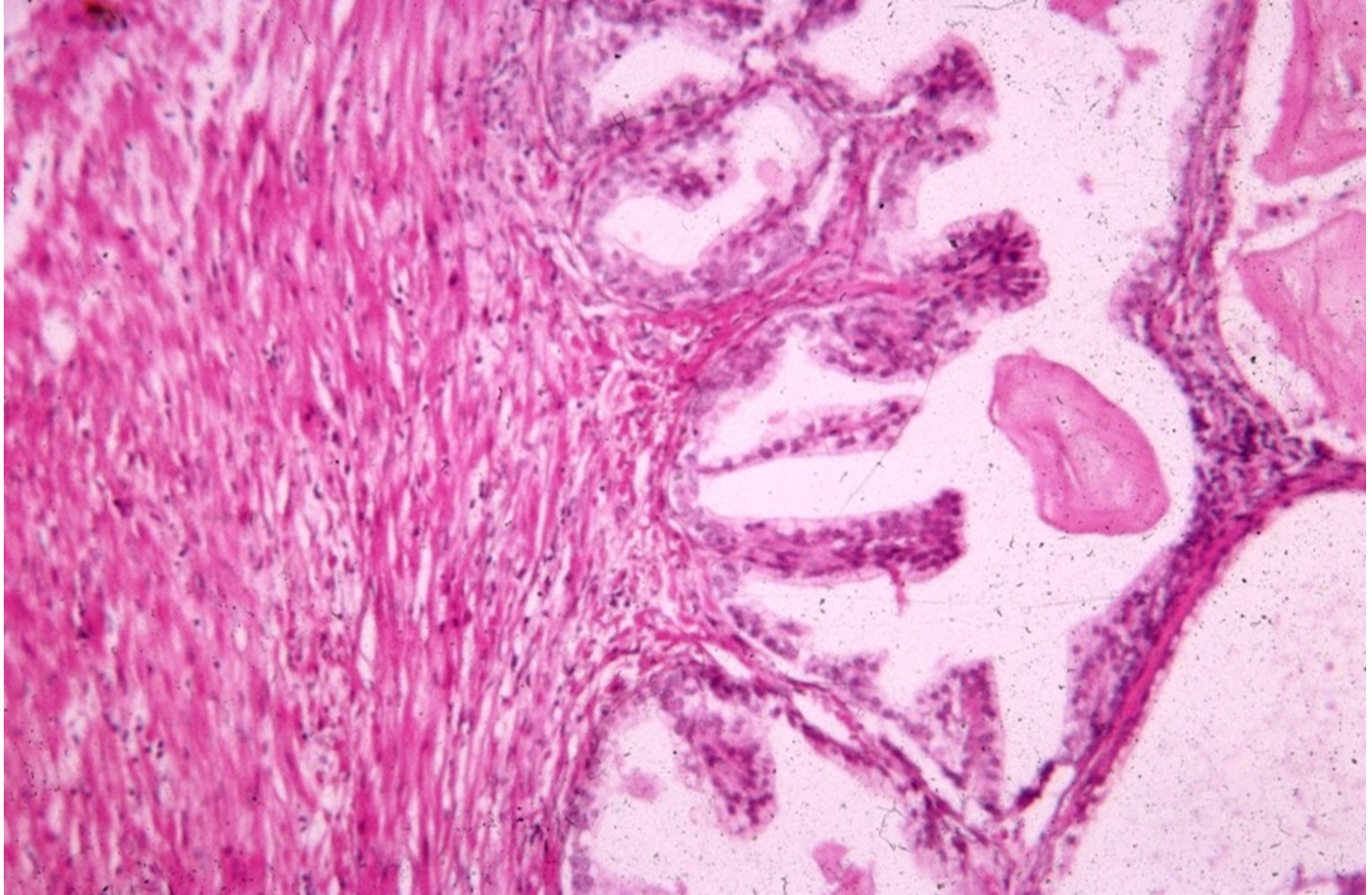

## Benign prostatic hyperplasia



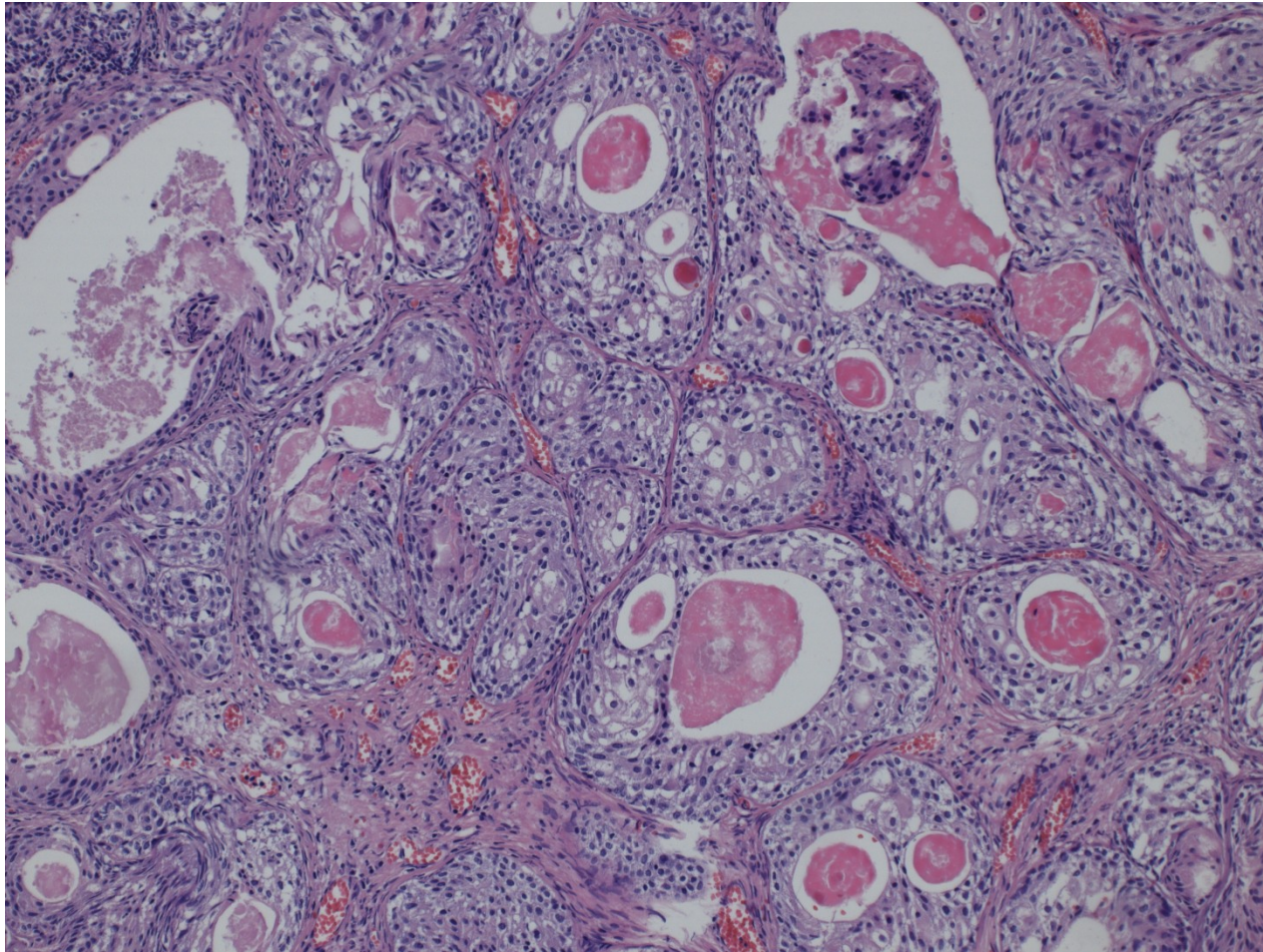


# Benign prostatic hyperplasia





# Prostate – squamous cell metaplasia



# Pseudotumors, tumors:

- Benign prostatic hyperplasia
- Carcinoma
  - **Acinar**
  - Ductal
  - Squamous cell
  - Adenosquamous
  - Transitional cell
  - Neuroendocrine
- Secondary tumors
  - local ca infiltration from adjacent organs (bladder, rectum)
  - haematogenous metastases (lung ca, malignant melanoma, ..)

# Prostatic carcinoma

- Adenocarcinoma: usually acinar, less common other types – ductal
- most common male ca (~1:6)
- late middle age – older males
- Highly variable course from clinically latent to extremely aggressive
- Recent studies: screening (PSA) questions – possible overtreatment x late diagnosis



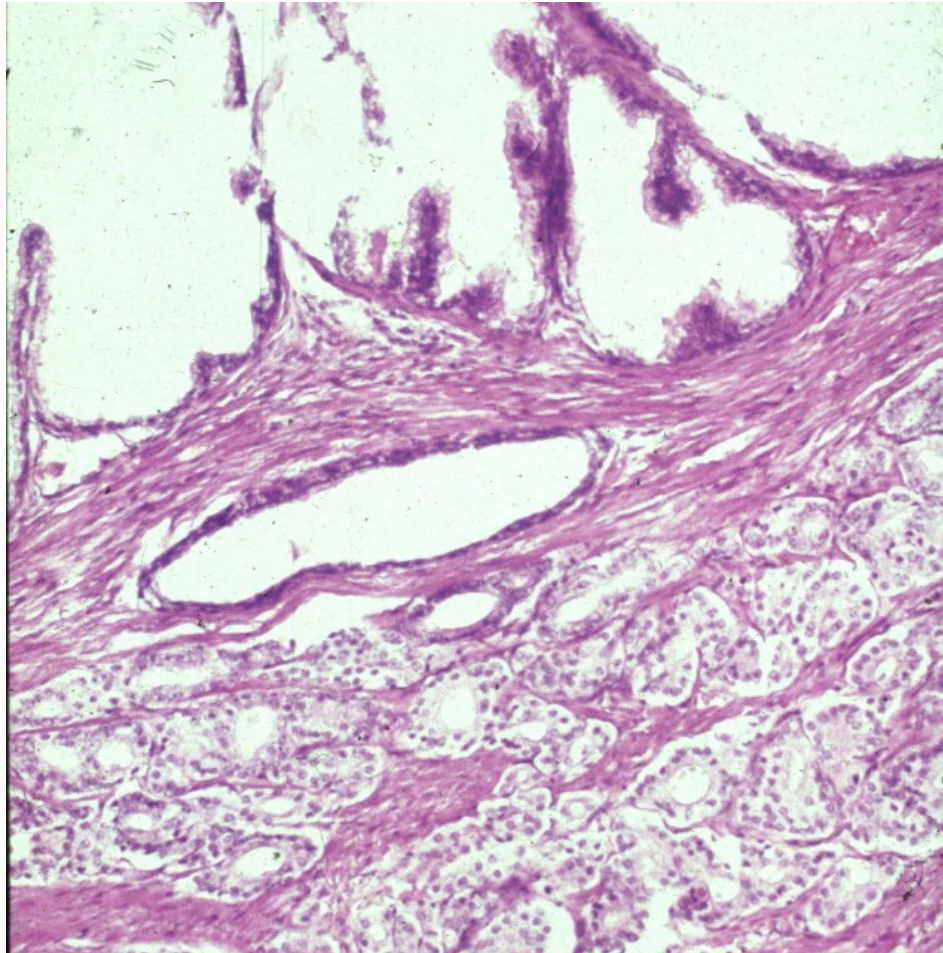
# Prostatic carcinoma

- Important factors: race, family history, age, hormone level (androgenes), environment
- Peripheral part (dorsal) – per rectum
- PIN: prostatic intraepithelial neoplasia – precursor lesion. High grade PIN important + included into pathological report
- Distinctive nucleoli, architectural changes, in PIN myoepithelial layer still present

# Prostatic carcinoma + hyperplasia

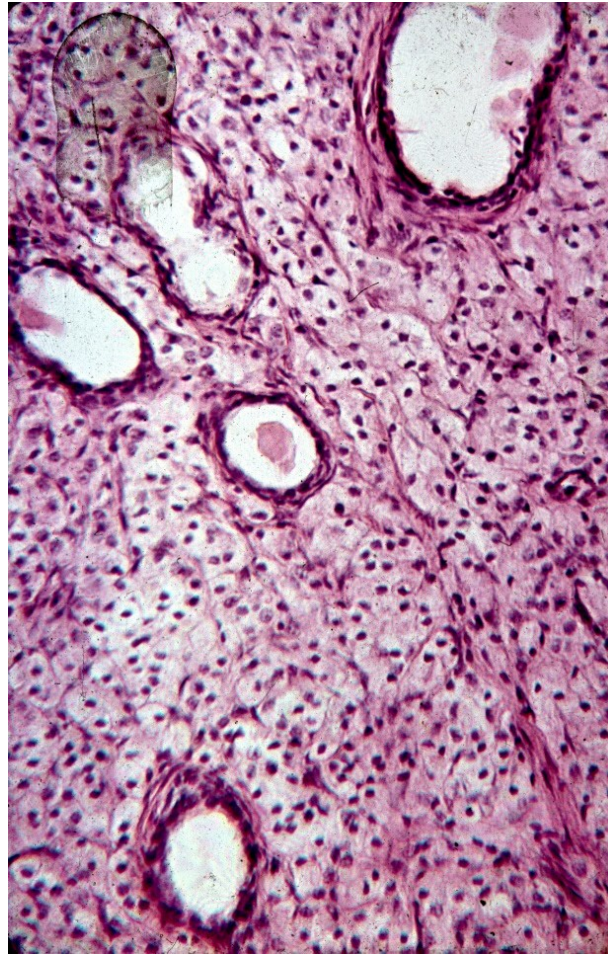


# Prostatic carcinoma

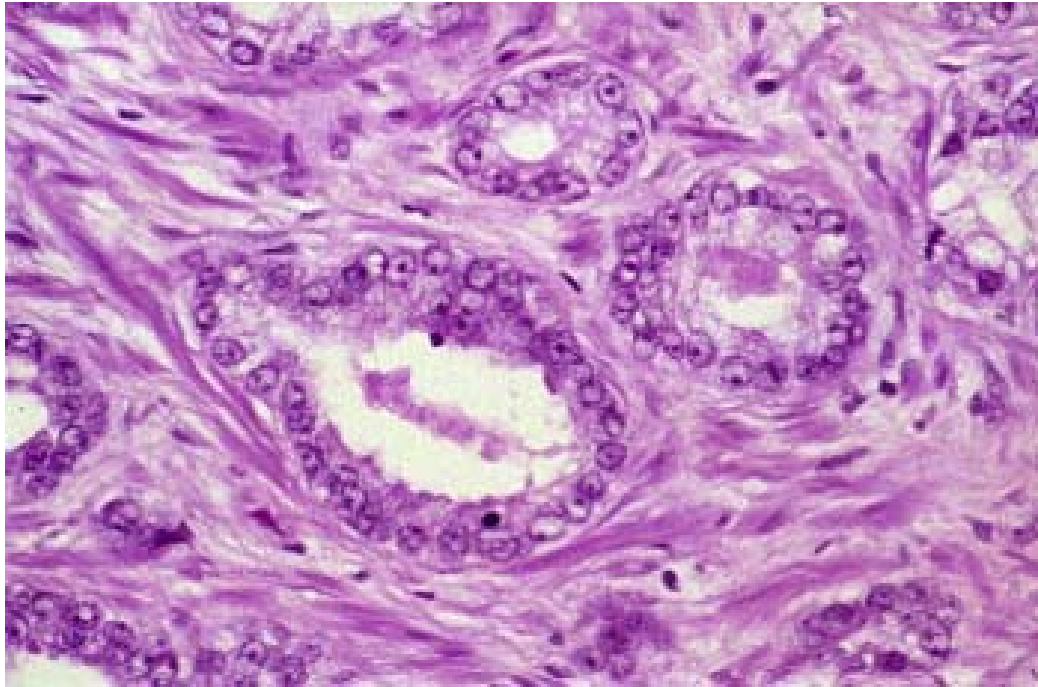




# Prostatic carcinoma

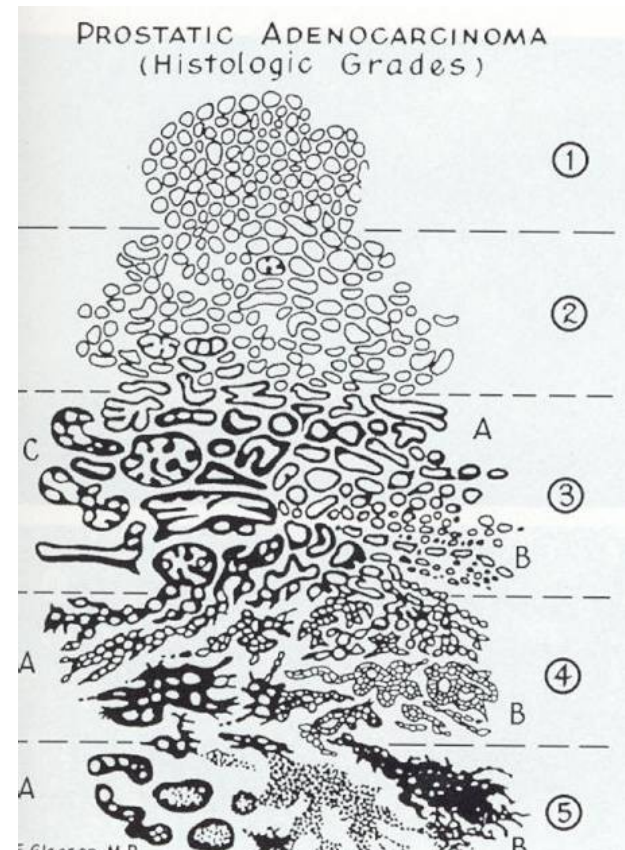


# Prostatic carcinoma



# Acinar prostatic adenocarcinoma

- **Gleason histologic grading (WHO modification):**
  - **grade of glandular differentiation, growth pattern**
  - **combined score - dominant + secondary pattern in 5-grade system**
    - grade 1 similar to normal prostatic tissue (uncommon in ca)
    - grade 5 with solid, dissociated pattern
  - final combined score, commonly Gleason score 7 (4+3)

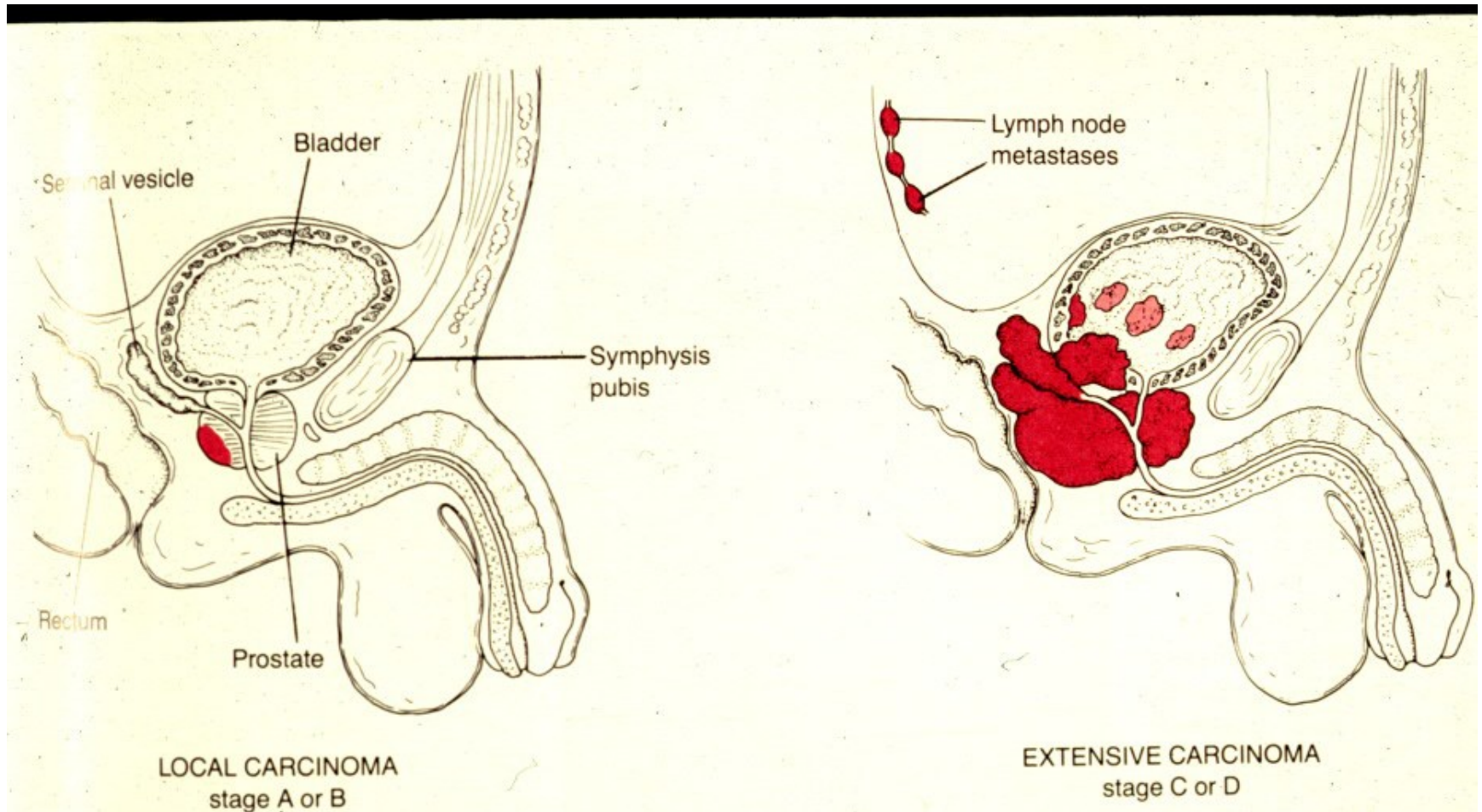




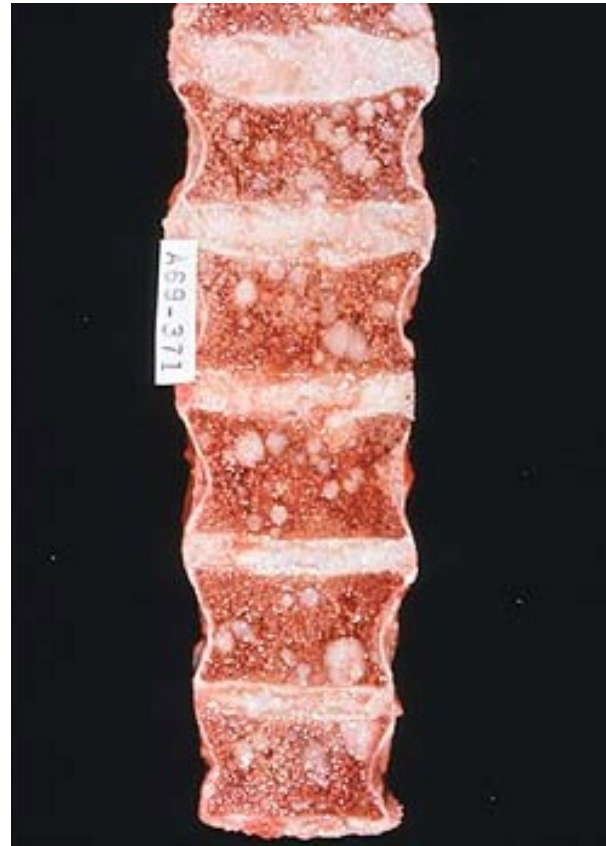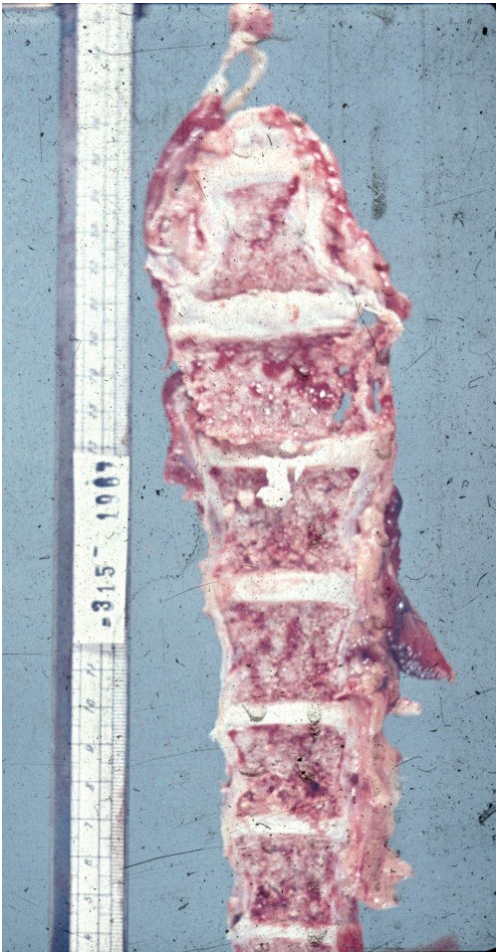# Prostatic carcinoma

- Local spread – into urinary bladder; diff. dg x high grade transitional cell ca, may be concurrent
- Metastatic spread: regional lymph nodes, hematogenous typical into bones – osteoplastic meta
- Symptoms – urinary commonly late, more due to prostatic hyperplasia; local spread; meta

# Prostatic carcinoma

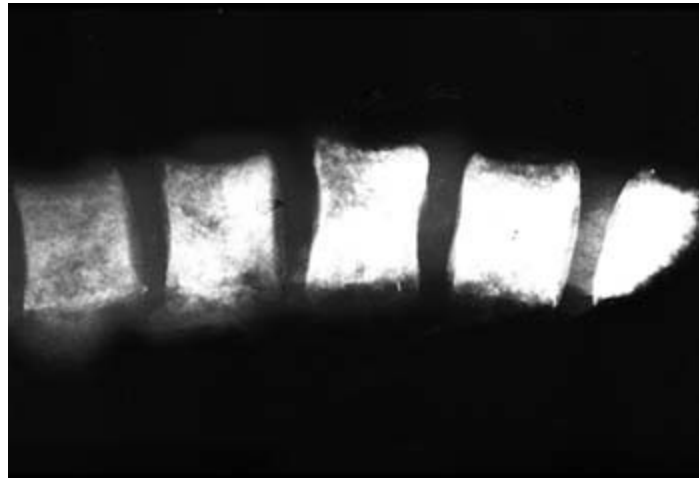


# Prostatic carcinoma - spine metastases

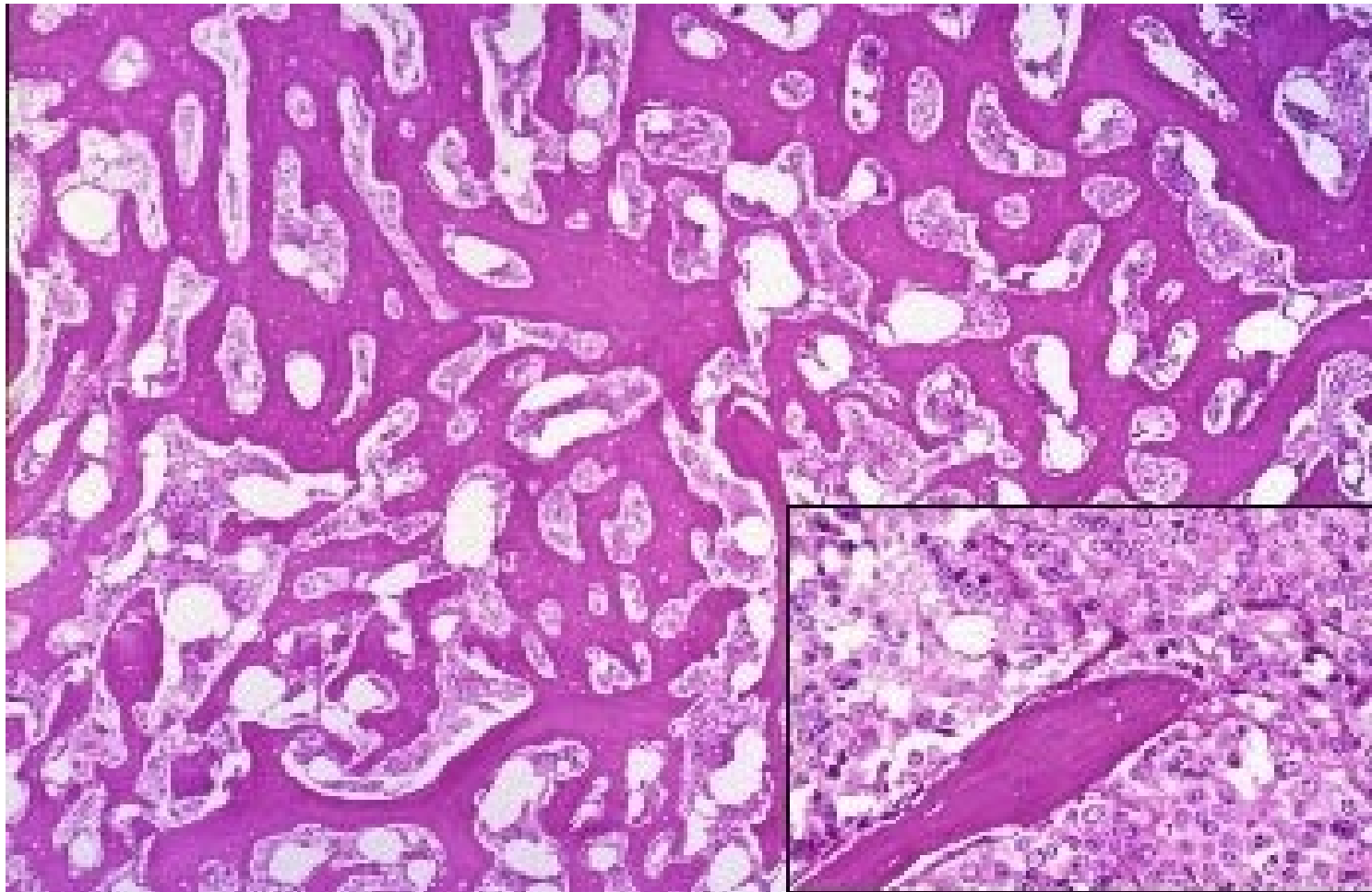




# Prostatic carcinoma - spine metastases, X-ray



## Prostatic ca metastasis in bone



# Testis, epididymis, cord

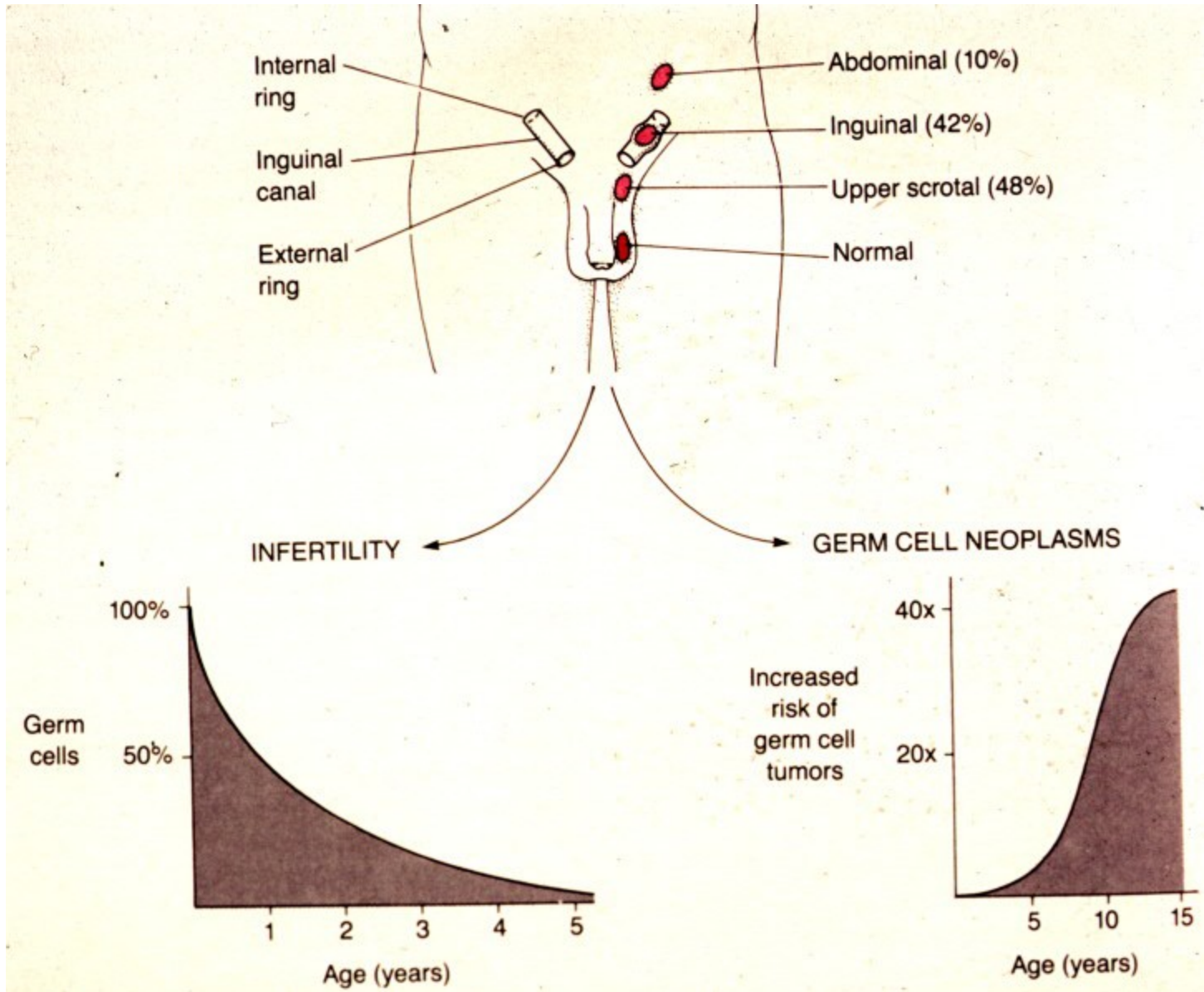
- **congenital** (cryptorchidism – atrophy, risk of neoplasia)
- **regressive changes** (atrophy, torsion)
- **inflammation** (orchitis – nonspecific acute/chronic, STD (gonorrhea, syphilis, chlamydia), mumps, tbc, idiopathic granulomatous)
- **tumors**



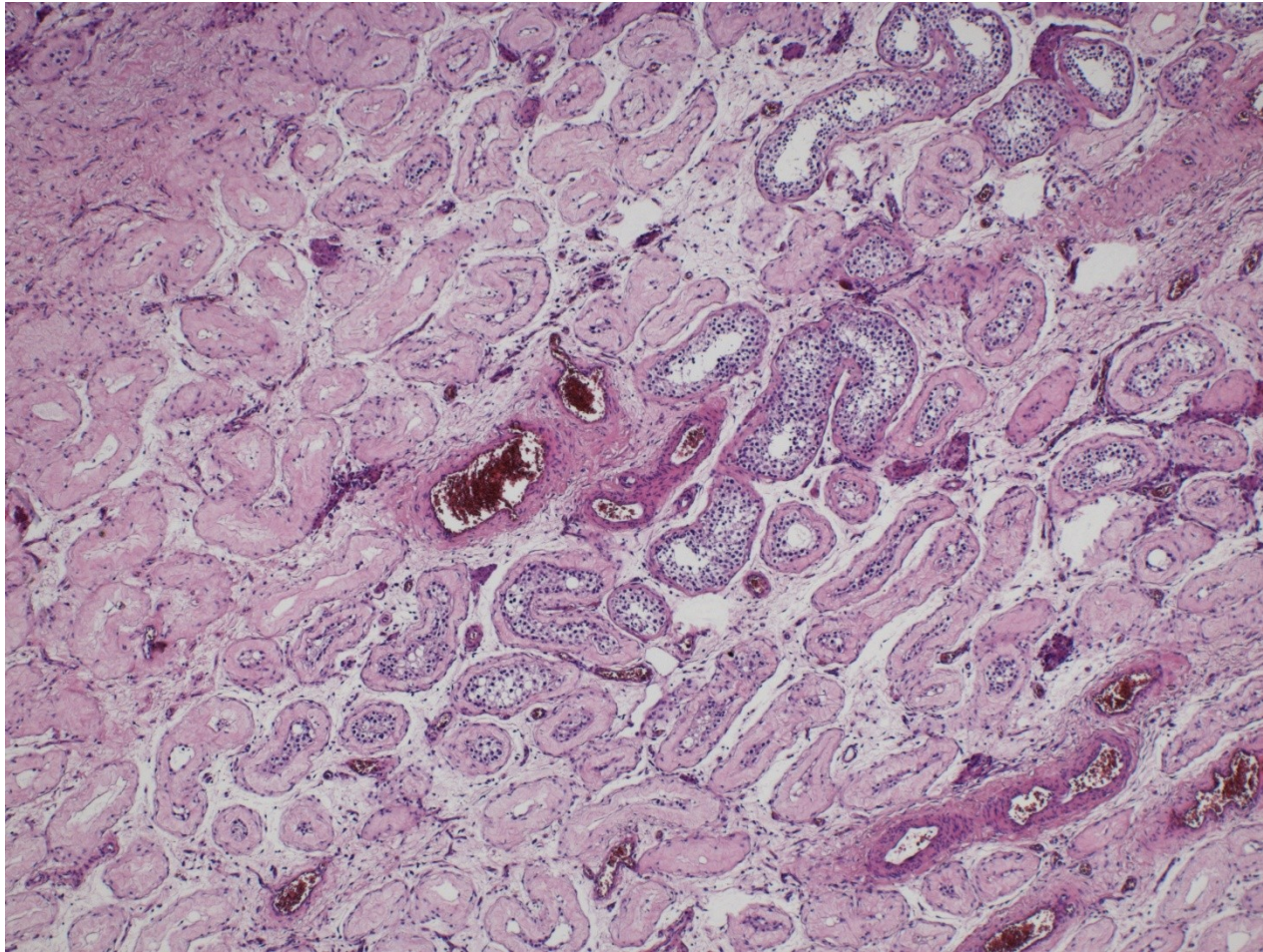
# Cryptorchidism

- Undescended testis
- 1 in 10 newborn males, usually descends during 1st year of life
- remains in inguinal canal or abdominal cavity – surgery necessary before puberty
- atrophy – infertility, germ-cell tumors

# Cryptorchidism

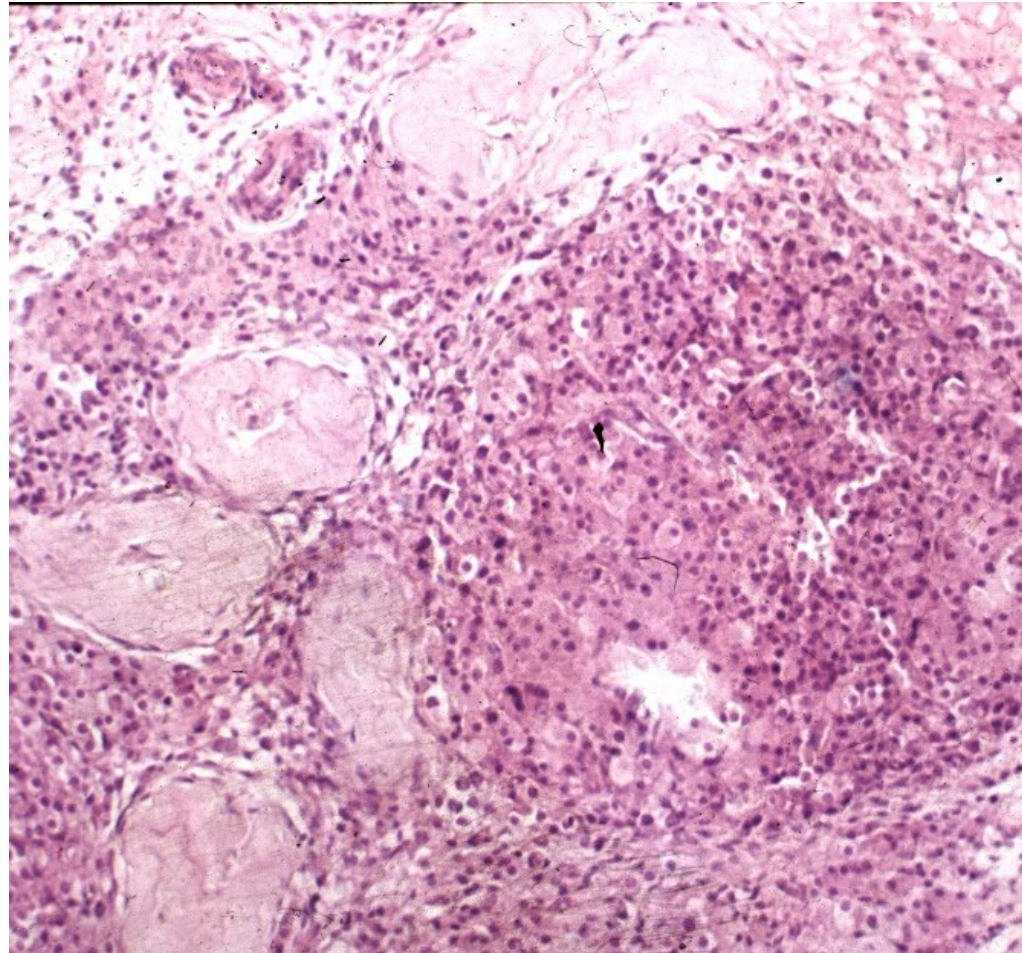


# Partial testicular atrophy





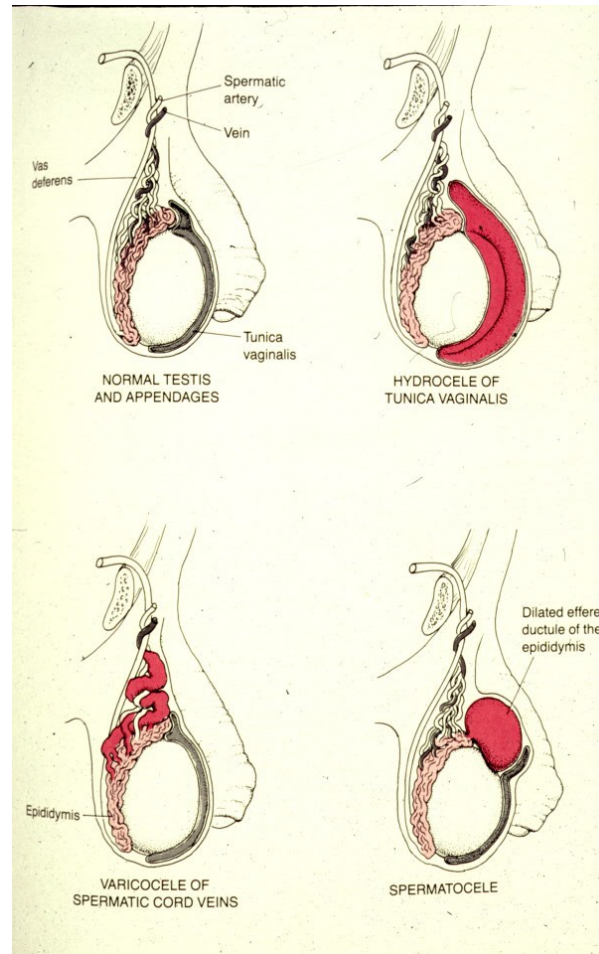
# Testicular atrophy + Leydig cell hypertrophy



# Intrascrotal swelling

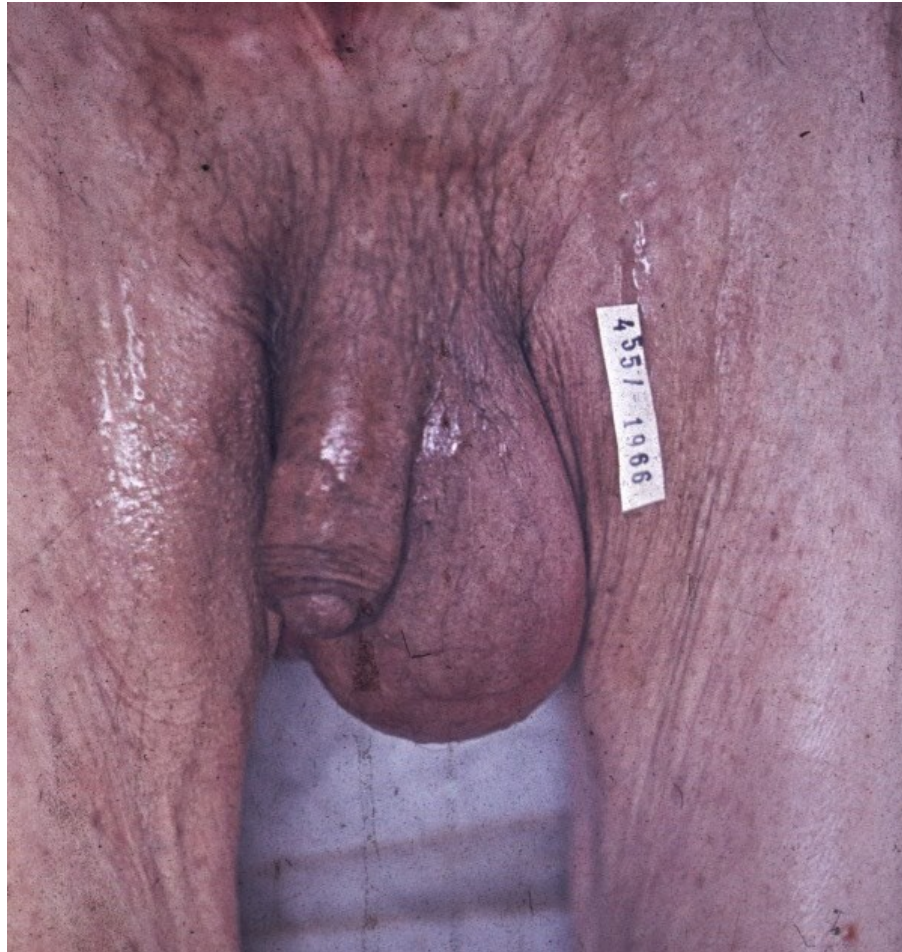- Commonly pathology of epididymis, tunica vaginalis
- Hydrocele – serous fluid in tunica vaginalis
- Haematocele – haemorrhage into tunica vaginalis
- Varicocele – dilated veins
- Spermatocele – epididymitis + cystic dilatation of ducts

# Intrascrotal swelling

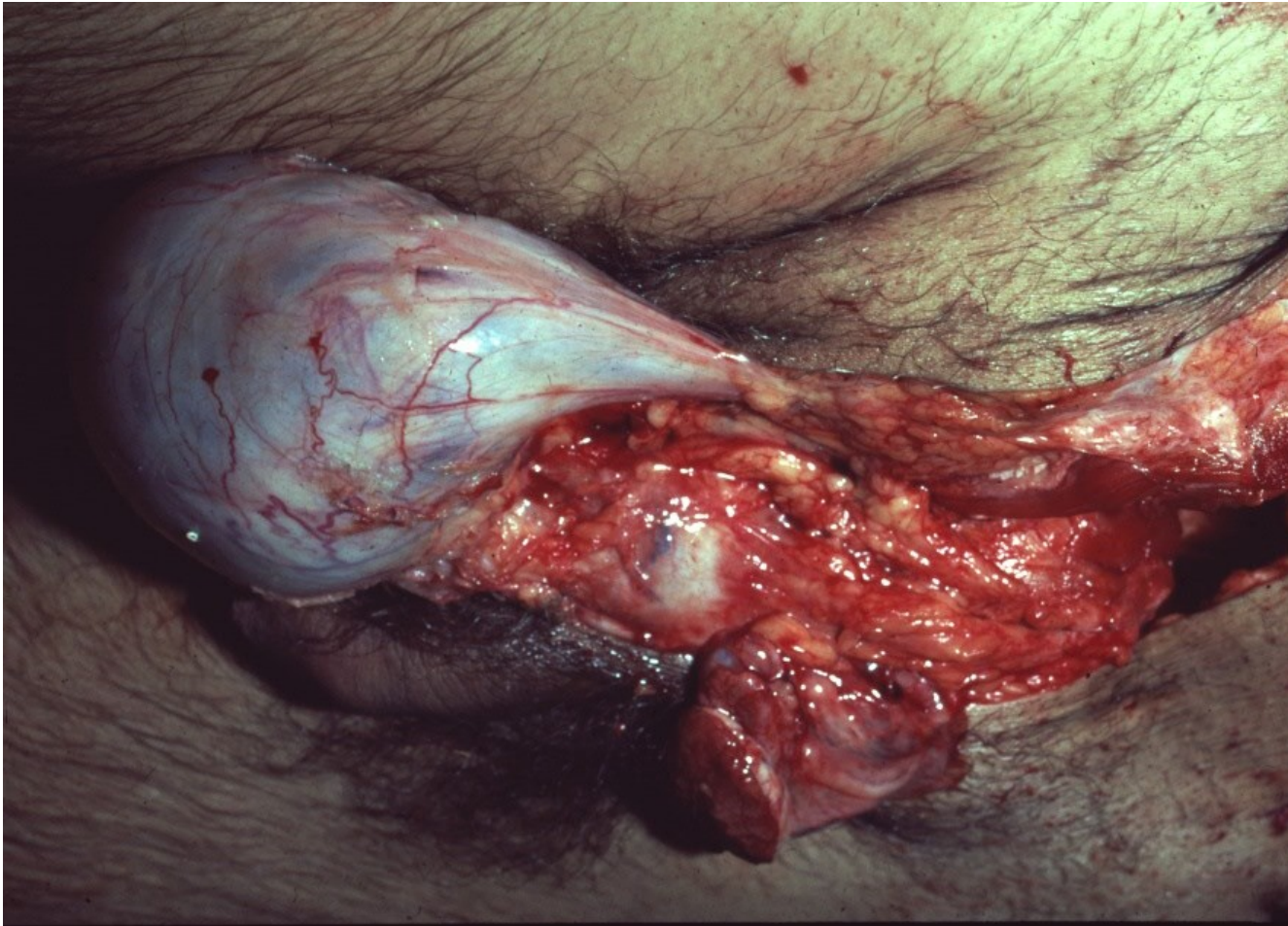




# Intrascrotal swelling - hydrocele



# Intrascrotal swelling - varicocele

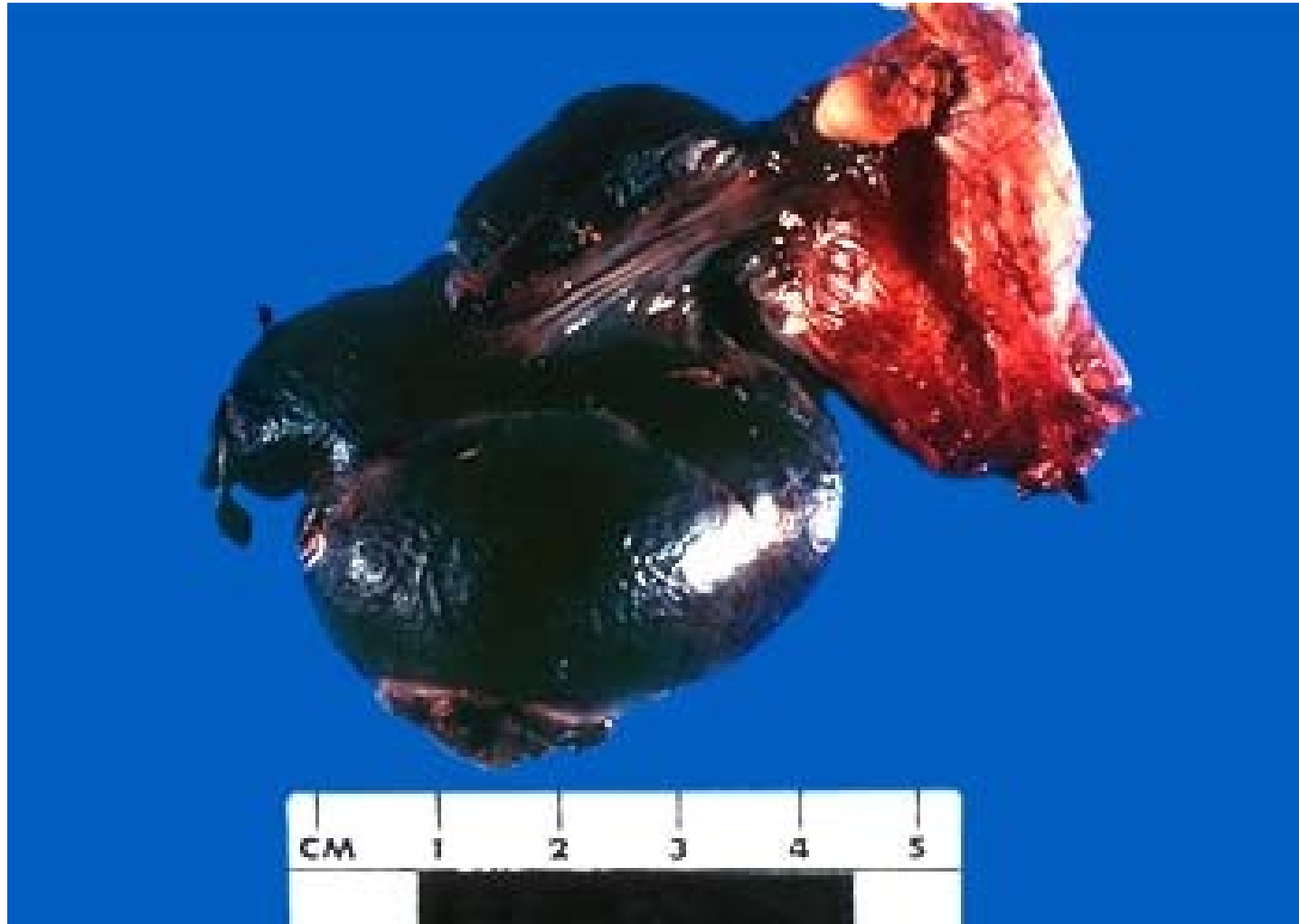

# Testicular torsion

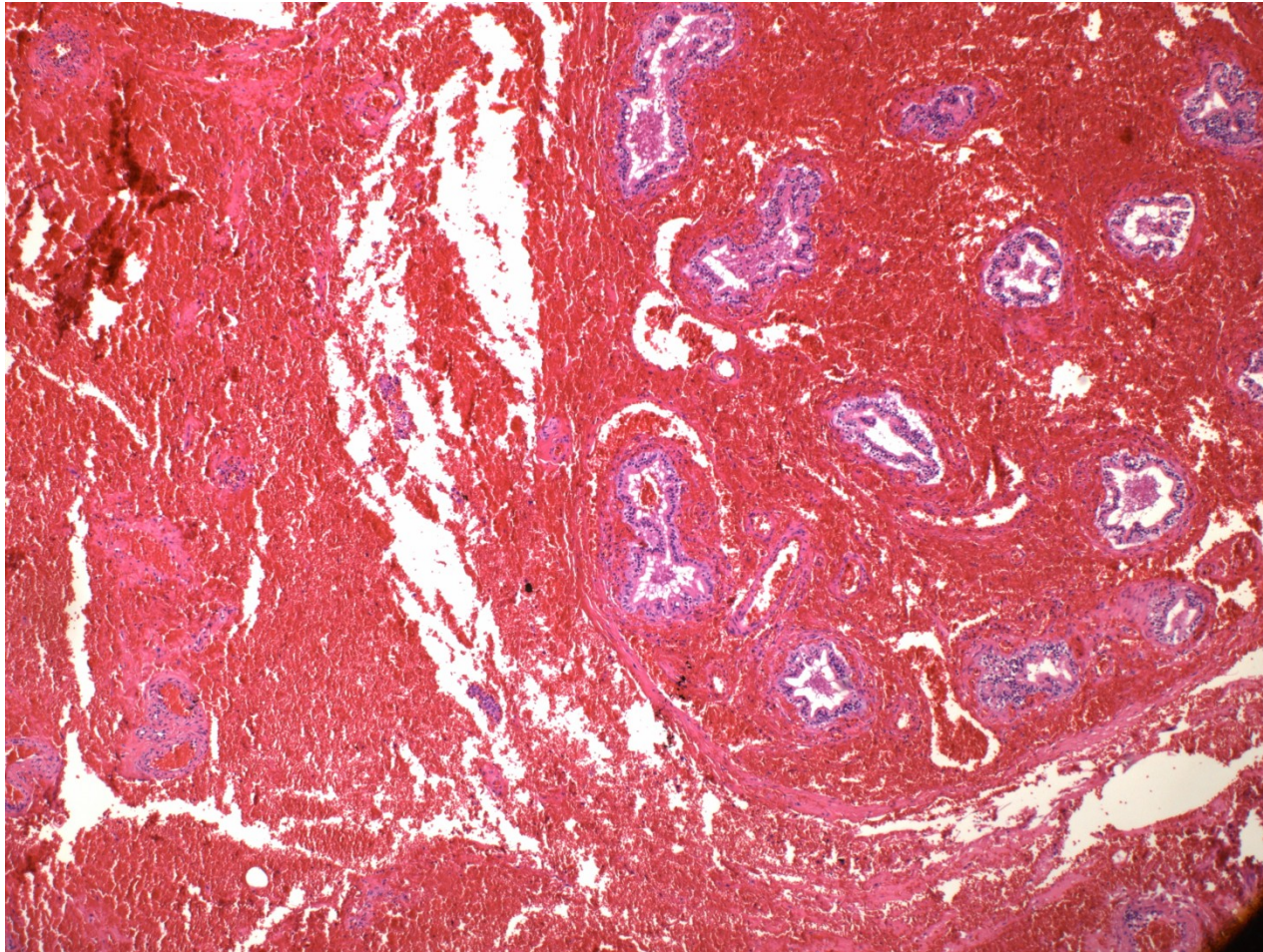
- Spermatic cord turns around its own axis
- Haemorrhagic necrosis
- Acute pain, swelling
- More common in young
- Immediate surgery necessary



# Torsion

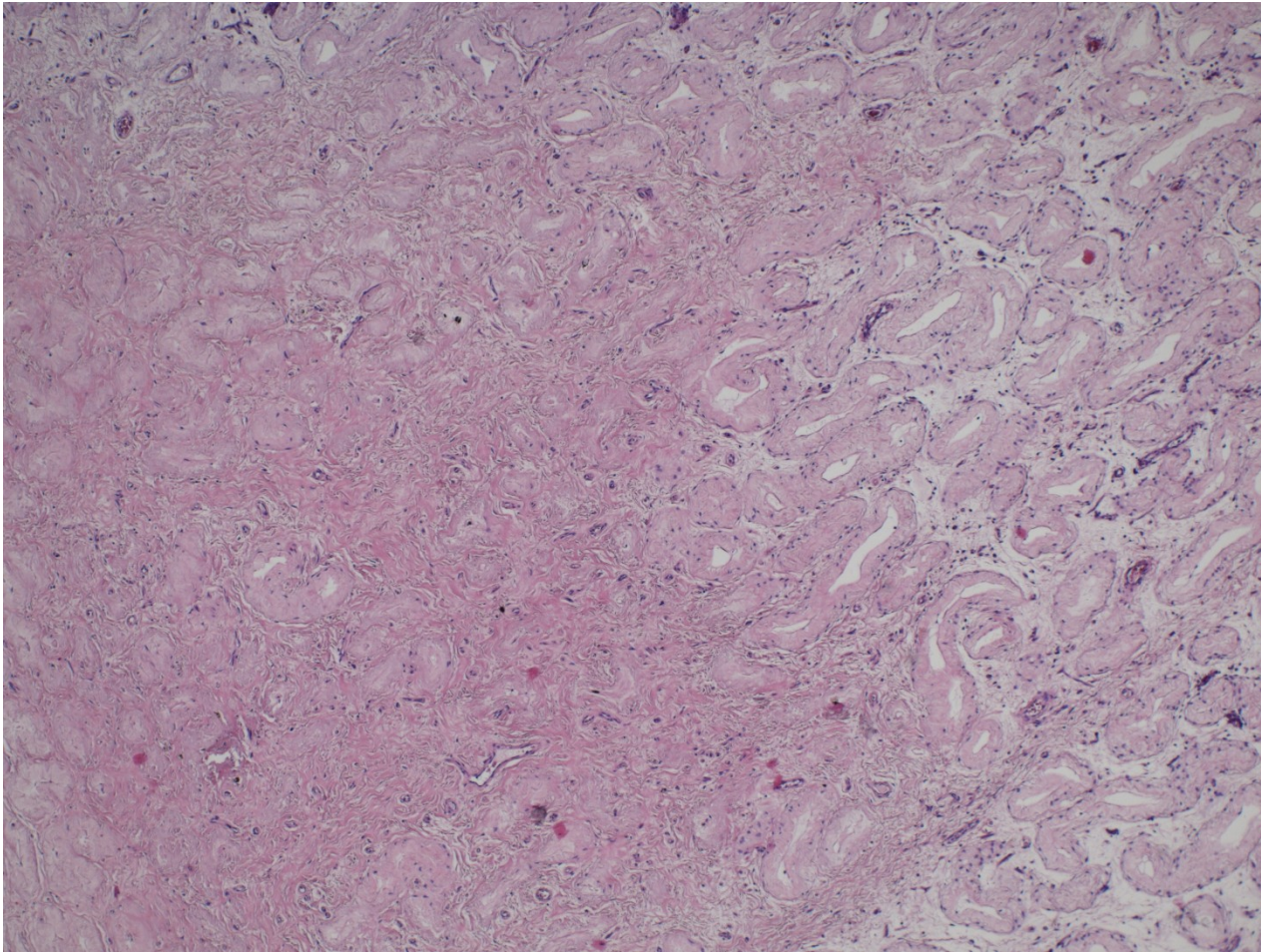


# Testicular torsion





# Testicular infarction





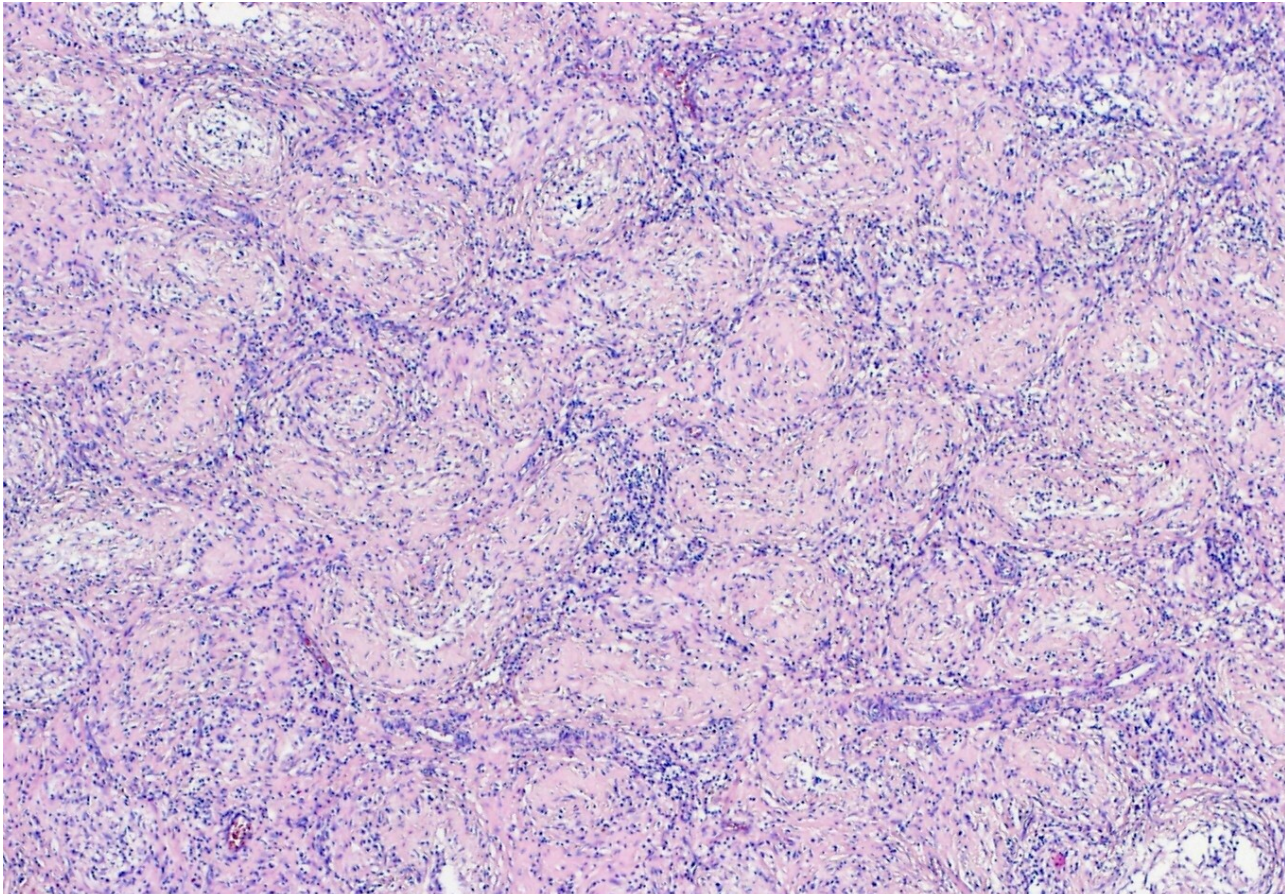
# Testis, epididymis inflammations

- epididymis >>> testis
- usually ascending from urinary tract and/or prostate
- caused by
  - gramnegative bacteria (children)
  - chlamydias, gonococcus (STI, adults)
  - E. coli (older adults)

# Testis, epididymis inflammations

- **Bacterial**
  - purulent → abscess, non-specific orchitis/epididymitis
- **Interstitial non-purulent orchitis**
  - mumps in adults
  - interstitial oedema + lymphocytes, plasma cells, macrophages
- **Granulomatous orchitis**
  - may be posttraumatic, v.s. autoimmune inflammation
  - non-caseating tuberculoid granulomas centered on tubules
  - firmer testicular mass (diff. dg. x tumor)
- **Spermatocytic granuloma**
  - in the head of epididymis due to rupture of tubules
  - reactive tuberculoid granulomas around spermatozoa

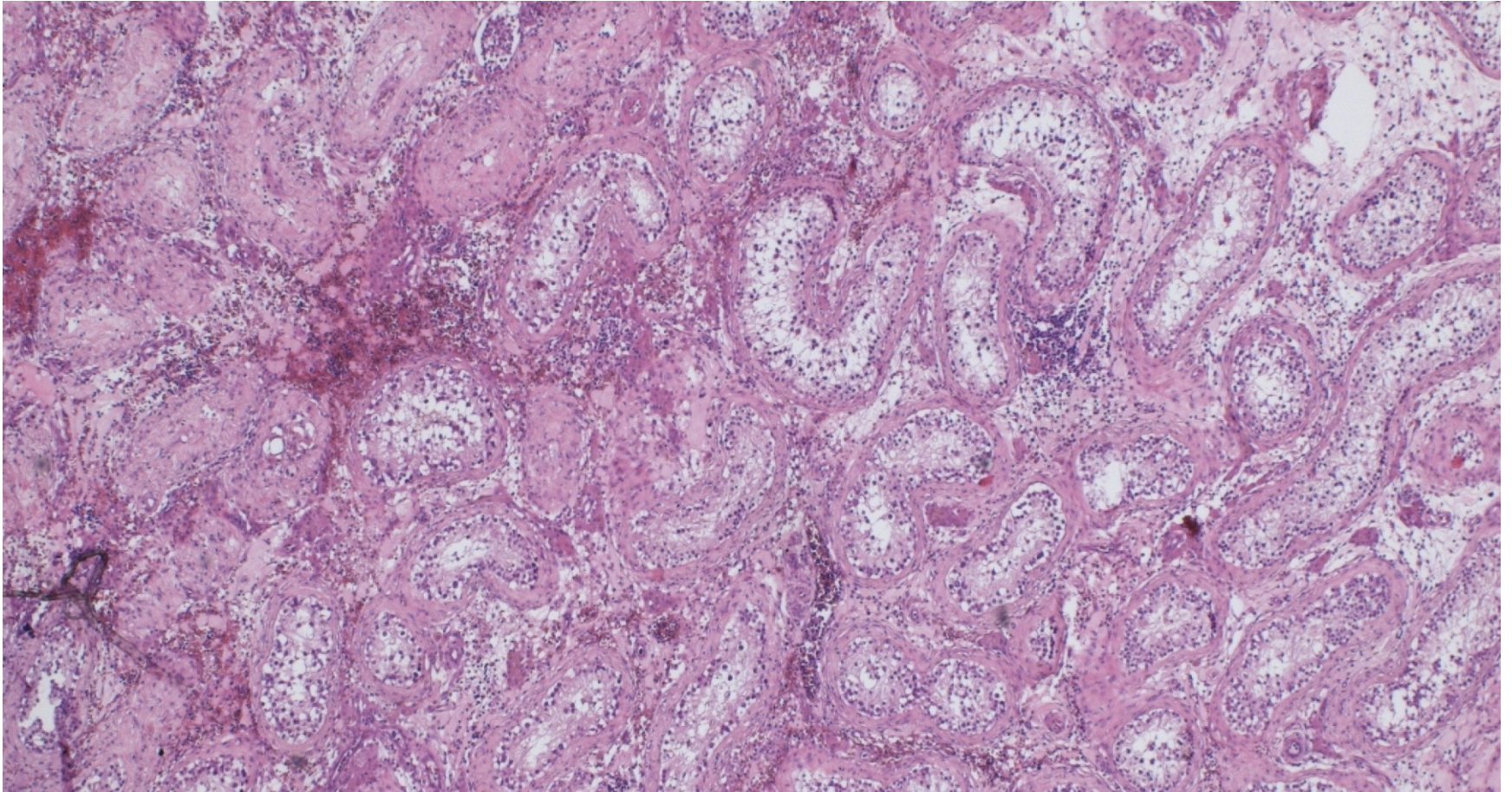
# Granulomatous orchitis



Tuberculoid granulomas.

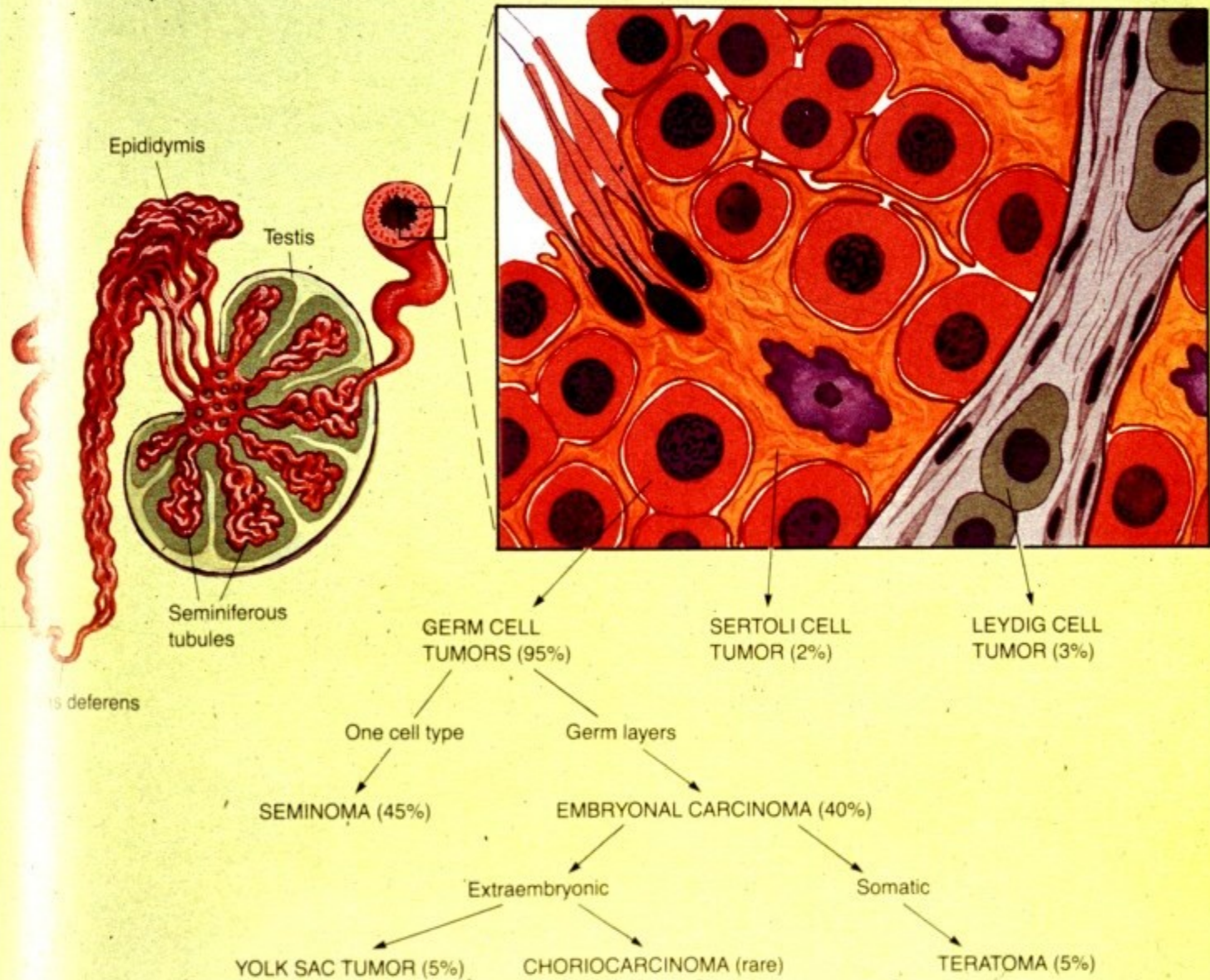


# Orchitis + atrophy





# Testicular tumors



# WHO pathologic classification of testicular tumors

## GERM CELL TUMORS

Derived from germ cell neoplasia in situ

**Tumors of one histologic pattern**

- Seminoma
- Embryonal carcinoma
- Yolk sac tumor (embryonal carcinoma, infantile type)
- Polyembryoma
- Choriocarcinoma



# GERM CELL TUMORS

## (cont.)

- Teratomas
- Mature
- Immature
- With malignant transformation

### **Tumors showing more than one histologic pattern**

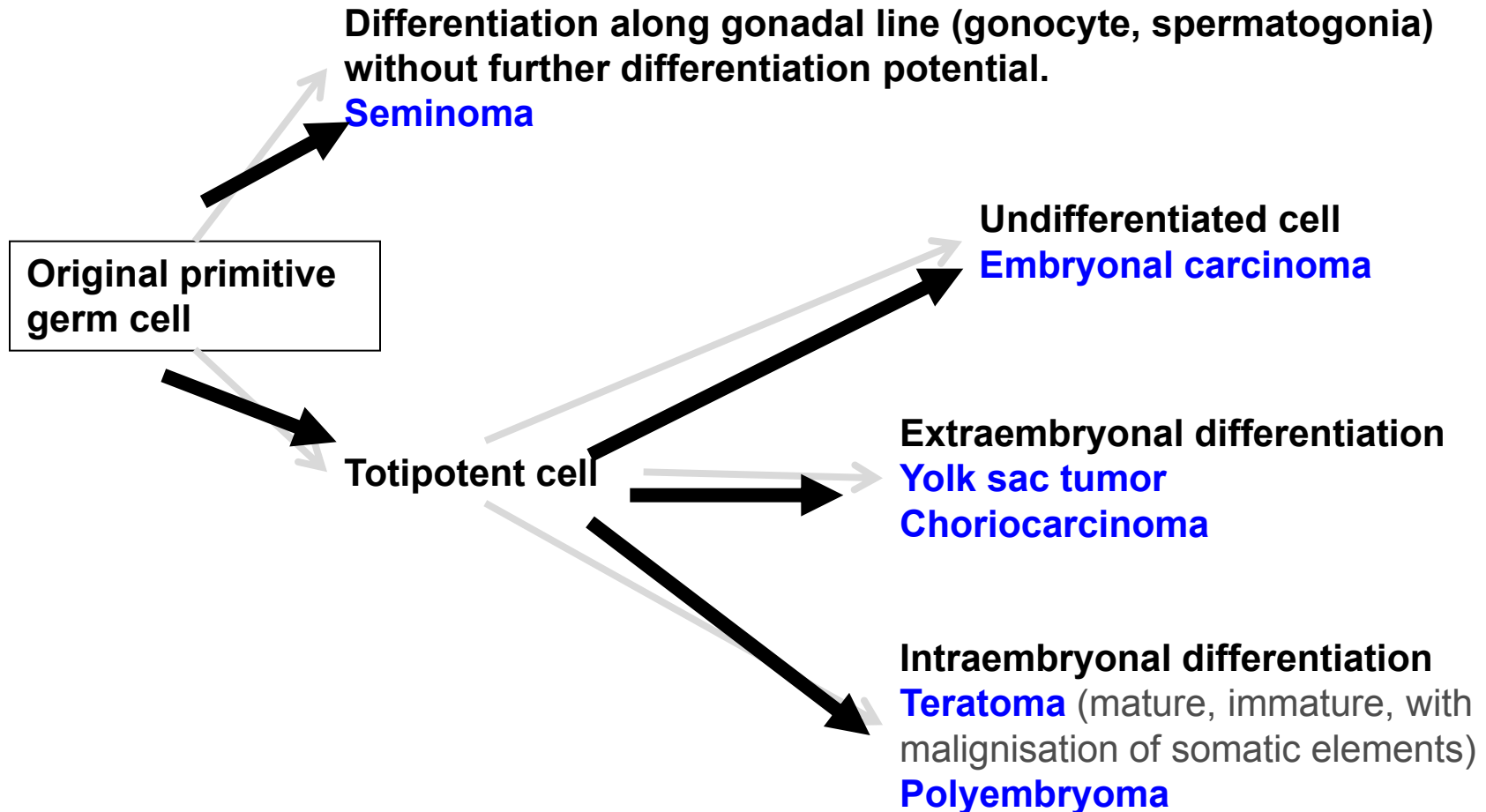
- Embryonal carcinoma + teratoma (teratocarcinoma)
- Choriocarcinoma + any other types
- Other combinations

# Germ cell tumors

Unrelated to germ cell neoplasia in situ

- Spermatocytic tumor (formerly spermatocytic seminoma)
- Teratoma, prepubertal type
- Yolk sac tumor, prepubertal type

# Germ cell tumors histogenesis





## SEX CORD-STROMAL TUMORS

- **Well-differentiated forms**
- **Mixed forms**
- Leydig cell tumor
- Sertoli cell tumor
- Granulosa cell tumor
- **Incompletely differentiated forms**

# Testicular tumors

- Other types

Neuroendocrine tumors

Haematopoietic neoplasms

Tumors of collecting ducts and rete testis  
(adenoma, carcinoma)

Tumors of paratesticular structures  
(mesothelial tumors, tumors of the  
epididymis, ...)

# Testicular tumors

## Clinical features

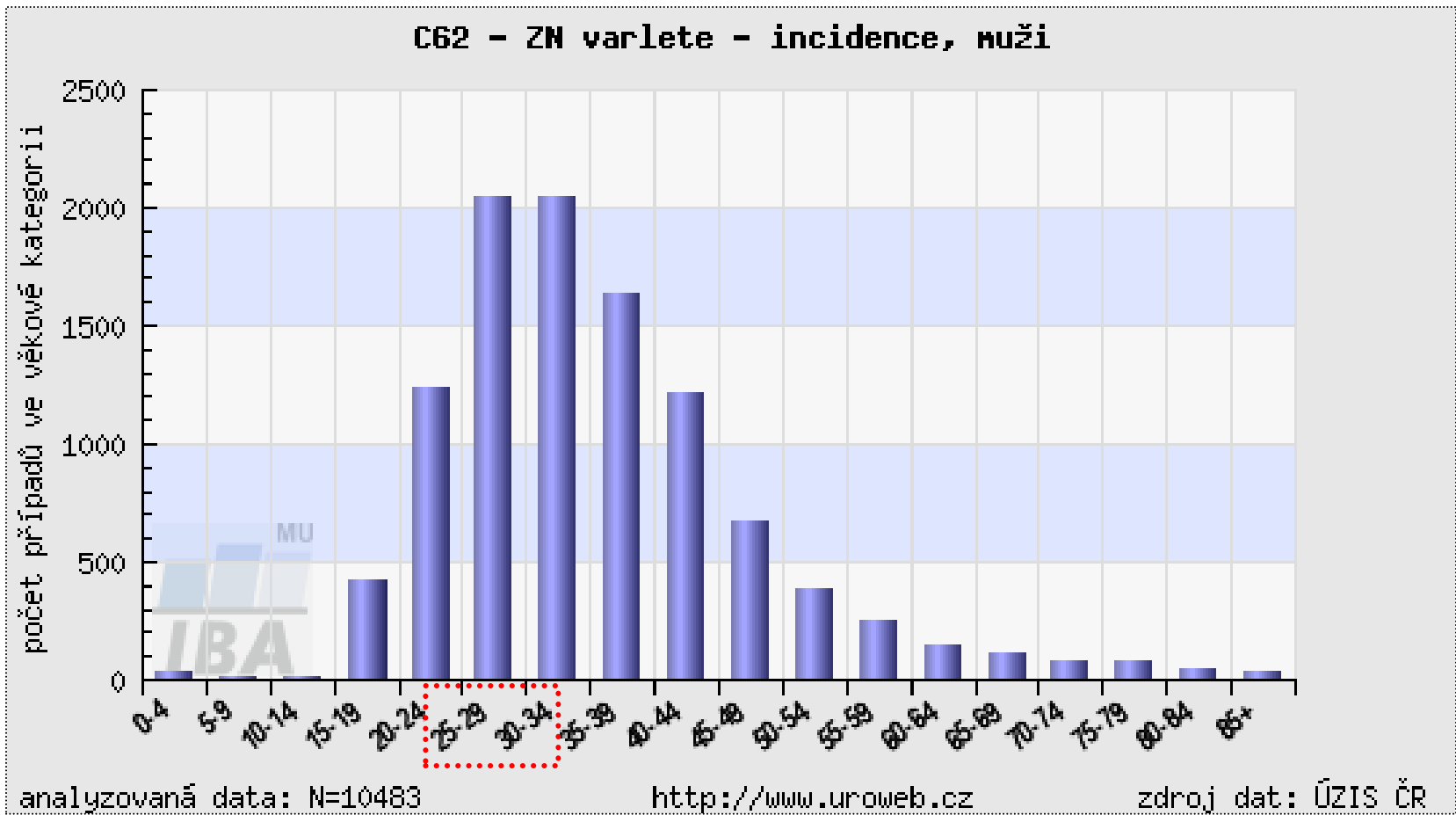
- painless unilateral enlargement of testis
- secondary hydrocele
- symptoms from metastases
- retroperitoneal mass
- gynaecomastia



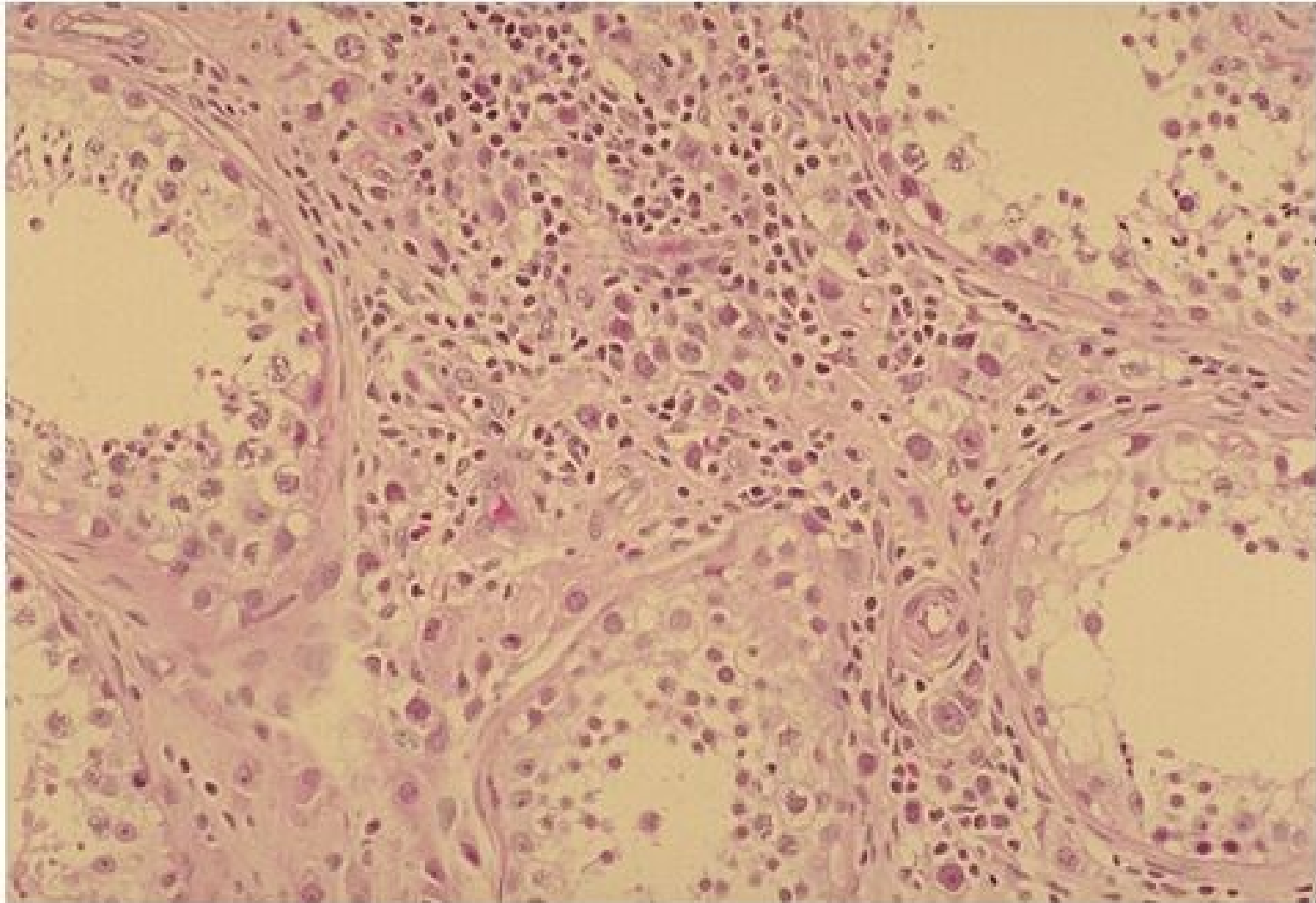
# Testicular tumors : histopathological report

- gross picture (incl. size)
- histological type
- presence of vascular / lymphatic propagation
- tumor staging (TNM classification)
- presence of intratubular germ cell neoplasia (ITGCN - in situ germ cell lesion)

# Age structure of testicular tumors patients

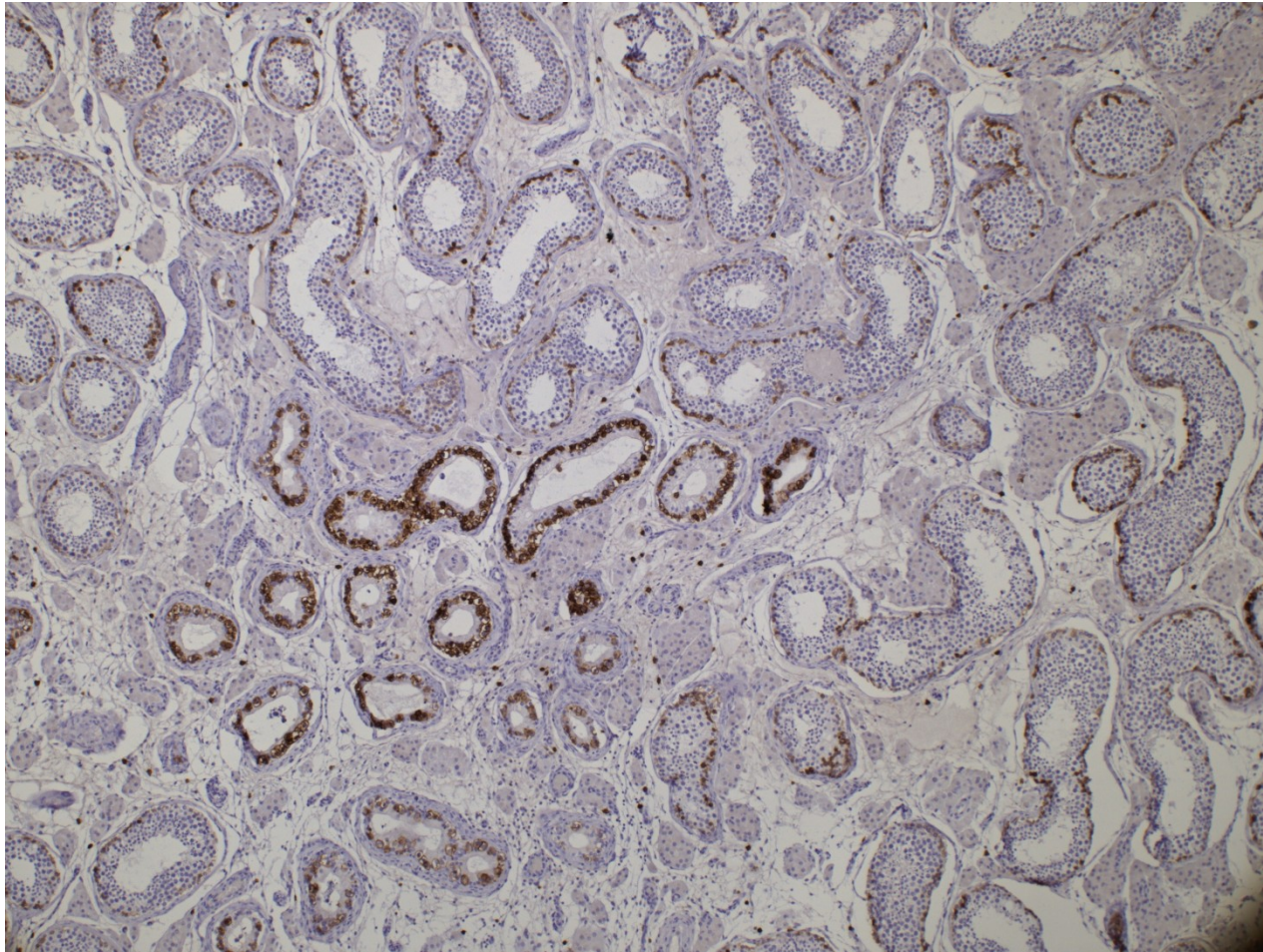


# Germ cell neoplasia in situ



Copyright © 2002, Elsevier Science (USA). All rights reserved.

# Germ cell neoplasia in situ - IHC

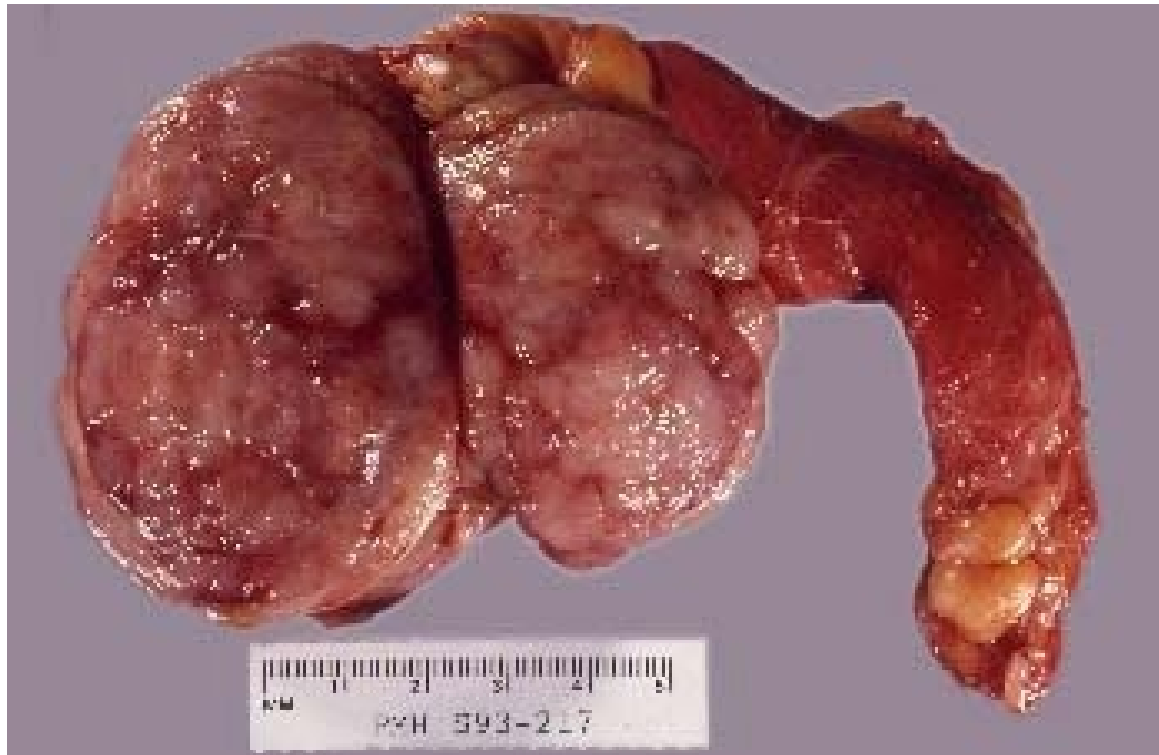



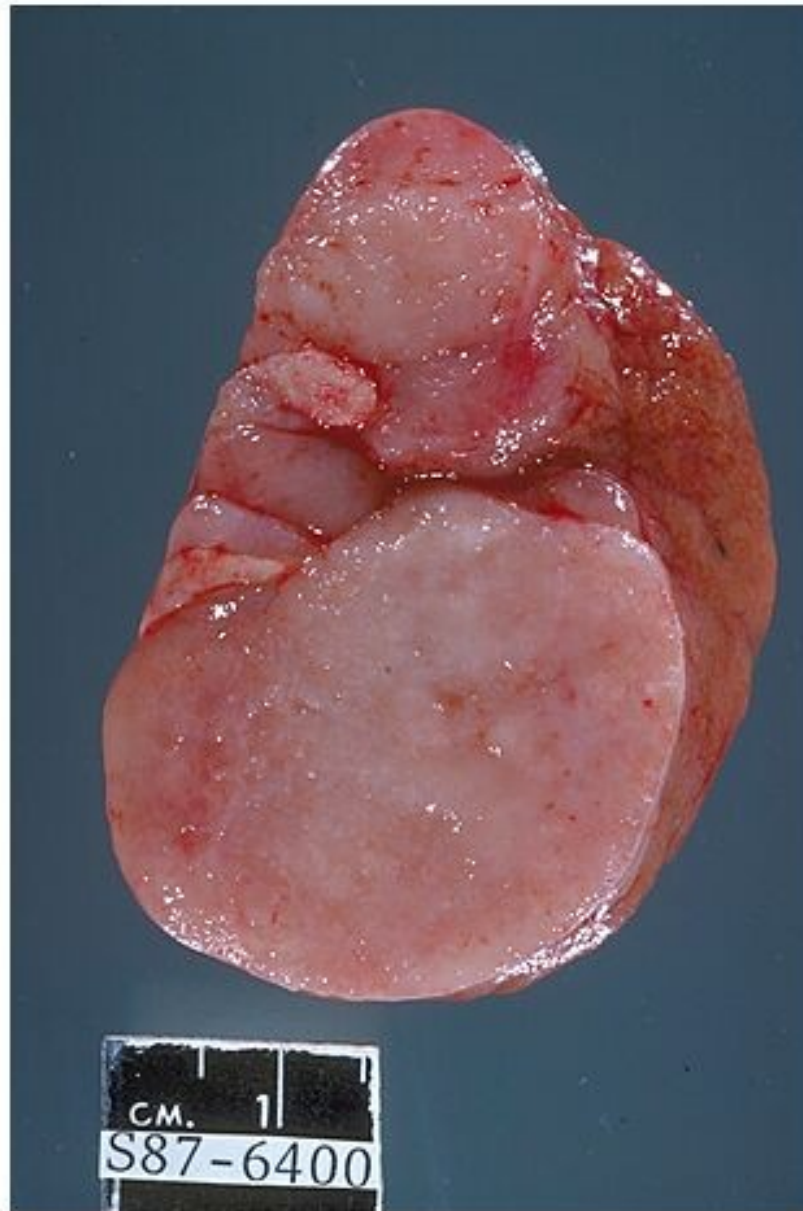
# Seminoma

- most common
- peak in 4th decade, not in infants
- gross: homogenous, greyish
- micro: large cells, clear cytoplasm, hyperchromatic nucleus
- stroma with lymphocytic reaction, granulomas possible
- good prognosis usual

# Seminoma

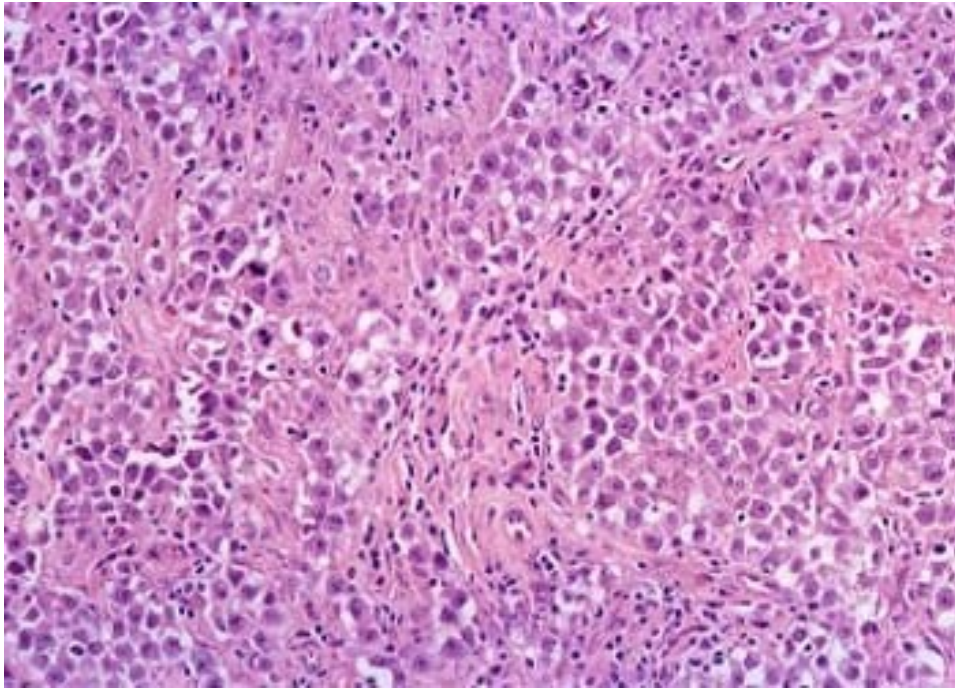


# Seminoma



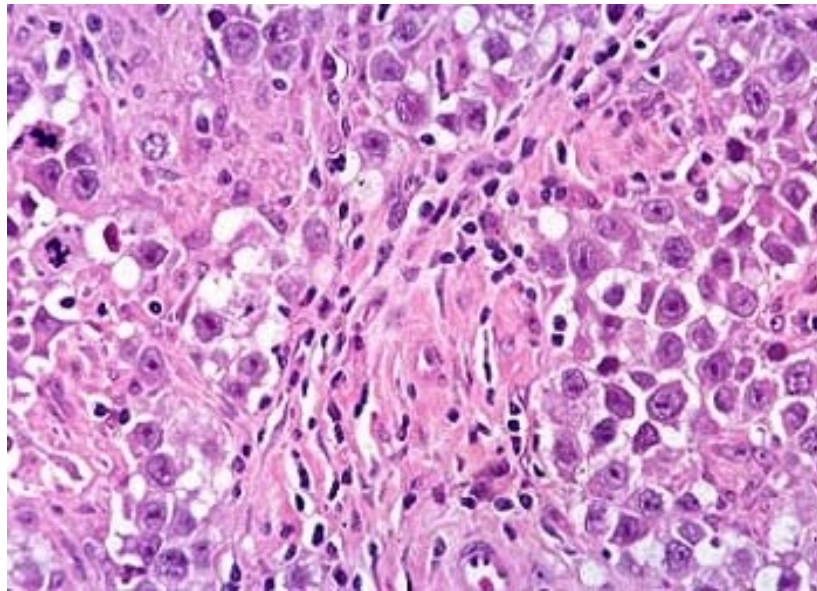
Copyright © 2002, Elsevier Science (USA). All rights reserved.

# Seminoma

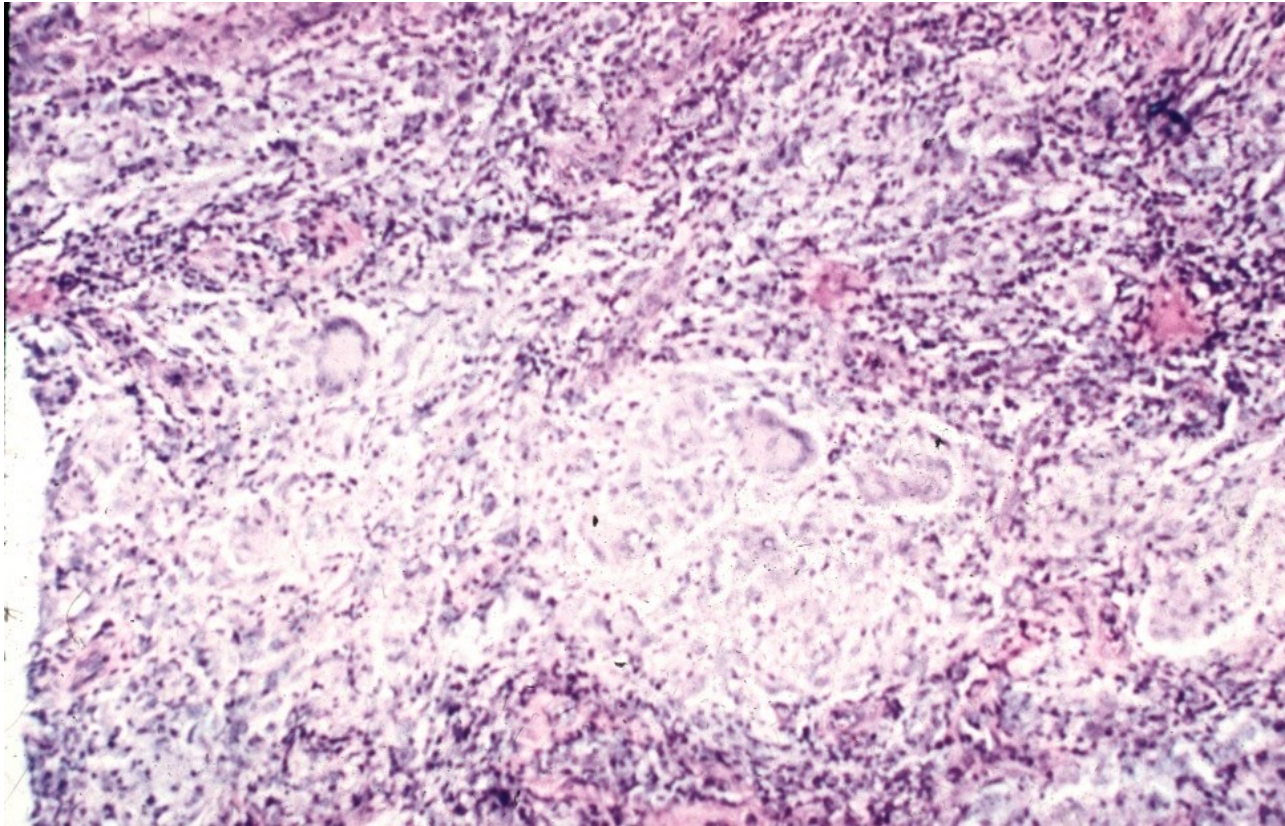




# Seminoma



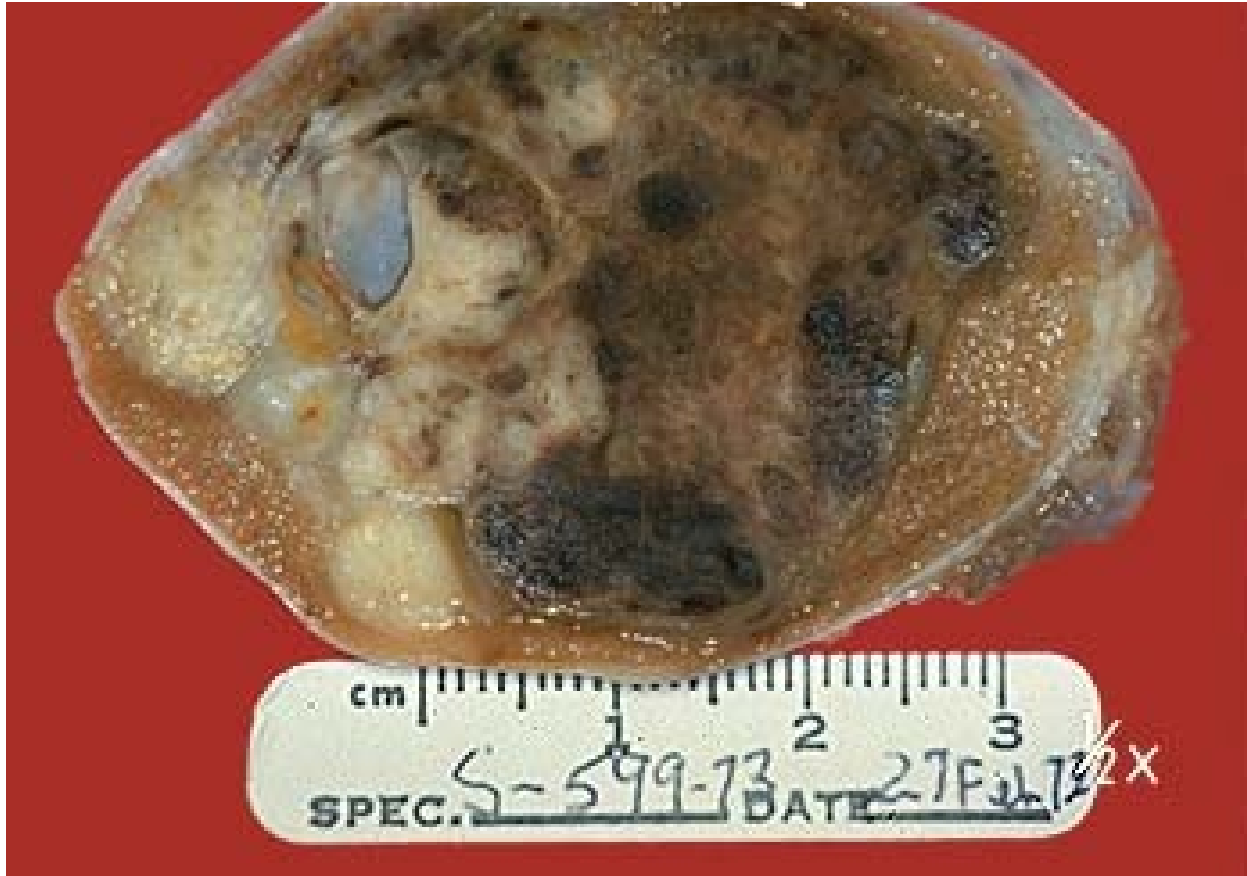# Seminoma



# Embryonal carcinoma

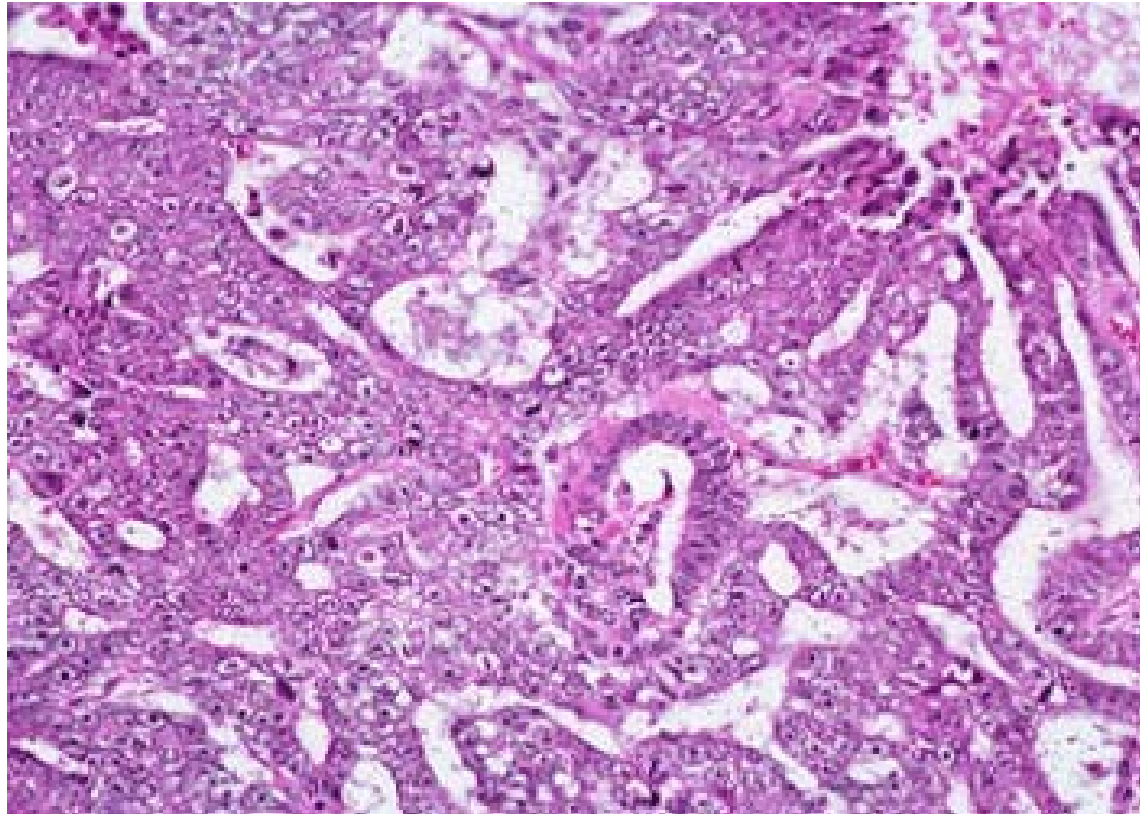
- mostly 20-30 yrs
- gross: variable, haemorrhage, necrosis
- micro: organoid glandular, trabecular formations
- large anaplastic cells

# Embryonal carcinoma

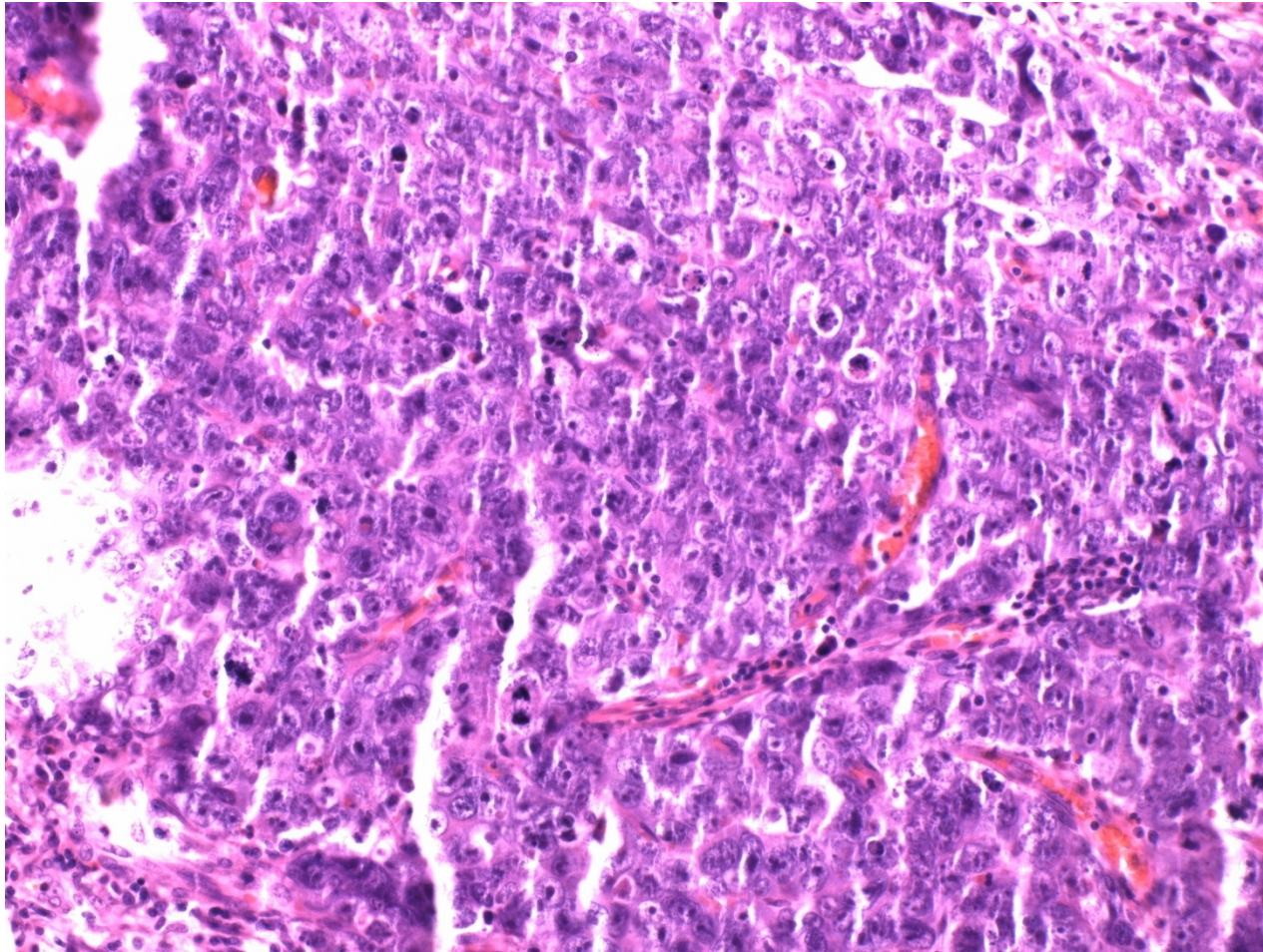




# Embryonal carcinoma



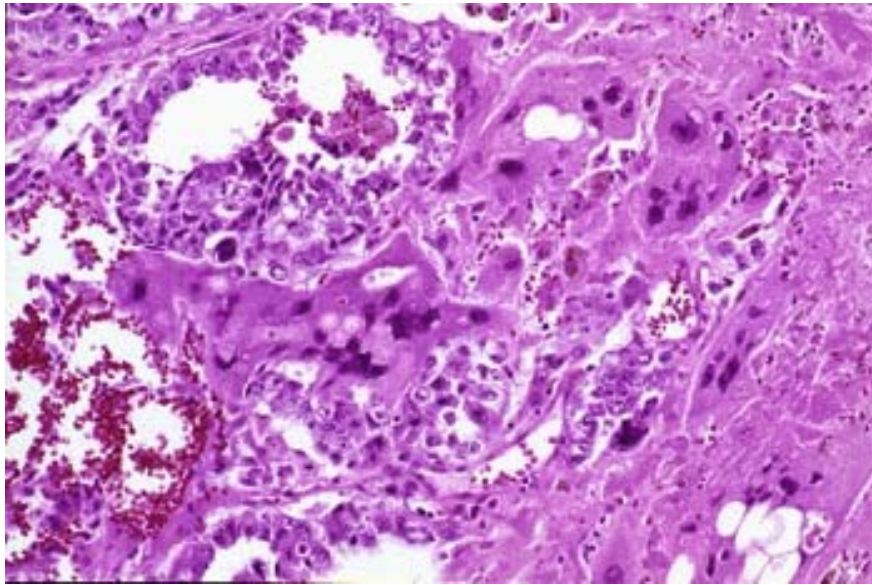
# Embryonal carcinoma



# Choriocarcinoma

- similar to gestational chca
- pure very rare, common admixture
- HCG production (! disperse trofoblastic cells possible in seminoma)
- extensive haemorrhage
- cyto- + syncytiotrophoblast

# Choriocarcinoma

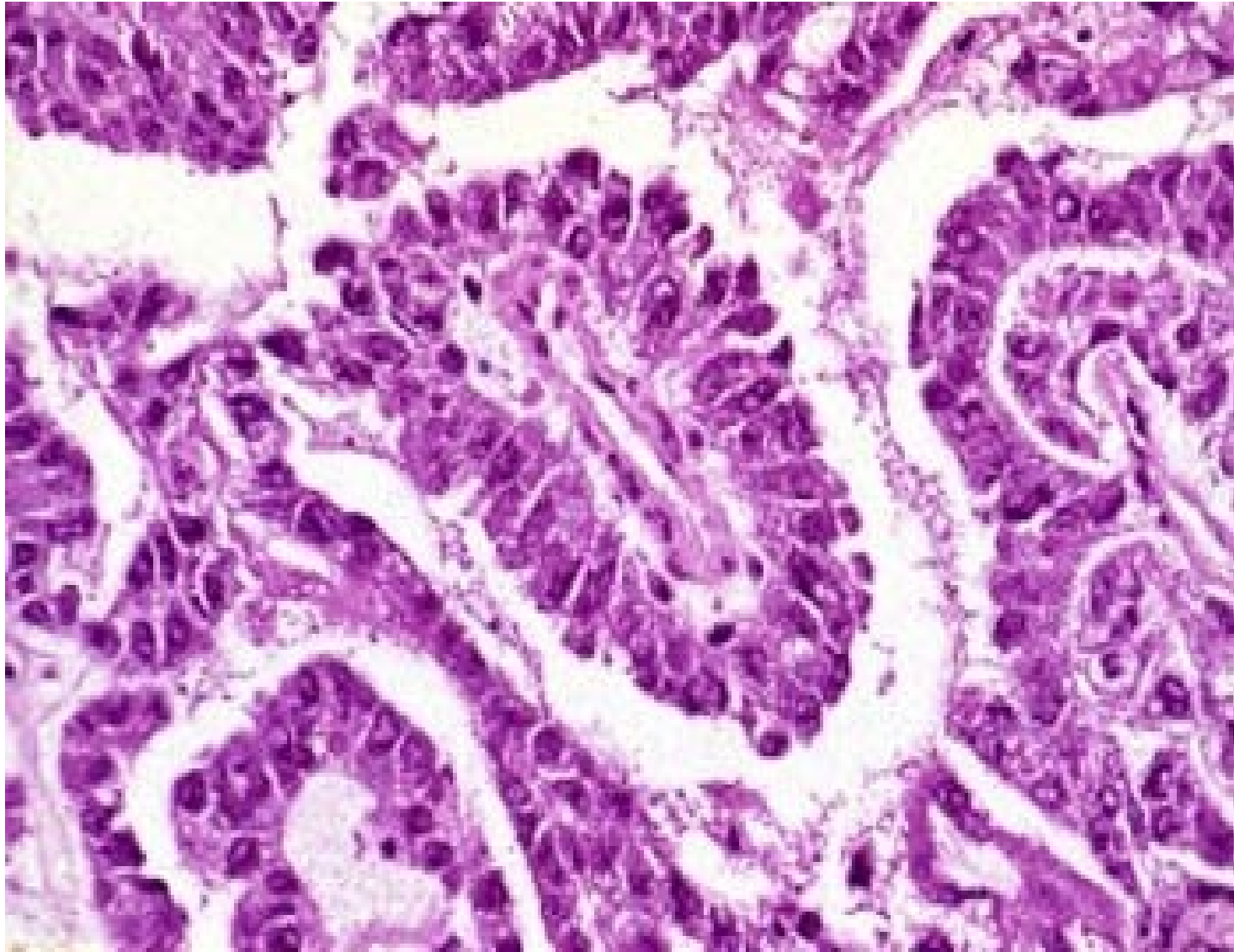




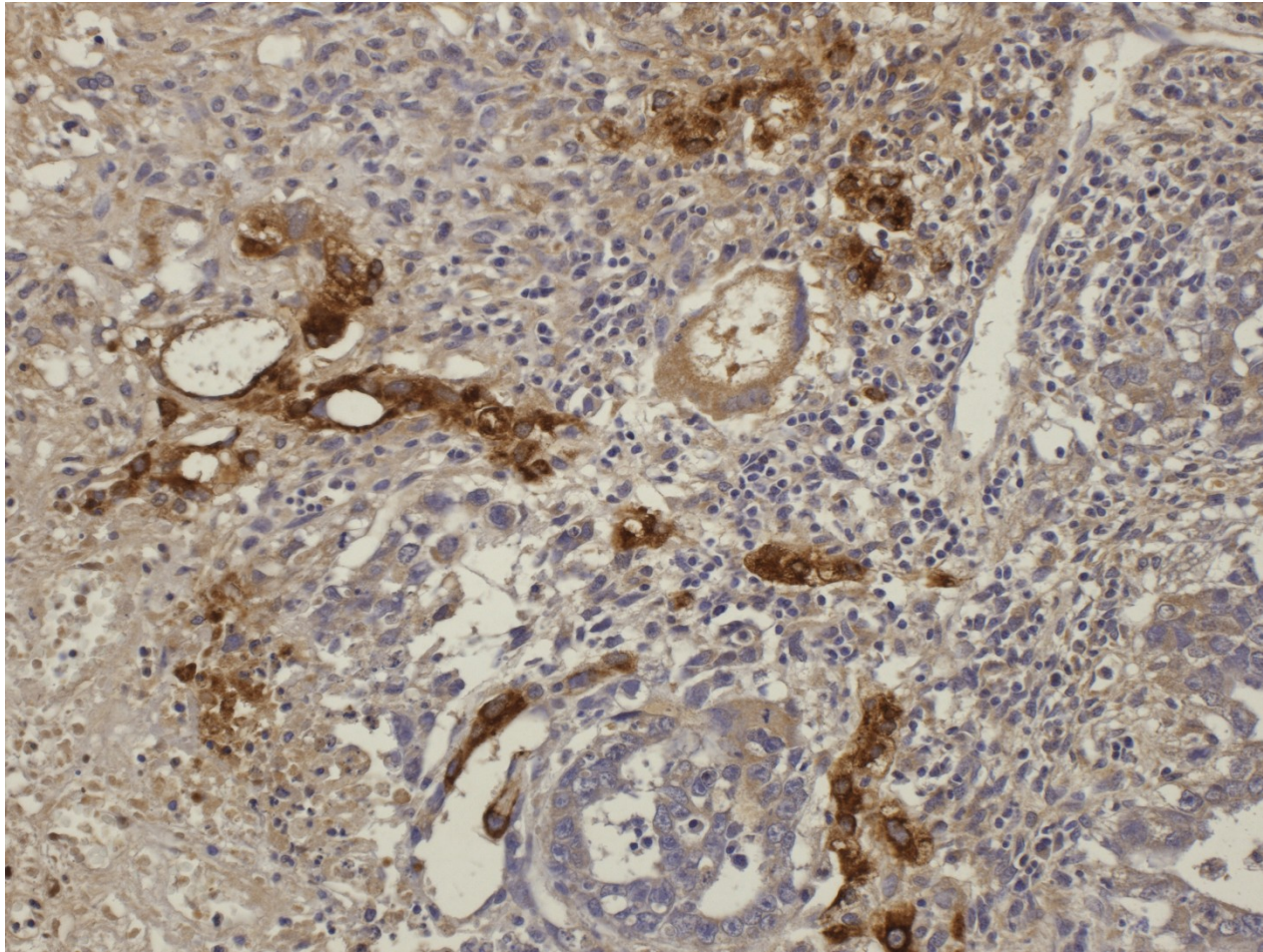
# Yolk sac tumor

- Pure: most common testicular tu in children < 3 yrs
- Common part of mixed germ cell tumors
- AFP production
- variable histology – microcystic, reticular, papillary formation, variable patterns
  - glomeruloid structures (Schiller-Duval bodies)
    - stalk with capillary lined on the surface by layer of tumor cells

# Yolk sac tumor



# Yolk sac tumor – AFP IHC



# Teratoma

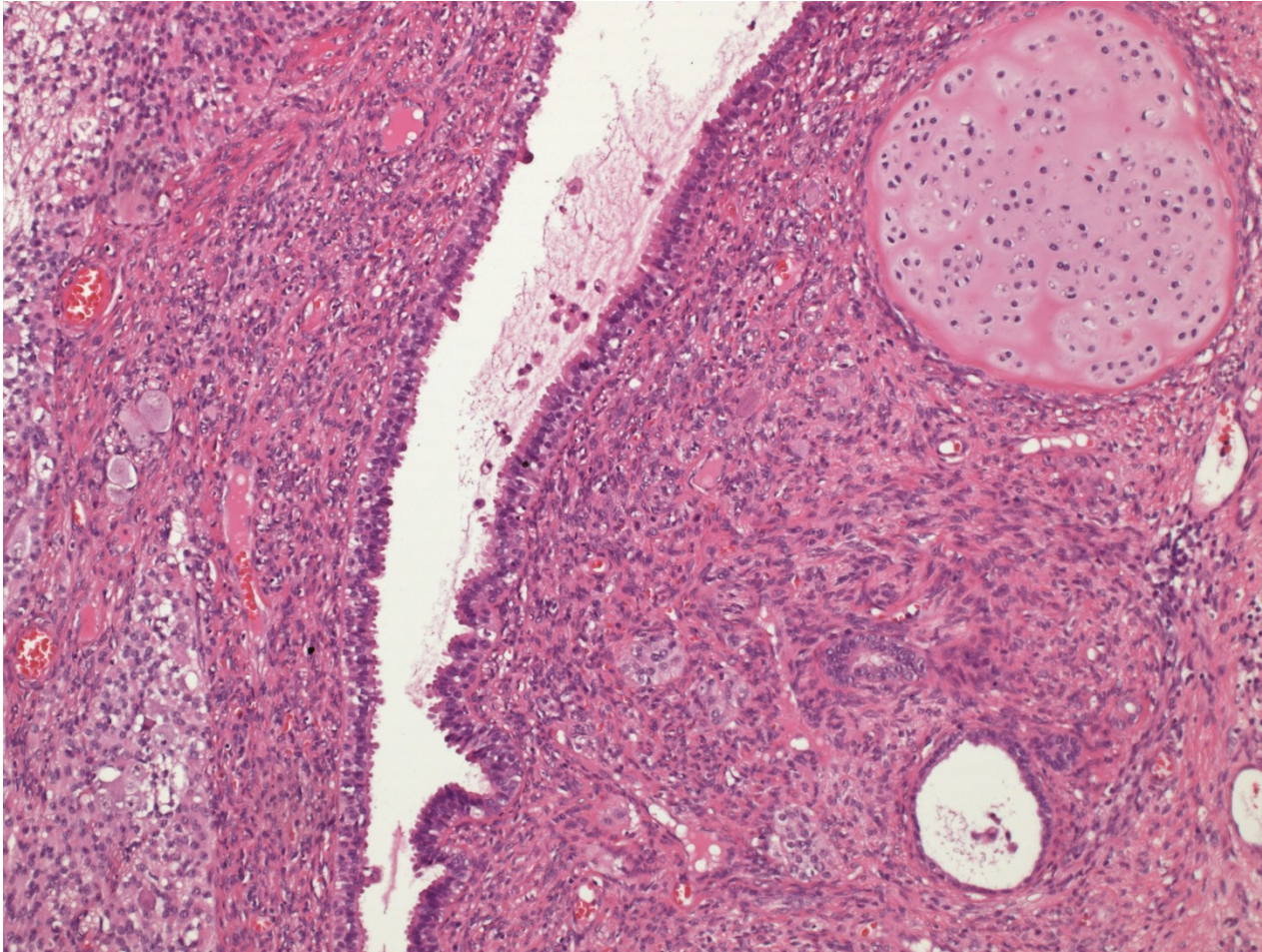
- variable components: ecto-, meso-  
endoderm (intraembryonal)
- commonly glandular + squamous  
epithelium
- mesenchymal tissues incl. cartilage
- in males usually immature, component of  
mixed germinal tu (x females)



# Teratoma

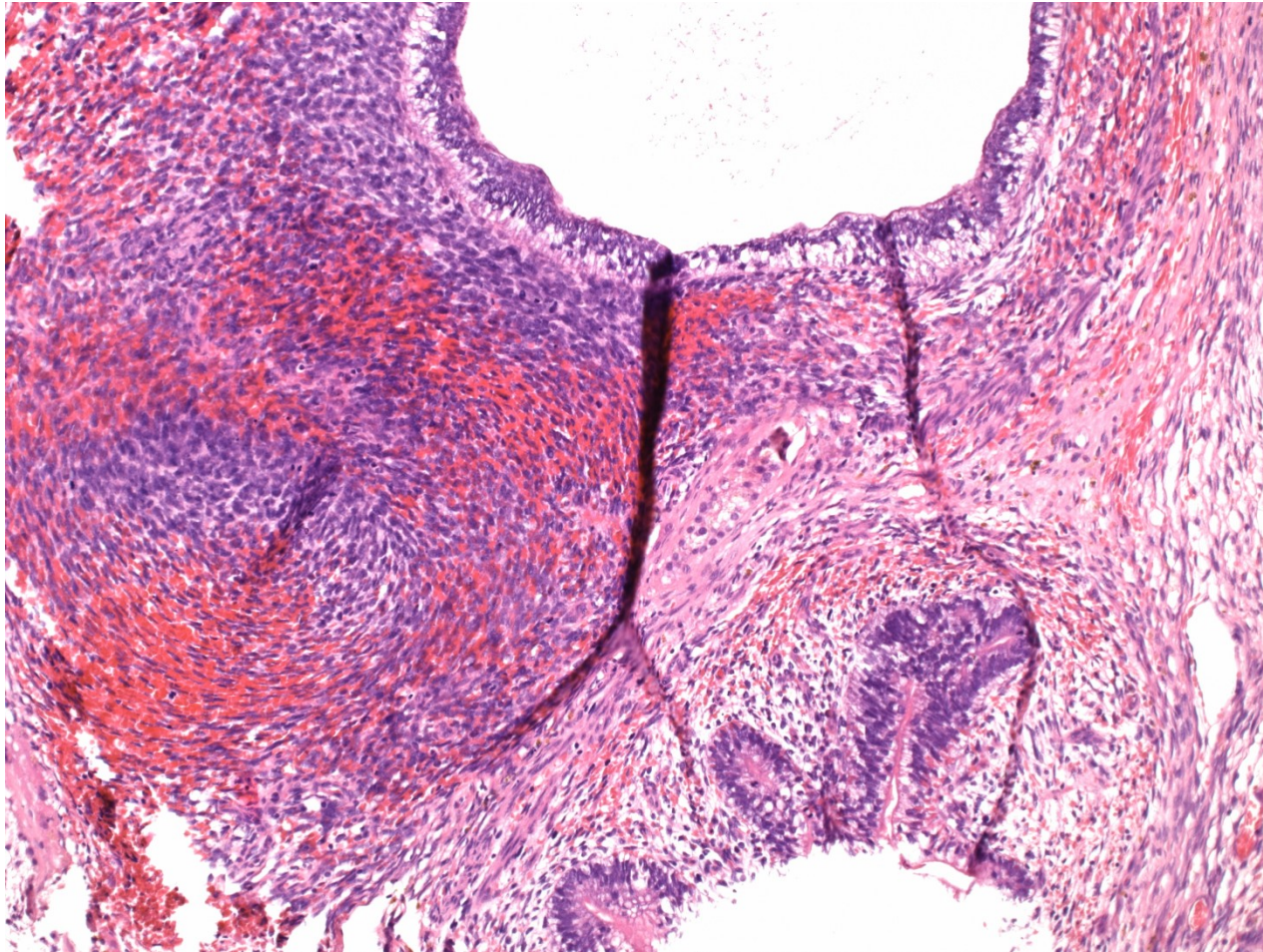
- histologic classification
  - differentiated mature t.
    - completely matured tissues with organoid structure
    - commonly cystic, containing serous fluid, mucus, keratin
  - differentiated immature t.
    - immature tissues of embryonal/fetal appearance (neuroectoderm, mesenchyme)
  - t. with somatic type malignancy
    - sarcoma, carcinoma, PNET, neuroblastoma

# Teratoma



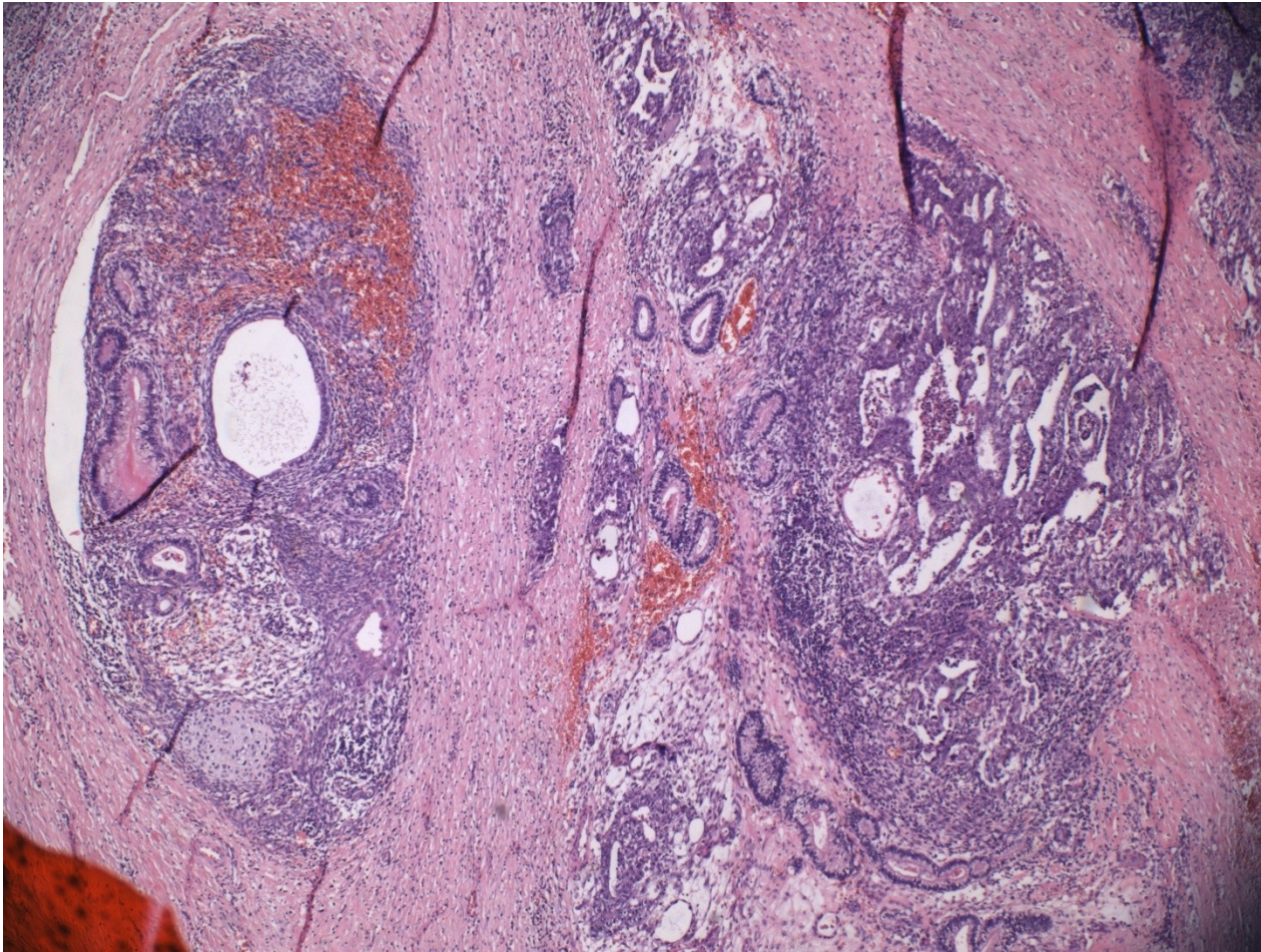


# Teratoma



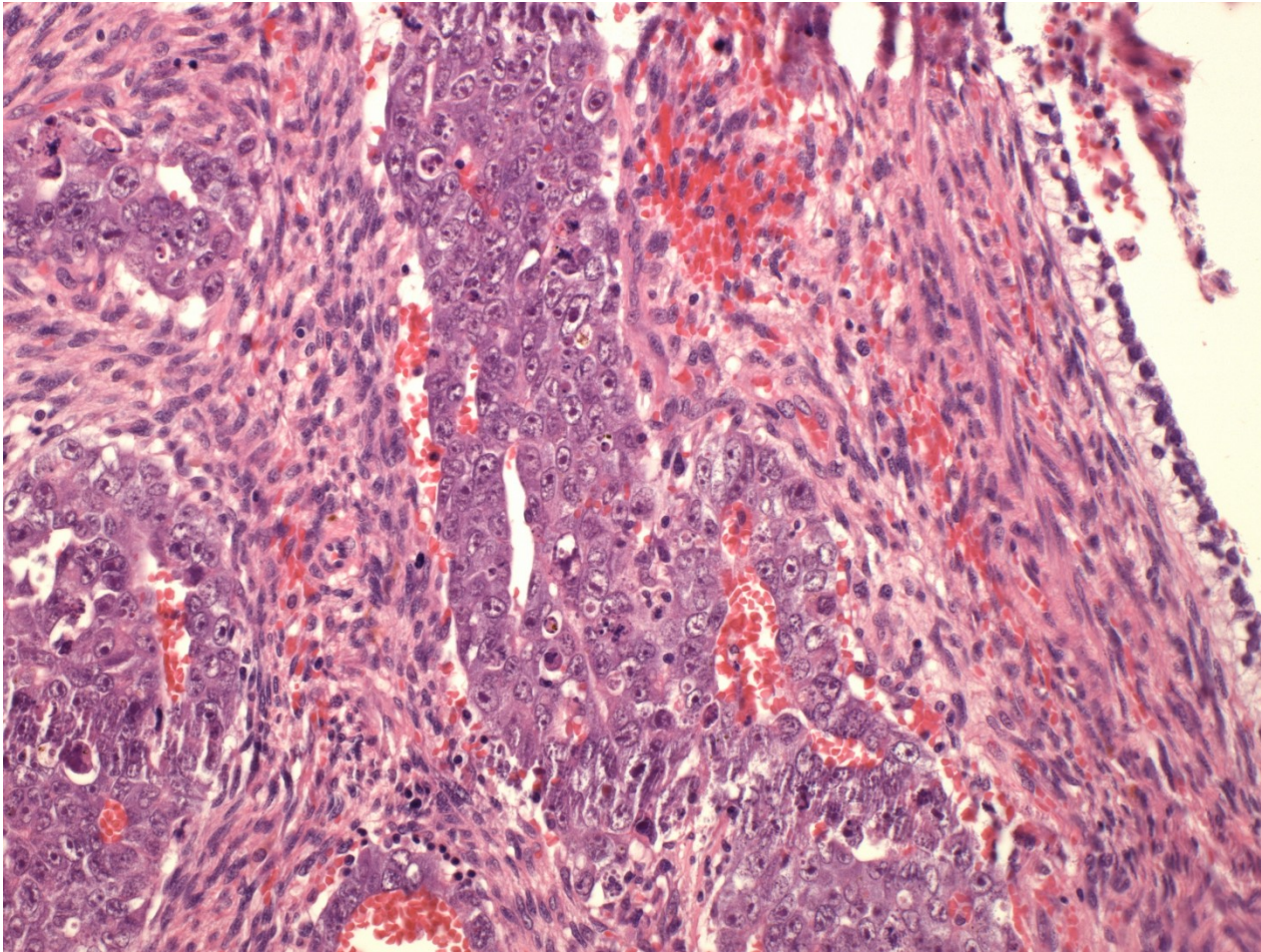


# Teratoma + embryonal ca

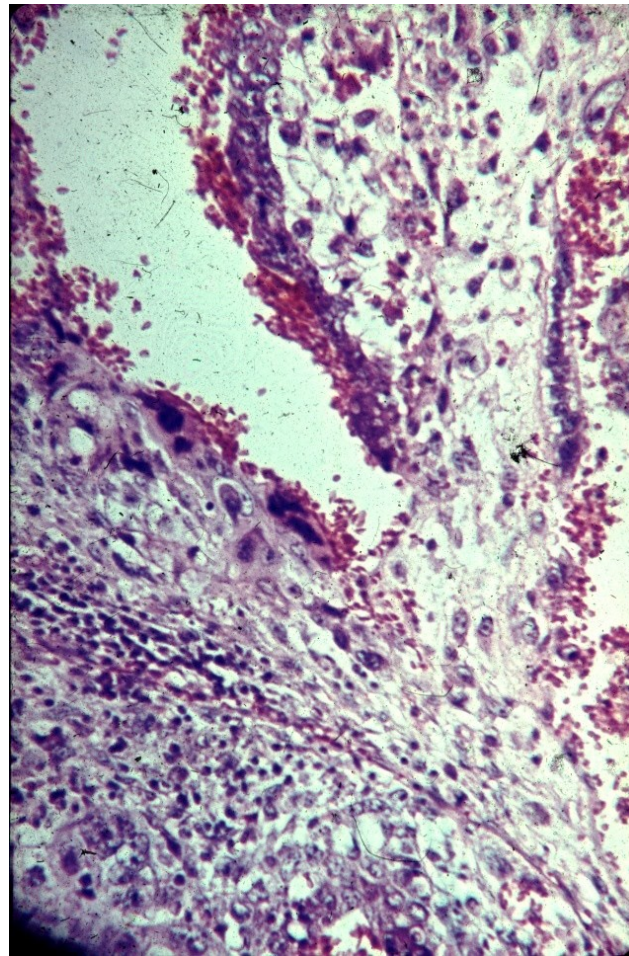




# Teratoma + embryonal ca

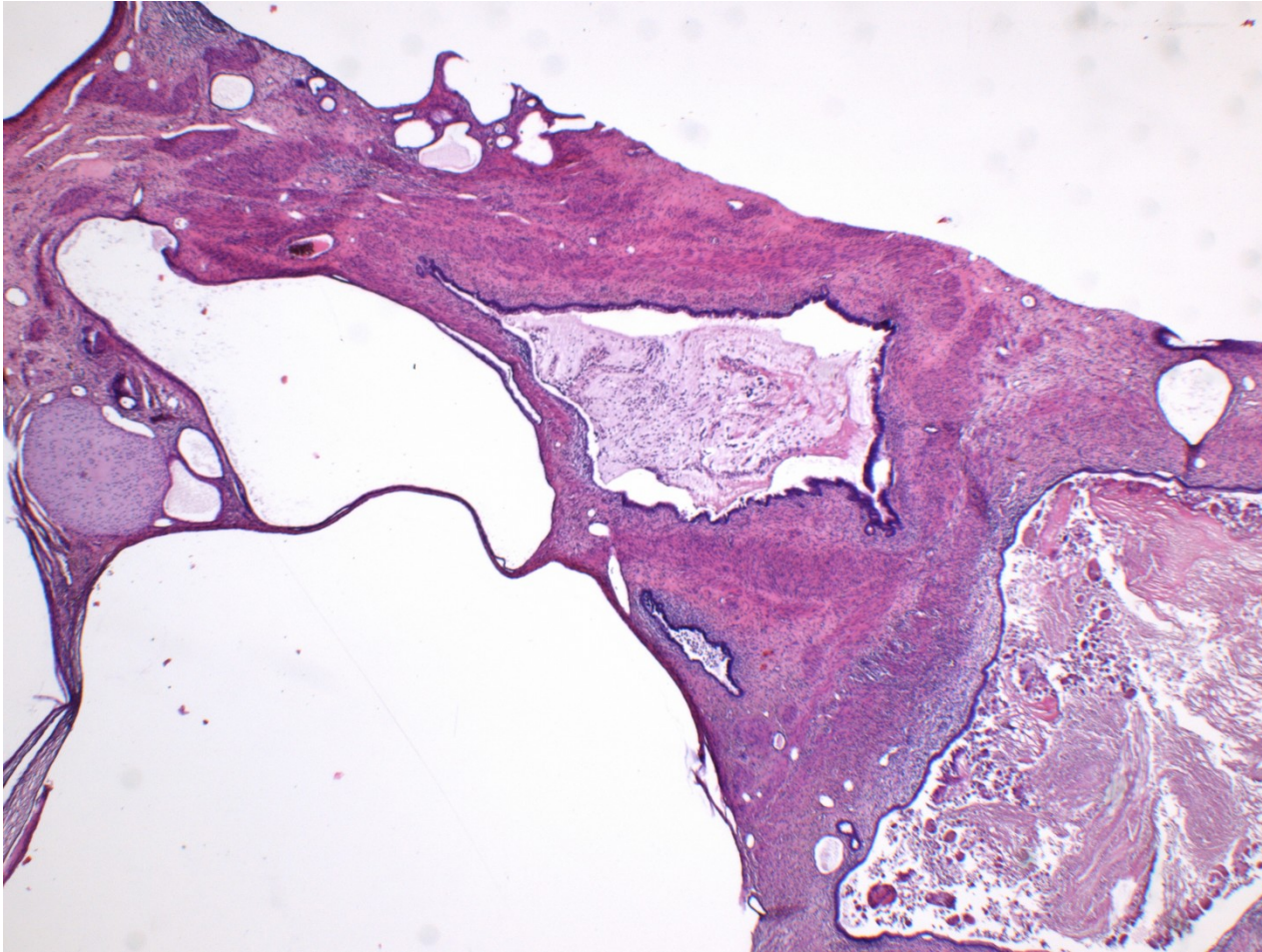


# Teratoma + choriocarcinoma

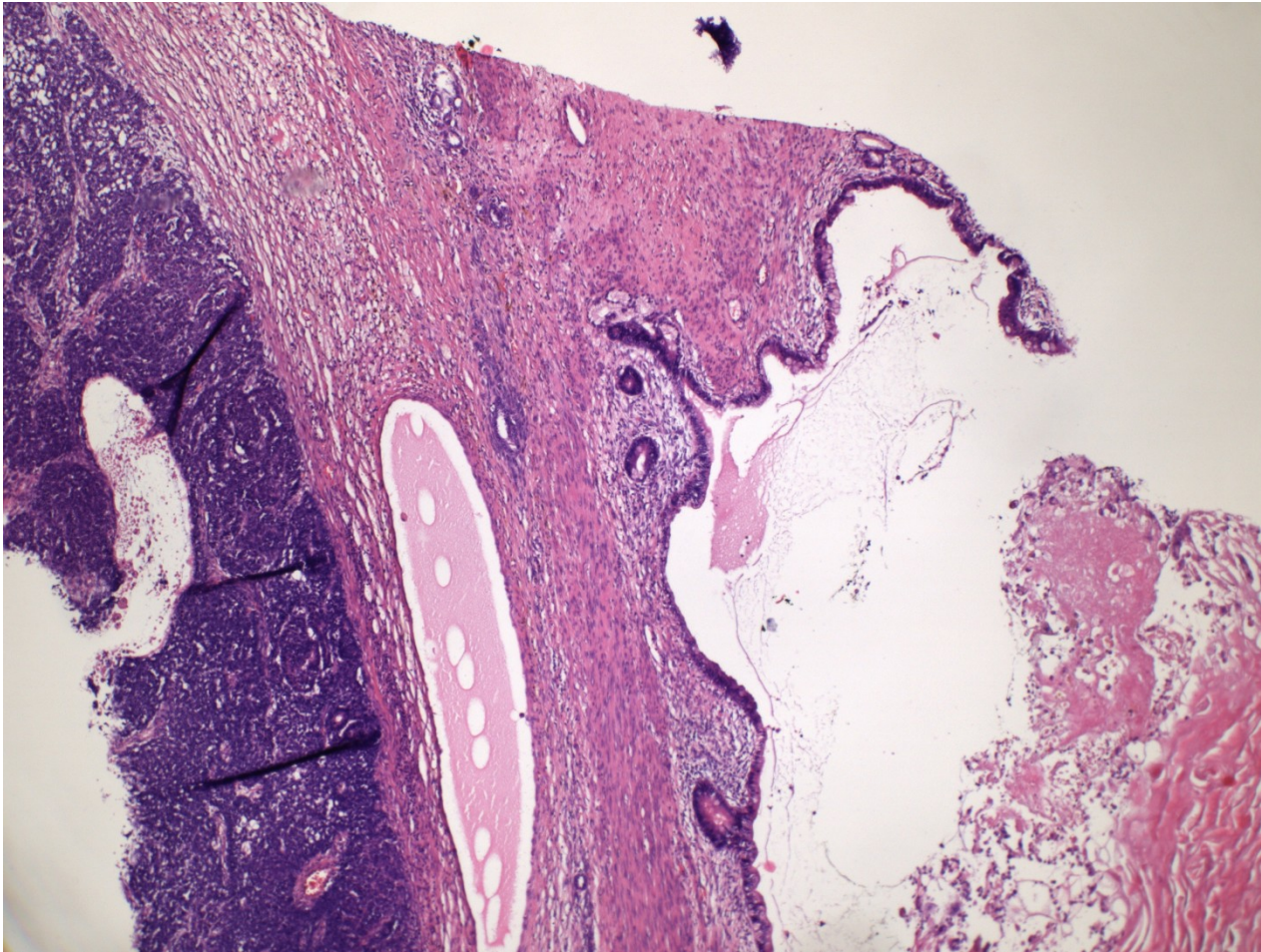




# Teratoma – meta in lungs



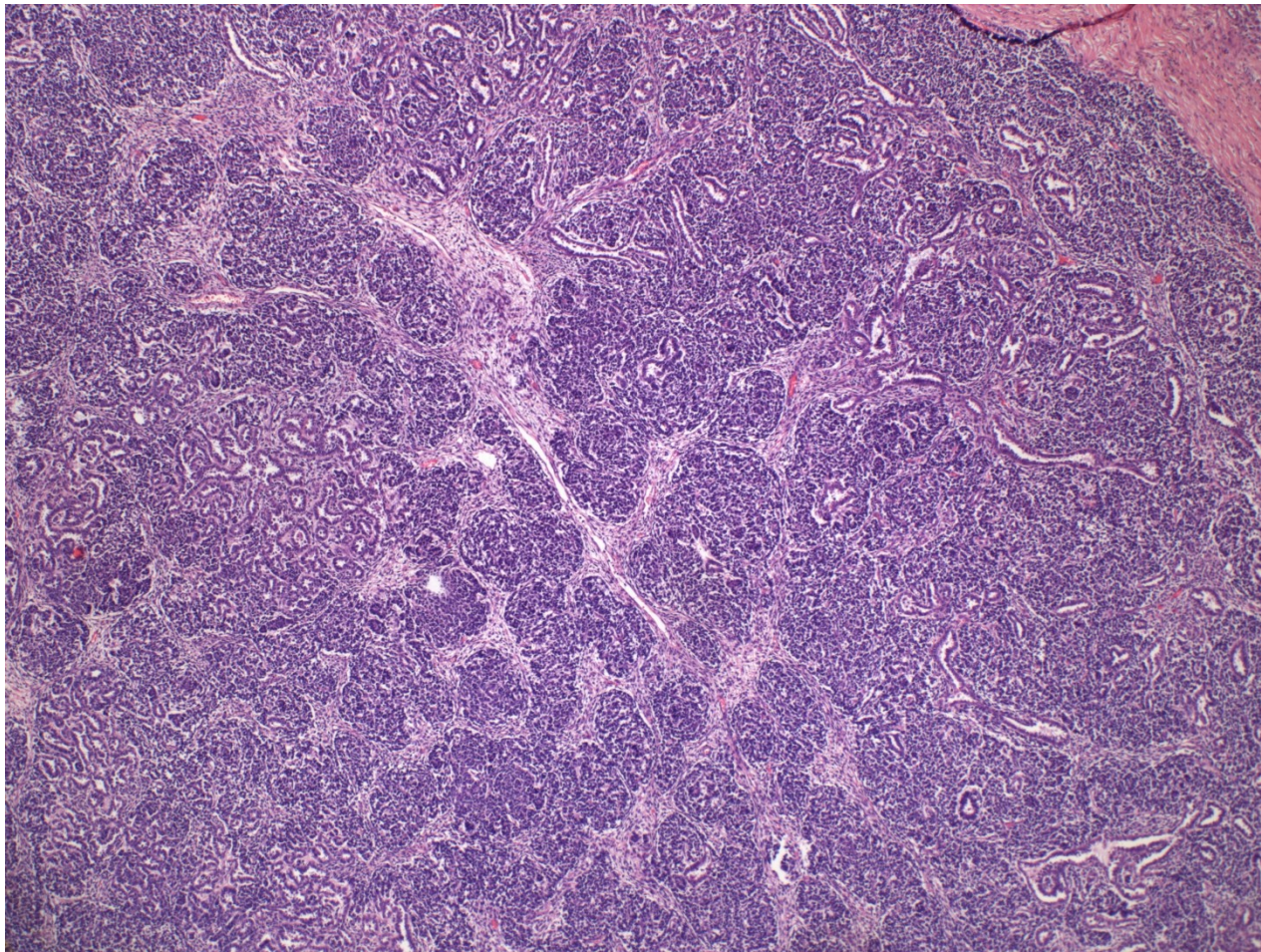
# Teratoma – meta in lungs





# Teratoma w. somatic malignancy

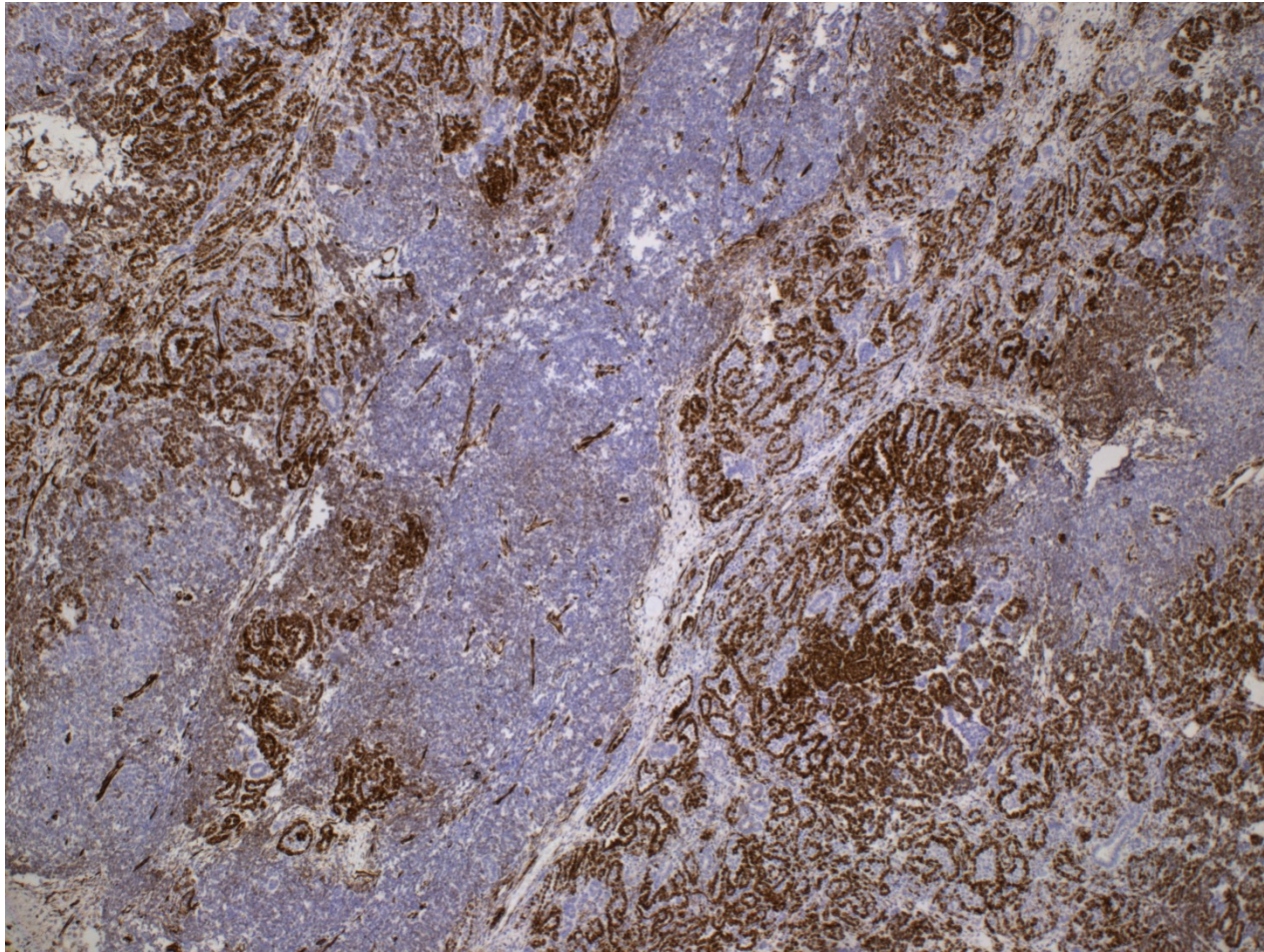
nephroblastoma





# Teratoma w. somatic malignancy

nephroblastoma



# Germ cell tumors

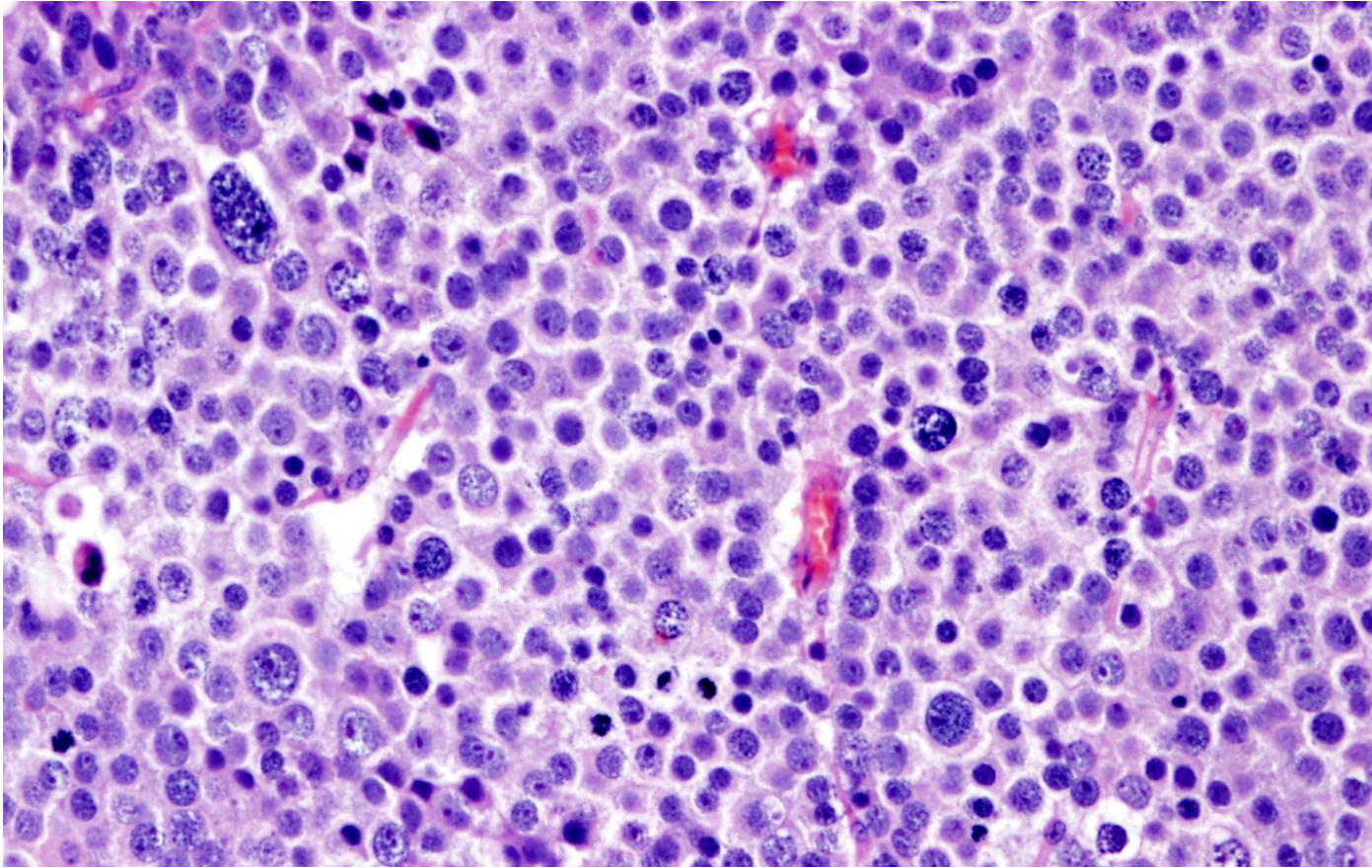
- lymphatic spread common (paraaortic LN)
- hematogenous possible, esp. in non-seminomatous (lungs, bones, liver, brain)
- different histology in metastasis possible
- scarring of the primary tumor possible (burn-out tumor) – diff. dg. x other primary localization

# Spermatocytic tumor

- unrelated to germ cell neoplasia in situ
- usual age > 65 yrs
- slow growth, rare metastasis
- more pleiomorphic cells – variable stages of differentiation
- no stromal reaction



# Spermatocytic tumor



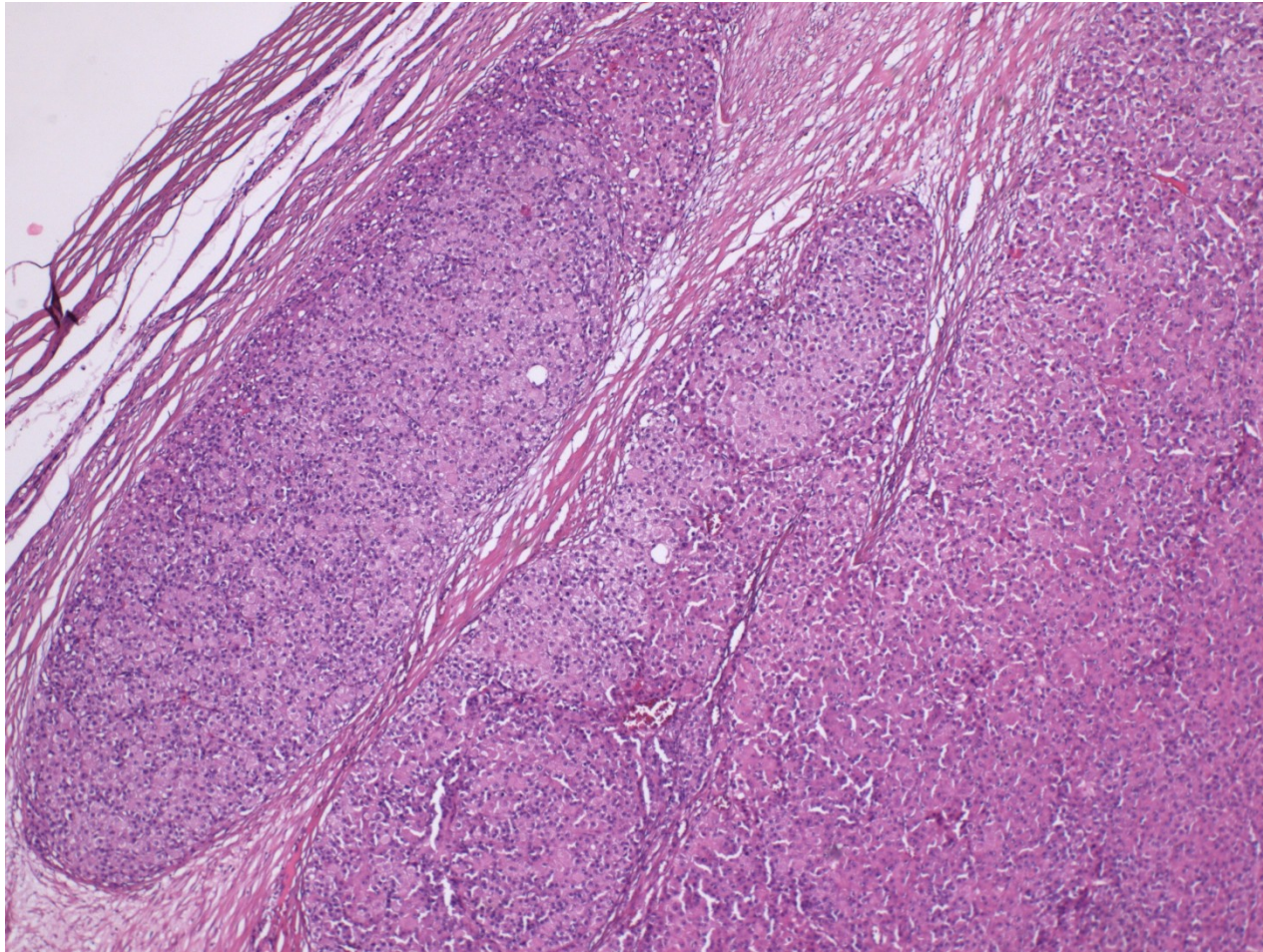
Mixture of polymorphic tumor cells (~ early stages of spermatogenesis): large cells with lacy chromatin, middle-sized cells with round nuclei, small lymphocyte-like cells.  
Fibrotic septa without lymphocytic infiltrate

# Sex cord-stromal tumors

- less common than germ cell tu
- Leydig cell tumor
  - any age, peak middle age
  - androgen secreting cells – clinical signs incl. precocious puberty
  - benign or malignant, similar histology
- Sertoli cell tumors
  - very uncommon, mostly benign



# Malignant Leydig cell tumor

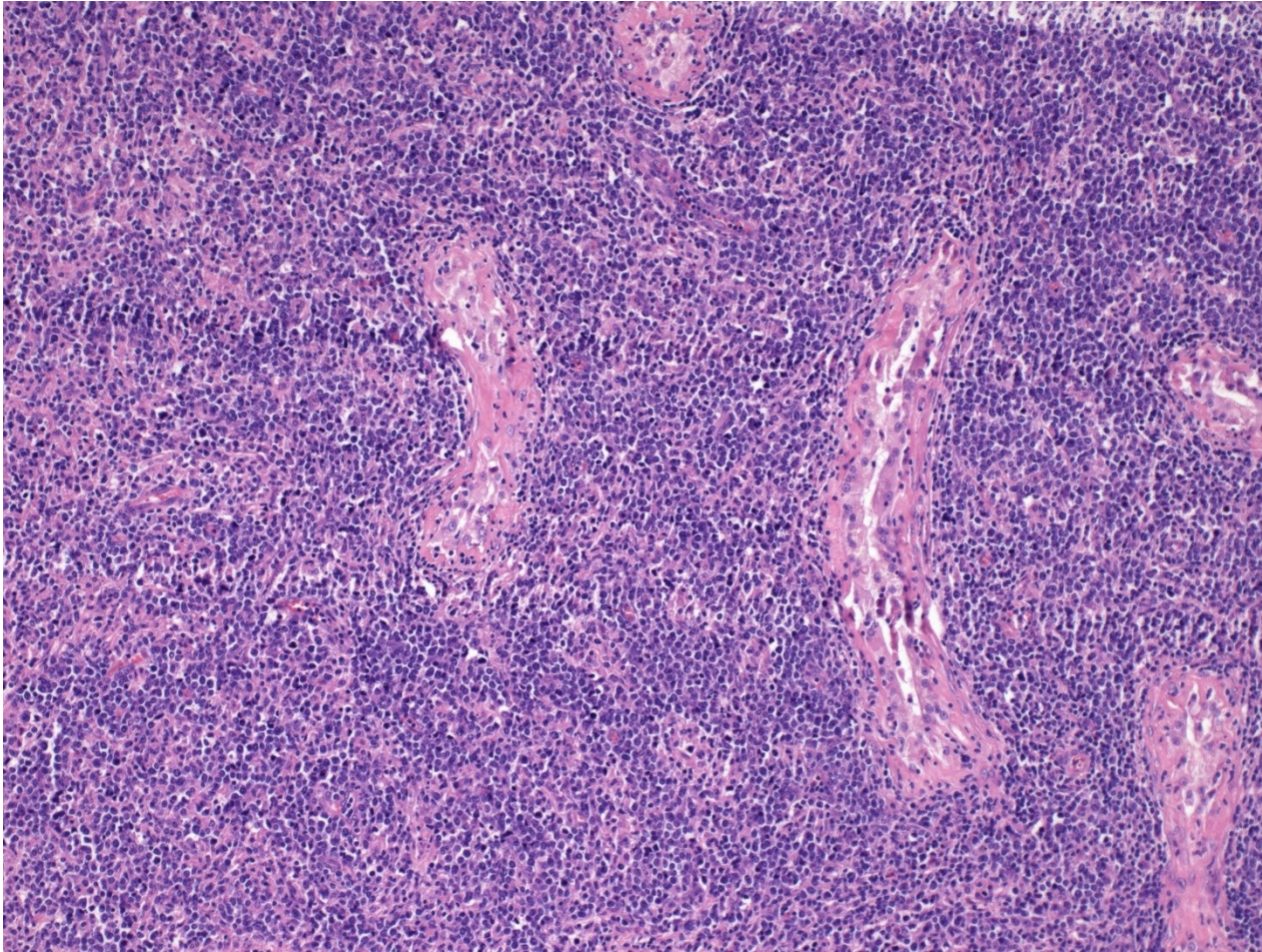


# Other testicular tumors

- primary malignant lymphoma
  - older males, in this age ML more common than germ cell tu
  - commonly DLBCL
  - may be already systemic

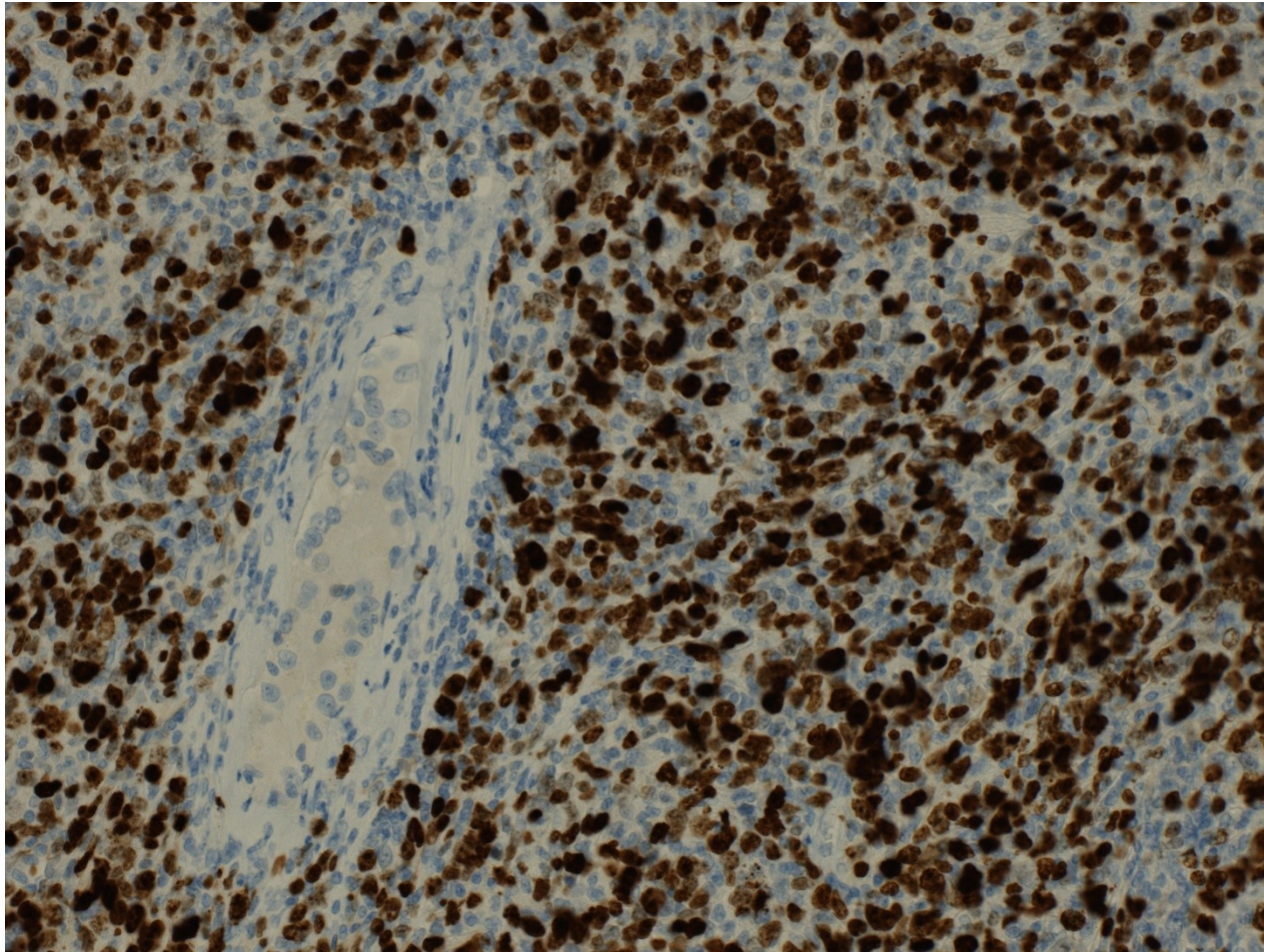


# Testicular DLBCL



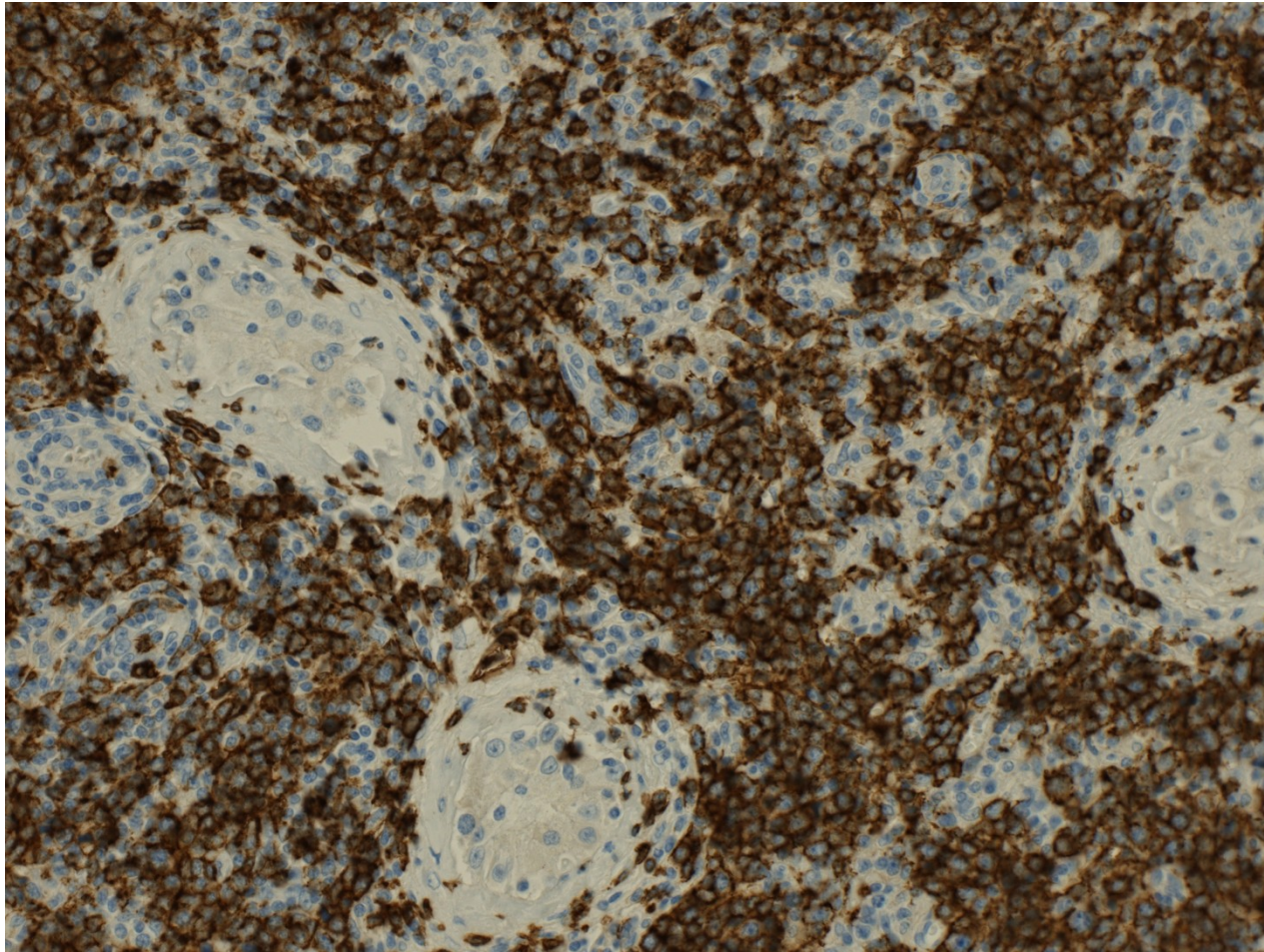


# Testicular DLBCL – Ki-67 proliferation rate





# Testicular DLBCL – CD20+ B-cell type

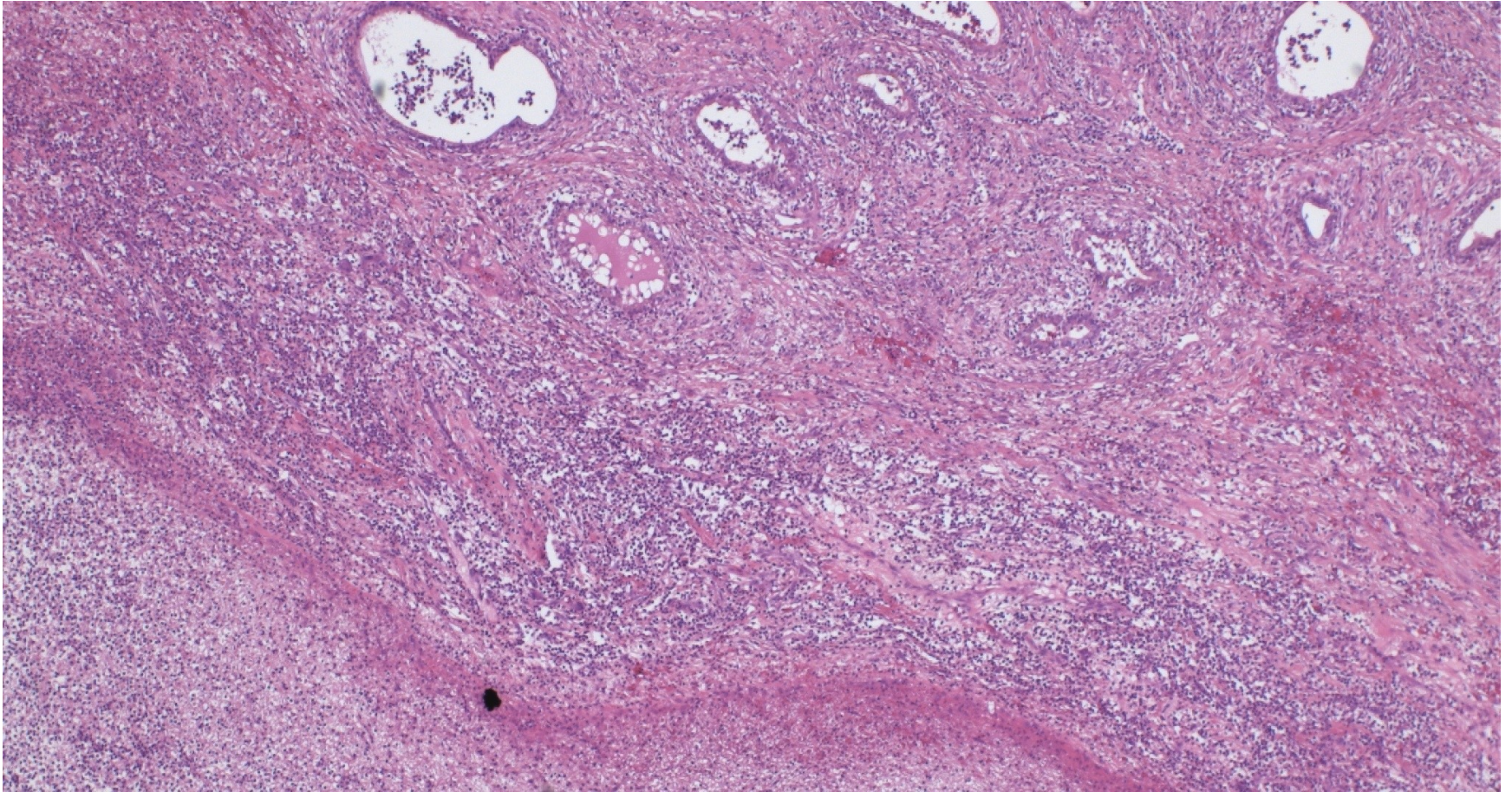




# Epididymitis

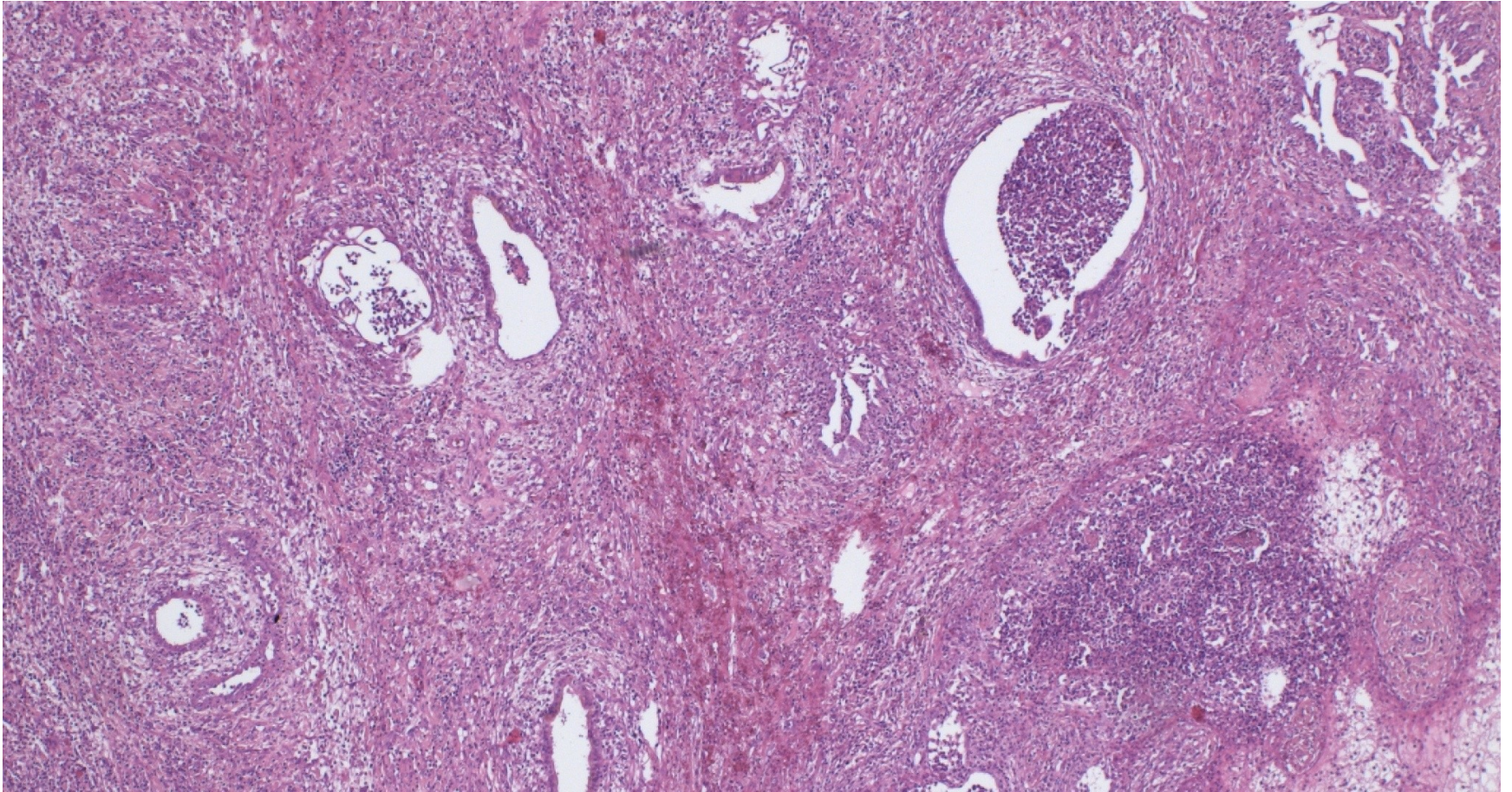
- nonspecific epididymitis most common
- usually connected to UTI, bacterial
- purulent, abscess formation, necrosis
- progression to orchitis
- healing by repair, fibrosis + cysts possible
- diff. dg. x tumors

# Epididymitis w. abscess





# Epididymitis w. abscess





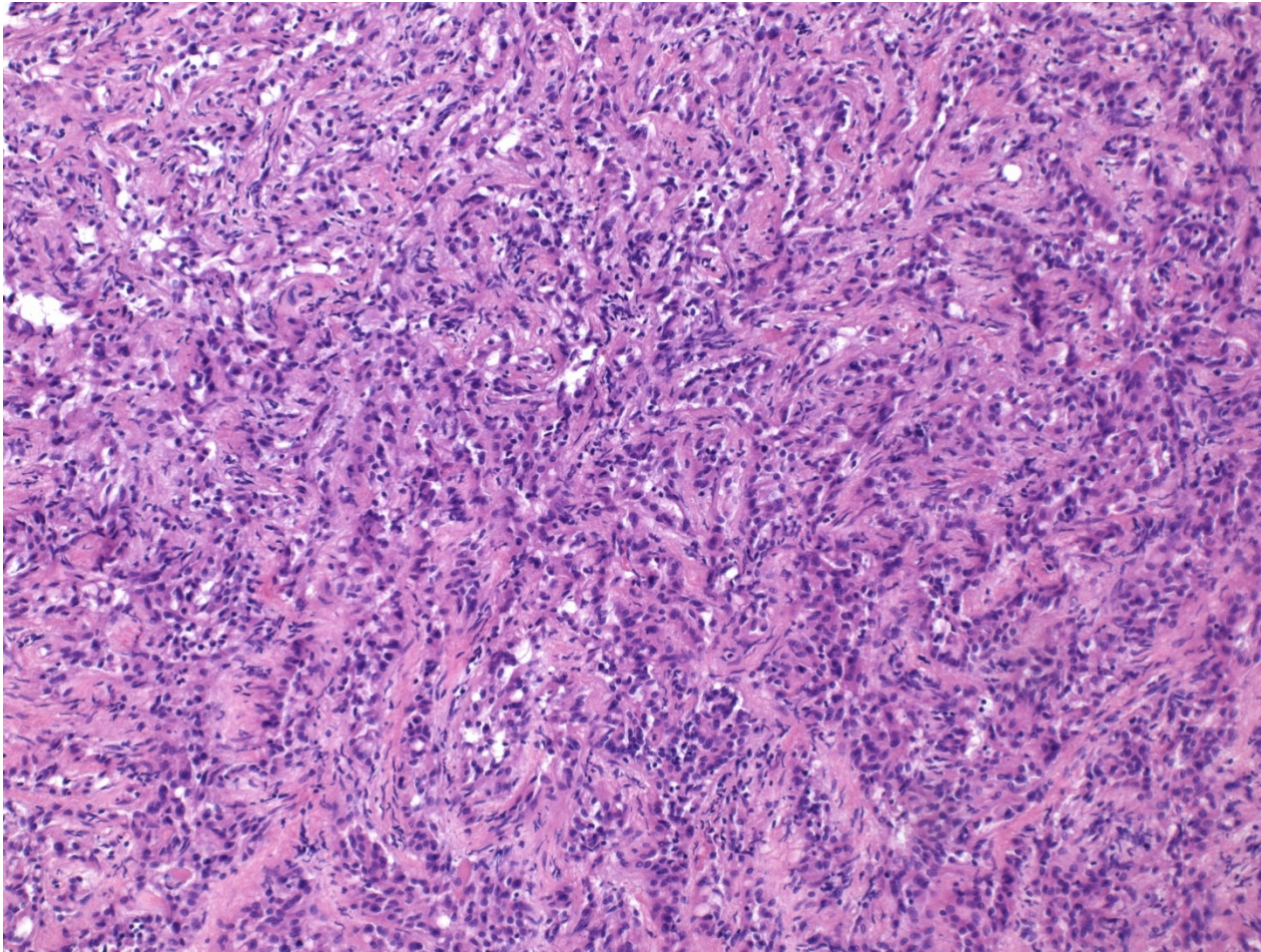
# Sperm granuloma

- pathological situation of sperm in direct contact with stroma
- chronic granulomatous inflammation
- diff. dg.
  - macro x tumor
  - micro x other causes of granuloma incl. TB

# Tumors

- most commonly extension from testicular tumors
- primary tumors rare
  - adenomatoid tumor: benign, phenotype mesothelial, possibly from remnants of Müllerian tract

# Adenomatoid tumor





# Adenomatoid tumor

