

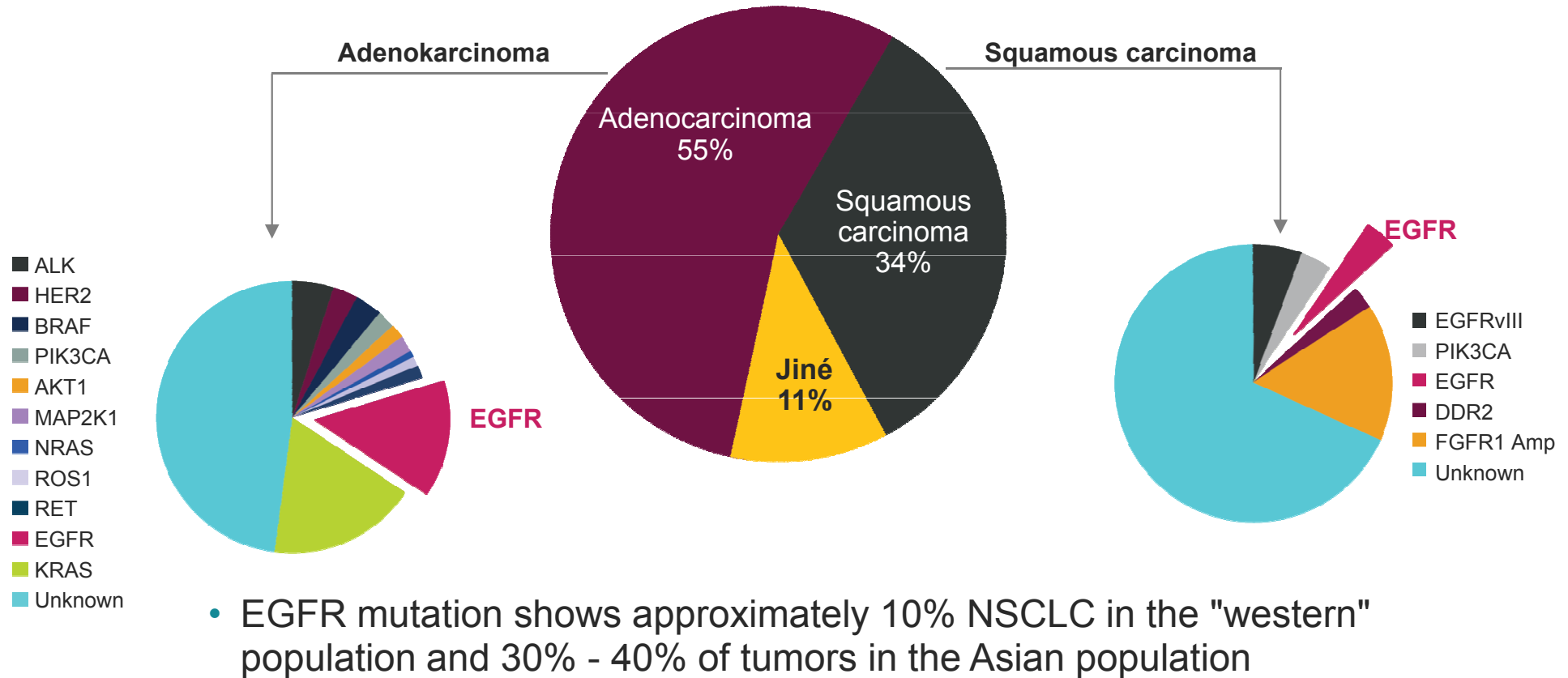
TARGETED THERAPY FOR THE  
TREATMENT OF METASTATIC LUNG  
ADENOCARCINOMA  
A CASE STUDY

MUDr. Bohdan Kadlec, Ph.D.

Department of pulmonary diseases and TB LF  
MU a FN Brno

# NSCLC classification is evolving from histological to molecular subtyping of the tumor

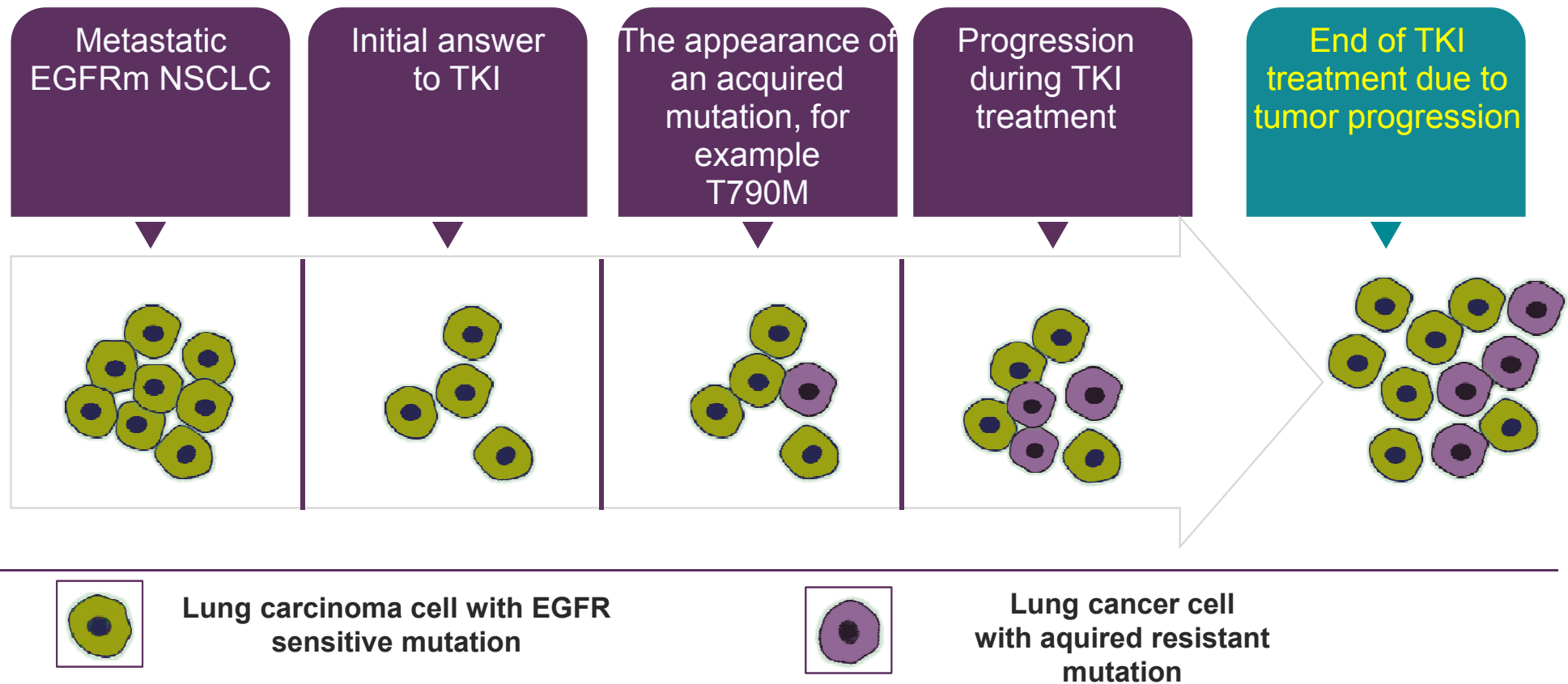
## Histological subtypes of NSCLC



AKT, protein kinase B; ALK, anaplastic lymphoma kinase; Amp, amplification; BRAF, serine-threonine kinase type B; DDR2, type 2 receptor tyrosine kinase; FGFR, fibroblast growth factor receptor; HER2, type 2 human epidermal growth factor receptor; KRAS, plasma tyrosine kinase; MAP2K1 mitogen-activated protein kinase type 1; NRAS, plasma tyrosine kinase; PIK3CA, alpha-4,5-diphosphate 3-kinase catalytic subunit; RET, receptor tyrosine kinase; ROS1, receptor tyrosine kinase



# Resistance due to an acquired mutation is the most common cause of disease progression<sup>1</sup>



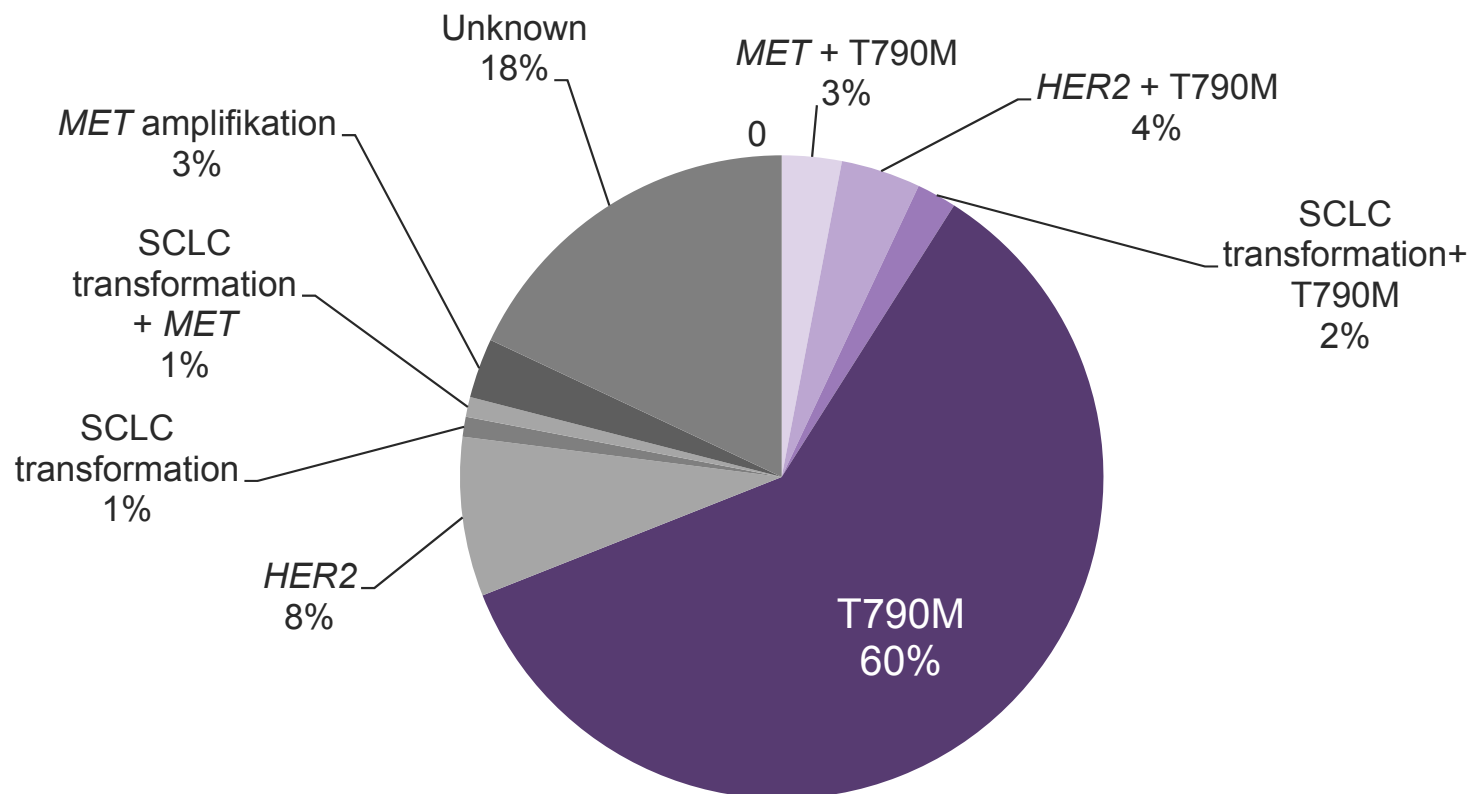
Most patients with metastatic EGFRm NSCLC progress within 8–14 months during first-line TKI treatment<sup>2</sup>



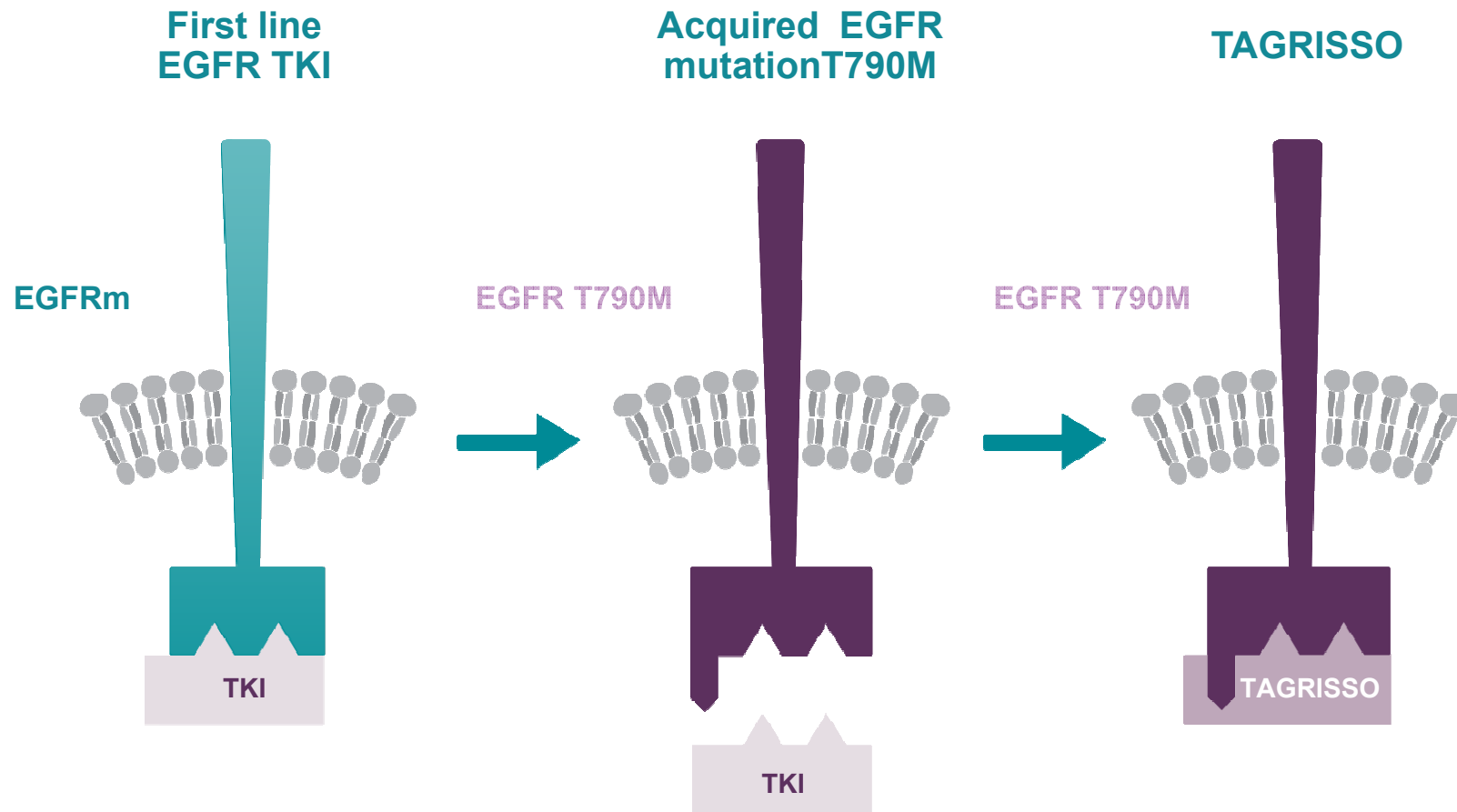
# EGFR T790M mutations are among the most common causes of acquired resistance to EGFR TKI treatment

Nearly two-thirds of patients with metastatic EGFRm NSCLC who progressed to EGFR TKI treatment had the presence of an acquired EGFR T790M mutation

Frequencies of different mechanisms of acquired resistance.



# Acquired resistance to EGFR TKI treatment



- 1st and 2nd generation TKI inhibits EGFR signaling

- The T790M mutation leads to the development of acquired resistance

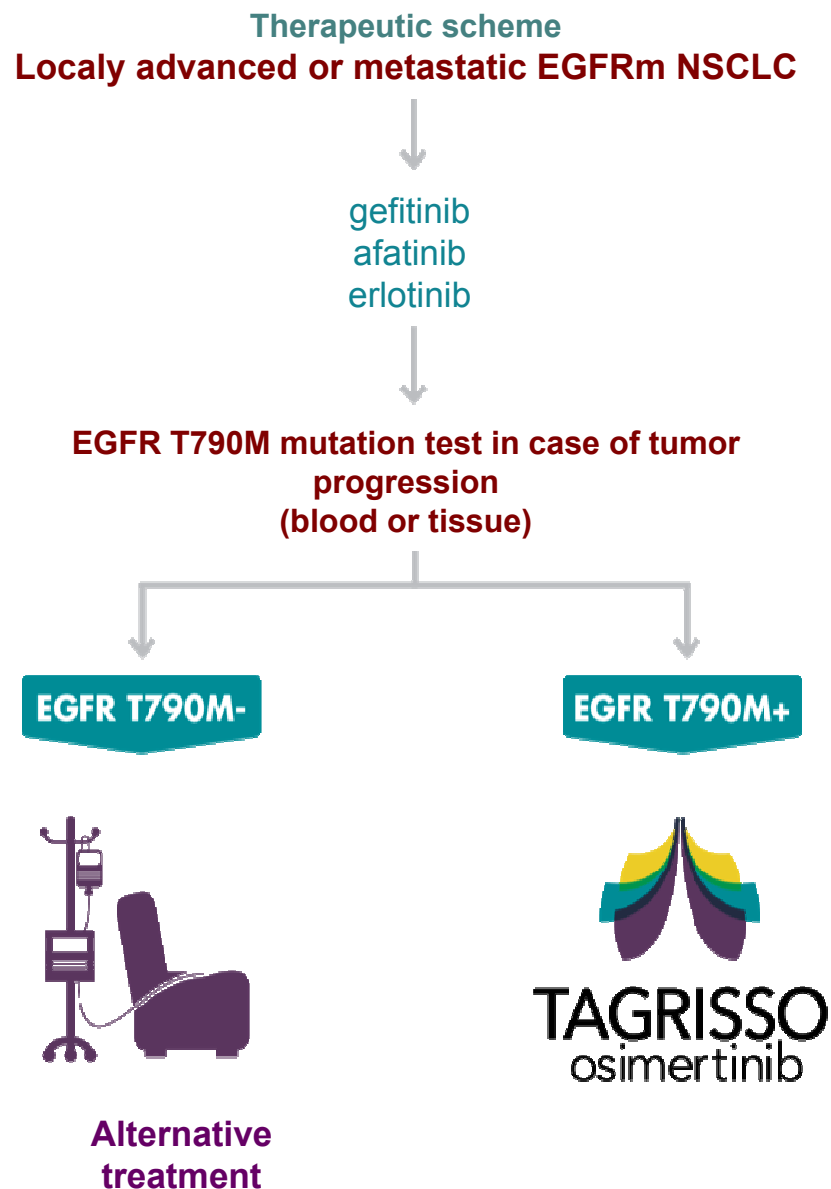
- TAGRISSO inhibits both the EGFR-sensitive mutation and the EGFR T790M mutation responsible for resistance to TKI 1./2. generation




# TAGRISSE® (osimertinib): Therapeutic indications

## Indication

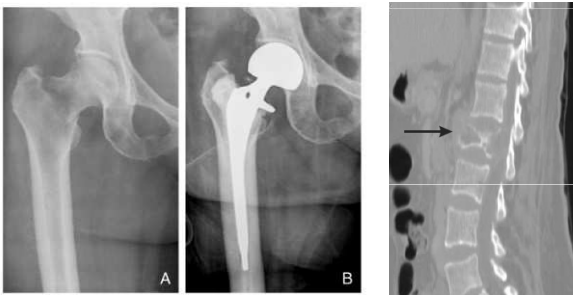
TAGRISSE is indicated for the treatment of adult patients with locally advanced or metastatic non-small cell lung cancer with a proven mutation in the T790M epidermal growth factor receptor (EGFR).



# Case study

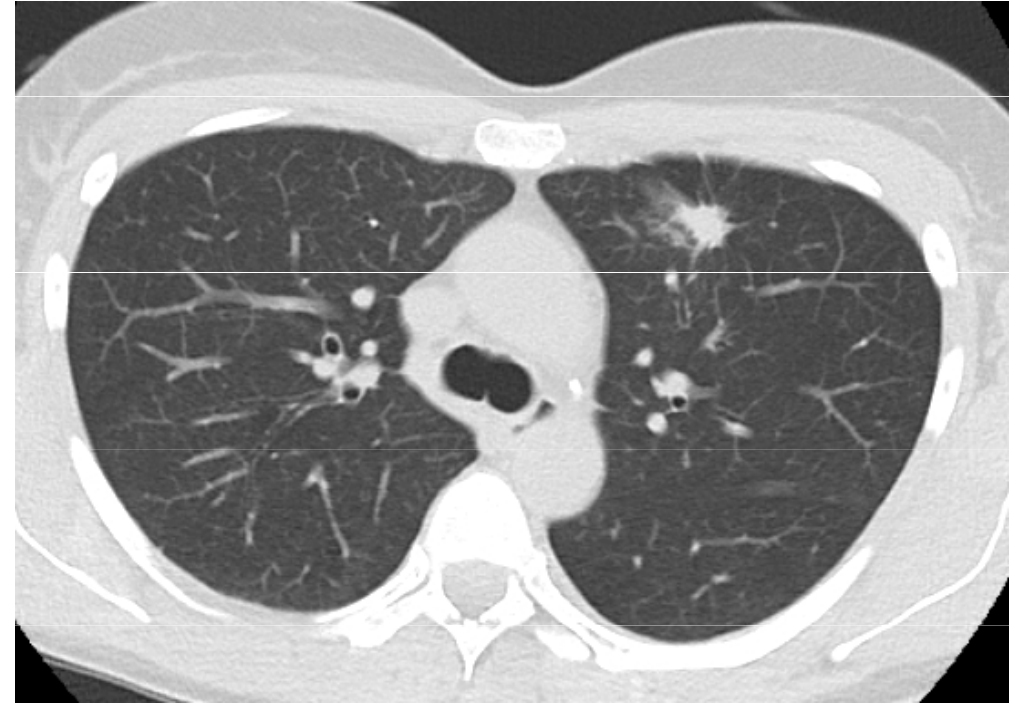
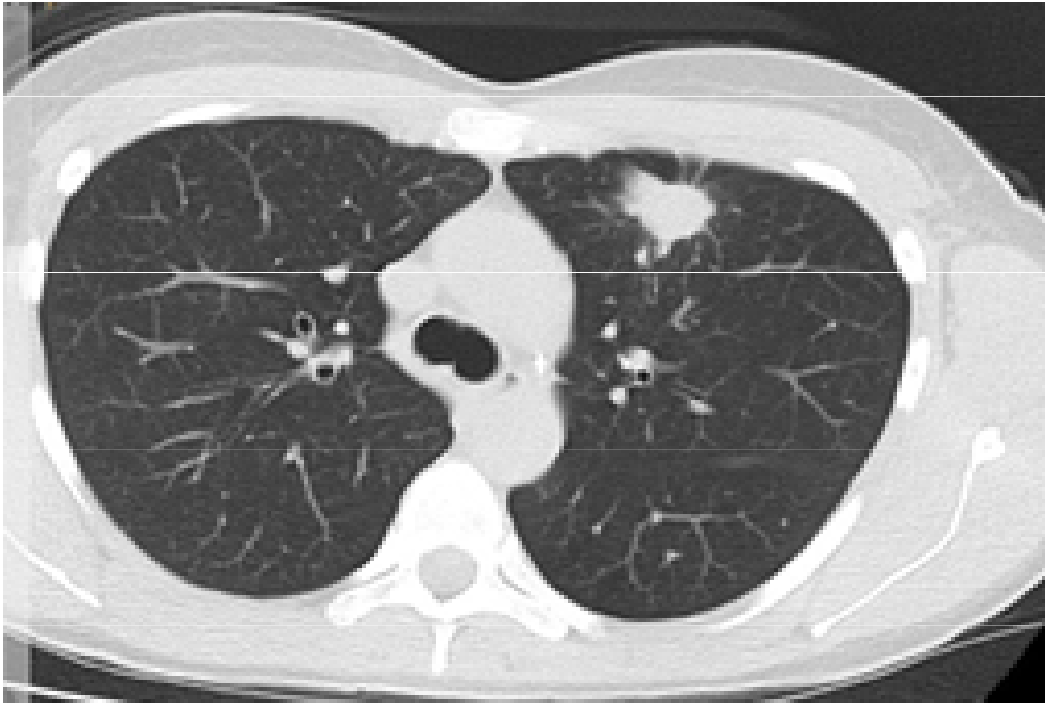


- woman, 46 years old
- english teacher
- never smoker still healthy
- 3/2016 dg. adenocarcinoma of the upper lobe of the left lung, wedge. st. IV with malignant pleural effusion and skeletal metastases
- EGFR M + deletion in exon 19
- symptoms: pain, shortness of breath,
- in April 2016 there is a pathological subcapital fracture of the femur on the left, which was resolved by a total endoprosthesis
- ECOG - PS 1-2



# Initiation of afatinib and denosumab treatment

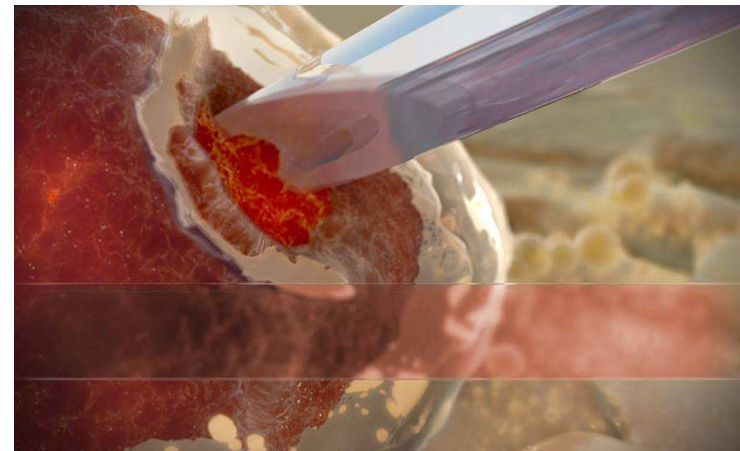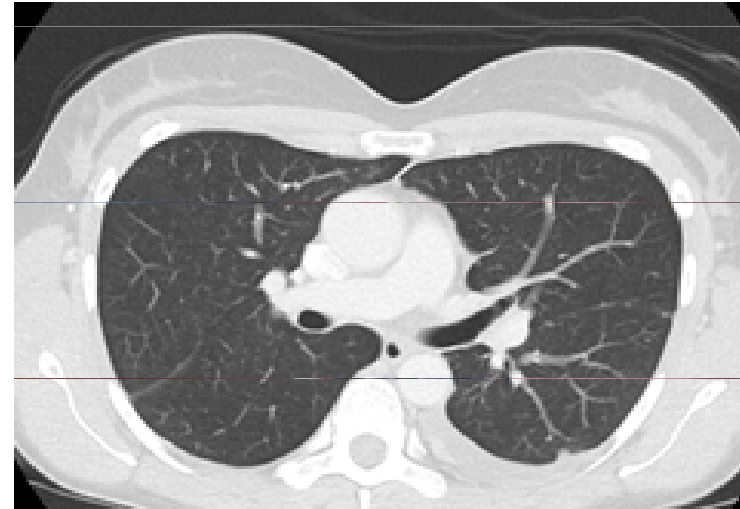Afatinib 4/2016 – 7/2017 (15 month)





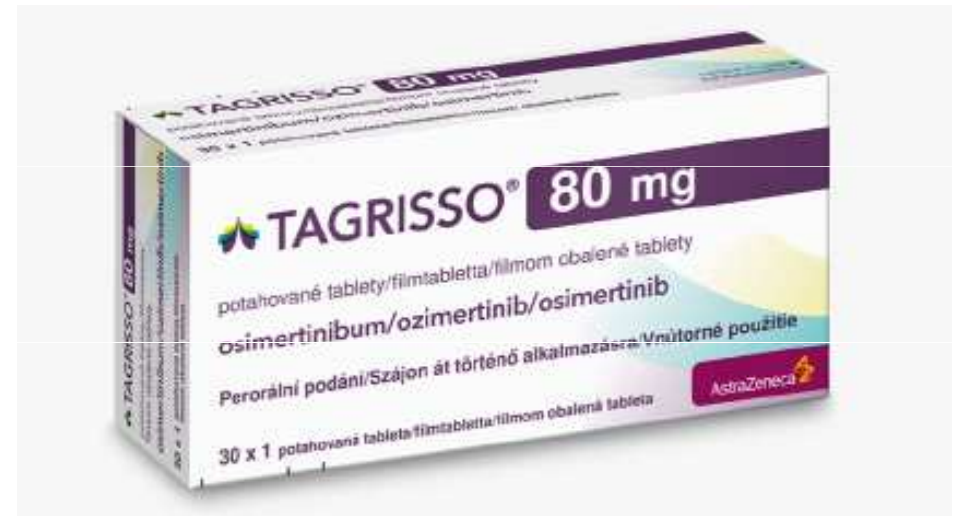# Discovery of a resistant mutation

- 7/2017 clinical deterioration, pleural pain, left pleural effusion detected
- performed a probatory puncture of pleural effusion from which the T790M mutation was proved

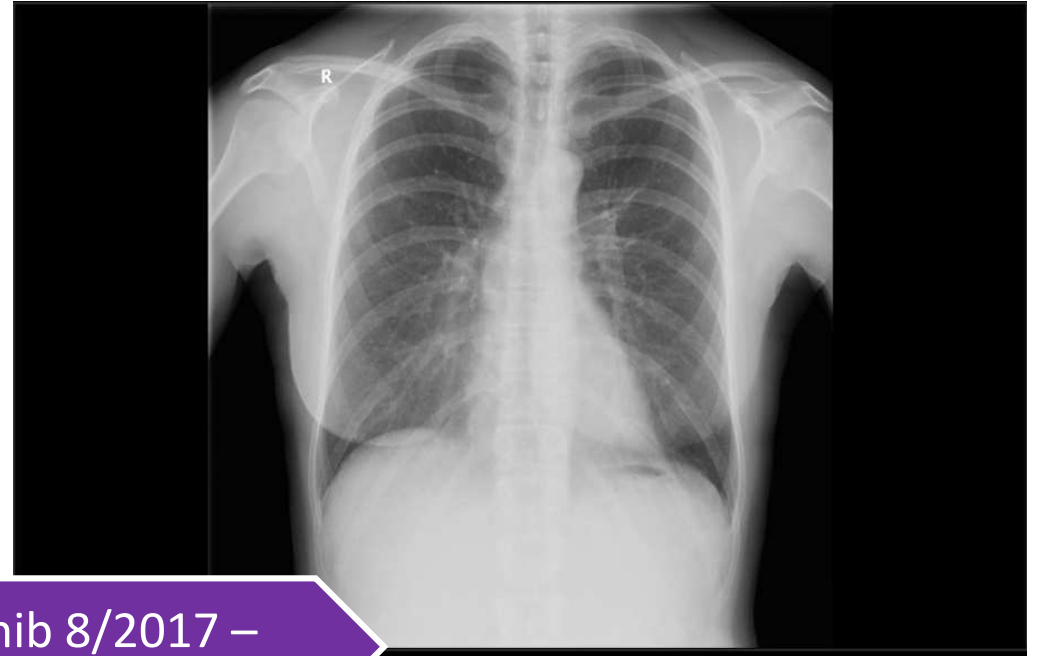
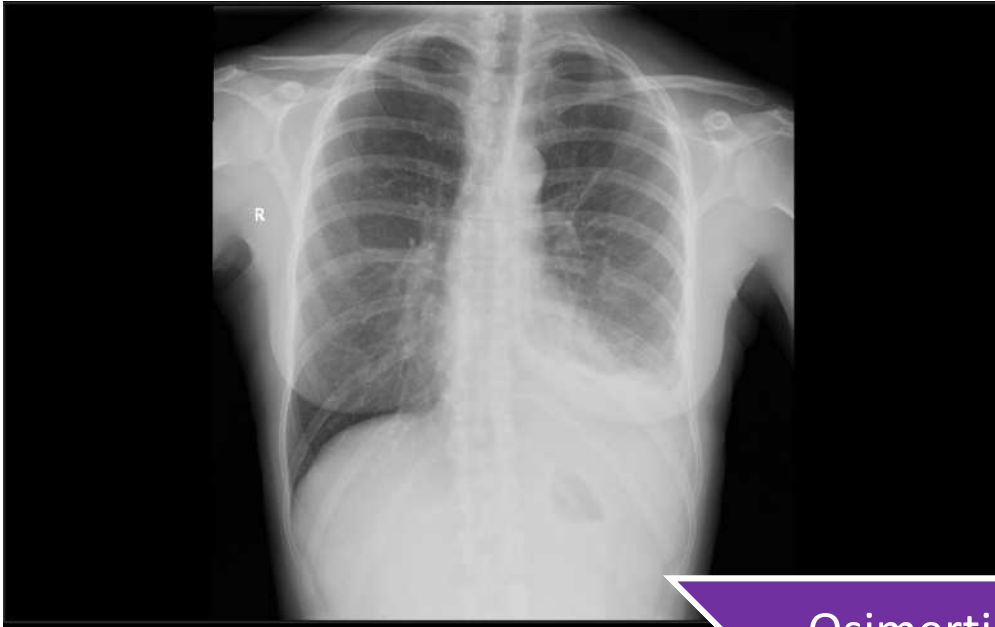


# Targeted therapy - osimertinib

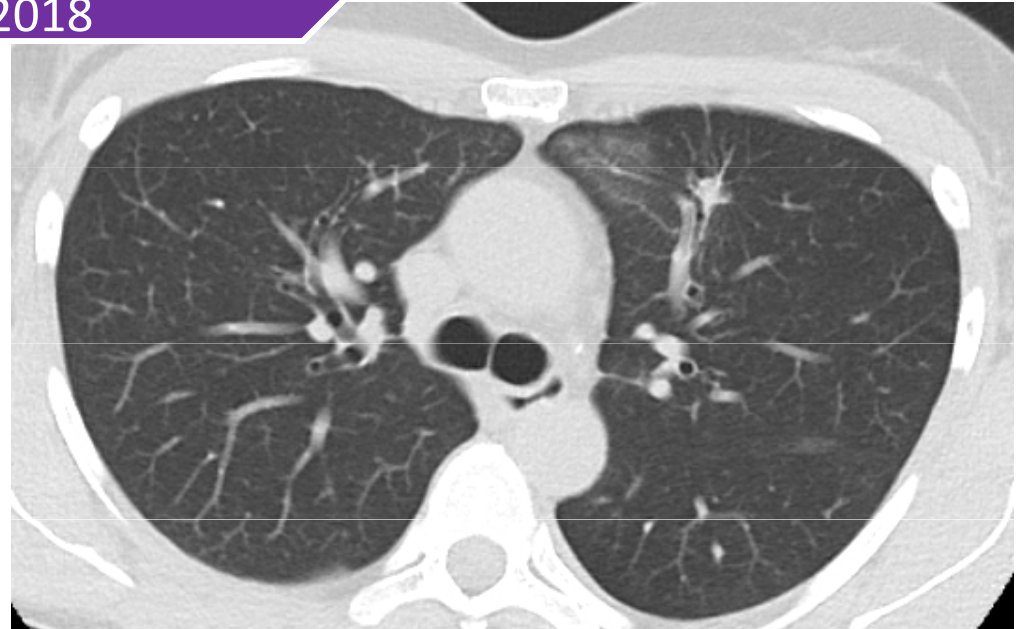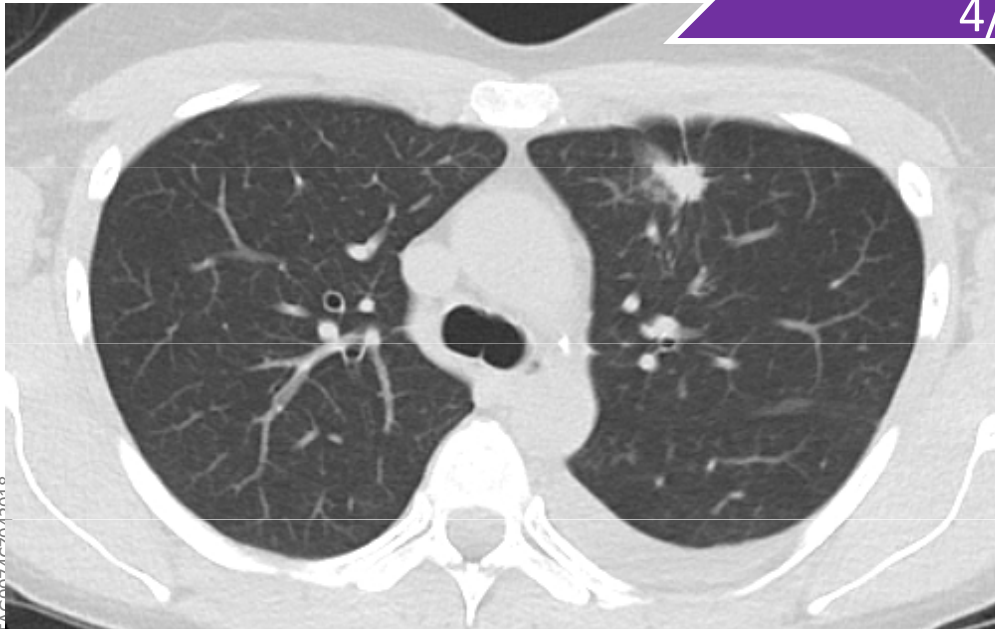
- started at a dose of 80 mg once a day from 8/2017
- pleural effusion regressed during treatment
- pain and shortness of breath improved



# Targeted therapy



Osimertinib 8/2017 –  
4/2018



# Conclusion

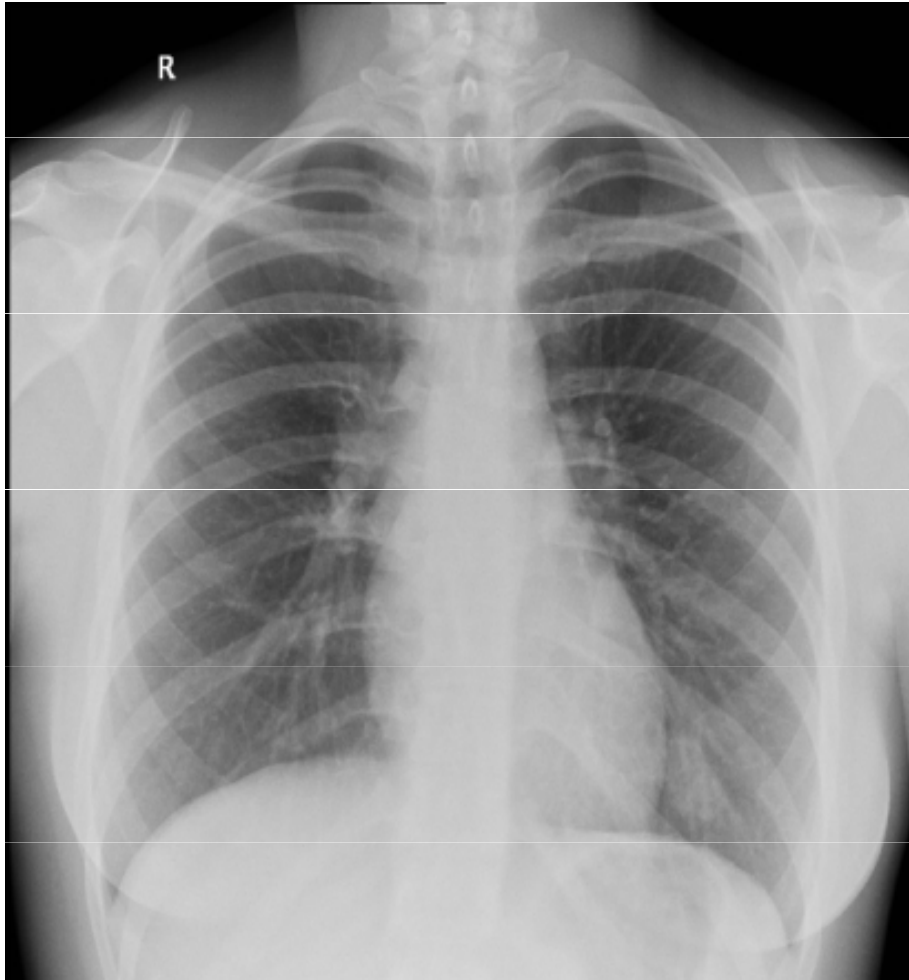
This case report demonstrates the treatment options of targeted therapy - osimertinib in metastatic lung cancer with the occurrence of the T790M mutation, shows significantly higher survival with comfortable oral administration and significantly lower toxicity compared to conventional chemotherapy treatment.

# A case study of a Vietnamese girl



- Female, 22 years old, Vietnamese
- Anamnestic - in the family without the occurrence of more serious diseases, non-smoking, allergies to grass pollens and mites.
- For more than a month, he has difficulty breathing, coughs, wheezes, catches his breath with less exertion, it gets worse overnight, he observes pressure on his chest, he does not give pain.

# Clinical and imaging examination



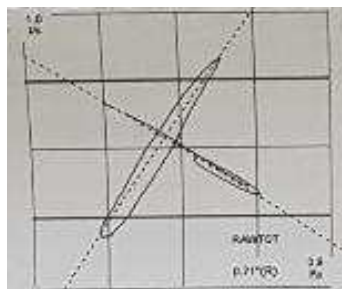
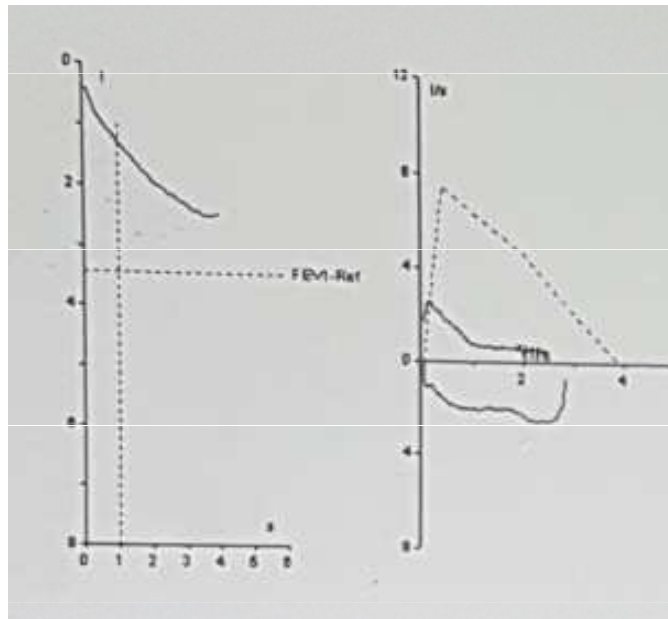
- Clinically numerous wheezing and wheezing on both sides.
- CRP 21, KP without respiratory insufficiency, other laboratory tests in the norm.
- Deployed ATB treatment, given bronchodilator infusions including corticoids, bronchodilator therapy and inhaled corticoids
- Accepted within a week for non-improving problems

# Suggestion for further examination?


- A) spirometry and bronchodilation test
- B) bronchoscopy
- C) CT of the chest
- D) PET-CT
- E) PET-MR



# Spirometry



Obr. 11: Křivka průtok-objem, typy obstrukcí



## Smyčka průtok / objem

| Parametr | Jednotka          | Náležitá h. | Měřená | %Nál. |
|----------|-------------------|-------------|--------|-------|
| VC       | l                 | 3.95        | 3.00   | 76    |
| ERV      | l                 | 1.35        | 1.03   | 76    |
| IRV      | l                 |             | 1.12   |       |
| IC       | l                 | 2.58        | 1.97   | 76    |
| IC/TLC   | %                 | 51          | 38     | 75    |
| FVCex    | l                 | 3.95        | 2.50   | 63    |
| FEV1     | l                 | 3.45        | 1.25   | 36    |
| FEV1/FVC | %                 | 84          | 50     | 59    |
| FEV1/IVC | %                 | 84          | 42     | 49    |
| PEF      | l/s               | 7.43        | 2.54   | 34    |
| MEF75    | l/s               | 6.42        | 1.48   | 23    |
| MEF50    | l/s               | 4.68        | 0.65   | 14    |
| MEF25    | l/s               | 2.26        | 0.61   | 27    |
| MEF25-75 | l/s               | 4.18        | 0.74   | 18    |
| Aex      | l <sup>2</sup> /s |             | 2.57   |       |

| Parametr | Jednotka  | Náležitá h. | Měřená | %Nál. |
|----------|-----------|-------------|--------|-------|
| FRC(TGV) | l         | 2.81        | 3.19   | 113   |
| TLC      | l         | 5.36        | 5.16   | 96    |
| VC       | l         |             | 2.81   |       |
| RV       | l         | 1.46        | 2.16   | 148   |
| TGV/TLC  | %         | 49          | 62     | 126   |
| RV/TLC   | %         | 27          | 42     | 152   |
| Raw      | kPa/(l/s) | 0.30        | 0.71   | 236   |
| sGAW     | l/kPa/s   | 1.48        | 0.44   | 30    |



# Hospitalization

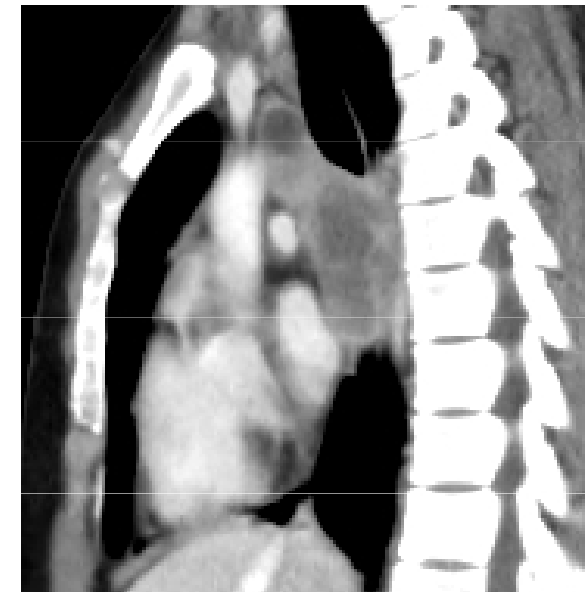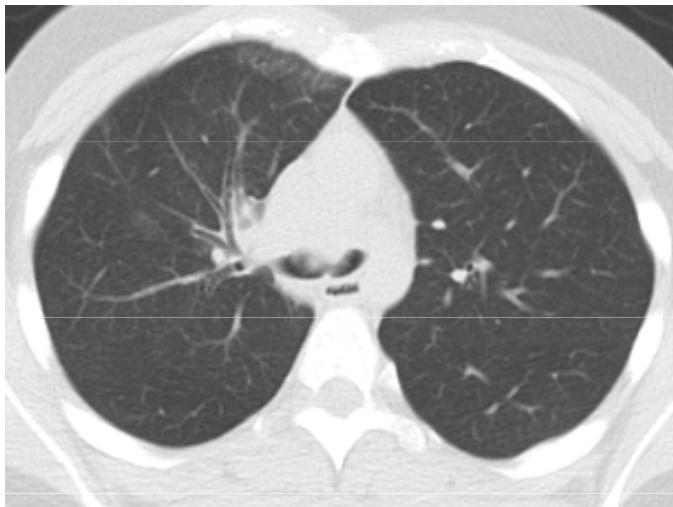
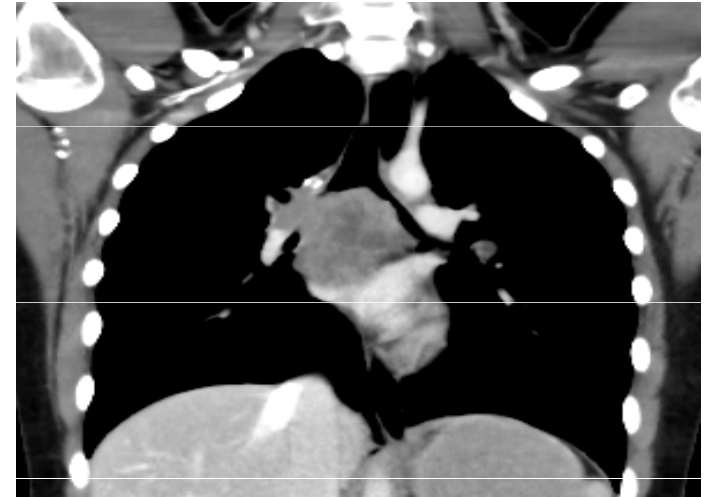
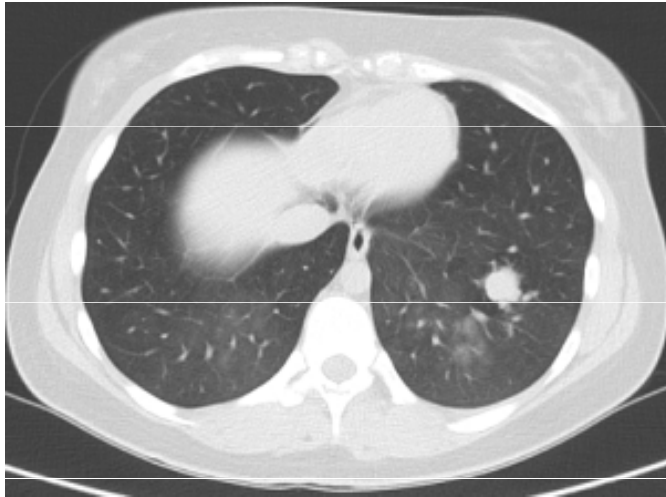## Laboratory:

- IgE **233** (0-90)
- hCG less than 2 ( 0 - 5 )  
SCCA 0.7 ( 0 - 1.5 )
- AFP 1.08 ( 0.74 - 7.29 )
- CYFRA **7.99** ( 0 - 3.3 )
- NSE **25.5** ( 0 - 16.3 )

## Bronchoscopy

- the trachea is normal
- the main carina is not identifiable, it is taken in a bumpy touch of slightly bleeding infiltration, which spreads to both main bronchi so that they are obturated from 2/3 and a slit remains dorsally, which allows ventilation

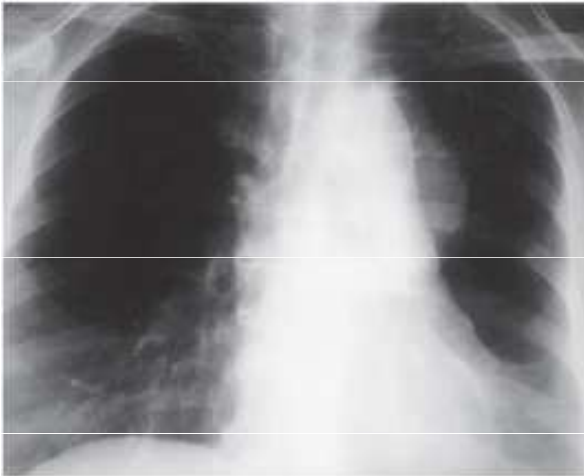
# Initial chest CT



# Differential diagnostics?

- A) Lymfoma
- B) Germininal tumor (teratoma)
- C) Lung cancer(NSCLC/SCLC)
- D) Carcinoid
- E) Another primary lung tumor

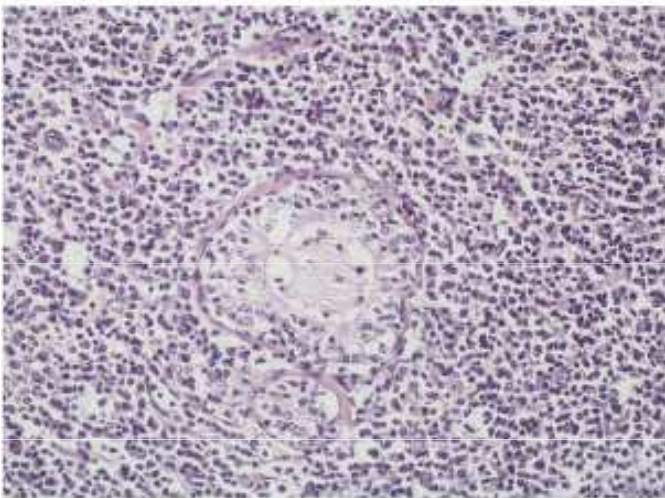
# B- lymfoma



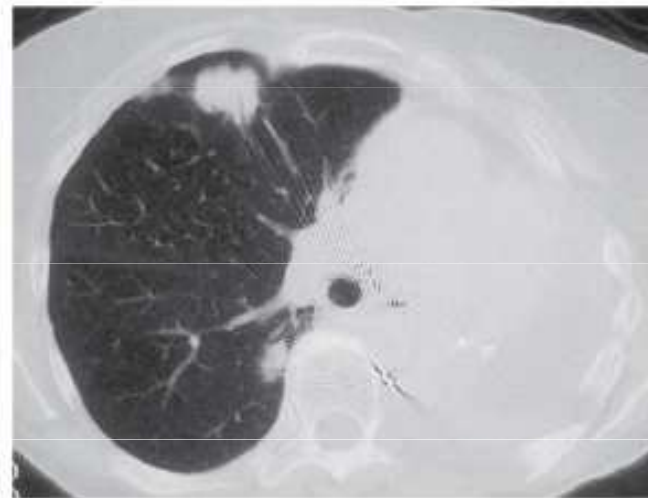
a.



b.



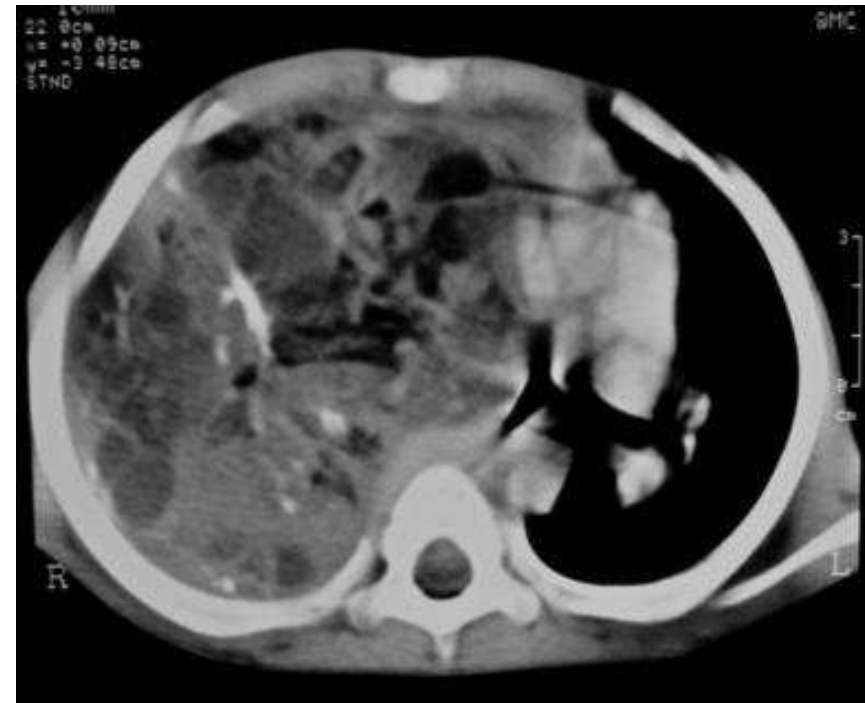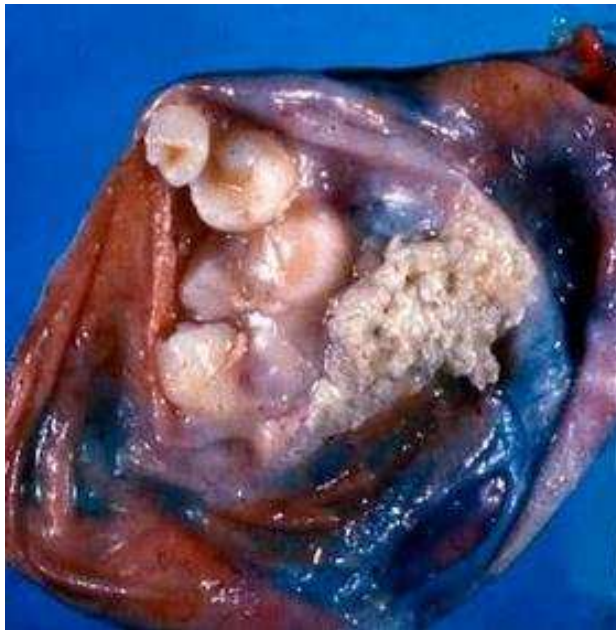c.



d.

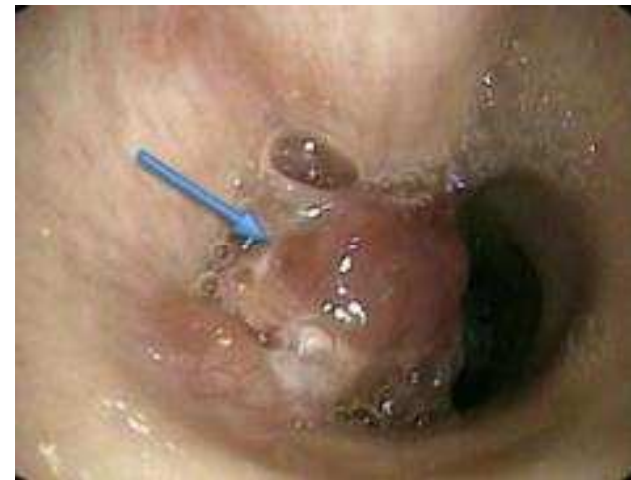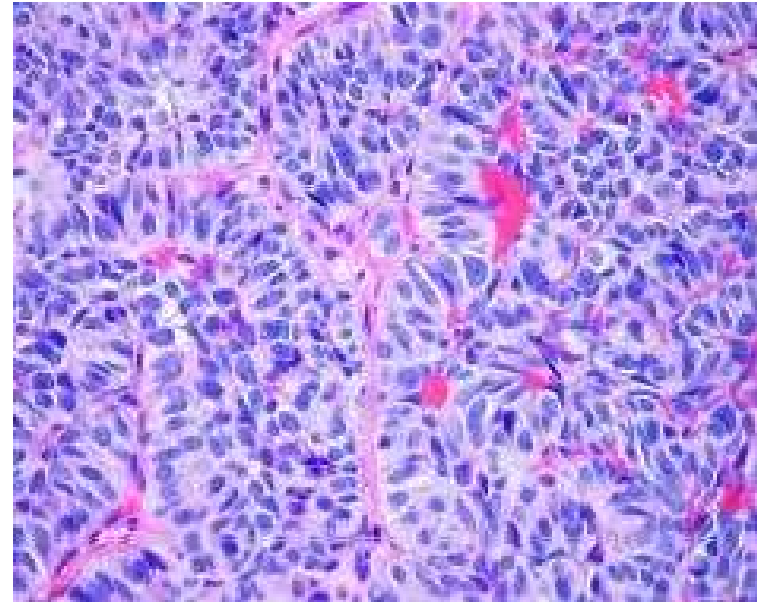
# Intrapulmonary teratoma

- Rare germ cell tumor.
- Causes pain, cough and haemoptysis.
- Main treatment is surgical



# Lung carcinoid

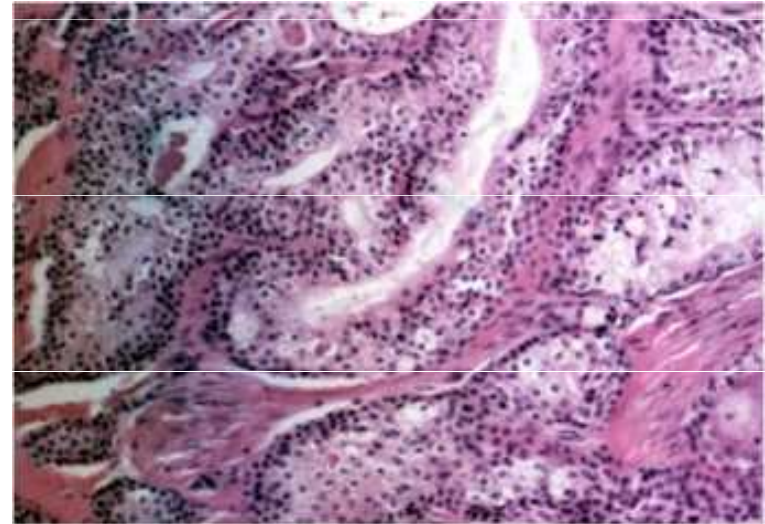
- They make up about 1% of lung tumors, incidence 0.5-1.5 / 105.
- It belongs to malignant lung tumors.
- Typical carcinoids occur more in the younger, atypical in the older.
- Central location predominates (> 80%), remaining peripherally, may metastasize to liver, bone, brain, adrenal glands and ovaries





# Biopsy

- necrotic tumor formed by dominantly merging squamous tumor pins precisely with monocellular keratinization. The tumor sparsely scattered light cells with smaller dark nuclei corresponding to mucinous cells, which are positive for mucus staining.
- Immuno: p63 +, CK5 / 6 +, TTF1- , CD5-, CD117-, CK7 +, CK20 fok. +, Chromogranin-, synaptophysin-



- Conclusion: mucoepidermoid carcinoma (high grade)

# Mukoepidermoid carcinoma

- Rare malignant tumor of the salivary glands (<1%), occurs in the small salivary glands of the bronchi. It occurs in young people and is not associated with smoking.

Symptoms include cough, hemoptysis, bronchitis, wheezing, fever, chest pain and are therefore often diagnosed as asthma, COPD or pneumonia.

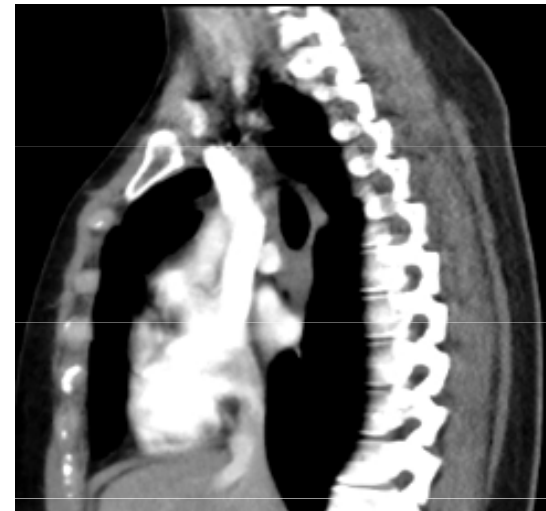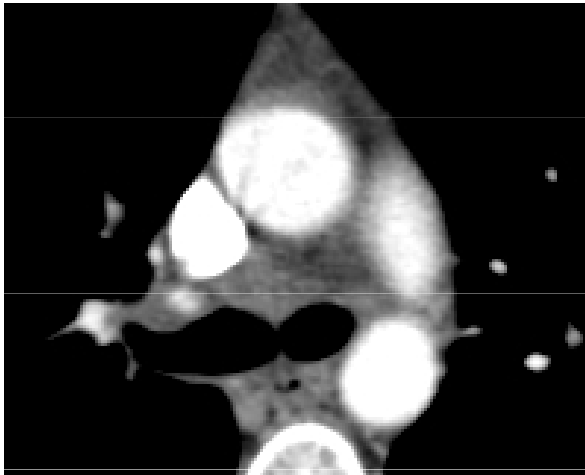
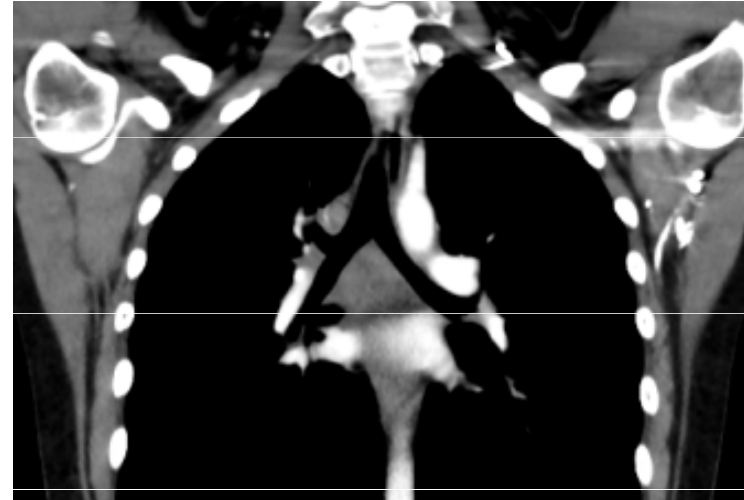
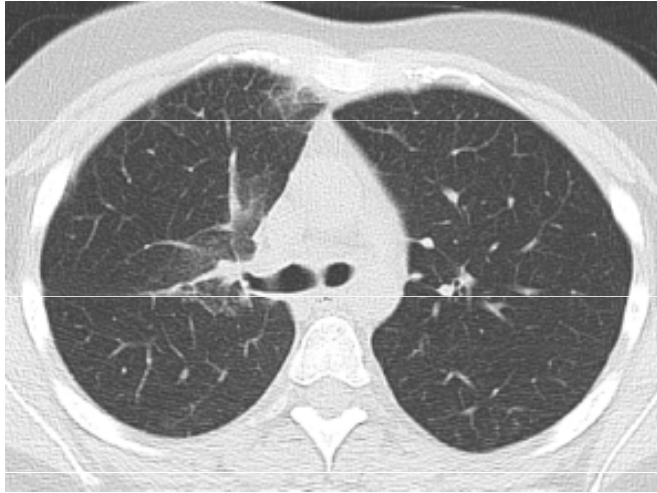Histologically, it is divided into low-grade and high-grade.

Treatment - similar to NSCLC, preferably surgery.

Prognosis: 95% of low-grade patients survive 5 years, high-grade patients survive <10%.

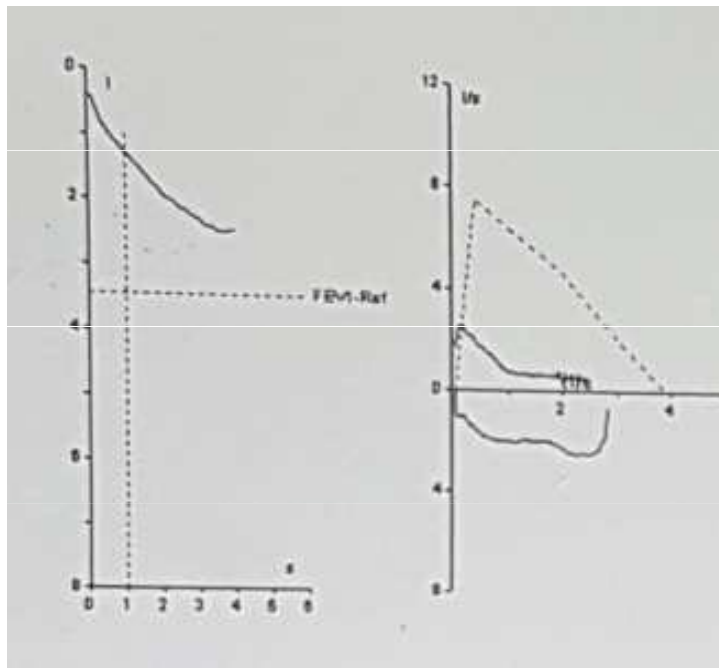


# CT regression after chemoradiotherapy

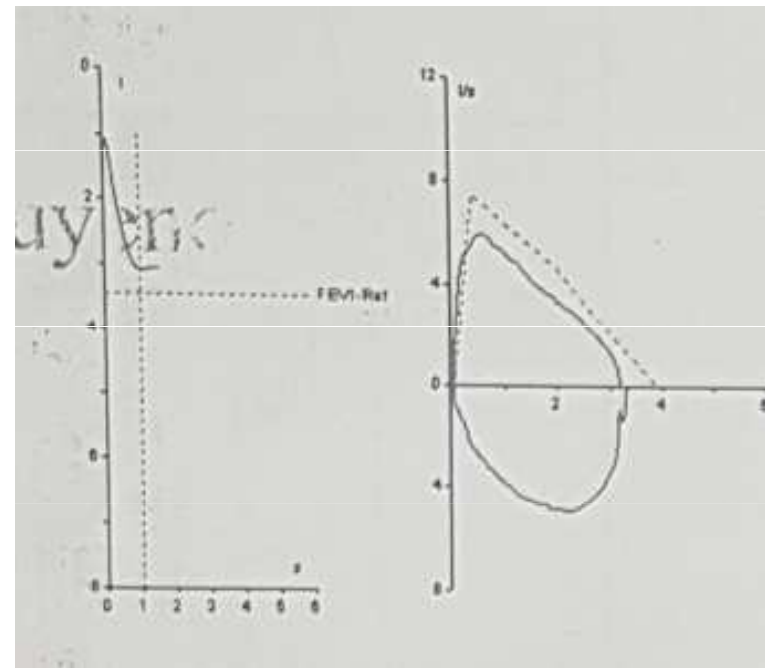


# Spirometry before and after treatment

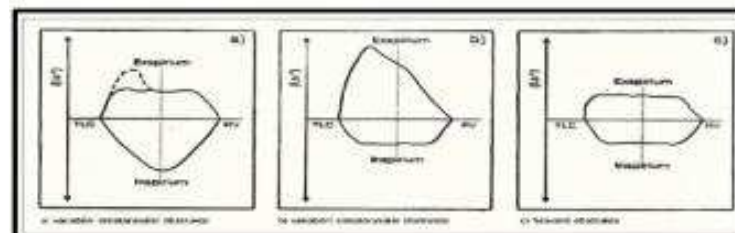
- Before



- After



Obr. 11: Křivky průtok objem, typy obstrukcí



# Conclusion

- This case report shows a case of malignant cancer of the airways, which is clinically reminiscent of an obstructive disease - bronchial asthma. It shows the need to think about this disease and perform examinations to exclude it in the initial differential diagnosis, especially in the case of persistent problems with bronchodilator therapy.