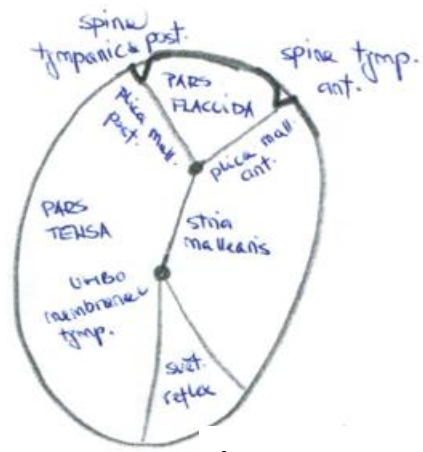
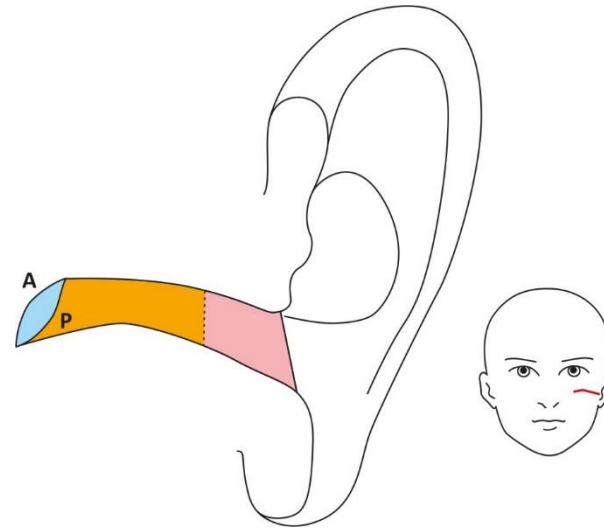
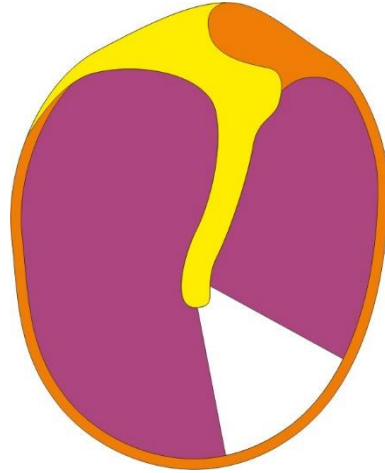


Schemas on ear

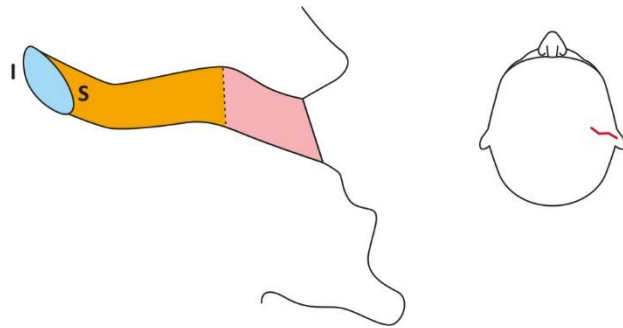
eardrum



Lower
inferior

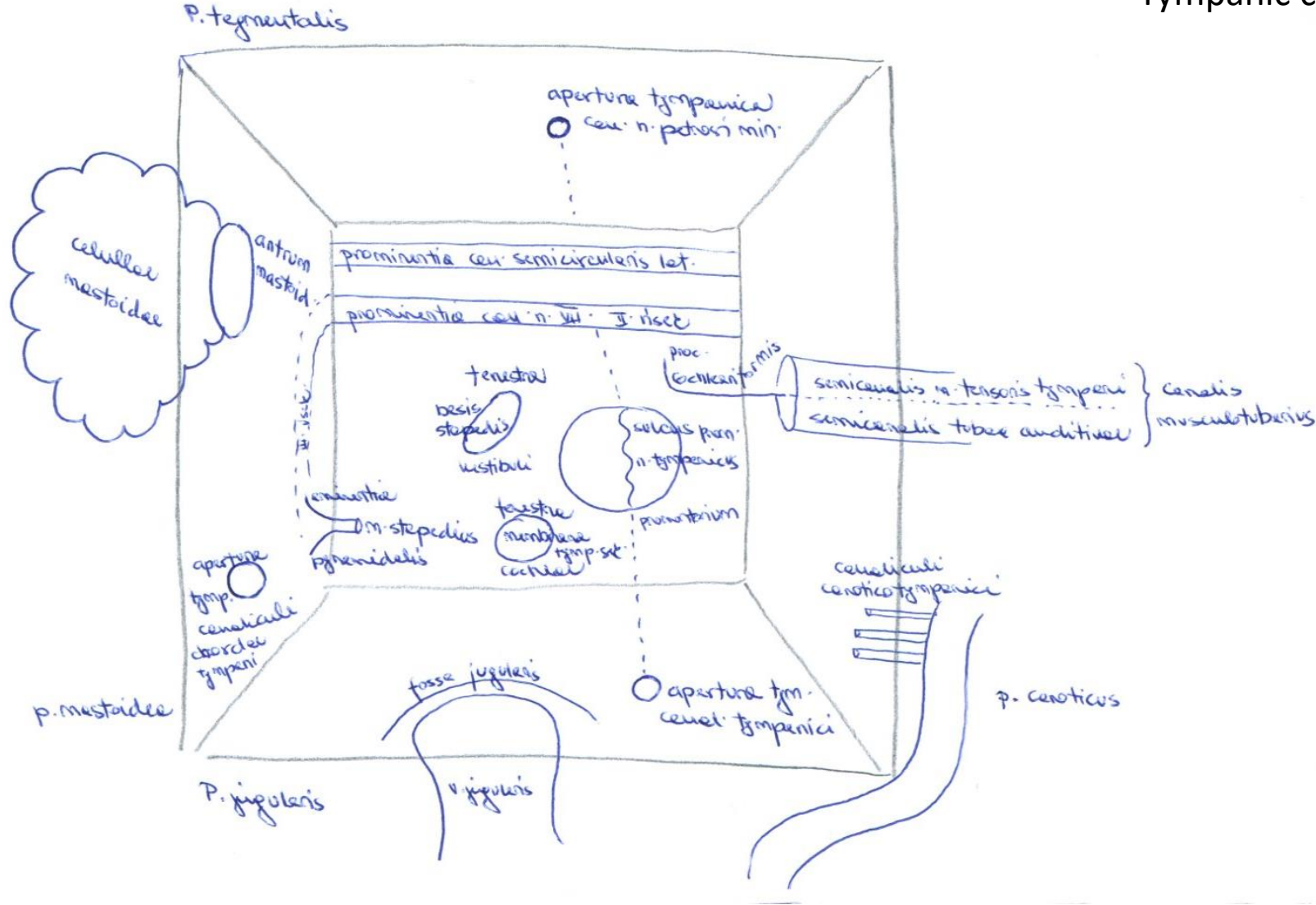


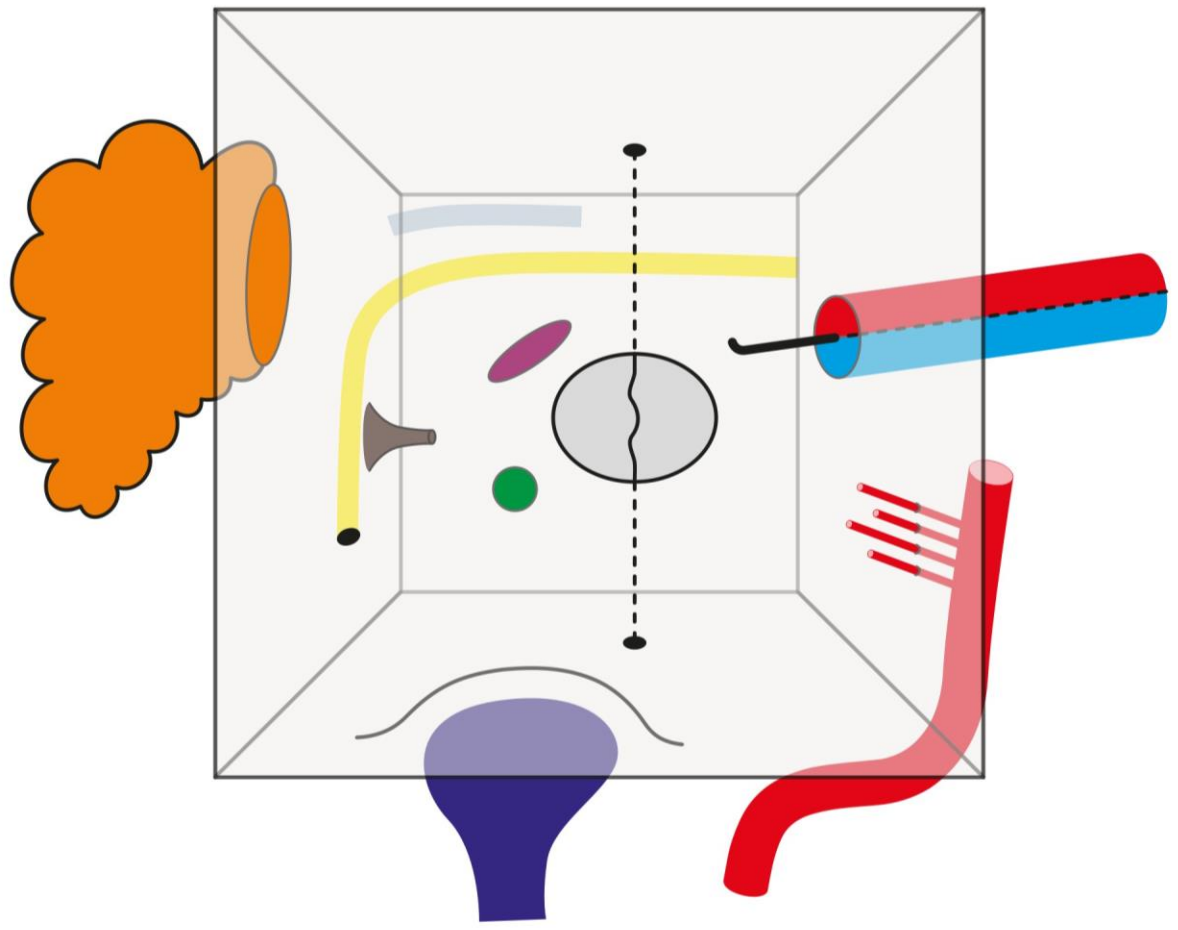
Frontal section through the meatus ac. ext.



Transversal section through the meatus ac. ext.

Tympanic cavity





12112015

