

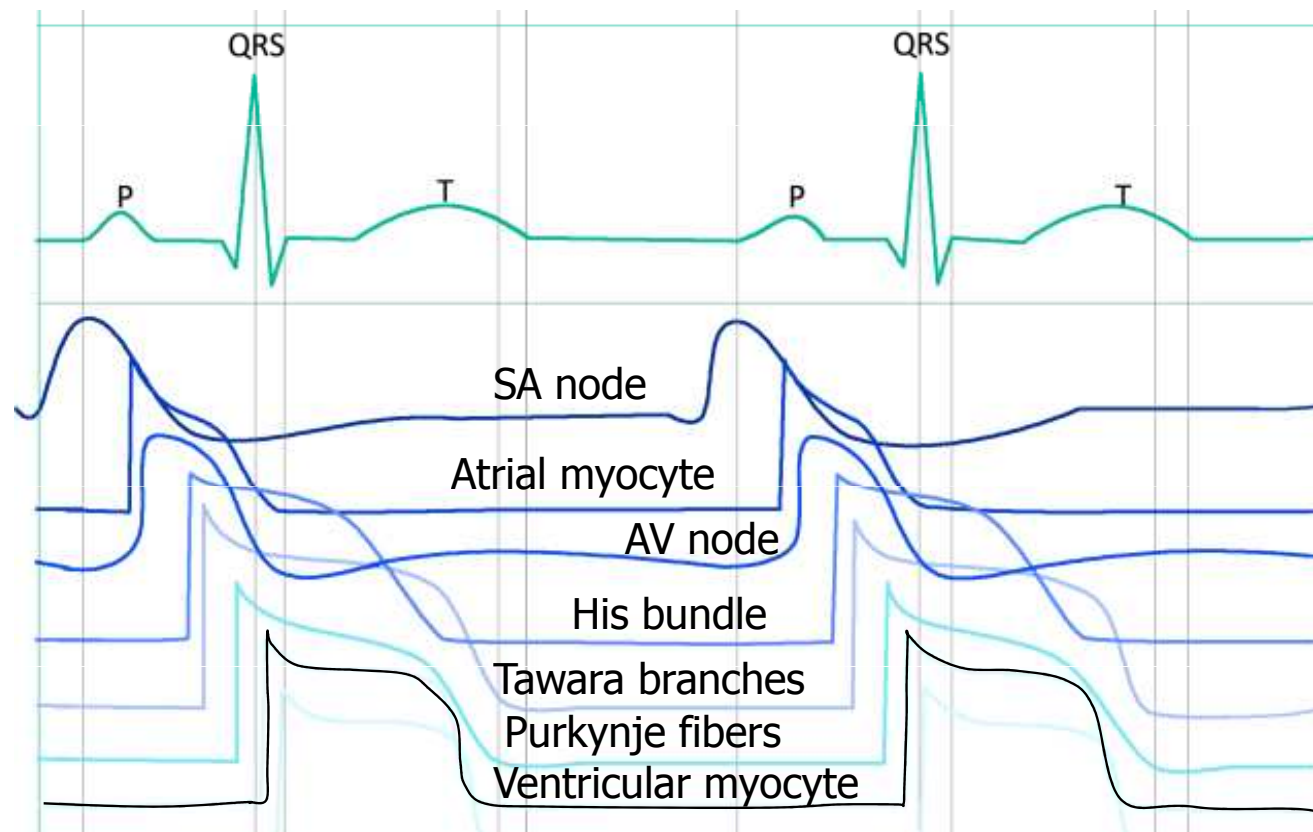
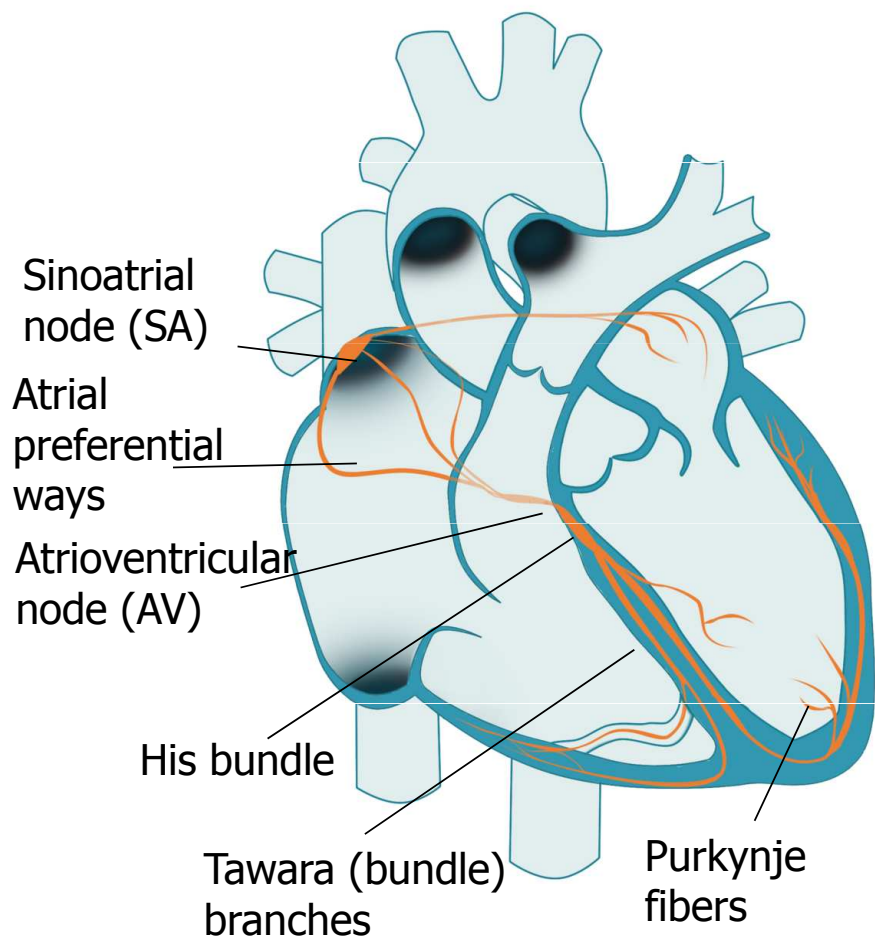
# ECG – Electrocardiography

Practical Exercises in Physiology (Spring semester: 4th - 6th weeks)

# Electrocardiography

- Definition: recording the cardiac electrical activity from the surface of the body  
(el. heart activity can also be obtained from the esophageal leads or the heart surface itself, but these methods are used by other names)

# Cardiac conduction system

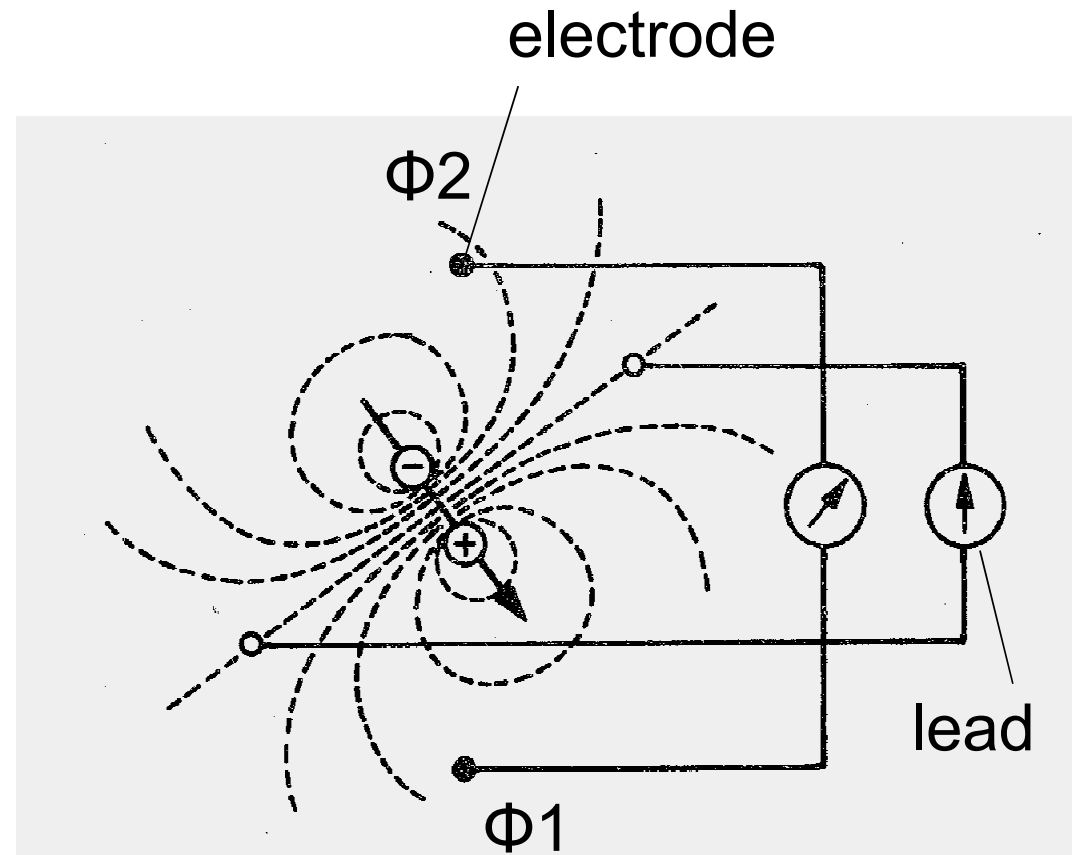


# Cardiac conduction system

- Function: AP formation and preferential conduction
  - The atriums are separated from the chambers by a non-conductive fibrous septum - the only way is through the AV
    - Sinoatrial node (SA) - natural frequency 100 bpm (mostly under parasympathetic damping effect), conduction velocity 0.05 m/s
    - Preferred internodal atrial ways - conduction velocity 0.8 - 1 m / s
    - Atrioventricular node - single conductive connection between atria and ventricles, natural frequency 40 - 55 bpm, conduction velocity only 0.05 m / s (nodal delay)
    - His bundle – conduction velocity 1–1,5 m/s
    - Tawara (bundle) branches – conduction velocity 1–1,5 m/s
    - Purkynje fibers – conduction velocity 3–3,5 m/s
- } natural frequencies of 20 - 40 bpm, they have slow spontaneous depolarization
- Sinus rhythm - AP starts at the SA node
  - Junction rhythm - AP is formed in the AV node or His bundle
  - Tertiary (ventricular) rhythm - AP is formed in bundle branches or Purkynje fiber
  - Ventricular myocardial activation - from inside to outside, markedly synchronized, determined by the onset of excitement
  - Repolarization of ventricular myocardium - in the opposite direction, less sharp, repolarization isles
  - Note: natural frequency is the frequency of AP formation unaffected by neural and hormonal control

# Electric dipole

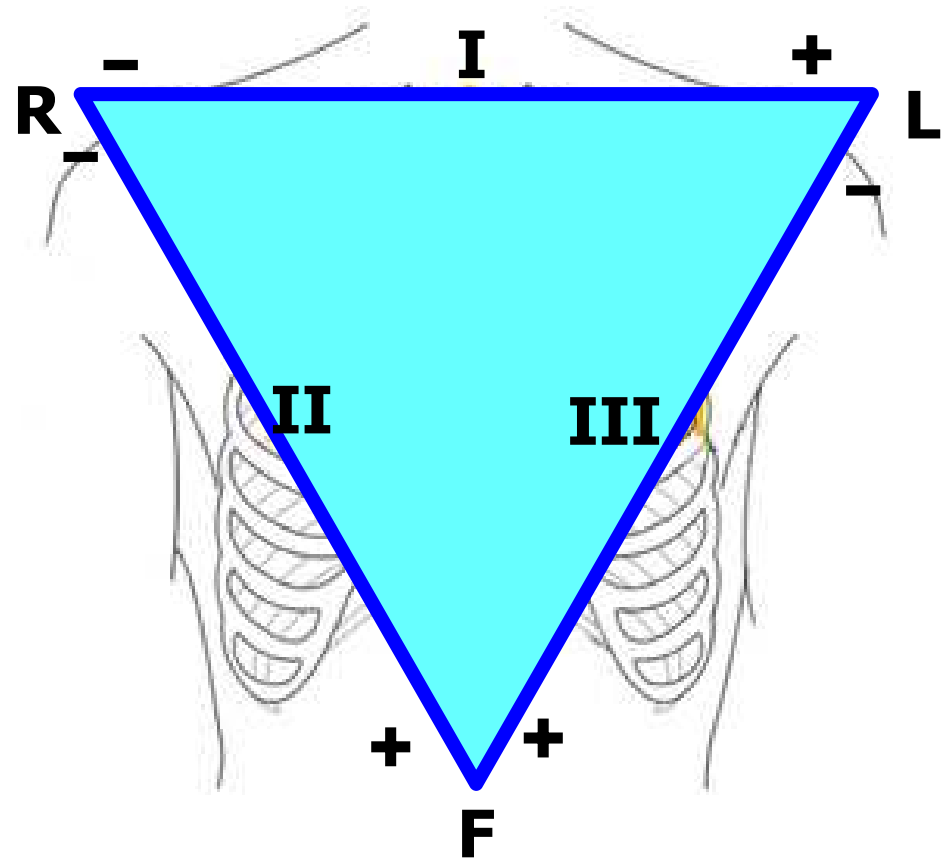
- Electrode: records electrical potential ( $\Phi$ )
- Electrical lead: connection of two electrodes
  - It records the voltage between the electrodes
  - Voltage: difference of el. potentials ( $V = \Phi_1 - \Phi_2$ )



# Einthoven triangle

(standard, limb, bipolar leads)

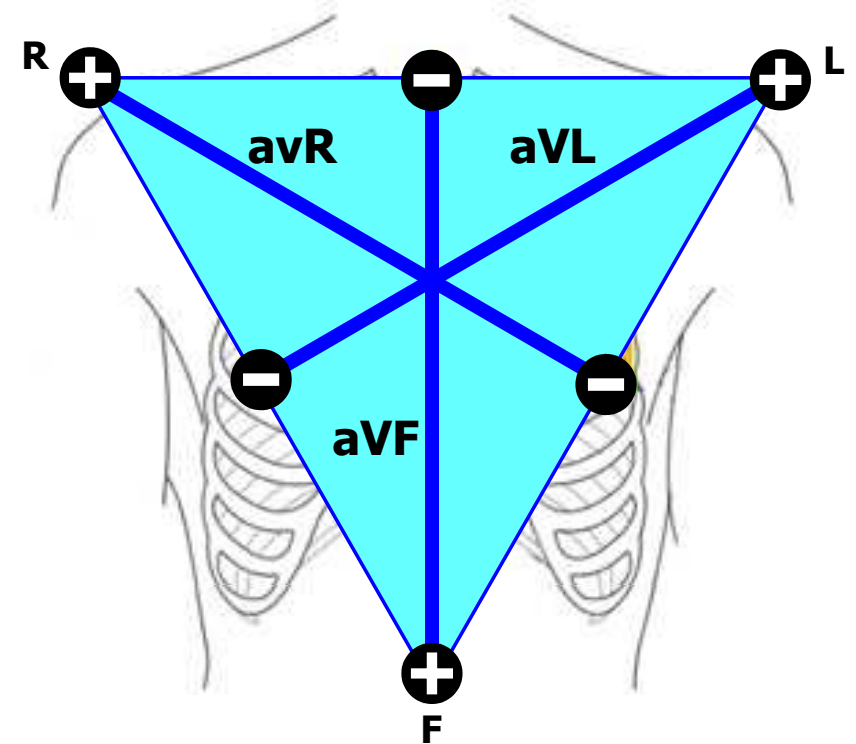
- Bipolar leads: both electrodes are active (variable electrical potential)
- Electrode colors:  
R: red, L: yellow, F: green



# Goldberger leads

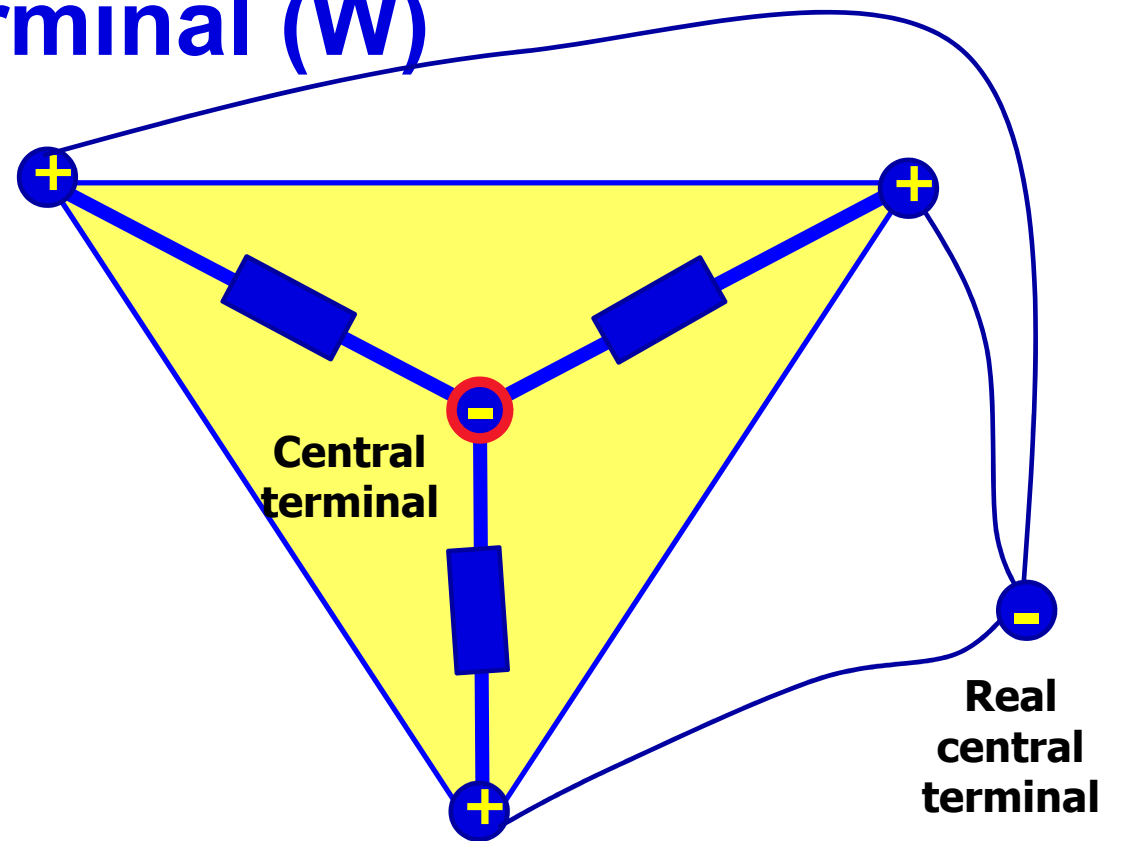
(augmented, limb, unipolar leads)

- Unipolar leads: one electrode is active (variable electric potential) and the other is inactive (constant electric potential, usually 0 mV)
- The active electrode is always positive



# Wilsonova central terminal (W)

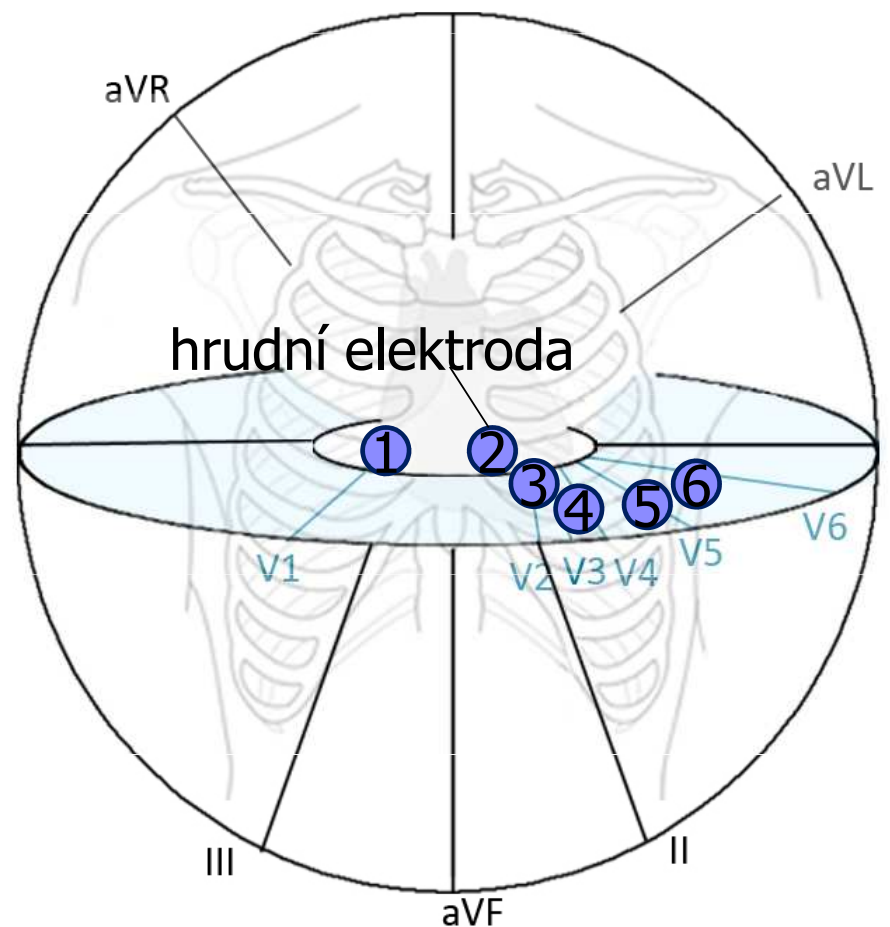
- It is formed by the connection of limb electrodes through resistors
- electrically represents the center of the heart (it is actually led out or it is calculated)
- Inactive electrode (constant potential)



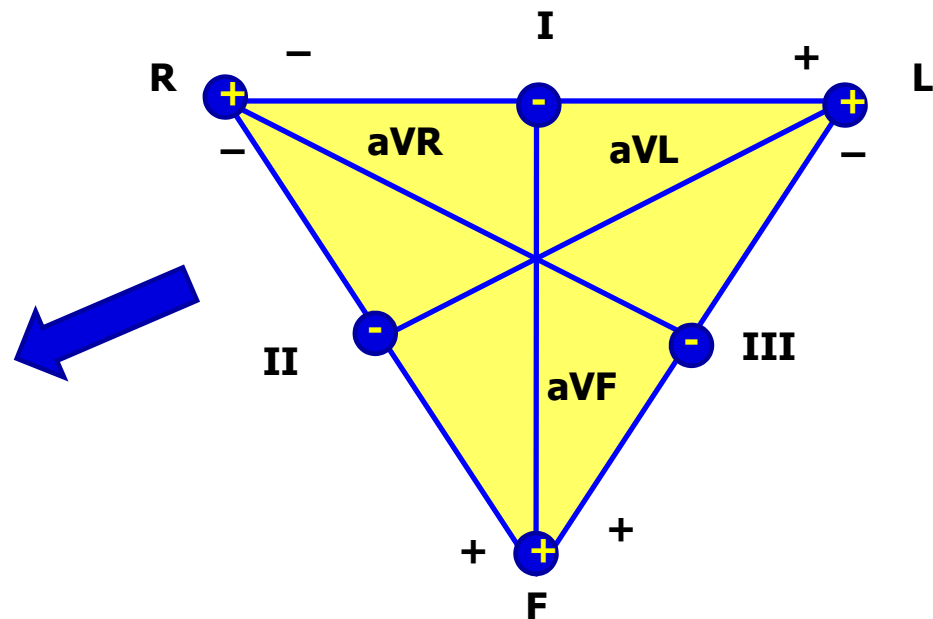
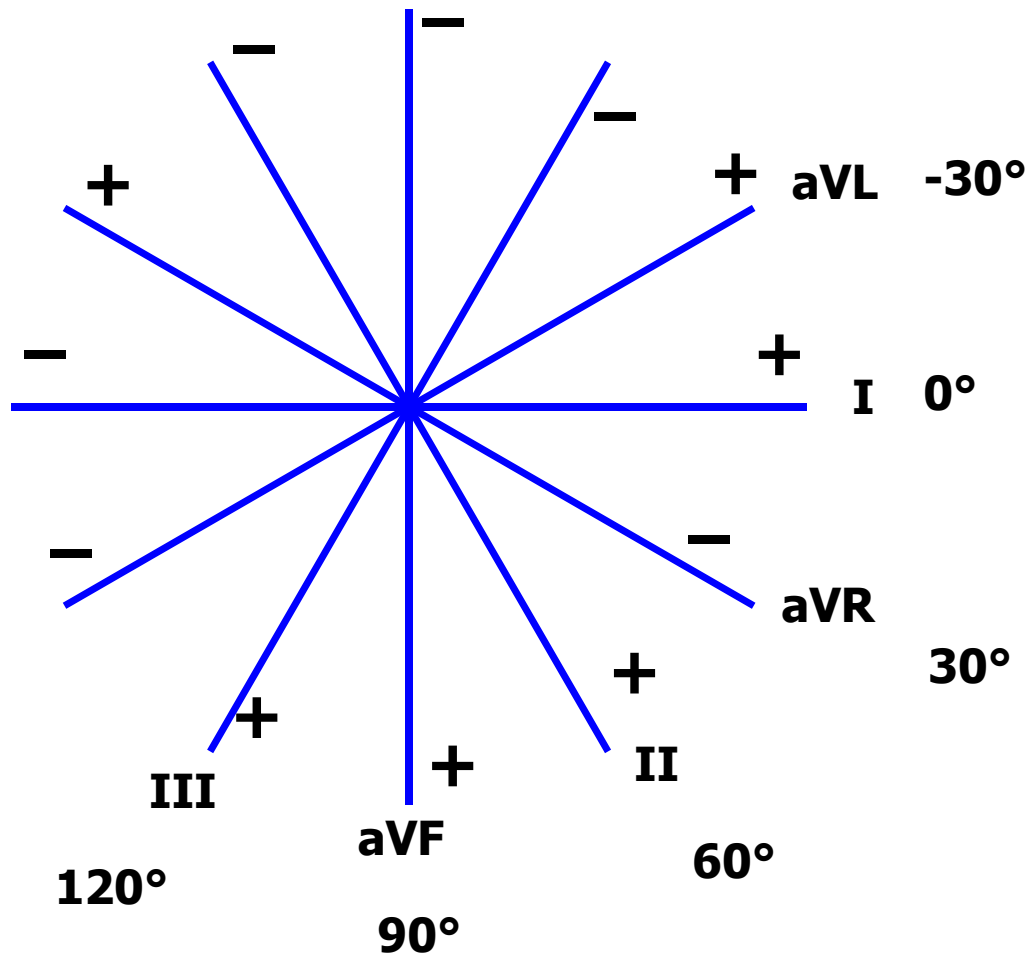


# Chest leads

- Chest lead: connection of chest electrode and central terminal
- Unipolar leads: chest electrode is active (positive) and central terminal is inactive (0 mV potential)

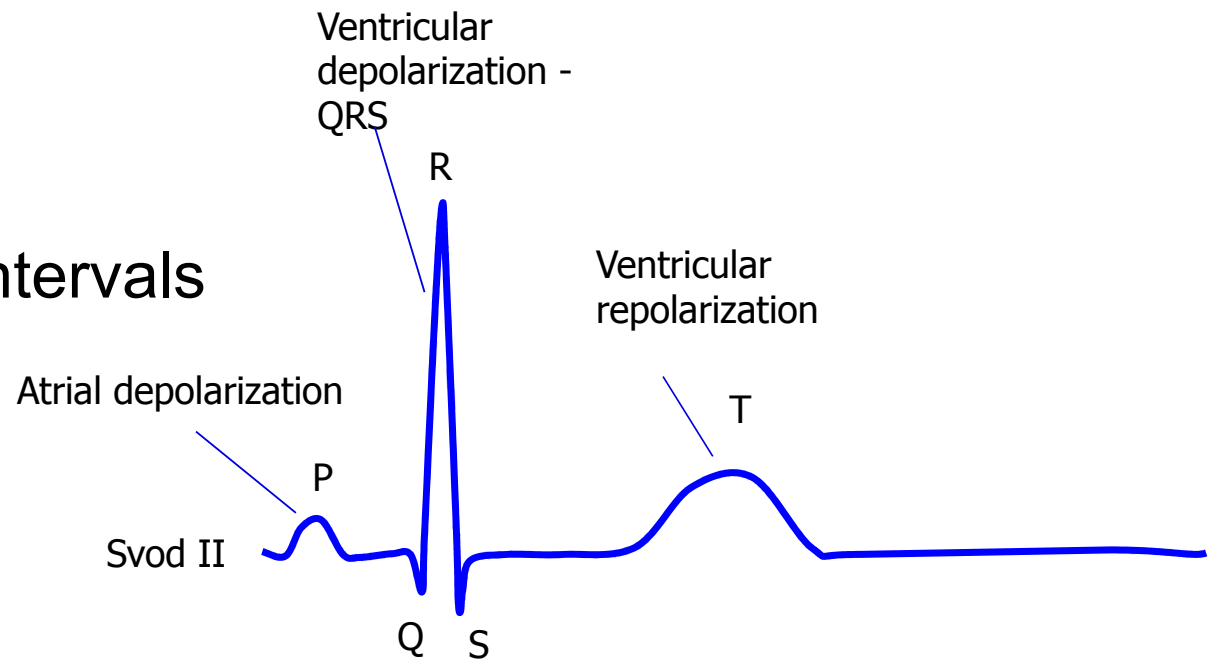


# Leads according to Cabrera



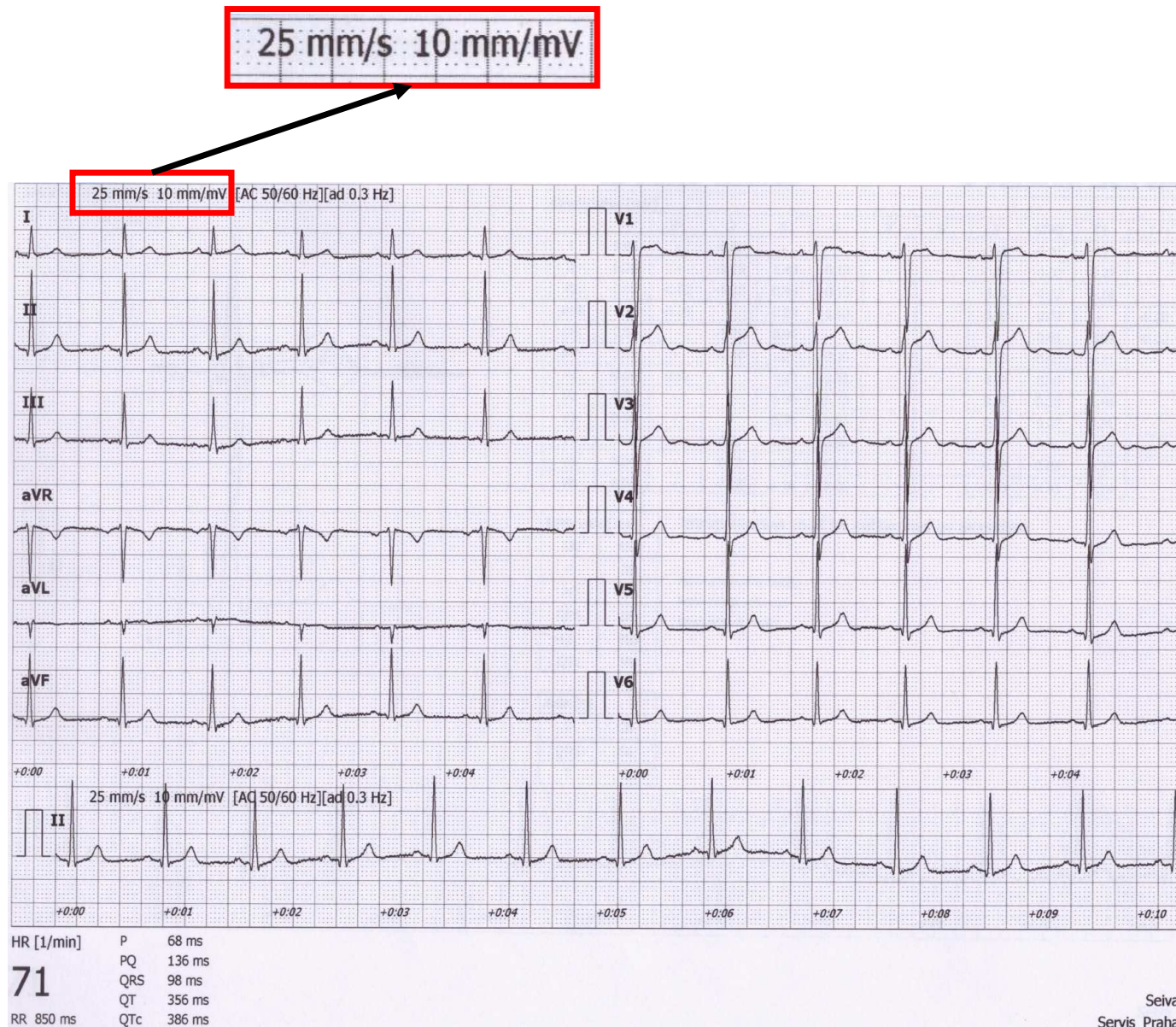
# Analysis of ECG

1. Heart action
2. Heart rhythm
3. Heart rate
4. Waves, segments and intervals
  - P wave
  - PQ interval
  - QRS complex
  - ST segment
  - T wave
  - QT interval
5. Electrical heart axis



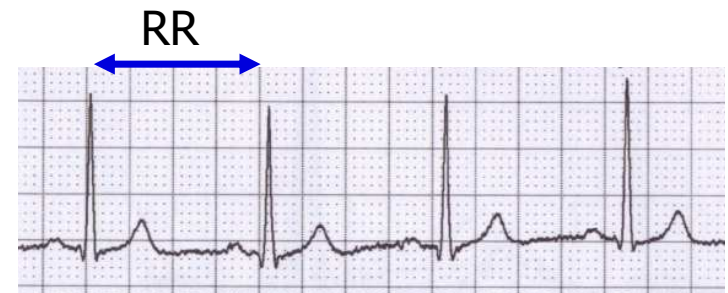
# Analysis of ECG

- A millimeter grid of paper will help in fast analysis
- See the paper speed (here 25 mm / s)
  - How many ms is one mm?
  - It is good to know how much mV is one mm



# 1) Heart action

- Regularity of distances between QRS complexes - RR intervals
- Calculate difference:  $RR - \text{mean } RR$   
(you only need to choose the shortest and longest RR in the record)
- Regular action: difference  $< 0,16$  s
- Irregular action: difference  $> 0,16$  s
  - Usually pathological
  - Beware of significant sinus respiratory arrhythmia - it is very physiological. If you are unsure, ask the patient to hold their breath during recording
- Note: if one extrasystole is present, but otherwise the action is regular, it is called regular



## 2) Heart rhythm

- Heart rhythm is determined by the source of action potentials that lead to ventricular depolarization

ventricular depolarization is crucial, because it determines cardiac output

- **Sinus rhythm**

- AP begins in SA node
- On ECG: present P wave (atrial depolarization) before QRS

- **Junction rhythm**

- AP begins in AV node or His bundle, the frequency is usually 40-60 bpm
- P wave is not before QRS, QRS is normal (narrow)
- Heart rate is low (40-60 bpm)
- Atrial depolarization can be present in the ECG if the ventricular impulses are transferred to the atria - wave is after QRS and has opposite polarity because it runs in opposite direction

- **Tertial (ventricular) rhythm**

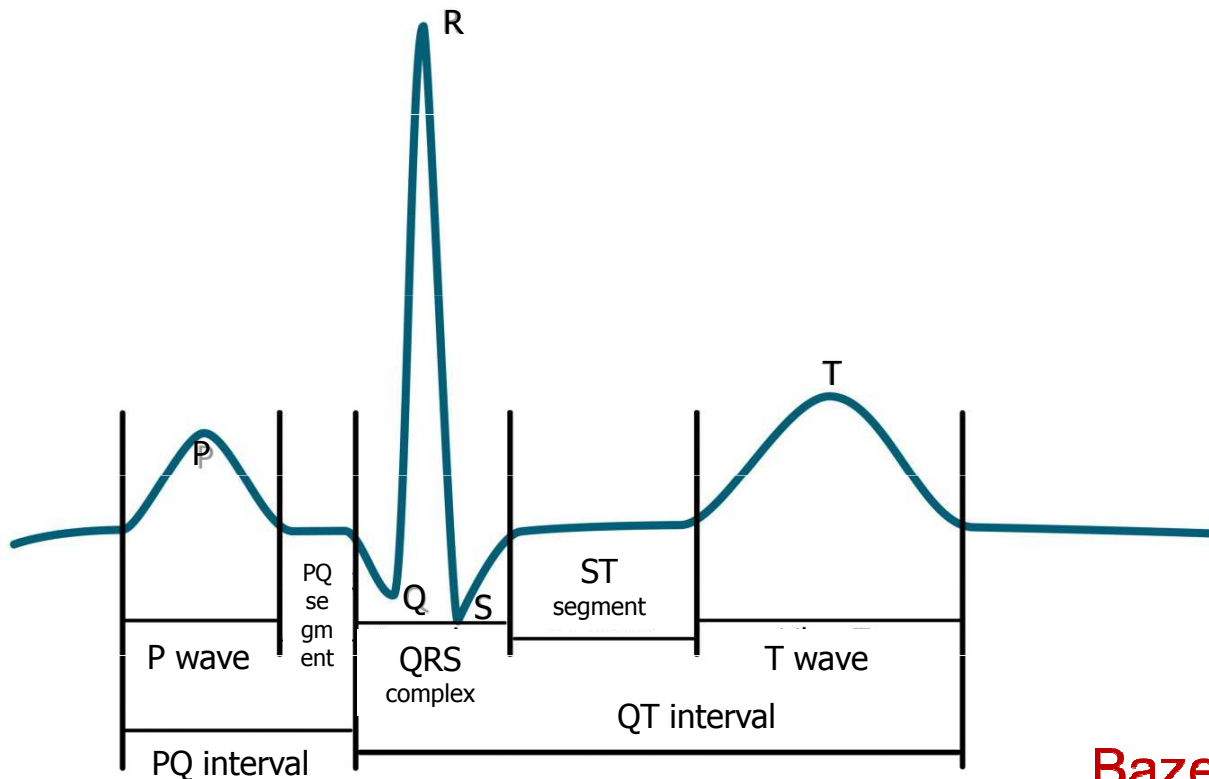
- AP begins in other parts of the conduction system, frequency 30-40 bpm
- QRS has a strange shape (wider), because it spreads in a non-standard direction in the ventricles



### 3) Heart rate (HR)

- Frequency of ventricular contraction (because it determines cardiac output); on ECG - frequency of ventricular depolarizations
- $HR = 1 / RR$  bpm
- Physiological: 60 - 90 bpm at rest
  
- Tachycardia:  $> 90$  bpm in rest
  - Can be sinus (increase sympathetic activity, medication, ...)
  - Tachyarrhythmias: rhythm is not sinus
- Bradycardia:  $< 60$  bpm
  - Can be sinus (increase sympathetic activity, sport heart - physiological)
  - $HR < 50$  bpm, rhythm probably is not sinus

## 4) Waves, segments, intervals



Name	Norm
wave P	80 ms
interval PQ (PR)	120-200 ms
segment PQ (PR)	50-120 ms
Q	-
complex QRS	80-100ms
R	-
S	-
segment ST	80-120 ms
interval QT	< 420ms
wave T	160 ms

**Bazett's formula:**  $QTc = \frac{QT}{\sqrt{RR}}$

QT depends on RR interval –  
correction of QT on RR



## 4) Waves, segments, intervals

name	Place and description	Physiological background	Norm
<b>wave P</b>	First round wave (negative or positive)	Atrial depolarization	80 ms
<b>Interval PQ (PR)</b>	Interval from beginning of P to beginning of Q (or R, if Q is not present)	Time interval from SA node activation to the Purkynje fibers activation	120-200 ms
<b>segment PQ (PR)</b>	From P wave end to beginning of Q (or R, if Q is not present)	Complete atrial depolarization, AP transfer from AV to ventricles	50-120 ms
<b>Q</b>	First negative deflection	Depolarization of septum and papilar muscles	-
<b>complex QRS</b>	From beginning of R to end of S	Ventricular depolarization	80-100ms
<b>R</b>	Positive deflection	Main ventricular depolarization	-
<b>S</b>	Negative deflection after positive deflection.		-
<b>segment ST</b>	Interval of isoelectric line between end of QRS and beginning of T wave	Complete depolarization of ventricles	80-120 ms
<b>Interval QT</b>	From beginning of Q (or R) to the end of wave T	Electrical systole	< 420ms
<b>wave T</b>	Second round wave (negative or positive)	Ventricular repolarization	160 ms

# 4) Waves

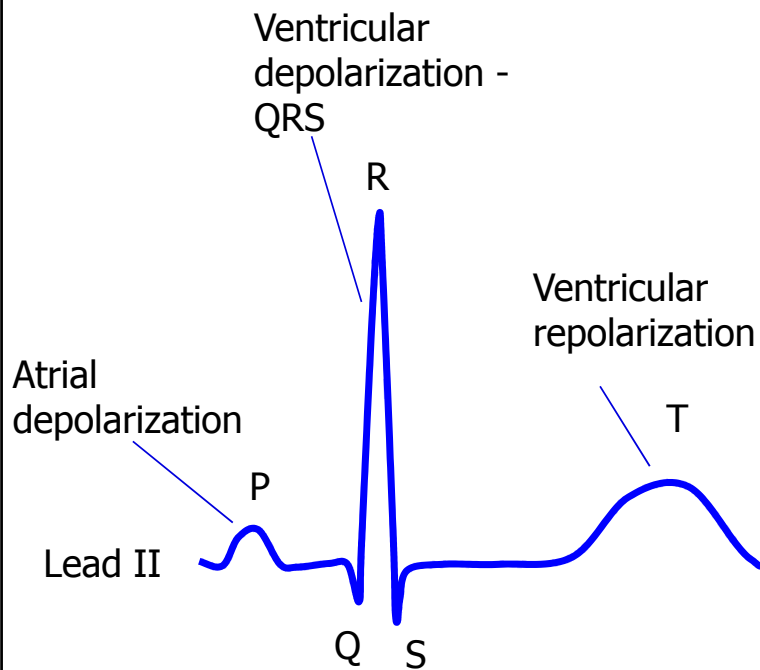
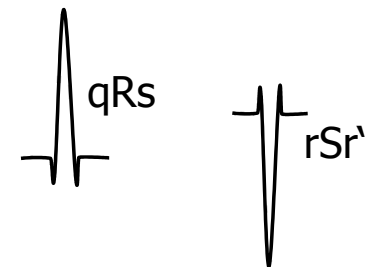
Wave P:

- Is present?
- Is positive/negative, one-peak/two-peak, high(>0,25mV)/normal/low?

QRS:

- Q: first negative deflection
- R: first positive deflection
- S: negative deflection after positive deflection

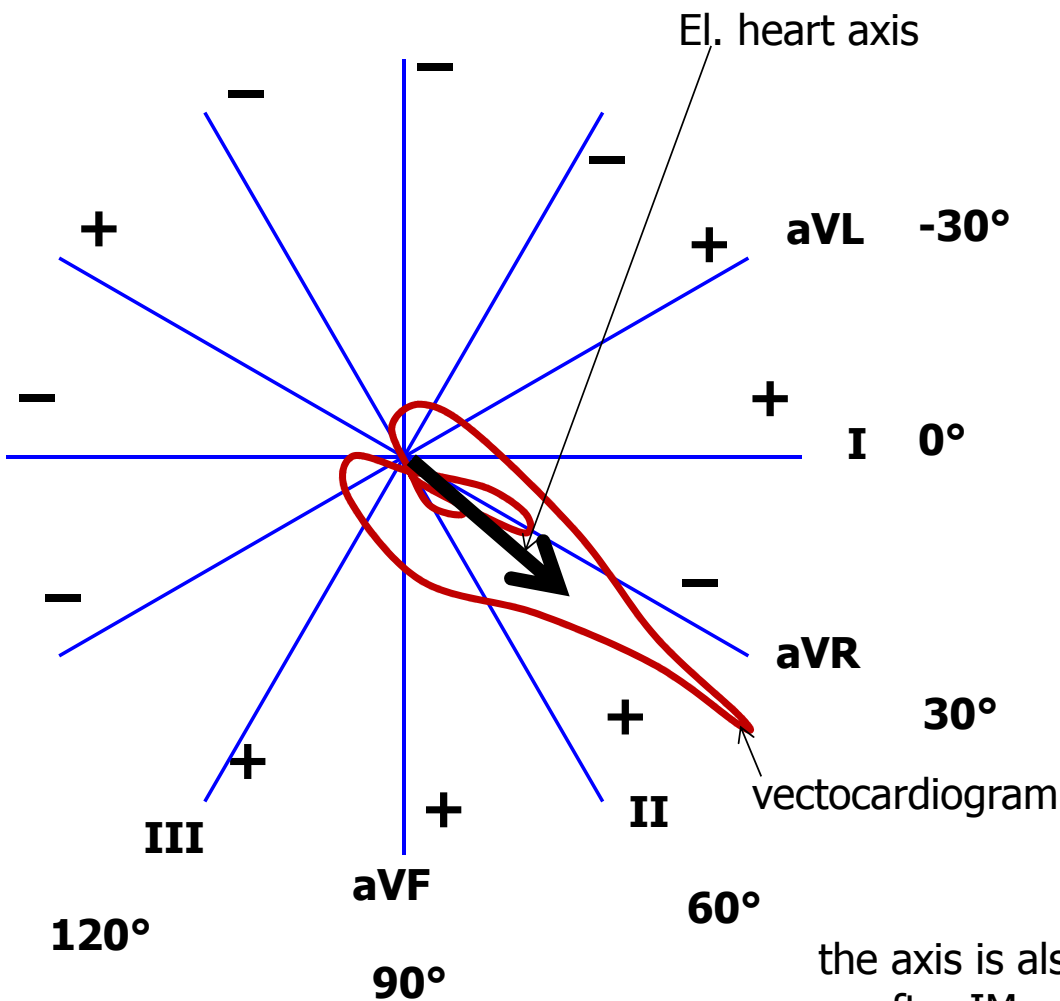
- small deflection (pod 0,5 mV) – small letter
- Strong deflection – capital letter
- Second positive deflection (')



Wave T:

- Is positive/negative/bipolar?
- Does it have the same polarity as the strongest QRS deflection?
  - Yes: concordant (ok), No: discordant (pathology)
- Bipolar T:
  - Preterminal negative (-/+)
  - Terminal negative (+/-)

# 5) Electrical heart axis



**Electrical heart axis: average direction of the electric heart vector during ventricular depolarization (QRS complex)**

(can also be determined for atrial depolarization: P, or ventricular repolarization: T, but in practice we will analyse ventricular depolarization)

Heart axis is physiologically directed down, left, back - refers to the real placement of the heart in the chest.  
- Here we solve only the frontal plane (limb leads)

**Physiological range:**

- Middle type 0° – 90°
- Left type -30° - 0°
- Right type 90° - 120°

**Pathological range:**

- Right deviation: > 120 ° (P ventricular hypertrophy, dextrocardia)
- Left deviation: < -30° (L ventricular hypertrophy, pregnancy, obesity)

the axis is also changed when Tawara branches are blocked or after IM, missing el. activity of part of chambers

# Electrical heart axis - evaluation

- Because the el. axis is related to ventricular depolarization in the frontal plane, use QRS in limb leads: I, II, III.
- Calculate the sum of QRS oscillations in leads I, II, III.  
When the oscillation is down, it is negative. When the oscillation is up, it is positive. Use a millimeter grid

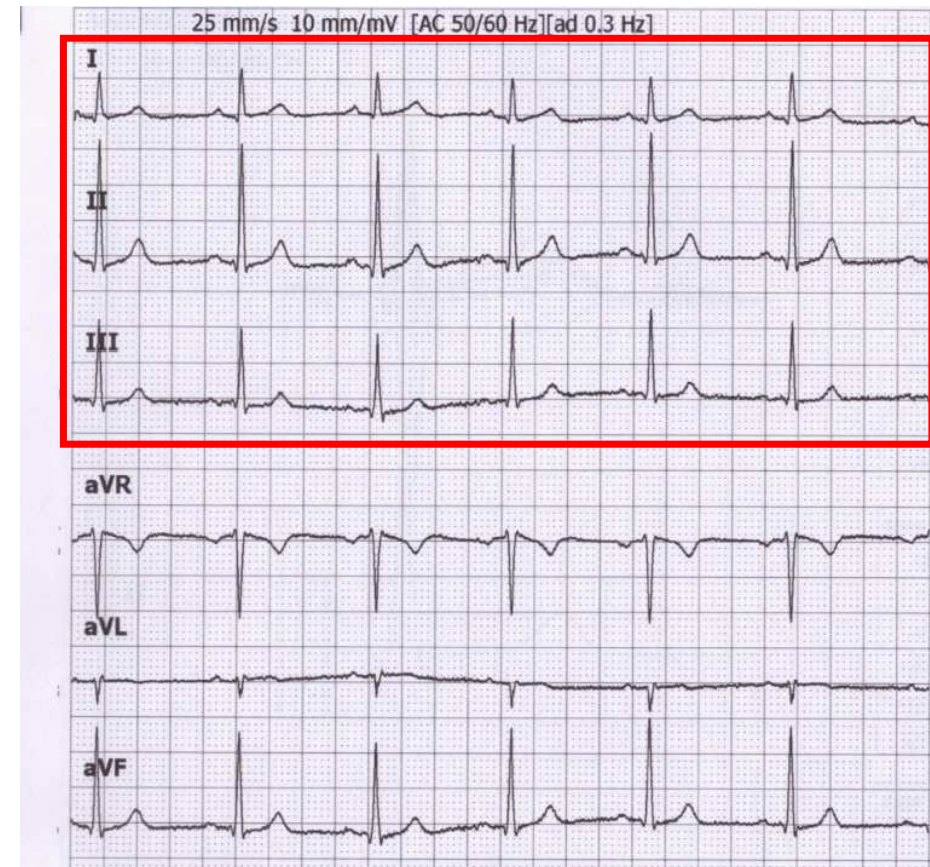
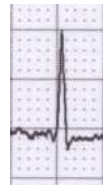- Lead I:  $Q_I = -1$ ;  $R_I = 6$ ;  $S_I = 0$ ;  
 $QRS_I = 5$



- Lead II:  $Q_{II} = -1$ ;  $R_{II} = 17$ ;  $S_{II} = -1$ ;  
 $QRS_{II} = 15$

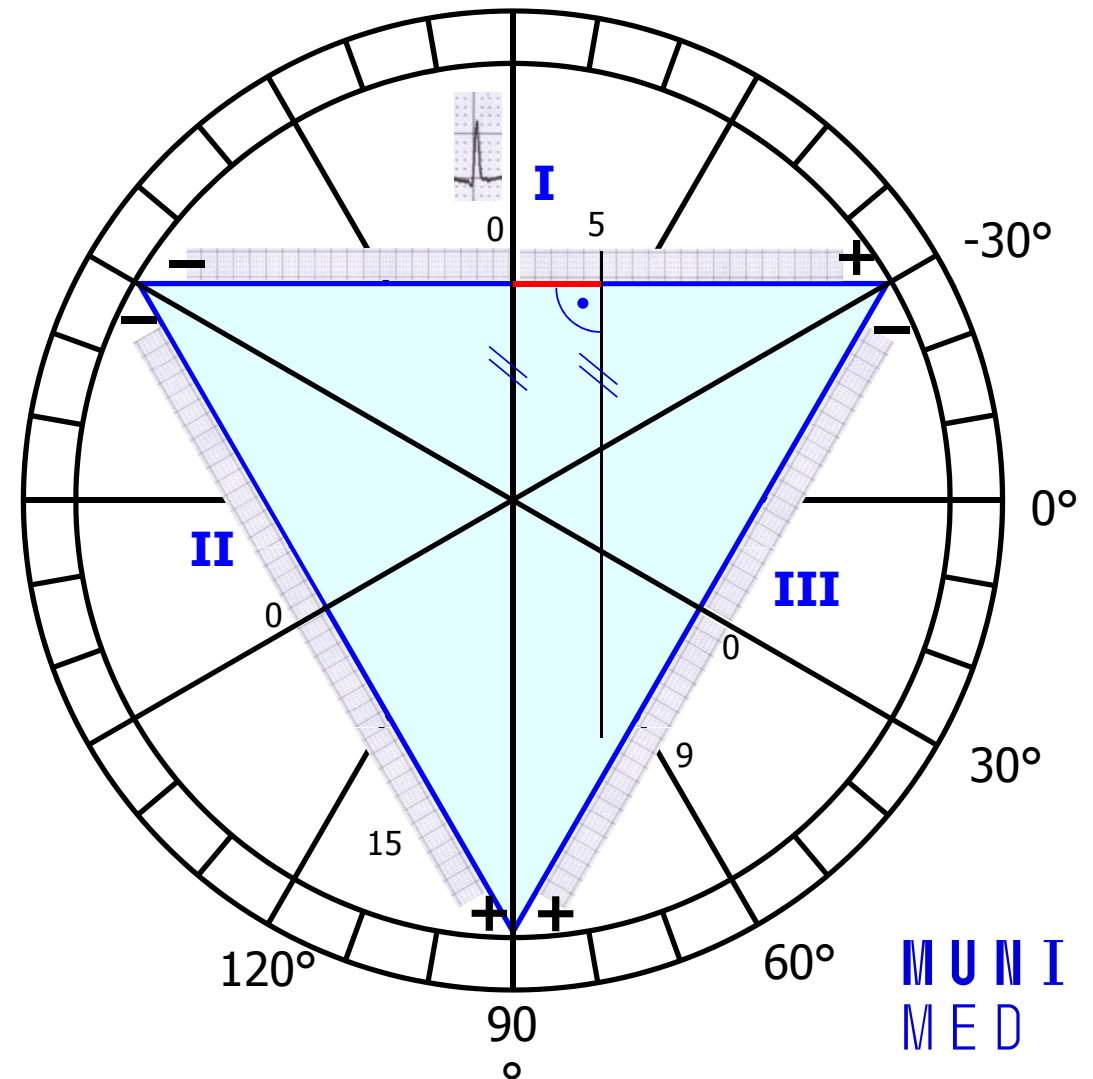


- Lead III:  $Q_{III} = 0$ ;  $R_{III} = 10$ ;  $S_{III} = -1$ ;  
 $QRS_{III} = 9$



# Electrical heart axis - evaluation

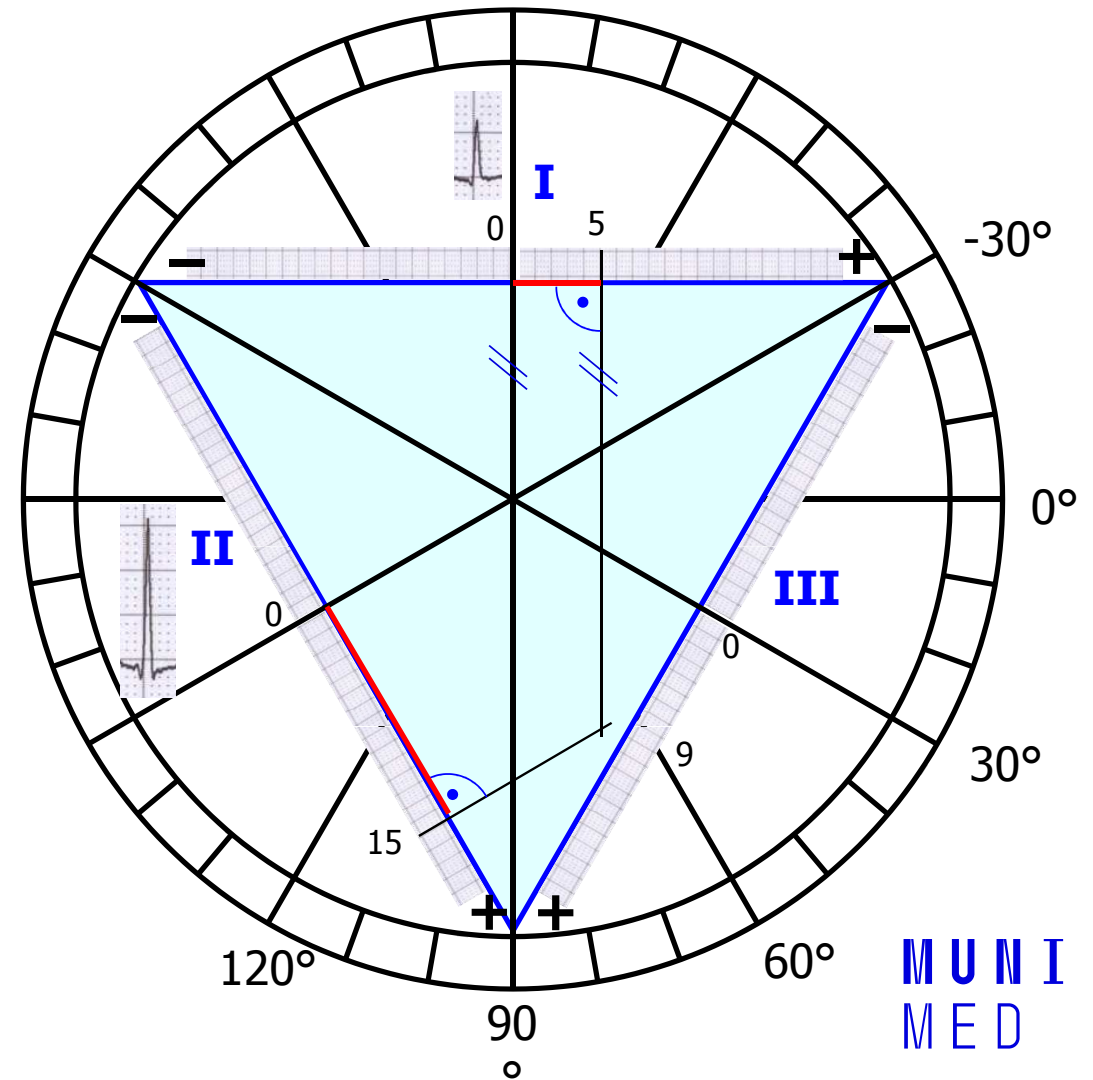
- Draw the Einthoven Triangle with Goldberger augmented Leads
- Mark the angles around the triangle (in the circle)
- Lead I:
  - 0 at lead I is in the center of lead
  - $QRS_I = 5$ , so from 0, measure 5mm towards the positive electrode, make a mark (or any other units, ratio is important)
  - If the sum of QRS is negative, you will go towards the negative electrode
  - Run a line from the mark perpendicular to the I lead (parallel to the aVF lead)



# Electrical heart axis - evaluation

## — Lead II:

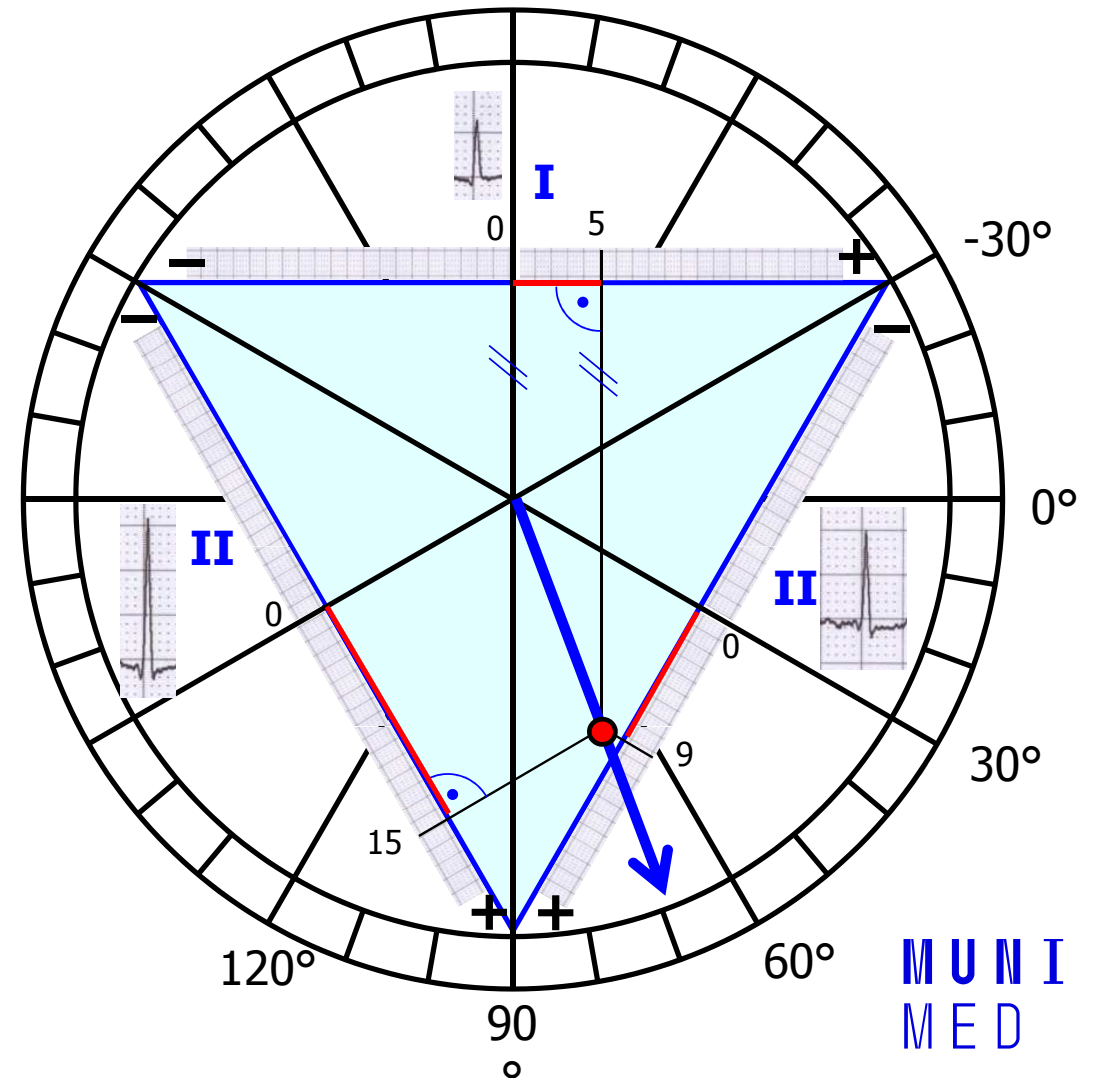
- 0 at lead II is again in the center of lead
- $QRS_{II} = 15$ , so from 0, measure 15 mm towards the positive electrode, make a mark (again, if the sum of QRS is negative, you will go towards the negative electrode)
- Run a line from the mark perpendicular to the II lead (parallel to the aVL lead)



# Electrical heart axis - evaluation

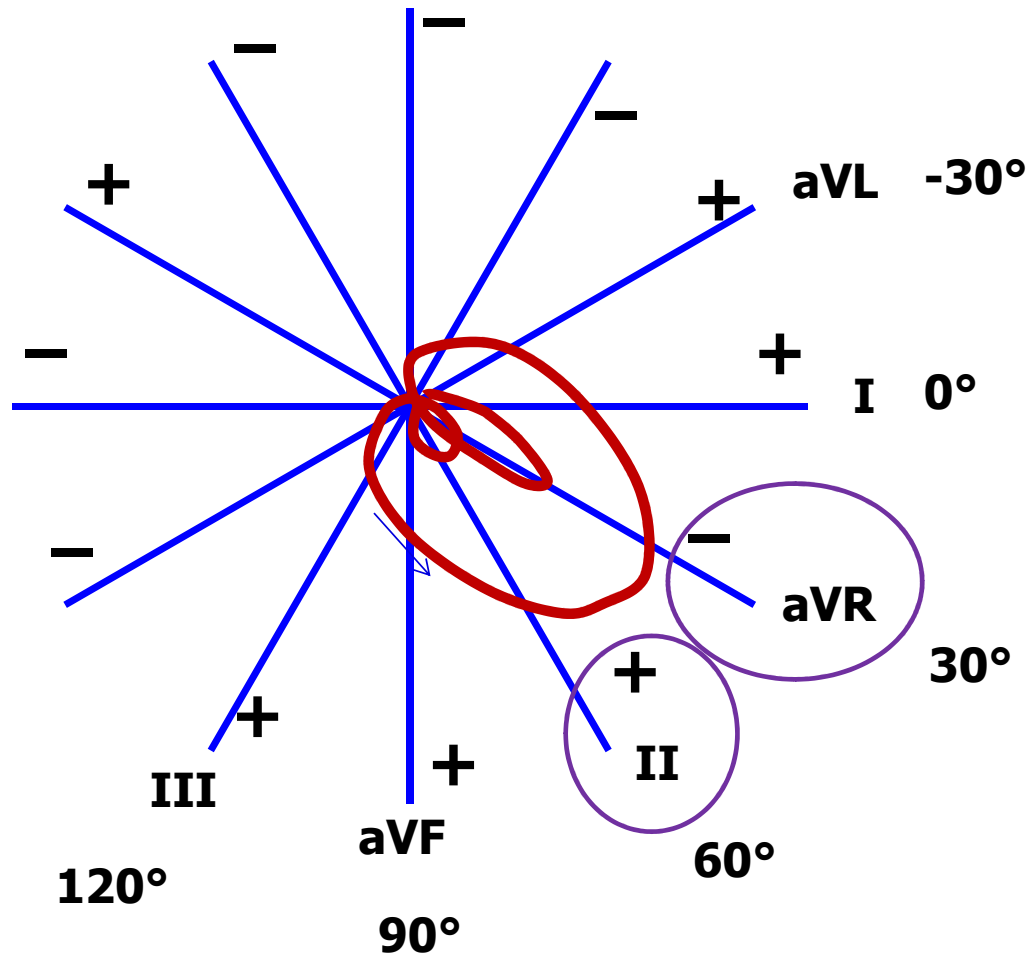
- Lead III:
  - The same way draw line for  $QRS_{III} = 9$
- Draw an arrow that starts at the center of the triangle and passes the cross of the drawn lines
- This arrow shows the direction of the cardiac electrical axis in the frontal plane
- Note. logically, only lines from two leads are sufficient

The cardiac electrical axis for ventricular depolarization in the frontal plane is  $70^\circ$

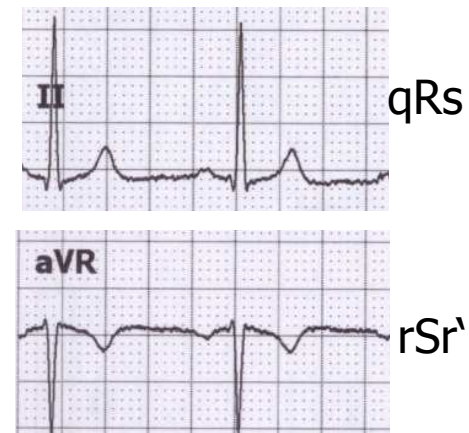




# Leads II a aVR



Note the appearance of the ECG in lead II and aVR. Both leads look at electrical cardiac activity from a similar angle (deviation only  $30^\circ$ ), but the aVR has the opposite polarity (it looks at the heart upside down compared to II). Therefore, leads II and aVR are similar, only mirror-inverted.

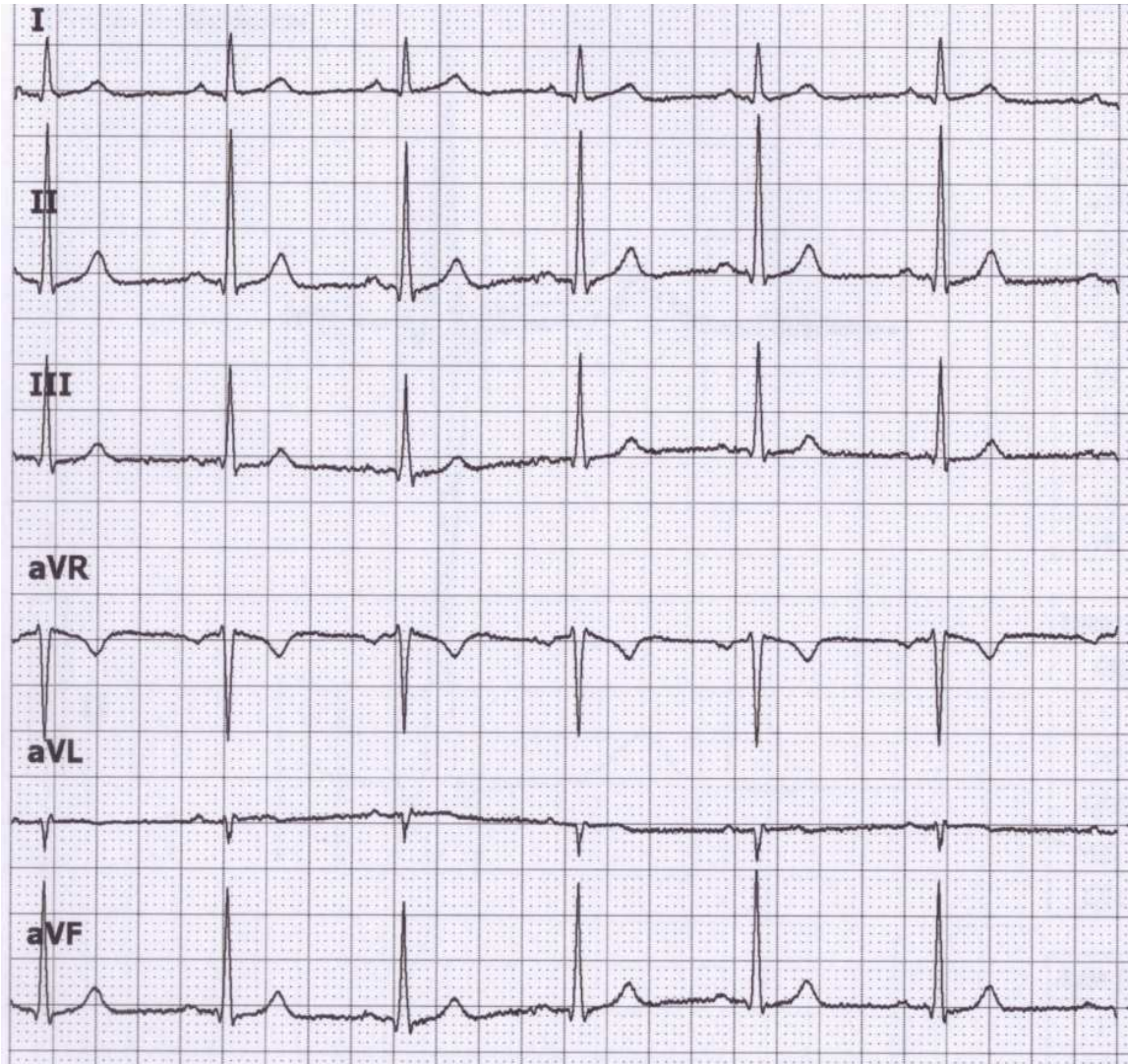


aVR usually has negative T and P

Due to its different appearance, QRS has different description in lead aVR and II.



# QRS in limb leads and axis



amplitudes of Q, R, and S	Sum of QRS	description of QRS
Q = -1 R = 6 S = 0	QRS = 5	qR
Q = -1 R = 17 S = -1	QRS = 15	qRs
Q = 0 R = 10 S = -1	QRS = 9	Rs
Q = 1 R = -11 S = 0	QRS = -10	rS
Q = 0 R = -3 S = 0	QRS = -3	q
Q = -1 R = 13 S = -1	QRS = 11	qRs

amplitudes of Q, R, and S Sum of QRS

I  
 Q = -1  
 R = 6 QRS = 5  
 S = 0

II  
 Q = -1  
 R = 17 QRS = 15  
 S = -1

III  
 Q = 0  
 R = 10 QRS = 9  
 S = -1

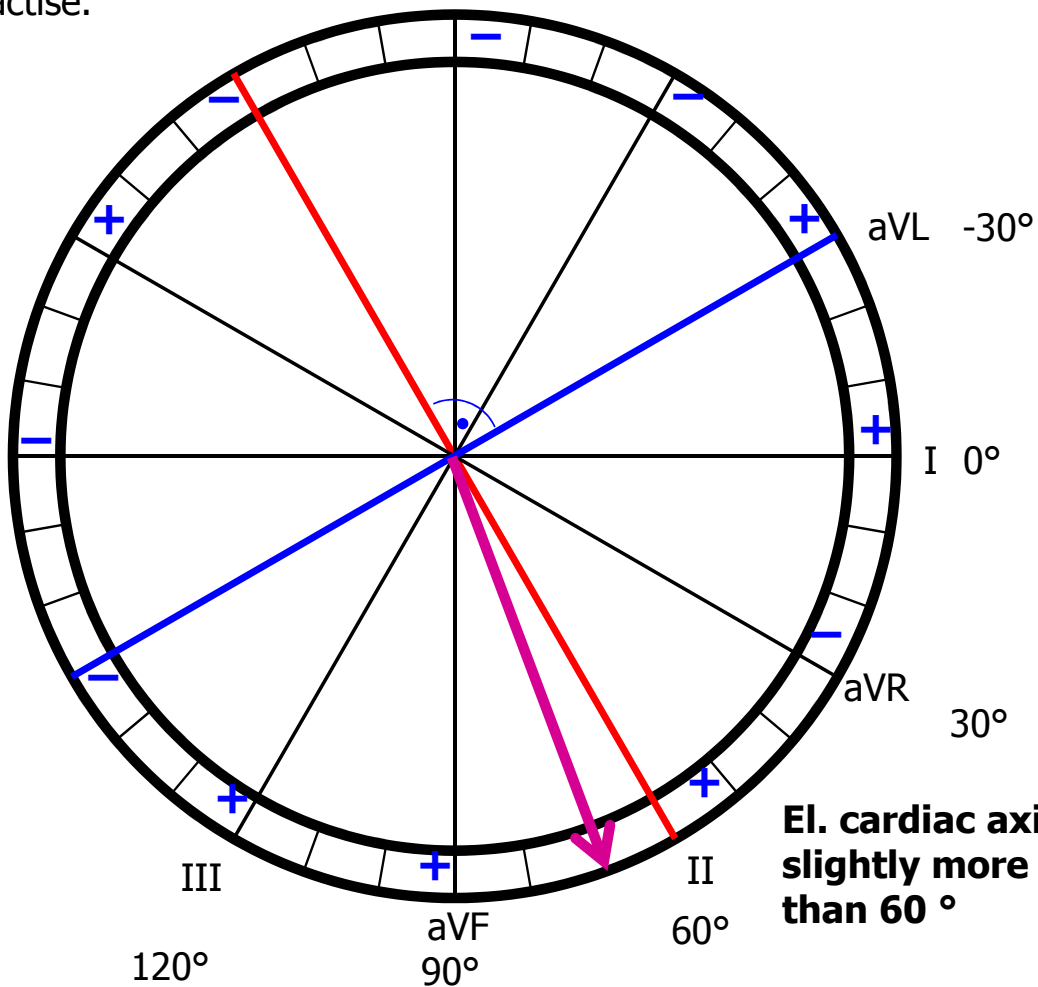
aVR  
 Q = 1  
 R = -11 QRS = -10  
 S = 0

aVL  
 Q = 0  
 R = -3 QRS = -3  
 S = 0

aVF  
 Q = -1  
 R = 13 QRS = 11  
 S = -1

### Electric axis estimation

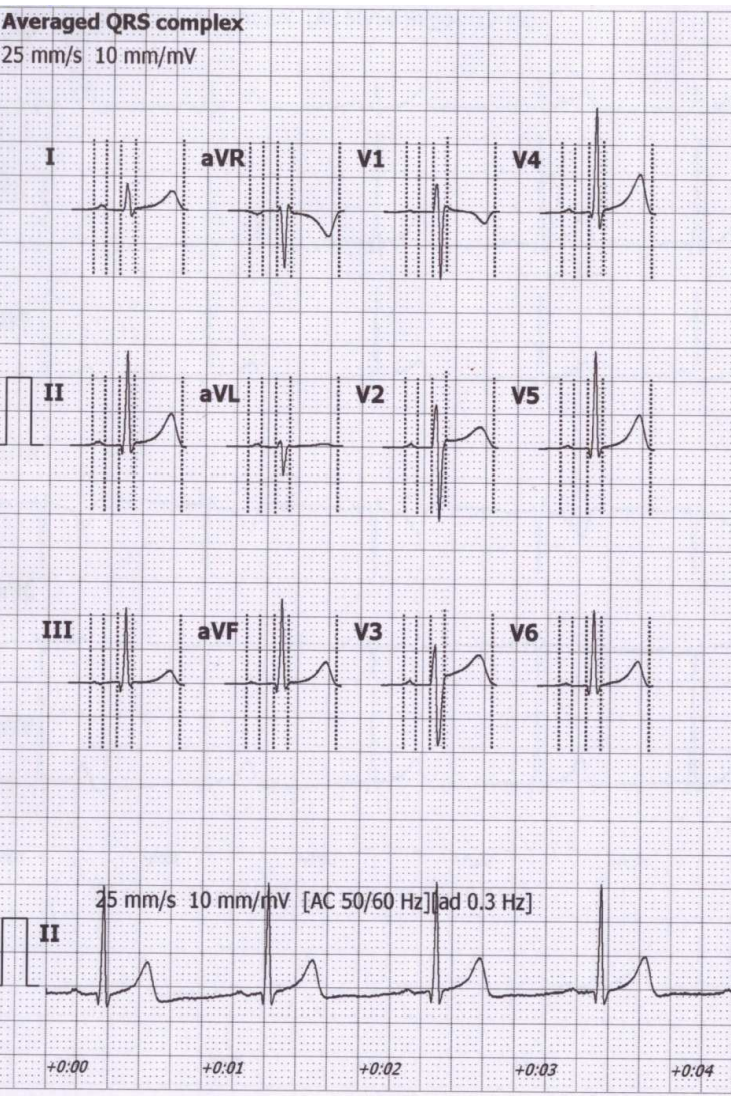
Find the lead with the largest and smallest sum of QRS (just by eye) - these leads will be perpendicular to each other. The angle of lead with the largest sum of QRS will determine approximately el. heart axis. It is not be perfectly accurate, but it is sufficient in practise.



El. cardiac axis slightly more than 60°



# Electric axis calculation by software



Amplitudes [mV]											
	P+	P-	Q	R	S	R'	S'	J	ST40	T+	T-
I	0.06	-	-	0.40	-0.09	-	-	0.03	0.03	0.28	-
II	0.05	-	-0.14	1.40	-0.12	-	-	0.03	0.05	0.48	-
III	0.02	-0.03	-0.16	1.10	-0.07	-	-	0.01	0.02	0.21	-
aVR	-	-0.05	-	0.07	-0.85	0.09	-	-0.03	-0.04	-	-0.37
aVL	0.04	-	-	0.11	-0.40	0.05	-	0.01	0	0.04	-
aVF	0.03	-	-0.15	1.25	-0.09	-	-	0.02	0.03	0.34	-
V1	0.02	-0.02	-	0.41	-1.02	0.09	-	0.08	0.03	-	-0.18
V2	0.05	-	-	0.63	-1.10	-	-	0.11	0.11	0.30	-
V3	0.06	-	-	0.59	-0.92	-	-	0.09	0.15	0.42	-
V4	0.05	-	-0.09	1.55	-0.26	-	-	0.04	0.07	0.58	-
V5	0.04	-	-0.16	1.43	-0.14	-	-	0.02	0.05	0.51	-
V6	0.04	-	-0.15	1.12	-0.13	-	-	0.01	0.04	0.37	-

Intervals [ms]	
RR	1031
P	81
PQ	173
QRS	93
QT	401
QTc	395

Interpretation must be authorized by physician

- Automatic marker setting
- Patient's age unknown
- Bradycardia

Axis [°]	
P	15
QRS	72
T	49

Electrical axis for atrial depolarization

72° Electrical axis for ventricular depolarization

Electrical axis for ventricular repolarization

HR [1/min]

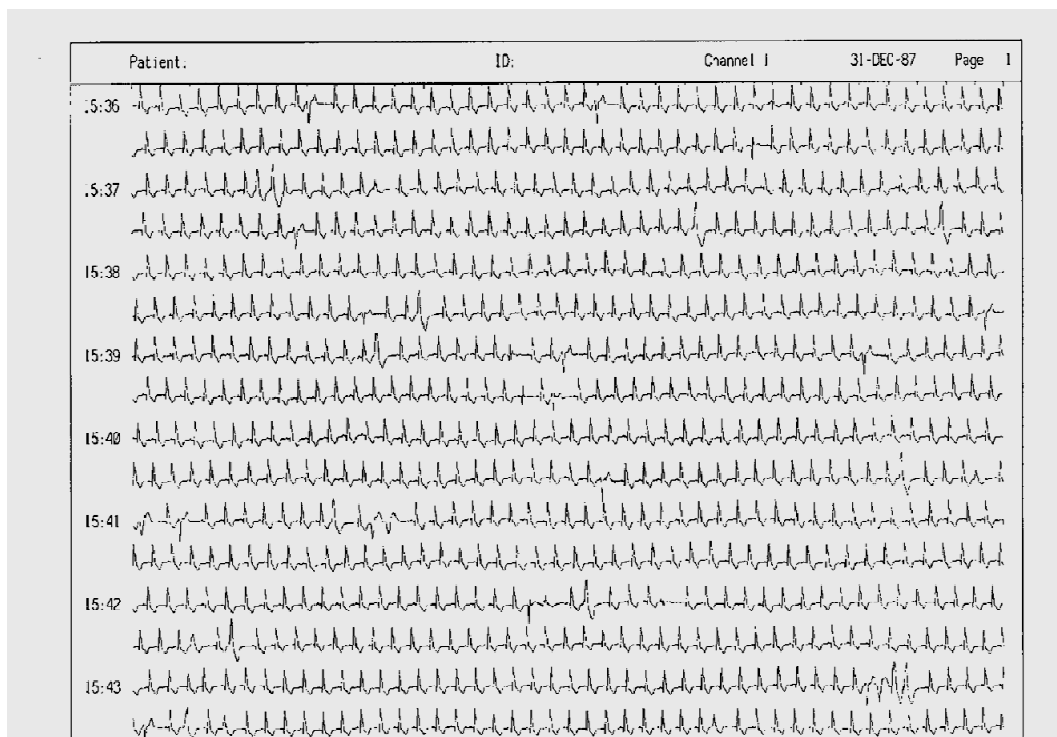
58

**MUNI  
MED**

# **Diagnostic use of ECG**

# ECG Holter

## 24-hour monitoring of ECG

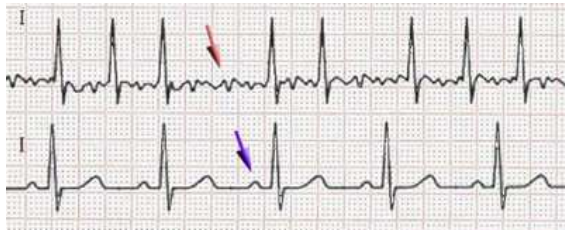


**Arrhythmia:** a disorder of heart rhythm, formation or conduction of the excitation

## Fibrillation

Fibrillation: unsynchronized cardiomyocyte activity. Cardiac muscle is „shaking“

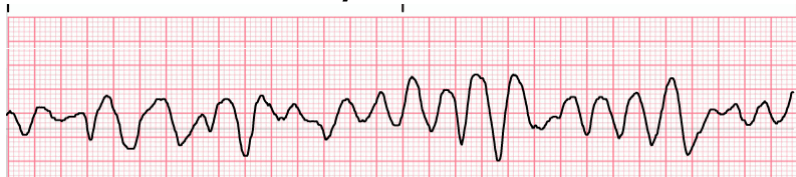
**Atrial** – missing P, slightly irregular "serrated" isoline, irregular RR (usually), frequency 80 - 180 bpm. QRS is normaly shaped. It is not life threatening. Ventricular refraction time protects ventricles from HR higher than 180 bpm, but it still exhausts the heart. Heart activity is not regulated. Risk of trombembolia



Fibrillation

Normal ECG

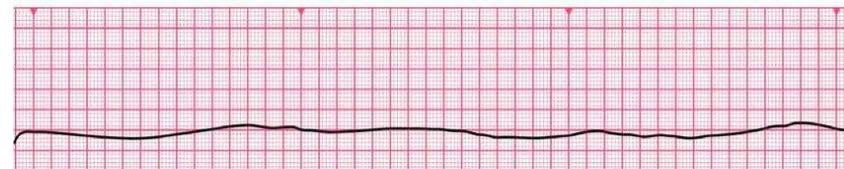
**Ventricular** – the heart does not function as a pump (cardiac arrest), zero cardiac output, brain damage after 3 - 5 minutes of fibrillation, without early defibrillation the cardiomyocytes become exhausted → asystole



→ Cardio-Pulmonary Resuscitation (CPR), early defibrillation (adrenalin and amiodaron)

Video: [https://www.youtube.com/watch?v=IU3NHrjw-IA&ab\\_channel=NerdDoctor](https://www.youtube.com/watch?v=IU3NHrjw-IA&ab_channel=NerdDoctor)

**Asystole** – no electrical activity of cardiomyocytes, non-defibrillable



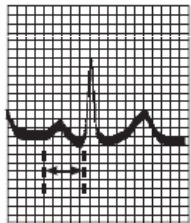
→ CPR and adrenalin



# Atrioventricular block (heart block)

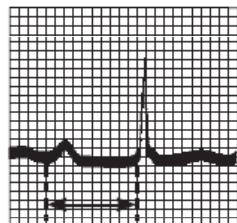
**AV block:** disorder of the transmission of depolarization from the atria to the ventricles

## AV block I. degree



PR = 0.16 s

Normal complex



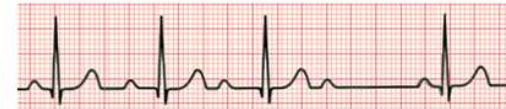PR = 0.38 s

First-degree heart block

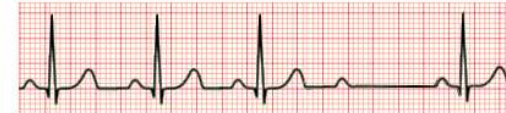prolongation of the transfer of depolarization from the atrium to the ventricles, prolonged PQ

## AV block II. degree

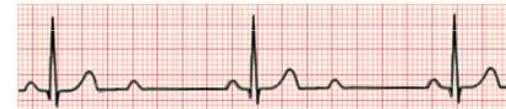Mobitz I or Wenckebach



Mobitz II

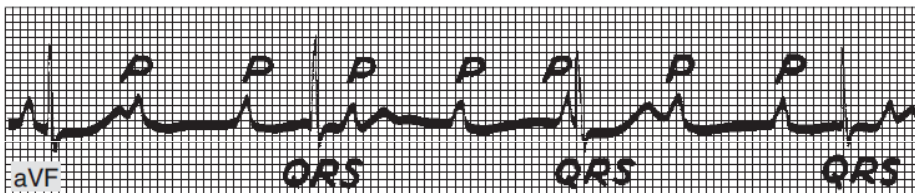


2:1 block



some atrial depolarizations do not transfer: occurrence of P, which is not followed by QRS

## AV block III. degree



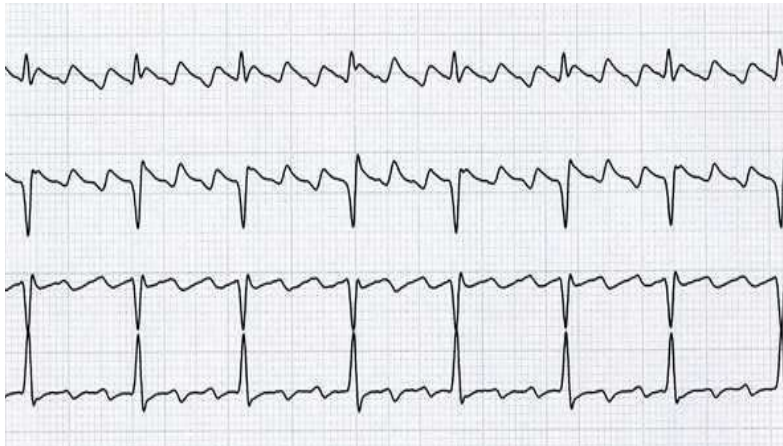
Complete heart block. Atrial rate, 107; ventricular rate, 43

A complete blockage of the transfer of depolarization from the atria to the ventricles, P and QRS are not synchronized  
Pulse rate possibly very low → insufficient cardiac output

[https://upload.wikimedia.org/wikipedia/commons/thumb/6/64/Afib\\_ecg.jpg/400px-Afib\\_ecg.jpg](https://upload.wikimedia.org/wikipedia/commons/thumb/6/64/Afib_ecg.jpg/400px-Afib_ecg.jpg)  
<http://www.queshiuniversity.com/Ventricular%20Fibrillation.gif>  
<https://ekg.academy/ekgtracings/313.gif>

MUNI  
MED

# Artial flutter



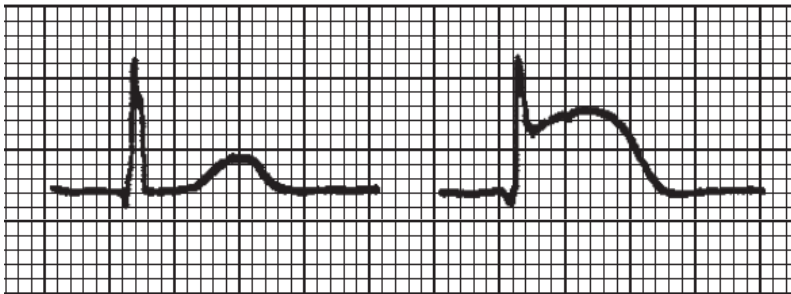
- Regular „teeth“ between the QRS.
- Regular RR, tachycardia.
- The basis is the atrial re-entry.
- The regularity is given by the number of "turns" of atrial depolarization per transfer to the chambers (in the picture: 3 turns per 1 transfer to the chambers, ie 3:1).
- If the flutter does not disappear, it changes into atrial fibrillation
- Danger of the deblocked flutter 1:1 (each atrial turn is transferred in ventricles) – exhaustion of ventricles
- Risk of trombembolia



# Diagnostic use of ECG

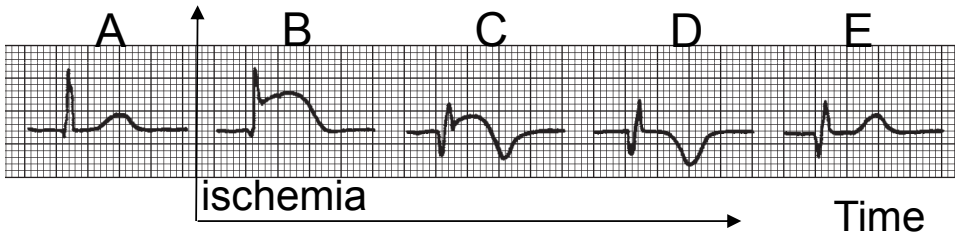
Cardiac ischemia, myocardial infarction

Electrolyte dysbalance - hyperkalemia



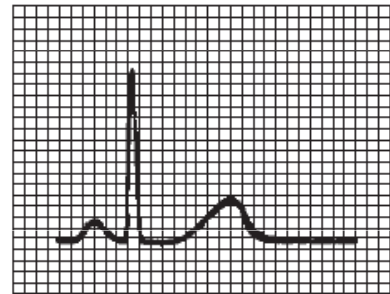
normal

ST elevation,  
sign of ischemia

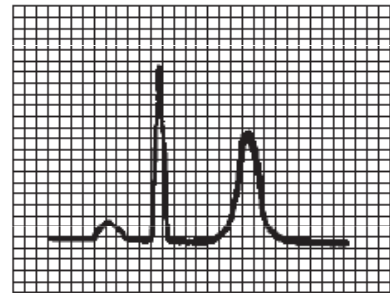


ischemia

Time



Normal tracing (plasma  $K^+$  4–5.5 meq/L).

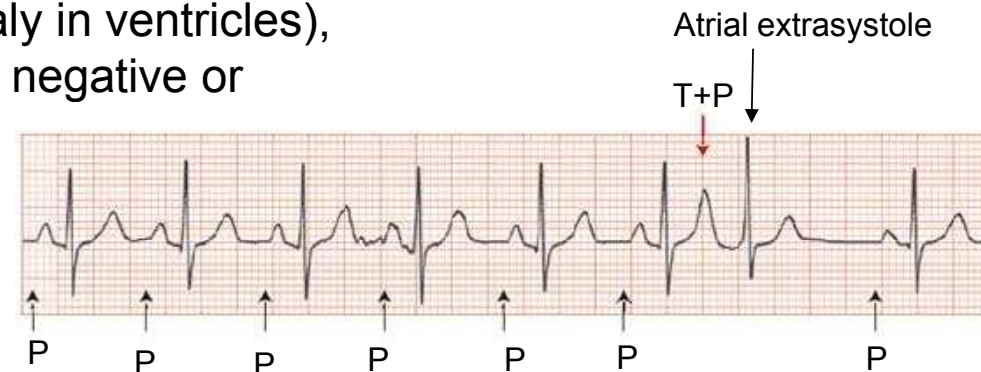
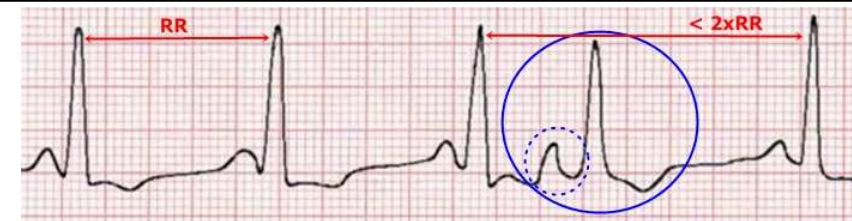


Large QRS, high T

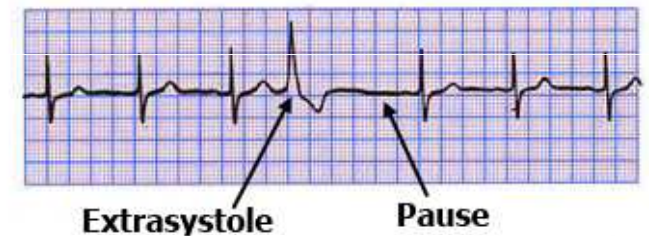
Hyperkalemia (plasma  $K^+$   $\pm$ 7.0 meq/L).

# Extrasystoles - ectopic excitements

- Supraventricular – atrial
  - normal shape of QRS (depolarization spreads normaly in ventricles),
    - P wave does not have a normal shape (it can be negative or covered by QRS),
    - may have a postextrasystolic pause (re-propagation of depolarization through the atria)
- Ventricular
  - Large, non-normal shape of QRS
  - at a slow heart rate there is no compensatory pause (extrasystole is interspersed between normal QRS)
  - or contains a compensating pause if the next depolarization coming from the SA node comes at a time when the ventricles are still refractory

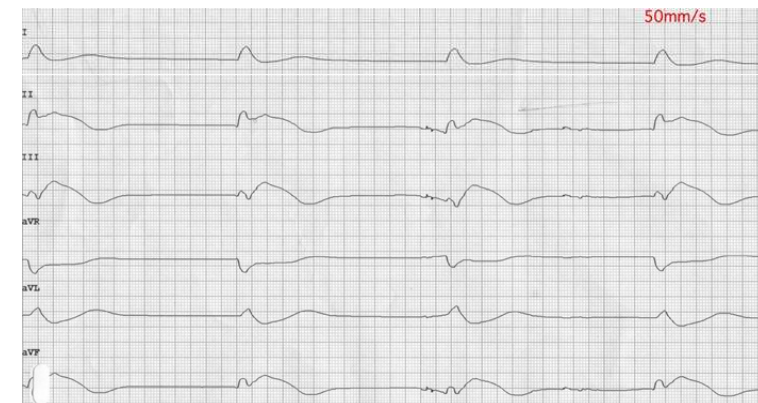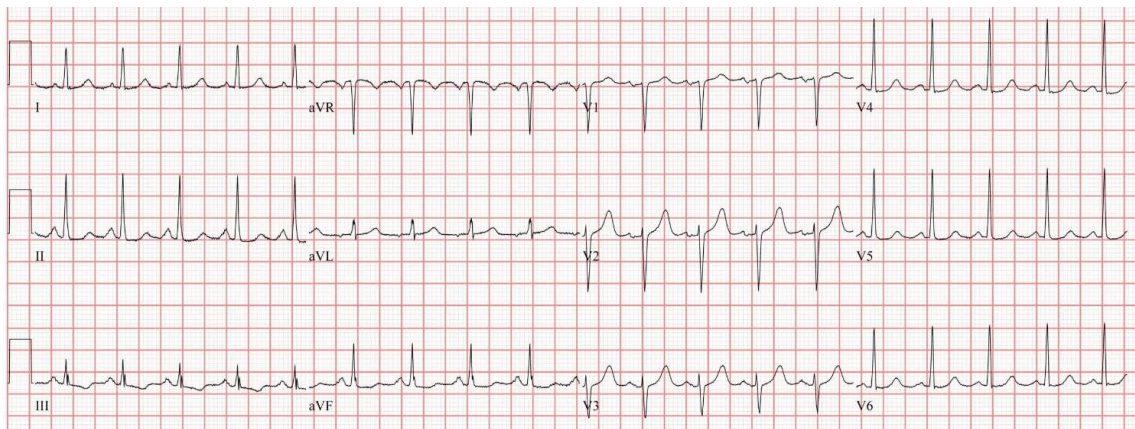


**Ventricular Extrasystole**



# PEA – pulseless electrical activity

- PEA refers to cardiac arrest in which the electrocardiogram shows a heart rhythm that should produce a pulse, but it does not. PEA can look almost like normal ECG activity. Pulseless electrical activity is found initially in about 55% of people in cardiac arrest.
- Under normal circumstances, electrical activation of muscle cells precedes mechanical contraction of the heart (known as *electromechanical coupling*). In PEA, there is electrical activity but insufficient cardiac output to generate a pulse and supply blood to the organs.
- **PEA is classified as a form of cardiac arrest.**
- **non-defibrillable, therapy: Cardio-Pulmonary Resuscitation and adrenalin**
- **Important !: Regular electrical activity on ECG does not mean maintained circulation. Always check for a central arterial pulse.**





# 11 Rhythms Nurses Need to Know

## Basic EKG/ECG Rhythms

Common & Formal Rhythm Names	6 Second Rhythm Strip	Identifiers
<b>S H O C K A B L E</b>	<b>V-Fib</b> Ventricular Fibrillation	 NO PULSE      Rate: Unmeasurable Irregular, No P Wave, No QRS
	<b>V-Tach</b> Ventricular Tachycardia	 NO PULSE      Wide QRS      Rate: Fast (100-250 bpm) Regular, No P Wave, Wide QRS
	<b>Torsade de Pointes</b> Type Of Ventricular Tachycardia	 NO PULSE      Rate: Very Fast (200-250 bpm)      Tall and Short Waves Irregular, No P Wave, Wide QRS
*Synchronized Cardioversion possible for SVT if medication ineffective.		
<b>SVT*</b> Supraventricular Tachycardia	 Rate: Very Fast (150-250 bpm) Regular, P Wave Hidden, Normal QRS	
<b>STEMI</b> ST Elevation Myocardial Infarction	 ST Elevation Reg or Irreg, P Wave, ST Elevated	
<b>A-Fib</b> Atrial Fibrillation	 ↑ Erratic Waves      * QRS normally narrow but not always Irregular, No P Wave, Normal QRS*	
<b>A-Flutter</b> Atrial Flutter	 ↑ "Sawtooth" Pattern Reg or Irreg, No P Wave, Normal QRS	
<b>PVC</b> Premature Ventricular Contraction	 PVC      PVC ← No P Waves → Irregular, No P Wave, Wide QRS	
<b>Sinus Brady</b> Sinus Bradycardia	 Rate: Slow (<60 bpm) Regular, P Wave, Normal QRS	
<b>Sinus Tach</b> Sinus Tachycardia	 Rate: Fast (> 100 bpm) Regular, P Wave, Normal QRS	
<b>NSR</b> Normal Sinus Rhythm	 Rate: Normal (60-100 bpm) Regular, P Wave, Normal QRS	

<https://www.medicalestudy.com/basic-ecgekg-rhythms-nclx-cheat-sheet/>