

MUSCULI MASTICATORII

Muscles of mastication

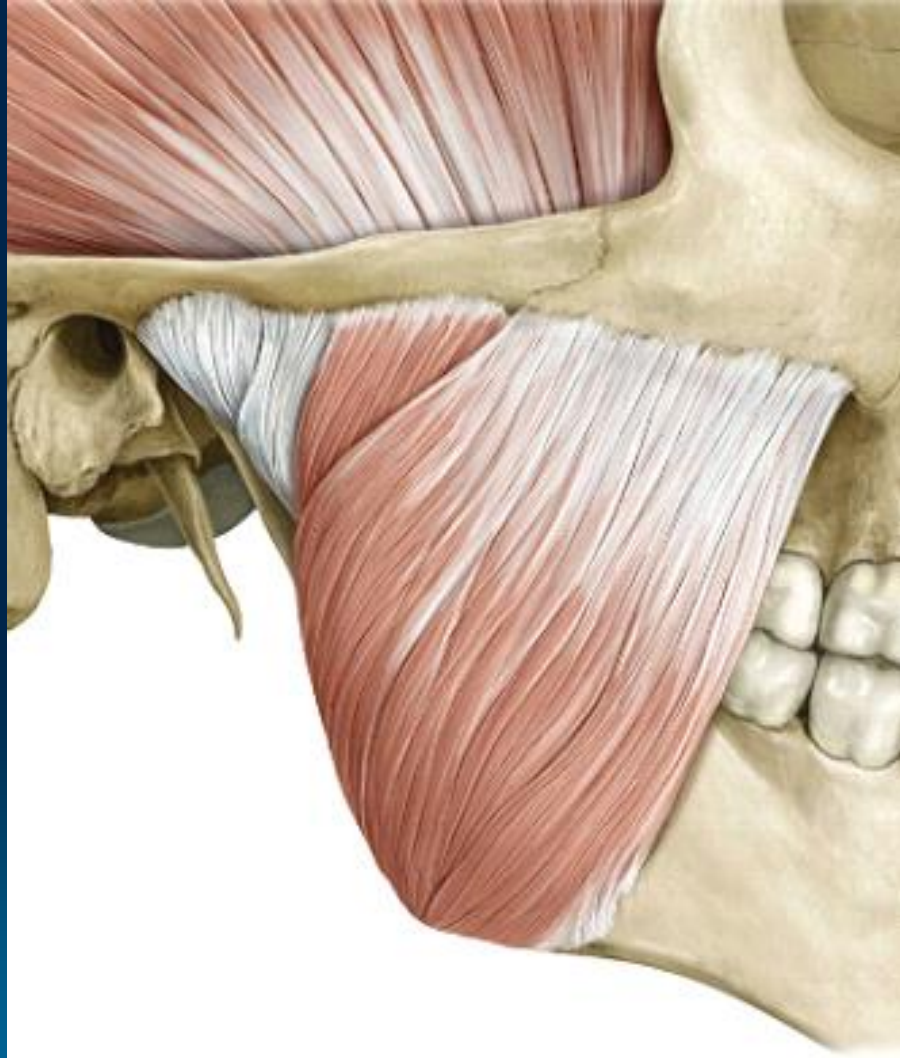The background features several decorative elements consisting of concentric circles in shades of blue, resembling ripples in water. These circles are positioned in the lower half of the slide, with one set on the right side and two larger sets on the left side.

- Lat. **masticare = to chew**
- Embryologically, the muscles of mastication develop from the first (mandibular) pharyngeal arch
- Movements of the mandible in the temporomandibular joint, while the rest of the skull remains stable
- origin - from the bones of the neurocranium (non-movable bones),
insertion - on the mandible (freely movable bone)

- Pinnate structure
- Blood supply: maxillary artery (end branch of ACE)
- Nerve supply: mandibular branch of trigeminal nerve
- 4 pairs of muscles



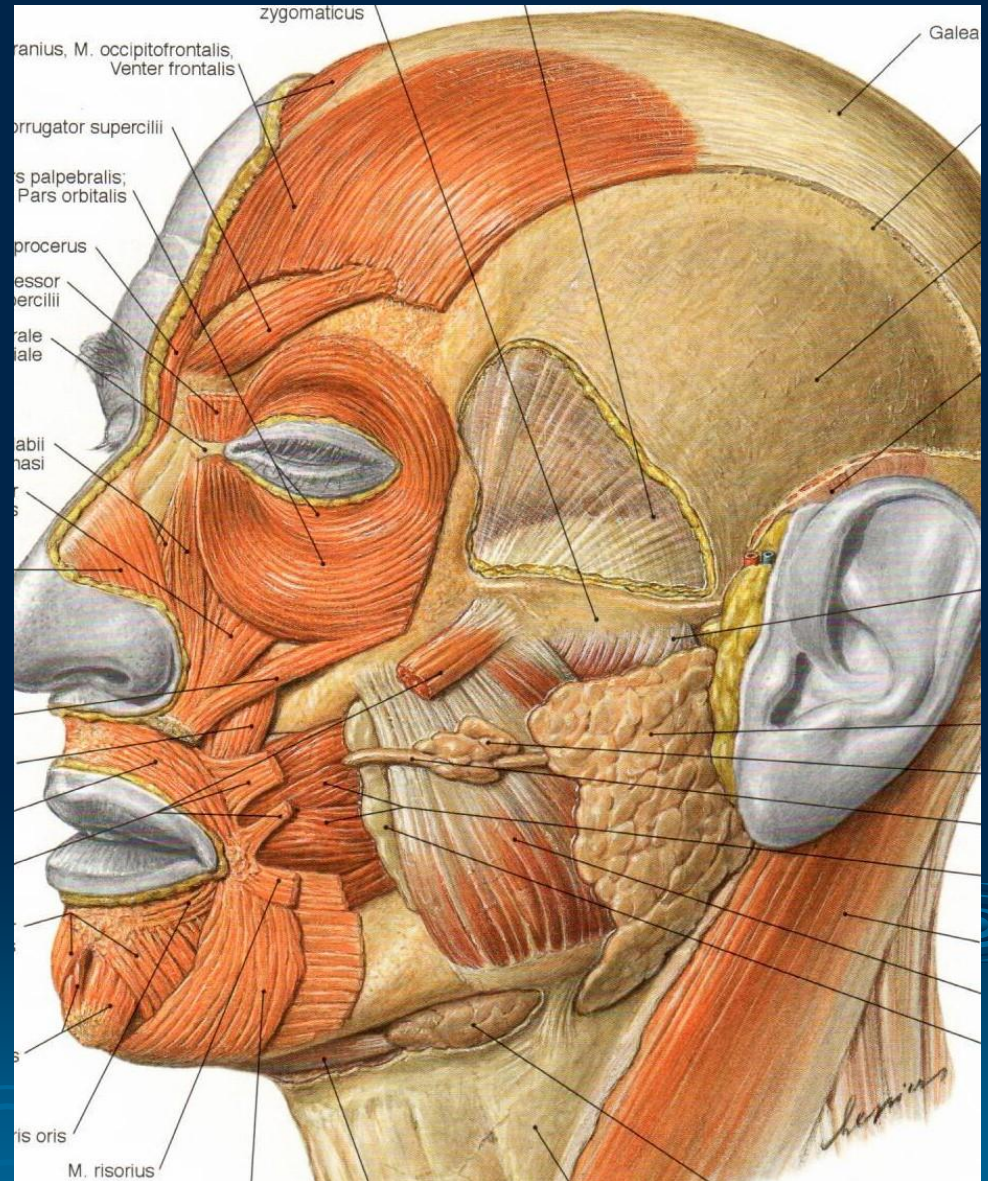
Masseter muscle



- Thick, quadrilateral muscle, superficially located – on the side of the face, anterior to the parotid salivary gland

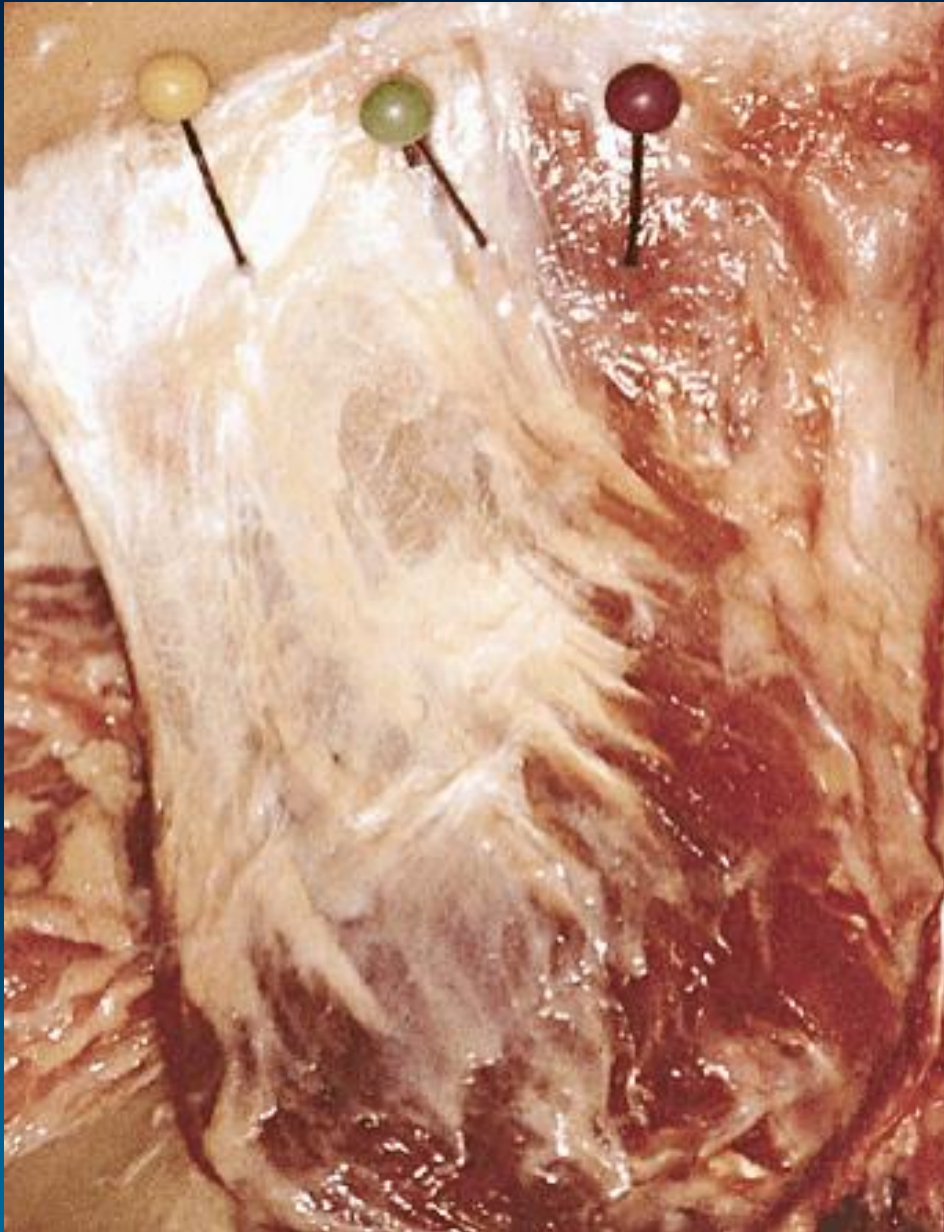
- Divided into Superficial, middle and deep portion

- innervation:
n. massetericus
(V3)



Functional organization of the human masseter muscle.

J.F. Gaudy et al. (2000) Surg Radiol Anat 22:181-190.



Pars superficialis

lamina spf.
lamina prof.

Pars intermedia

Pars profunda

pars ventralis
pars dorsalis:

- l. spf.
- l. intermedia
- l. prof.

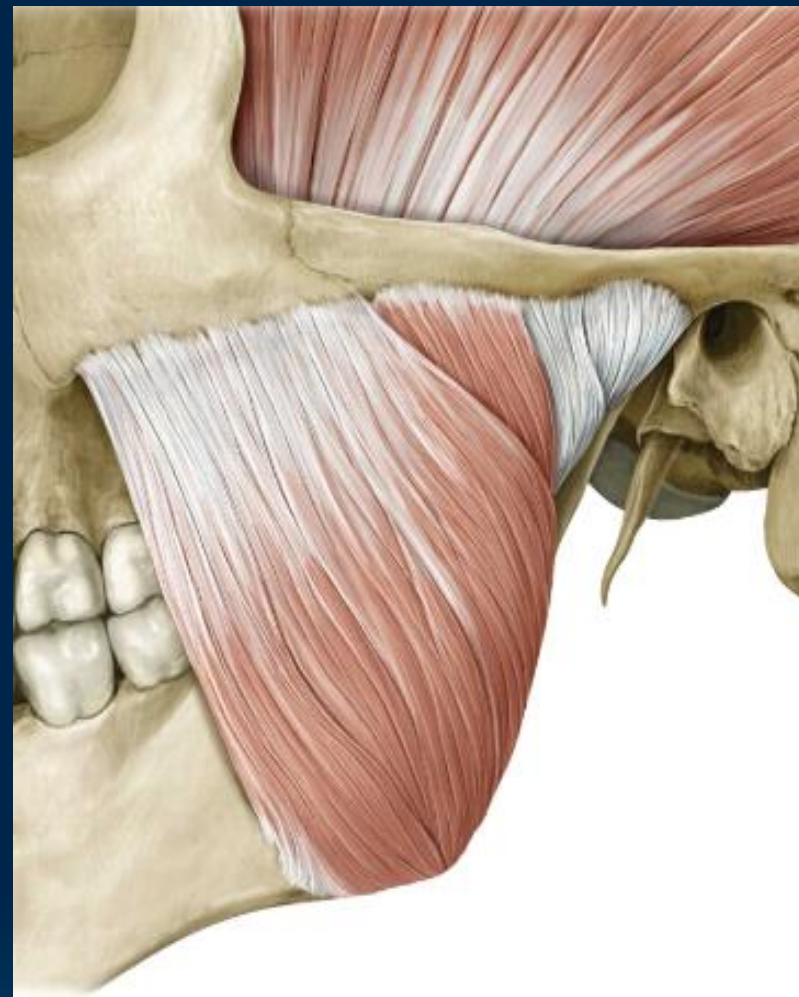Pars spf.

Origo

the lower edge of the os zygomaticum up to the zygomaticotemporal suture

Insertio

outer surface of the ramus mandibulae
lower $\frac{1}{2}$ up to tuberositas masseterica



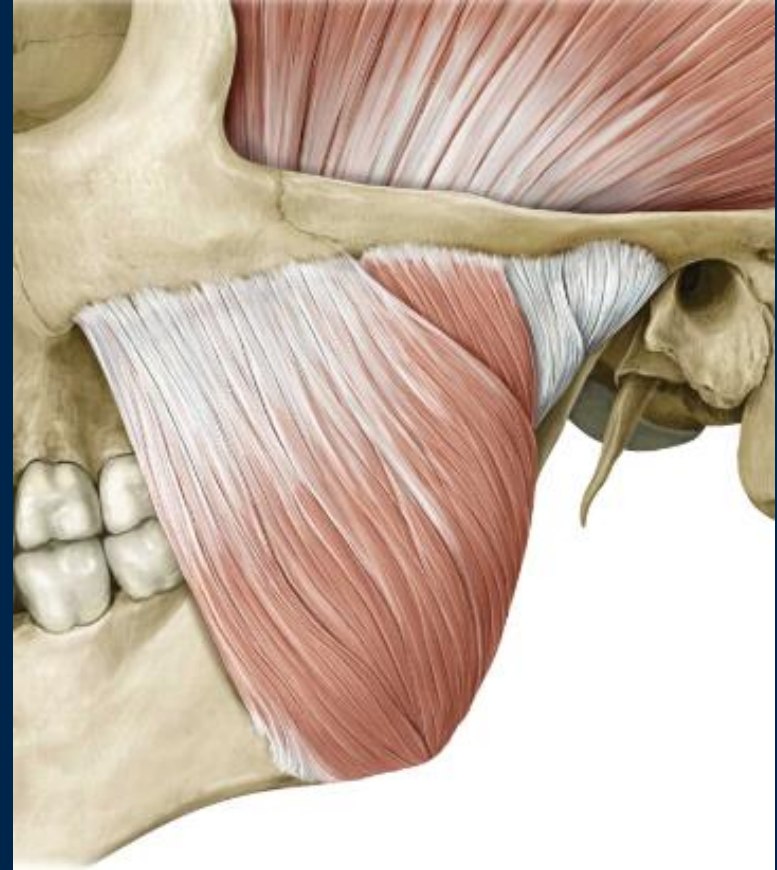Pars media

Origo

lower edge of anterior 2/3 arcus zygomaticus

Insertio

middle 1/3 of ramus mandibulae



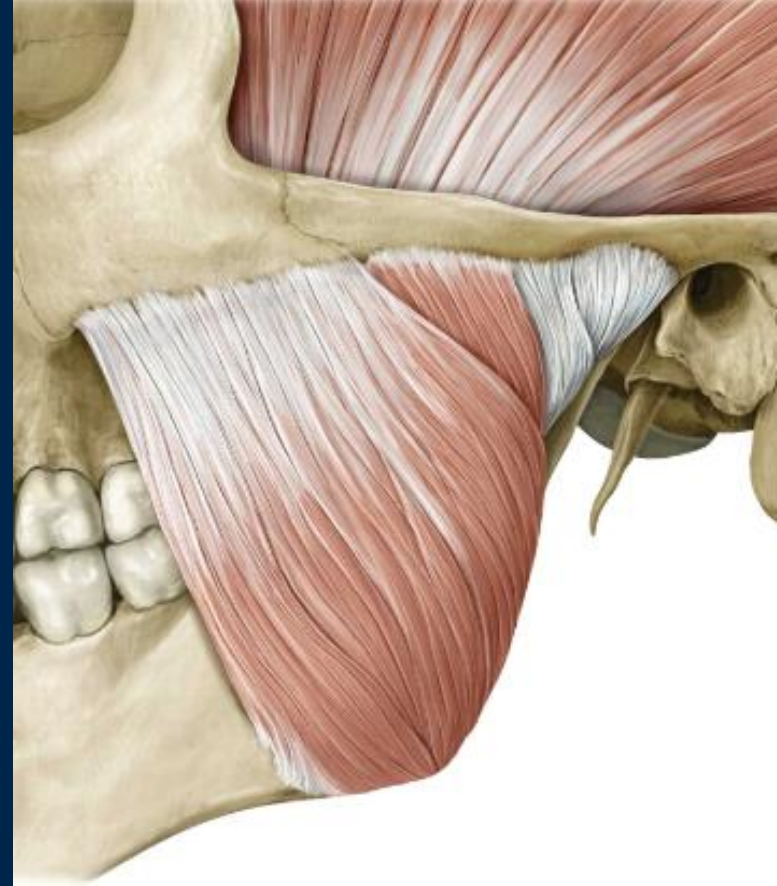
Pars prof.

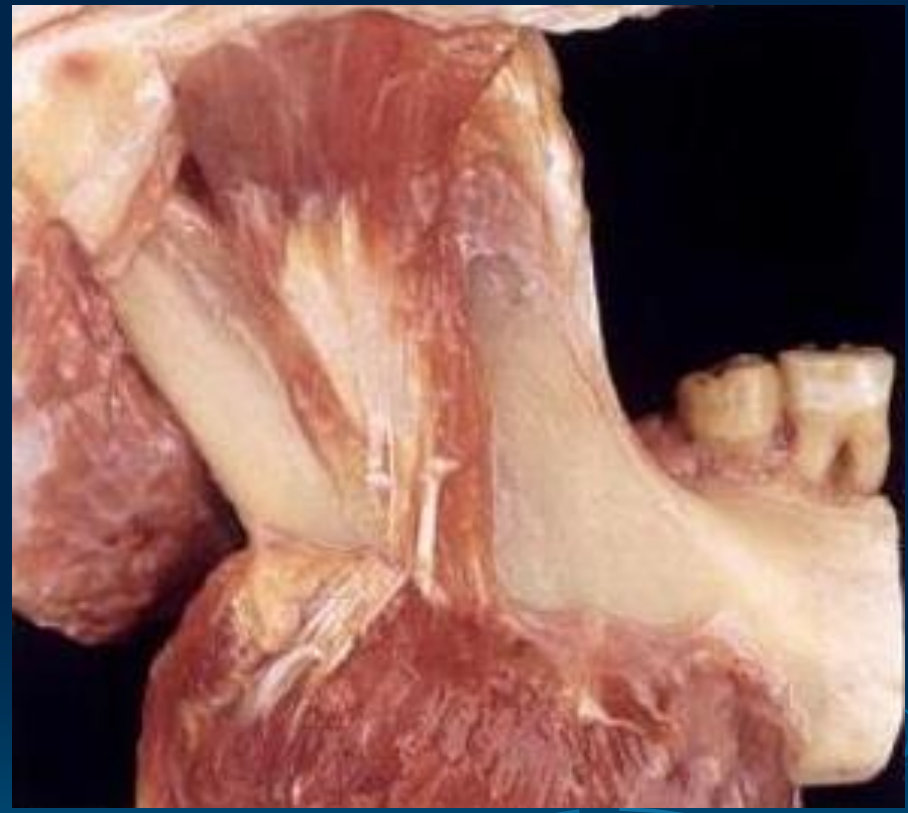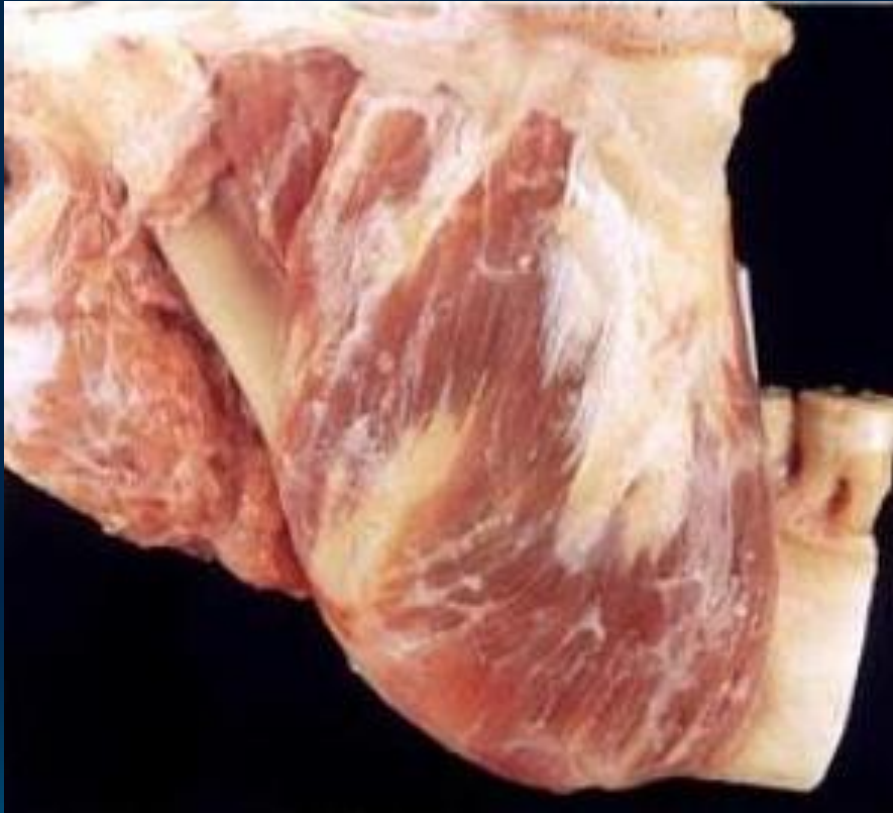
Origo

inner side of arcus zygomat.
deep lamina of temporal fascia

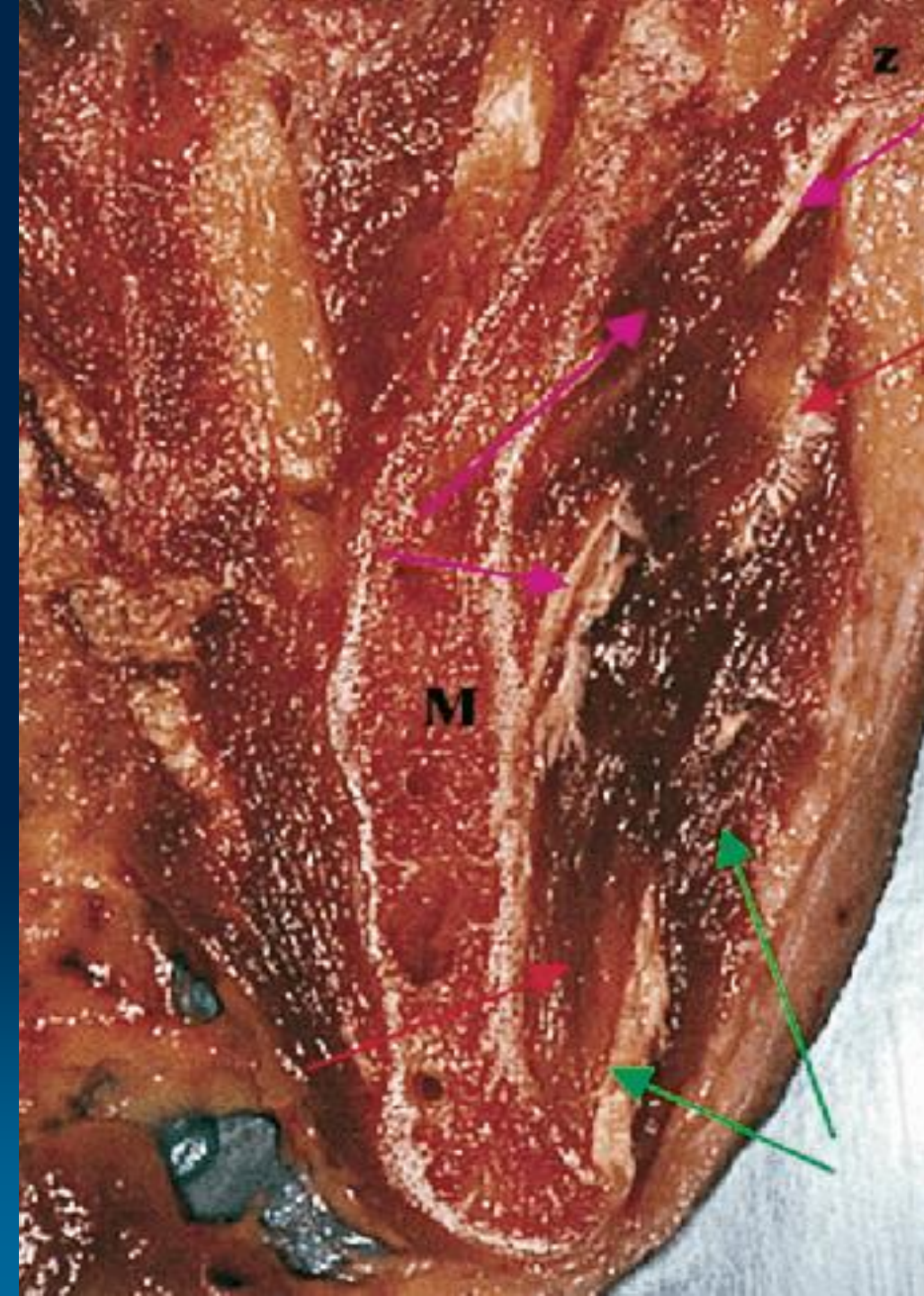
Insertio

outer side of ramus mandibulae (upper $\frac{1}{2}$) visible
as so-called **fovea m. zygomaticomandibularis**





Functional organization of the human masseter muscle
www.springerlink.com/index/U007G453650W2163.pdf



Frontal section

p. superficialis

p. intermedia

p. profunda

Function

Pars media et profunda
works together as one unit

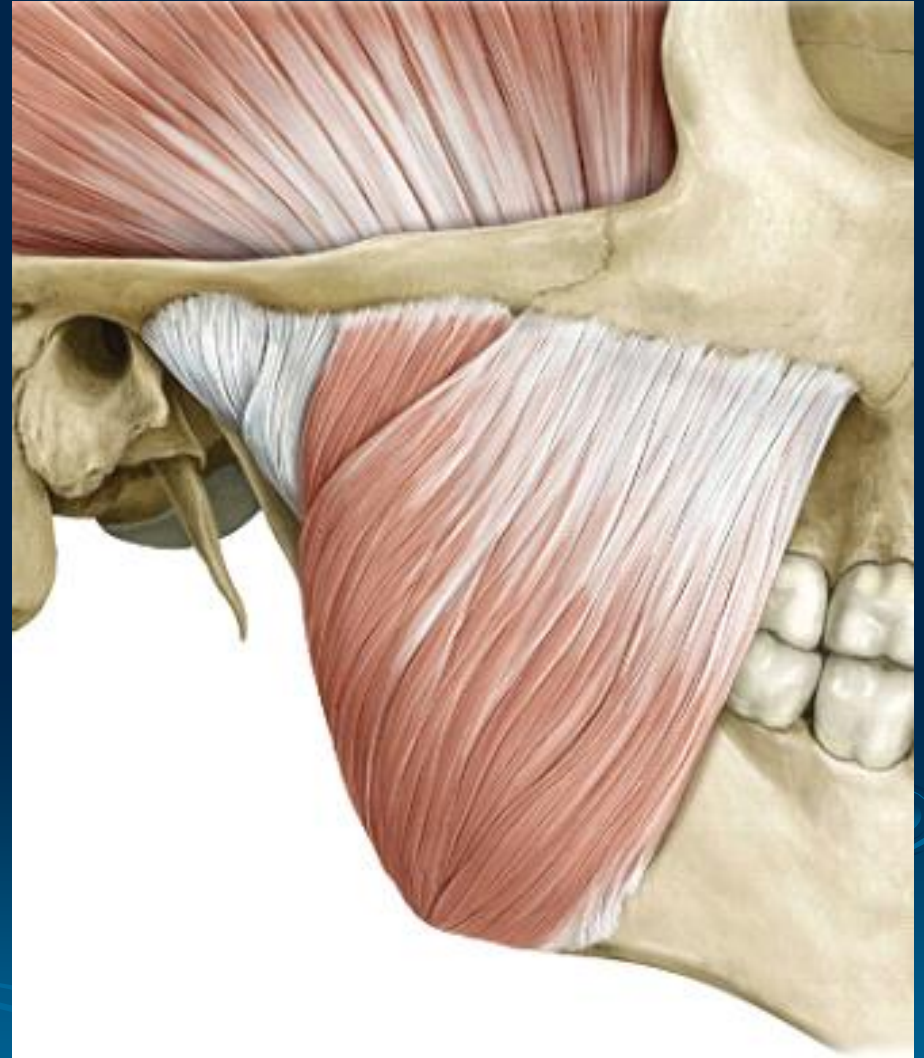
Bilateral contraction:

The superficial part:

Elevation – closes the
mouth
propulsion

The deep portion:
elevation

Unilateral contraction:
ipsilateral lateropulsion



The Architecture

- The typical pinnate structure
- Zones of muscular and aponeurotic attachments
- The structure allows spreading the infection
(**submasseteric abscess**)

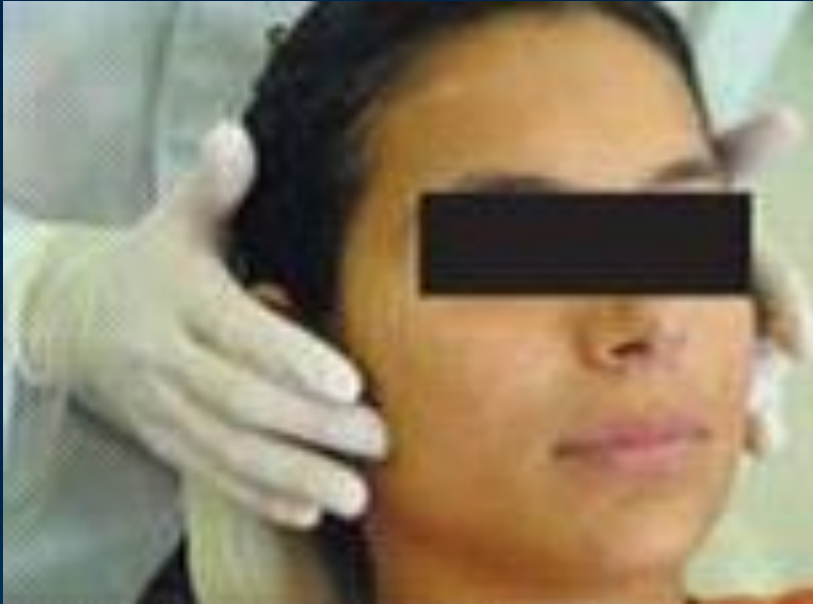

The Masseteric Fascia

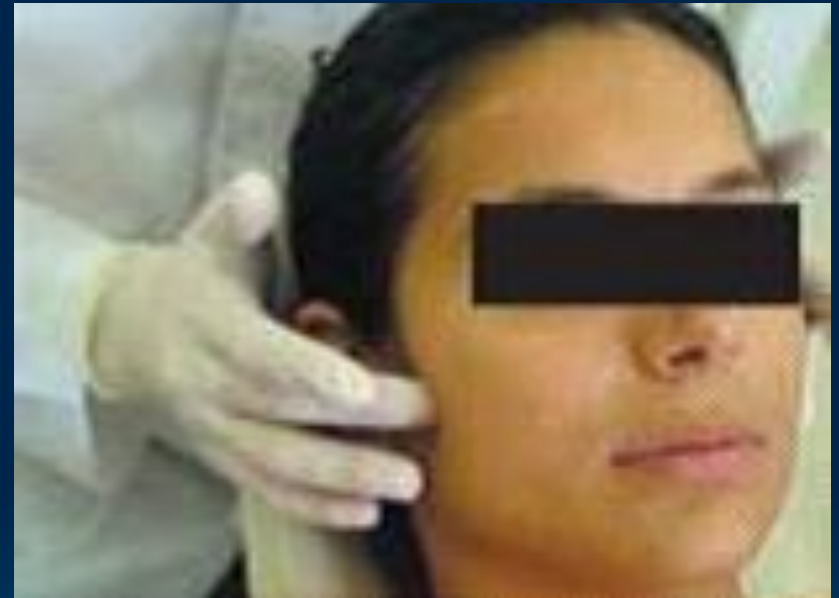- Firmly connected with the muscle
- From arcus zygomaticus to basis mandibulae
- Dorsally merge with fascia parotis (fascia parotideomasseterica)
- Caudally connected with basis mandibulae -> fascia colli spf.
- Ventrally attached to the ramus mandibulae

Palpation

Palpation of the masseter muscle by having patient clench the teeth

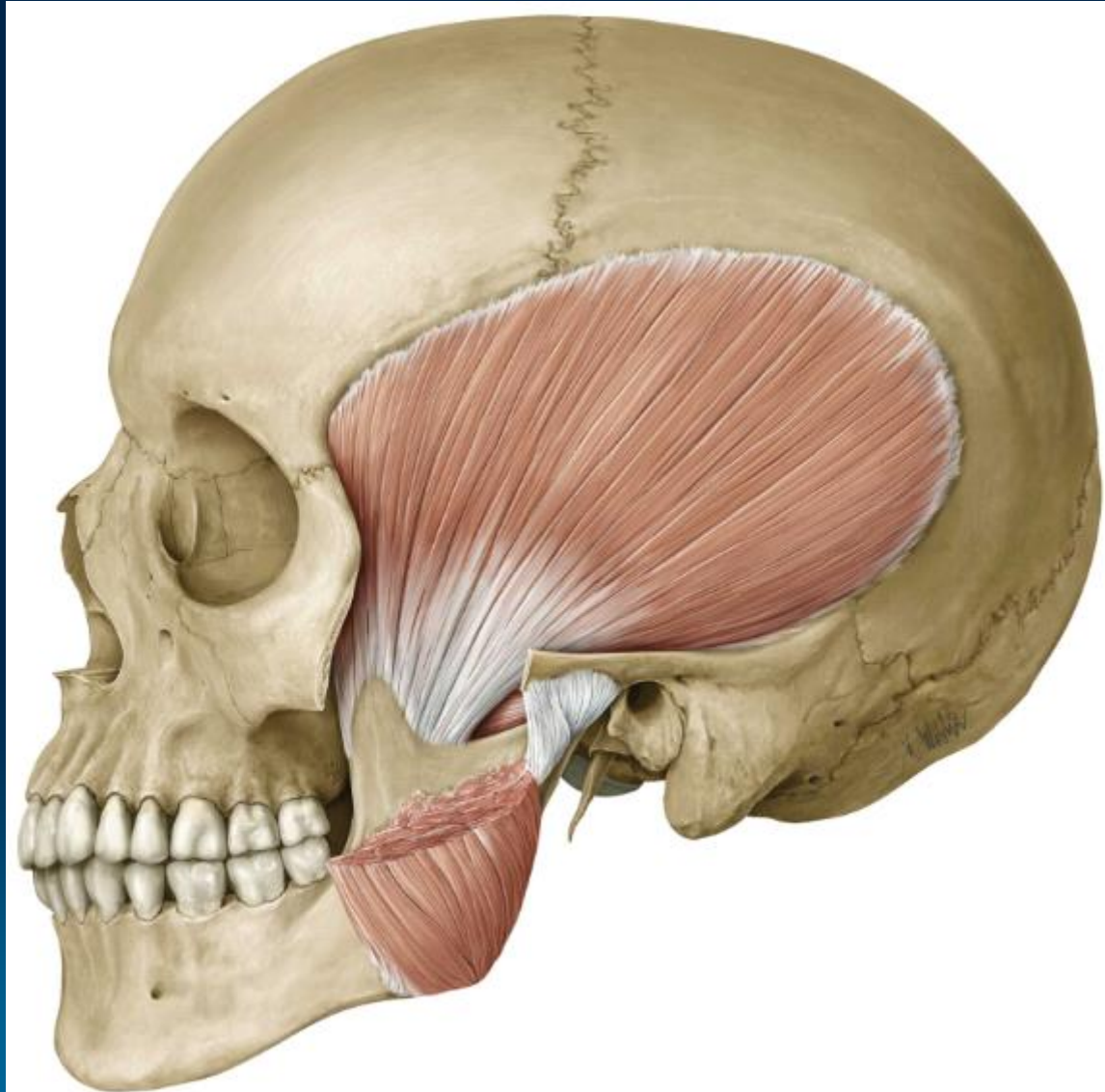


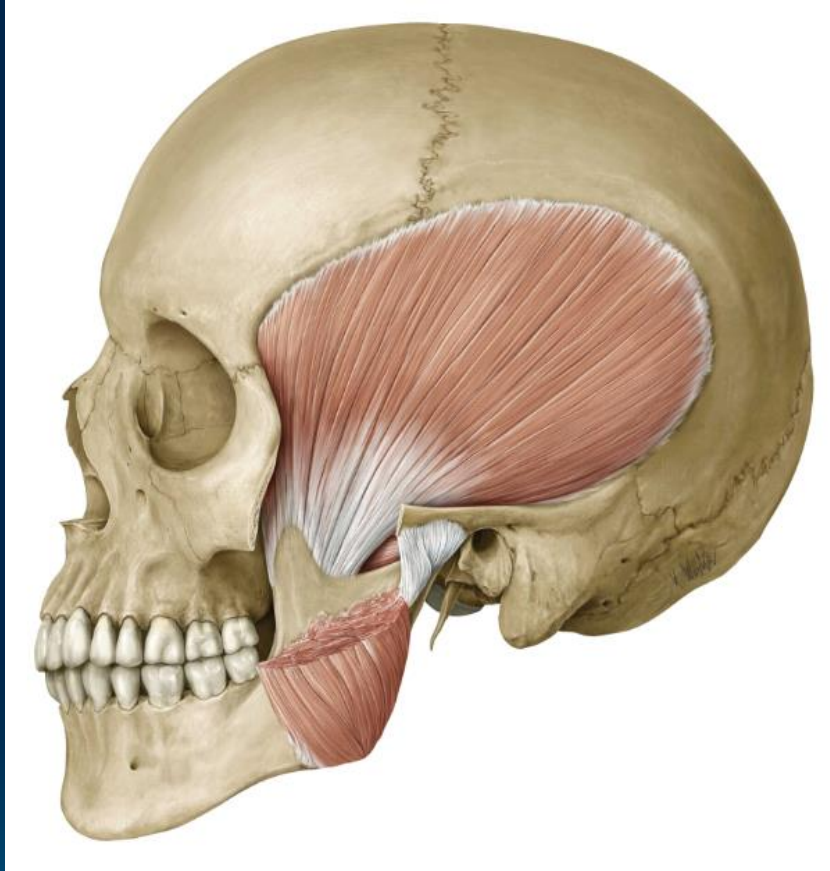
The Superficial Portion



The Deep Portion

Temporalis muscle





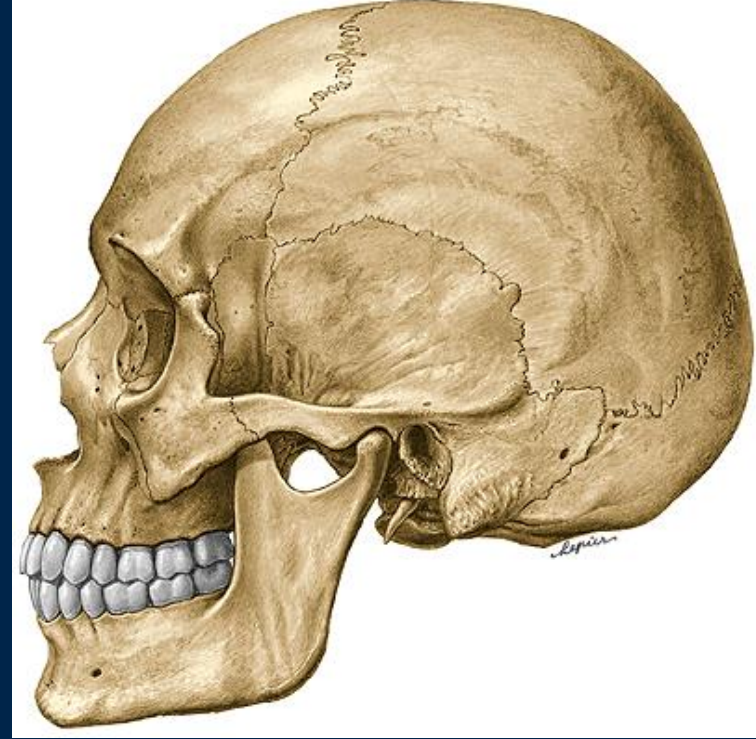
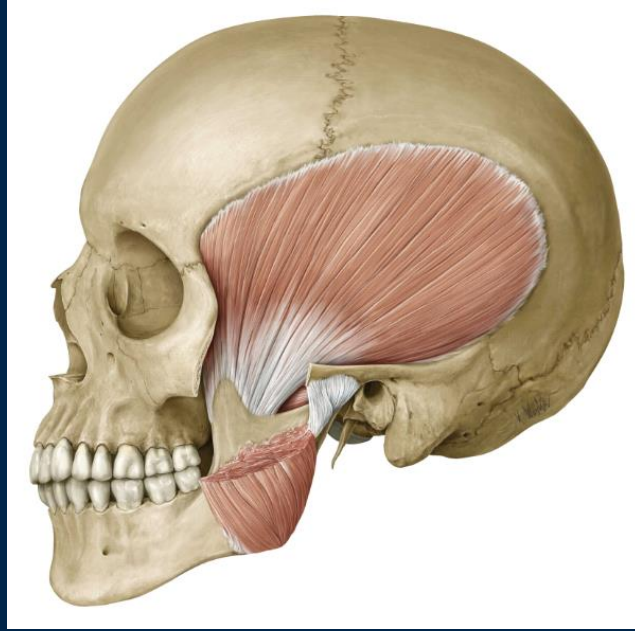
- Lies in fossa temporalis
- Flat muscle
- Fan shape, pinnate
- Covered by fascia temporalis

- Blood supply.: a. tempor. media (a.tempor.superfic.)
a. tempor. prof. (a.maxillaris)
- innervation: nn. tempor. prof. (V3)

In the long axis of the muscle, a caudally strengthening **central tendon** (double pinched muscle) is formed.

Therefore, some authors divide muscle into :

- part ventrally from the tendon – pars anterior
- part dorsally from the tendon – pars posterior



Origo

- fossa temporalis – planum temporale

ANTERIOR PART: linea temporalis inf. ossis pariet.,

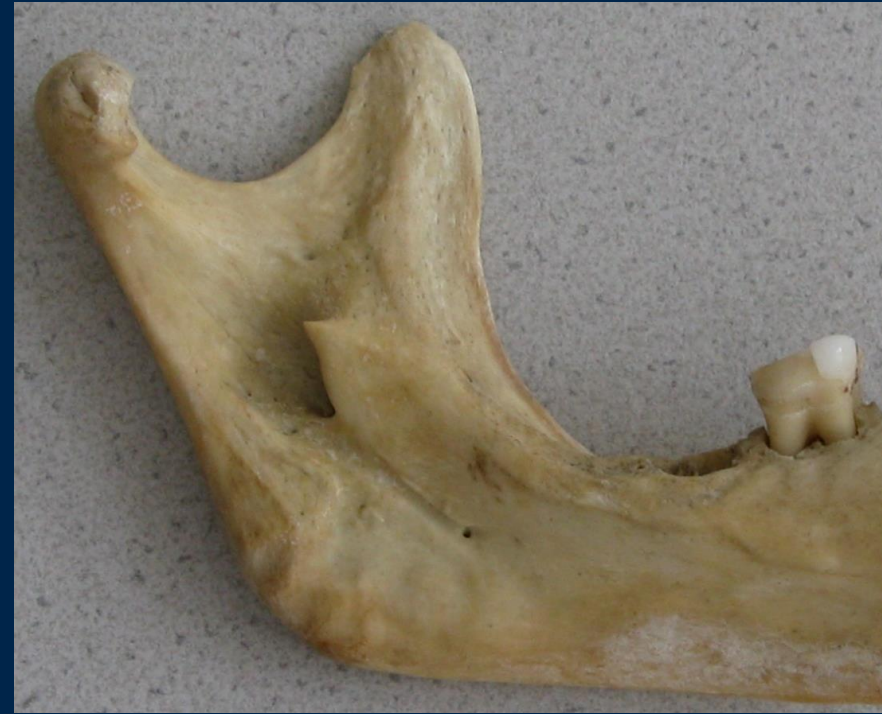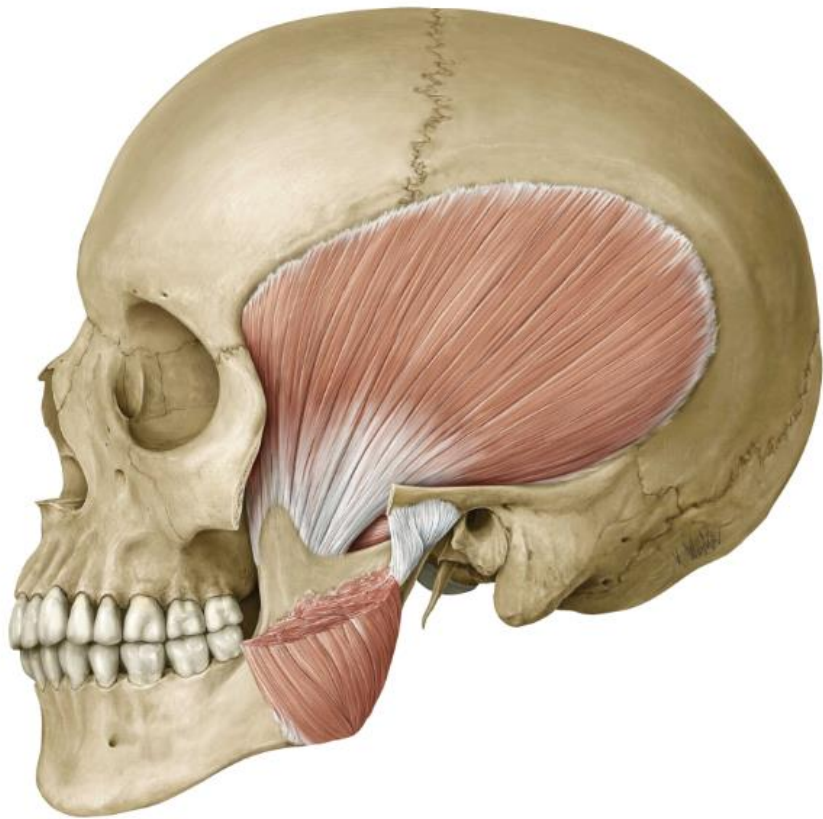
facies temporalis alae majoris ossis sphen.,

adjacent part of os frontale and os parietale

+ inner surface of the deep lamina of the fascia

temporalis

POSTERIOR PART: squama ossis temporalis

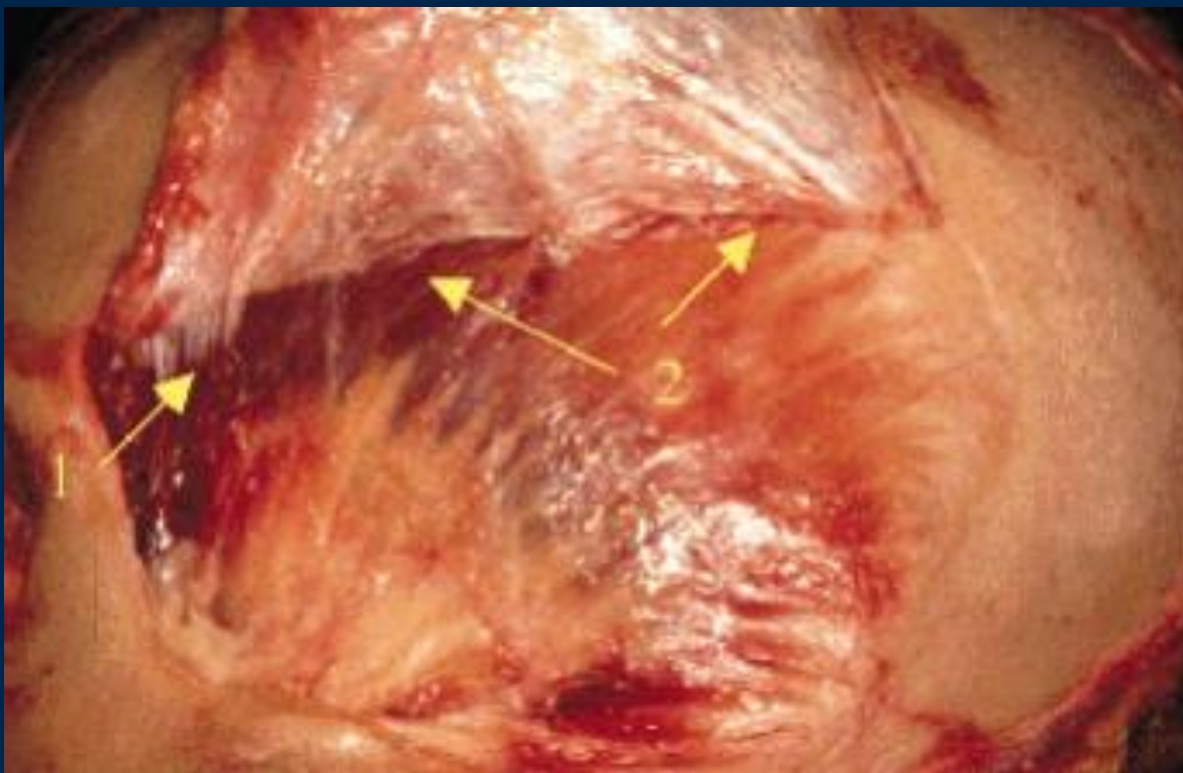


Insertio - muscle fibers converge caudally into a strong tendon

- tendon on the processus coronoideus

- further converges along the line obliqua and crista temporalis (up to the trig. retromolare)

- also attached to the lig. pterygomandibulare



1 - pars ant. (orbitalis)

1/3, width approx. 3 cm, dark color, adheres to fascia temporalis

2 - pars post. (temp.)

2/3, light color, connection with fascia looser

Detailed description

The temporalis muscle consists of three parts:

superficial

zygomatic

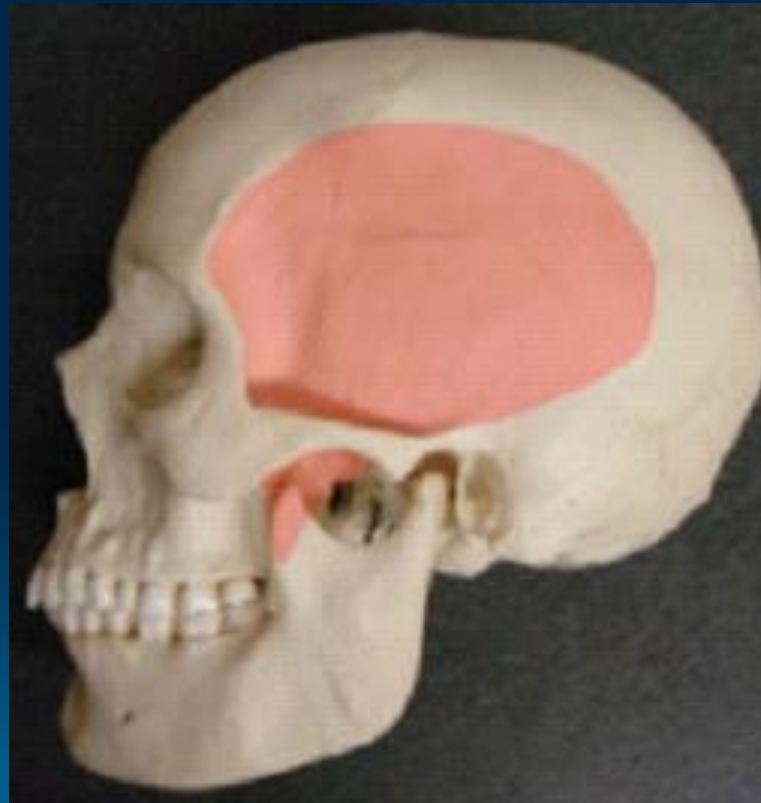deep portion

[The human temporalis muscle: Superficial, deep, and zygomatic ...](#)
[onlinelibrary.wiley.com](#) › ... › [Journal Home](#) › [Vol 22 Issue 6](#)

The Superficial Portion

Origo: temporal aponeurosis, temporal line

Insertion: the coronoid process of the mandible



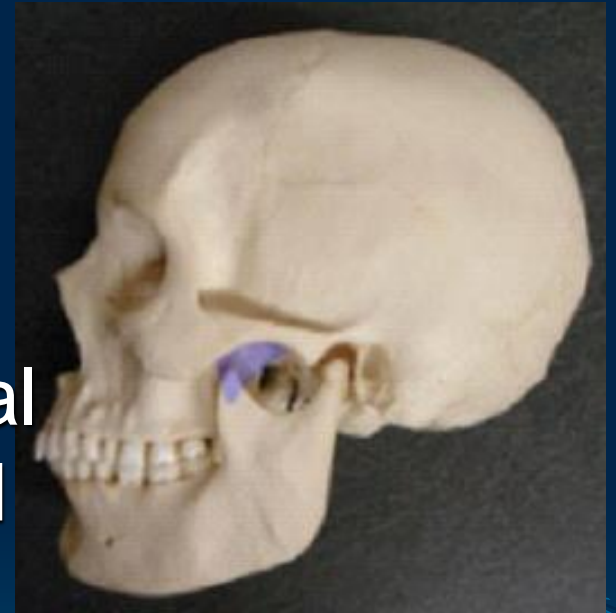
The Zygomatic Portion

Origo: superior and medial zygoma and zygomatic arch

Insertion: coronoid process

Fuse with tendon of the superficial part of the temporalis muscle and with the deep masseter portion.

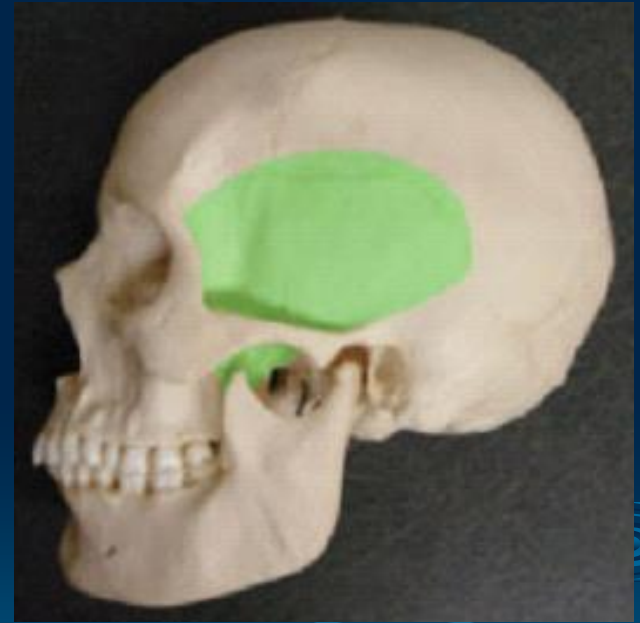Rostrally interdigitated with the portion of the deep temporalis part



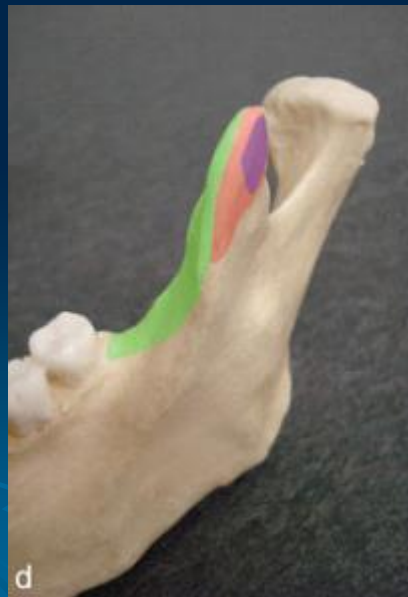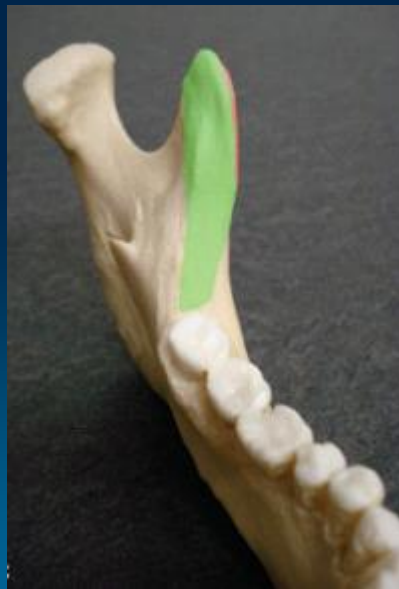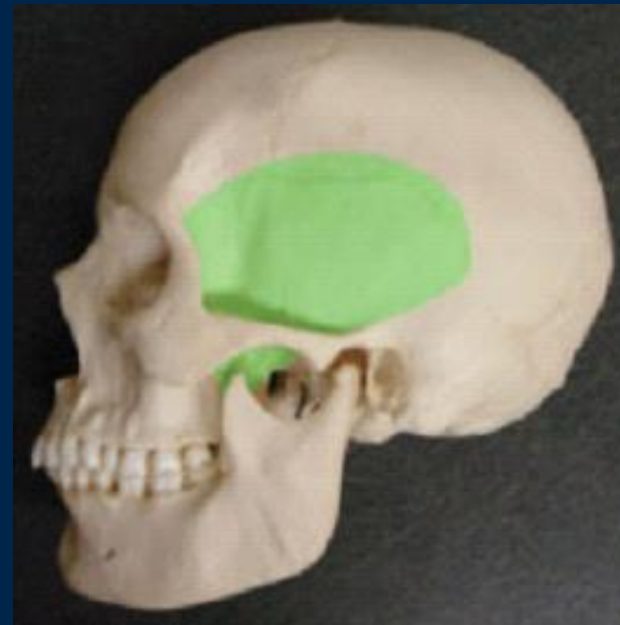
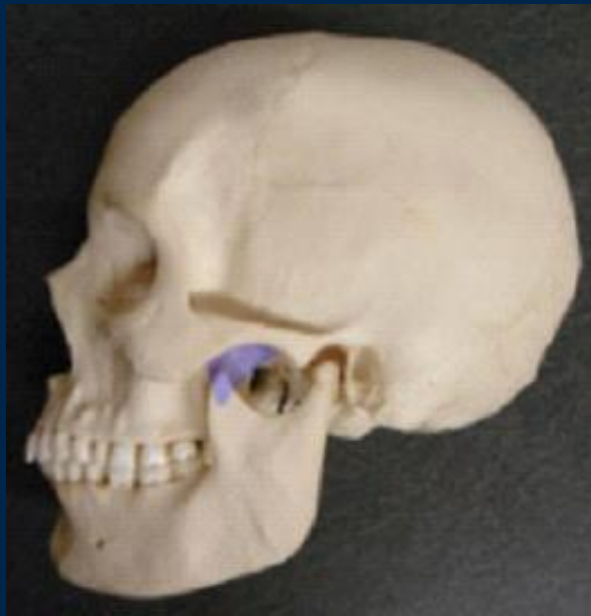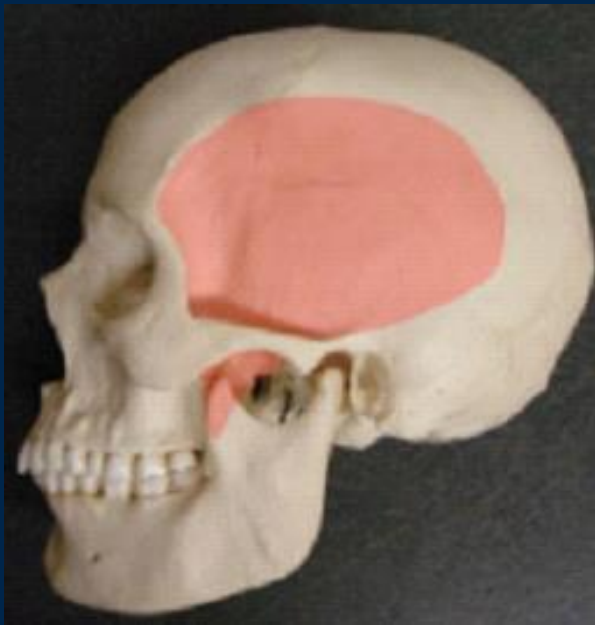The Deep Portion

Origo: bony surface of the frontal, sphenoid, parietal and temporal bones

Insertion: coronoid process and the ramus of the mandible, just caudal to the last molar (retromolar triangle)



Fibers from deep part interdigitated with the buccinator and the superior pharyngeal constrictor



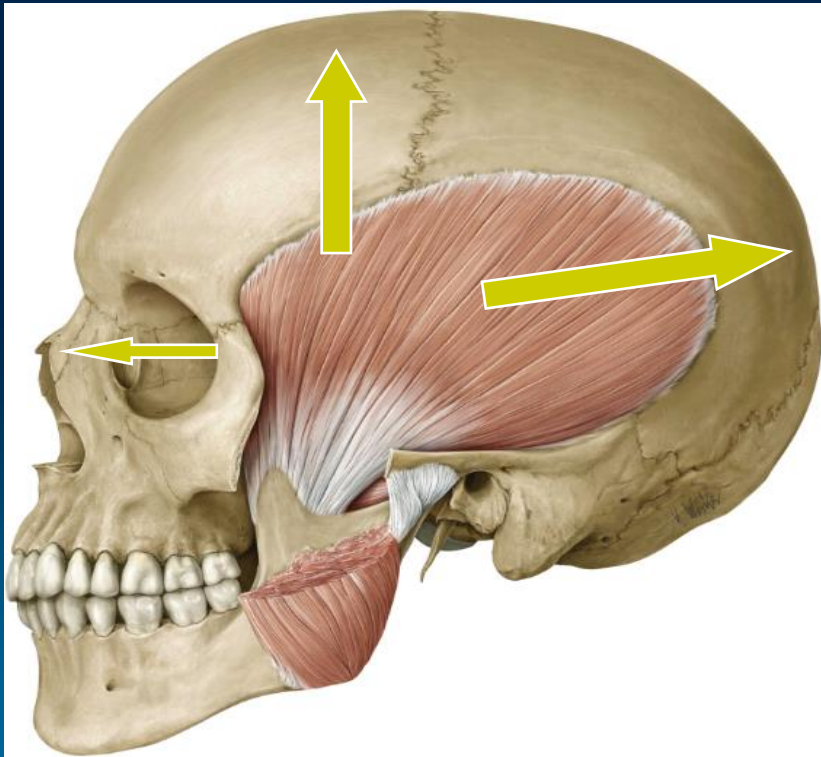
Function

Contraction **bilateral**:

- ant. and middle fibers = **elevation, propulsion**
- Posterior fibers = **retropulsion**

Contraction **unilateral**:

kontralateral lateropulsion



Maintains the middle position of TMJ

The Temporal Fascia

Covers the temporal muscle

Origo: superior temporal line

Insertion: zygomatic arch

Has two layers:

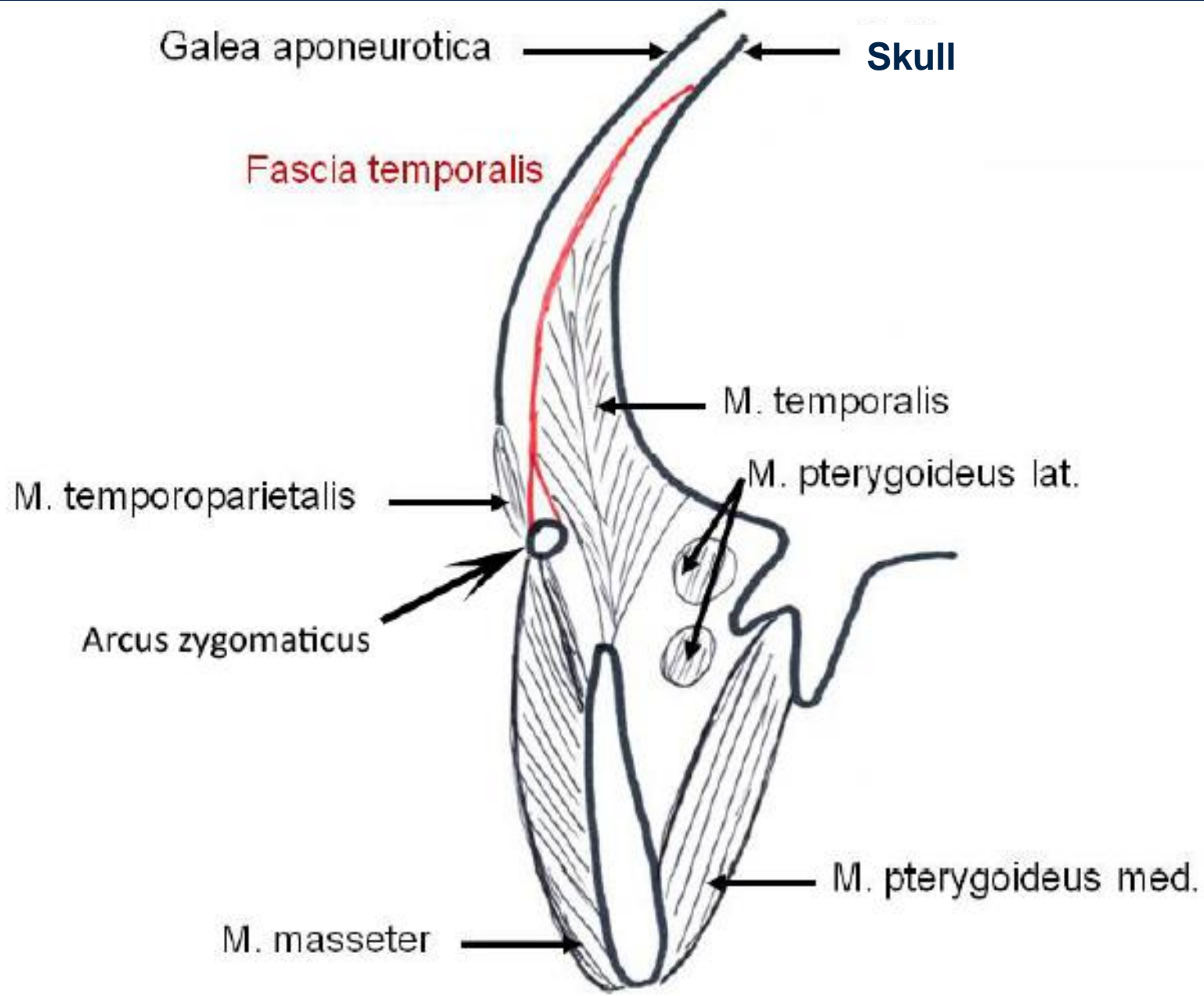
1. superficial

inserted into **the lateral border of the arch**

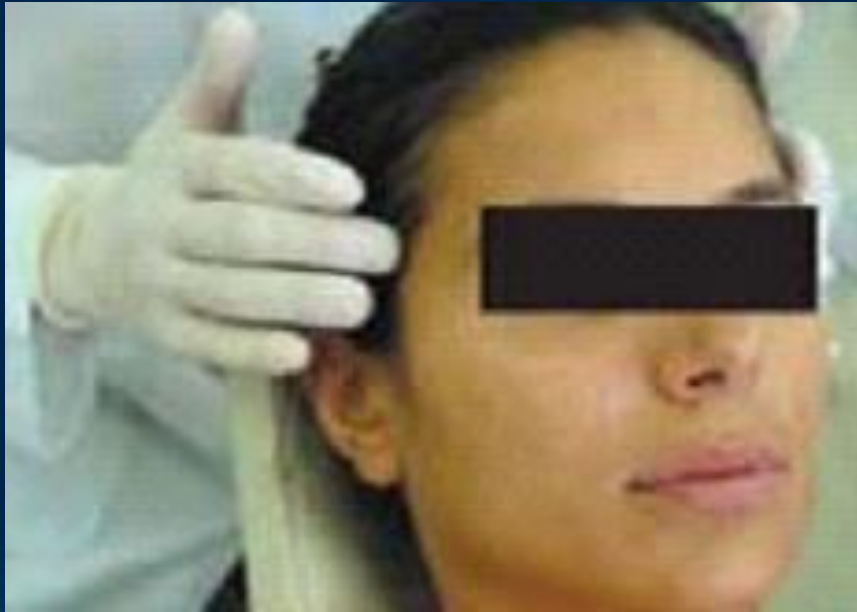2. deep

inserted into the **medial border of the arch**

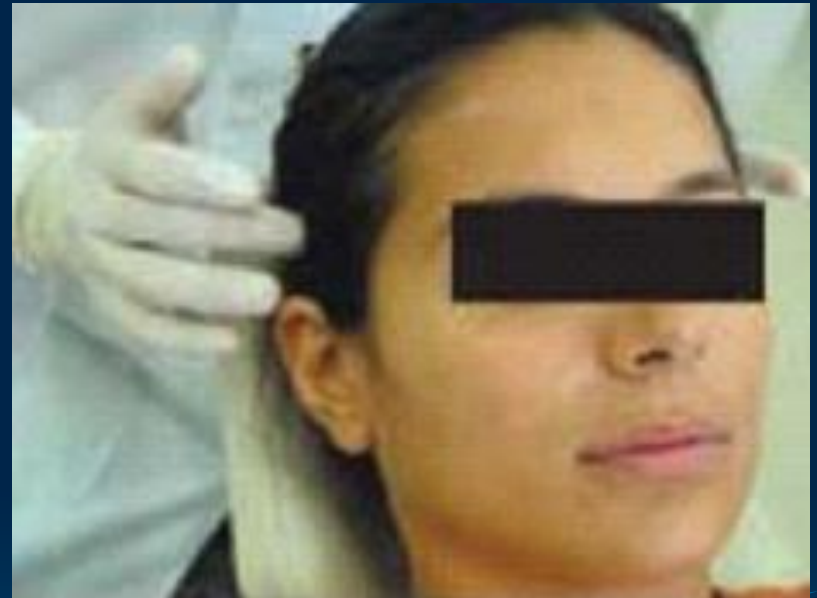Between these layers is a small quantity of fat and attachment of the superficial fibres of the temporal muscle



Palpation

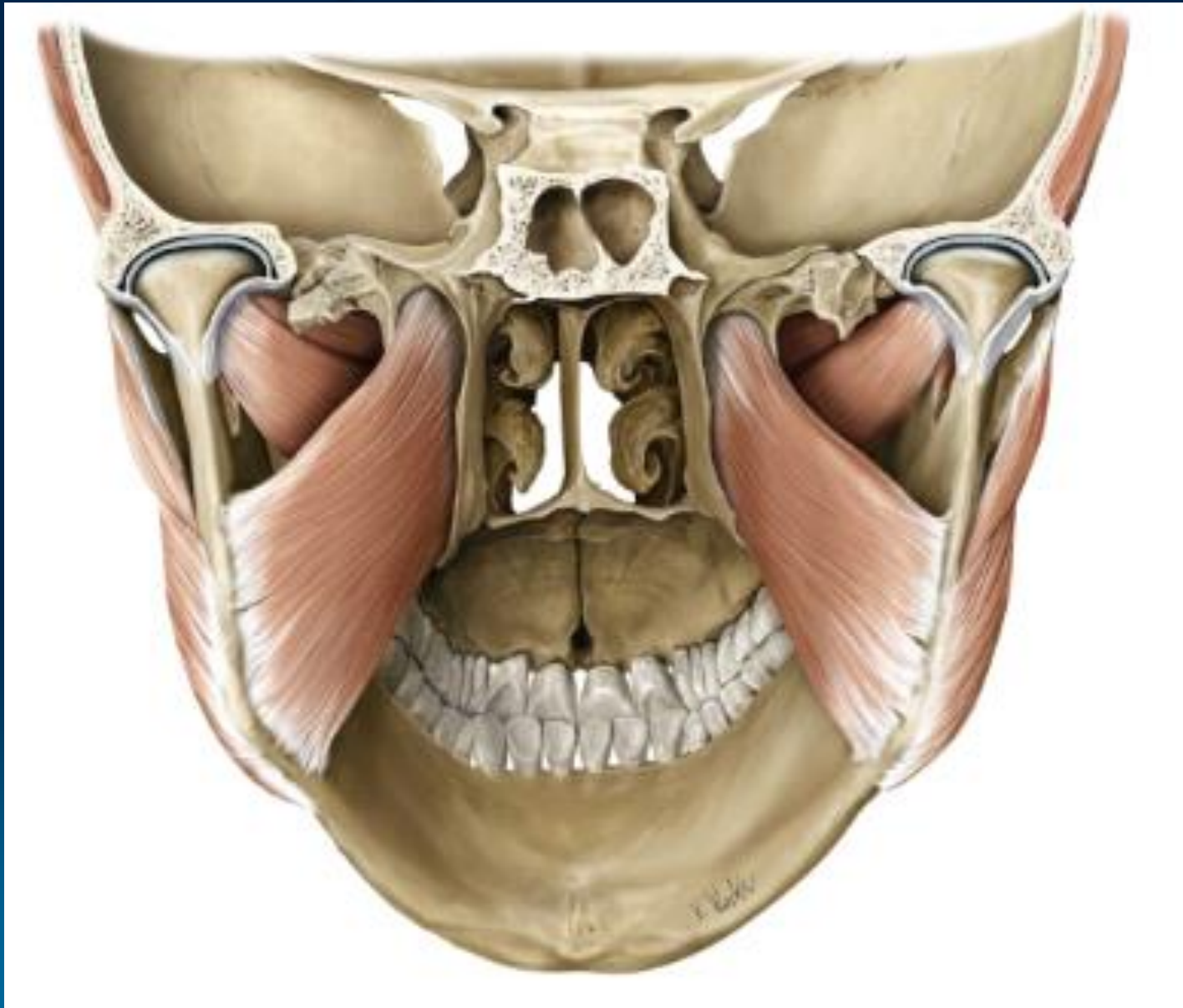


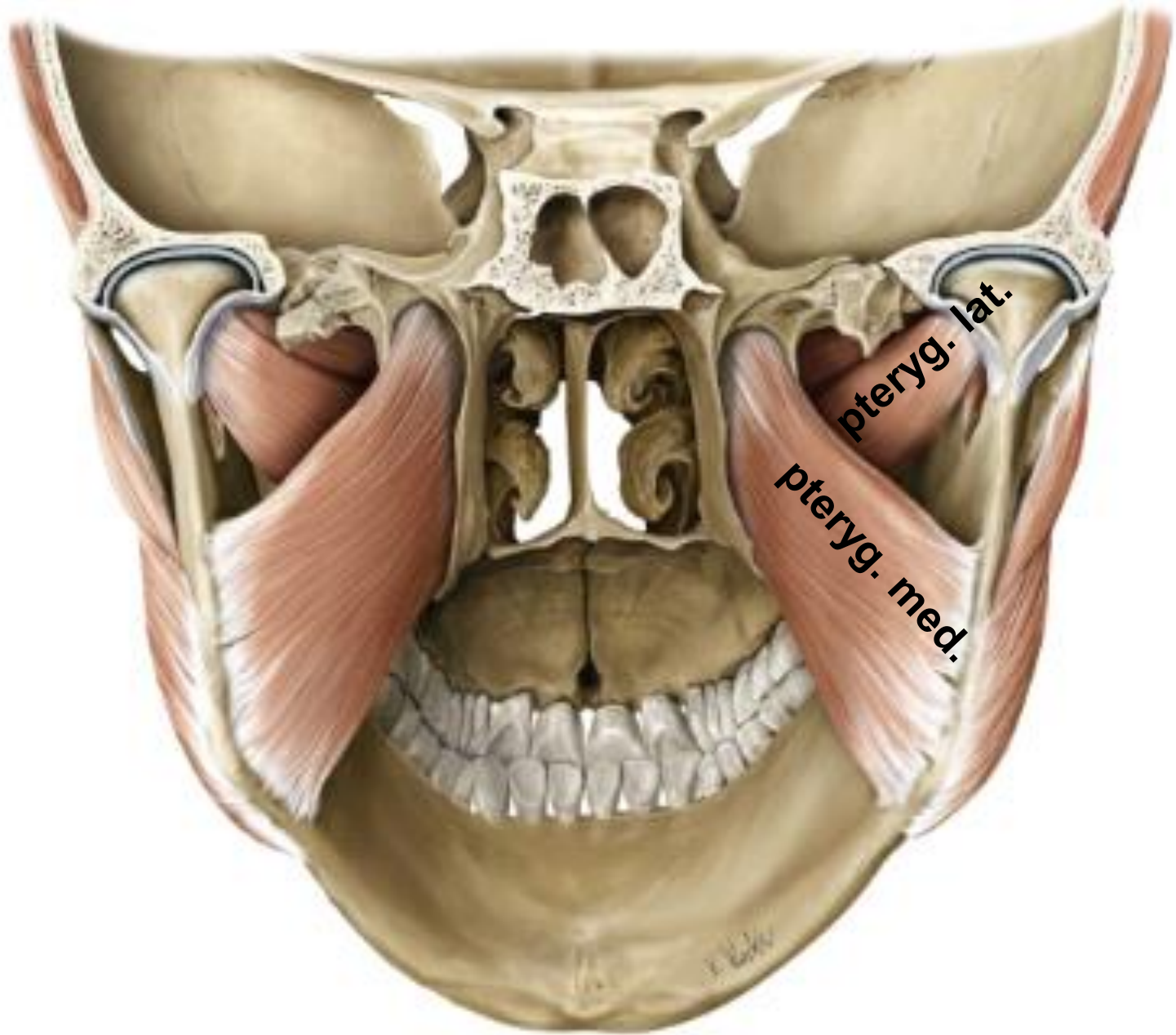
The Anterior Part



The Posterior Part

Pterygoid muscles



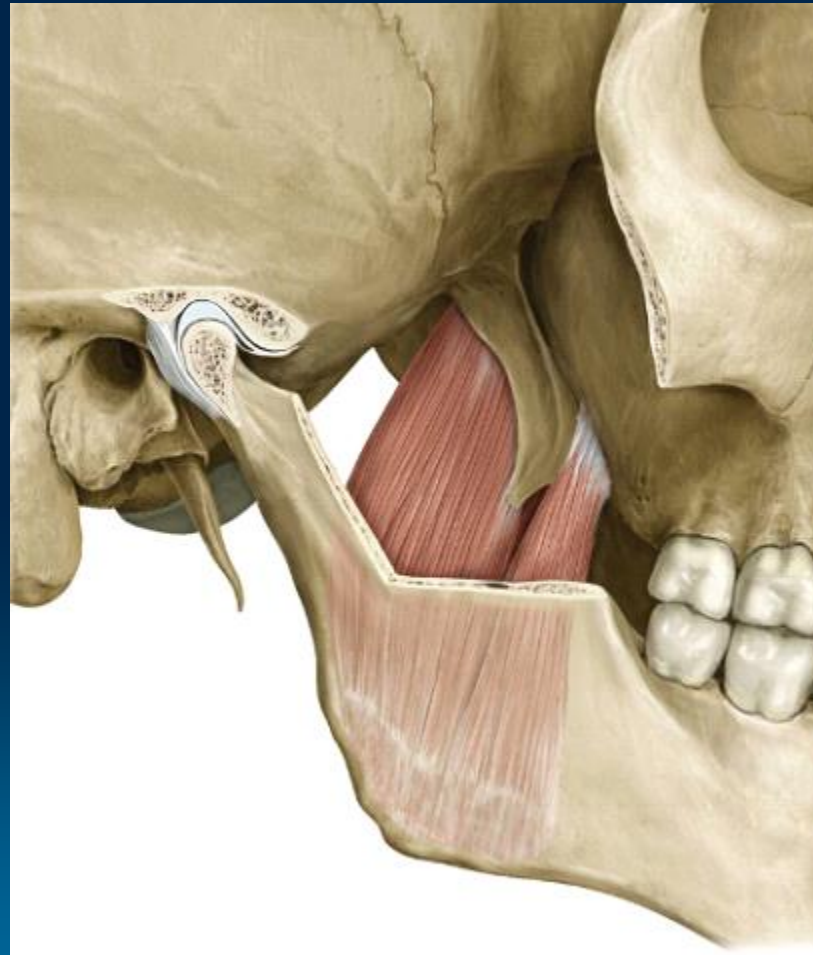

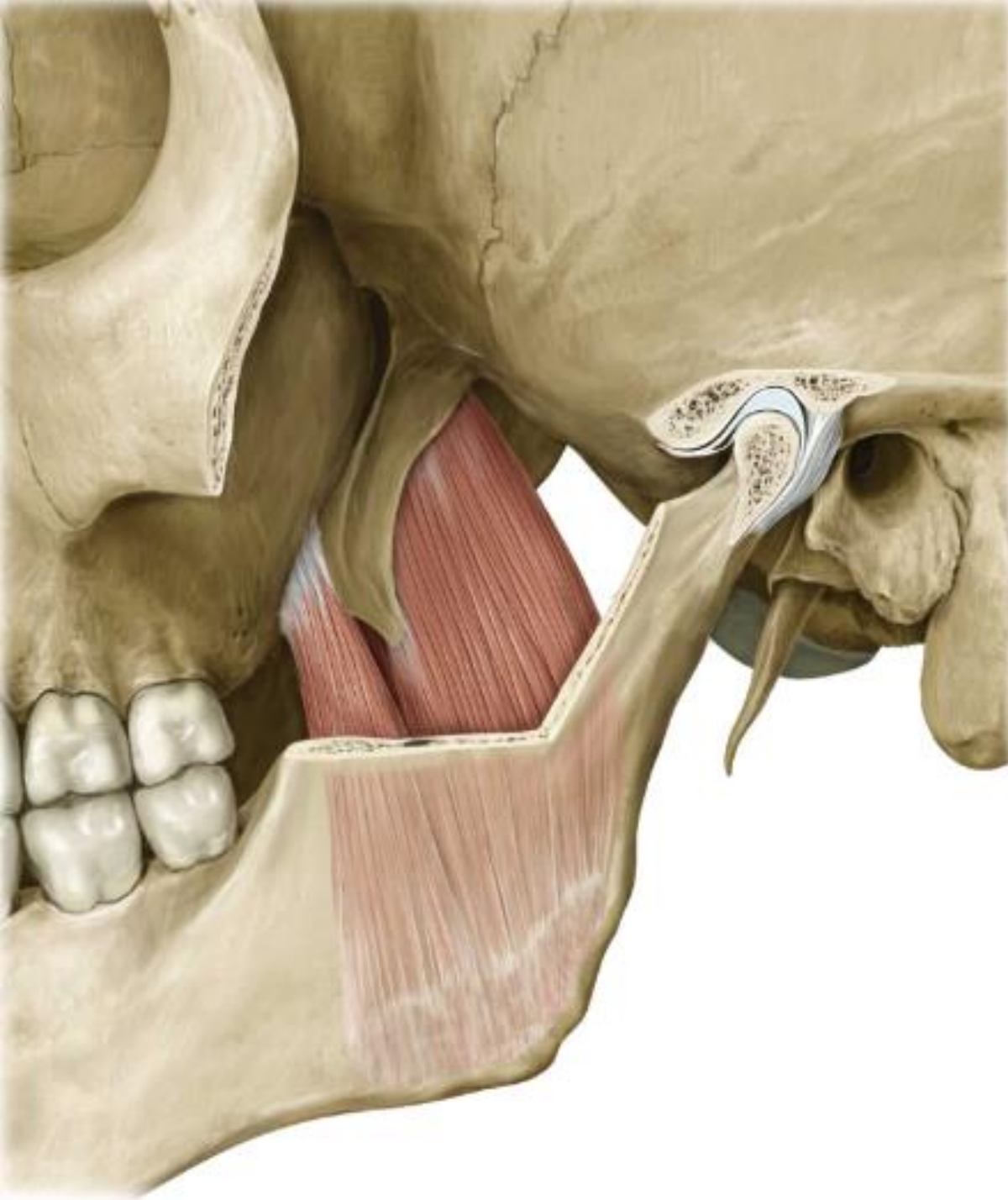
pteryg. lat.

pteryg. med.



Medial (Internal) Pterygoid Muscle





M. pterygoideus med.

- Internal wing muscle
- Strong flattened muscle
- In the infratemporal fossa
- It is similar to the masseter on the inside of the ramus mandibulae
- Part of the muscle loop around the mandible

Caput lat.

smaller

Origo: tuber maxillae

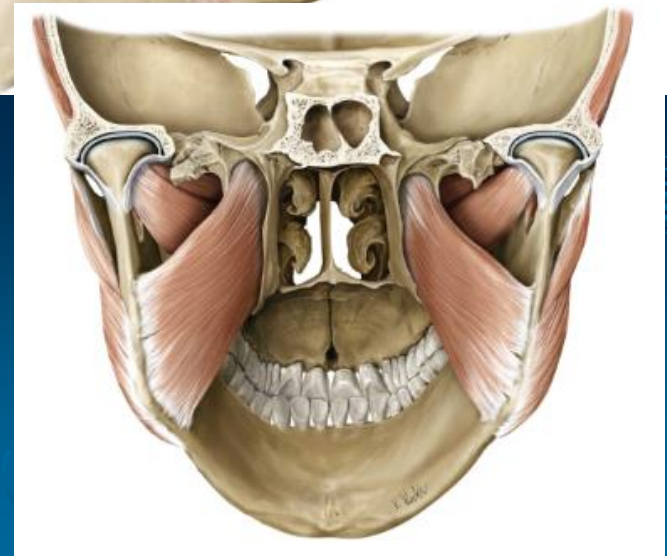
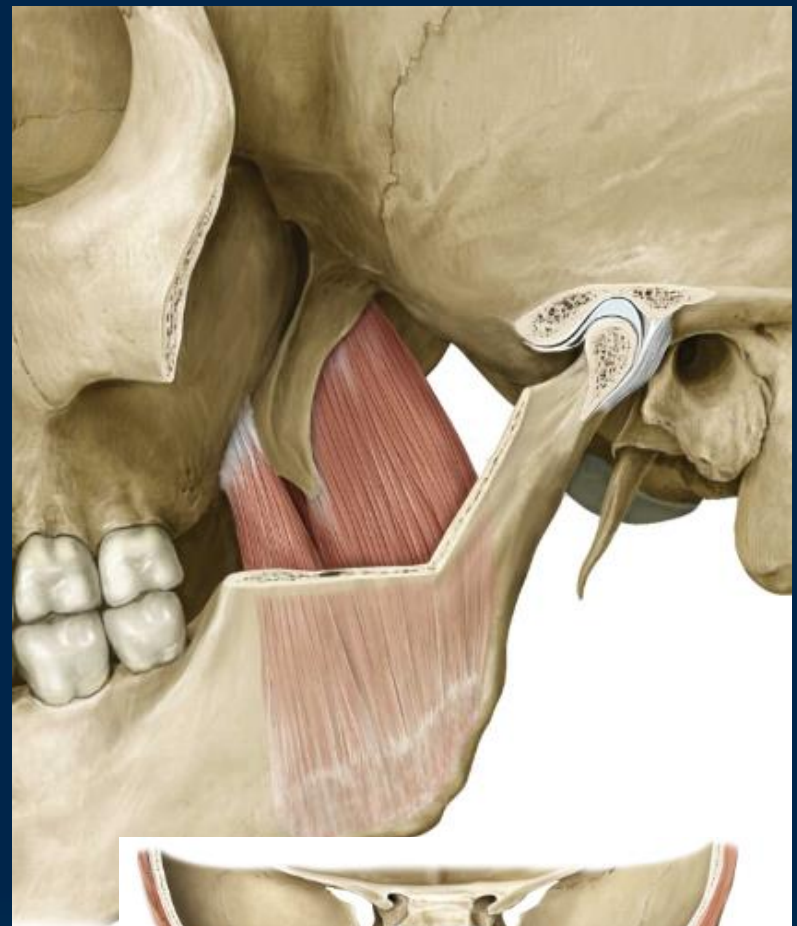
Caput med.

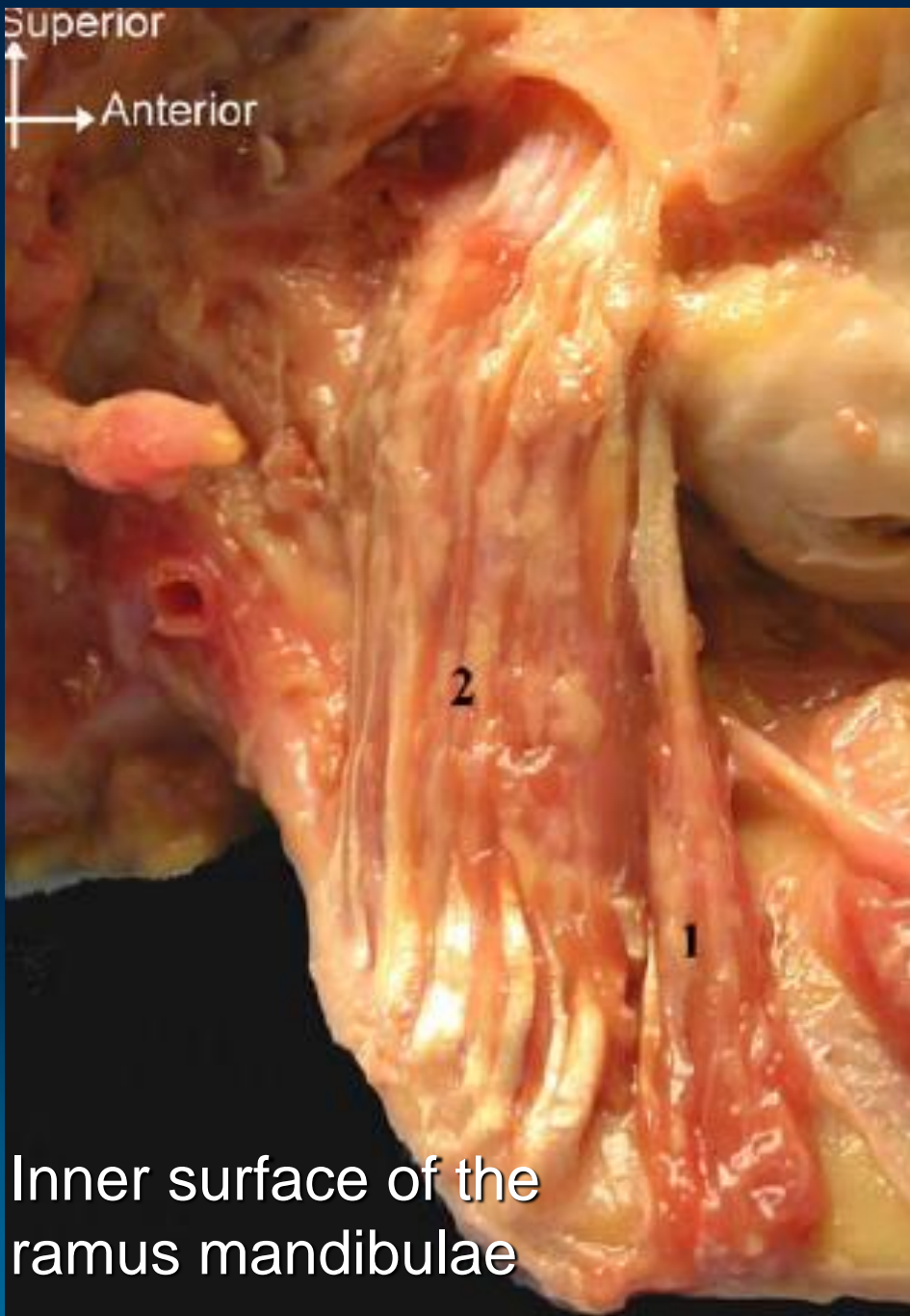
bigger

Origo: fossa pterygoidea, from the med. surface of lamina later. proc. pteryg., proc. pyramidalis ossis palatini

Course of fibers: caudally, dorsally, later.

Insertio: tuberositas pterygoidea med. side angulus mandib., part of ramus mandib. above tuberosity





- 1 - lateral part
- 2 - medial part

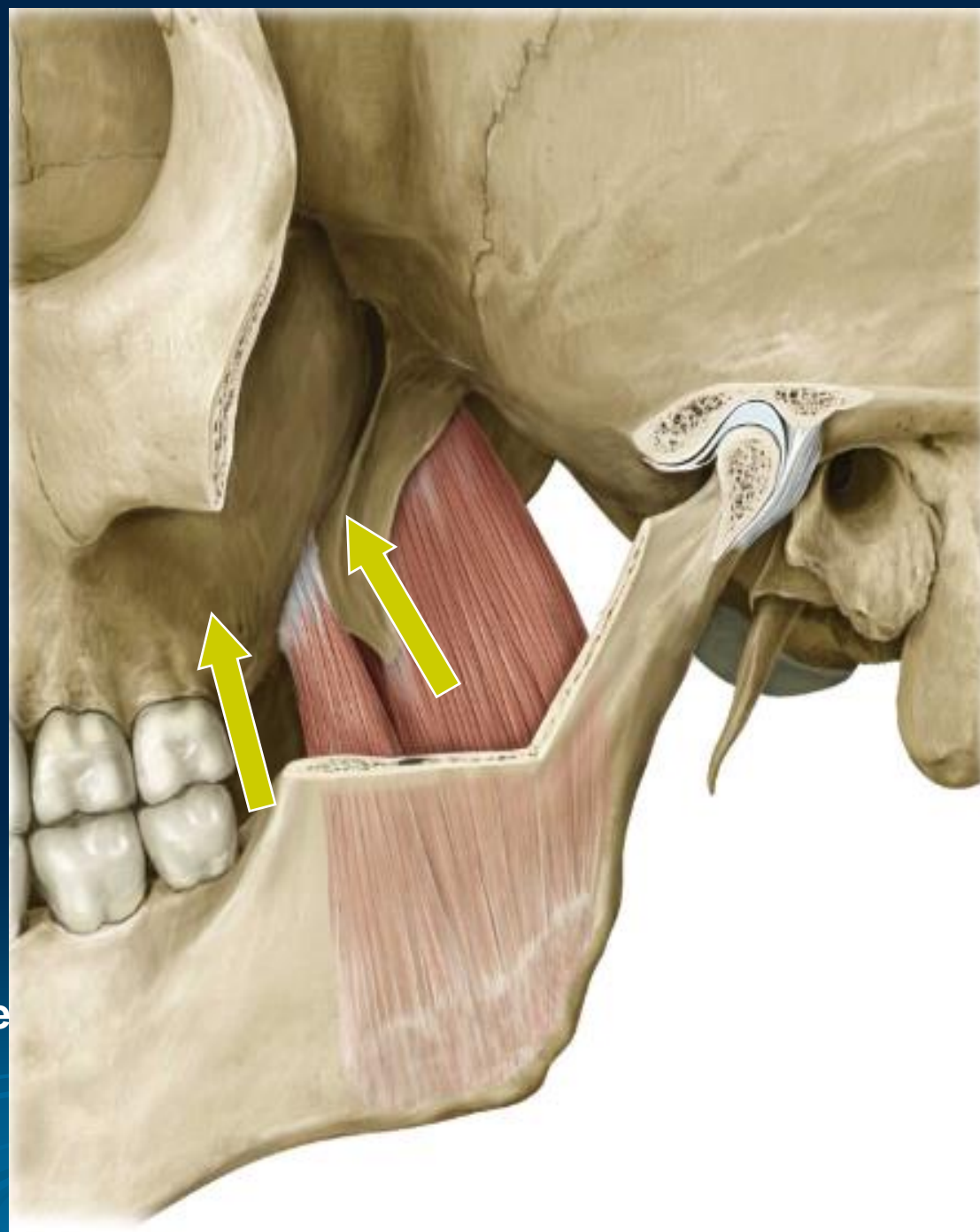
Inner surface of the
ramus mandibulae

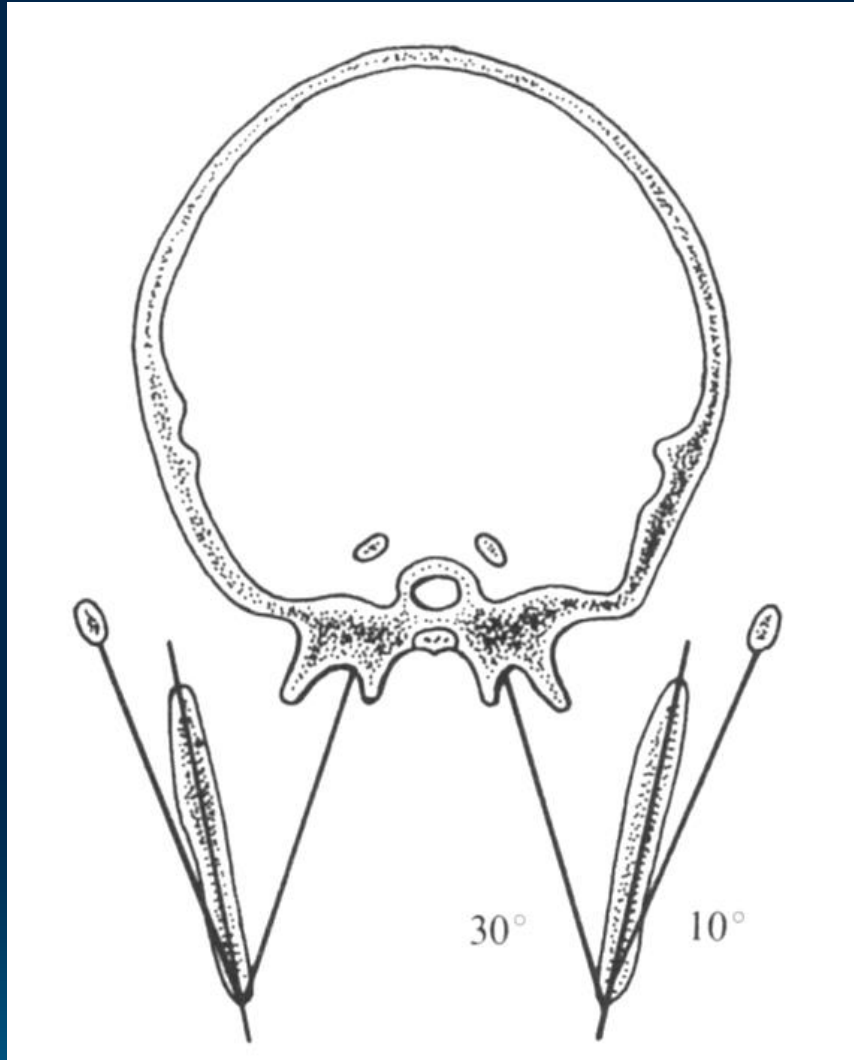
Funktion

Bilateral contraction:
elevation
propulsion

Unilateral contraction
kontralateral
lateropulsion

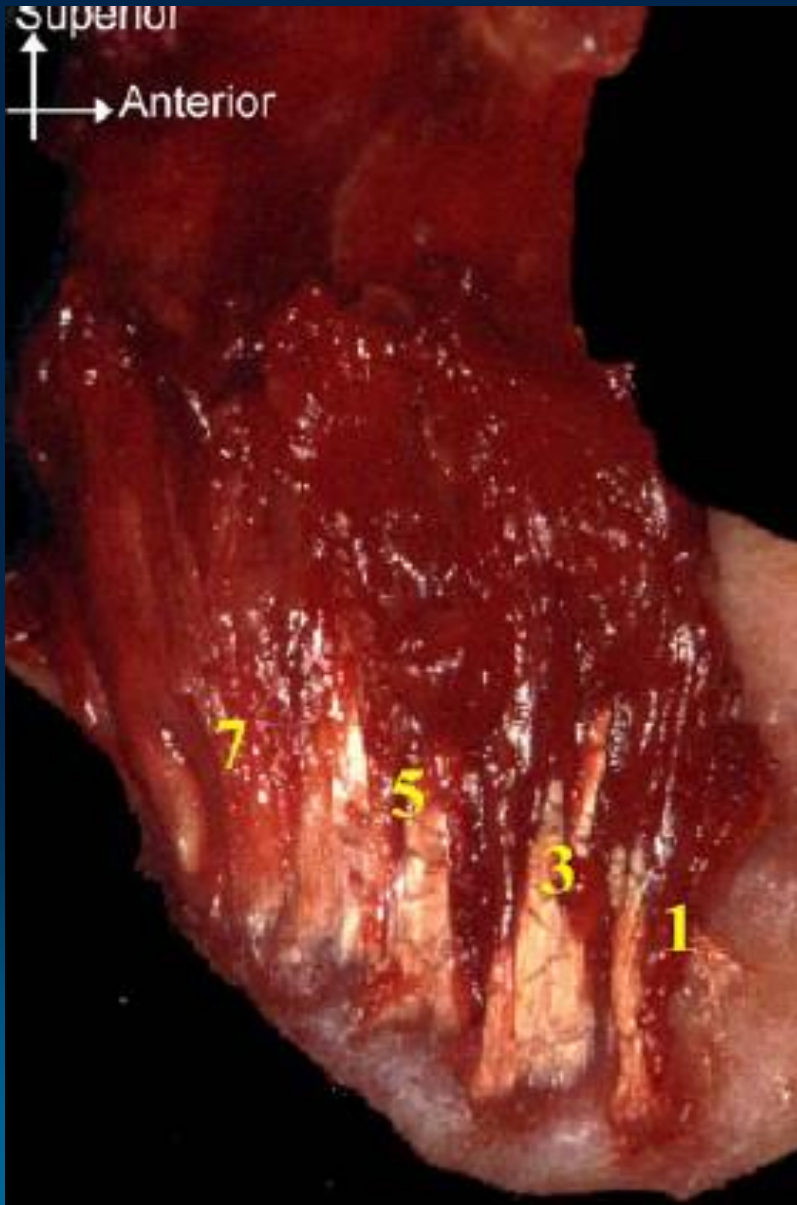The beginning of the muscle is closer to the midline than the attachment, so in a one-sided contraction it pulls the mandible to the opposite side; plays a major role in frictional chewing movements





Some muscle fibres in area of angulus mandibulae could be connected with m. masseter – then create a loop around angulus mandibulae

The Architecture



7 musculo-aponeurotic layers are making up a penniform structure



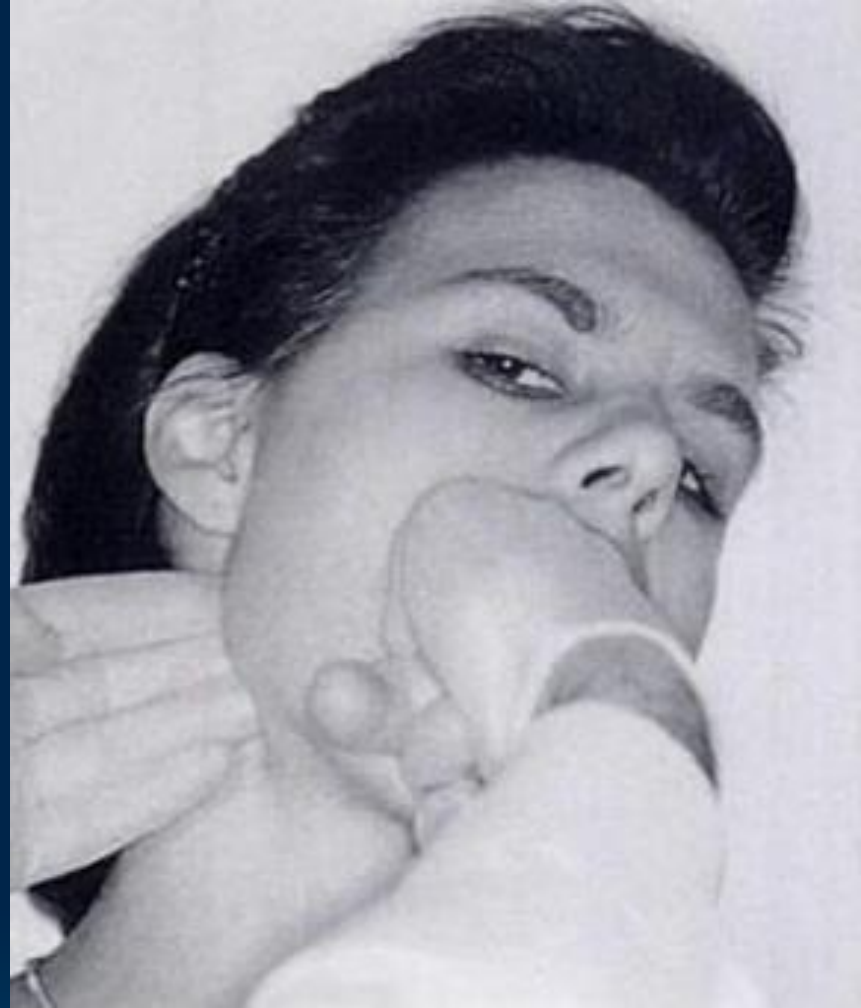
Palpation

Difficult

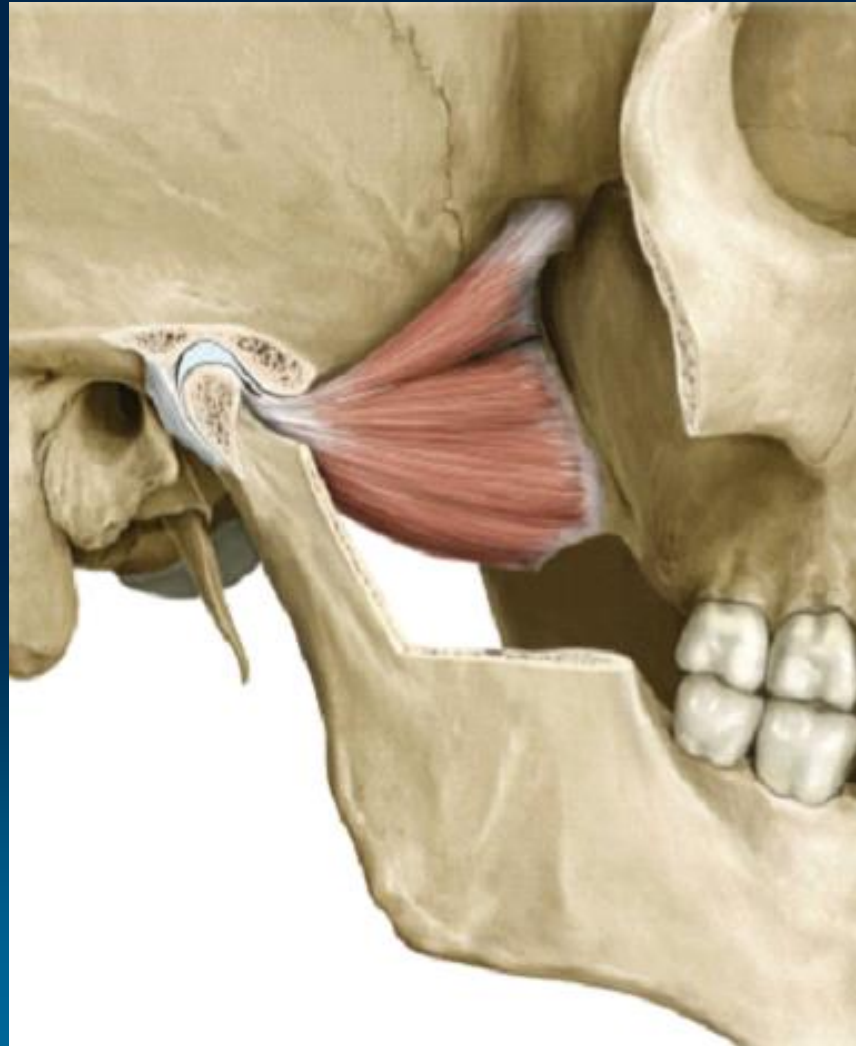
It is performed simultaneously intra and extraorally:

Intraorally: at the site of application of seductive anesthesia and laterally

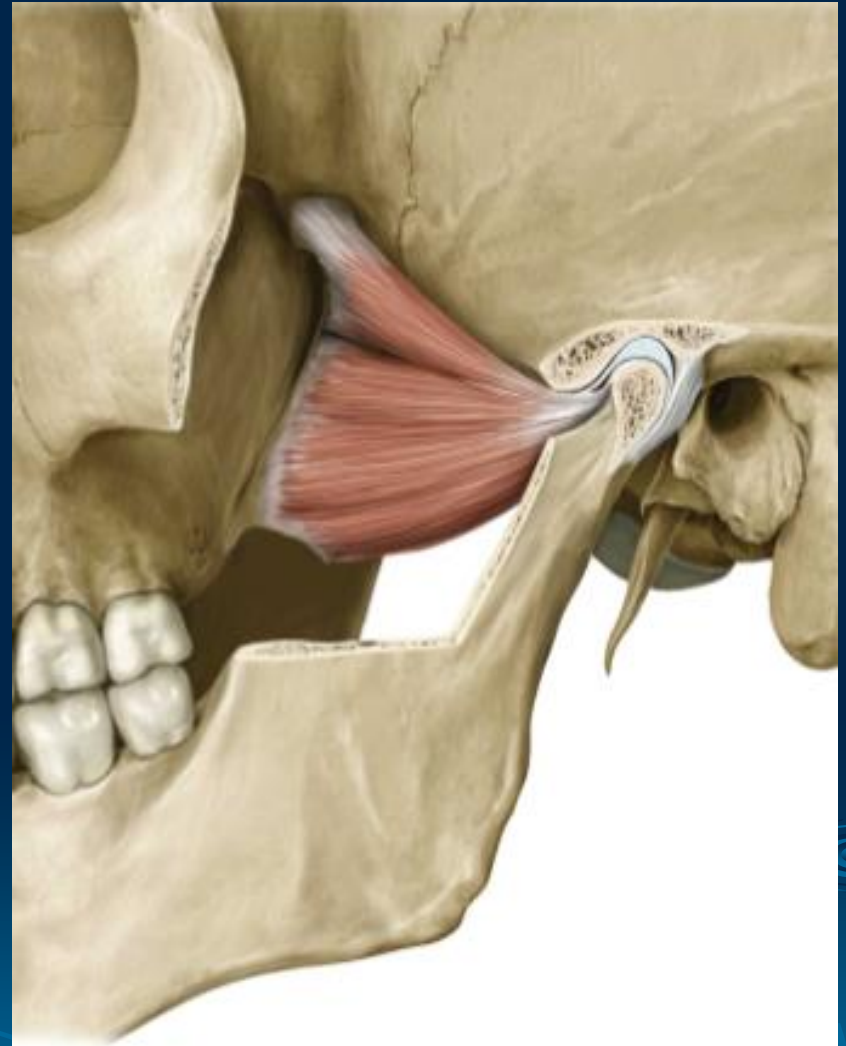
Extraorally: med. From lower edge of ramus mandibulae



Lateral (External) Pterygoid Muscle



- Short, thick muscle, conical in form
- Located in upper part of infratemporal fossa, deep to the temporalis muscle
- Innervation: n. pteryg. lat. (V3)
- Two separate heads of origin, they fuse posteriorly



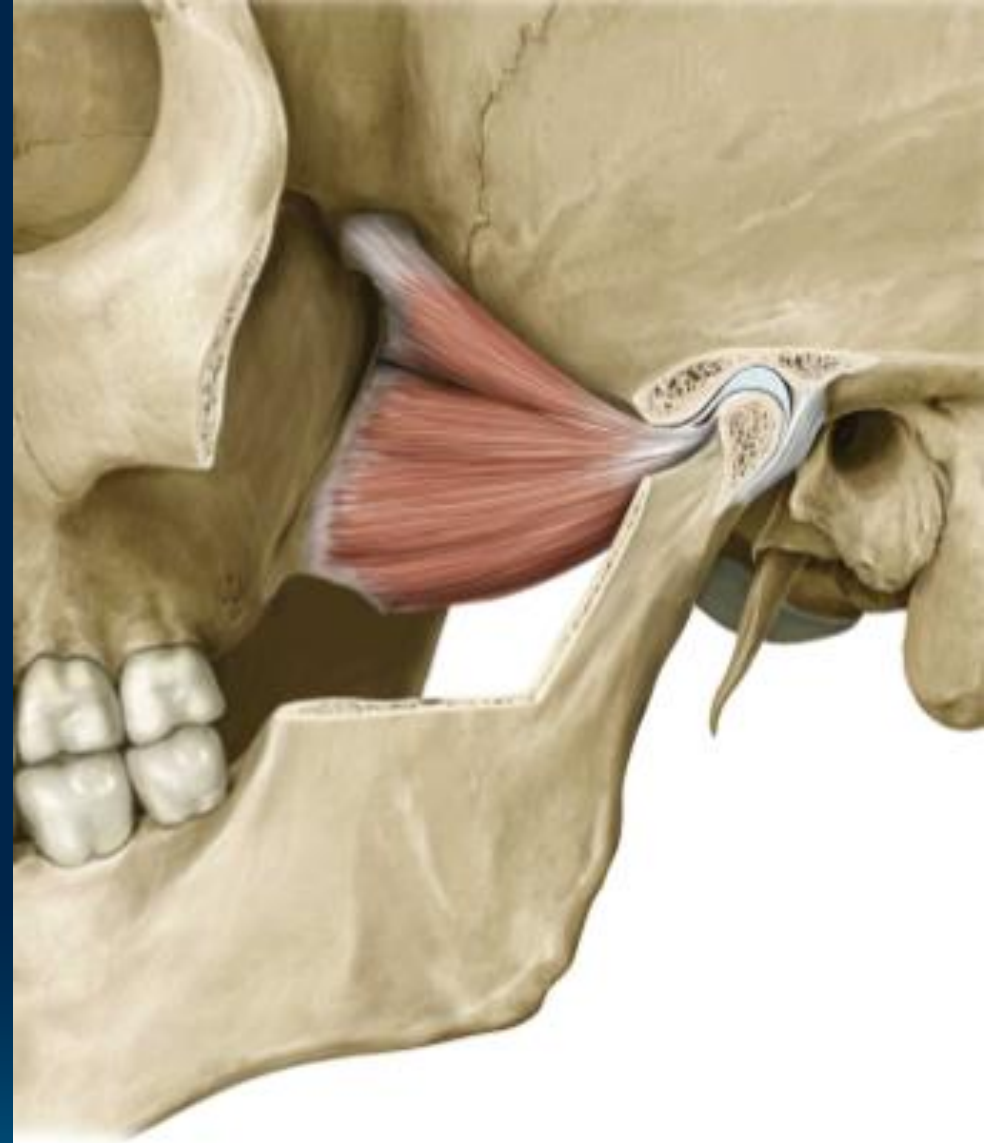
Origo:

caput sup.

**crista infratempor. alae
maj. ossis sphenoidalis**

caput inf.

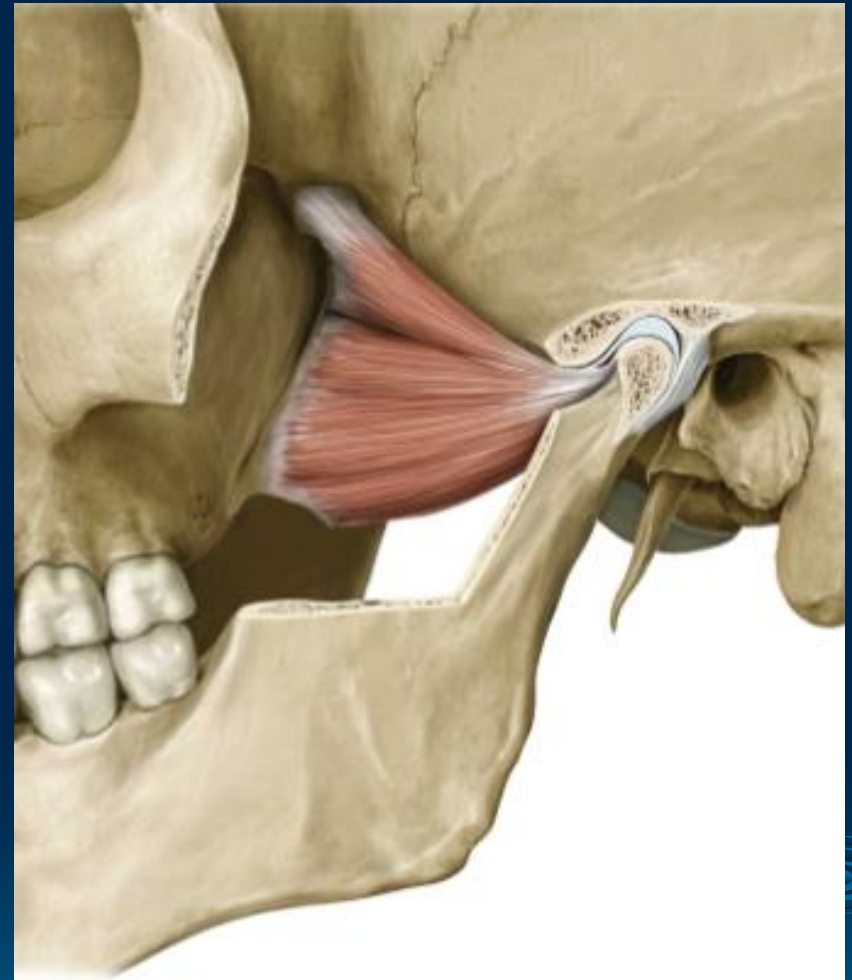
**lower $\frac{3}{4}$ of lat. surface
lamina lat. pr.
pterygoidei**



Fibres pass horizontally backward and laterally

Insertion:

- fovea pterygoidea (depression in front of the neck of the condyle)
- joint capsule and articular disc of the TMJ (front margin)



Function

Bilateral contraction:

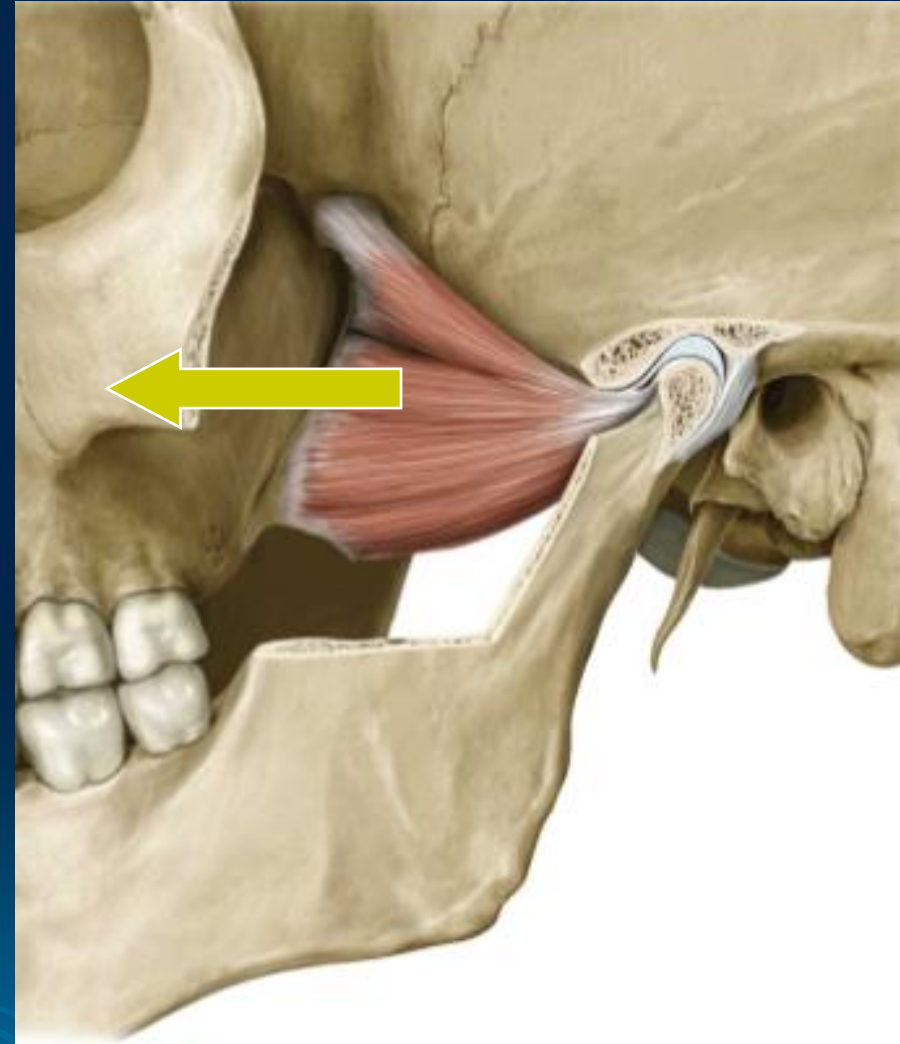
protraction, *brings the lower jaw forward*

Depression, *opening of the jaw*

- tightens the disc and the front part of the joint capsule - prevents it from closing

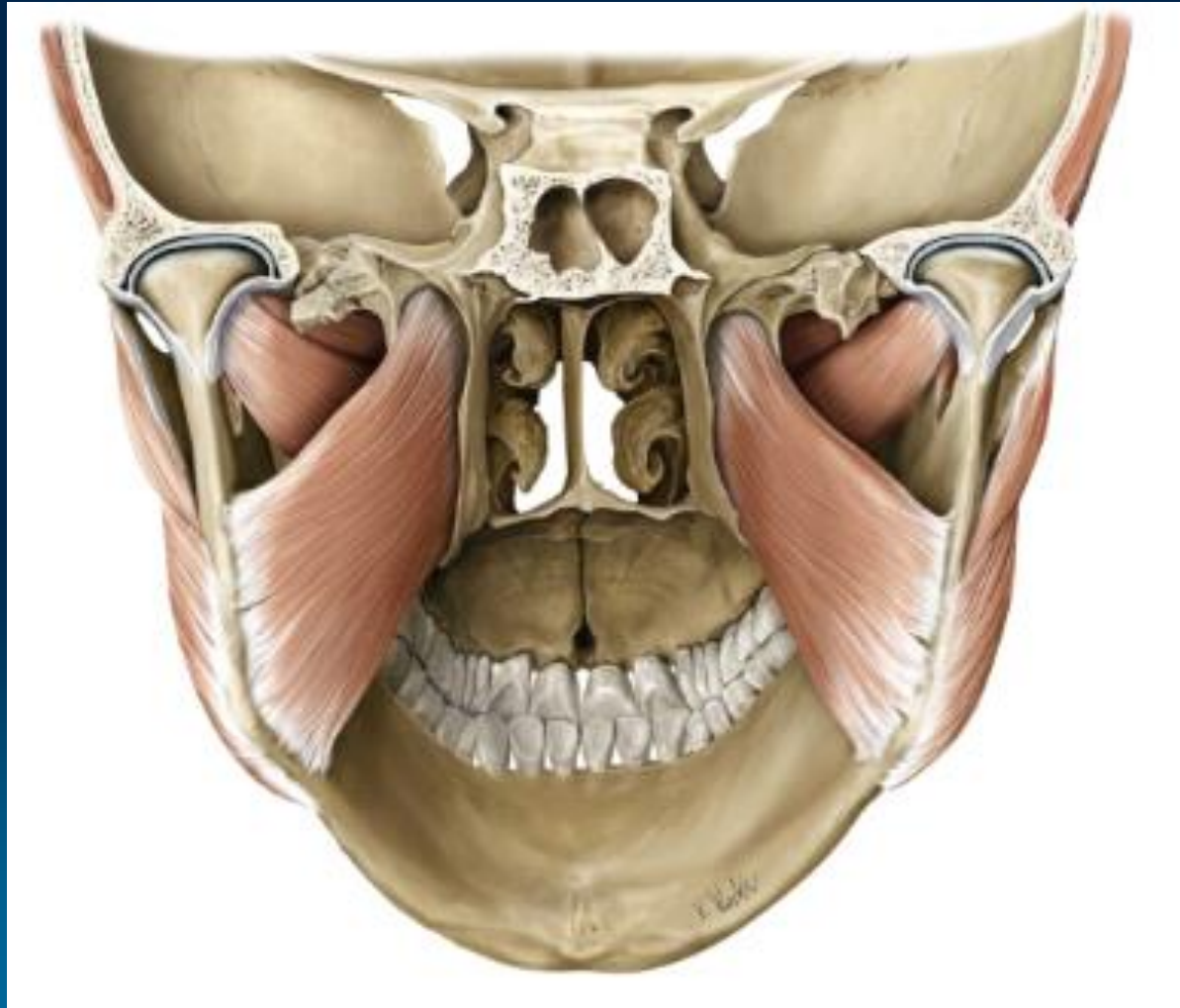
Unilateral contraction:

lateropulsion, *it pulls the jaw to the contralateral side*



Palpation

This muscle is inaccessible to intraoral palpation



The Interpterygoid Fascia

Between the medial and lateral pterygoid muscles

Origo: the base of the skull

Insertion: inner surface of the mandible

The border is reinforced by sphenomandibular ligament

Contain nerves and vessels

Allow spread of infection

From the functional viewpoint, some of suprahyoid muscles pull the mandible caudally and cause the mandibular depression (mouth opening) – **m.mylohyoideus, venter ant. m. digastrici** – and form the masticatory muscles. They both start on corpus mandibulae and are innervated by *n.mylohyoideus (V3)*