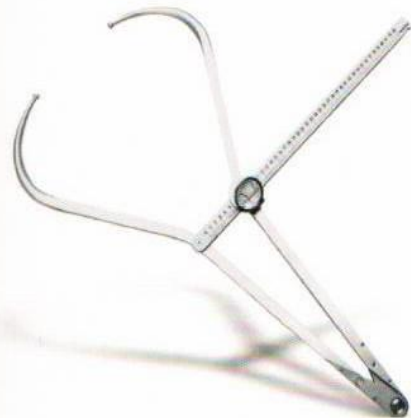

BASIS OF CRANIOMETRY & CEPHALOMETRY

Kefalometr K-211



■ Kefalometr – celkový pohled



■ Kefalometr – lupa



■ Kefalometr – ocelový kloub

Craniometry

*the branch of physical **anthropology** dealing with the study and measurement of **dry skull** after removal of its soft part*

Cephalometry

- *Is a measurement of the **head and facial structures***
- *Is used in **dentistry**, and especially in orthodontics, to gauge the **size and special relationships of the teeth, jaws, and cranium.***
- *This analysis informs about treatment planning, quantifies changes during treatment, and provides data for clinical research*

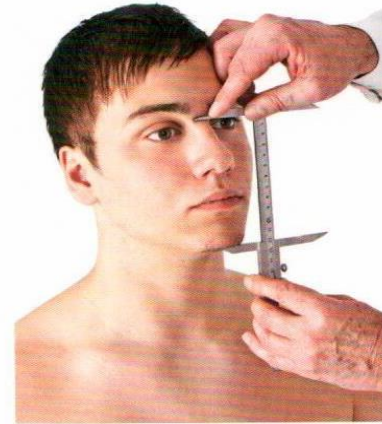

The way of measurement

using antropometric instruments

(sliding gauge, cephalometr)

Obrázek 22.

Posuvné měřítko M-222
praktické použití



Použití kefalometru při měření délky a šířky hlavy a šířky obličeje



■ délka hlavy



■ šířka hlavy



■ šířka obličeje

Craniometric / cephalometric Points



The most important craniometric points

Points marked with Greek or Latin names

Unpaired – *in the middle line*

nasion

glabella

bregma

lambda

opisthocranion

basion

akanthion

gnathion

orale

staphylion

Paired

pteryon

porion

euryon

zygion

gonion

endomolare

UNPAIRED

bregma

glabella

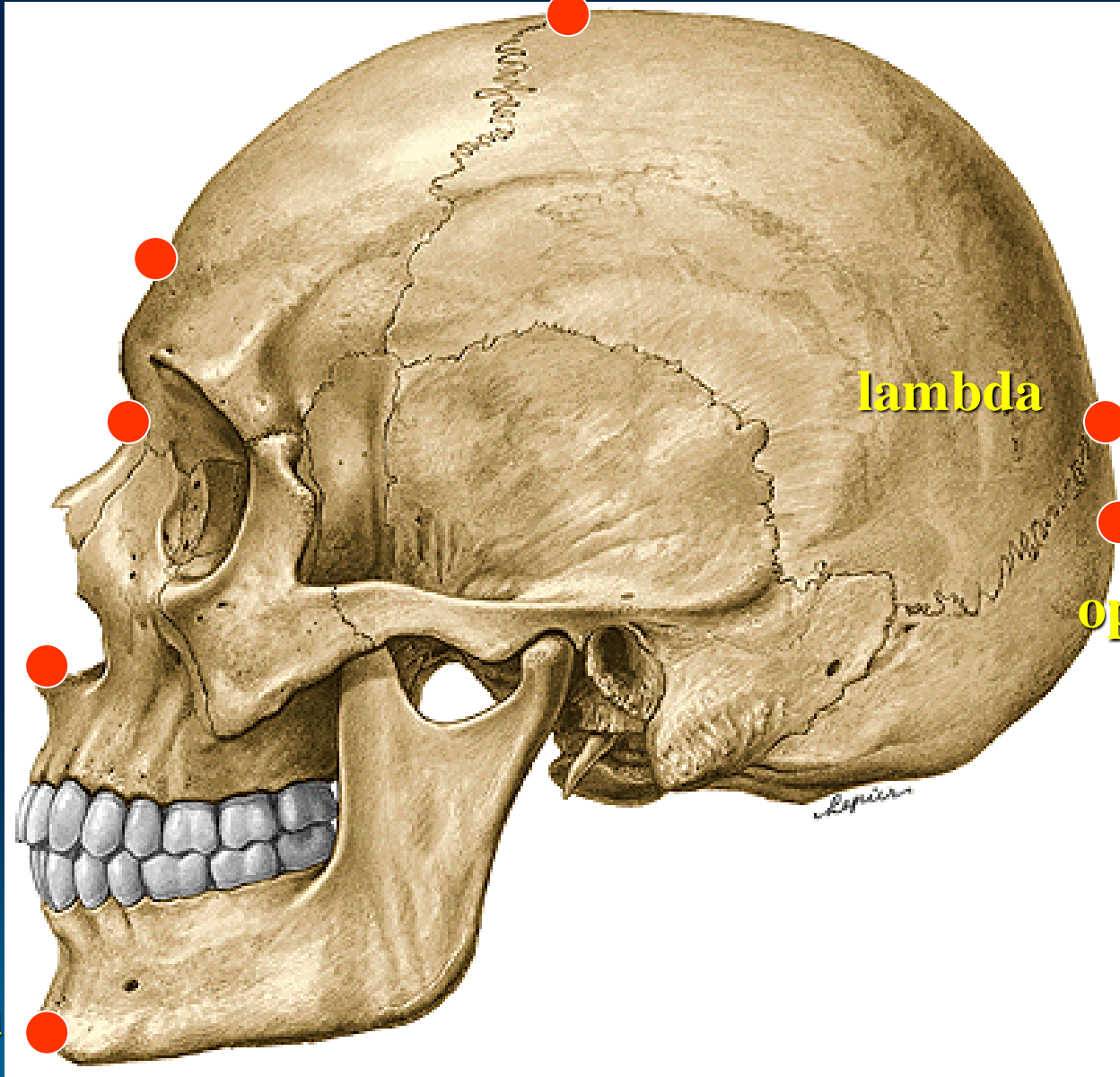
nasion

akanthion

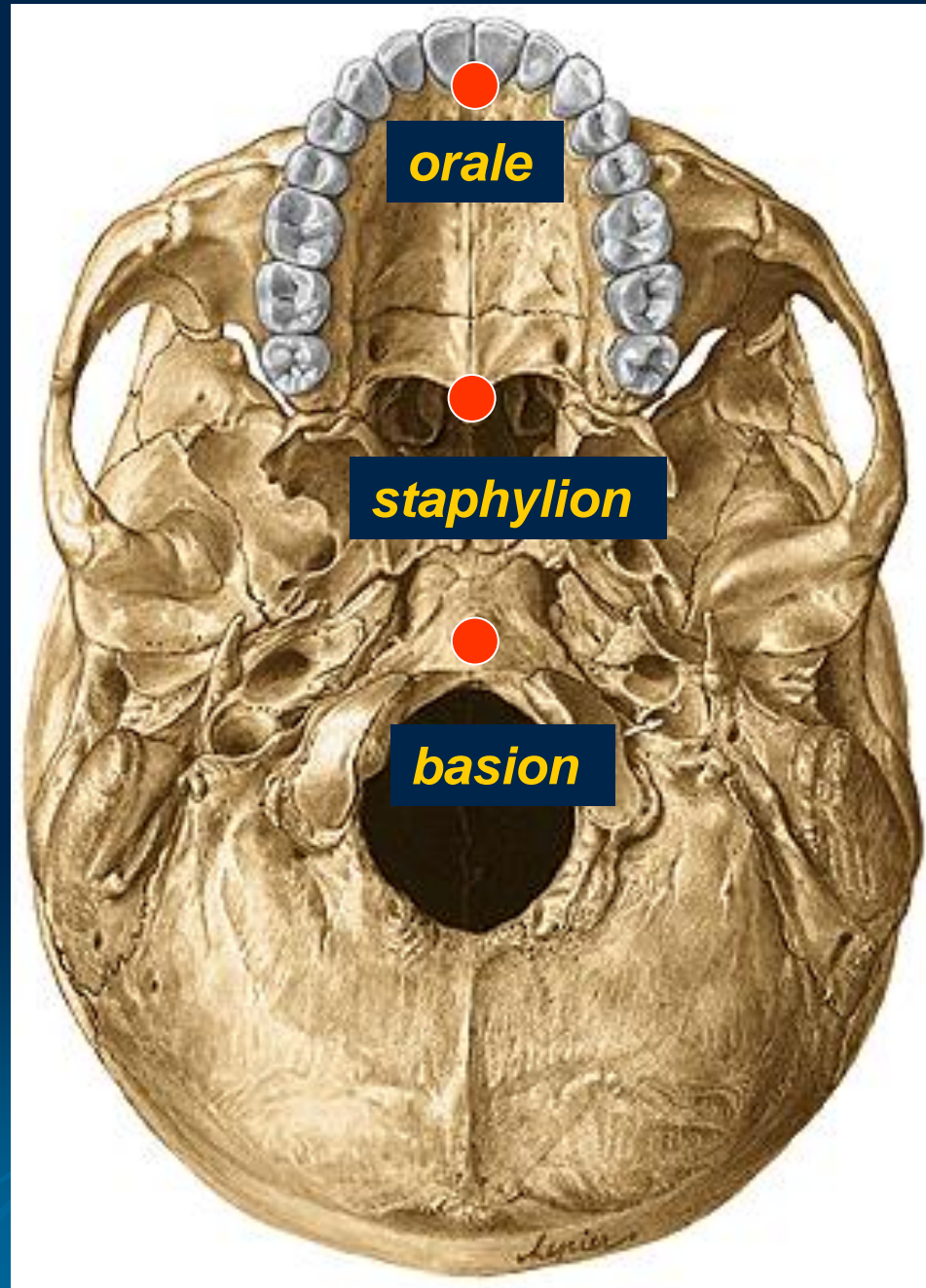
gnathion

lambda

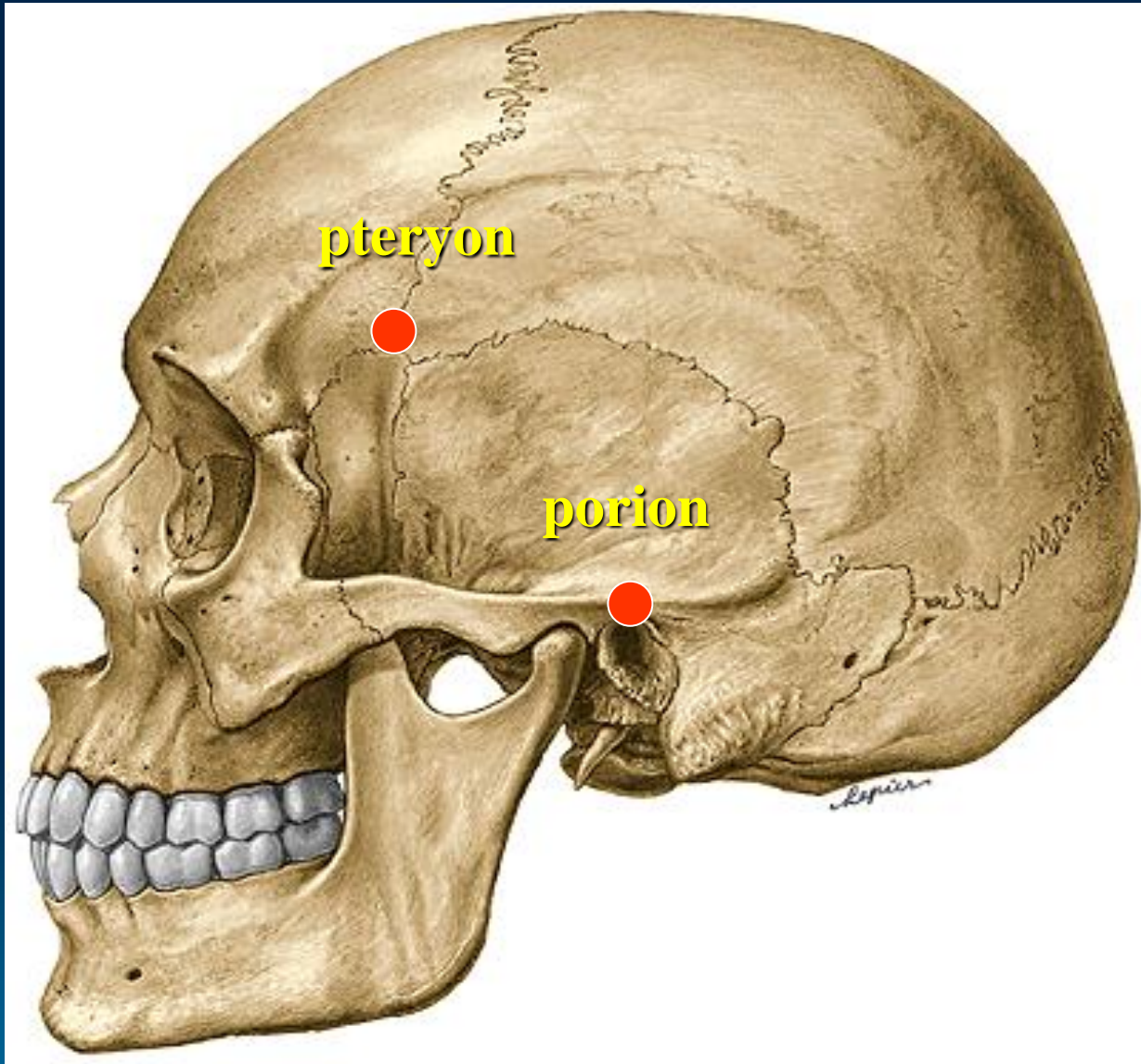
opistocranium



UNPAIRED



PAIRED



PAIRED

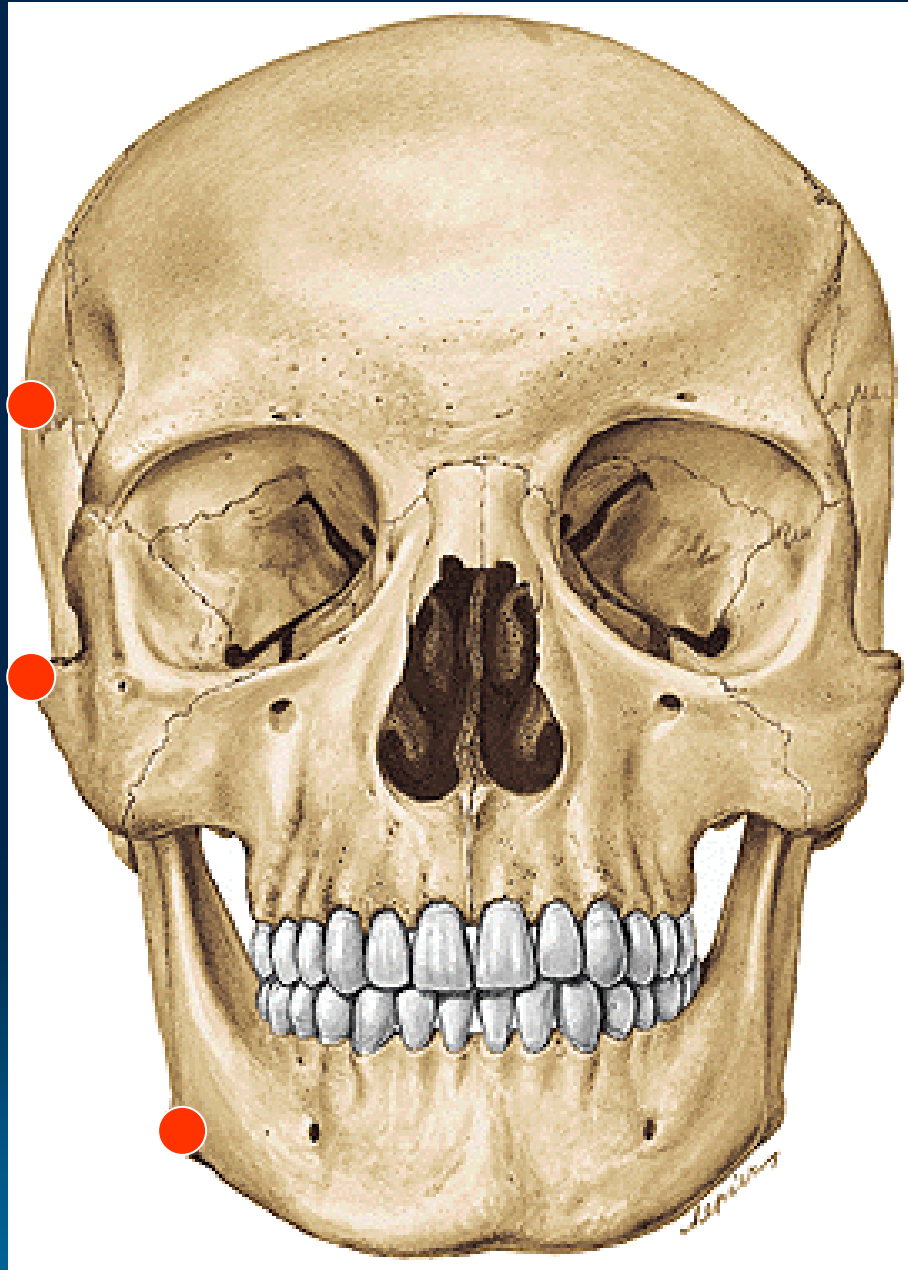
euryon



zygion

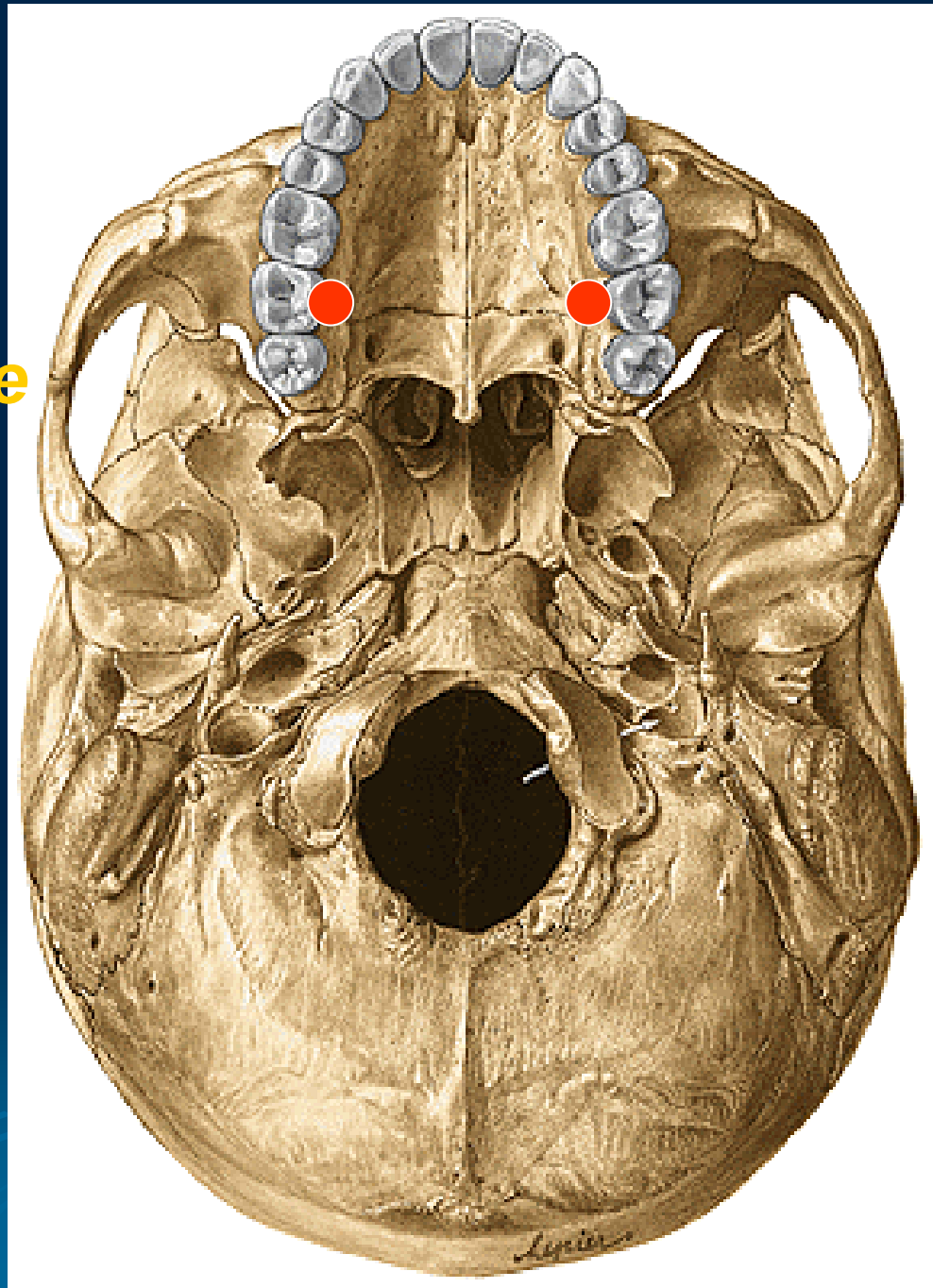


gonion

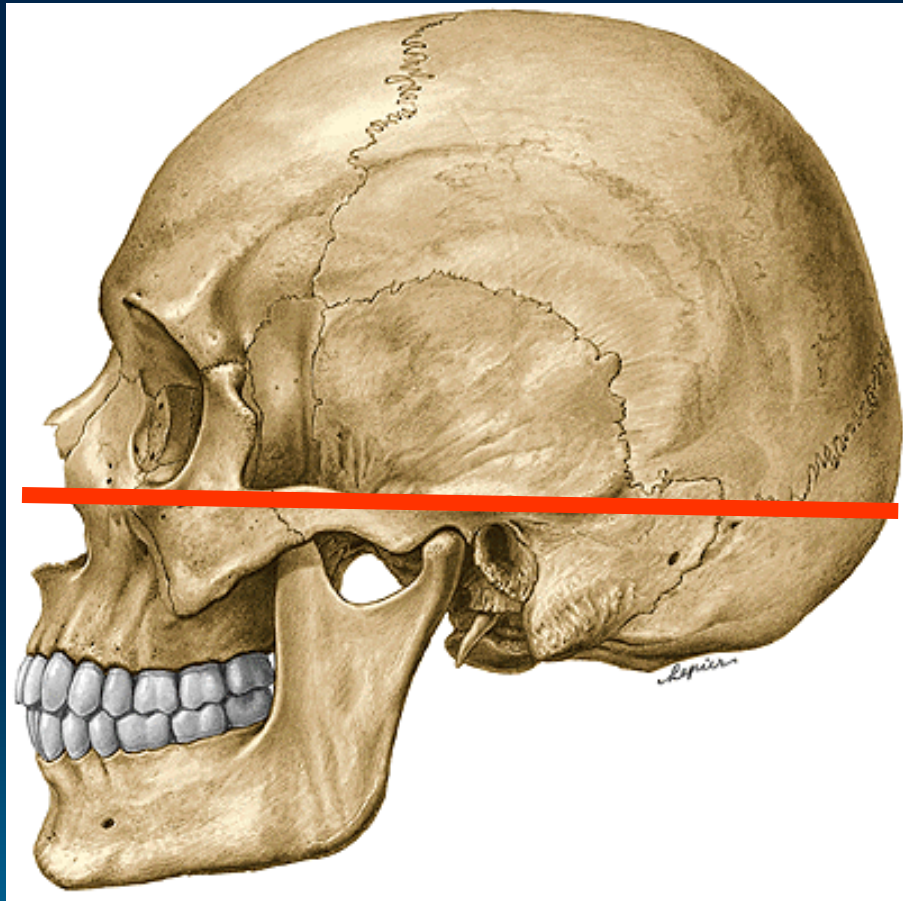


PAIRED

endomolare



Frankfurt horizontal plane



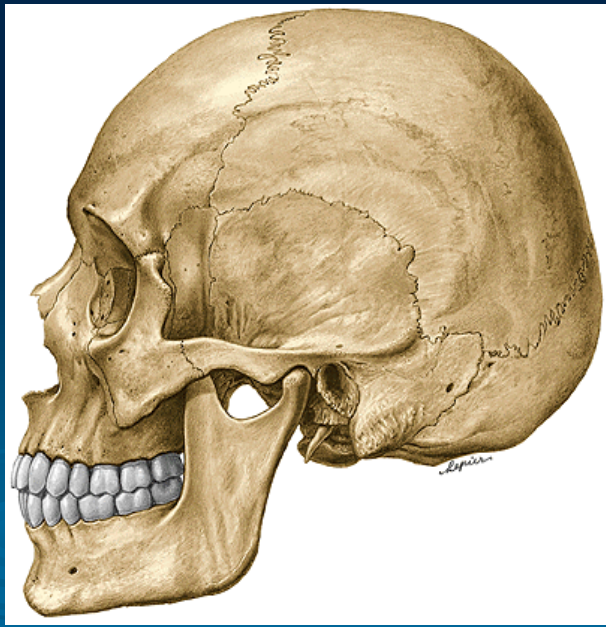
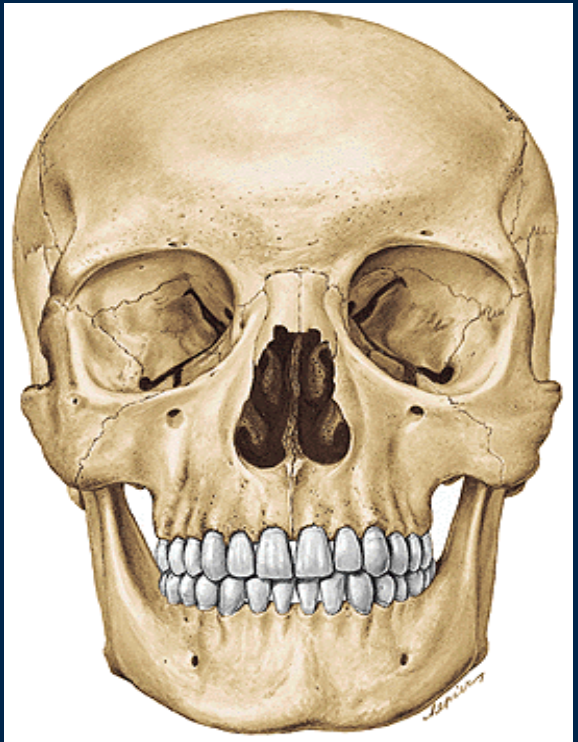
A prerequisite for correct measurement is the position of the head in the basic orientation plane

**linea horizontalis
auriculoorbitalis**

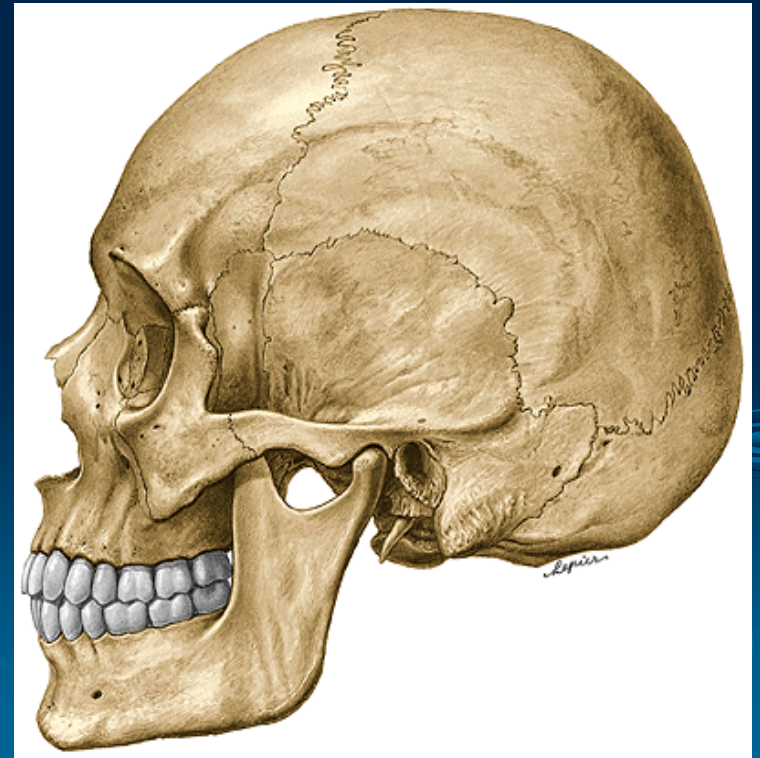

The Size Of The Human Skull



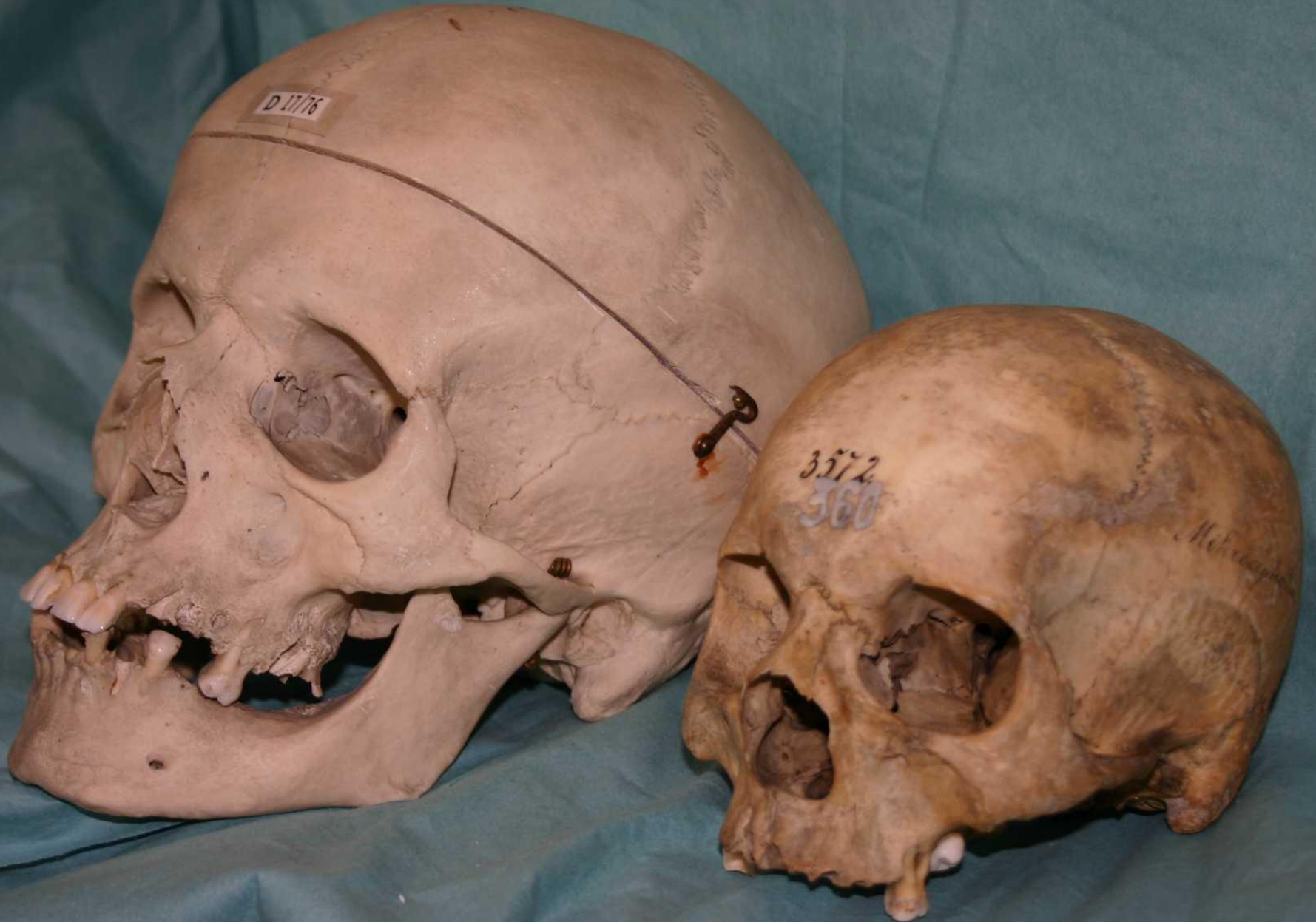	FROM	TO
Length	glabella	opisthocranion
Width	euryon	euryon
Height	bregma	basion
Facial length	nasion	gnathion
Facial width	zygion	zygion
Palatal width	endomolare	endomolare
Palatal length	orale	staphylion



Peripheral measurement - ***circumferentia horizontalis frontooccipitalis***



Variability in the skull size



We distinguish several **specific views** on the measured skull –

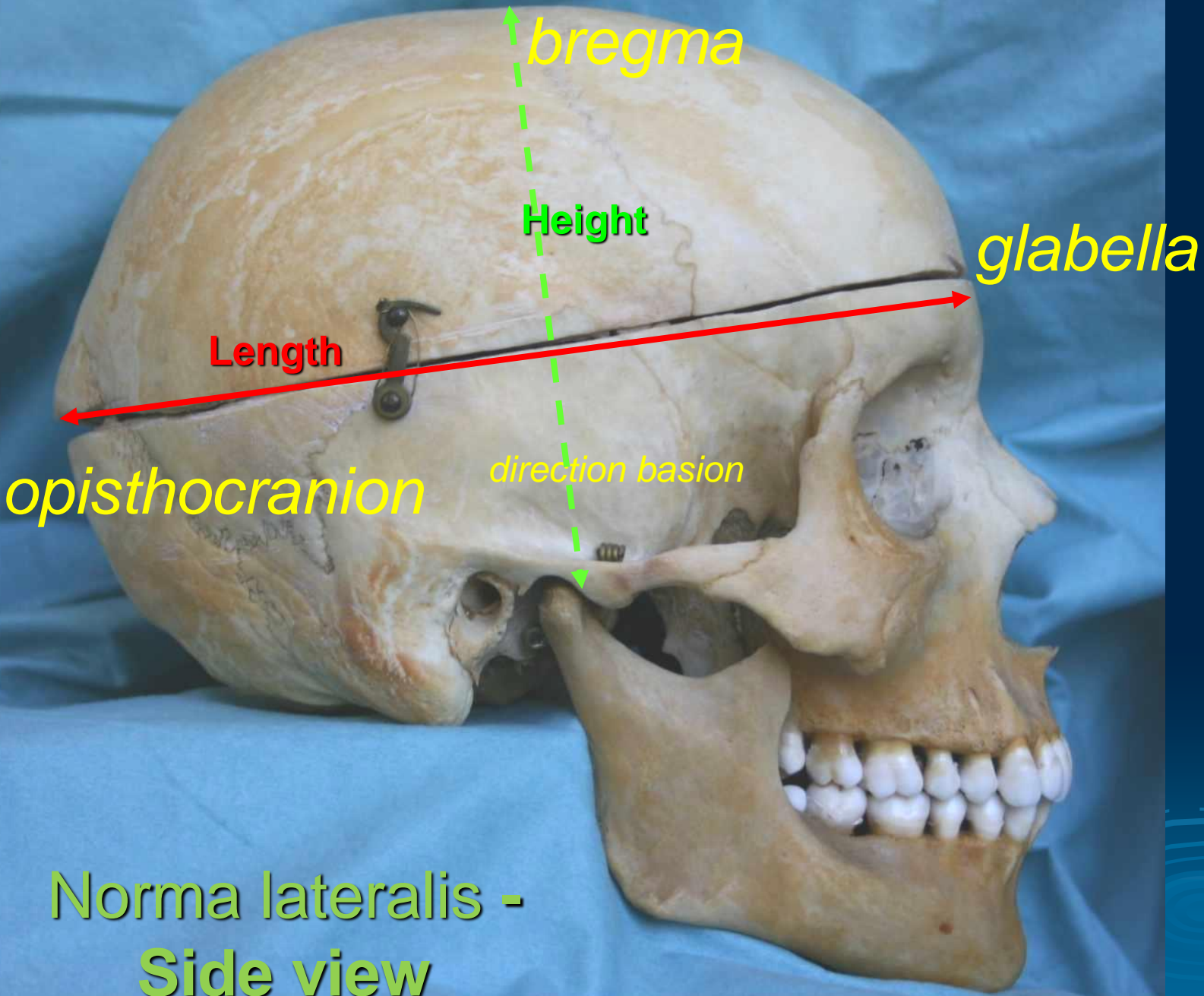
side view (norma lateralis)

front view (norma frontalis)

view from above (norma verticalis)

to be able to compare objectively

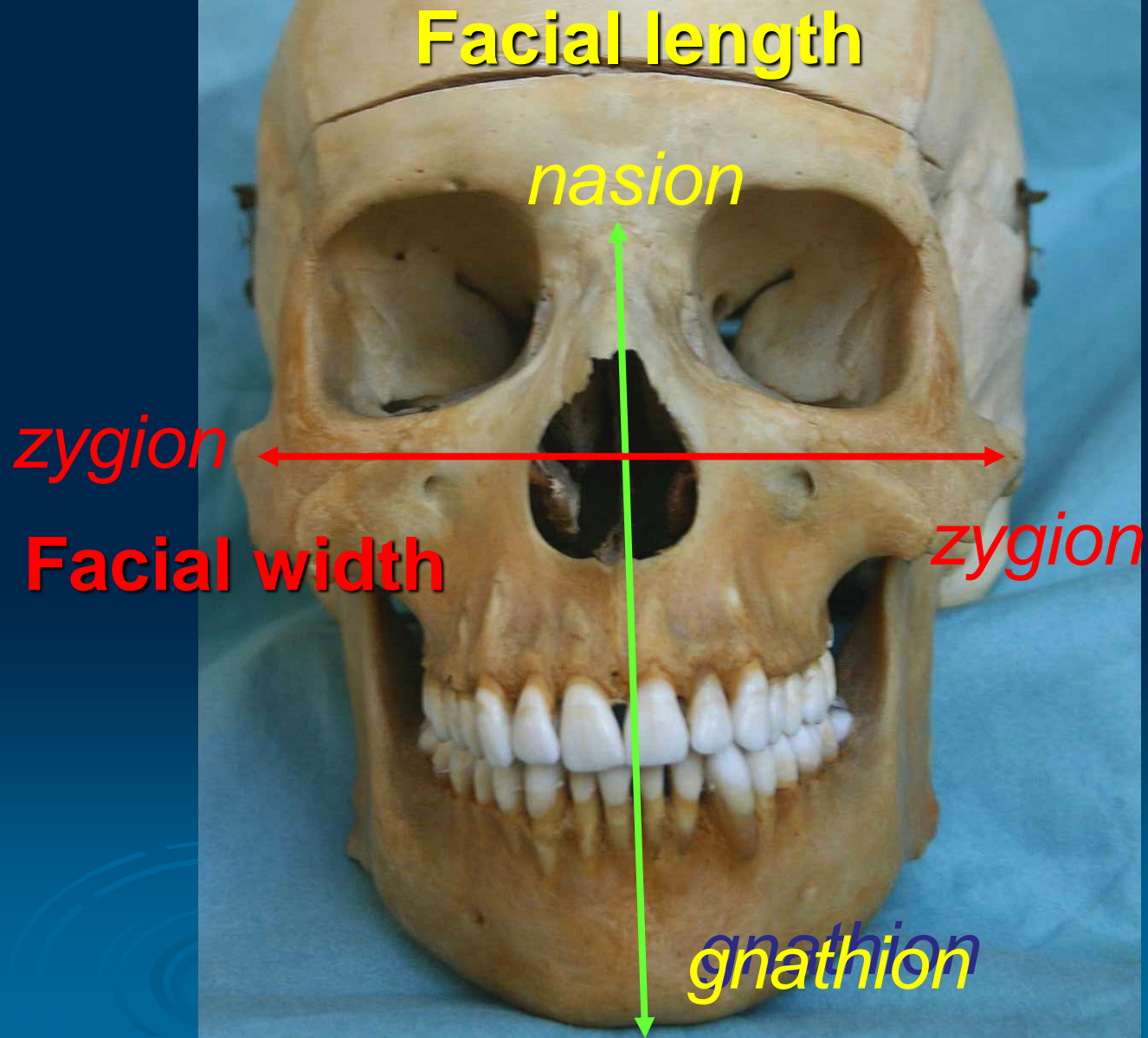




Norma lateralis -
Side view



*Norma frontalis –
front view*



*Norma verticalis –
view from above*

euryon


Width

glabella

Length

opisthocranion

euryon



On the basis of measured parameters we can calculate *indexes*:

Cephalic index (CI)

the ratio of the maximum width of the head multiplied by 100 and divided by its maximum length

Facial index (FI)

the ratio of the length of the face multiplied by 100 divided by width

Palatamaxillary index (PMI)

the ratio of the length of the hard palate to its breadth (width) multiplied by 100

CI	Dolichocephalic $x - 74,9$ (<i>long-headed</i>)
	Mesocephalic $75,0 - 79,9$ (<i>medium-headed</i>)
	Brachycephalic $80,0 - x$ (<i>short-headed</i>)
FI	Leptoprosopic $90,9 - x$ (<i>long narrow face</i>)
	Mesoprosopic $85,0 - 89,9$ (<i>average width face</i>)
	Euryprosopic $x - 84,9$ (<i>short broad face</i>)
PMI	Leptostaphylic $x - 79,9$ (<i>narrow palatum</i>)
	Mesostaphylic $80,0 - 84,9$ (<i>average width</i>)
	Eurystaphylic $85,0 - x$ (<i>broad palatum</i>)

Clinical Diagnosis of Orofacial Anomalies

Use of craniometry in dentistry



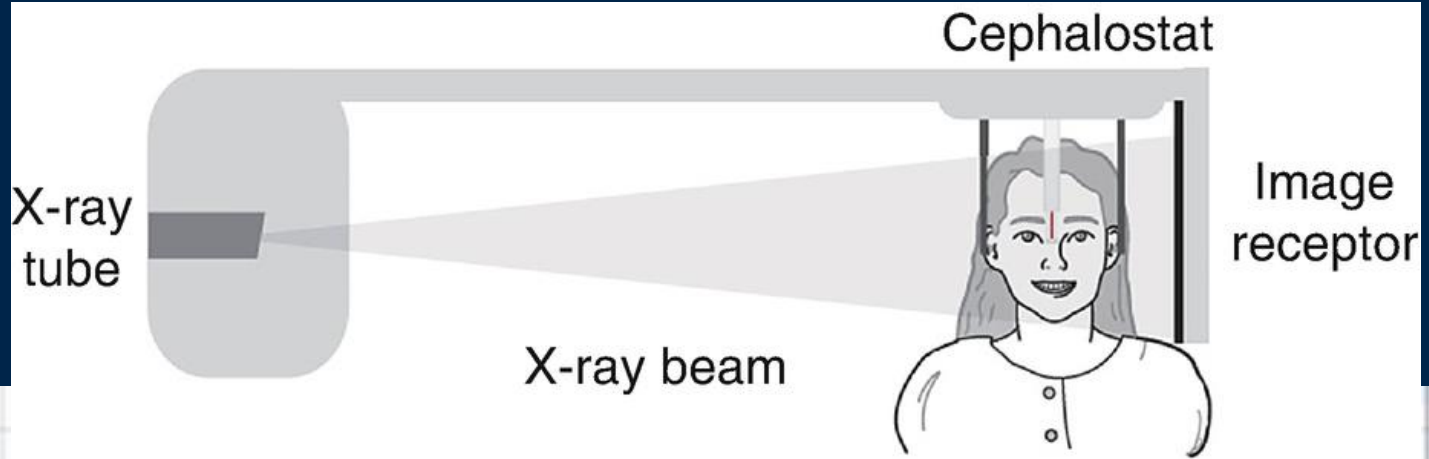
- Anamnesis (patient's medical history)
- Examination of orofacial region:
 - Intraoral, extraoral
 - Functional
 - Others: photographs (en face, profile), analysis of models, X-rays: **1.orthopantomogram (OPG)**
2.teleradiography – basis for cephalometric analysis



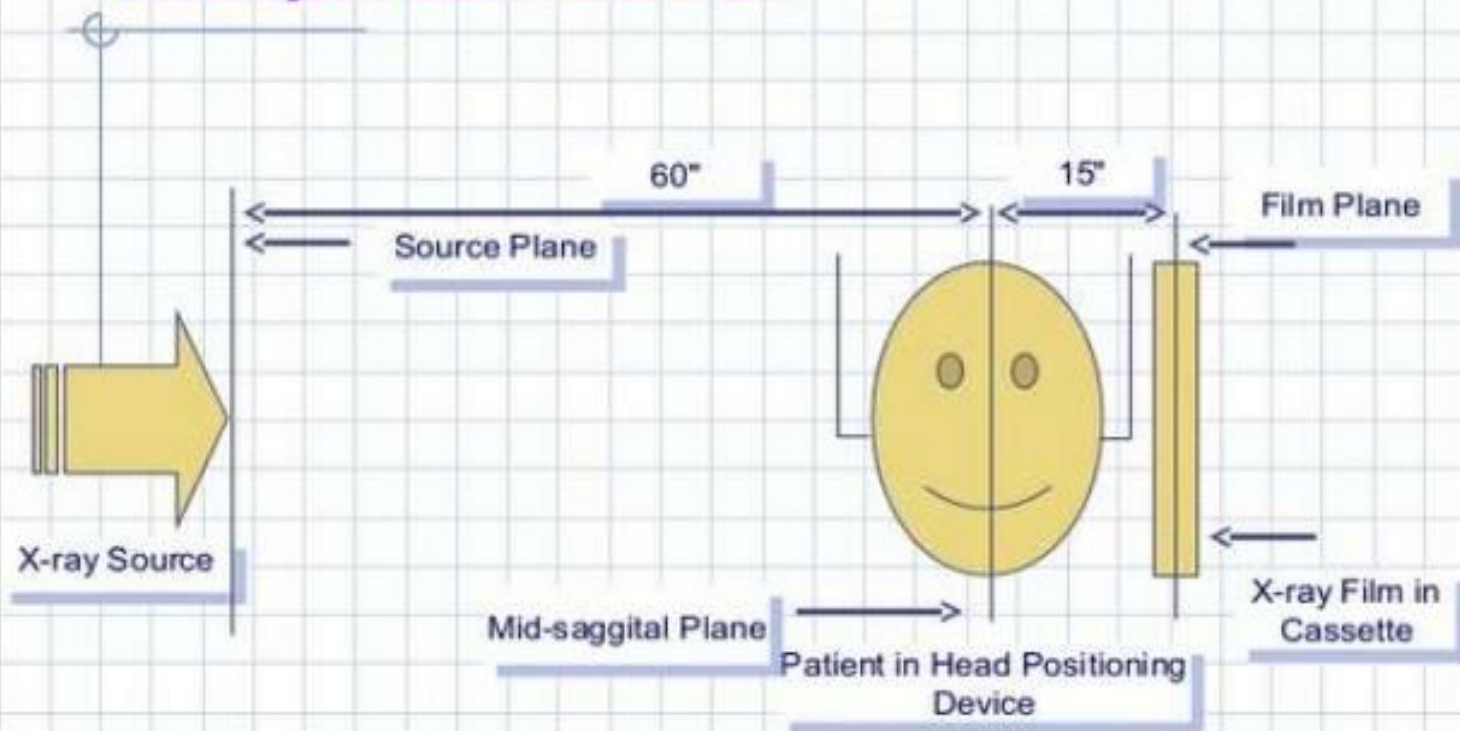
2. Cephalometry

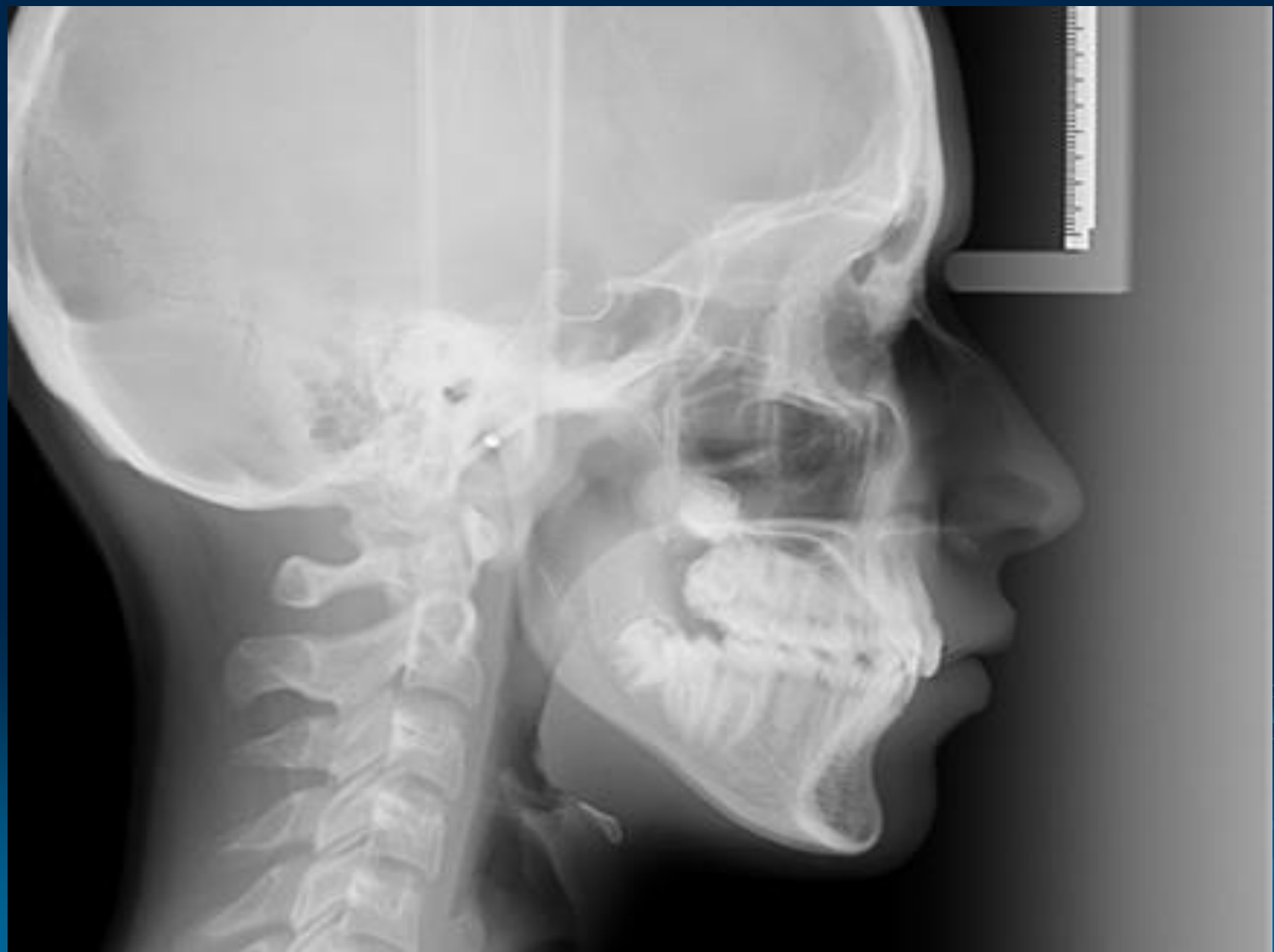- *A standardized and reproducible form of skull radiography used extensively **in orthodontics** to assess **the relationships of the teeth to the jaws and the jaws to the rest of the facial skeleton***
- *Main indications - monitoring treatment progress, preoperative evaluation of skeletal and soft tissue patterns, postoperative appraisal of the results of surgery and long-term follow-up studies*

- *The patient is positioned within the **cephalostat** in the Frankfort plane horizontal, teeth should be in maximum intercuspation*
- *The head is immobilized within the apparatus with the plastic ear rods being inserted into the external auditory meati*
- *The X-ray beam is horizontal and centred on the ear rods*
- *Soft x-rays*



Cephalostat





Cephalometric Analysis



S Sella mid point of sella turcica

N Nasion most anterior point on fronto-nasal suture

Or Orbitale most inferior anterior point on margin of orbit

Po Porion upper most point on bony external auditory meatus

ANS anterior Nasal Spine

PNS posterior Nasal Spine

Go Gonion most posterior inferior point on angle of mandible

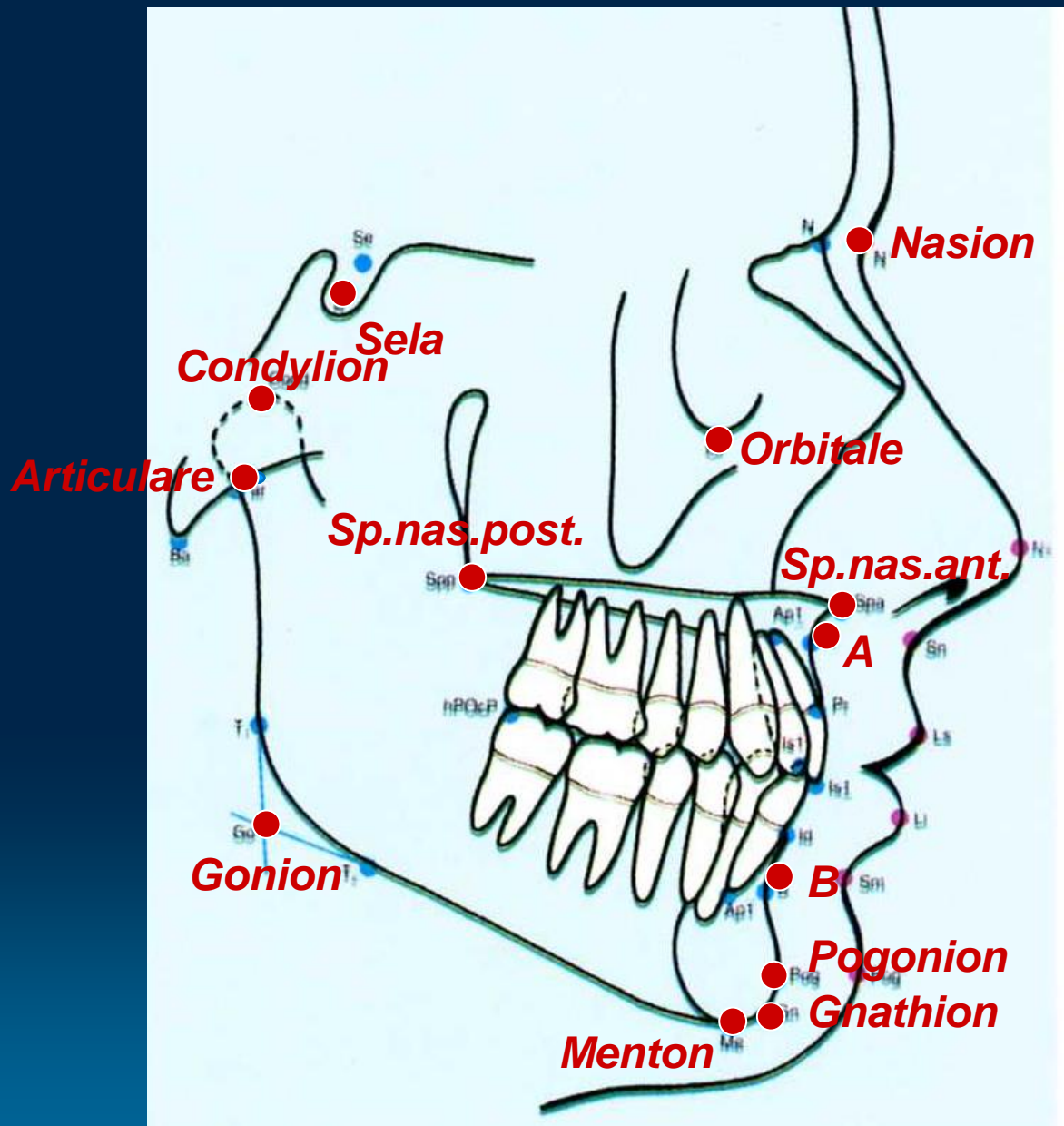
Me Menton lowest point on the mandibular symphysis

A point deepest concavity on anterior profile of maxilla

B point deepest concavity on anterior profile of mandibular symphysis

Pog Pogonion the most ventr point of the bony chin in the med plane

Ar Articulare intersection of the shadow of ramus mandib. and the lower edge of the base of the skull

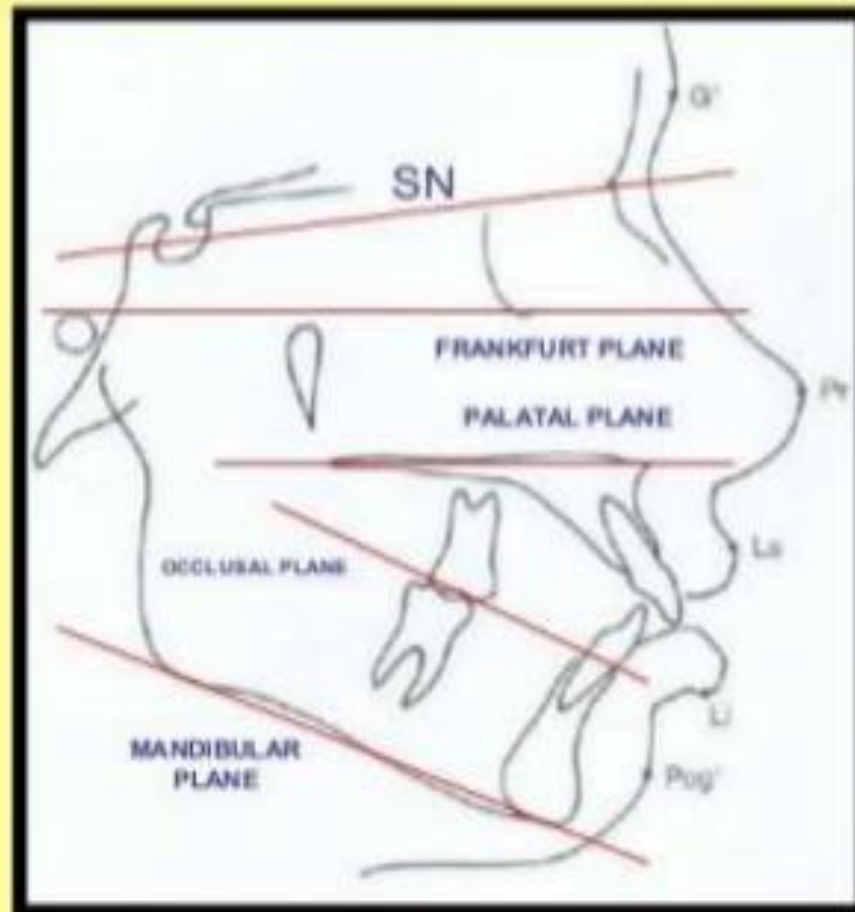


Frankfort Plane Po - Or Equivalent to the true horizontal when patient is standing upright

Maxillary Plane PNS - ANS Gives inclination of maxilla relative to other lines/planes

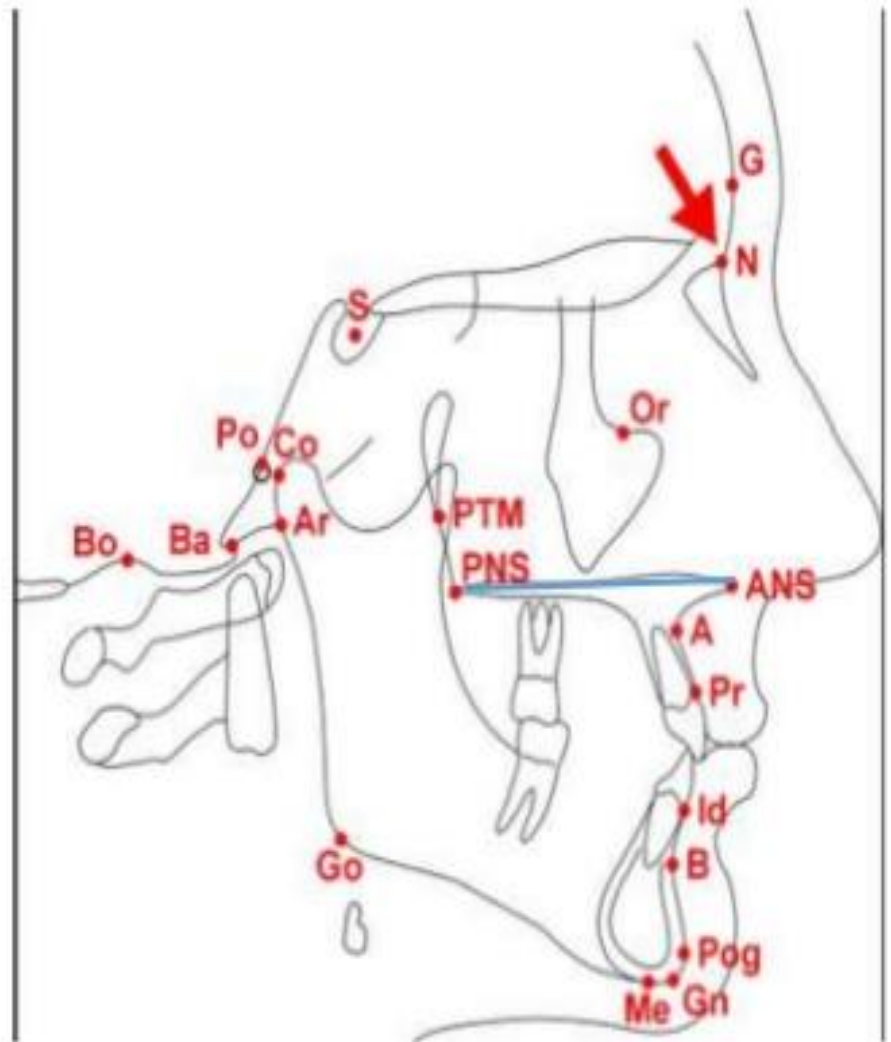
Mandibular Plane Go - Me Gives inclination of mandible relative to other lines/planes

CEPHALOMETRIC PLANES



PALATAL PLANE

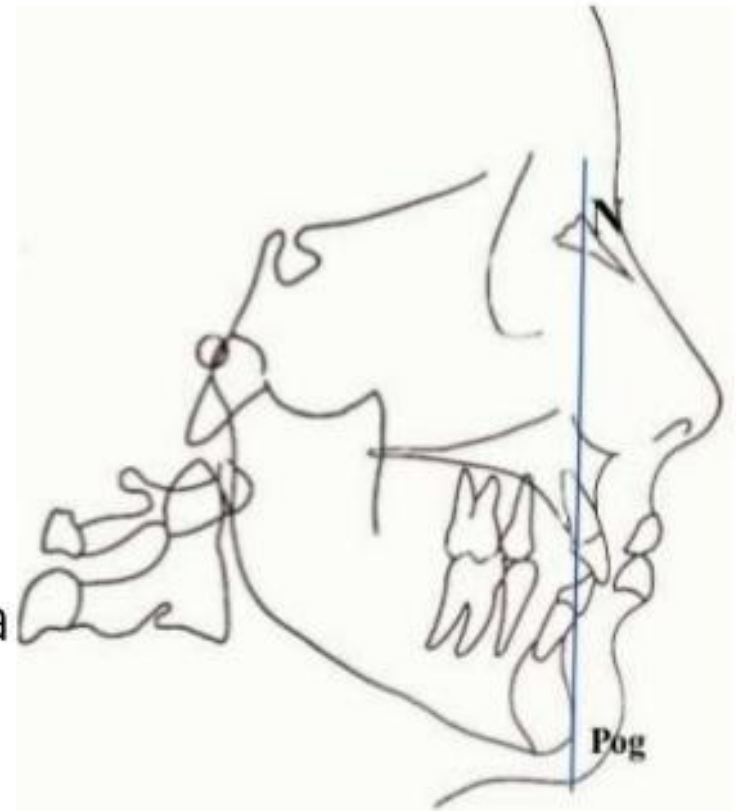
- This plane extends through the ANS to PNS.
- The relationship of this plane to FH plane is useful in evaluating treatment changes occurring in the maxilla.
- Assessment of remaining alveolar bone for implant placement.



FACIAL Plane :

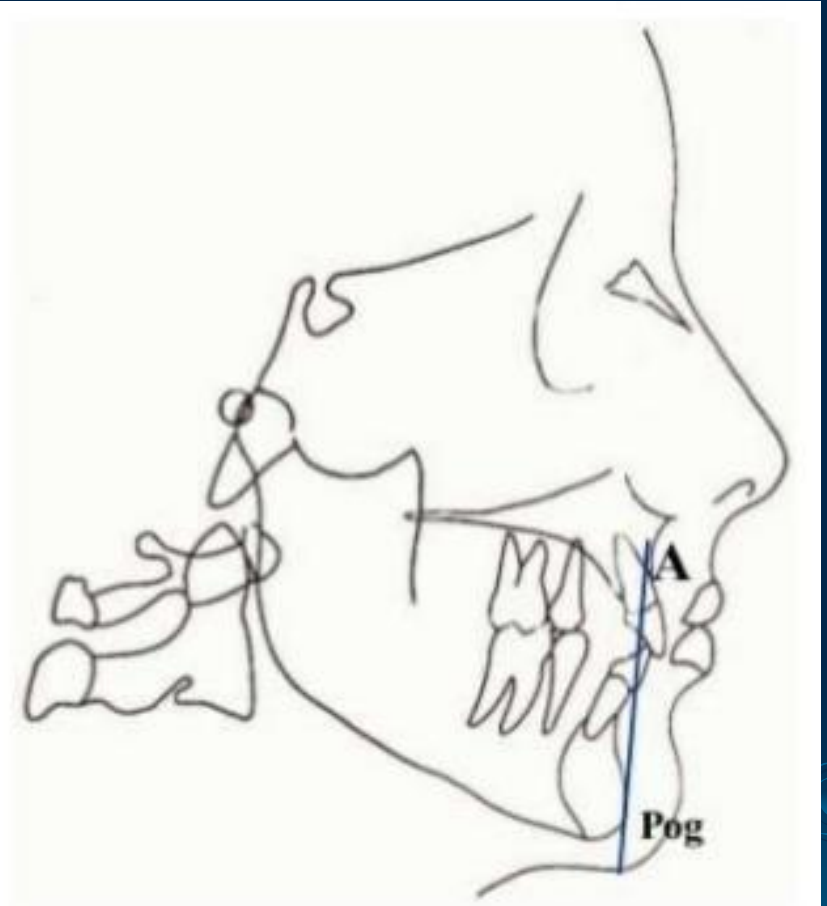
It is a line from the anterior point of the frontonasal suture (N) to the most anterior point of the mandible (Pog).

Used to record position of chin.
And to relate position of maxilla to facial plane.



A-Pog plane:

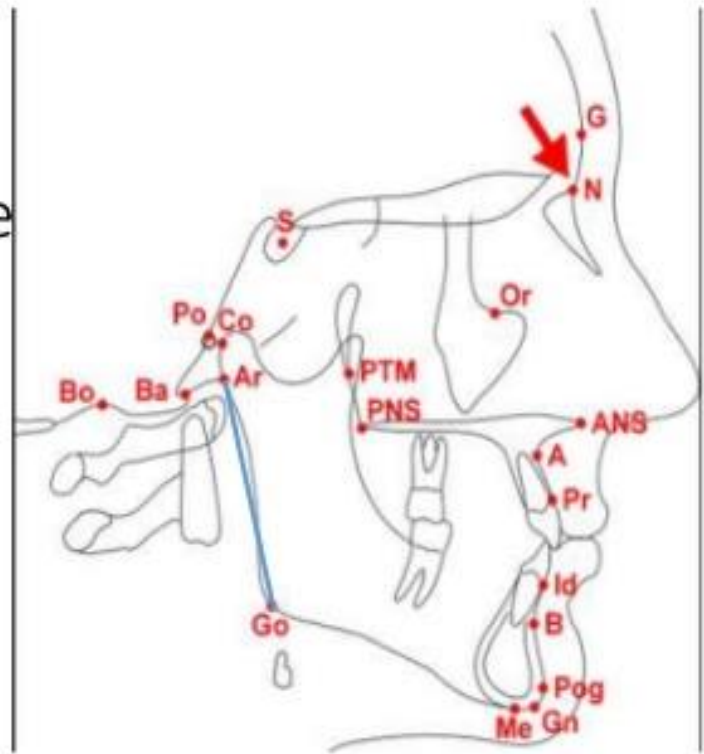
- It is a line from point A on the maxilla to pogonion on the mandible.
- Also known as Dental plane.
- Used in measure position of anterior teeth.



Ar-Go plane:

This plane is formed by the line connecting from Articulare to Gonion.

It is important in the determination of length of ramus.



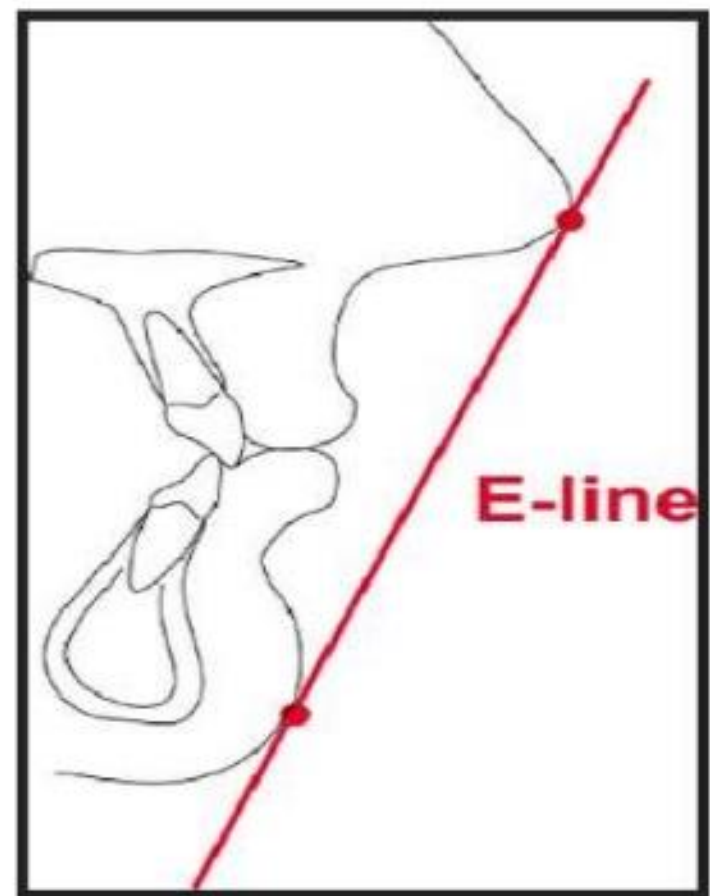
E – PLANE: (soft tissue)

It is also called as Esthetic plane.

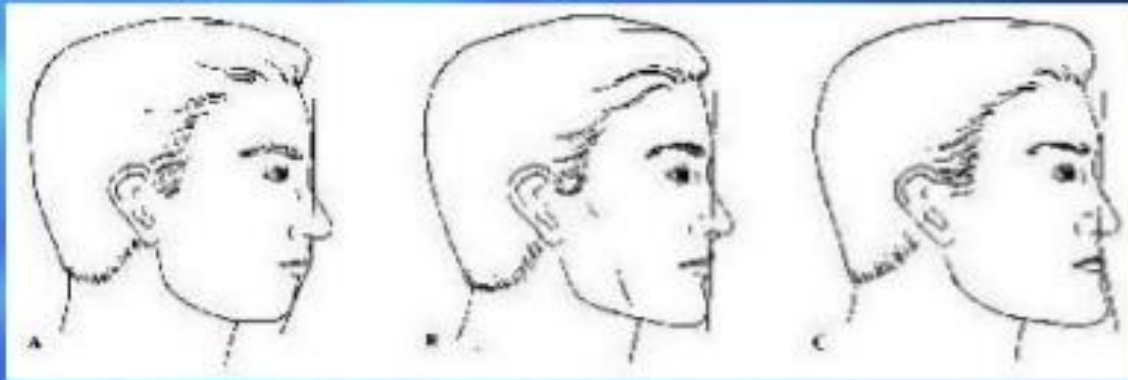
It is also known as RICKETT's esthetic line (By rickett in 1960). Which extends from the tip of the nose to the chin.

The lips should be slightly behind this line for esthetics.

This affects the lips prominency.



Soft Tissue Profile



Convex

straight

concave

retrognathic

orthognathic

prognathic

S - N Line indicates orientation of anterior cranial base

N - A indicates relative position of maxilla to the cranial base

N - B indicates relative position of mandib. to the cranial base

The angles SNA; SNB; ANB indicate relative position of maxilla or mandible to each other and to the cranial base

