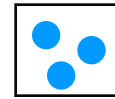
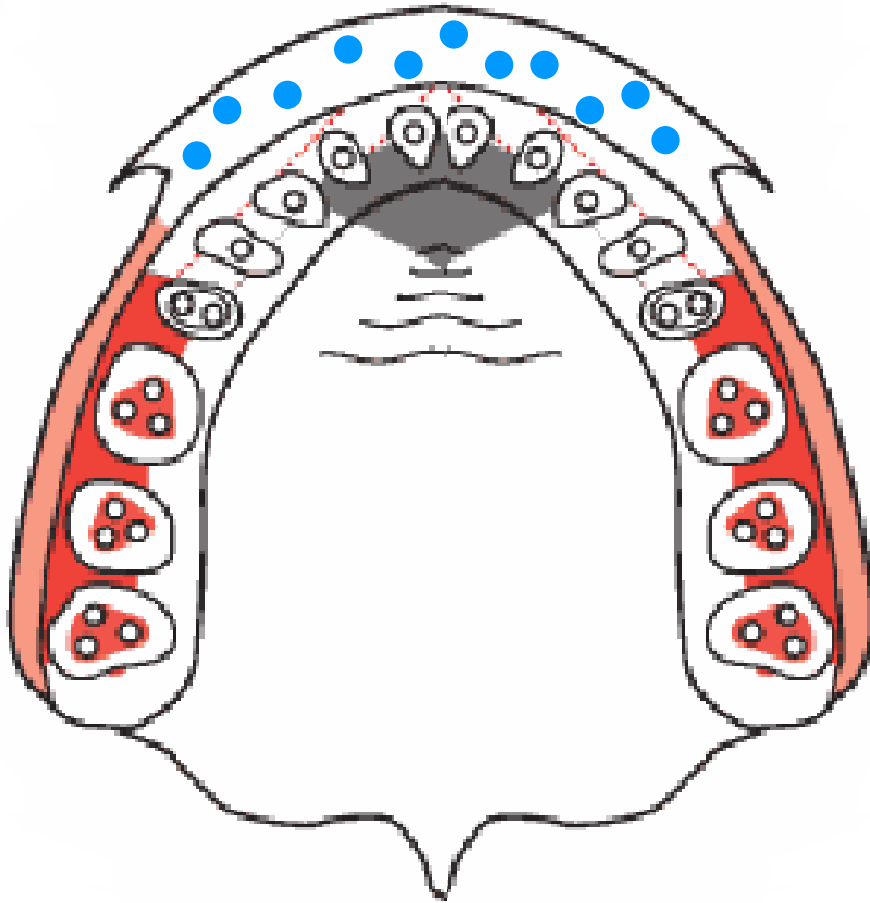

DENTAL ANESTHESIA



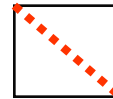
MAXILLA



Rr. labiales sup.



N. buccalis



Rr. alveolares sup. ant.
et medii



Rr. alveolares sup. post.

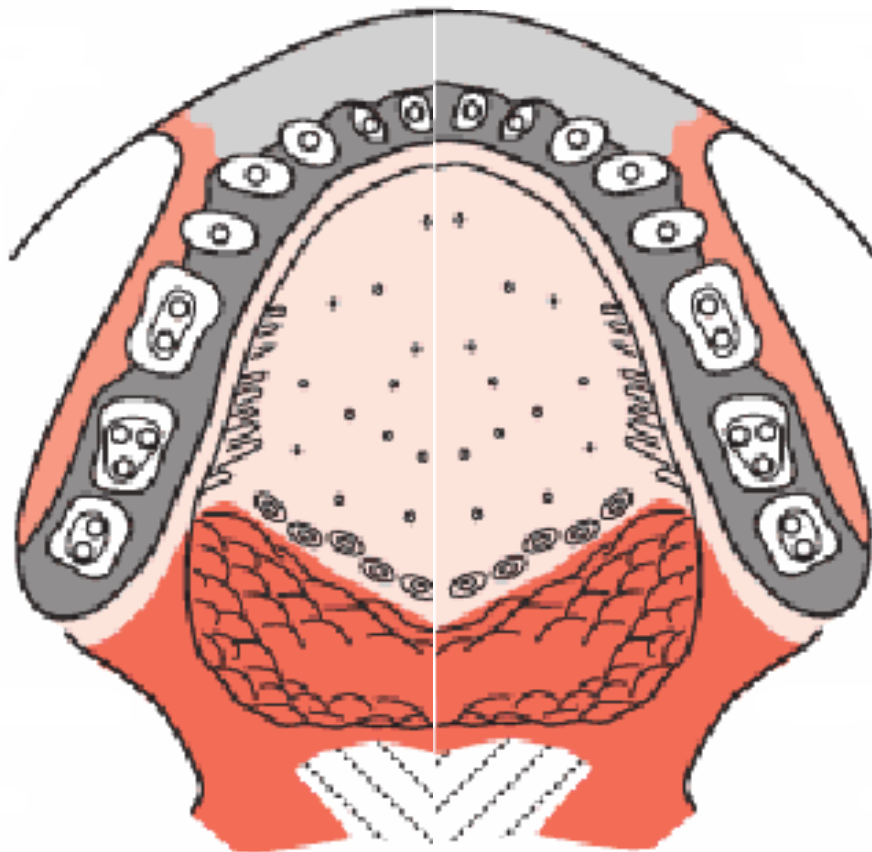


N. nasopalatinus



Nn. palatini

MANDIBLE



N. mentalis



N. buccalis




N. alveolaris inf.



N. lingualis



N. glossopharyngeus



N. vagus


- **Operative procedures** require cutting through sensitive structures, producing extreme discomfort and **pain**
- Pain is a result of stimulation of nociceptors that are receptors preferentially sensitive to a noxious stimulus (**A δ , C fiber afferent axons**)
- **Local anesthetics (LA)** cause:
reversible block sensory nerve conduction of noxious stimuli from periphery to the CNS

The effectiveness of local anesthetics is improved by the addition of a **vasoconstrictor**:

- increase - **duration** of action
 - **depth** of anesthesia
- decrease - **systemic toxic reactions**
 - **local bleeding**

- To minimize anesthetic failure, the dentist must have a good **knowledge of the anatomy** of the head region, particularly the neuroanatomy of the maxillary and mandibular regions of the face !
- **Onset of action of anesthesia!!!**

General Potential Complications

- 1. Nerve injury**
 - 2. Injuries to blood vessels**
 - 3. Intraglandular injections**
 - 4. Trauma to muscles**
 - 5. Systematic reactions**
- 

1. Nerve Injury

- 1) **Paresthesia** (loss of sensation)
 - commonly involve the tongue and lower lip
- 2) **Hyperesthesia** (increased sensitivity to painful stimuli)
- 3) **Dysesthesia** (pain following nonnoxious stimuli)
- 4) **Dysgeusia** (impaired sense of taste)

5) **Xerostomia** (reduced salivation)

- the chorda tympani is traumatized

6) **Ocular and extraocular symptoms**

The passive process of diffusion of anesthetic through the orbit leads to ocular and extraocular symptoms:

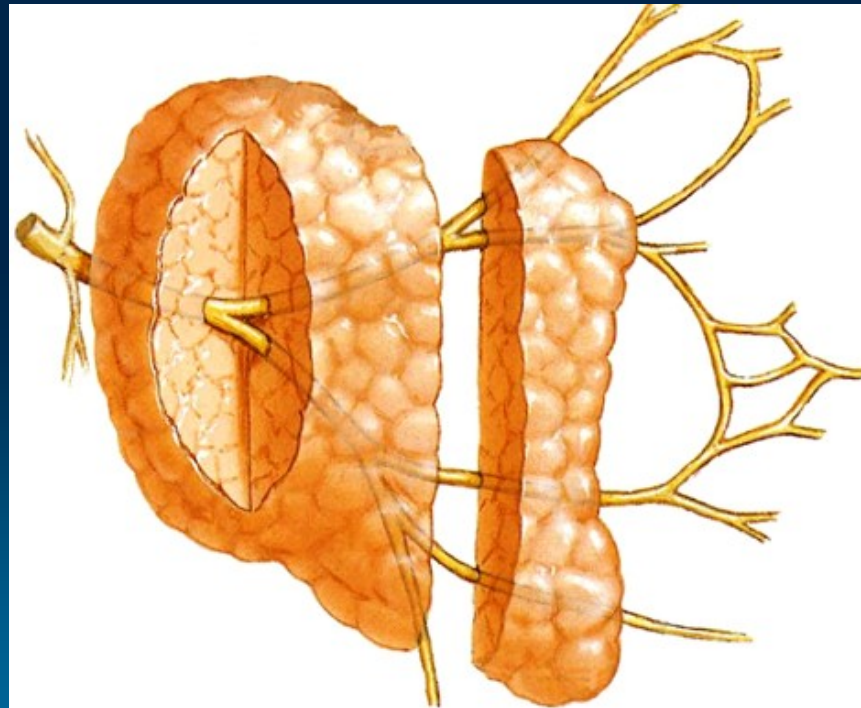
- **paralysis extraocular muscle**
- **diplopia**
- **amaurosis** (temporary blindness)
- **Horner's syndrome** (enophthalmos, miosis, palpebral ptosis)

2. Bleeding

- Intravascular injection → vascular damage → hemorrhage with hematoma formation
- If the vein is engaged, the bleeding is minimal and is usually evidenced a few days later
- Artery damage with significant hematoma formation and extensive intra or extraoral swelling
- Potential anesthetizing sympathetic nerve may result vasoconstriction

3. Intraglandular injection

Transient paralysis of the ipsilateral facial muscles - caused by anesthesia of the facial nerve in parotid gland



4. Trauma of muscle

Muscle trismus = spasm of jaw muscles, which restricts mouth opening (temporal and medial pterygoid muscle)

5. Systematic complication

Failure of the **cardiorespiratory system**
Anaphylaxis



Type of local anesthesia

I. Local Infiltration

Small nerve endings in the small area of soft tissue or bone are flooded with small amount of local anesthetic solution

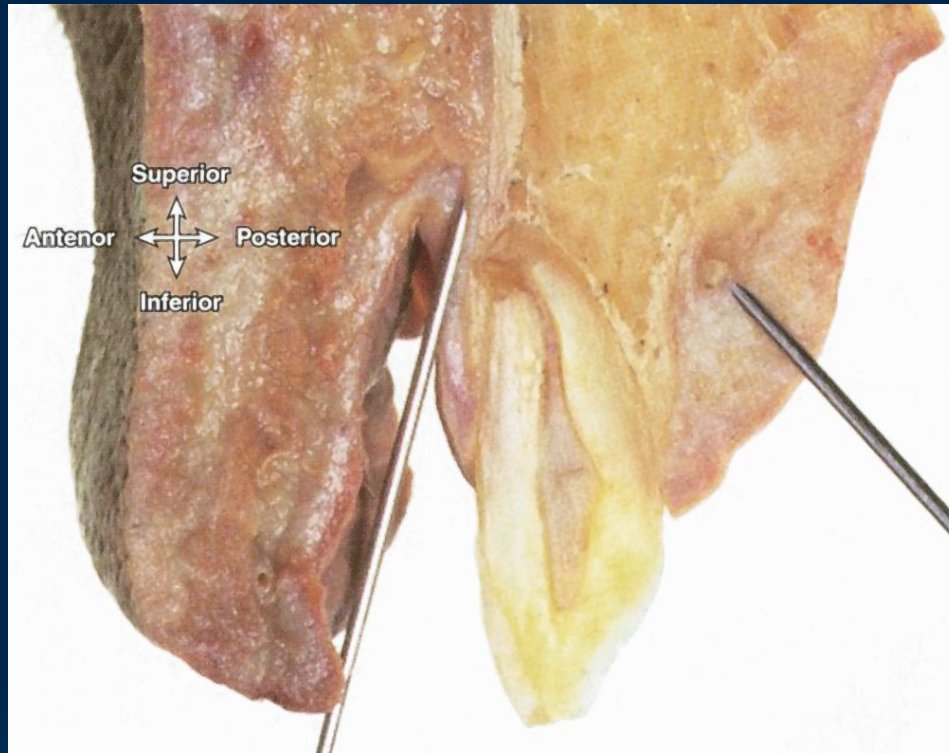
II. Nerve Block

The local anesthetic solution is deposed within close proximity to a main peripheral nerve

III. Field blocks

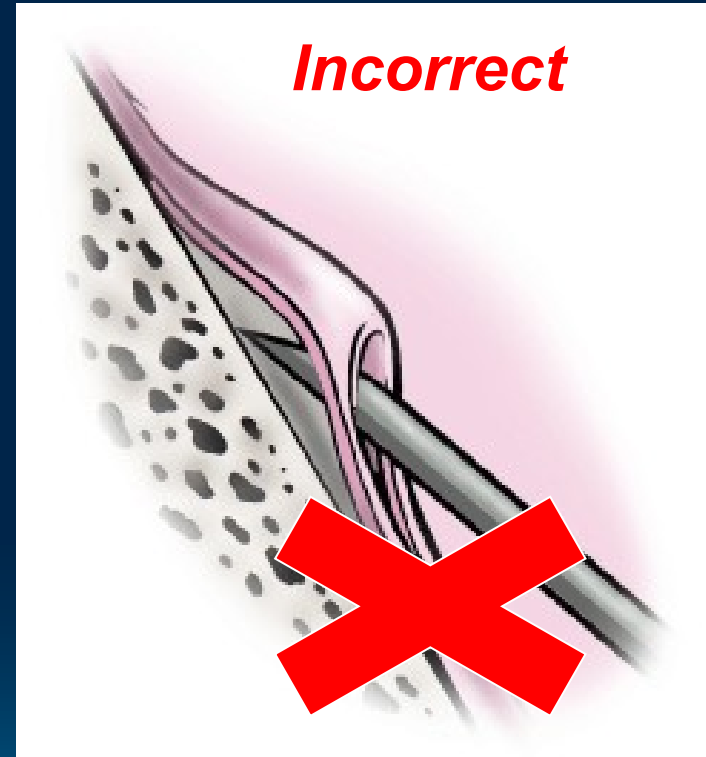
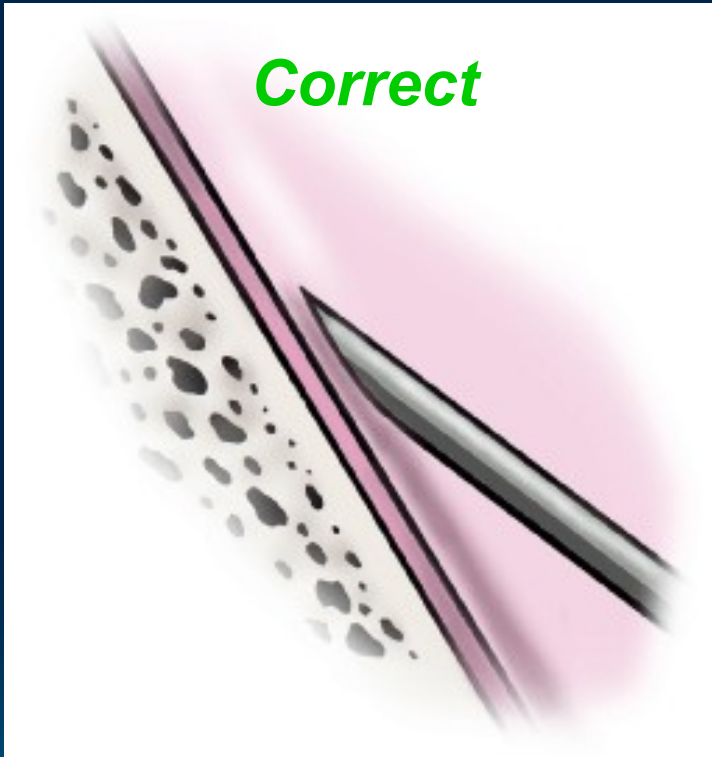
Local anesthetic is deposited near a larger nerve trunks

I. Local Infiltration



The needle pervade at a height of insertion of mucobuccal fold to the apex and ...

the anesthetic agent is deposited supraperiostally !

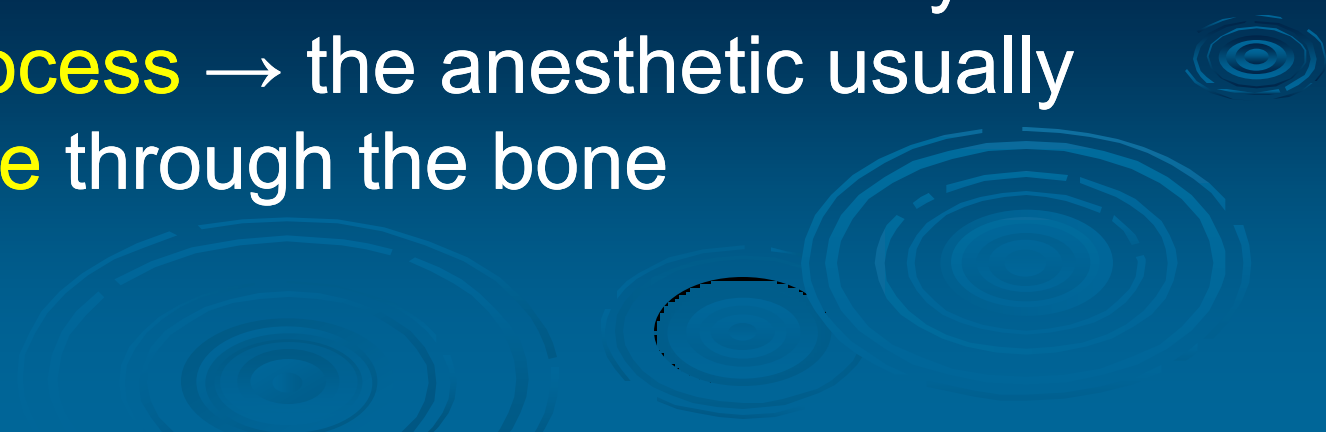


There is **different composition** of the **cortical plate** of maxillary and mandibular alveolar process

Maxilla

Local infiltration is successful in all parts of maxilla – both buccal and lingual

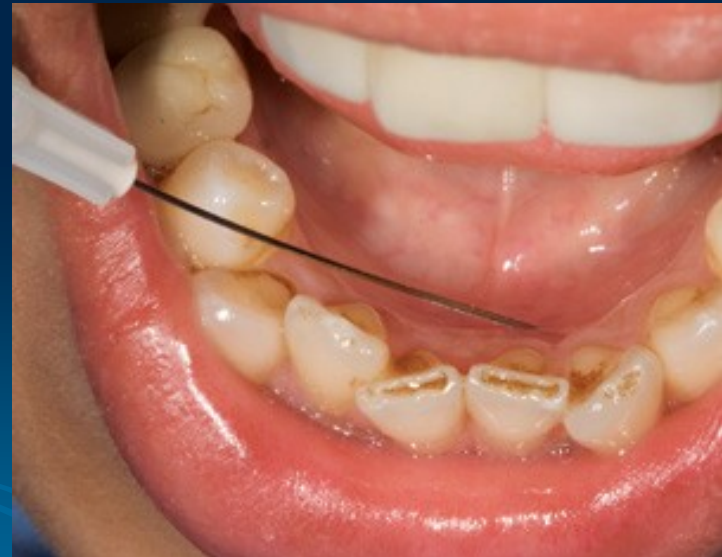
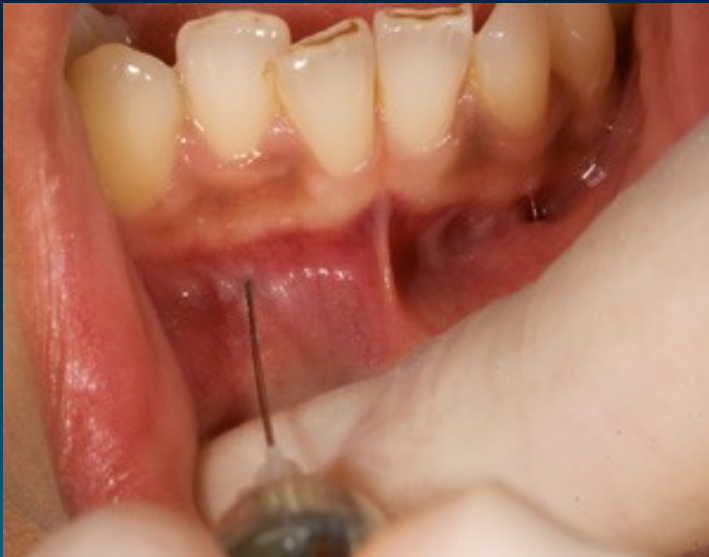The problem may be only on buccal plate at the 1st molar, which his roots are covered by the **zygomatic process** → the anesthetic usually **doesn't diffuse** through the bone



Mandible

The **cortical plate** of the mandible is sufficiently **dense** to preclude effective infiltration anesthesia

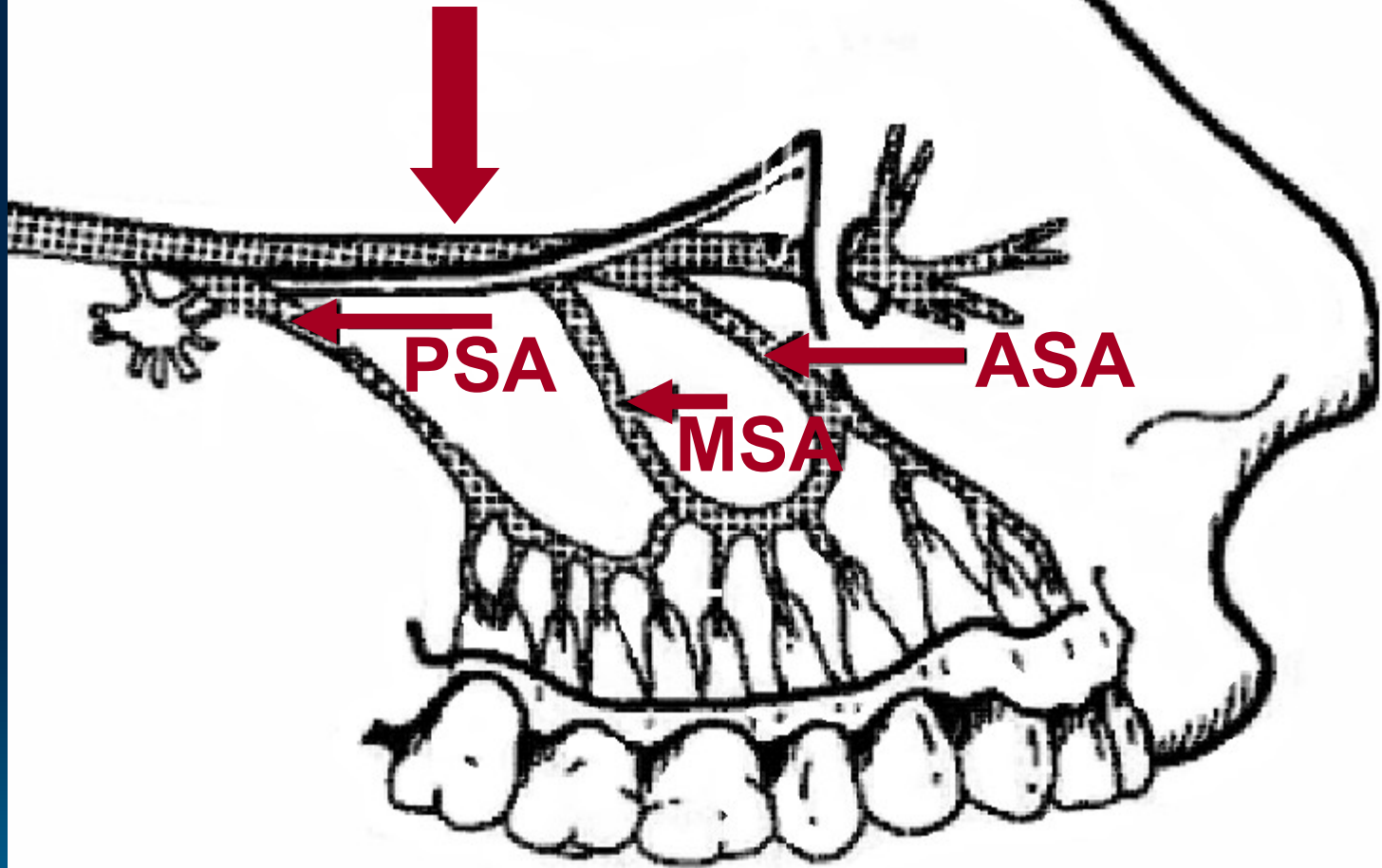
Thus, local infiltration is **ineffective**, **except mandibular incisors** (buccal and lingual)



II. Nerve Block

1. Posterior superior alveolar - **PSA**
2. Middle superior alveolar - **MSA**
3. Anterior superior alveolar - **ASA**
4. Infraorbital
5. Greater palatine
6. Nasopalatine
7. Alveolar inferior (*Halstead, Gow-Gates, Akinosi*)
8. Mental
9. Lingual
10. Buccal

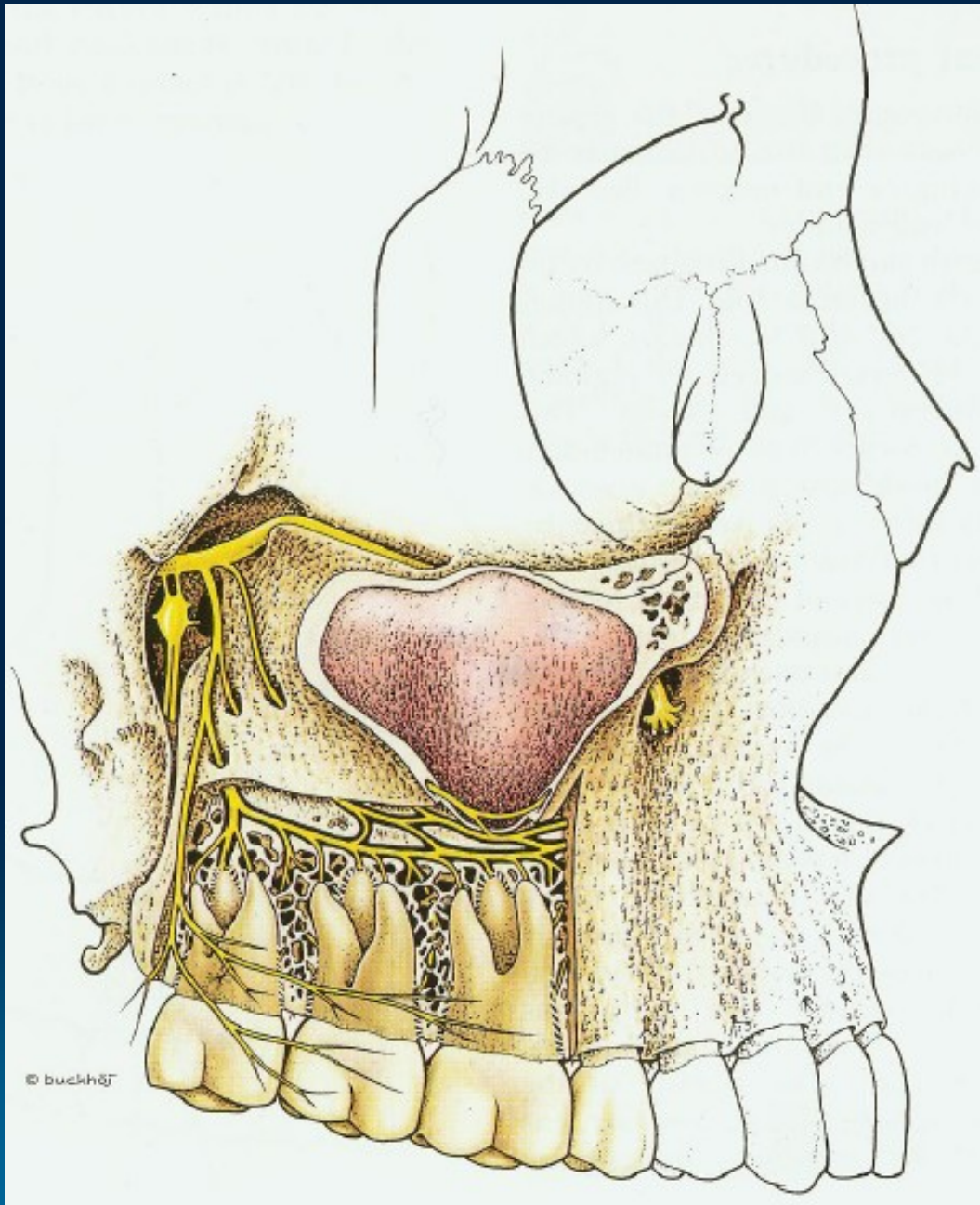
Infraorbital nerve

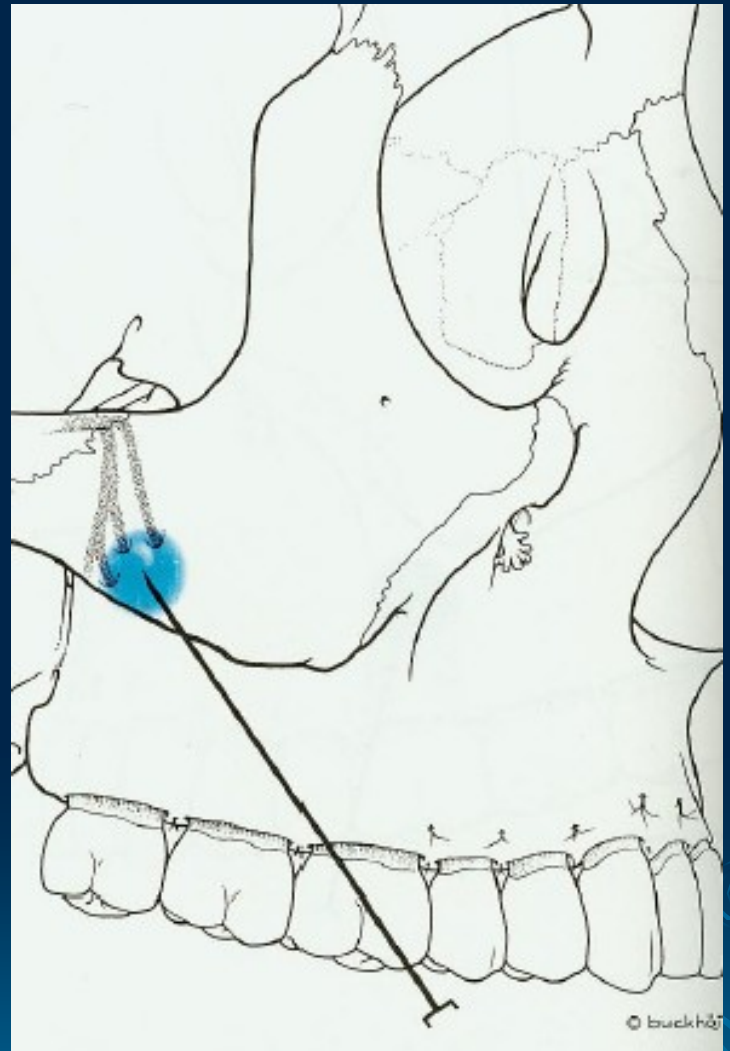
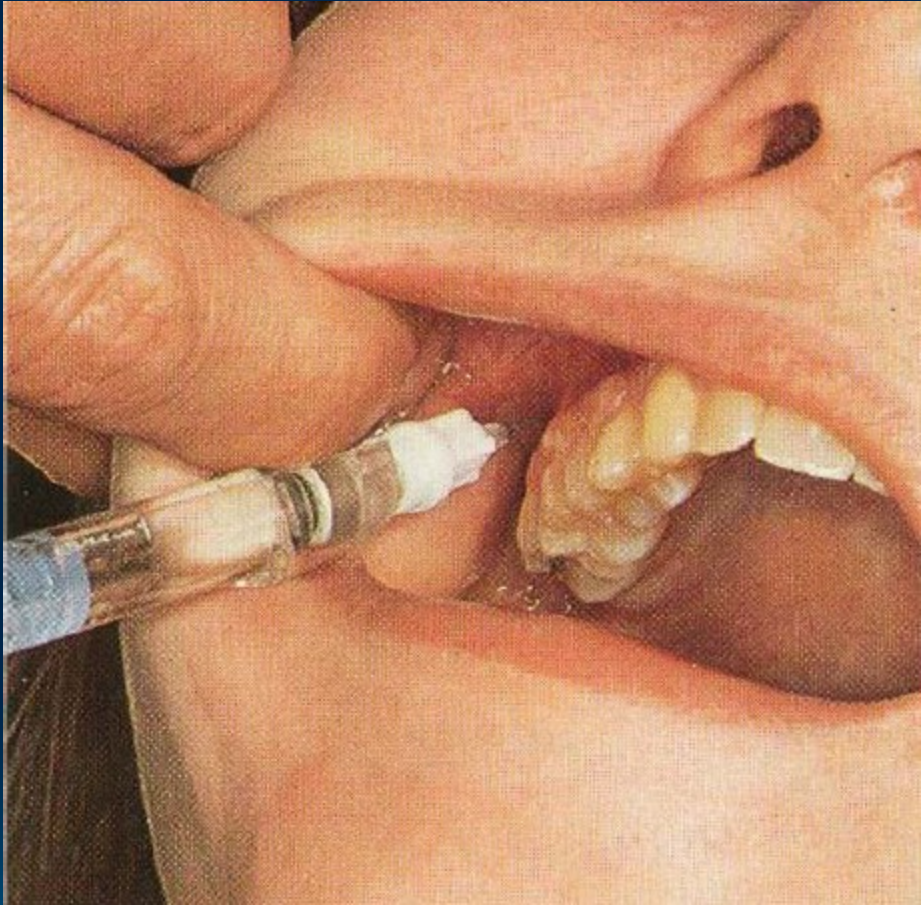


1. PSA Block

- Anesthetize the **pulps and periodontal ligaments** of the **maxillary molars**, corresponding **buccal alveolar bone and gingival tissue** and posterior portion of the **maxillary sinus**.
Mesiobuccal root 6 can be innervated by middle superior alveolar nerve !

Technique - between 1st and 2nd molar at a height of insertion of mucobuccal fold, angle at 45° superiorly and medially



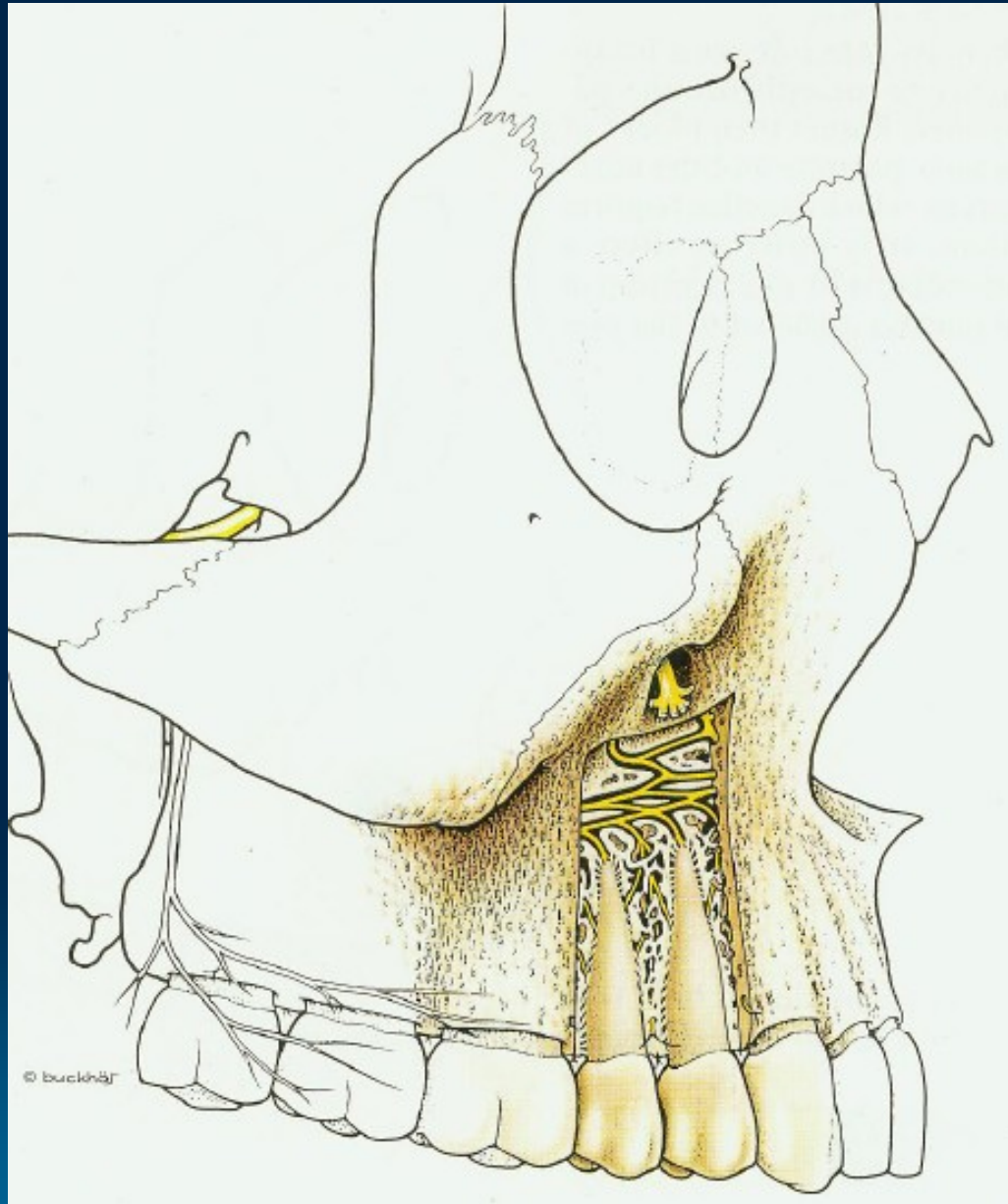


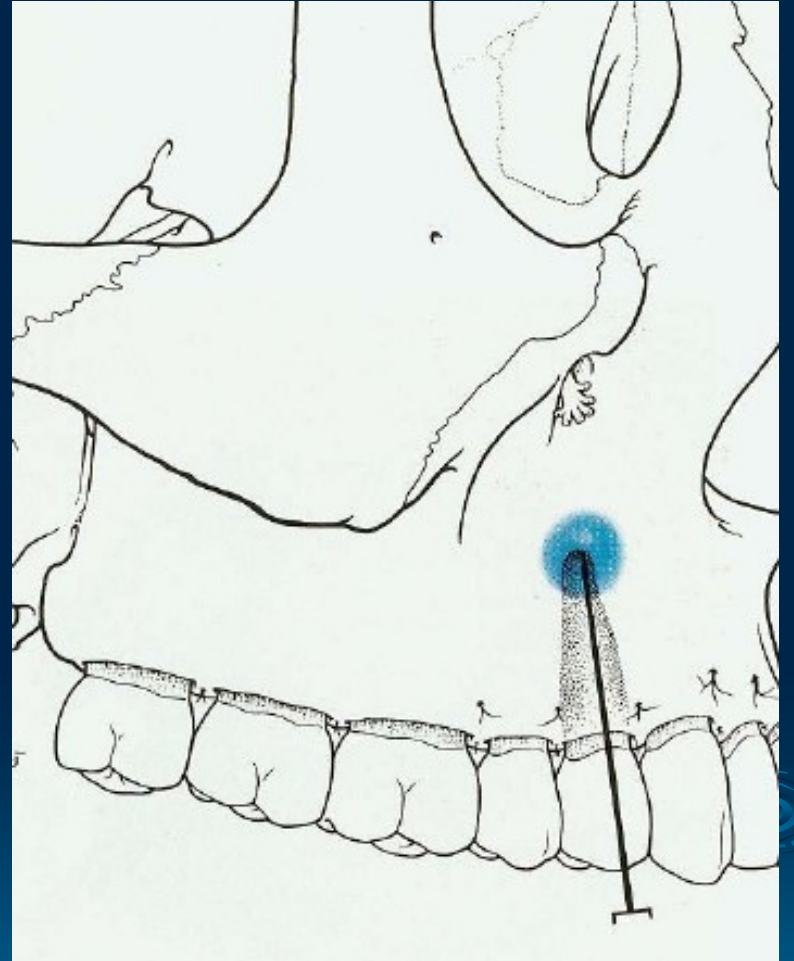
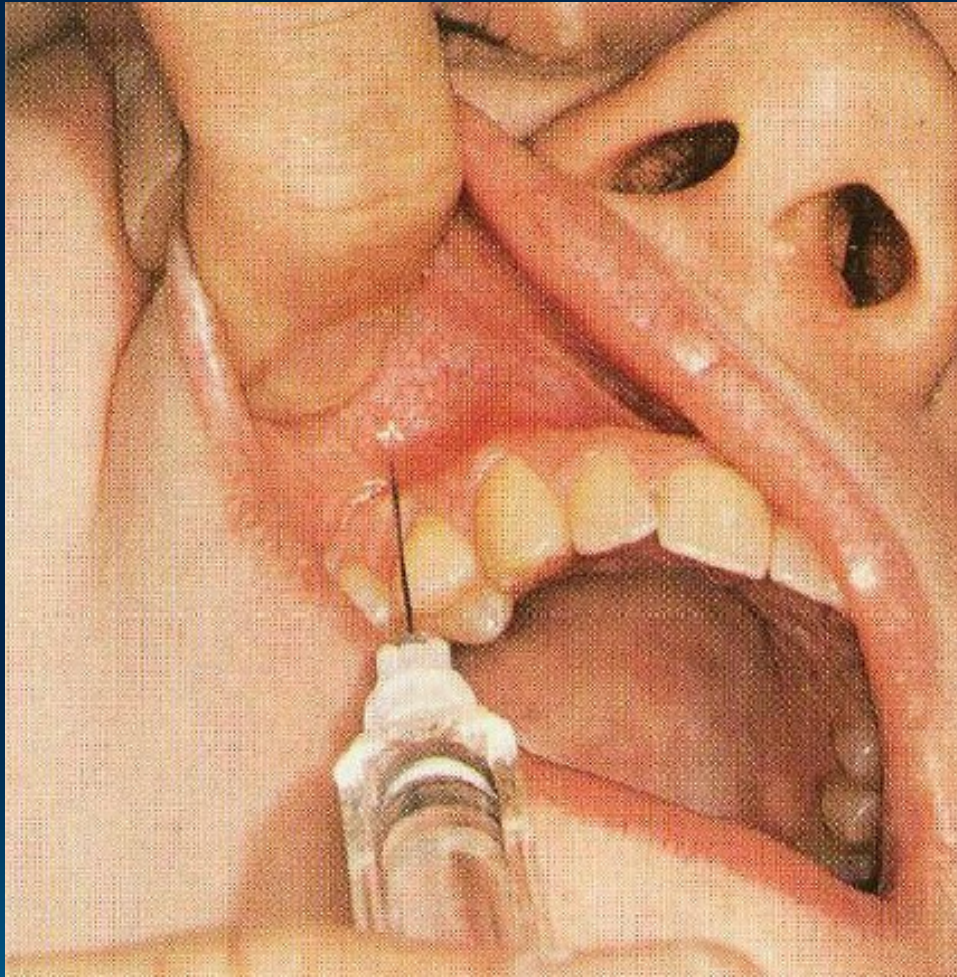
2. MSA Block

- Anesthetize the **maxillary premolars**, corresponding **buccal alveolar bone and gingival tissue**
- Used if the infraorbital block fails to anesthetize premolars

Technique - between 1st and 2nd premolar at a height of insertion of mucobuccal fold

In the Czech republic MSA is a rarely used technique, more often are used local infiltration



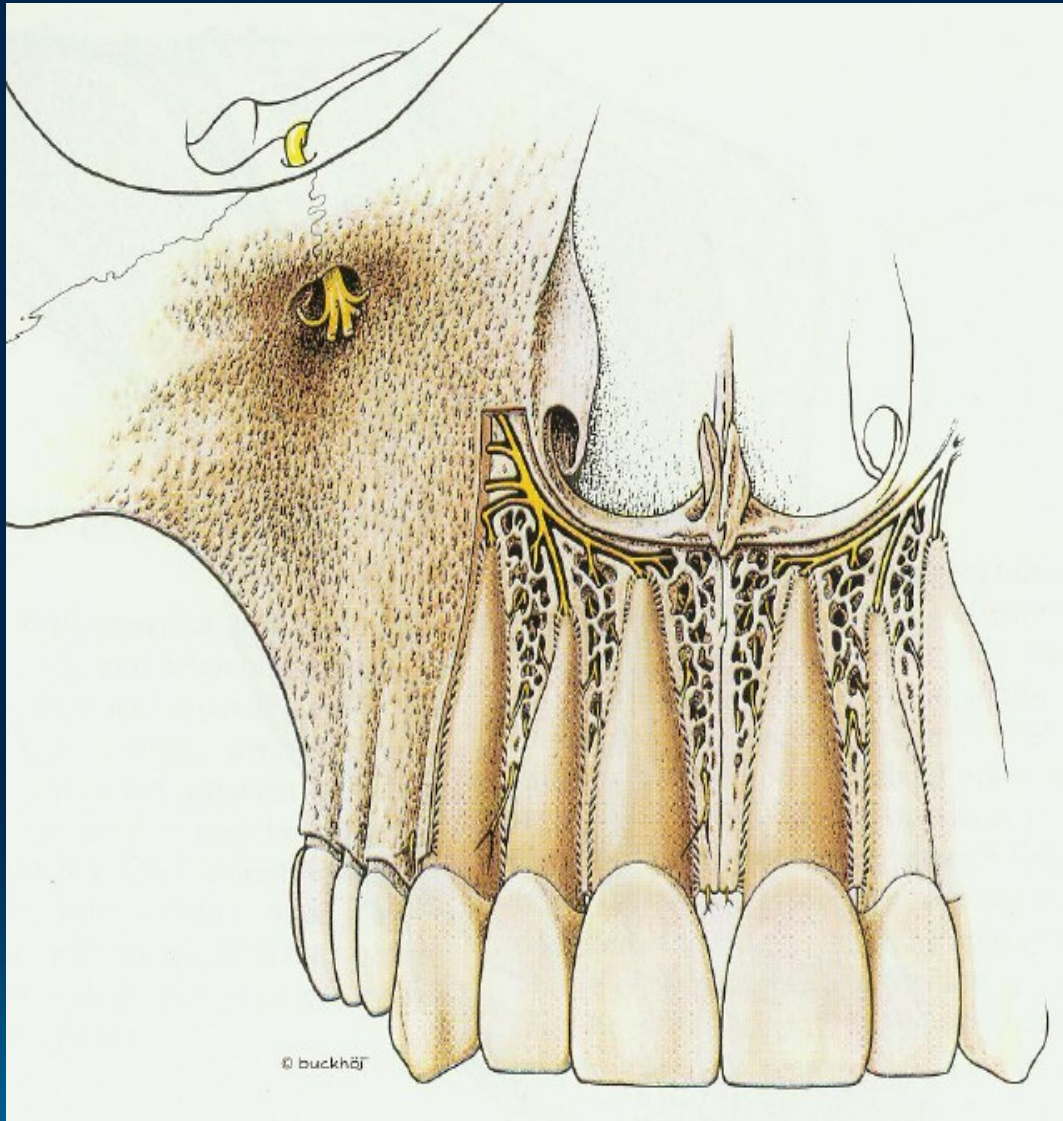


3. ASA Block

- Anesthetize the **canine, incisors**, corresponding buccal **alveolar bone and gingival tissue**

Technique - the area of lateral incisor at a height of insertion of mucobuccal fold

In the Czech republic MSA is a rarely used technique, more often are used local infiltration

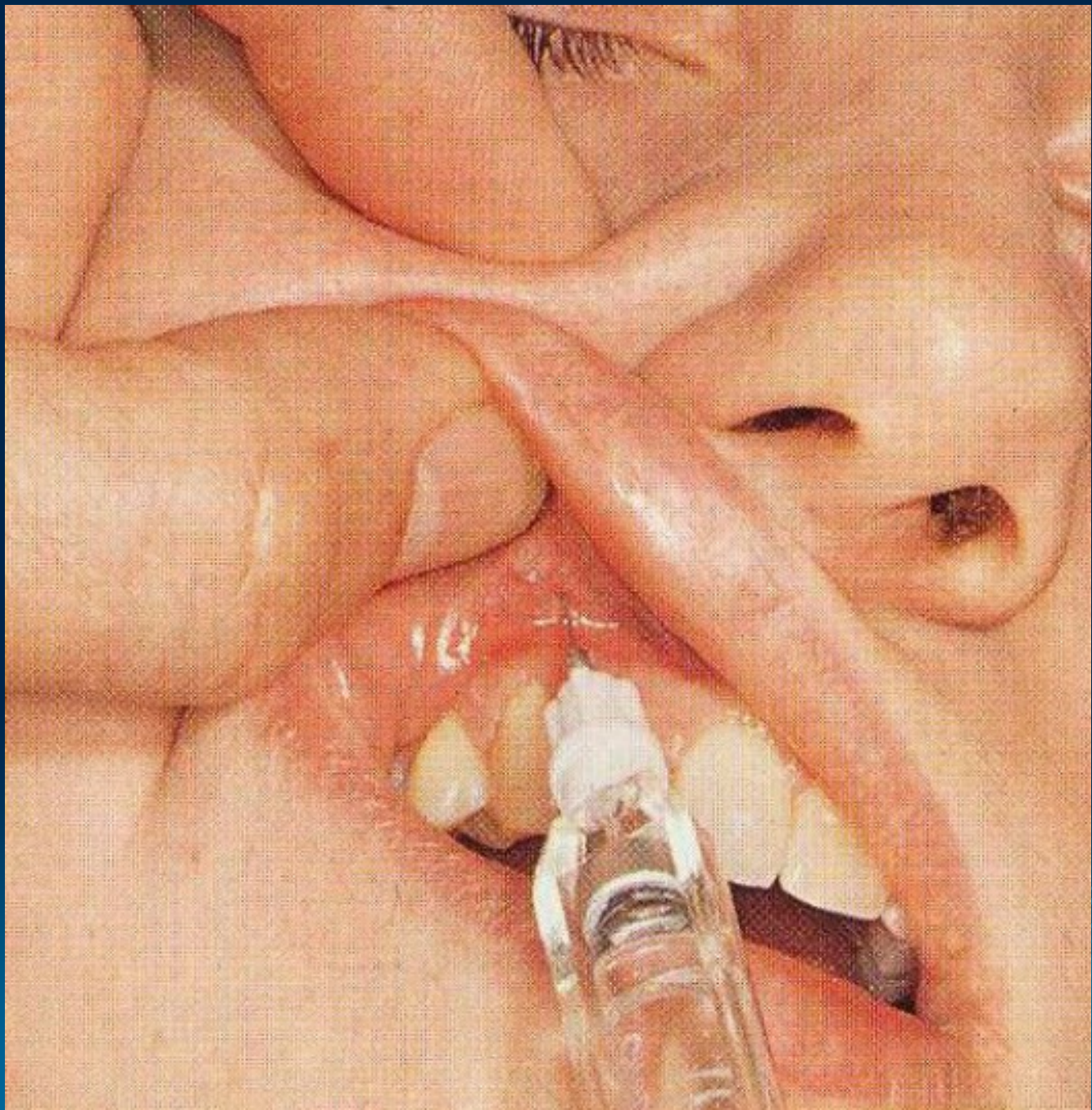


4. Infraorbital Nerve Block

- Combine ASA and MSA block
- Anesthetize the **maxillary premolars, canine, incisors**, corresponding buccal **alveolar bone** and **gingiva**, also the terminal branches of infraorbital nerve (**lower eyelid, external nose tissue, upper lip**, the anterior aspect of the **maxillary sinus**)

Technique - palpate infraorbital foramen

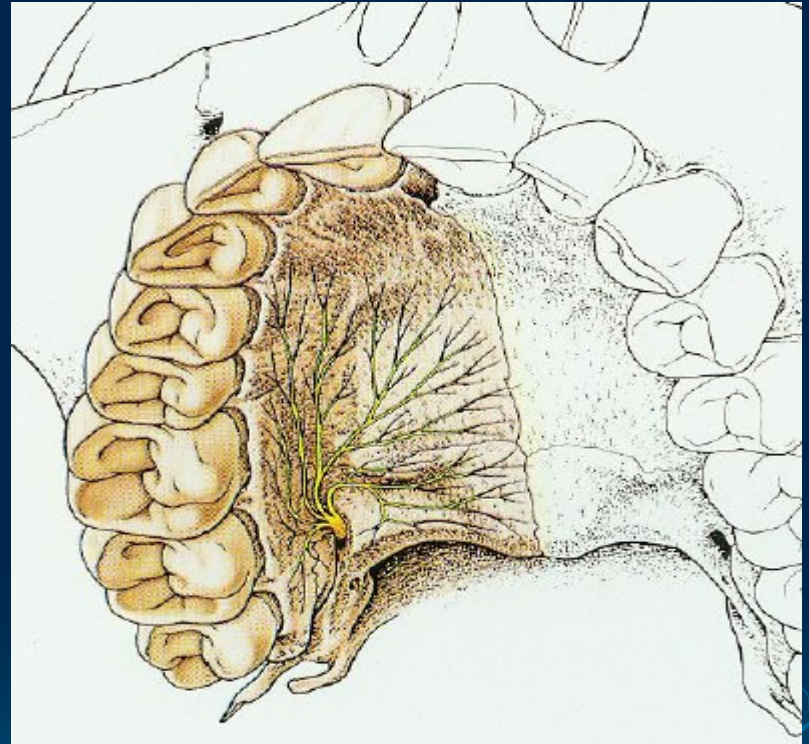
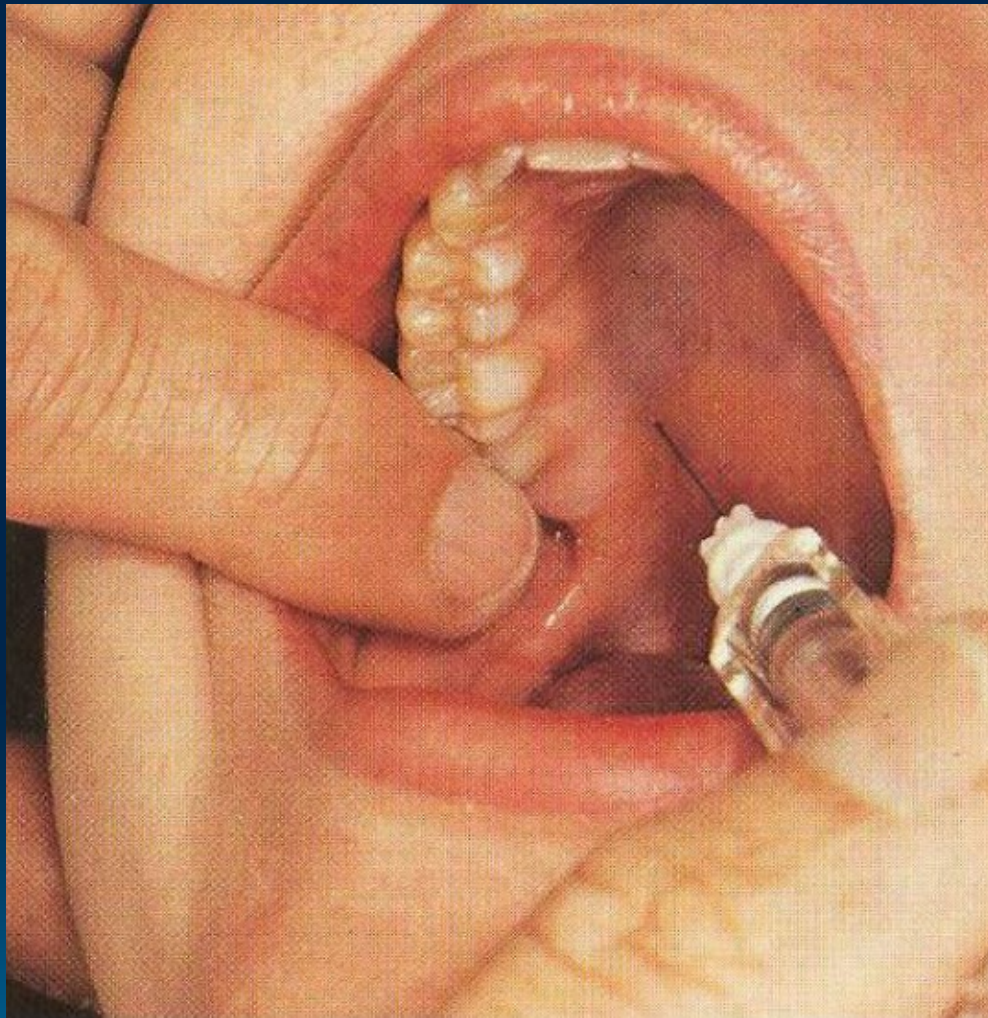
- retract the upper lip → inject to area of 3/4
- contact bone in infraorbital region
- inject 0,9 -1,2ml



5. Greater Palatine Nerve Block

- Anesthetize **all palatal mucosa** of the side injected and **lingual gingivae posterior** to the maxillary **canines** and corresponding **bone**

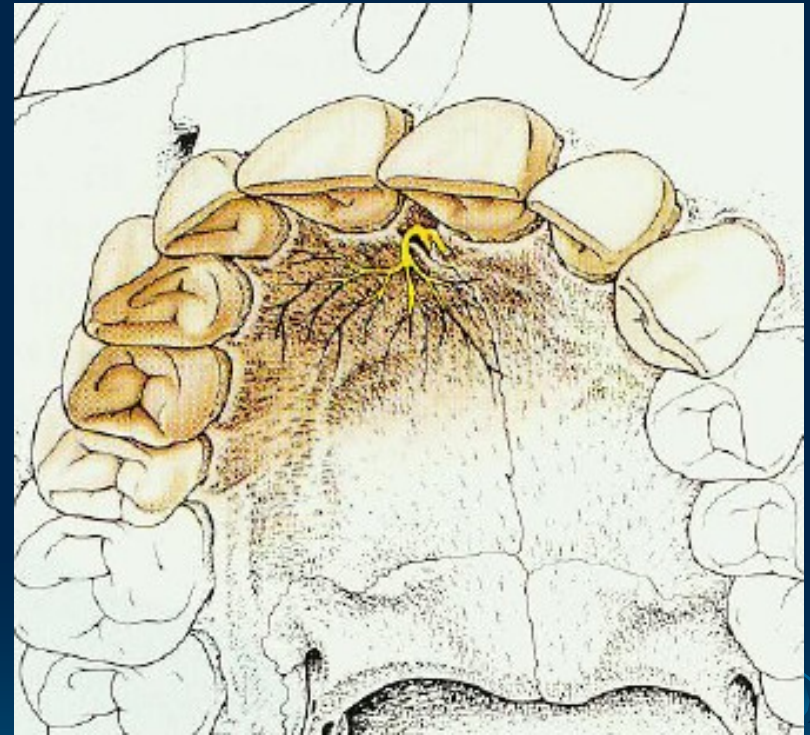
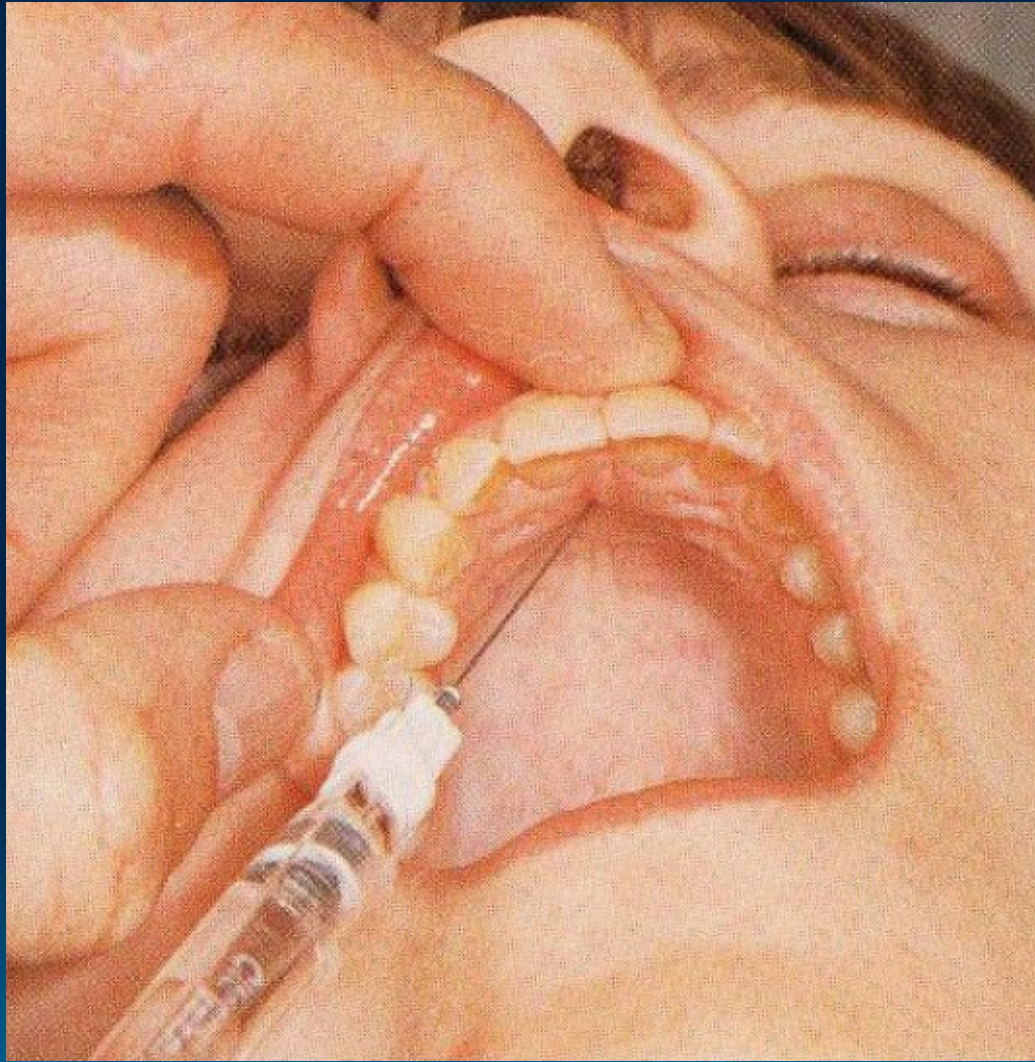
Technique - on the hard palate between the 2nd and 3rd molars approximately 1cm medially, inject cca 0,3 - 0,5ml



6. Nasopalatine Nerve Block

- Anesthetize the **soft and hard tissue** of the maxillary anterior six teeth - **from canine one side to canine other side**

Technique - approximately 1,5 cm posterior to the alveolar crest between the central incisors - posterior to the incisive papilla; depth less than 10mm and inject 0,3 - 0,5 ml

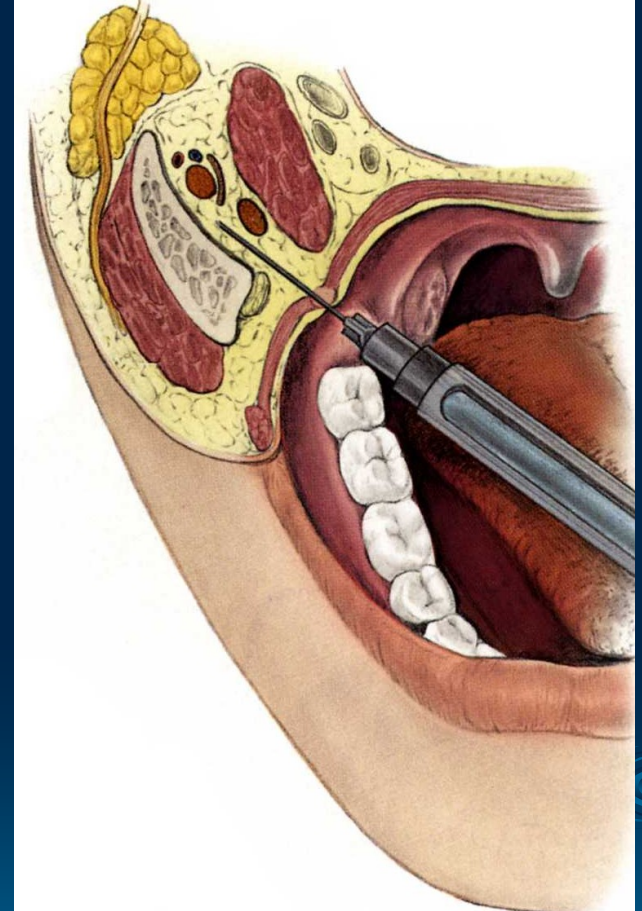
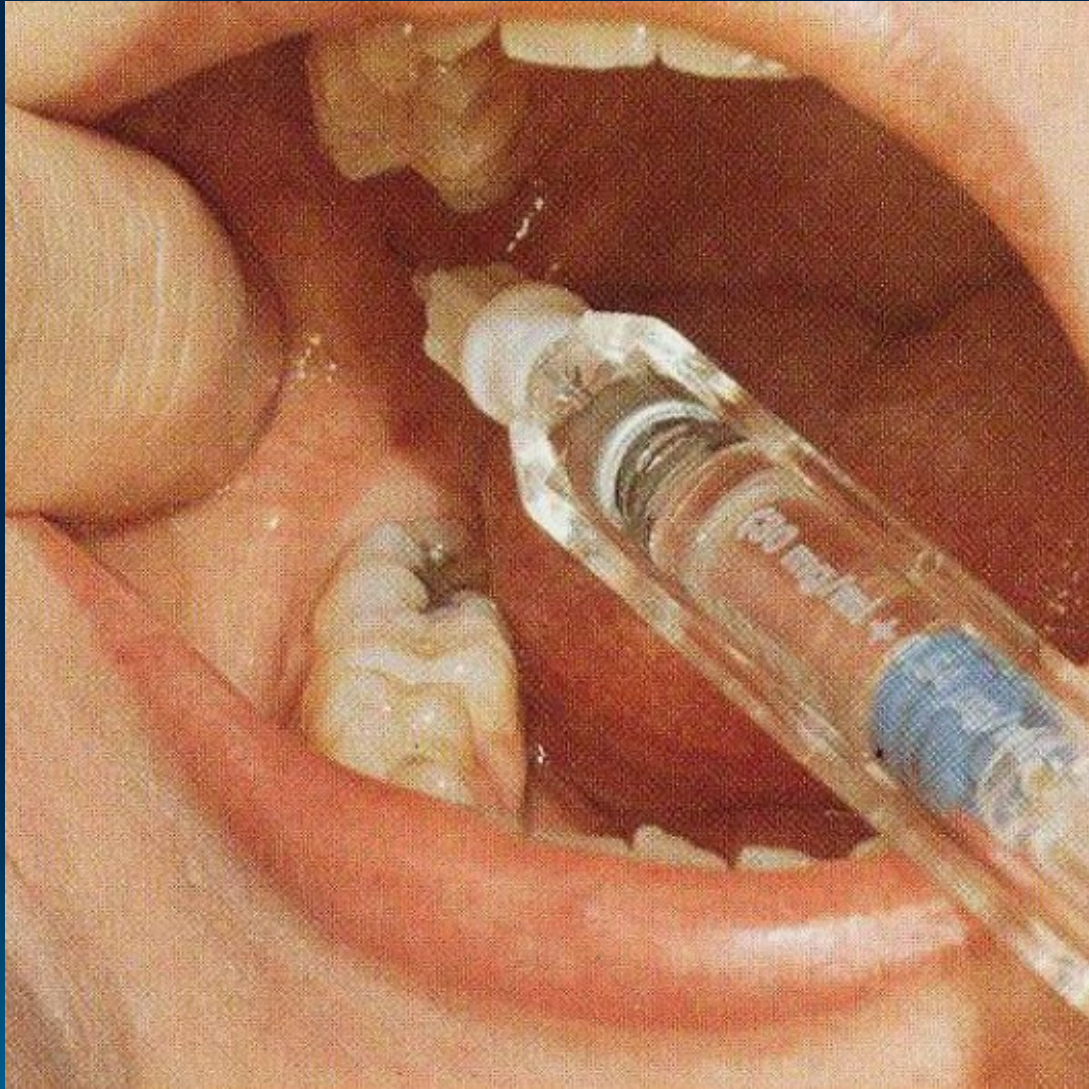


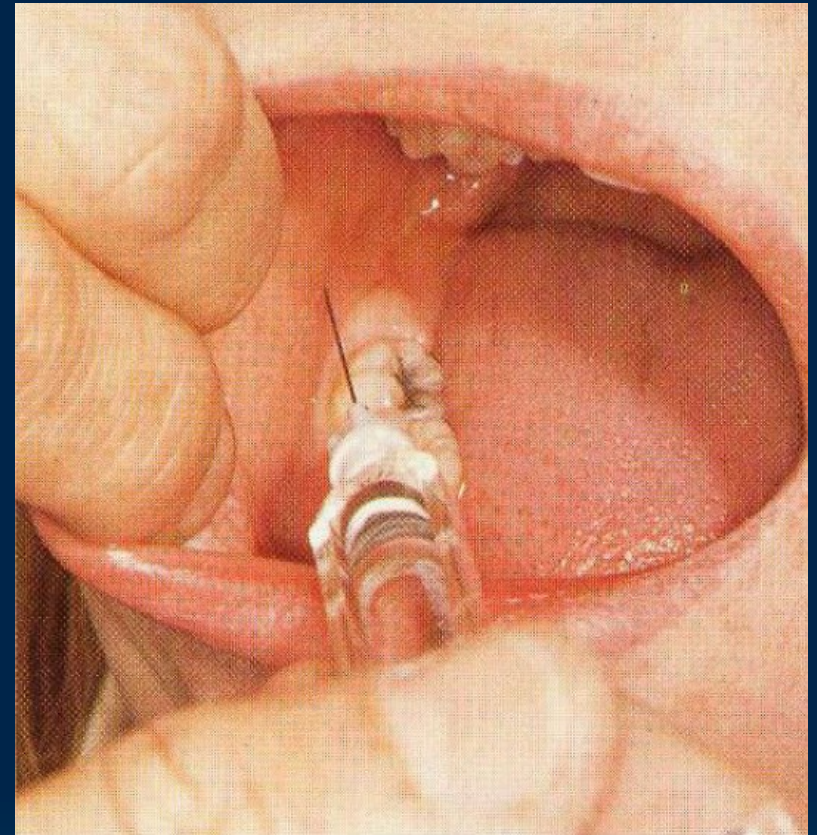
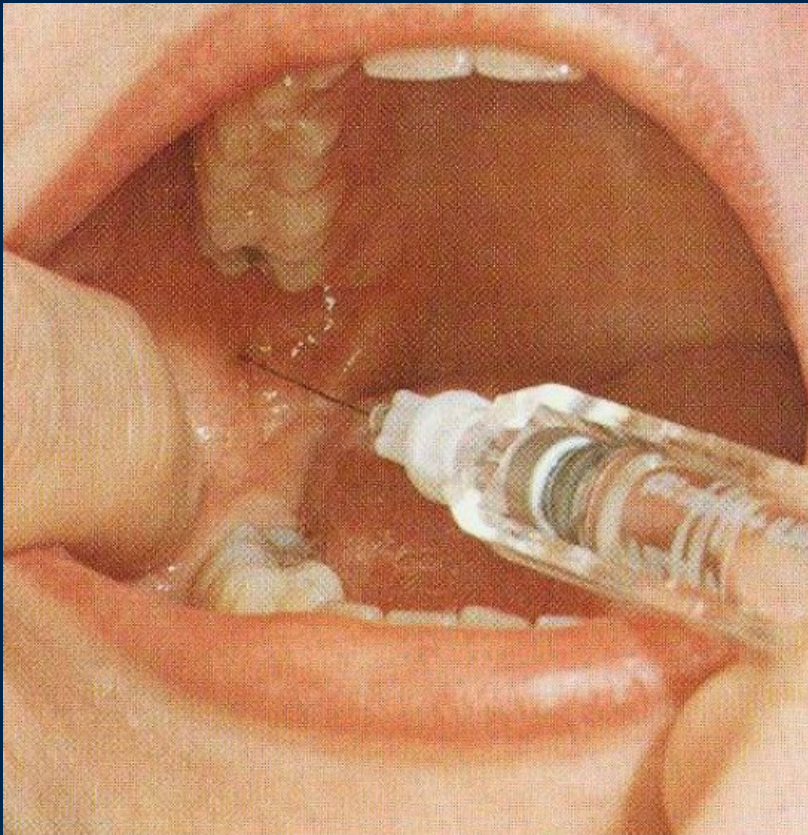
7. Inferior Alveolar Nerve Block

- Individual variations in the locations of the mandibular foramen
- Be aware of the proximal extremity of the maxillary artery. **Aspiration !**
 - a) Halstead method
 - b) Gow-Gates method
 - c) Akinosi method

a) Halstead Open-Mouth method

- The finger in the **retromolar fossa** with the fingernail pointing backward
- A line is sighted from **occlusal surfaces of the premolars of the opposite side** to the midpoint of the fingernail
- Inject 0,5 - 1ml solution
- Continue to inject 0,5ml on removal from injection site to anesthetize the **lingual branch**



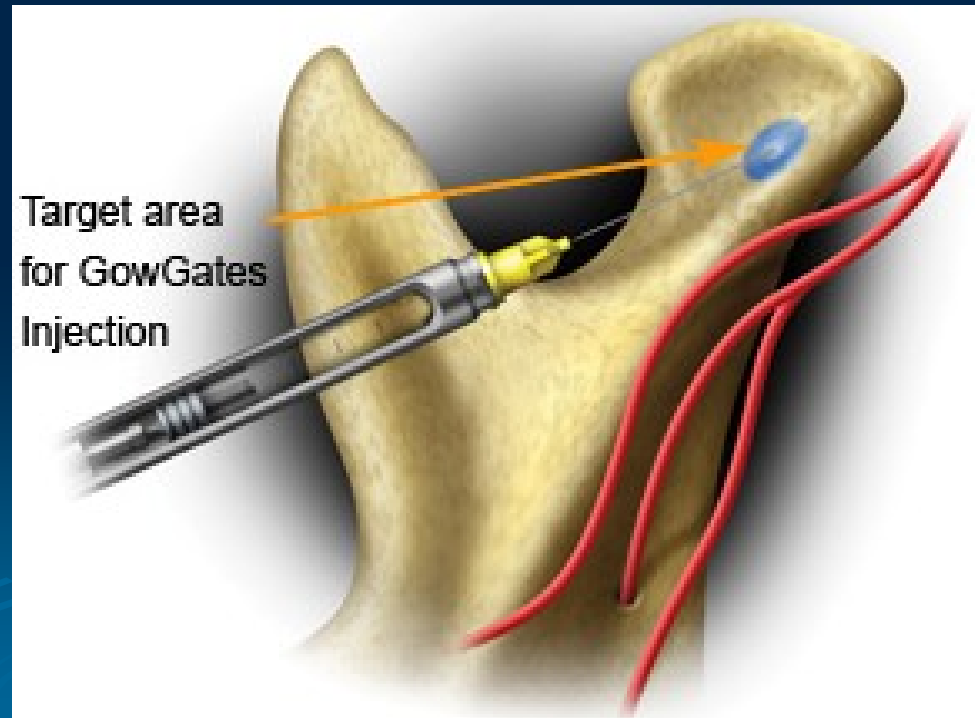


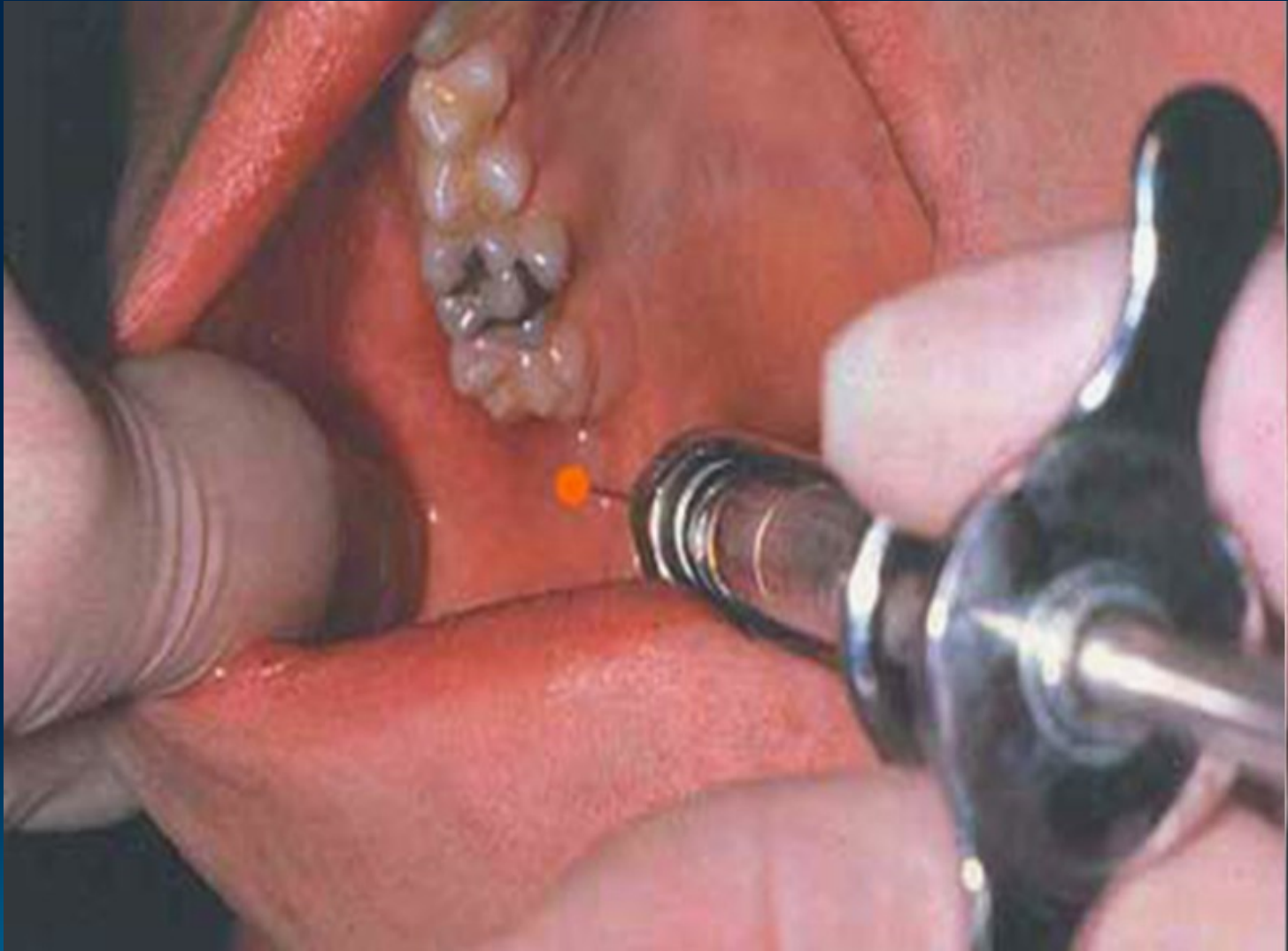- Inject remaining anesthetic into coronoid notch region in the mucous membrane distal and buccal to most distal molar to perform a **long buccal nerve block**

b) Gow-Gates method

- **Field block** anesthesia
- The injection site is higher than Halstead
- **Below** the insertion of the **lateral pterygoid muscle** at the **anterior side** of the **condyle** at maximal opening in relatively avascular area
- The injection line is parallel with the external line from the **intertragal notch** to the **angle of the mouth**

- The diffusion of the anesthetic solution reach all three oral **sensory portion of mandibular branch V.n.** and other sensory nerves in this region
- High success rate, fewer complication x slower rate of onset



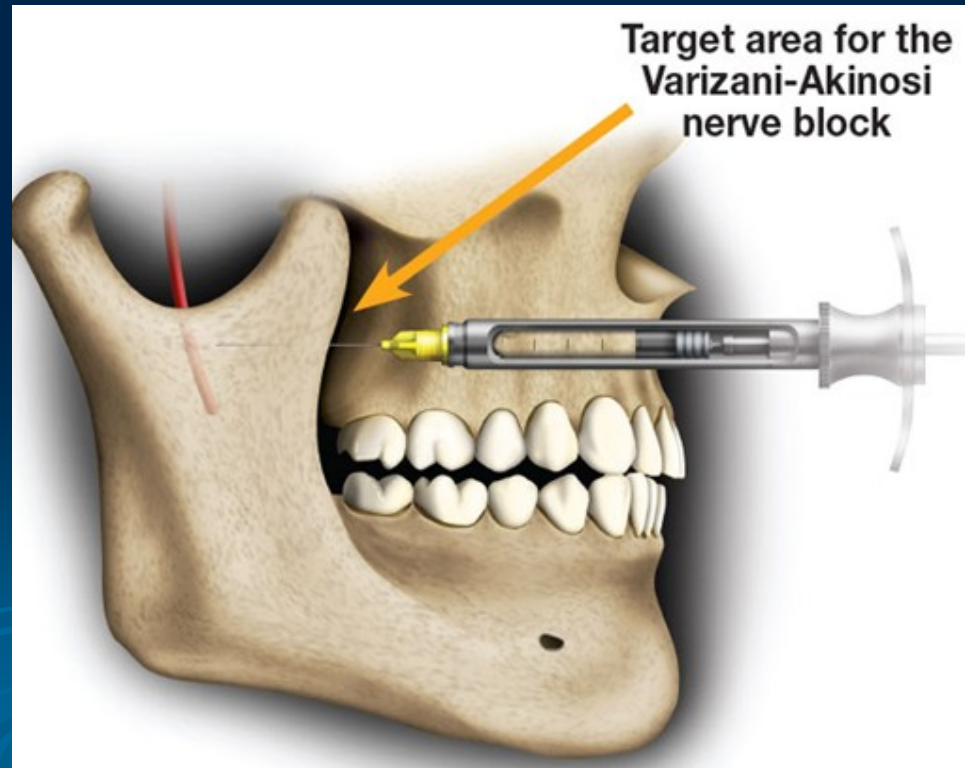


c) Vazirani-Akinosi closed mouth method

- **Field block** anesthesia
- For patient with limited opening due **trismus**, **ankylosis**, **fracture**

The **gingival margin above** the maxillary **2nd** and **3rd molars** and the **pterygomandibular raphae** serve as landmarks for this technique

- The needle is advanced through the mucous membrane and buccinator muscle to enter the **pterygomandibular space**
- Penetrate to a depth 25mm
- Remaining anesthetic in **long buccal nerve** area



8. Mental Nerve Block

- Terminal branch of the inferior alveolar nerve, exits the mandible via the mental foramen
- The position of this foramen is most frequently **near the apex of the mandibular 2nd premolar**
- The foramen open **upward and slightly posteriorly!**

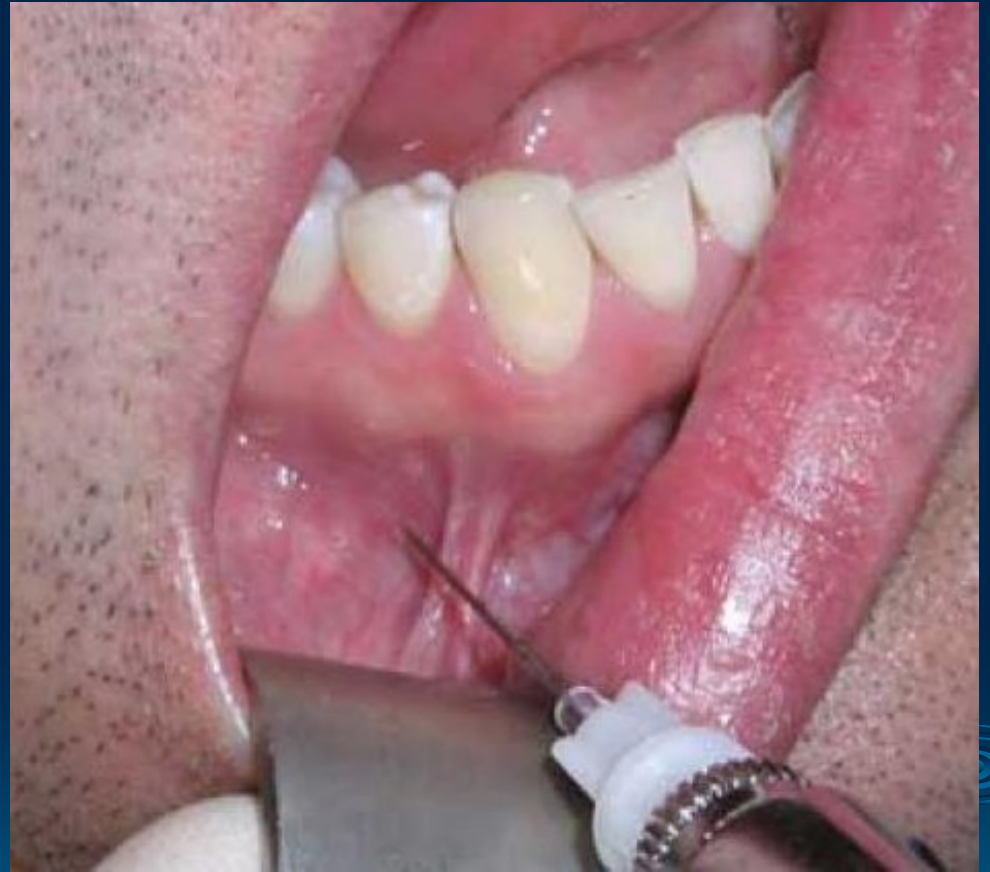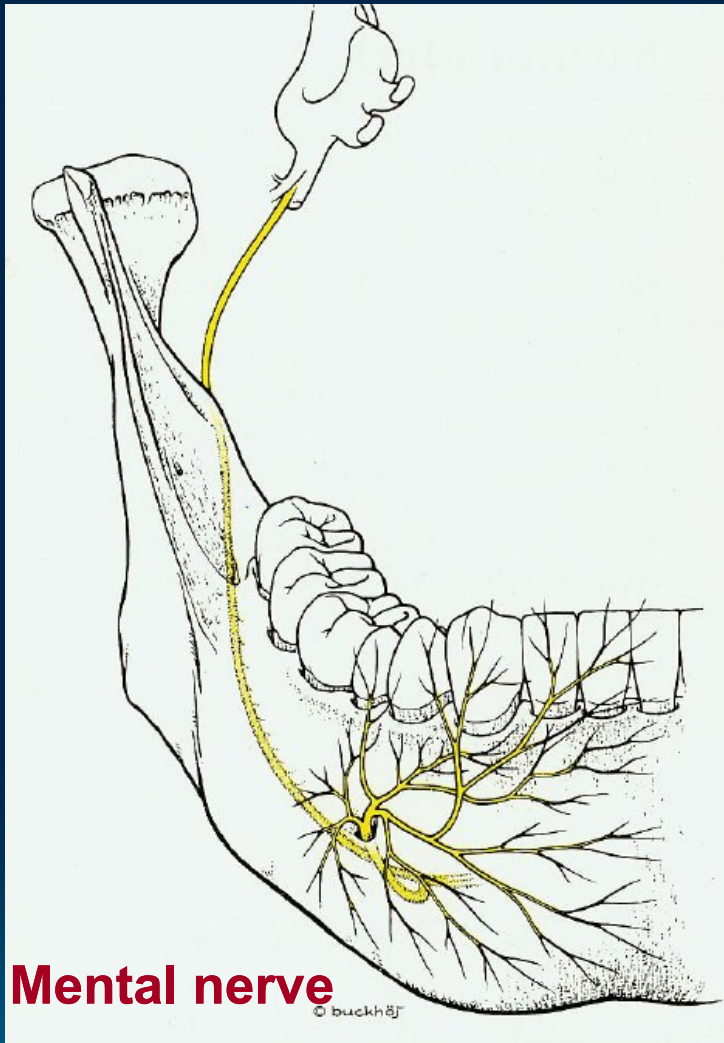
- Anesthetized **lower lip, chin**, labial gingiva, alveolar mucosa, pulpal/periodontal tissue for the **canine, incisors** and **premolars** on side blocked

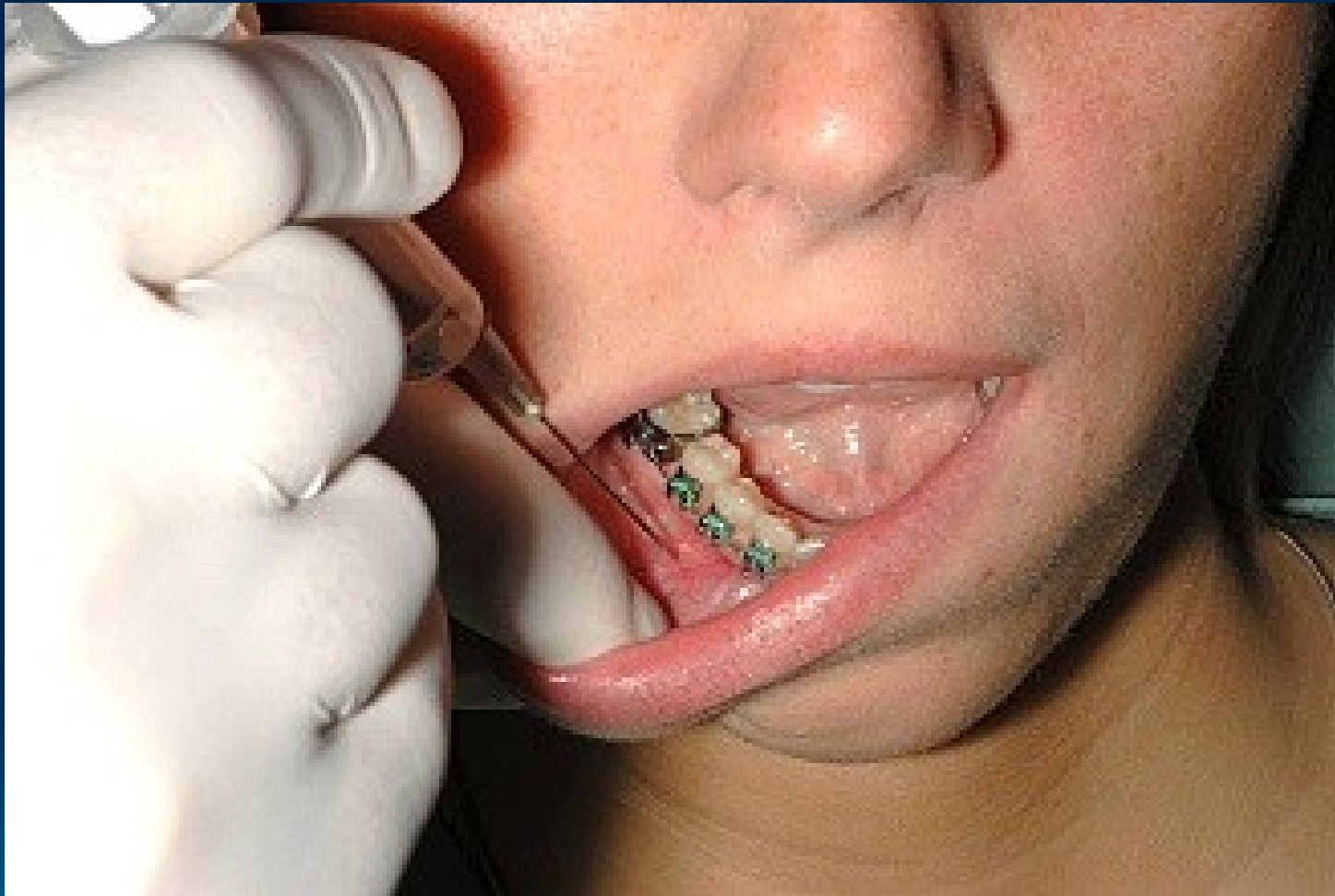Technique

The tip of needle be **directed** or **anterior** to approximate the position of the foramen, but **not enter the foramen !**

Penetrate to a depth 5 mm, inject 0,5 - 1,0 ml

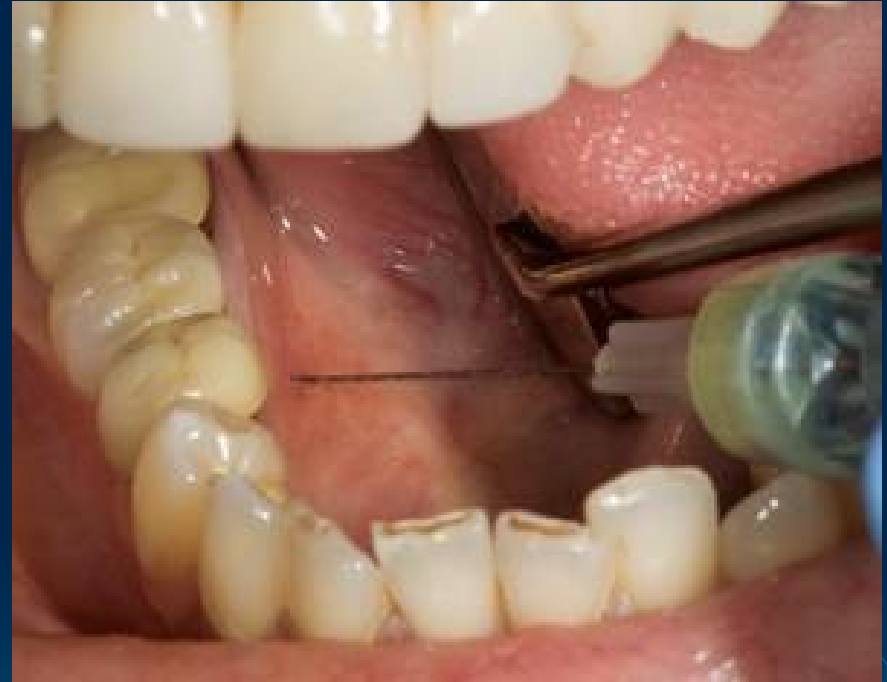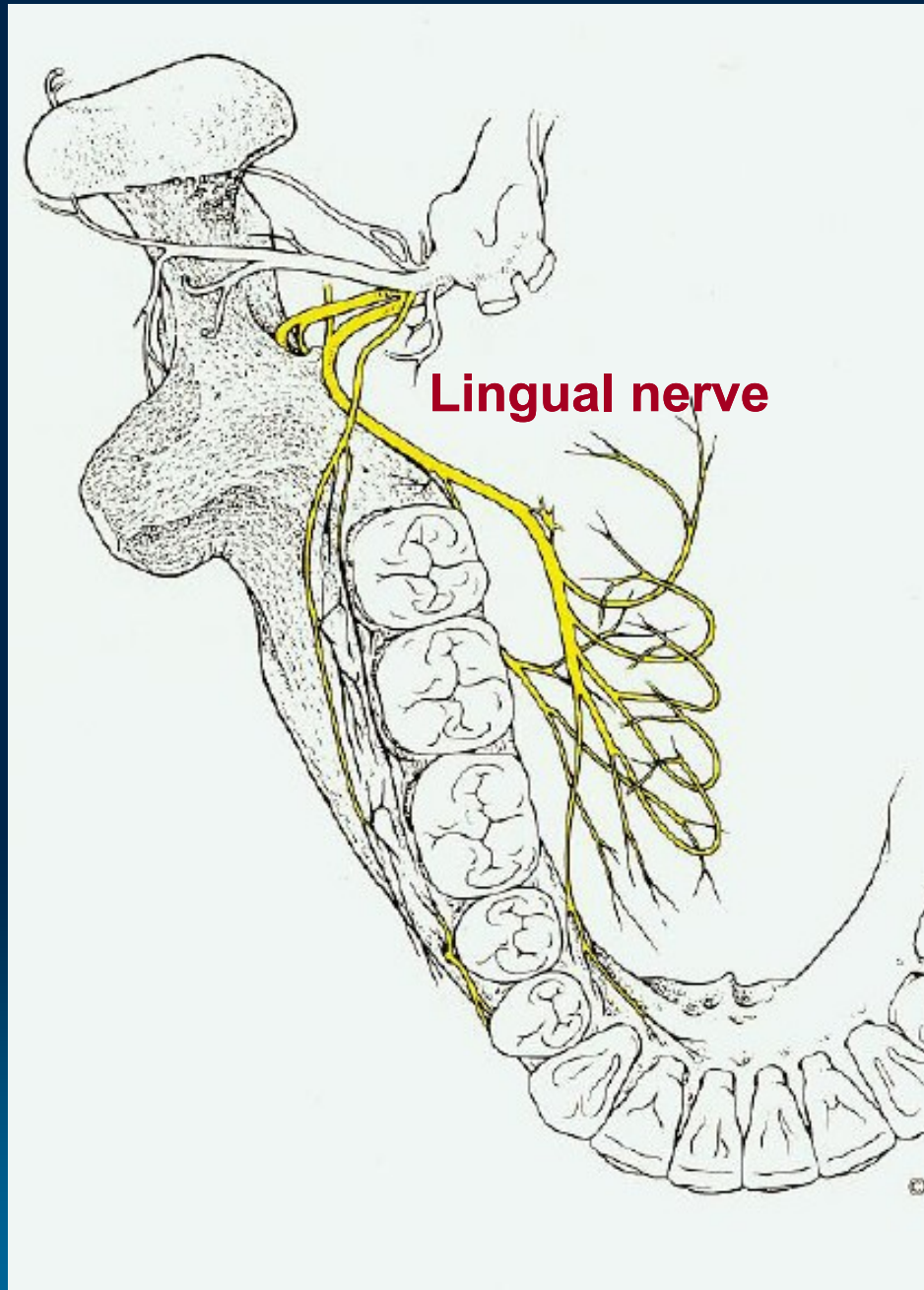
To provide **incisive nerve anesthesia** via the application of **finger pressure over the foramen** after local anesthetic solution is deposited there





9. Lingual Nerve Block

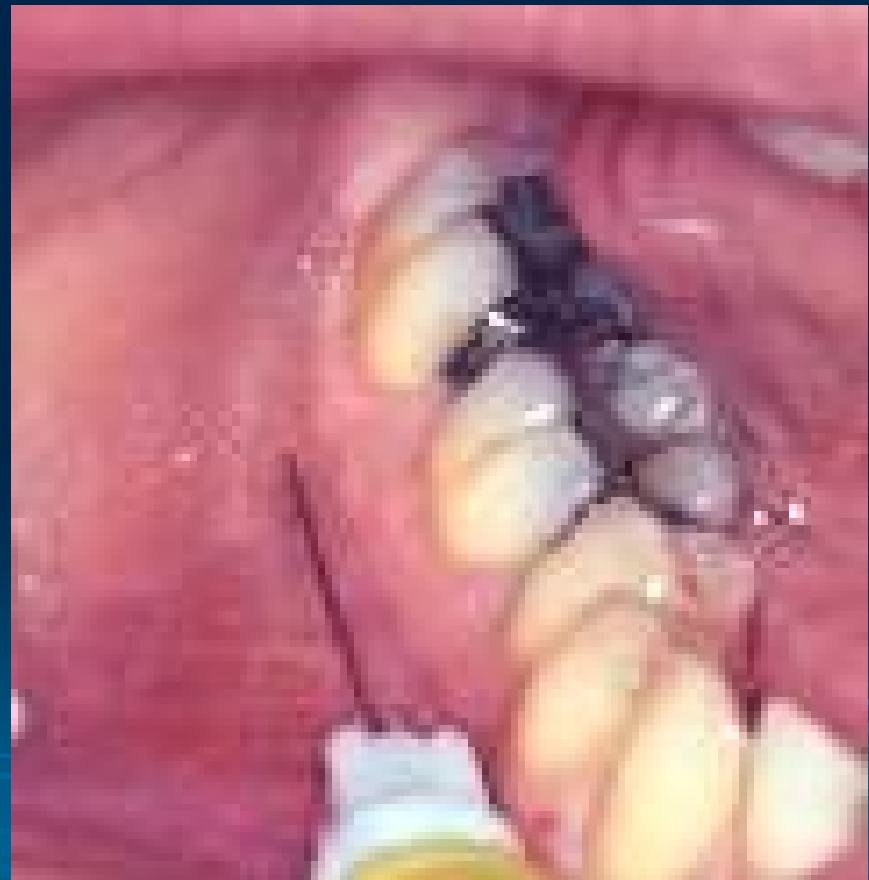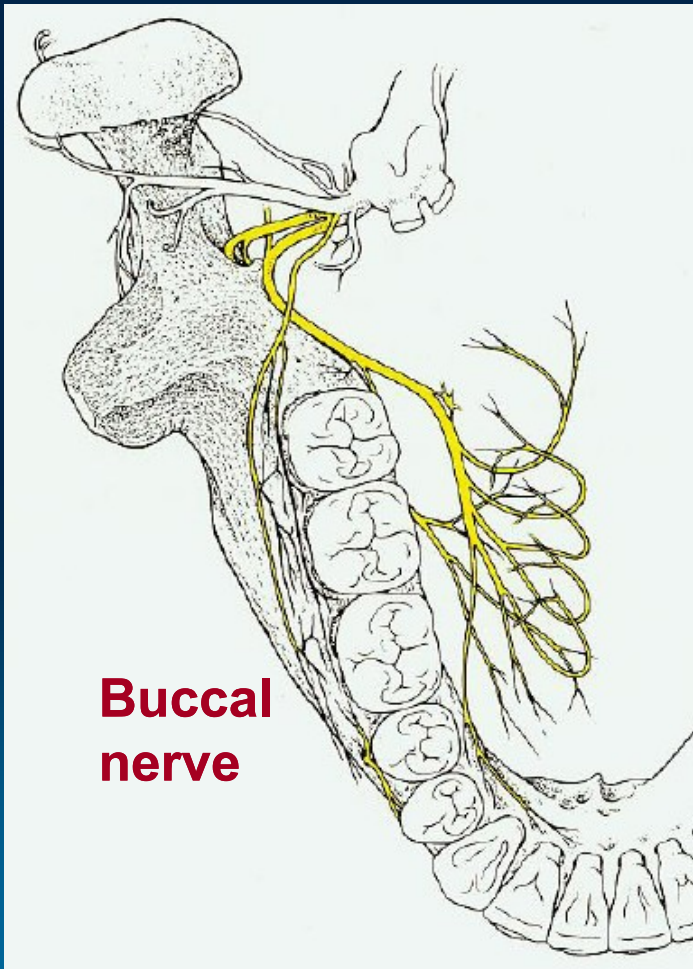
- Nerve passes from the infratemporal fossa into the floor of the mouth, in the vicinity of the 2nd and 3rd molars, is quite vulnerable
- Is anesthetized **during the inferior alveolar nerve block** or with a **bolus of anesthetic solution** injected after an inferior alveolar nerve block
- Anesthetized **anterior $\frac{2}{3}$ of the tongue, lingual gingiva and adjacent mucosa**

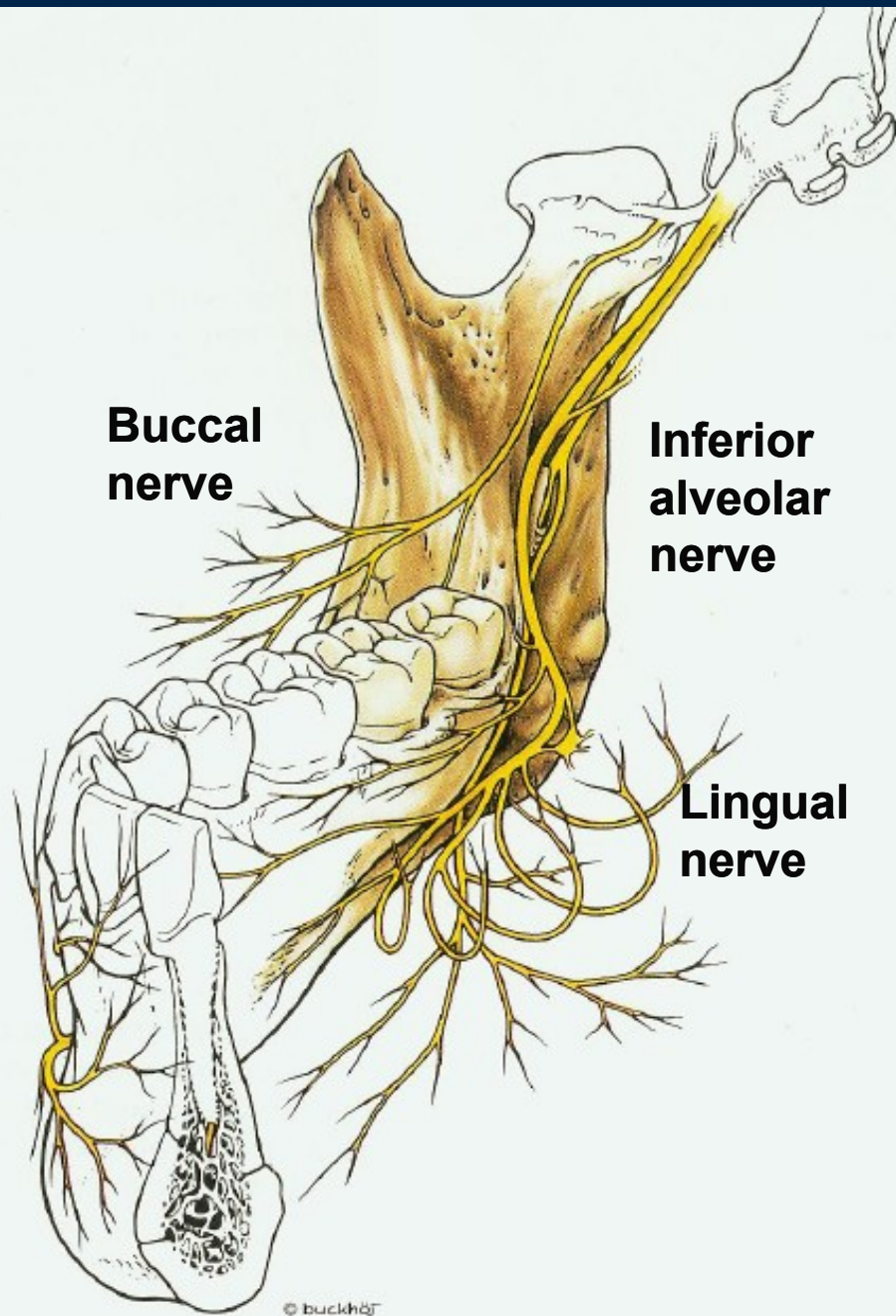


10. Buccal Nerve Block

- Arises in the infratemporal fossa and crosses the anterior border of the ramus to give multiple branches
- Supplies **buccal gingiva and mucosa** of the mandible for a **variable length**, from the vicinity of the **3th molar to the canine**

Technique - anterior ramus of the mandible at the level of the mandibular molar occlusal plane in the vicinity of the retromolar fossa





**Buccal
nerve**

**Inferior
alveolar
nerve**

**Lingual
nerve**

**Mental
nerve**

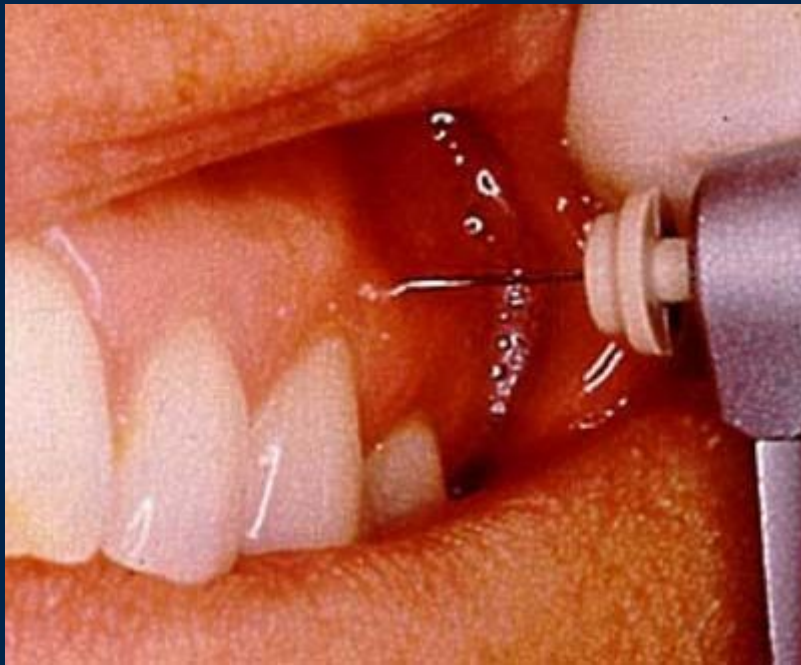
Alternative delivery methods

1. Intraosseous injection
2. Intraligamentary injection
3. Intrapulpal injection
4. Topical anesthetic patches

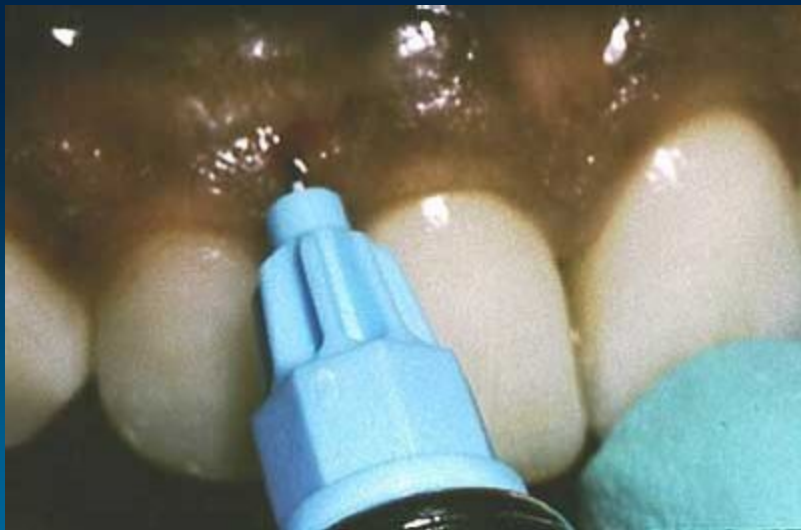

1. Intraosseous Injection

- Involves the placement of anesthetic solution **directly into the cancellous bone** adjacent to the tooth to be anesthetized, and allows for rapid onset of profound pulpal anesthesia
- The site of injection involves the **attached gingiva 2mm apical to the gingival margin** and interproximal relative to the teeth
- Provide anesthesia of a **single tooth or multiple teeth in a quadrant**



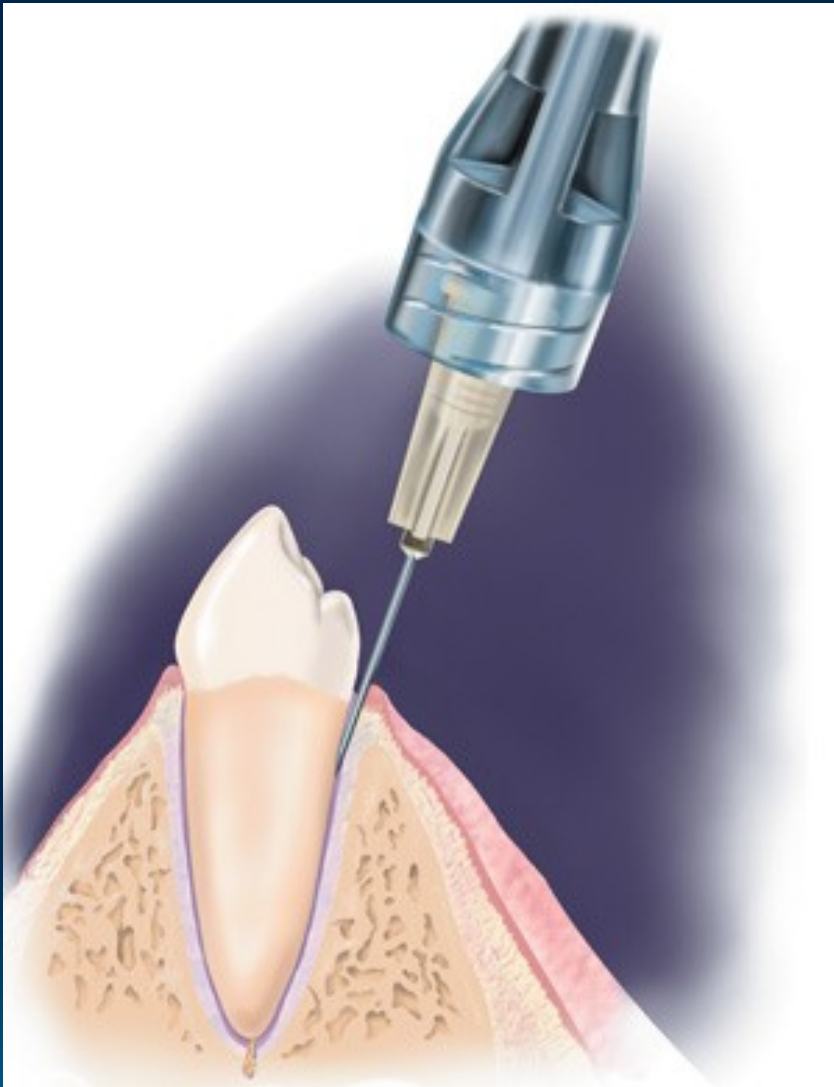
The first step - to drill a small hole through the soft tissue and cortical bone to a depth of 5 – 8mm



The second step - inserting a needle to the same depth and manually injected the desired volume of anesthetic solution into the cancellous bone

2. Intraligamentary Injection

- Is occasionally used as the **sole technique for anesthetizing a single tooth**
- The needle is inserted, directly along the long axis and as apically as possible, through the gingival sulcus and **into the periodontal ligament** between the tooth and the alveolar bone
- Slowly injected approximately **0,2ml** of anesthetic solution under pressure to control the pain of the associated tooth



Contraindication:

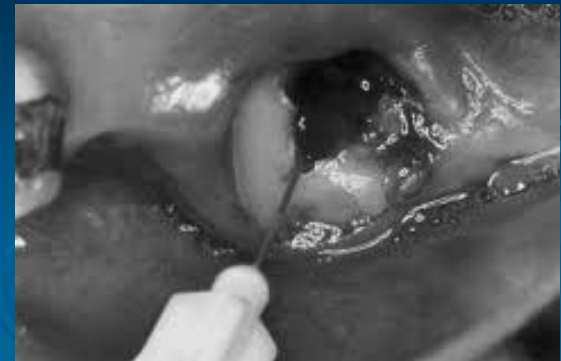- deciduous teeth
- periodontal infection

3. Intrapulpal Injection

- When **pulp chamber has been exposed** and treatment can't proceed

Technique - a small needle is inserted into the pulp chamber until resistance is encountered → injected under the pressure

- As the injection is started there will be a brief moment of **intense discomfort**



4. Topical anesthetic patches

- Be indicated to **minimize the sensation of needle insertion** or for very brief relief from **painful mucosal lesions**
- A **bioadhesive patch** impregnated with 10% or 20% lidocaine
- Typically, is used to anesthetize only the **outer 1-3 mm of mucosa**, not deeper structures

Spray



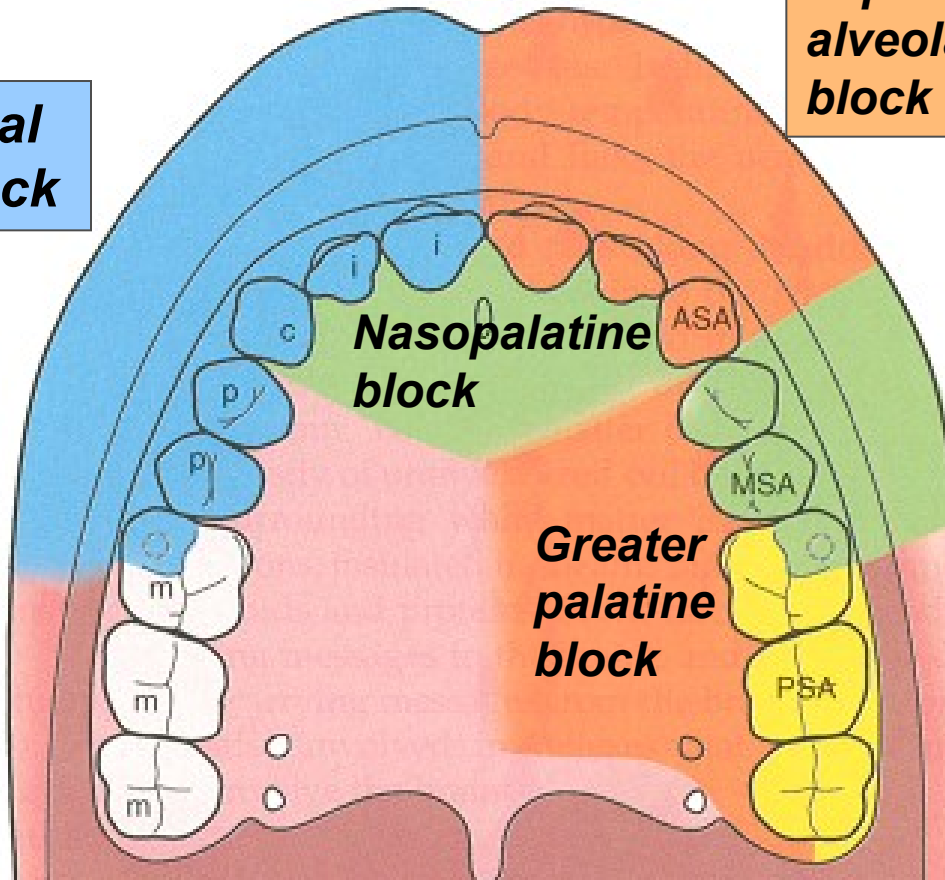
Gel



Maxilla

**Infraorbital
nerve block**

**Anterior
superior
alveolar
block**



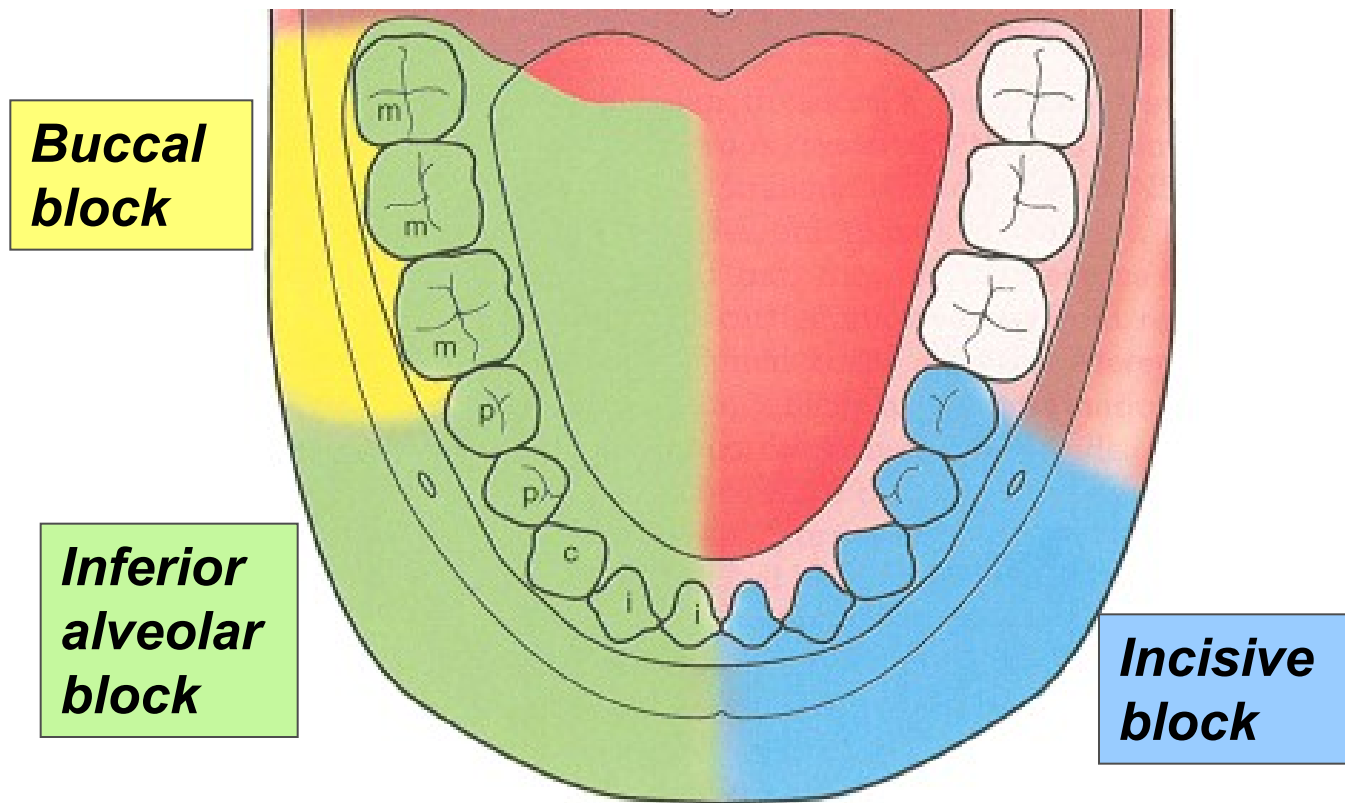
**Nasopalatine
block**

**Middle
superior
alveolar
block**

**Greater
palatine
block**

**Posterior
superior
alveolar
block**

Mandible



**Buccal
block**

**Inferior
alveolar
block**

**Incisive
block**