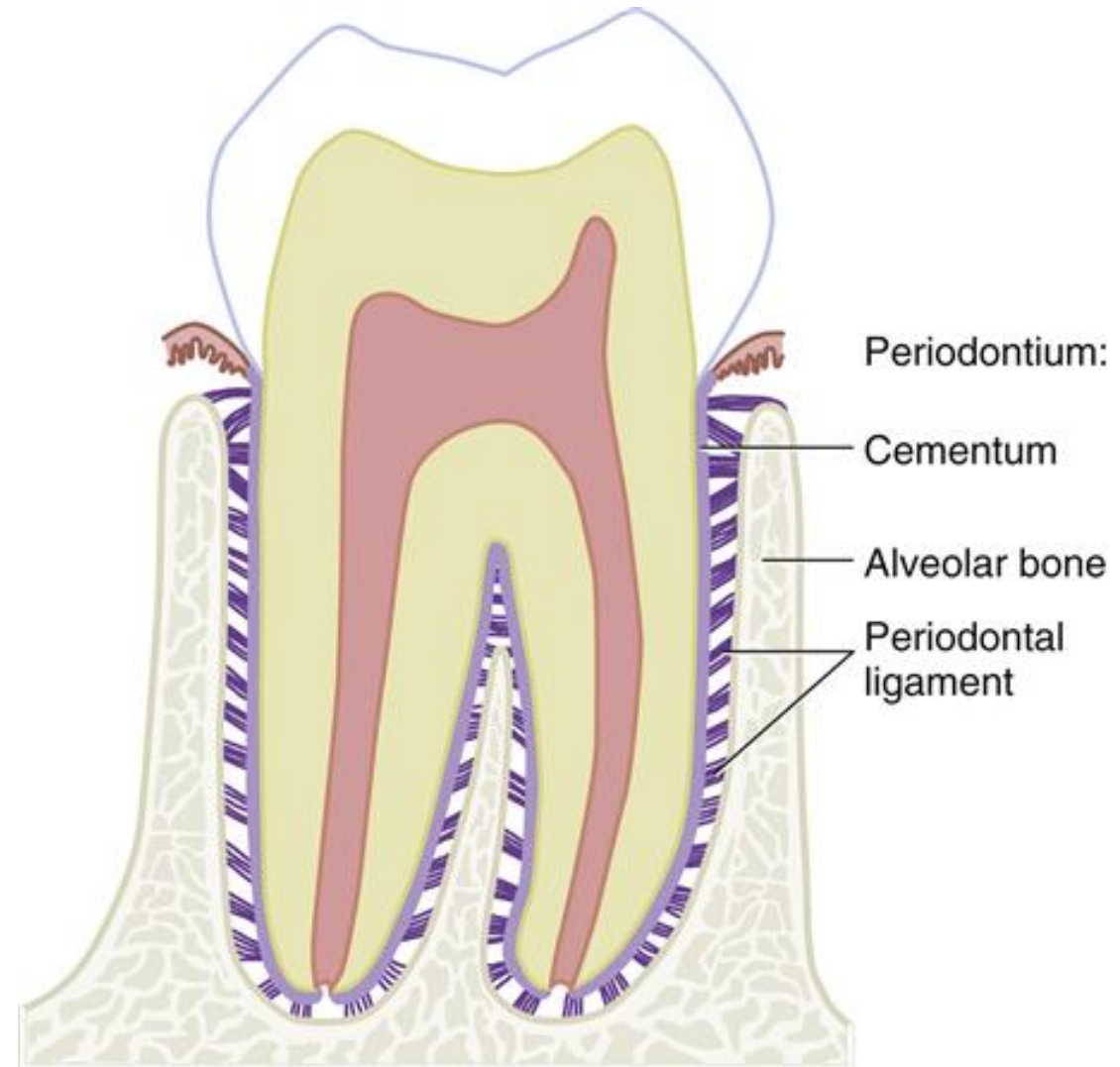


Microscopic structure of alveolar process and clinical aspects of its remodelling

Periodontium



Jan Křivánek
22. 3. 2022

Overview of bone microstructure, and bone plasticity

Two main functions:

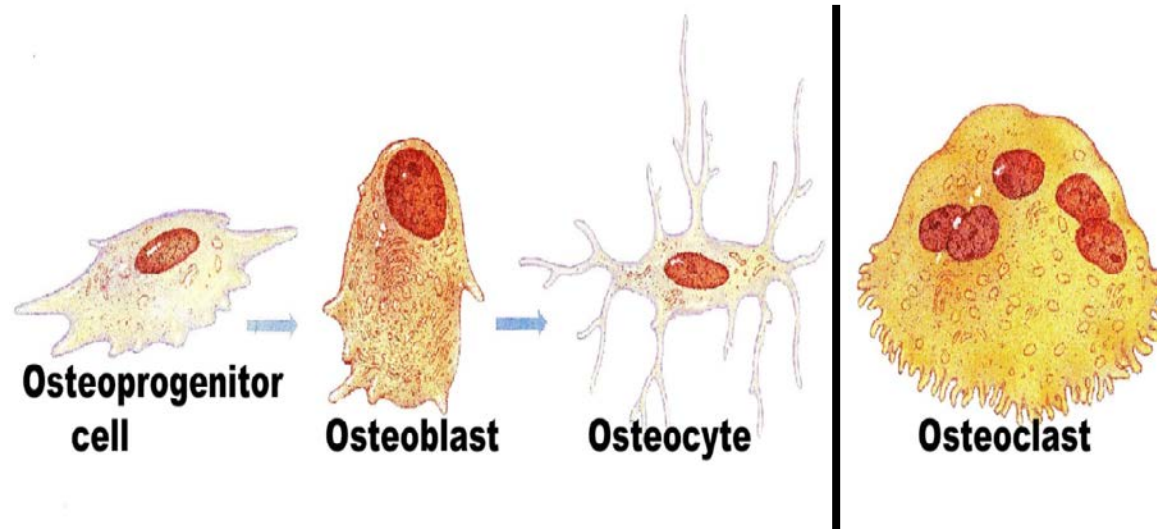
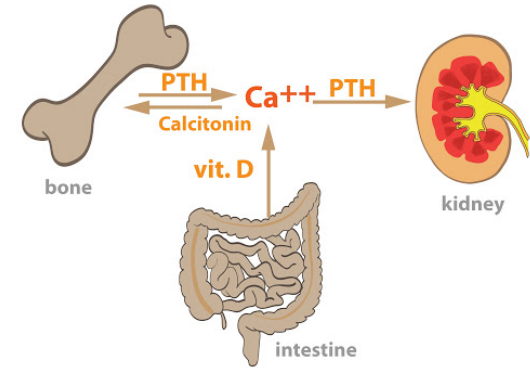
Structural – forming skeleton

Storage of Ca^{2+} in our bodies (99 %) - releasing calcium from bone into blood and vice versa

Composition:

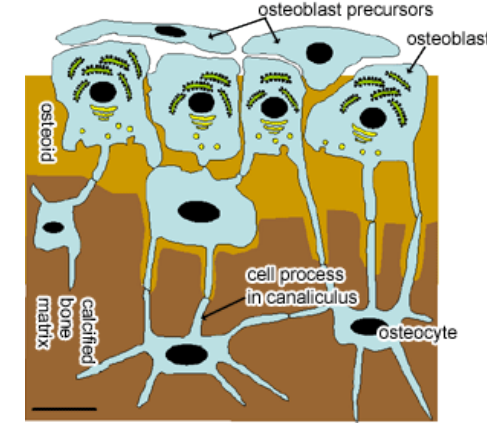
Cells

Extracellular matrix (ECM) - bone matrix



Cells in bone

osteoblasts a osteocytes; osteoclasts



Osteoblasts

Synthesize organic component of extracelullar bone matrix:
Collagen I, proteoglycans, glycoproteins

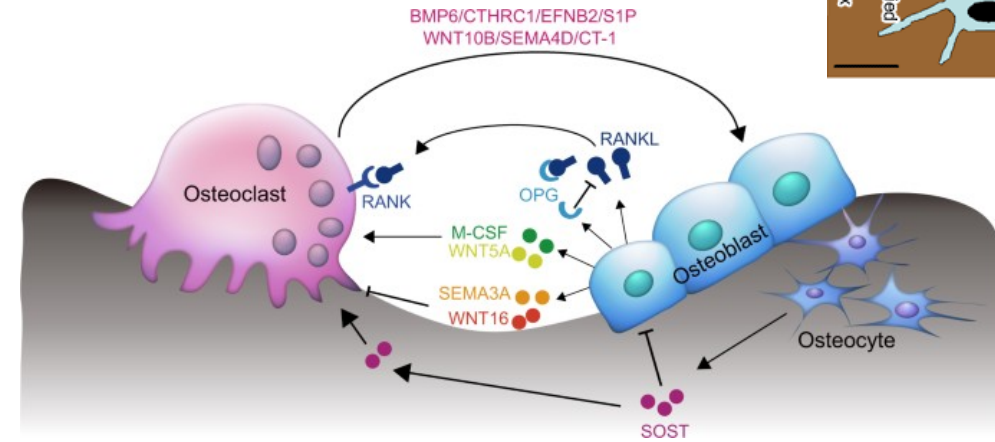
Deposit inorganic salts in matrix

During development forms one layer of cells on the surface

Osteocytes

„Resting“ forms of osteoblasts, have small oval bodies with thin cytoplasmic processes

Inhabit bone lacunea and its procesess are in **canaliculi ossium**

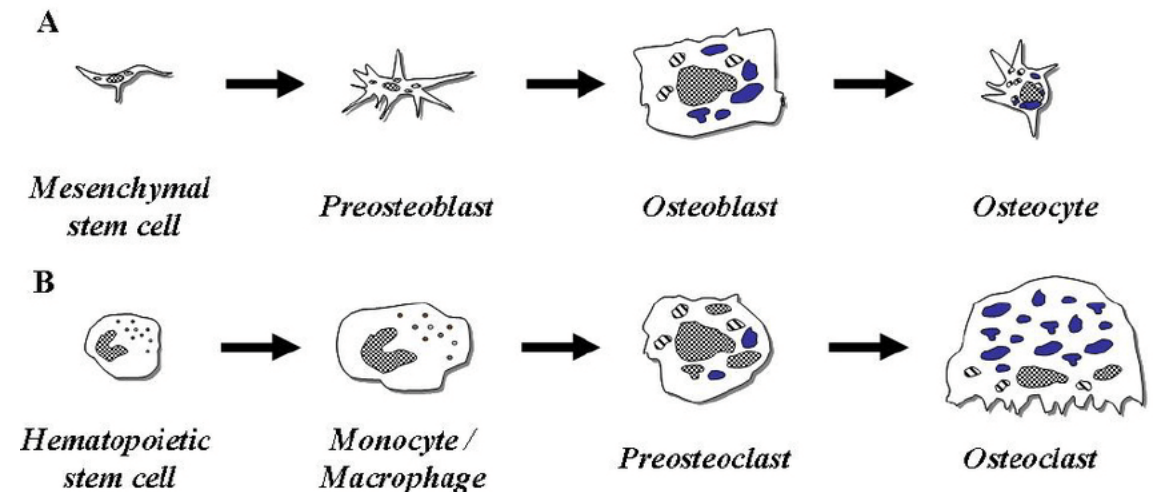


Osteoclasts

Large cells (diameter around 100 um), with multiple iregular procesess

Multinuclear – number of nuclei may be 50 or more, originate by the fusion of monocytes/macrophages

Digest/decompose bone matrix. Essential for bone remodelling



Extracellular matrix (ECM) – Bone matrix

Inorganic (+- 45 %) and **Organic** (+- 30 %), rest is Water

Inorganic component

Responsible for hardness and stiffness of bones

Formed by hydroxyapatite crystals – have shape of flat plates of hexagonal profile measuring 40 x 25 x 3 nm, deposited parallel to collagen fibrils

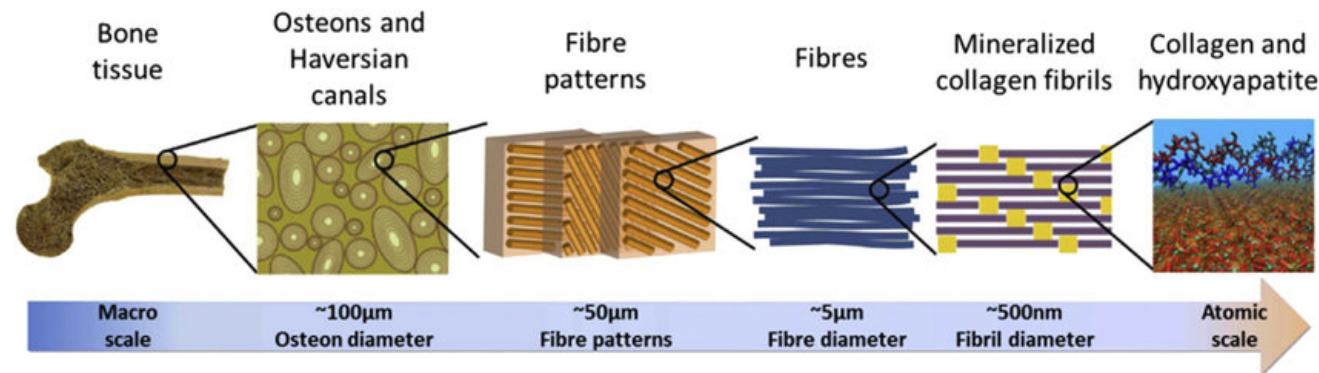
Organic component

Mainly **Collagen I**, then **proteoglycans** (glycosaminoglycans associated with proteins) and **adhesive proteins** – sialoprotein, osteocalcin, osteopontin, osteonectin

Important role in calcium deposition during bone growth and remodelling

Inorganic components are responsible for bone hardness while collagenous fibres determine the resilience and flexibility of bone

The ratio between inorganic and organic component is essential for the right mechanical behaviour



Histologically we divide 2 types of bone tissue

Woven bone (primary)

Primitive structure

Resembles calcified fibrous connective tissue

Firstly developer (during growth and remodelling)

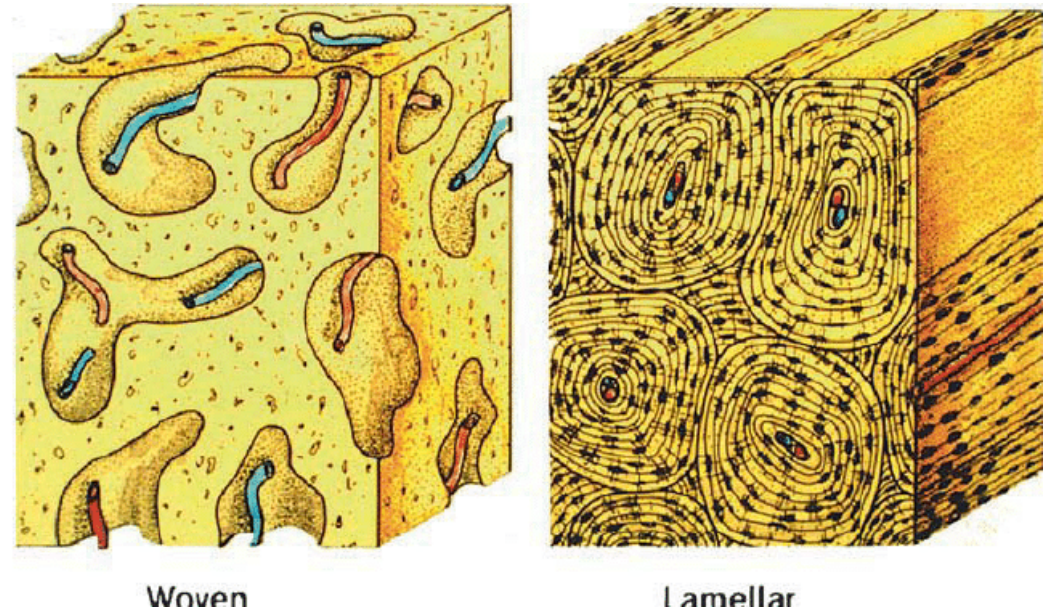
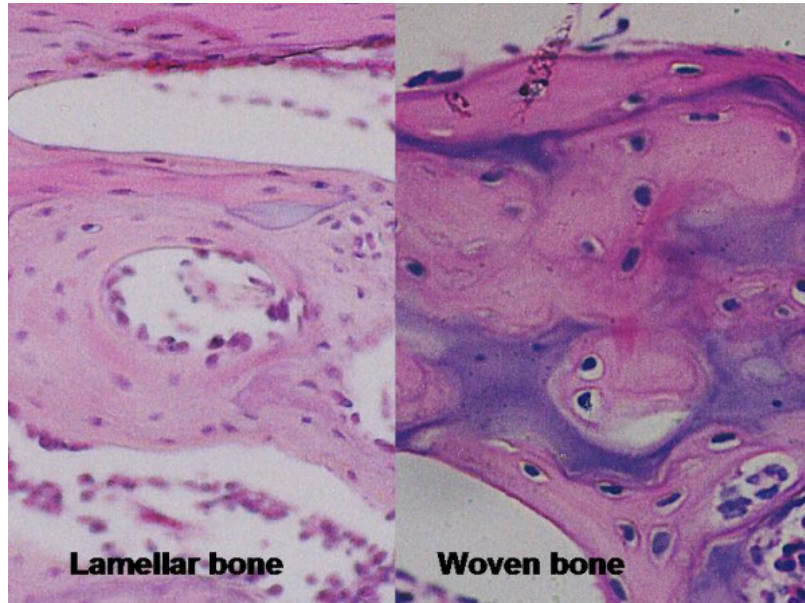
Lamellar bone (secondary)

Developmentally and functionally better developed

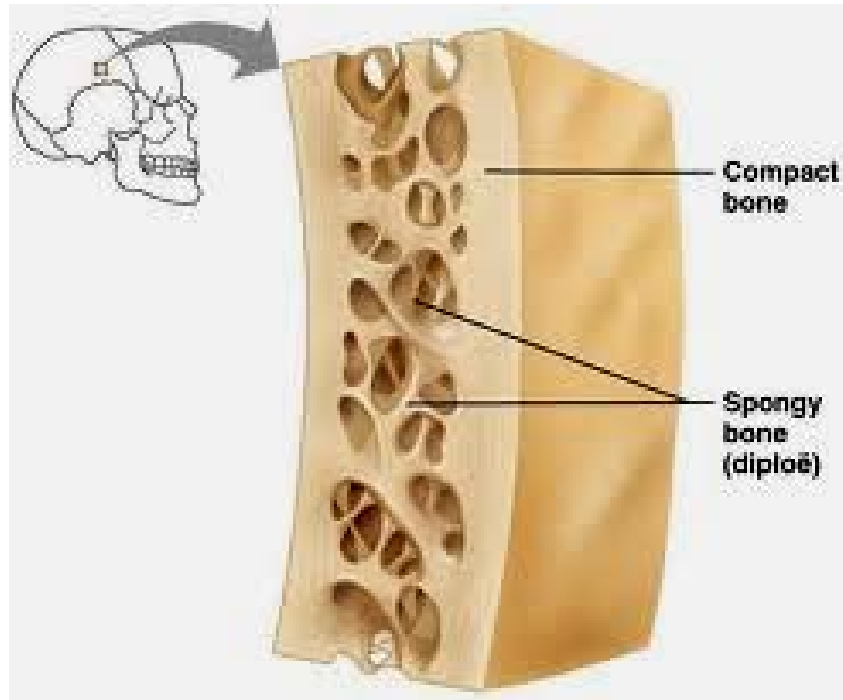
Bone lamellae = 3-7 μm

Collagenous fibres in lamellae always in the same direction

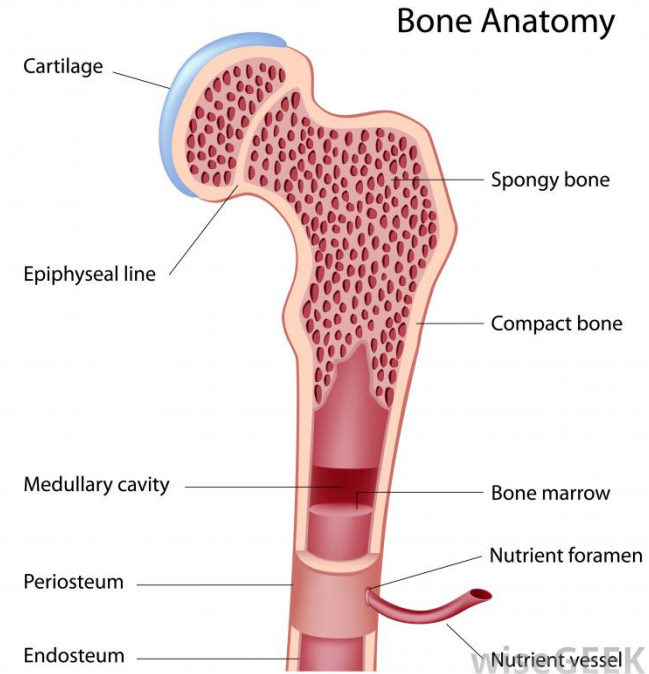
Osteocytes between lamellae



All bones of skeleton (long, short, flat, irregular) – are composed only by lamellar type
Lamellae are present in both forms: **Compact (dense) bone** and **Spongy (cancellous, trabecular)**



Flat bone



Long bone

External and internal surfaces are covered by a connective tissue coats – the periosteum (well developed) and the endosteum (less obvious)

Compact bone consists of **three types** of lamellae

Concentrically arranged lamellae around longitudinal haversian canals, number: 4 to 20

Form cylindrical units called **osteons** that run parallel to longitudinal axis of bone

In cross sections, osteons appear as concentric rings around circular opening (Haversian canal),

In longitudinal sections lamellae resemble closely spaced bands

Interstitial lamellae

Are lamellae without relations to blood vessels

Supposed to be rests of old non-functional Haversian systems which are just being resorbed

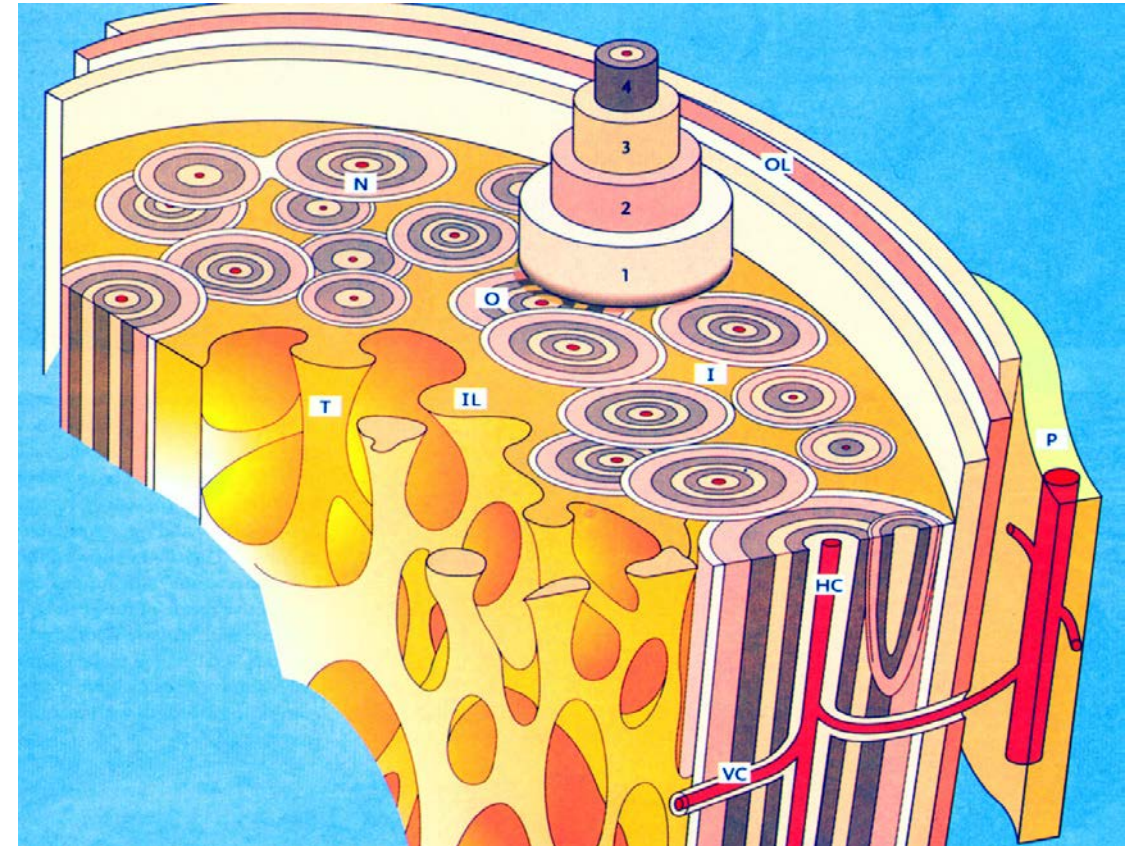
Circumferential lamellae

Located at outer and at inner surface of bone

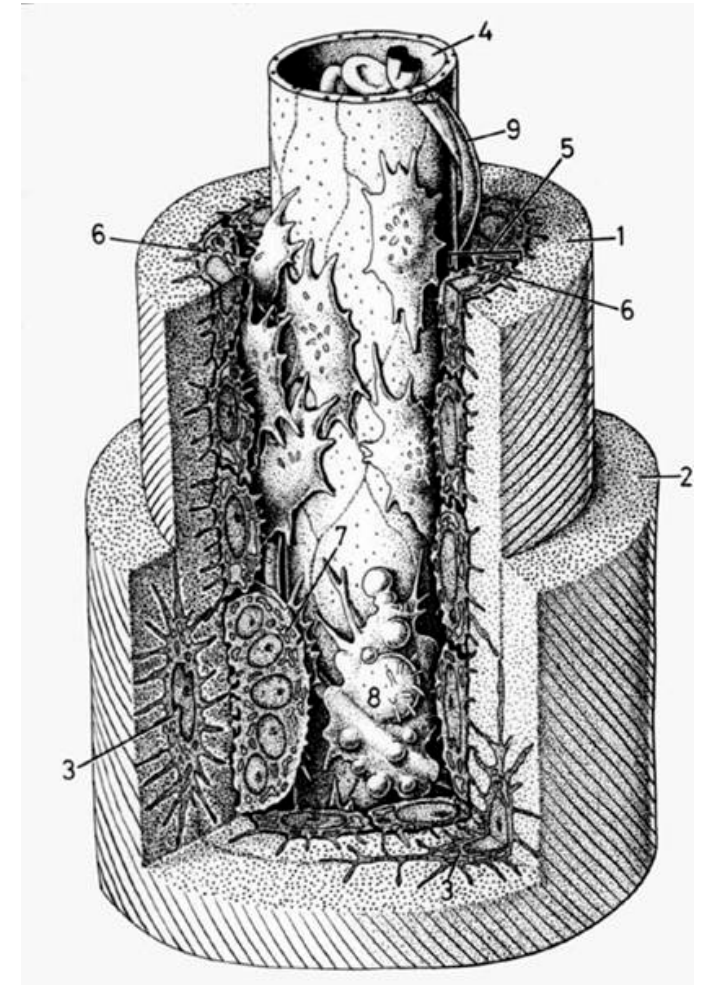
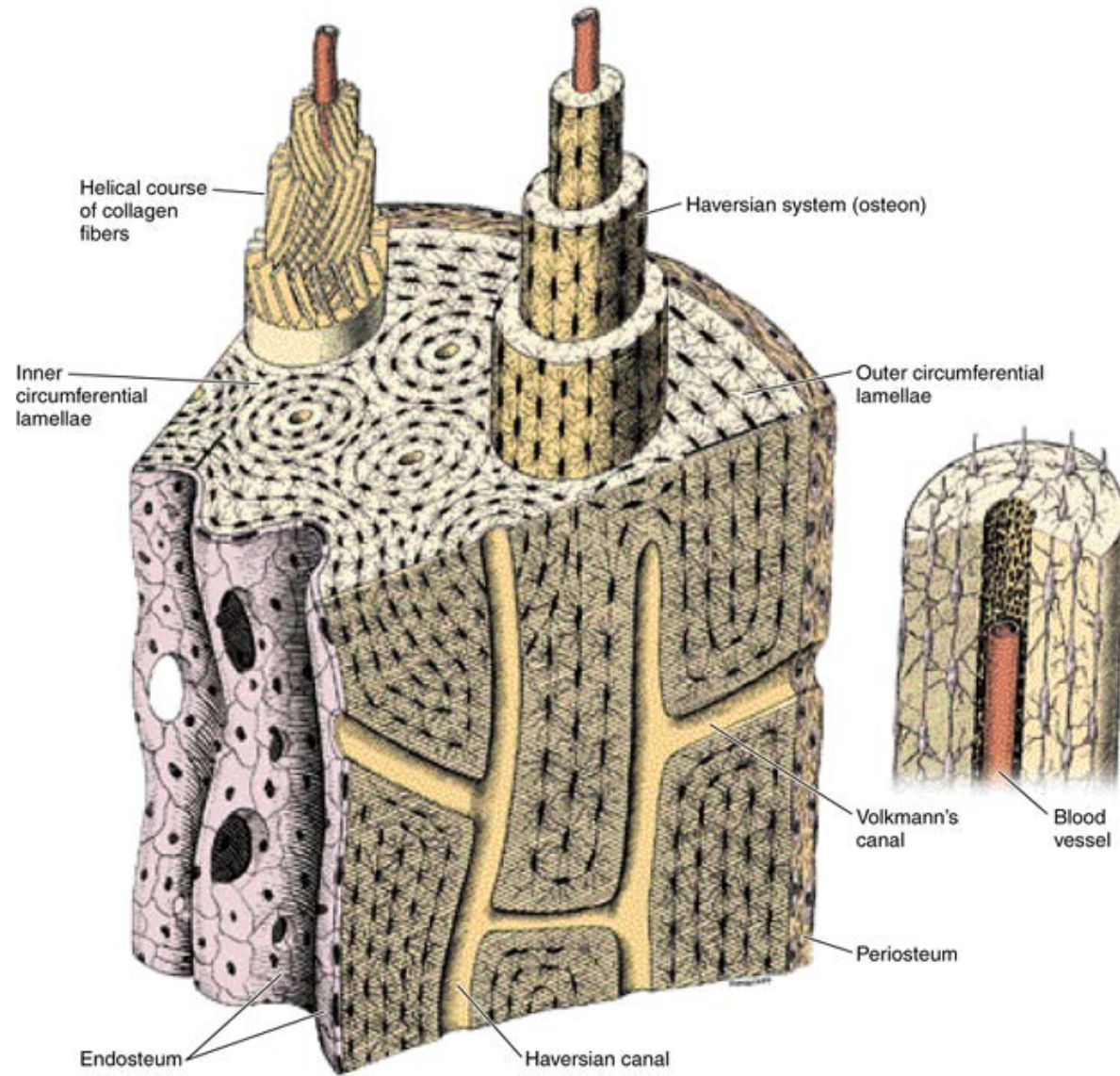
Run in parallel to the periosteum or parallel to endosteum (around the central cavity)

Outer circumferential lamellae

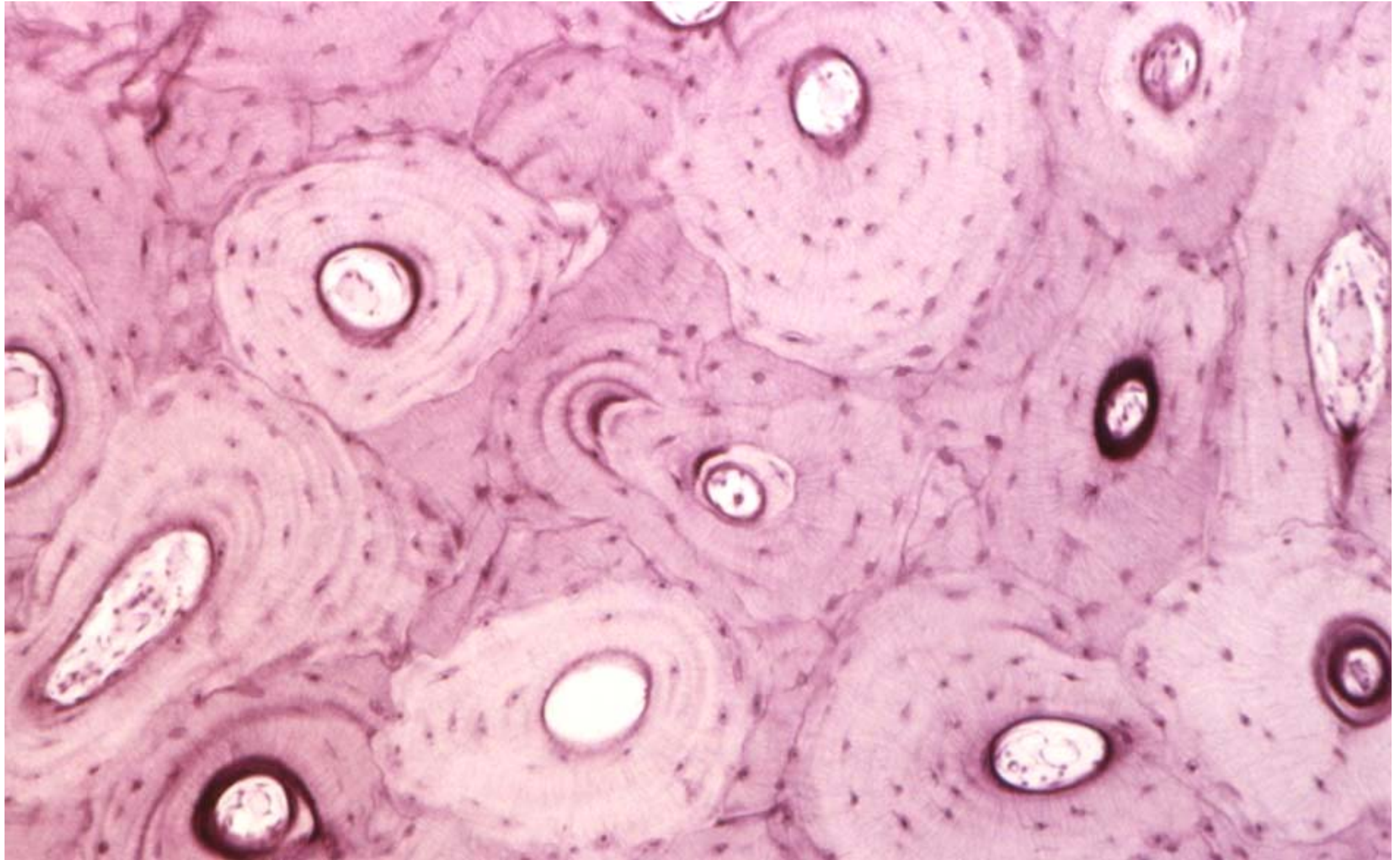
Inner circumferential lamellae



Osteon



Diaphysis transversally (HE)



2 types of vascular channels in the compact bone

Haversian canals

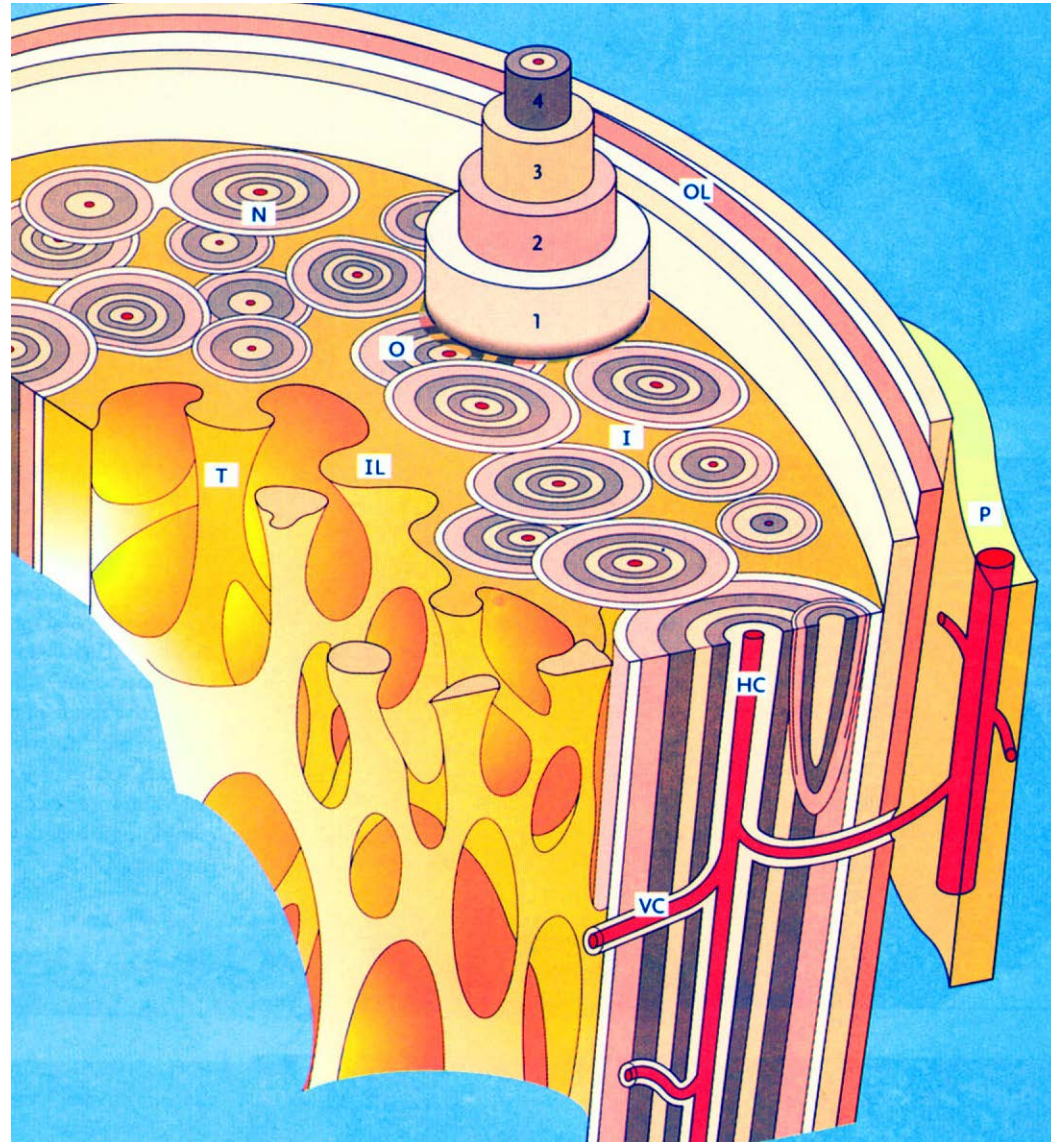
In the centers of Haversian systems

Contain one or two blood vessels

Volkman's canals

Are not surrounded by lamellae and traverse the bone in perpendicular or oblique direction to the Haversian canals

Function: connect Haversian canals with one other and serve for vessels entering the compact from the periosteum or the marrow cavity

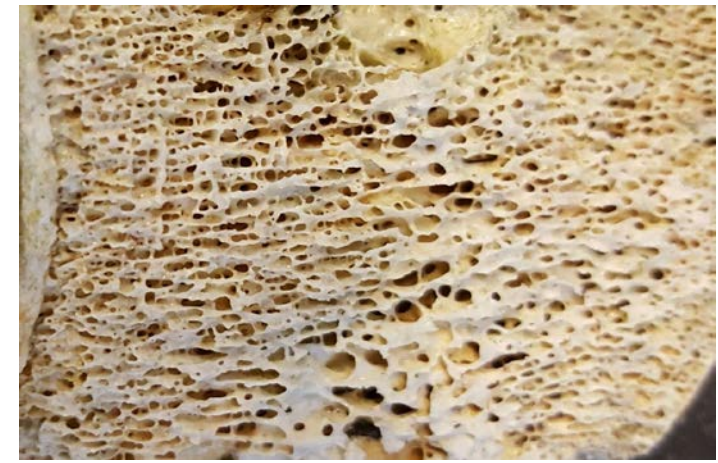

Haversian and Volkmans canals

Cancellous/Trabecular bone

composed by trabeculated bone tissue

The course of depends of forces from outer environment



Periosteum

Around the bone – from outside

Highly innervated (pain)

2 layers:

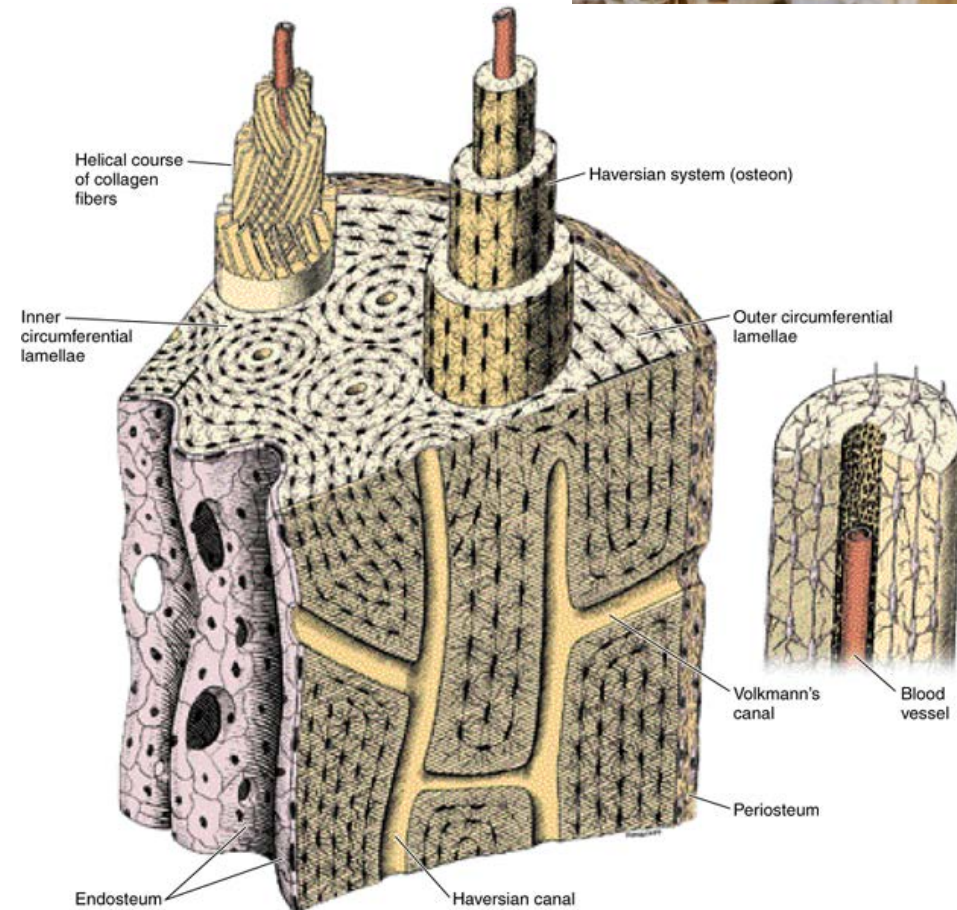
Stratum fibrosum, Sharpey's fibres

Stratum osteogenicum – osteoprogenitor cells

Endosteum

On the inner surface

Same structure as the periosteum, but thinner



Bone plasticity

Bones as organs can remodel the internal structure to match the actual mechanical load

Remodelling: interaction/equilibrium between osteoblasts and osteoclasts activity

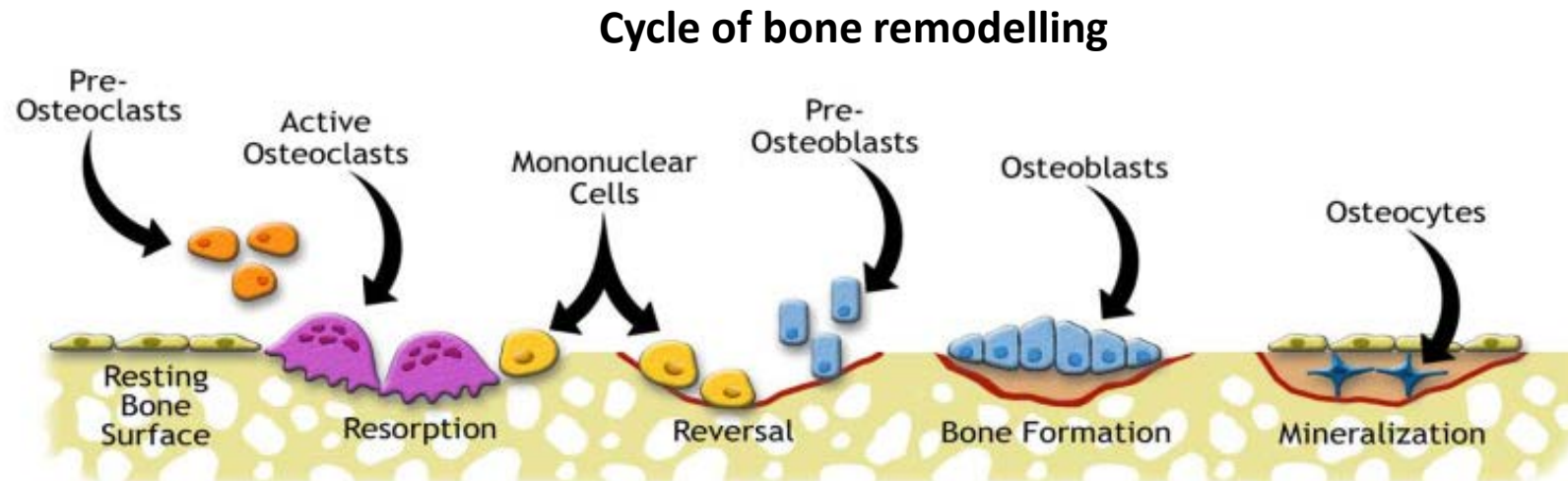
Remodeling is rapid in childhood - it is reported that about 10% of skeletal bones are rebuilt each year

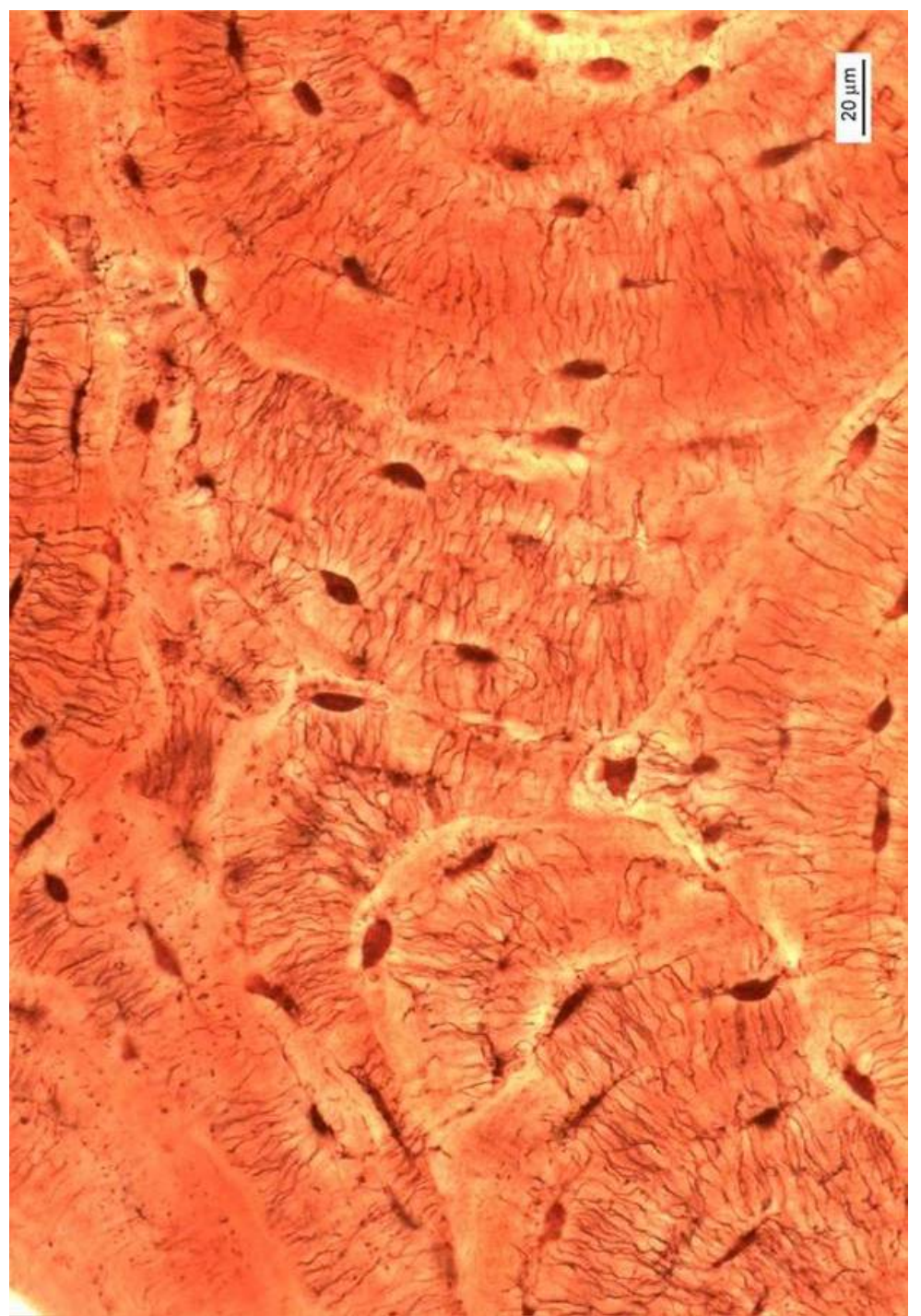
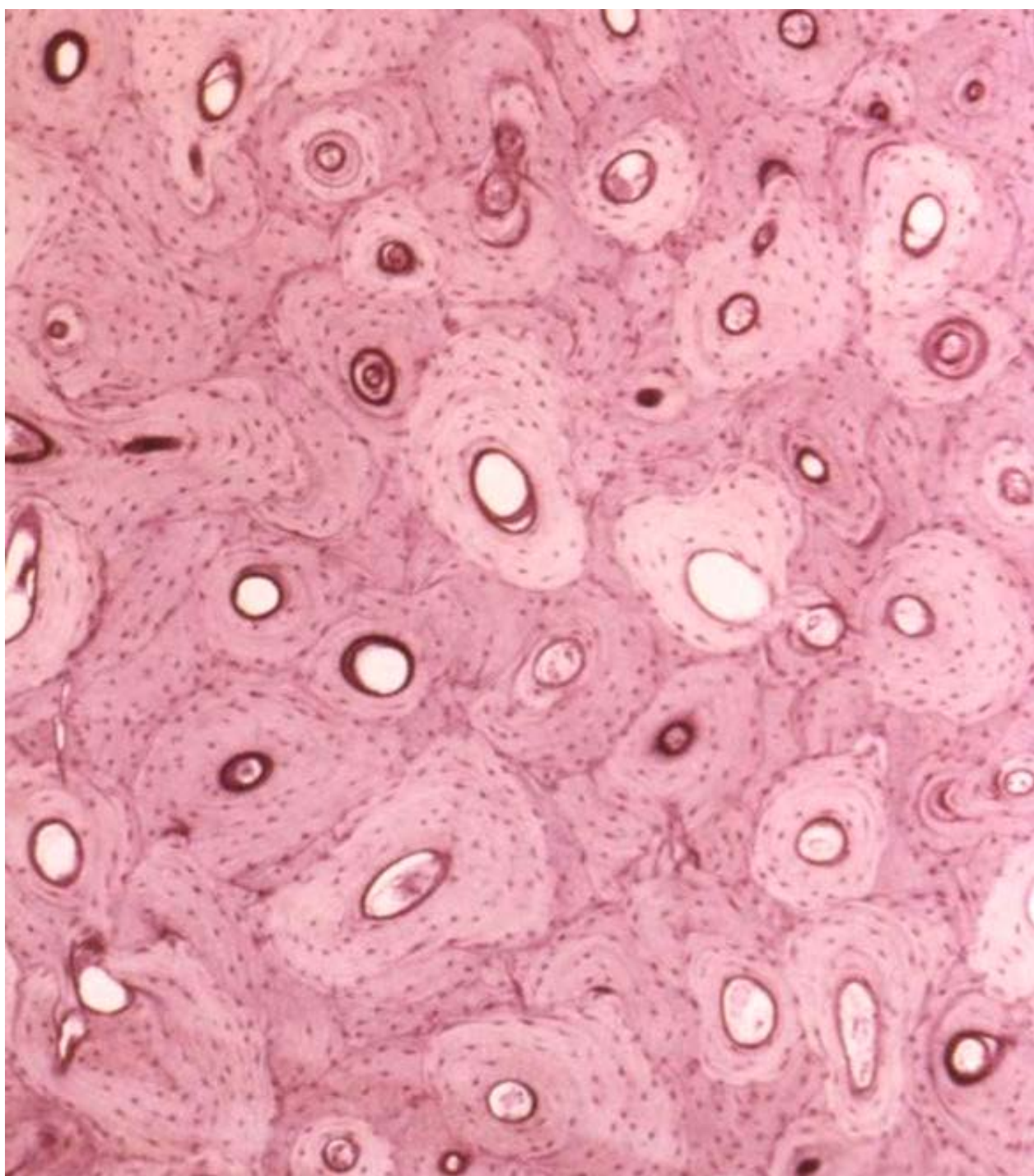
Bone remodeling can be induced by artificial stimuli: by the action of tension or pressure

The action of tension creates new bone tissue,

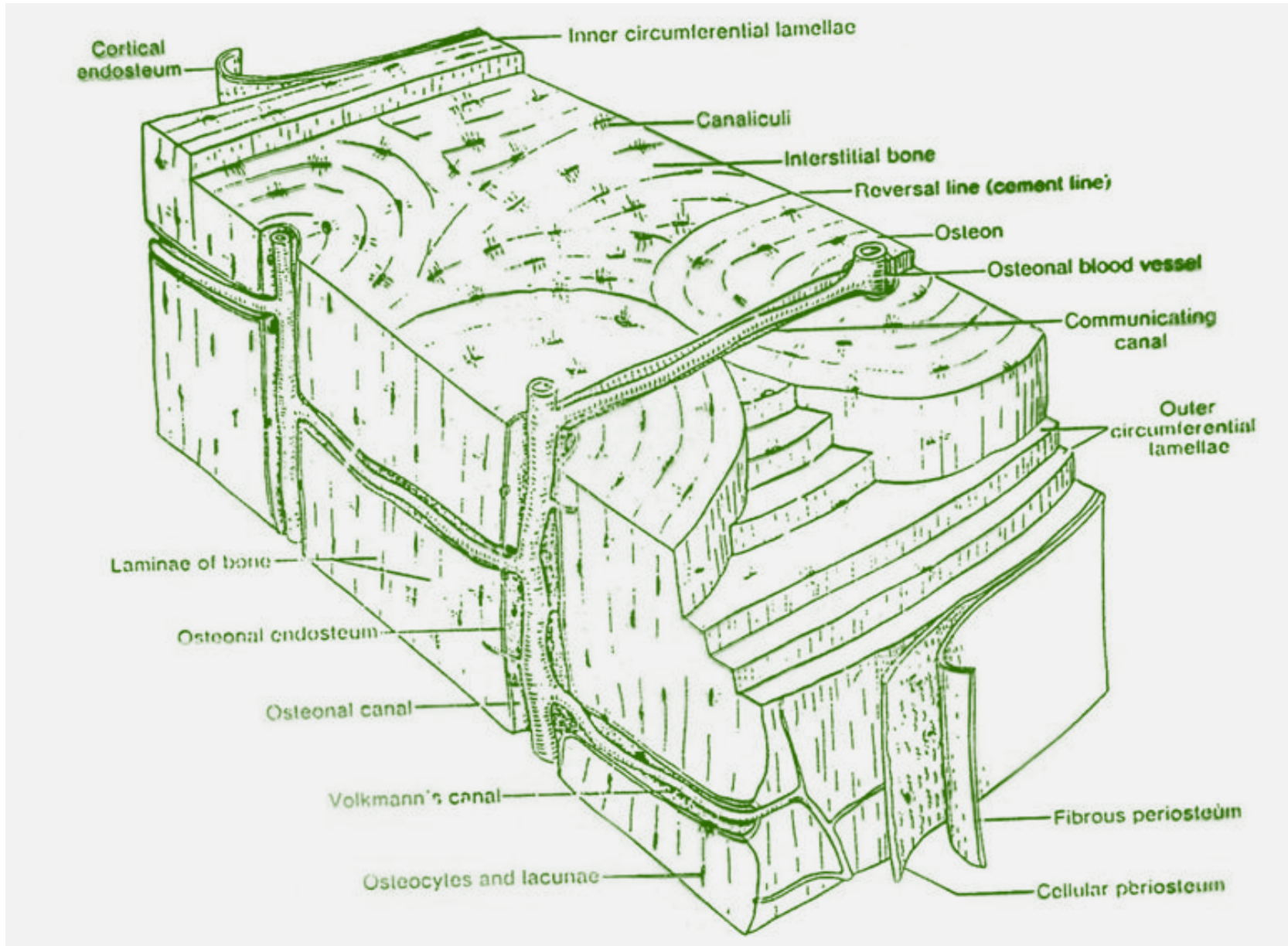
Opposite, it is resorbed under the action of pressure

The role of osteocytes - they act as mechanosensors, they transmit a signal to osteoblasts in the endost or periosteum, and they transmit it to osteoclasts





Summary



Alveolar process (*processus alveolaris*)


Part of the jaw which form the bony support for teeth (*alveoli dentales*)

The protrusion, like other anatomical sections of the jaws, is composed of **lamellar-type bone tissue - dense and spongy**

Compact bone structure

2 plates:

- **Cortical (external alveolar)** - forms the vestibular or oral side of the alveoli
- **Cribriform (internal alveolar, os alveolaris, lamina dura)** - forms the wall of alveoli



Cortical (outer alveolar) plate

Thicknes: 1,5 - 3,0 mm

Divided into:

- Lamina vestibularis
- Lamina oralis

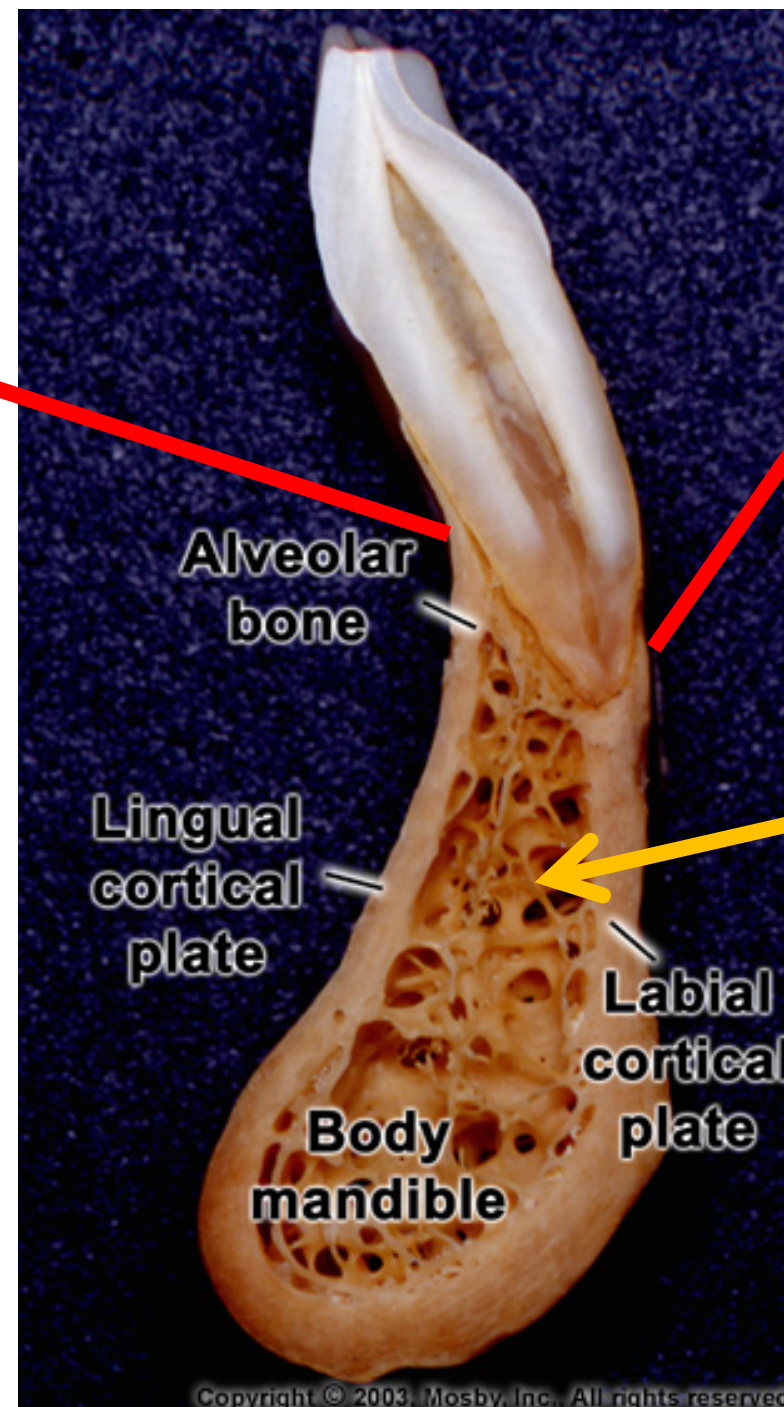
Both are covered by periosteum

Osteons in different directions

In the area of mandibular molars is lamina oralis usually thickened

lamina oralis

lamina vestibularis



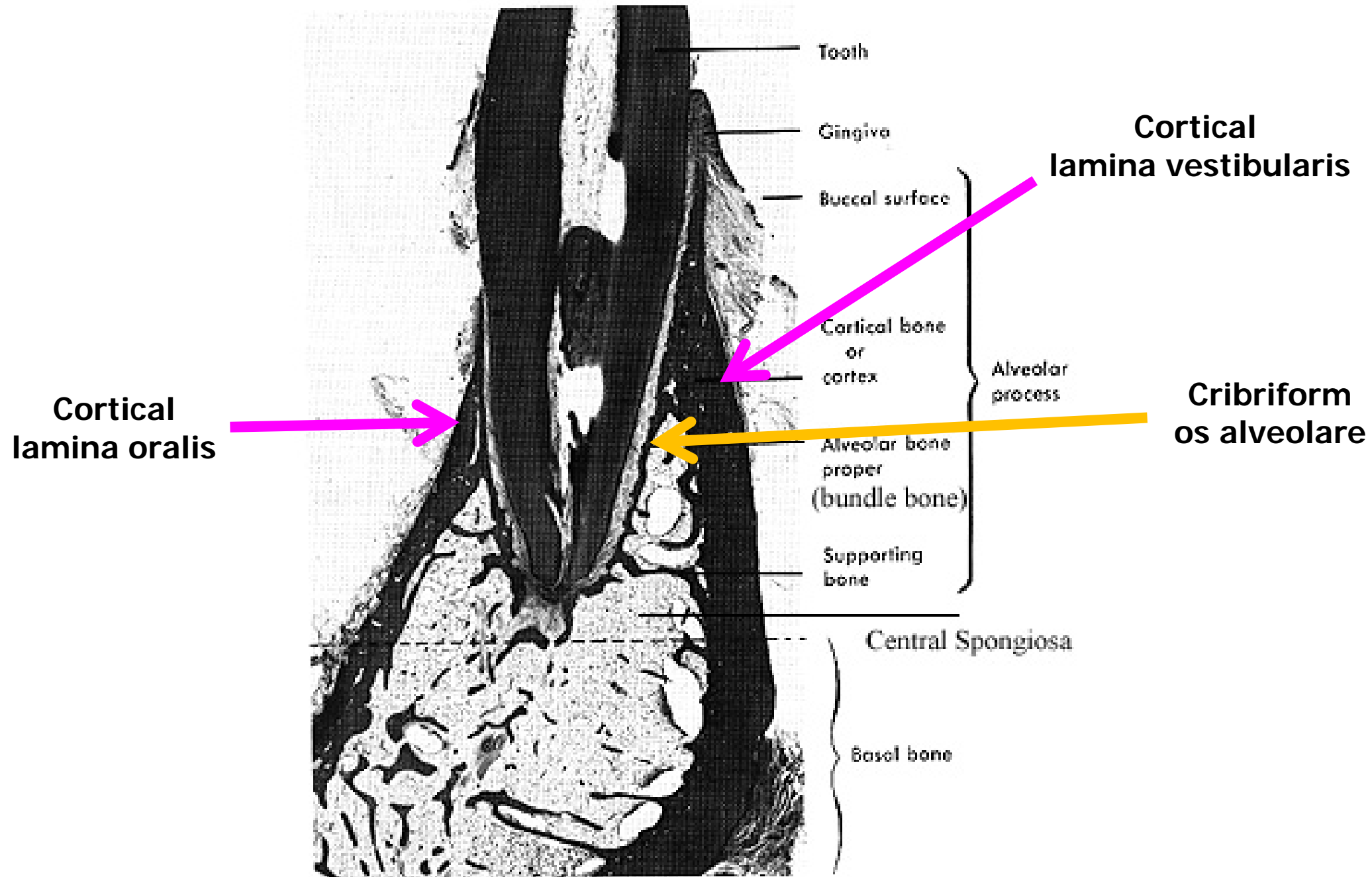
Alveolar
bone

Lingual
cortical
plate

Labial
cortical
plate

Body
mandible

Cancellous
bone



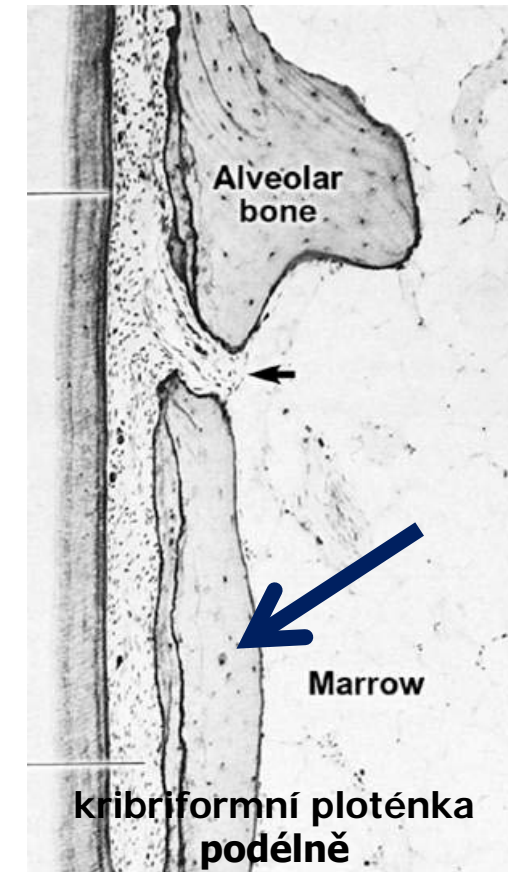
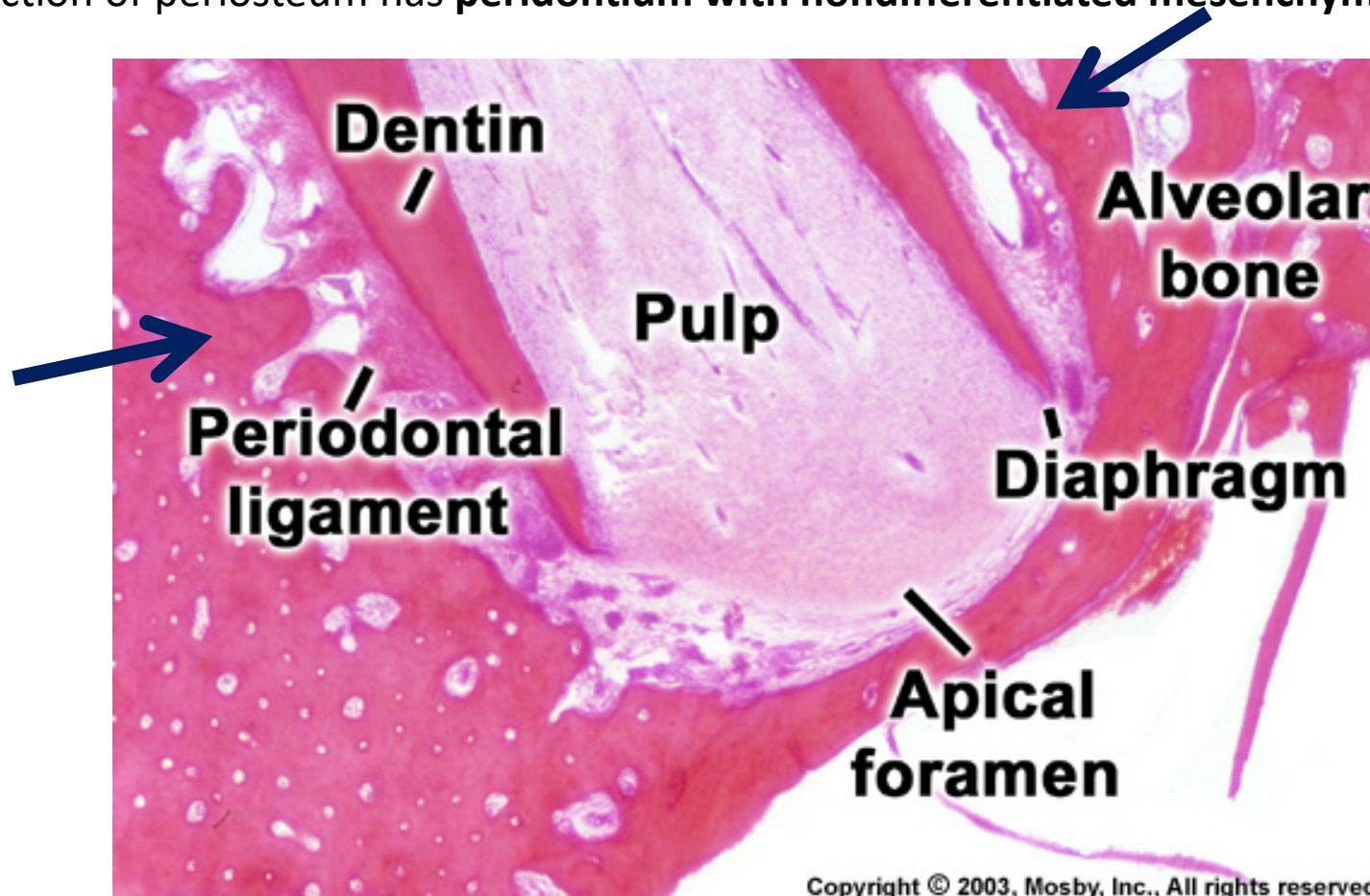
Cribriform plate (inner alveolar plate = os alveolare)

Forms the wall of alveolus, is thinner – 0,5 - 1,0 mm

Perforated by Volmanns channels (for interalveolar vessels and nerves)

Structure similar as in cortical plate, but no periosteum

The function of periosteum has **peridontium with nondifferentiated mesenchymal cells** (diferentiate into different -blasts)



In cribriform plate are anchored PDL endings – Sharpey's fibres

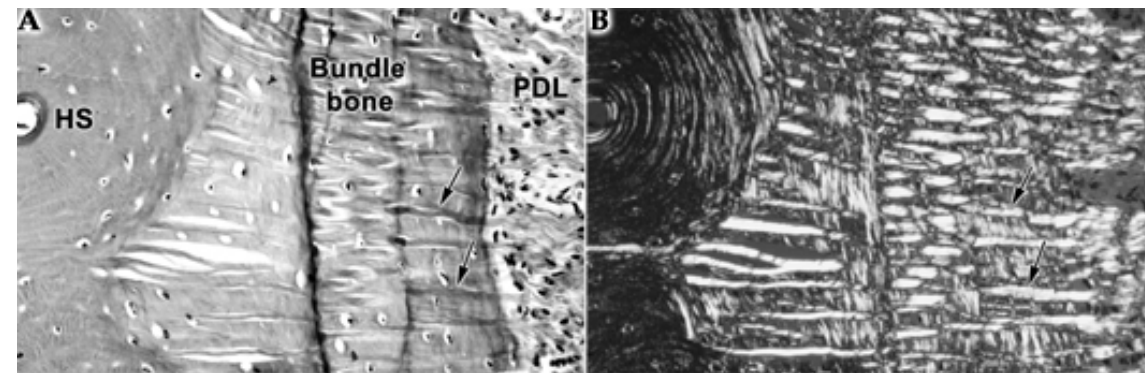
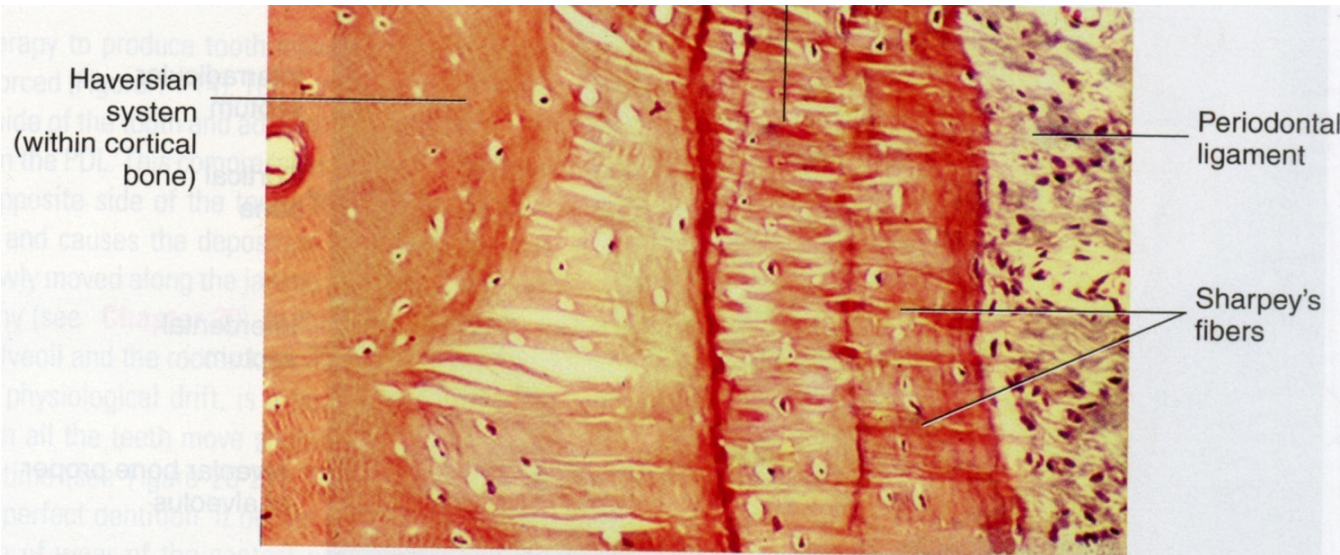
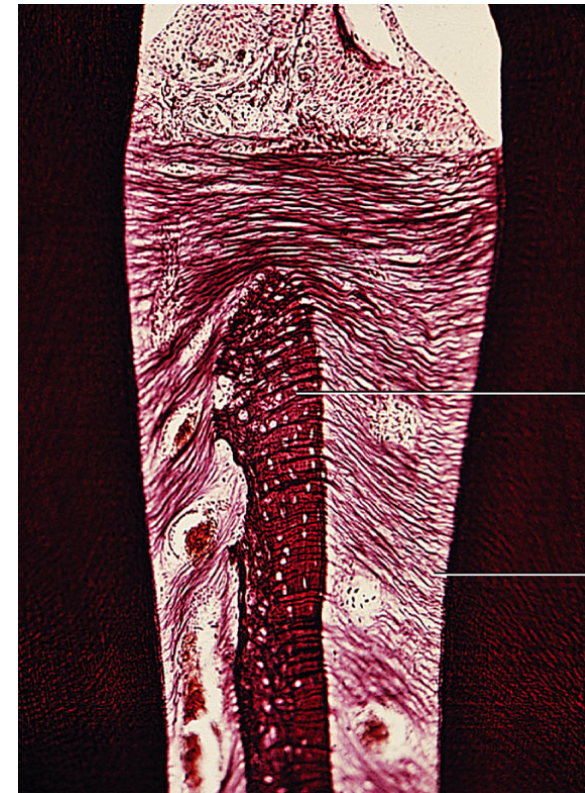
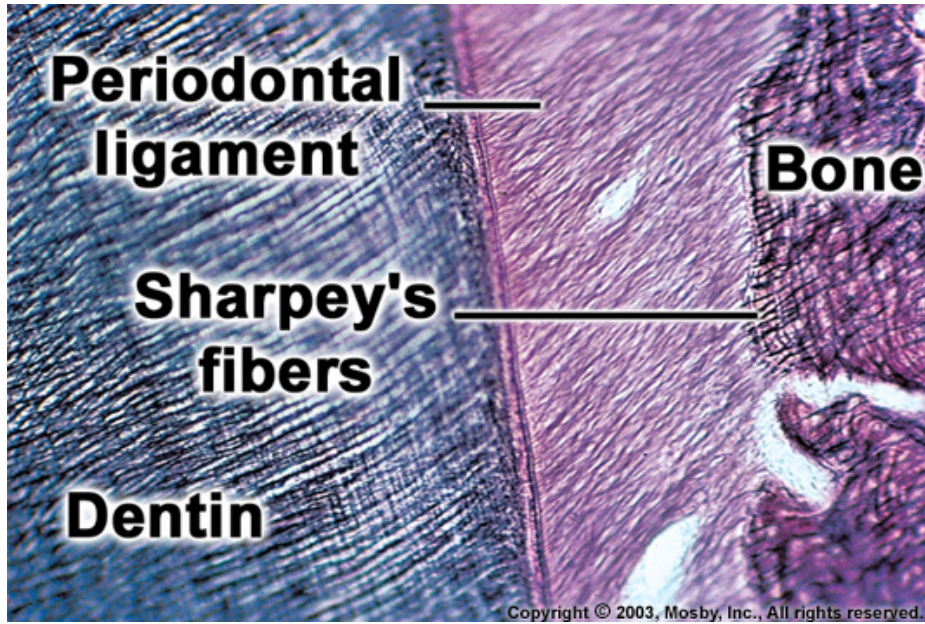
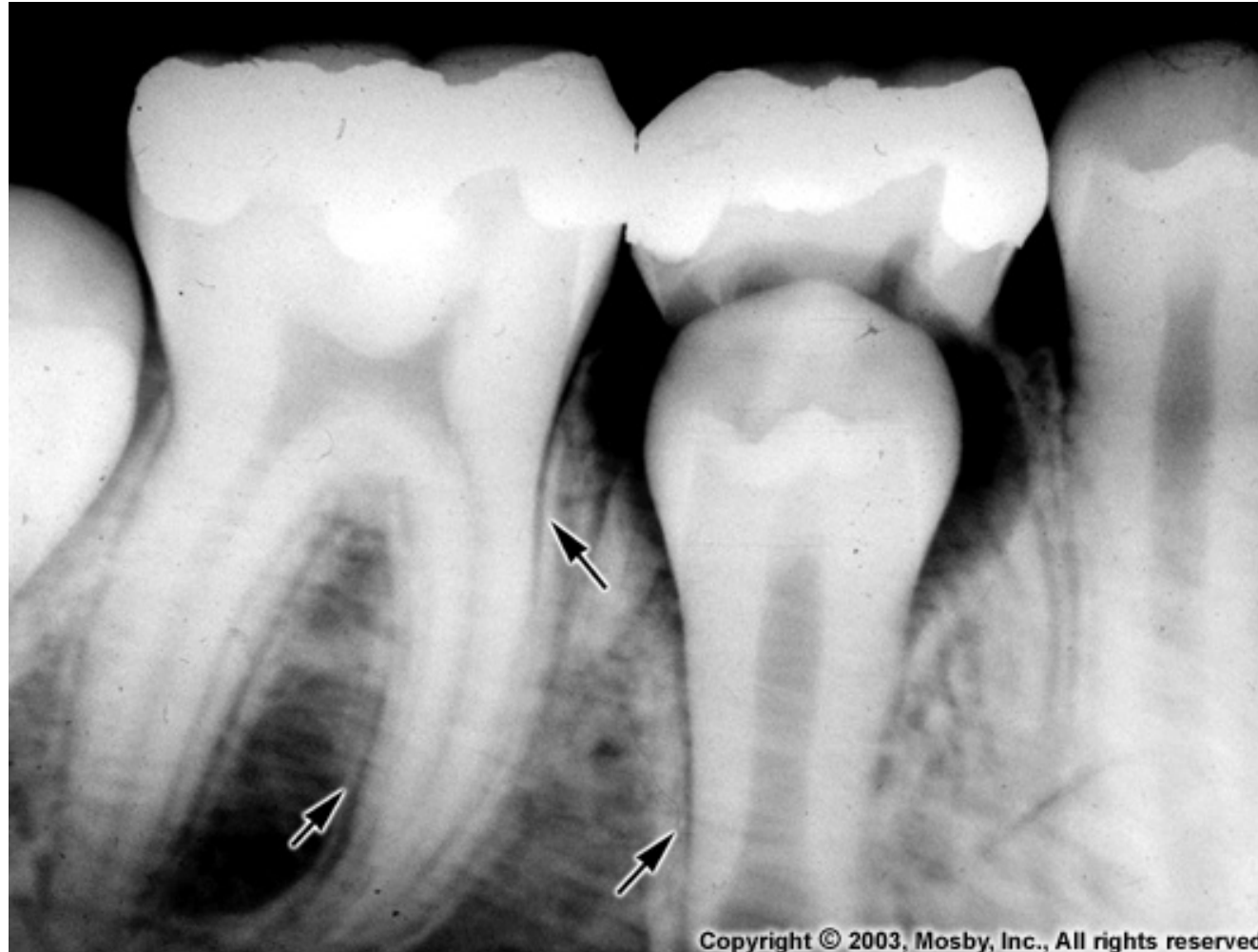

FIGURE 14-16 Microscopic view of the insertion of Sharpey's fibers from the periodontal ligament into the alveolar bone proper in the root area. Note the Haversian system within the cortical bone. (From Nanci A: Ten Cate's Oral Histology, ed 7, Mosby, St Louis, 2008.)

Cribriform plate is more mineralized – on X-ray has higher density – **lamina dura**



Copyright © 2003, Mosby, Inc., All rights reserved.

In teeth of primary dentition and young secondary the **lamina dura** is flat, later has wavy structure

Cancellous / Spongy bone

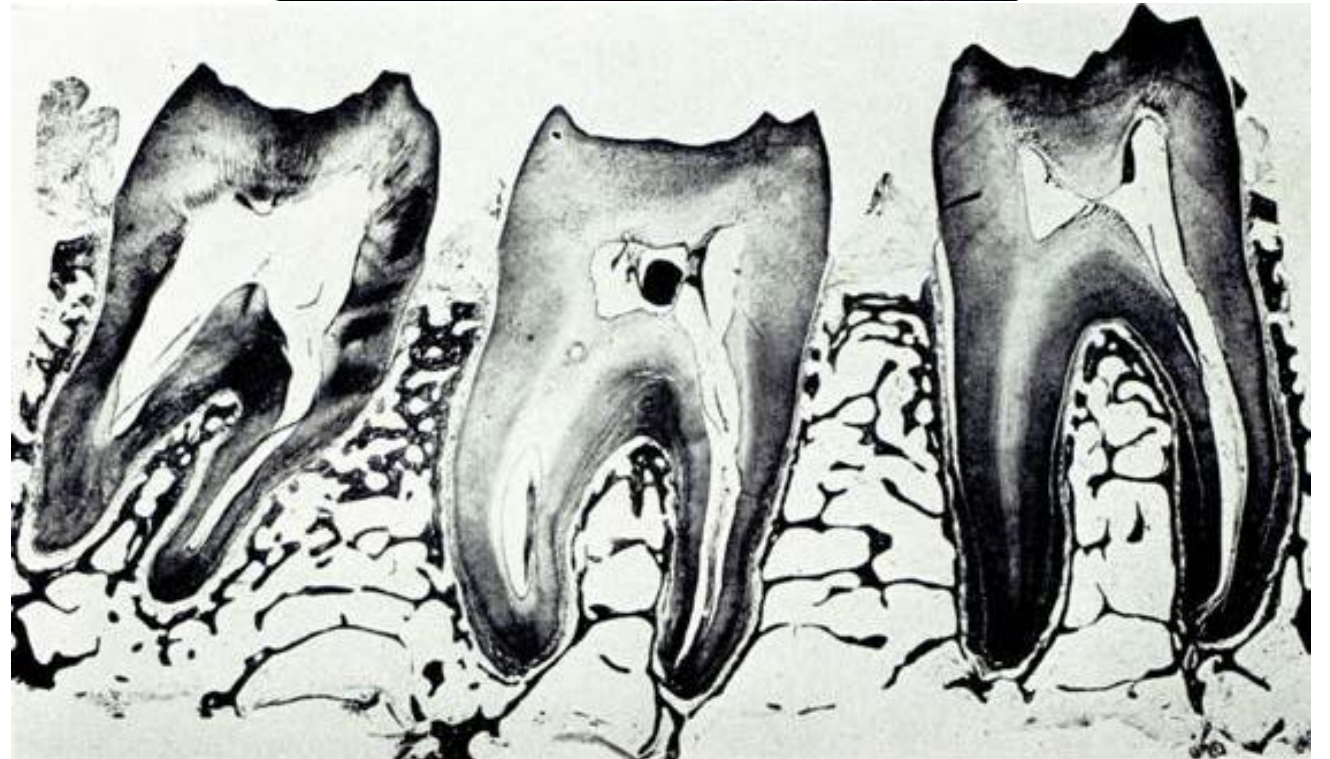
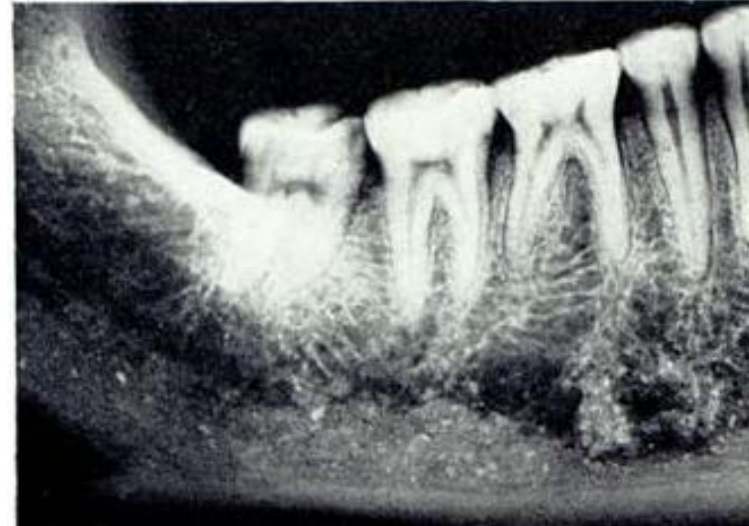Trabeculae - filling between the plates, high variability in the arrangement of the trabeculae (mostly horizontal direction)

Located between plates and in interdental and interradicular septae

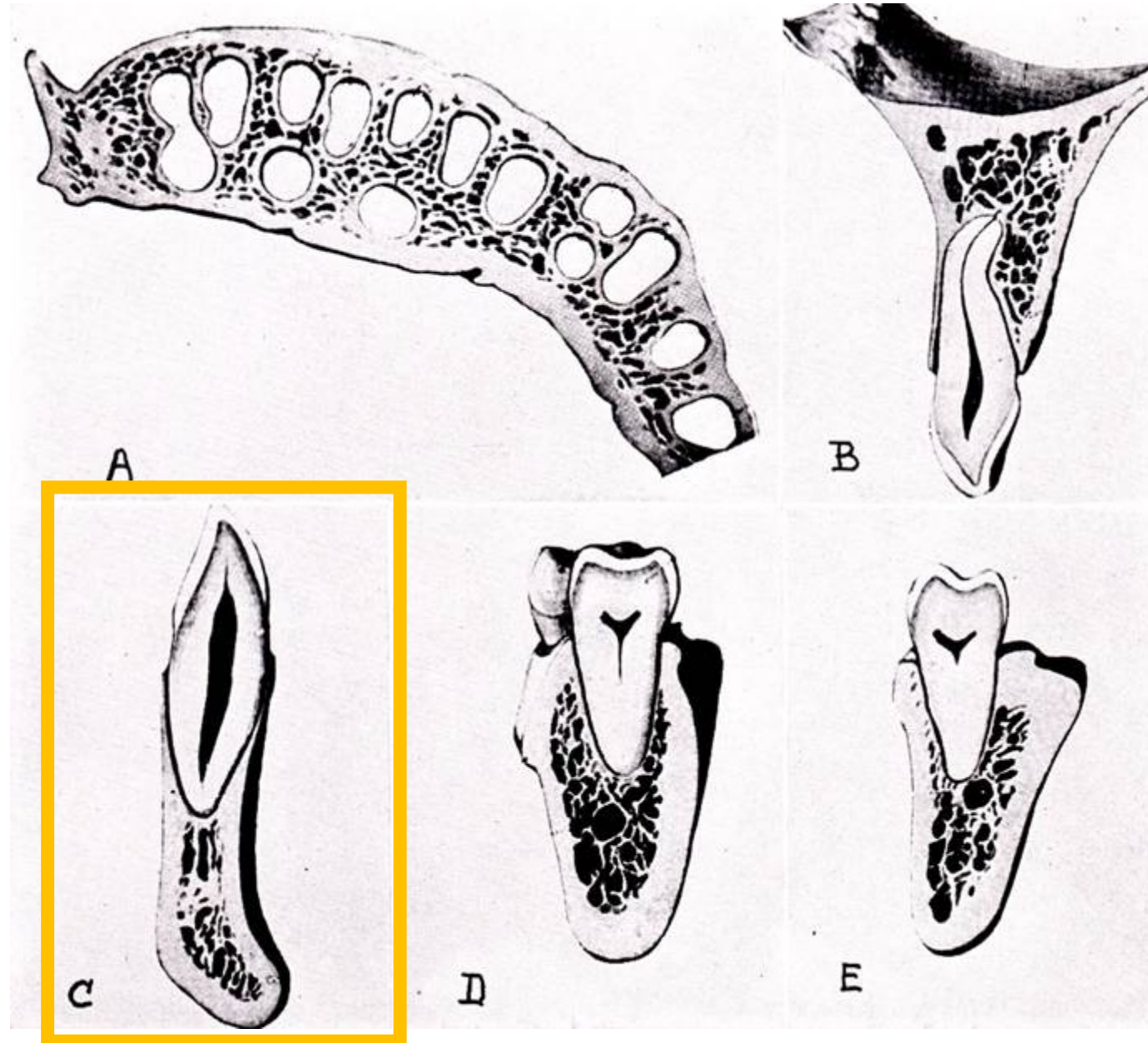
High variability in the arrangement of trabeculae

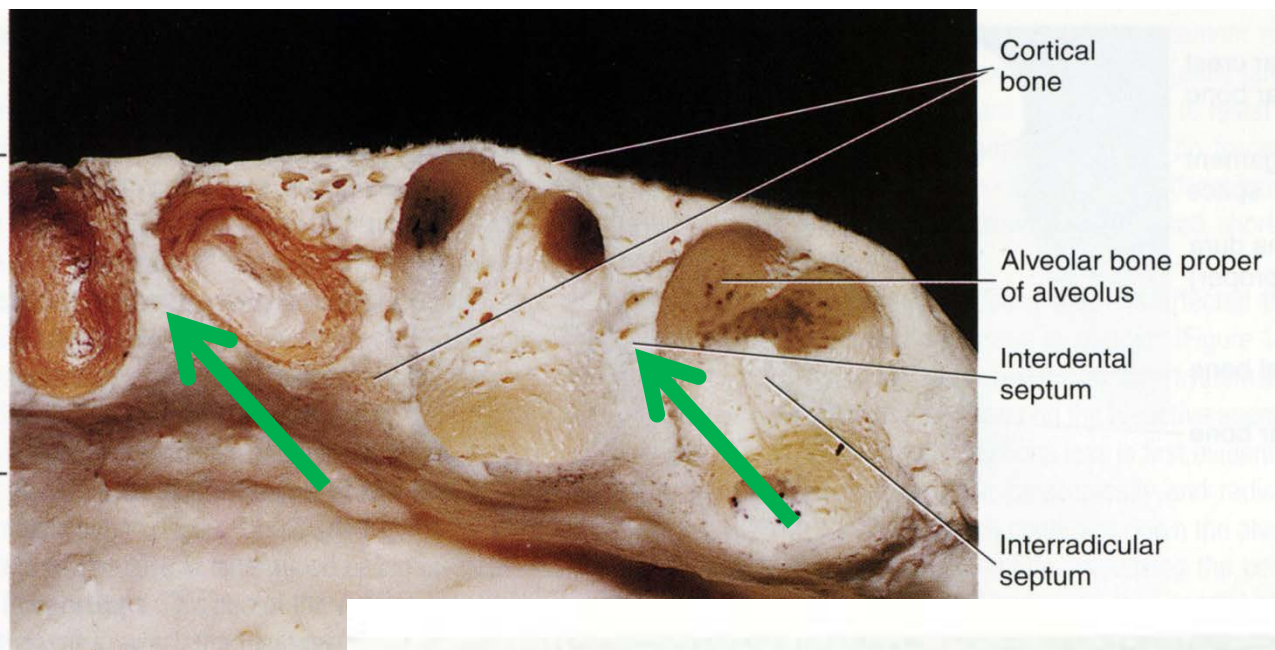
Horizontal course

Between the trabeculae is a hematopoietic bone marrow



In the area of maxillary and mandibular incisors: both lamina oralis and vestibularis fuse with the cribriform plate



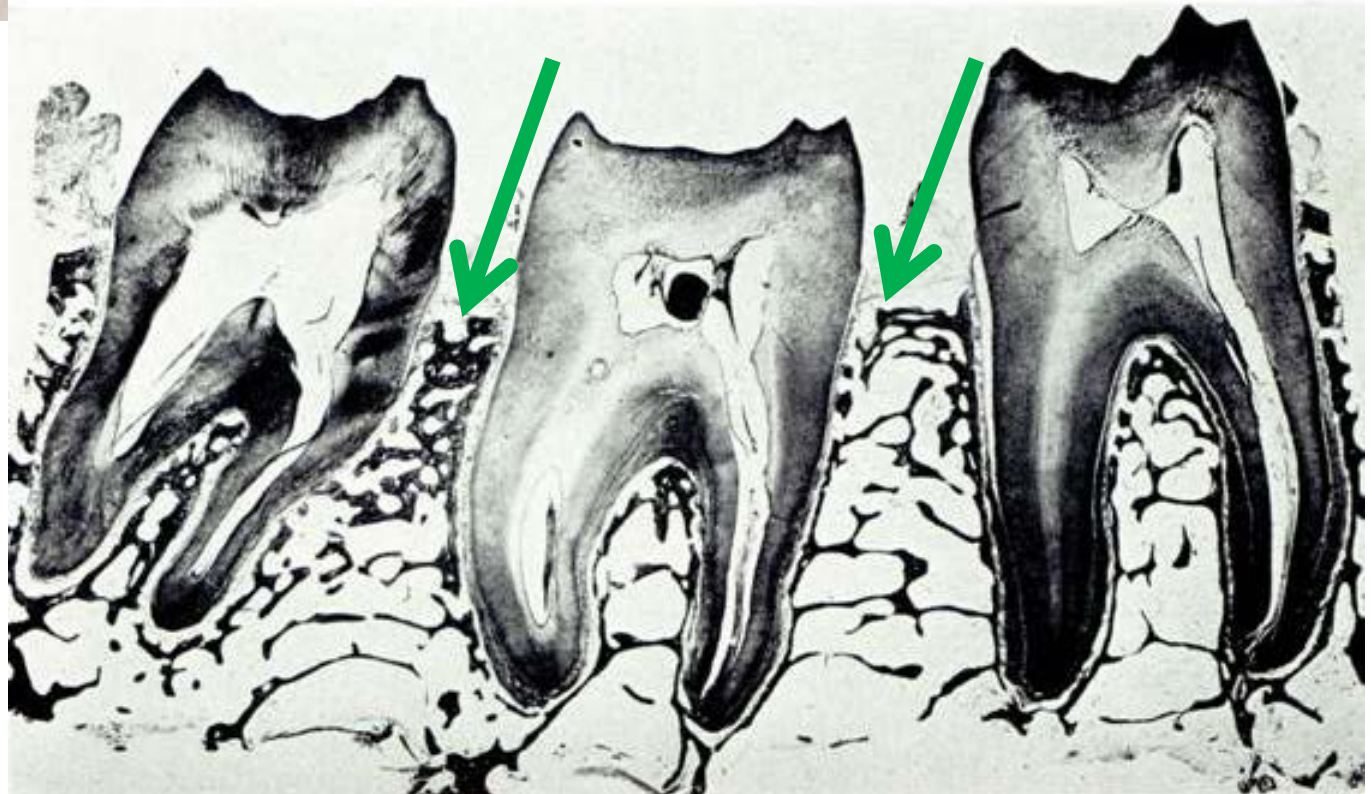


Different alveoli separates:

Interalveolar septae = septae interdentalia

Perpendicularly oriented partitions formed by the fusion of mesial and distal parts of cribriform plates of adjacent alveoli

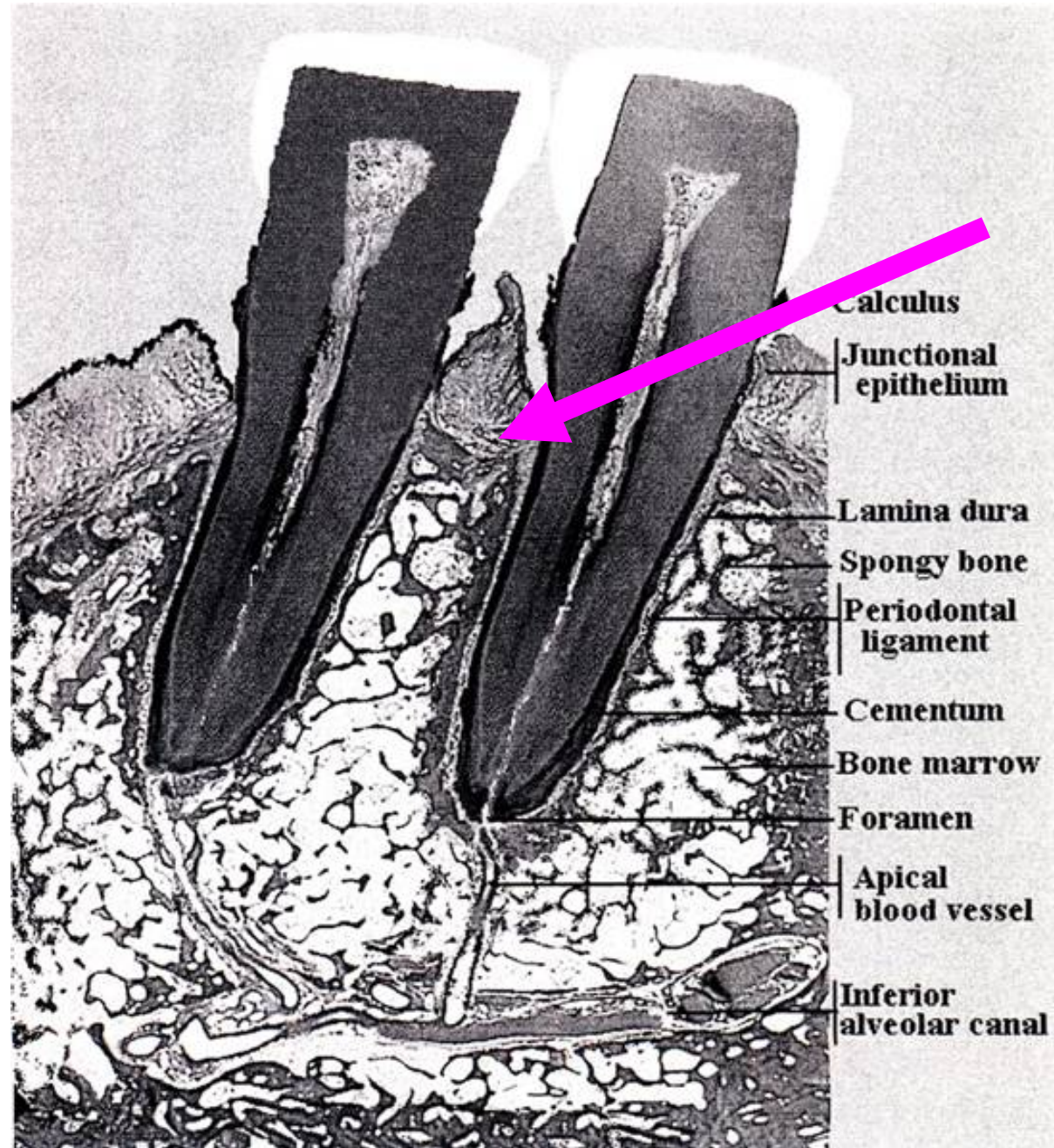
The ridges of the interdental septae are usually rounded and reach the CEJ level



Transseptal fibres

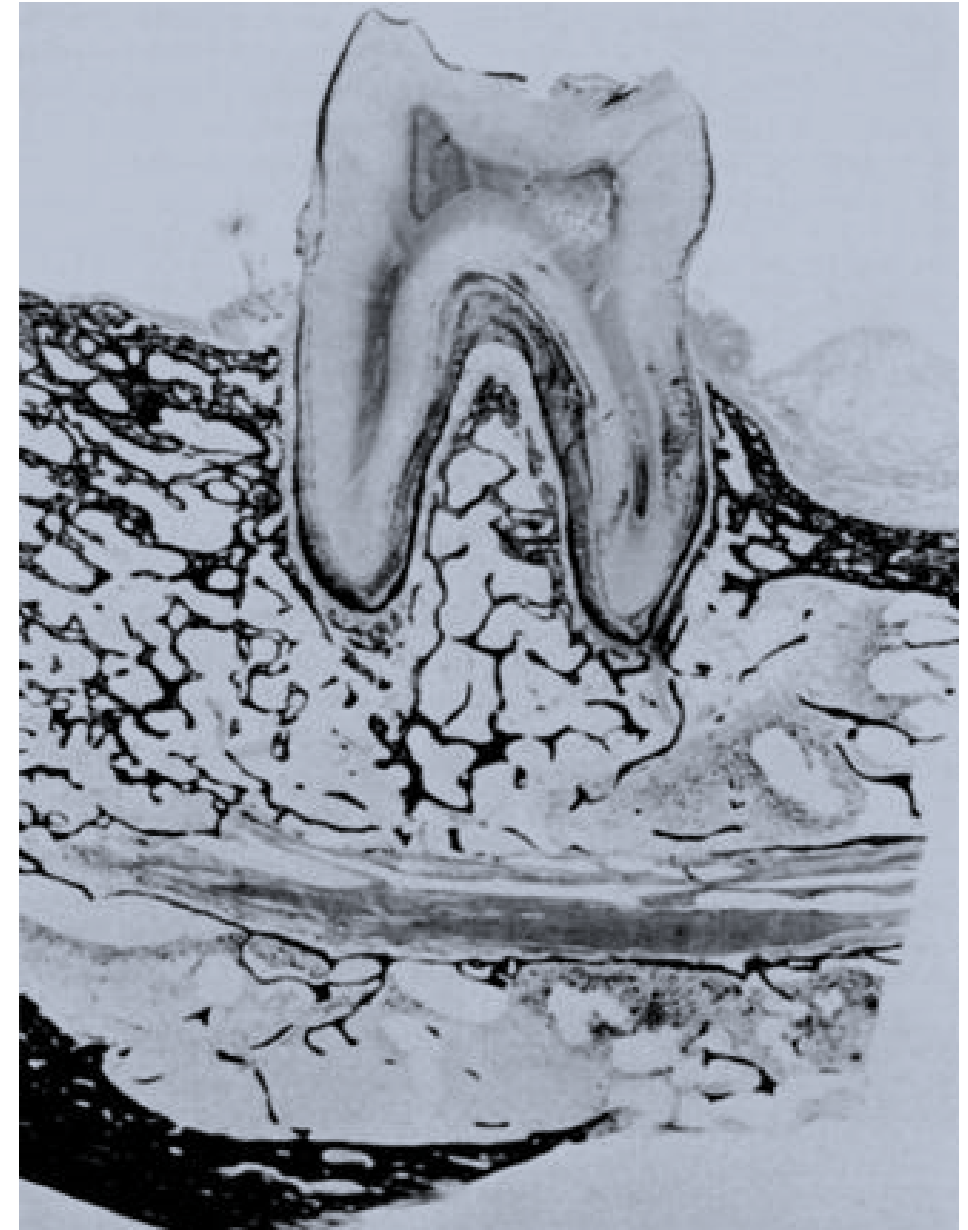
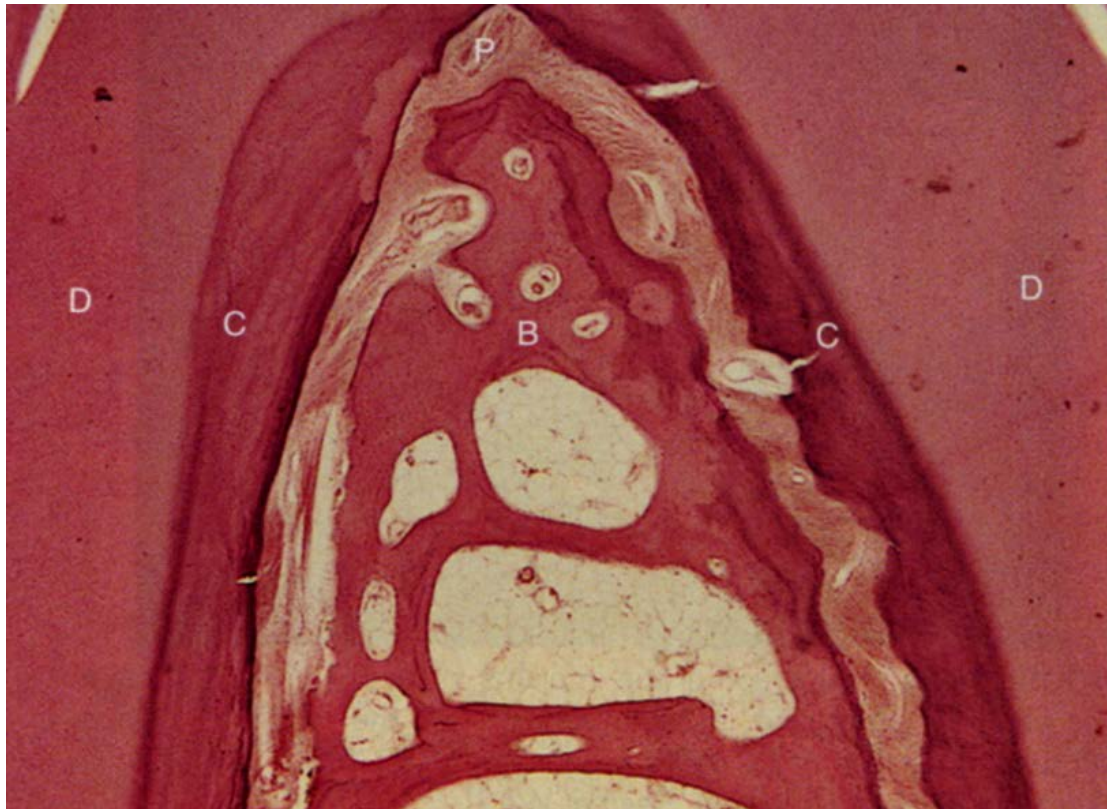Above interdental septae are **transseptal fibres vlákná** (lig. interdentalia) – forms the shape of crests

When teeth are inclined the pressure of fibres causes the tilt of crest in the direction of inclination (secondarily, the septum may be shortened)

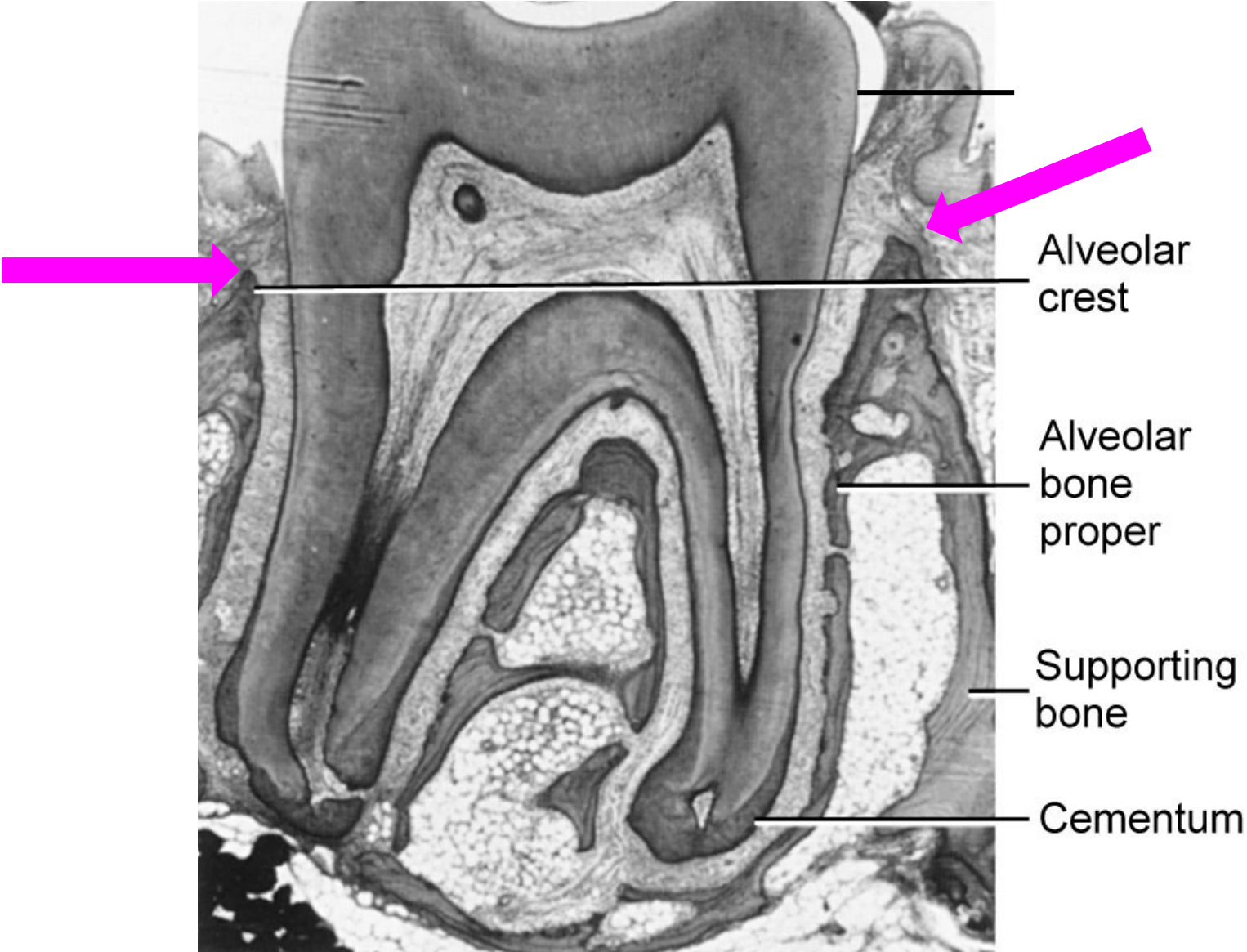


Septa interradicularia

Present only in teeth with more roots
Cribriform plate together with trabecules of cancellous bone forms interradicular septs - **septa interradicularia**



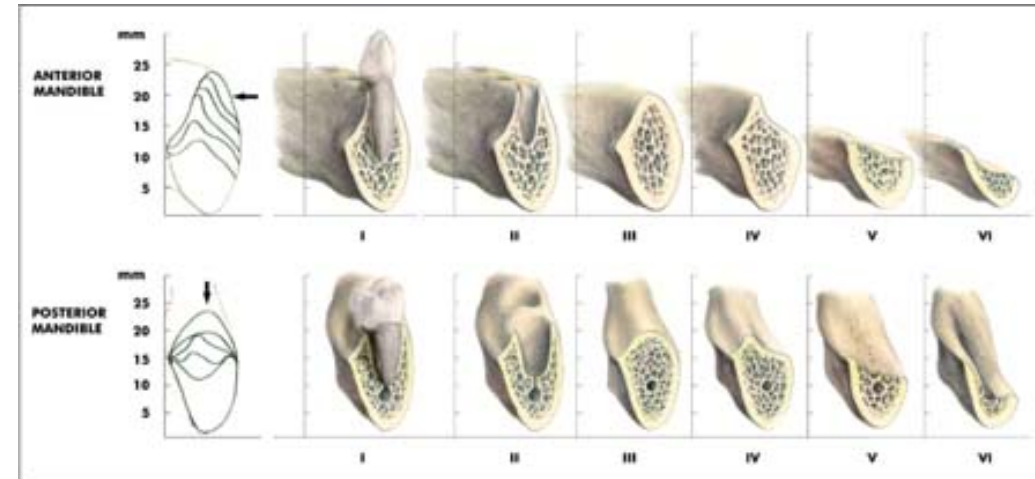
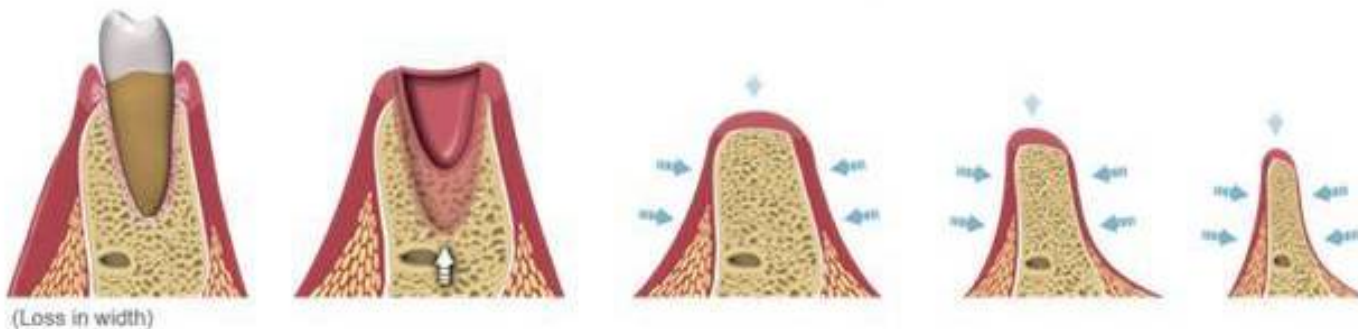
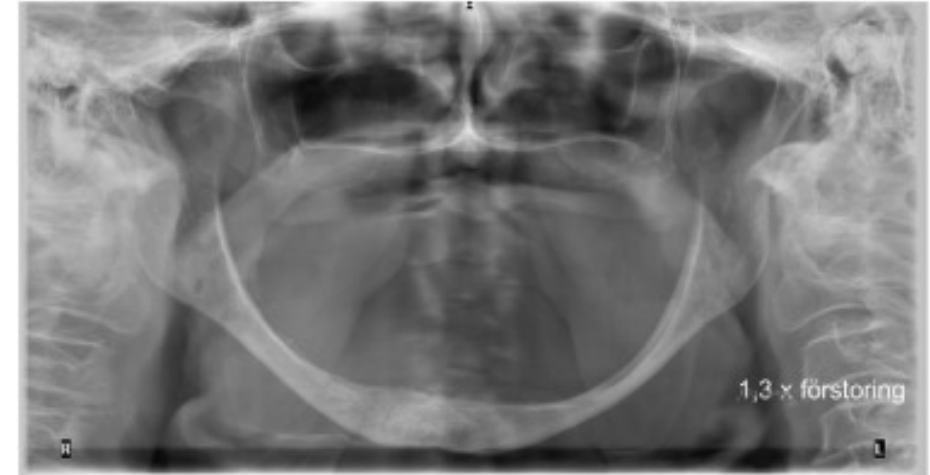Edge of tooth alveolus – Alveolar crest – is the place where the coronal end of cribriform plate meets lamina vestibularis or lamina oralis



Clinical relevance of alveoli plasticity

The structure and arrangement of the alveolar ridge is affected by a number of factors such as:

- **Overall nutritional status**
- **Hormones (hyper-, hypo- production)**
- **Masticatory forces during food processing**
- **Growth of dental roots and tooth eruption**
- **Infection**
- **Tooth extraction**



Clinical relevance of alveoli plasticity

1. Because of different effect of long-lasting tension and pressure on the bone remodeling the bone structure can be achieved

Long-lasting tension – tooth formation (**tension zone**)

Long-lasting pressure – tooth resorbtion (**pressure zone**)

This is widely used in orthodontics

2. When the bone is not adequately loaded for a long time, structural changes occur

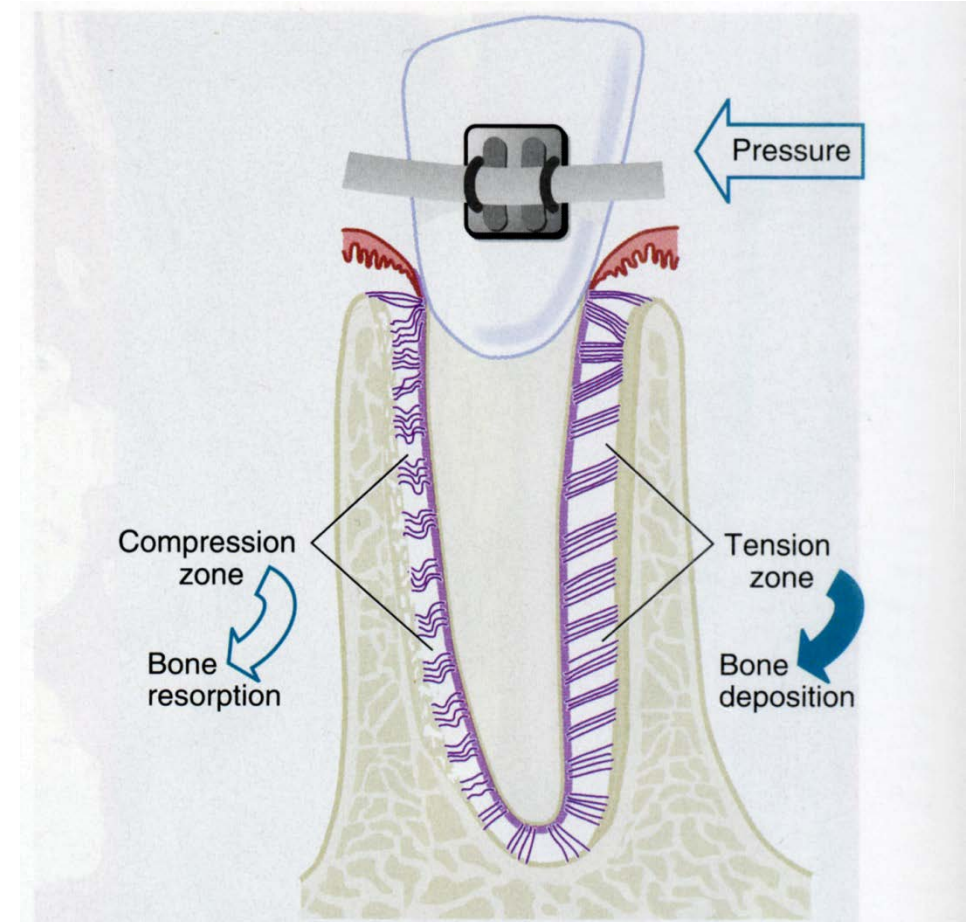
Applies for both the upper and lower jaw

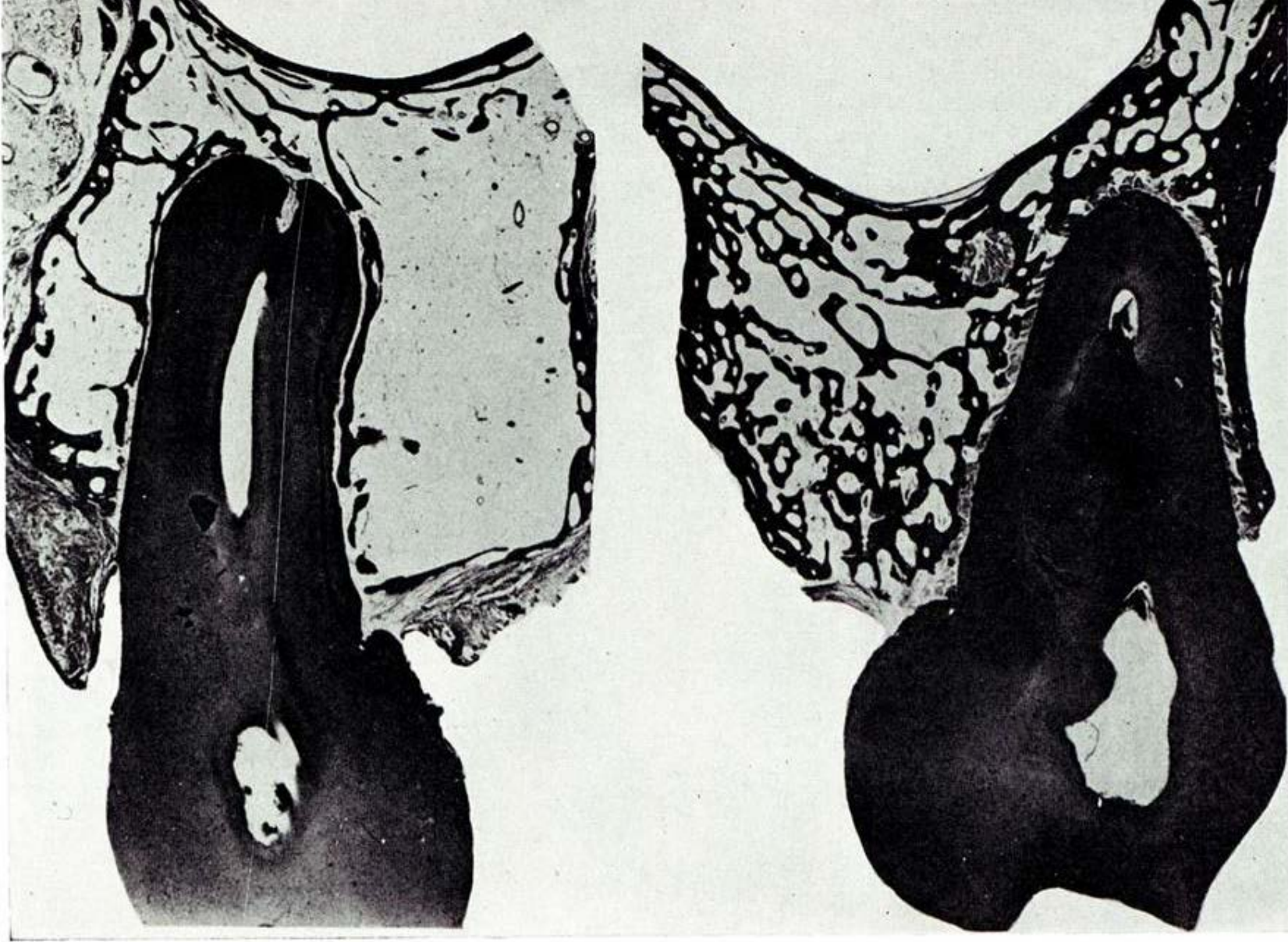
REMEMBER:

When antagonists are lost – if this condition last for a longer period of time (in the order of months) - there are changes in the alveolus and periodontal ligaments

2 conclusions:

- Carefully indicate teeth extractions
- Fill missing or extracted teeth



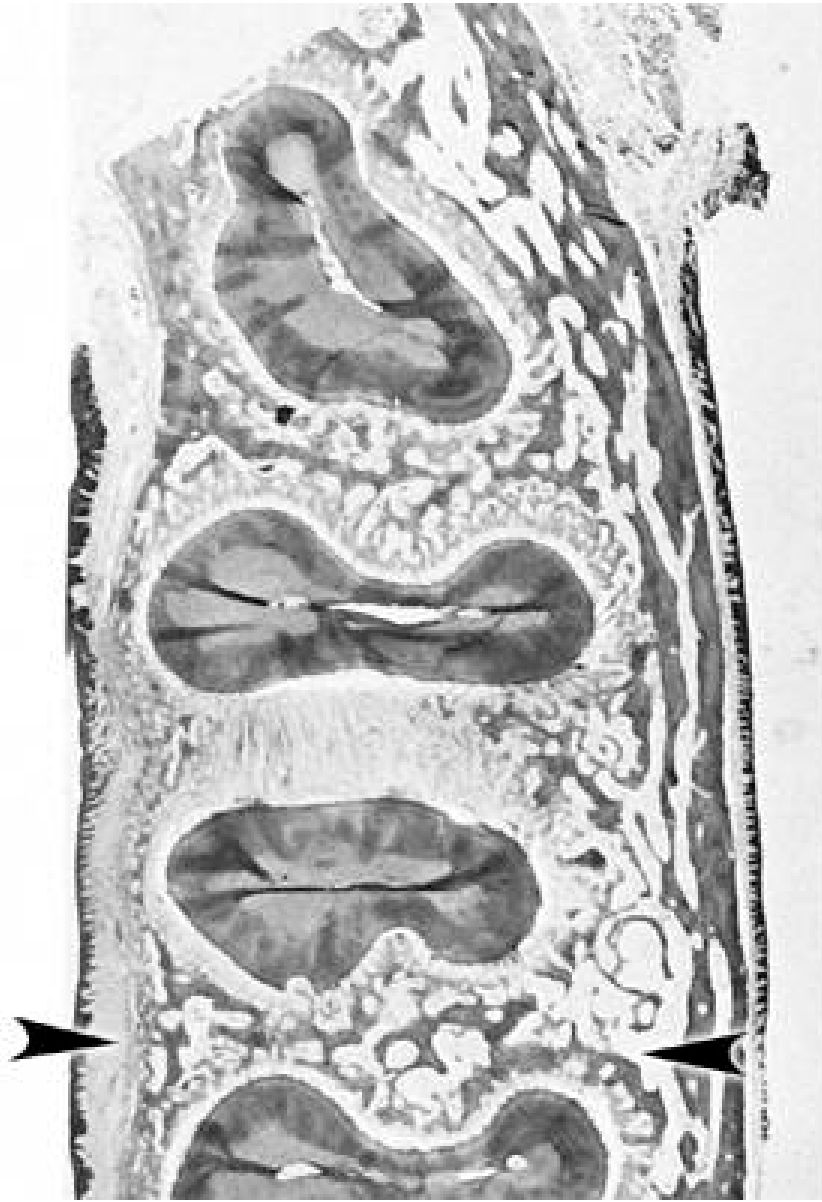


A

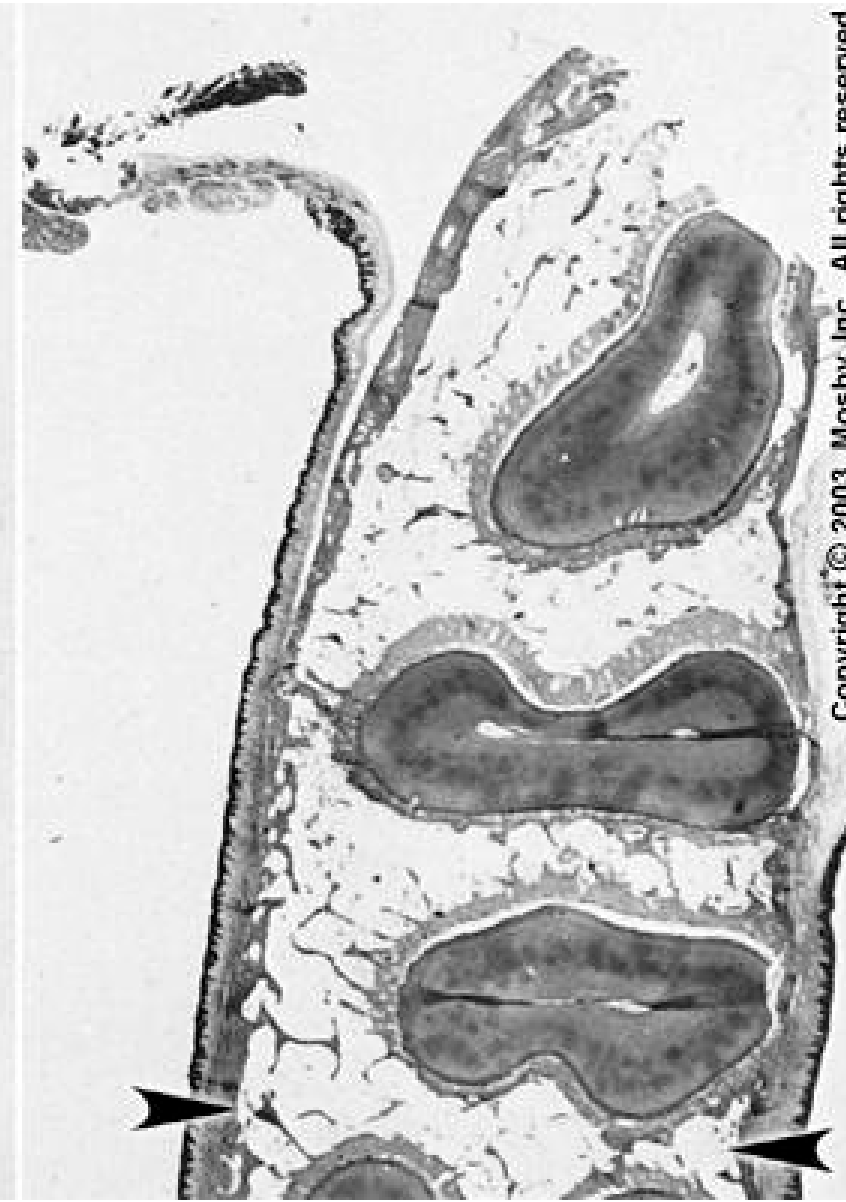B

A – changes after removal of antagonizing teeth

B – control



normal loading



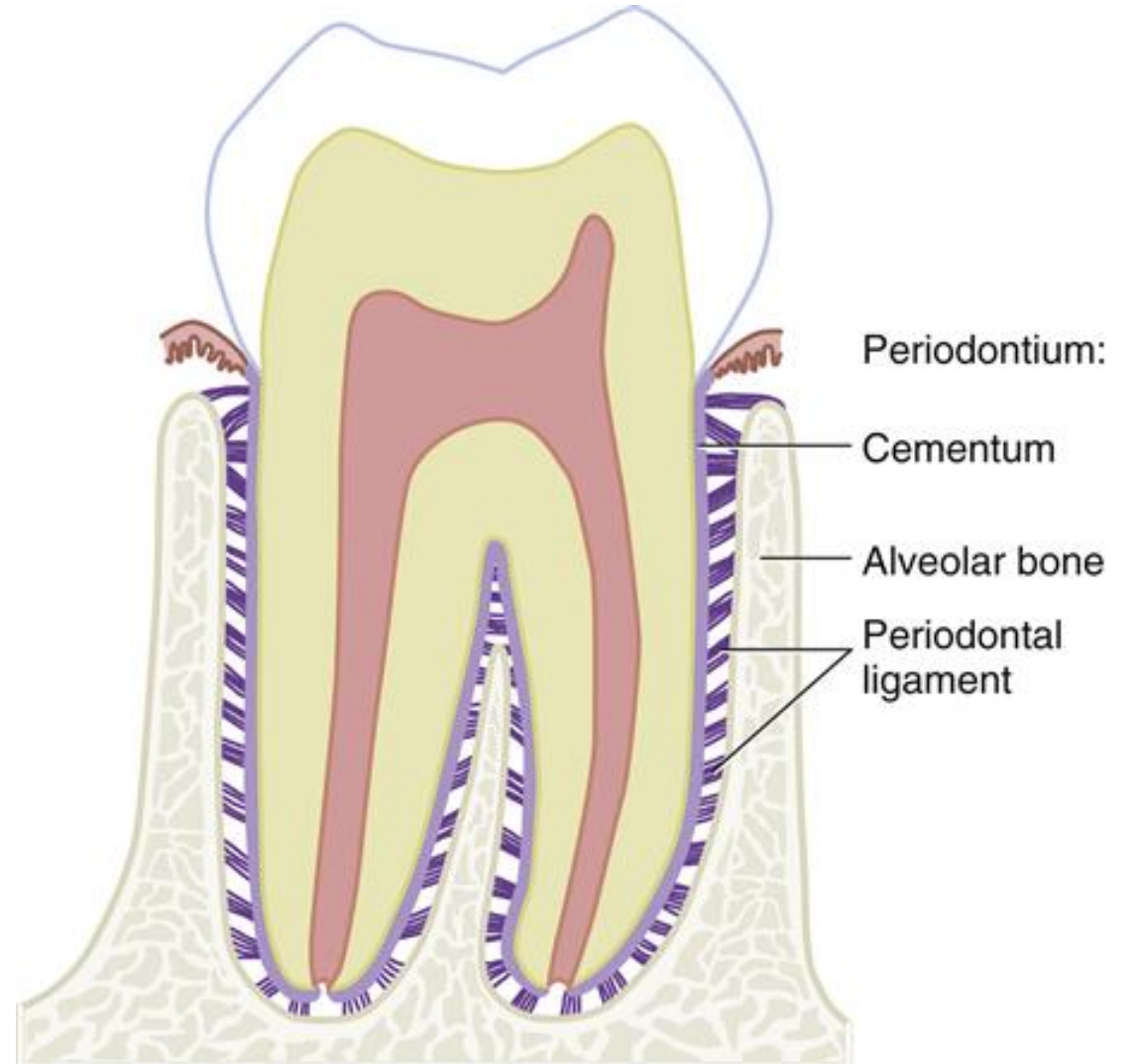
changes from inactivity

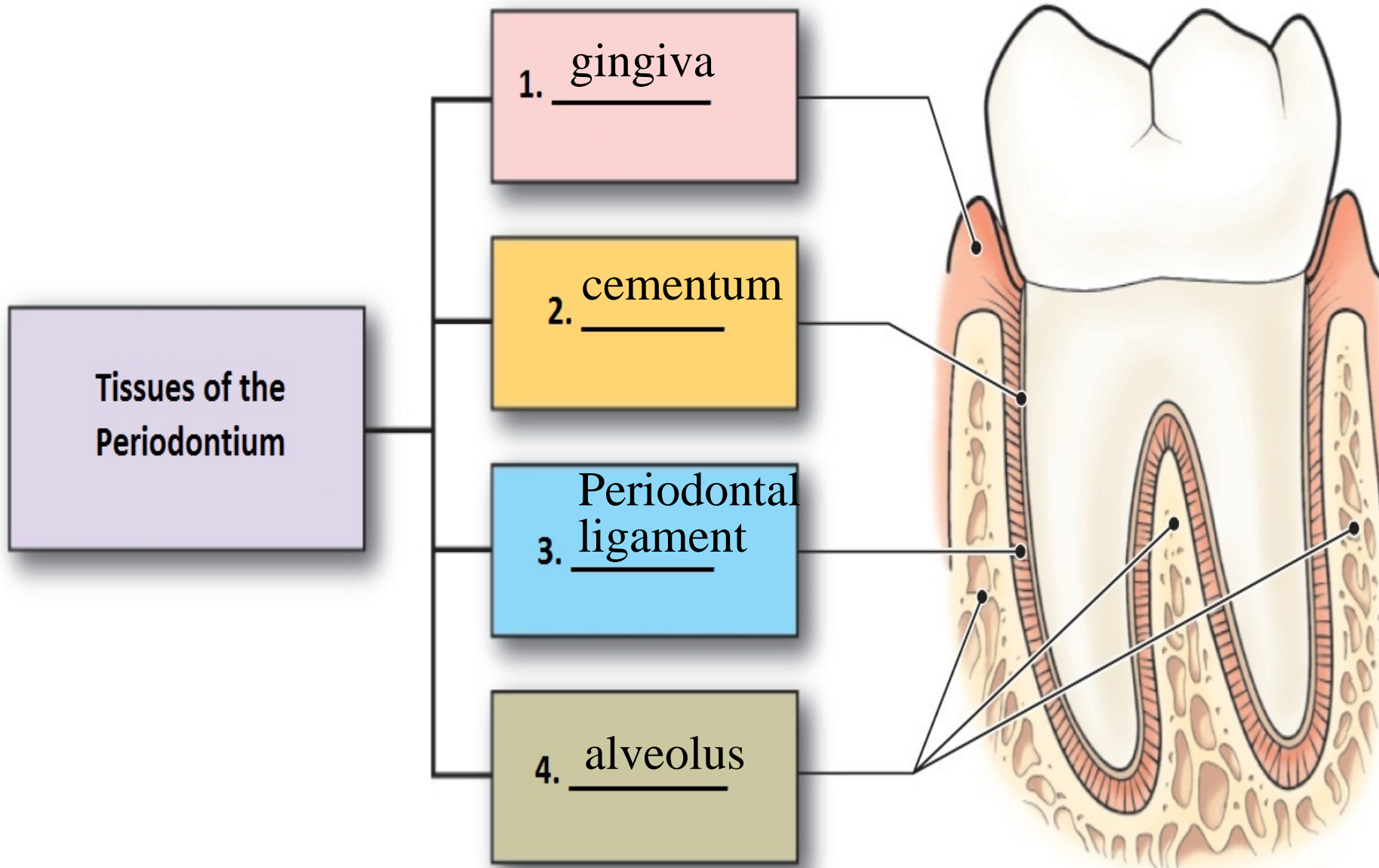
**Microscopic structure of the periodontium,
its function and clinical significance**

Periodontium (in general meaning)

Consists of:

- **Alveolus**
- **Periodontal ligament** – dense collagenous tissue which ensure tooth stability and its attachment inside the alveolus
- **Cementum** – covering roots
- **Gingiva**





Periodontal ligaments

Hold teeth inside the alveolus – Balance and compensate the forces acting during mastication (**theodontn dentition**)

Transforms compressive forces during chewing into tensile, which the dental bed better resists and is also better adapted to

Fills the space between the cribriform plate of dental socket and root (cementum)

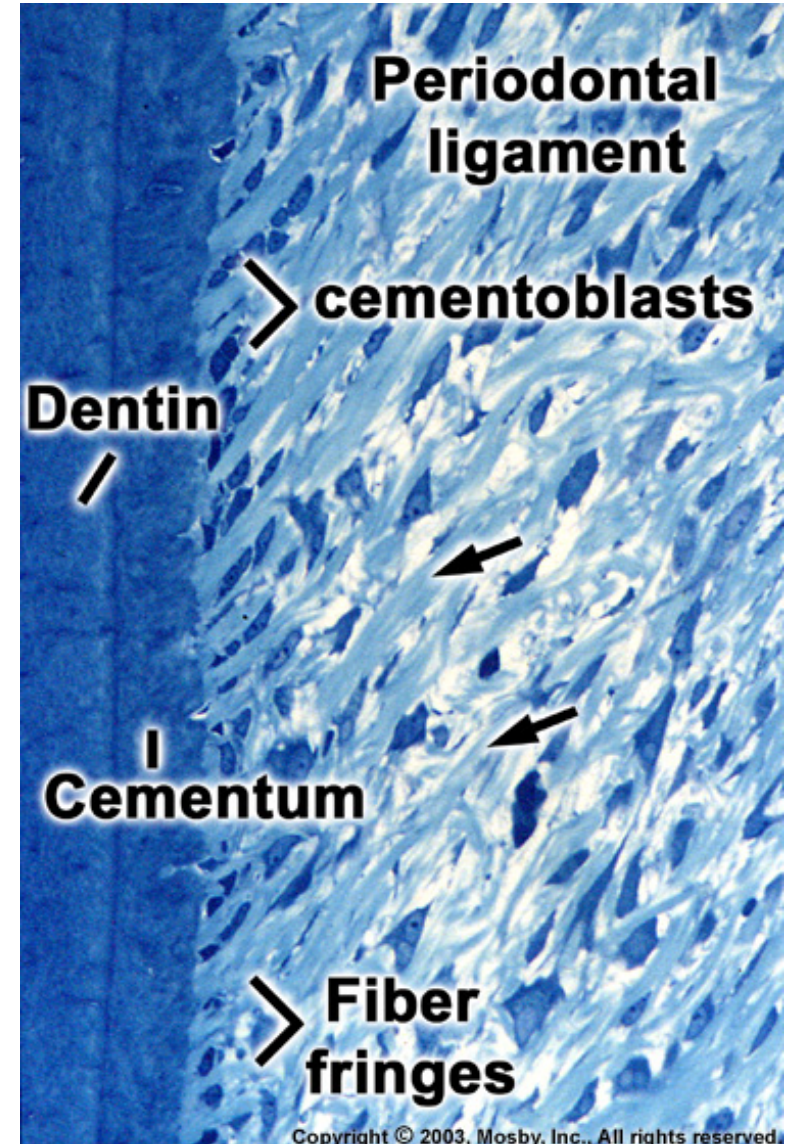
Dense collagenous tissue with higher amount of ECM (extracellular matrix)

Periodontium thickness - 0.18 - 1.0 mm, the thinnest in the middle part of the root

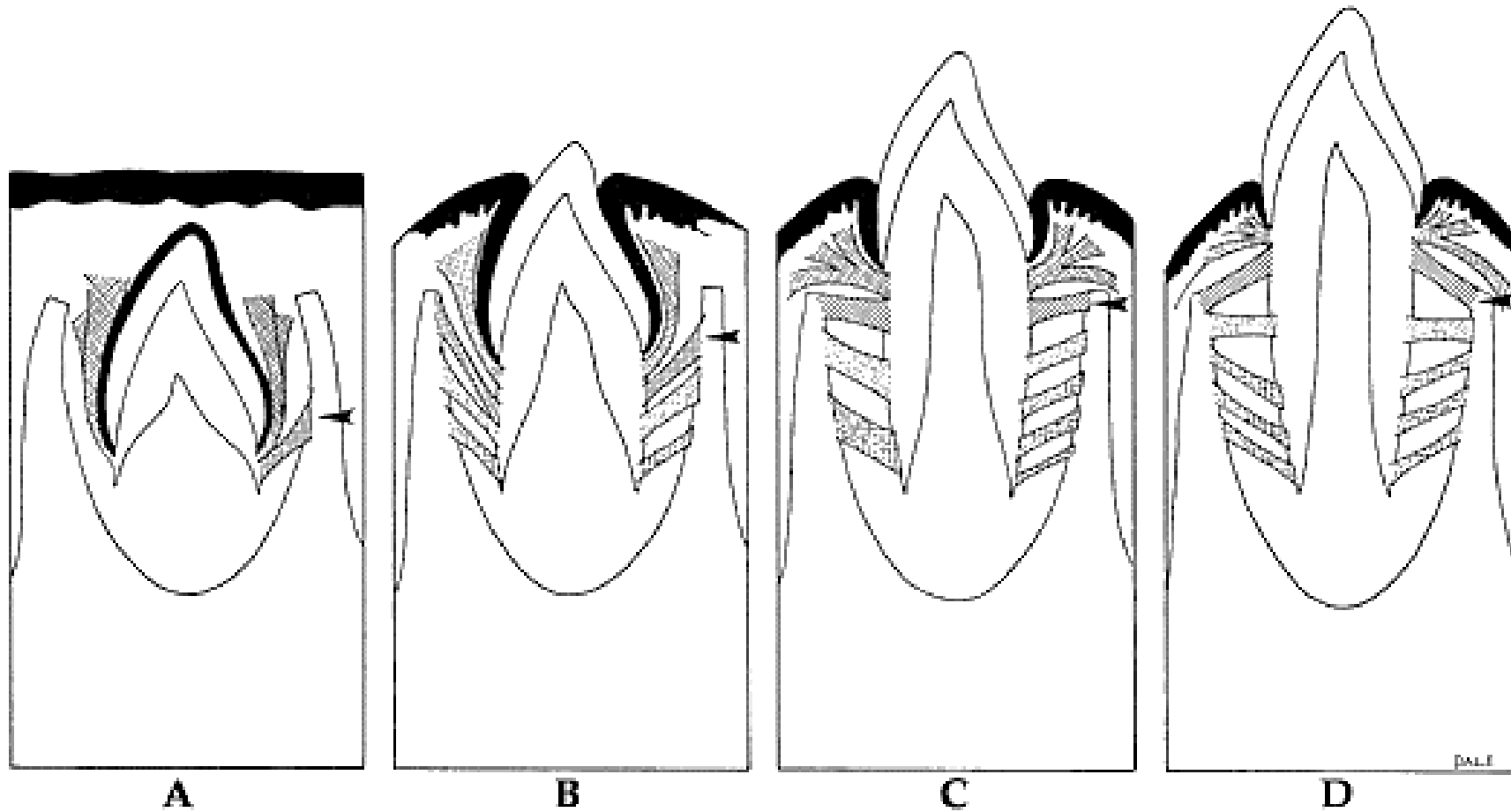
Collagenous fibers - fiber bundles - periodontal ligaments (ligaments)

Ends anchored in dental cementum and lamellar bone of cribriform plate (as Sharpey fibers)

They are of different thicknesses and have a wavy course



Development



Microscopic structure

Cellular: **Fibroblasts a Fibrocytes**

ECM:


Collagen fibres (I, III a XII)

Fast turnover

Organized into bundles

Elastic fibres

Oxytalan fibres (immature elastic fibres)

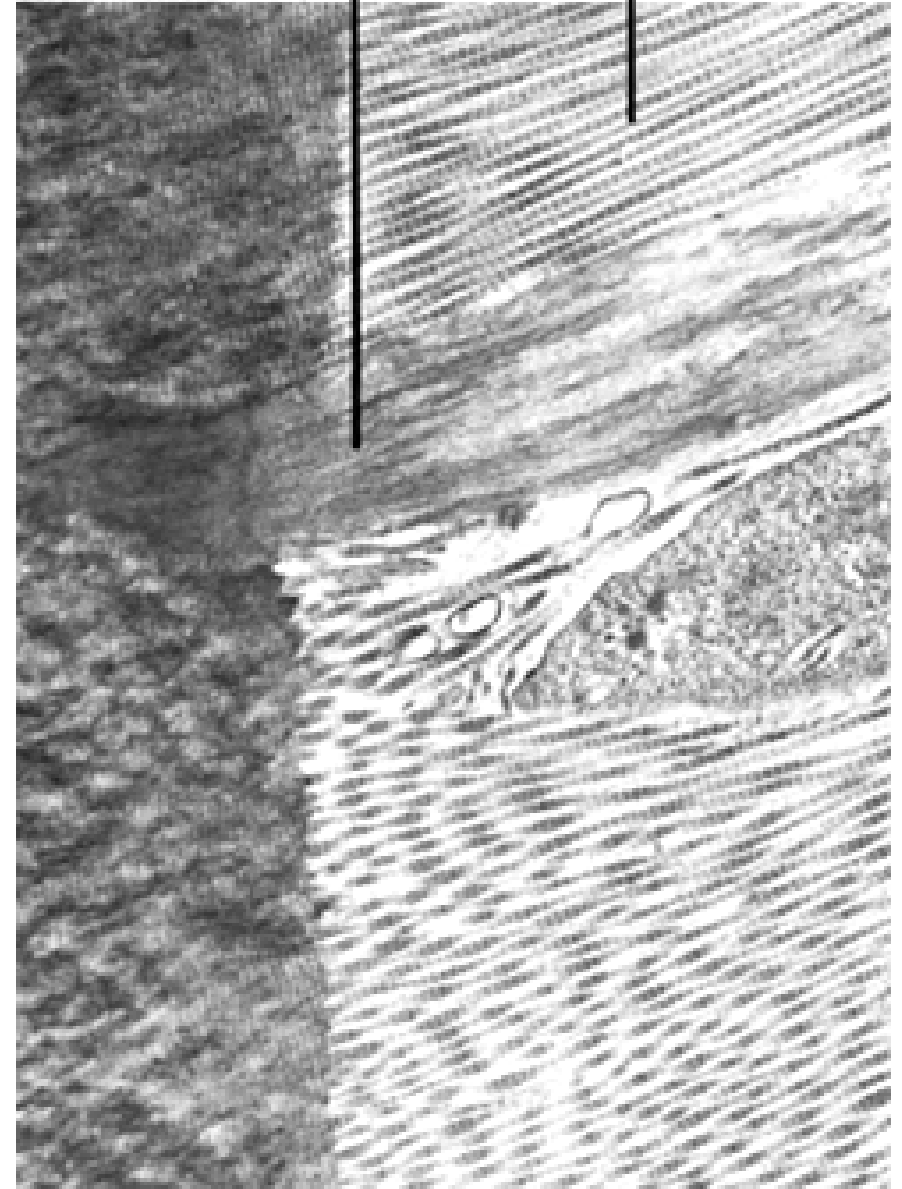


Periodontal
ligament
fibers

Oxytalan
fibers

Oxytalan

Collagen



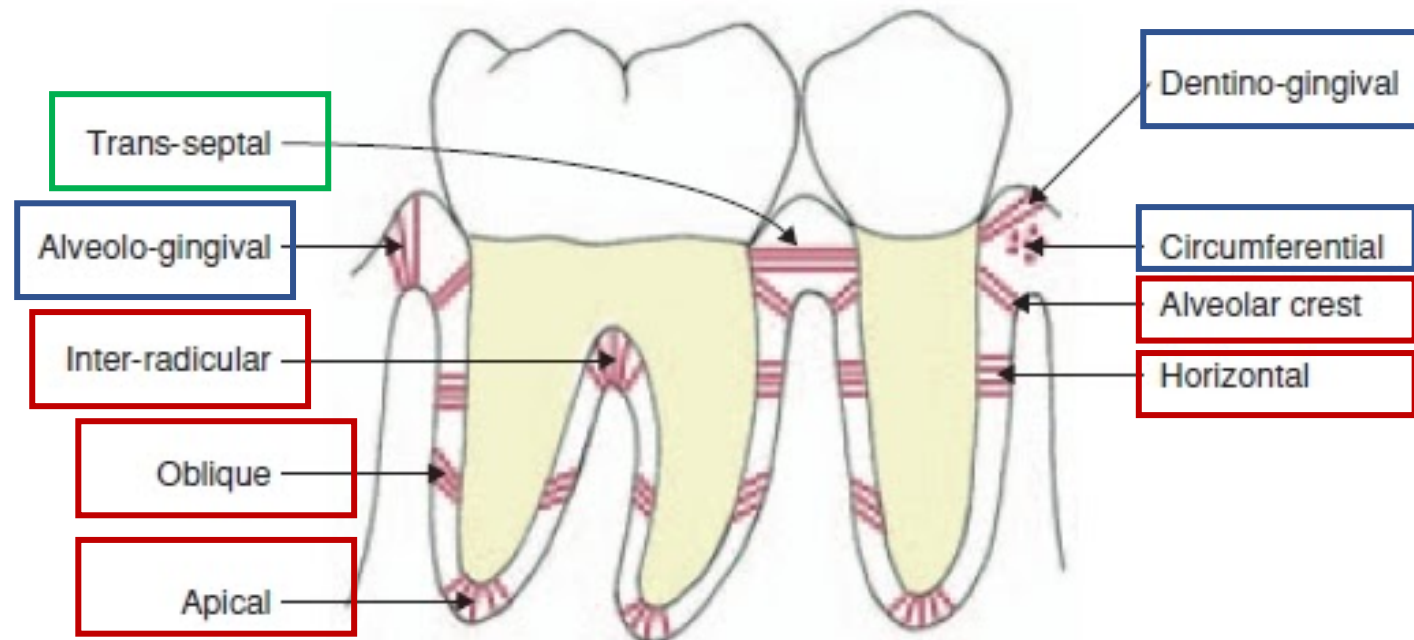
Arrangement of periodontal ligaments

3 main groups:

Gingival fibres

Transseptal (interdental) fibres

Alveolar fibres (fibrae principales)



Gingival fibres – attach the gingiva to the neck of the tooth

they are not actually part of the periodontium (they lie in the lamina propria of the gingiva)

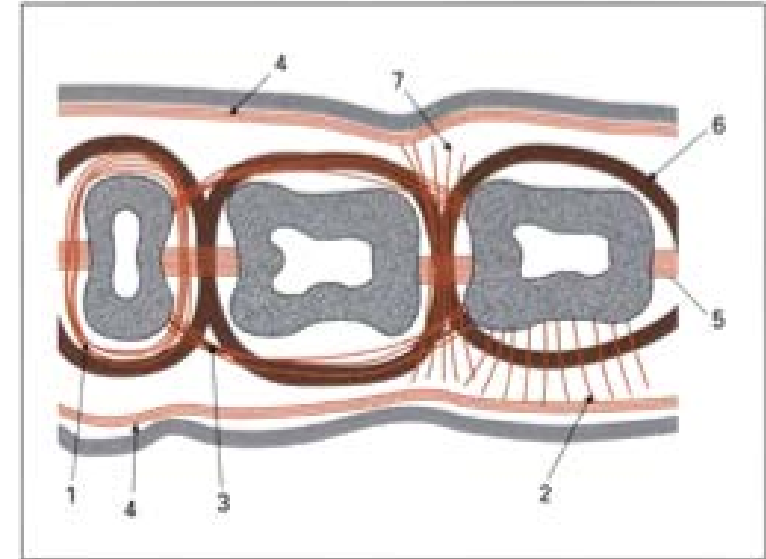
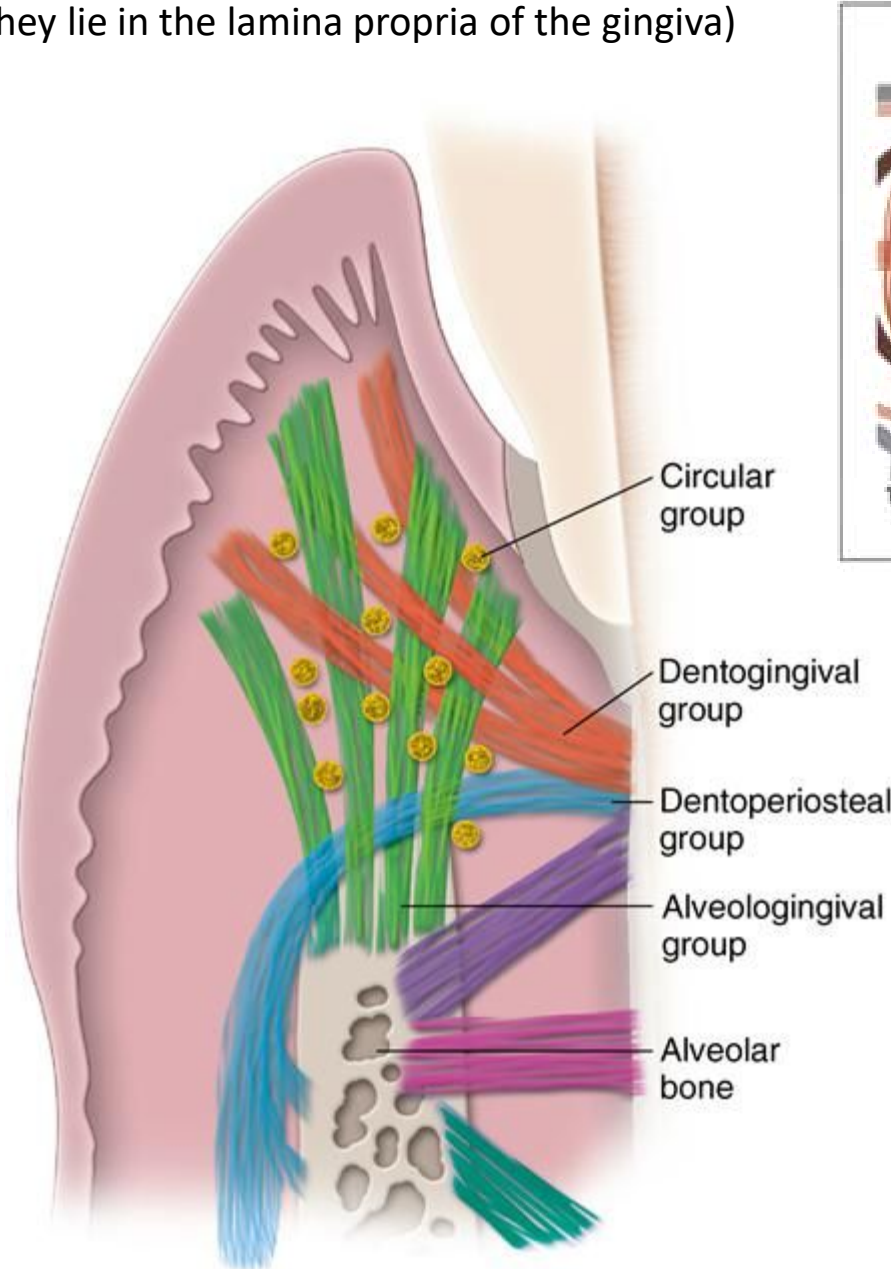
4 directions (groups):

Dentogingival – from cementum at the tooth neck to gingiva afixa and libera. Most abundant

Alveologingival - from the edge of the alveolus gingiva afixa and libera

Circular - placed in free gingiva and they surround the neck of the tooth

Dentoperiosteal - from the neck through the edge of the alveolus on the vestibular surface or lingual plate




Gingival CT fiber groups in horizontal section:

- (1) **circular fibers**
- (2) **dentogingival fibers**
- (3) **intercircular fibers**
- (4) **intergingival fibers**
- (5) **transseptal fibers**
- (6) **transgingival fibers**
- (7) **interpapillary fibers**

Dentogingival

Dentoperiosteal



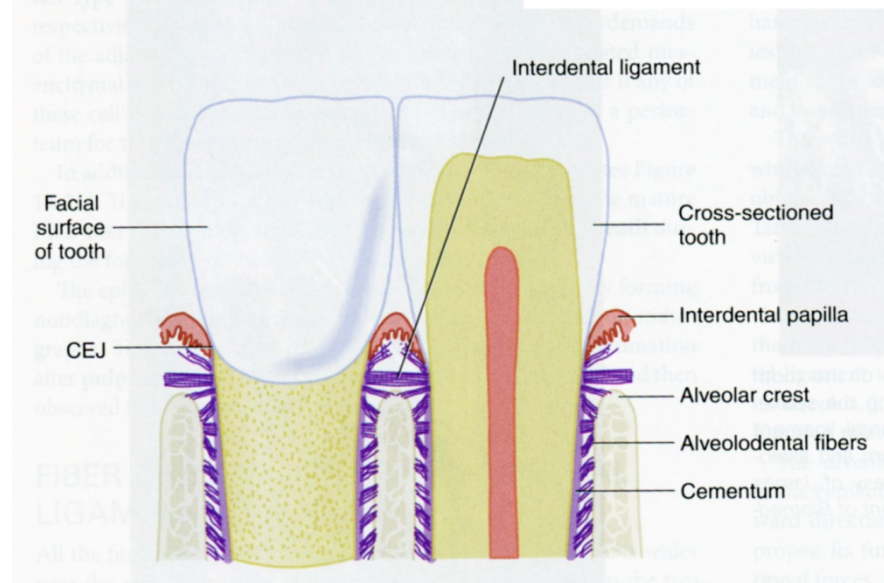
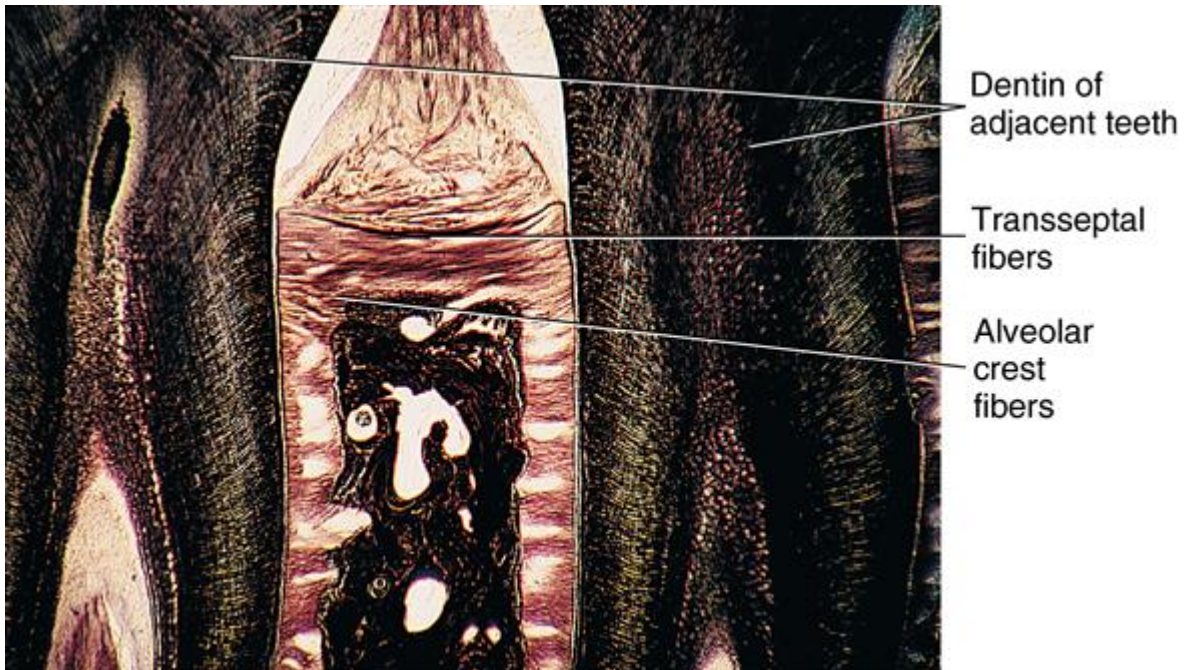
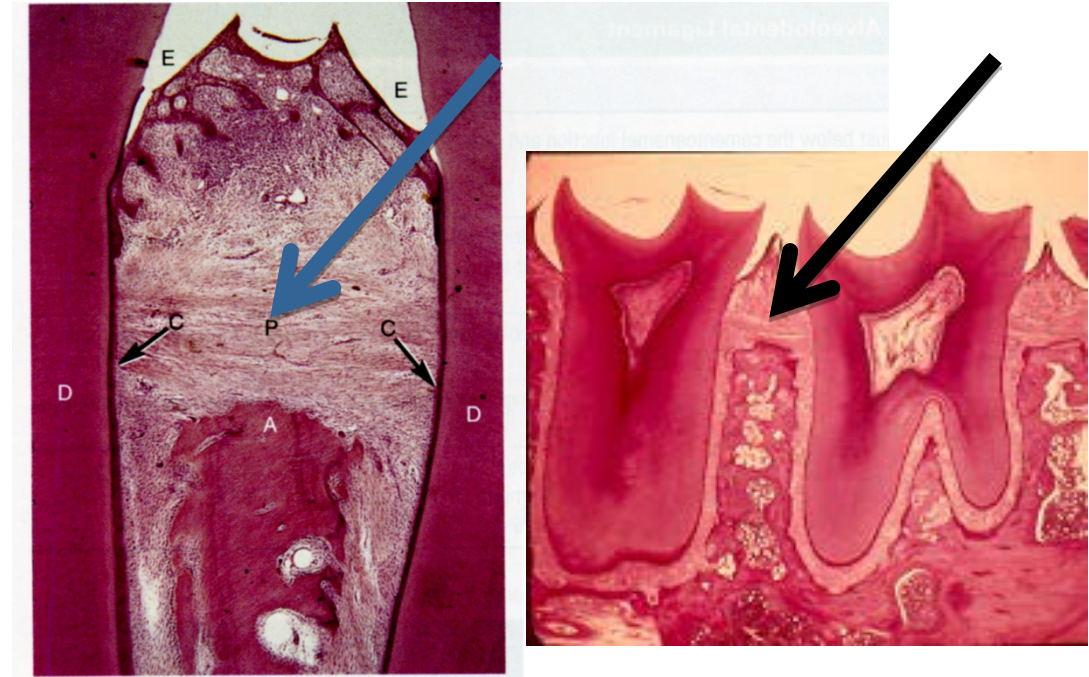
Transseptal fibres – connect necks of neighboring teeth

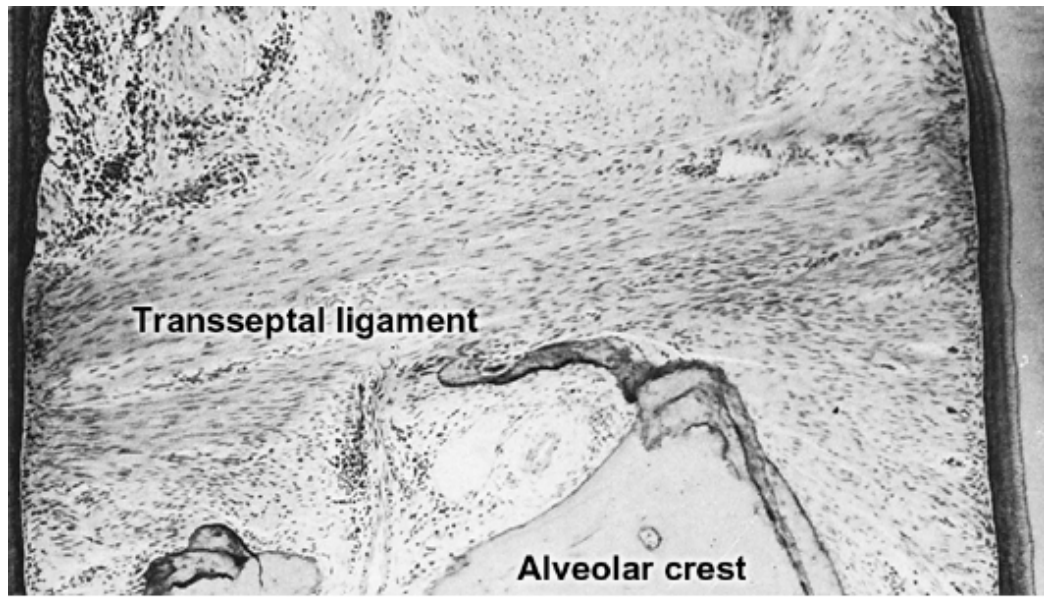
Mesiodistally above the interalveolar septa

They strengthen the linear alignment of the teeth in the arch and form the basis for interdental papillae

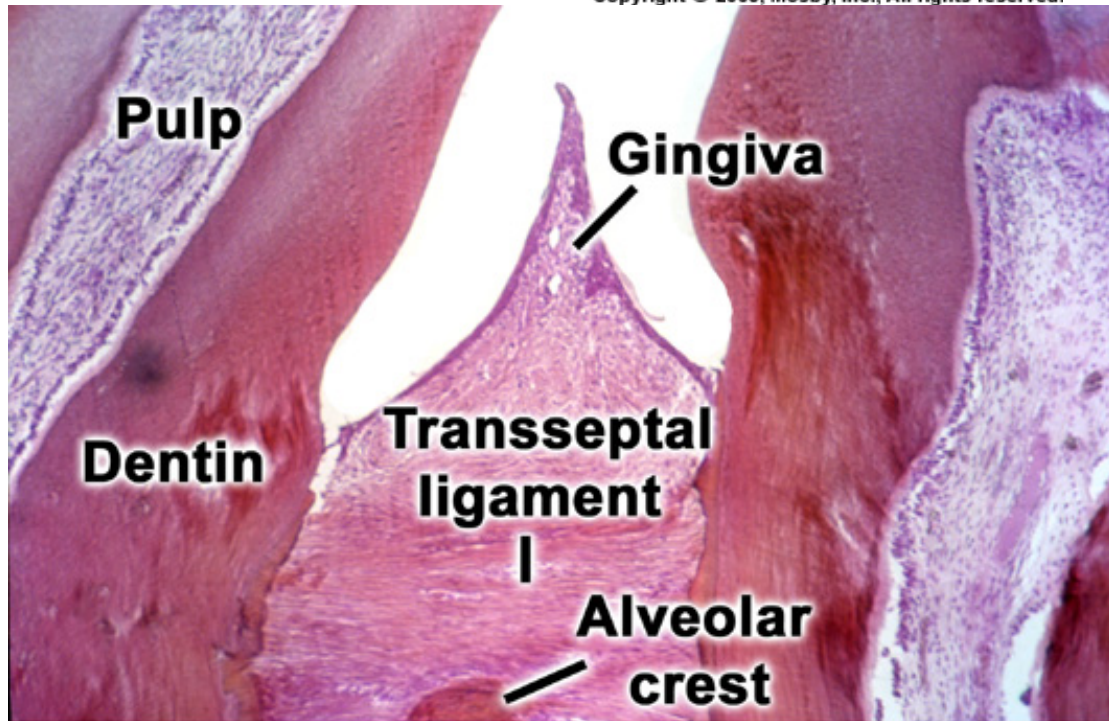
They form the shape of the ridges of the interalveolar septum

X-ray configuration (with inclination of septal tilt and depression)

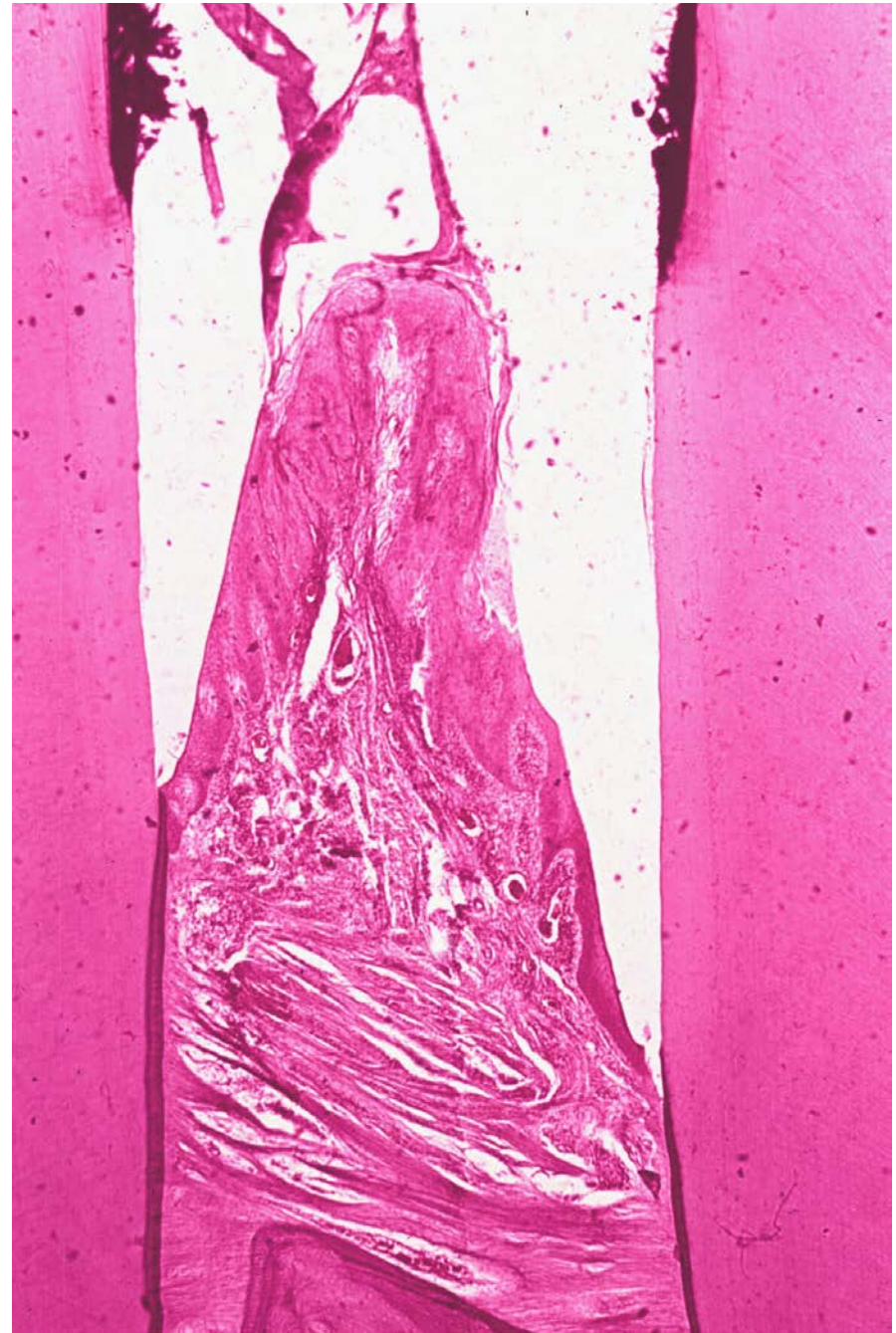




Copyright © 2003, Mosby, Inc., All rights reserved.



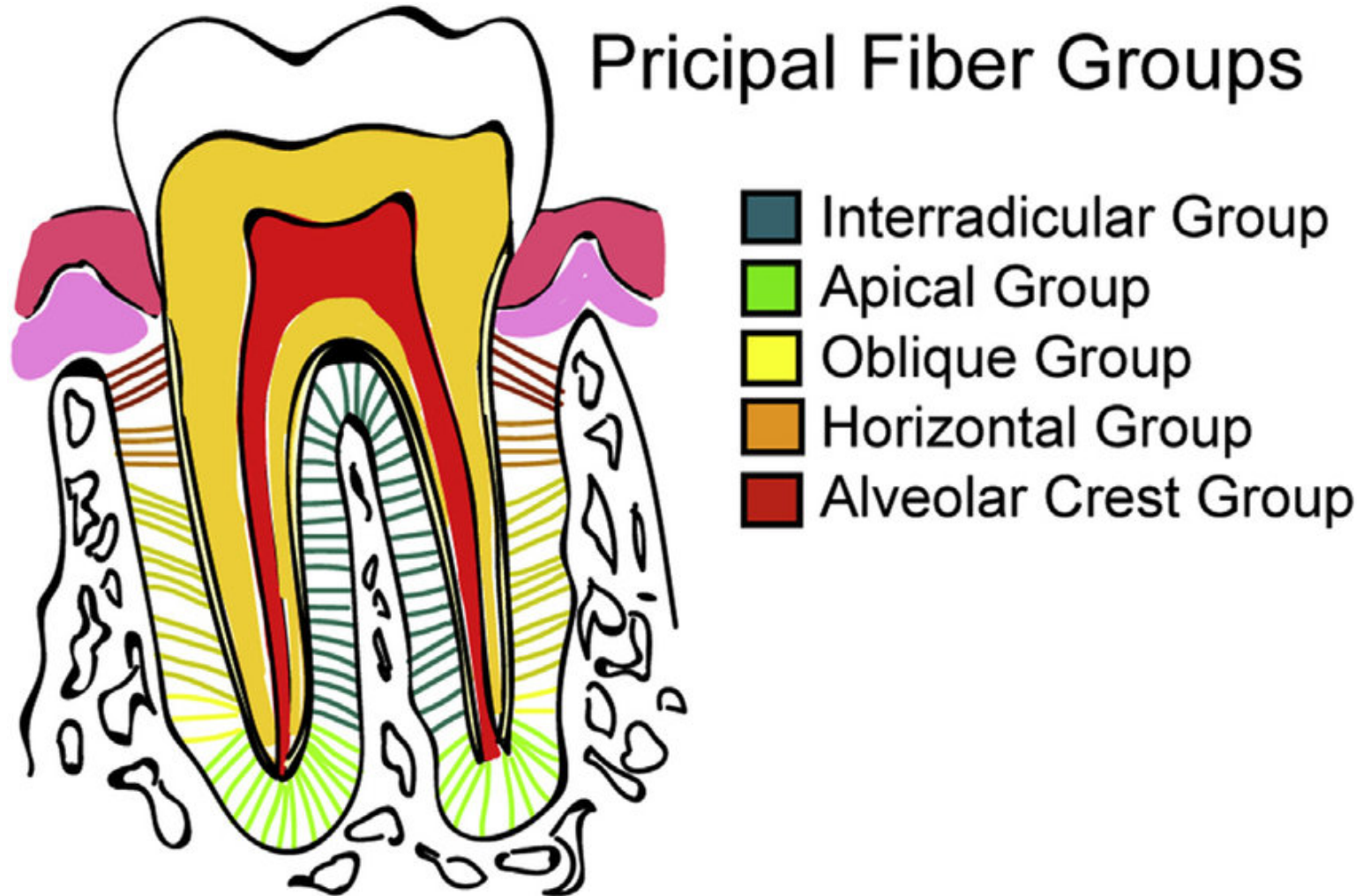
Copyright © 2003, Mosby, Inc., All rights reserved.



Alveolar fibres

Between root and cribriform plate of alveolus (*os alveolare*)

Most abundant



Alveolar fibres

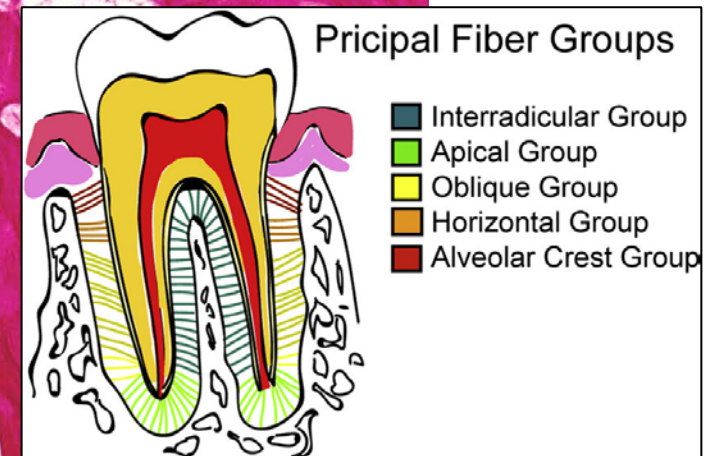
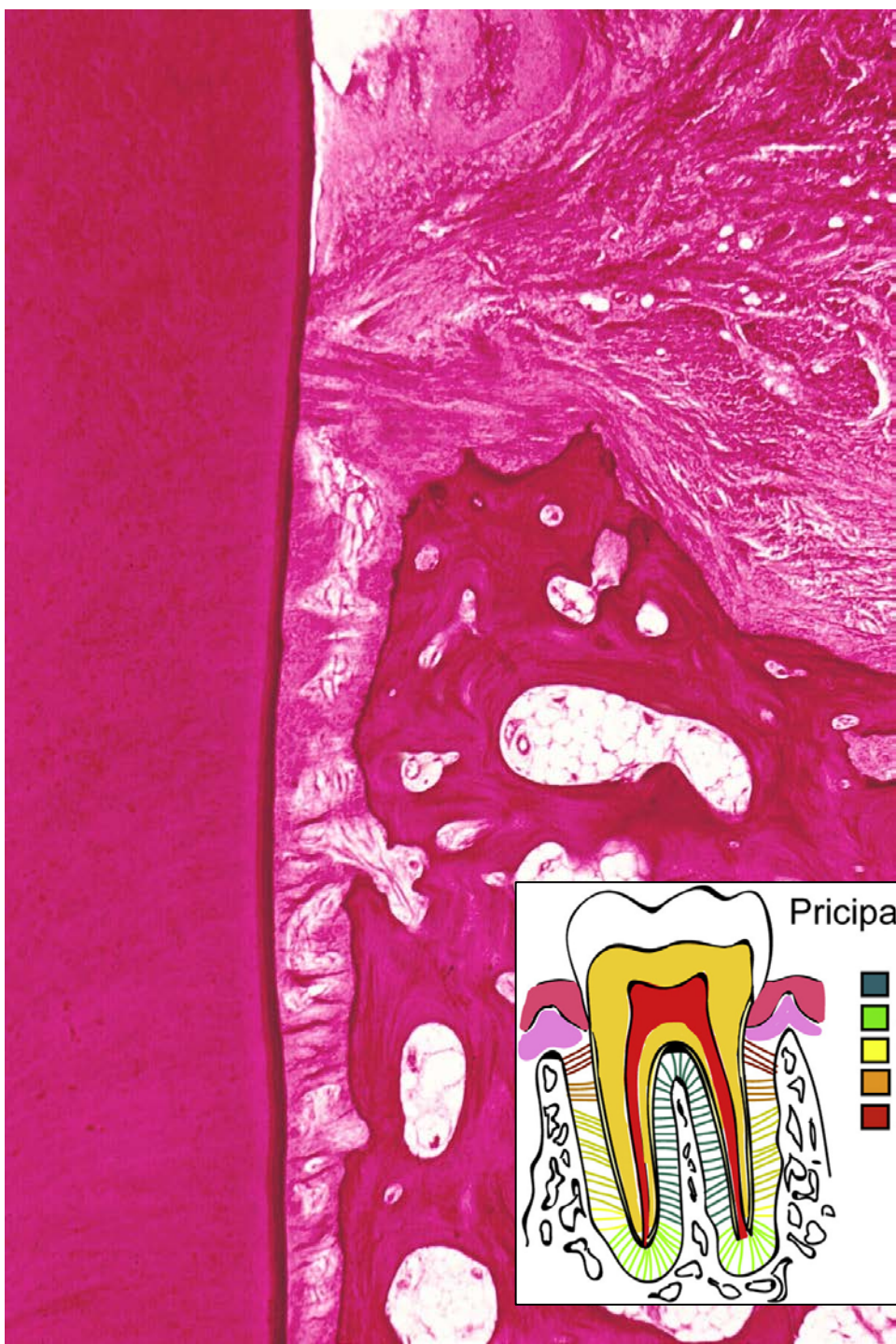Alveolar crest group – from the neck to periosteum of interalveolar septum or periosteum of coronal edge of alveolus.

Function: **They prevent the tooth from moving out of the alveolus (sometimes missing)**

Horizontal group – in coronal third of tooth root and alveolus

Perpendicular to the longitudinal axis of the tooth

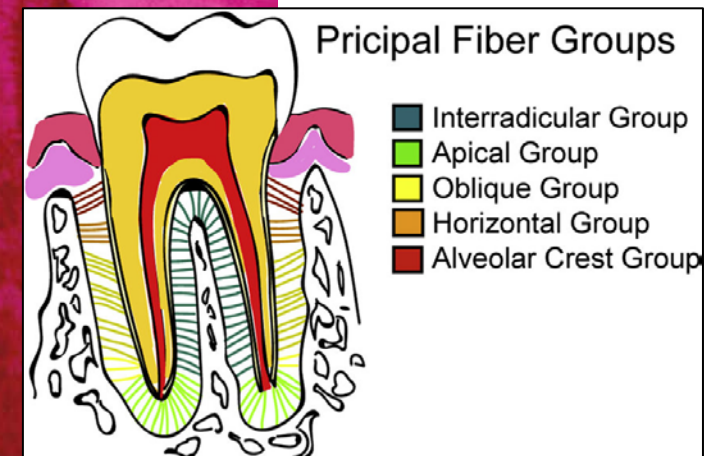
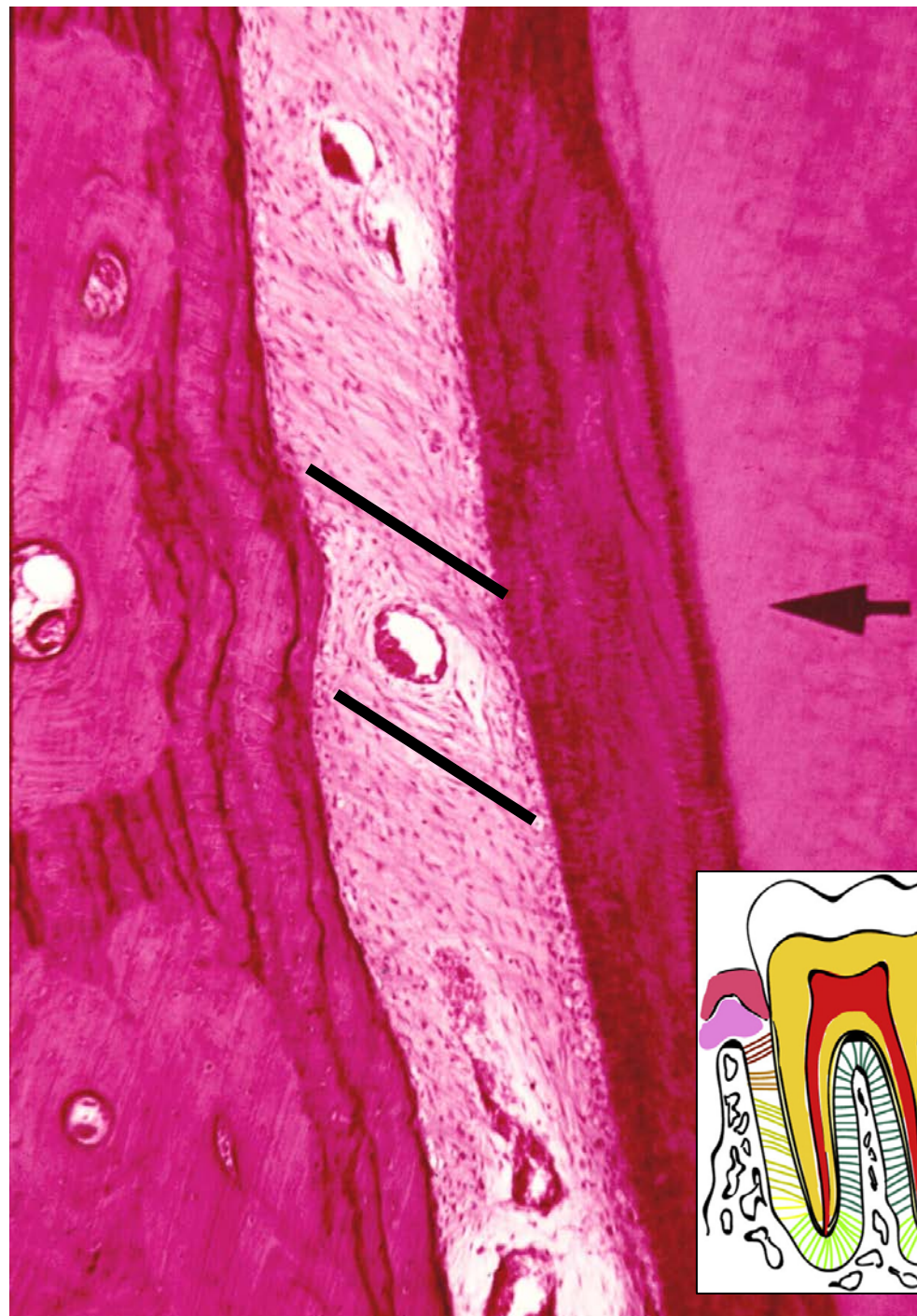Function - **Prevents lateral (horizontal) movements of the teeth**



Oblique group – in the middle and apical third of root/alveolus

Diagonal course - the attachments on the cement positioned more apically than the insertion in the cribriform plate

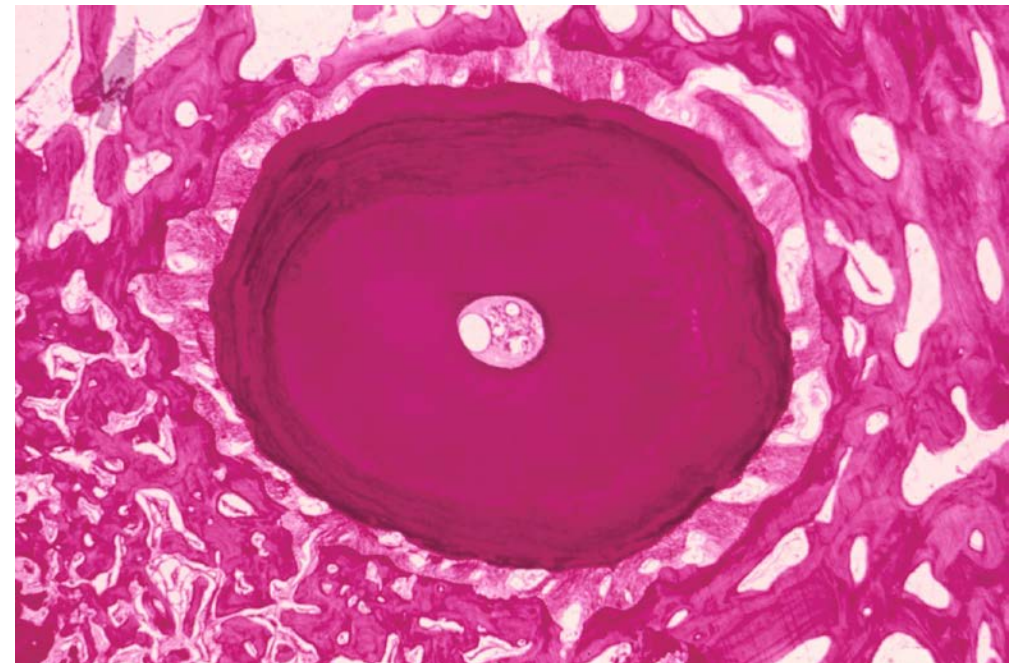
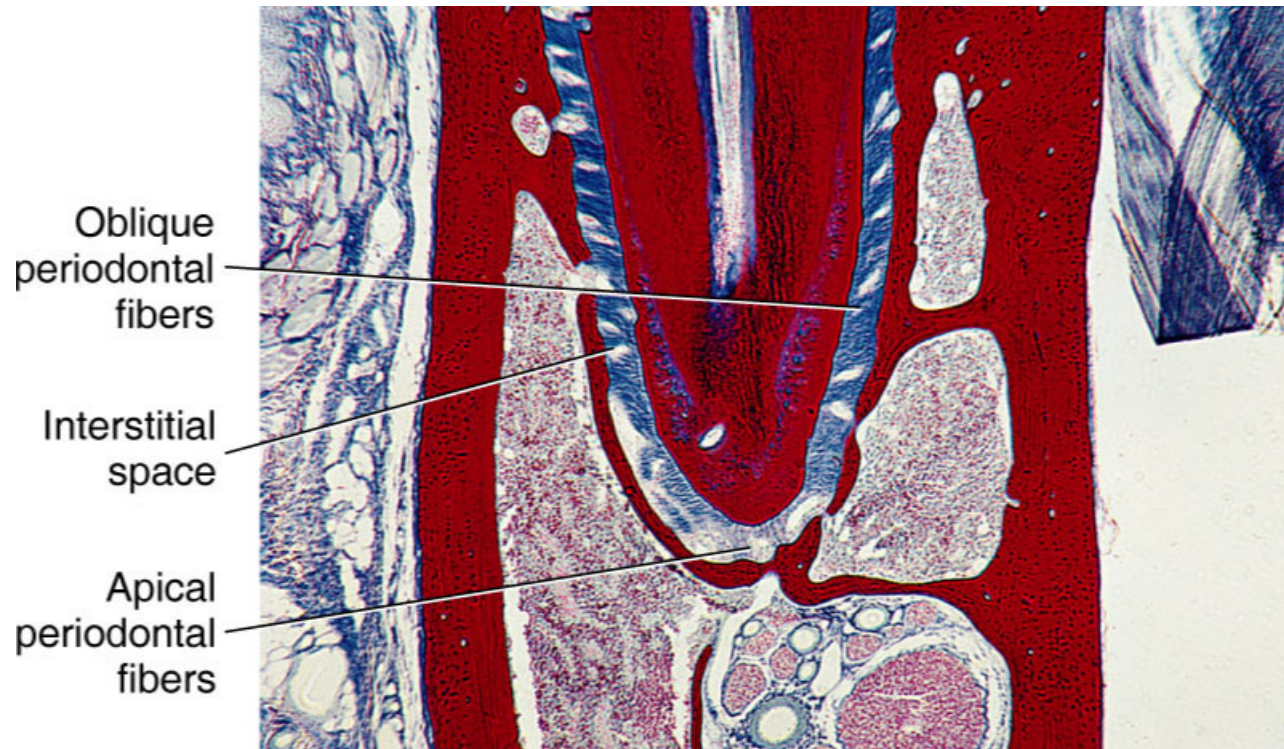
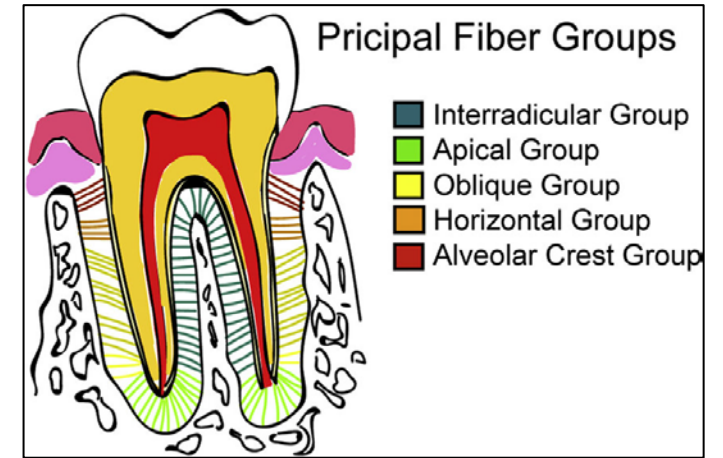
Function - **Prevents the root from being pushed into the bed**



Apical – from the tooth apex to the bottom part of alveolus

Radial course

Function – **Prevent the tooth from moving out of the alveolus (sometimes missing)**

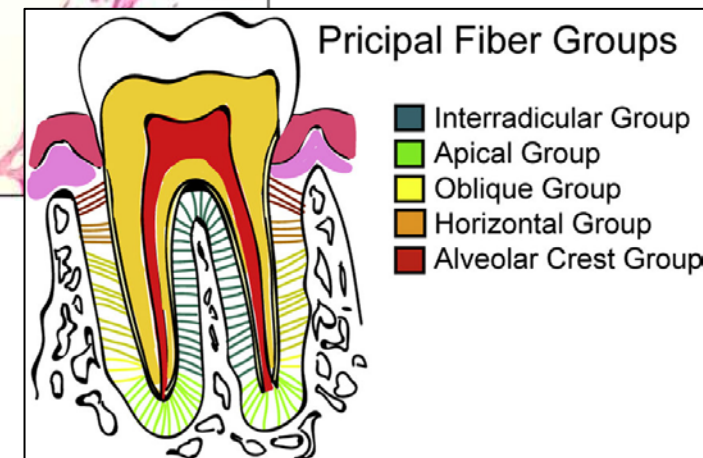
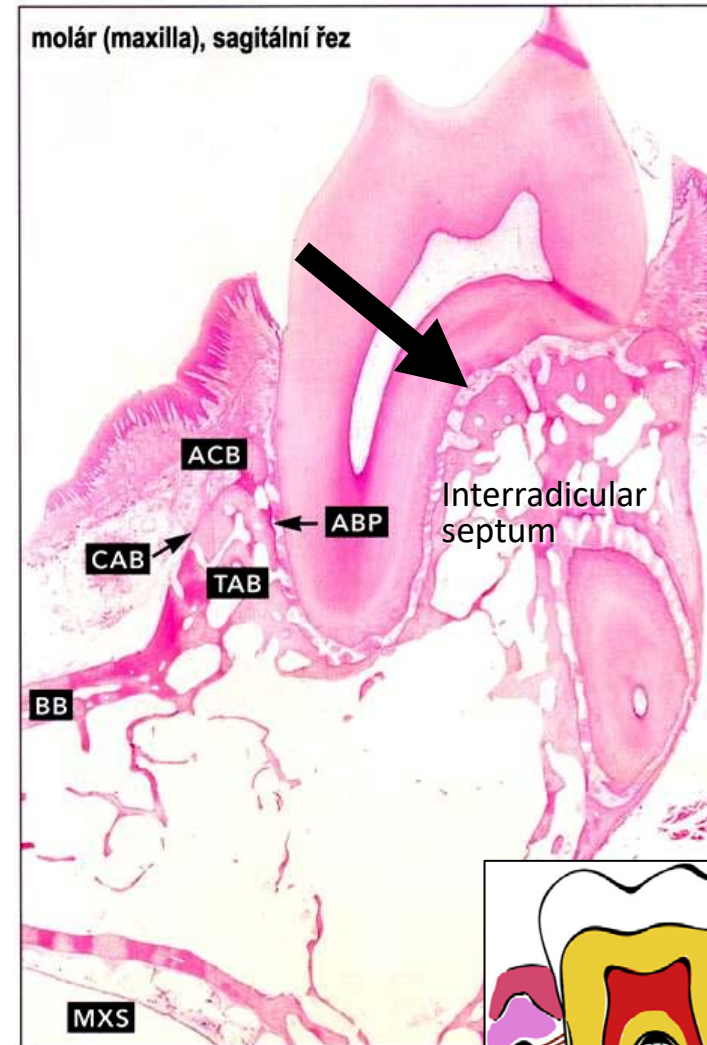
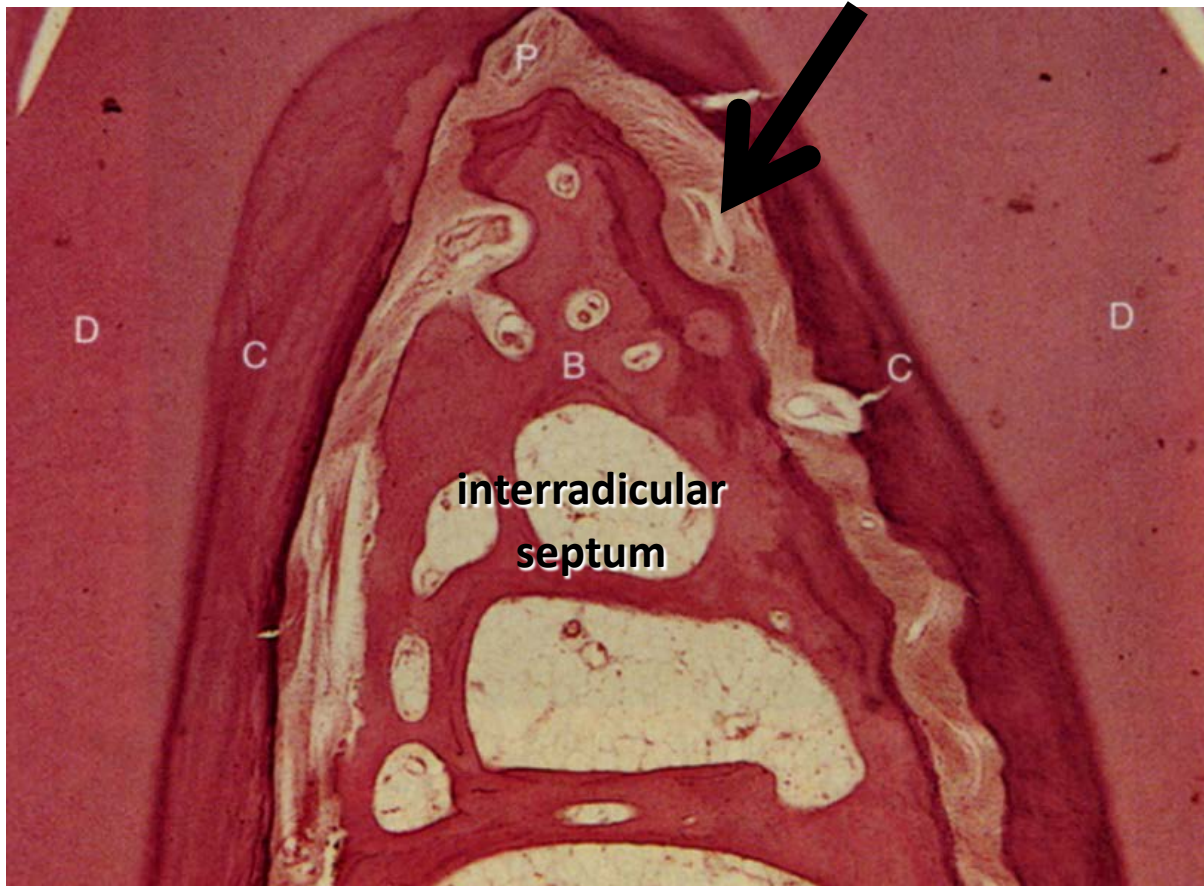


Interradicular – only in teeth with more roots

At the place of root branching

Attached to the alveolar septum between roots

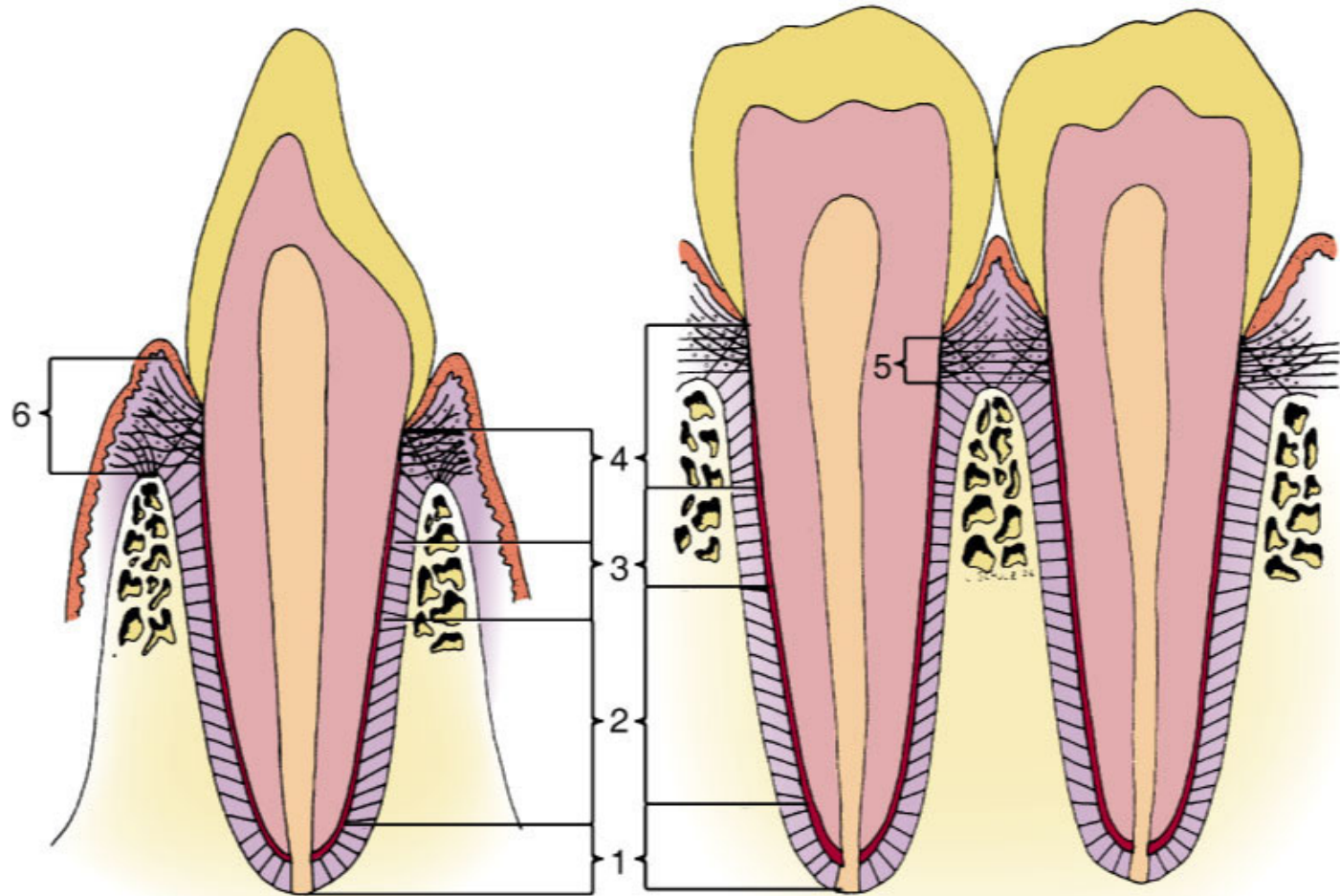
Function – prevent the tooth from moving out of the alveolus and the rotation



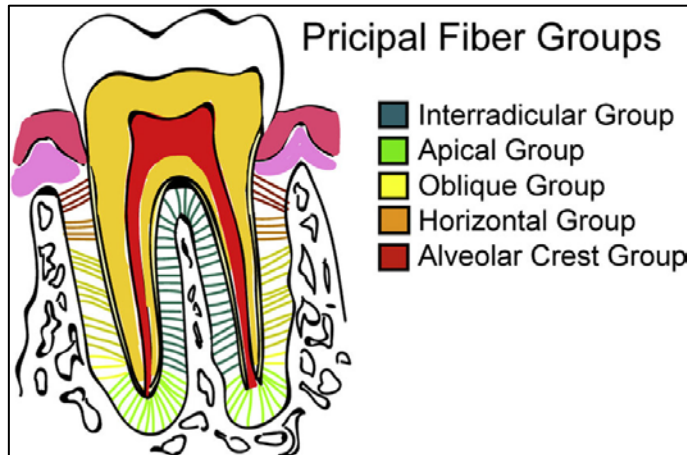
Summarization

Buccolingual

Mesiodistal



1. Apical
2. Oblique
3. Horizontal
4. Alveolar crest
5. Transseptal
6. Gingival group



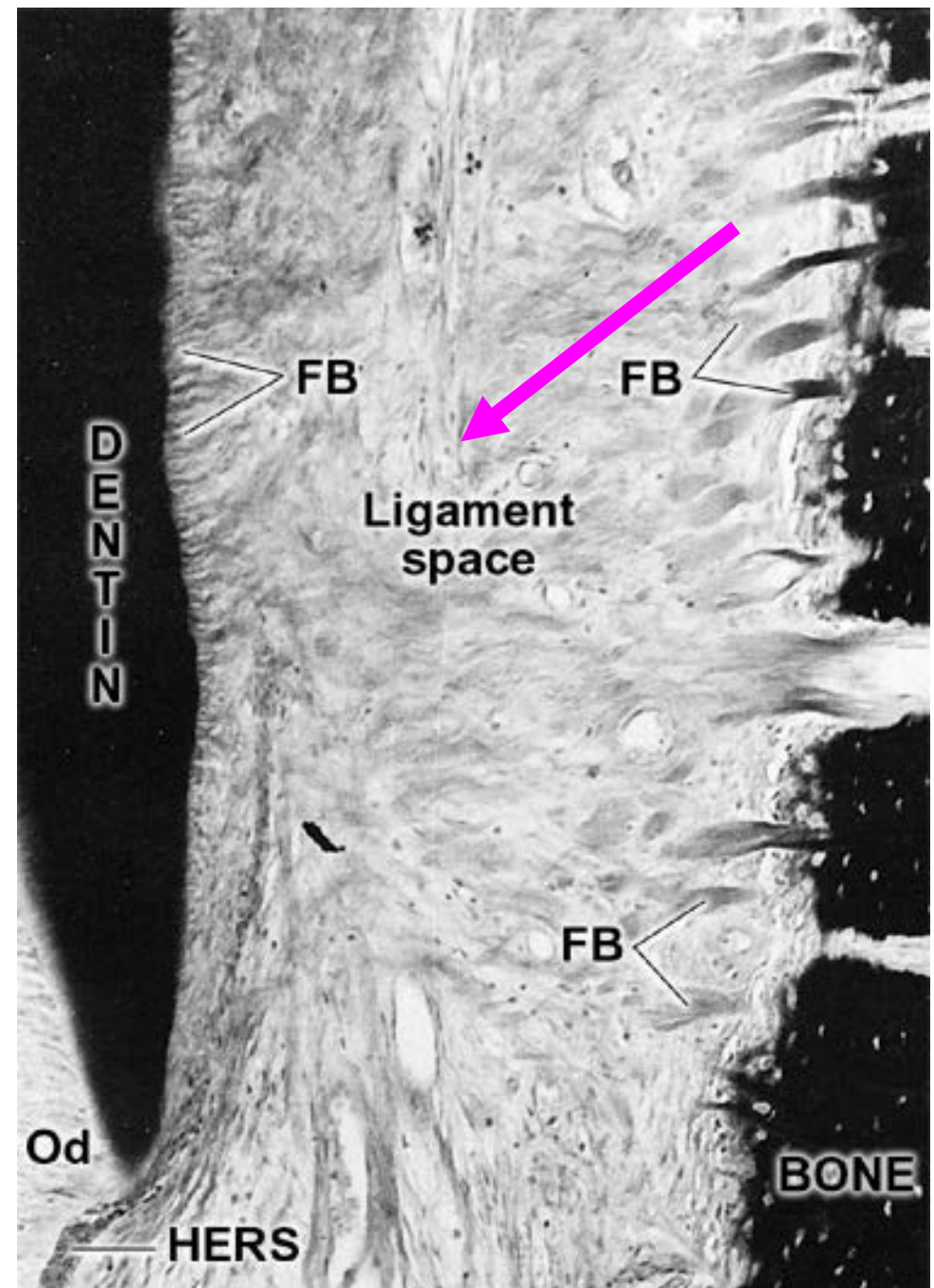
Intermediate plexus

Some fibres has only one attachment – either in cementum or in cribriform plate of alveolar bone and the other is free

From this fibres is constituted
Intermediate plexus

Function:

- Morphological and functional supply for potential reorganization of periodontal ligament
- Support for interstitial areas



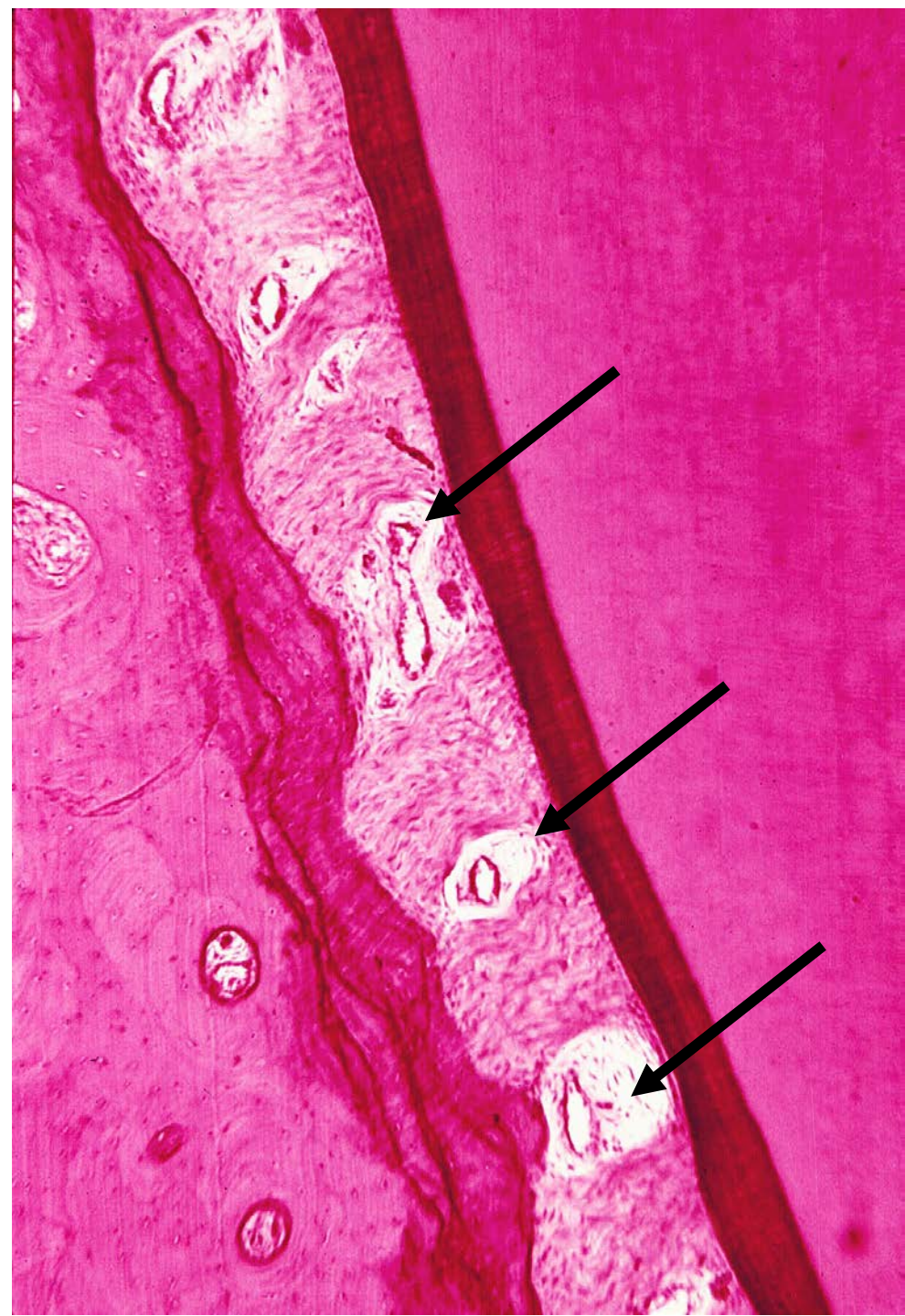
Interstitial areas

Regions of **loose collagenous tissue**

Separate bundles of ligaments

Space for blood vessels and nerves which are responsible for periodontal space vitality

On samples they are paler tissue with obvious blood vessels and surrounded by amorphous tissue



Blood and nervous supply of periodontal space

Highly innervated and numerous blood vessels in this region

Arterioles derived from gingival, „pulpal“ and interalveolar branches

In interstitial areas they form a dense capillary network which branches can be found also between the ligaments

Lymphatic vessels

PERIODONTAL LIGAMENT 197

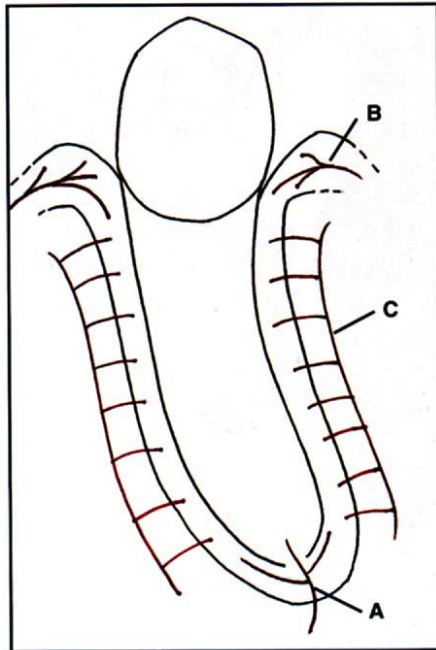
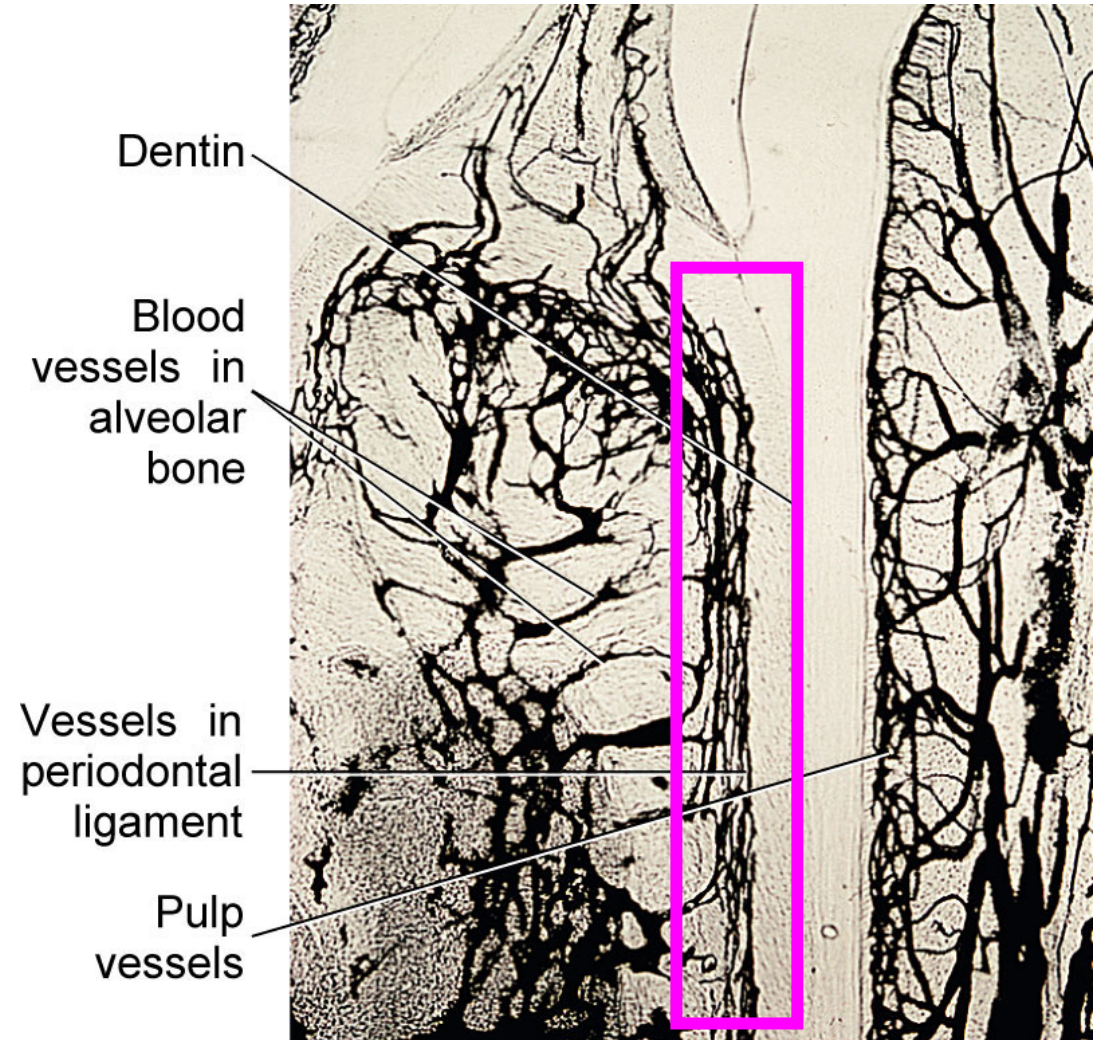


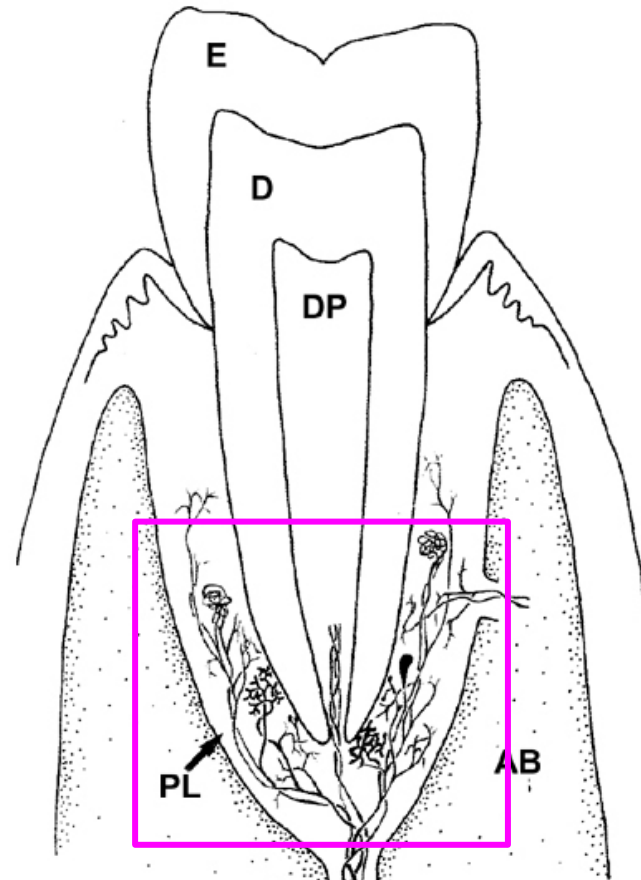
Fig. 12.52 The blood supply to the periodontal ligament. A = Arteries from dental pulp; B = arteries from gingiva; C = arteries from alveolar bone.



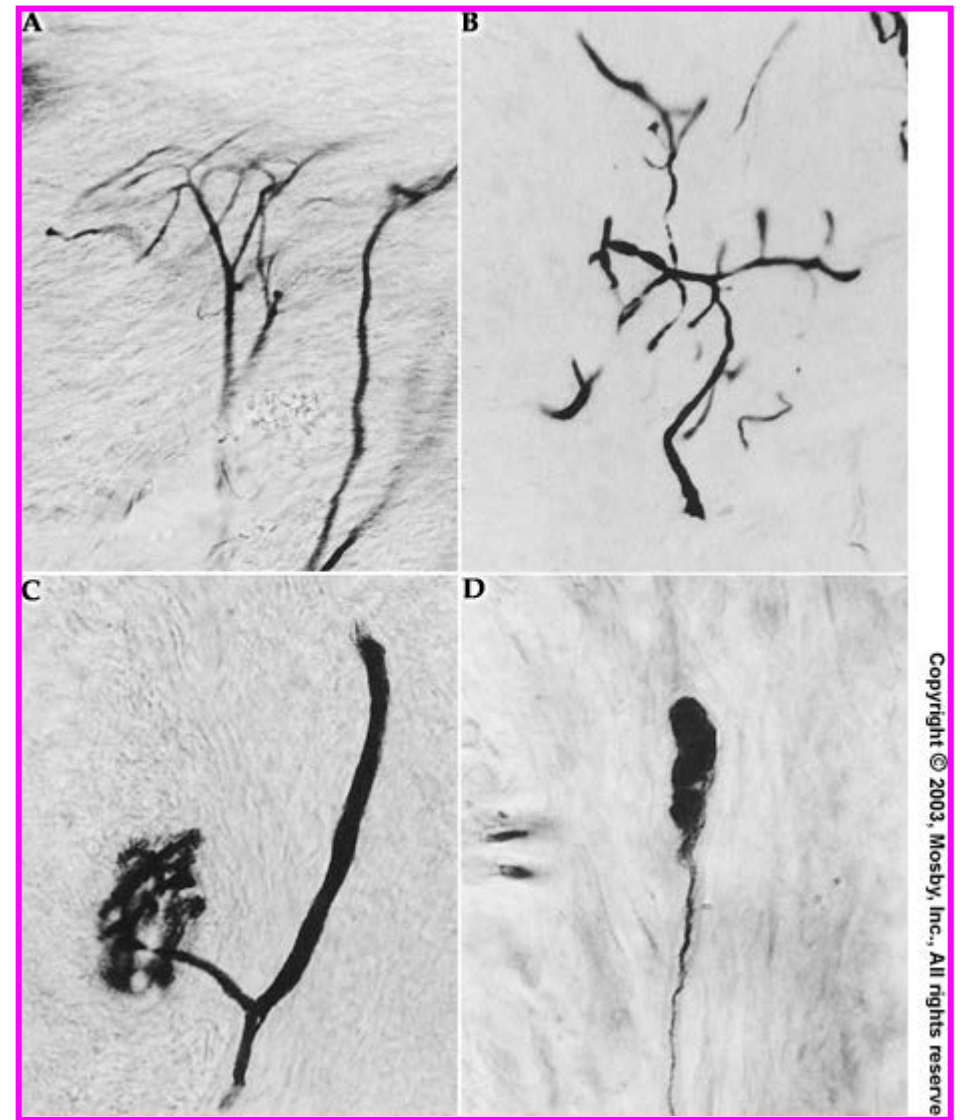
Innervation

Three types of nerve endings

- **Free nerve endings** (pain) – from unmyelinated or from myelinated nerve fibers)
- **Ruffini-like endings** – In apical part of PDL
- **Lamellated corpuscles**



Copyright © 2003, Mosby, Inc., All rights reserved.



Copyright © 2003, Mosby, Inc., All rights reserved.

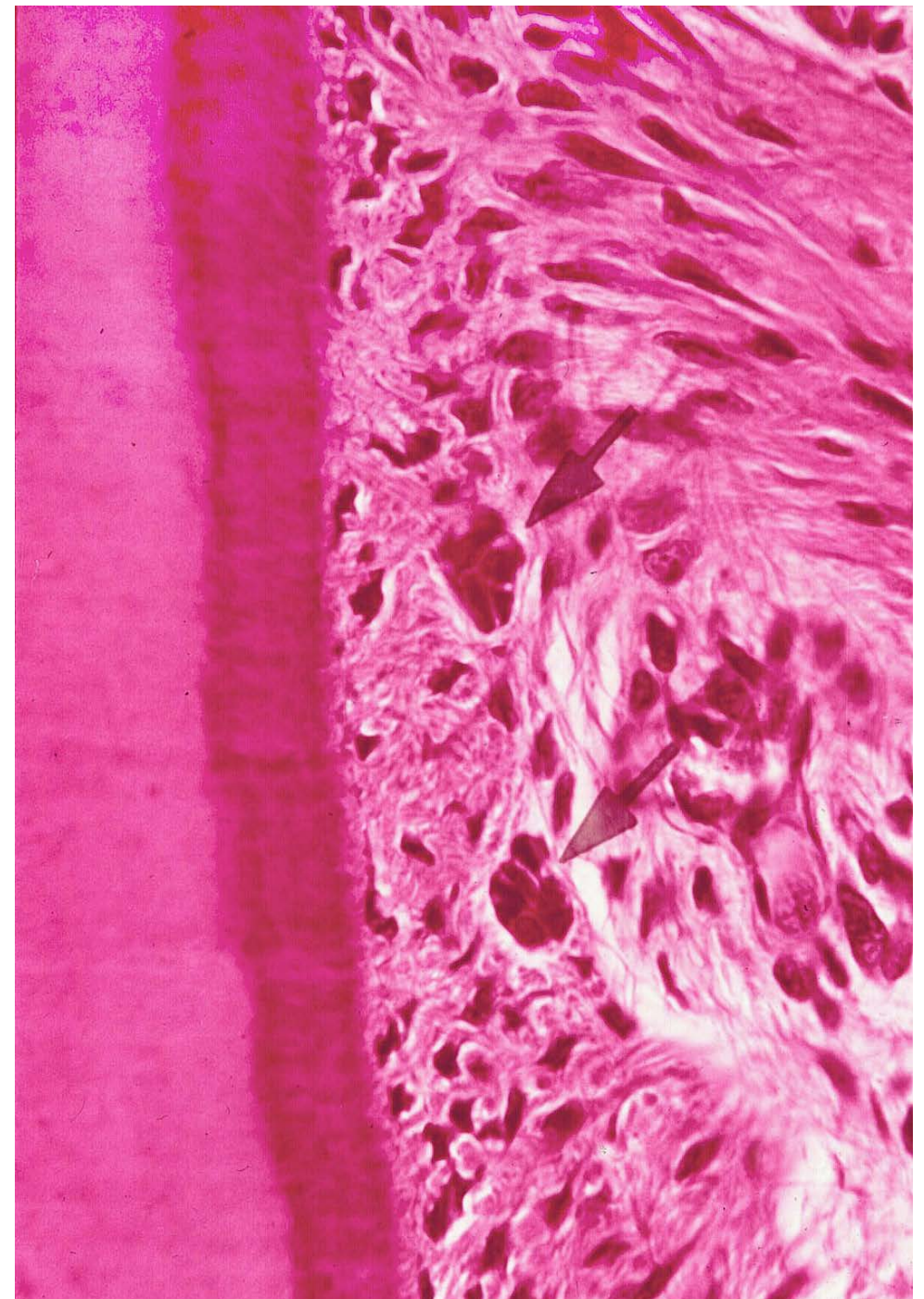
Other structures in periodontal space

ERM (Epithelial rests of Malassez)

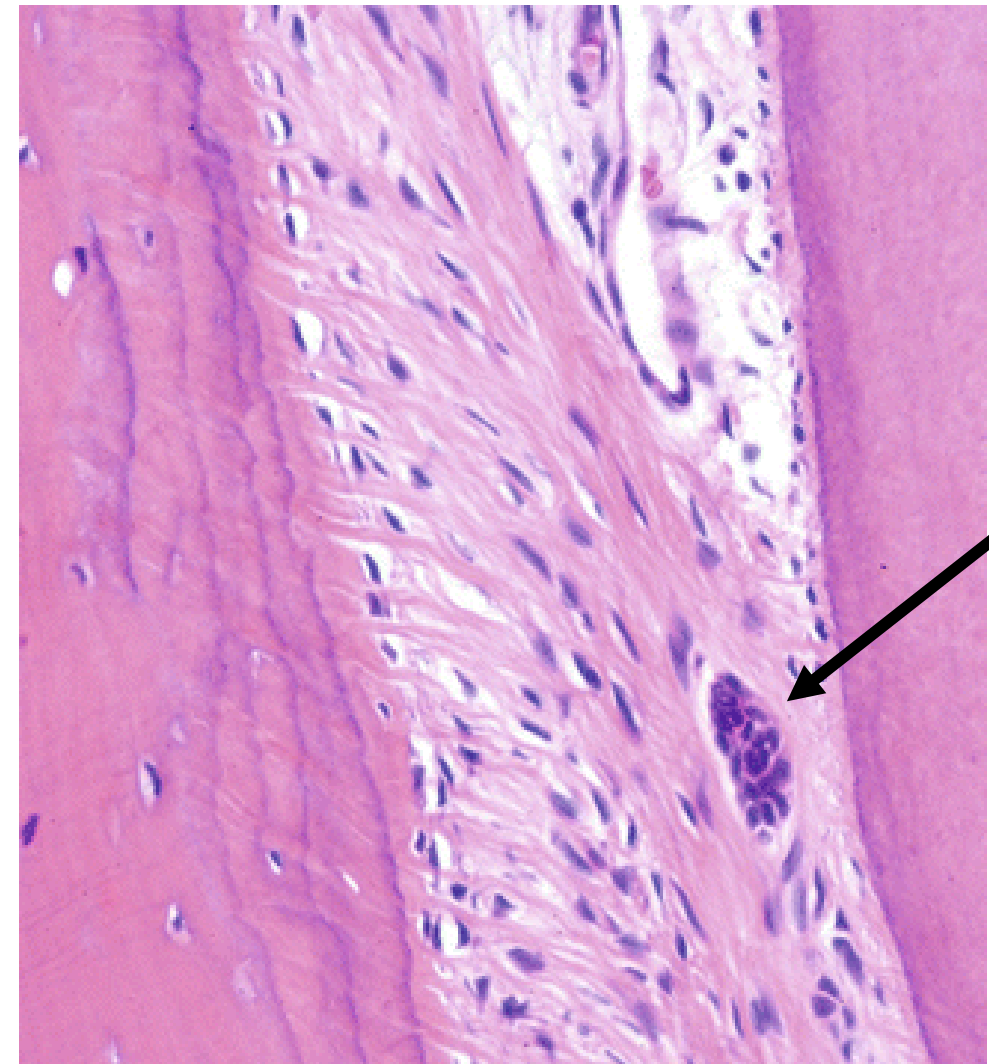
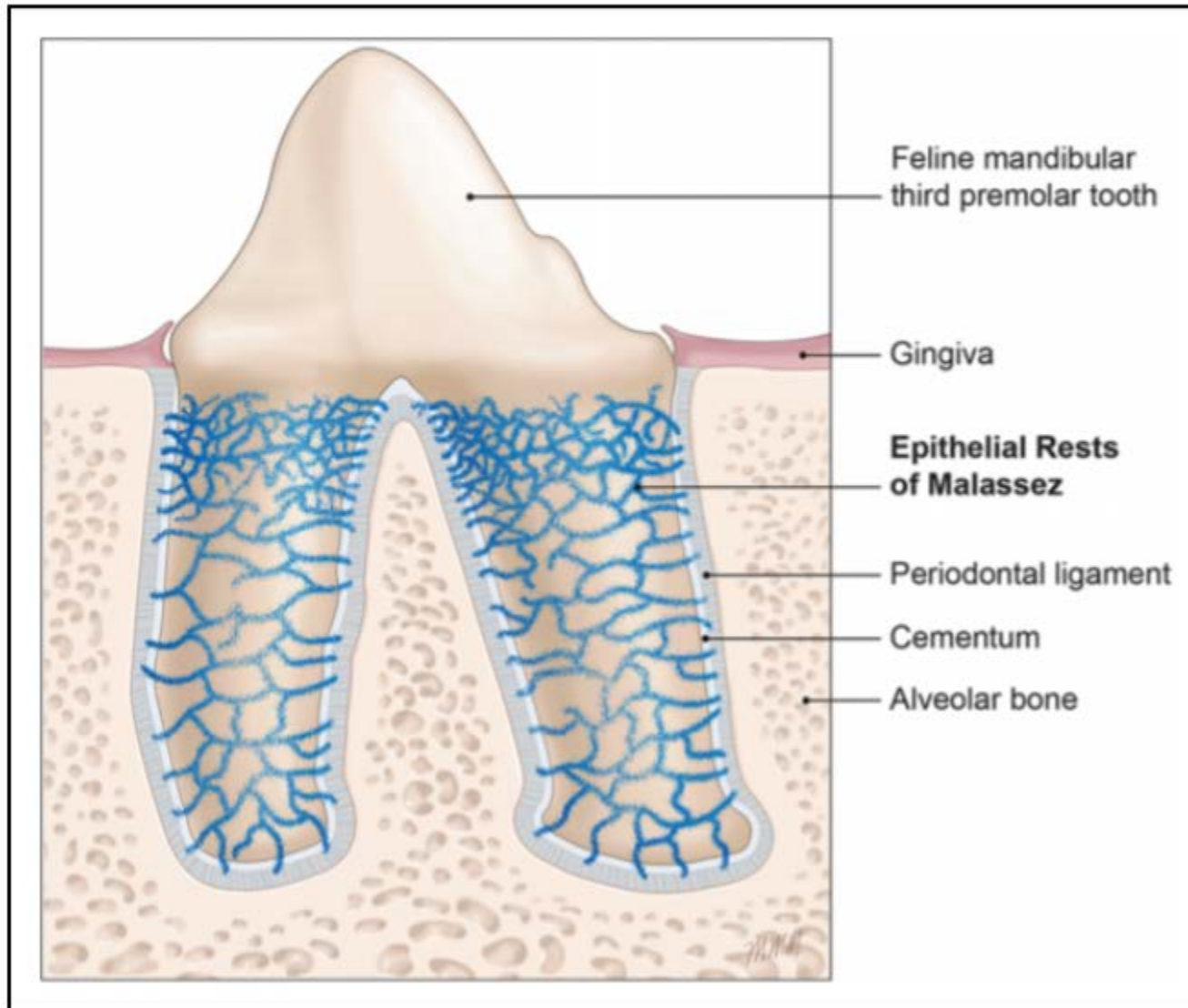
- Epithelial remnants from disintegrated **HERS** (Hertwig Epithelial Root Sheat)
- Pool of stem cells, interactive support for adjacent cells
- Can undergo **EMT** (Epithelial to Mesenchymal Transition)

Granulomas and cysts

Cementicles



ERM = Epithelial rests of Malassez



Periodontal changes during ageing

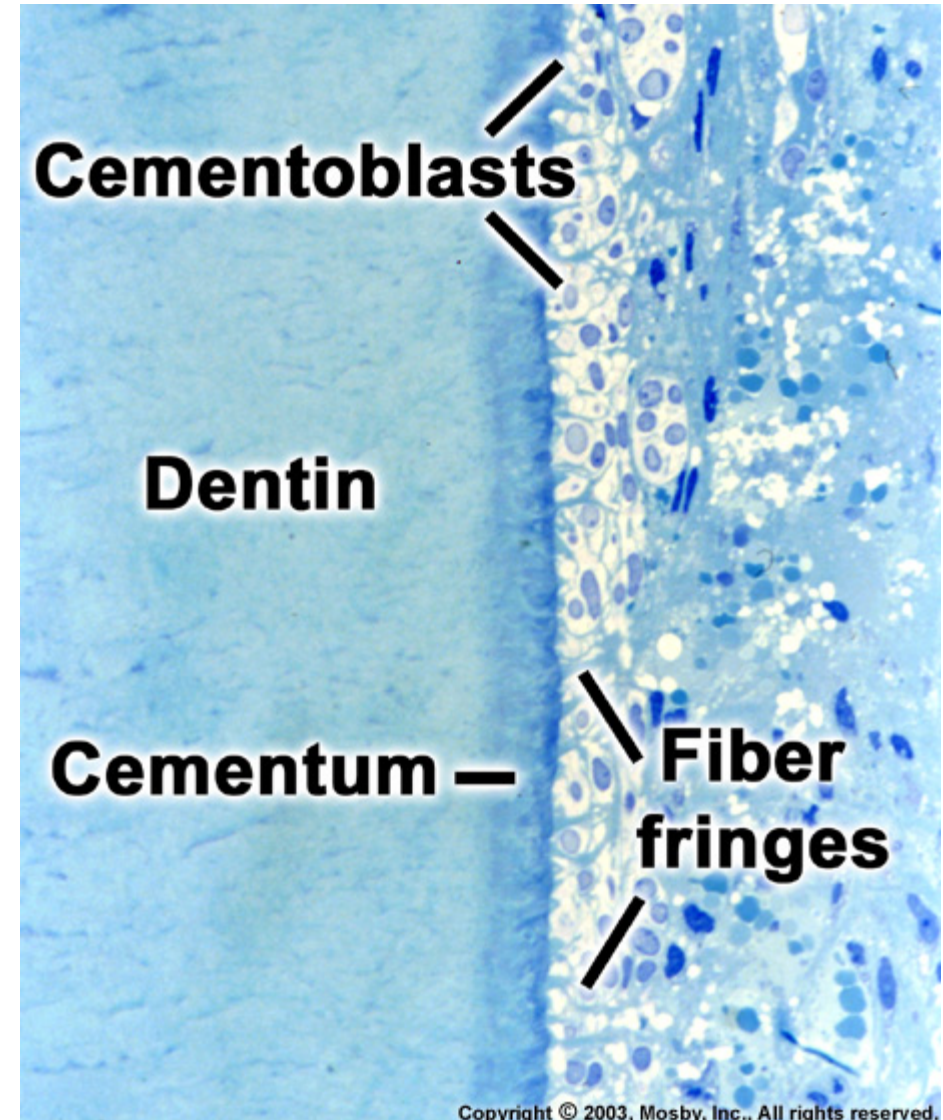
Changes while losing an antagonist – nonfunction

- Periodontal space narrowing
- Weakening and loosening of fibers
- Cementum thickening
- Weakening of the cribriform disc

Changes due to overload

Acute (trauma) – blood effusions, fiber rupture, necrosis and resorption, ankylosis

Chronical – hypercementosis



Periodontal fibres (ligaments) - terminology

Gingival fibres - fibrae gingivales (fibrae gingivodentales, fibrae gingivales circulares)

Transseptal fibres - fibrae interdentes

Alveolar fibres - fibrae alveolodentales (fibrae principales)

Alveolar cres - lig. dentale superius

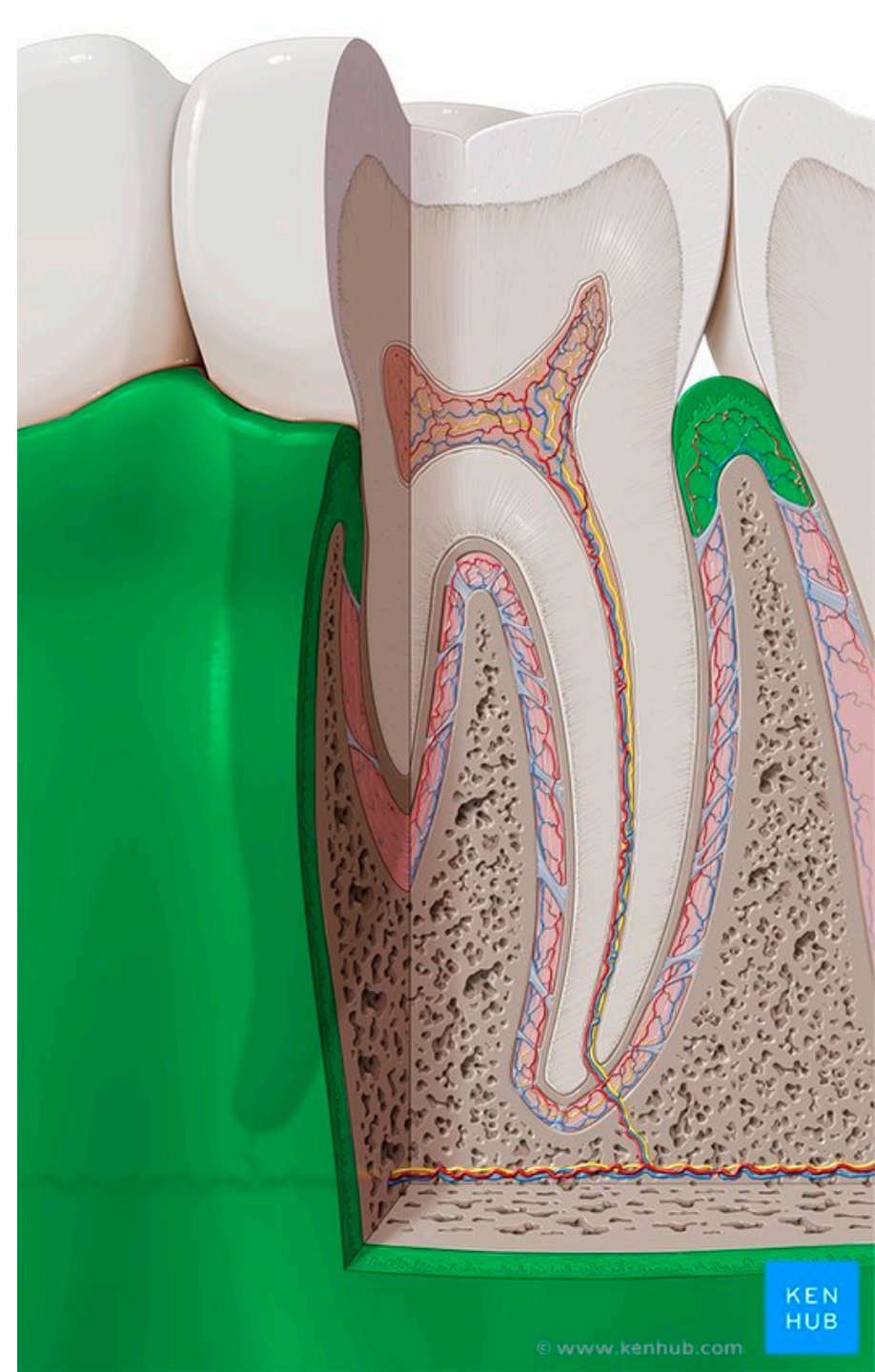
Horizontal - fibrae alveolodentales transversae

Oblique - lig. dentale inferius

Apical - fibrae apicales

Interradicular - fibrae interradiculares

Gingiva

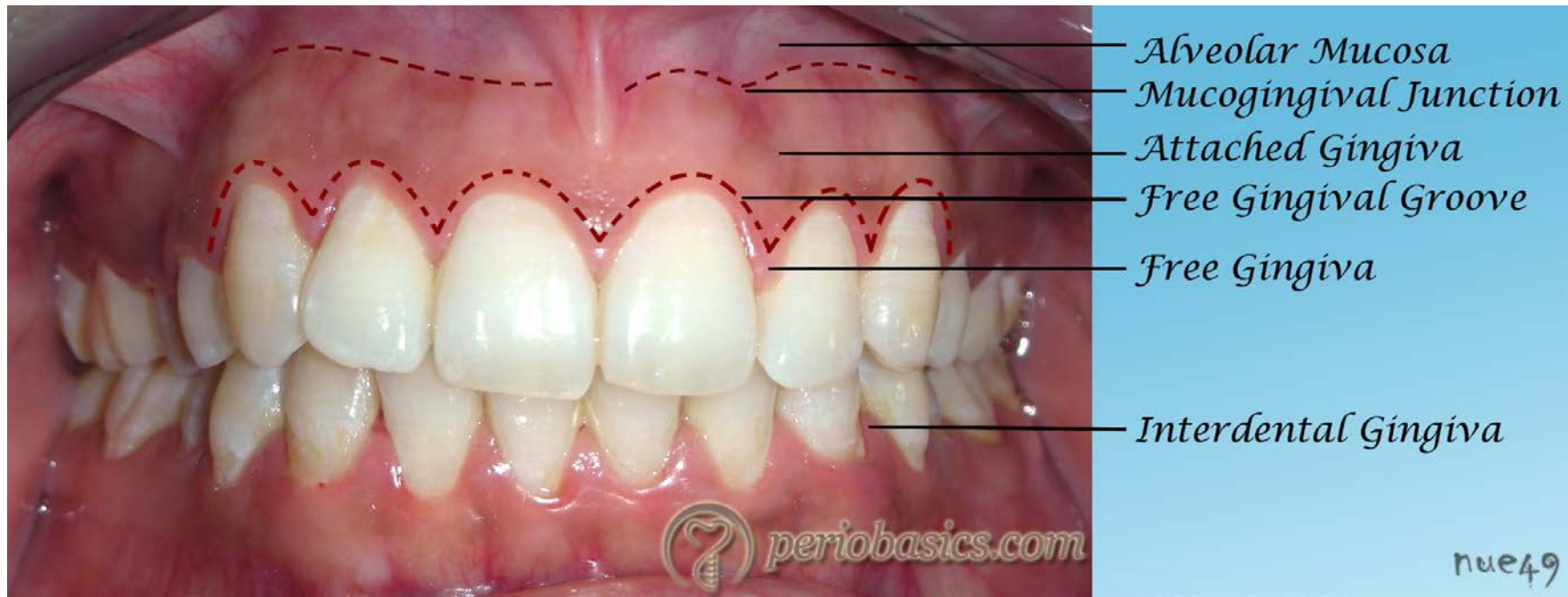


Gingiva

- Masticatory oral mucosa
- Around tooth necks and covering alveolar bone. Firmly attached to adjacent hard tissues
- Very stiff, pale pink color, resistant to pressure and friction
- It is not movable – forming mucoperiosteum

Mucogingival junction (line)

- The border between gingiva and lining mucosa which covers the rest of alveolar process
- Apparent on the vestibular aspect of both mandible and maxilla and on lingual aspect of mandible



Gingiva

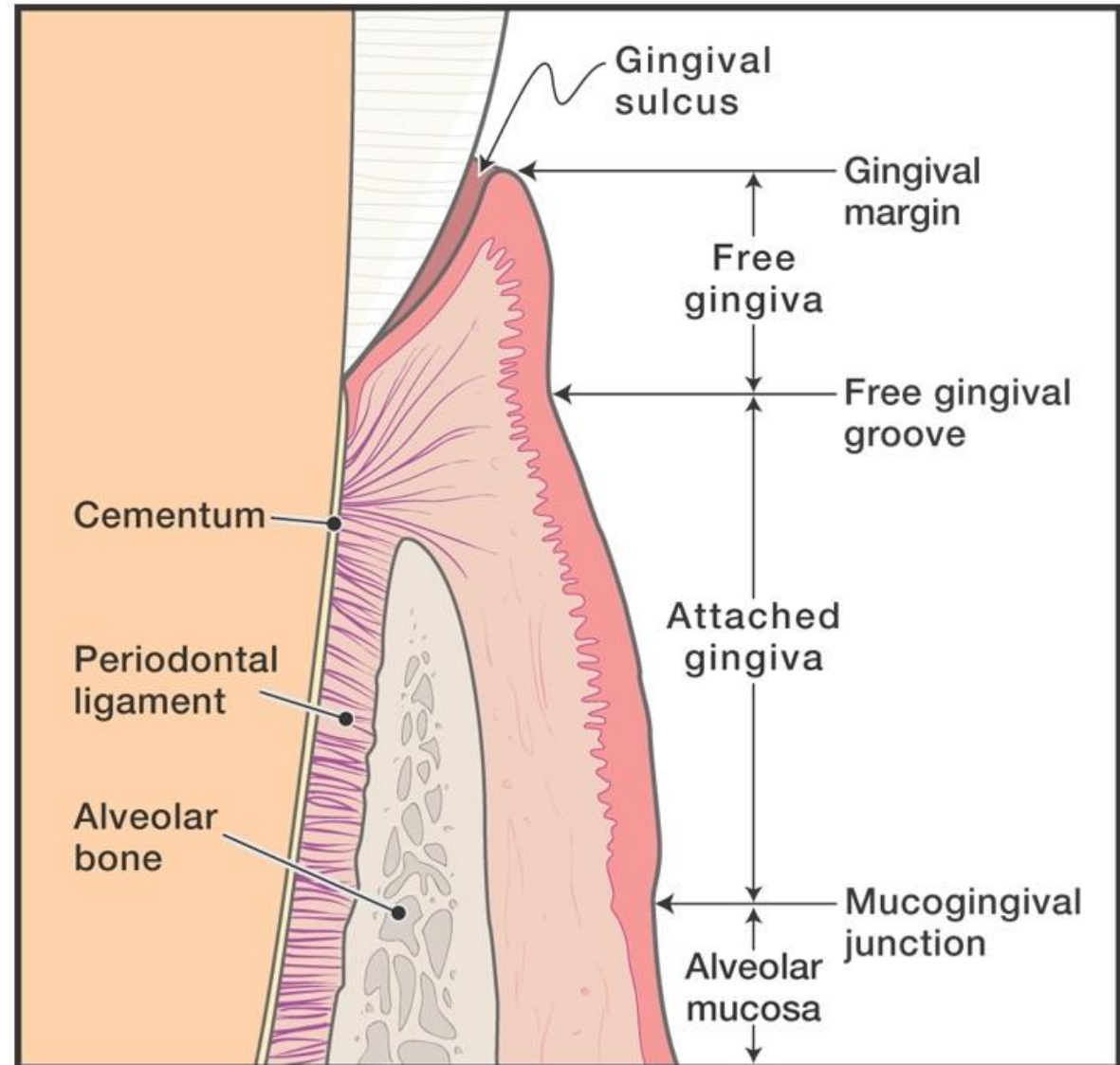
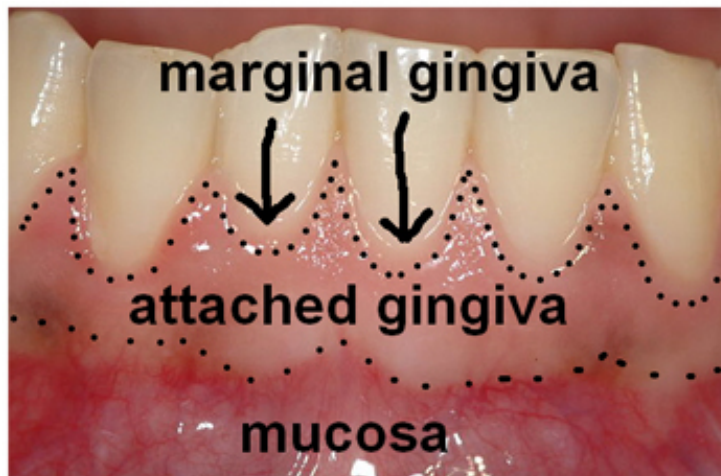
Topography: **2 compartments**

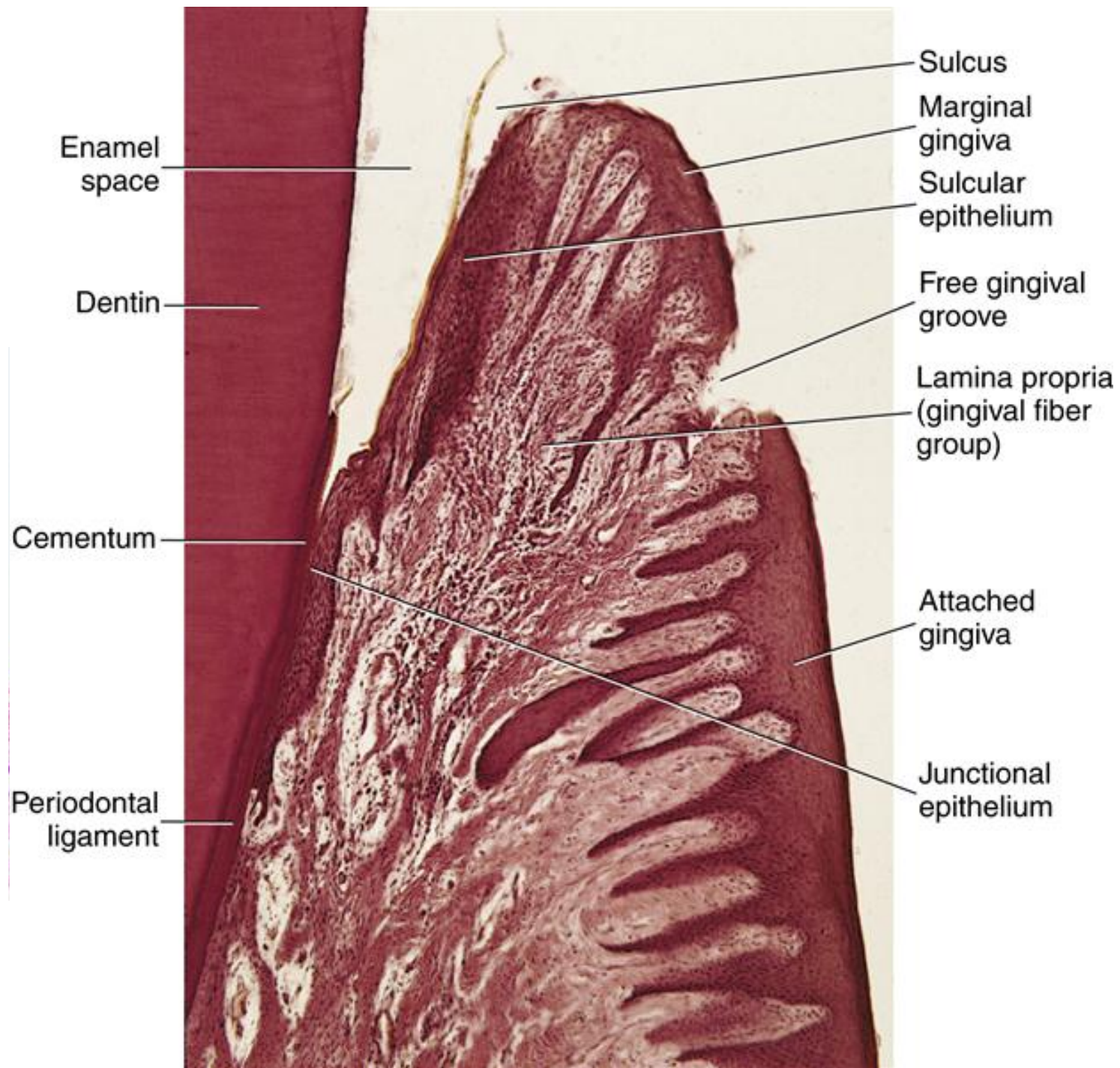
Gingiva libera (Free gingiva)

(gingiva supraalveolaris)

Gingiva affixa (Attached gingiva)

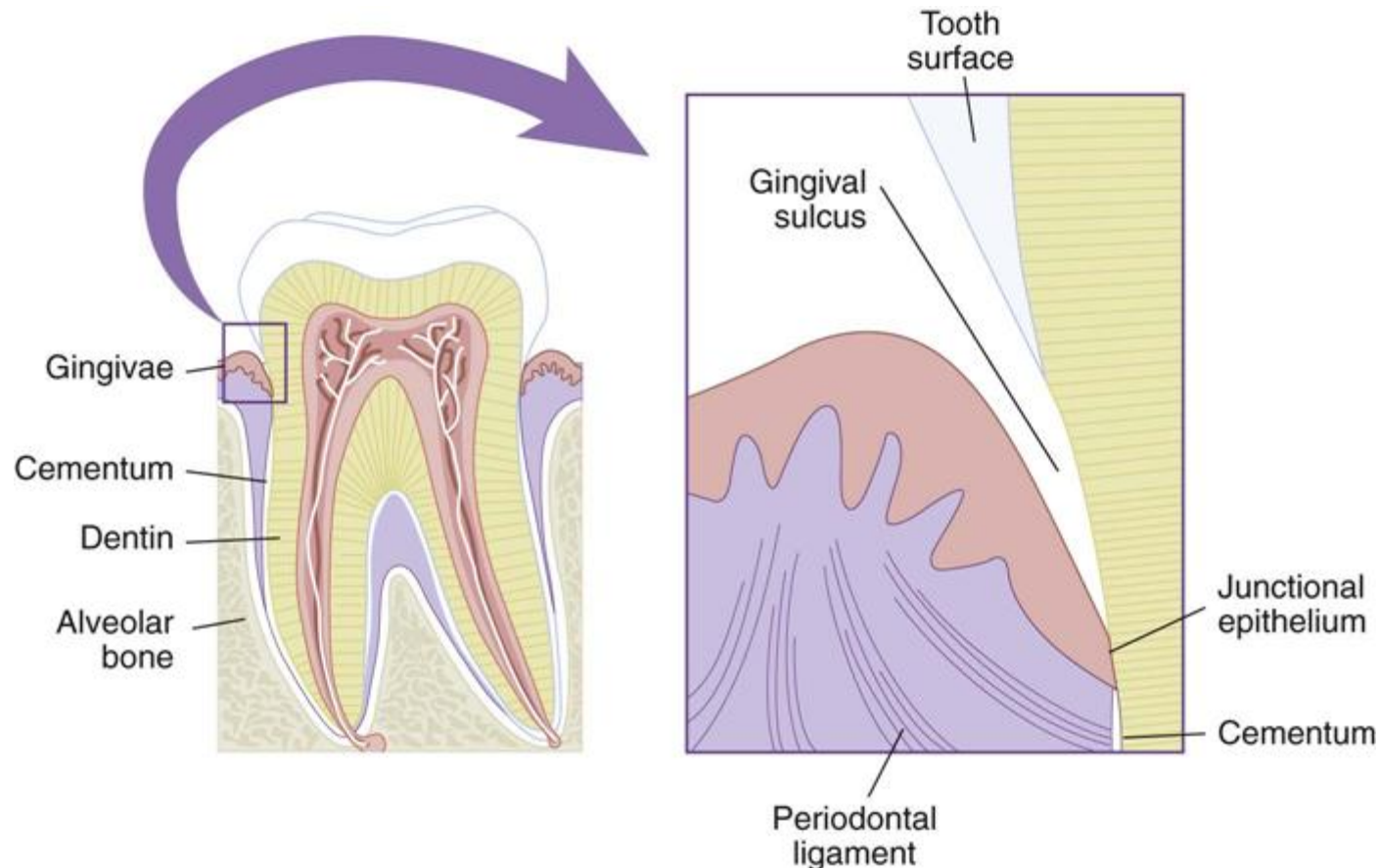
(gingiva alveolaris)





Sulcus gingivalis (Gingival sulcus)

- Circular groove, physiological depth: 1-2 mm
- **Liquor gingivalis:** plasma-like fluid which leaks from adjacent capillaries. The fluid has antimicrobial and anti-inflammatory properties, contains proteins and carbohydrates



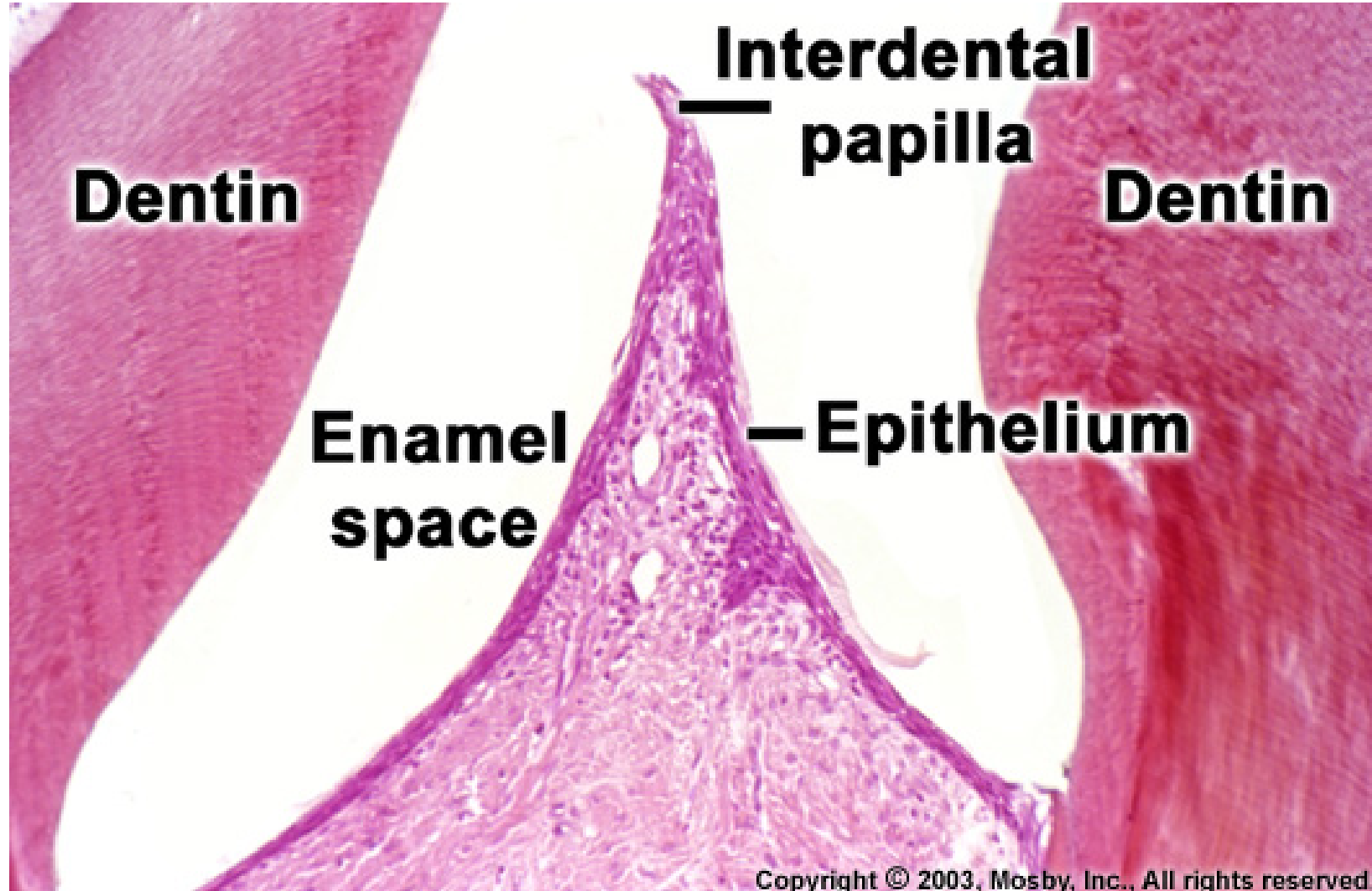
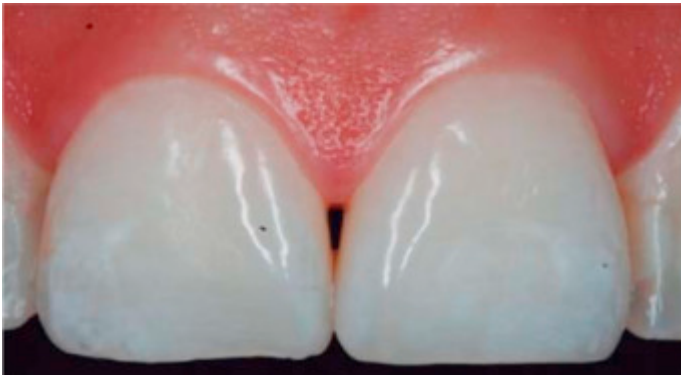Trigonum interdentalale

Interdental papillae, interdental gingiva

Between neighbouring teeth, free gingiva forms a protrusion: **trigonum interdentalale**

Vestibular and lingual aspect

Každá má vestibulární a linguální část, connected by interdental saddle



Microscopic structure of gingiva

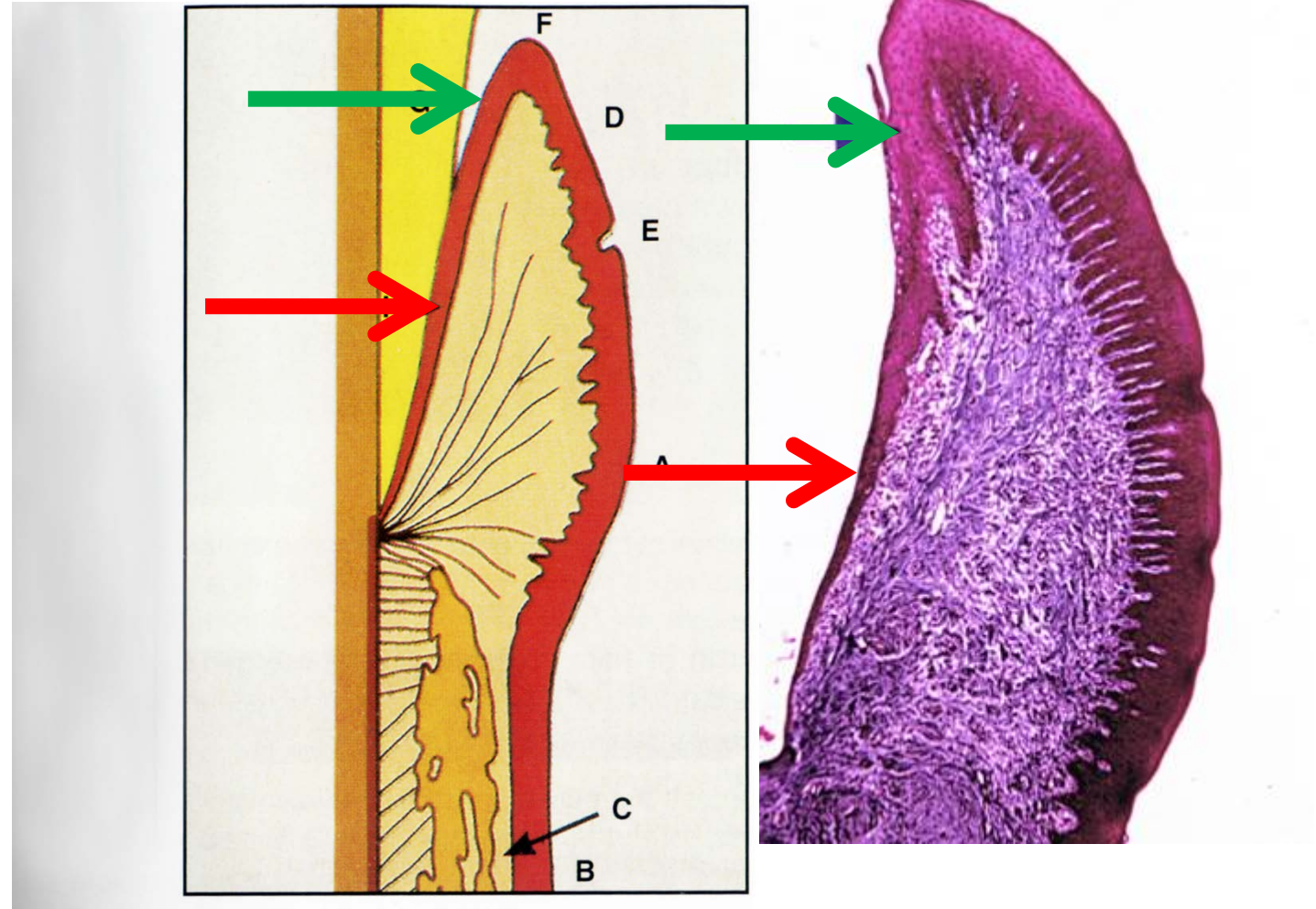
Stratified squamous epithelium

Keratinized at vestibular and palatinal side

No keratinization on the side facing teeth: Sulcular epithelium

On the side facing teeth it keeps non-differentiated epithelium characteristics.

Junctional epithelium (epithelial attachment of Gottlieb) is firmly attached to teeth and seal the periodontal space from the environment of oral cavity.



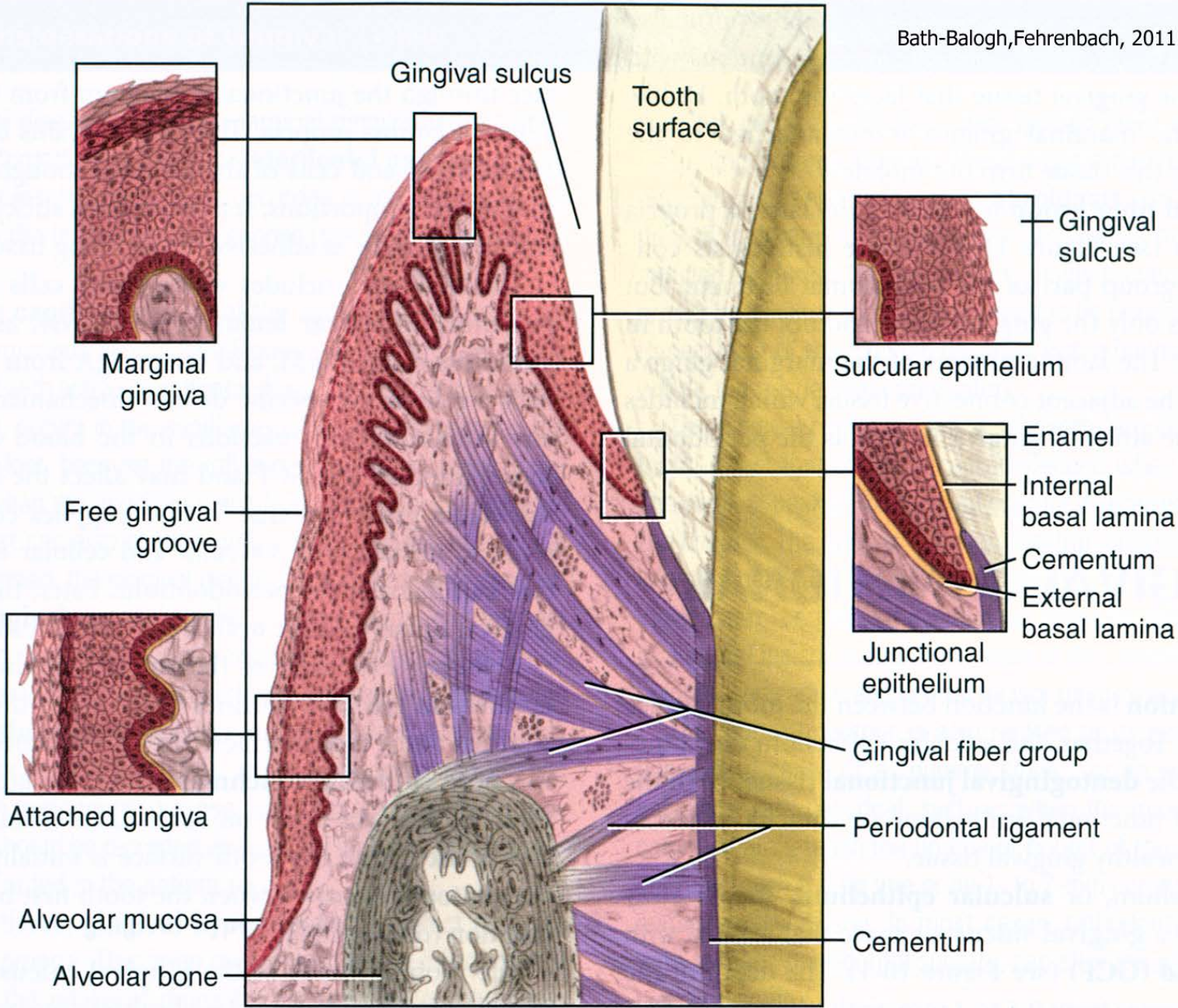


FIGURE 10-1 Gingival and dentogingival junctional tissue: marginal gingiva, attached gingiva, sulcular epithelium, and junctional epithelium.

Lamina propria

Gingiva affixa

Dense collagenous connective tissue with papillas which are numerous and thin. Their presence causes a rough surface

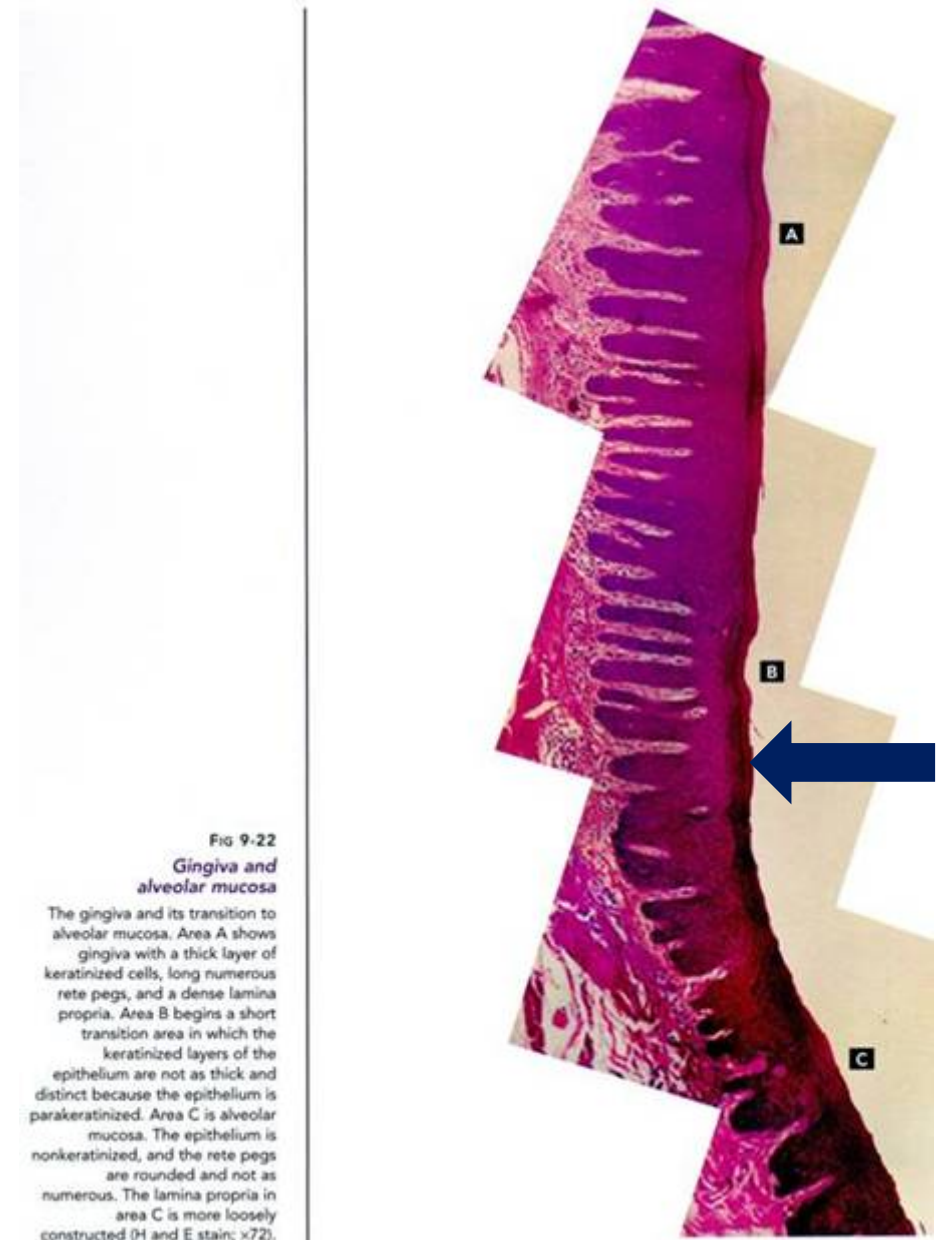
Gingiva libera

Under the epithelium of free gingiva is lower amount of papillas and always missing under epithelium which is facing teeth

Collagenous fibres are ordered into 4 groups:

dentogingival, circular, dentoperiosteal and alveologingival

(chapter periodontium)



Junctional epithelium

Epithelial attachment, epithelial attachment of Gottlieb,

Protects the periodontal space from aggressive outer environment of oral cavity resp. sulcus gingivalis (against bacteria, toxins, pieces of food)

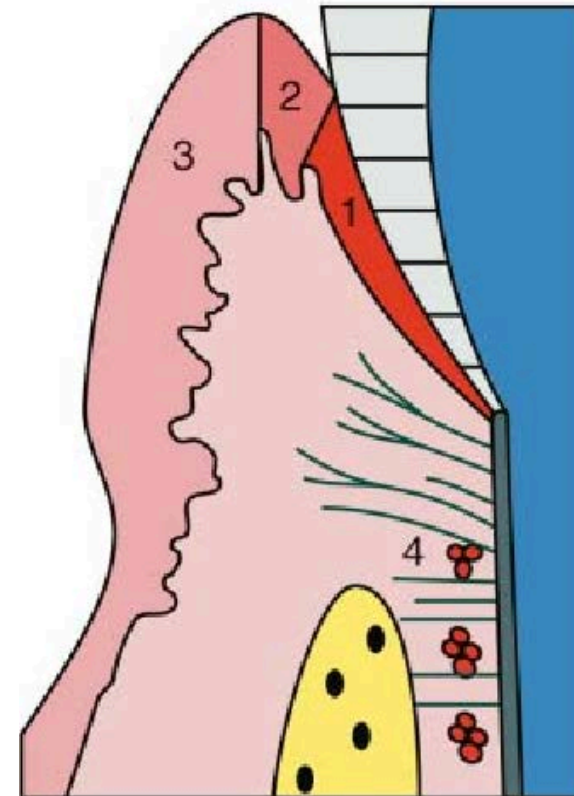
It is characteristic by the **fusion of sulcular epithelium with hard tissues of teeth in the are of the neck**

Zone of fusion is under the sulcus gingivalis

Width: 0,25 - 1 mm

This epithelium is permanently actively regenerated
– stem cell activity

Cells are in several layers, flattened



Dento-gingival junction

1. Junctional epithelium (JE)
2. Sulcular epithelium
3. Oral epithelium
4. Epithelial rests of Malassez

JE functions

- attachment to tooth
- barrier
- rapid turnover
- antimicrobial defence
- GCF flow

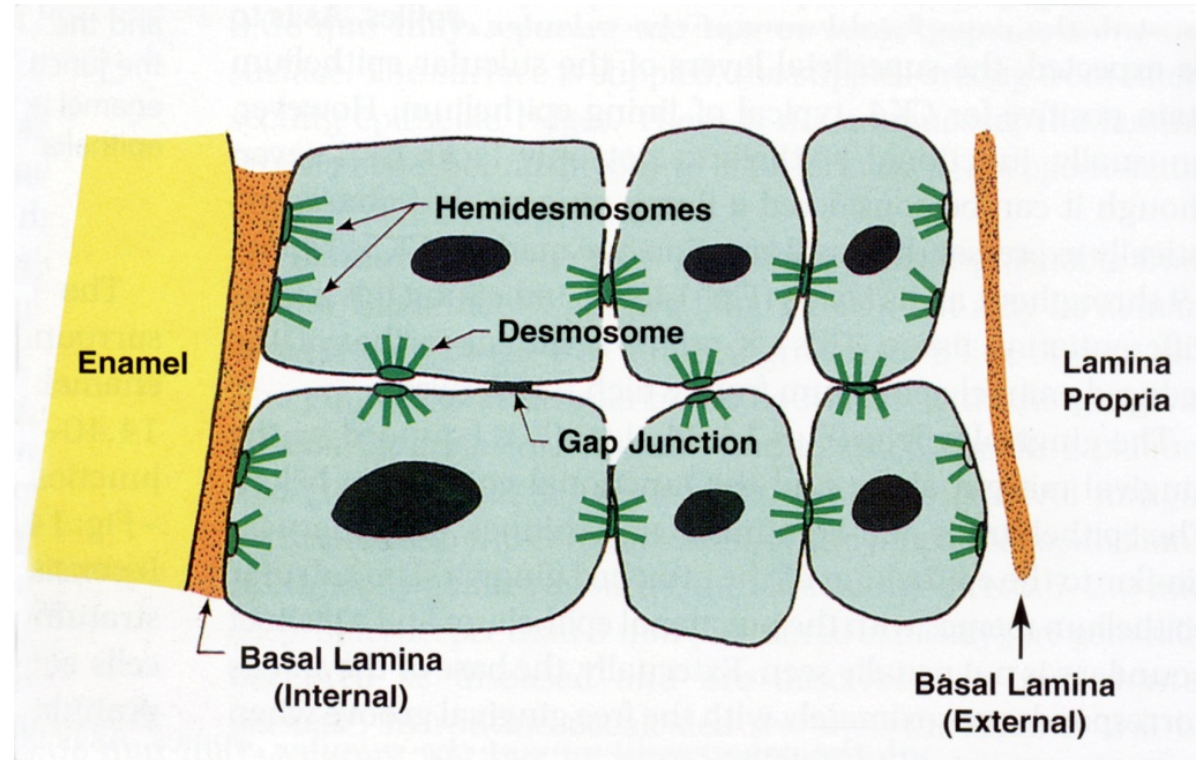
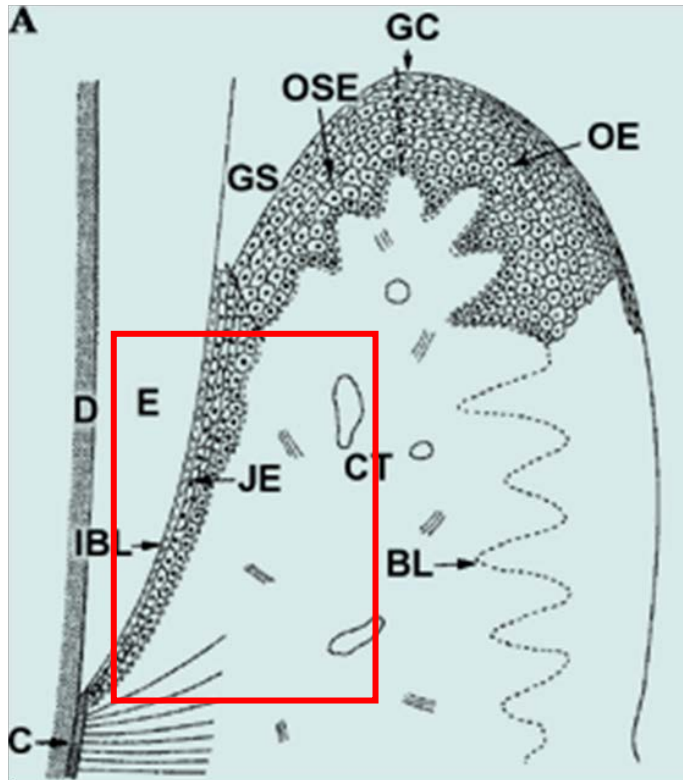
Junctional epithelium

Between the innermost layer of cells and hard tissue are hemidesmosomes, between cells are desmosomes

The line between epithelium and connective tissue is **smooth** (no papillae), connective tissue contains numerous leukocytes and B-lymphocytes, acts as an immunological barrier

Narrowing at the apical end

Fast turnover: **4-6 days**. Regenerates well after mechanical damage



Gingival recession

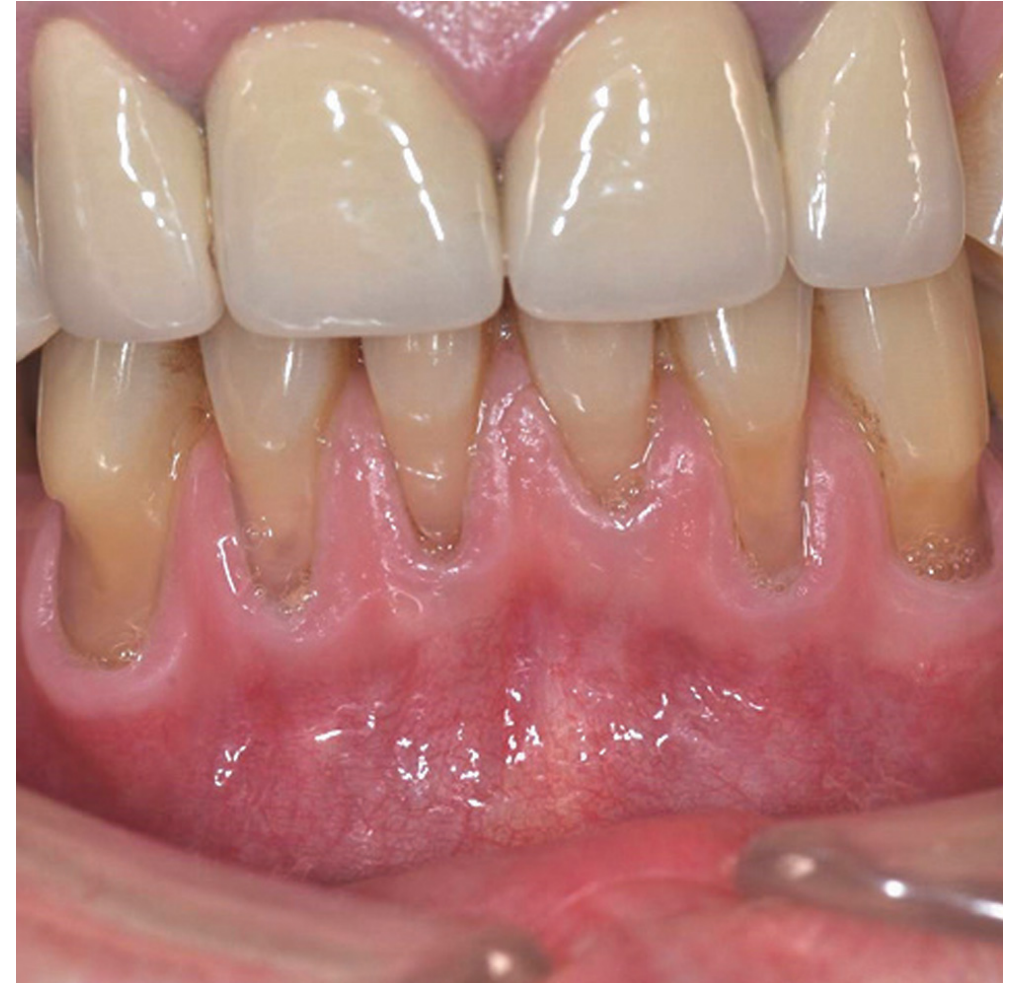Consequence: tooth loosening and ultimately tooth loss

Gingival recession in periodontitis

Normal state: in primary dentition and healthy permanent dentition up to 20'-30' – the apical end of the junctional epithelium at CEJ

Later junctional epithelium moves more apically, until it finally moves to the cementum of the tooth neck

In old age, cementum, can be exposed and a condition in which the clinical crown becomes larger than the anatomical crown



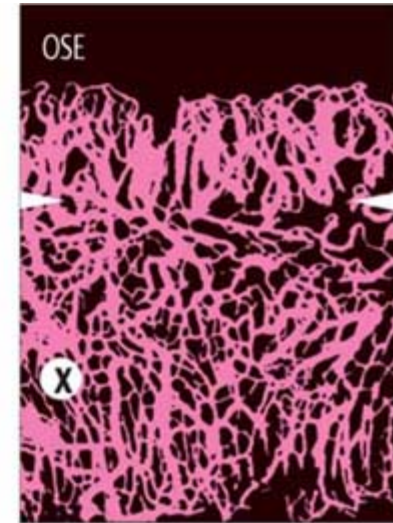
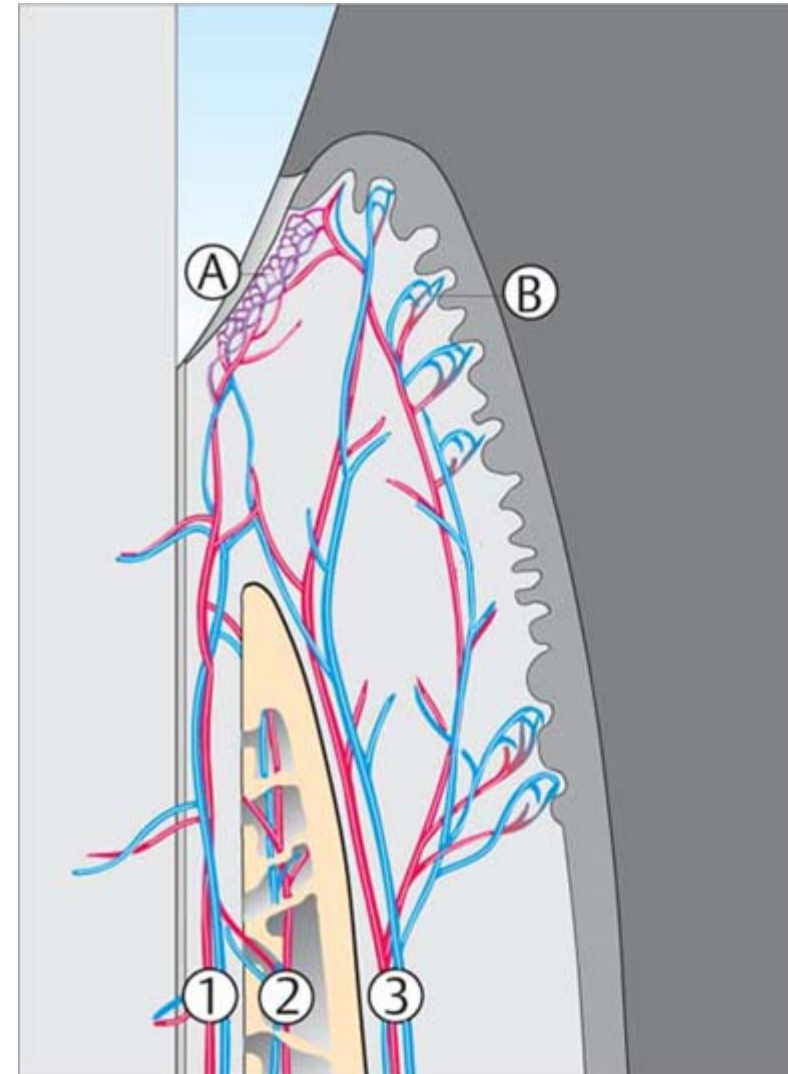
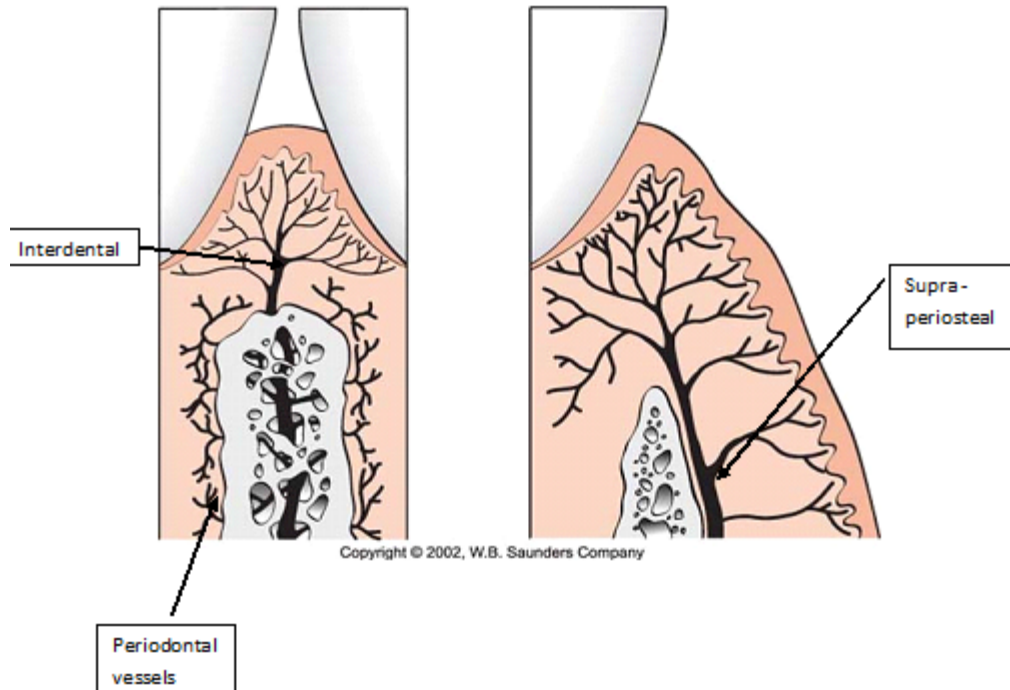
Blood supply and innervation of gingiva

Arterioles from aa. alveolares, a. mentalis, aa. palatinae, a. buccinatoria

Branch into capillary networks with anastomosis with the periodontal network

Lymphatic vessels and along the blood vessels

Nerve fibres as a free nerve endings and form corpuscles



Blood Supply Pathways

- 1 Periodontal
- 2 Alveolar
- 3 Supraperiosteal/mucogingival

A Post-capillary Venous Plexus

B Sub-epithelial Capillary Loops