

ORTHODONTICS

Diagnostic examination

MUDr. Alena Bryšová, Ph.D.



Diagnostic examination

1. ANAMNESIS

a] Family anamnesis

- dental problems of parents
- orthodontic anomalies of parents
- genetic health problems



Diagnostic examination

1. ANAMNESIS

b] health anamnesis of the patient

- medicaments
- allergy
- facial and dental injury
- contagious disease



Diagnostic examination

1. ANAMNESIS

c] special anamnesis of the patient

- frenulectomy
- adenotomy
- habits
- mouth breathing



Diagnostic examination

2. CLINICAL EXAMINATION

a] extraoral examination

- profile [convex, concave, straight]
- face symmetry
- temporomandibular joints



Diagnostic examination

2. CLINICAL EXAMINATION

b] intraoral examination

- Status of dentition, caries, fillings
- Anomalies of the relationship of dental arches –
Angles classification
- Overjet, overbite
- Status of oral soft tissues, frenulum
- Functional examination, centric occlusion
- hygiene



Diagnostic examination

3. MODEL EXAMINATION

- space analysis, discrepancy
- arch form
- dental anatomy
- intercuspidation



Diagnostic examination

4. RADIOGRAPHS

a] Panoramic

- detection of congenital absences of teeth
- detection of supernumerary teeth
- evaluation of the dental health of the permanent teeth
- assessment of trauma to the teeth after injury
- determination of dental age of the patient
- calculation of root resorption
- condyles







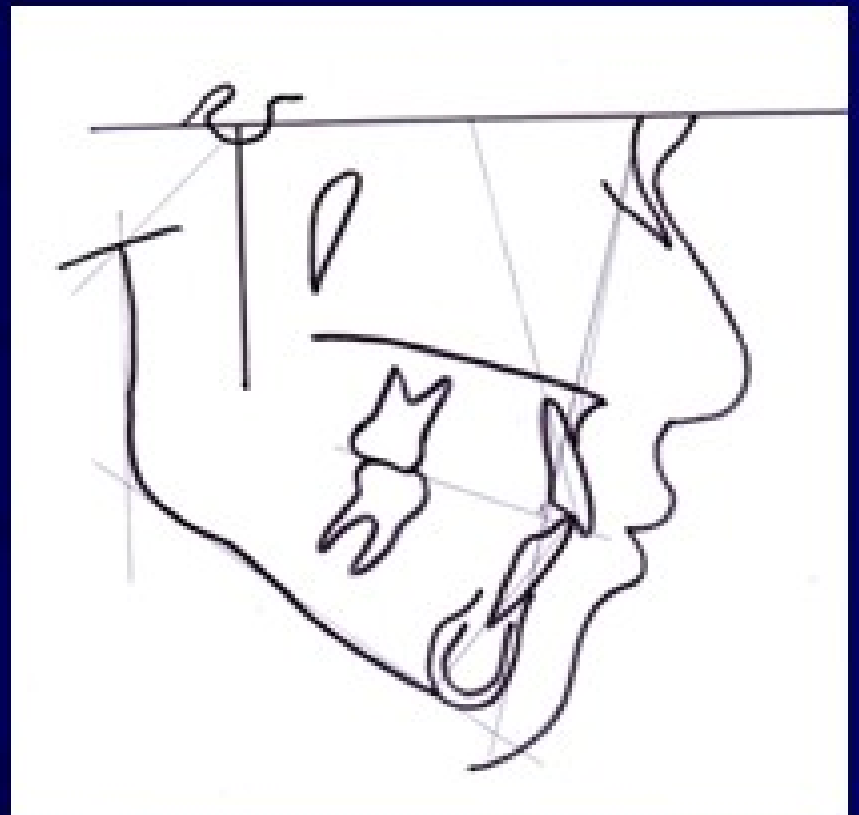
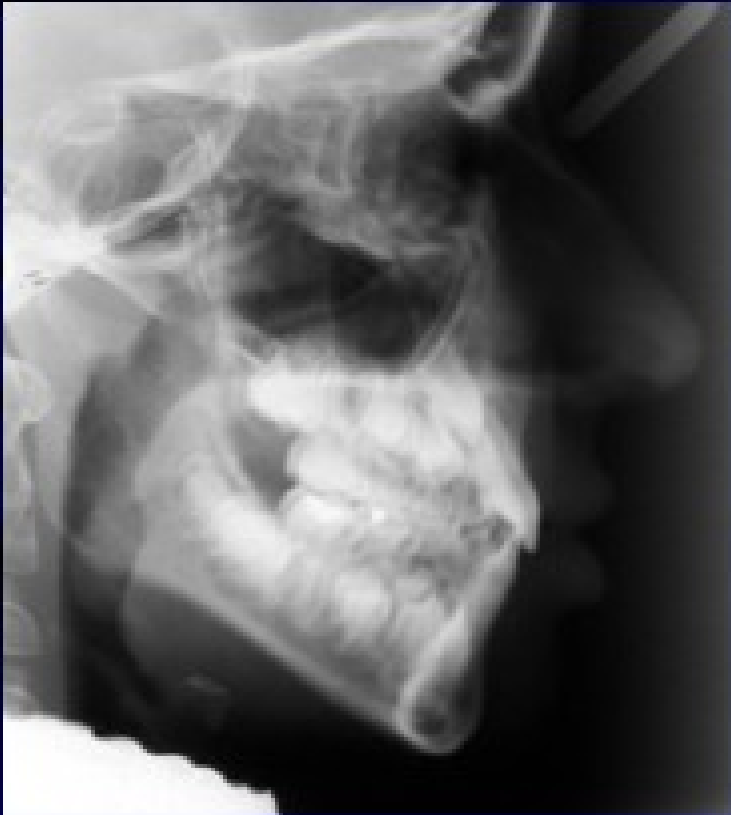Diagnostic examination

4. RADIOGRAPHS

b] Cephalometric radiographs

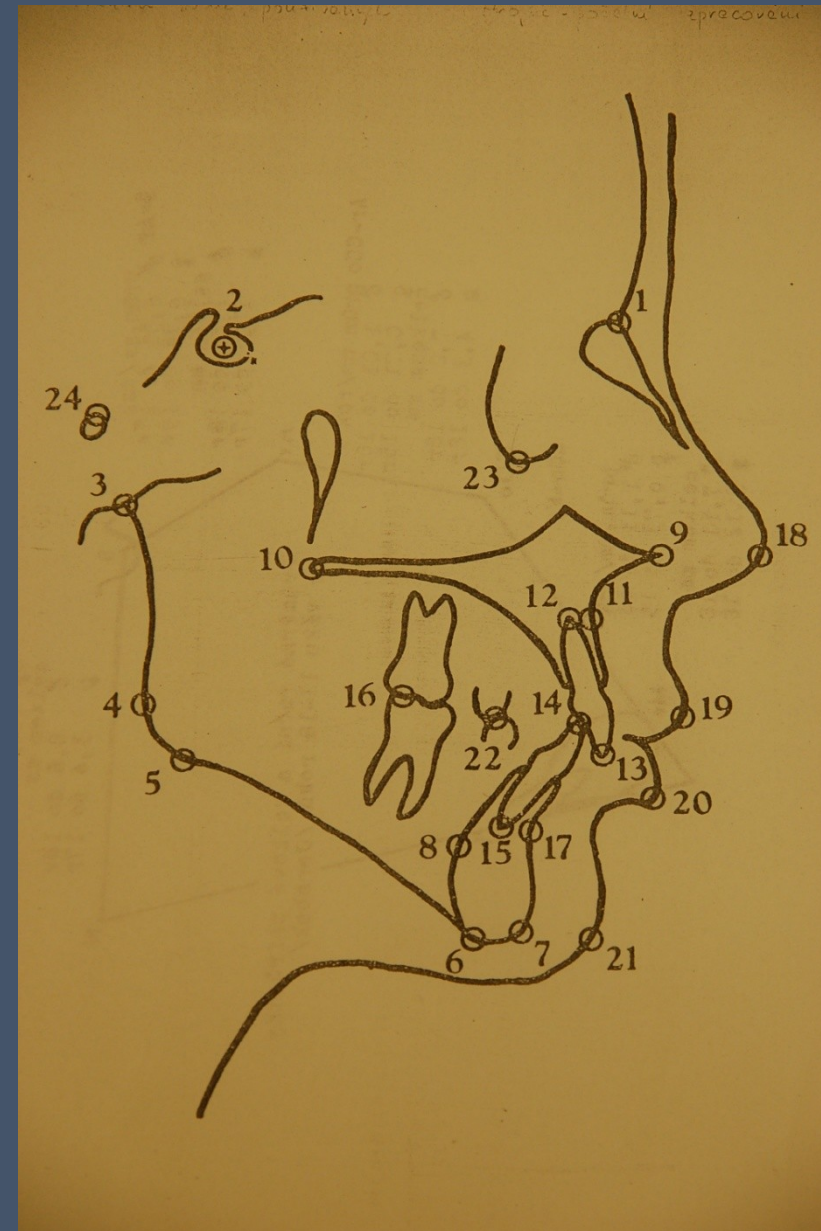
- evaluation of craniofaciodental relationship
- assessment of the soft tissue matrix
- determination of mandibular position
- prediction of growth and development
- detection of skeletal age



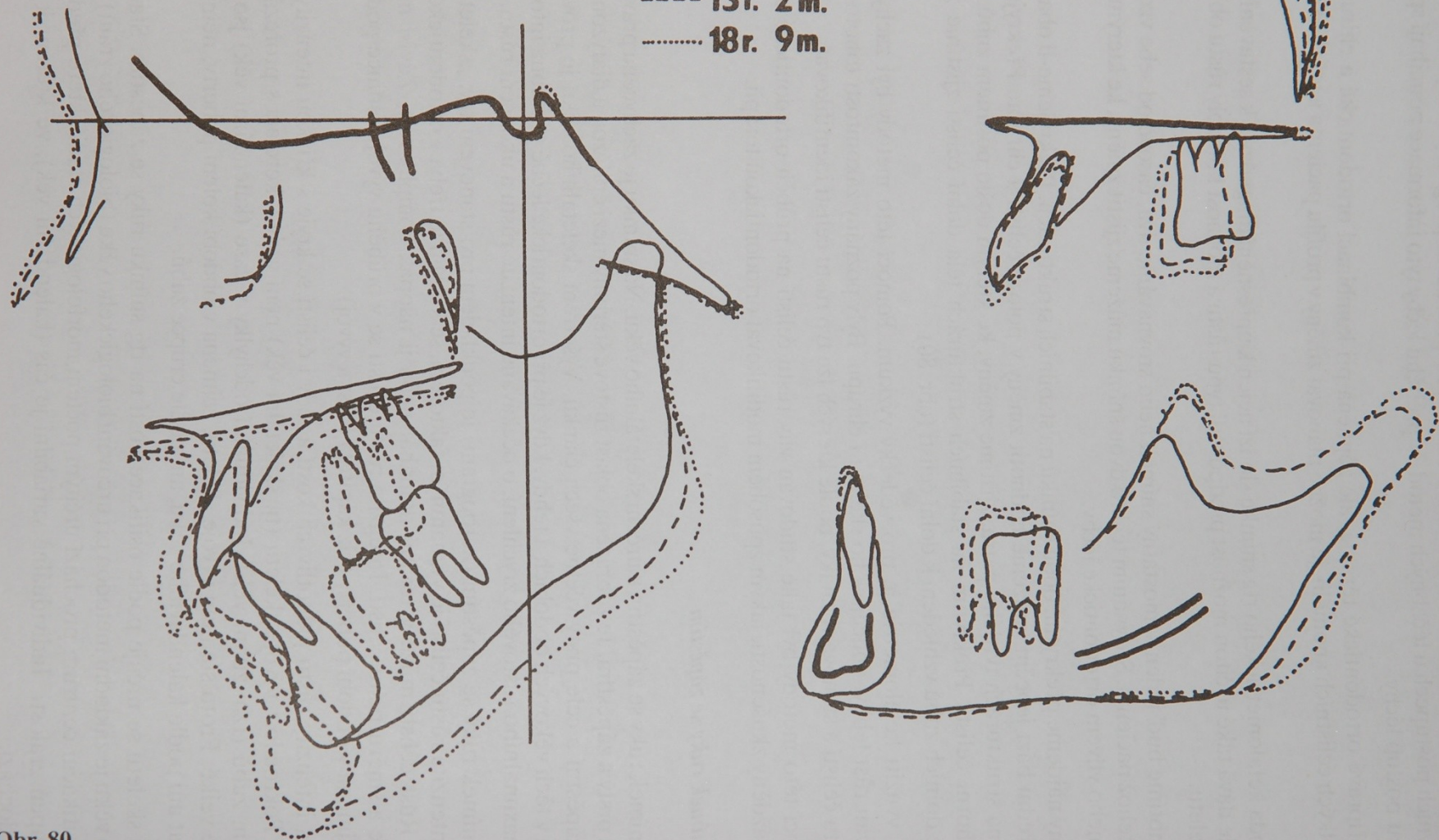


ANALÝZA KEFALOMETRICKÉHO SNÍMKU

- N - nasion (1)
- S - sella (2)
- a - articulare (3)
- Me - menton (6)
- Po - pogonion (7)
- SpA - spina nasalis ant. (9)
- SpP - spina nasalis post. (10)
- A - bod A (11)
- Is' - apex horního středního řezáku (12)
- Is - incisale superius (13)
- Ii - incisale inferius (14)
- Ii' - apex dolního řezáku (15)
- B - bod B (17)
- Go - gonion (kontr. bod: 1. a-4, 2. ML)
- Gn - gnation (konstr. bod: 1. N-Po, 2. ML)
- ML - mandibulární linie (Me-5)
- FOL - funkční okluzální linie

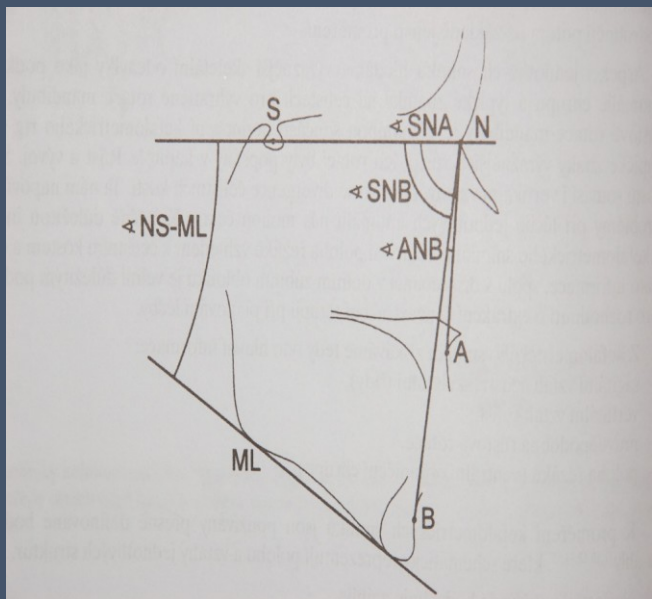


— 9r. 2m.
- - - 13r. 2m.
· · · · · 18r. 9m.



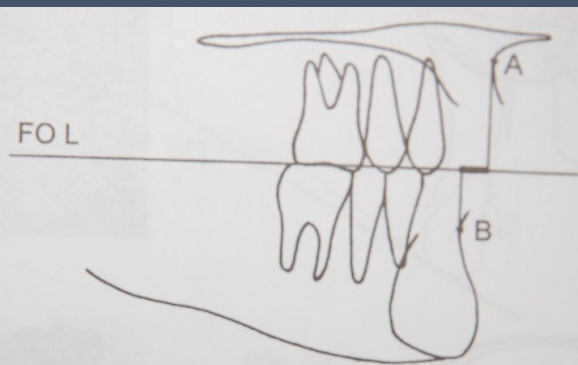
Obr. 80





skeletal analysis

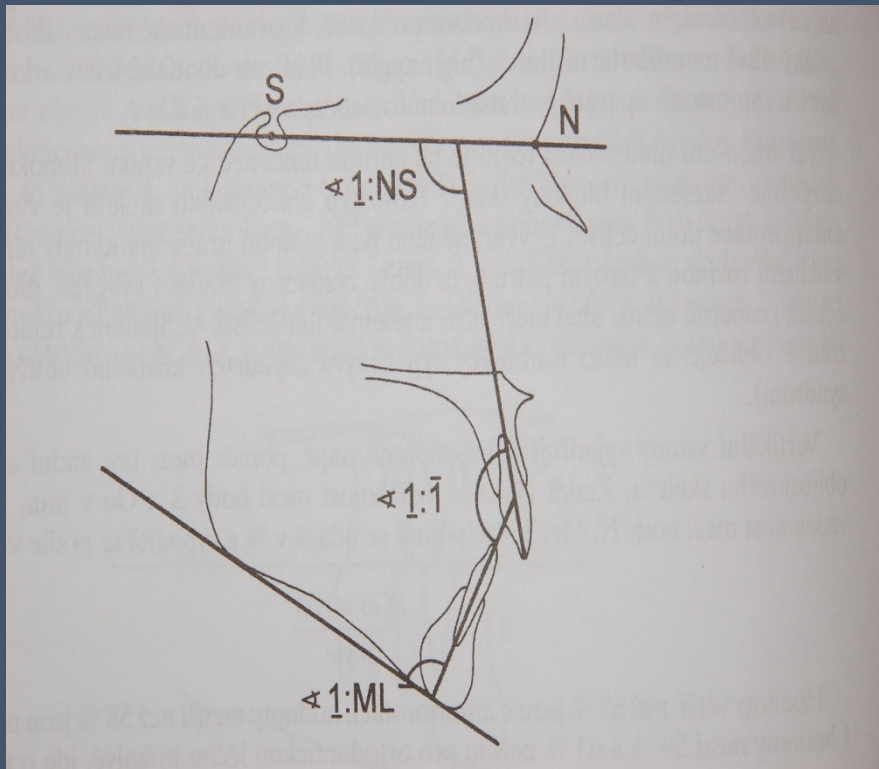
- ANB (-1 až +5 stupňů)



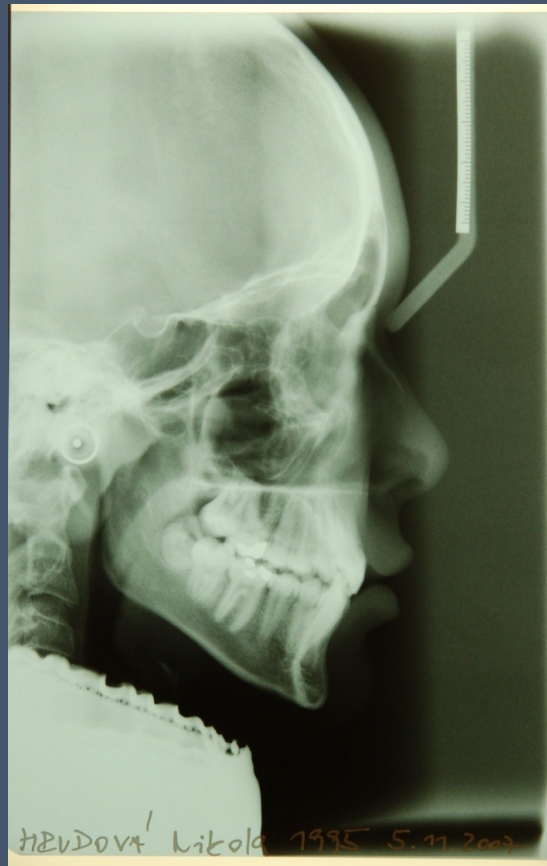Obr. 74
Rozměr WITS.

- WITS (-2 až +2)



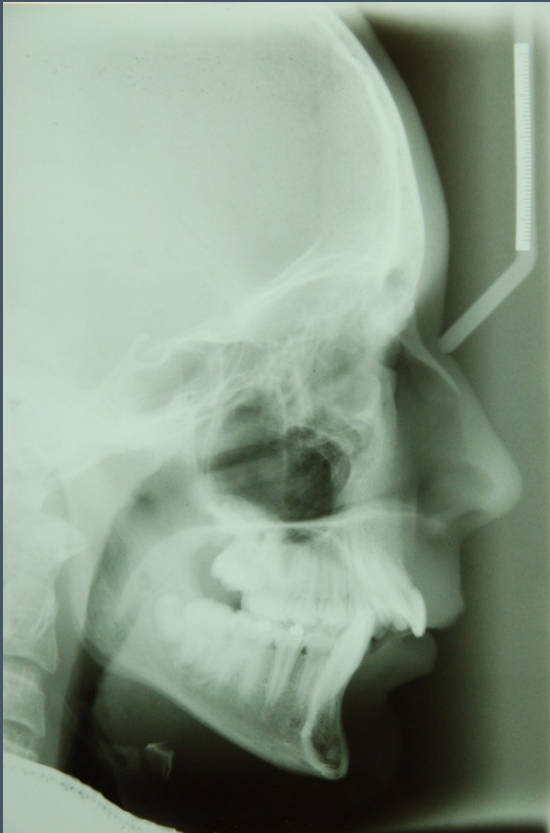

Skeletal class I

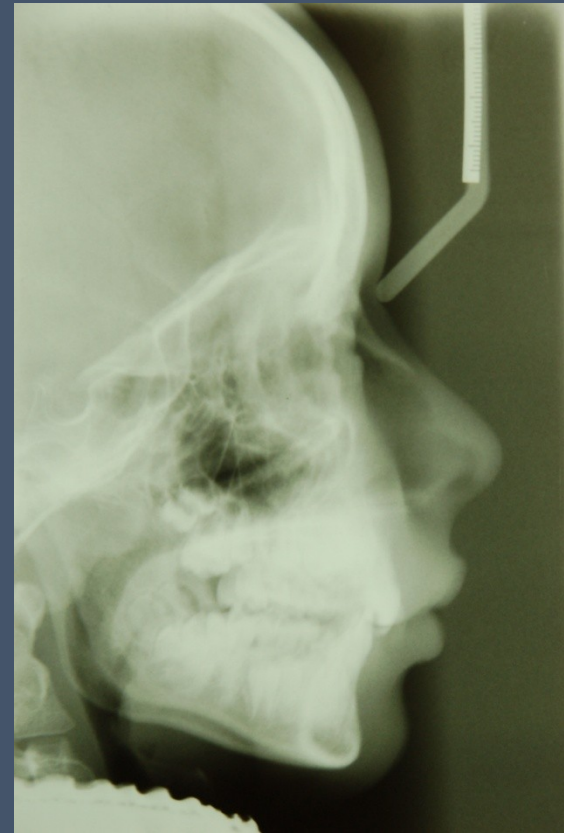

Skeletal class II

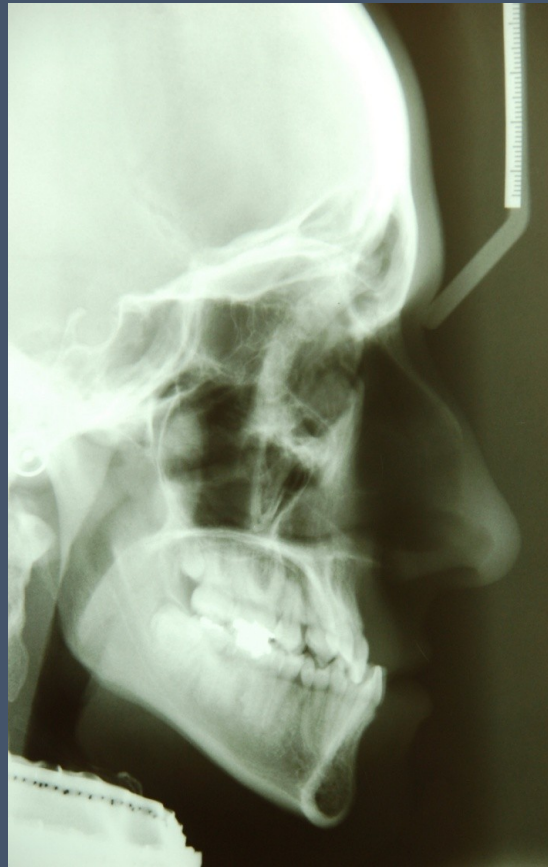div. 1 with protrusion



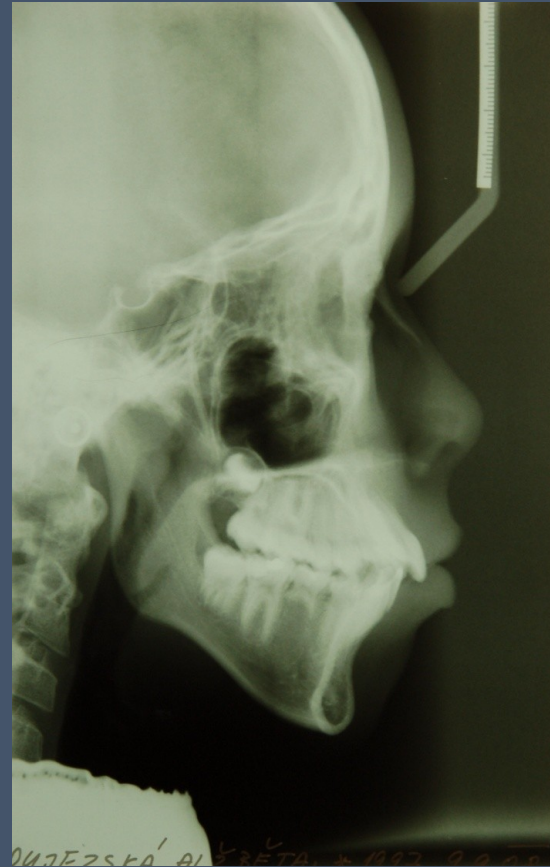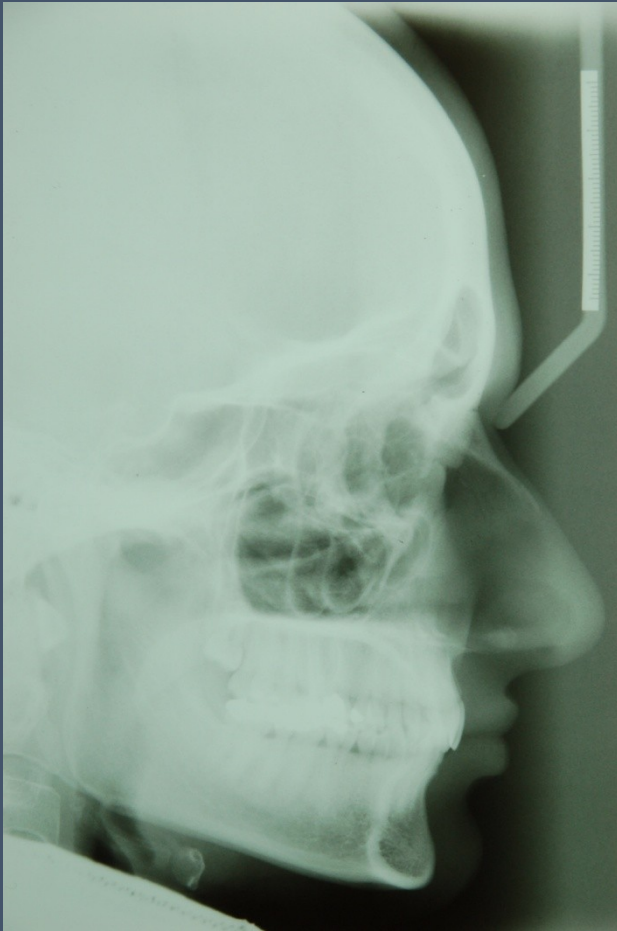div. 2 - with retrusion



Skeletal class III



Bimaxillary protrusion



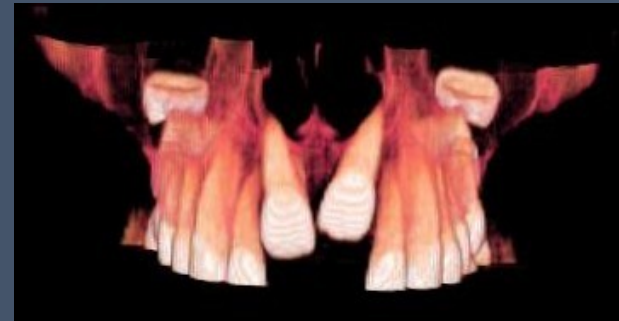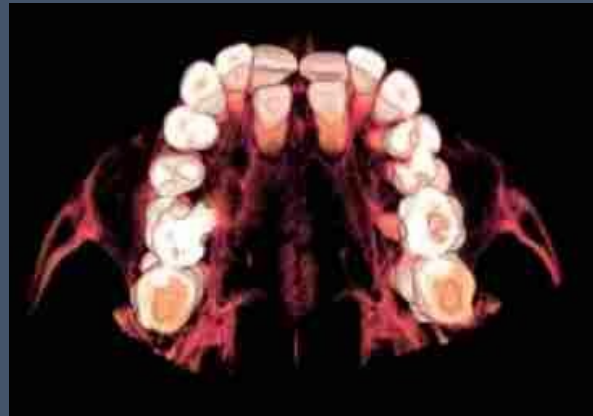
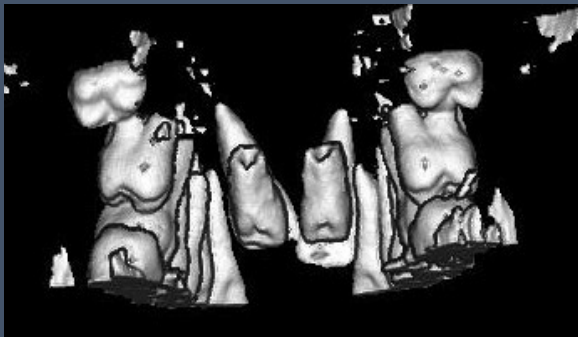
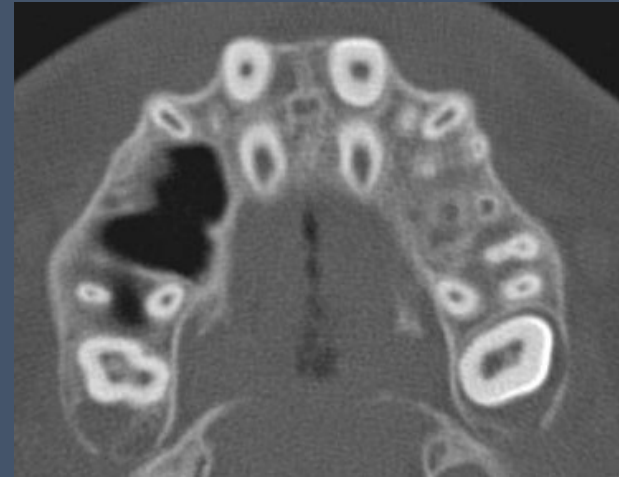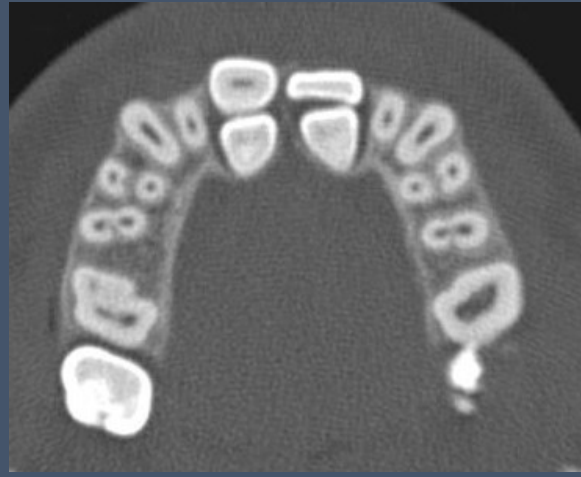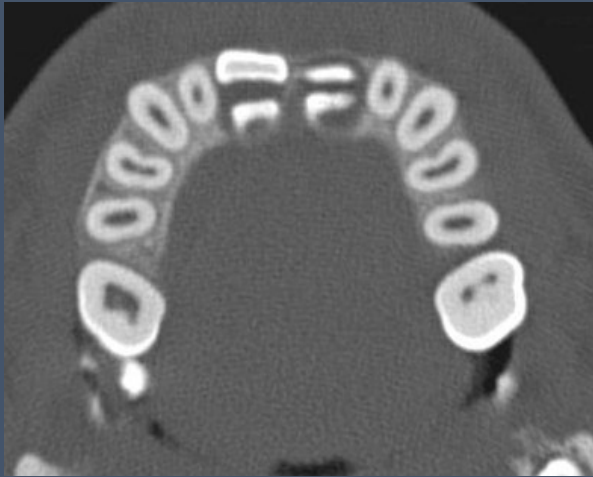
Diagnostic examination

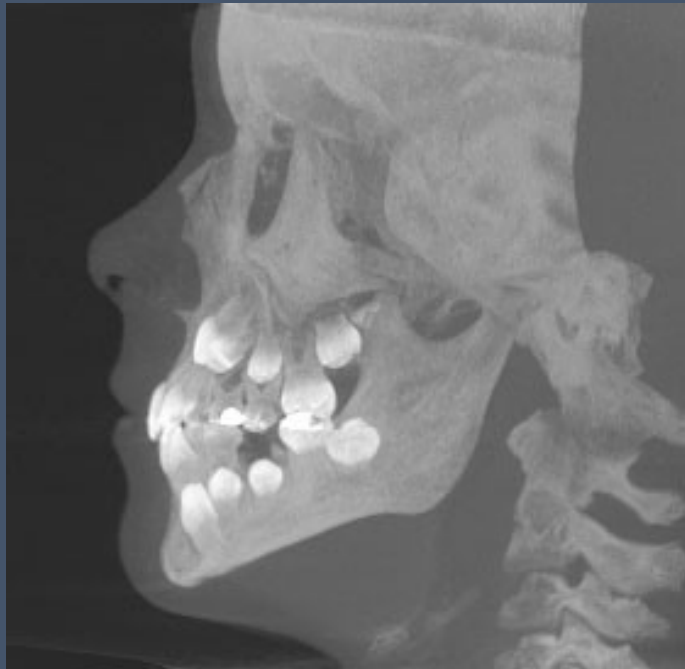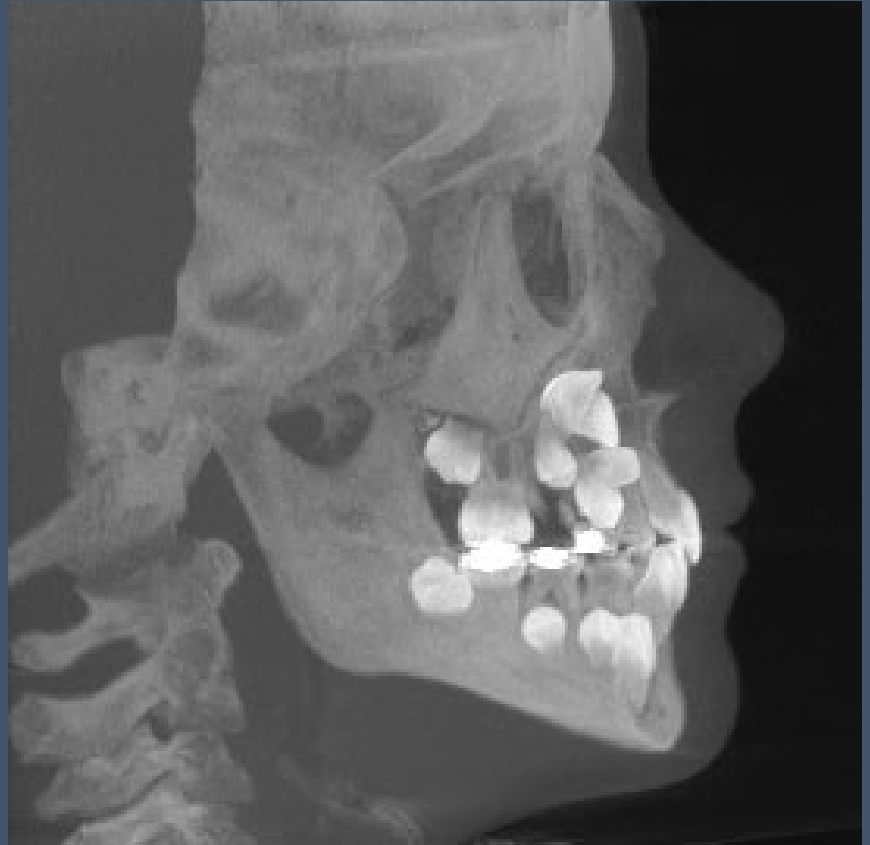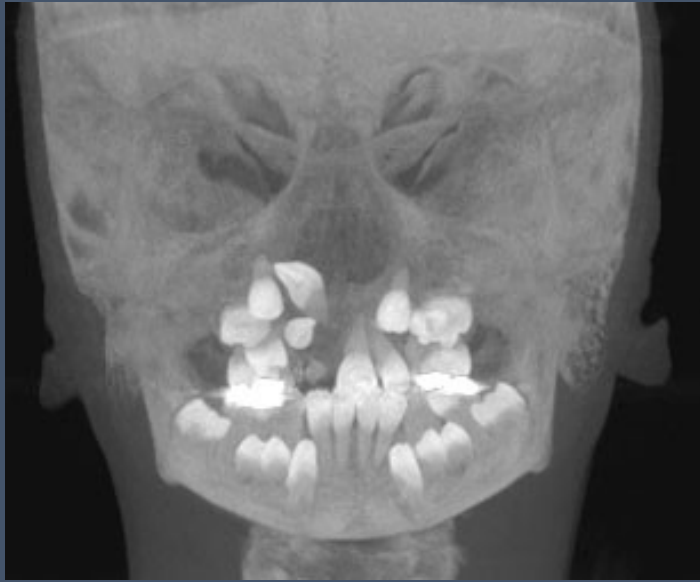4. RADIOGRAPHS

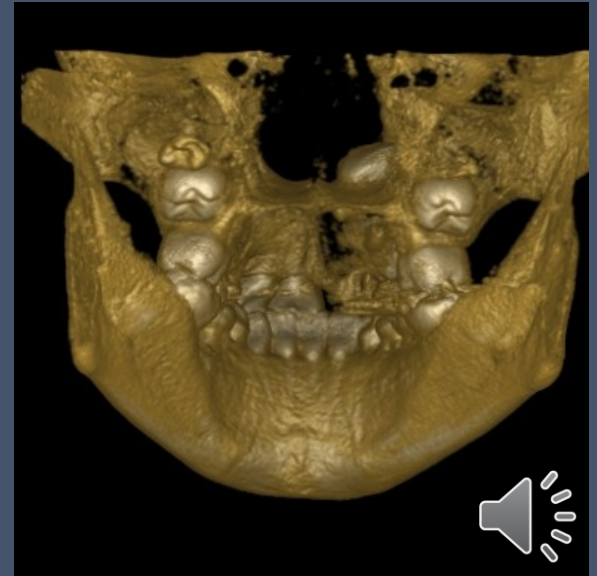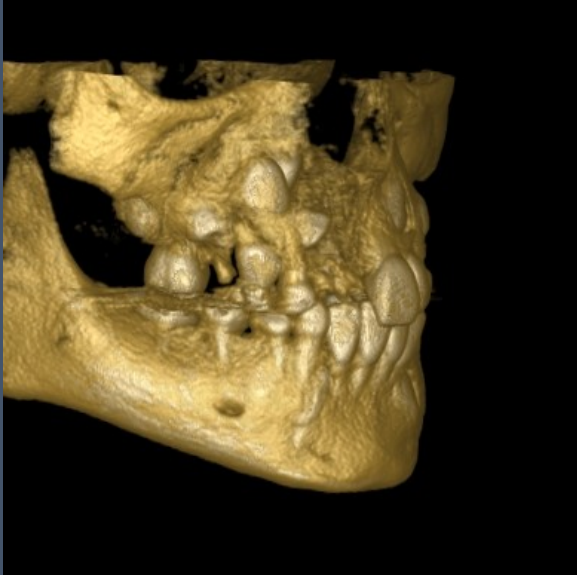
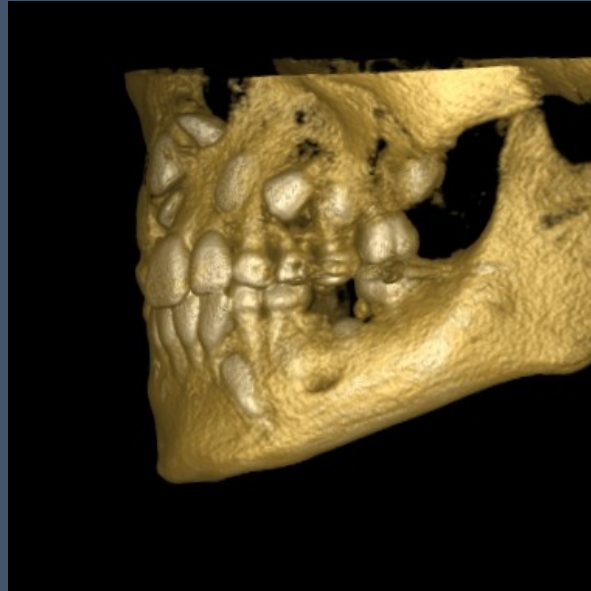
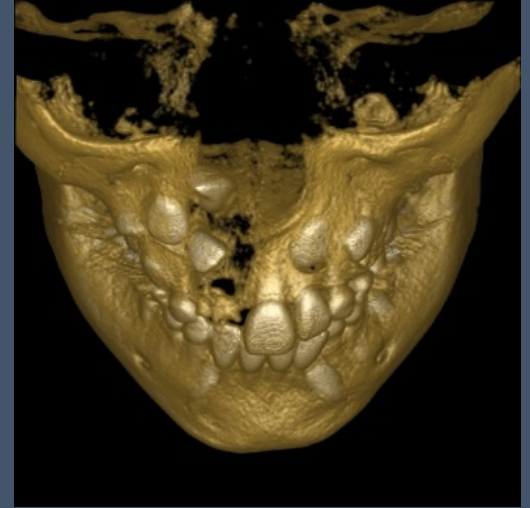
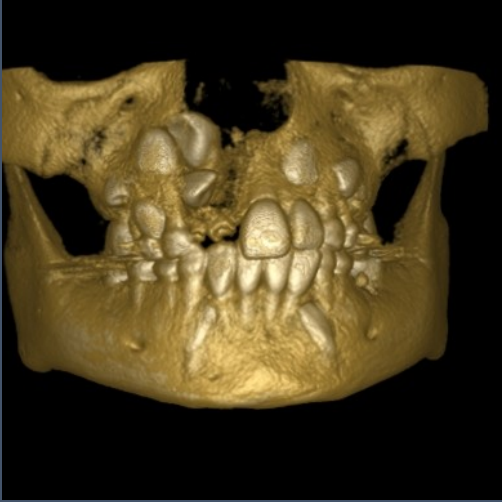c] Other radiographs

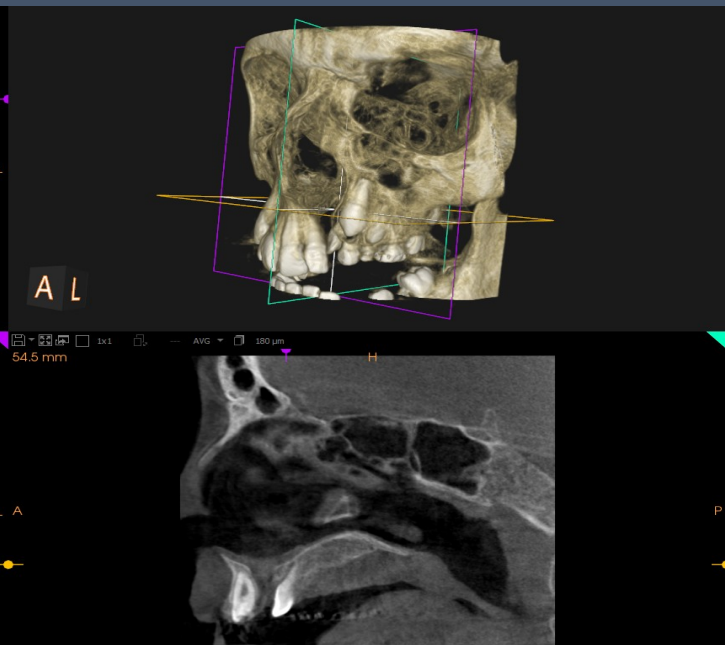
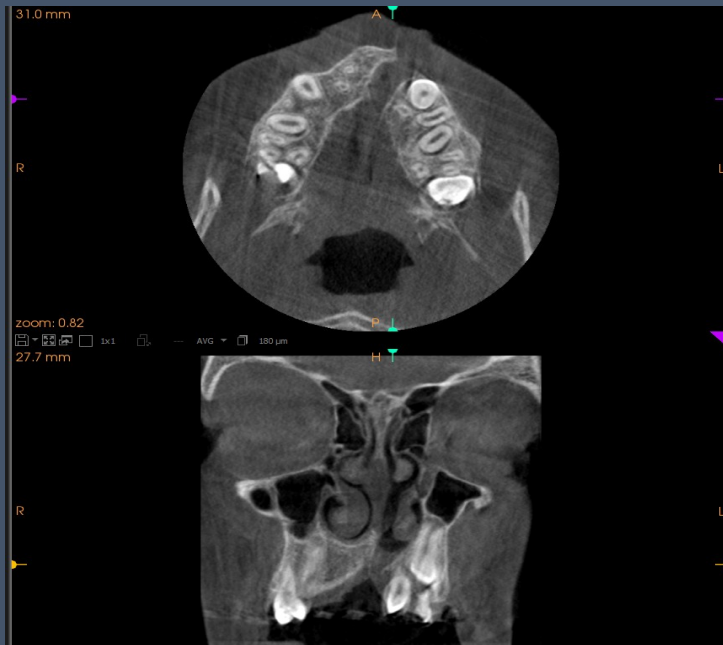
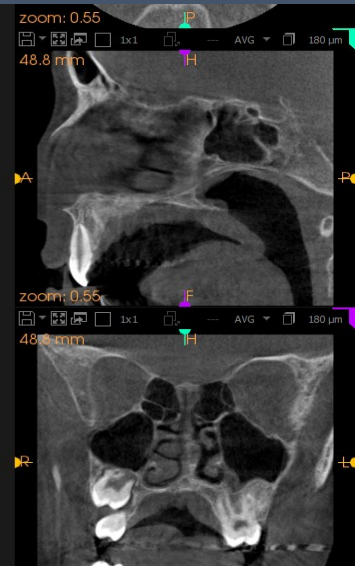
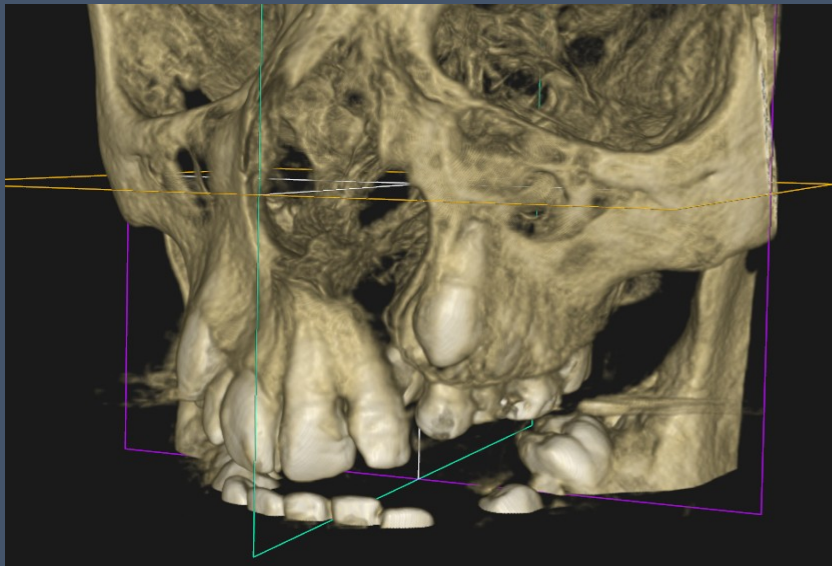
- Bitewing – caries detection
- Hand wrist – detection of skeletal age
- Computer tomography –CT scan [impacted tooth, ankylosed tooth, difficult skeletal anomalies
- Digital imaging – computer generated model reconstructed from the initial imaging data









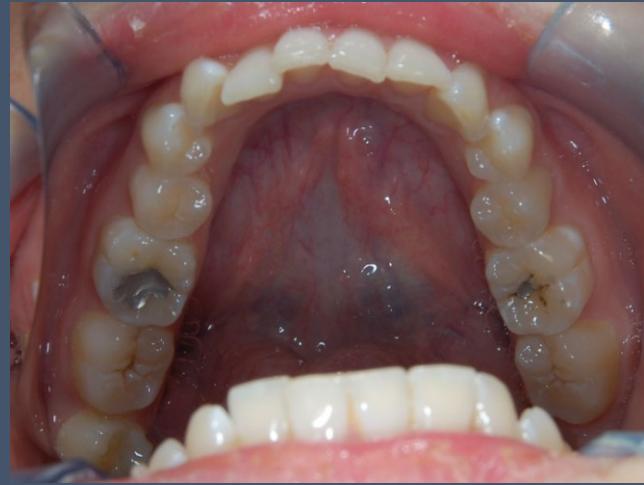
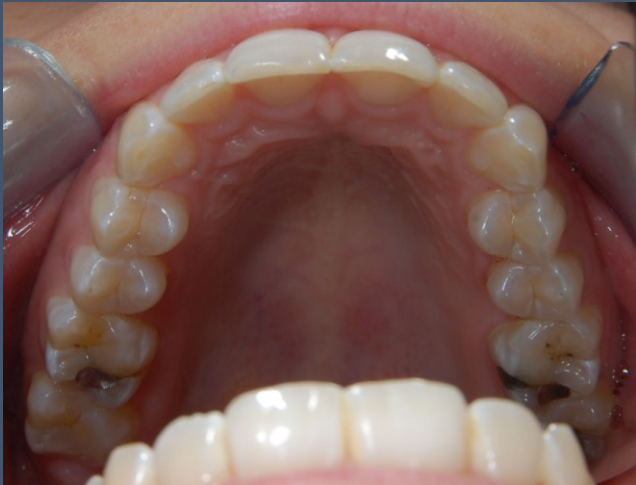
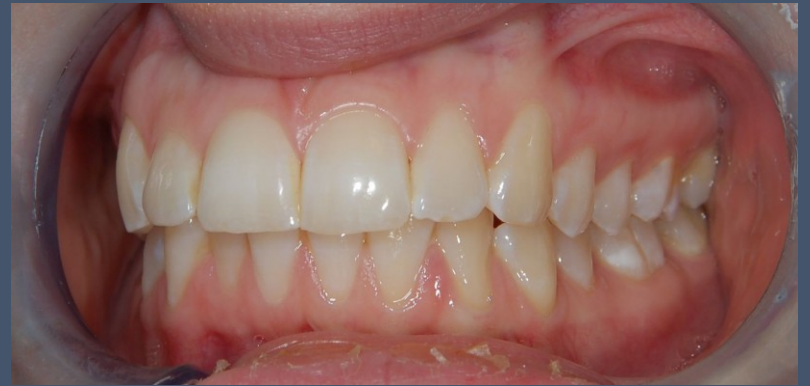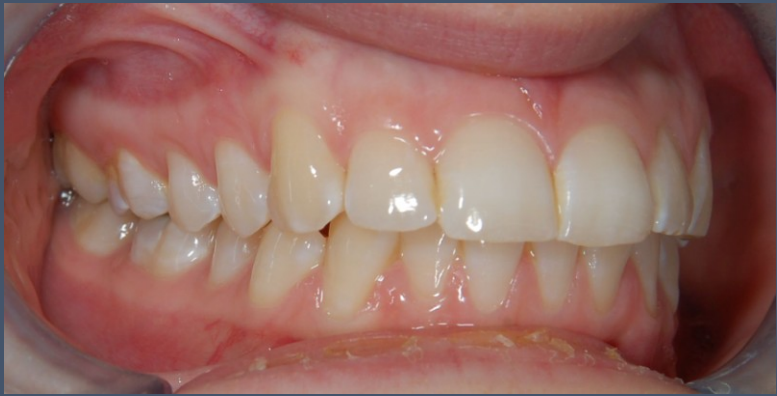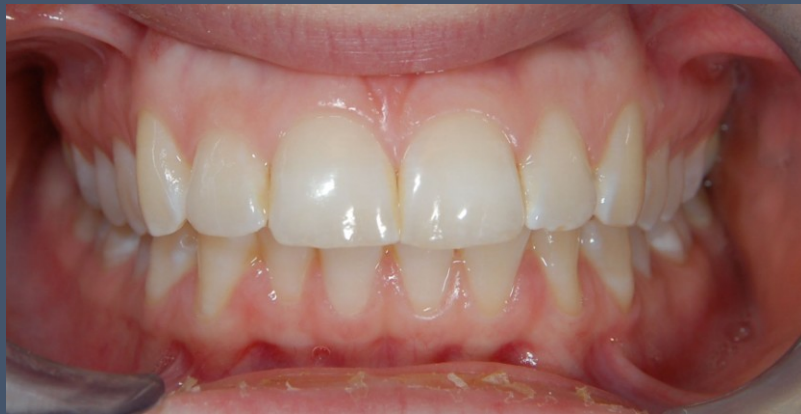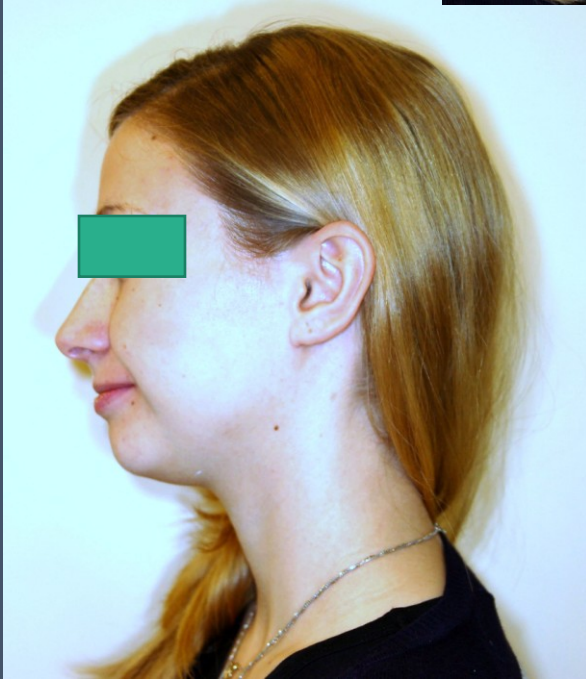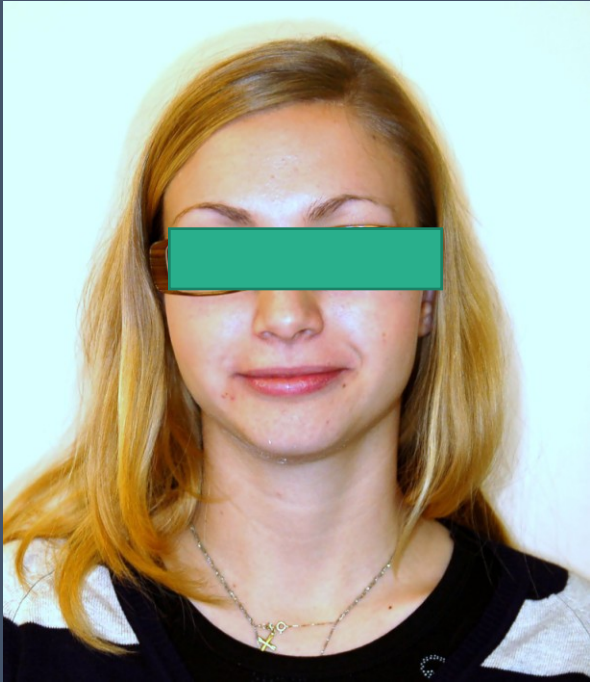Diagnostic examination

5. PHOTOGRAPHS

- extraoral photographs - frontal
 - profile
 - smile
- Intraoral photographs - frontal teeth
 - right and left side
 - upper and lower arch



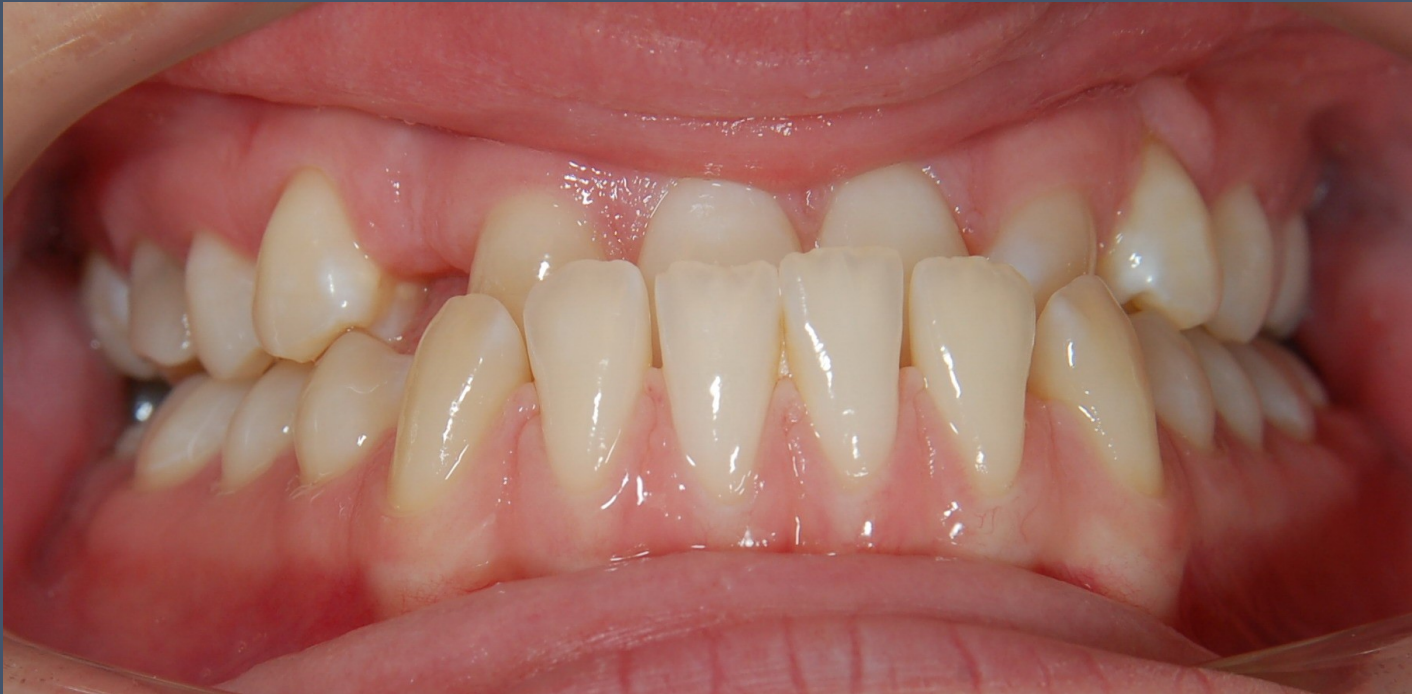



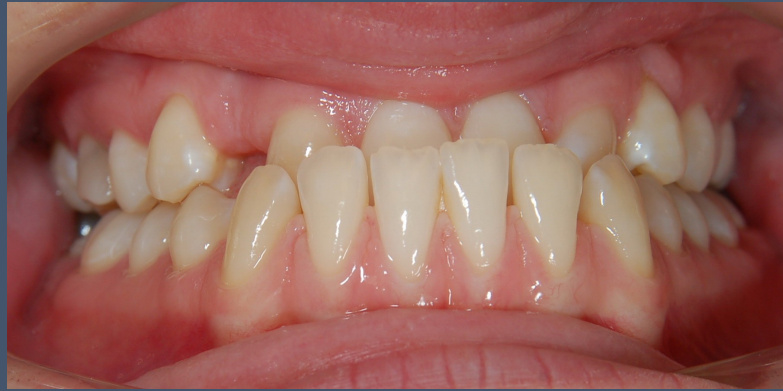try to diagnose orthodontic anomalies



Case 1- ?



Case 1



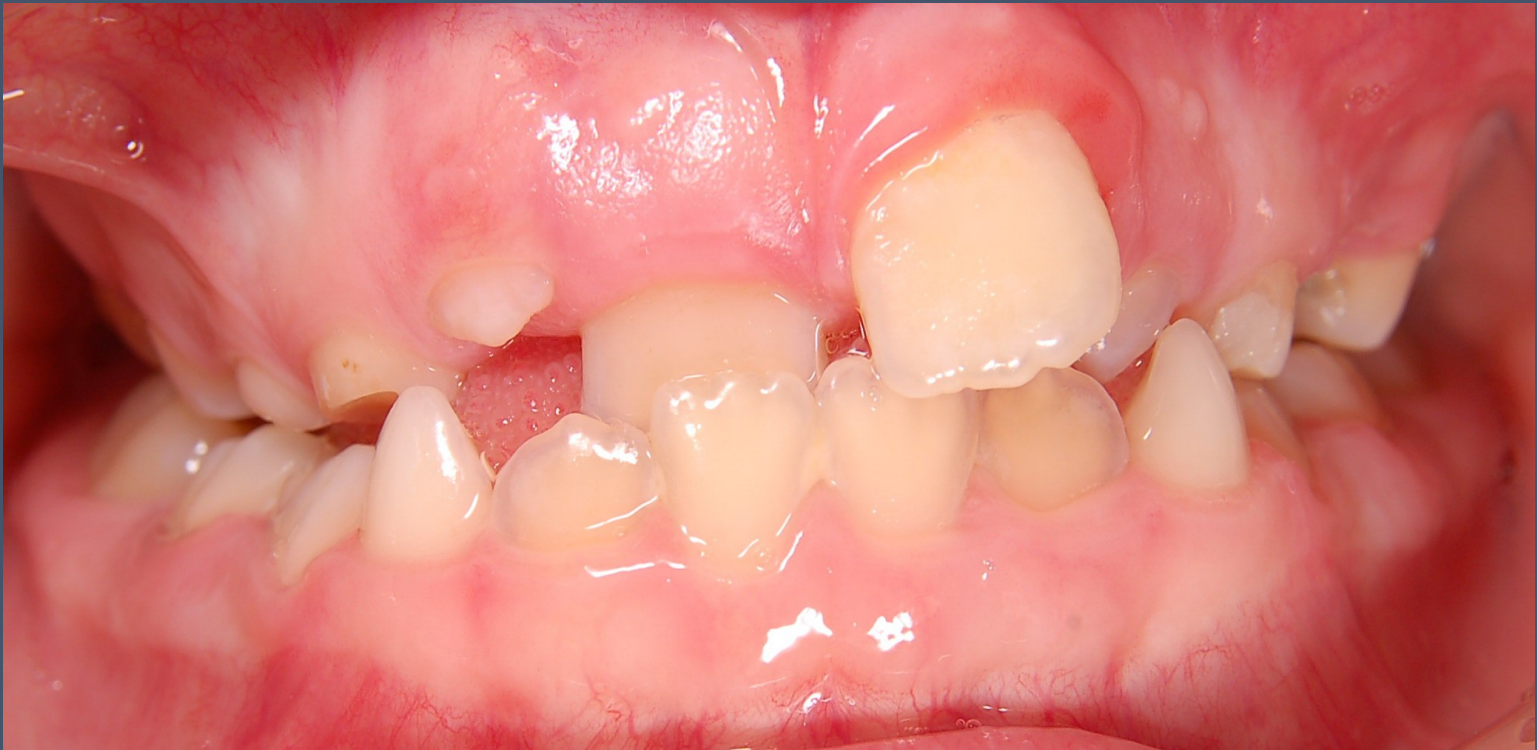Inverted bite

Shifted midline

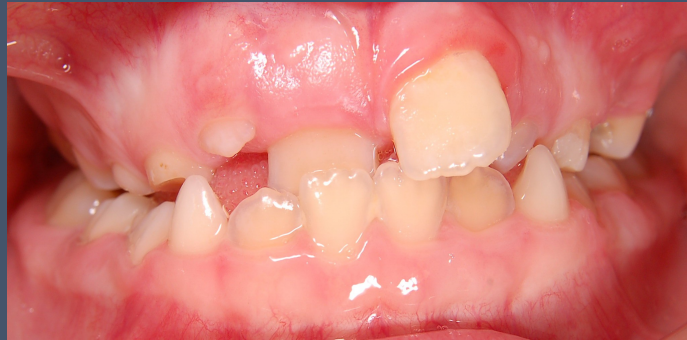Missing 13,23



Case 2 -?



Case 2



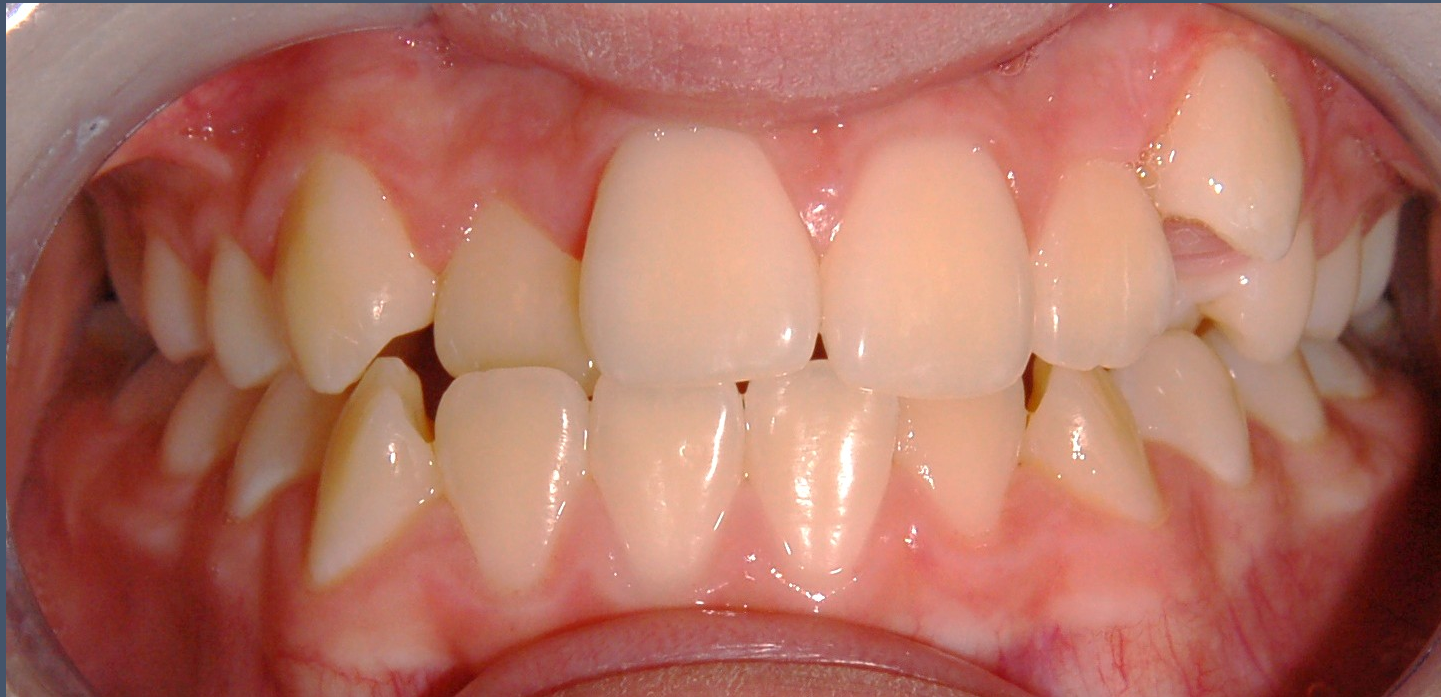Anterior cross bite 11, 22

Protrusion of 21

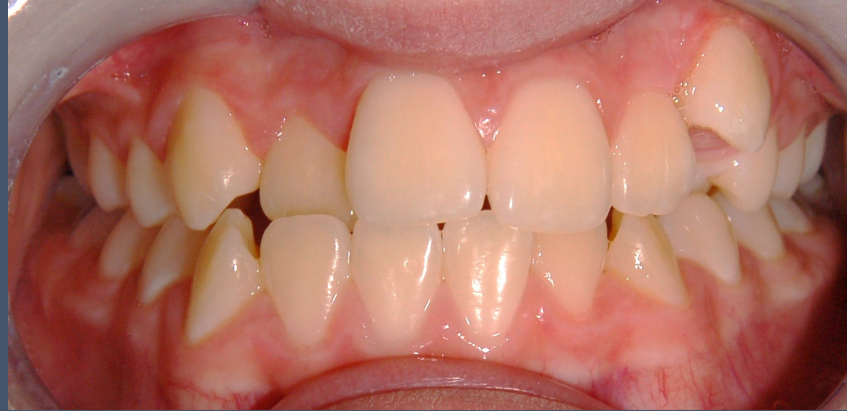Mixed dentition



Case 3 - ?



Case 3



Crowding

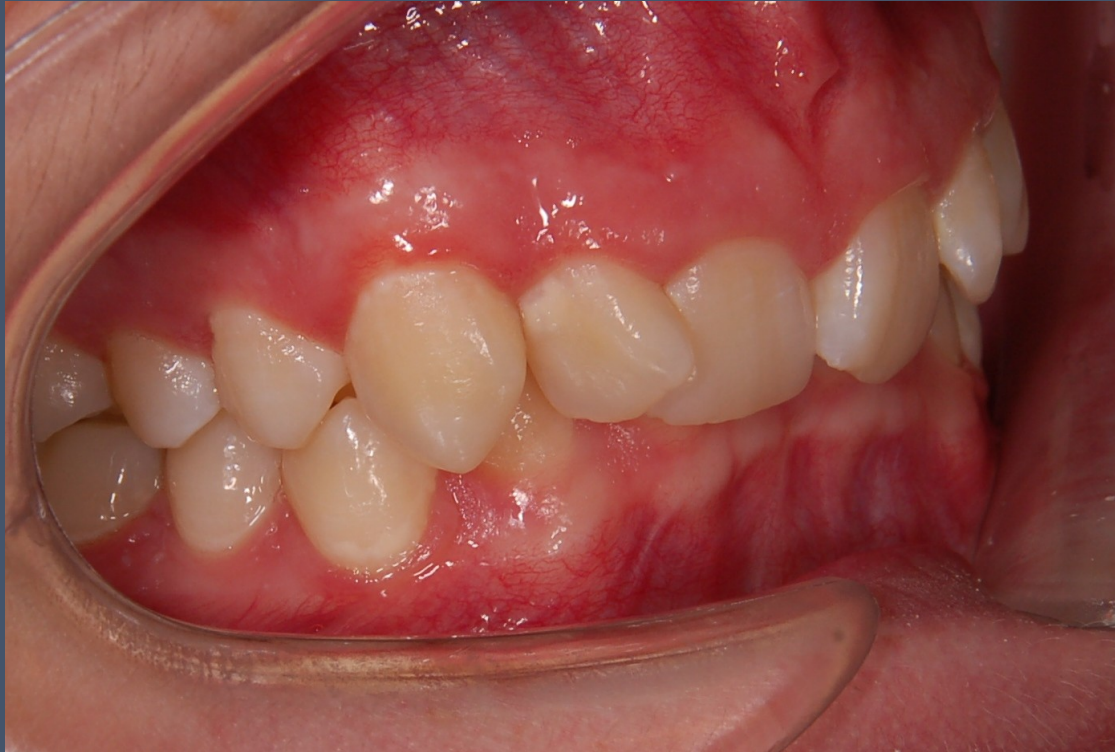Shifted midline

Vestibular eruption 23

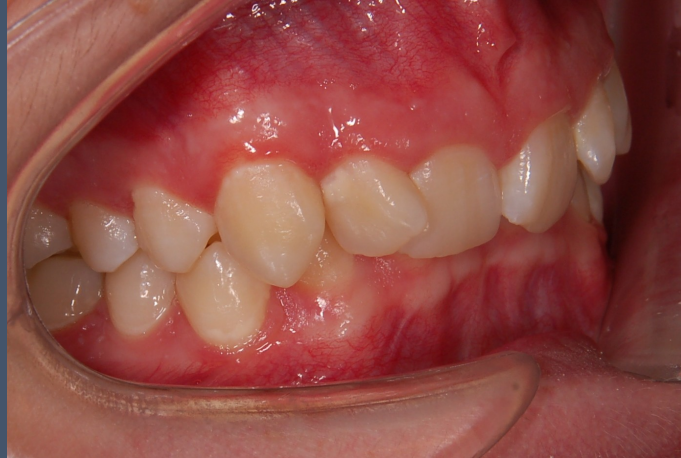Anterior cross bite 12



Case 4 -?



Case 4



Deep bite

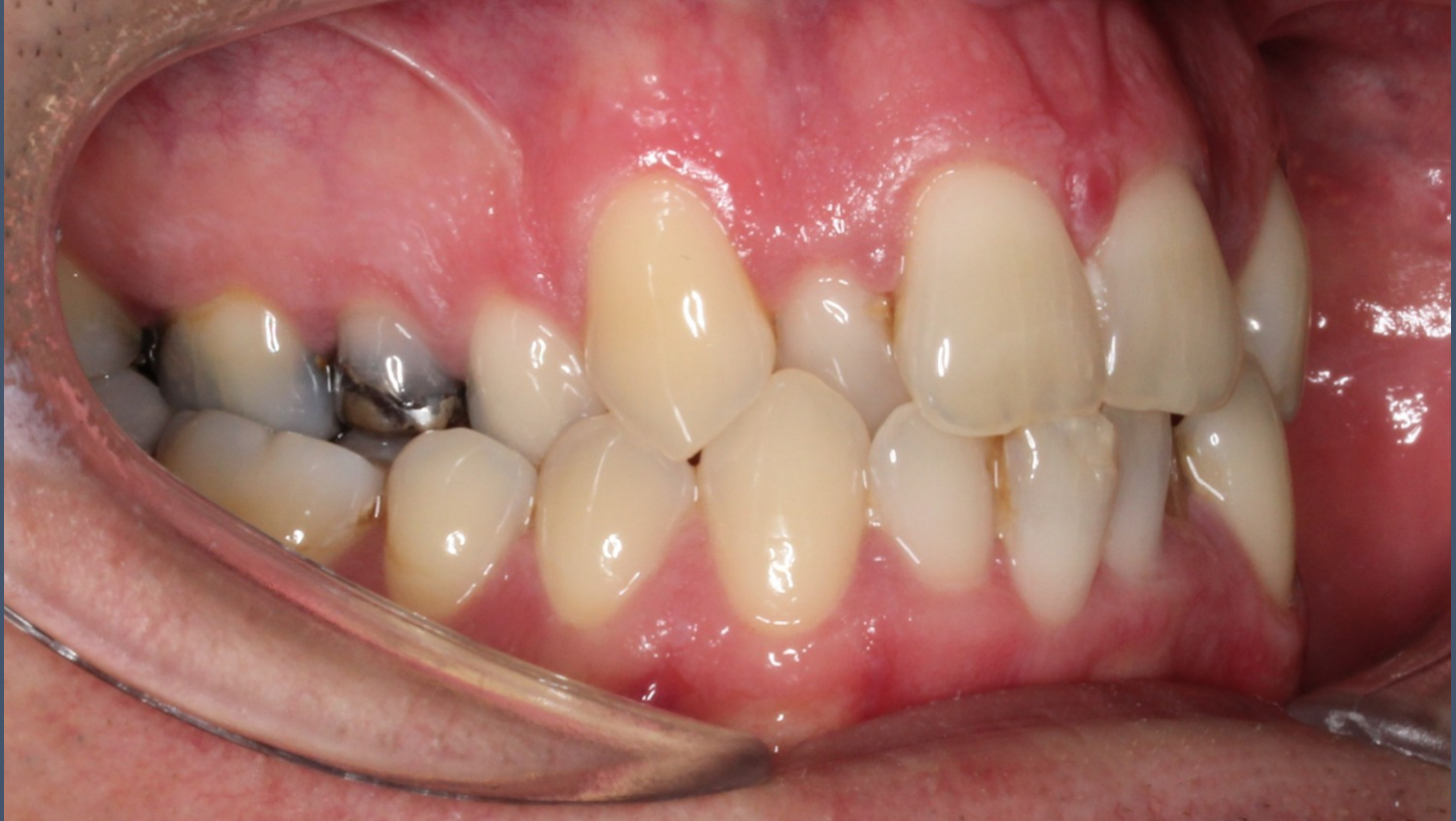Angle class I

Crowding

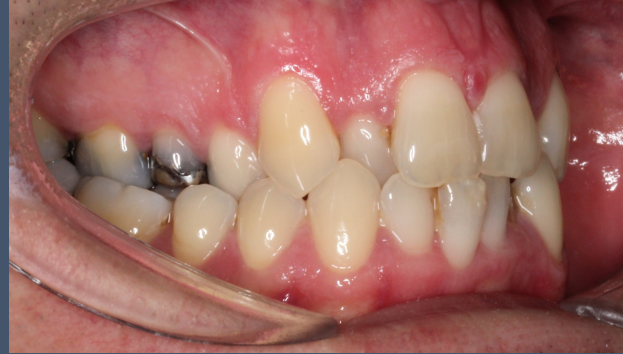Mesial inclination 12, 21



Case 5 - ?



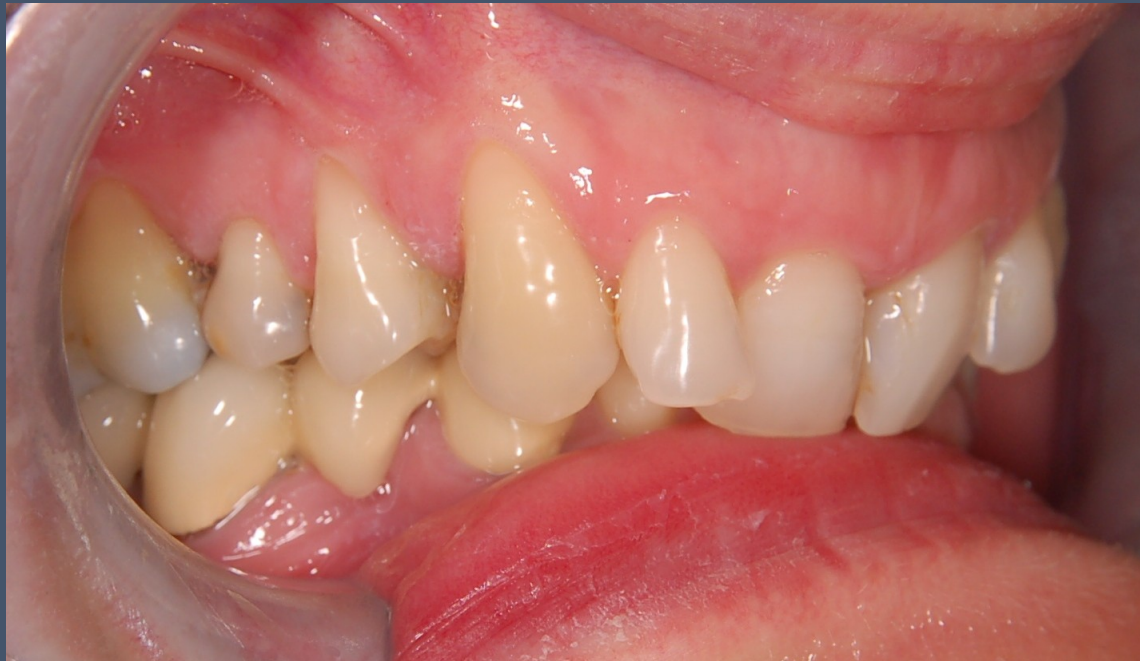Case 5



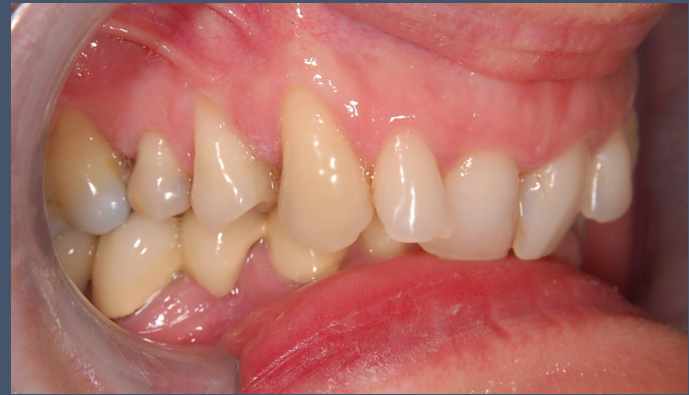Lateral Cross bite
Crowding
Angle class I



Case 6 - ?



Case 6



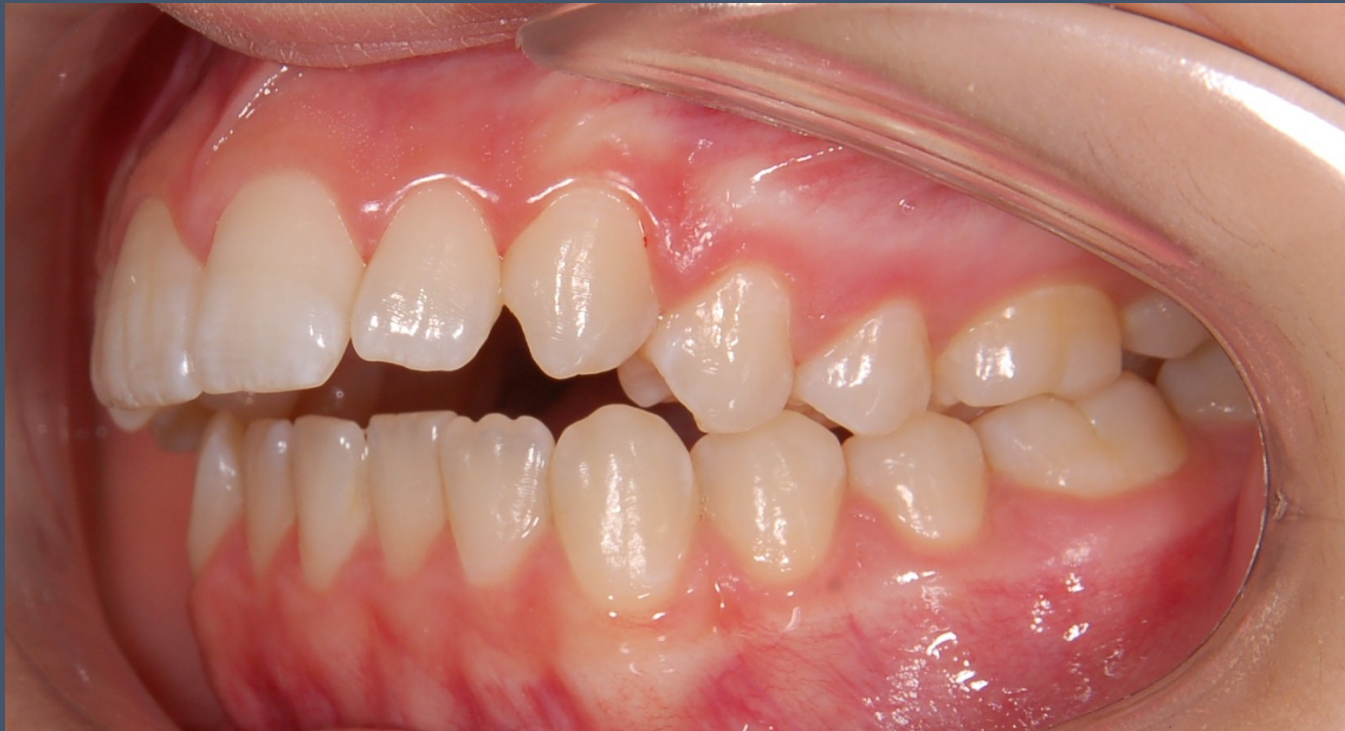Deep bite

Angle class I

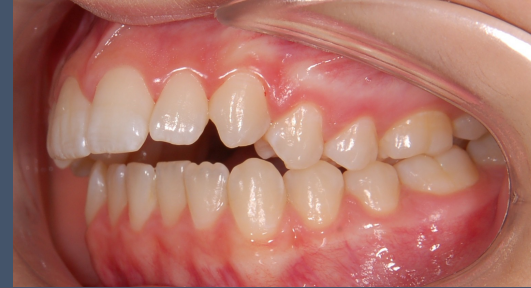Retrusion 11, 21



Case 7 - ?



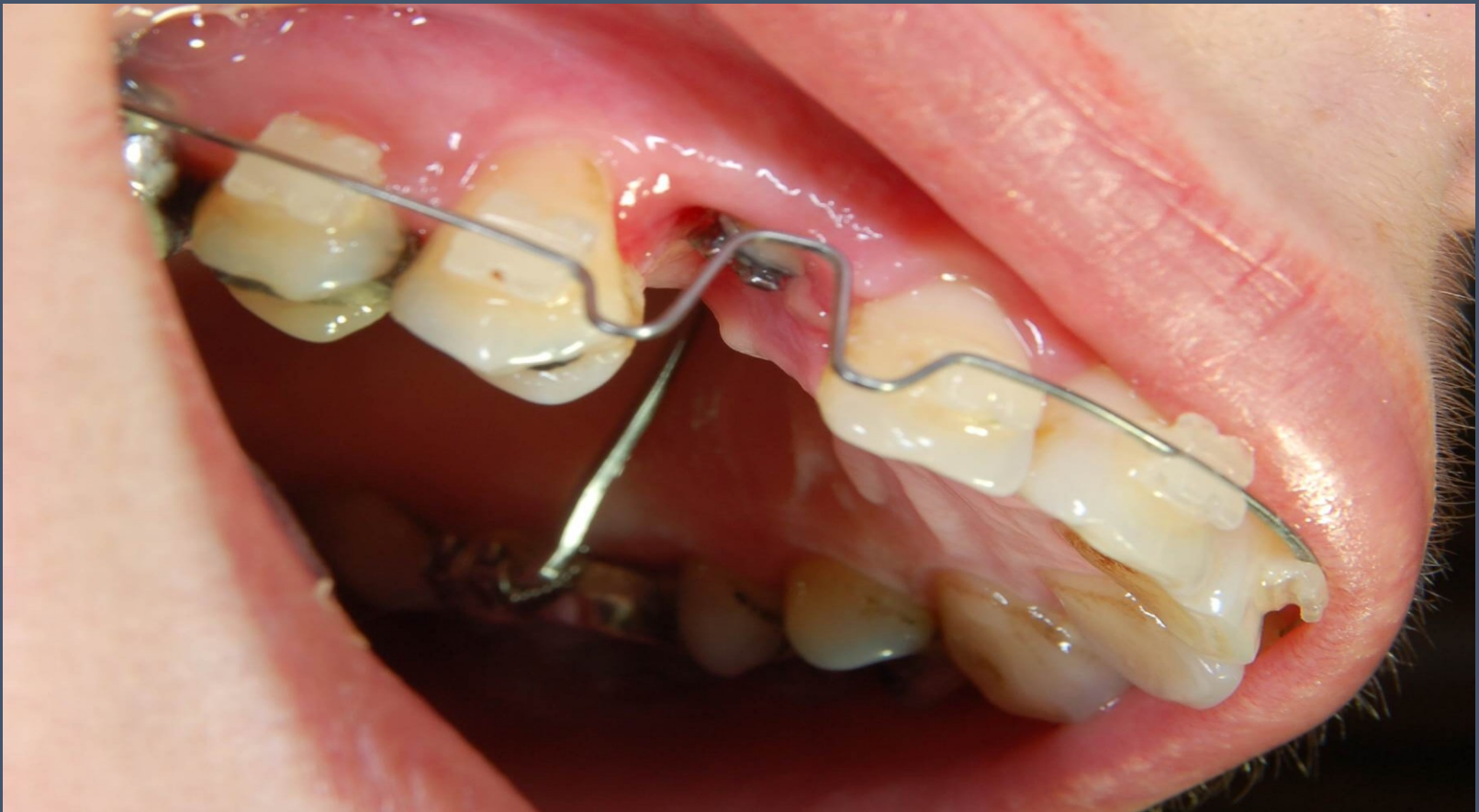Case 7



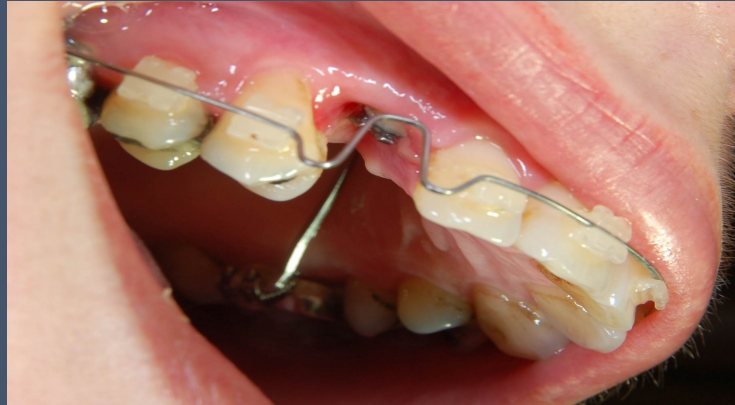Open bite
Angle Class II
Protrusion upper incisors



Case 8 - ?



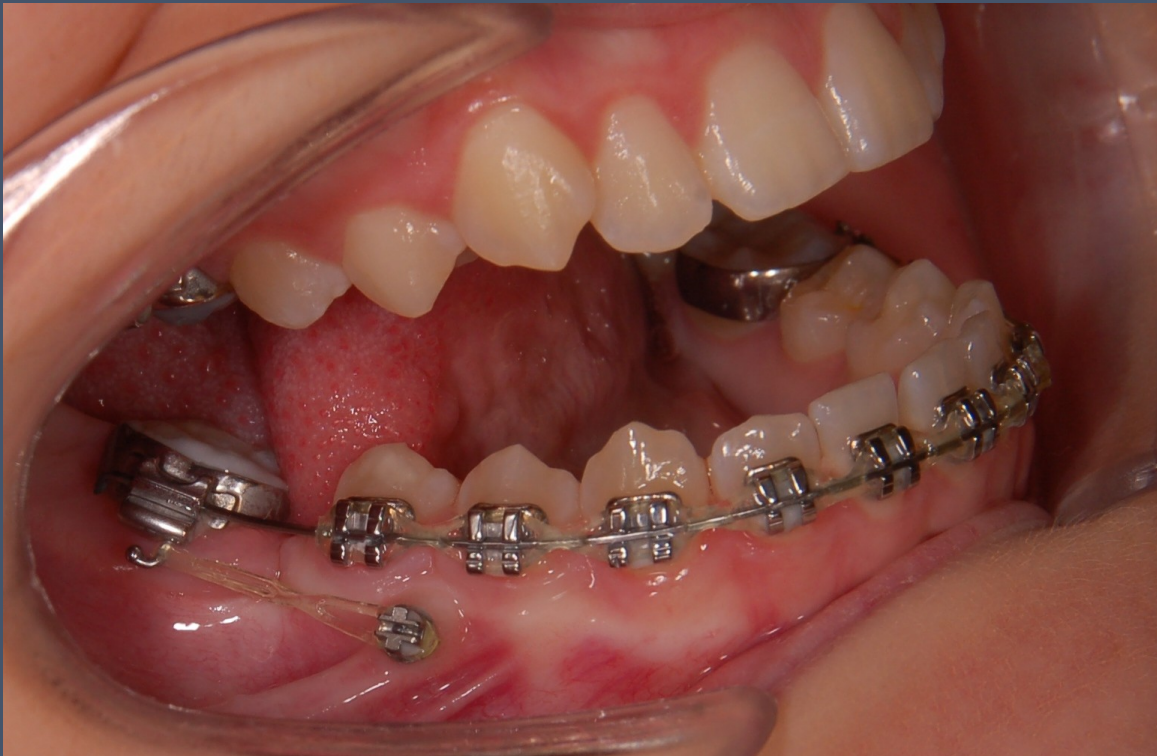Case 8



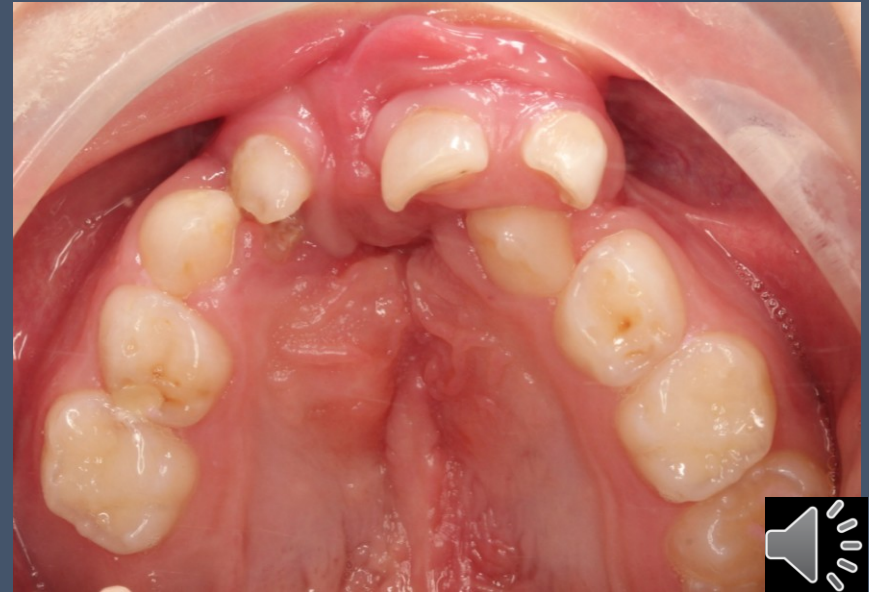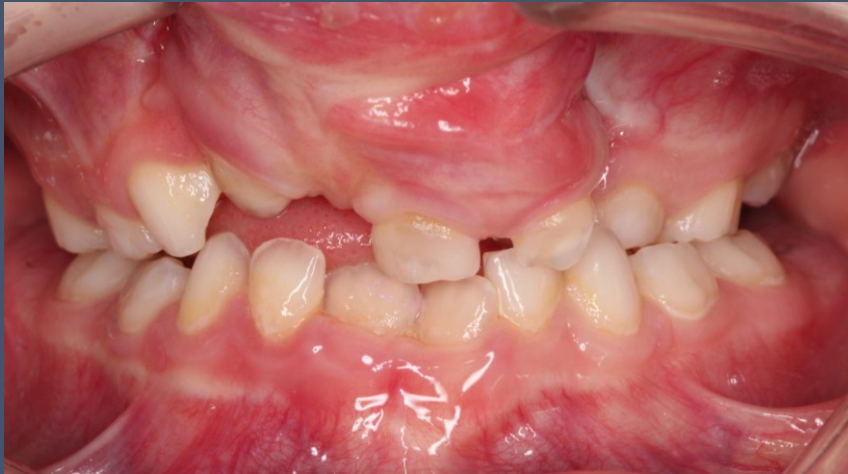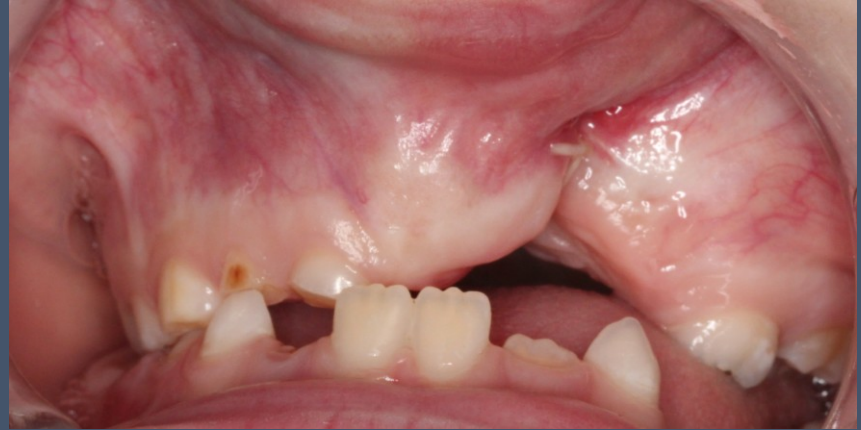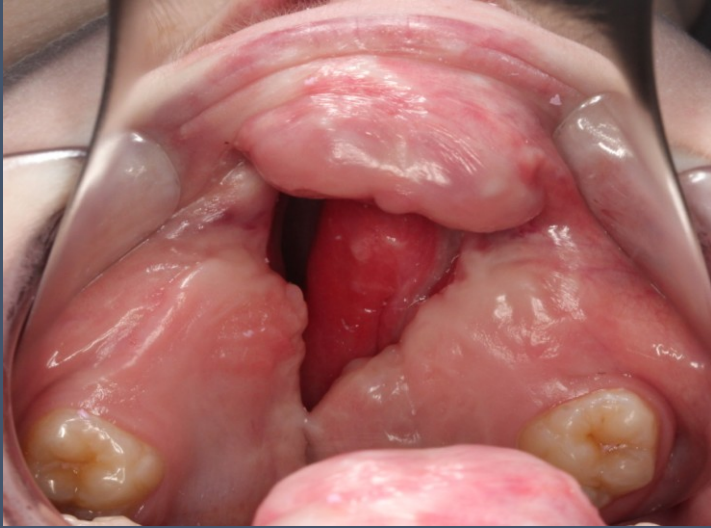Retention of 13



Mezialization 47 on the 46 position with minisrew –
space closure



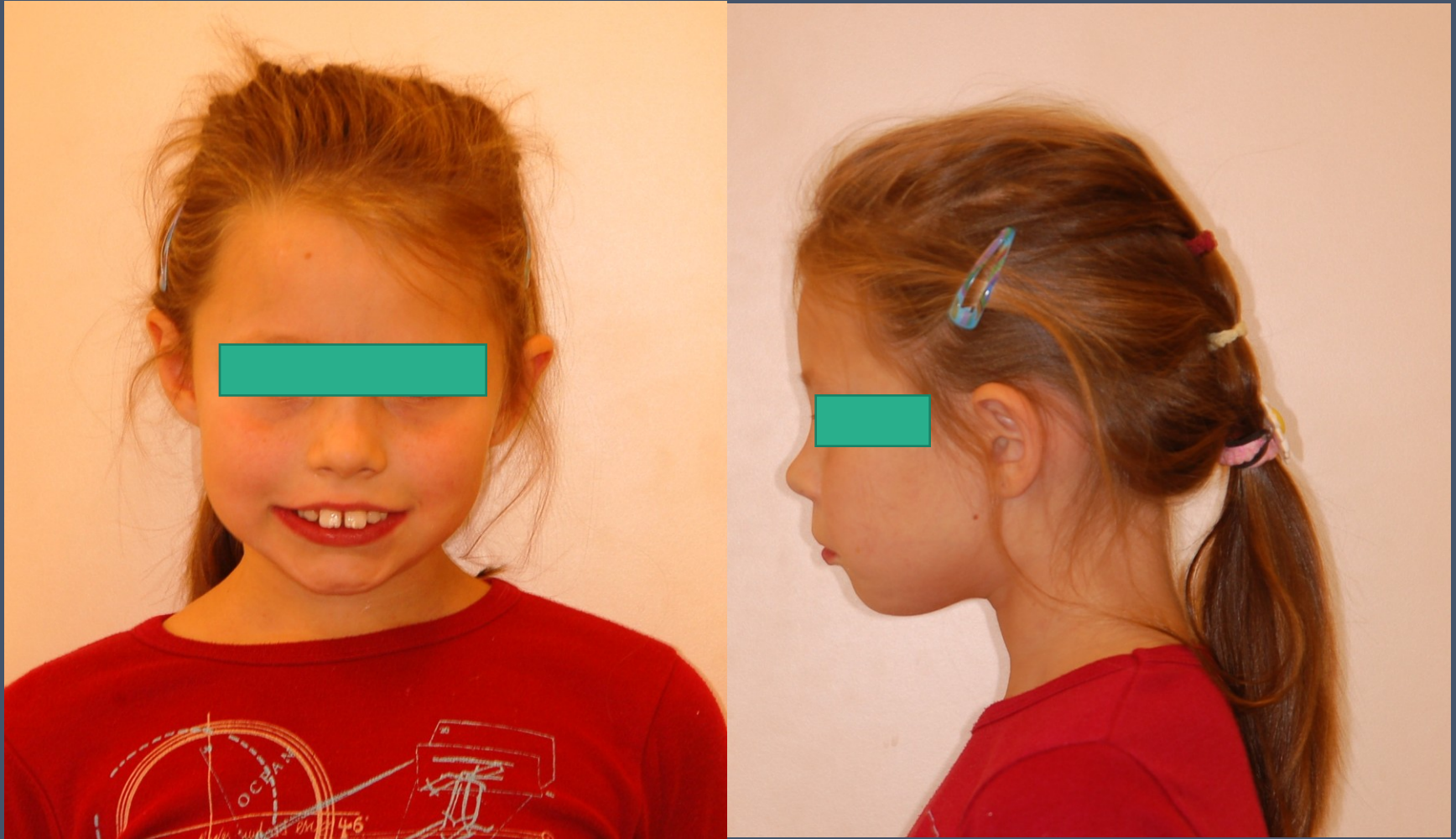Cleft lip and palate patients



Gummy smile, inclined occlusal plane



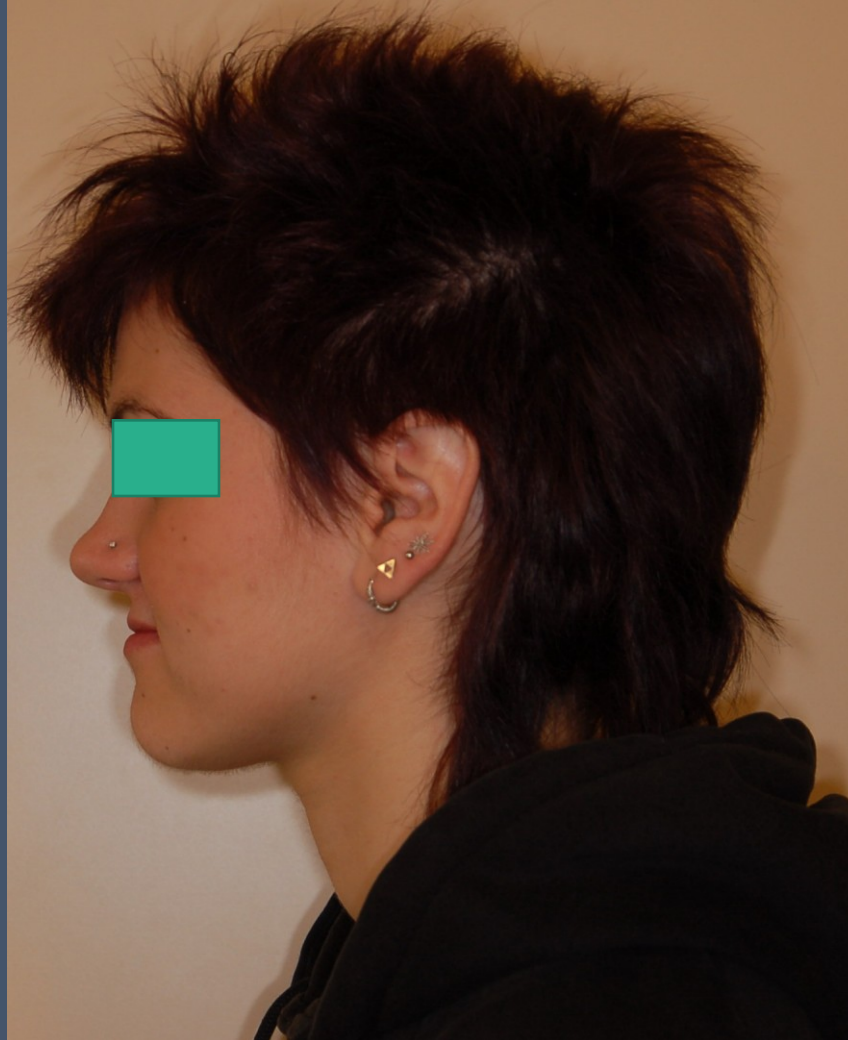Skeletal class II, protrusion upper incisors



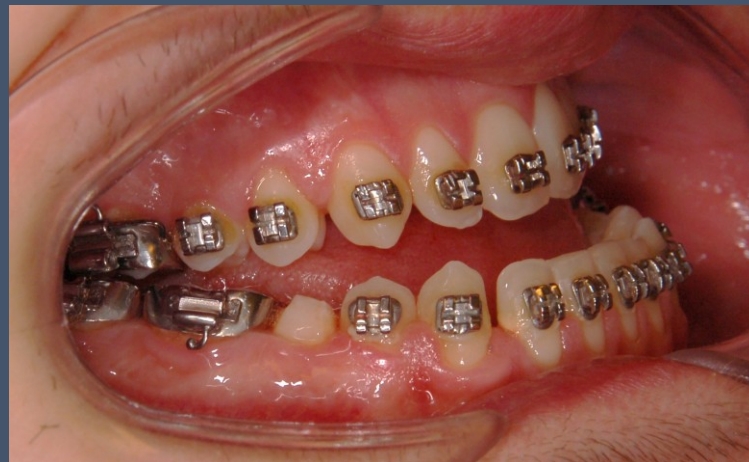Skeletal class II



Skeletal class III



Skeletal class III, open bite, inverted bite



Thank You for Your attention

Questions – email – alena.brysova@fnusa.cz

Consultation – Orthodontic department - St. Anne's Hospital, building D2b – Thursday 1-2 p.m.

