

Pathology of the Liver and Biliary Tract

V. Žampachová

I. ÚP

Hepatopathy

- prediagnostic stage, some suspicious signs present
- detailed diagnosis necessary, varied examination possibilities
- clinical findings
- laboratory findings
- imaging procedures
- morphological findings

Diagnostic steps

- primary x secondary liver disease
- diffuse x focal liver disease
- if icterus present → pre-, intra-, posthepatic
- type of pathologic change: hepatitis, fibrosis, advanced - cirrhosis, cholestasis, focal lesion, tumor, ...

Diagnostic steps

- **etiology**: genetic, metabolic, toxic, immunologic, vascular, infection, ...
- **stage**: prodromal, acute, chronic (> 6 months), cured
- **activity** of the process, **course** (regressive, stationary, progressive), **prognosis**

Remarks on pathophysiology

- different forms of blood flow
 - portal arteries, portal veins
 - sinusoids lined by fenestrated endothelial cells + limited amount of extracellular matrix, incomplete BM: slow, low-pressure mixed blood flow → enough time for adequate contact of plasma substances with hepatocytes → physiological solute exchange with resorption, excretion
 - central veins: low-pressure venous blood

Remarks on pathophysiology

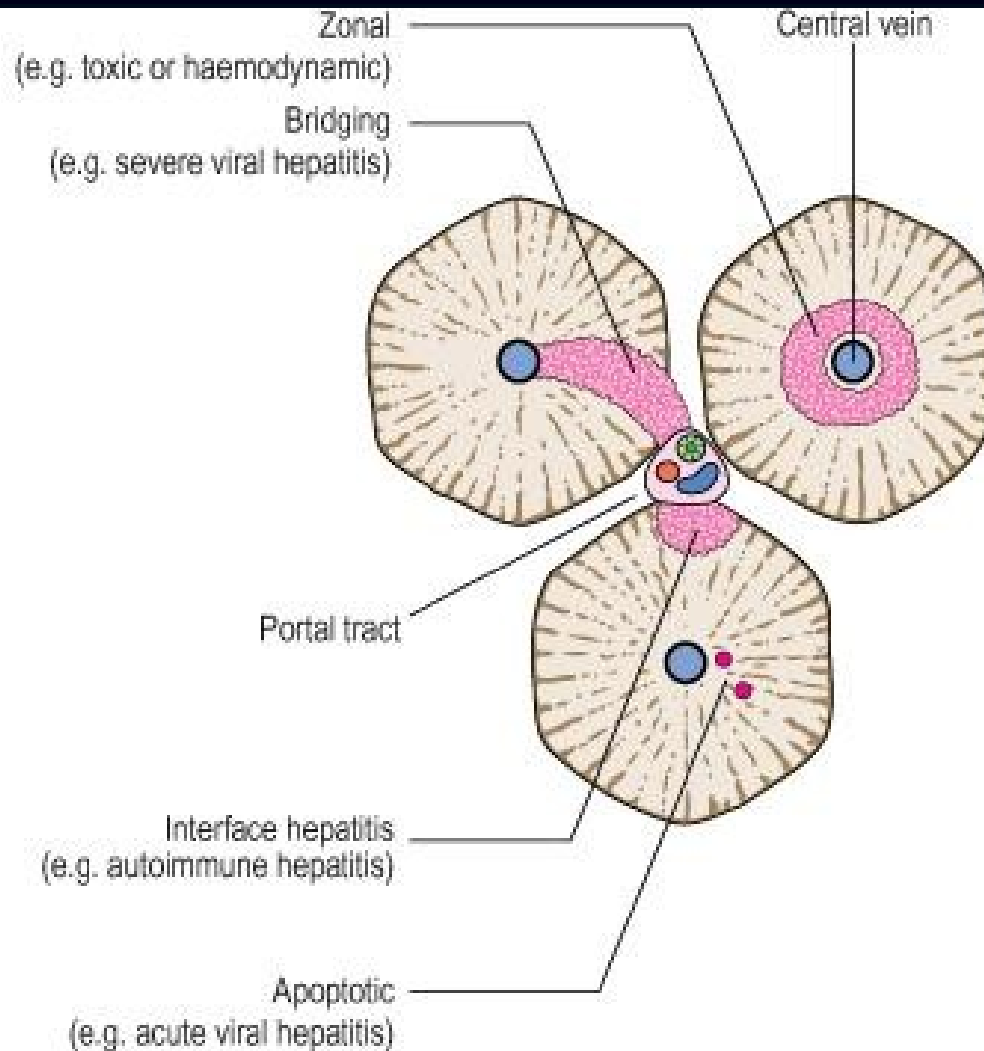
- Pathological conditions with blood flow/resistance alteration → hepatocyte dysfunction:
 - ↑ blood pressure in central veins (thrombosis, heart failure, etc.) → ↑ BP in sinusoids → transformation of lining cells, loss of fenestration → ↓ solute exchange → hepatocyte dysfunction
 - inflammation → activation of ECM producing cells → deposition of collagen between endothelial cells and hepatocytes → ↓ solute exchange → hepatocyte dysfunction
 - shunts between arteries and veins → bypass of lobules

Patterns of hepatic injury

- hepatocyte degeneration and/or pathologic intracellular accumulation (i. e. fatty liver, pigment, ...)
- hepatocyte necrosis, apoptosis
- vascular remodeling
- inflammation
- regeneration
- fibrosis
- neoplasia

Histopathology

- Histological evidence of:
 - liver cell degeneration or death
 - inflammatory reaction
 - regenerative changes
 - others
- Diagnostic changes only partially specific to the causative agent.
- Pattern and type of liver cell damage important



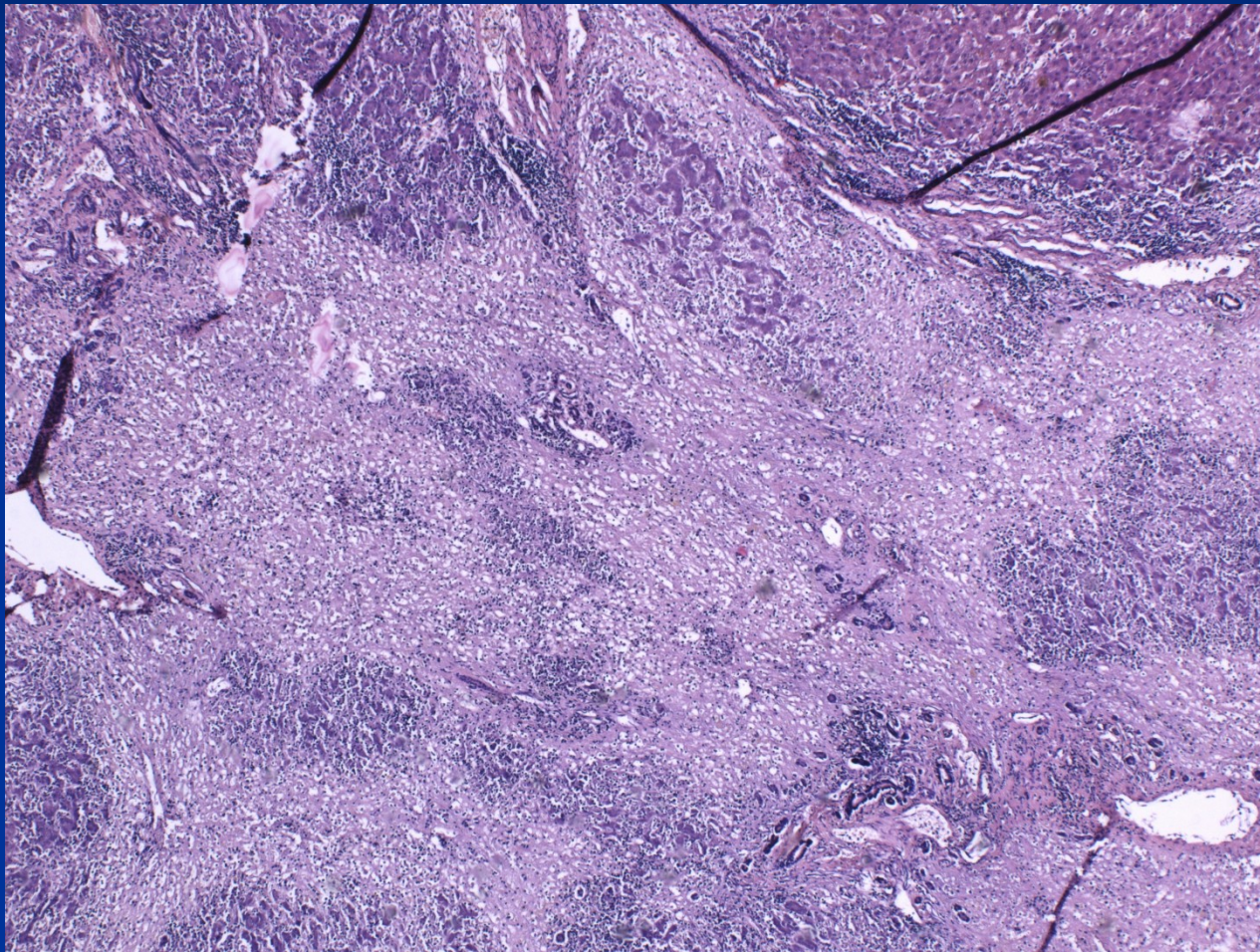
copy

Patterns of liver cell death

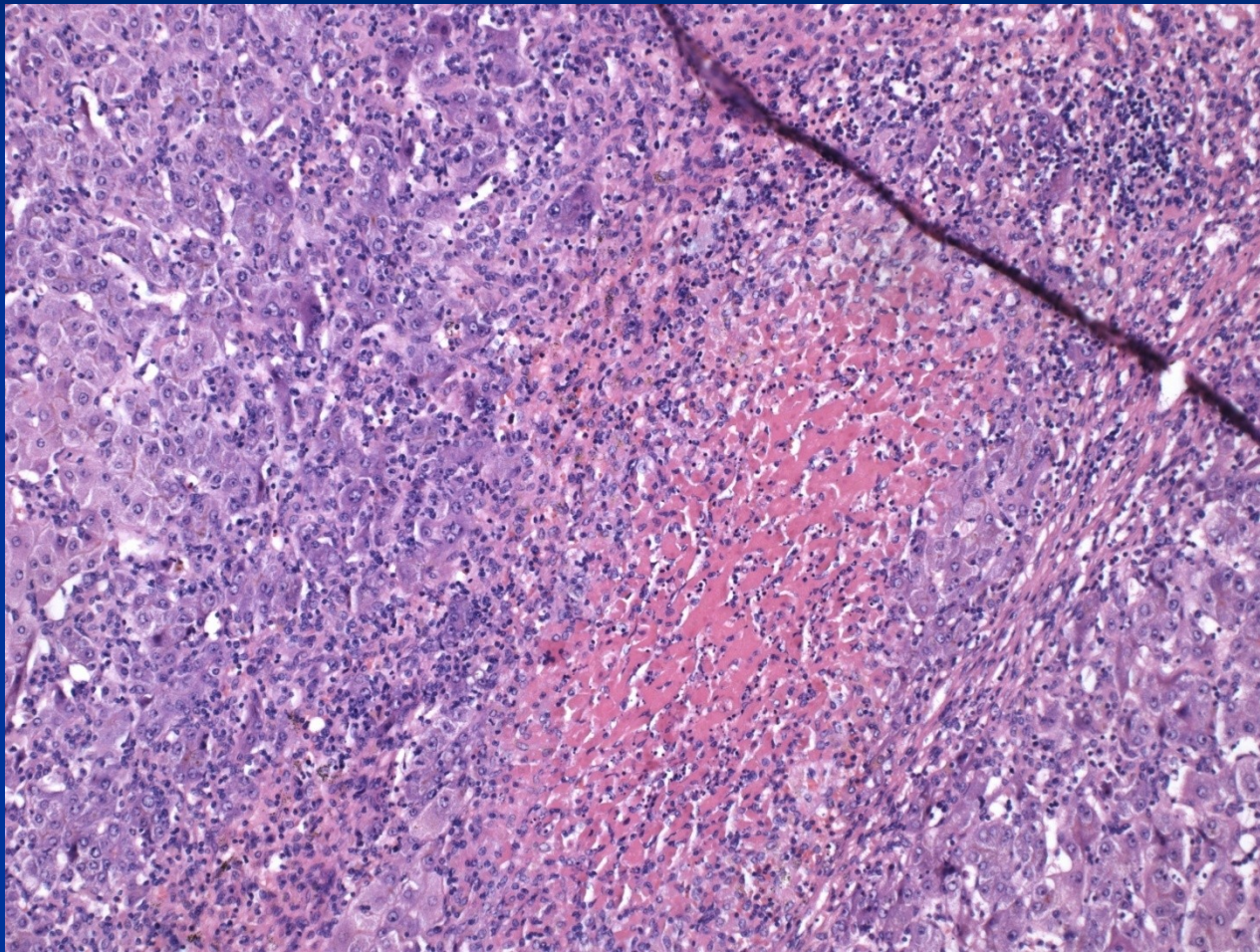
Necrosis distribution

- Interface hepatitis (piecemeal necrosis) - periportal hepatocytes, mostly in chronic hepatitis, ↑ risk of cirrhosis
- Centrilobular → necrosis around central vein (ischaemia; toxins; drugs)
- Bridging - severe inflammation or toxins
 - Portal-to-portal
 - Portal-to-central
 - Central-to-central
- Panacinar necrosis
 - entire acinus
 - diffuse → liver failure, risk of immediate death.

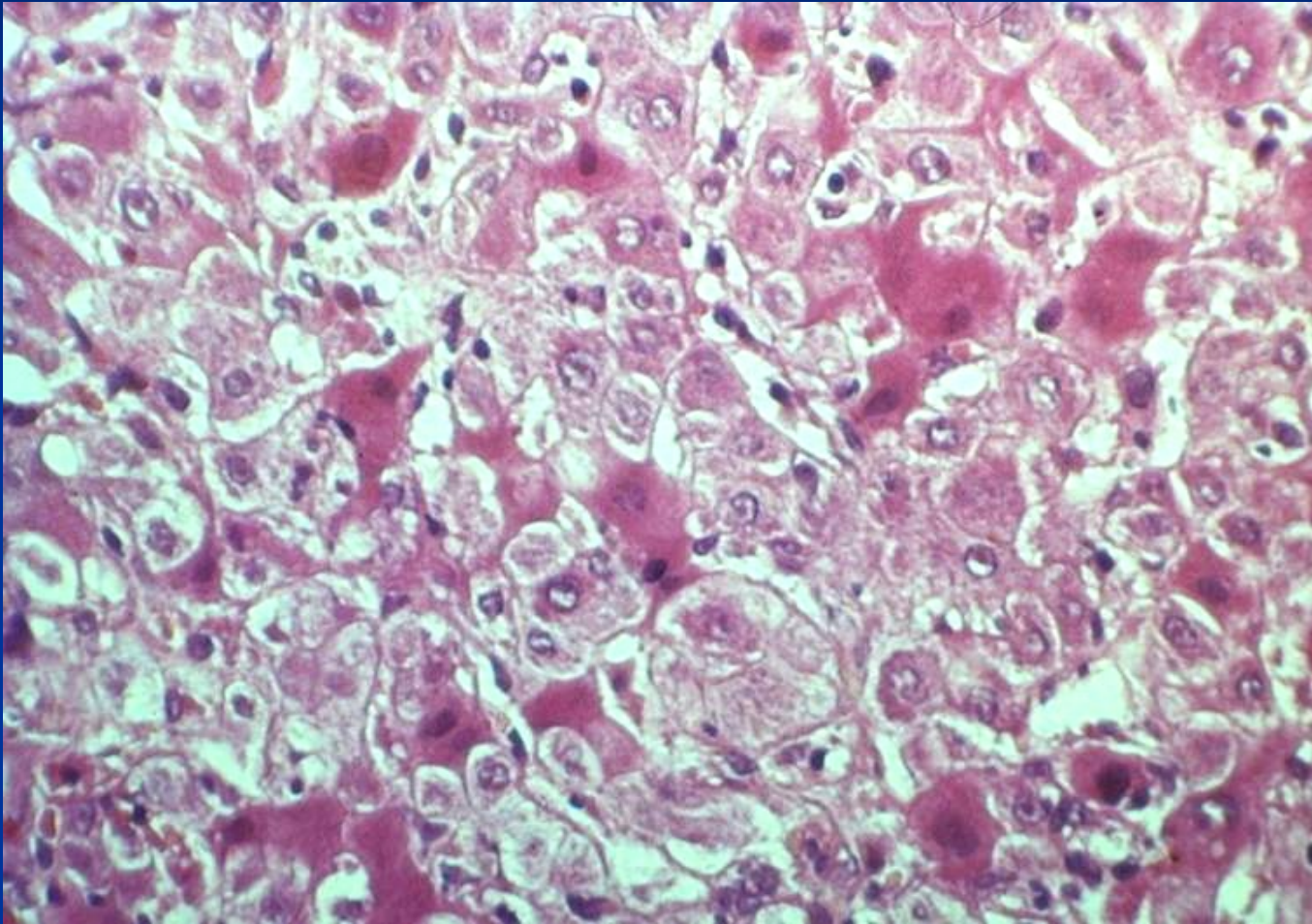
Liver necrosis (acetaminophen)



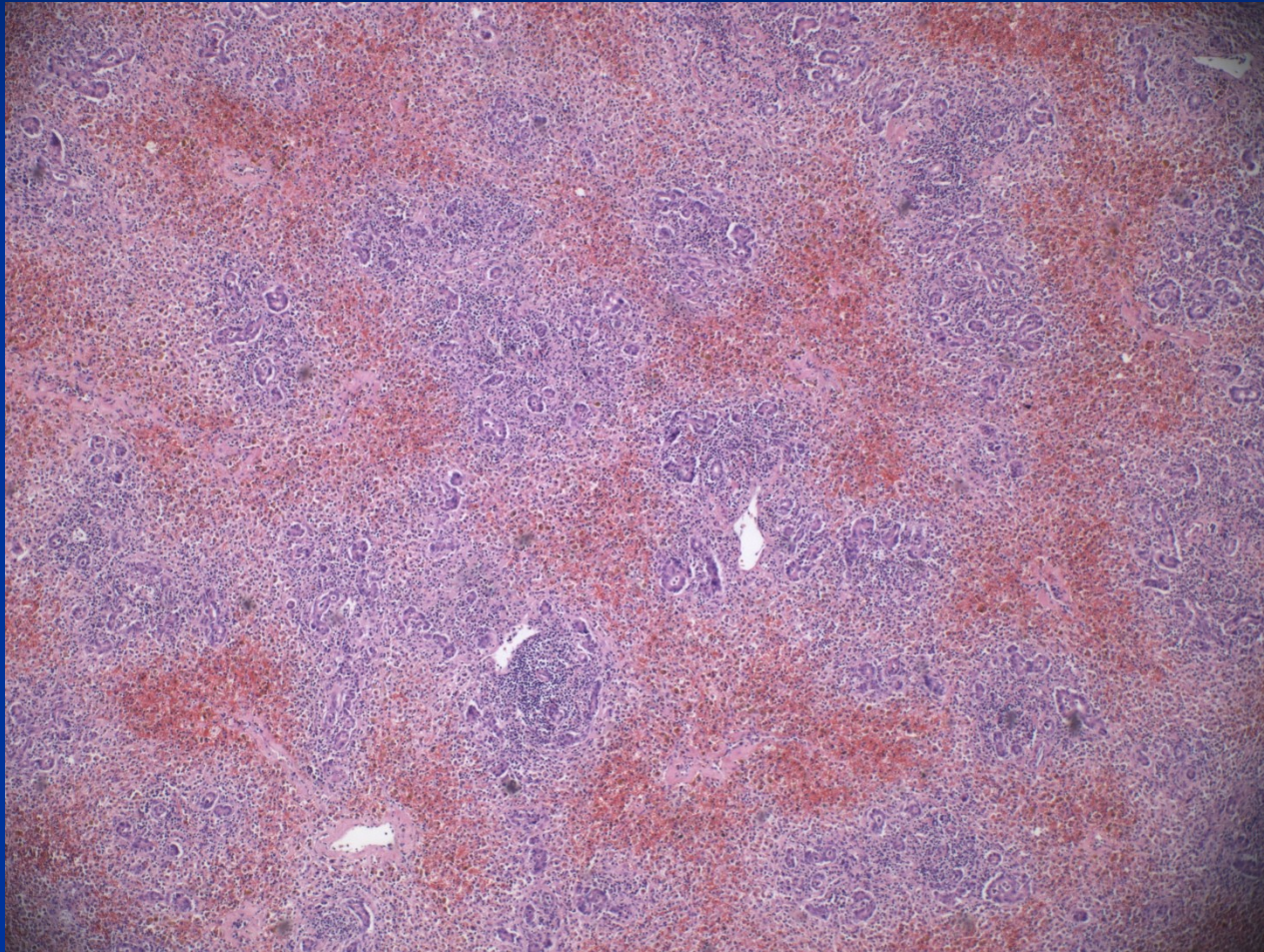
Liver necrosis (acetaminophen)



Hepatocyte necrosis



Necrosis - repair



Necrosis

- Coagulative → eosinophilic hepatocytes without nuclei (ischaemia)
- Apoptosis → death of individual liver cells, pyknosis
 - most frequent pattern in viral hepatitis
 - usually possible recovery
 - toxic; immunologic
- Lytic necrosis → hepatocytes swell and rupture

Fibrosis

- Response to inflammation
- Mostly irreversible (under favorable conditions reversible to some extent)
- Intrasinusoidal deposition of collagen → effects on hepatic metabolism and blood flow
- In/around portal tracts or central veins → spreads → links other regions (bridging fibrosis)
- Basic lobular architecture partially preserved

Advanced stage of chronic liver disease („cirrhosis“)

- Complete loss of original architecture
- Regenerating groups of hepatocytes surrounded by fibrotic scar tissue
- Due to continued parenchymal injury and fibrosis
- Commonly late/end form of severe liver disease
- A process, possible reparative/regenerative changes and/or worsening of the lesion

Liver failure

- Most severe clinical consequence of liver disease
- **Result of:**
 - Sudden and massive hepatic destruction
 - End-point of progressive liver damage (insidious or repeated)
- **Results in:**
 - Inadequate synthesis of albumin, clotting factors, etc.
 - Failure to eliminate endogenous products (e.g. ammonia, bilirubin; hormones)
- Often triggered by intercurrent disease:
 - Systemic infections
 - Electrolyte disturbances
 - Stress (e.g. surgery)
 - GIT bleeding

Liver failure

- **Acute liver failure:** acute illness → encephalopathy + coagulopathy \leq 6 months (fulminant \leq 2 weeks). Massive hepatic necrosis and/or massive steatosis.
 - Fulminant hepatitis (viral, autoimmune)
 - Drugs and chemicals, e.g., acetaminophen, carbon tetrachloride, mushroom poisoning. Alcohol.
 - Biliary obstruction, commonly due to gallstones.
 - Direct physical injury to the liver (e.g. laceration in a road traffic accident)
 - Vascular lesion

Acute liver failure

- Possible recovery from acute liver injury (focal or diffuse) due to the capacity of the organ for cellular regeneration.
- Loss of a part of the liver – regrowth, regeneration
- Loss of the basic structure - repair

- The same agent may produce either an acute or a chronic illness, commonly without any preceding clinically evident acute phase.

Chronic liver failure

- **Chronic liver disease** → advanced stage of chronic hepatitis, biliary diseases, ...
- Massive neoplastic infiltration.
- Functional stage important
 - well compensated
 - partially decompensated
 - decompensated

Hepatic signs

- **Hepatomegaly** – hepatitis, intracellular accumulation, focal lesion
- **Jaundice** – hyperbilirubinemia un-conjugated, + event. dark urine, acholic pale faeces, pruritus
- **Oedema** - ↓ protein synthesis, hypoalbuminemia
- **Ascites** – portal hypertension + hypoalbuminemia
- **Splenomegaly** - portal hypertension + immune reactions, possible → anemia, thrombocytopenia

Hepatic signs

- **Bleeding** - ↓ clotting factors + fibrinolysis inhibitors synthesis
- **Varices** (oesophagus, cardia, caput Medusae) - portal hypertension
- **Spider naevi, gynecomastia, impotence, palmar erythema** – hyperoestrogenism
- **Hepatorenal syndrome** - idiopathic renal failure (cortical vasoconstriction, acute tubular necrosis)
- **Encephalopathy** - ↓ detoxification, complex metabolic disorder of the CNS, neuromuscular synapses
 - Elevated blood ammonia level and deranged neurotransmission
 - Rigidity, hyperreflexia, seizures

Portal hypertension

■ Prehepatic

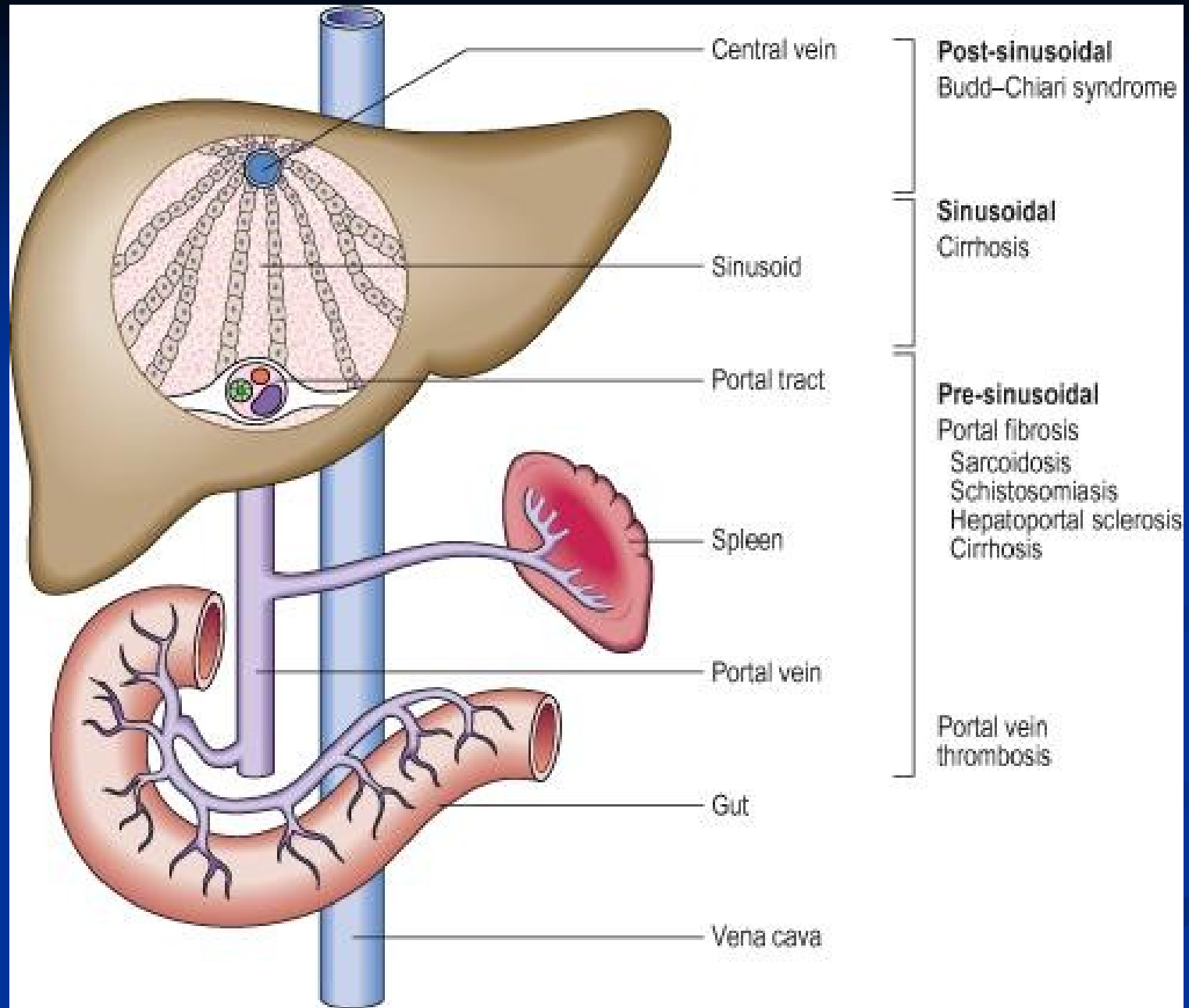
- Occlusive thrombosis (tumor, drugs), narrowing of the portal vein (inborn, acquired external pressure...)

■ Intrahepatic

- Advanced stage of liver disease (cirrhosis)
- Schistosomiasis, massive fatty change, diffuse granulomatous diseases (sarcoidosis, miliary TB), massive neoplastic infiltration

■ Posthepatic

- Right-sided heart failure, constrictive pericarditis, hepatic vein outflow obstruction



Portal hypertension complications

- **Varices** (+ rupture, shunting of toxic products into systemic circulation – ammonia, bacterial by-products – hepatic foetor)
- **GIT venous congestion** → gastric, intestinal phlegmona
- **Ascites** commonly + infection - peritonitis
- **Hepatopulmonary sy** – dyspnoea, respiratory insufficiency

Cholestasis

Results from:

- Hepatocellular dysfunction
- Biliary obstruction

Signs:

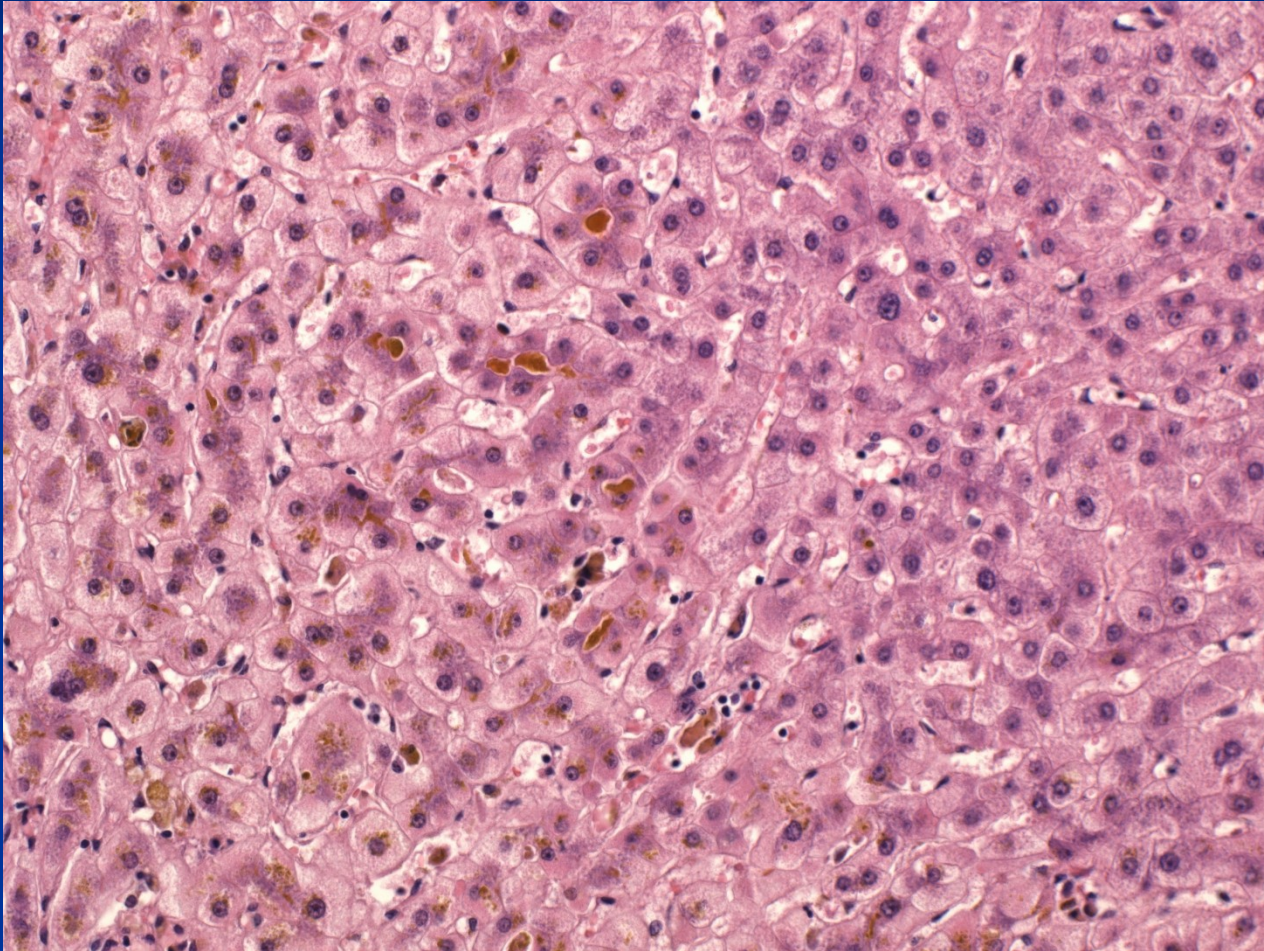
- Pruritus (↑ serum bile acids)
- Hyperlipidaemia → skin xanthomas (focal cholesterol accumulation)
- Malabsorption → ↓ fat soluble vitamins (A; D; K)
- ↑ serum alkaline phosphatase

Cholestasis

Morphology:

- Accumulation of bile pigment in hepatic parenchyma
- Elongated green plugs of bile visible in dilated canaliculi → rupture → extravasion of bile into sinusoids → phagocytosed by Kupffer cells
- Oedema, periductal neutrophilic infiltrates in portal tract
- Prolonged obstruction → portal tract fibrosis → biliary cirrhosis

Cholestasis

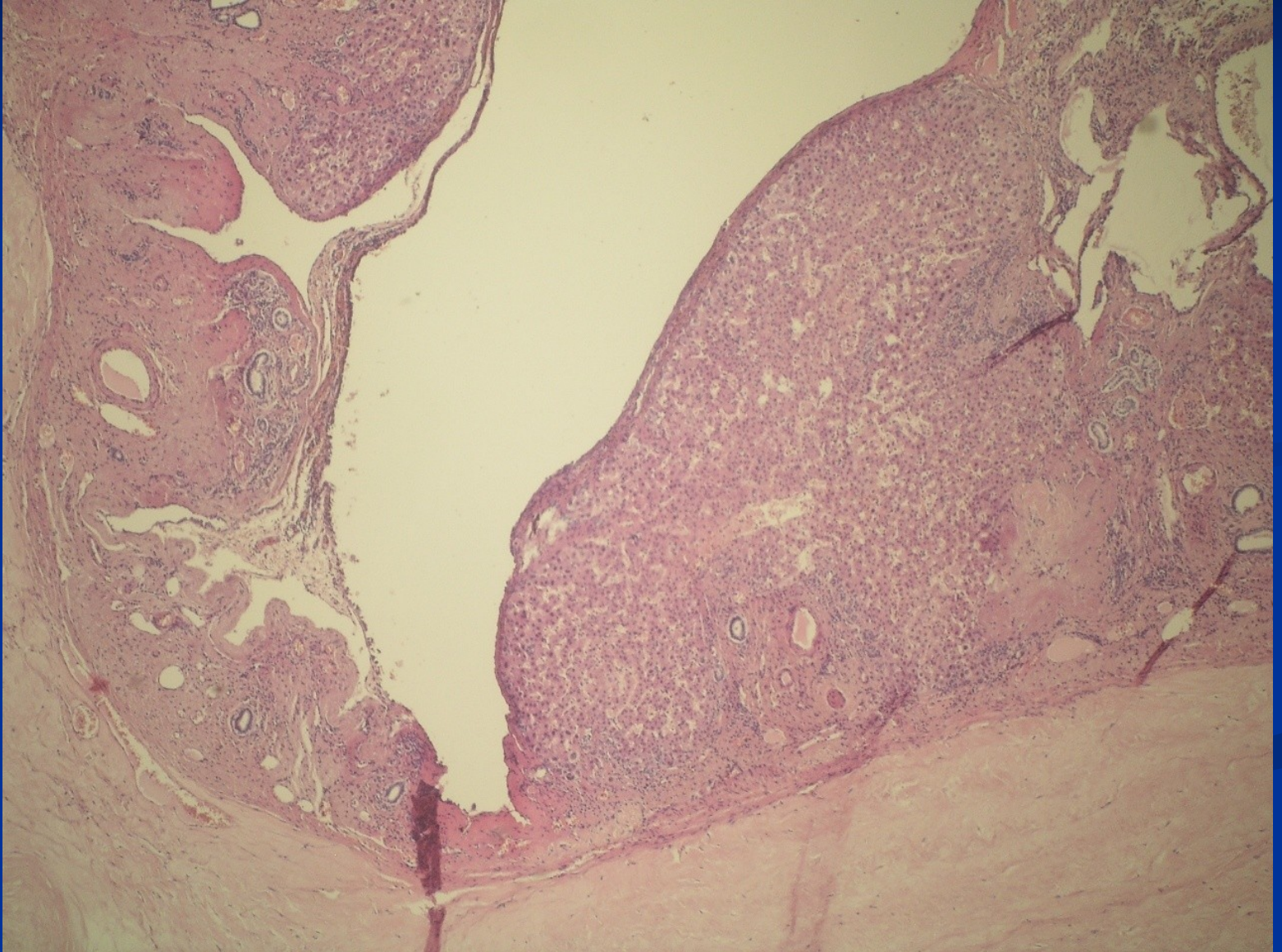


Developmental abnormalities

■ Bile-duct anomalies

- biliary atresia – mostly extrahepatic, possible fetal viral infection, treatment by anastomosis or transplantation
- congenital dilatation of the bile duct – **cysts**, autosomal polycystic disease (recessive x dominant)
- biliary hamartoma – small lesion, slow growth/dilatation, commonly superficial - *pseudotumor*

Polycystic disease



Metabolic disorders

- Commonly **genetic** enzymatic defects (Wilson disease, hemochromatosis, porphyria, etc.).
 - **Primary hepatic** manifestation (accumulation of a metabolite due to an enzymatic defect – i.e. sphingomyelin).
 - **Secondary hepatic** manifestation (liver changes resulting from extrahepatic pathology).
- Possible **acquired** accumulation of various substances (i.e. secondary hemosiderosis, amyloidosis).

Metabolic liver diseases

- **Hemochromatosis** – iron overload
- **Wilson disease** – copper overload
- **Bilirubin metabolism defects**
- **α 1-antitrypsin deficiency**
- **Storage disorders** (glycogenoses, mucopolysaccharidoses, lipidoses,...)

Hemochromatosis

- Primary or hereditary hemochromatosis

- HLA-linked autosomal recessive disease

Primary defect in regulation of intestinal absorption of dietary iron, iron accumulation of 0.5 to 1.0 g/yr (total body iron ~ 2-6g), heterozygous → increased Fe absorption, homozygous → dangerous levels

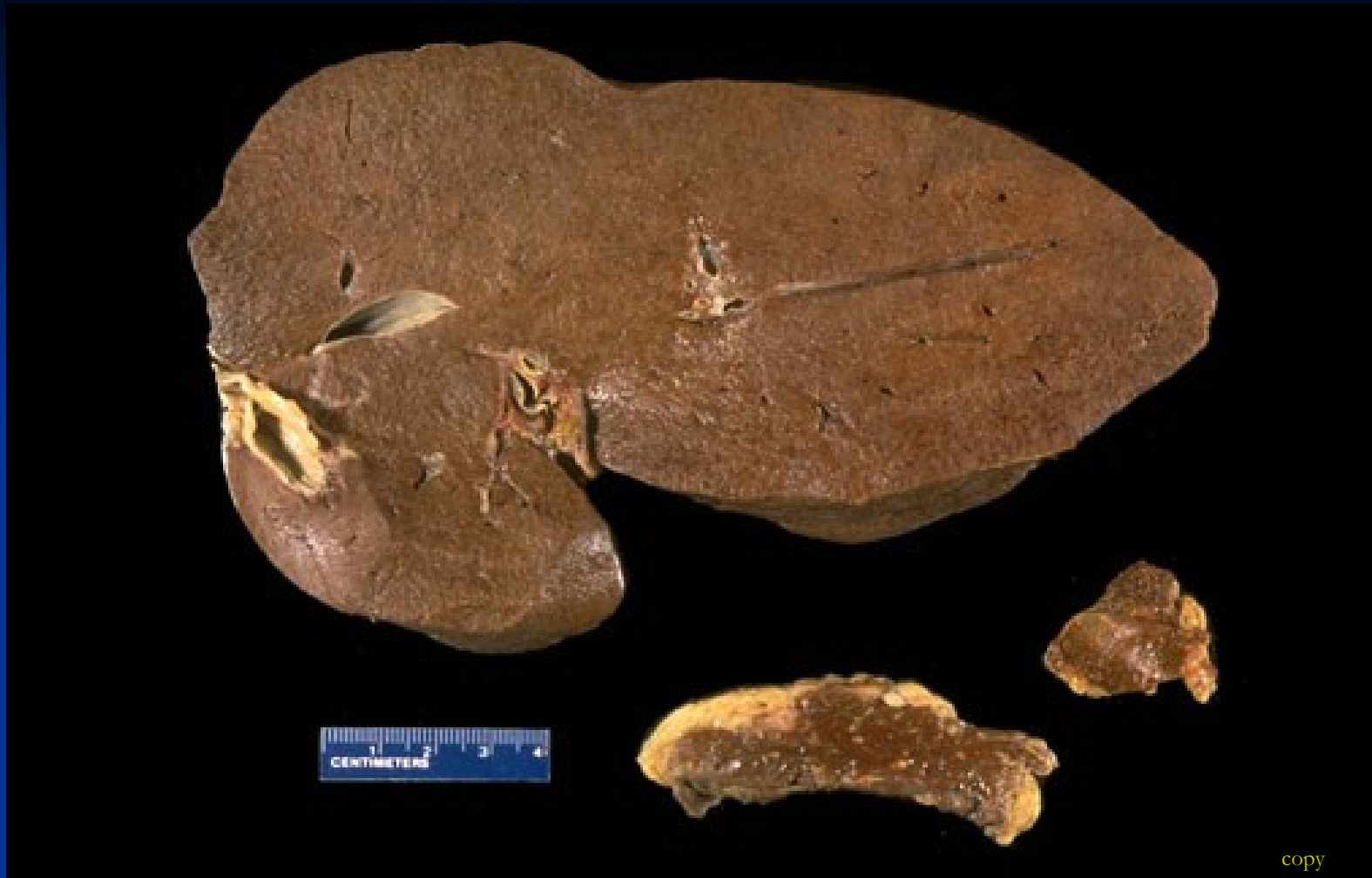- Heterozygous: 8-10% of West-, North-, Middle Europe
- Homozygous: incidence approx. 1 : 300-400
- Possible accelerated progression of other chronic liver diseases (alcohol liver disease, etc.)
- Therapy: venesection

Hemochromatosis

- Deposition of hemosiderin in the liver, pancreas, myocardium (congestive heart failure), pituitary, adrenal, thyroid and parathyroid glands, testes, joints (arthritis), and skin („bronze diabetes“)
- Chronic hepatitis → micronodular cirrhosis
- Significant risk for HCC (hepatocellular carcinoma)
- Pancreatic interstitial fibrosis and parenchymal atrophy → DM

Secondary hemosiderosis

- Transfusion dependent
- Ineffective erythropoiesis with increased erythroid activity
- Excessive oral Fe intake (supplements)
- Chronic liver disease (alcohol hepatitis - ↑ Fe absorption, chronic hepatitis C)



The dark brown color of the liver, the pancreas, lymph nodes due to extensive iron deposition in **hereditary hemochromatosis**

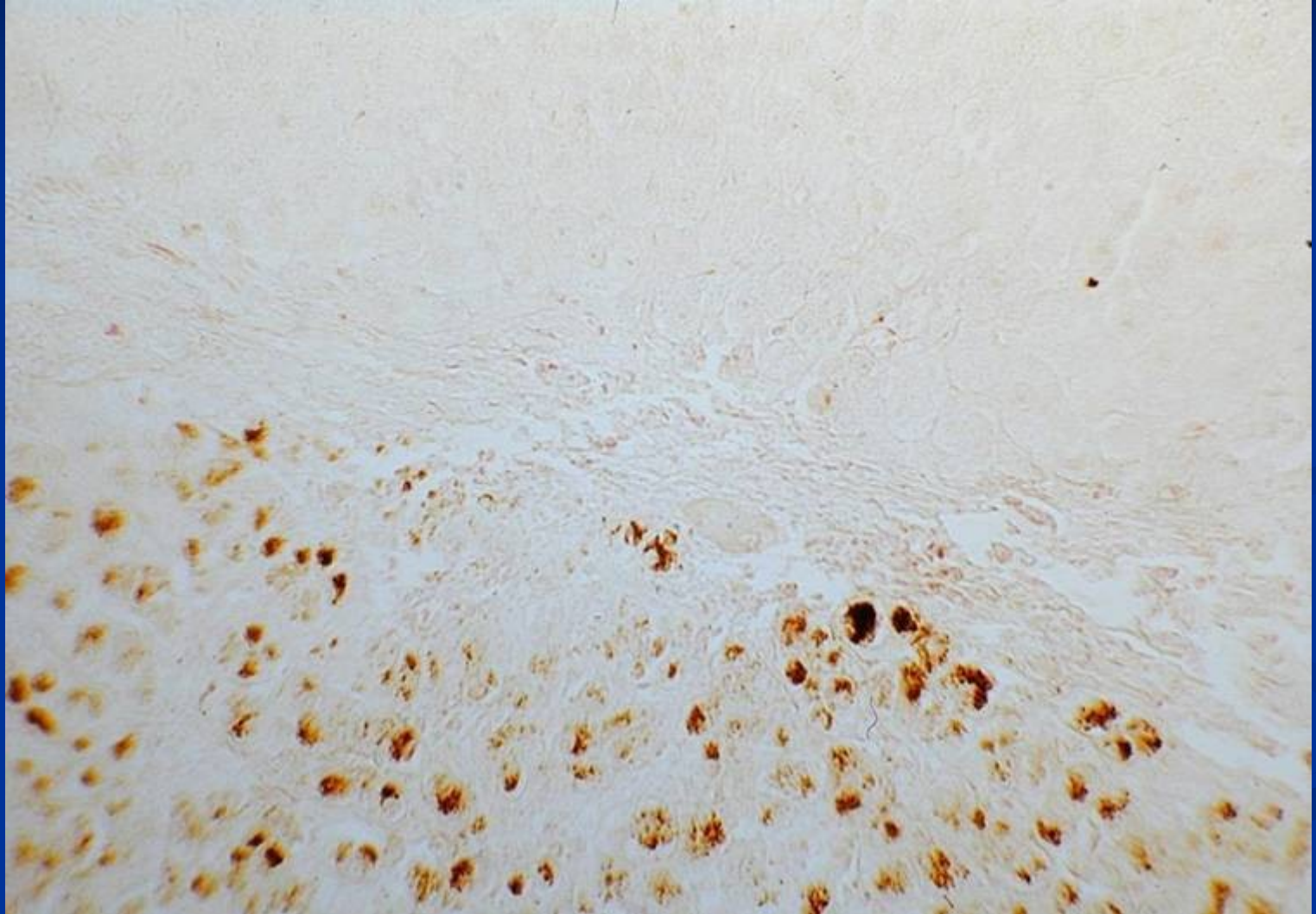
Wilson disease

- Hepatolenticular degeneration
- Autosomal recessive disorder of copper metabolism
- Failure to excrete copper into bile
- Copper → progressive liver injury
- Affects brain, cornea, kidneys, bones, joints, and parathyroid glands
- Dg: ↓ serum ceruloplasmin, ↑ hepatic copper content, ↑ urinary copper

Wilson disease - clinical

- Manifestations rare before 6 yrs
- Acute or chronic liver disease – most common
- Neuropsychiatric manifestations
- Possible haemolytic attack
- Copper chelation therapy with D-penicillamine
- Liver transplantation

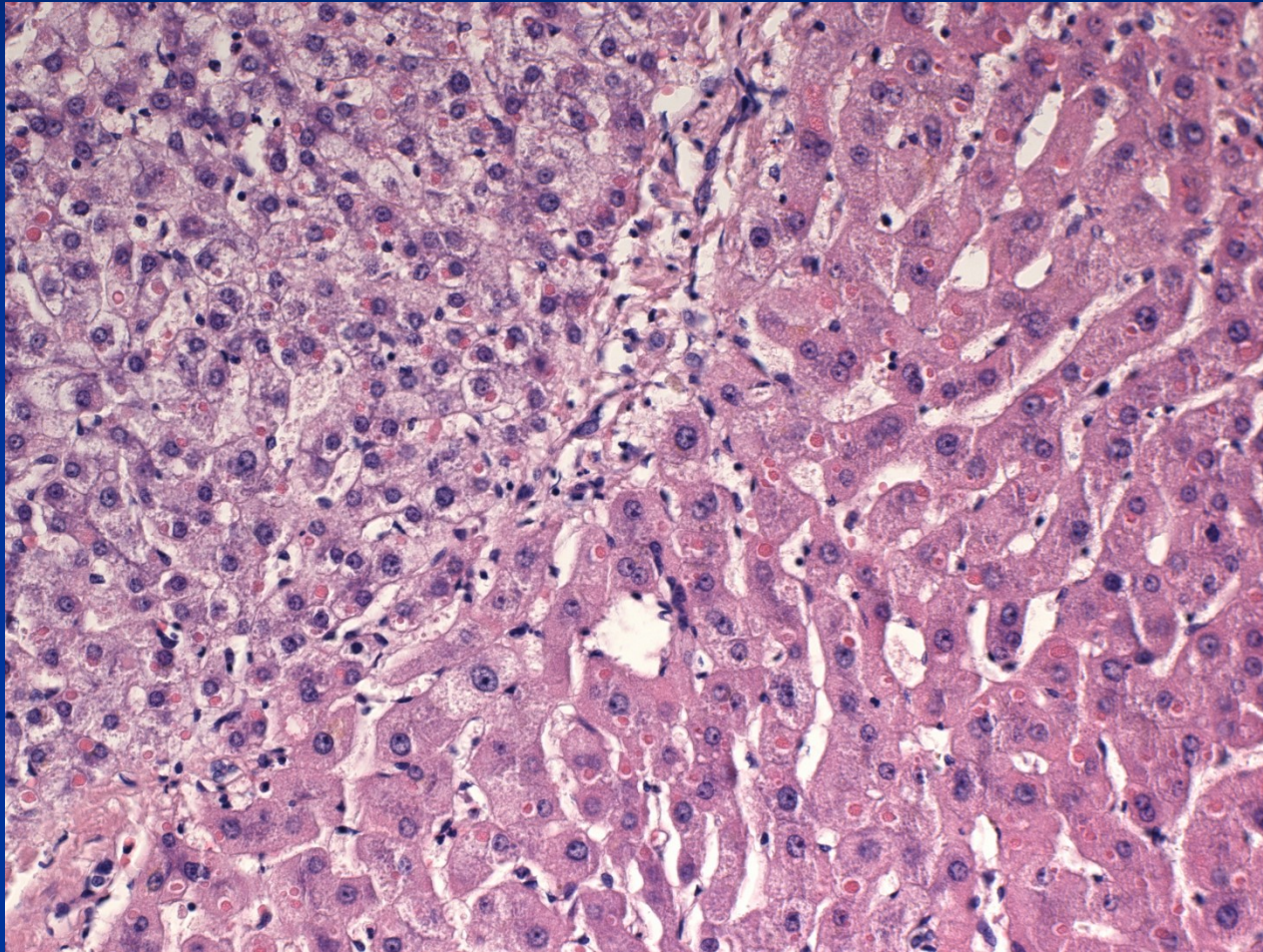
Wilson's disease : Cu pigment



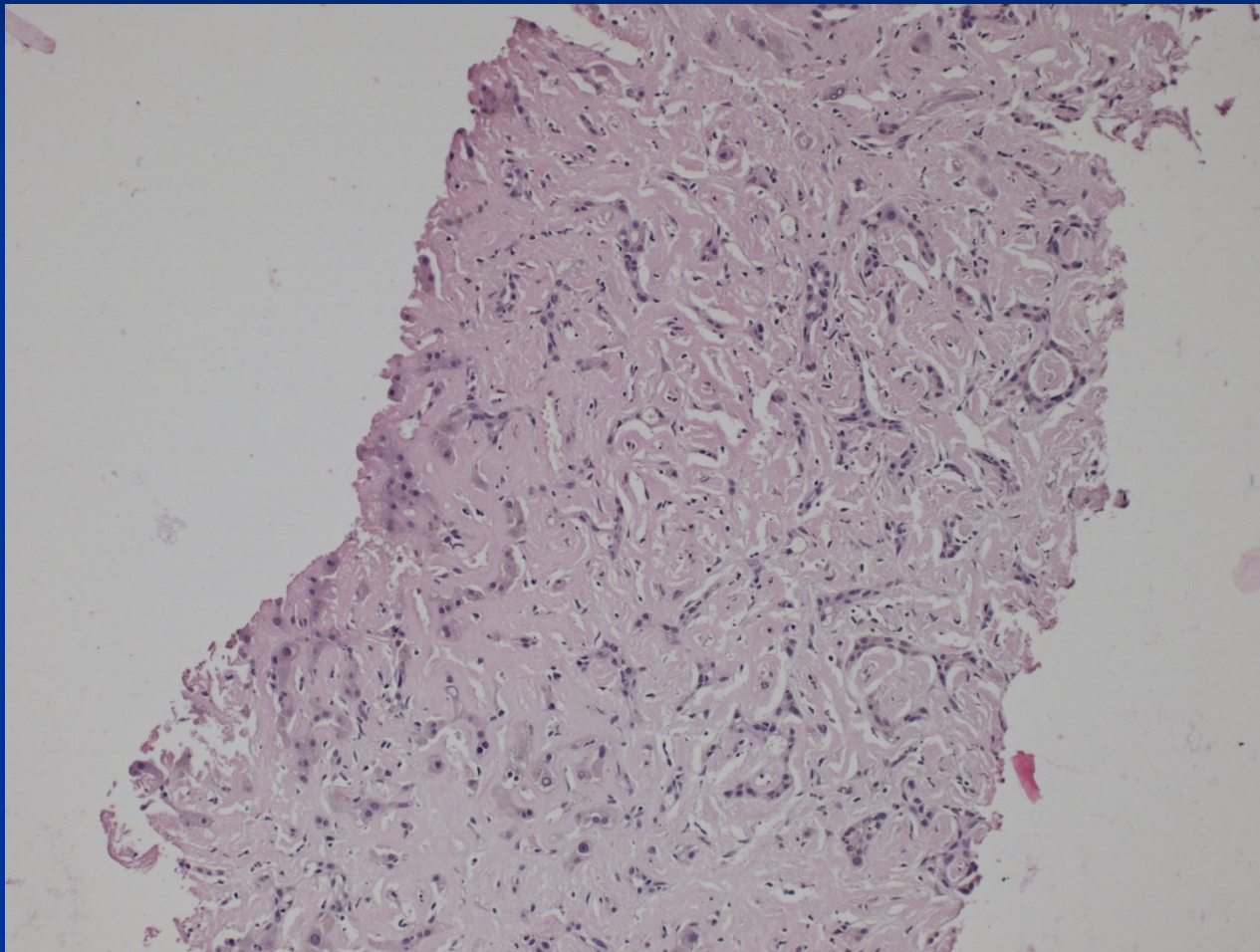
α_1 -antitrypsin deficiency

- Autosomal recessive disorder
- AAT - a protease inhibitor, particularly neutrophil elastase released at sites of inflammation
- Liver changes (cholestasis + necrosis even in newborns, children or adults – chronic hepatitis → cirrhosis, ↑ risk of hepatocellular carcinoma)
- Pulmonary emphysema due to tissue destructive enzymes (!combination of factors in smokers)

α_1 -antitrypsin deficiency + HCC




Liver AL amyloidosis



Liver AL amyloidosis

Kappa light chain
IHC



Hepatitis: etiology

Infectious (acute, chronic)

viruses (most common, hepatotropic - hepatitis viruses; systemic – EBV, CMV, HSV, yellow fever – similar to „viral hepatitis“, rubella, enteroviruses, ...)

bacteria (pyogenic bacteria, TBC, malaria, salmonellosis, leptospirosis,...)

parazites (ecchinococcus, schistosoma, ...)

protozoal (amebiasis)

Non-infectious (acute, chronic)

autoimmune

metabolic

drug induced

cryptogenic

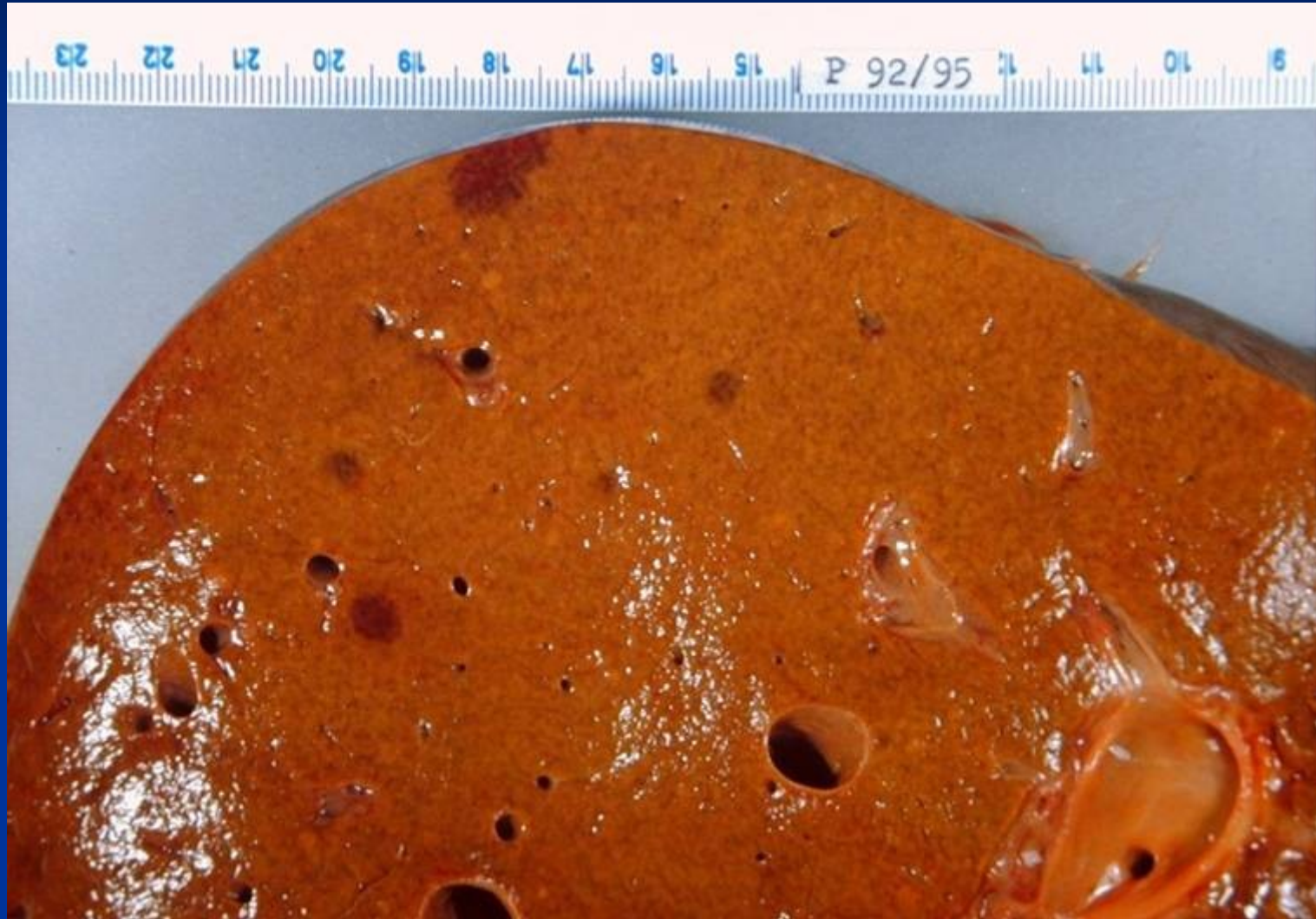
Viral hepatitis

- hepatitis viruses immunologically distinct → infection usually confers life-long immunity to the specific type/subtype of the infecting virus but not to the others
- exceptions - HCV
- Ab detection: IgM → acute disease;
IgG → memory cells

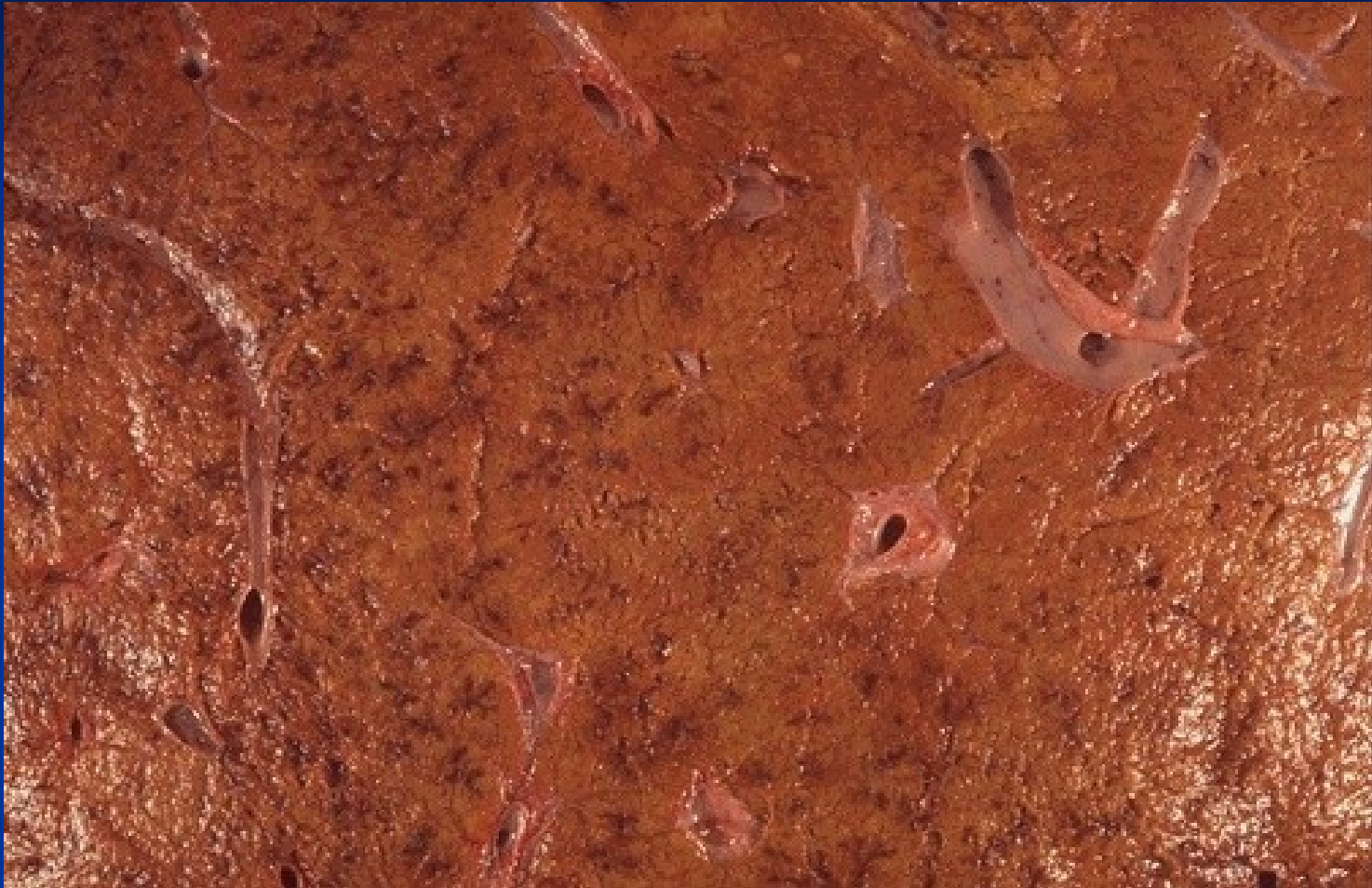Viral hepatitis: course

- **Acute** (HAV, HBV, HCV, HDV, HEV)
- **Fulminant** (HAV, HBV, HEV)
- **Chronic** (HBV, HBV + HDV, HCV; rare HEV, exceptional HAV)
 - *risk of advanced stage disease/cirrhosis development*
 - *risk of hepatocellular carcinoma development*

Acute hepatitis: HBV



Morphology - gross



Edema, hyperemia. Necrosis and lobular collapse - areas of hemorrhage and irregularities on the cut surface of the liver.

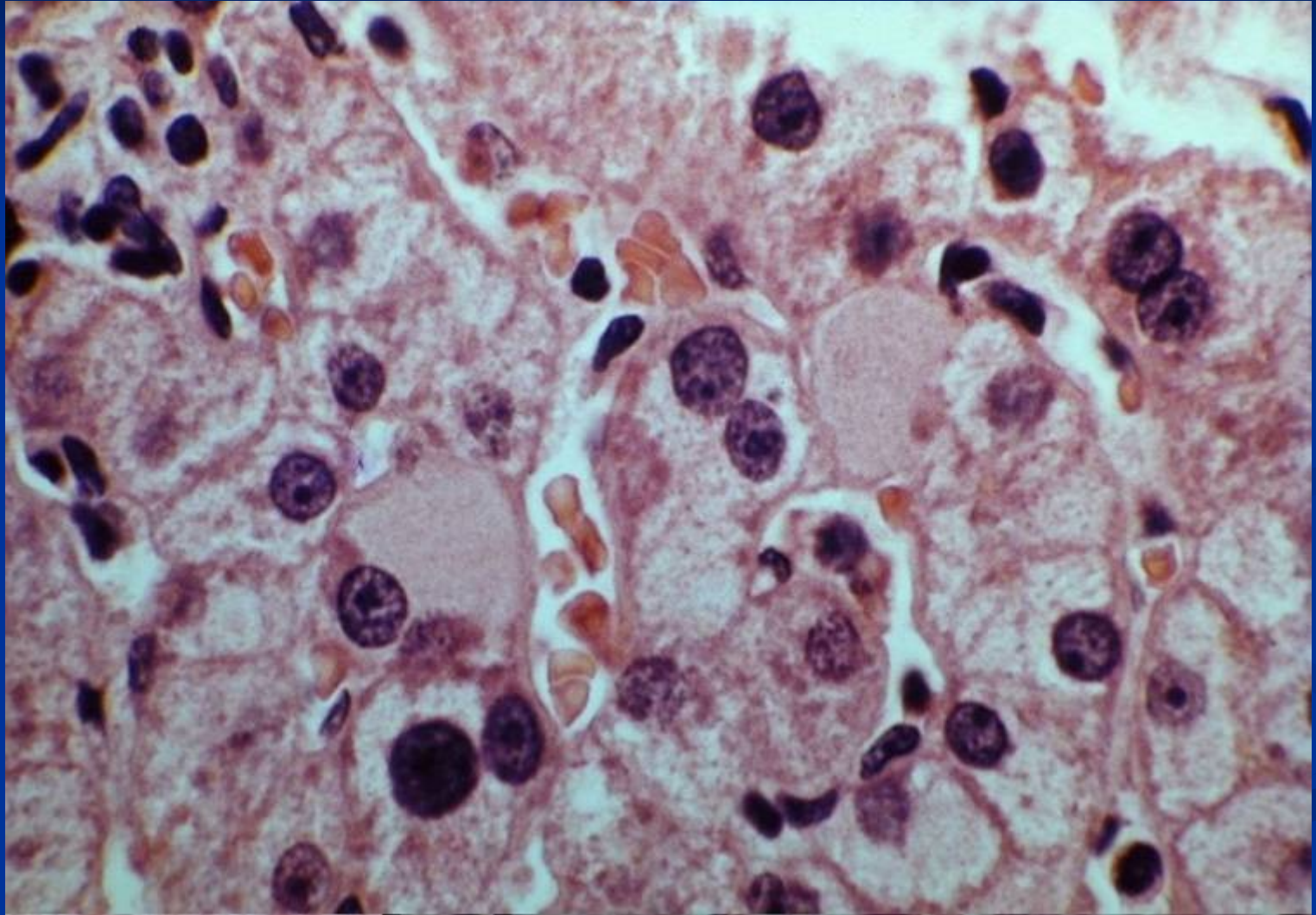
Morphology

- Hepatocyte degenerative changes – ballooning
- Hepatocyte apoptosis (eosinophilic bodies)
- Portal inflammatory infiltrate + edema
- Interface hepatitis – infiltrate + death of periportal hepatocytes
- Possible confluent/bridging necrosis
- Possible cholestasis in hepatocytes and/or bile canaliculi
- Kupffer cell reaction + hyperplasia
- Regenerative changes

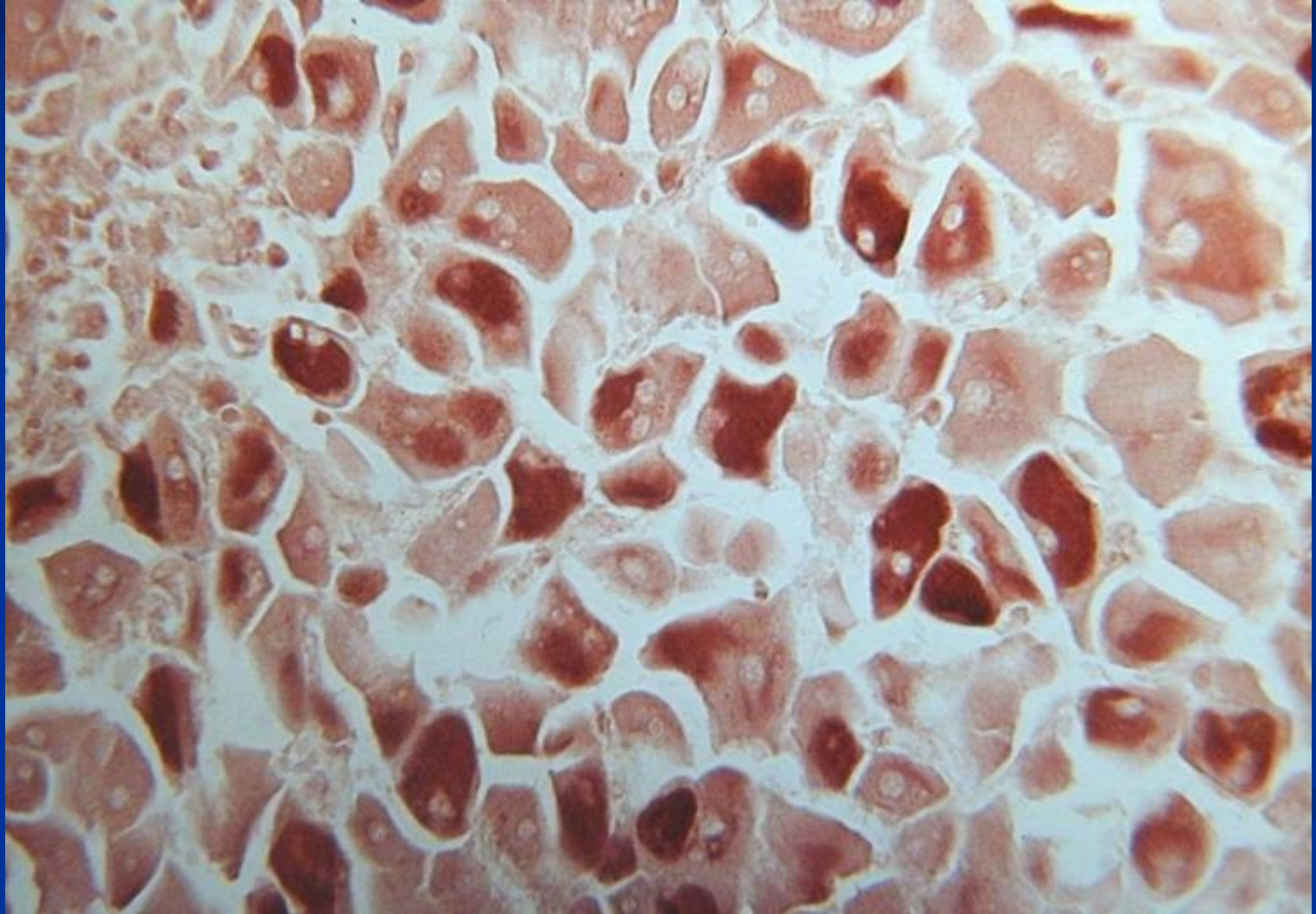
Morphology

- *HAV* – numerous plasmacytes
- *HBV* – ground-glass hepatocytes
- *HCV* – hepatocyte fatty change, ductal damage, lymphocytic aggregates in portal spaces

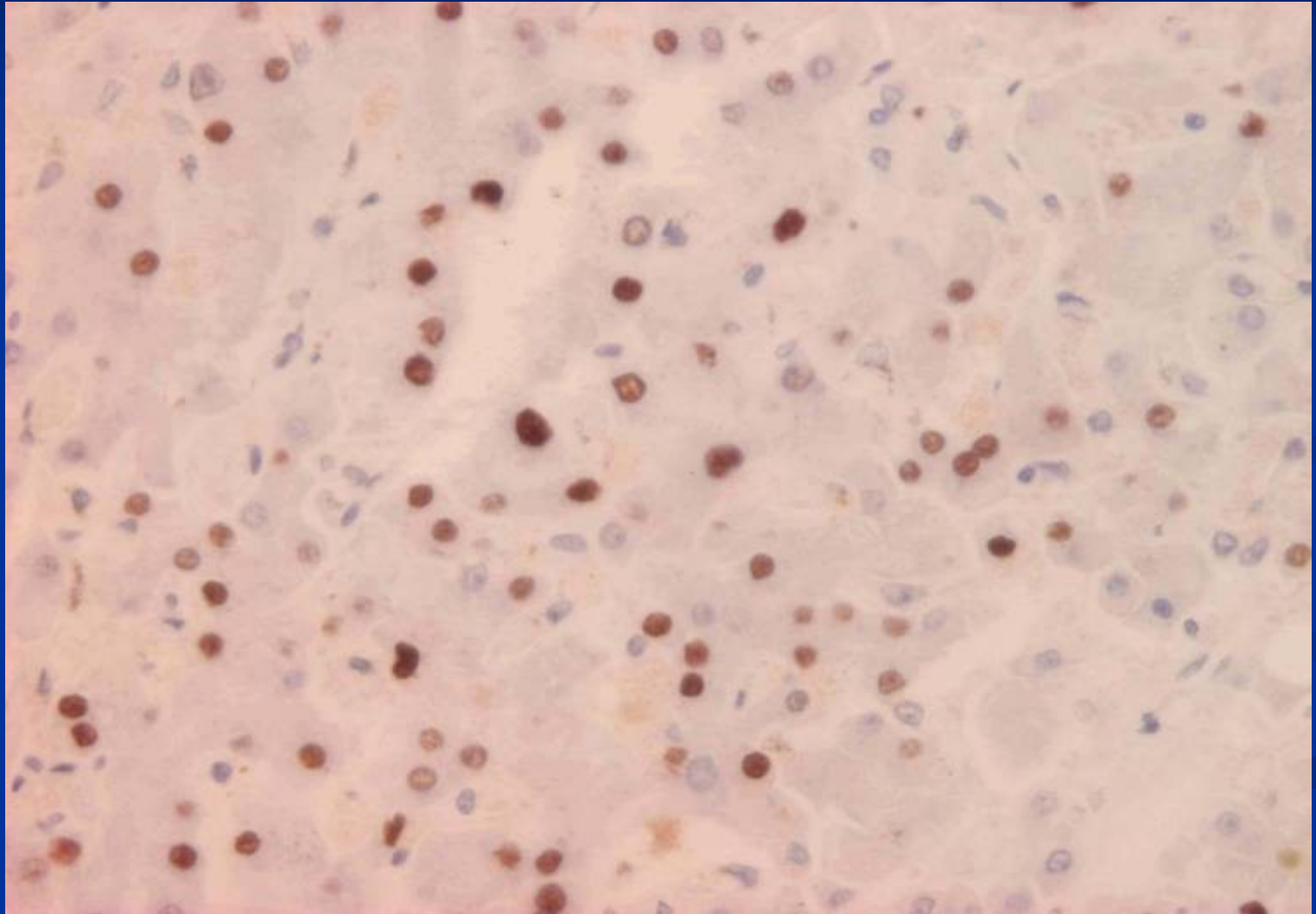
Viral hepatitis: HBsAg, ground glass



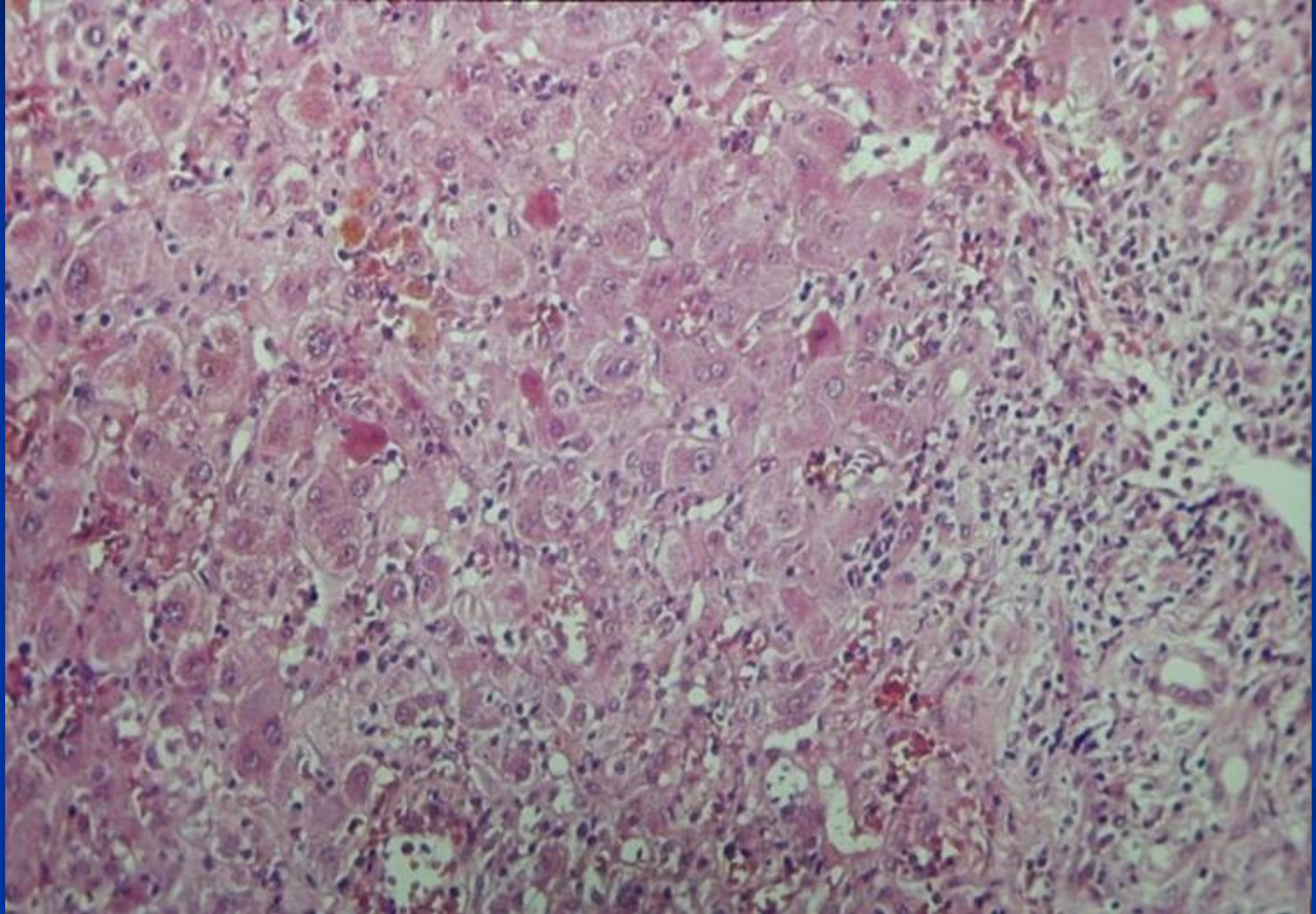
Viral hepatitis: HBsAg, Orcein staining



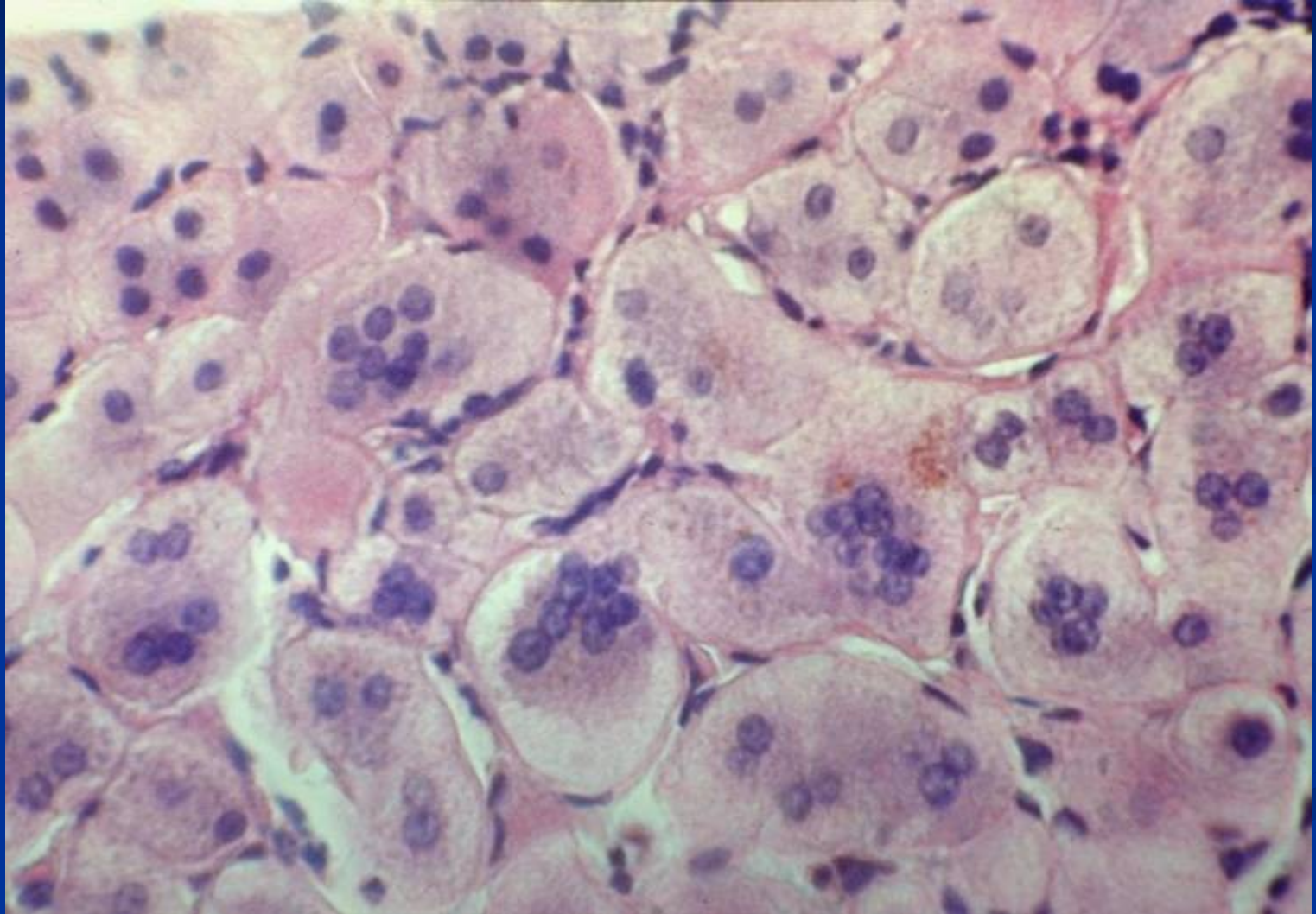
Viral hepatitis: HBcAg, immunohistochemistry



Acute hepatitis



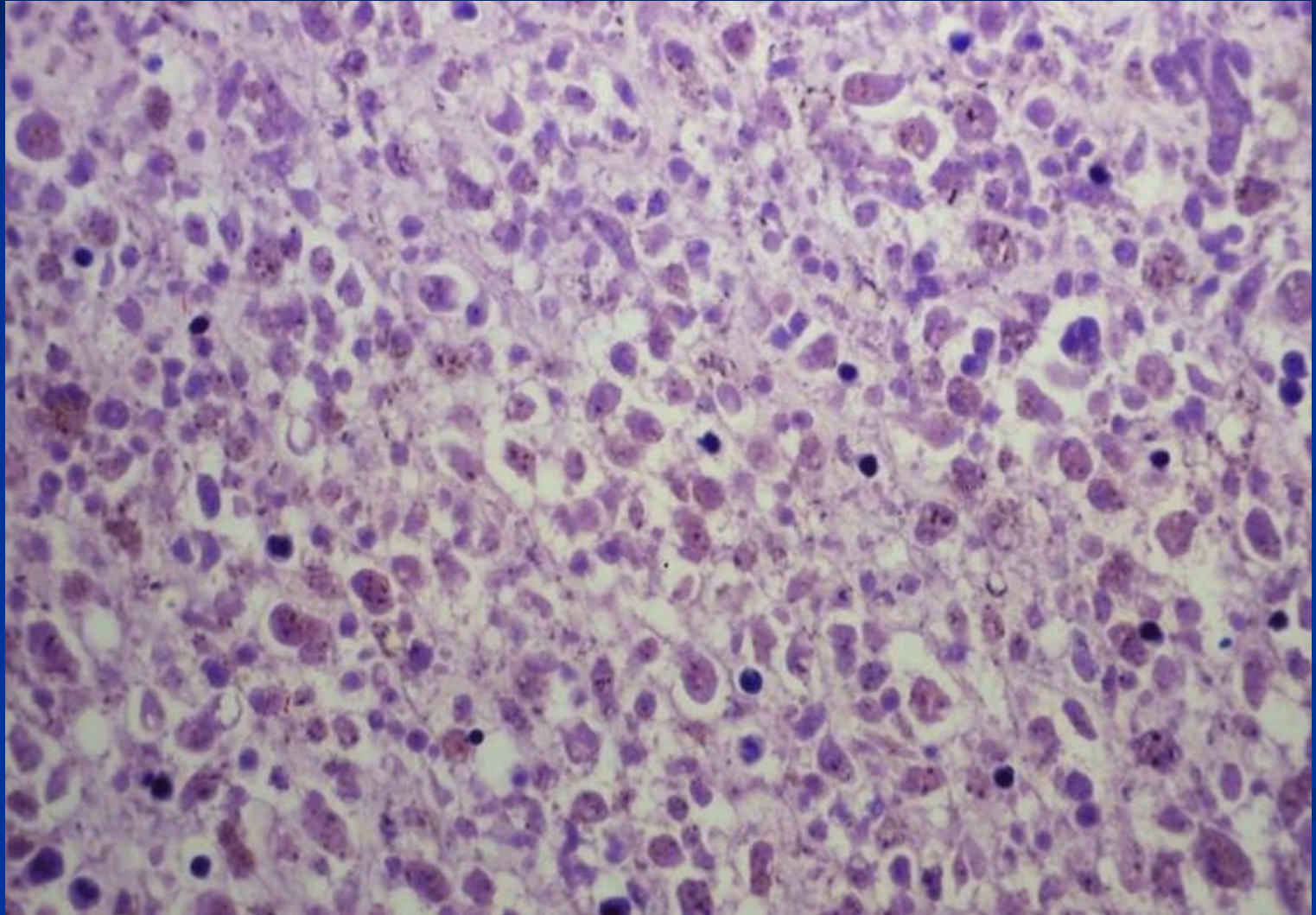
Acute hepatitis: regeneration



Fulminant hepatitis

- Grossly: soft consistency
- Microscopic: complete necrosis of parenchyma
- Course:
 - liver failure - coma - death
 - transplantation
 - regeneration – postnecrotic cirrhosis

Fulminant hepatitis: HBV



Other infections

- Viruses – EBV, CMV (in immunosuppressed)
- Malaria
- Schistosomiasis
- Leishmania

Liver abscess

- Low-income countries
 - Parasitic liver abscesses more common
 - E.g. amoeba; helminthic
- High-income countries
 - Bacterial or fungal origin more common
 - Complication of infections elsewhere or systemic
- Organisms reach liver via
 - Ascending infection in biliary tract (ascending cholangitis)
 - Vascular seeding → portal or arterial
 - Direct liver invasion from nearby source
 - Penetrating injury

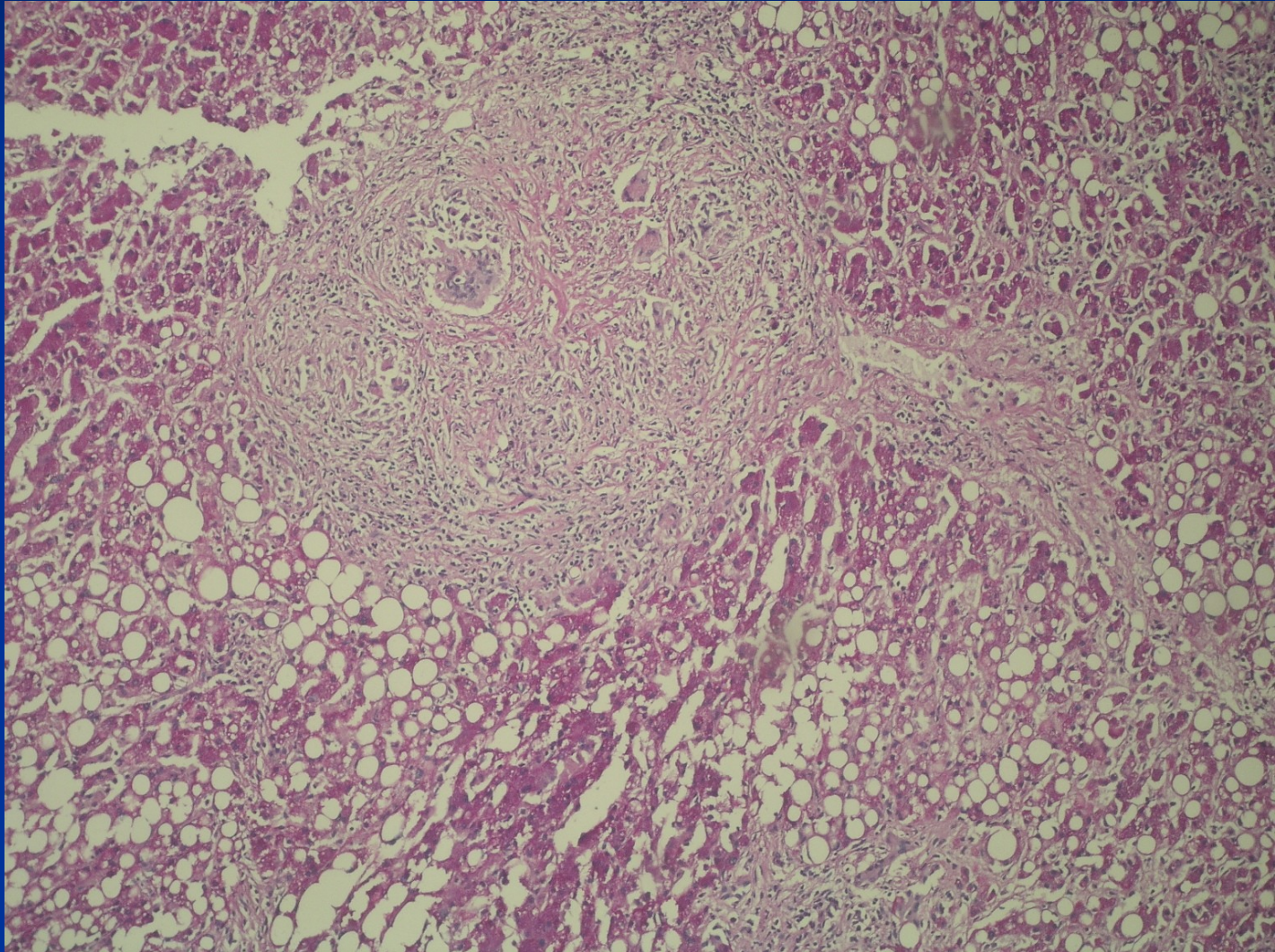
Liver abscess

- Risk factors: debilitating disease with immunodeficiency:
 - Immunocompromised
 - Chemotherapy
 - Old age
 - Bone marrow failure
- Pyogenic bacteria hepatic abscesses
 - Solitary or multiple lesions
 - Small to massive in size

Granulomatous inflammation

- Infections – tbc, typhoid, 3rd stage of syphilis, fungal, parasitic
- Sarcoidosis
- Granulomas as part of other diseases (primary biliary cholangitis, drug reaction,...)

Sarcoidosis



Chronic hepatitis: etiology

Hepatotropic viruses

Steatohepatitis – alcoholic, non-alcoholic NASH

Autoimmune

Drug induced

Metabolic (Wilson disease, hemochromatosis, α 1-antitrypsin deficiency)

Cryptogenic

Chronic hepatitis: clinical definition

Clinical symptoms of hepatitis more than:

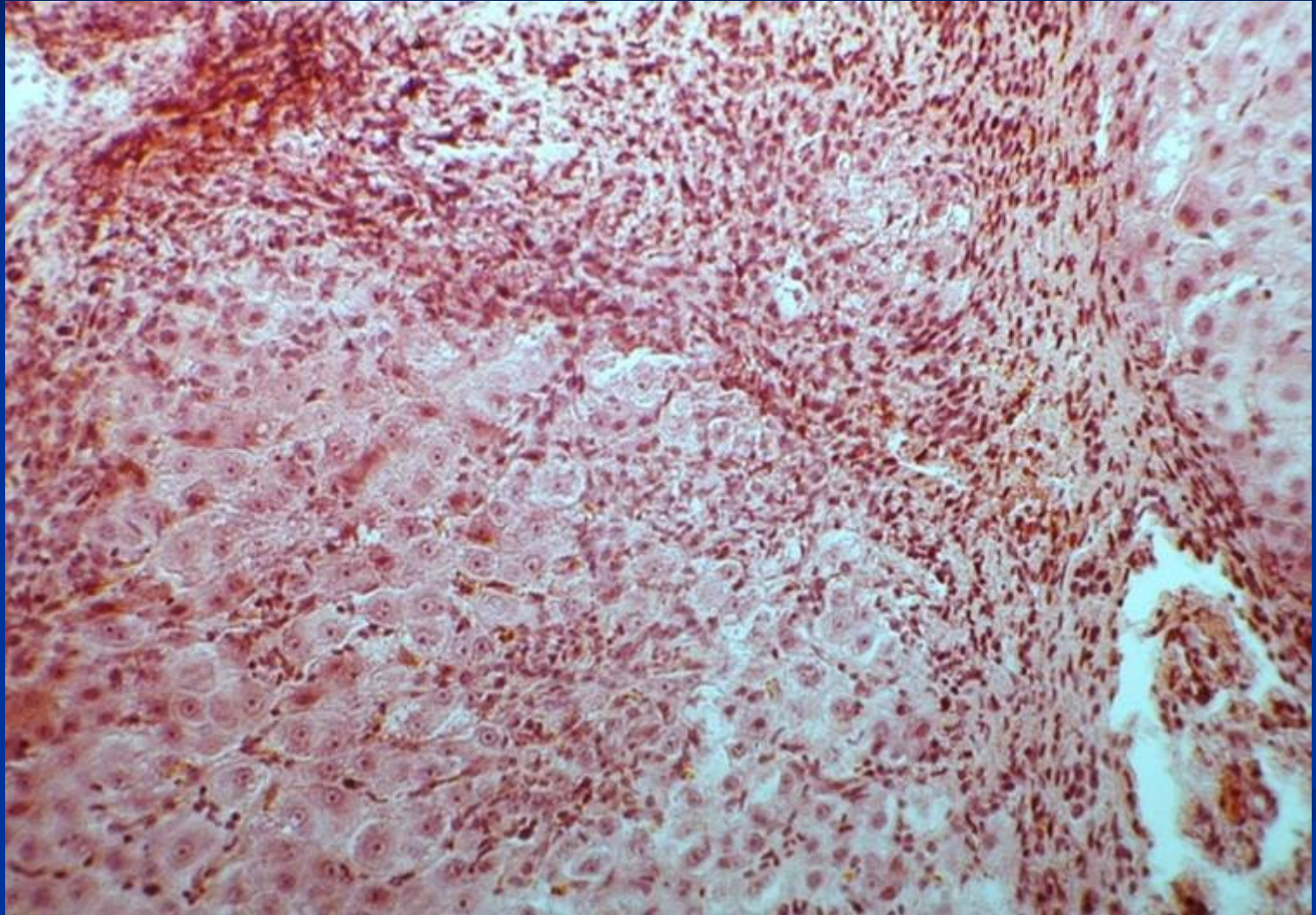
6 months

12 months in HCV

Chronic hepatitis - histopathology

- **Disease activity:** grade of necroinflammatory changes in portal spaces and lobules (interface activity; type, grade and localisation of necrosis; grade of inflammatory infiltrate)
- **Disease stage:** stage of fibrosis and architectural changes (portal fibrotic expansion, bridging fibrosis, nodularity → advanced stage/cirrhosis)

Chronic hepatitis: high grade



Toxic and drug induced liver damage: effect

Most substances completely or partially metabolized in liver → wide area for possible pathologic reactions and changes

- Injury due to
 - Direct toxicity
 - Conversion of drug/non-endogenous substance to active toxin
 - Immune mechanisms → drug/toxin acting as a haptenAcute or chronic.

- **Expectable (intrinsic):** typical reaction, known for drug/dose/patient (i.e. acetaminophen)
- **Non-expectable (idiosyncratic):** atypical immunologic reaction, non-preventable, often combination of multiple factors

Toxic and drug induced liver damage

- **Anorganic substances**
- **Organic substances**
- **Industrial substances**
- **Poisons/venoms**
- **Drugs**
- **Alcohol**

Toxic and drug induced liver damage : forms

Generally any form of damage possible (diff. dg.!)</p></div><div data-bbox="84 261 738 753" data-label="List-Group"><ul style="list-style-type: none;"><li data-bbox="84 261 658 307">▪ **Necrosis** (acetaminophen/paracetamol)<li data-bbox="84 325 738 500">▪ **Steatosis**

Cholestasis (steroids-anabolic, contraceptives)<li data-bbox="84 582 718 628">▪ **Hepatitis mild** (aspirin, synthetic penicilines)<li data-bbox="84 646 488 692">▪ **Hepatitis serious** (halotan)<li data-bbox="84 710 738 756">▪ **Chronic periportal hepatitis** (sulphonamides)</div>

Toxic and drug induced liver damage : forms

- **Granulomatous hepatitis** (phenylbutazone)
- **Vascular lesions** (contraceptives, cytostatics)
- **Hyperplasia, neoplasia** (contraceptives)

Alcoholic liver disease (ALD)

- **Steatosis (90%)**
- **Acoholic steatohepatitis**
- **Alcoholic cirrhosis**
- **Hepatocellular carcinoma**

Diff. dg: NAFLD/NASH (non-alcoholic fatty liver disease/ non-alcoholic steatohepatitis)

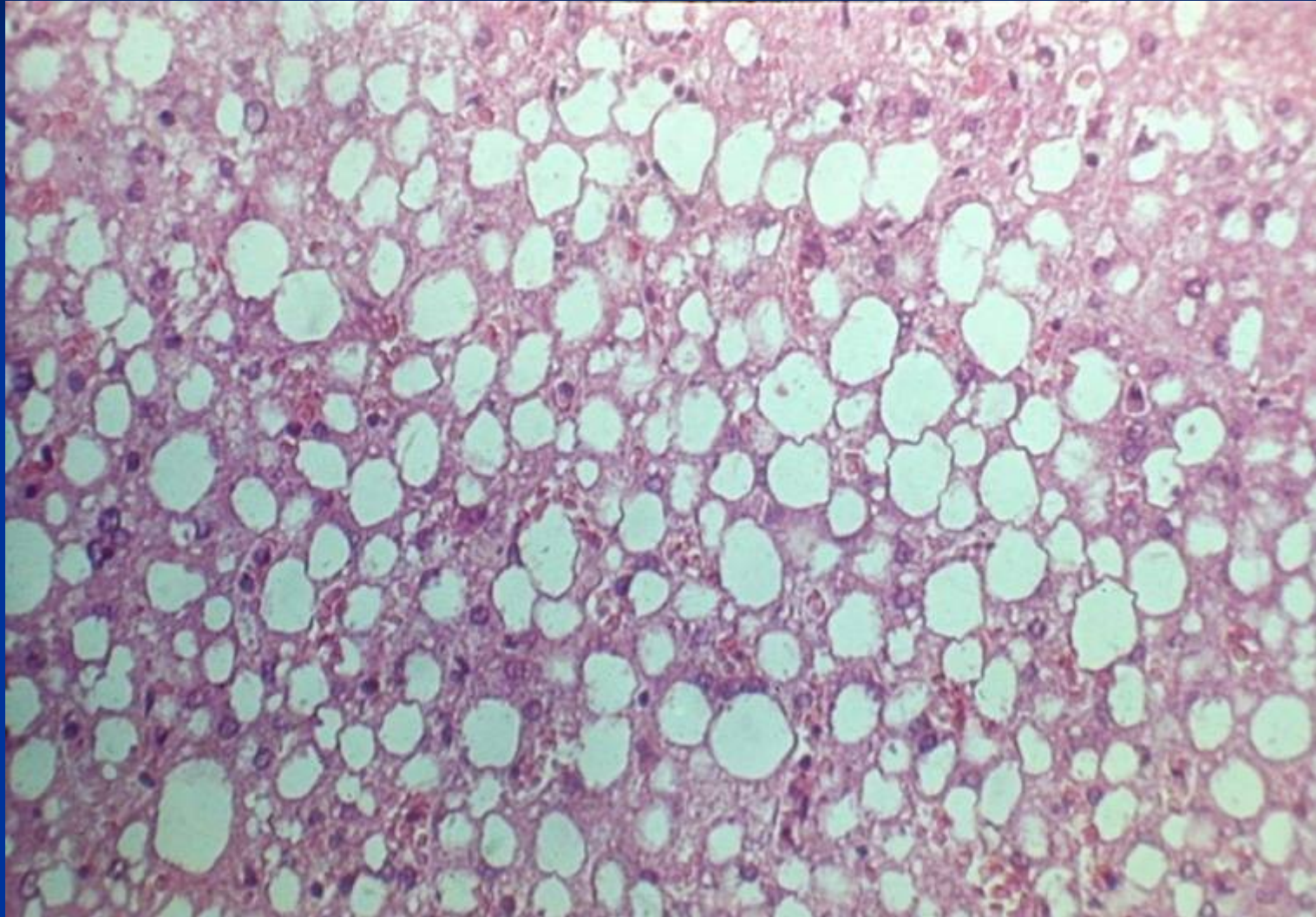
Alcoholic liver disease

- Alcohol abuse: common cause of serious liver disease in Western societies
- Asymptomatic people who drank moderate-to-heavy amounts of alcohol: prevalence of alcoholic hepatitis - 25-30%.
- the 1-year mortality rate after hospitalization for acute alcoholic hepatitis is approximately 40%.

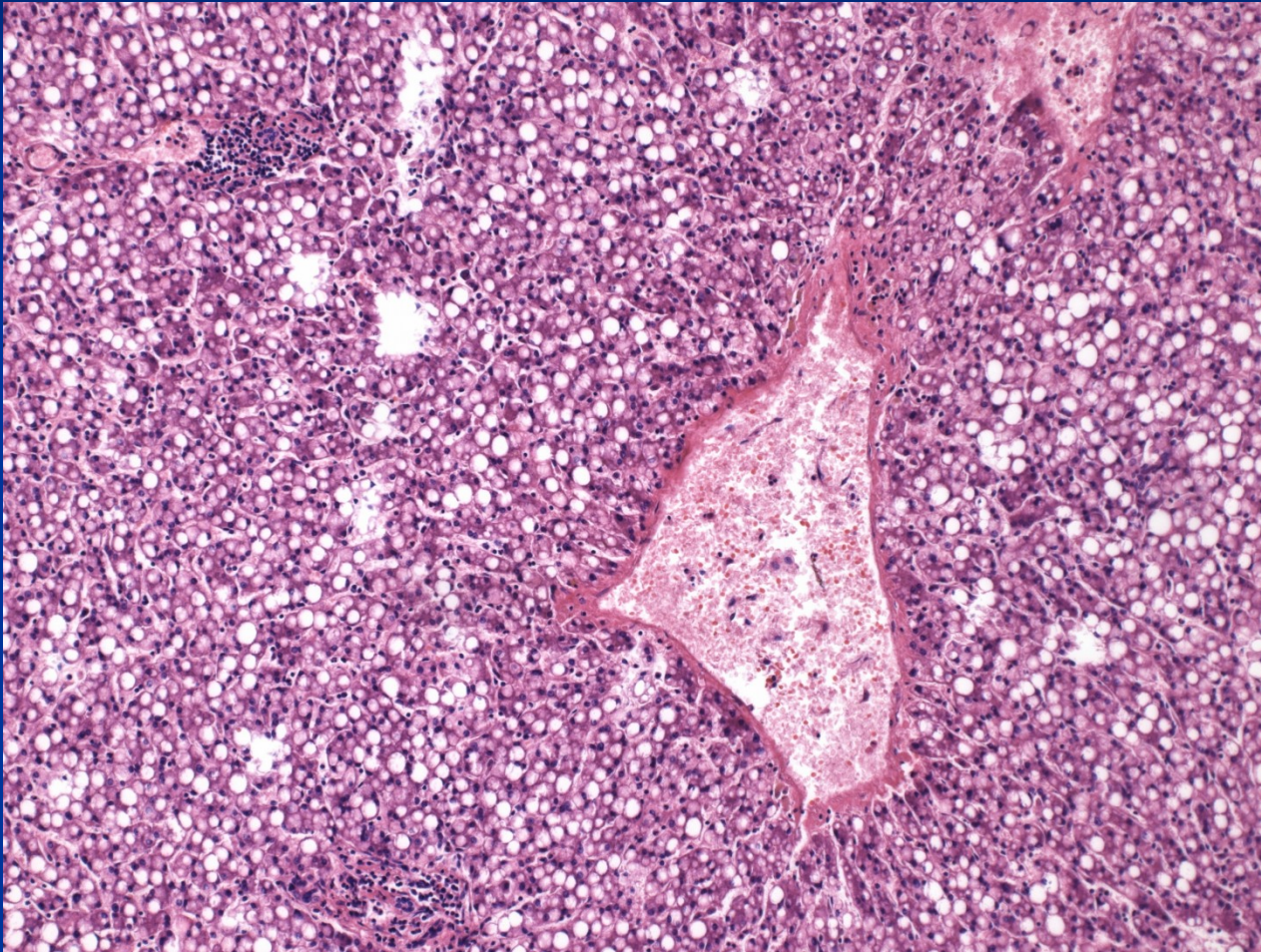
Alcoholic liver disease

- Estimated minimum daily ethanol intake required for the development of cirrhosis:
 - 40 g for adult males
 - 20 g for adult females
 - different individual susceptibility (genetic, environmental)
- Patients who continue to drink after a diagnosis of alcoholic liver disease:
 - 5-year survival rate ~ 30% for females
 - 70% for males

Alcoholic liver disease (ALD) : steatosis



Steatohepatitis



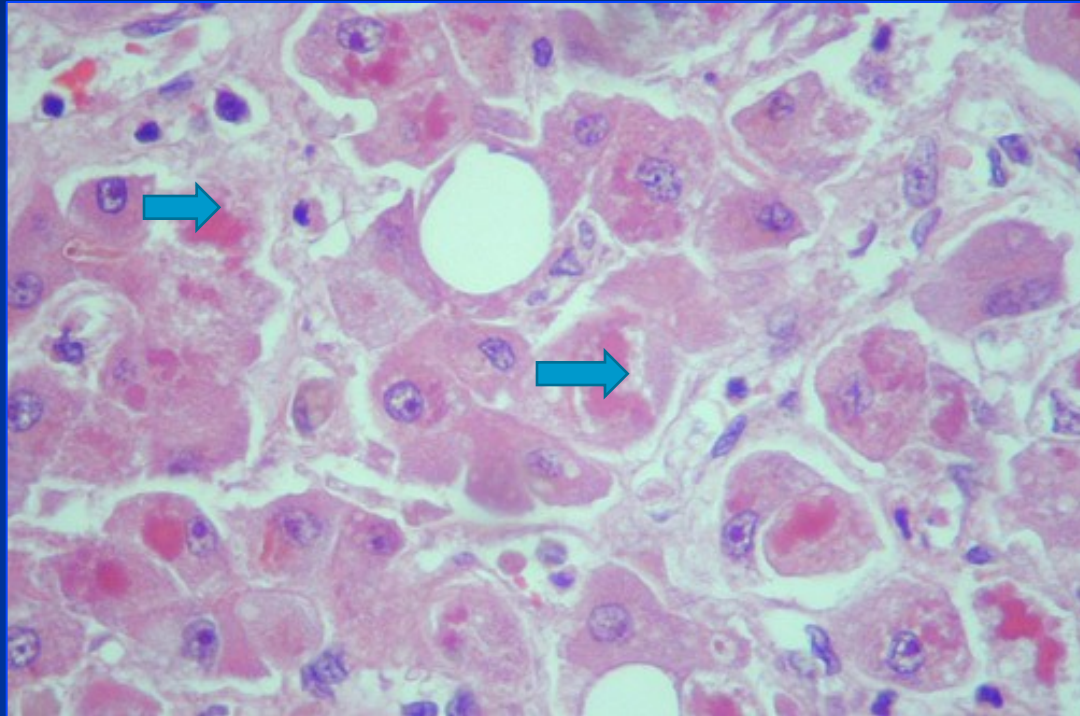
Alcoholic hepatitis

- syndrome of progressive inflammatory liver injury associated with long-term heavy intake of ethanol
- subacute onset of *fever*, hepatomegaly, leukocytosis, marked *impairment of liver function* (eg. jaundice, coagulopathy), and manifestations of *portal hypertension* (eg, ascites, hepatic encephalopathy, variceal hemorrhage).

Alcoholic hepatitis

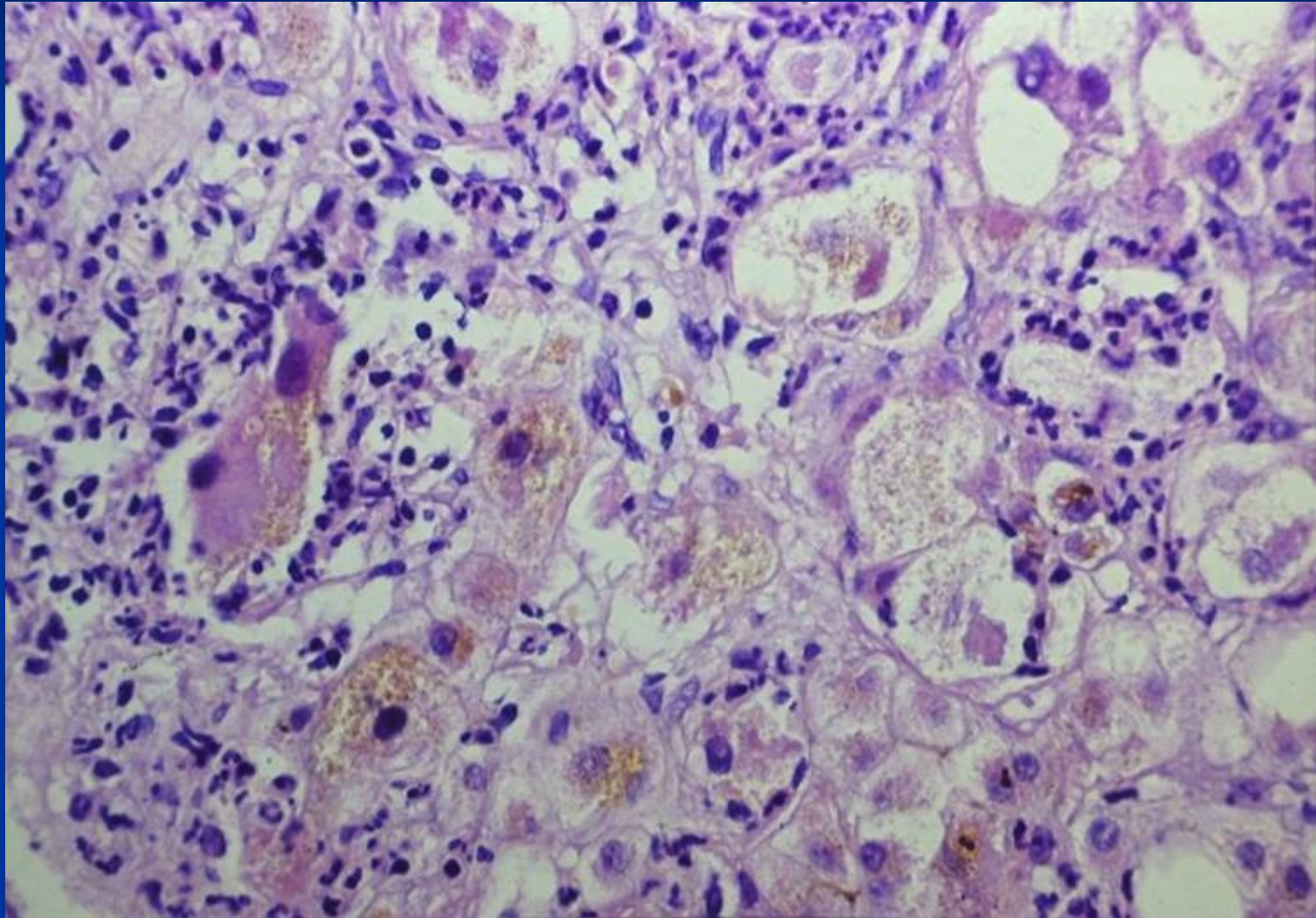
- Centrilobular ballooning necrosis of hepatocytes, neutrophilic infiltration, Mallory hyaline inclusions. Steatosis and cirrhosis frequent.
- Usually persists and progresses to advanced stage/cirrhosis if heavy alcohol use continues
- Alcohol consumption may exacerbate injury caused by other pathogenic factors, incl. hepatitis viruses.

Alcoholic hepatitis



Mallory-Denk bodies: globular red hyaline material within hepatocytes, not entirely specific for alcoholic etiology.

Alcoholic hepatitis : steatohepatitis, cholestasis, Mallory-Denk bodies



NAFLD/NASH: non-alcoholic fatty liver disease/steatohepatitis

Spreading silent epidemics

In many countries the most common chronic liver disease

Patients with metabolic/insulin resistance syndrome:

„male-type“ obesity (intraabdominal fat accumulation – waist size)

hyperlipidemia

DM of II type, hyperglycaemia

NASH: non-alcoholic steatohepatitis

Other diseases related to NASH

Acquired metabolic diseases (parenteral nutrition)

Inherited metabolic diseases

(abetalipoproteinaemia, tyrosinaemia)

Surgery (jejunoileal bypass, extensive resections of small intestine...)

Drugs, toxins (amiodarone, glucocorticoids, tamoxifen, synthetic estrogens...)

NASH: non-alcoholic steatohepatitis

Hepatomegaly

Increase of aminotransferases (ALT>AST)

Histology – similar to alcoholic hepatitis without alcohol consumption, glycogenated „clear“ nuclei of hepatocytes, ...

Natural history – may lead to advanced stage/cirrhosis, etc.

Autoimmune hepatitis - AIH

- Chronic disease of unknown cause, continuing hepatocellular inflammation and necrosis → advanced stage/cirrhosis
- Immune serum markers (autoantibodies ANA, ...) frequently present, common association with other autoimmune diseases.
- Response to steroid and/or immunosuppressive therapy
- In progressive + relapsing disease - transplantation

AIH

- 70-80% of patients are women
- acute hepatitis, chronic hepatitis, or well-established advanced stage/cirrhosis.
- symptoms of acute hepatitis marked by fever, hepatic tenderness, and jaundice.
- non-specific signs: pruritus, skin rash, myalgia, diarrhea, etc.

Advanced stage liver disease/Cirrhosis

- Alcoholic liver disease (60%, rising tendency)
- Cryptogenic (hidden) cirrhosis, usually former NASH (10-15%, ↑)
- Viral hepatitis → HBV, HCV (10%, HBV ↓, HCV expected ↓ - antivirotics)
- Hereditary haemochromatosis
- Autoimmune liver disease
 - Autoimmune hepatitis
 - Primary biliary cholangitis (PBC)
- Recurrent biliary obstruction (5-10%)
- Wilson disease; AAT deficiency (rare)

Pathogenesis

- Hepatocellular death → regeneration → recurrent death → nodularity lacking zonal structure
- Progressive stimulus for synthesis + deposition of collagen (chronic inflammatory cytokine production, direct stimulation of stellate cells) → fibrosis
- Shunts develop → sinusoids become high pressure, fast flowing vascular channels → no solute exchange

Morphology

Micronodular cirrhosis

Nodules <3mm diameter, common in alcoholic hepatitis; may be a late stage of cirrhosis with low activity

Macronodular cirrhosis

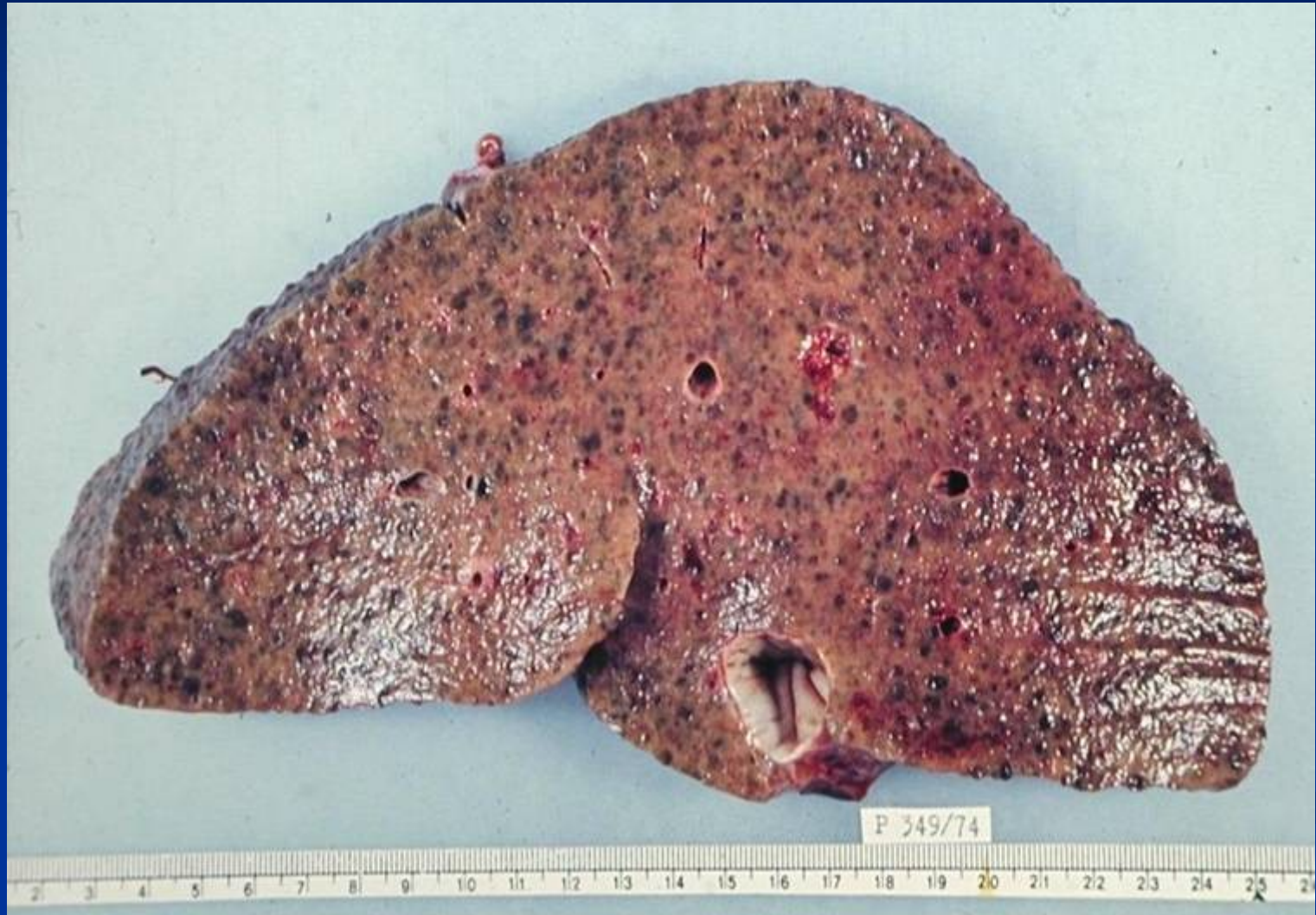Nodules >3mm diameter, uneven changes, early stage of active cirrhosis

Mixed cirrhosis

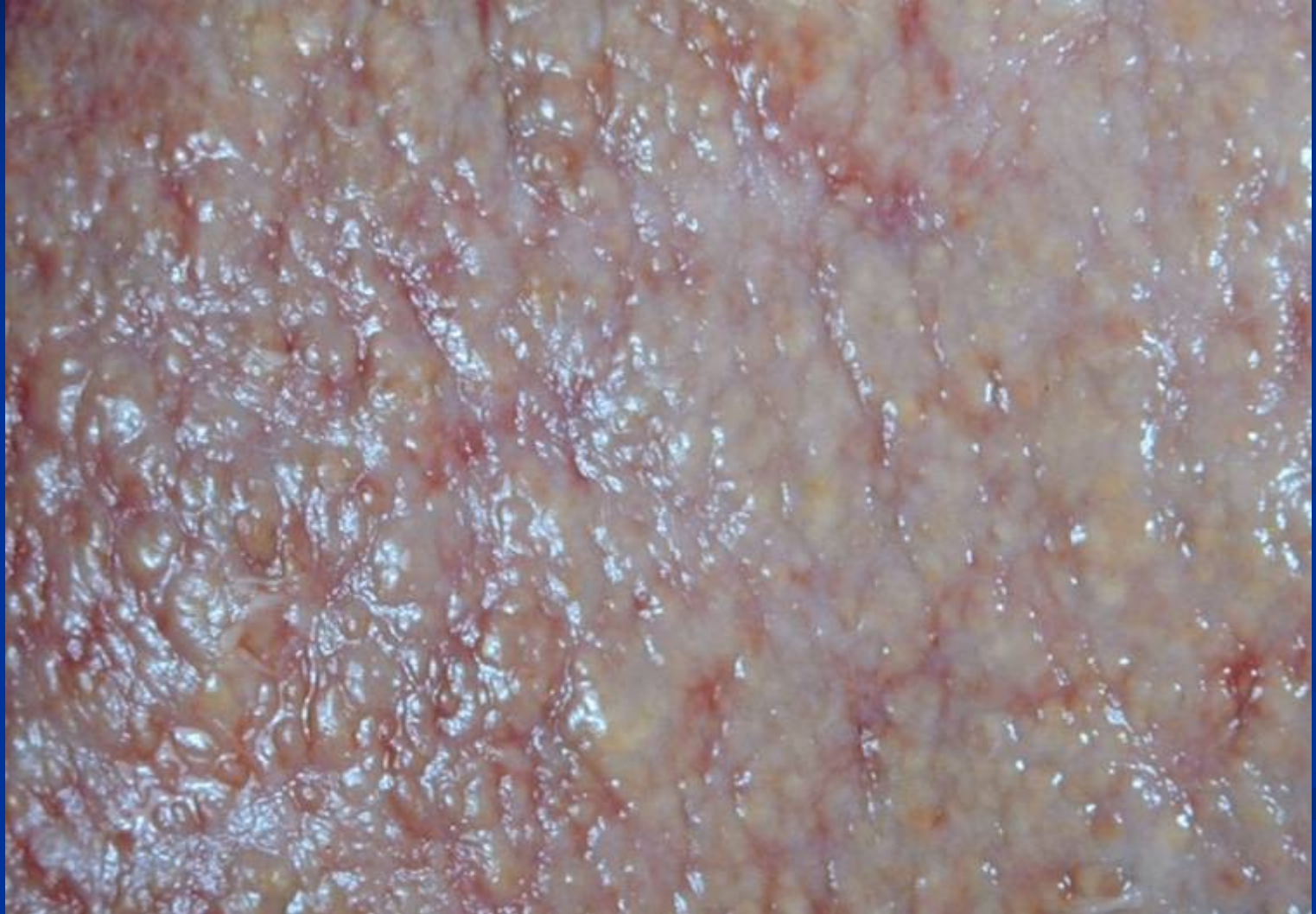Intermediate between the above categories, in progression

Pattern not stable, possibility of progression and/or regression

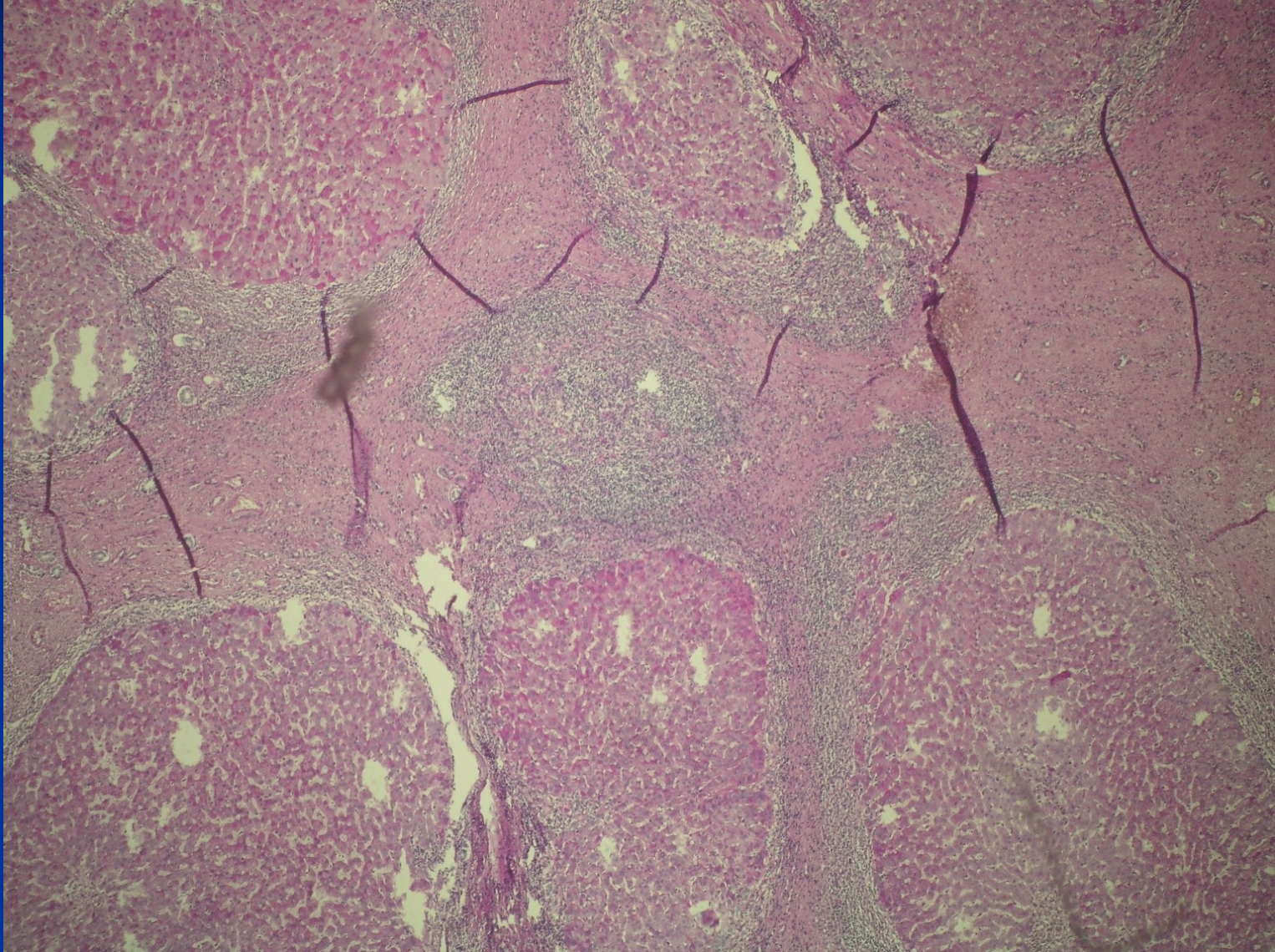
Advanced stage / Cirrhosis



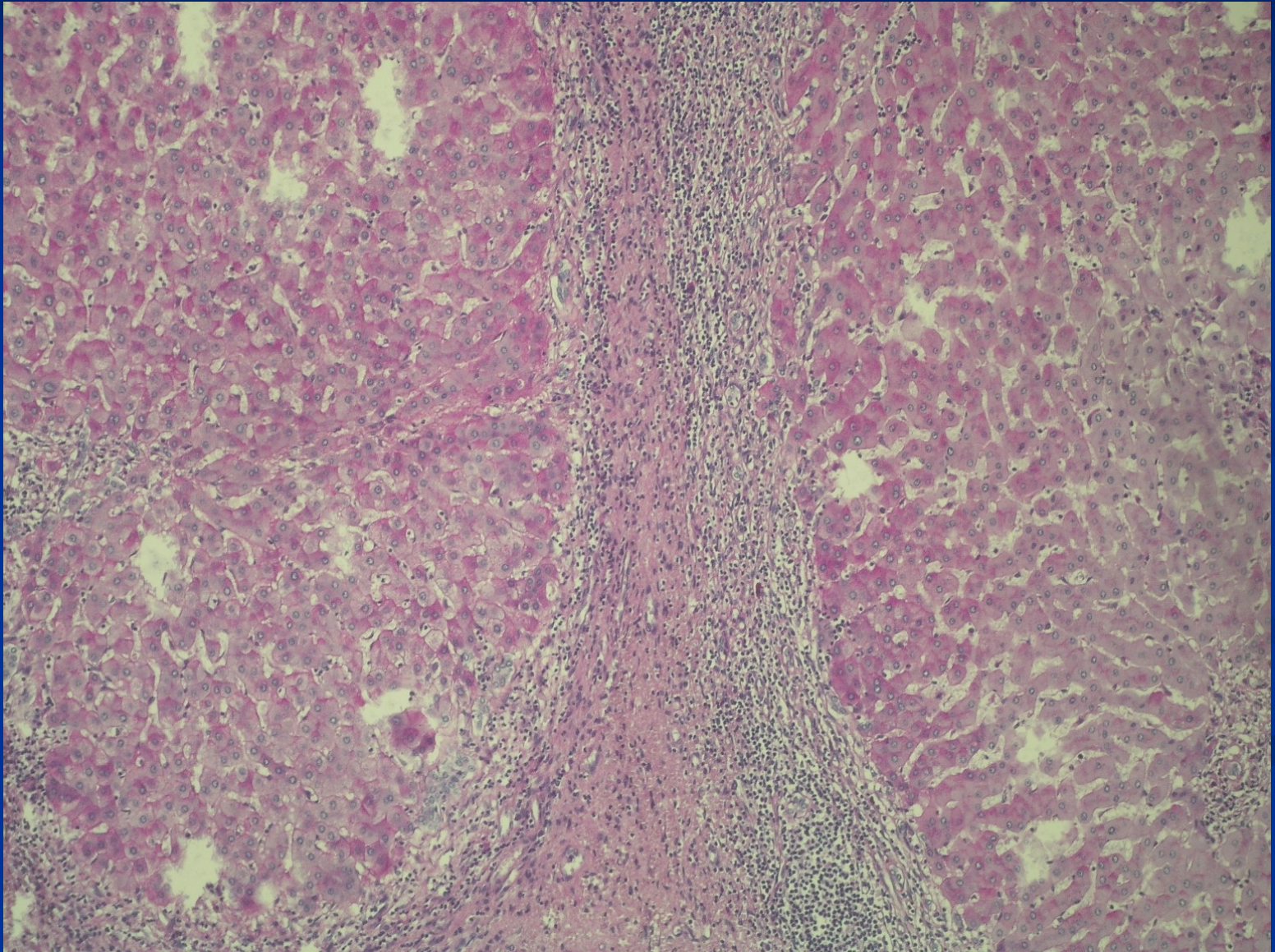
Advanced stage / Cirrhosis



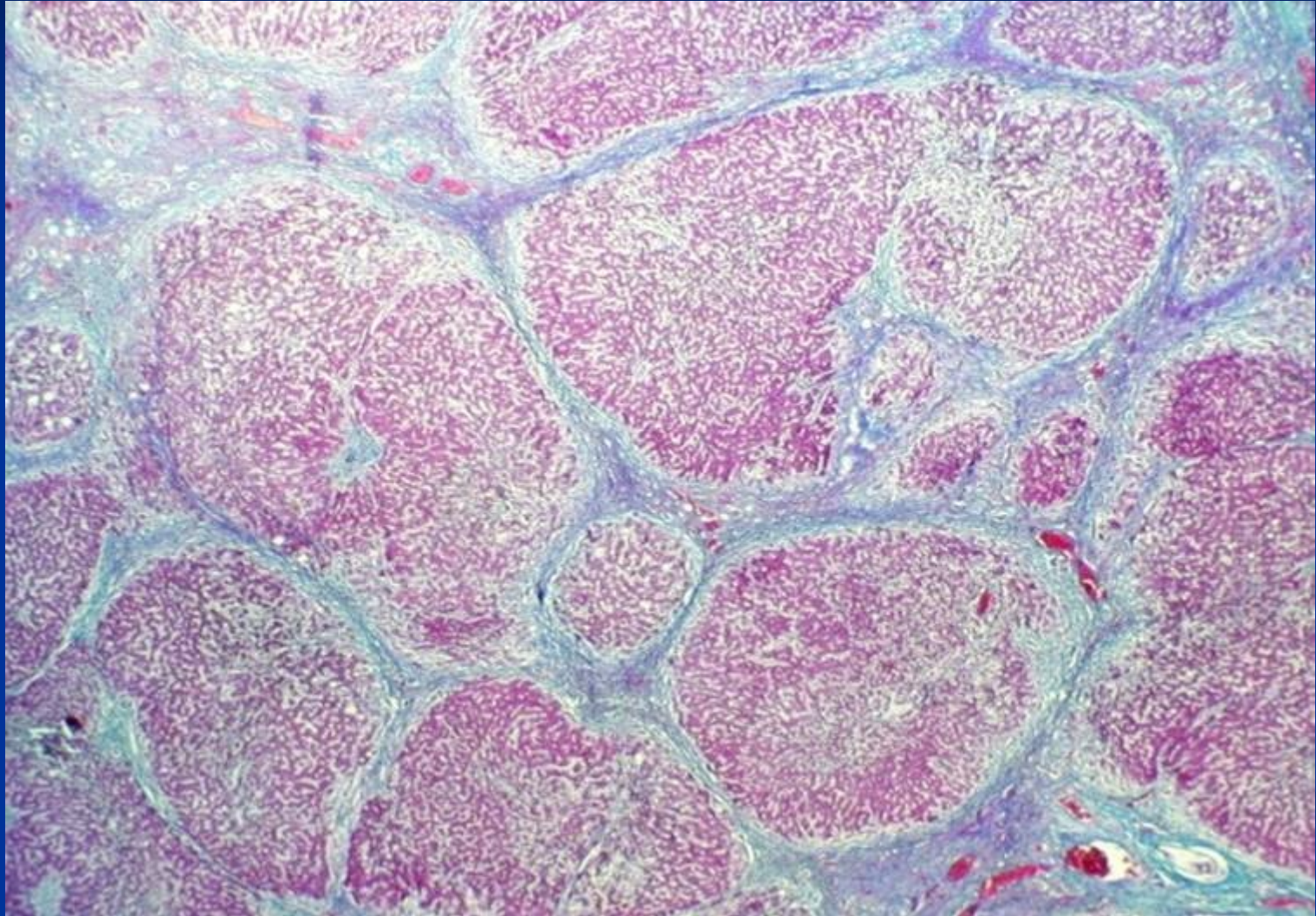
Advanced stage / Cirrhosis



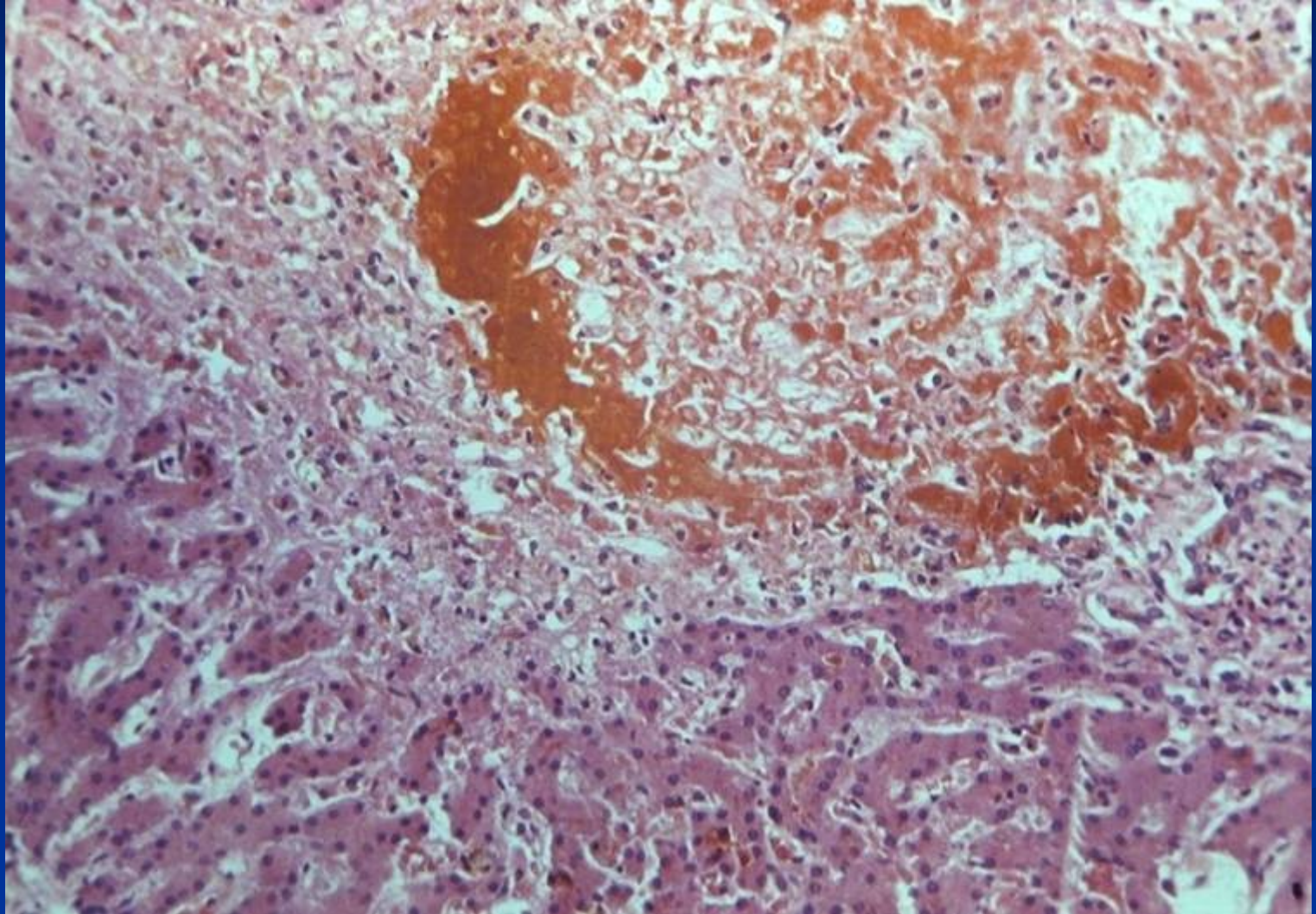
Advanced stage / Cirrhosis

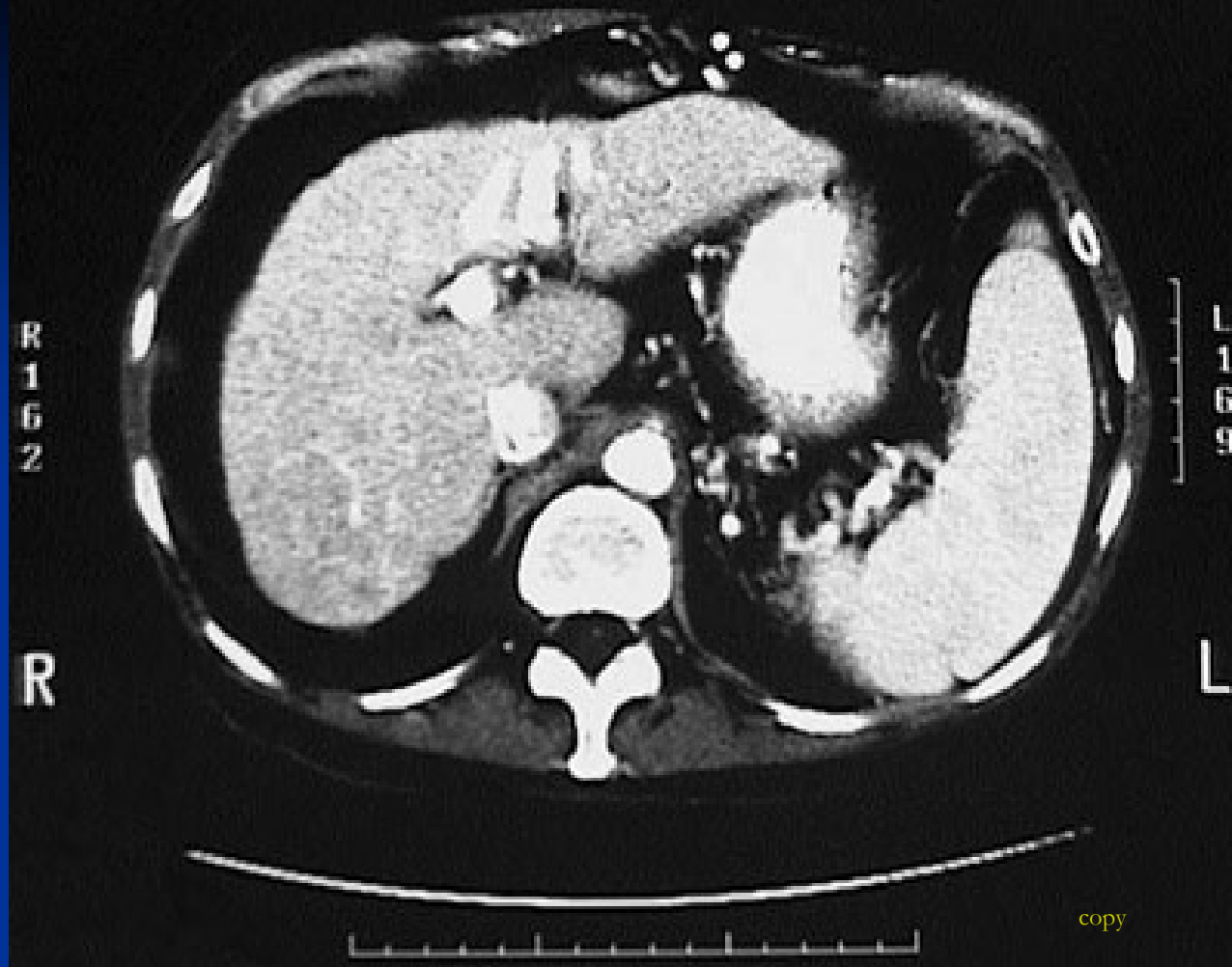


Advanced stage / Cirrhosis: Masson staining



Advanced stage / Cirrhosis: biliary





CT scan with contrast of the abdomen in transverse view demonstrates a **small liver with cirrhosis**. The spleen is enlarged from portal hypertension.

Pathology of intrahepatic bile ducts

- Inborn defects
- Cholelithiasis
- **Inflammation – infection** – cholangitis, usually ascending.
Secondary biliary cirrhosis

Immunologically mediated inflammatory disorders

- Primary biliary cholangitis (PBC)
- Primary sclerosing cholangitis (PSC)

Preneoplastic lesions + tumors

Cholangitis

- infection of the biliary tract
- choledocholithiasis → biliary tract obstruction → cholangitis.
- biliary tract interventions and stents - common causes of cholangitis.
- hepatobiliary malignancies

Cholangitis

- Triad of fever, jaundice, and right upper quadrant pain.
- Multiple organisms in 60% of patients. Aerobic *Escherichia coli*, *Klebsiella*, *Enterococcus*; anaerobic *Bacteroides fragilis*.

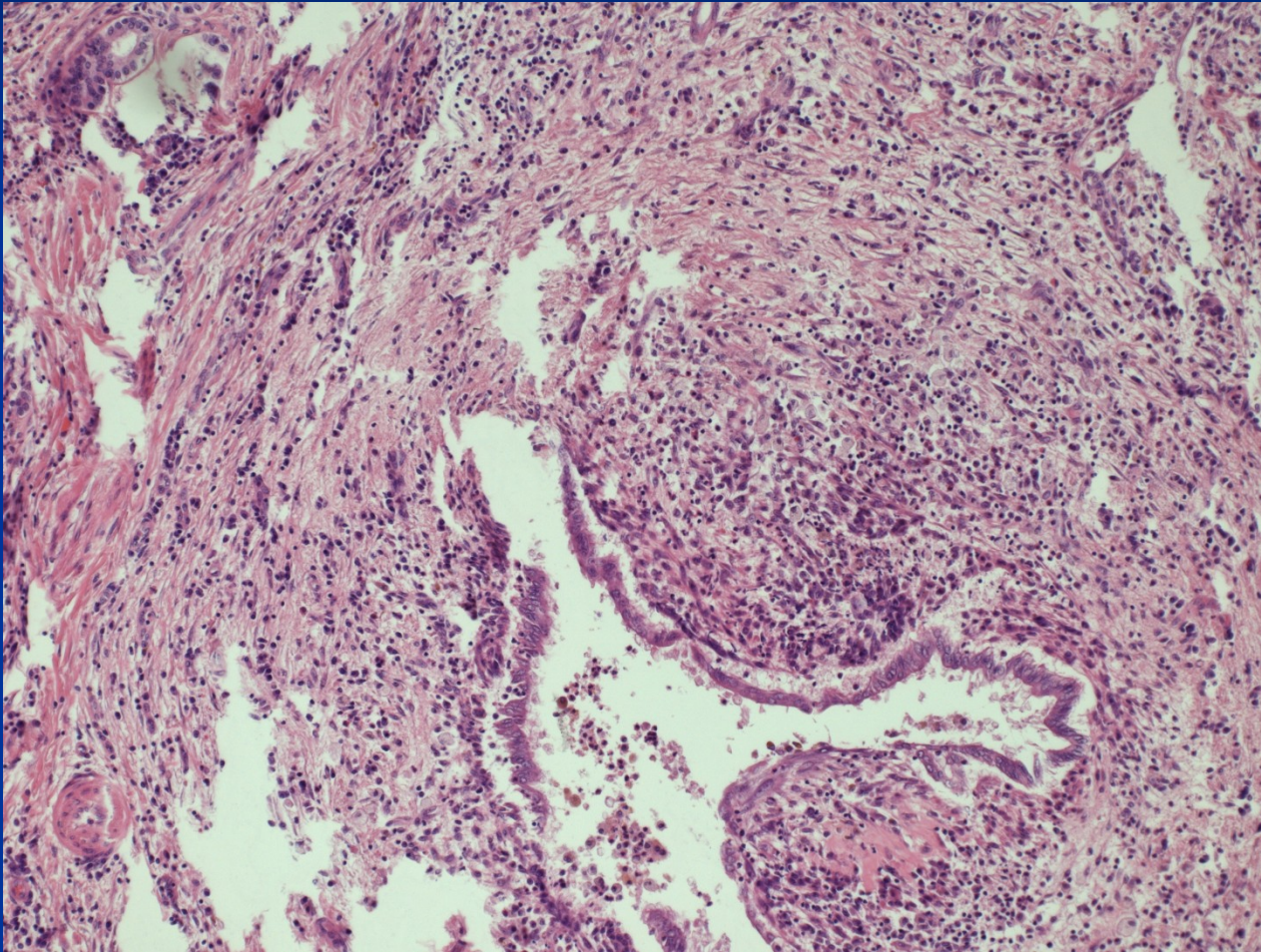
Primary sclerosing cholangitis - PSC

- progressive chronic liver disease - cholestasis with inflammation and fibrosis of the intrahepatic and extrahepatic bile ducts → cirrhosis
- unknown etiology
- autoimmune mechanism
- some cases part of IgG4-associated systemic sclerosing disease
- 75-90% of patients with PSC have inflammatory bowel disease (IBD).
- exposure of genetically predisposed individuals to an environmental antigen that subsequently elicits an aberrant immune response

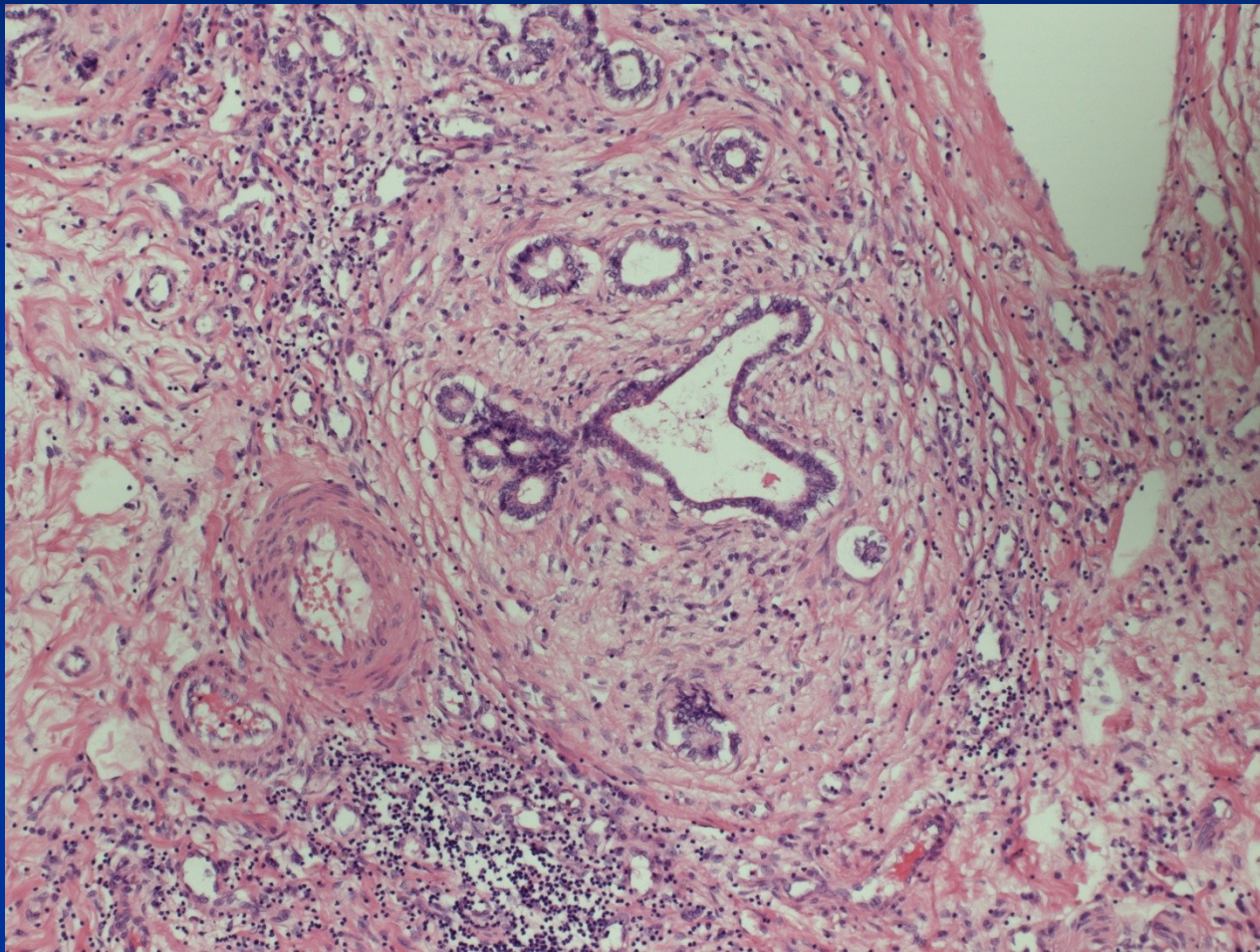
Primary sclerosing cholangitis - PSC

- The median length of survival from diagnosis to death ~ 12 years.
- 70% of patients with PSC males,
- Mean age of diagnosis around 40 years
- Histology: inflammation and obliterative fibrosis of large intrahepatic/extrahepatic bile ducts. Concentric periductal fibrosis.
- Risk of cholangiocellular carcinoma (diff. dg.!)

PSC – duct destruction



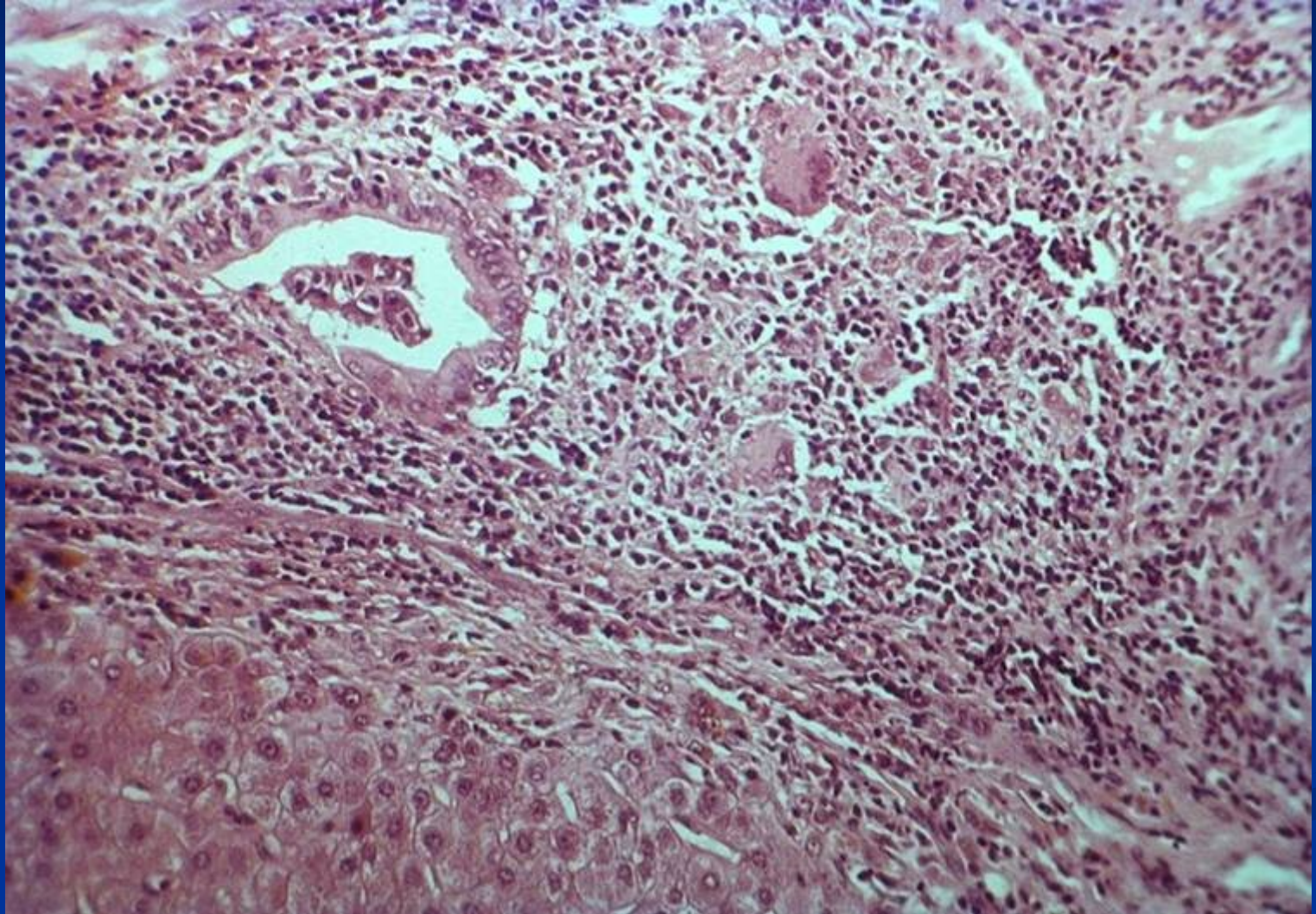
PSC – peribiliary fibrosis



Primary biliary cholangitis PBC

- Middle-aged women
- M:F = 1:10
- Autoimmune (AMA), + other AI -Sjögren sy., arthritis, thyroiditis, vasculitis
- Insidious onset, usually pruritus, hepatomegaly
- Hyperbilirubinemia, jaundice, cirrhosis late
- ↑ alkaline phosphatase, cholesterol
- Nonsuppurative, granulomatous destruction of medium-sized intrahepatic bile ducts = florid duct lesion

PBC: duct lesion



Secondary biliary cirrhosis

Obstruction of extrahepatal bile ducts: atresia, lithiasis, tumor, iatrogenic

- Most common cause is extrahepatic cholelithiasis
- Biliary atresia, malignancies of the biliary tree and head of the pancreas, and strictures

Cholestasis

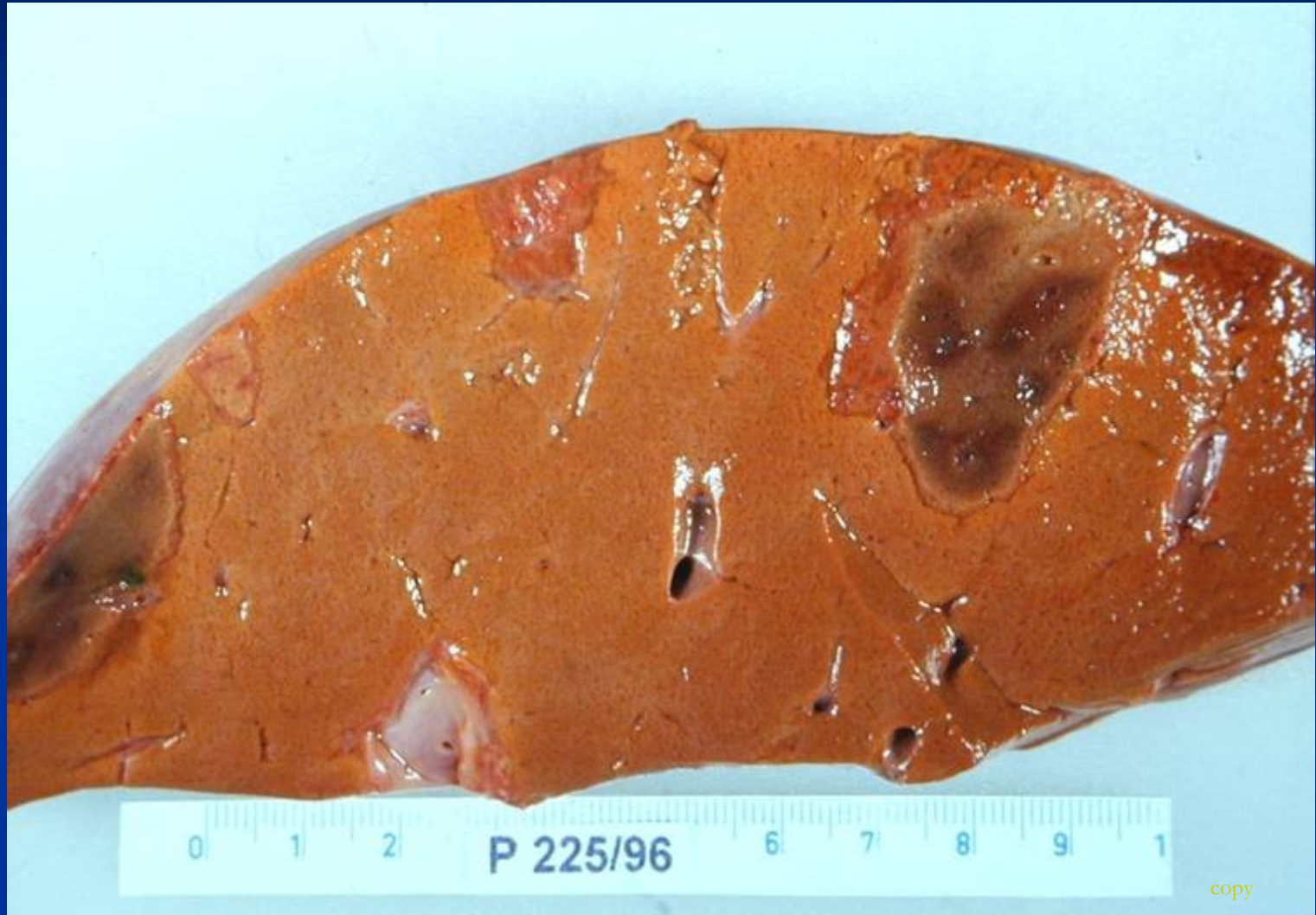Bile duct proliferation with surrounding neutrophils

Periportal fibrosis

Circulatory disorders of the liver

- **Disorders of arterial system** (liver infarct, ...)
- **Disorders of portal system** (portal vein occlusion)
- **Disorders of venous system** (hepatic vein thrombosis, ...)
- **Disorders of sinusoids**

Liver infarct

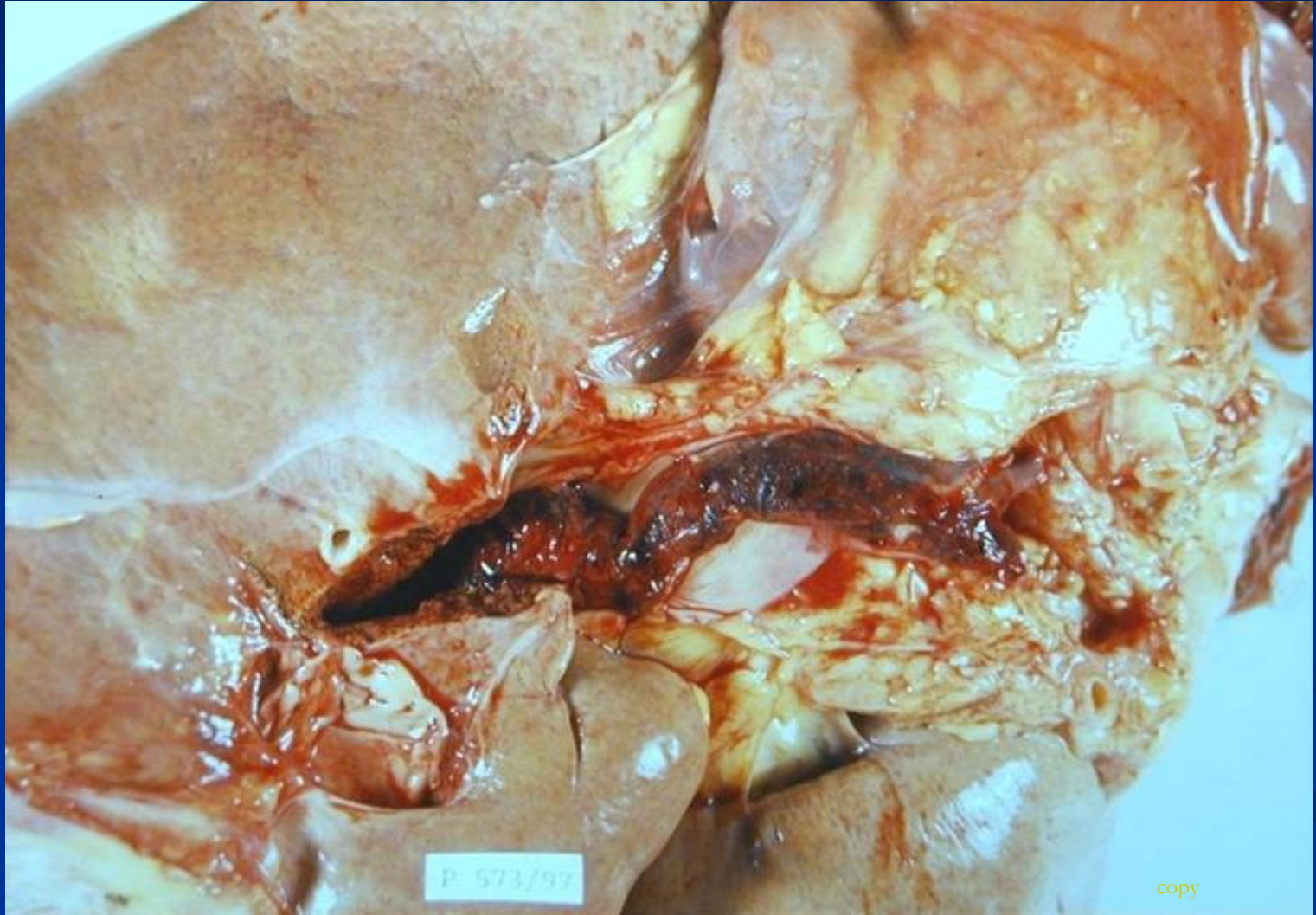

Disorders of portal system

Thrombosis and occlusion of v. portae

- **Extrahepatal** (phlebitis, pancreatitis, surgery, trauma)
- **Intrahepatal** (invasion of tumor). No ischemic infarction, area of red-blue discoloration (infarct of Zahn).

Thrombosis of v.portae



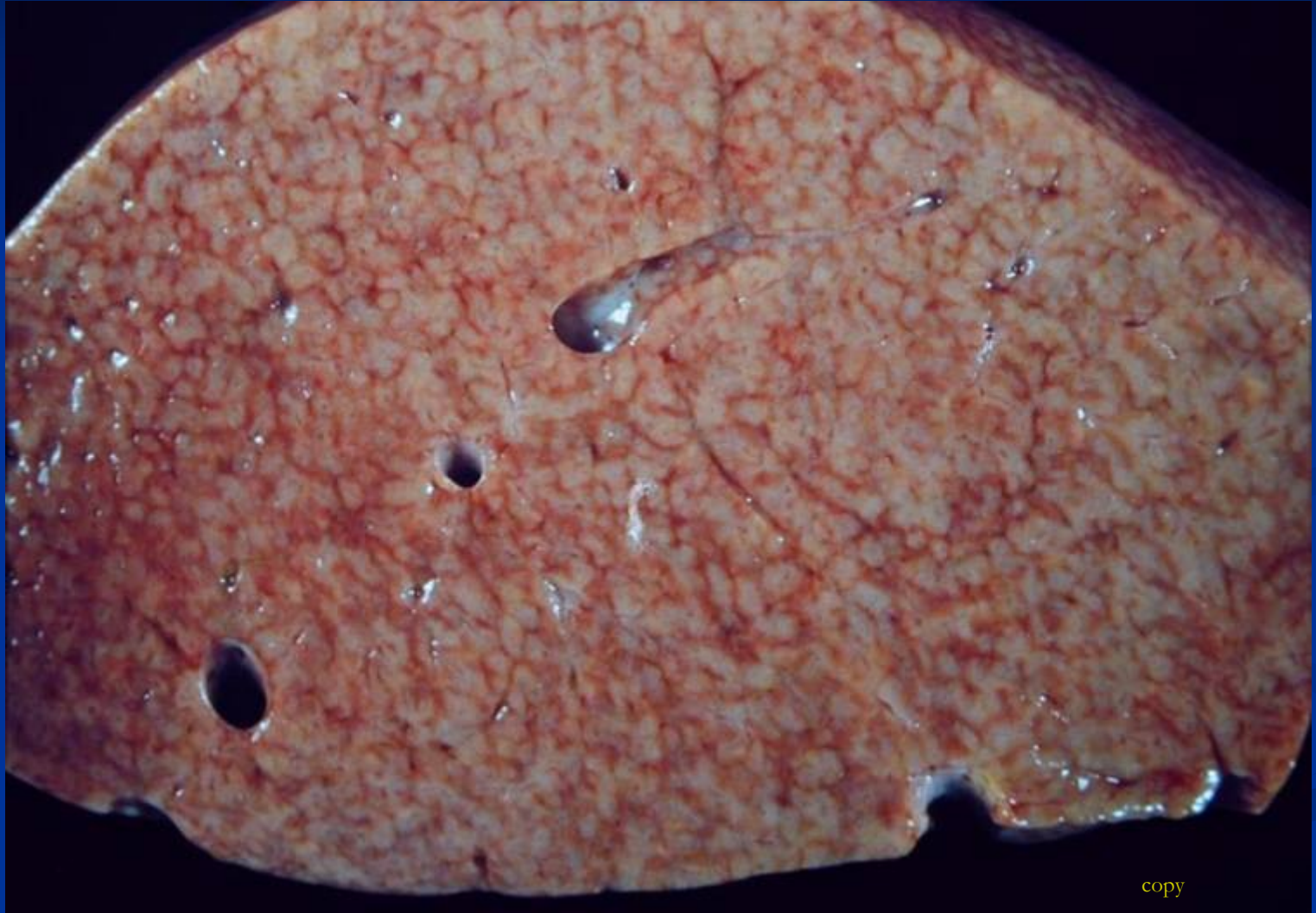Disorders of sinusoids

Occlusion of sinuses: cirrhosis, eclampsy (DIC), sickle cell anaemia

Systemic circulation: right-sided heart failure → congestion of centrilobular sinusoids, nutmeg liver (venostasis/steatosis)

Left-sided heart failure → hypoperfusion and hypoxia → centrilobular necrosis

Congestion



copy

Focal lesions and tumors

- Tumor-like lesions
- Benign tumors
- Malignant tumors: primary, secondary

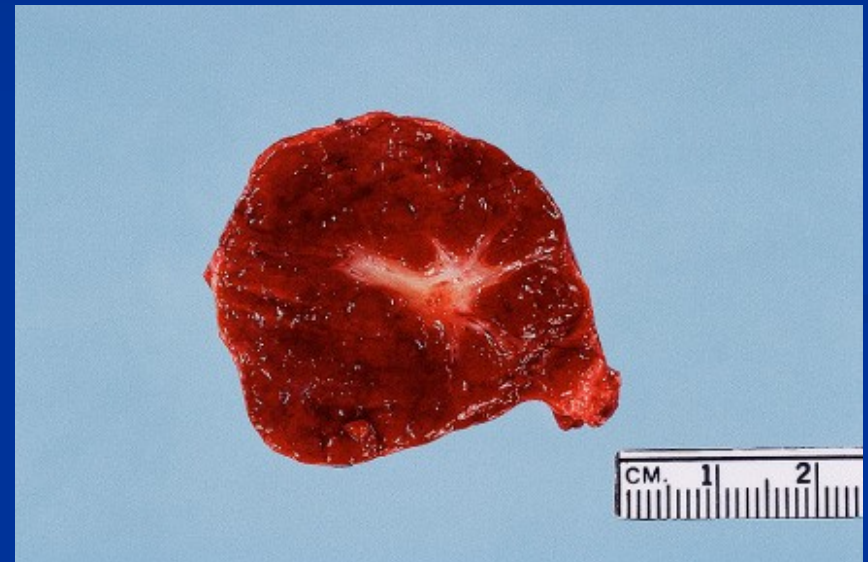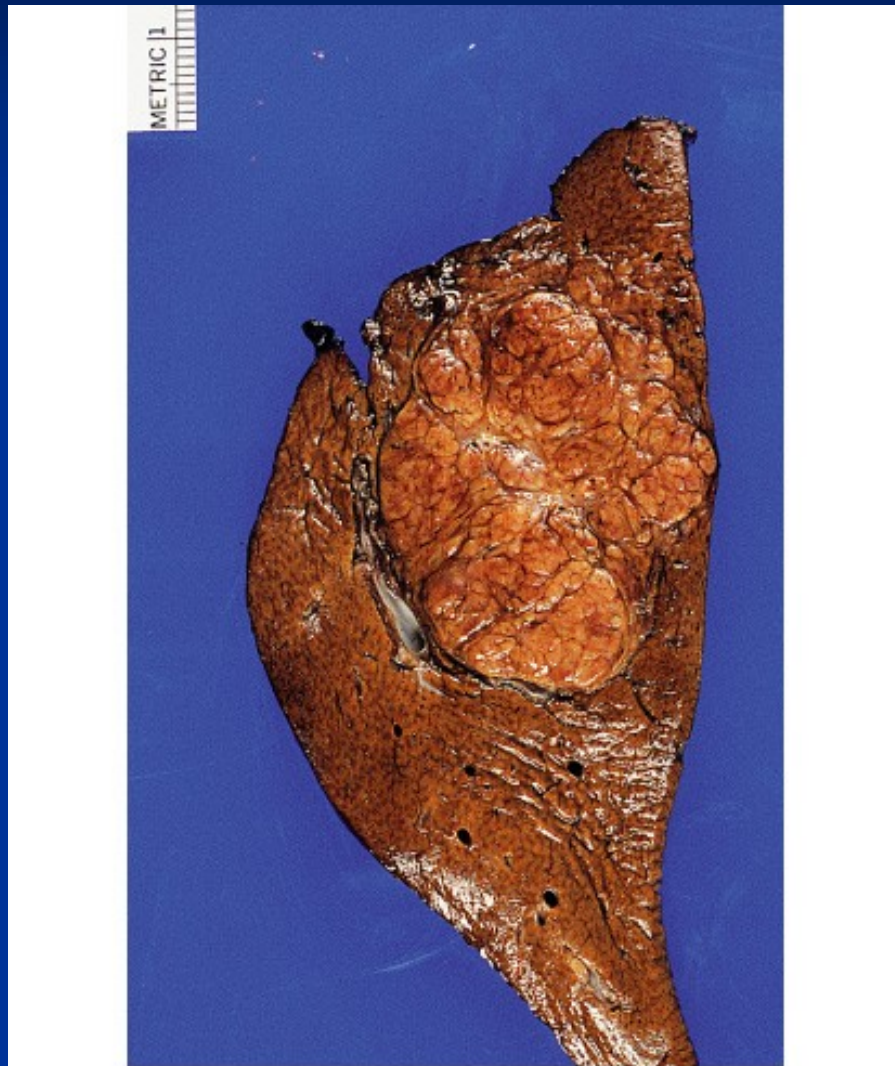
Tumor-like lesions

- Focal nodular hyperplasia
- Nodular regenerative hyperplasia (lack of fibrosis)
- Cysts
- Biliary hamartoma (von Meyenburg complex)

Focal nodular hyperplasia

- Localized benign hepatocellular nodules with central stellate fibrous scar
- Single or multiple
- Due to focal increased blood flow - hypertrophy of well-vascularized lobules
- More common in females, oral contraceptives – estrogens
- Diff. dg. x tumors

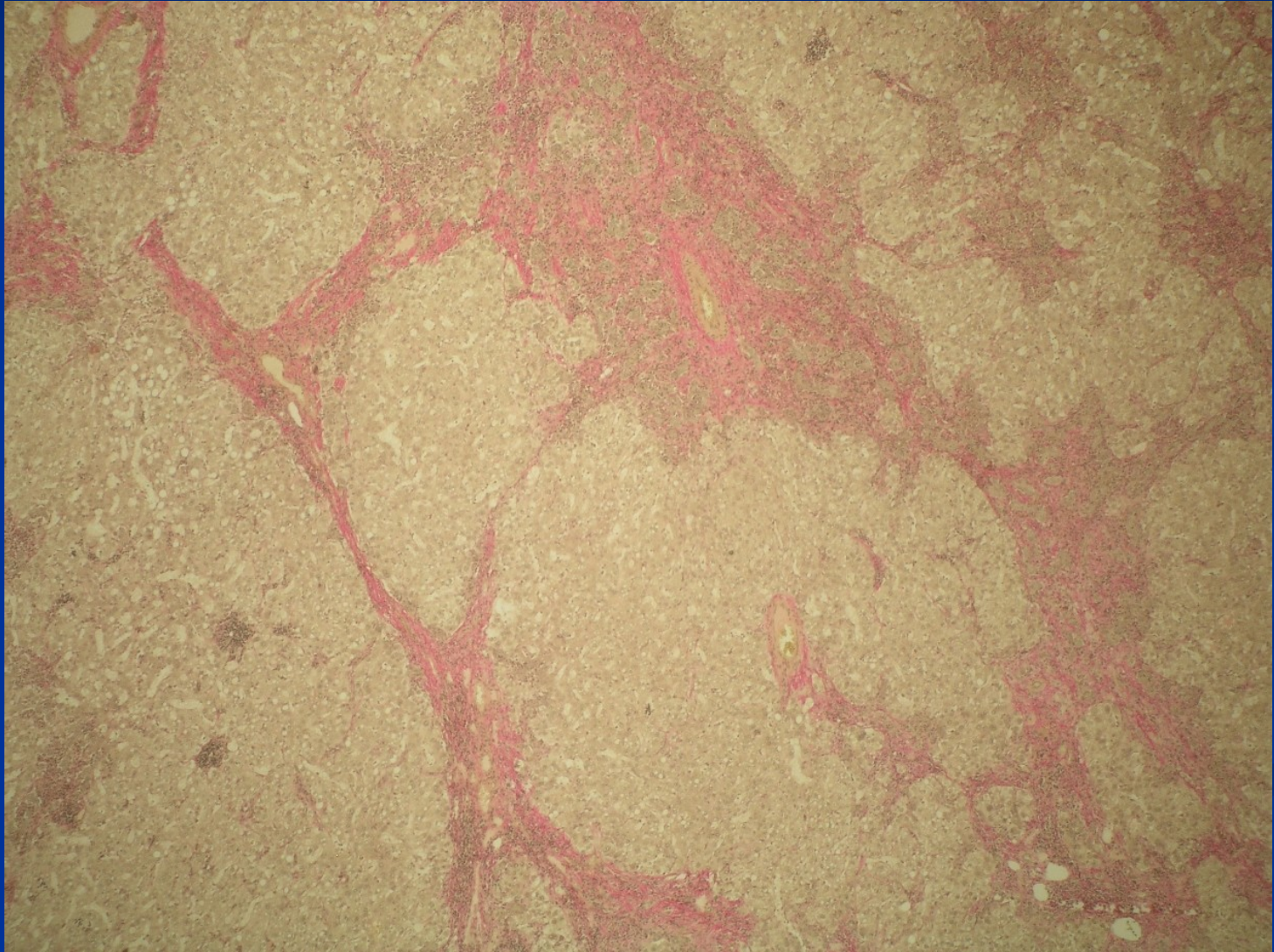
Focal nodular hyperplasia



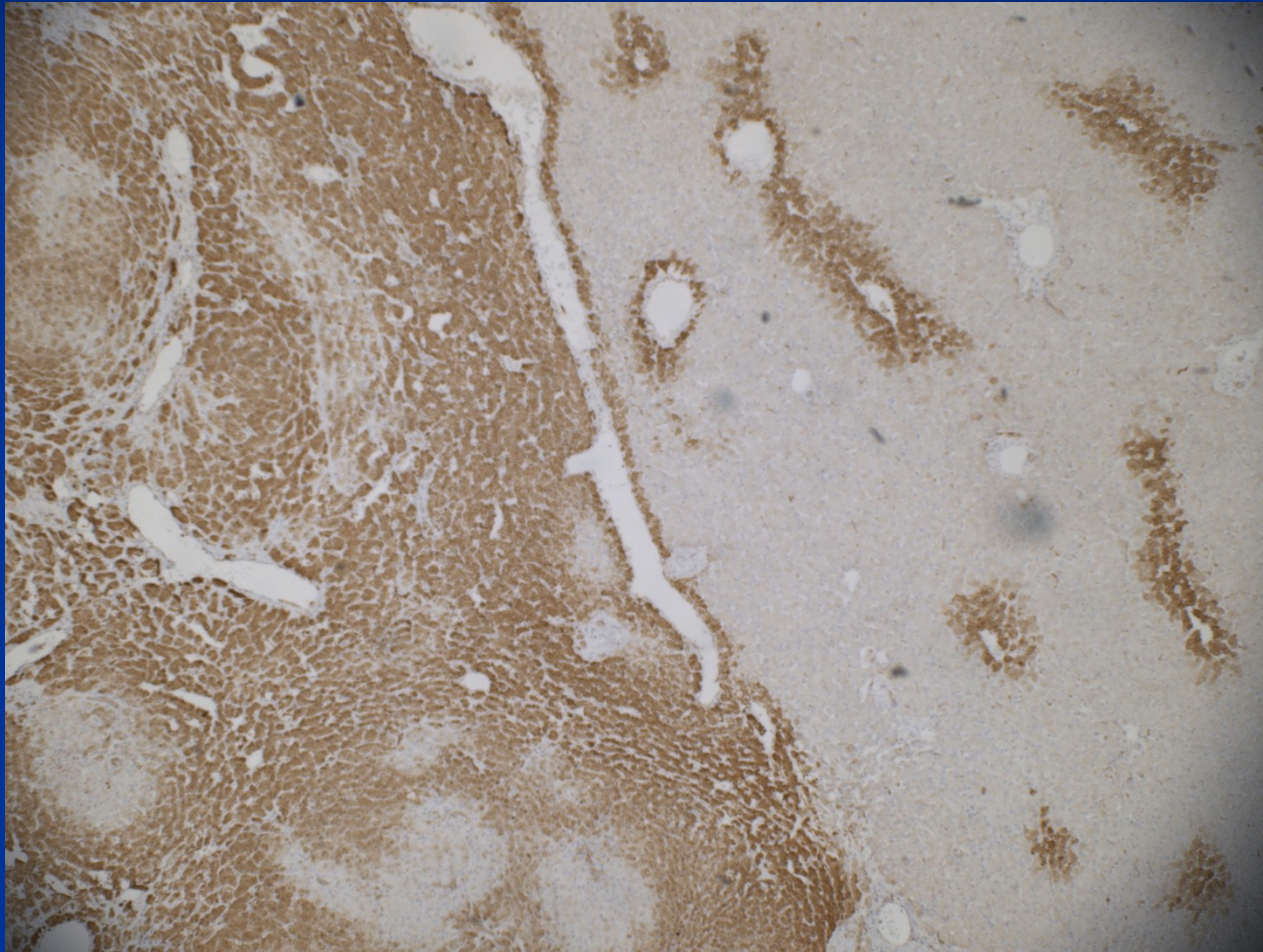
© Elsevier Inc 2004 Rosai and Ackerman's Surgical Pathology 9e

© Elsevier Inc 2004 Rosai and Ackerman's Surgical Pathology 9e

FNH



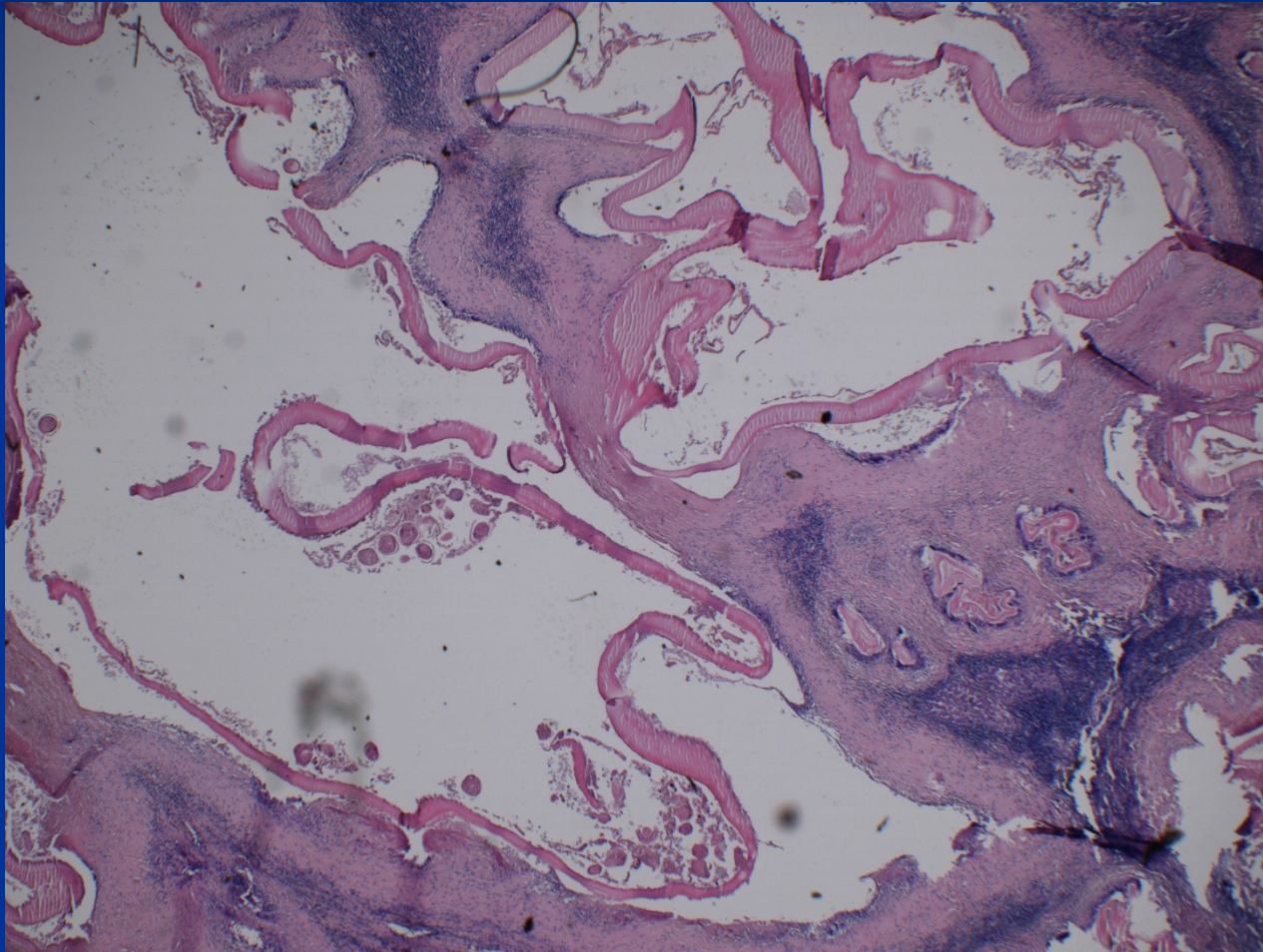
FNH - IHC



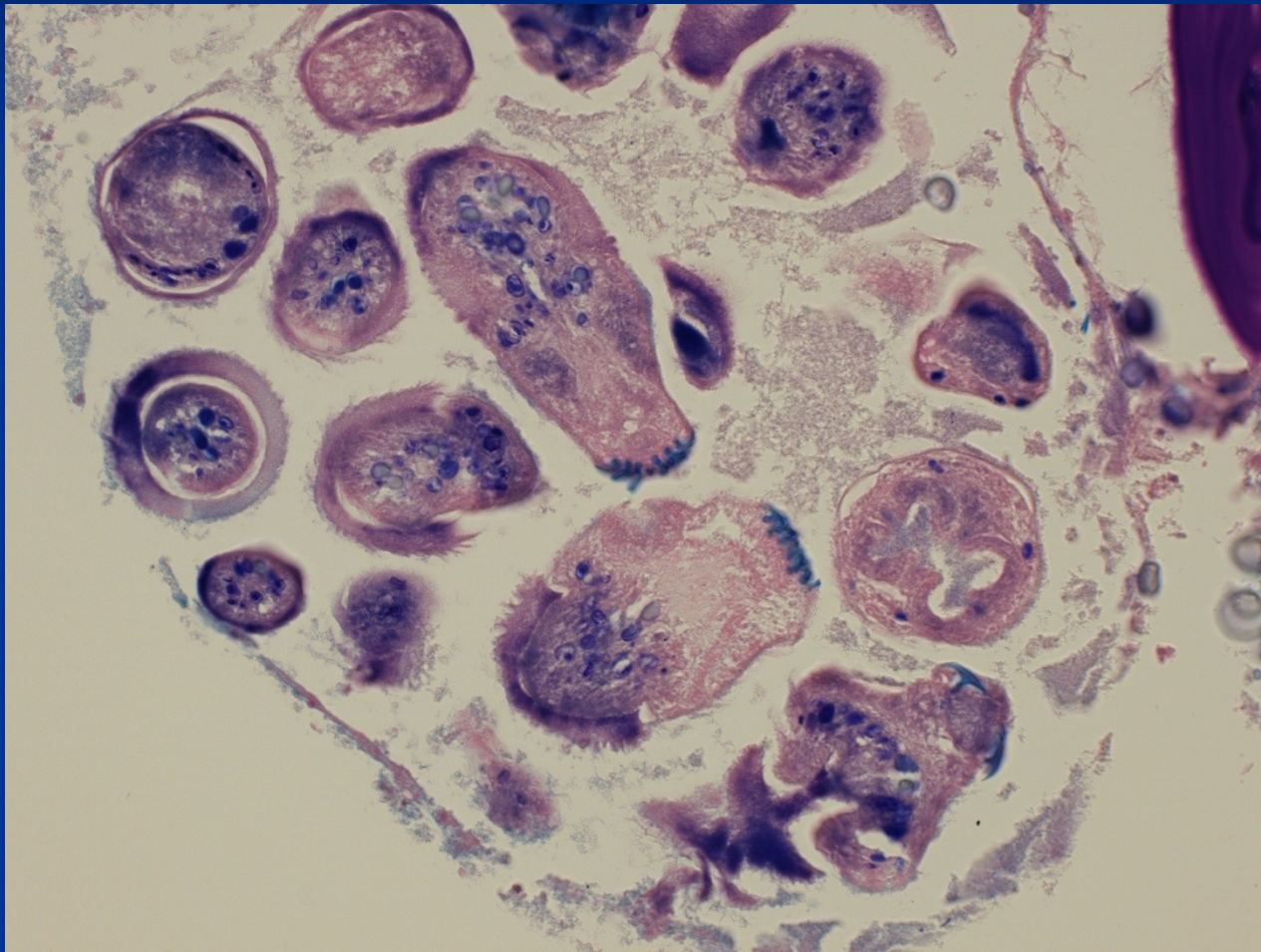
Cysts

- inborn (polycystic disease etc.)
- acquired simple biliary cyst
- parasitic cyst
- ! cystic tumors

Parasitic hydatid cyst – alveolar echinococcosis



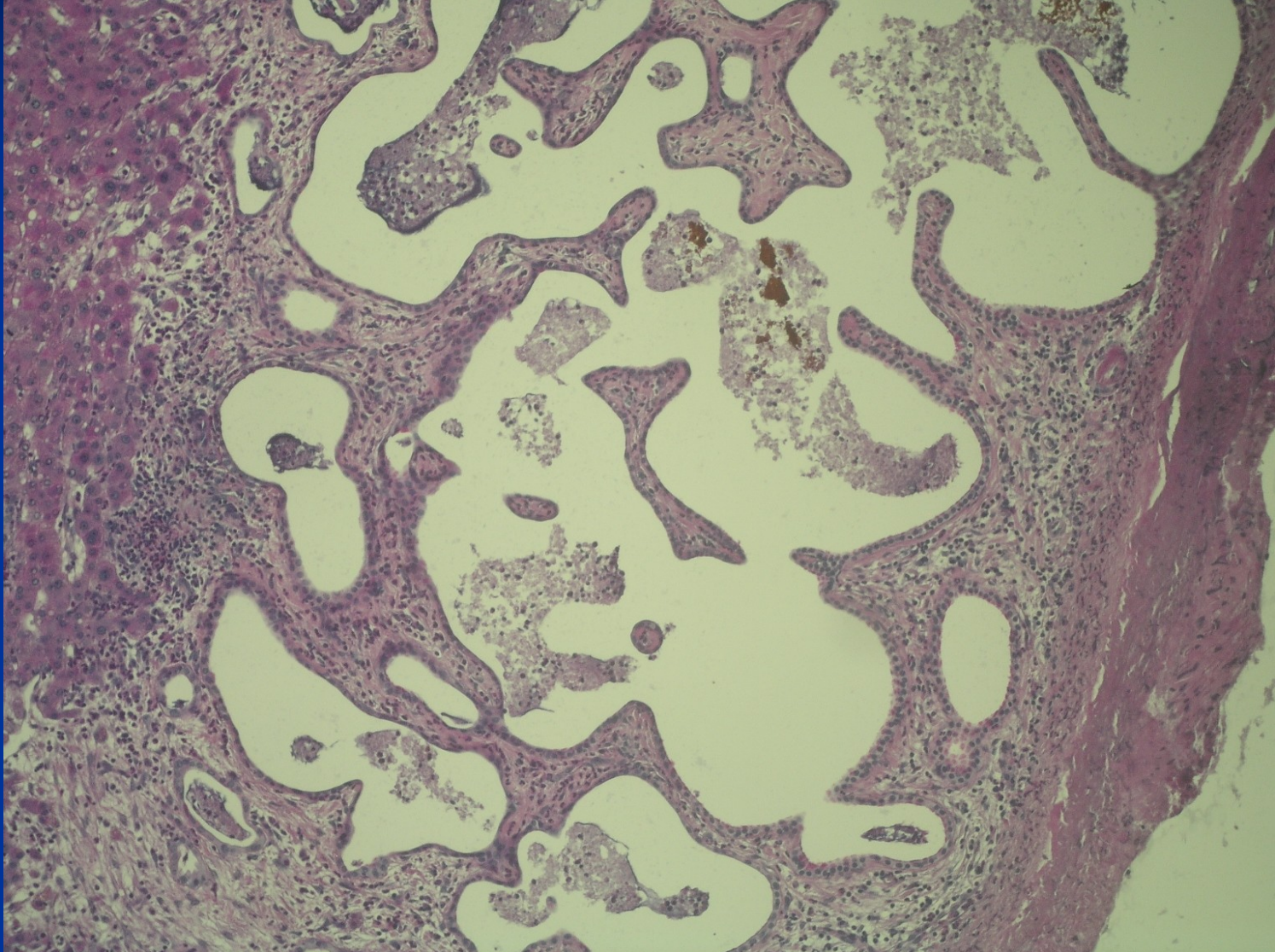
Hydatid cyst – alveolar echinococcosis



Biliary hamartoma

- Foci of dilatated biliary ducts – cysts
- Subcapsular, commonly multiple
- Benign condition, abortive polycystic disease
- Diff. dg. x metastatic spread

Biliary hamartoma



Benign tumors

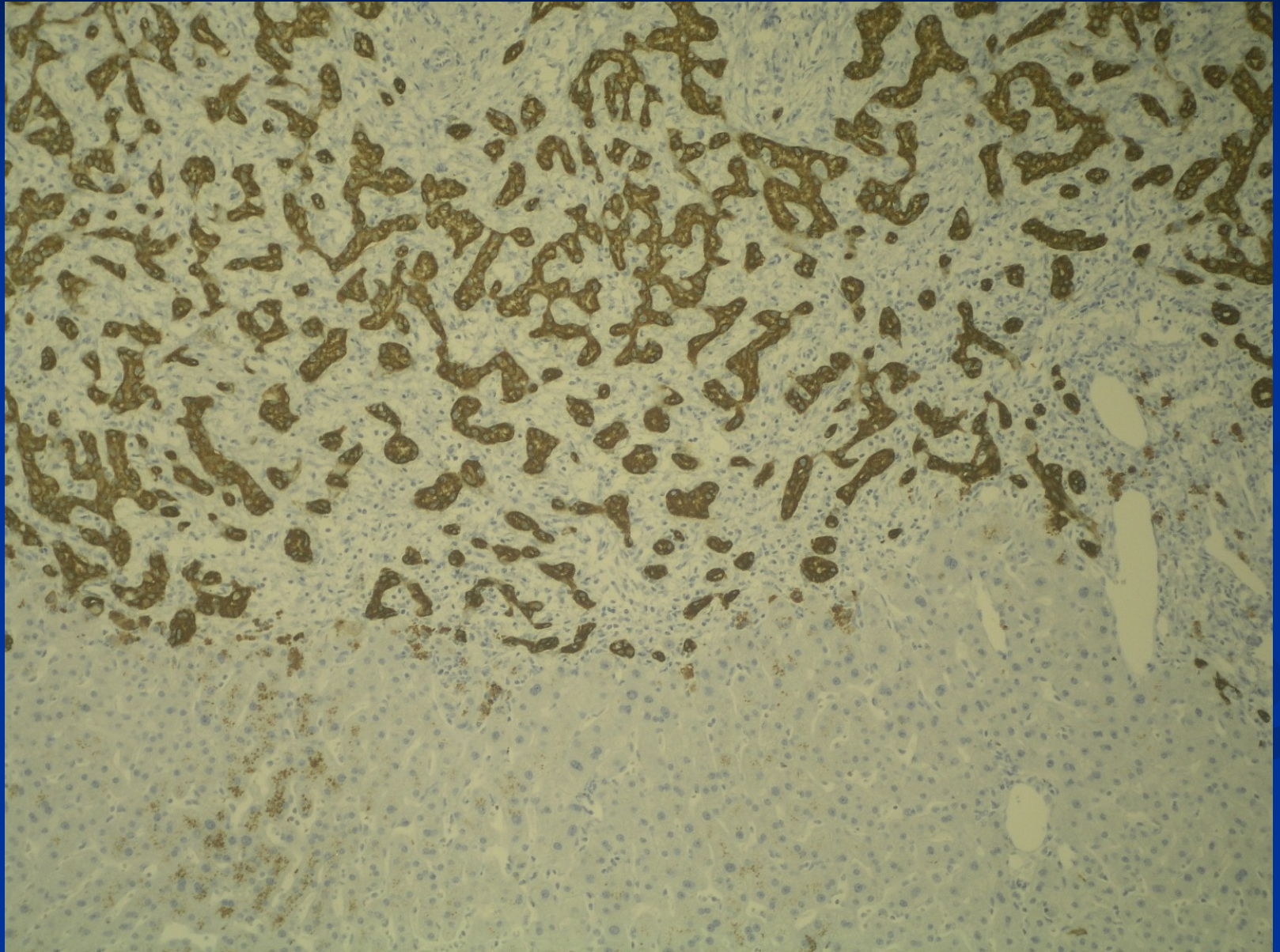
Adenoma

- **hepatocellular** (lack of portal tracts, risk of bleeding/necrosis, different subtypes, some with ↑ risk of carcinoma) , dif. dg. x HCC, FNH; may be multiple
- **cholangiocellular** - biliary (accumulation of regular ducts, lack of bile production, <1cm, subcapsular)
- **cystadenoma** (mucinous, rare)

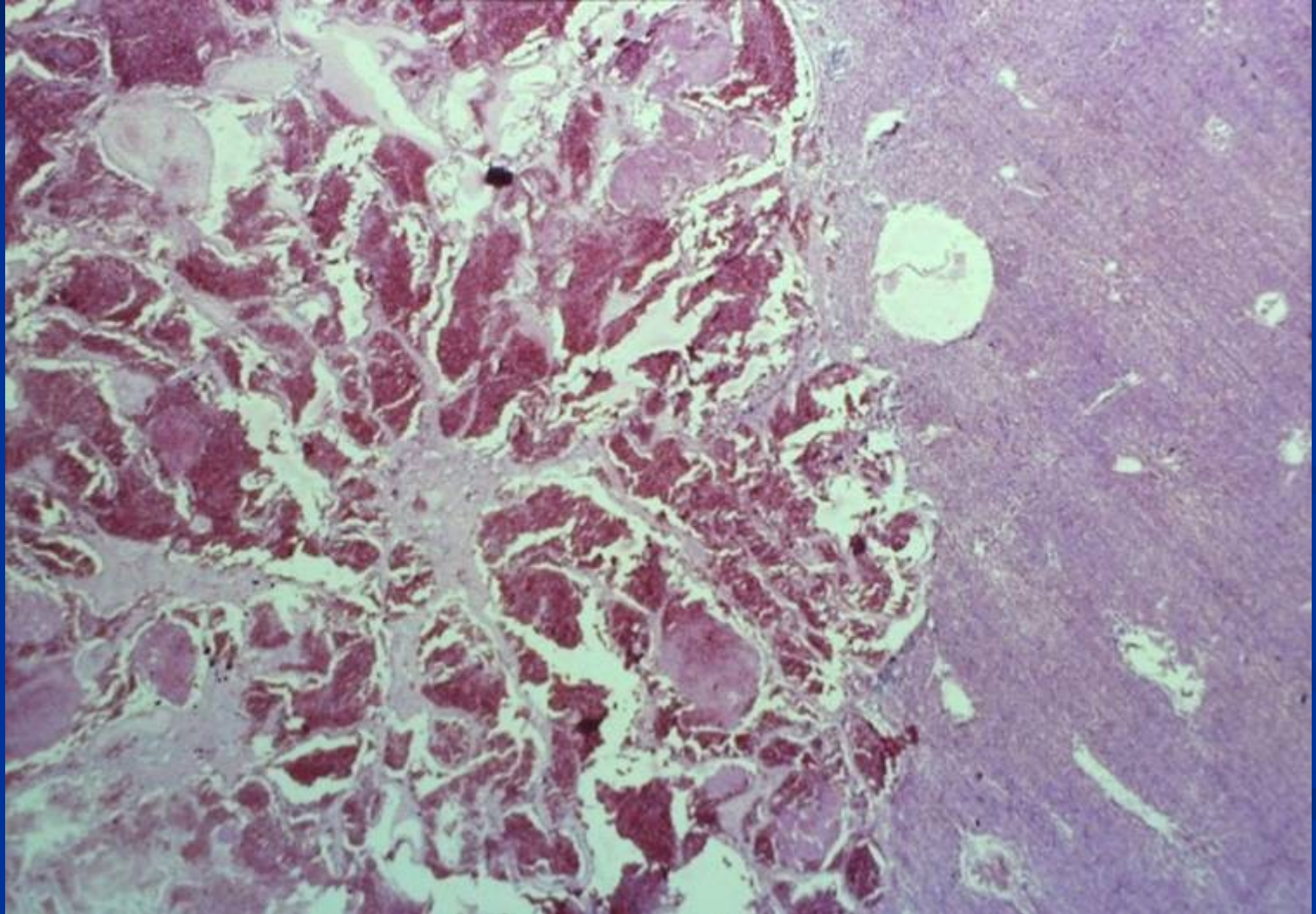
Haemangioma

- **cavernous** (subcapsular, bleeding risk during puncture!)
 - size up to 15 cm,
 - regressive changes possible – alteration of usual picture on imaging

Biliary adenoma



Cavernous haemangioma



Malignant tumors

■ Primary

- Hepatocellular carcinoma (90%)
- Cholangiocarcinoma (↑ incidence)
- Mixed hepato-cholangiocellular ca
- Hepatoblastoma – children
- Angiosarcoma – very rare

Malignant tumors

■ Secondary

- Metastatic carcinomas – most common (GIT incl. pancreatic/biliary, lung, breast, kidney,...), other metastatic tumors (melanoma,...)
- Hemopoietic neoplasms – leukemia infiltrates, lymphomas

Hepatocellular carcinoma

- Different incidence due to the cause

Lower in Europe, America, associated with cirrhosis, commonly alcoholic, NASH, HCV,

High in eastern Asia, HBV carrier since infancy = 200x risk, inactivation of p53;

High in Africa – aflatoxin

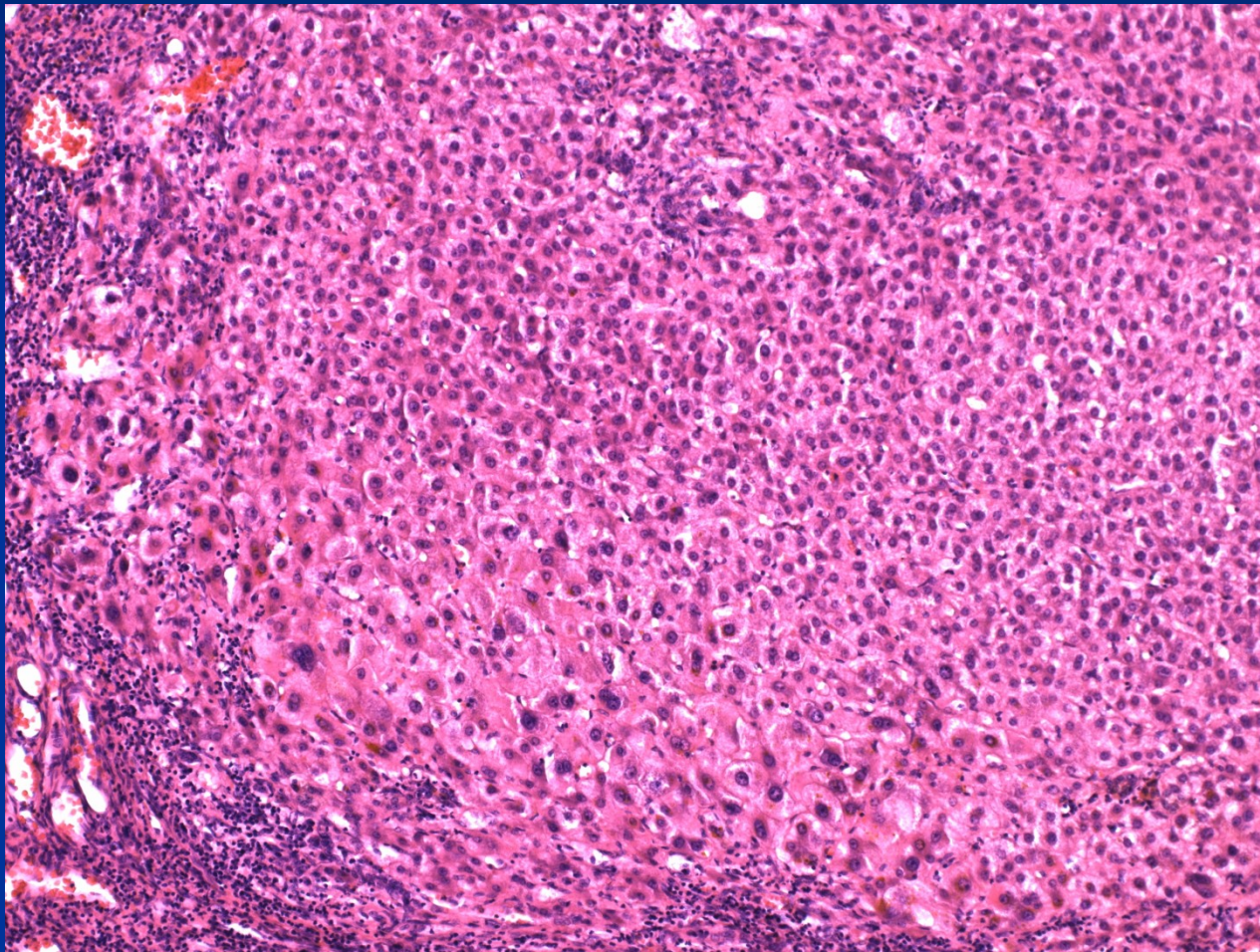
- Most of future HCC could be prevented

- HBV vaccination
- HCV treatment
- Life style (alcohol, NASH)
- Non-contaminated food

Preneoplastic changes

- **Liver cell dysplasia** – low grade, high grade
usually in cirrhosis, small foci or nodules, microcellular
– smaller cells with less cytoplasm + bigger nuclei
Diff. dg. x well diff. HCC

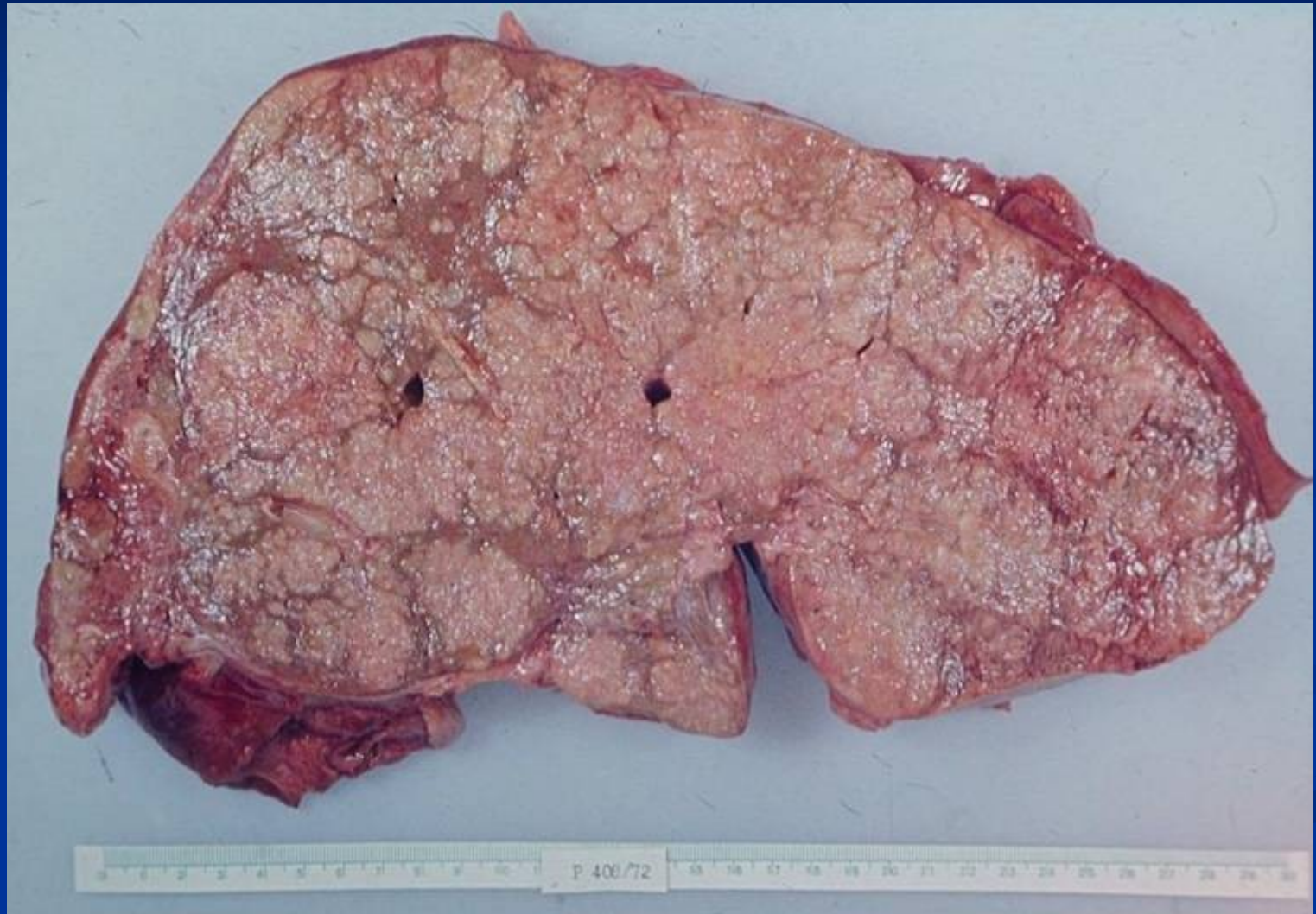
Microcellular change/dysplasia



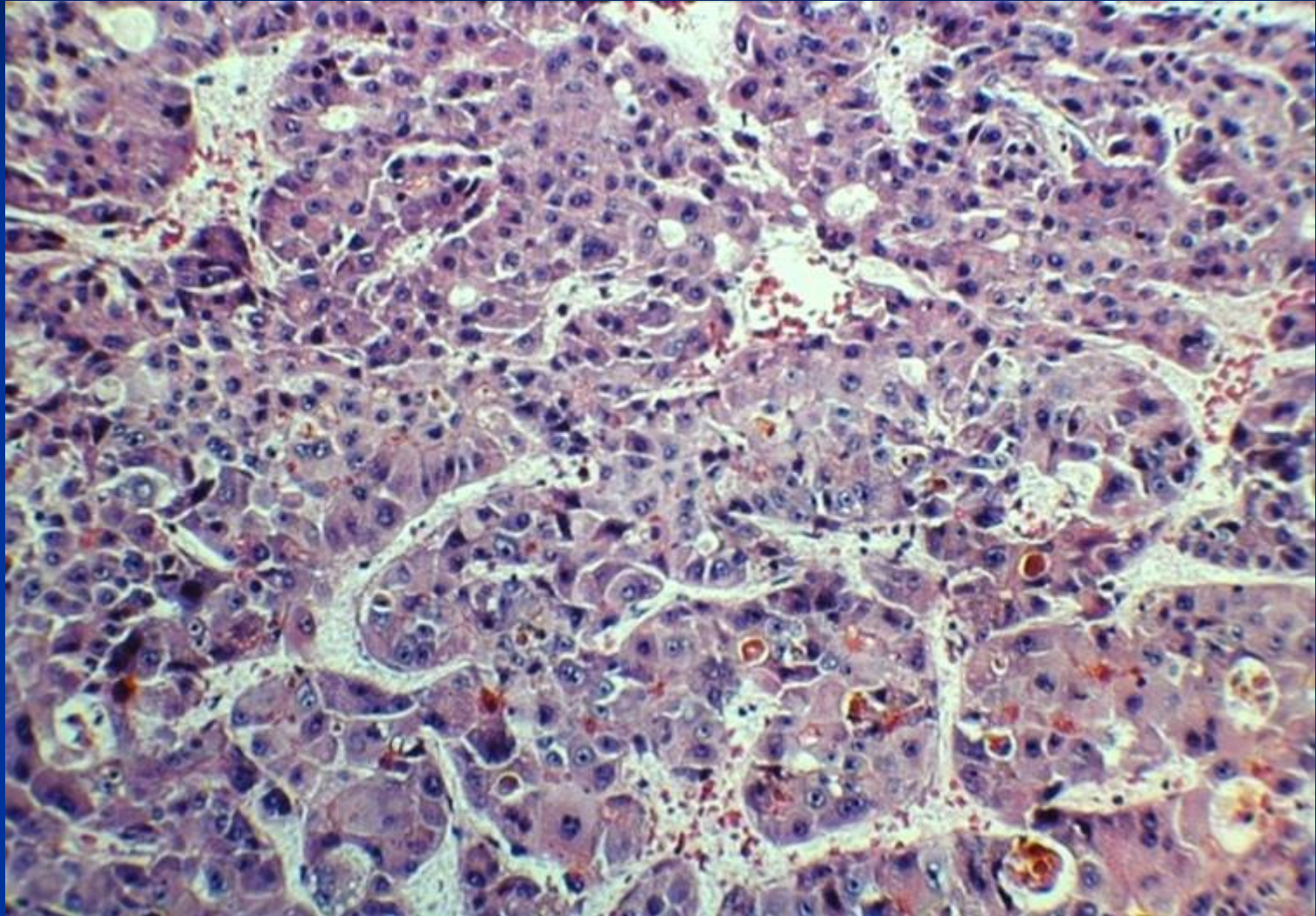
Morphology of HCC

- **Clinical** hepatomegaly, right upper quadrant pain, weight loss
- Unifocal, multifocal, or infiltrative growth
- Strong propensity for vascular invasion
- Well-differentiated – intracellular bile
- Trabecular, acinar, pseudoglandular, solid
- Usually scant stroma → soft
- Metastasizes to LN, lung, bone, adrenals, ...
- Commonly serologic increase of AFP

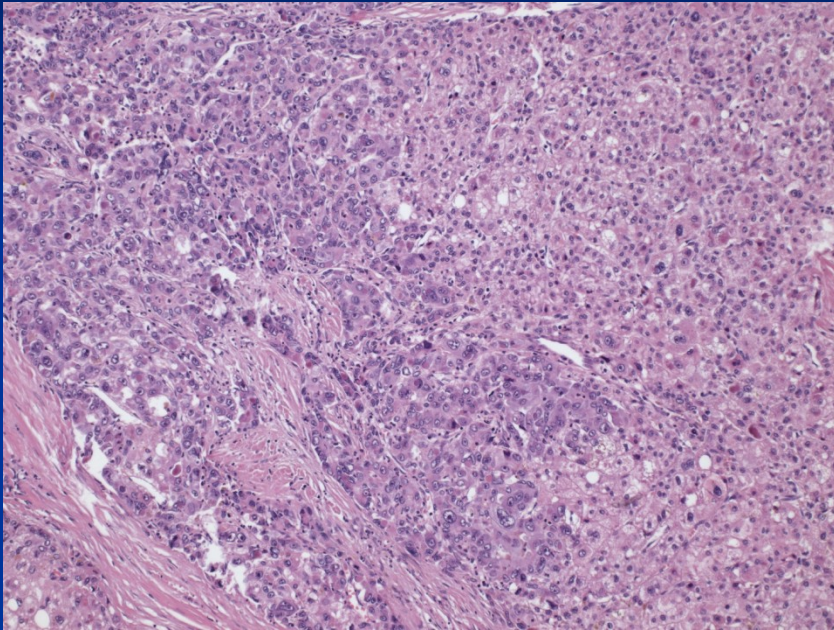
HCC



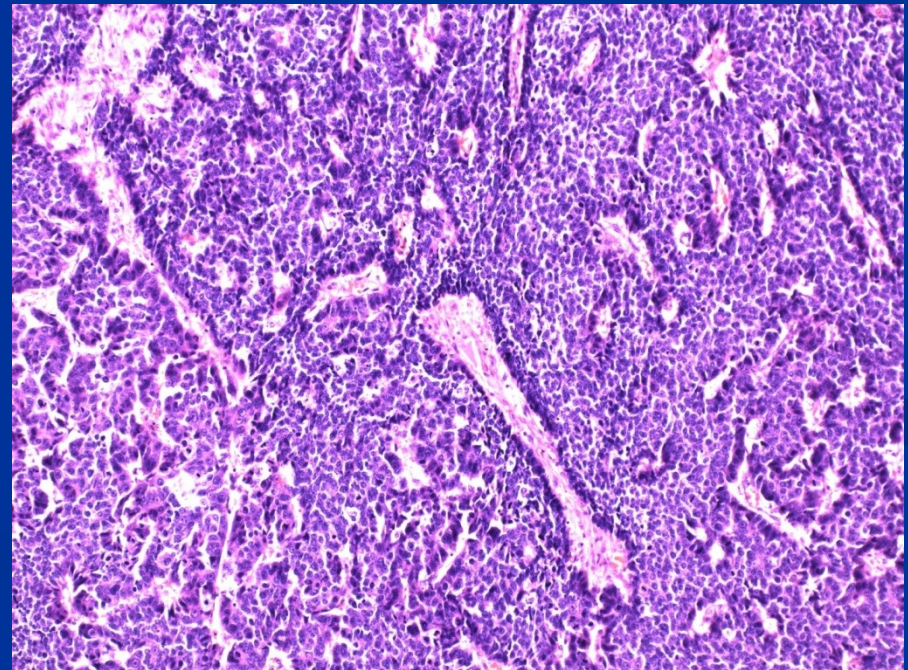
HCC – bile production by tumor cells



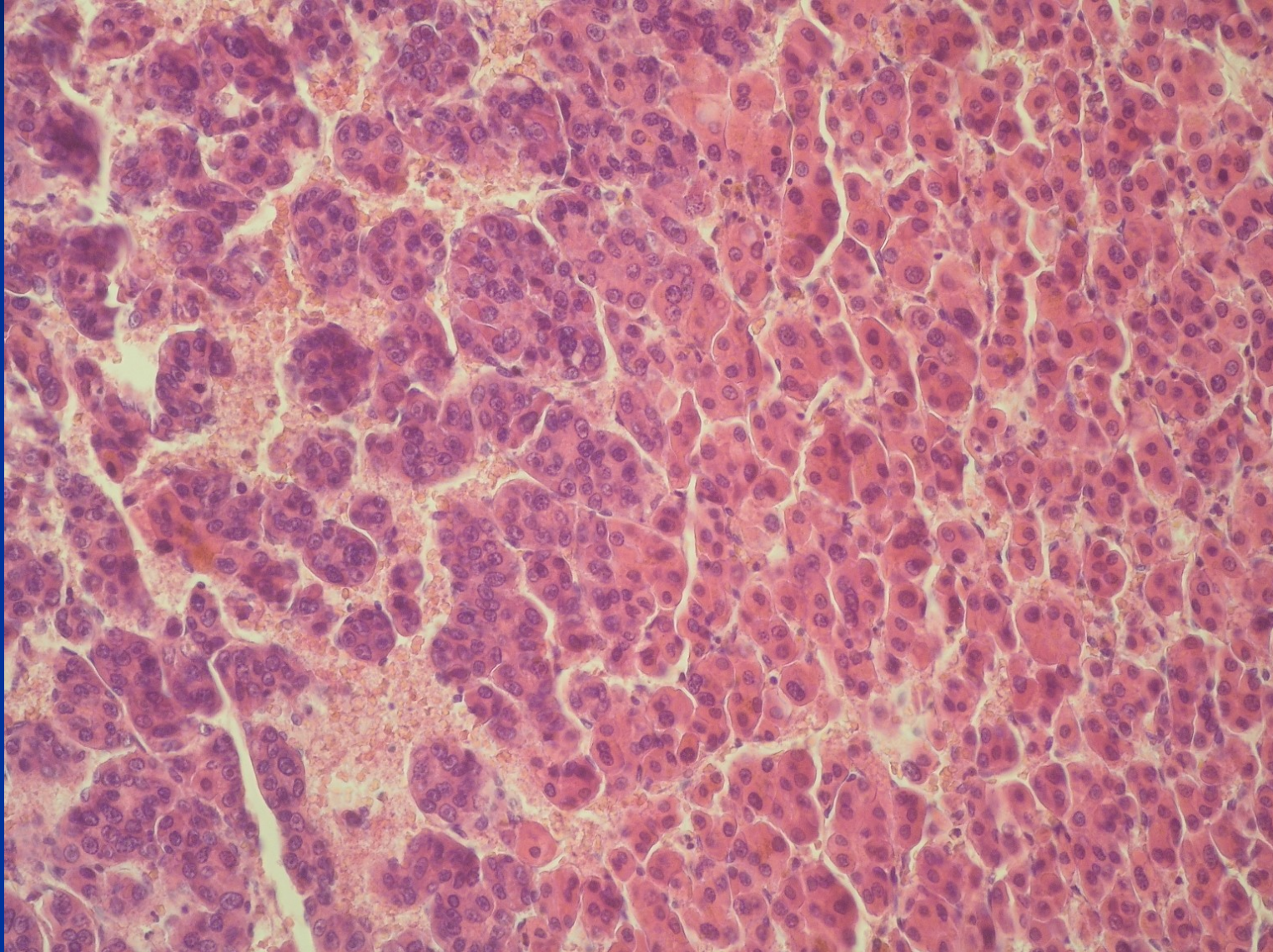
HCC – variable morphology



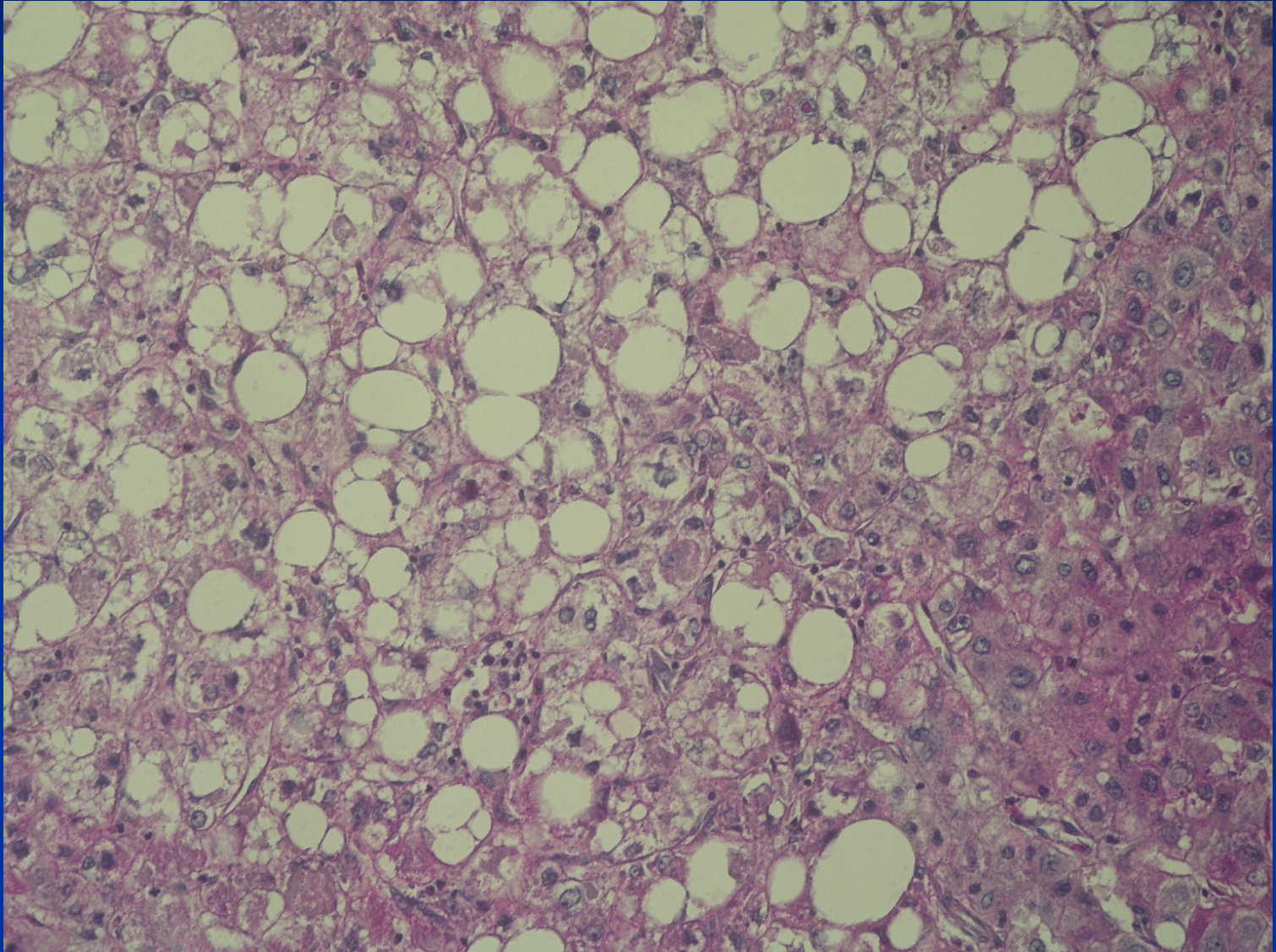
One patient, the same
tumor



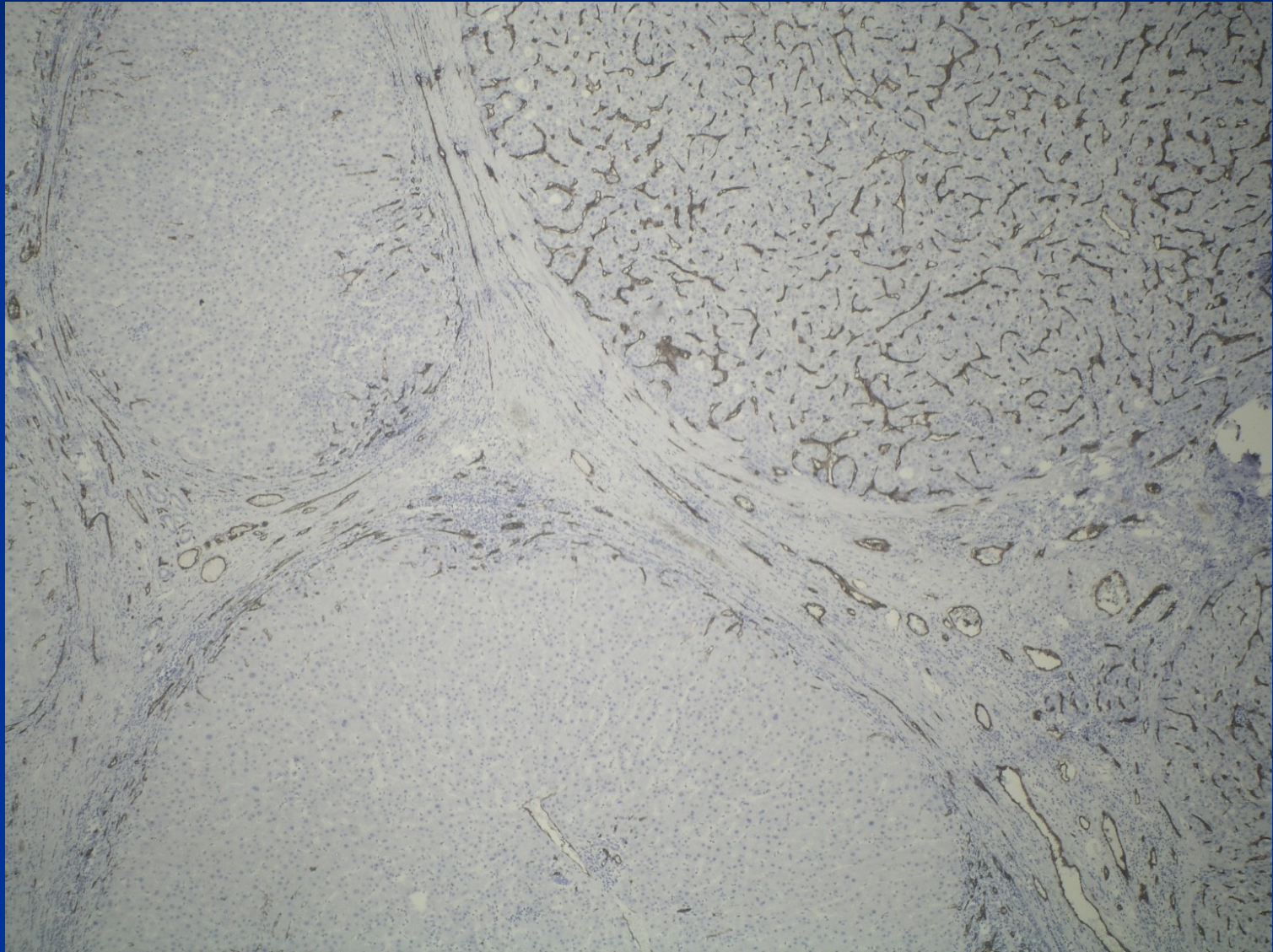
HCC – variable morphology



HCC – variable morphology



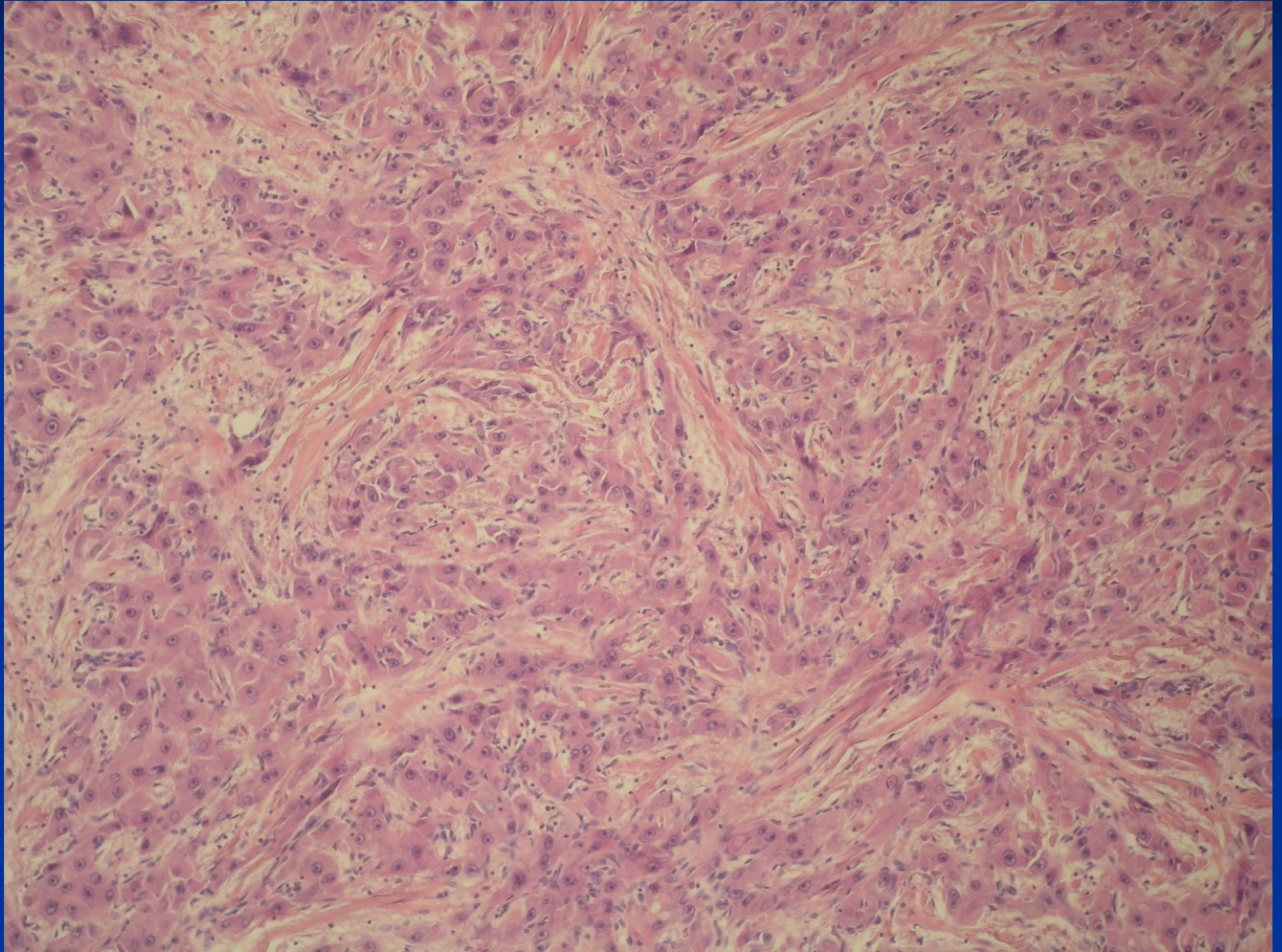
HCC – CD34+ capillaries



Fibrolamellar carcinoma

- 20-40 yrs, M=F
- Uncommon
- No assoc. with cirrhosis or other risk factors
- Single, resectable, 5 year survival = 60%,
- PAS + inclusions (hyaline globules)
- Tumor cells separated by dense parallel collagen strands
- Better prognosis

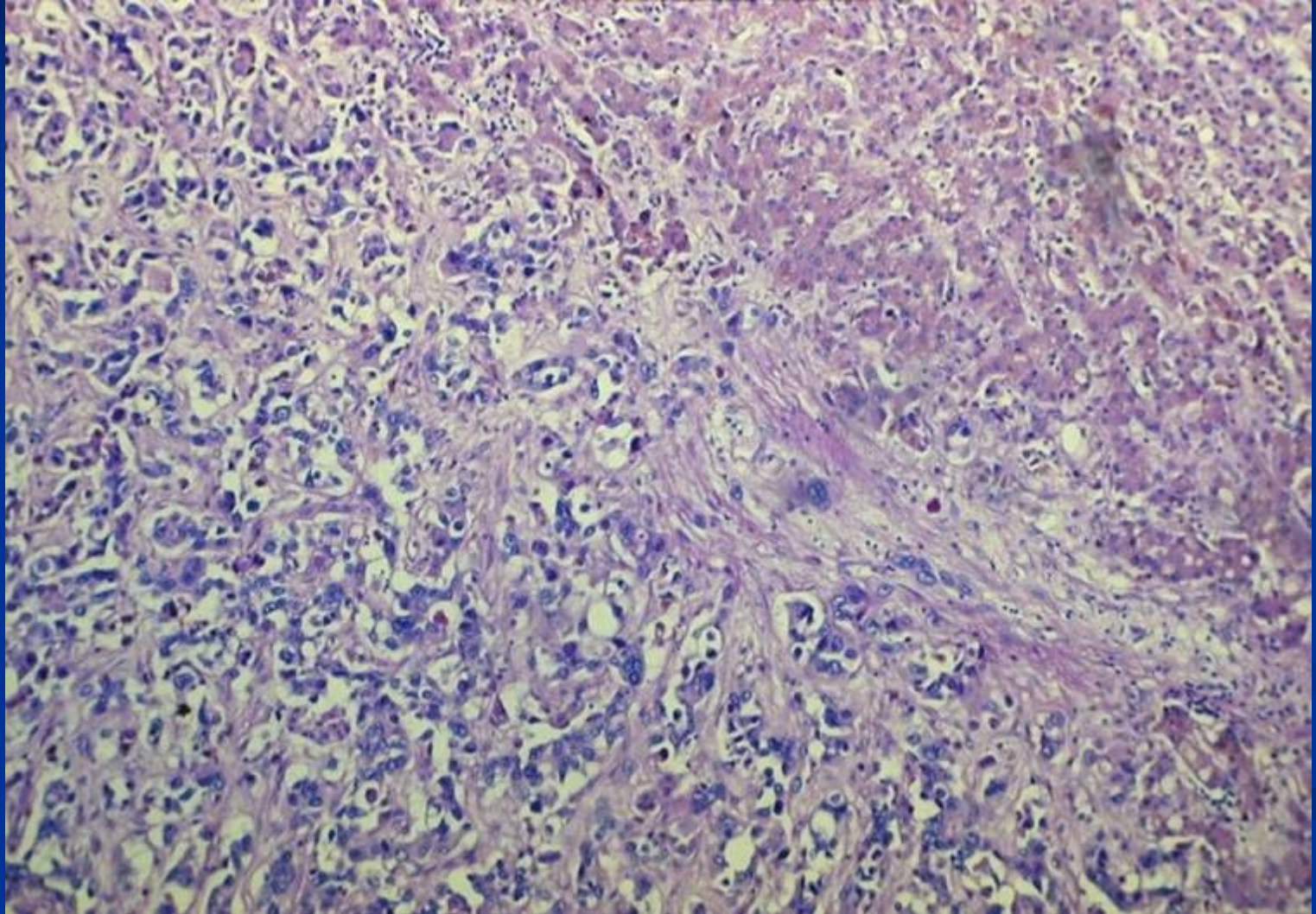
Fibrolamellar carcinoma



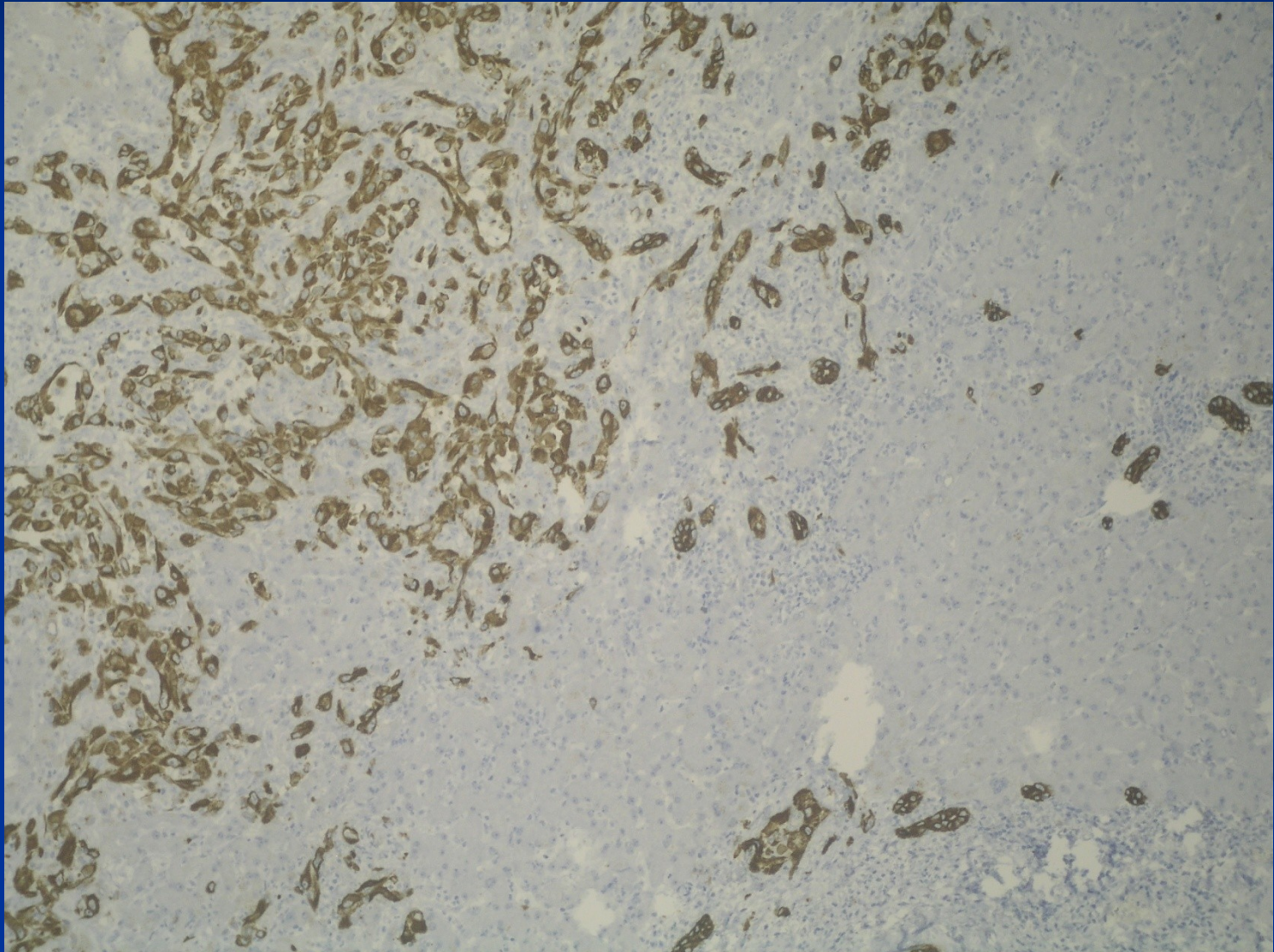
Cholangiocarcinoma

- From intrahepatic biliary ducts
- ↑ risk in PSC, HCV cirrhosis, some parasitic infections (Clonorchis), polycystic disease
- mucin secretion, mostly no bilirubin pigment
- irregular ducts, strands of cells
- commonly dense or myxoid stroma
- diff. dg. x metastatic or direct spread – gallbladder, pancreas, colorectal ca
- mostly bad prognosis

Cholangiocellular carcinoma

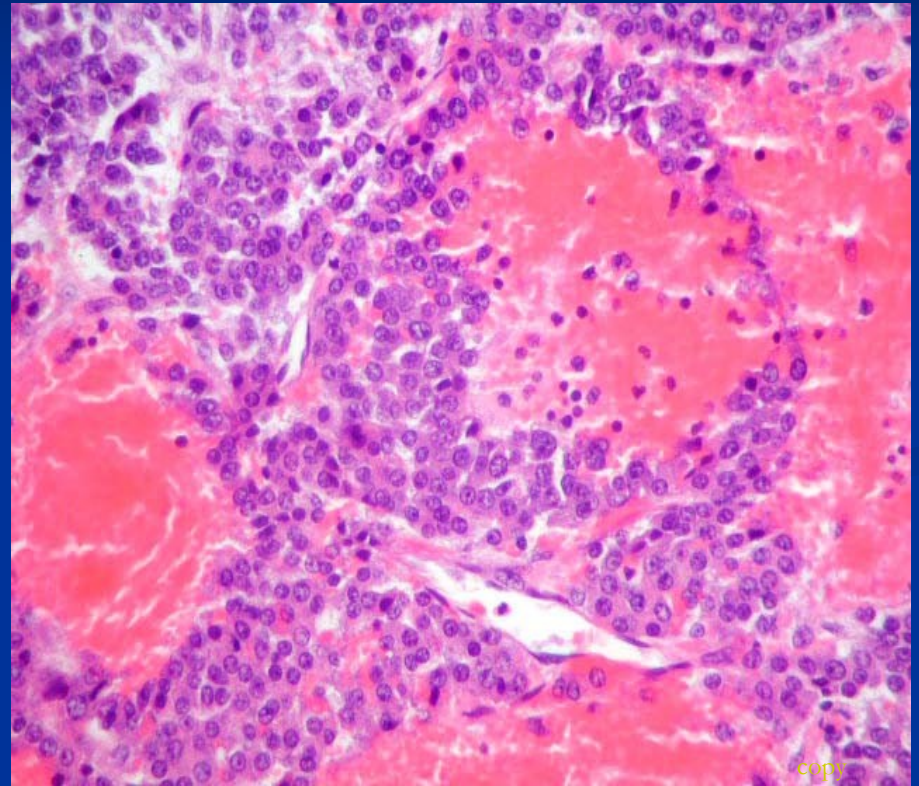


Cholangiocellular carcinoma IHC CK7



Hepatoblastoma

- from primitive – stem cells
- resembles embryonal/fetal liver
- heterogenous elements (cartilage, bone, muscle, ...)
- infants, children



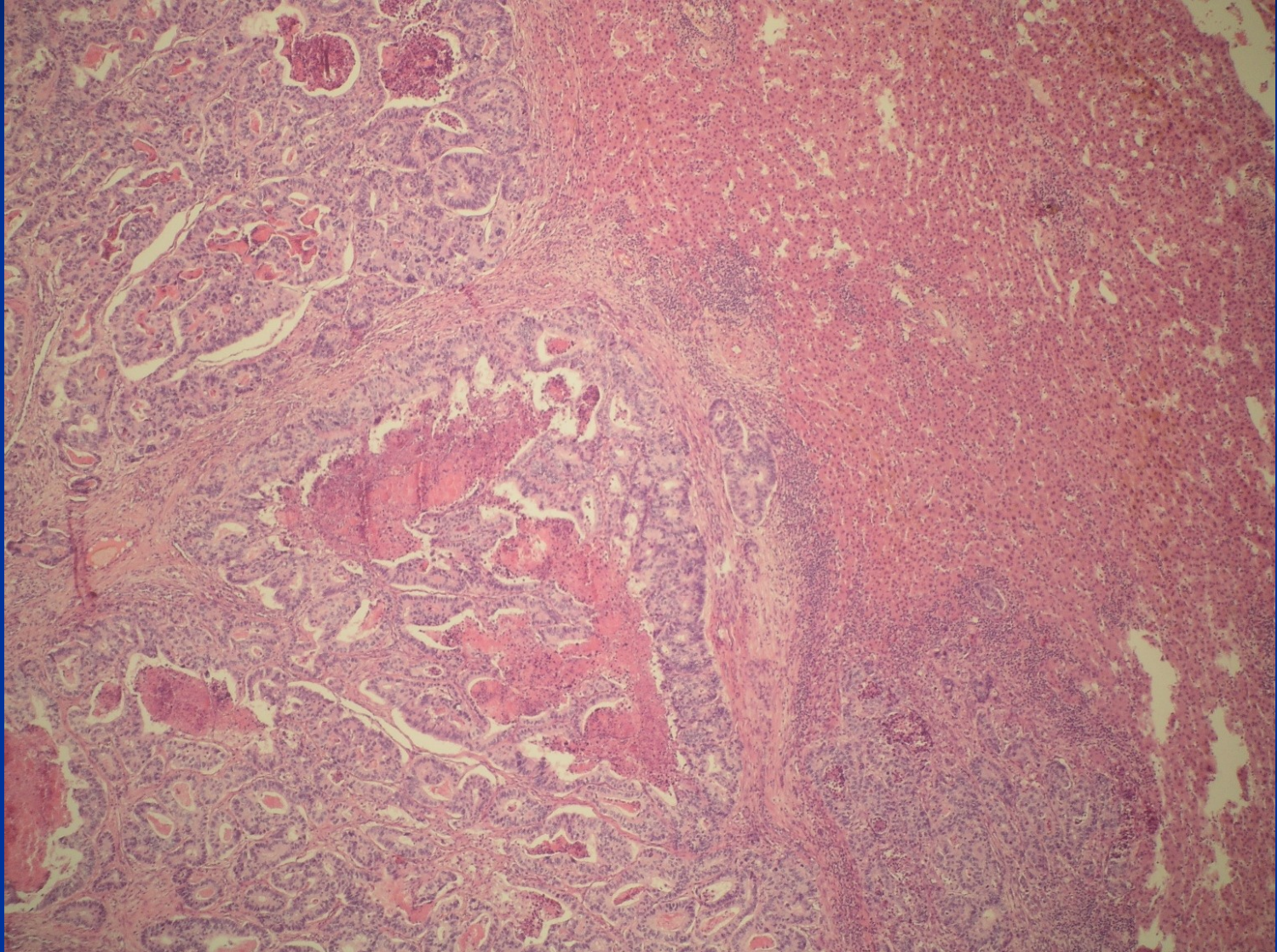
Malignant vascular tumors

- **Angiosarcoma** – highly malignant, very rare, but most common liver sarcoma, associated with professional risk (vinylchloride in plastic industry), thorocontrast exposure
- **Epithelioid hemangioendothelioma** – less malignant, transplantation event. possible

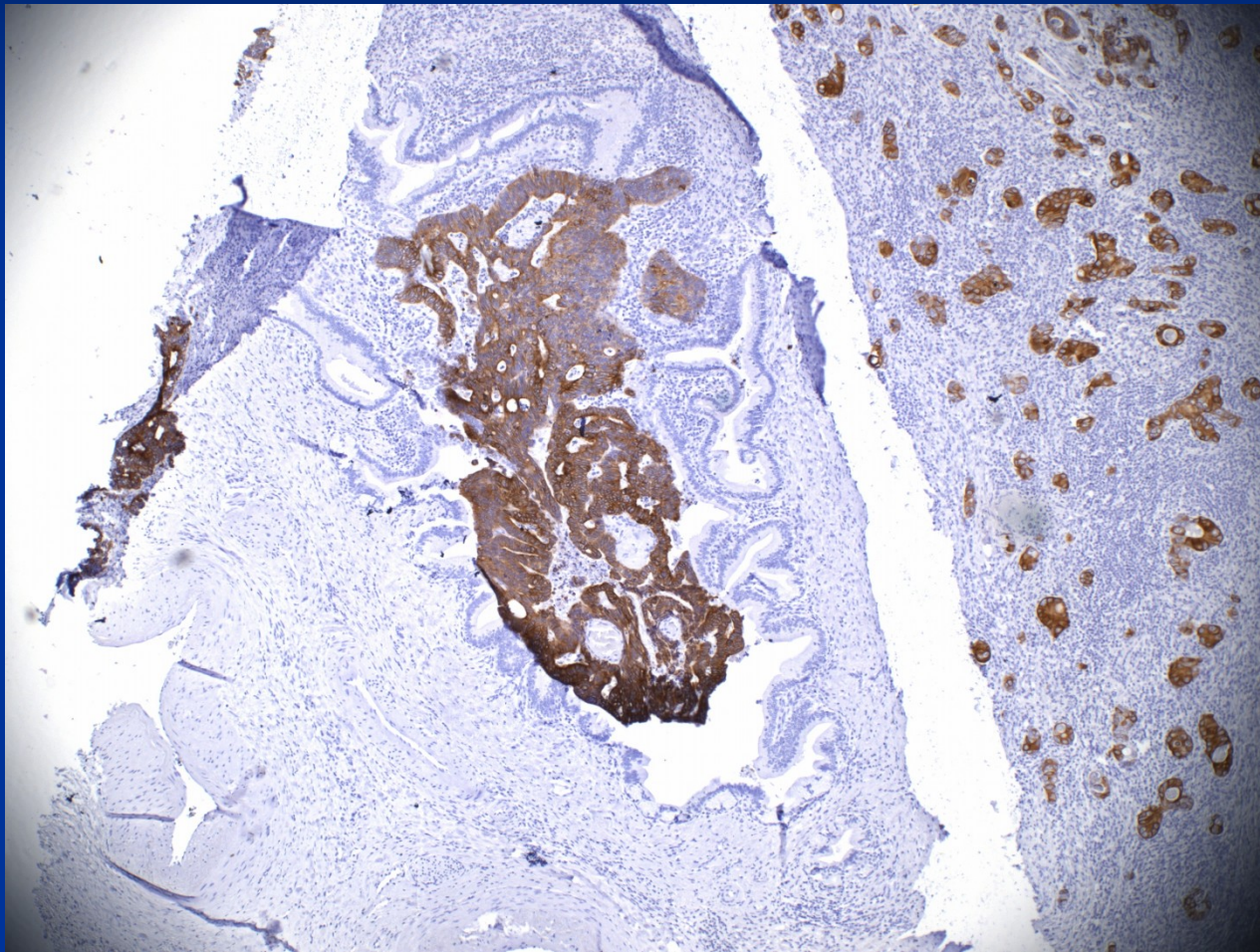
Secondary tumors

- more common than primary
- usually multiple
- treatment by surgical excision, thermal ablation, alcohol injection; chemotherapy in lymphomas/leukemias

Colorectal ca metastasis

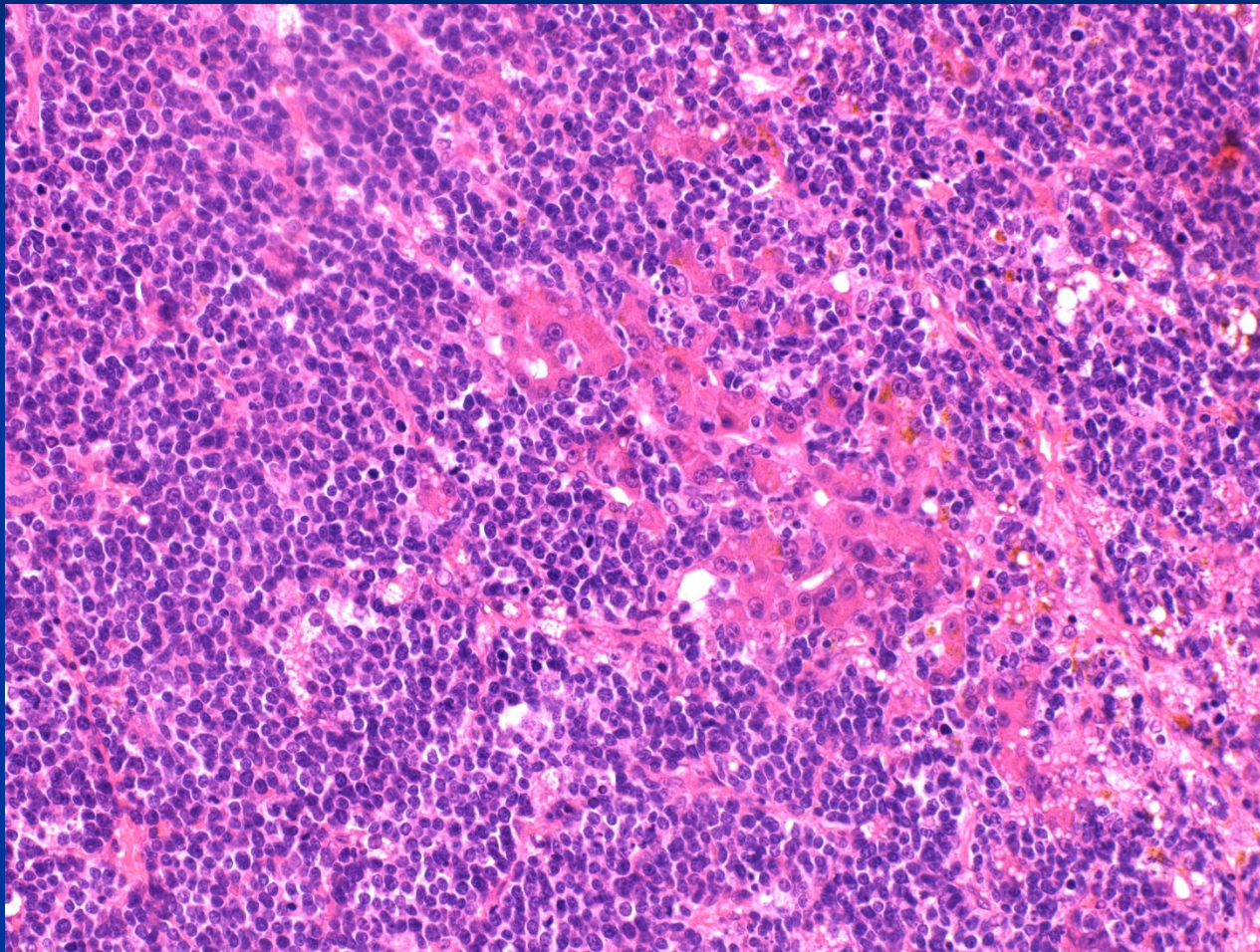


Colorectal ca metastasis

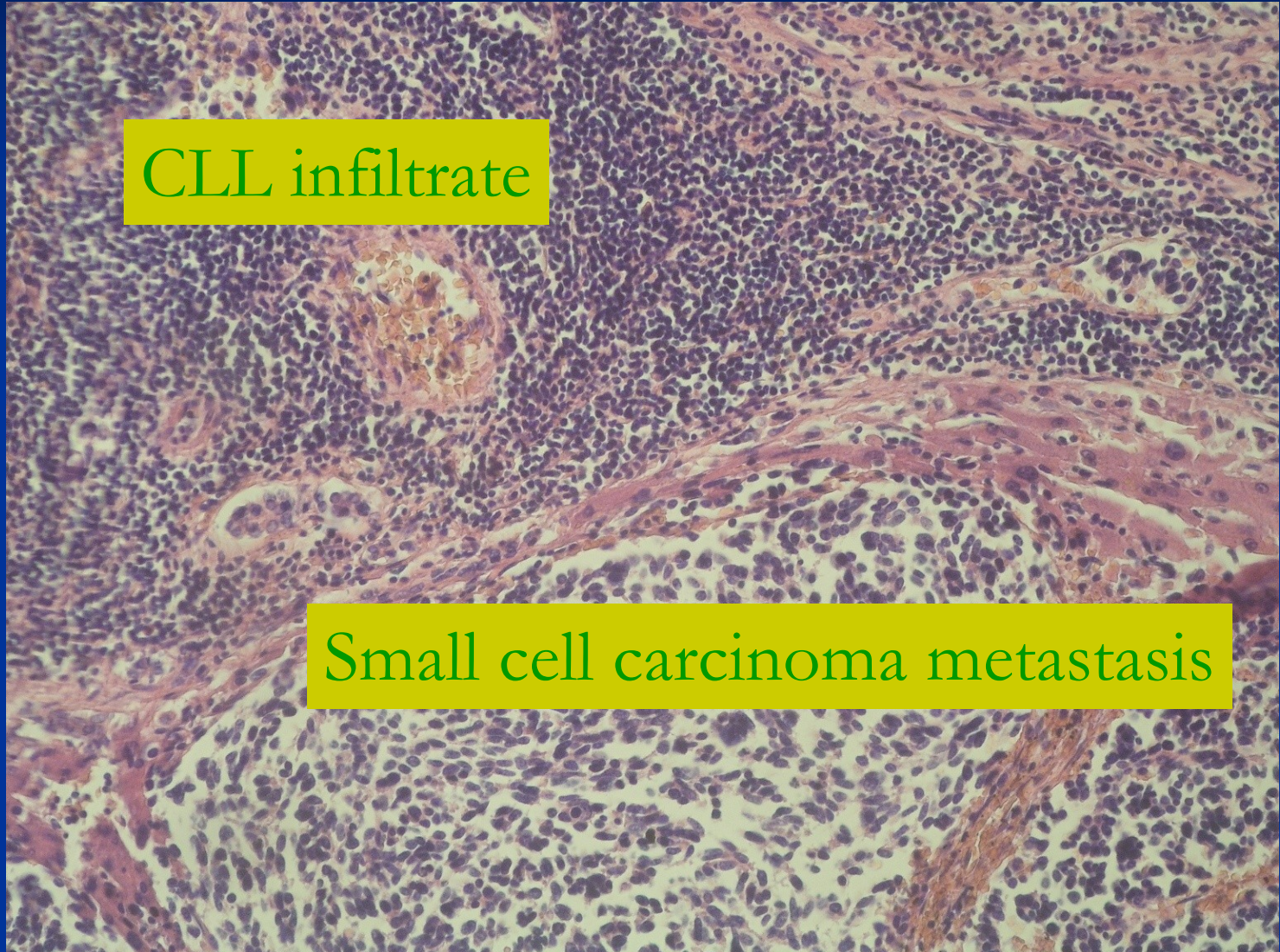


IHC CK20+ tumor in a CK20 neg. biliary duct

HG malignant lymphoma in liver



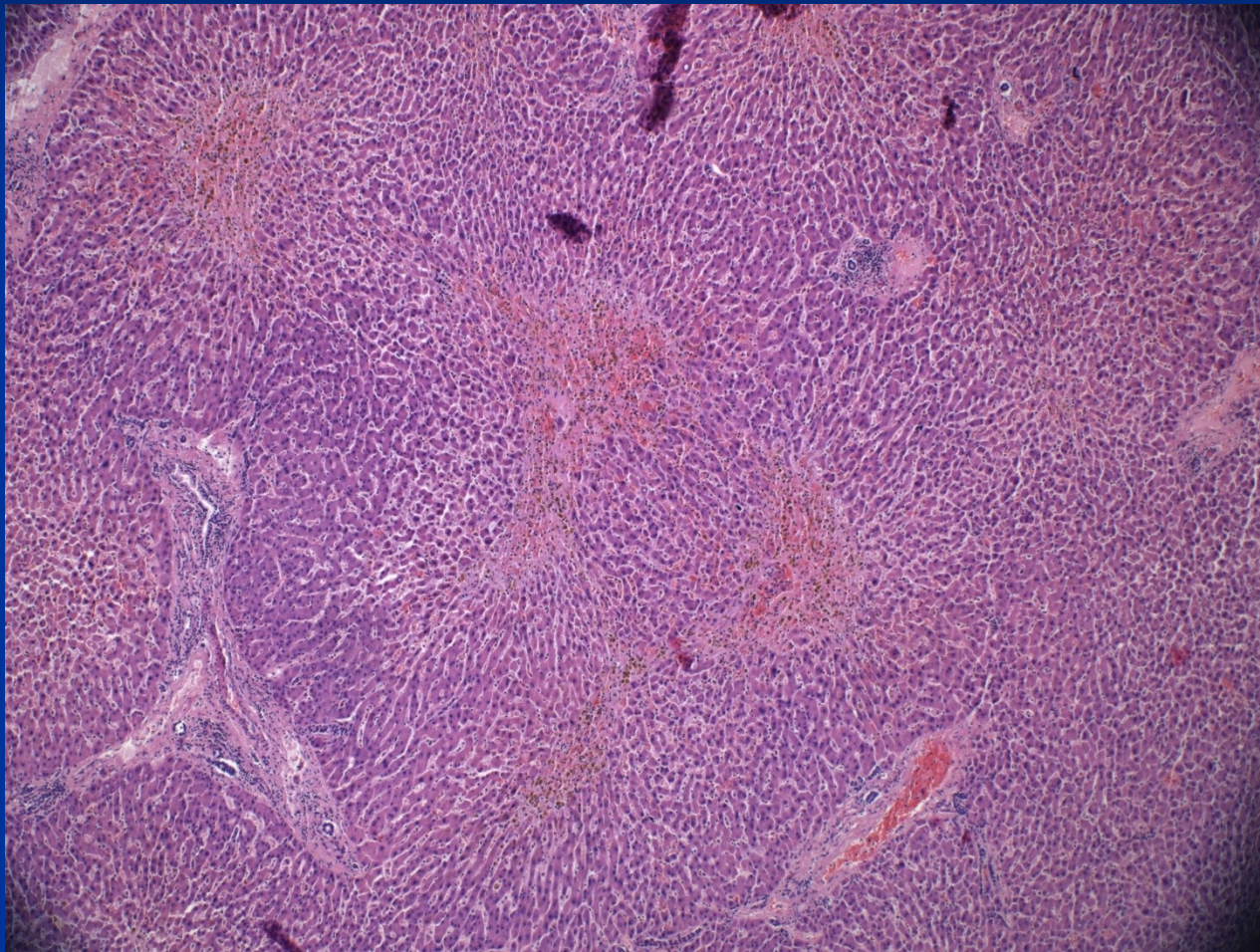
Two secondary liver neoplasias



Liver involvement in systemic disease

- Liver affected by diseases of single organs in the vicinity
 - pancreas, bile ducts – obstruction
 - heart - congestion,
 - lungs - hypoxemia,
 - systemic metabolic diseases (DM, amyloidosis)
 - systemic infections incl. sepsis
- extramedullary hematopoiesis
- acute fatty liver of pregnancy

Central necrosis in heart failure



Liver and transplantation

Indication for transplantation

- inborn defects (biliary atresia)
- irreversible stages of chronic liver diseases - hepatitis, PBC, PSC
- acute liver failure (toxic, vascular, trauma)
- some tumors (small/solitary HCC; EHE, large complicated hemangiomas); some focal lesions – FNH, parasitic cysts, ...

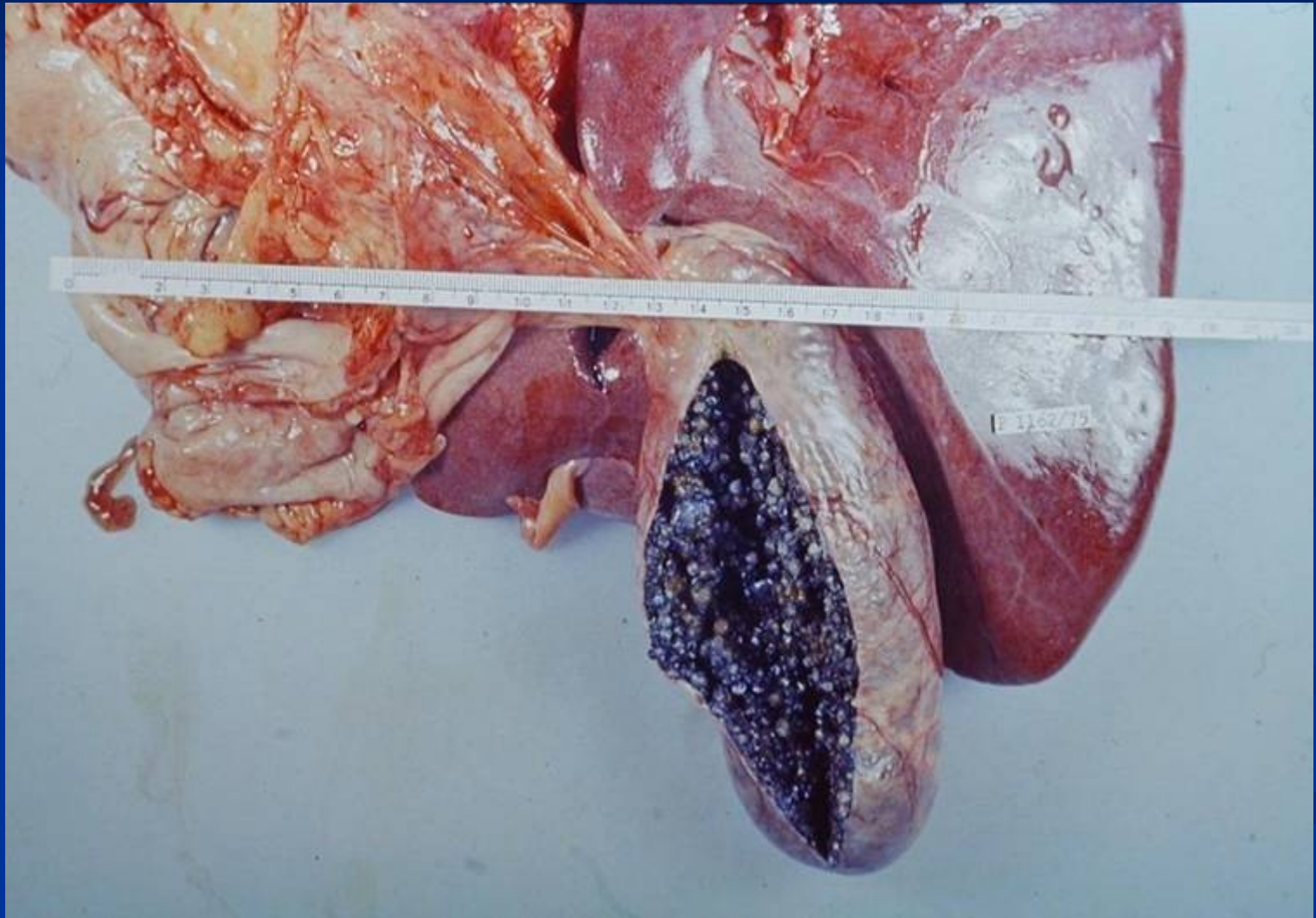
Cholelithiasis

- Very common
- Cholesterol stones
 - Bile is supersaturated with cholesterol
 - Gallbladder stasis
 - F>M
 - Obesity
 - Advancing age
- Pigment stones – calcium bilirubinate salts
 - Asian more than Western
 - Chronic hemolytic syndromes

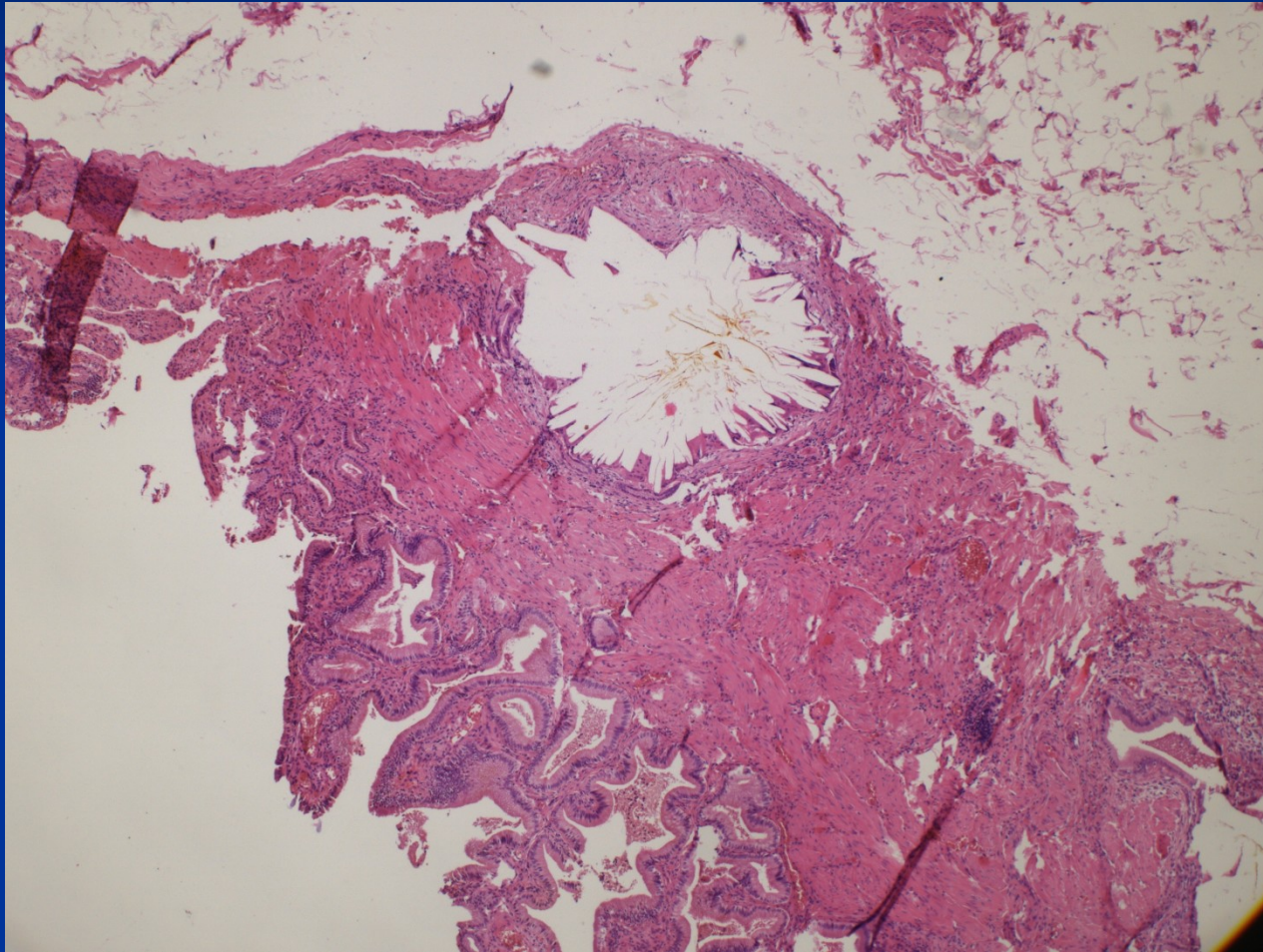
Clinical features

- Asymptomatic
- Biliary colic
- Cholecystitis
- Perforation, fistula
- Gallstone ileus

Cholecystolithiasis



Intramural cholesterol stone



Cholecystitis

■ Acute calculous

- Obstruction of GB neck or cystic duct
- Local pain radiating to right shoulder
- Fever, nausea, leukocytosis
- Potential surgical emergency

Empyema of the gallbladder

Gangrenous cholecystitis

Cholecystitis

- **Acute acalculous** – seriously ill patients (postoperative, trauma, burns, sepsis,...)
- **Chronic**
 - Recurrent attacks of pain
 - Nausea and vomiting
 - Associated with fatty meals

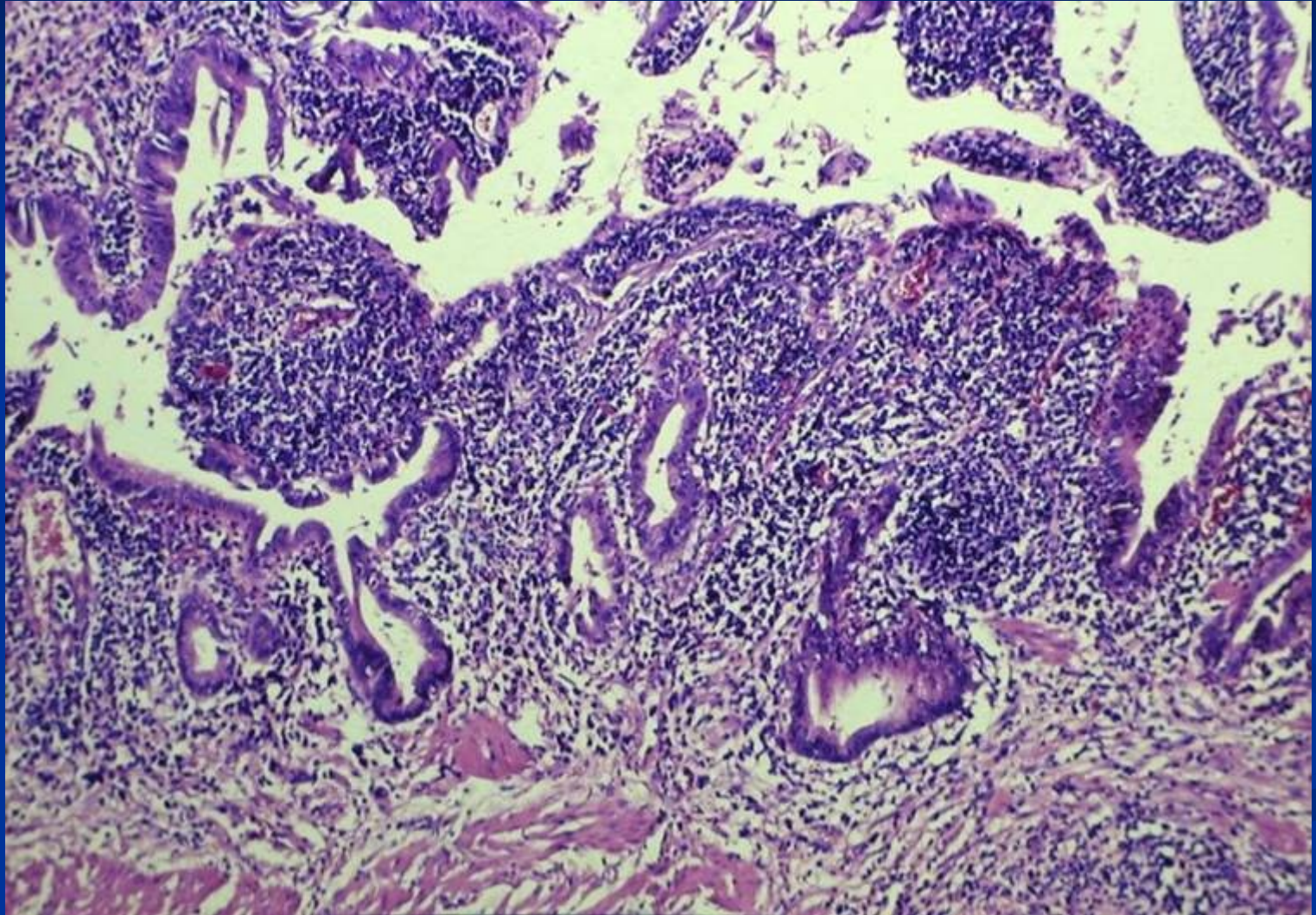
Fibroproduction (thickening of the wall, adhesions)

Chronic inflammation (risk of carcinoma development)

Dystrophic calcification

Hydrops

Active chronic cholecystitis



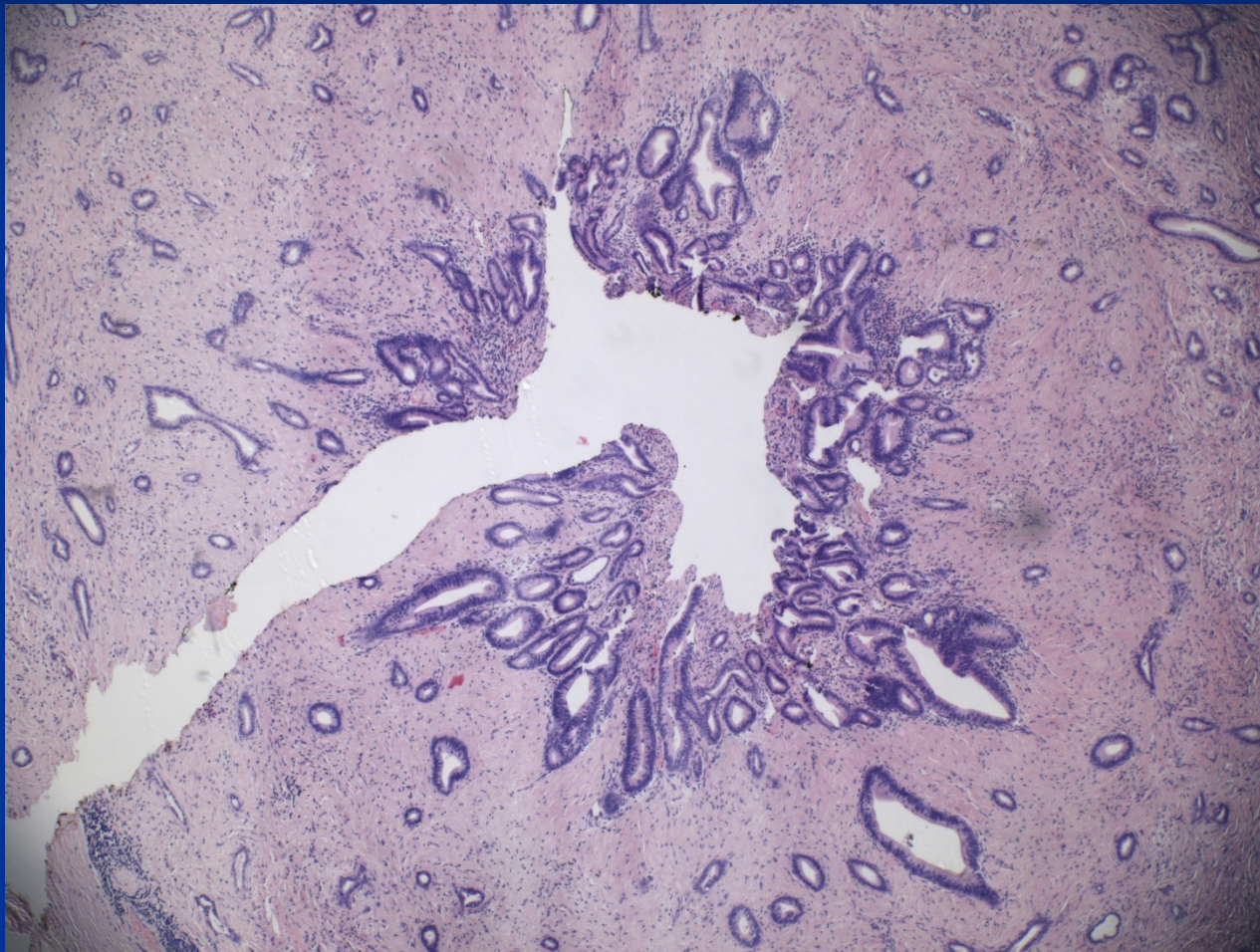
Choledocholithiasis

- Stones within the biliary tree
- West – from gallbladder
- Asia – primary ductal and intrahepatic stone formation
- Symptoms due to:
 - Biliary obstruction
 - Pancreatitis
 - Cholangitis
 - Hepatic abscess

Biliary intraepithelial neoplasia

- Precursor lesions for carcinoma
- Variable grade of cellular and architectural atypia
- BilIN 1 low grade, BilIN 2 intermediate grade
- BilIN 3 high grade, commonly already associated with invasive carcinoma
- Not visible by imaging methods
- Incidental finding in biopsy/cholecystectomy

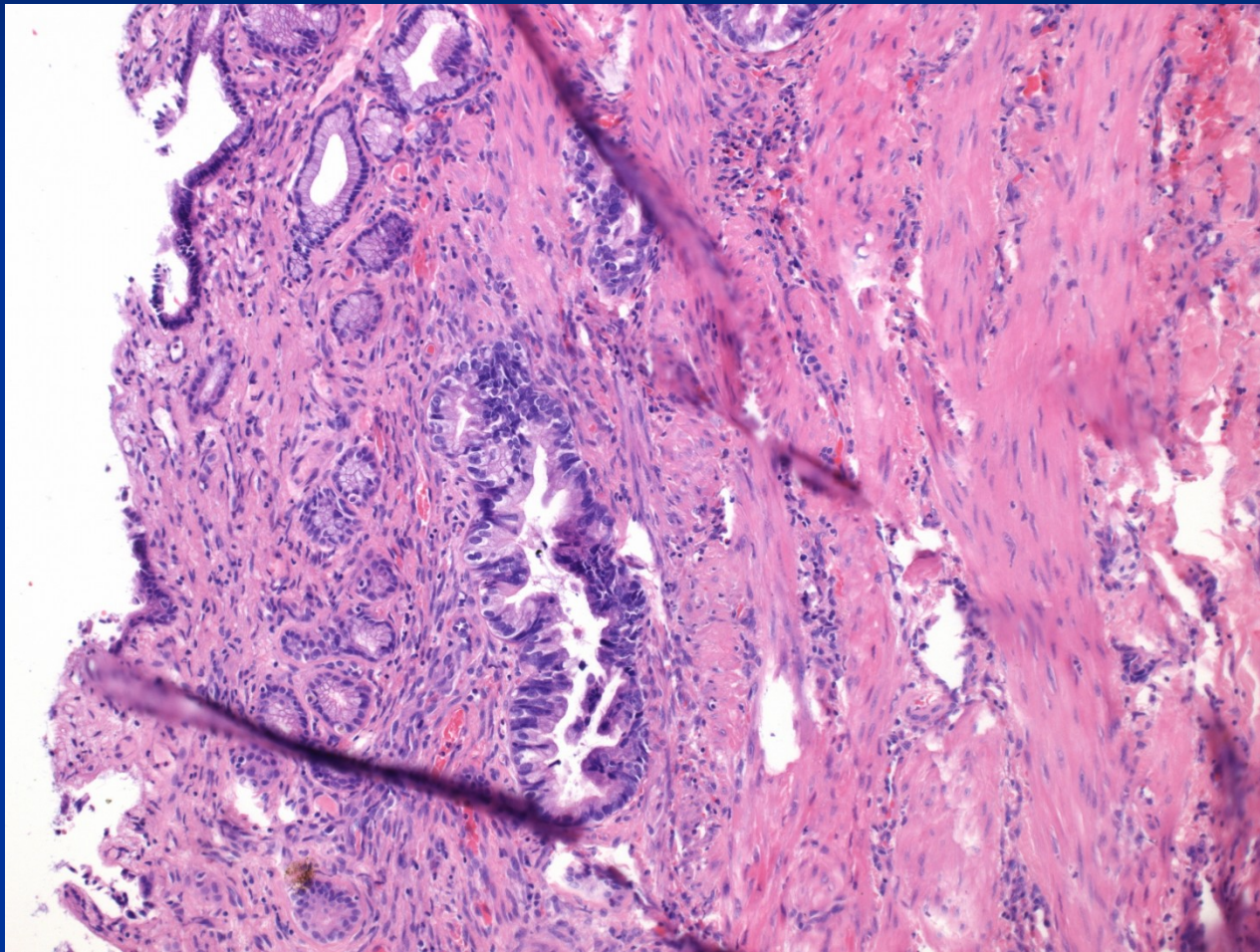
BiIN 3 + invasive carcinoma



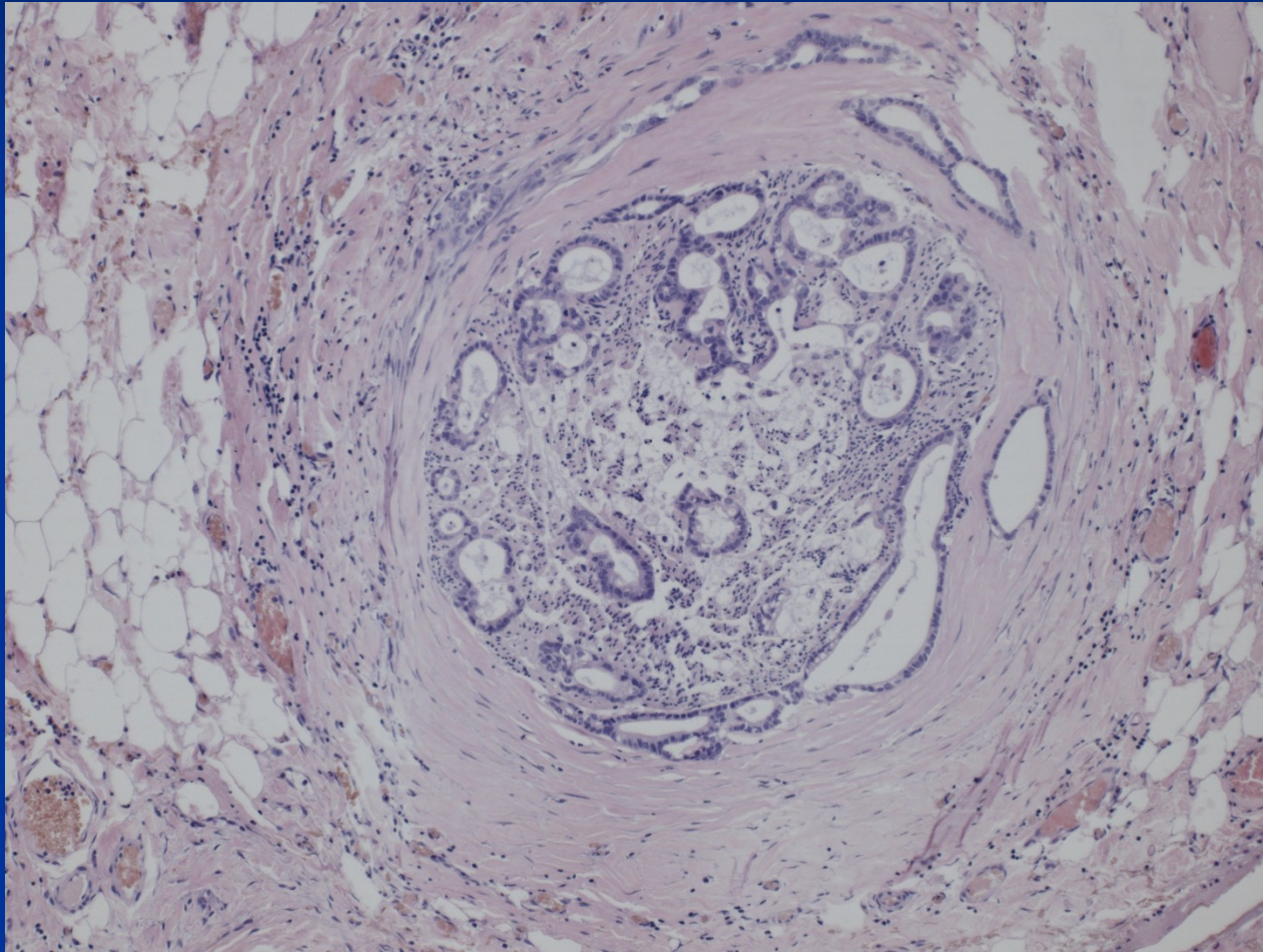
Gallbladder carcinoma

- Seventh decade
- F>M
- Discovered at late stage, usually incidental
- Exophytic and infiltrating types
- Adenocarcinoma
- Local extension into liver, cystic duct, portal LN
- Mean 5 yrs survival 1%

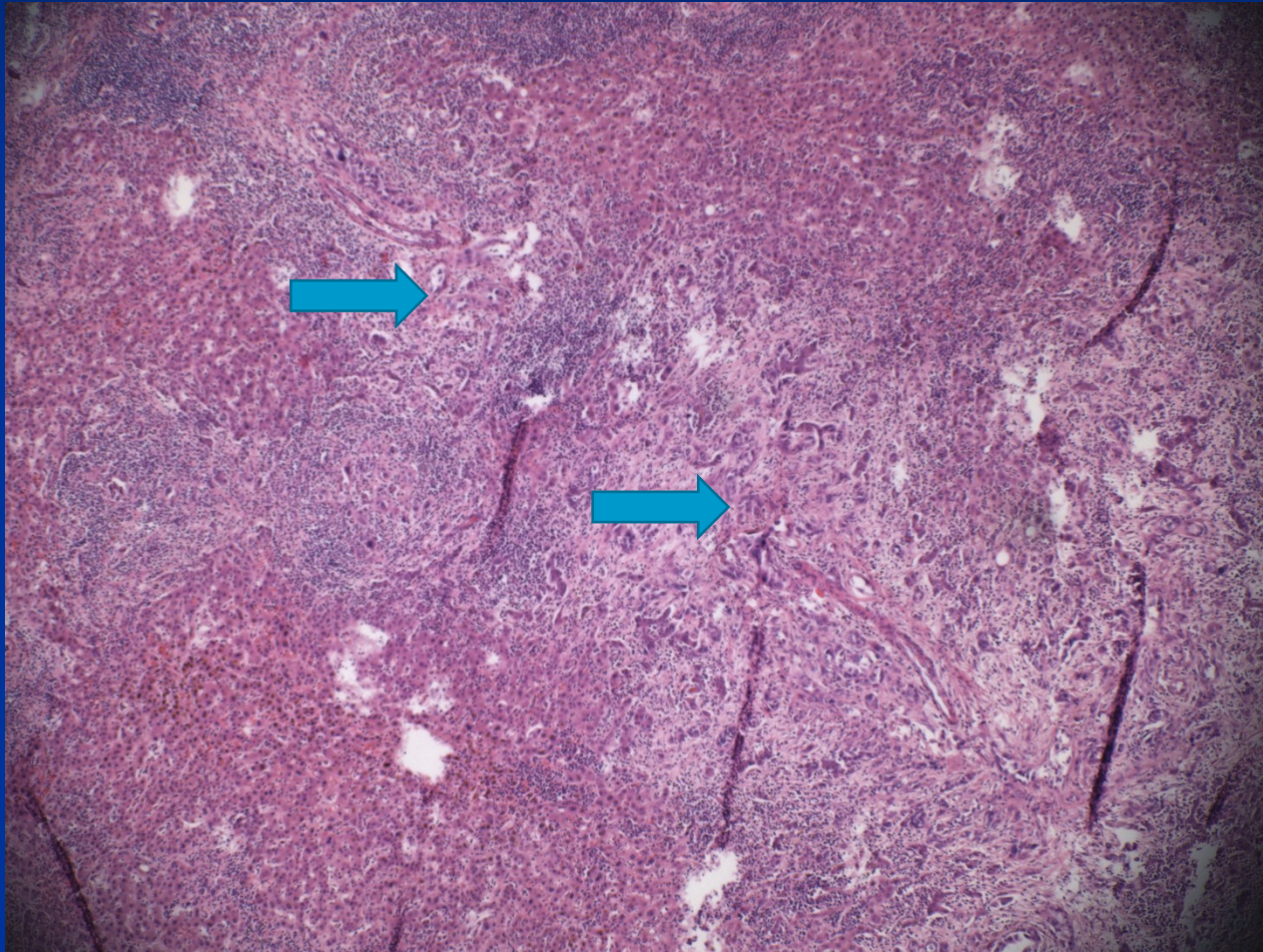
Neoplastic + non-neoplastic glands



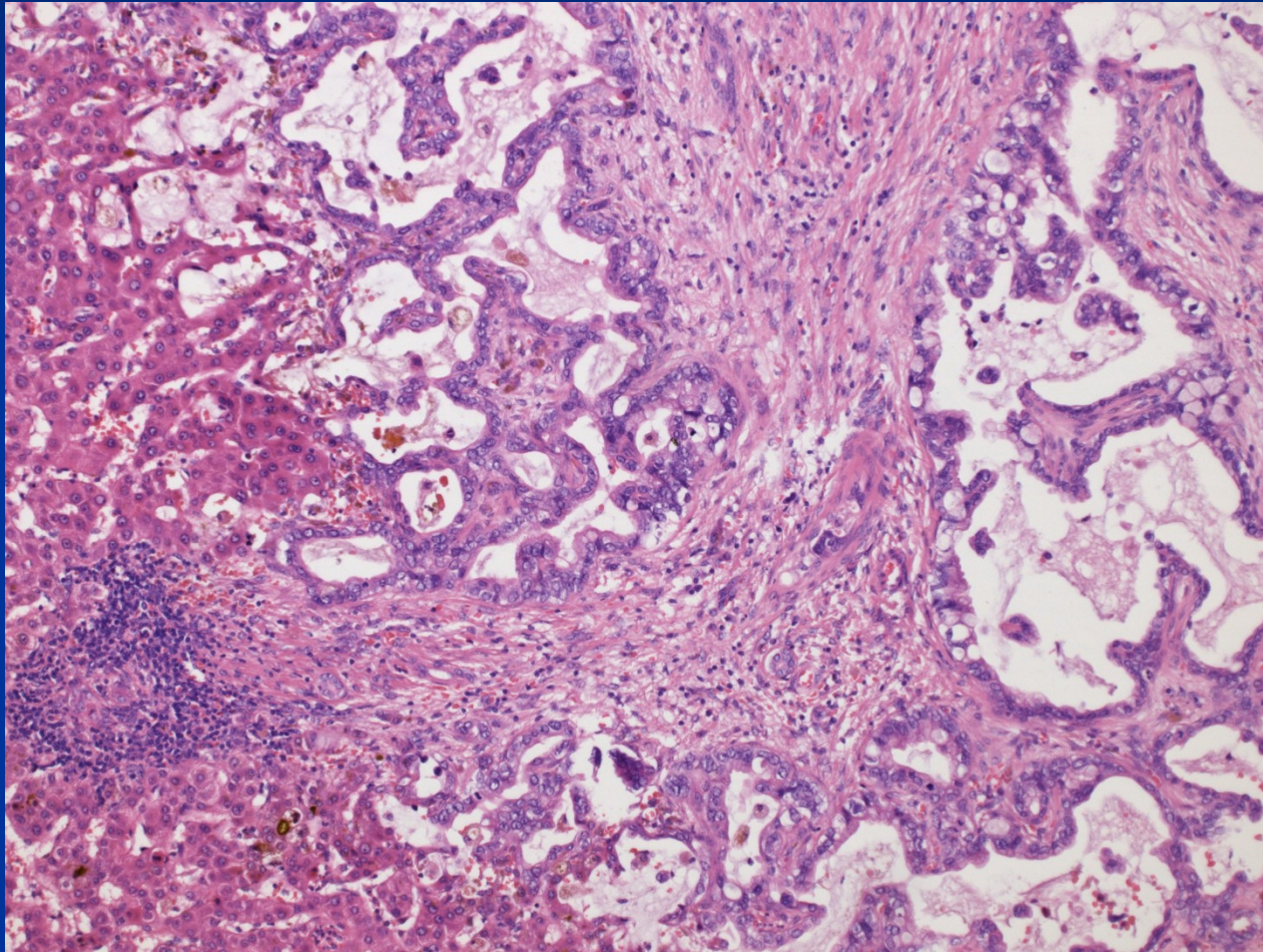
Peri- and intraneural invasion



Liver invasion



Liver invasion



Other disorders of extrahepatic biliary system

- Atresia of bile ducts (unclear etiopathogenesis, inborn disorder, rapid progression, cirrhosis)
- Primary sclerosing cholangitis - PSC
- Cholesterolosis (strawberry gallbladder)
- Tumors of papilla Vateri (ampuloma, periampular carcinoma – difficult diagnosis)

