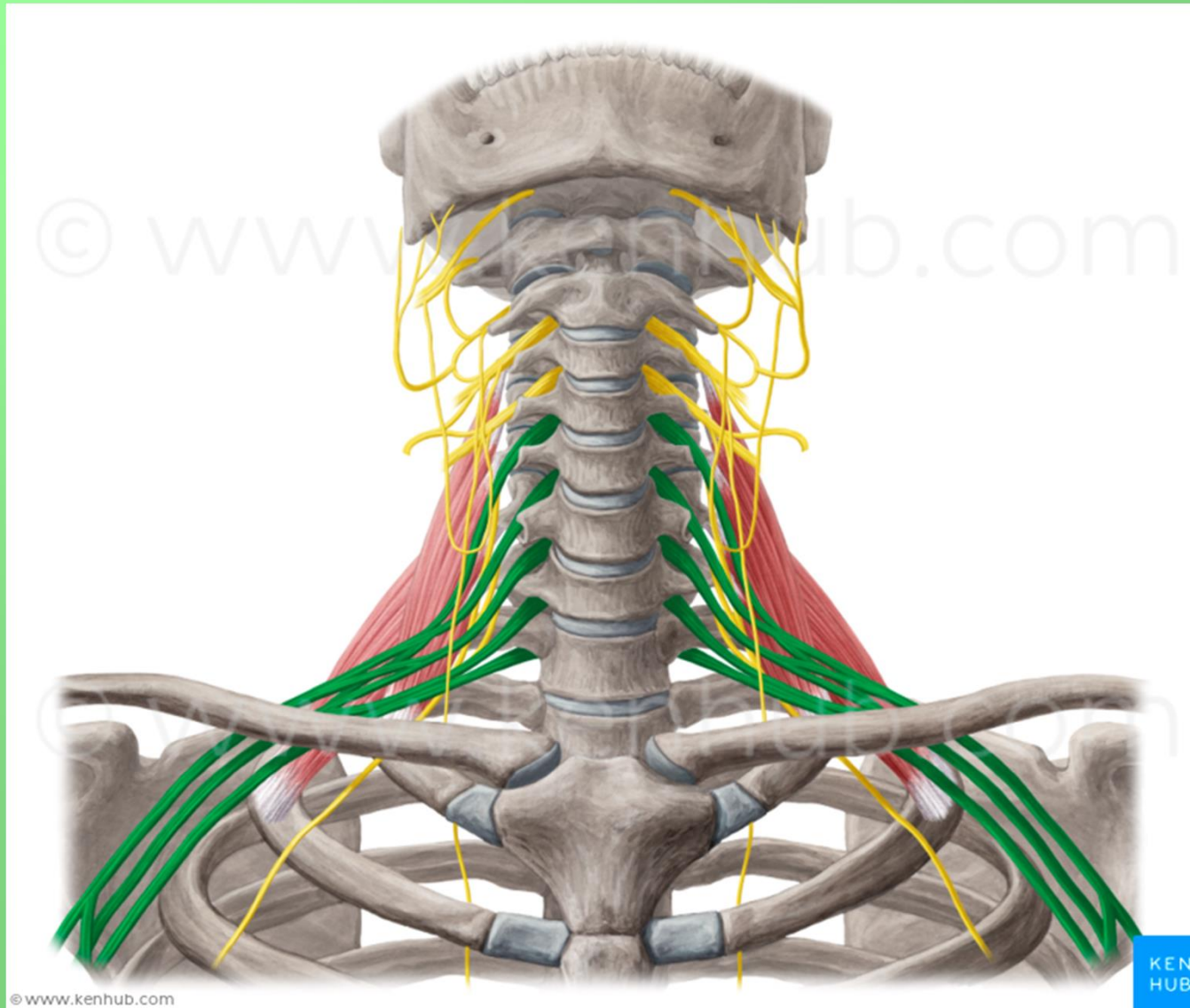
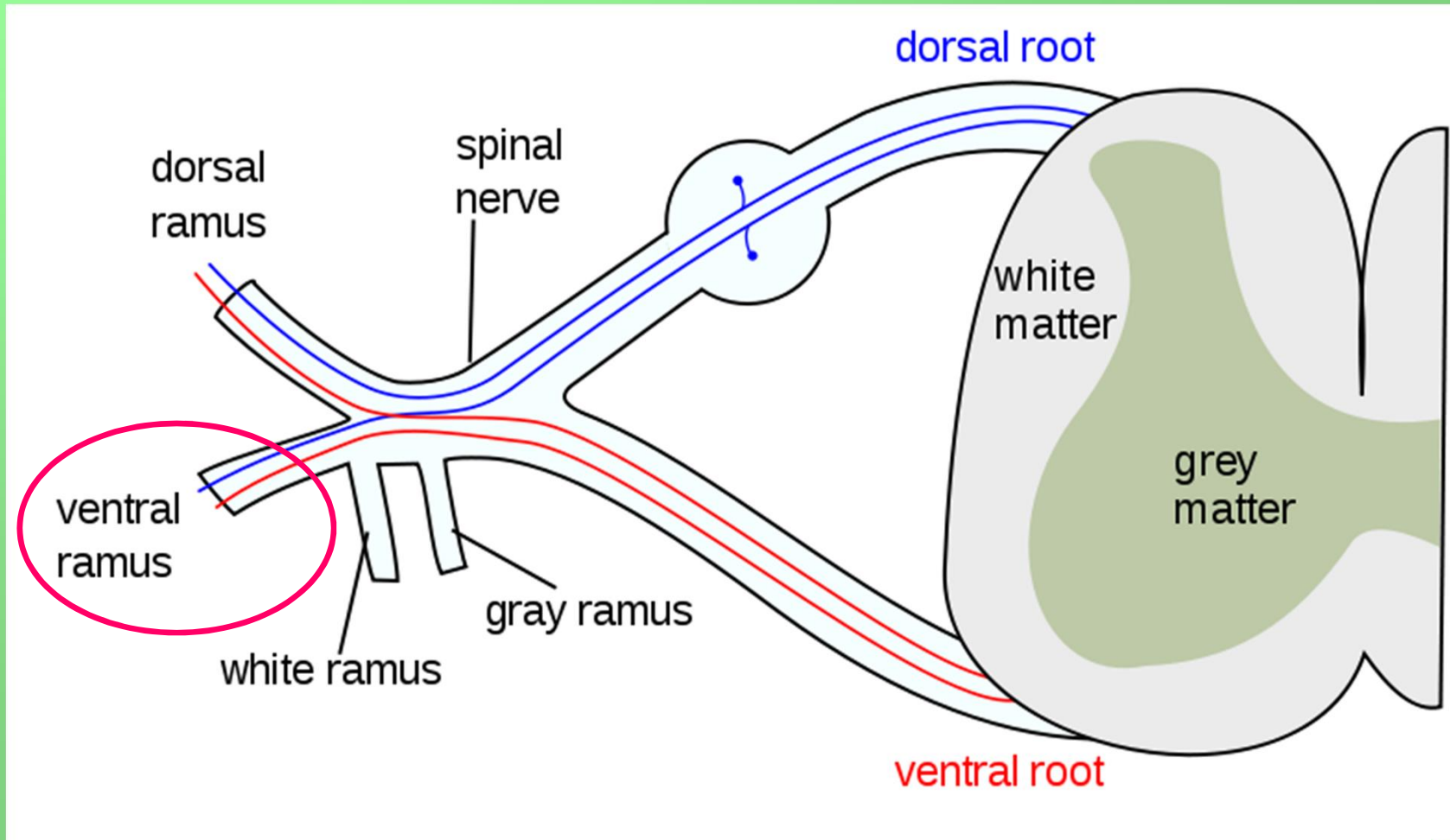


# PLEXUS BRACHIALIS



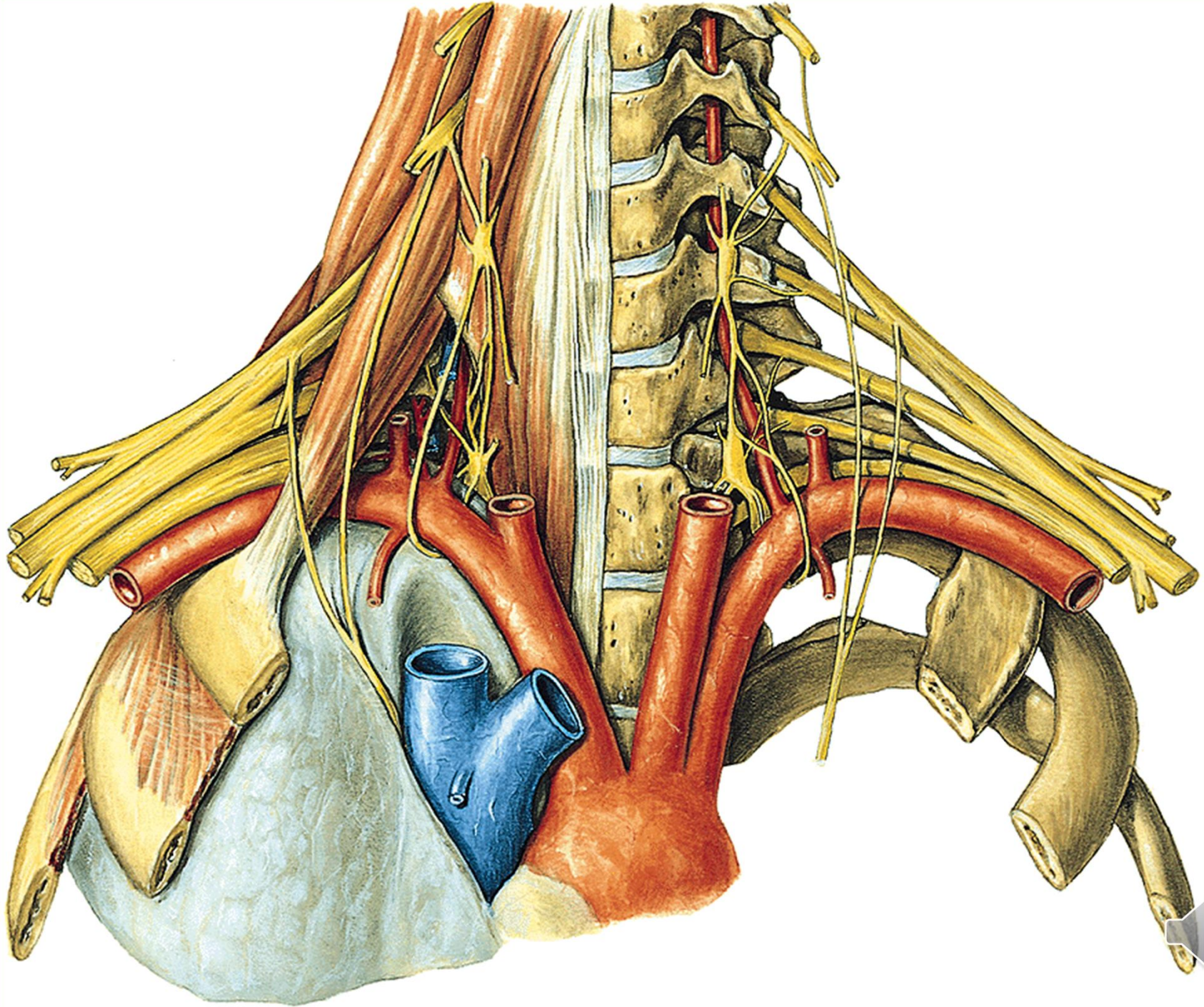
# Nervus spinalis



# Plexus brachialis (C4-Th1)

- ve fissura scalenorum
- senzoricky kůži na horní končetině
- motoricky svaly horní končetiny a také heterochtonní svaly zad a hrudníku





# Plexus brachialis (C4-Th1)

Primární svazky:

Truncus superior (C4) C5+6

Truncus medius C7

Truncus inferior C8+Th1

Sekundární svazky:

**Fasciculus posterior:** spojení všech dorzálních větví

**Fasciculus lateralis:** spojení ventrálních větví truncus superior a medius

**Fasciculus medialis:** ventrální větev truncus inferior

Oddělení jednotlivých nervových kmenů z fascikulů:

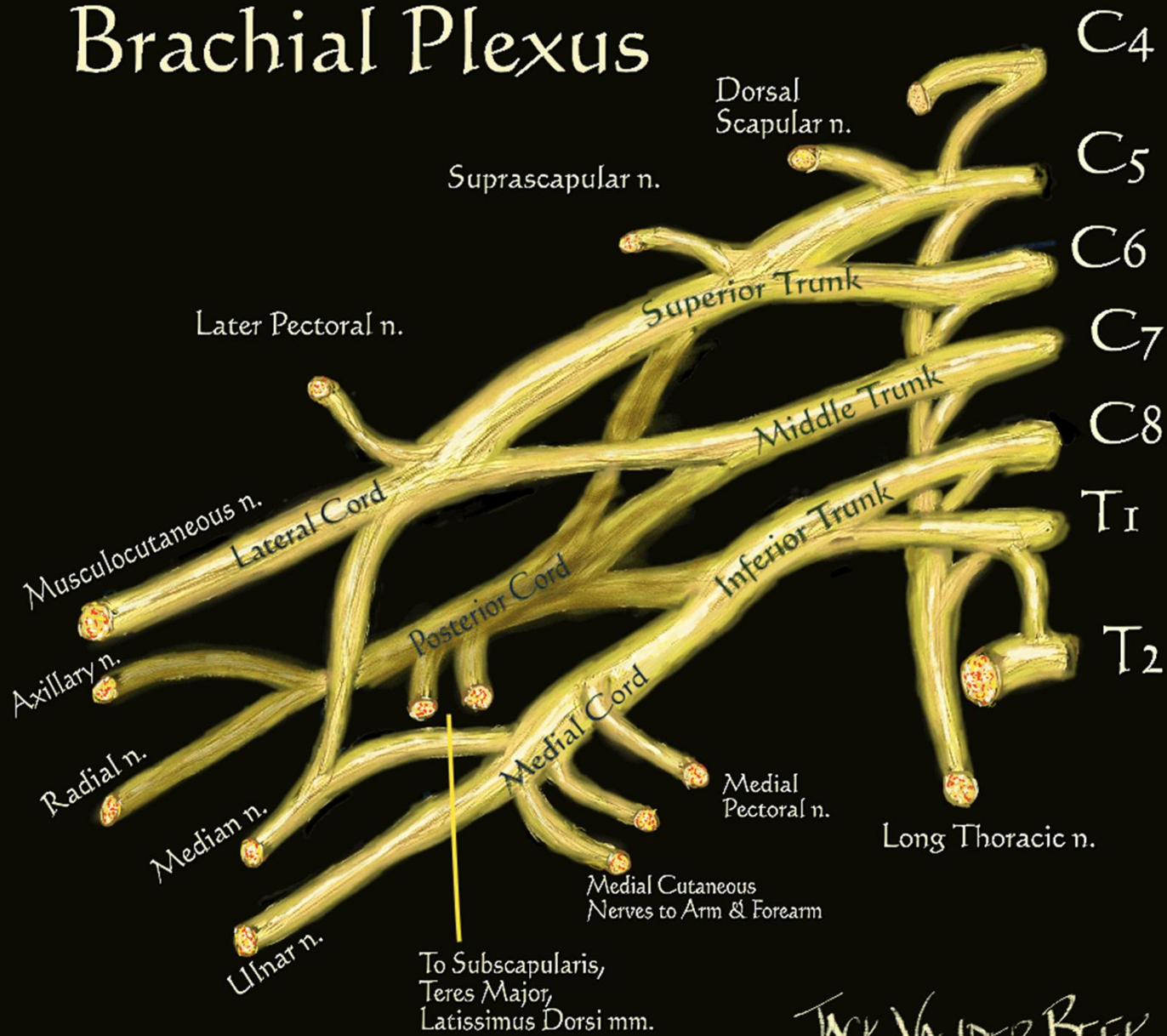
**FP:** n. radialis, n. axillaris

**FL:** n. musculocutaneus + část n. medianus

**FM:** n. ulnaris + část n. medianus



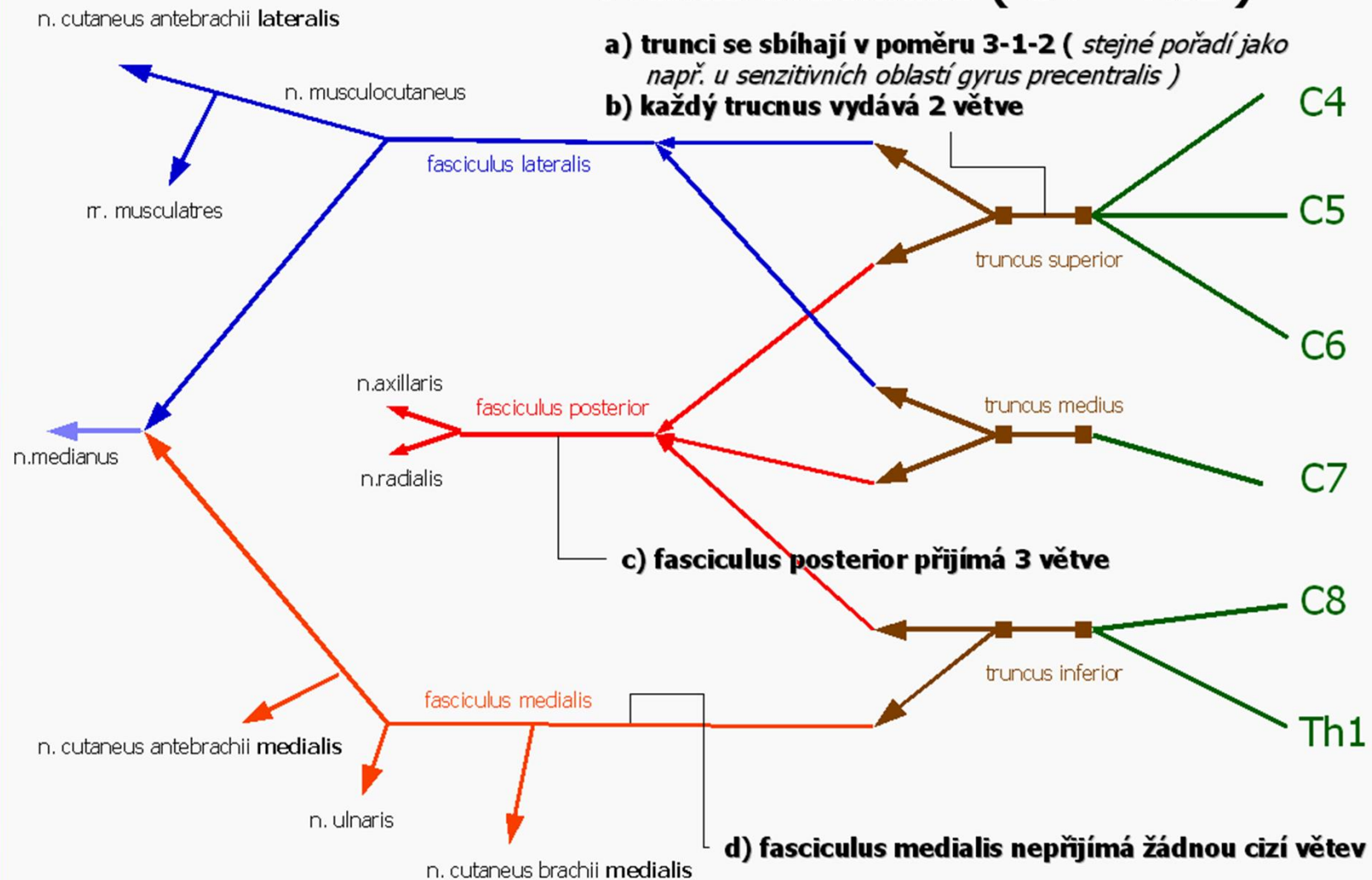
# Brachial Plexus



JACK VANDER BEEK  
(c) 2005 neuraxiom.com



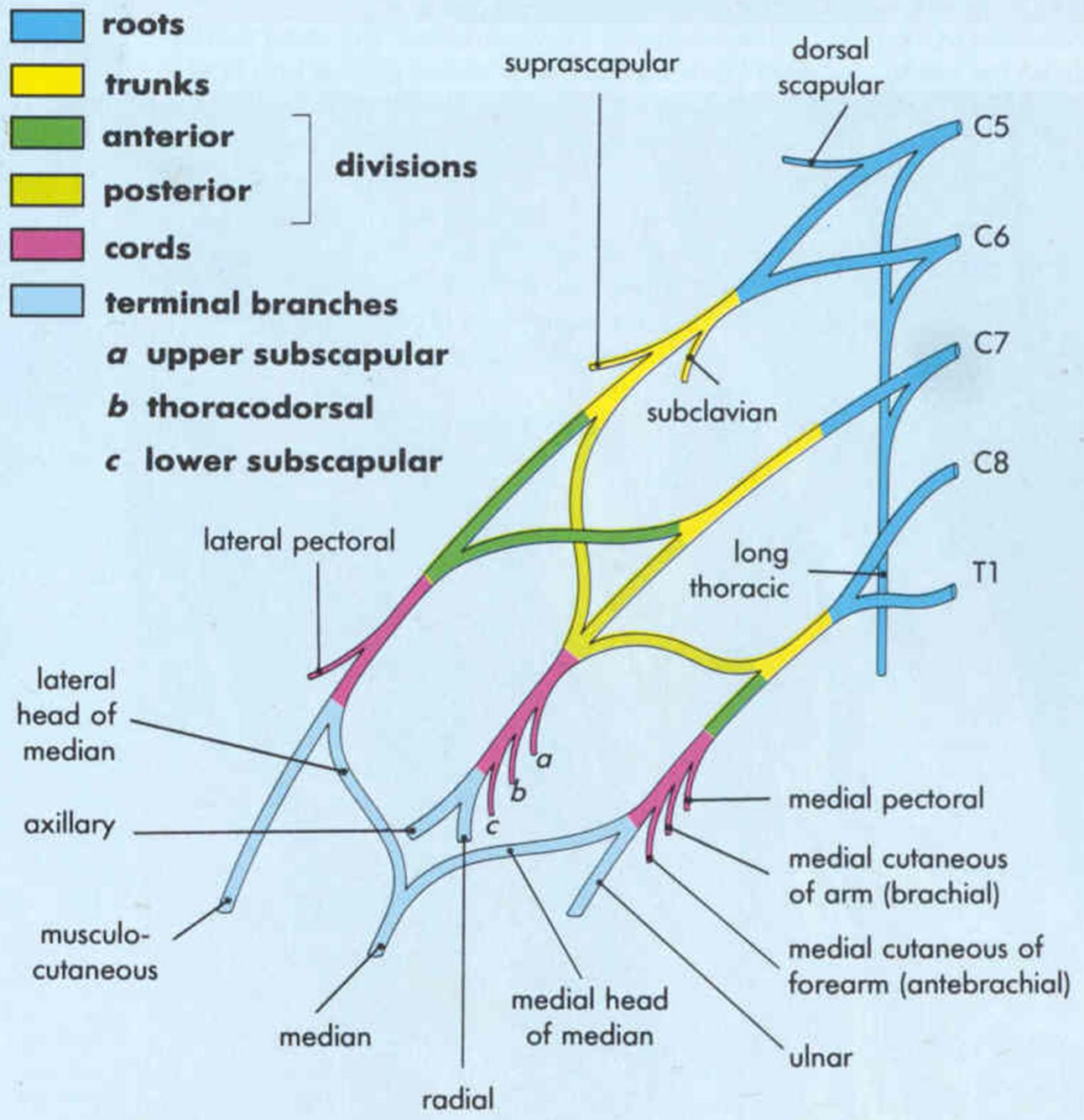
# Plexus brachialis ( C4 – Th1 )



© physiotherapy.cz/edu/

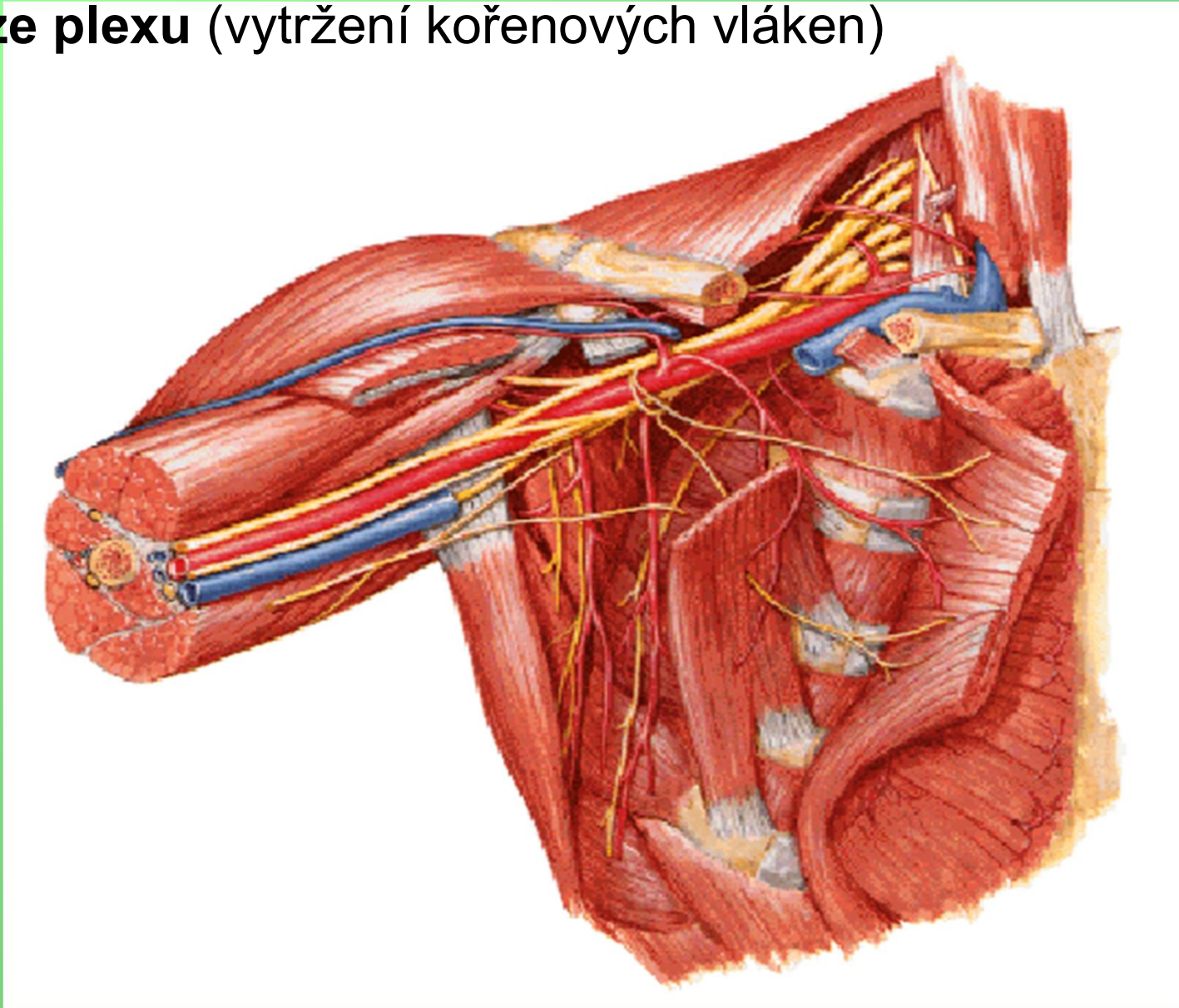
Důsledek: v jednom nervovém kmeni jsou obsaženy axony z více segmentů - při porušení kořene obrna více svalů

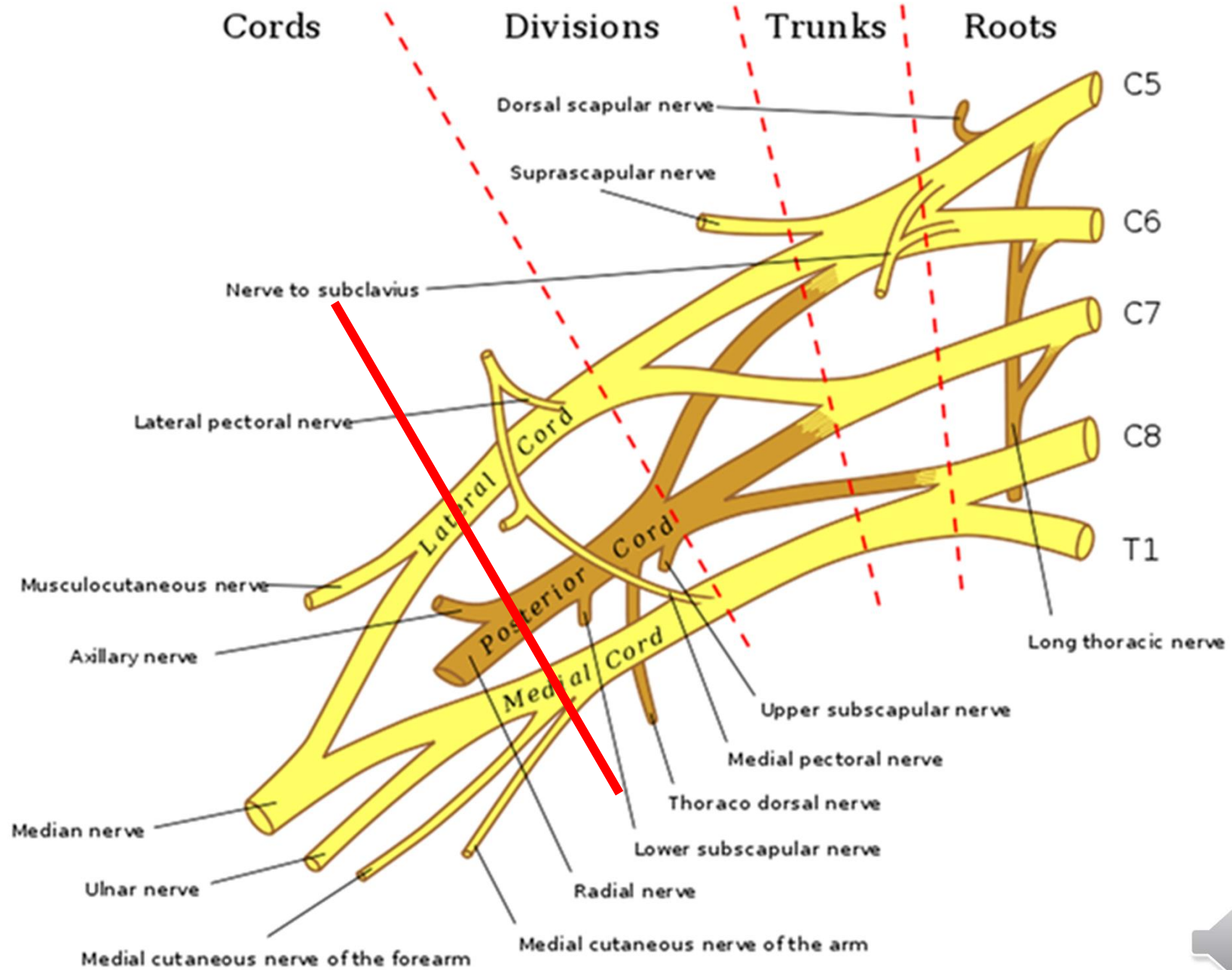






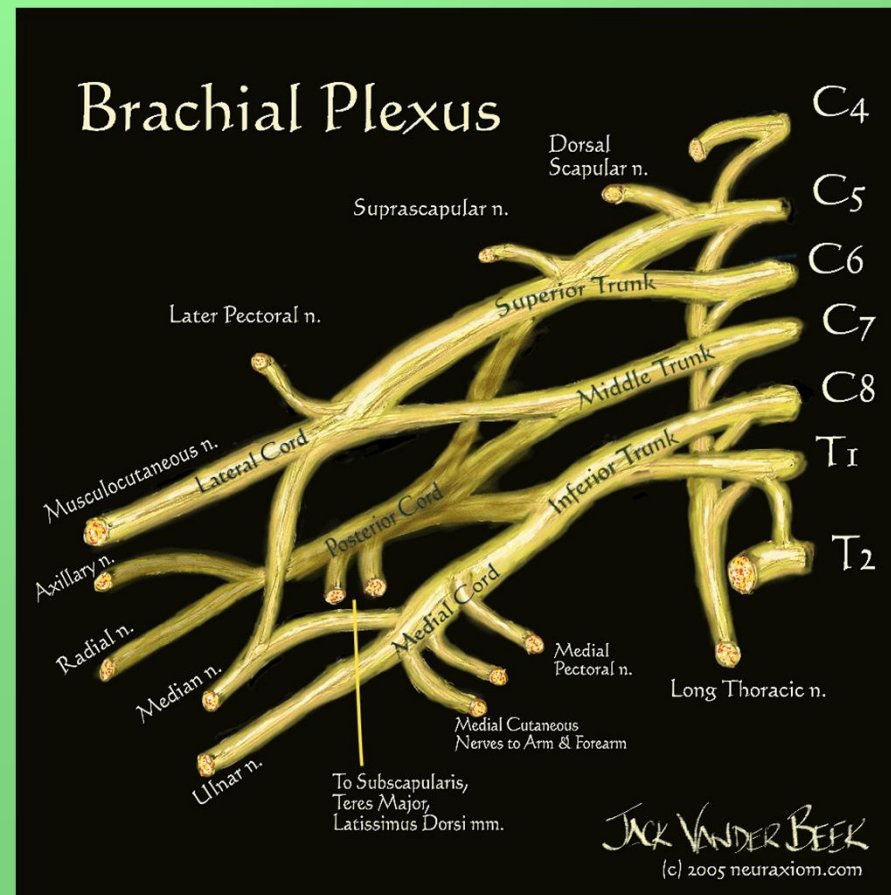
- **skalenový syndrom** (fissura scalenorum)
- **syndrom kostoklavikulární komprese** (1. žebro a clavicula)
- **avulze plexu** (vytržení kořenových vláken)

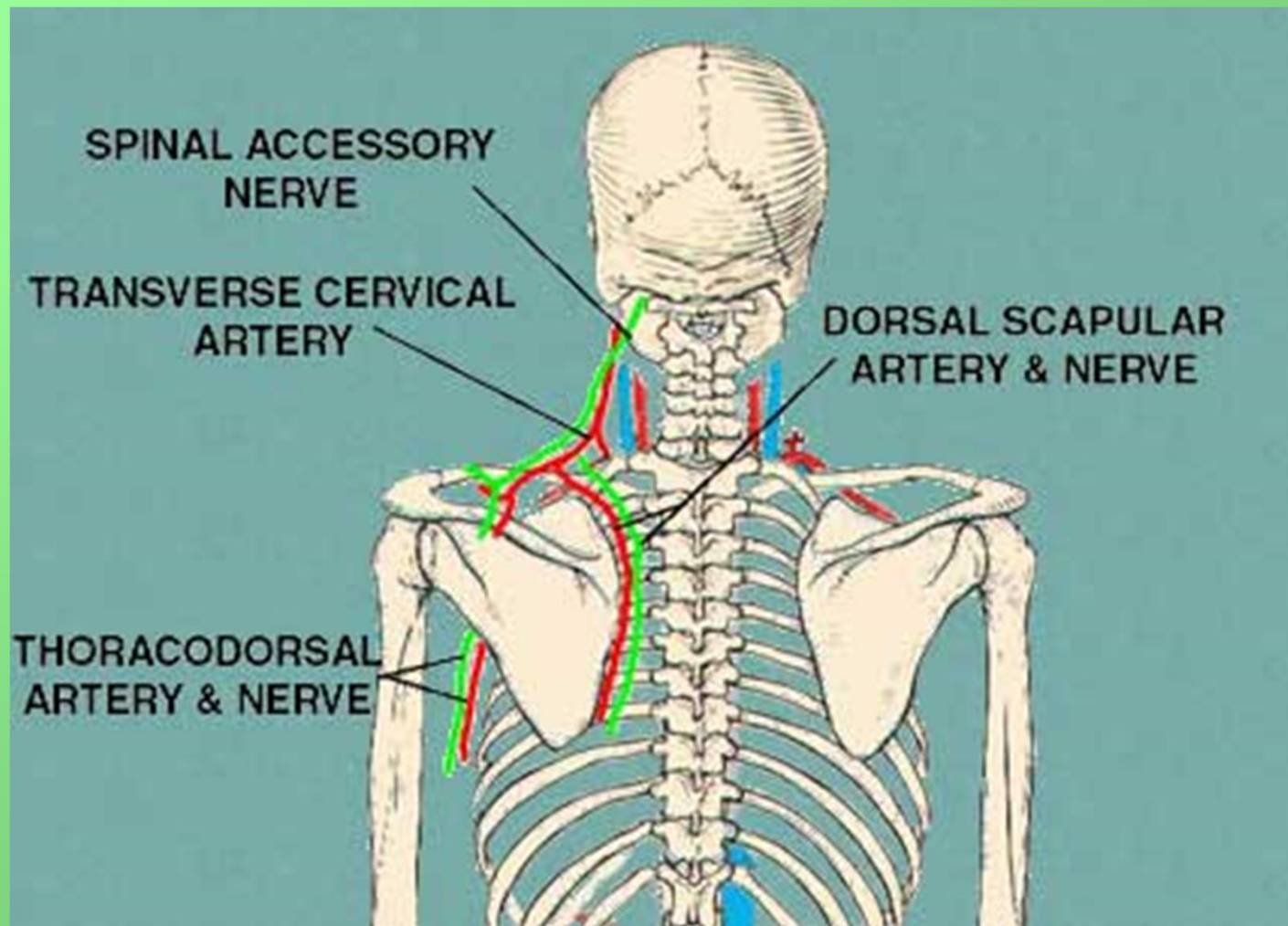




# nervus dorsalis scapulae (C5-6)

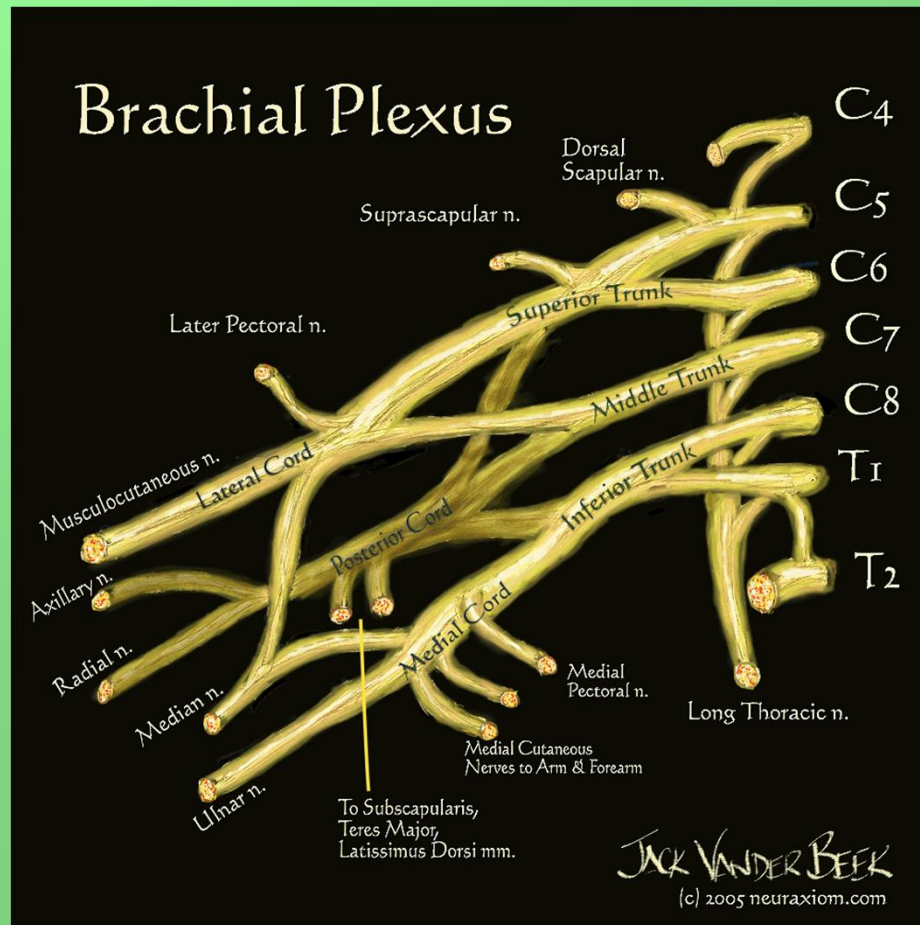
- m. levator scapulae et mm. rhomboidei



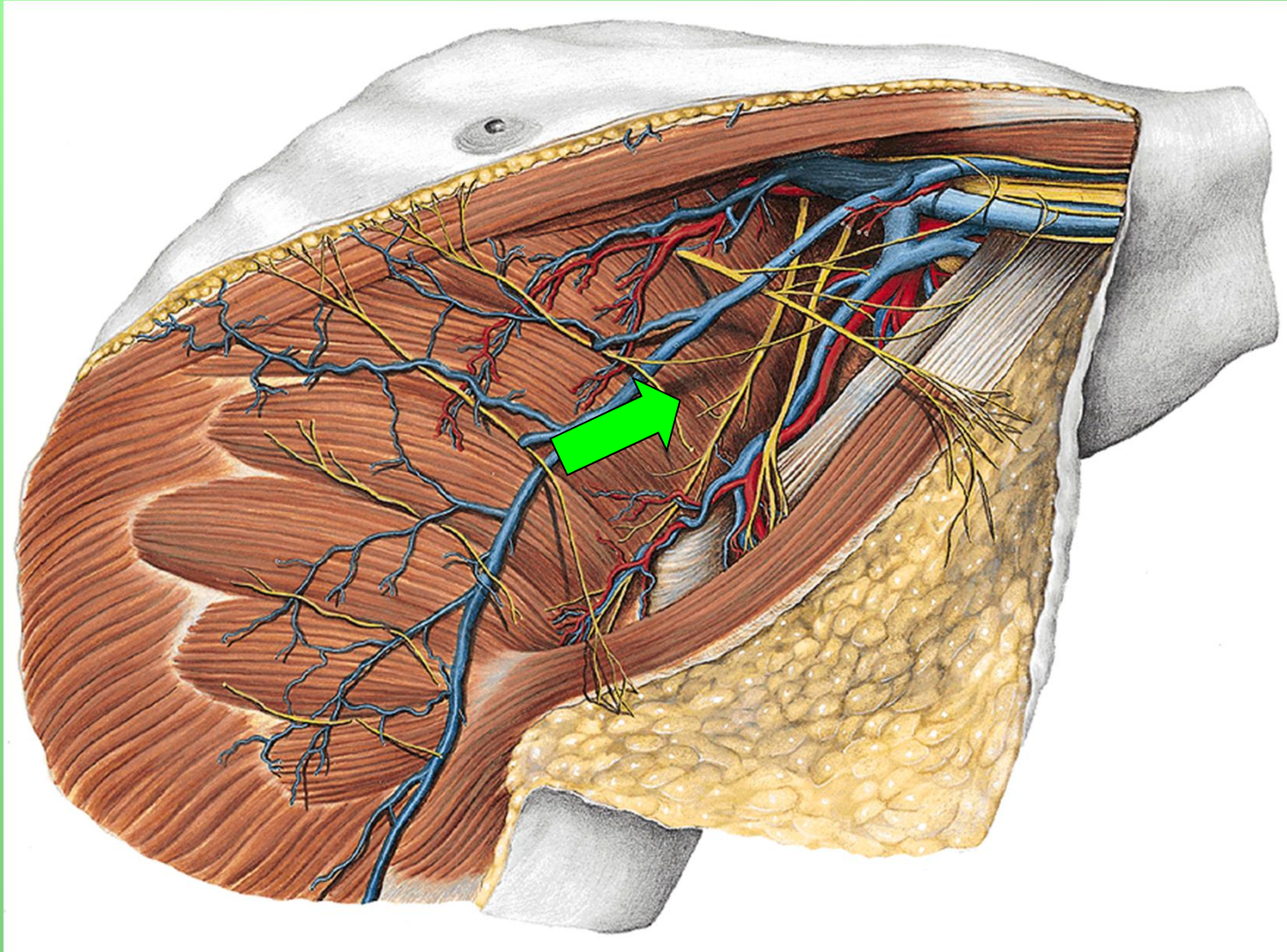


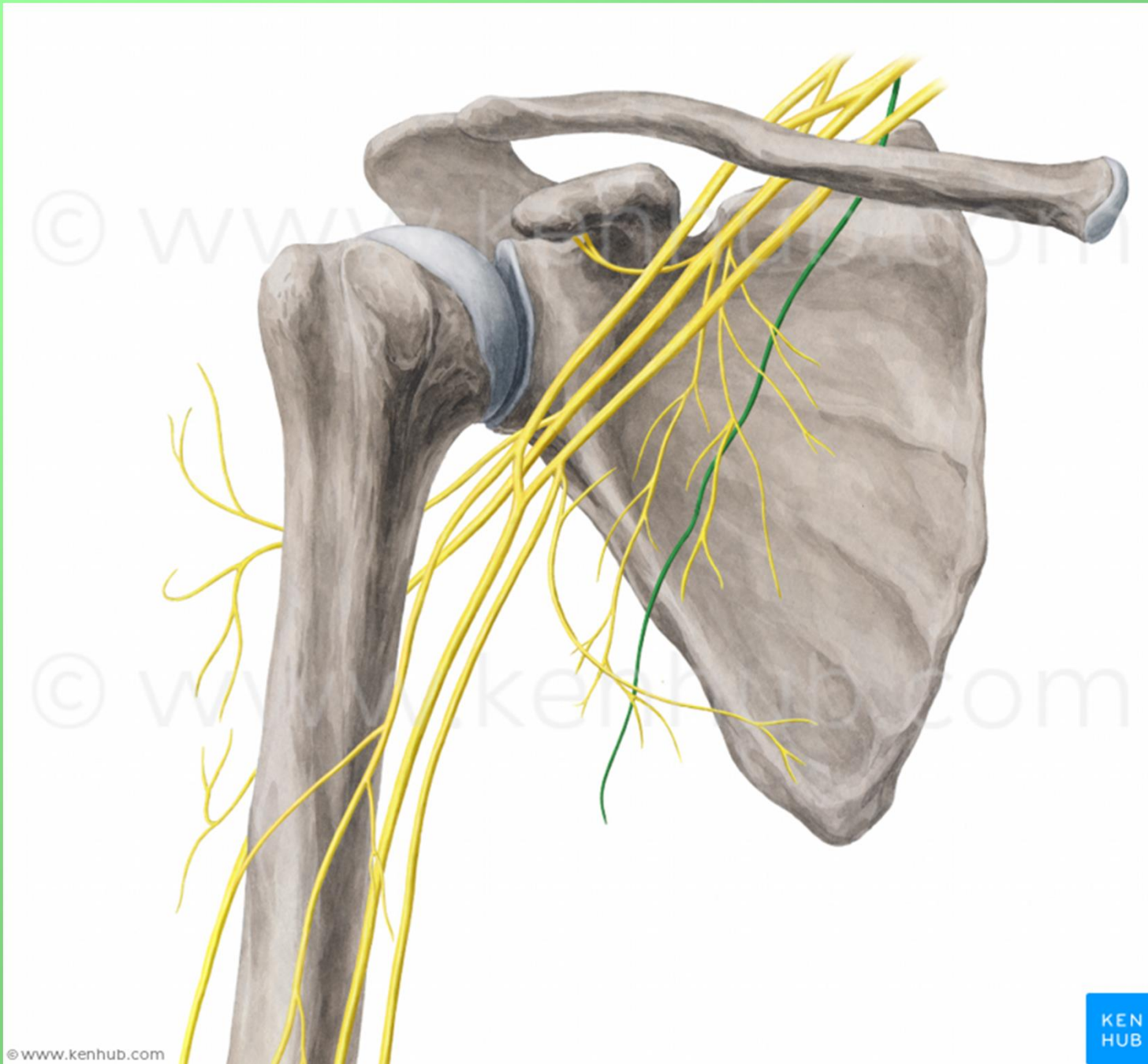
# nervus thoracicus longus (C5-7)

- m. serratus anterior



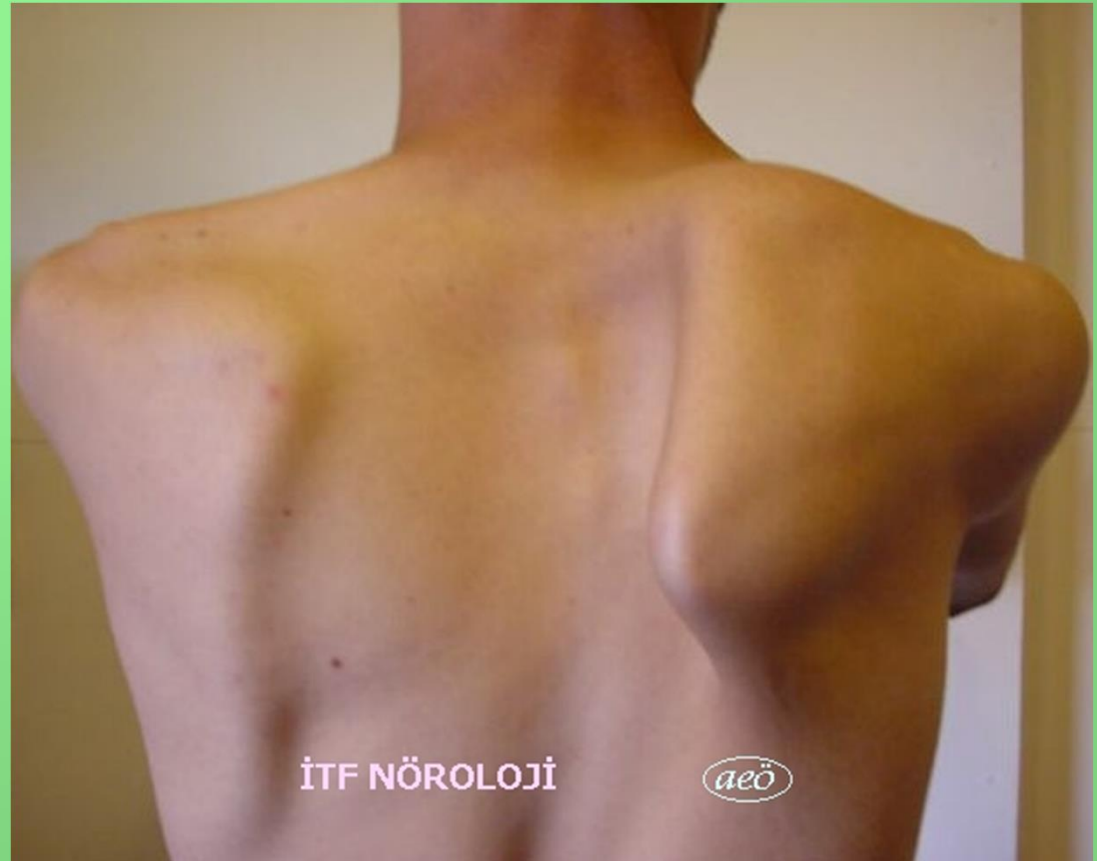# nervus thoracicus longus (C5-7)





# nervus thoracicus longus (C5-7)

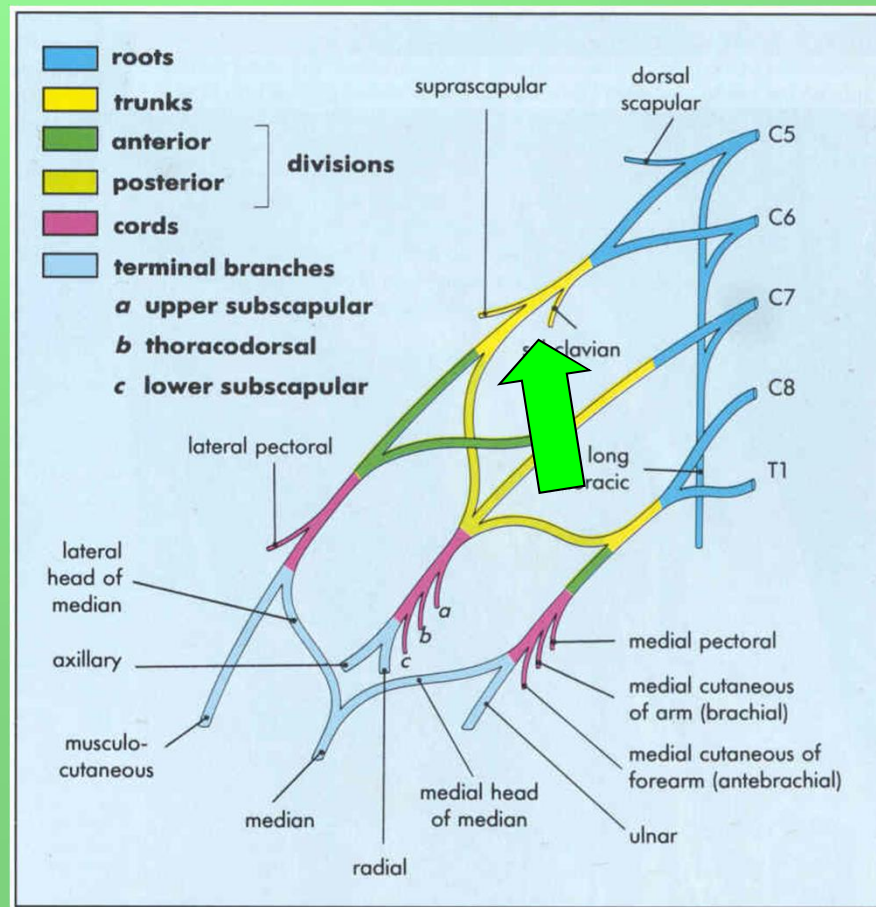
- scapula alata





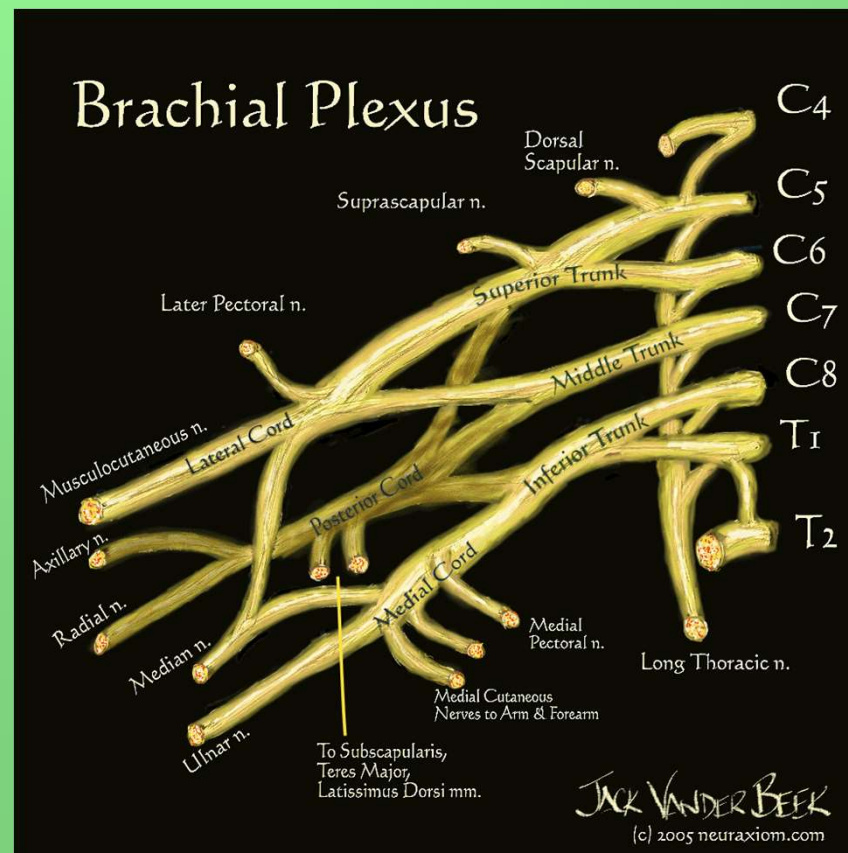
# nervus subclavius C4-6

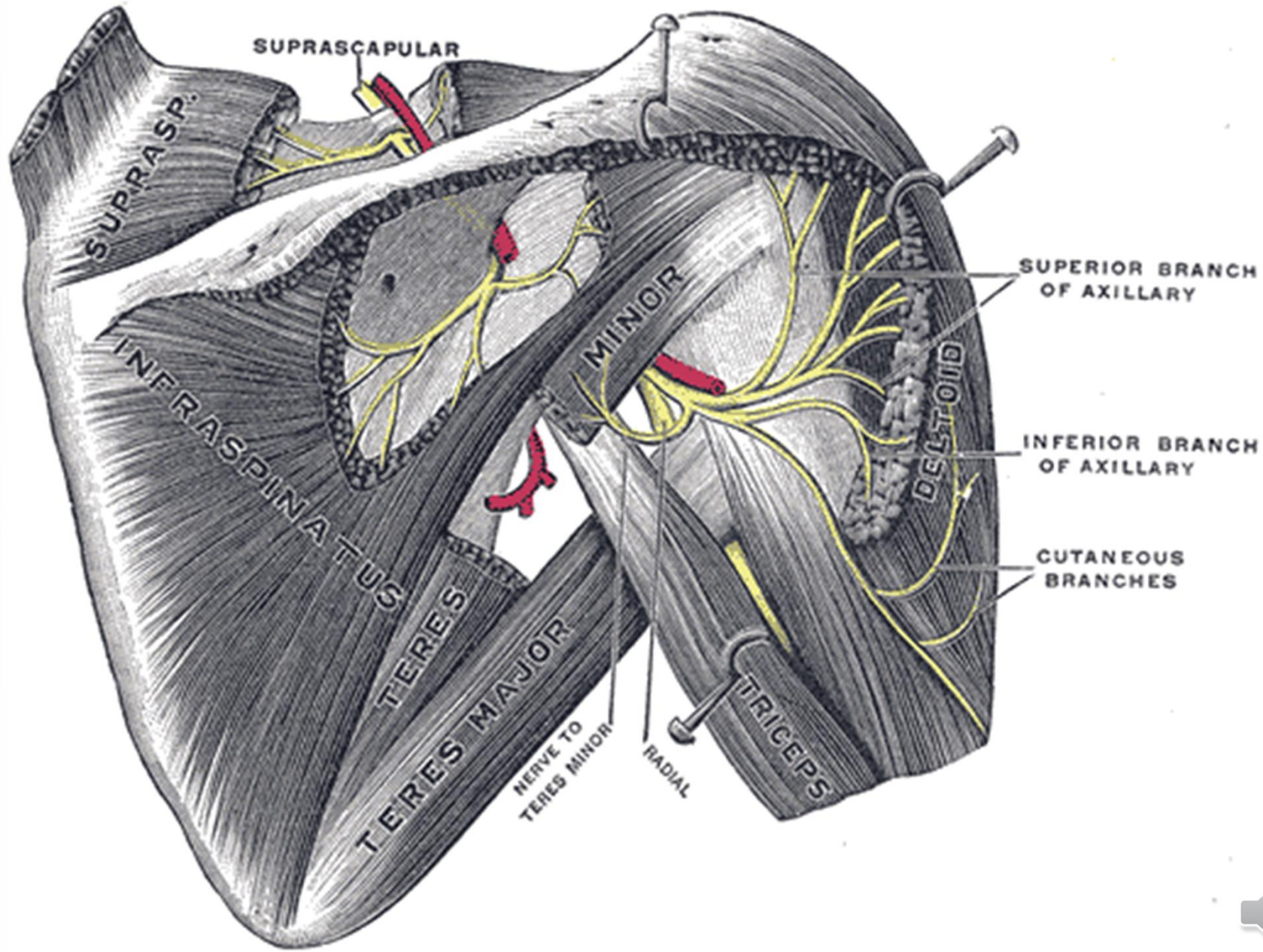
- m. subclavius

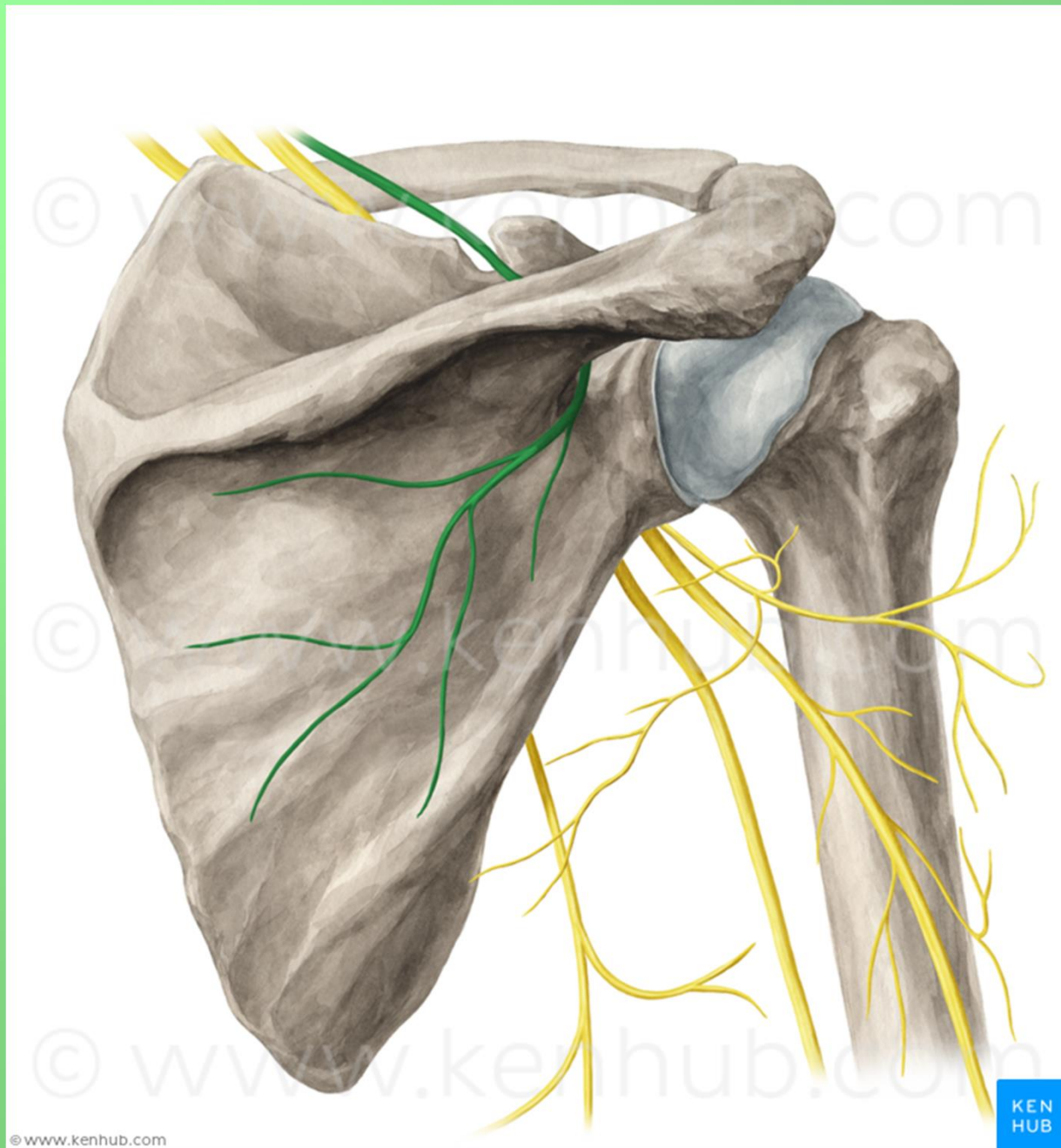


# nervus suprascapularis (C4-6)

- m. supraspinatus, m. infraspinatus, senzoricky pouzdro ramenního kloubu







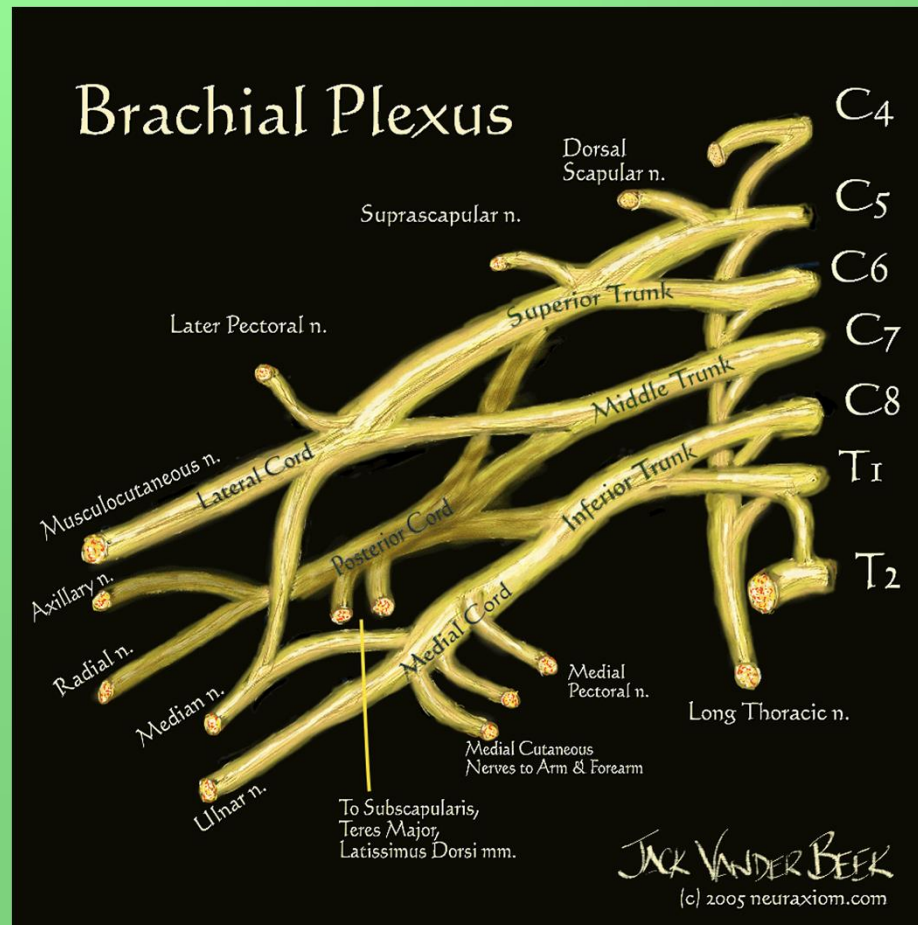
© www.kenhub.com

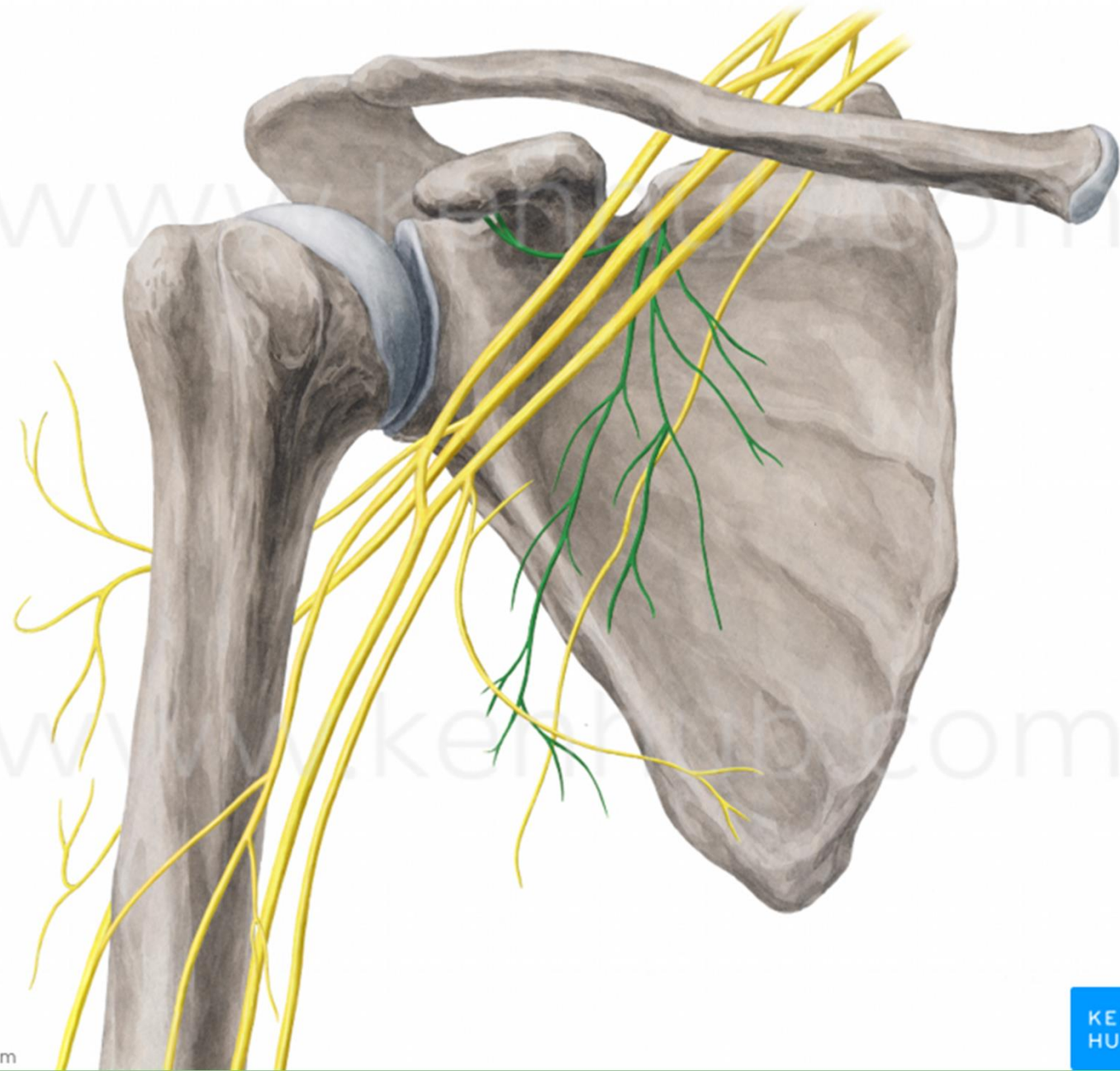
KEN  
HUB



# nervi subscapulares C5-7

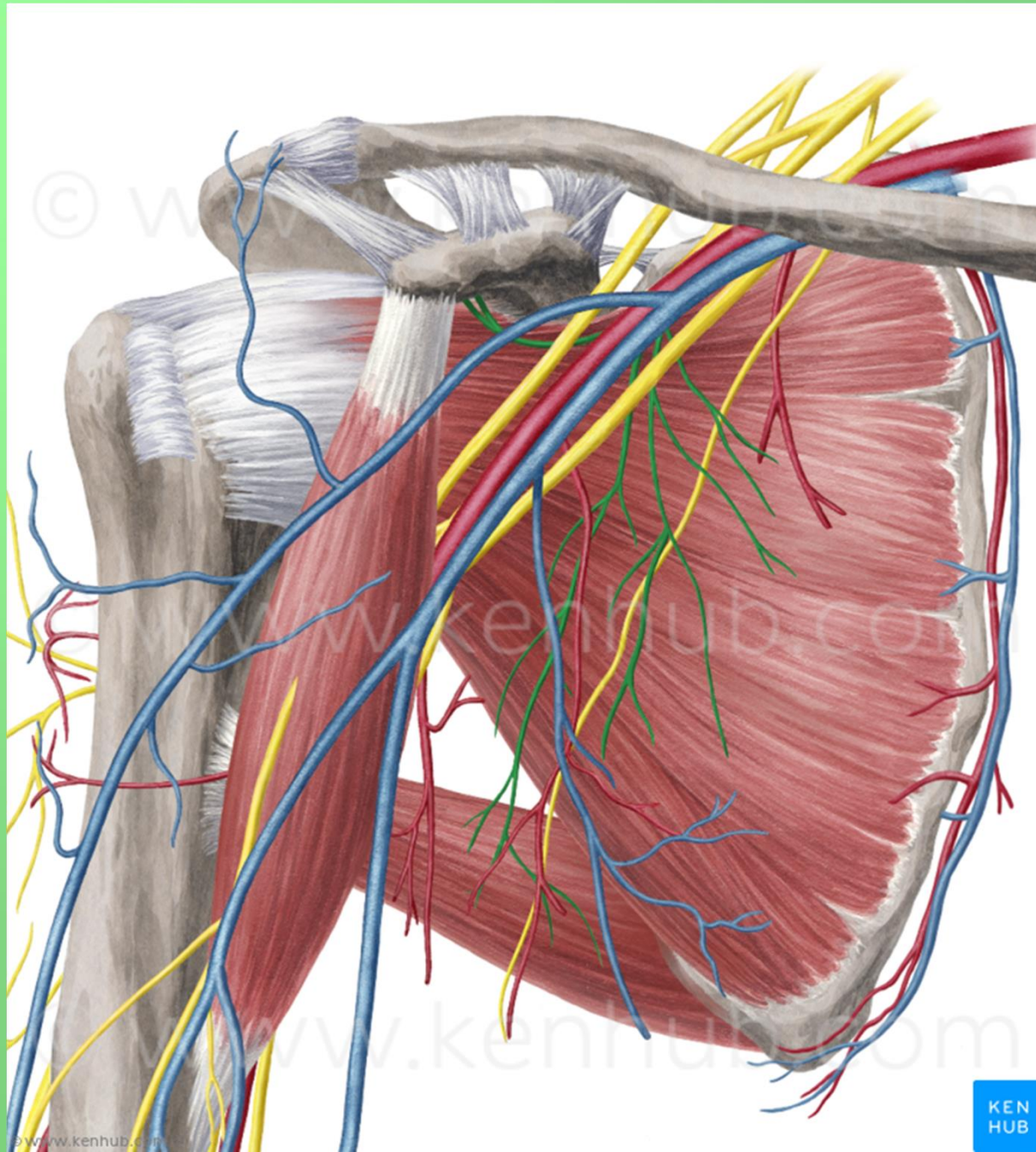
- m. subscapularis, m. teres major





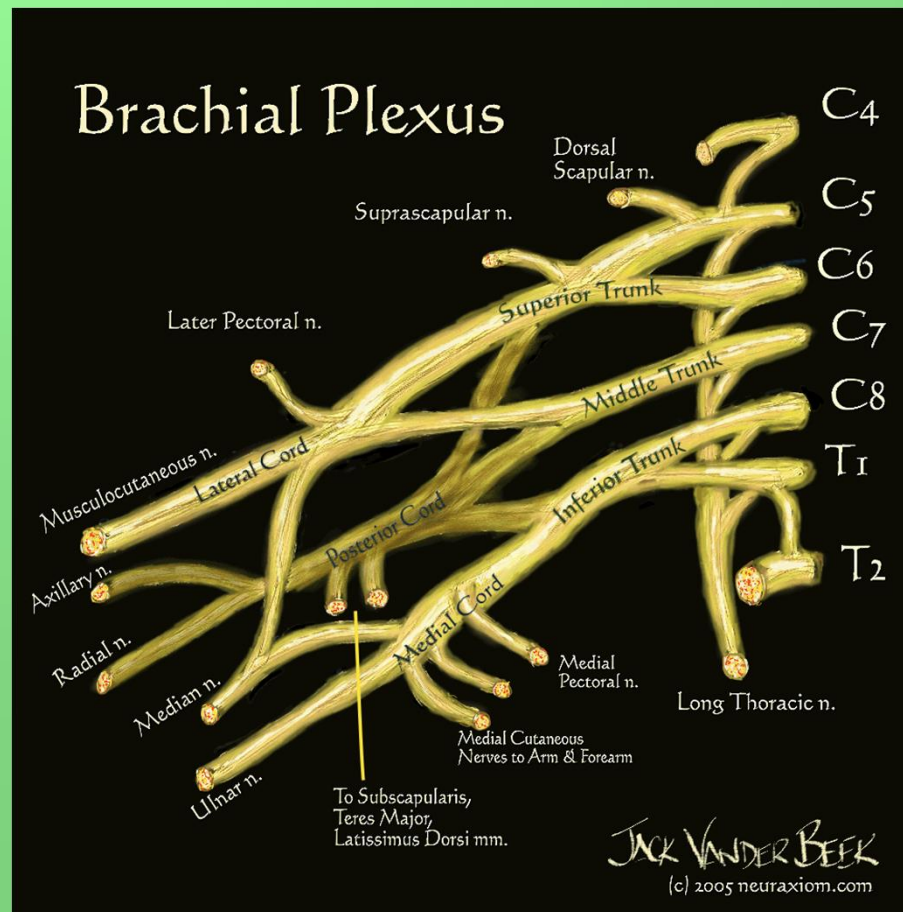
© www.kenhub.com

© www.kenhub.com

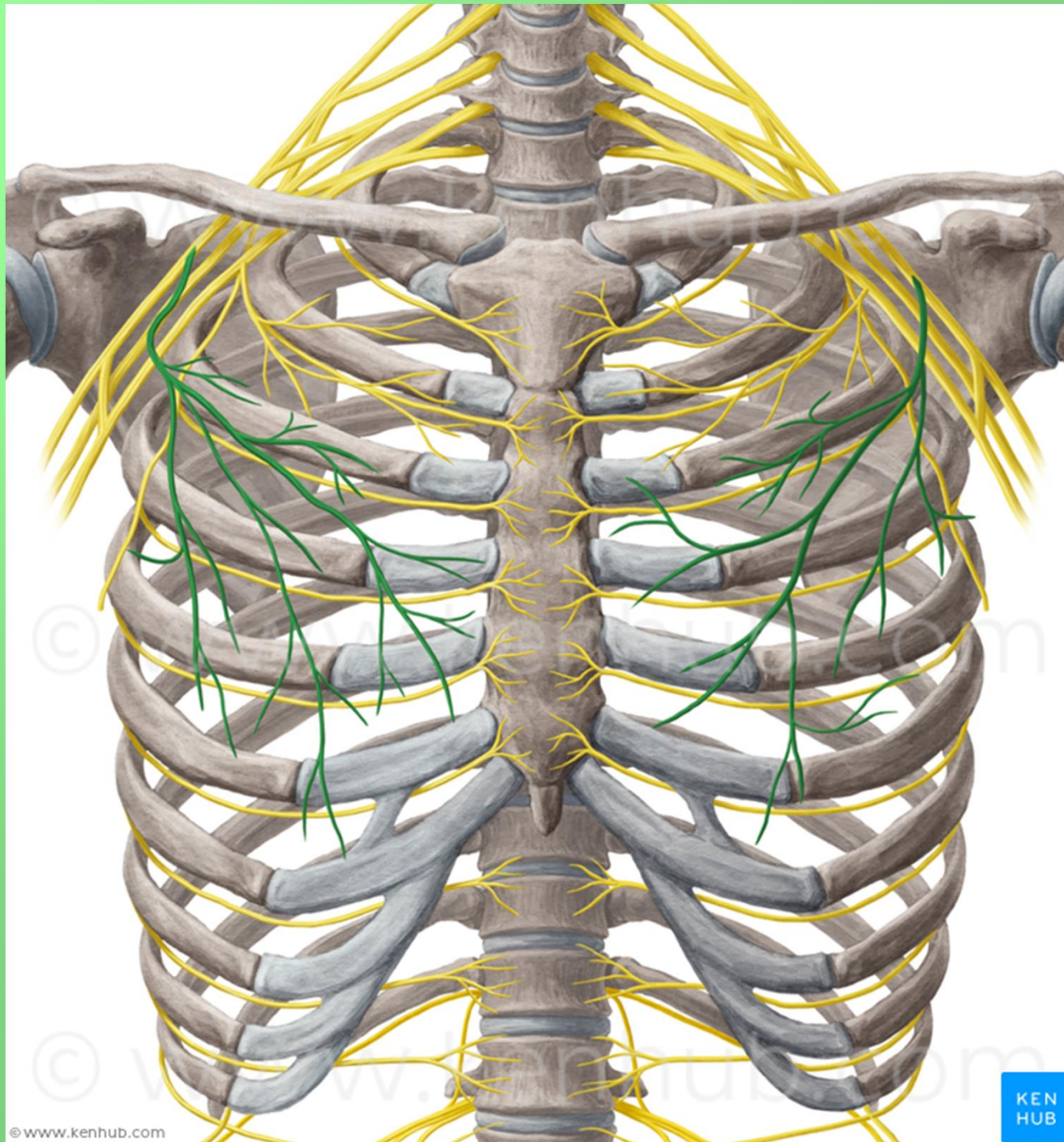


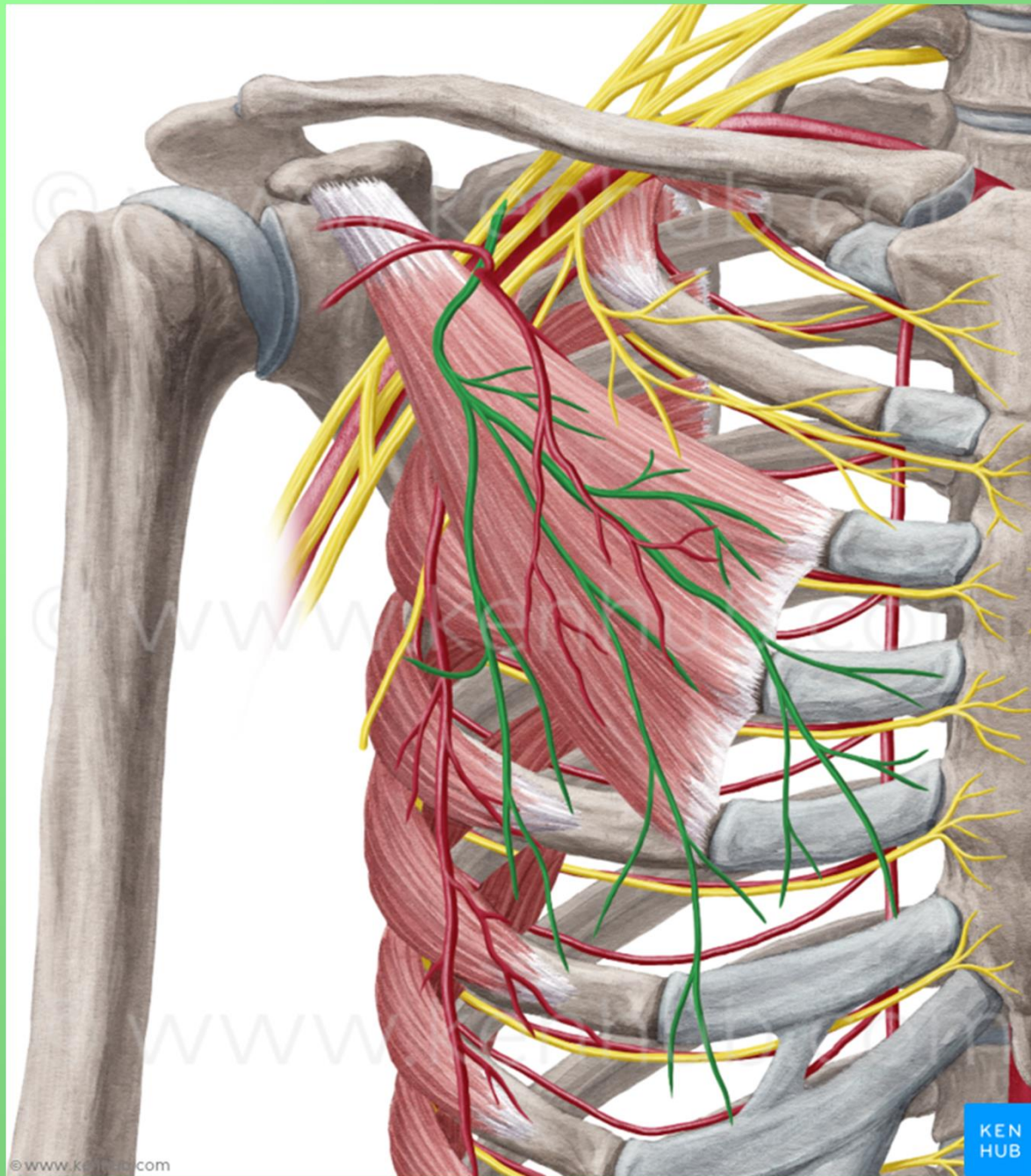
# nervus pectoralis lateralis C5-7

- m. pectoralis major et minor










© www.kenhub.com

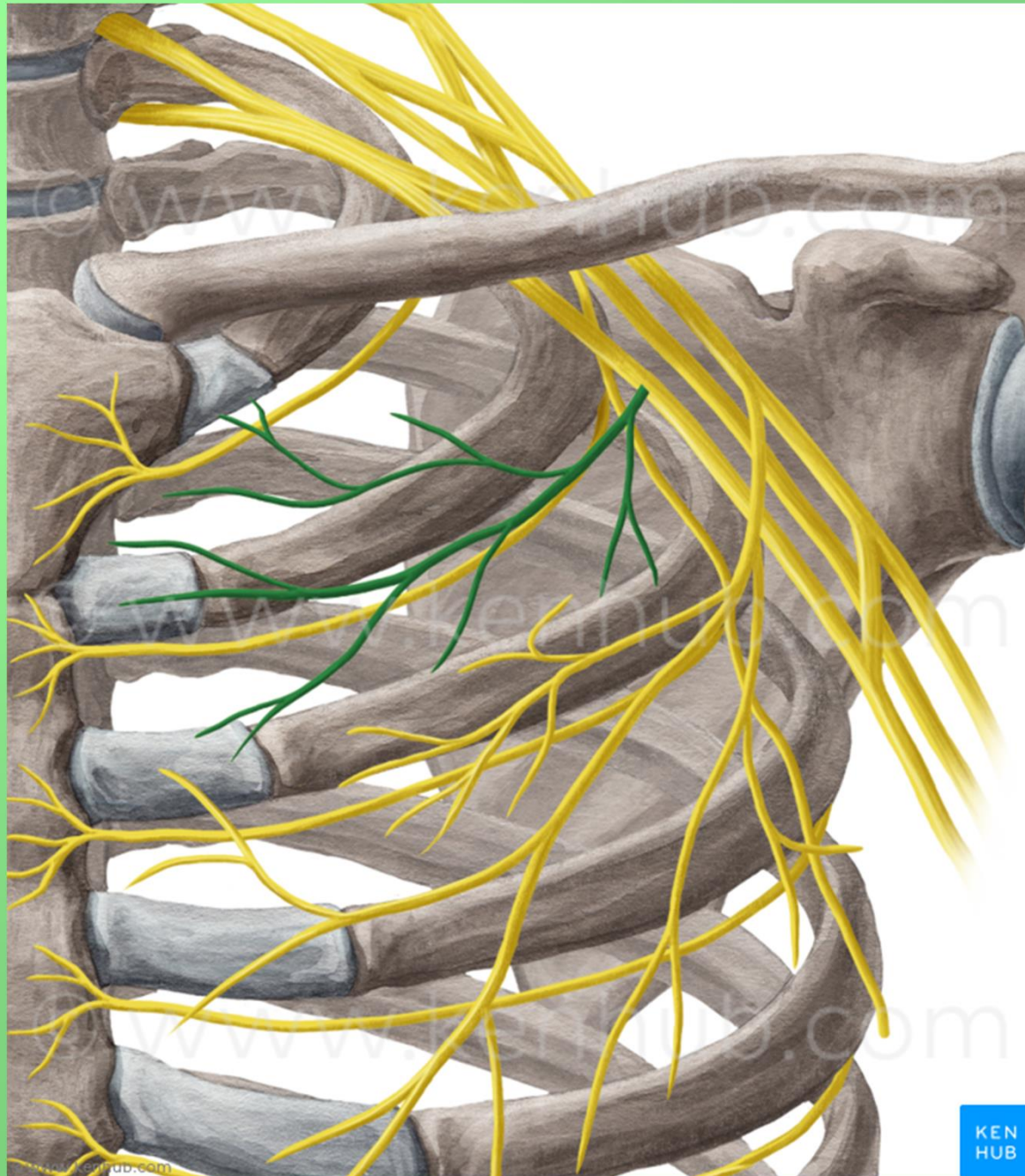
KEN  
HUB



# nervus pectoralis medialis C8-Th1

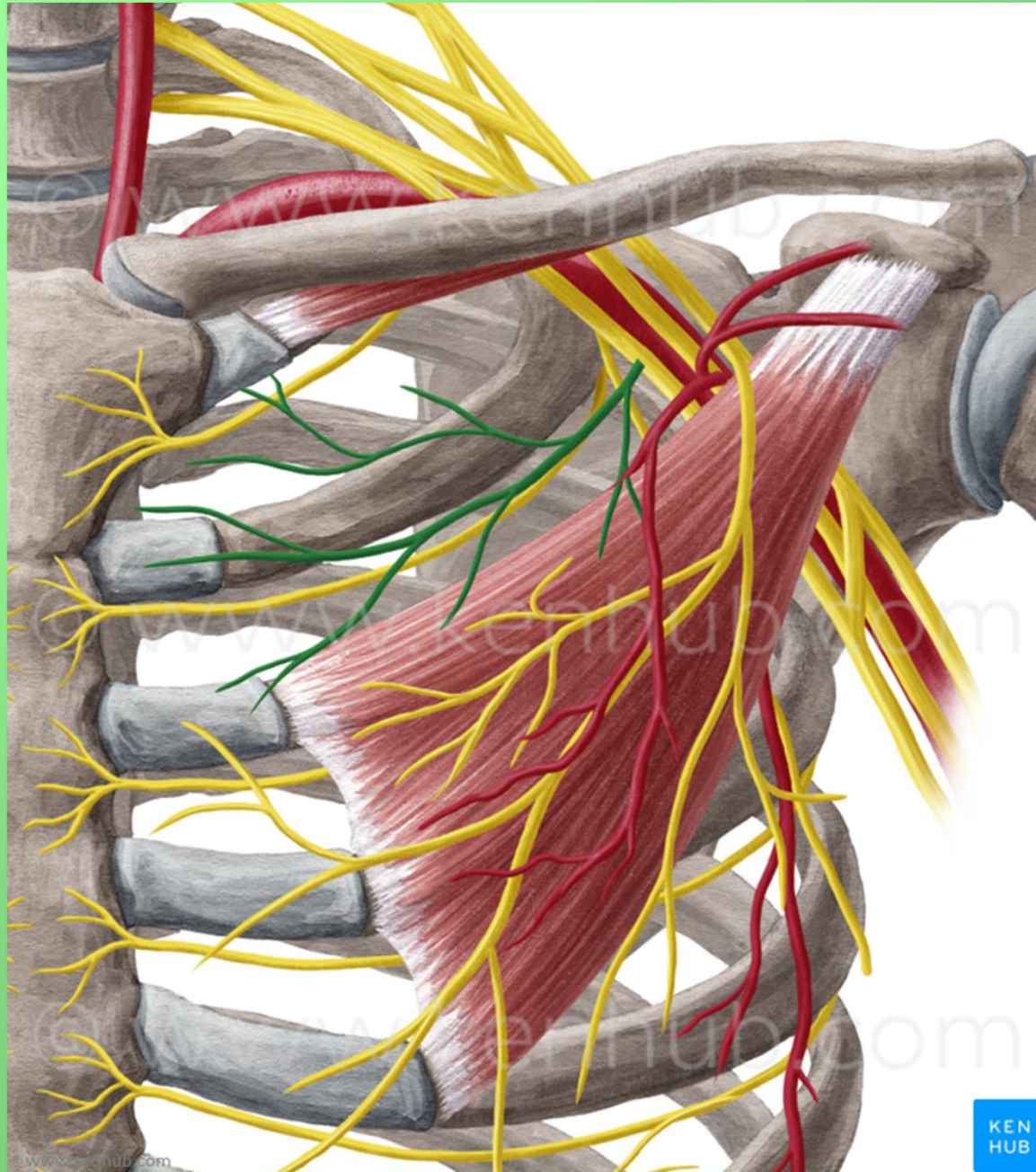
- m. pectoralis major et minor





KEN  
HUB



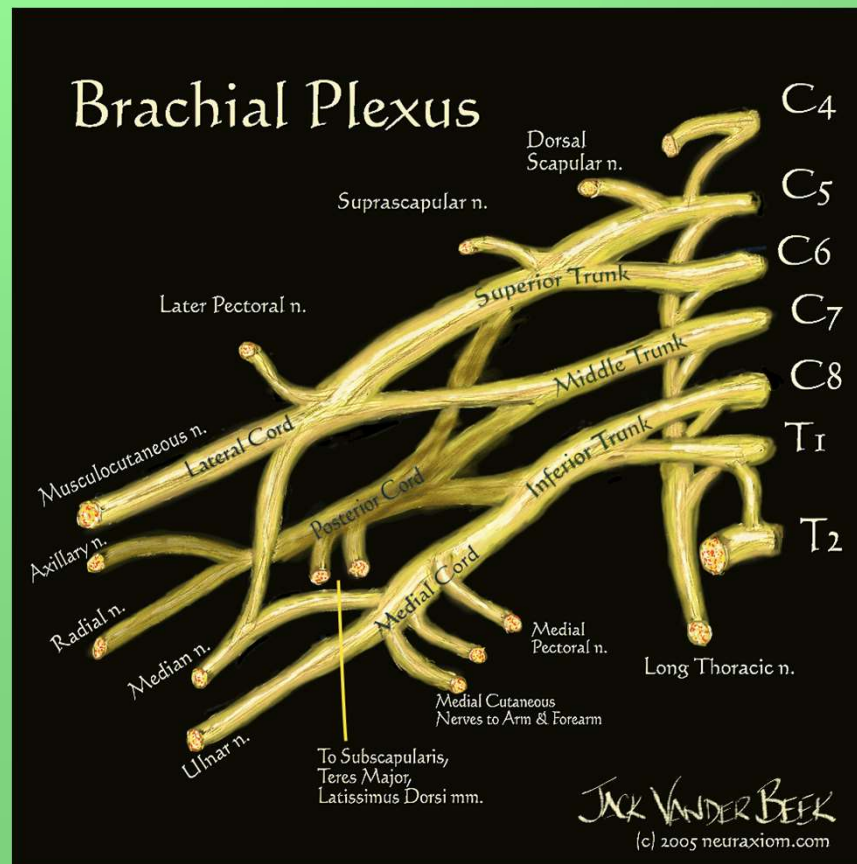


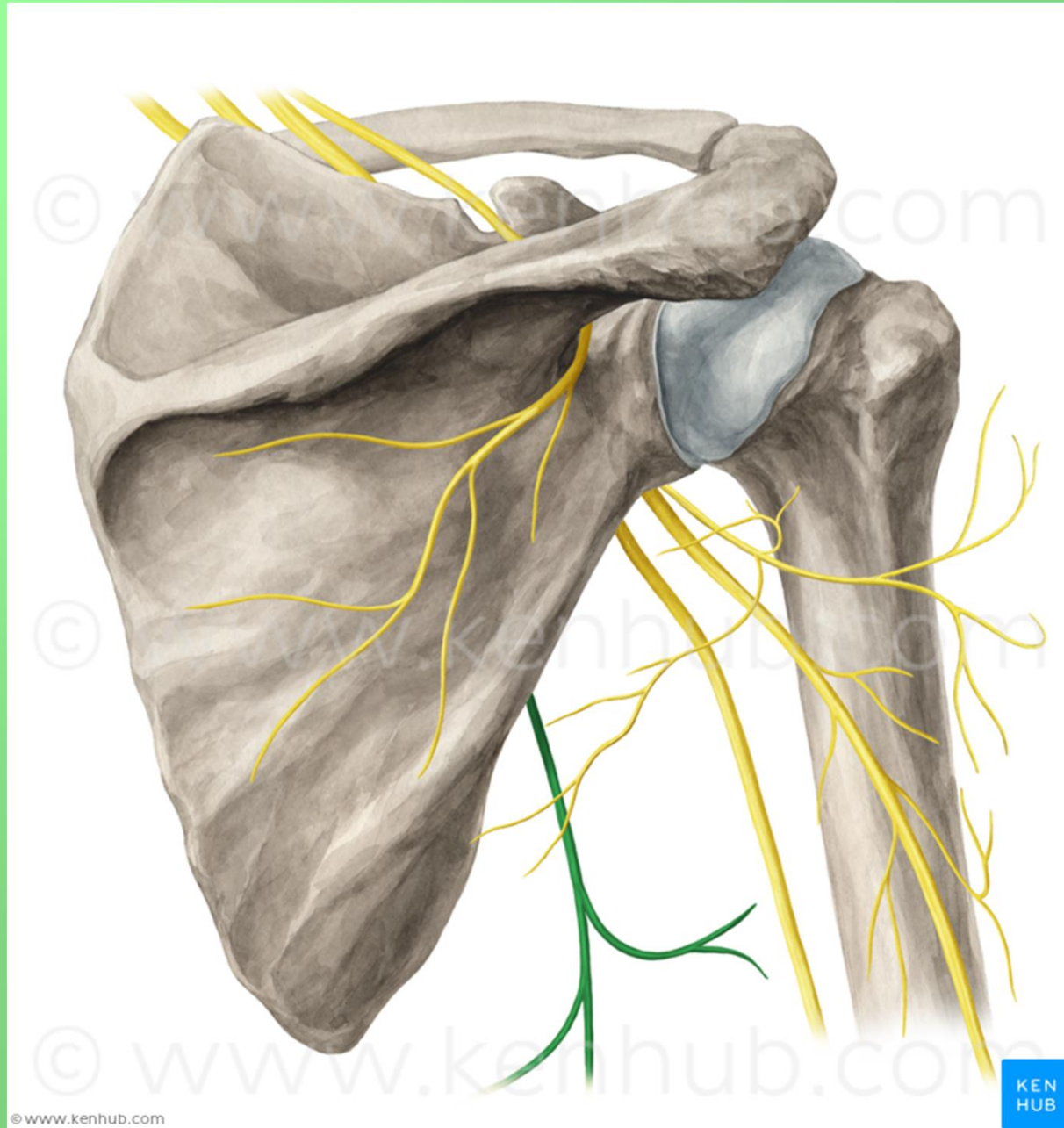
KEN  
HUB



# nervus thoracodorsalis C6-8

- m. latissimus dorsi

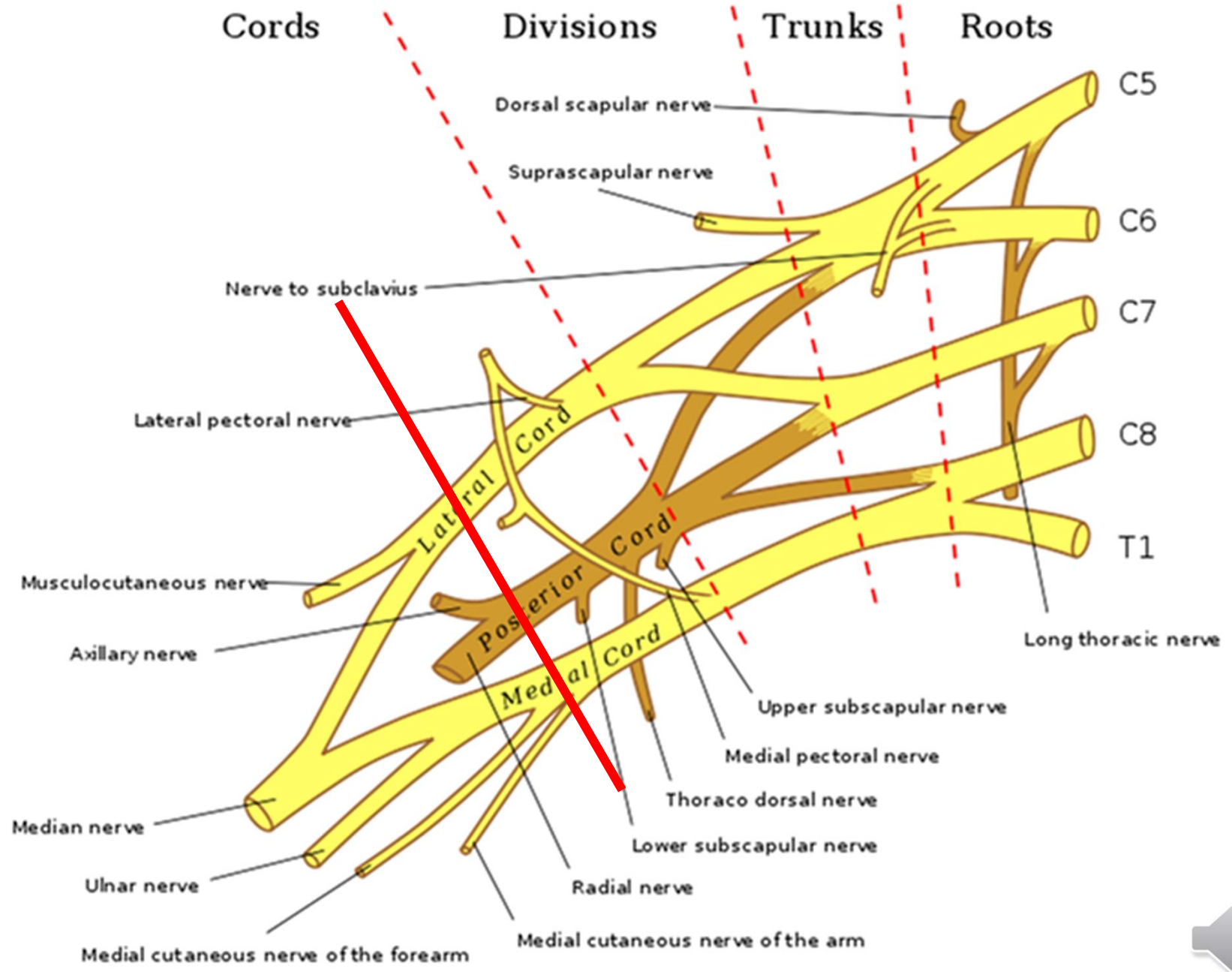




© www.kenhub.com

KEN  
HUB

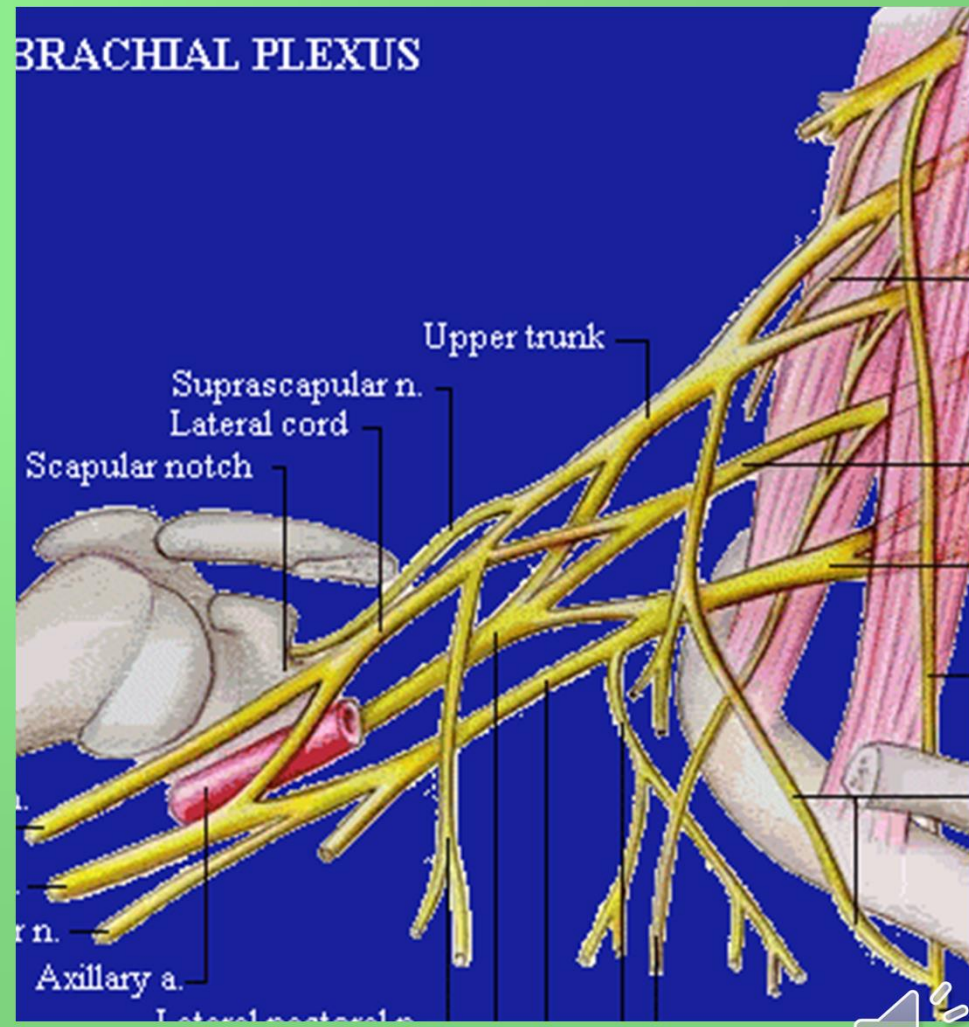


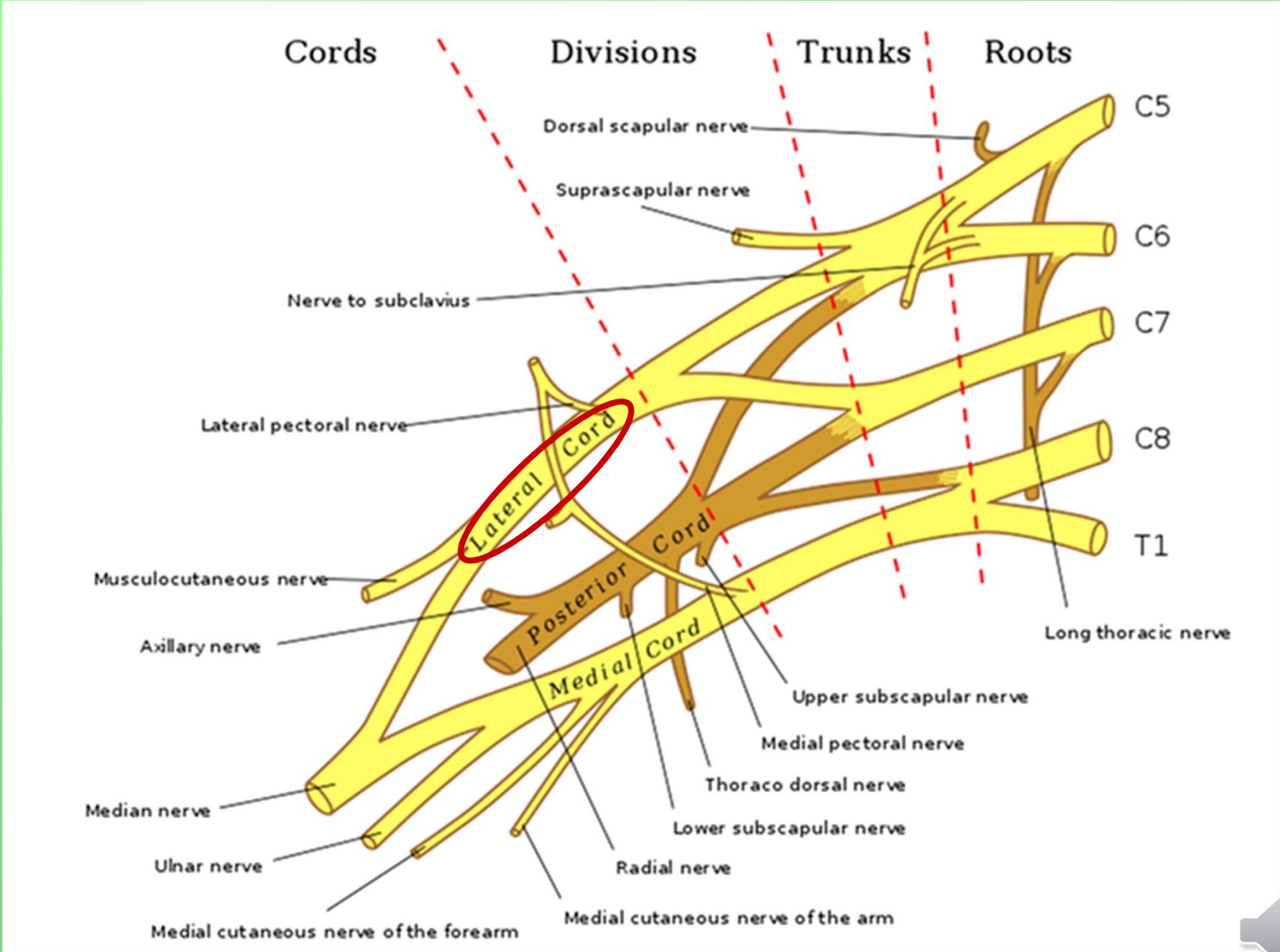




# Pars infraclavicularis plexus brachialis

- fasciculus lateralis
- fasciculus medialis
- fasciculus posterior





## Fasciculus lateralis

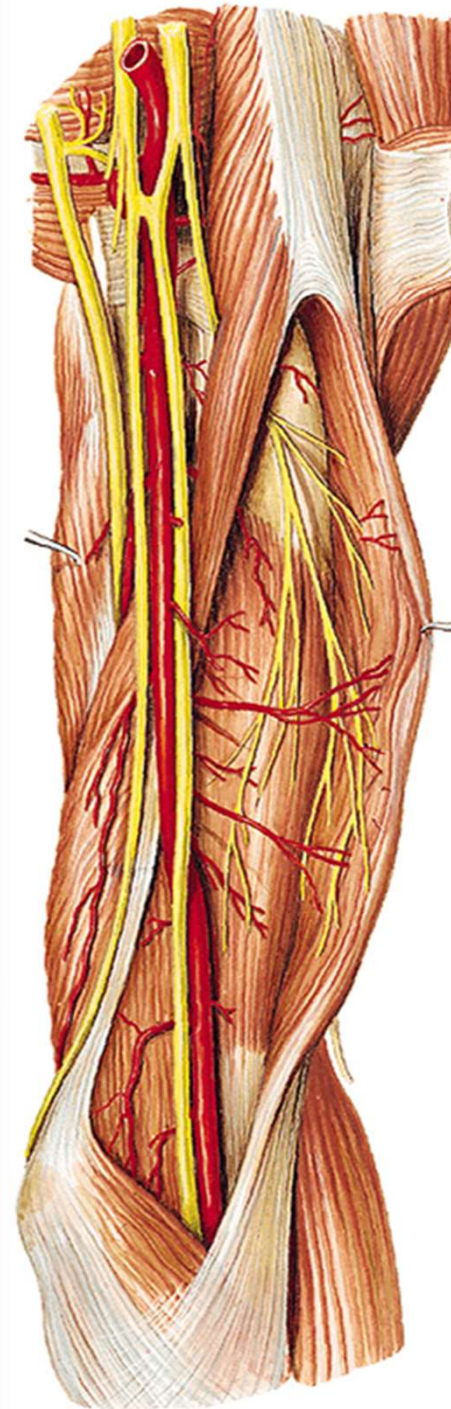
### n. musculocutaneus

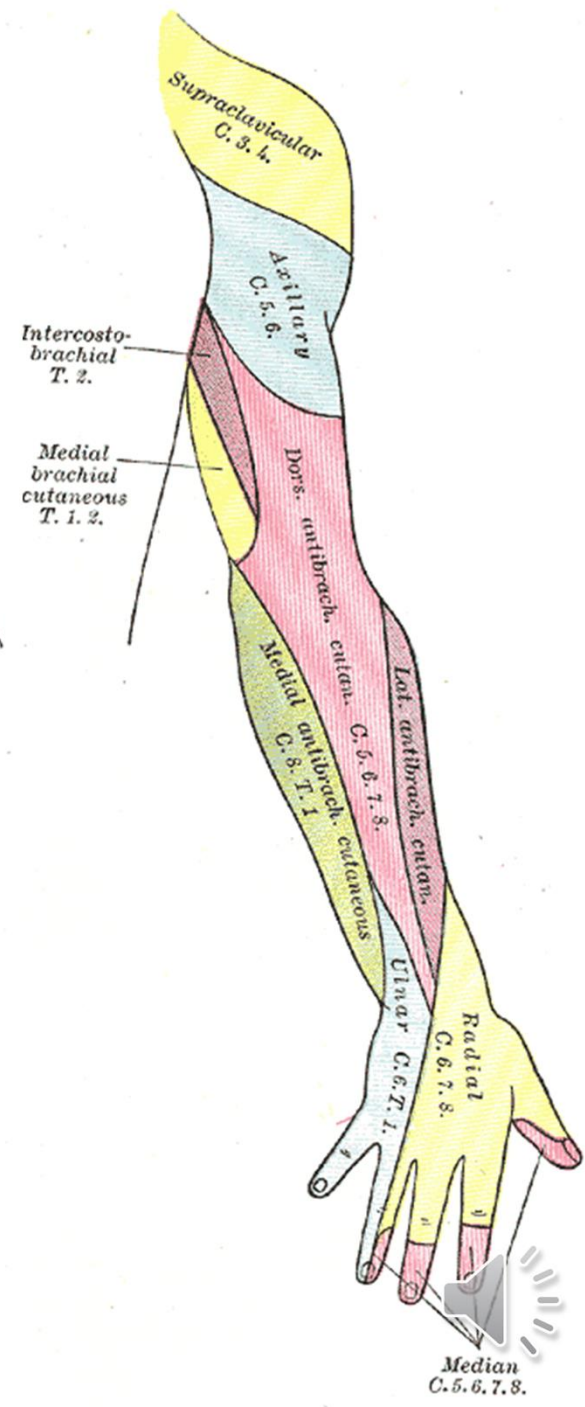
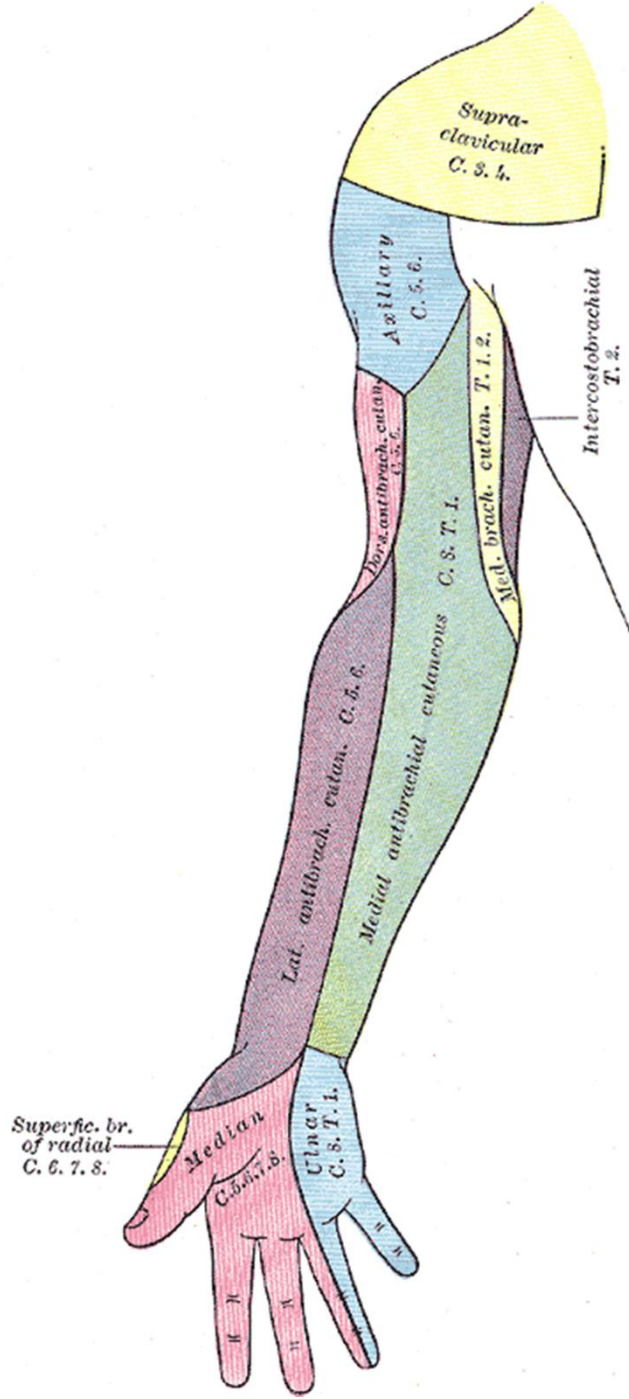
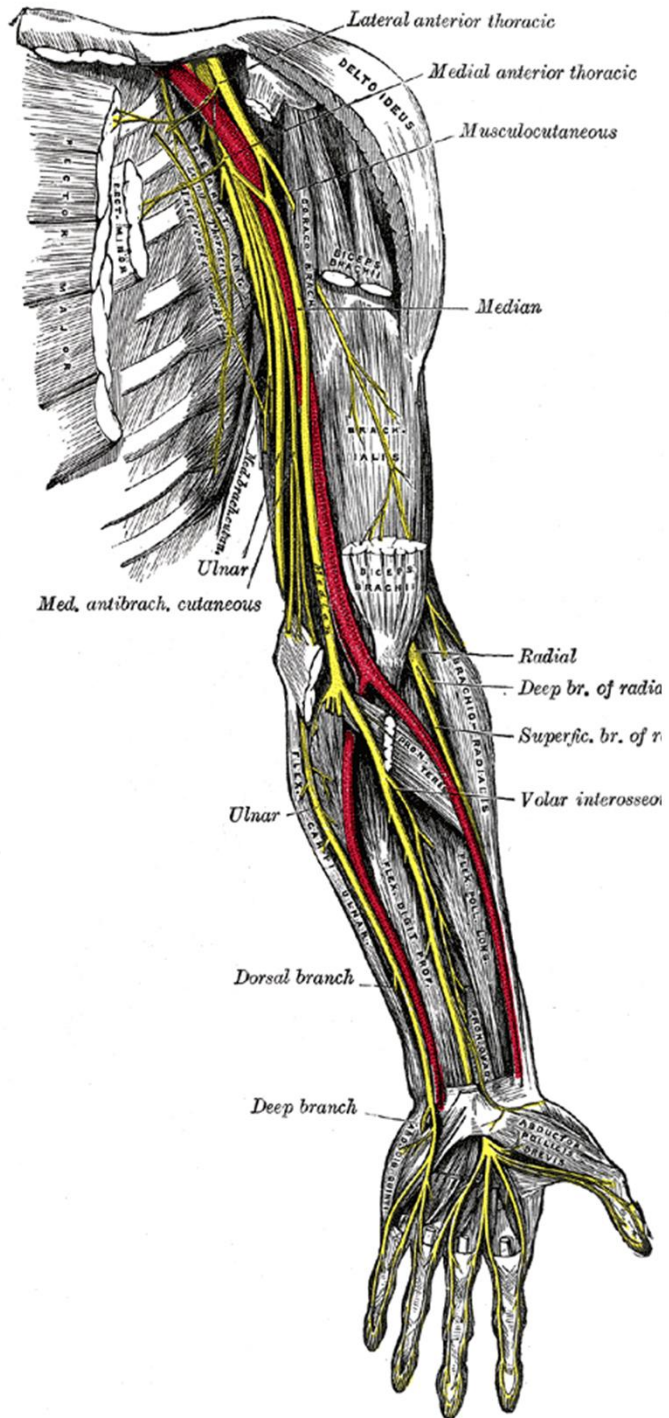
(smíšený) (C5-7)

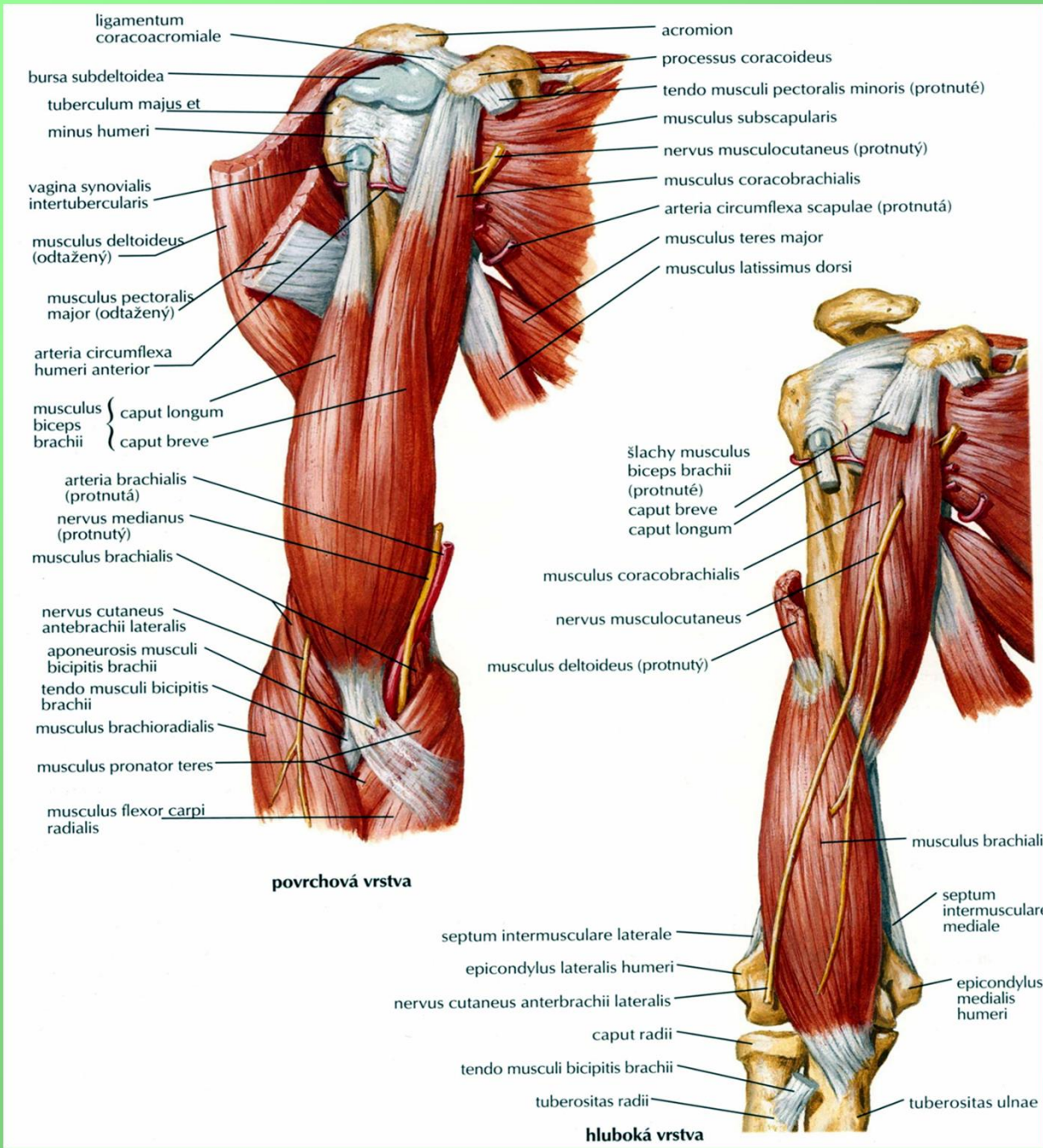
rr. musculares (m. coracobrachialis,  
m. biceps brachii, m. brachialis)

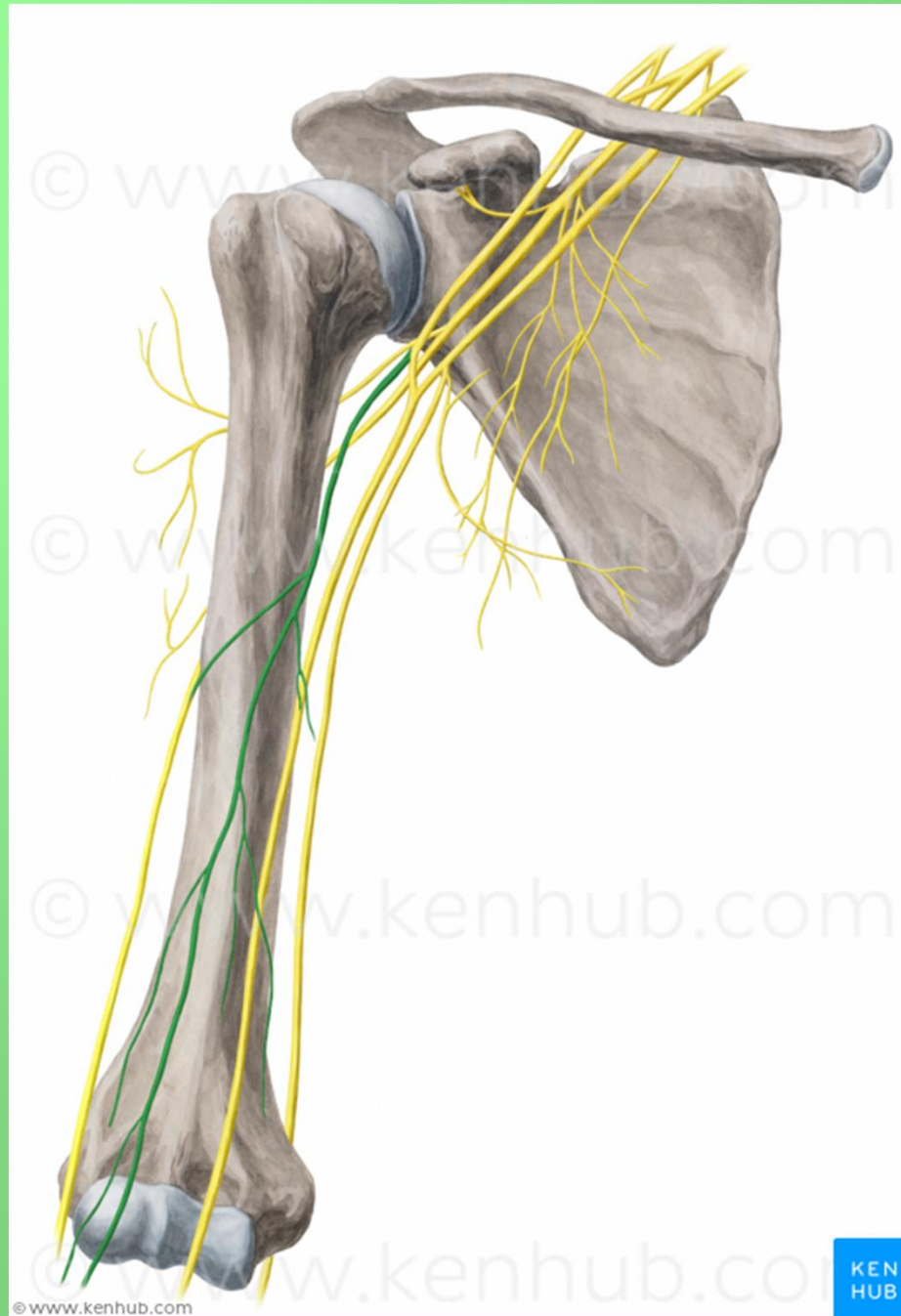
n. cutaneus antebrachii lateralis  
vulnerabilní místo - fossa cubiti

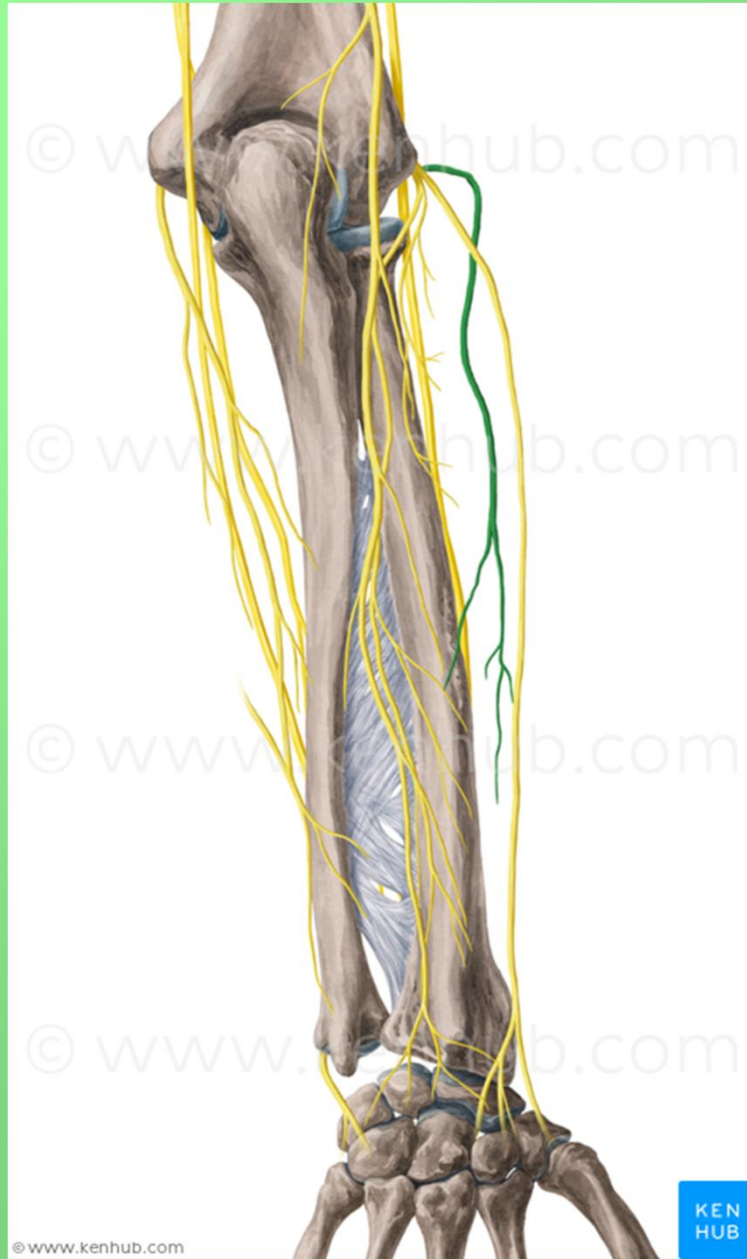
### radix lateralis n. mediani

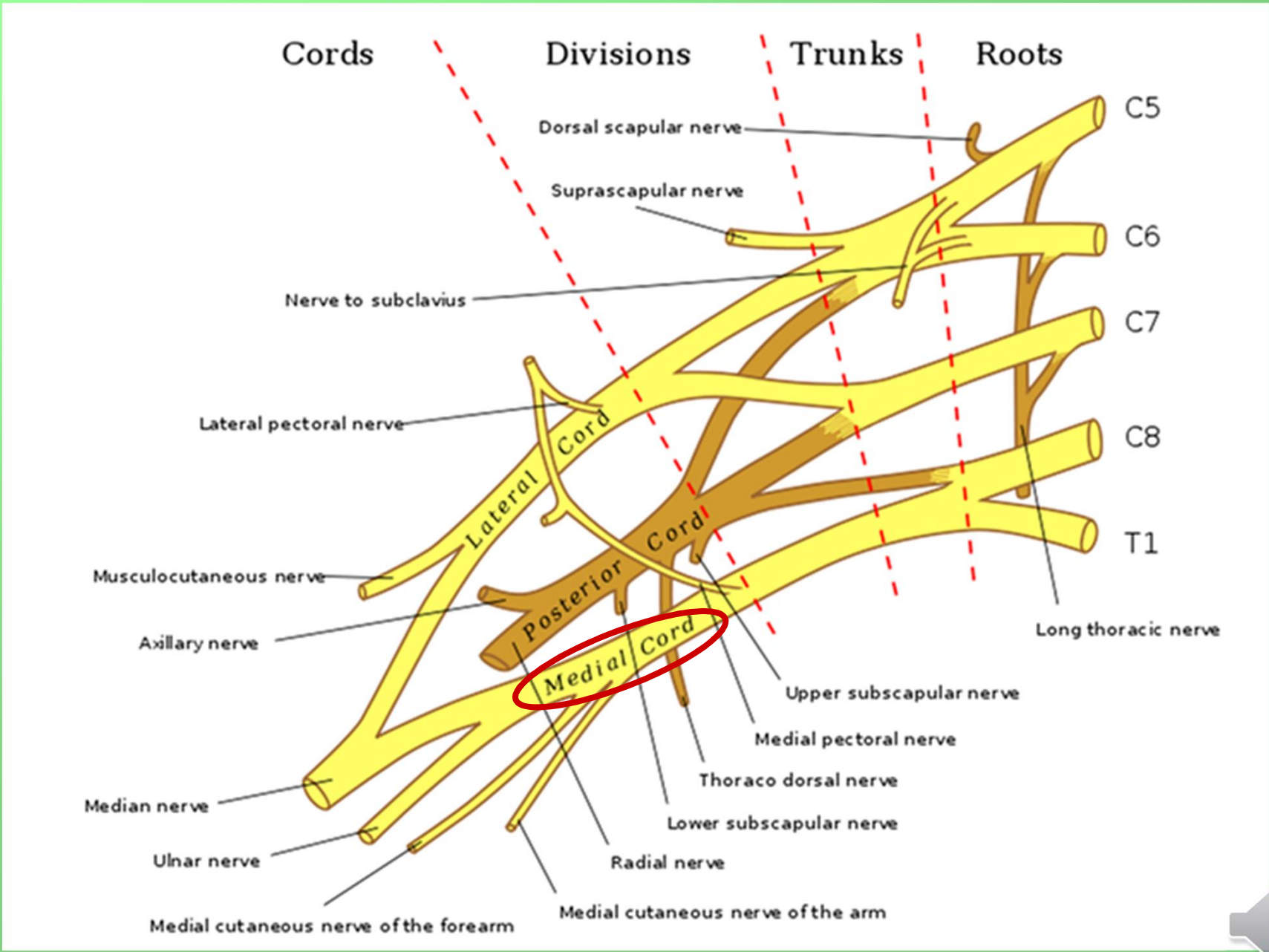














# Fasciculus medialis

## radix medialis n. mediani

### n. cutaneus brachii medialis (C8–Th1)

- spojky s nn. intercostales II., (III.) – nn. intercostobrachiales

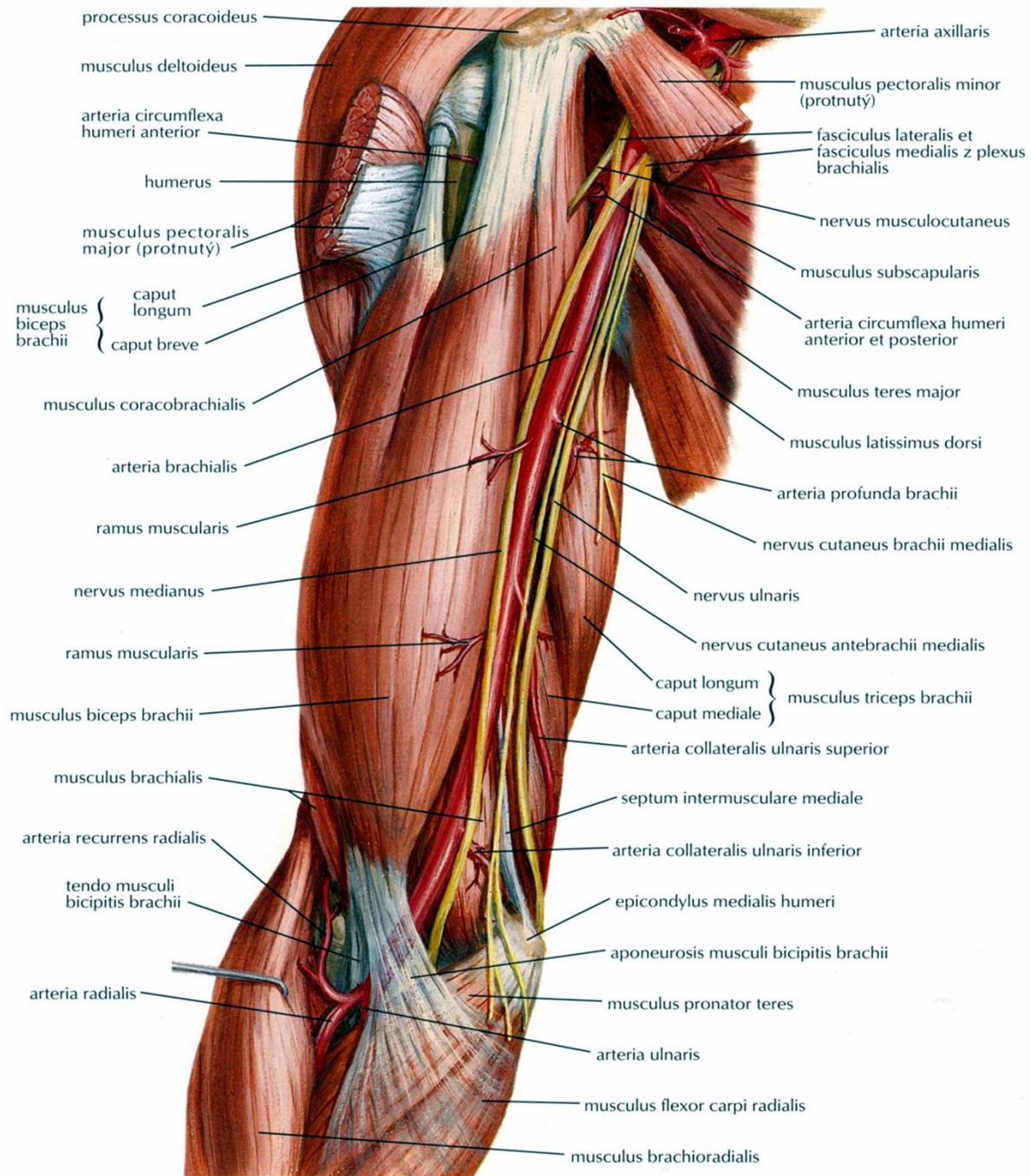
### n. cutaneus antebrachii medialis (C8–Th1)

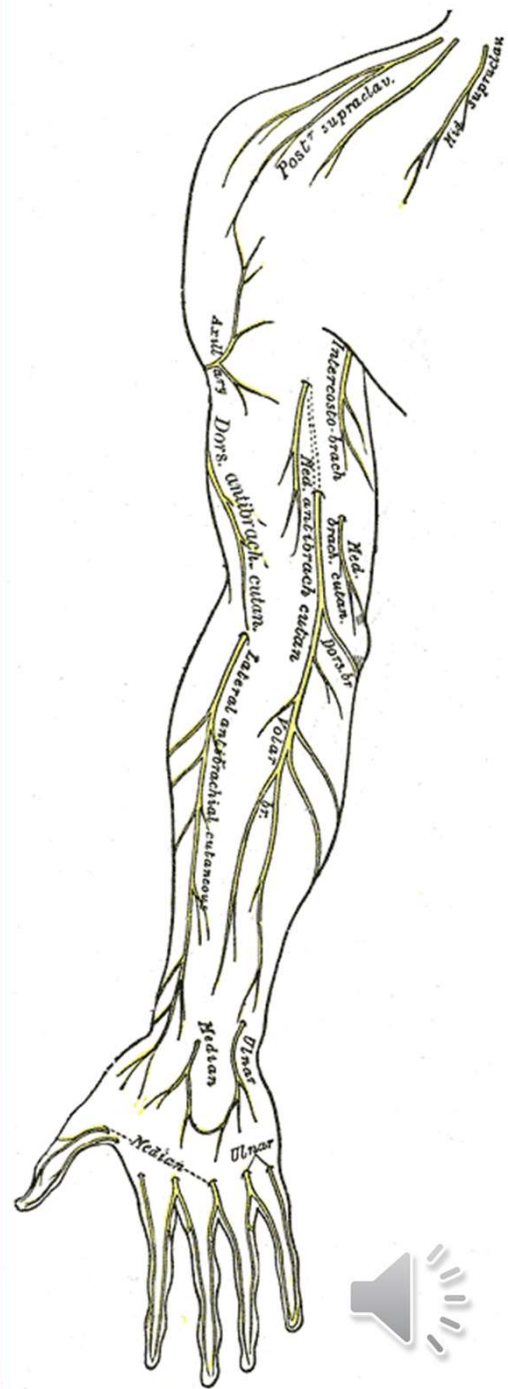
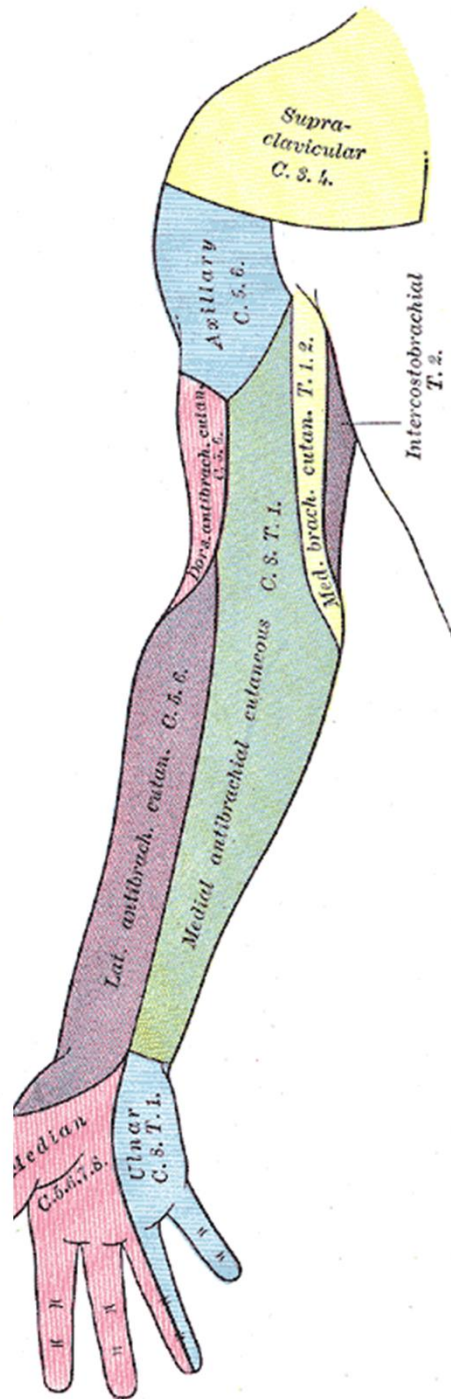
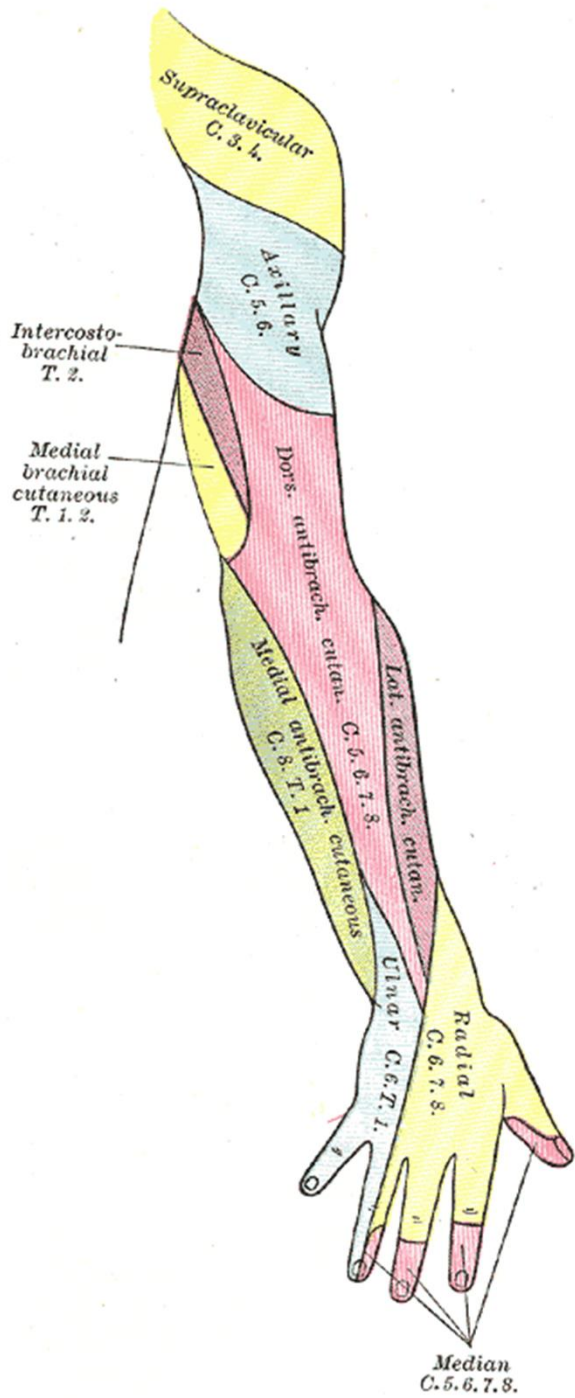
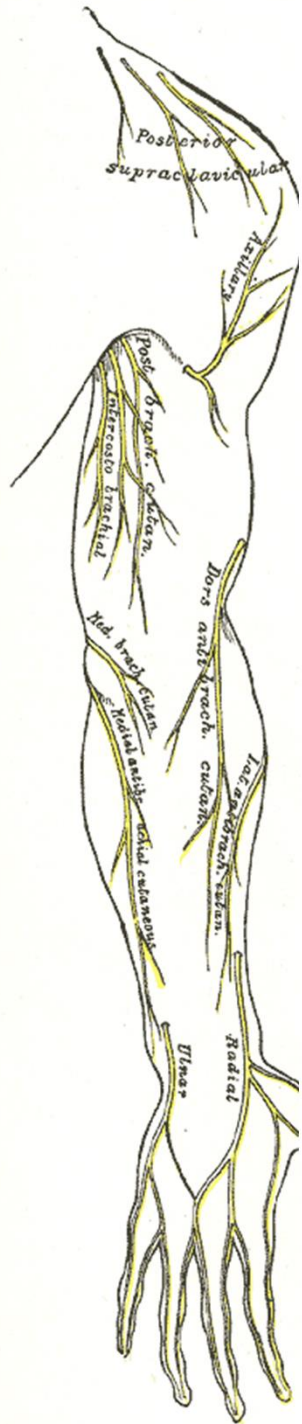
(skrže hiatus basilicus do podkoží a jde distálně po předloktí)

r. anterior et r. ulnaris

## n. ulnaris







© www.kenhub.com

© www.kenhub.com

© www.kenhub.com

© www.kenhub.com

© www.kenhub.com

KEN  
HUB



## n. ulnaris - (smíšený) (C8–Th1)

- po paži mediálně od n. medianus, sulcus nervi ulnaris, mezi m. flexor carpi ulnaris a m. flexor digitorum profundus s a. ulnaris a do dlaně na povrchu retinaculum flexorum

- **rr. articulares**

- **rr. musculares**

- **r. dorsalis n. ulnari**

  - nn. digitales dorsales

- **r. palmaris n. ulnaris**

Kmen n. ulnaris se v dlaní větví na:

- **r. superficialis**

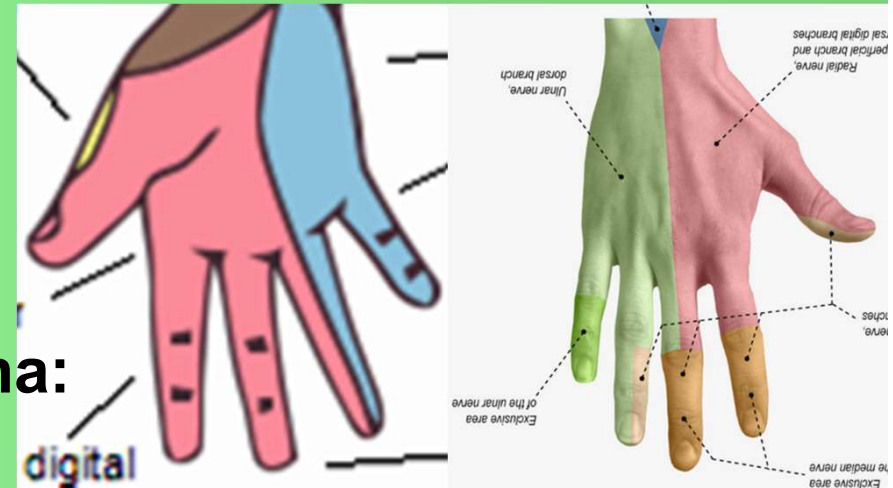
  - r. muscularis (m. palmaris brevis)

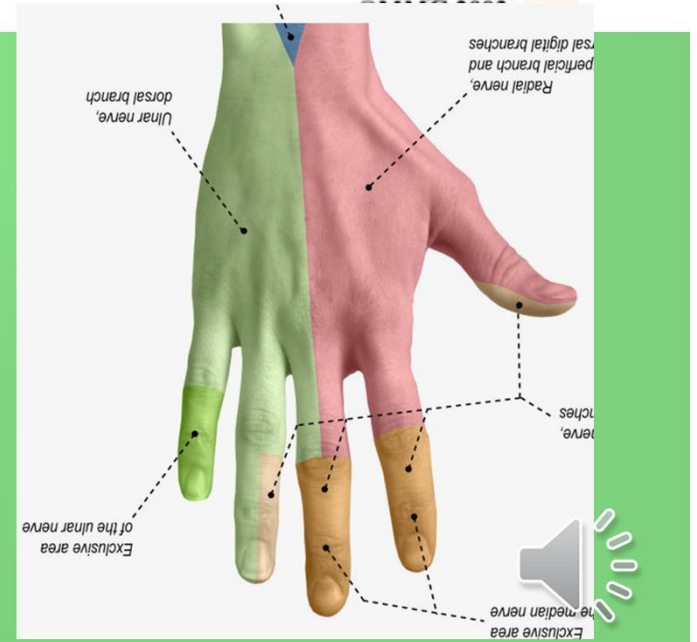
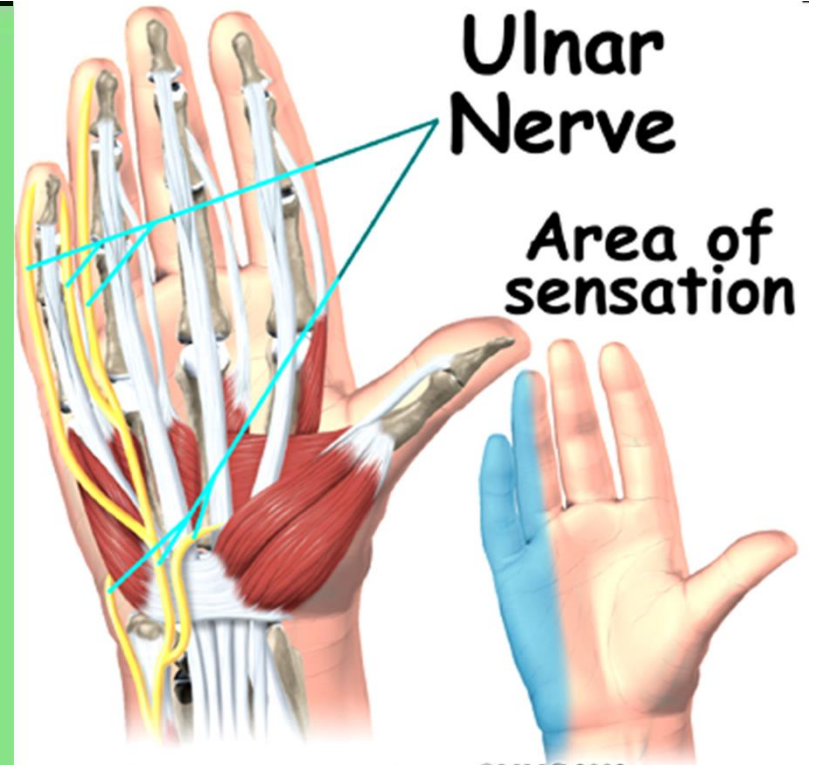
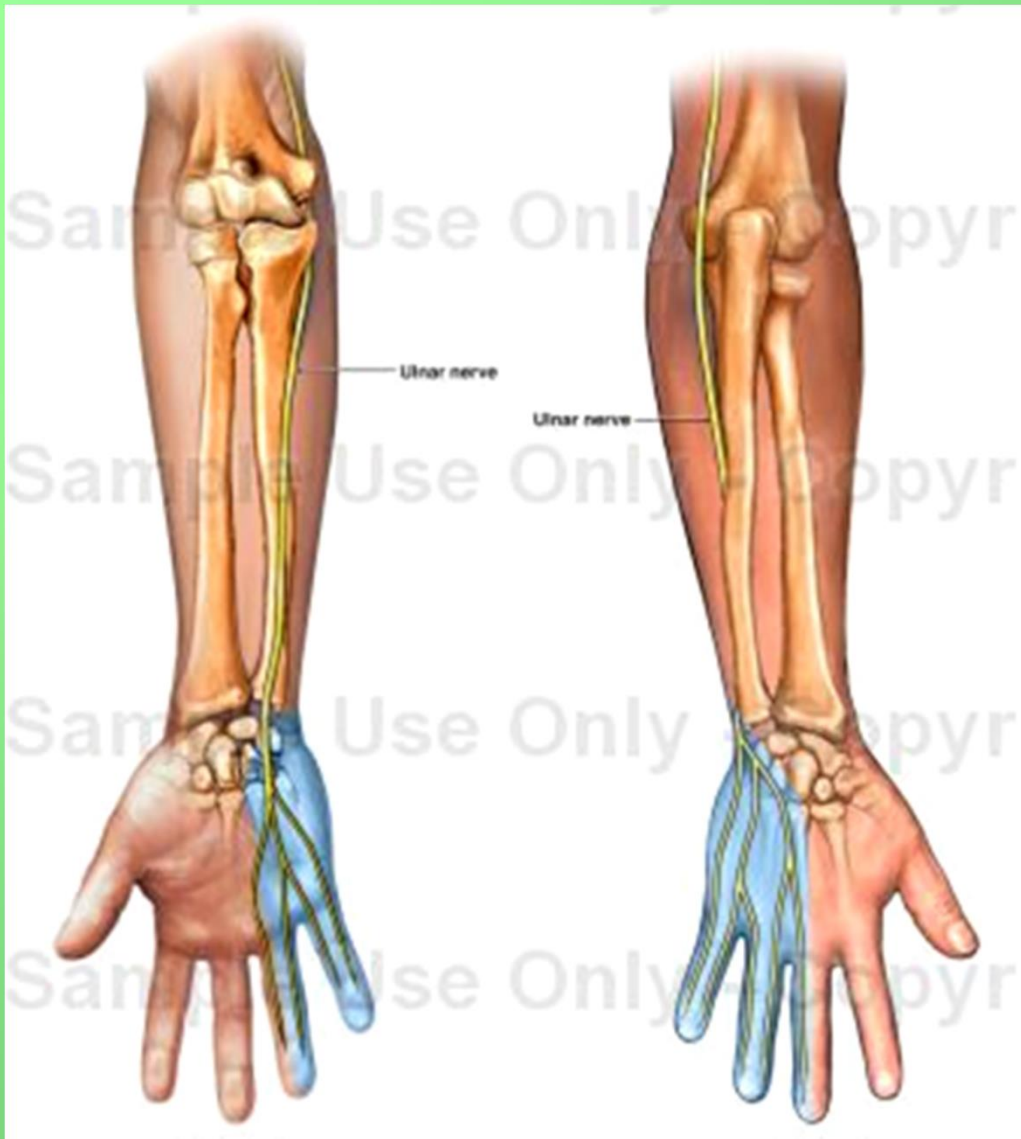
  - 2 nn. digitales palmares communes et proprii

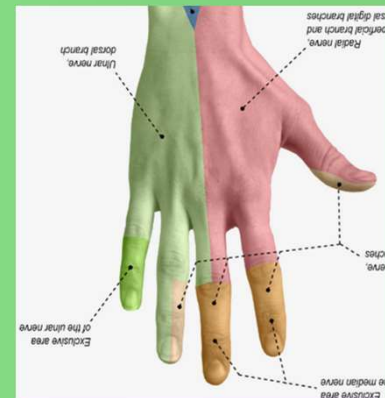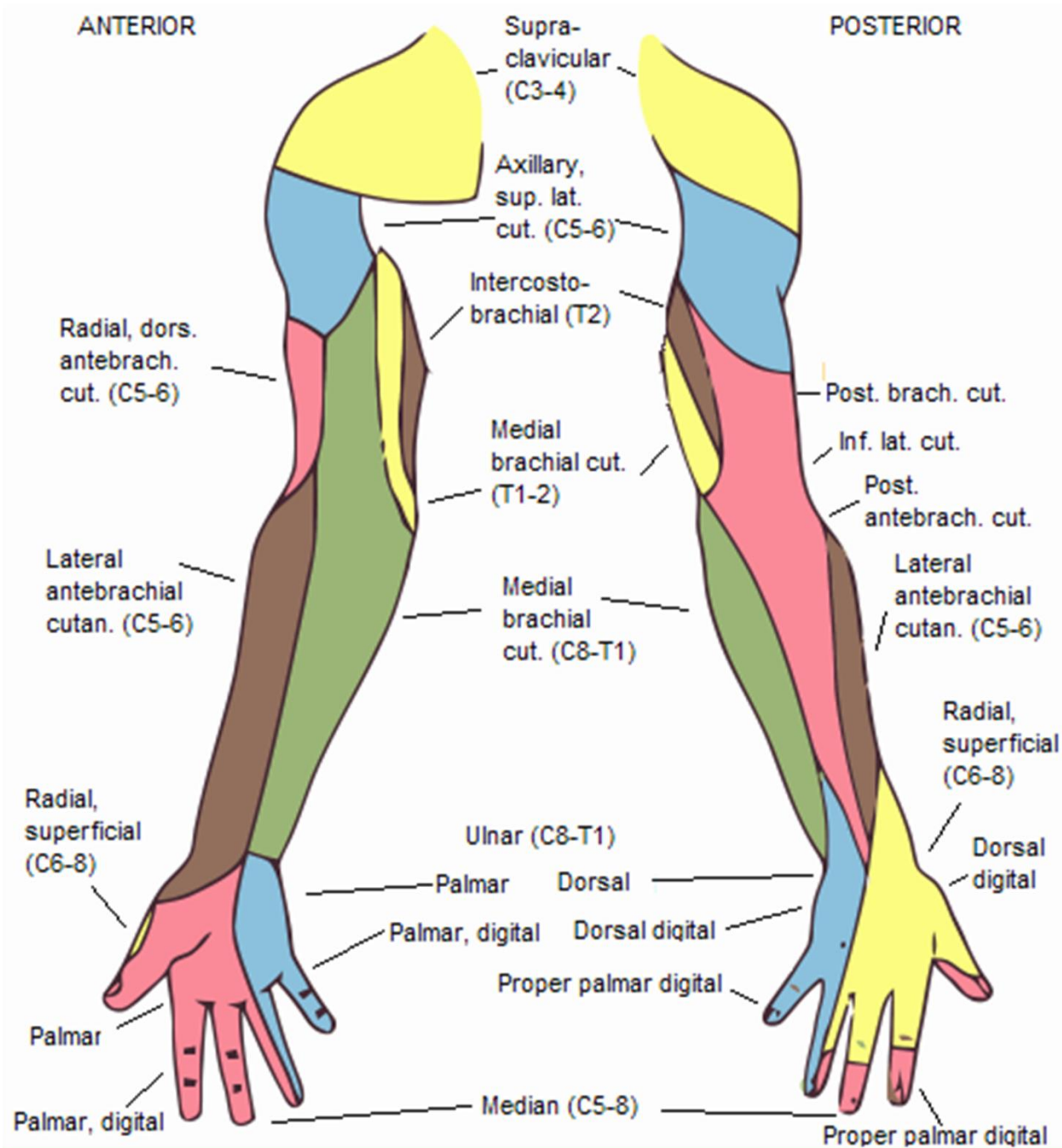
- **r. profundus** - rr. musculares

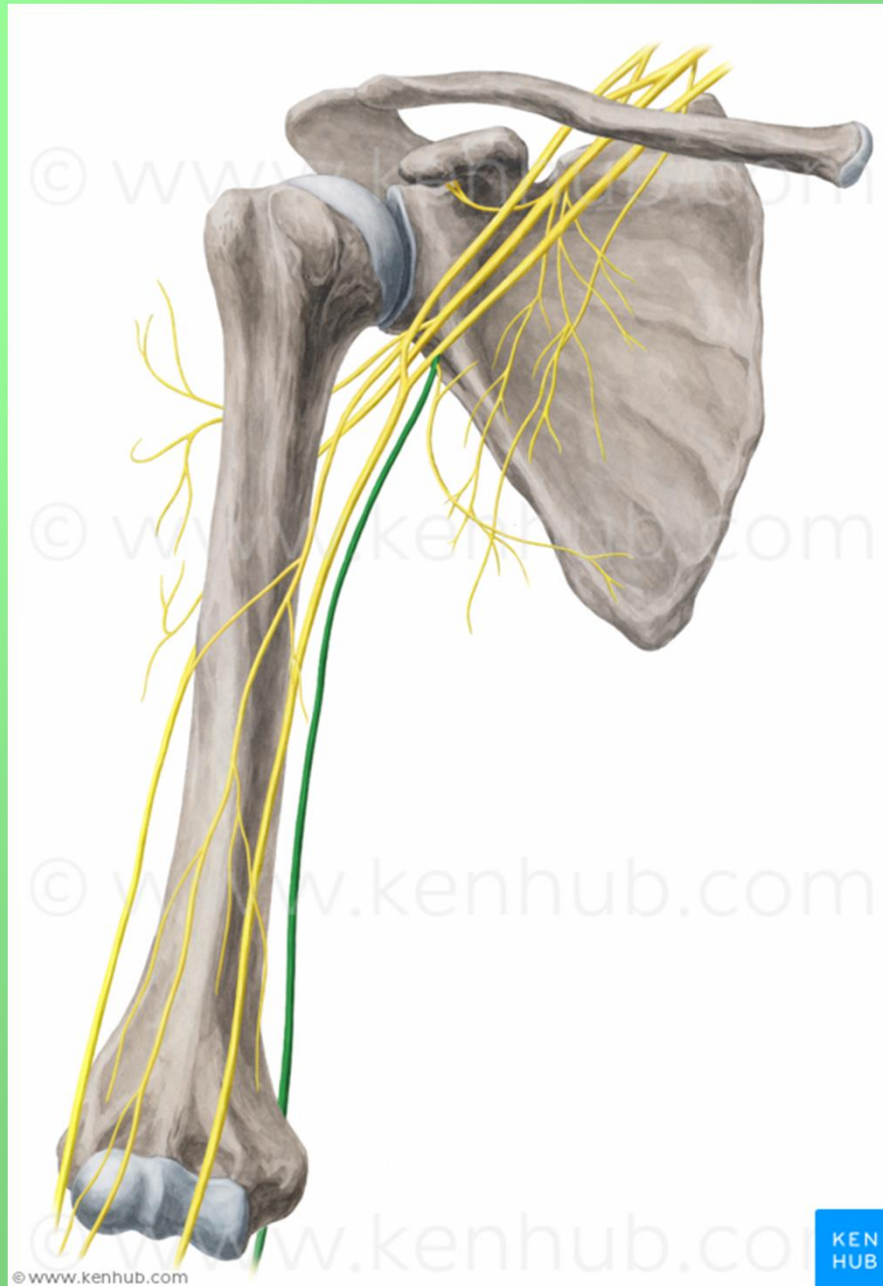
**Motoricky:** m. flexor carpi ulnaris, m. flexor digitorum profundus (4. a 5. prst), svaly hypothenaru, m. adductor pollicis a m. flexor pollicis brevis (caput profundum), mm. interossei, mm. lumbricales (III. a IV.)

**Senzoricky:** palmárně: 5. a polovinu 4. prstu  
dorsálně: 5., 4., a polovinu 3. prstu





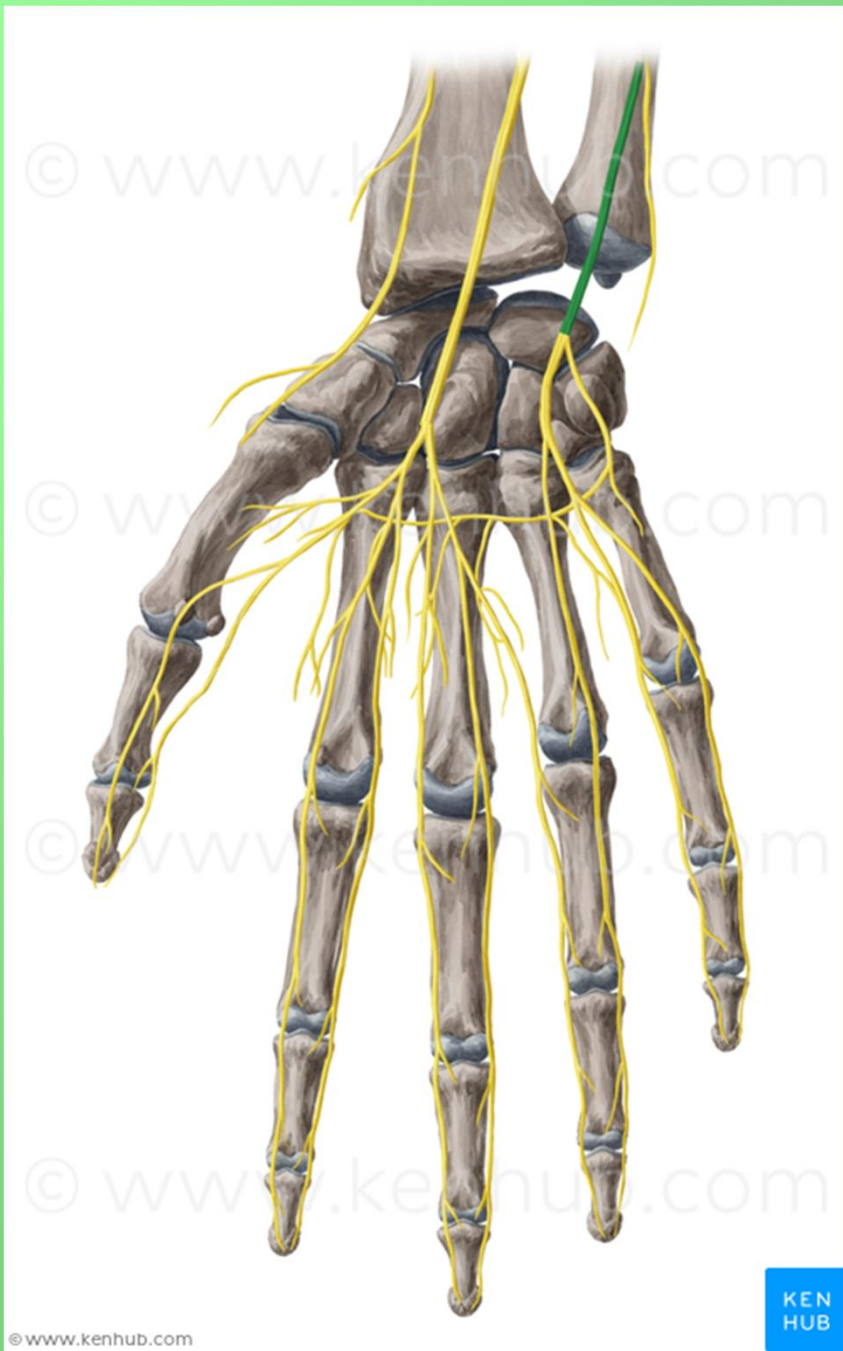




KEN  
HUB







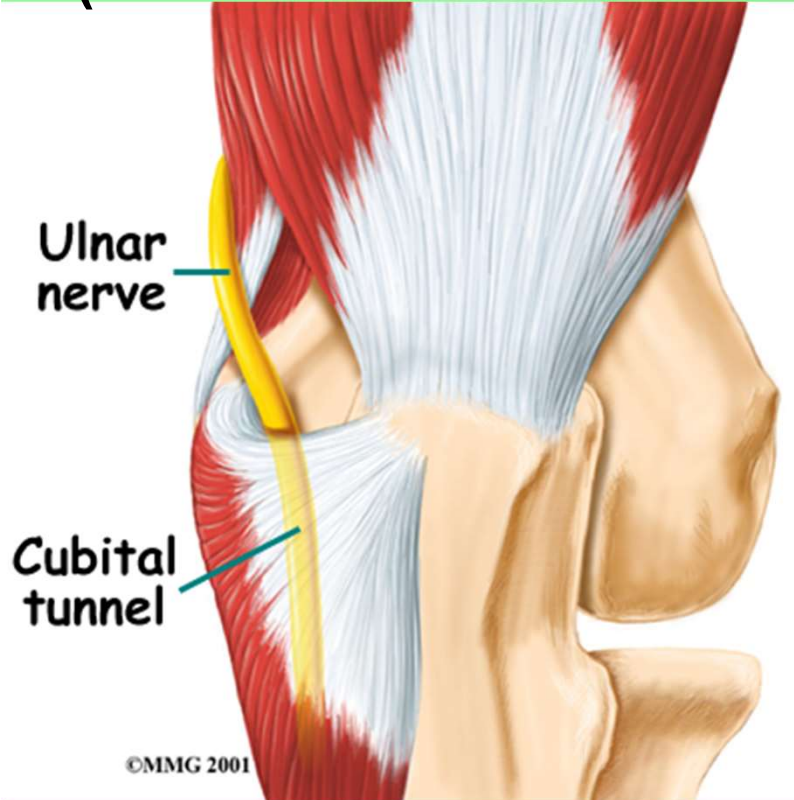
©www.kenhub.com

KEN  
HUB



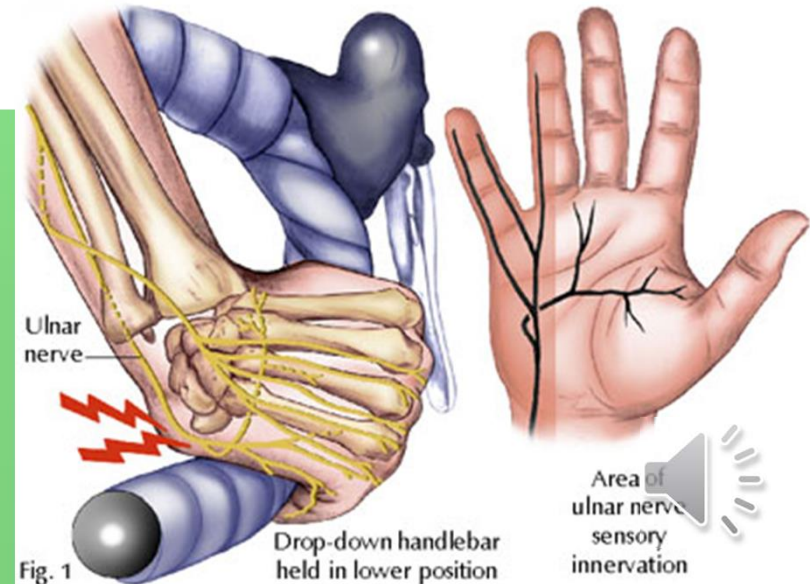
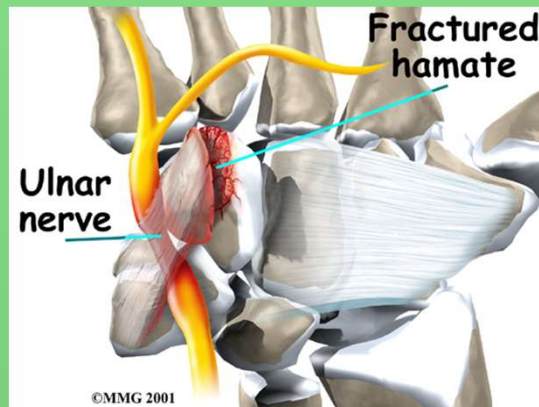
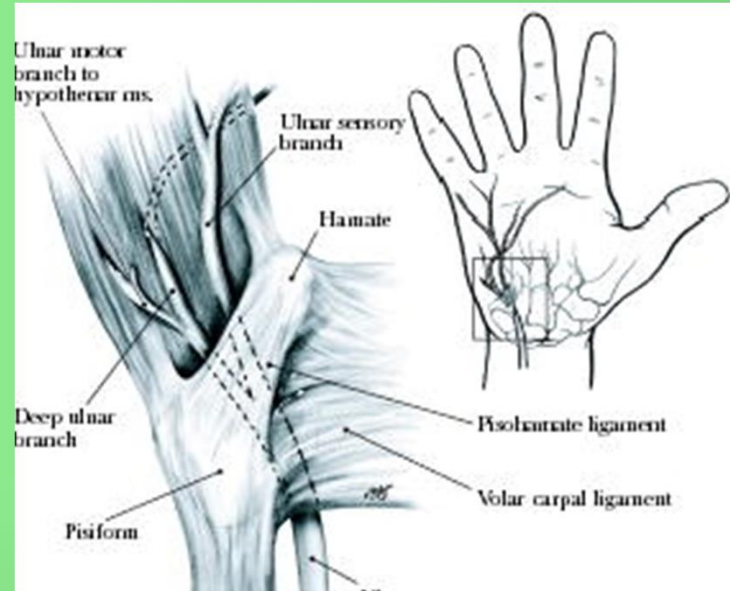
# Canalis cubitalis

-kubitální syndrom  
(léze v sulcus n. ulnaris)

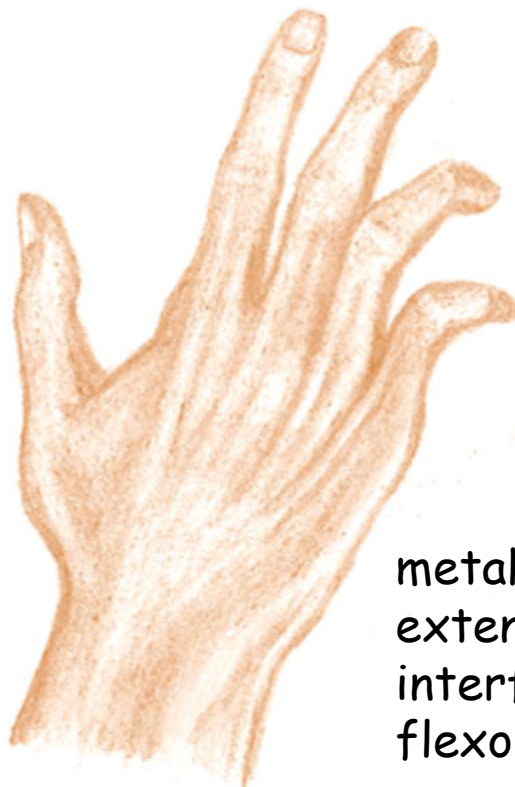
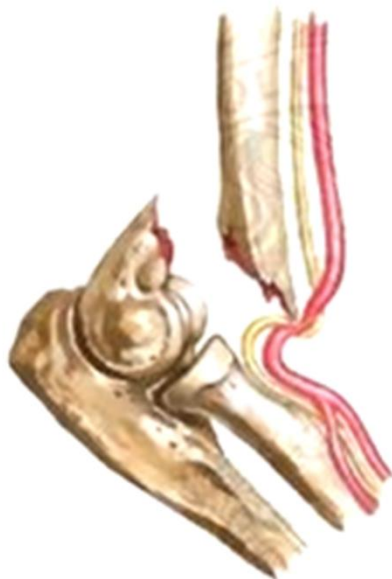
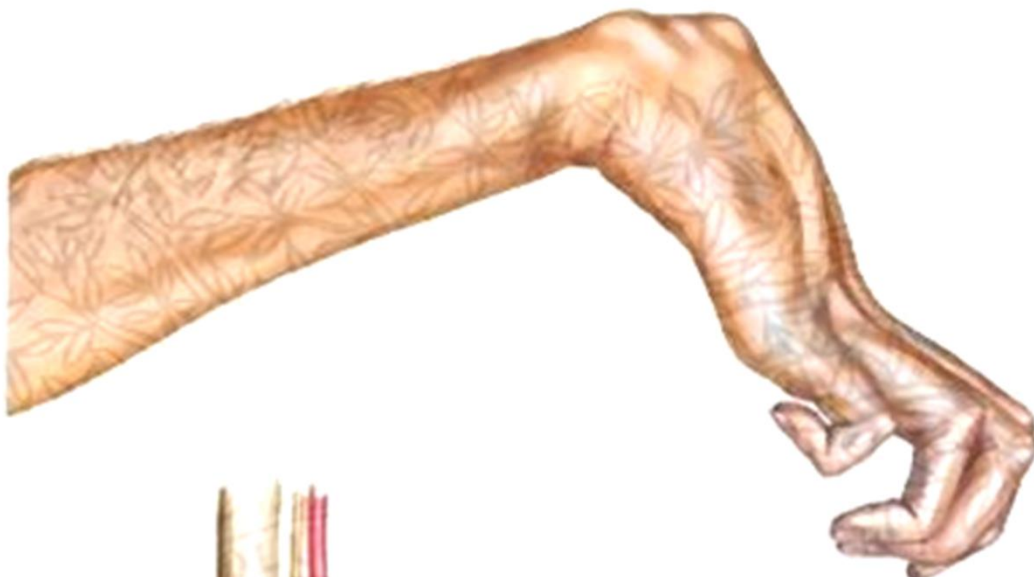# Guyonův kanálek

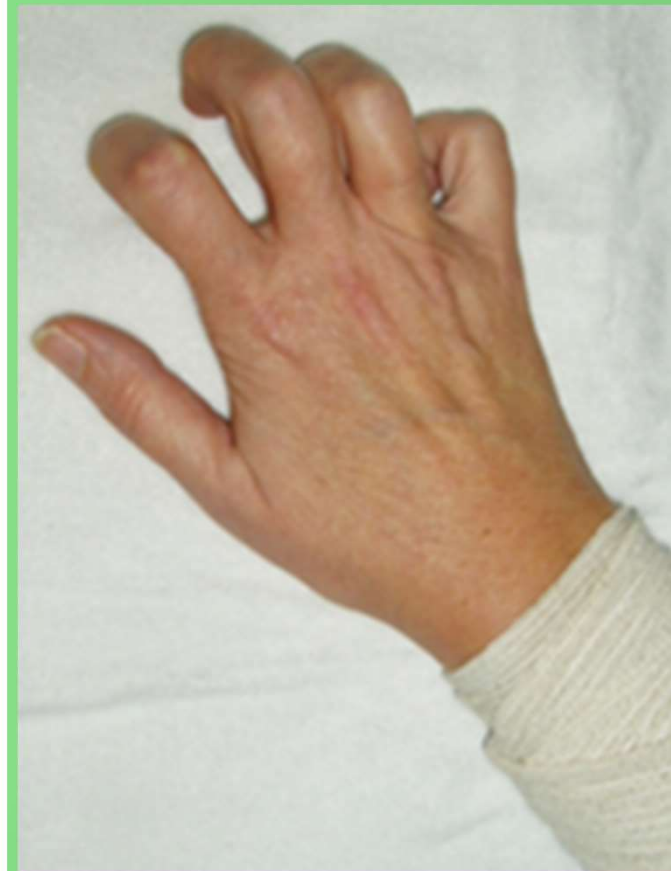(mezi os pisiforme a hamulus ossis hamati)



## Drápovitá ruka



metakarpofalangeální klouby  
extendovány (převaha extensorů),  
interfalangeální klouby ve flexi (převaha  
flexorů), palec abdukován.



## n. medianus

smíšený (C5–Th1) – *radix med.* (C8–Th1), *radix lat.* (C6-8)

podél a. brachialis, mezi m. pronator teres a flexor digitorum superficialis pak mezi hlubokým a povrchovým flexorem (do dlaně pod retinaculum flexorum)

- **rr. musculares, rr. articulares**
- **n. interosseus antebrachii anterior**
- **r. palmaris**

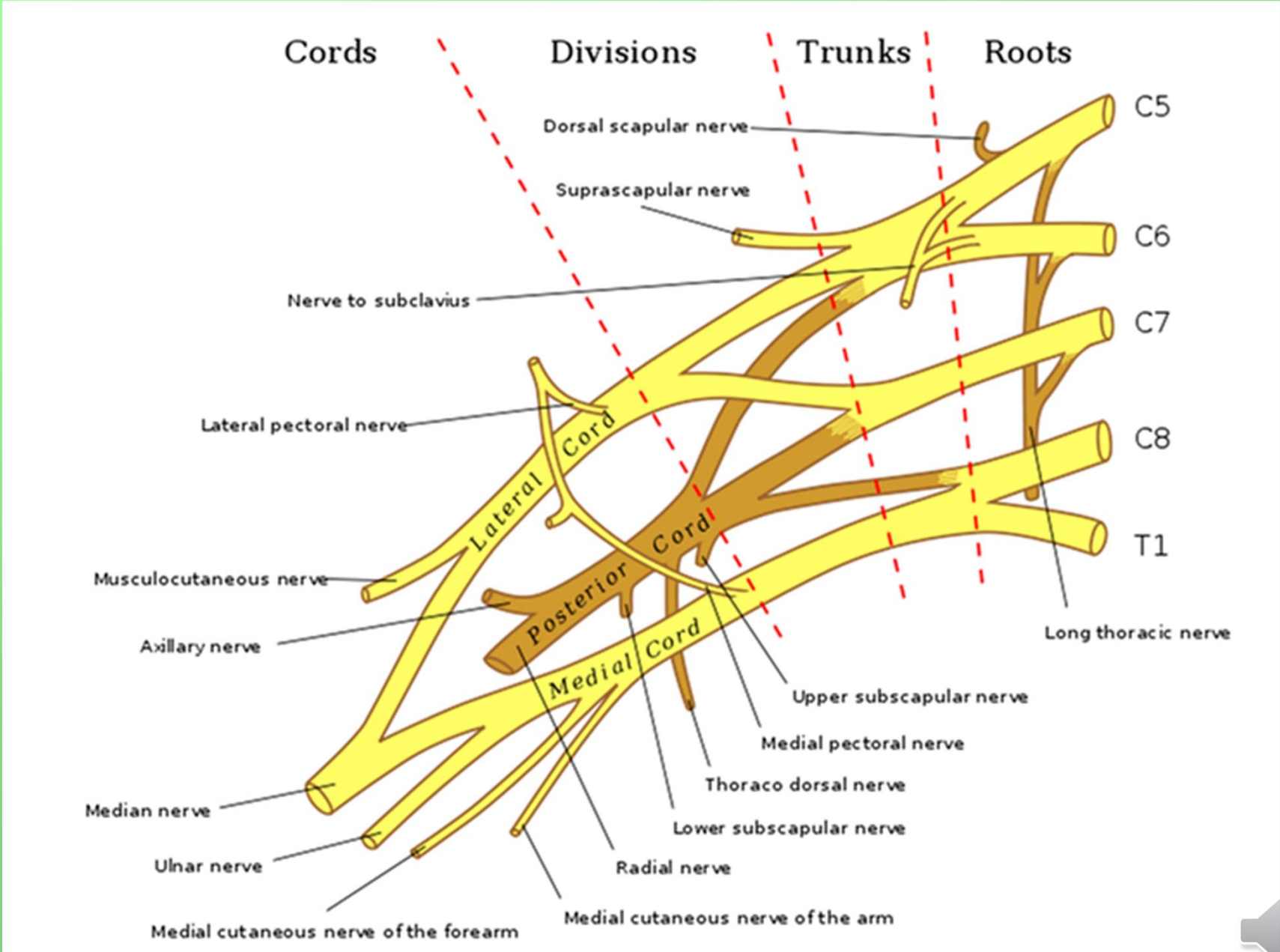
### V dlani:

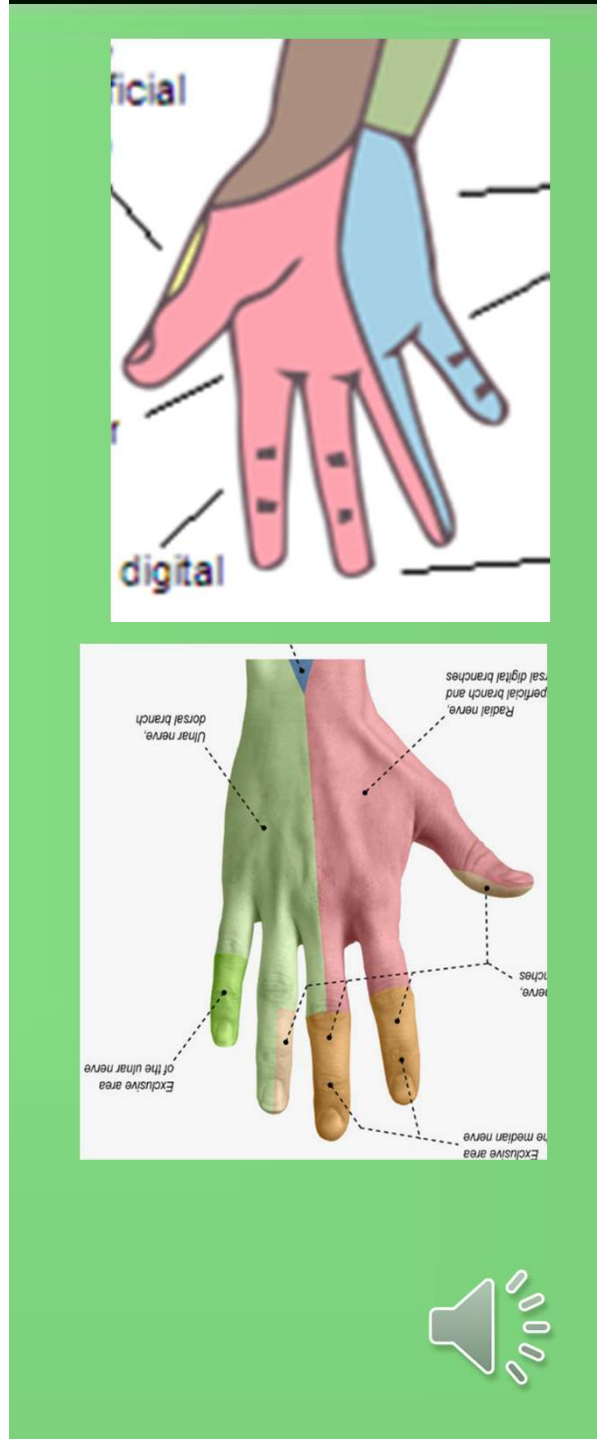
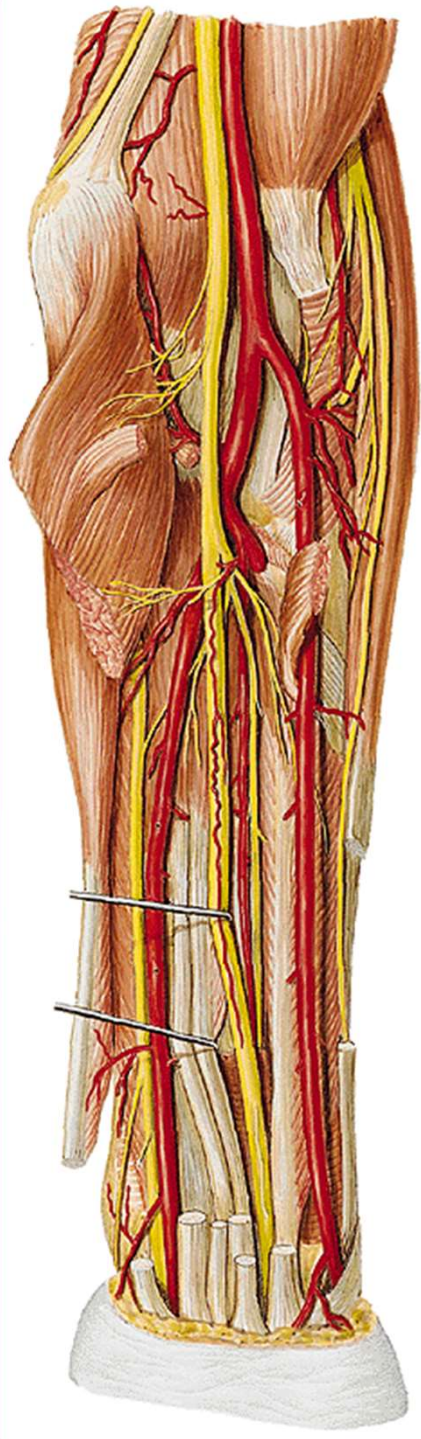
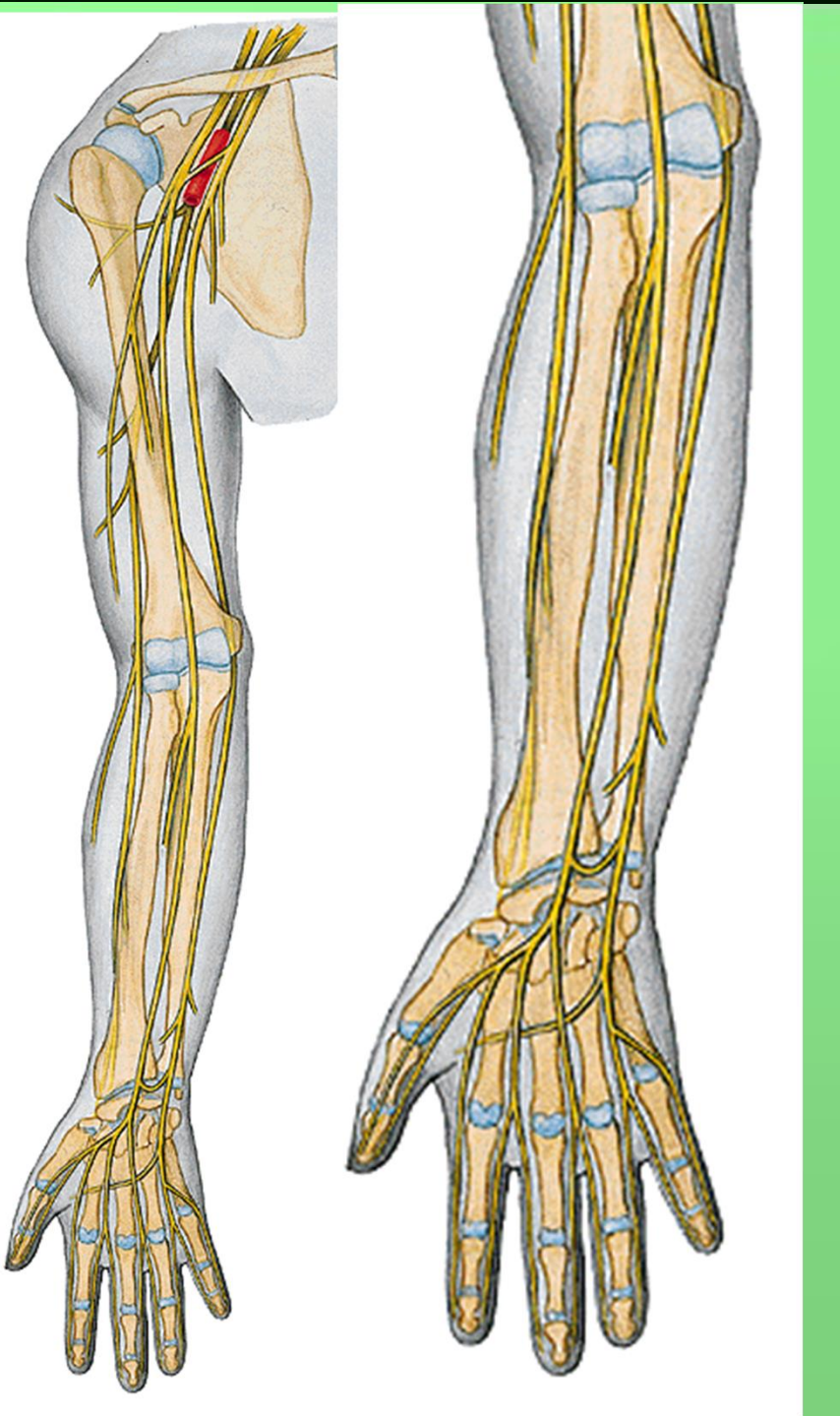
- **r. communicans cum nervo ulnari** (úroveň canalis carpi)
- **r. thenaris** (rr. musculares)
- **nn. digitales palmares comm.- nn. digitales palmares proprii**

**Motoricky:** svaly přední skupiny předloktí (kromě m. flexor carpi ulnaris a části m. flexor digitorum profundus), m. abductor pollicis brevis , m. opponens pollicis, m. flexor pollicis brevis (caput superficiale)

**Senzoricky:** thenarovou část dlaně a dlaňovou část prstů až po hranici jdoucí 4. prstem

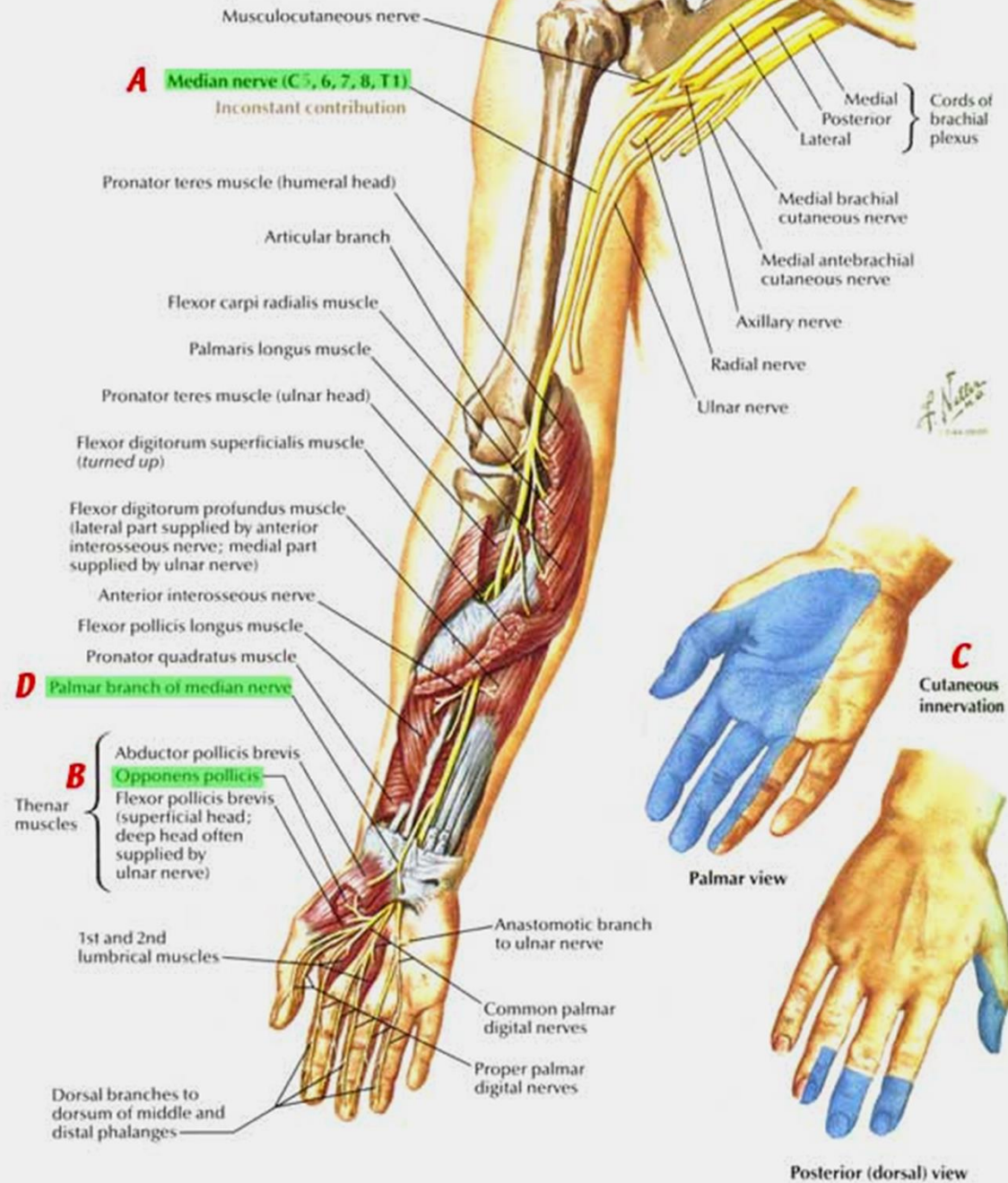


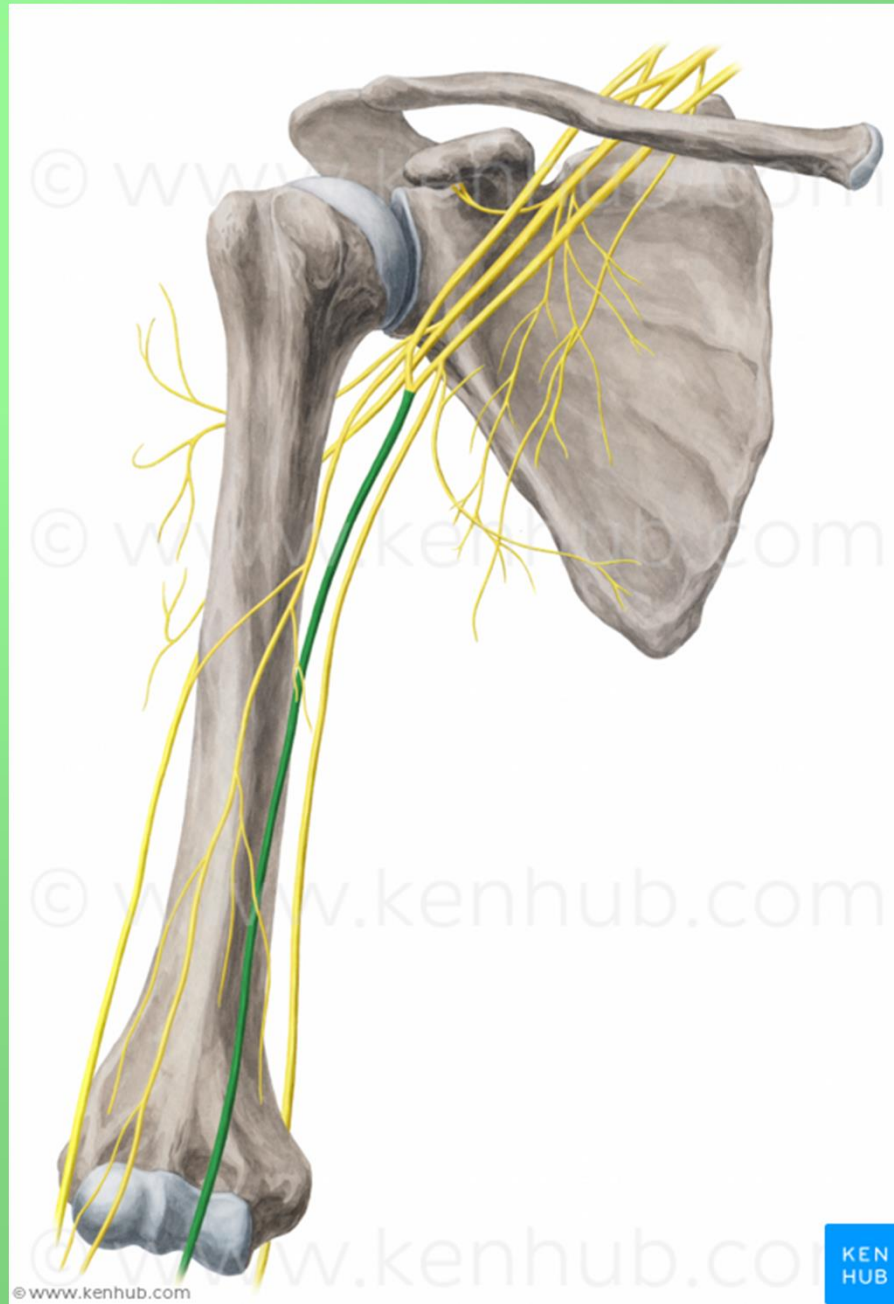




**Anterior view**

Note: only muscles innervated by median nerve shown

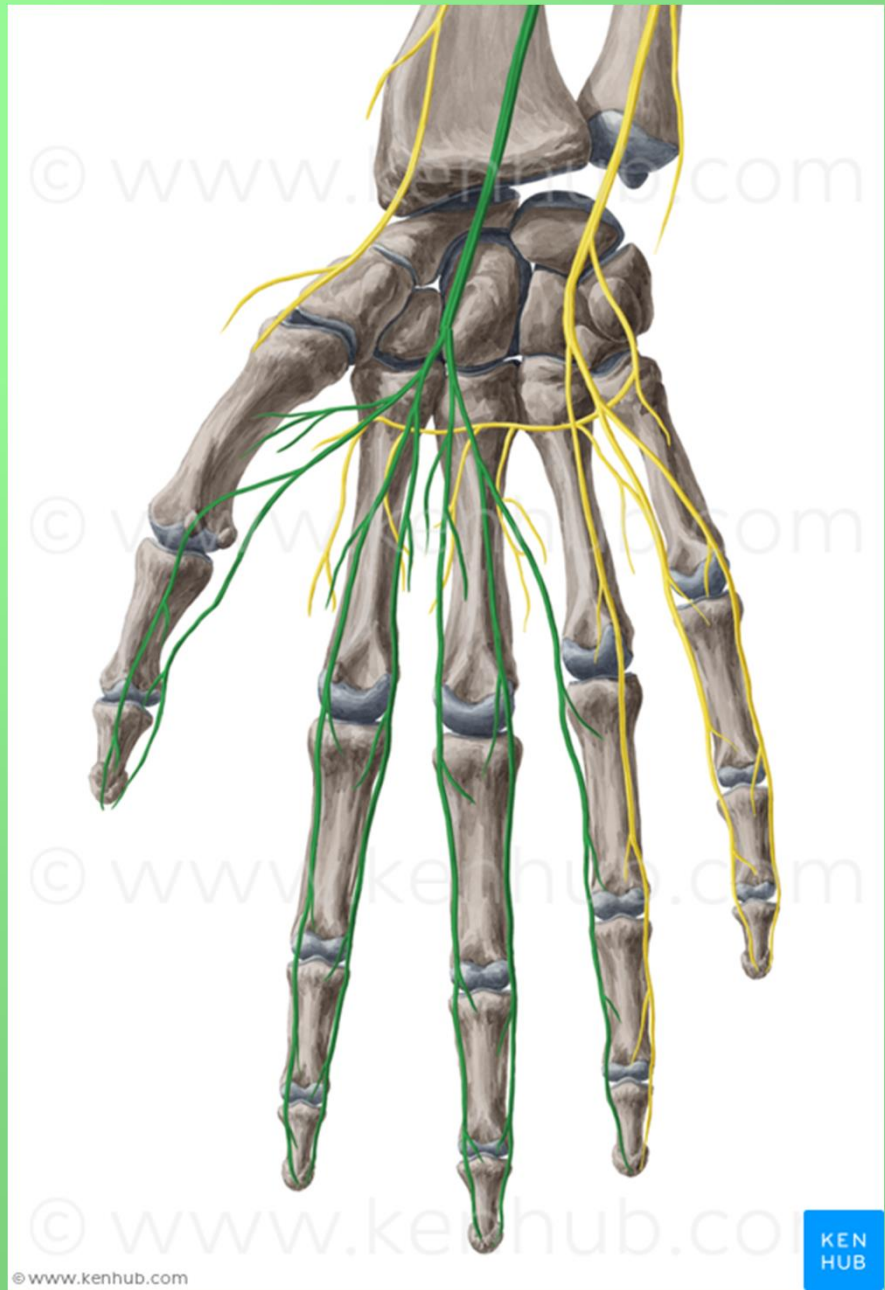




KEN  
HUB

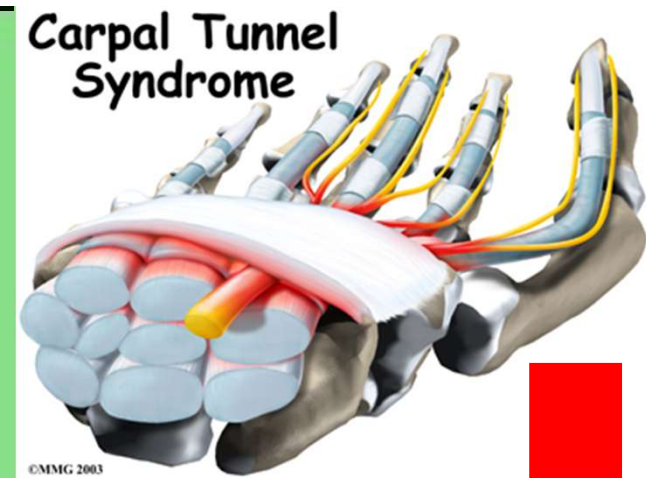




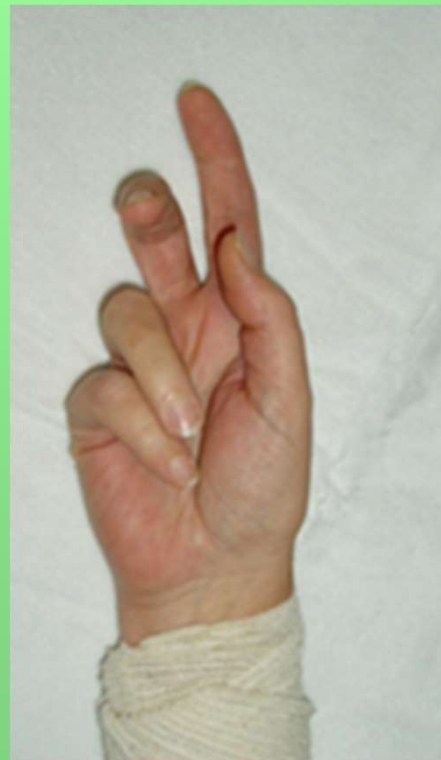
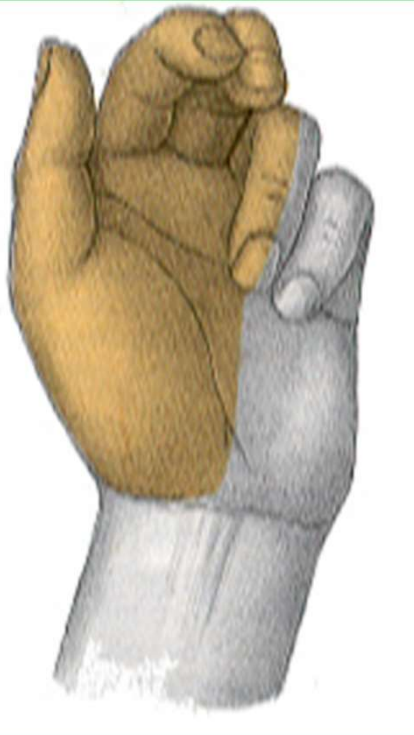
## Poškození nervu:

- sebevražedné pokusy (řezné poranění)
- patologické změny v karpálním tunelu
- chybí úchopový pohyb (opozice palce, zaškrábání ukazovákem)

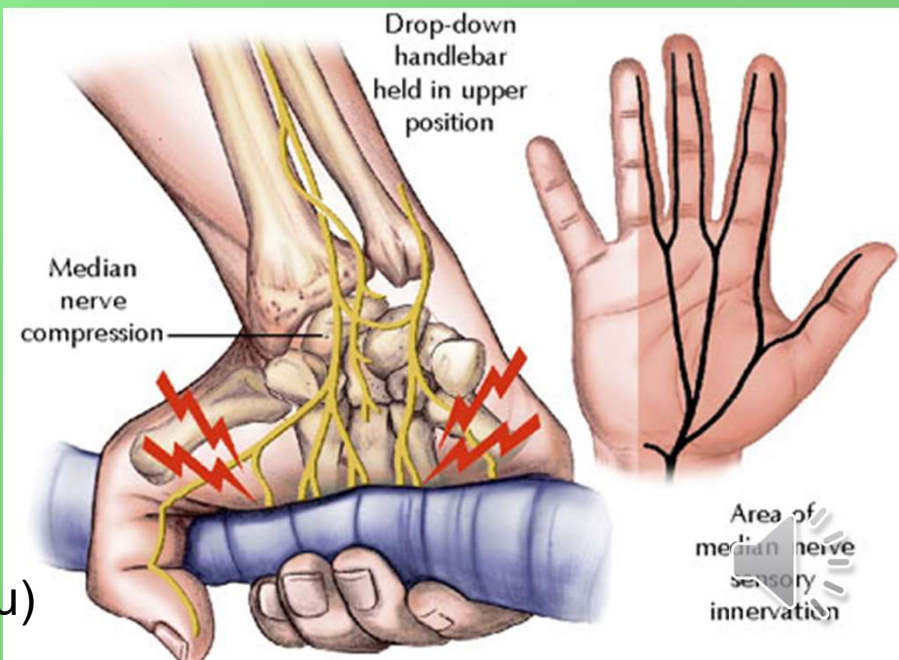


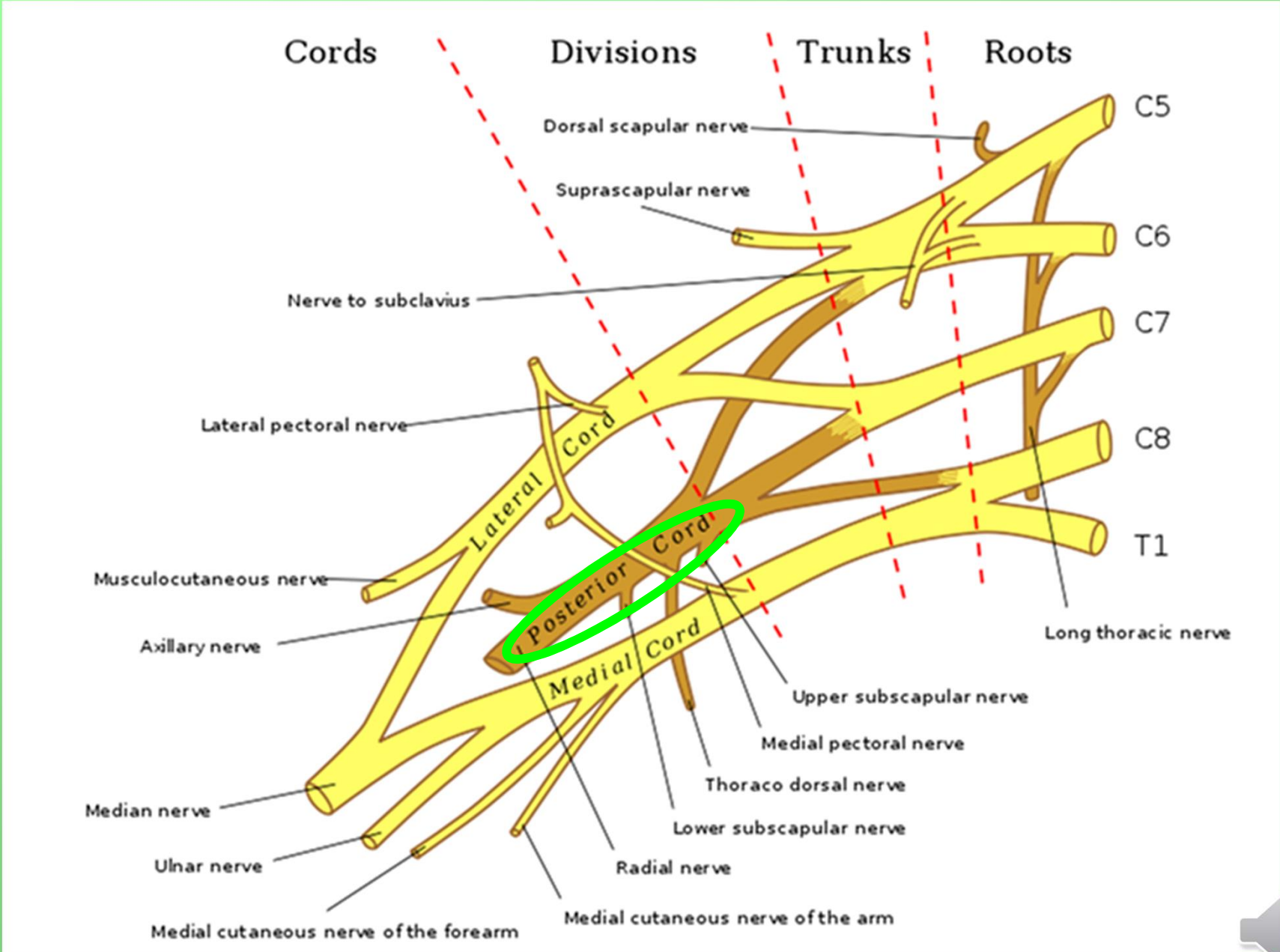
## Syndrom opičí ruky - vážne opozice palce



## Přísahající ruka

(neschopnost opozice palce a flexe 2. a 3. prstu)



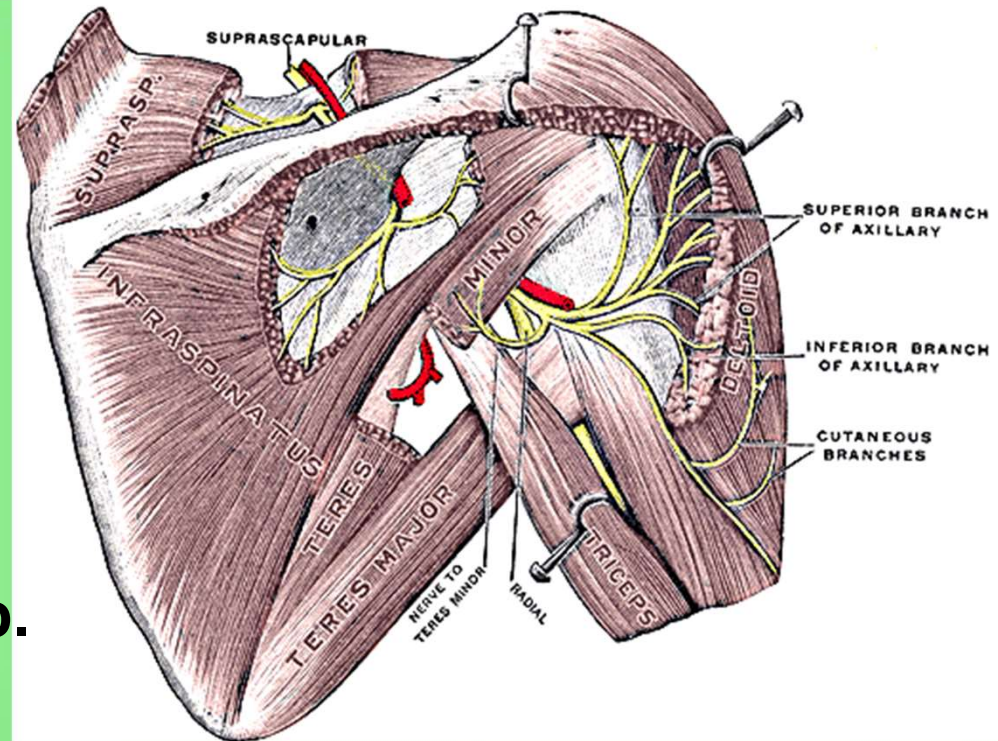


# Fasciculus posterior

## n. axillaris

foramen humerotricipitale  
(smíšený) (C5–6)

- rr. musculares
- rr. articulares
- n. cutaneus brachii lat. sup.



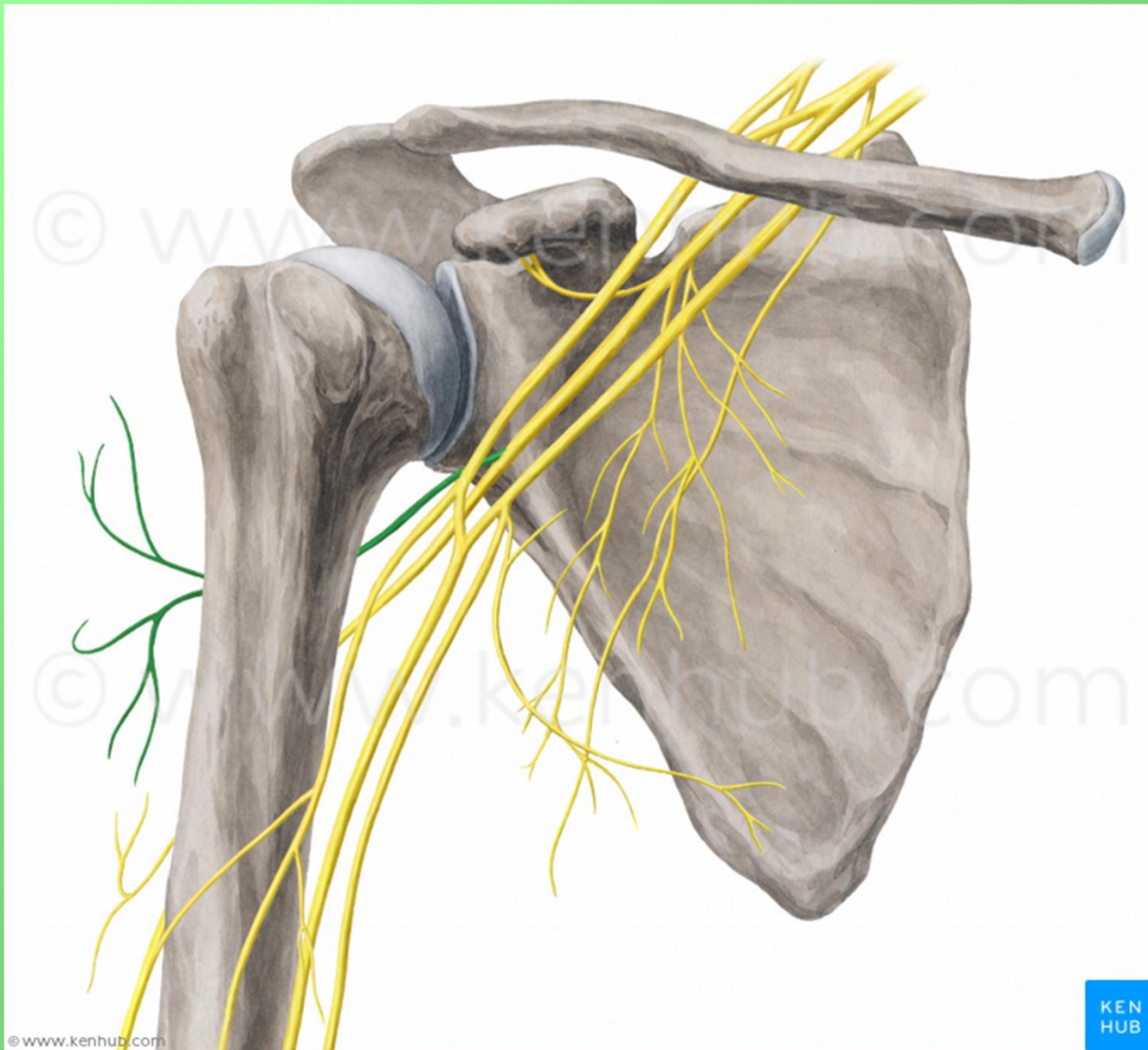
**Motoricky:** m. deltoideus, m. teres minor

**Senzoricky:** oblast ramene

**Poškození nervu** (luxace, zlomenina v collum chirurgicum)

- chybí zevní rotace a abdukce paže do horizontály

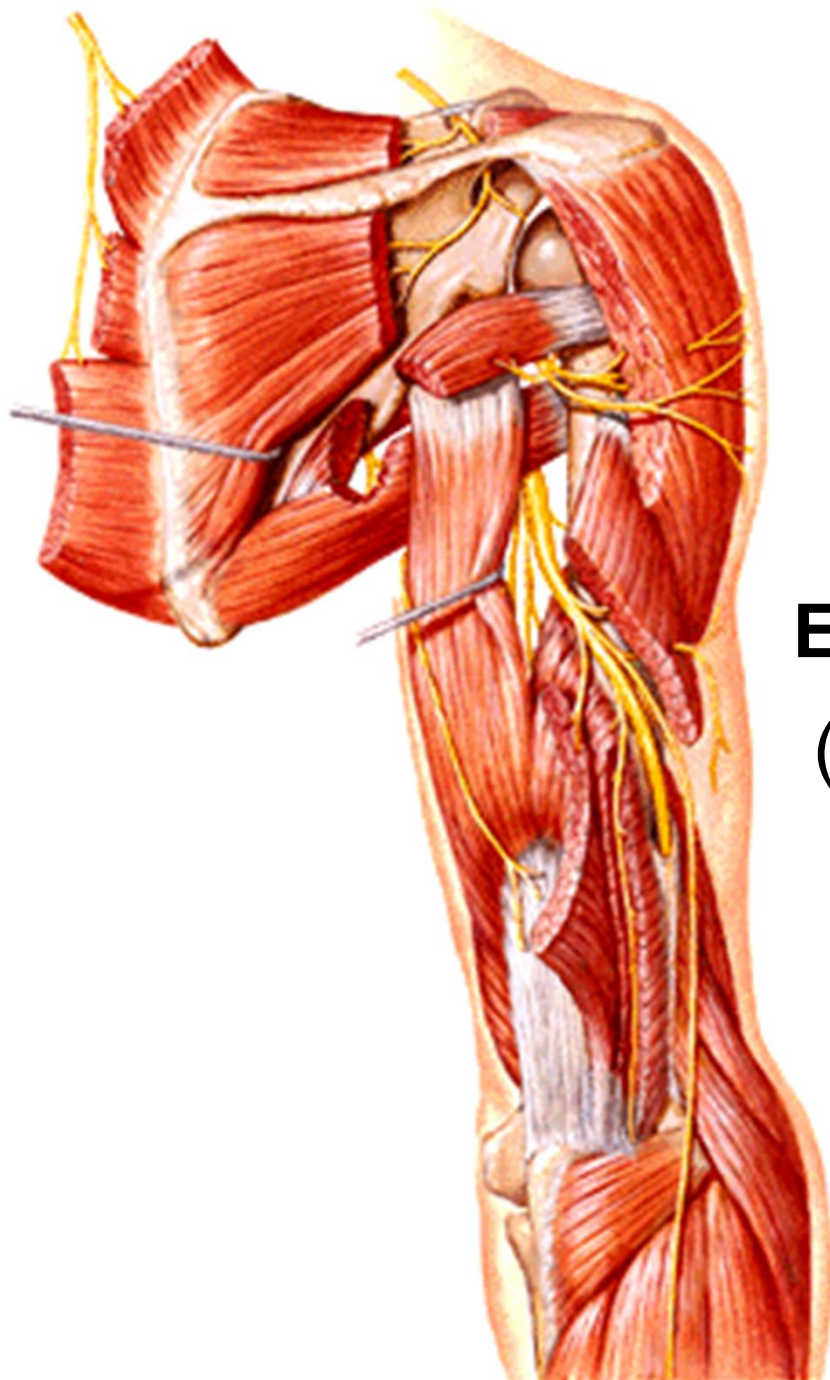




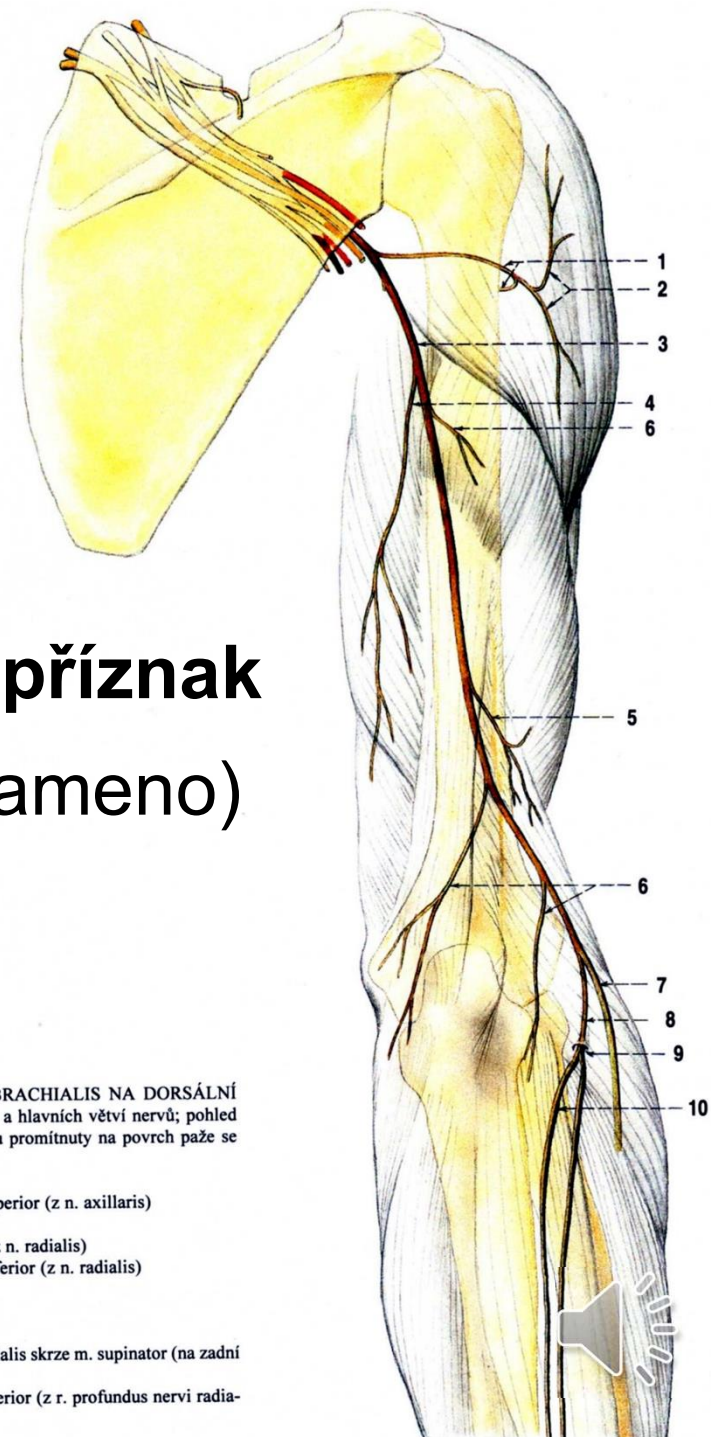
© www.kenhub.com

KEN  
HUB





## Epoletový příznak (pokleslé rameno)



Obr. 292. NERVY Z PLEXUS BRACHIALIS NA DORSÁLNÍ STRANĚ PAŽE; schéma průběhu a hlavních větví nervů; pohled zezadu na pravou paži; nervy jsou promítnuty na povrch paže se znázorněným skeletem

- 1 n. axillaris
- 2 n. cutaneus brachii lateralis superior (z n. axillaris)
- 3 n. radialis
- 4 n. cutaneus brachii posterior (z n. radialis)
- 5 n. cutaneus brachii lateralis inferior (z n. radialis)
- 6 rr. musculares (nervi radialis)
- 7 r. superficialis nervi radialis
- 8 r. profundus nervi radialis
- 9 průchod r. profundus nervi radialis skrze m. supinator (na zadní stranu předlokti)
- 10 n. interosseus antebrachii posterior (z r. profundus nervi radialis)

# n. radialis

(smíšený) (C5–Th1)

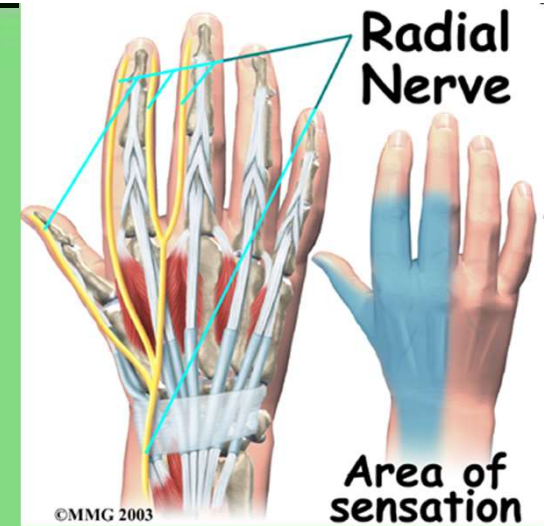
- n. cutaneus brachii posterior
- n. cutaneus brachii lateralis inferior
- rr. musculares
- n. cutaneus antebrachii posterior

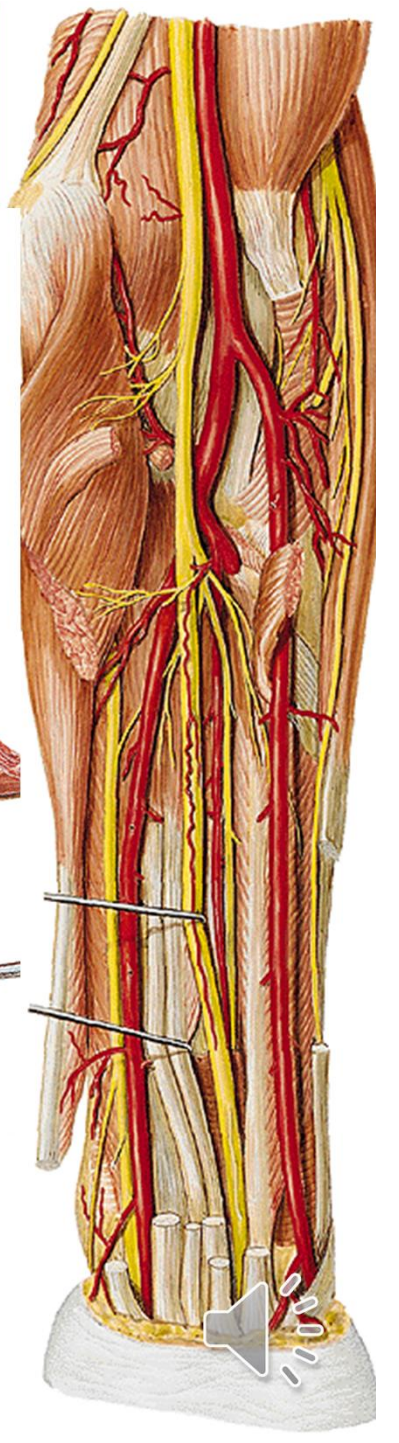
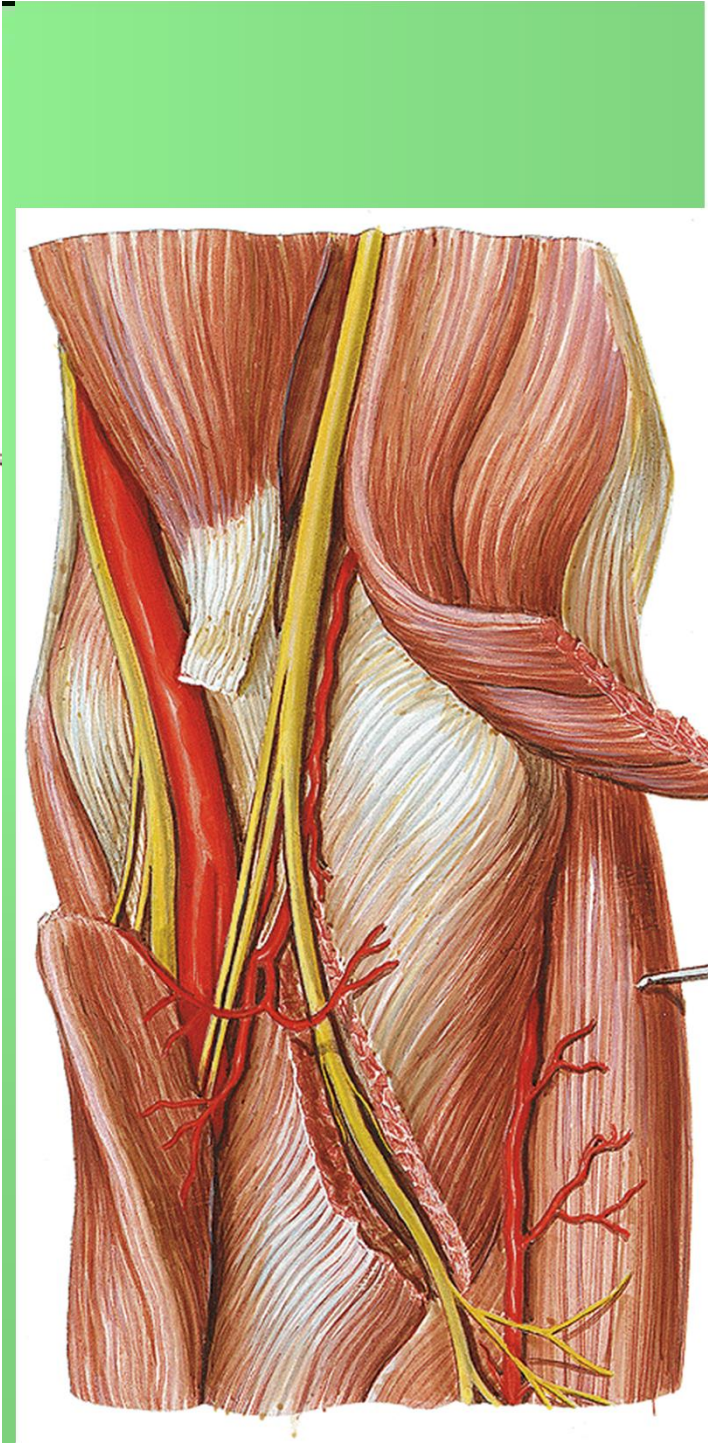
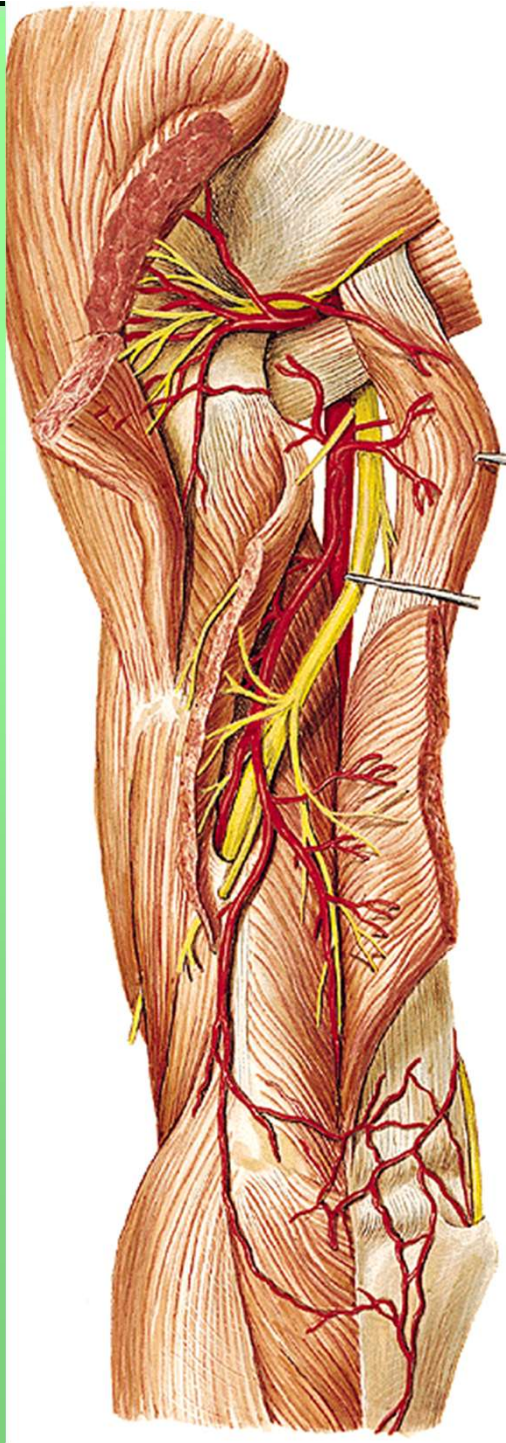
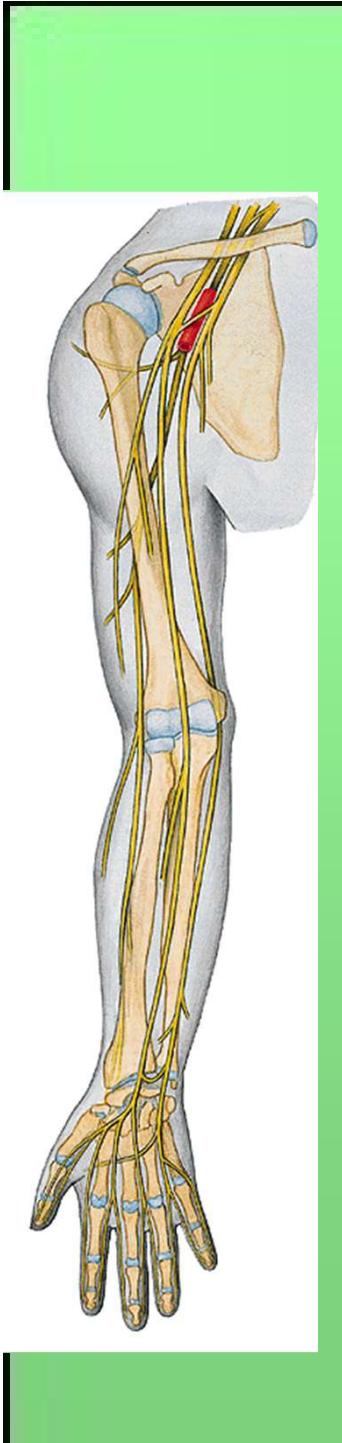
Větvení v oblasti lokte (mezi m. brachialis a m. brachioradialis)

- r. profundus (svaly dorsální skupiny předloktí)
  - n. interosseus antebrachii posterior (senzitivní nerv)
- r. superficialis (pod m. brachioradialis na hřbet ruky)
  - nn. digitales dorsales

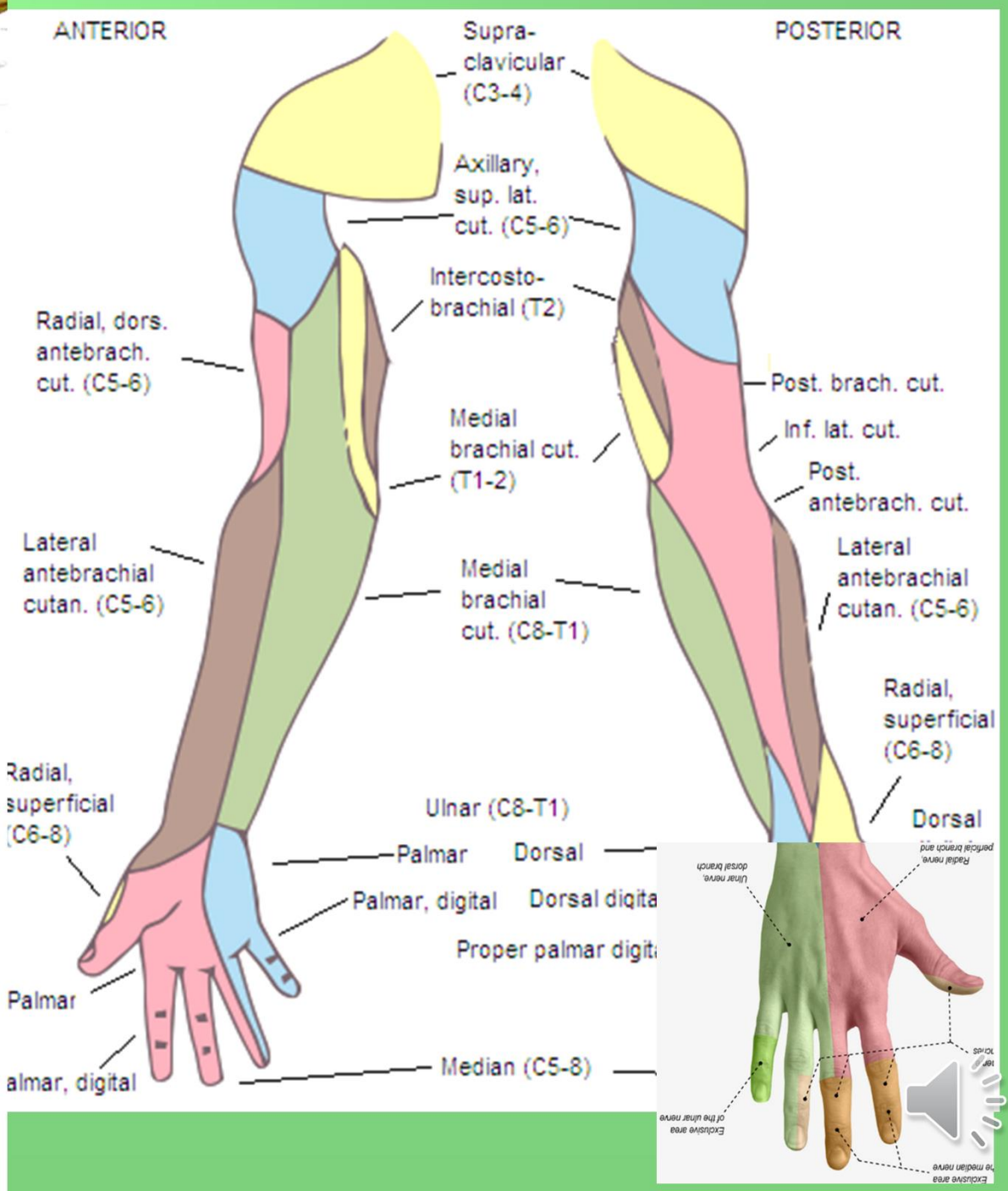
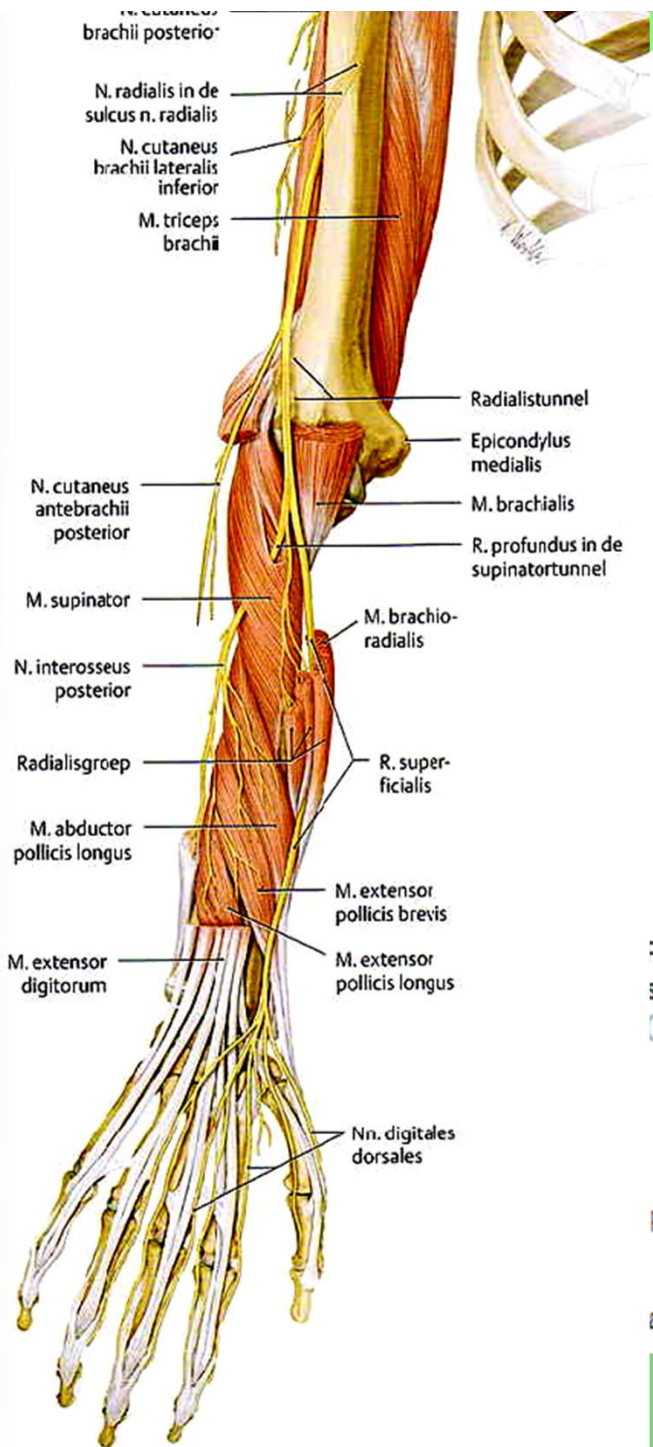
**Motoricky:** m. triceps brachii, laterální skupinu svalů předloktí, m. supinator, svaly zadní skupiny předloktí

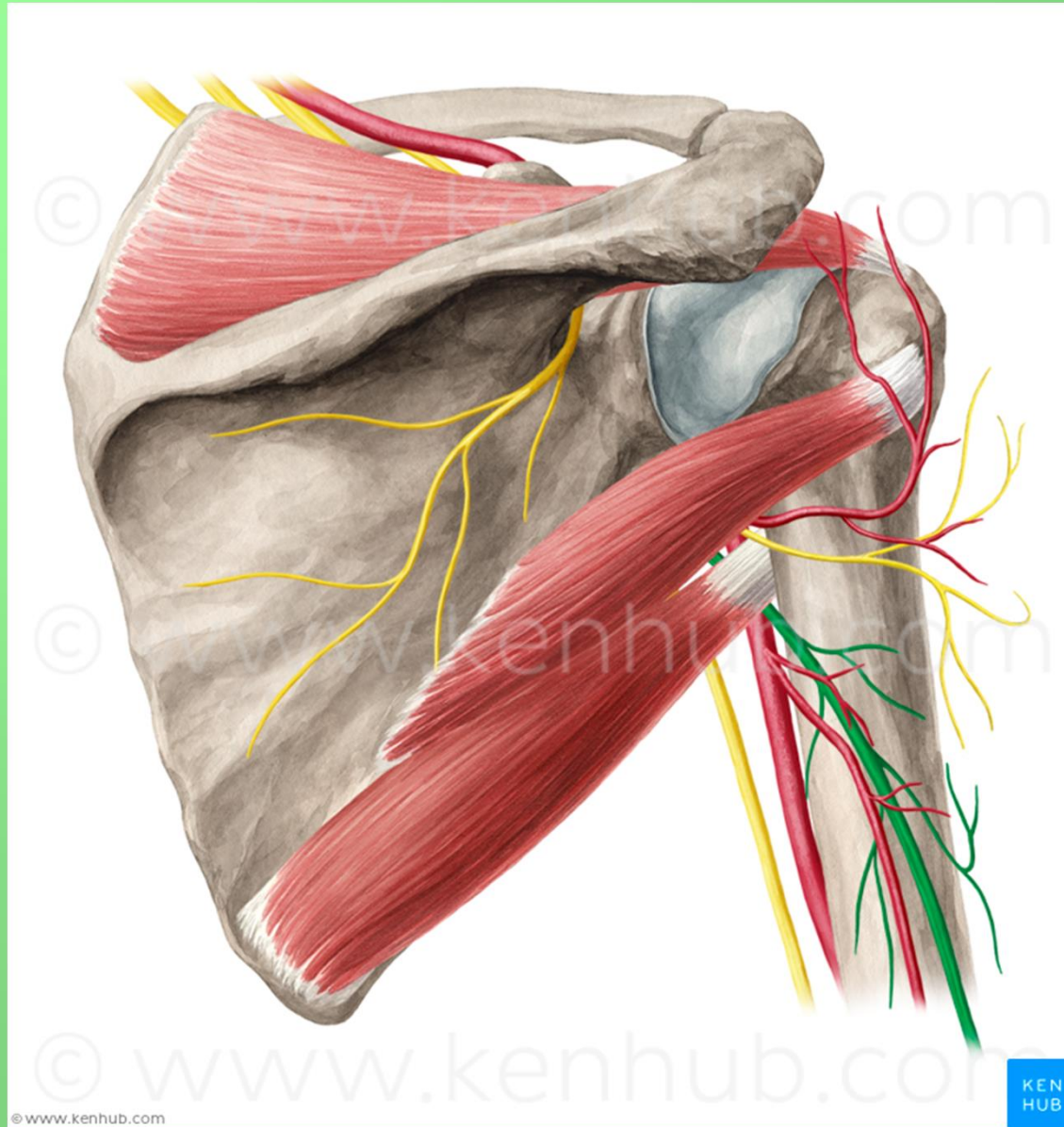
**Senzoricky:** hřbetní plocha zápěstí a 1., 2. a polovinu 3. prstu

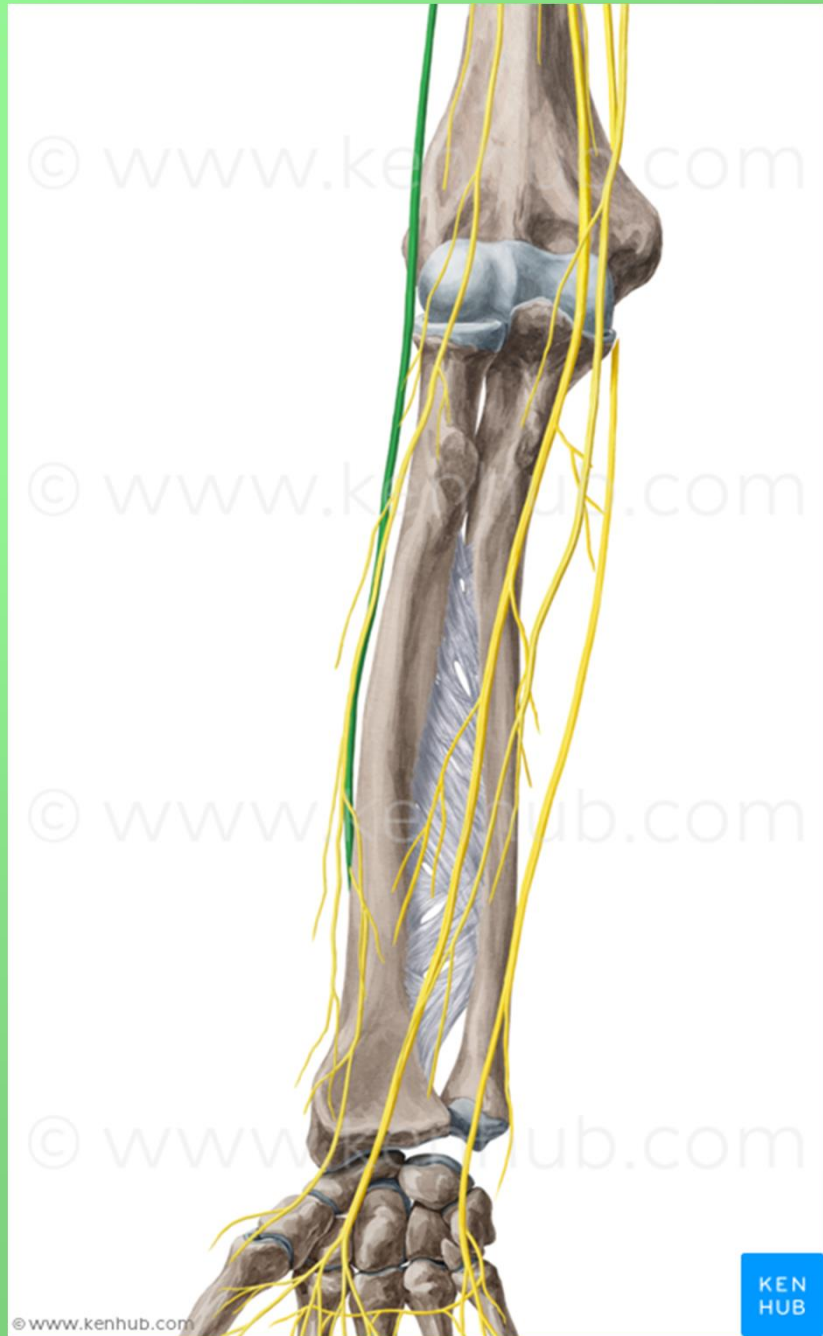











© www.kenhub.com

© www.kenhub.com

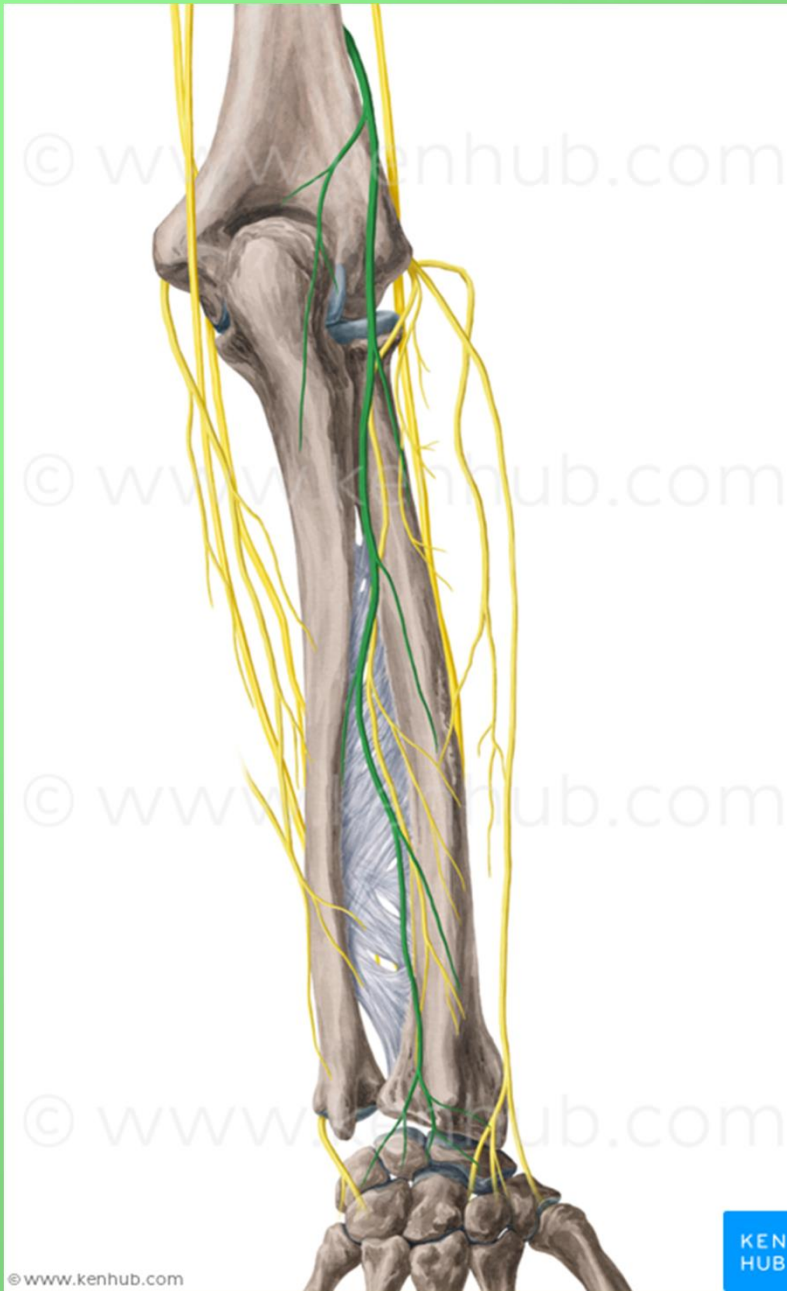
© www.kenhub.com

© www.kenhub.com

© www.kenhub.com

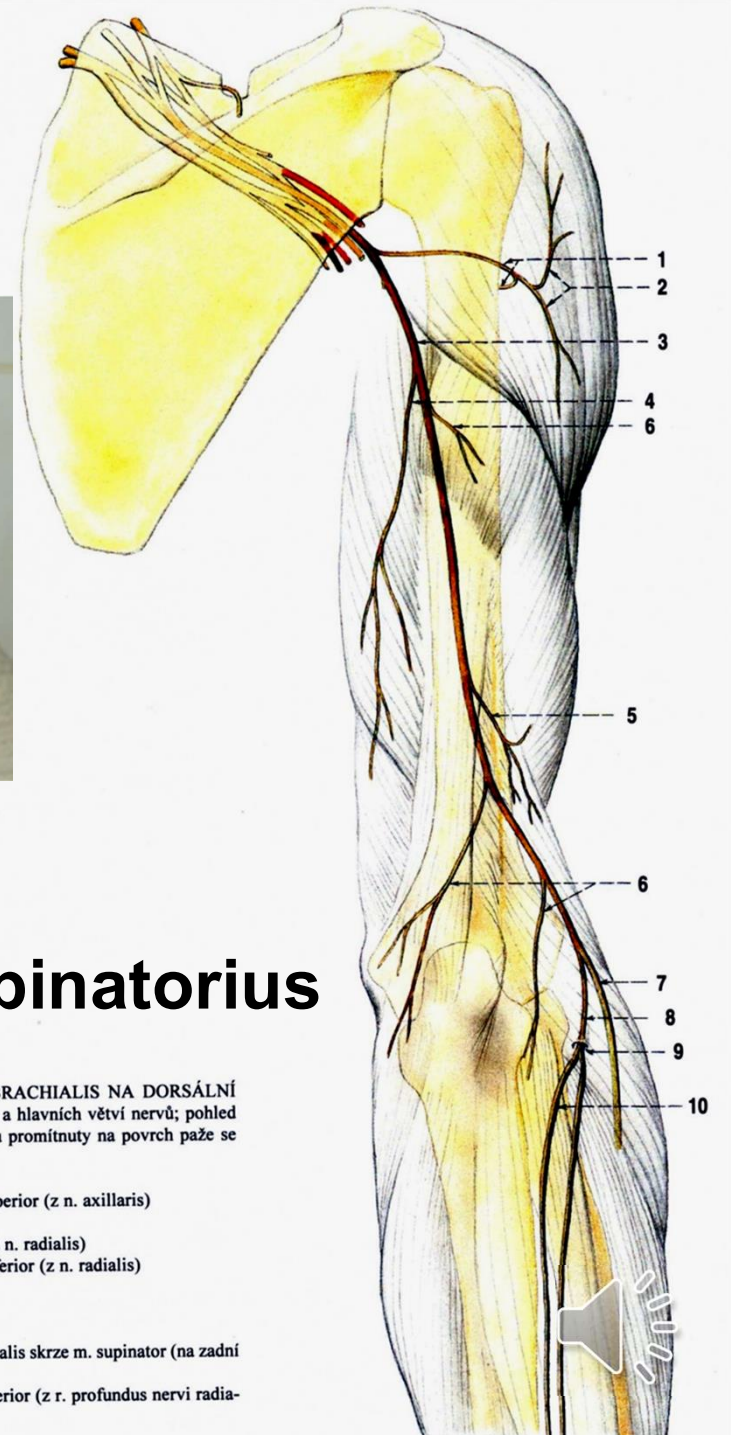
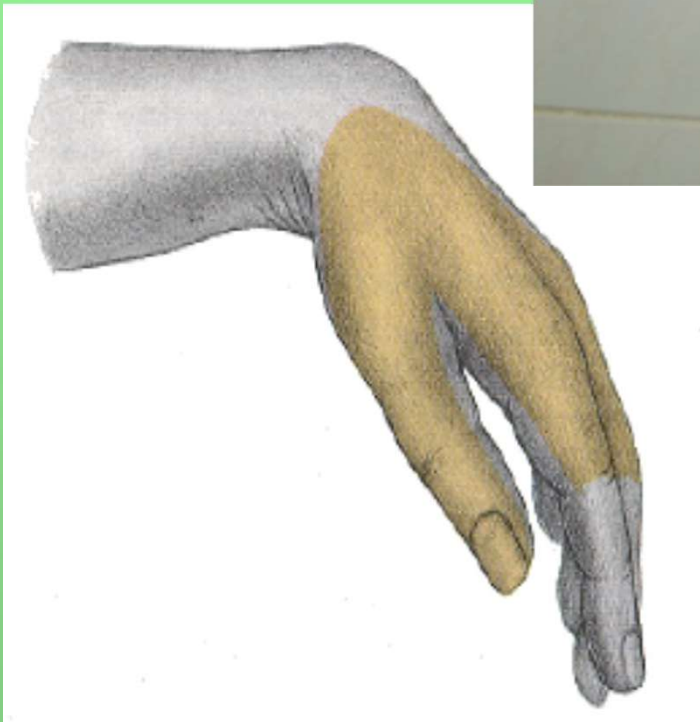
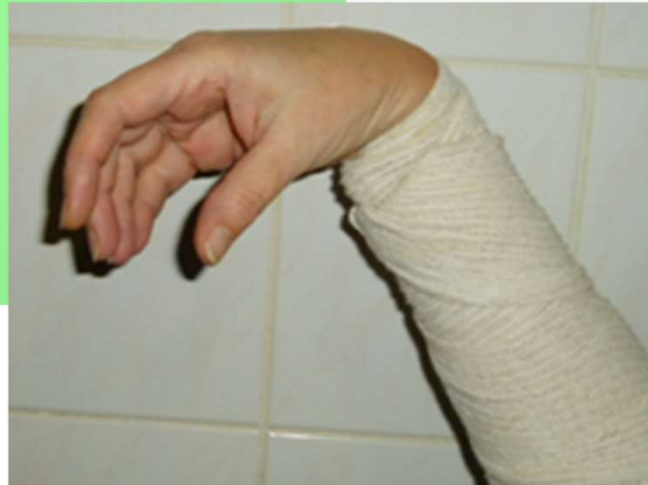KEN  
HUB





## Poranění nervu: na paži (zlomeniny)

- obrna extensorů ruky přepadá palmárně

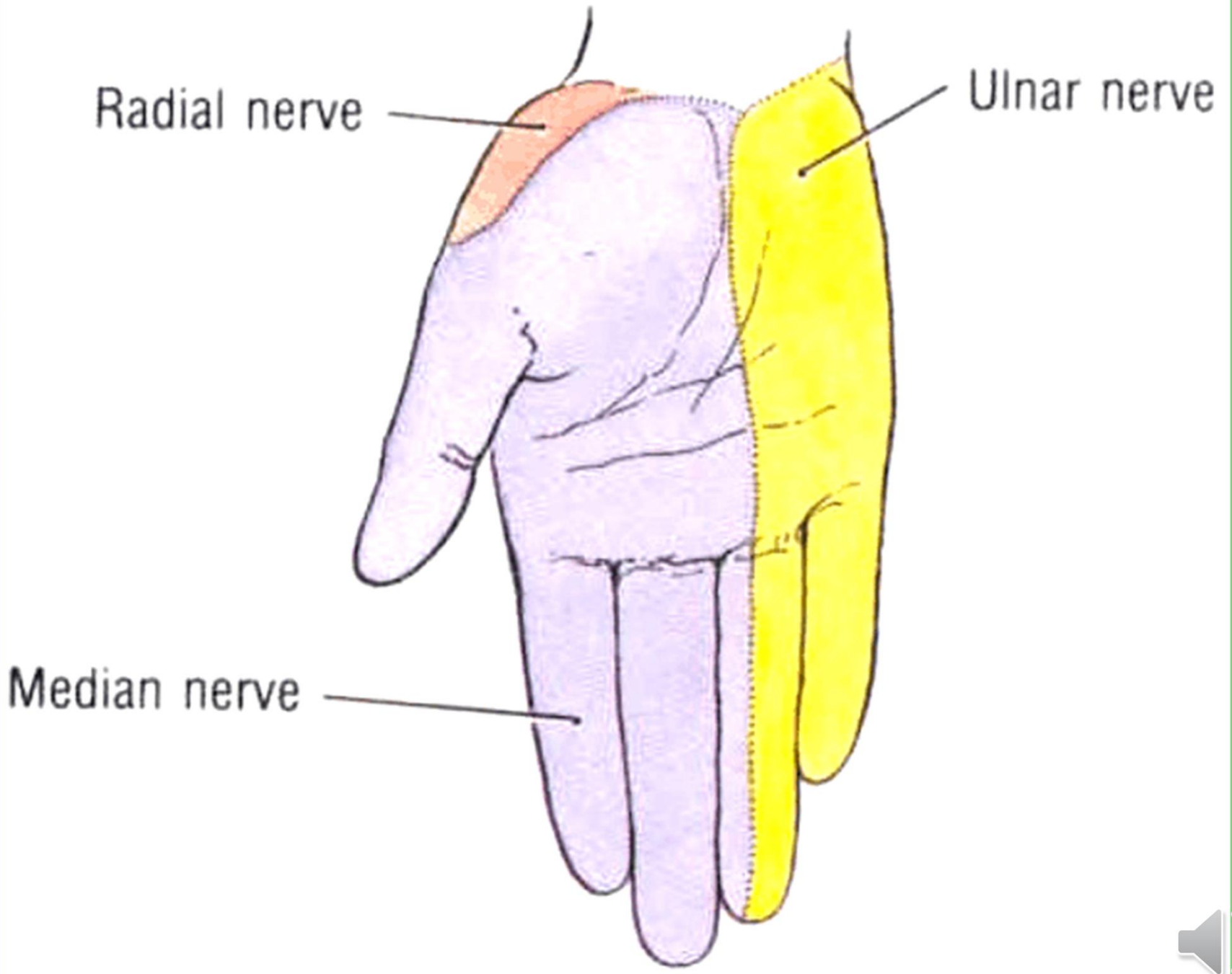


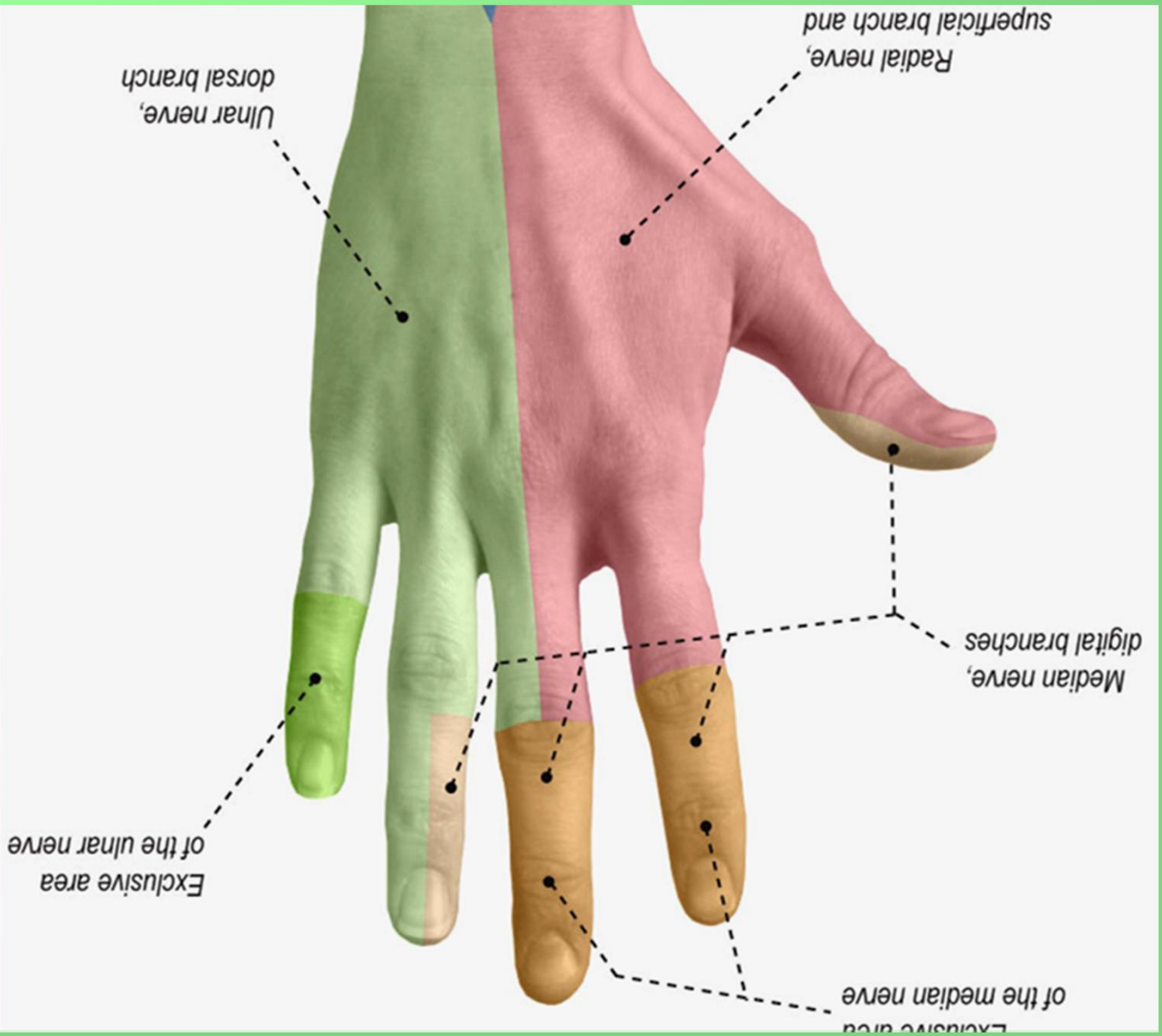
## Canalis supinatorius

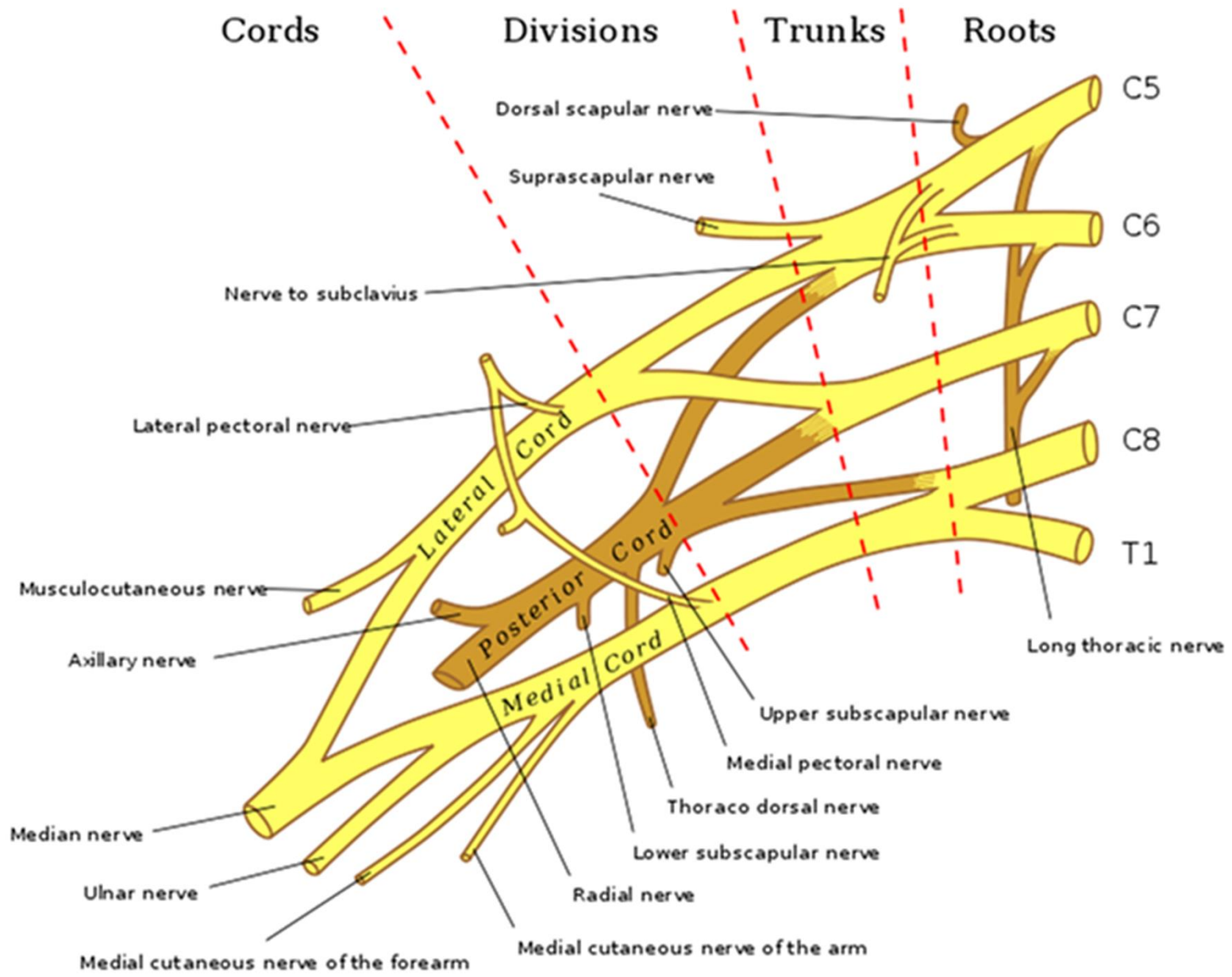
Obr. 292. NERVY Z PLEXUS BRACHIALIS NA DORSÁLNÍ STRANĚ PAŽE; schéma průběhu a hlavních větví nervů; pohled zezadu na pravou paži; nervy jsou promítány na povrch paže se znázorněným skeletem

- 1 n. axillaris
- 2 n. cutaneus brachii lateralis superior (z n. axillaris)
- 3 n. radialis
- 4 n. cutaneus brachii posterior (z n. radialis)
- 5 n. cutaneus brachii lateralis inferior (z n. radialis)
- 6 rr. musculares (nervi radialis)
- 7 r. superficialis nervi radialis
- 8 r. profundus nervi radialis
- 9 průchod r. profundus nervi radialis skrze m. supinator (na zadní stranu předloktí)
- 10 n. interosseus antebrachii posterior (z r. profundus nervi radialis)

## Syndrom labutí šíje









- **Obrázky:**
- **Atlas der Anatomie des Menschen/Sobotta. Putz,R., und Pabst,R. 20. Auflage. München:Urban & Schwarzenberg, 1993**
- **Netter: Interactive Atlas of Human Anatomy.**
- **Naňka, Elišková: Přehled anatomie. Galén, Praha 2009.**
- **Čihák: Anatomie I, II, III.**
- **Drake et al: Gray´s Anatomy for Students. 2010**



*Děkuji za pozornost!*

