

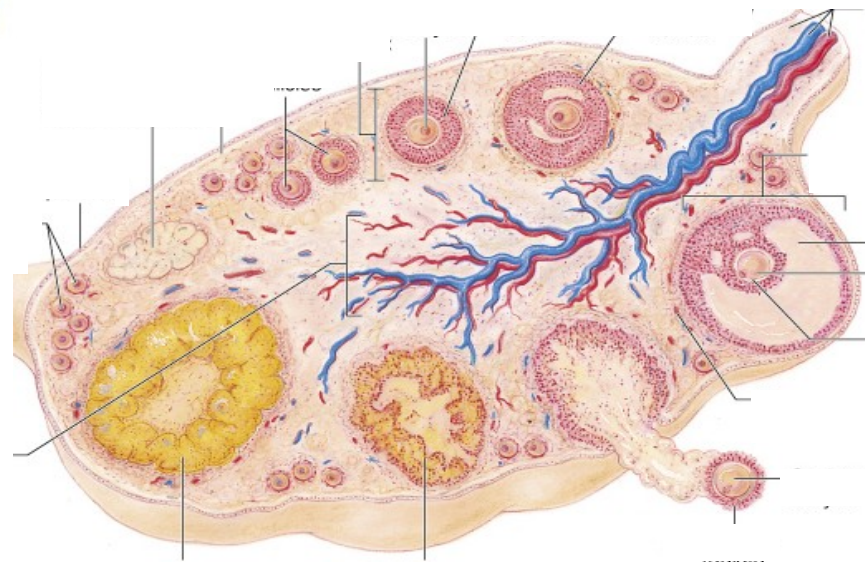
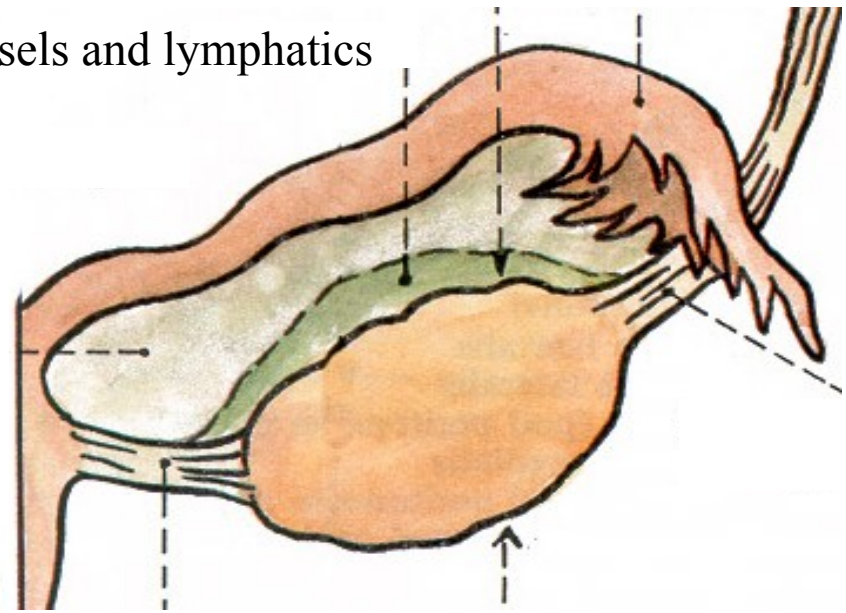
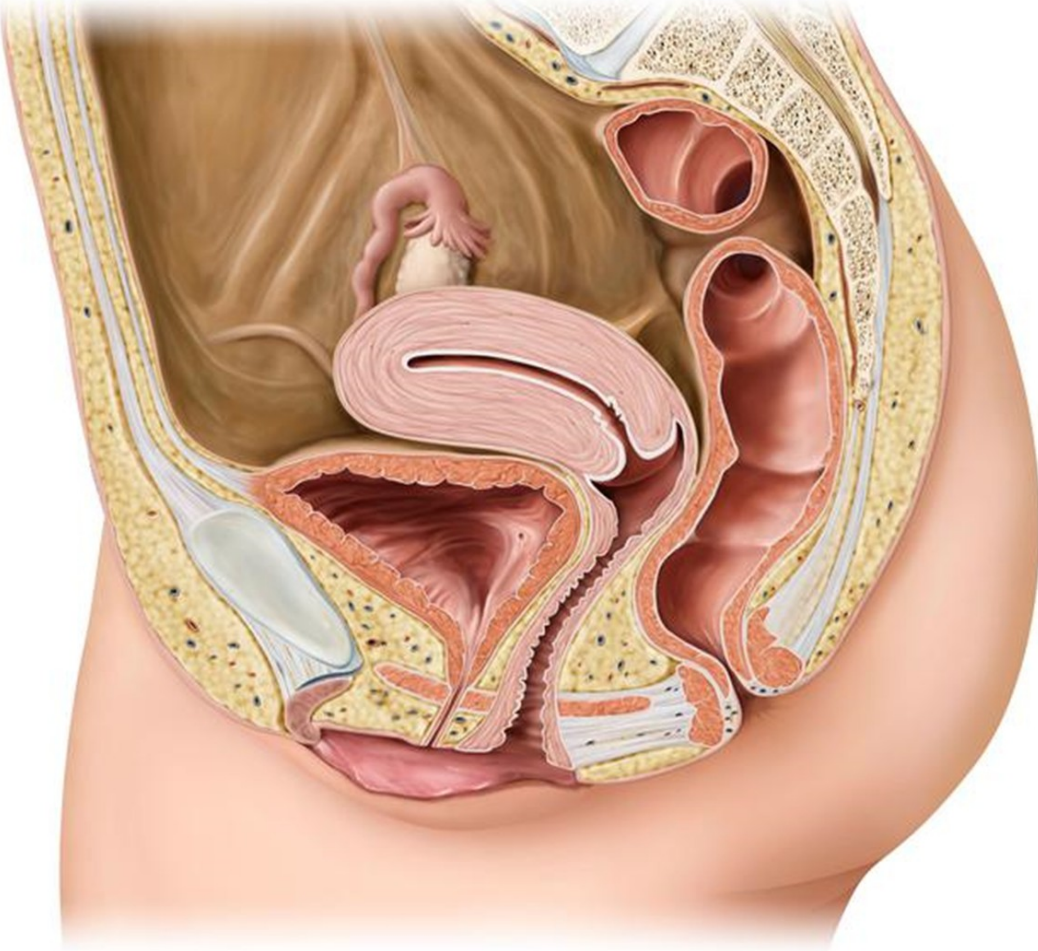


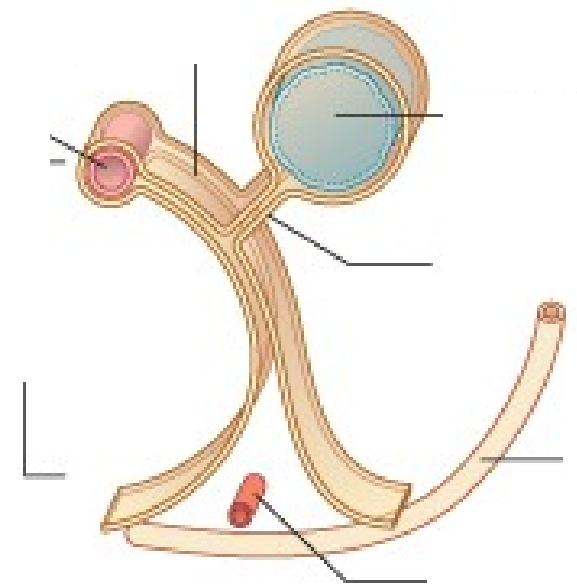
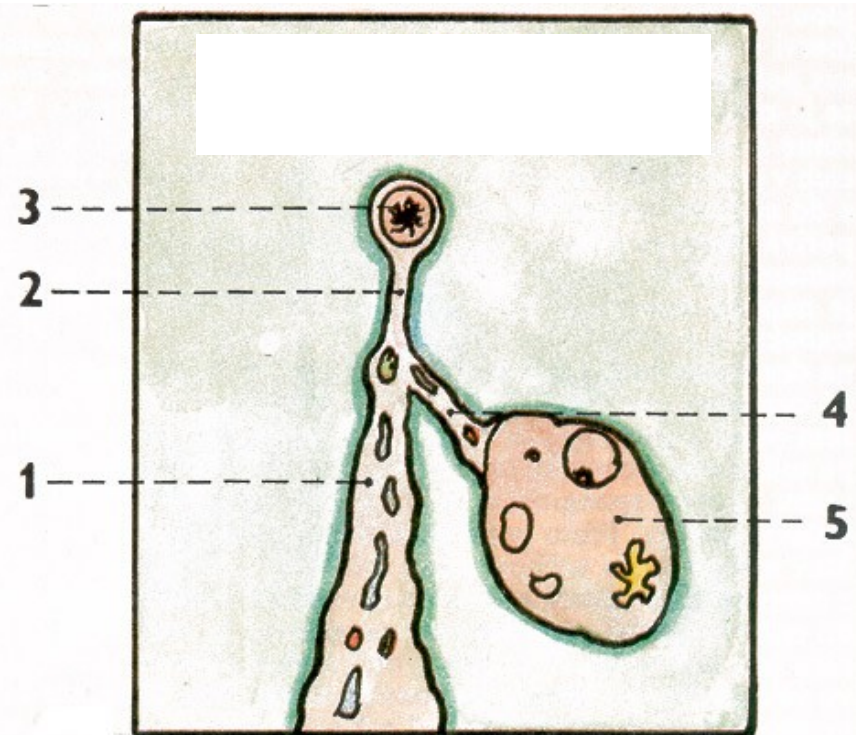
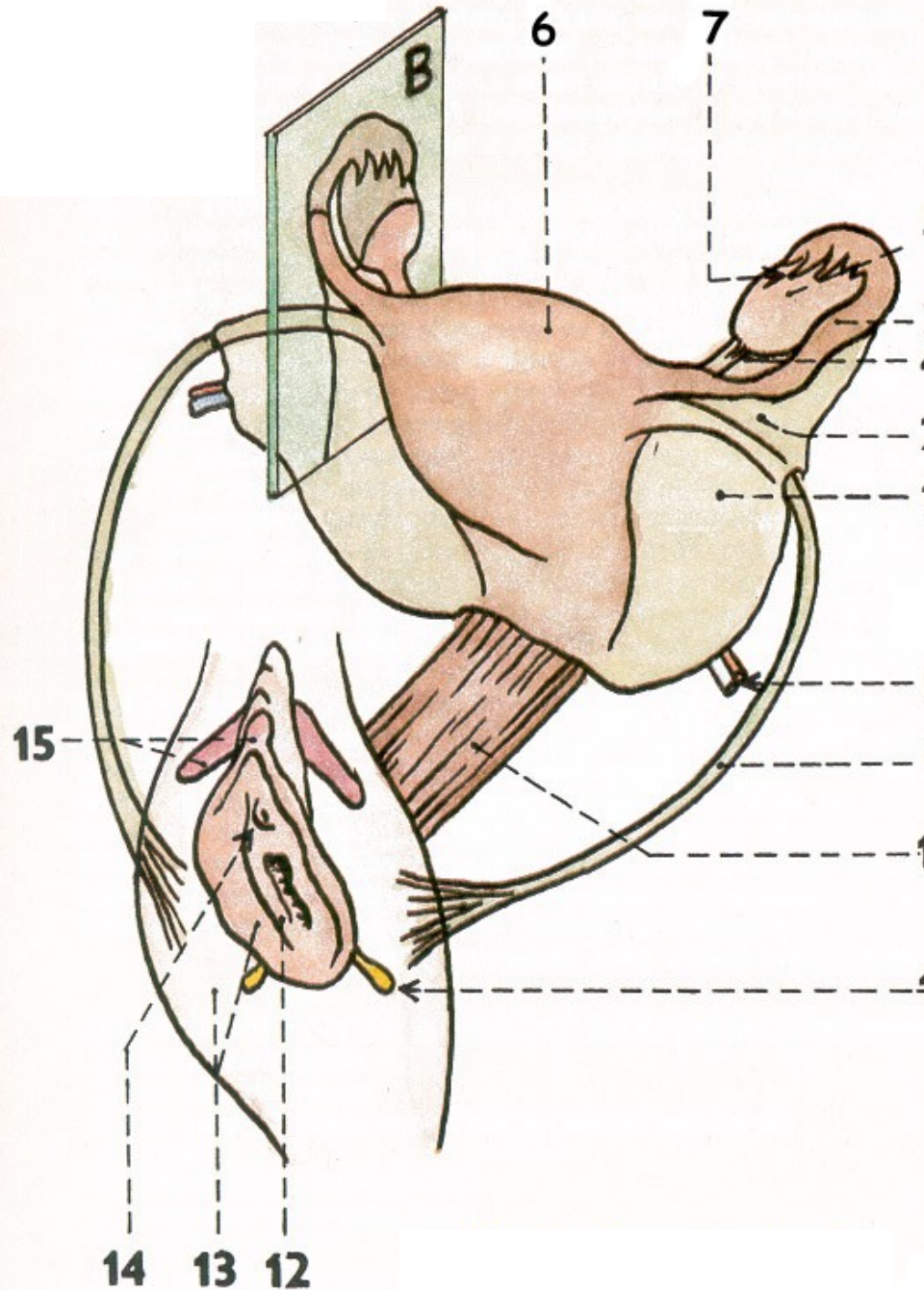
FEMALE GENITAL SYSTEM



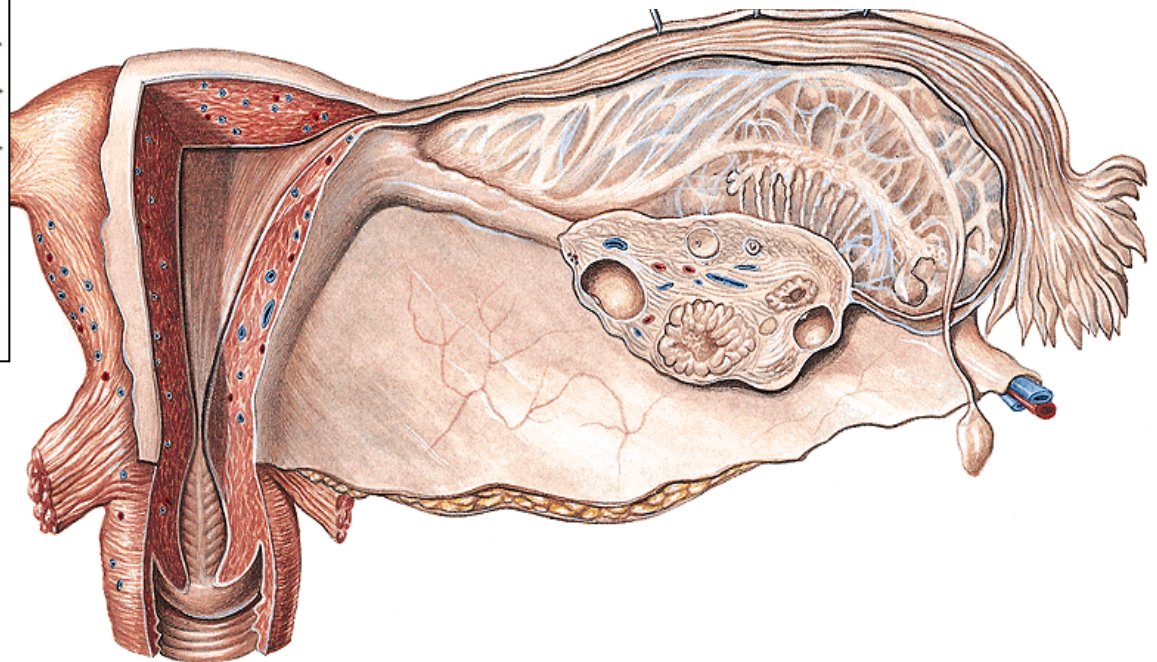
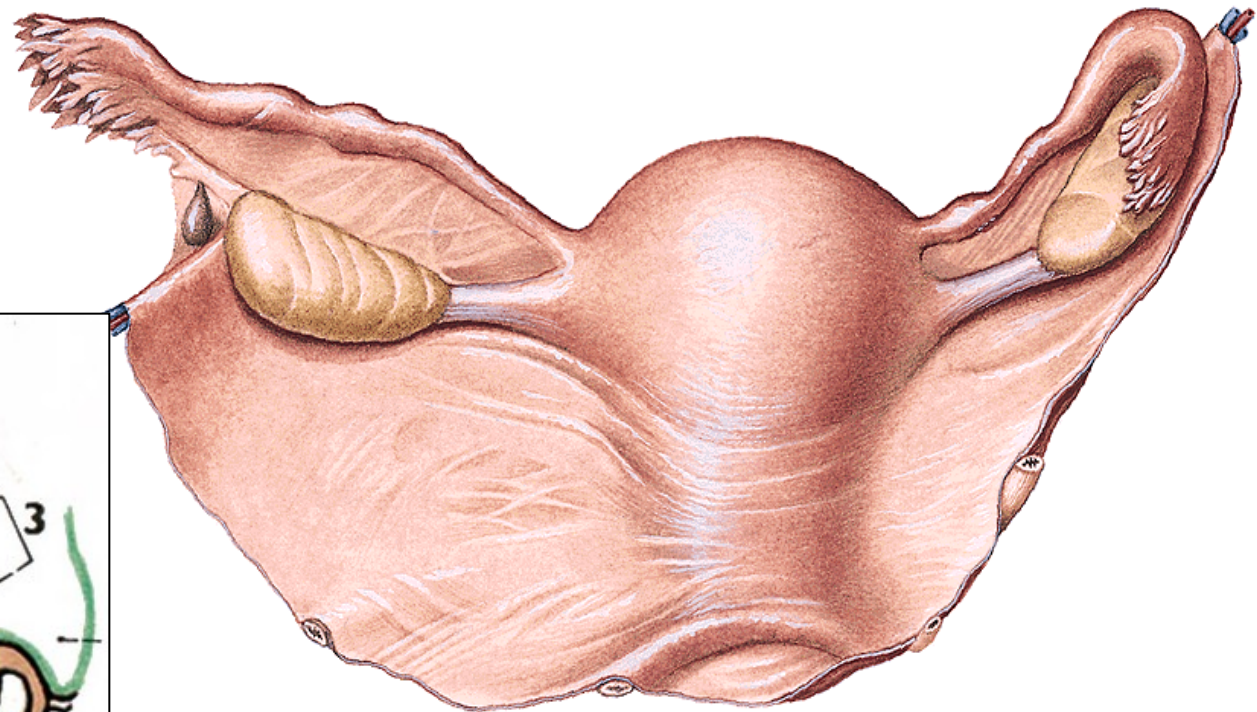
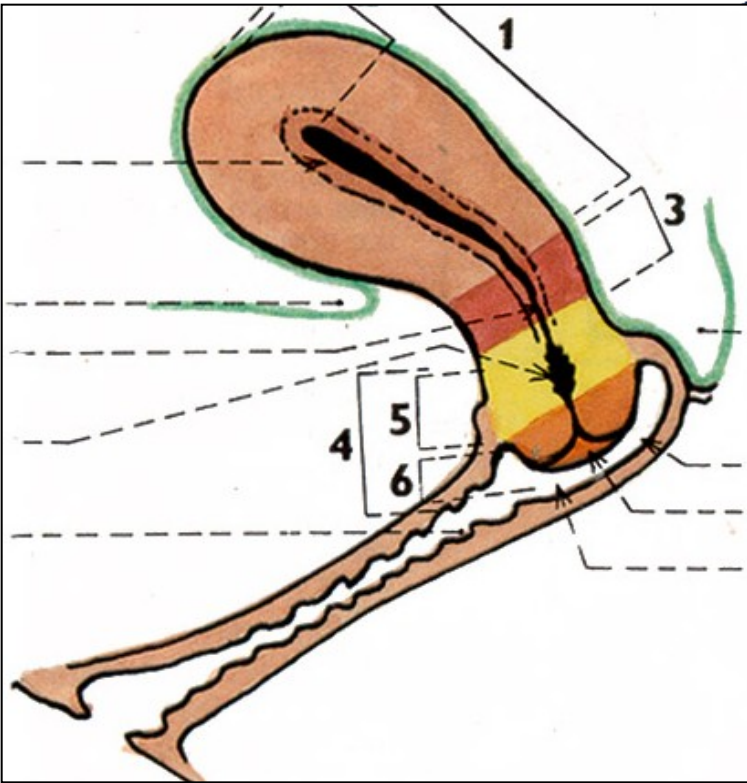
1. Ovary (*ovarium*): description, syntopy, blood vessels and lymphatics

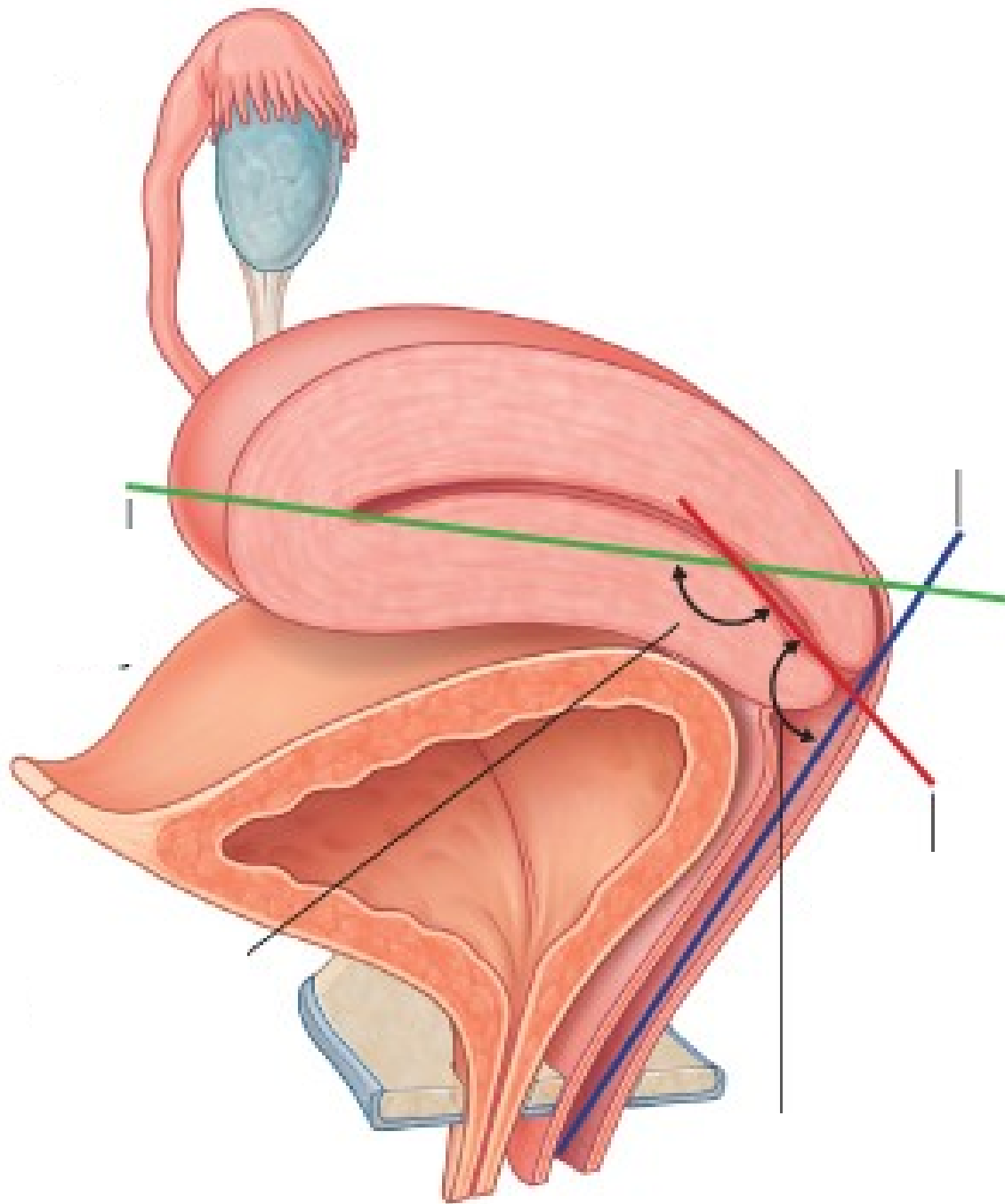


1. Uterine tube (*tuba uterina*): description, syntopy

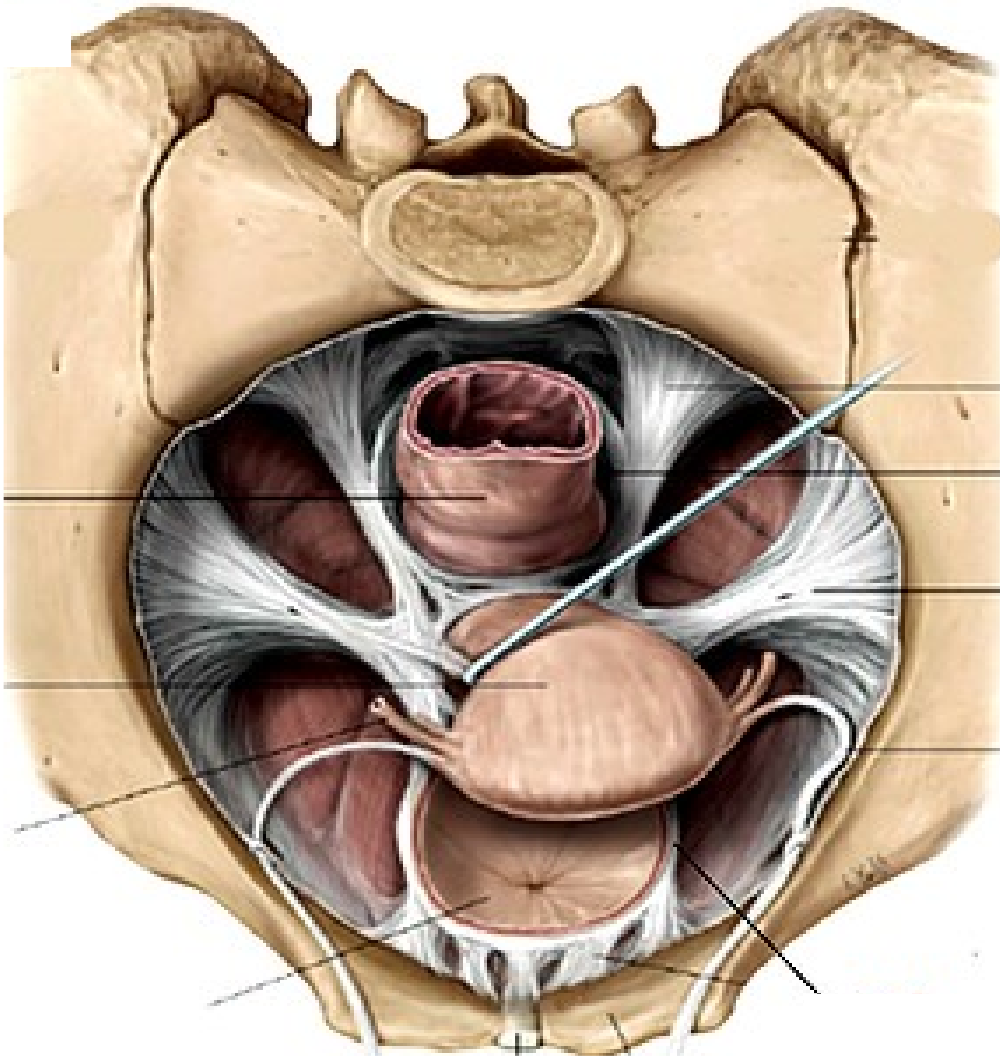
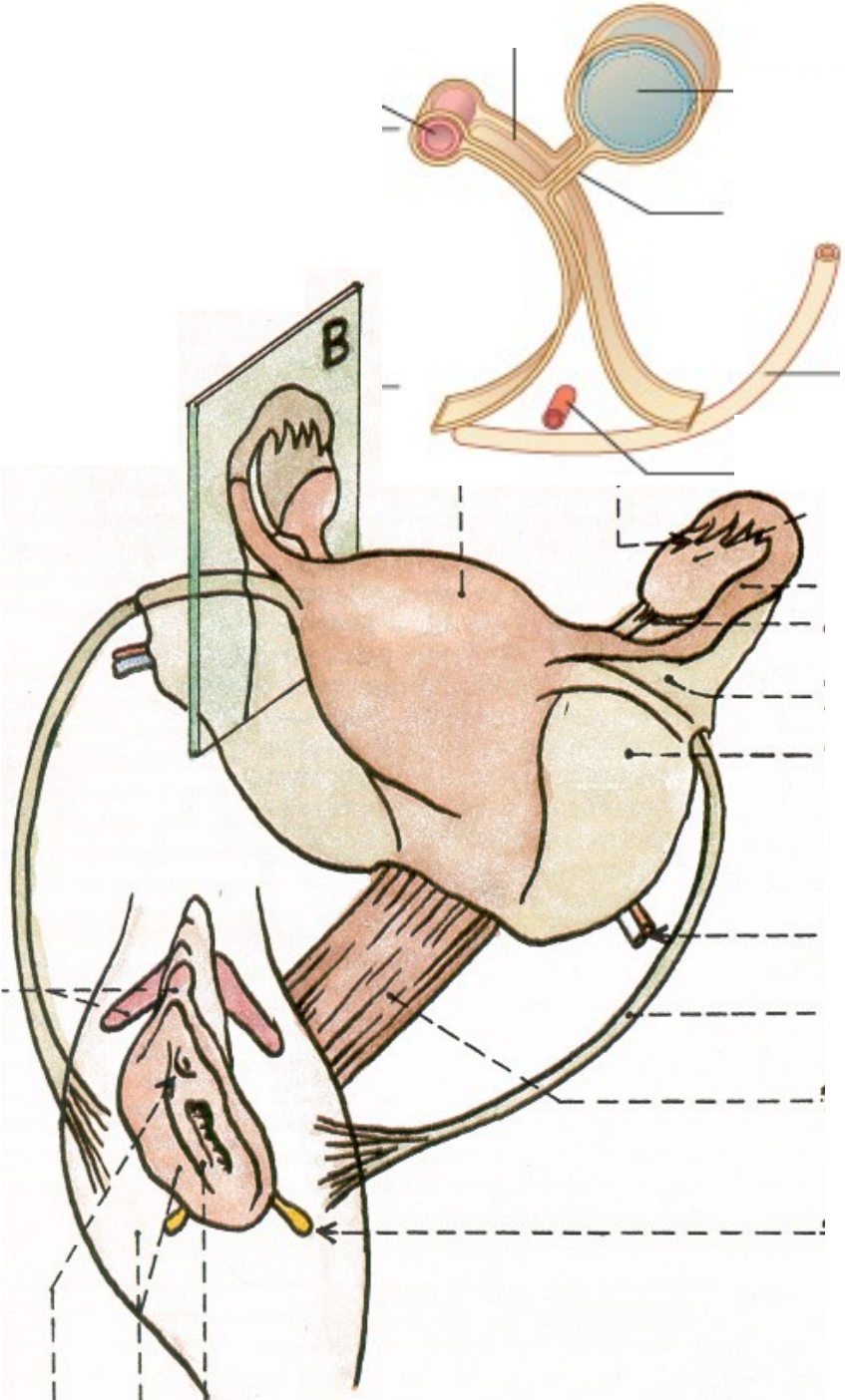


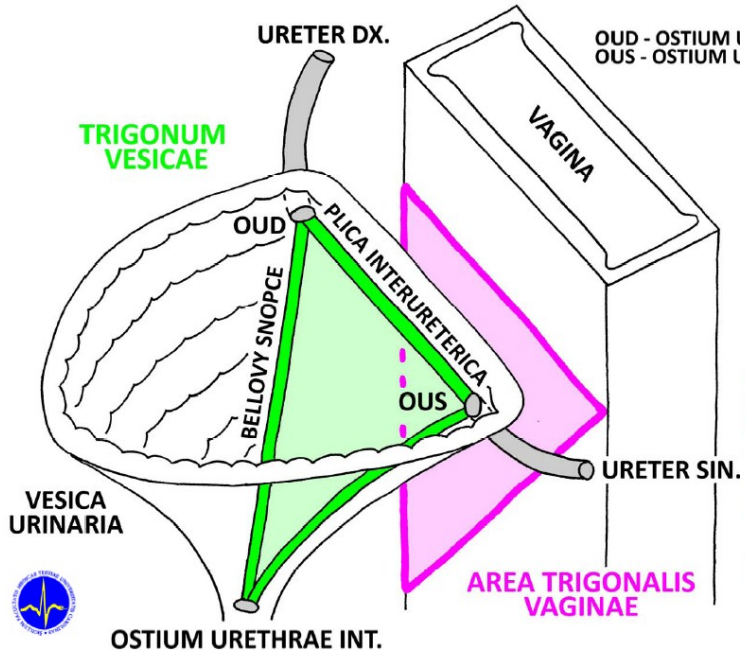
1. Uterus: description,
syntopy, blood vessels and
lymphatics



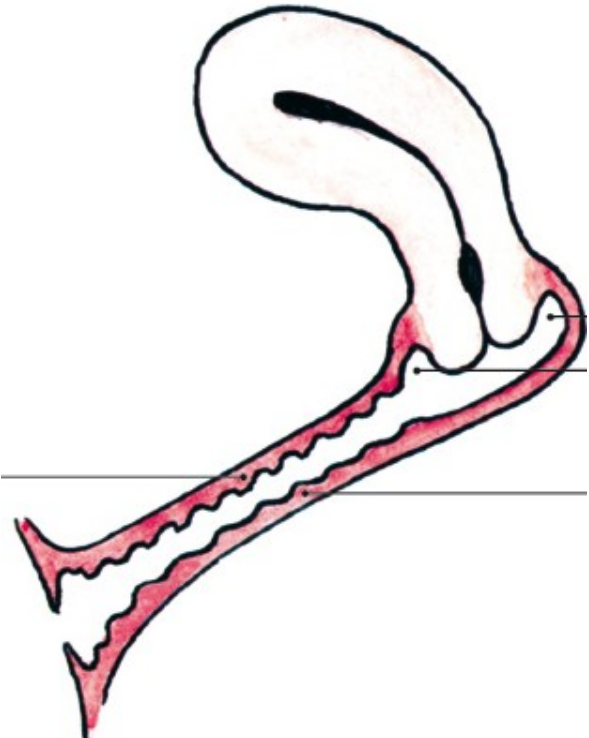
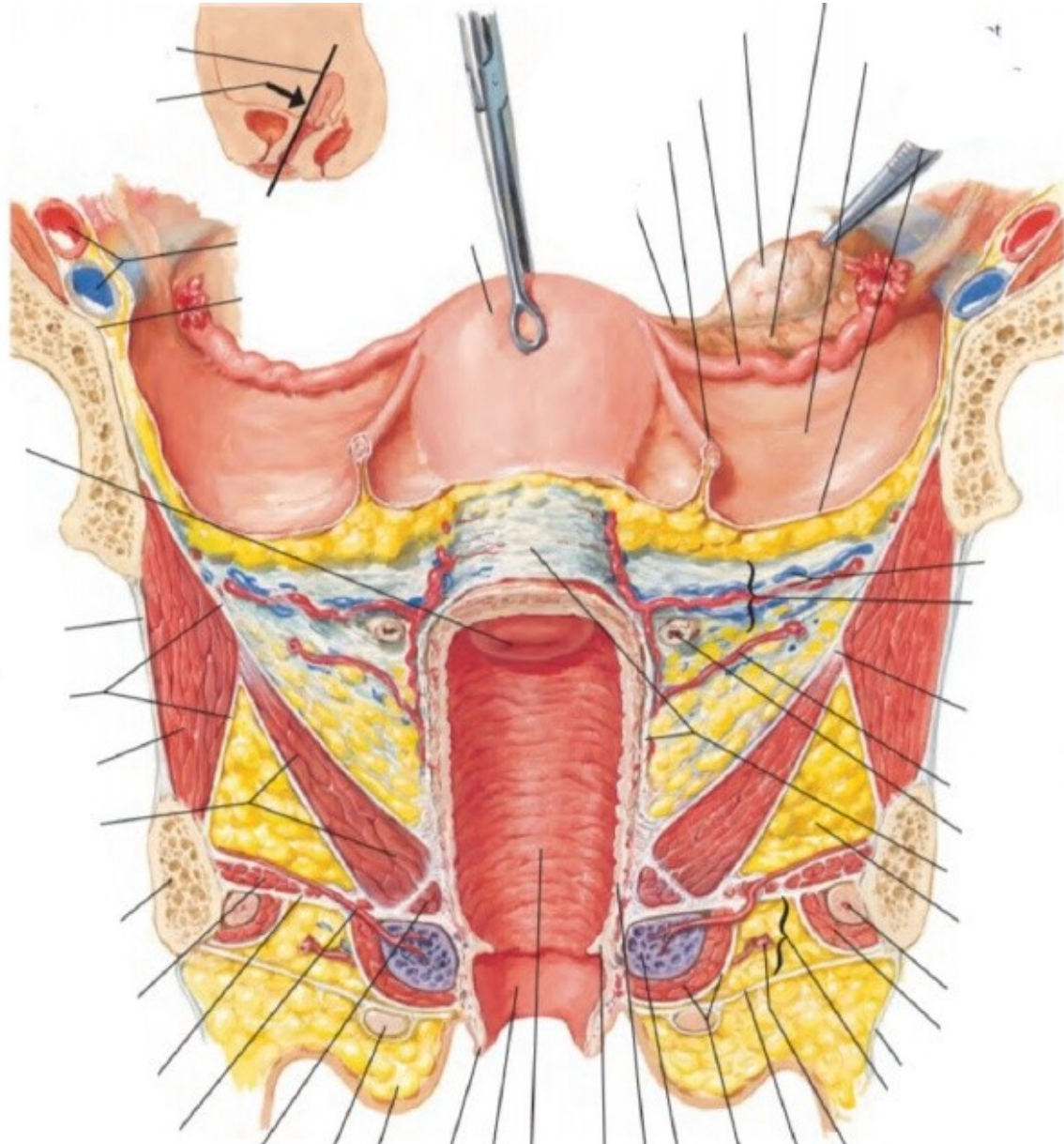


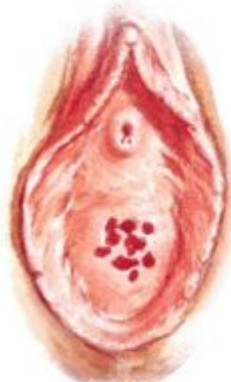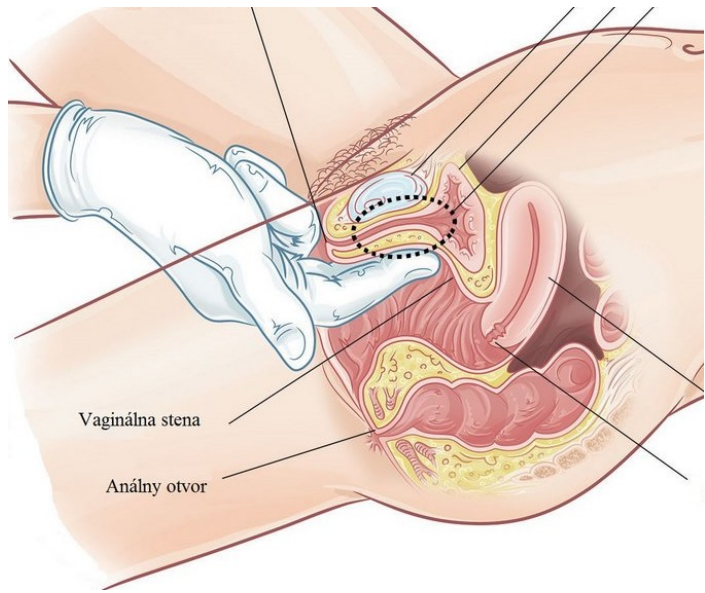
1. Uterus: structure, ligaments



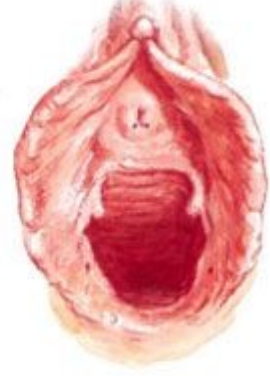

1. Vagina

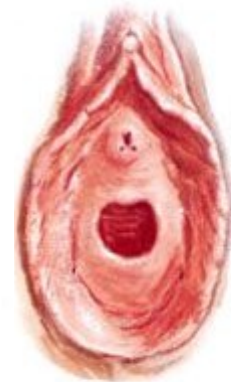



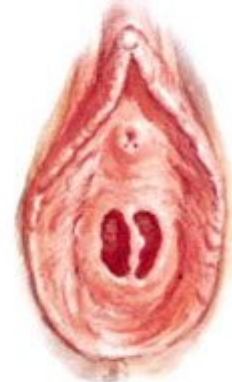Hymen cribriformis



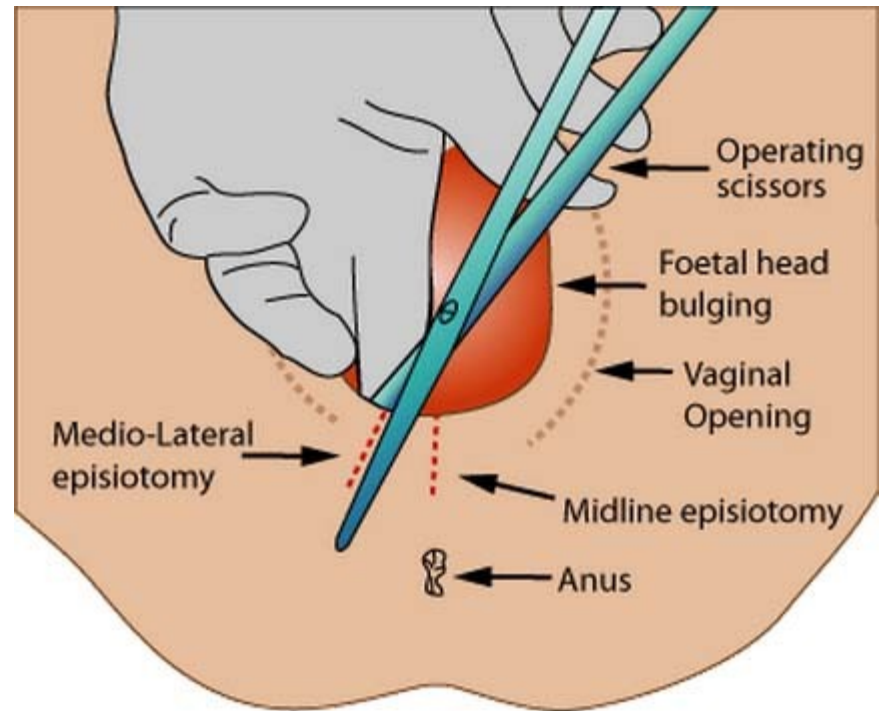
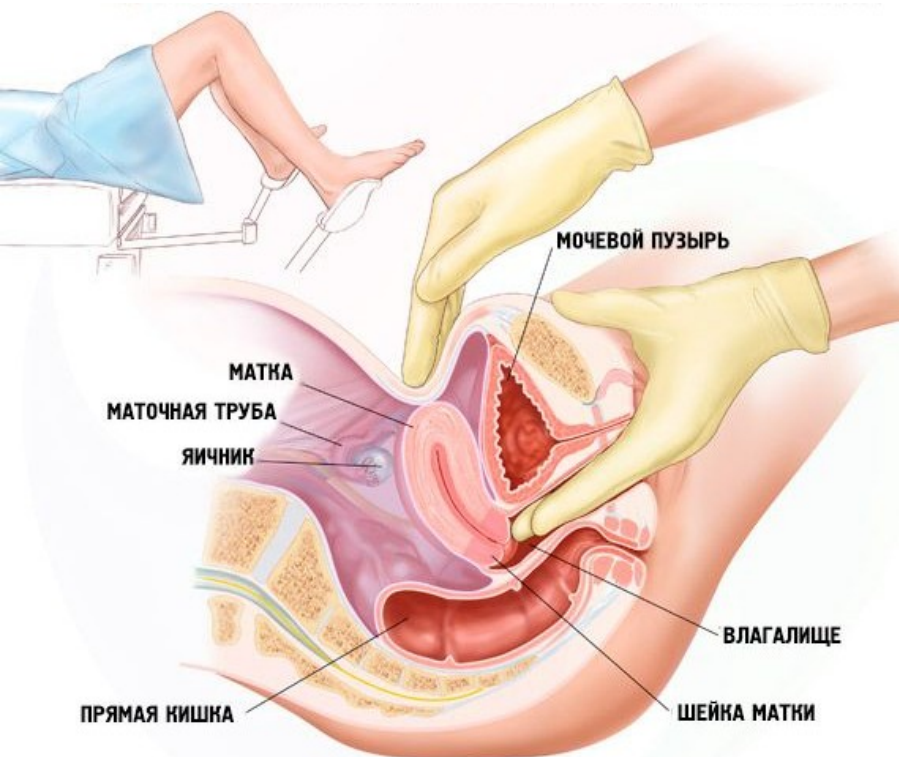
Ostium vaginae (porus introitus)

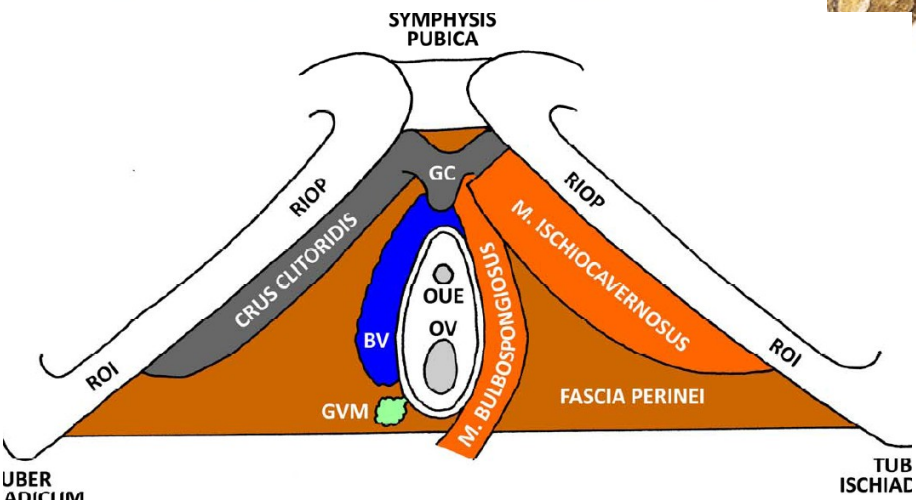
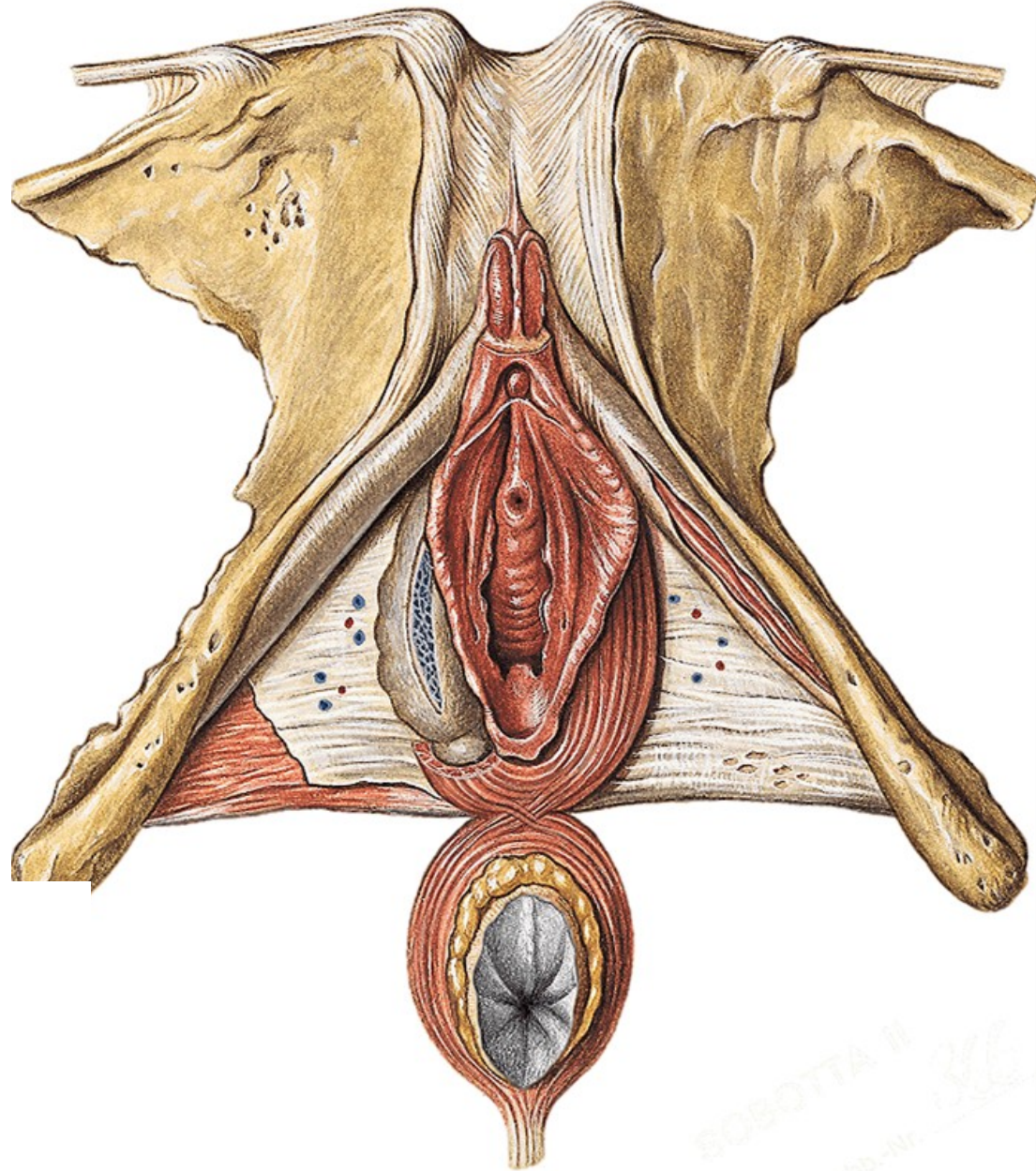
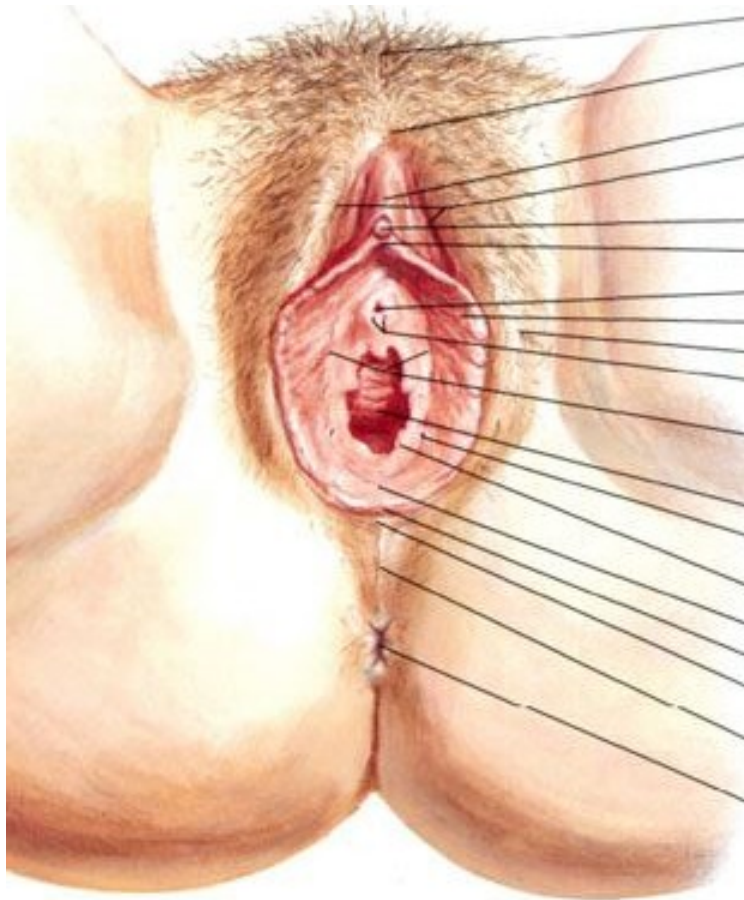


Hymen anularis



Hymen septus

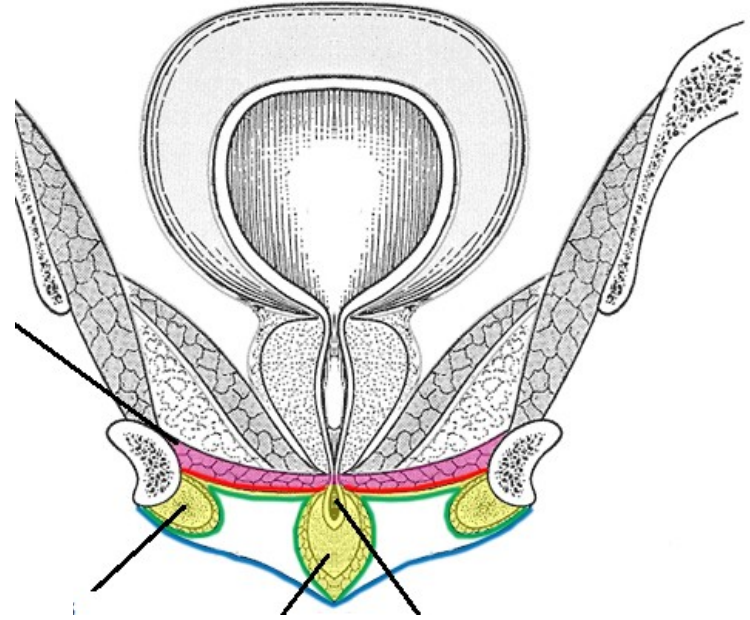
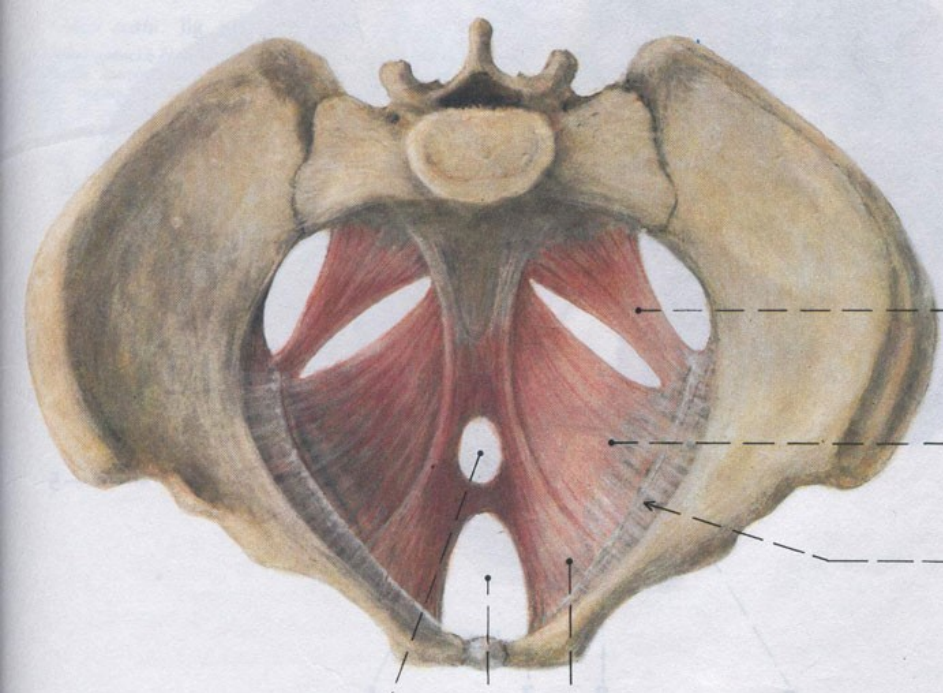
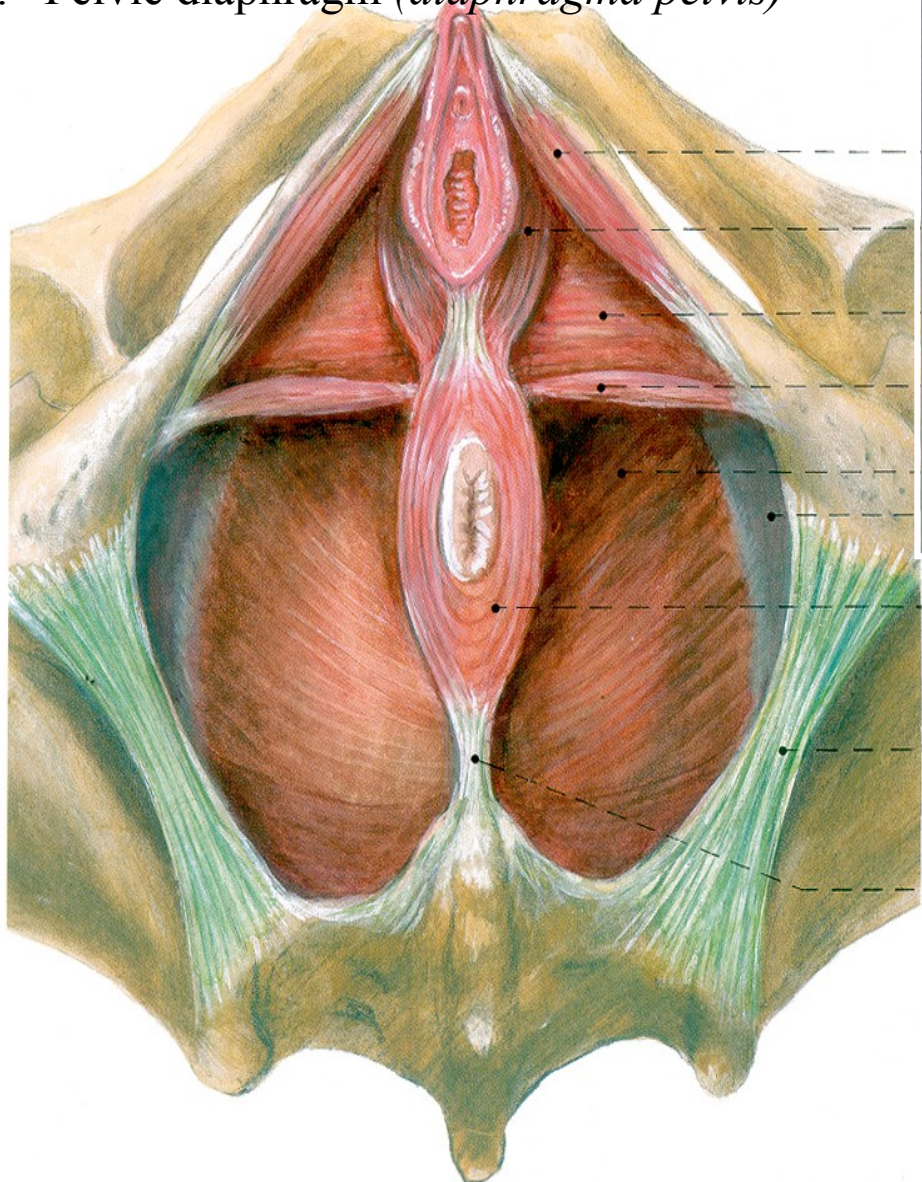


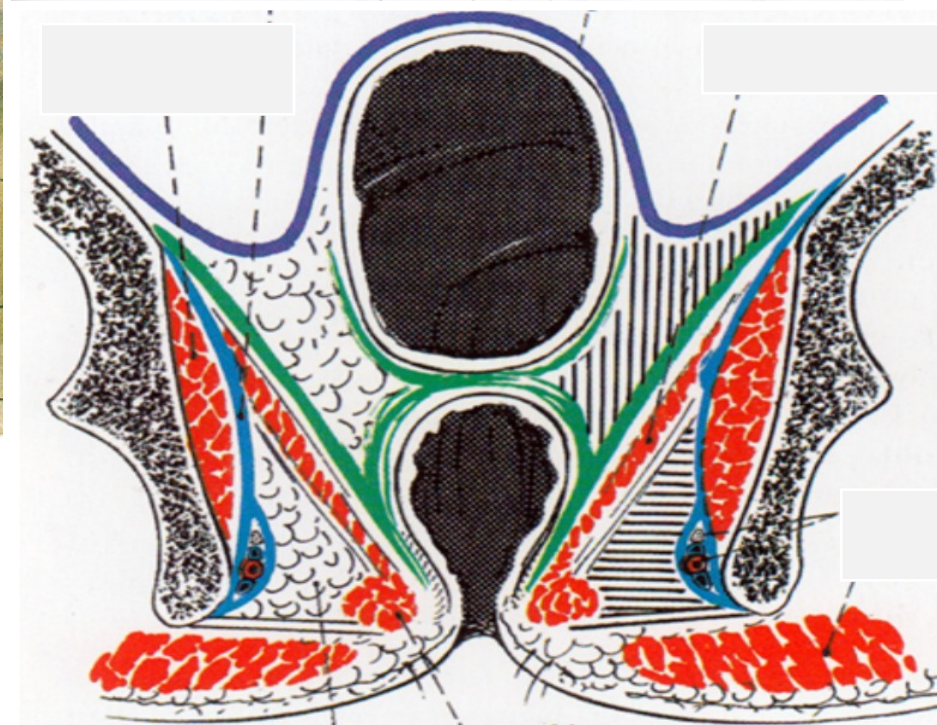
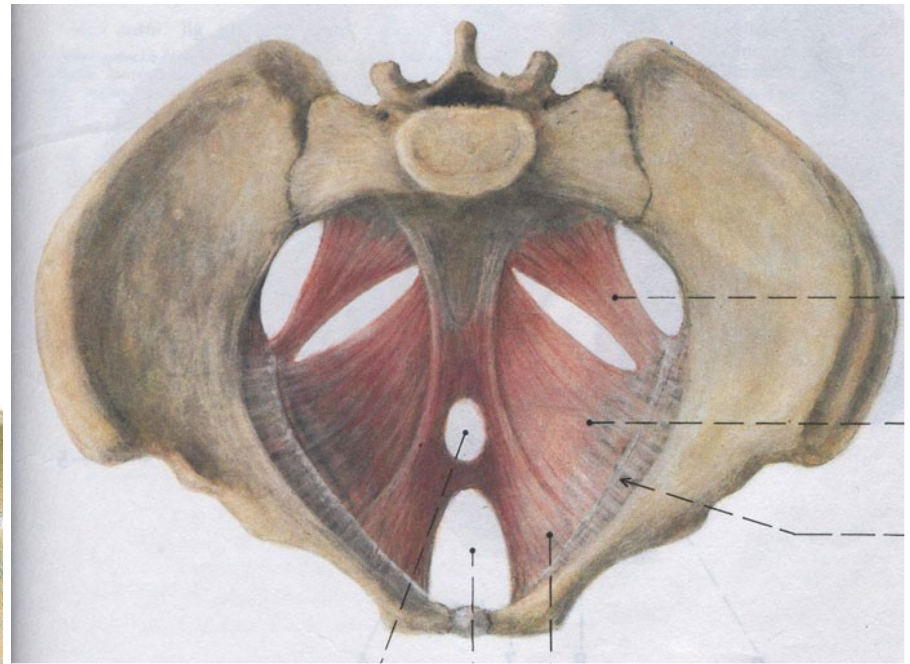
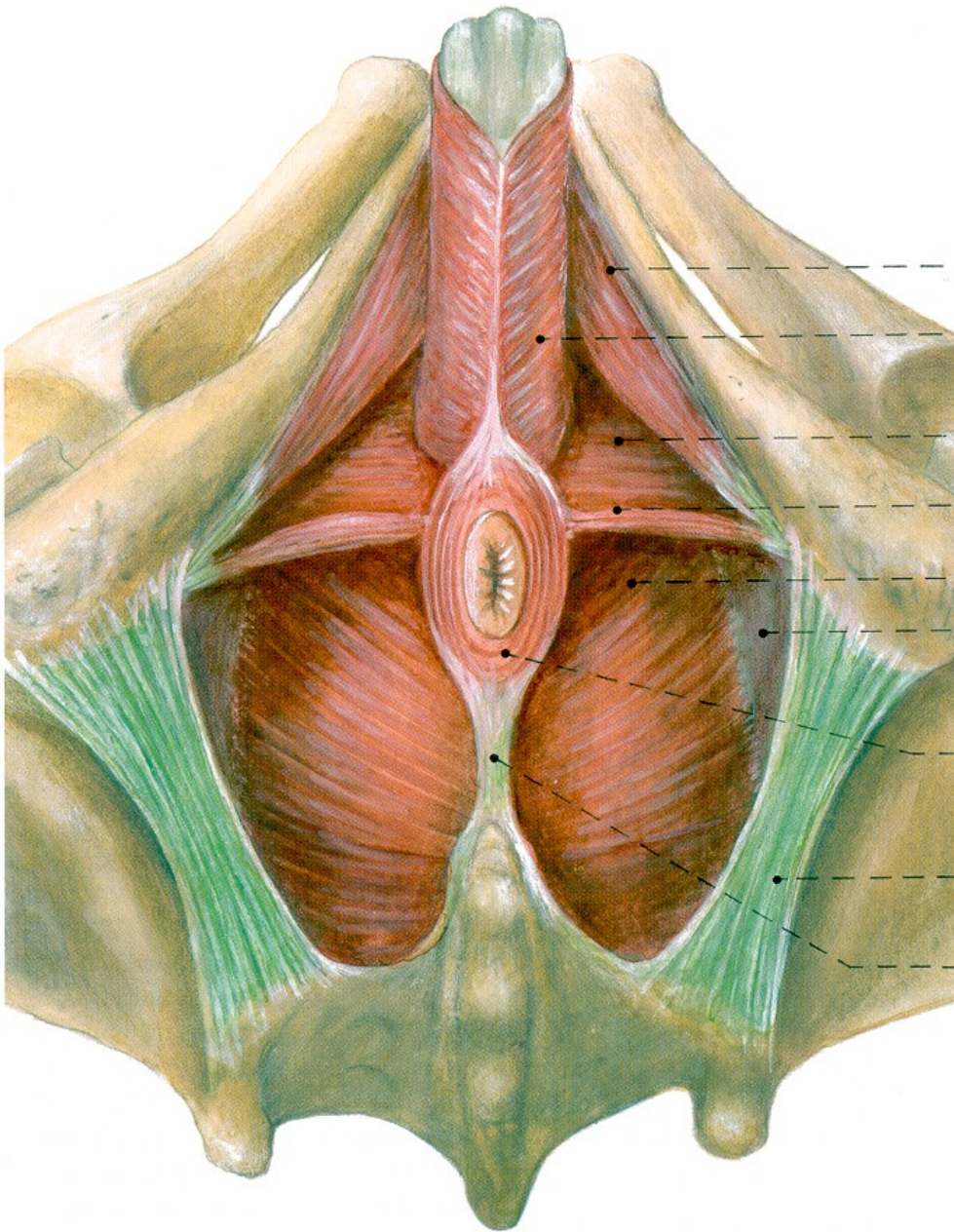


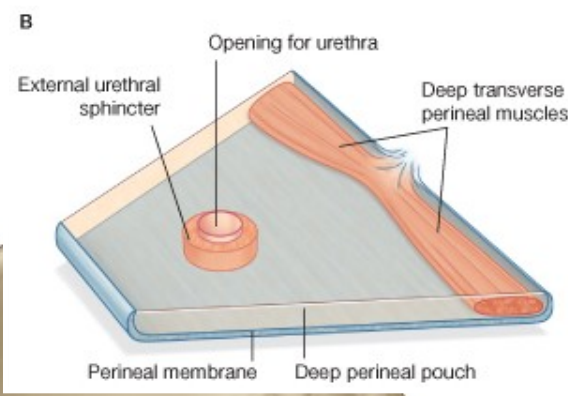
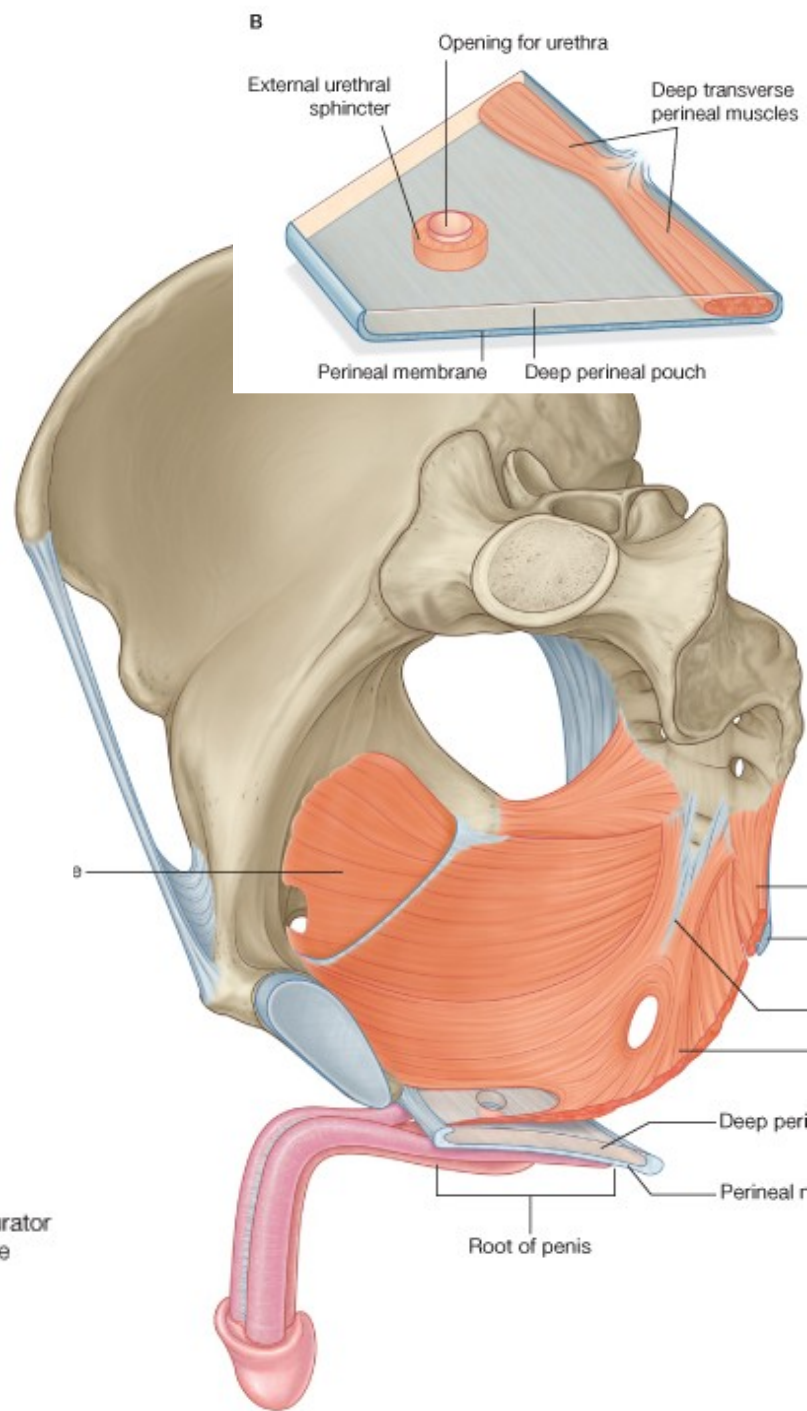
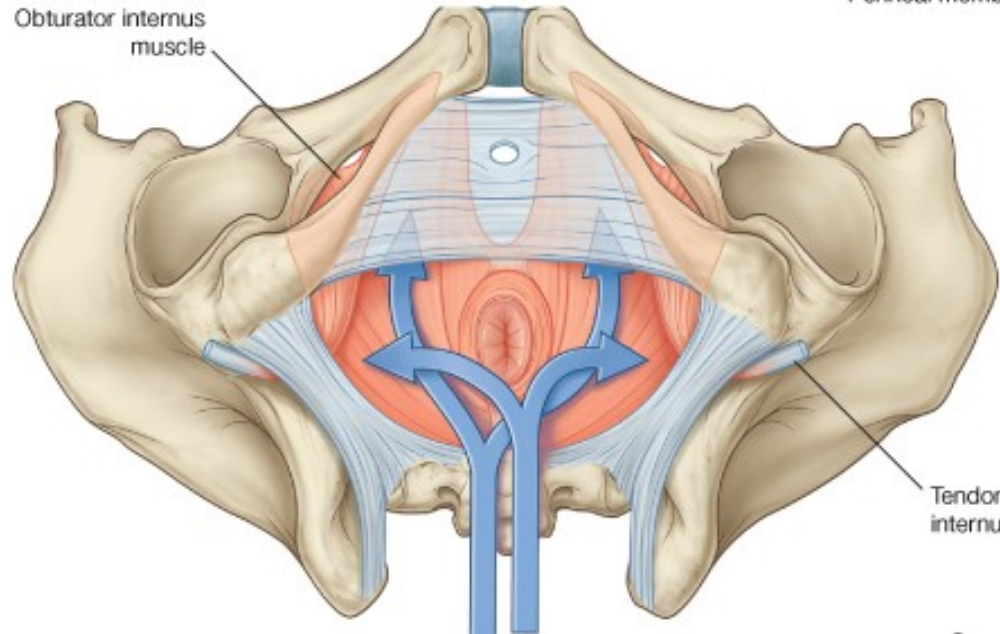
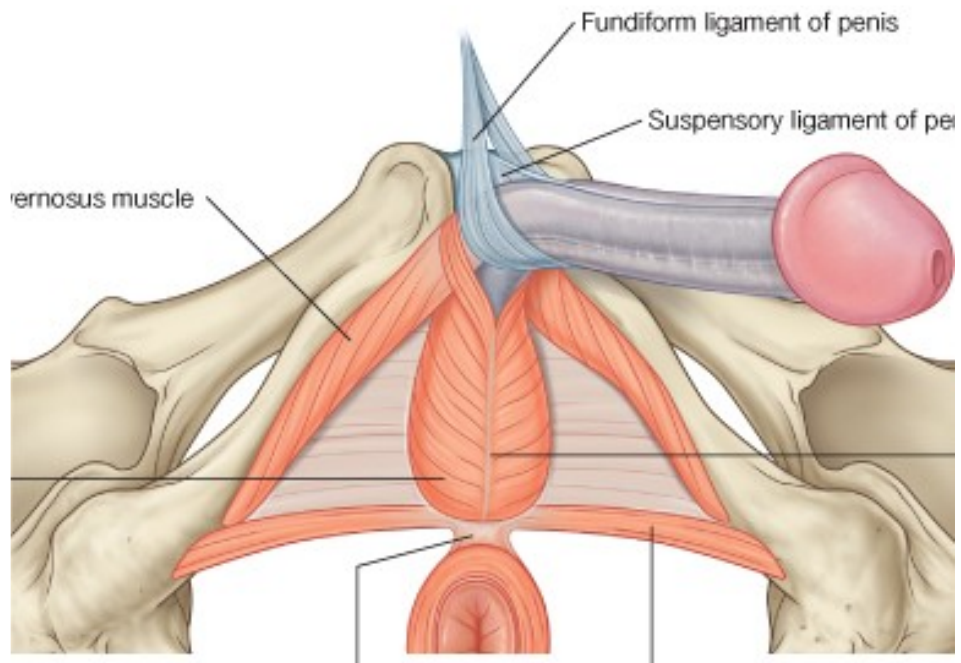
1. Female external genital organs (*organa genitalia feminina externa*)

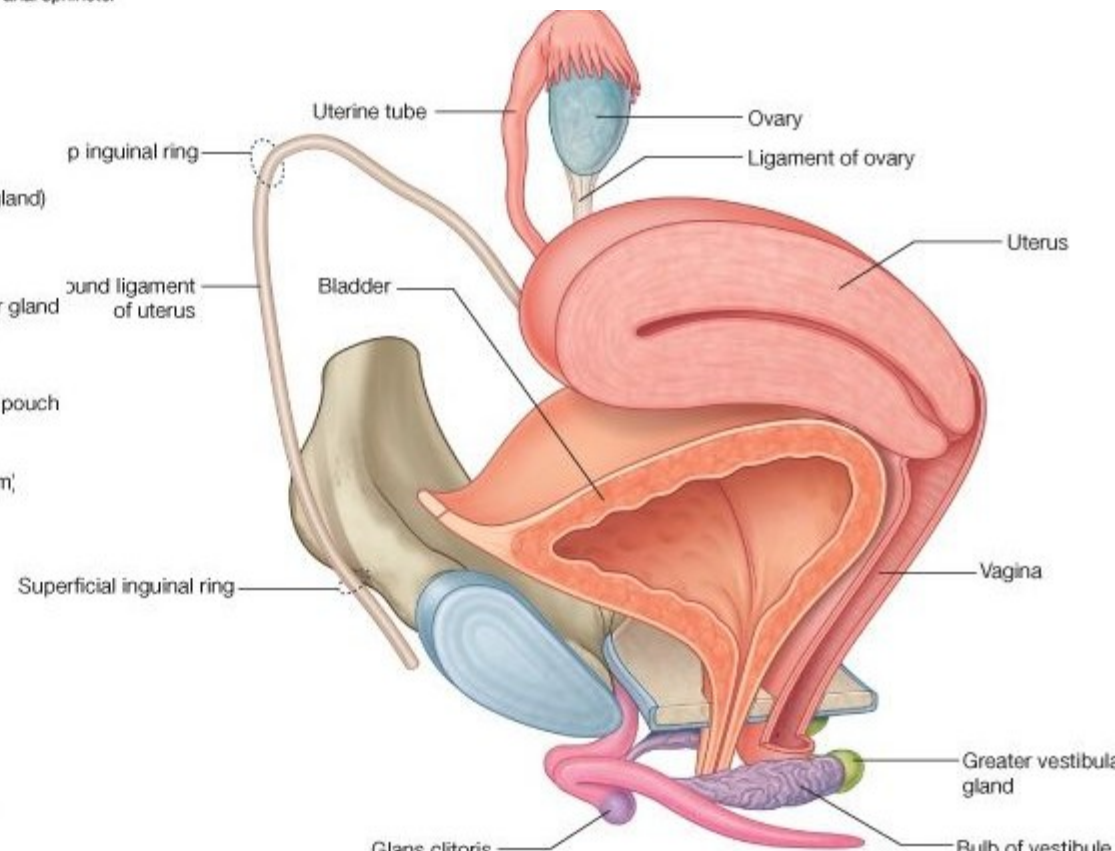
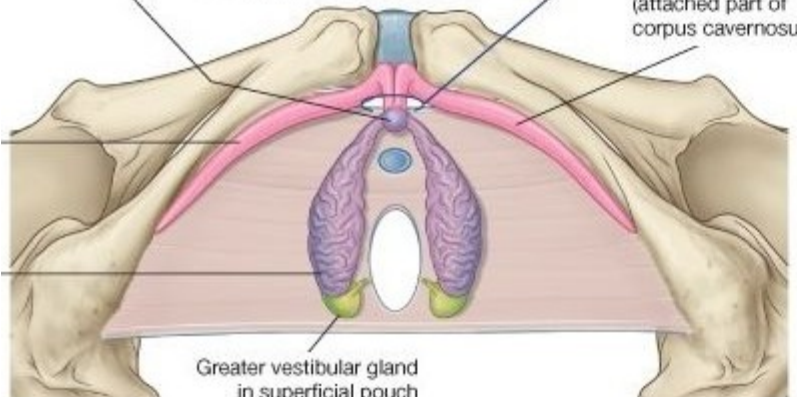
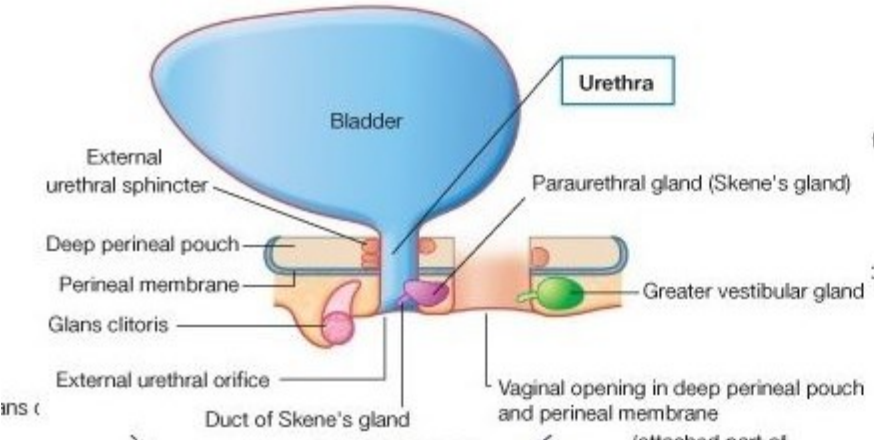
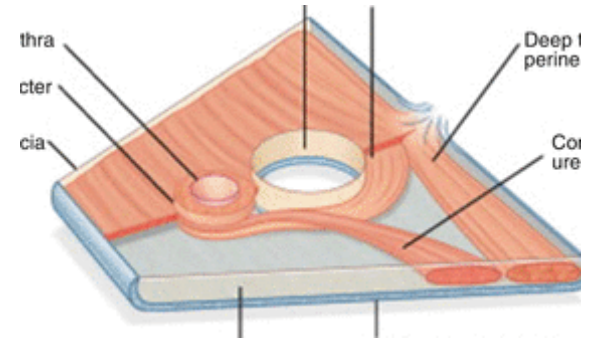
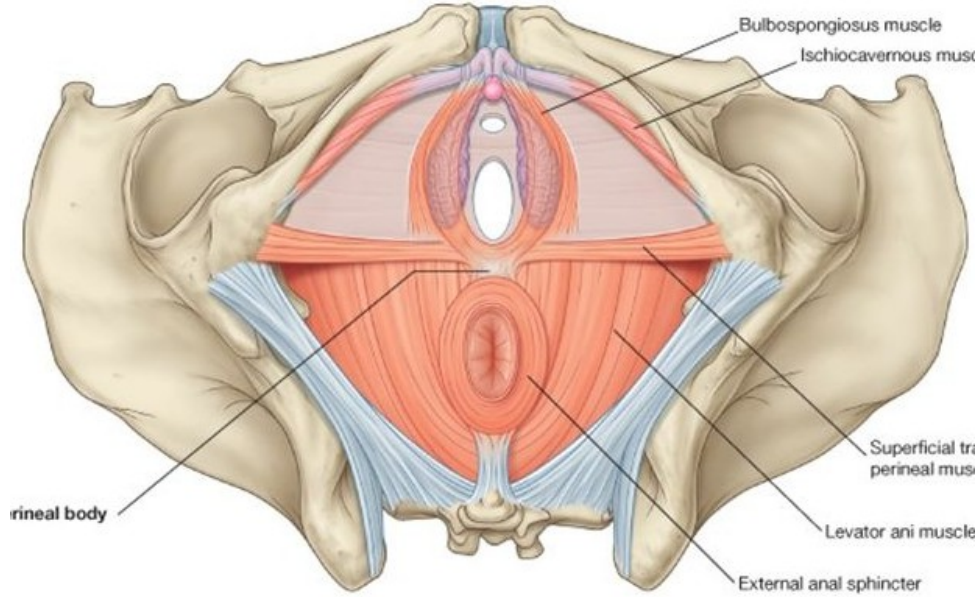
1. Female superficial and deep perineal pouches (*spatium perinei superficiale, diaphragma urogenitale femininum*)

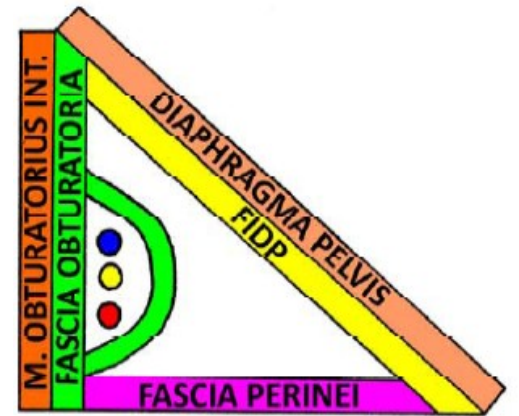
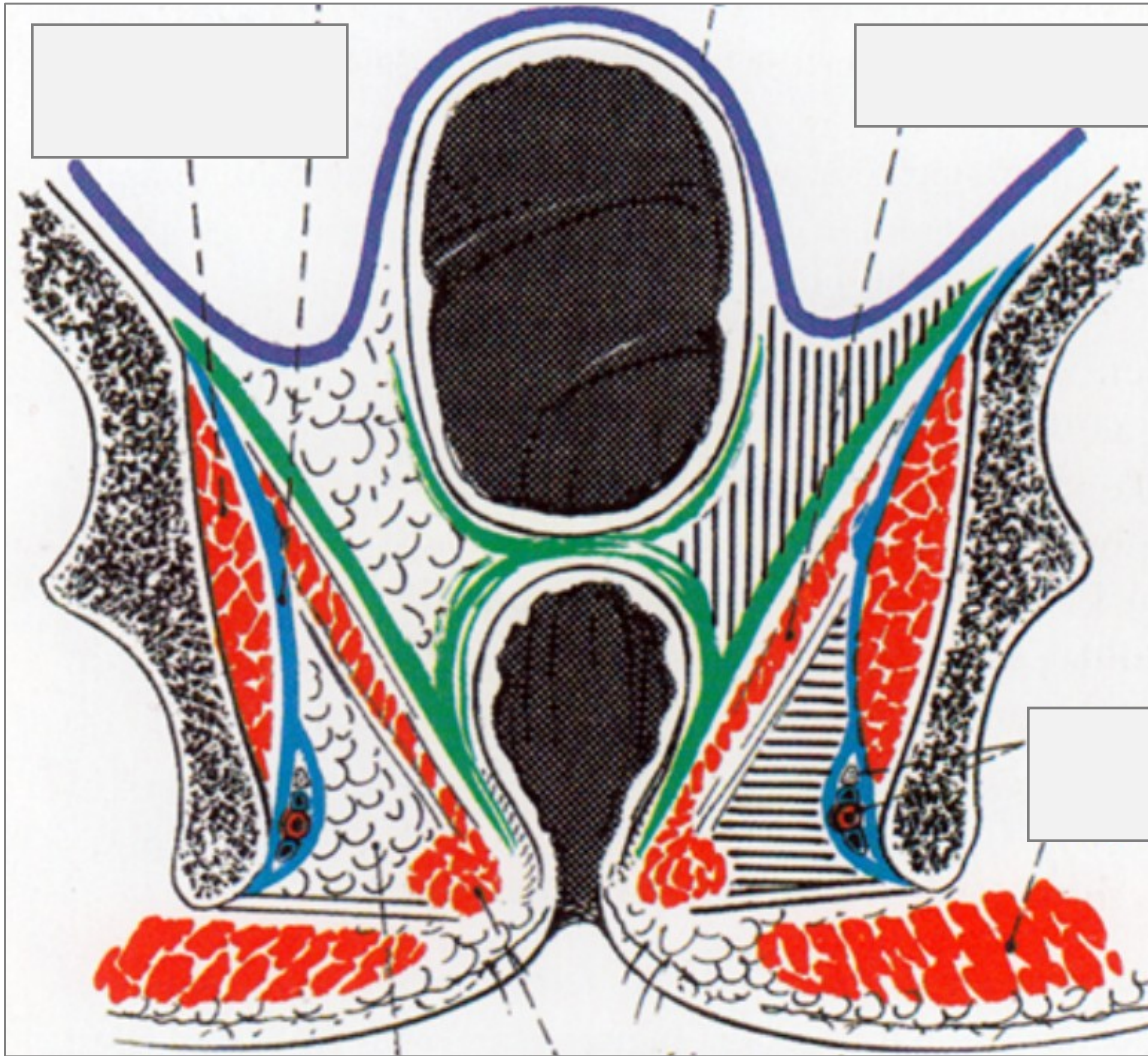
2. Pelvic diaphragm (*diaphragma pelvis*)



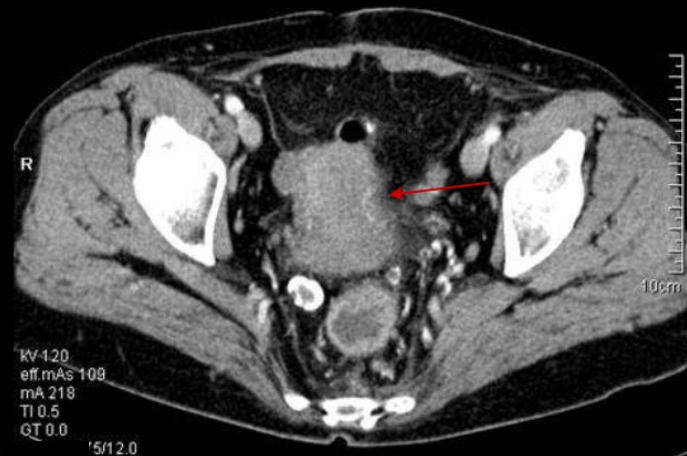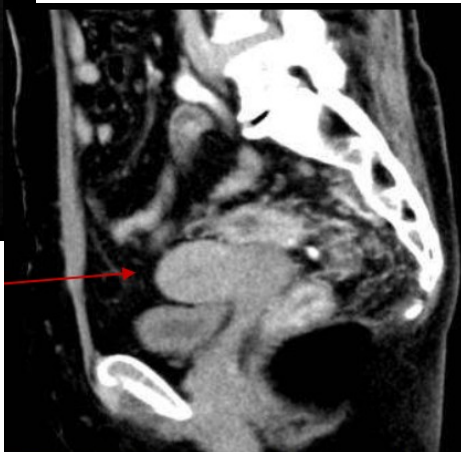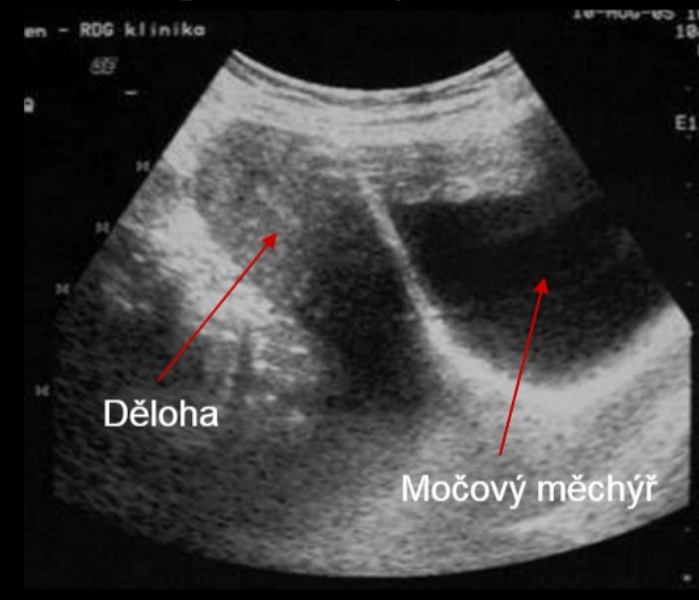




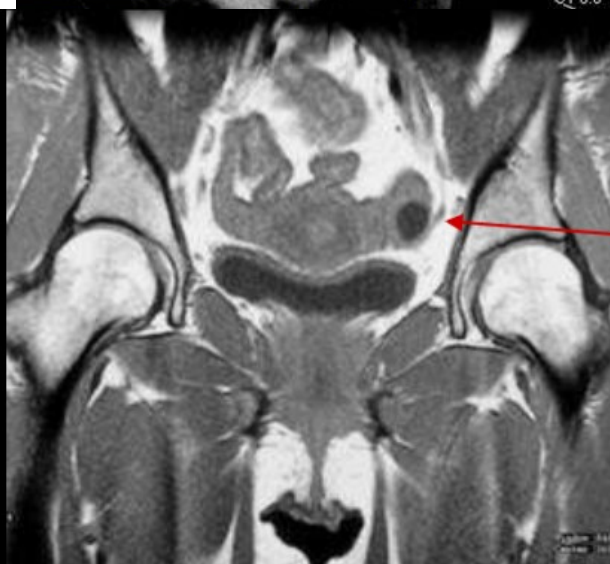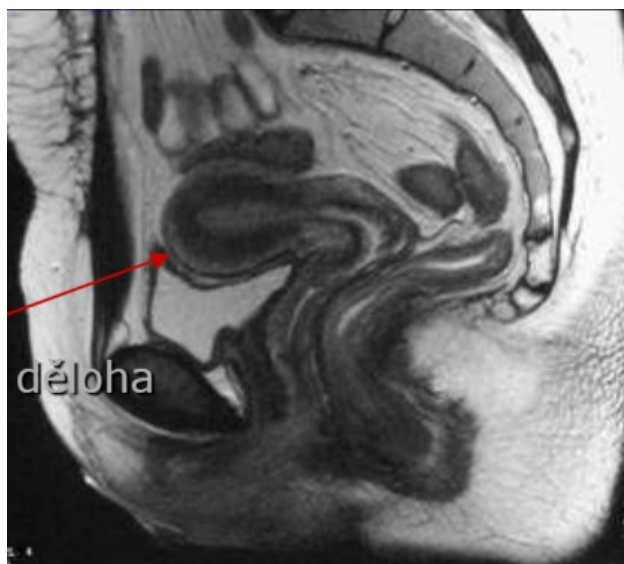




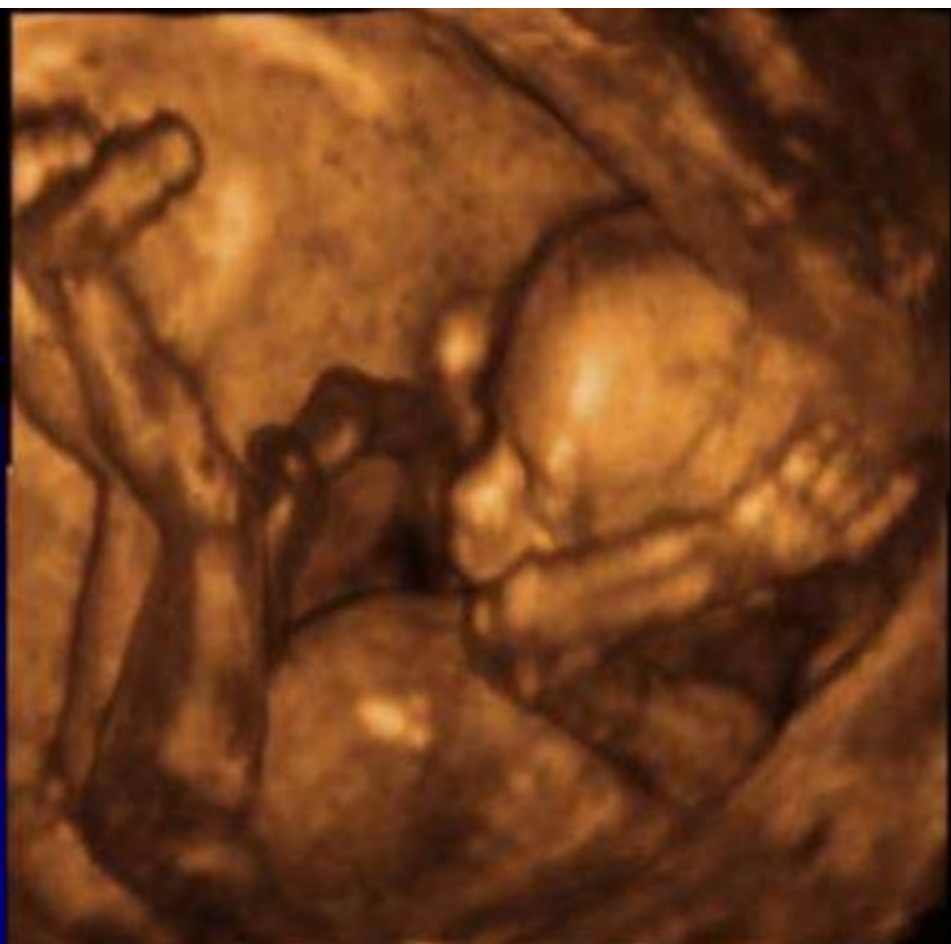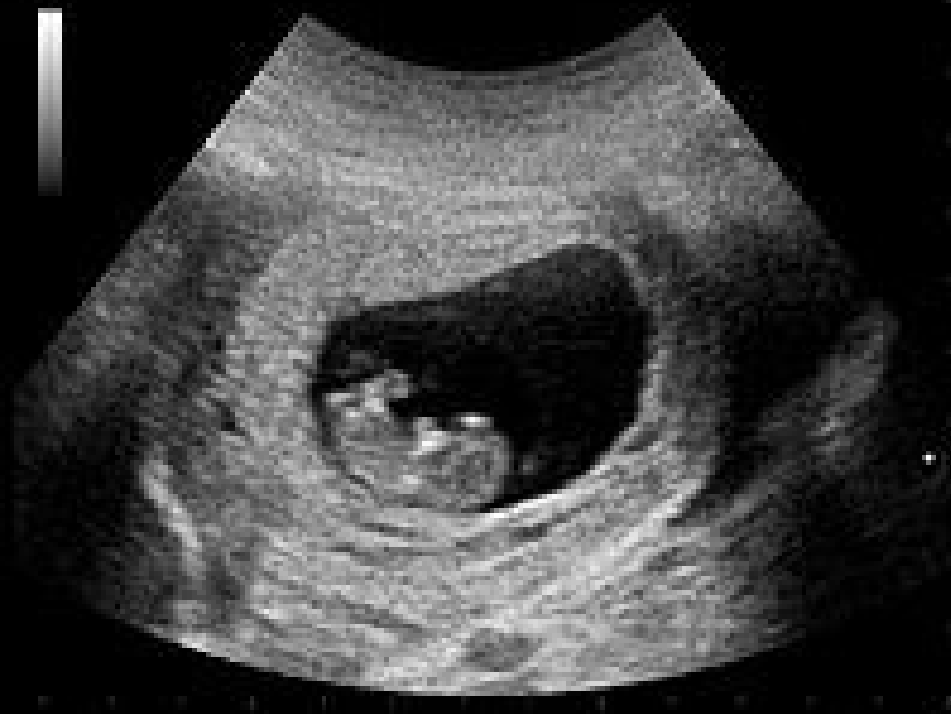Sagitální řez pánví

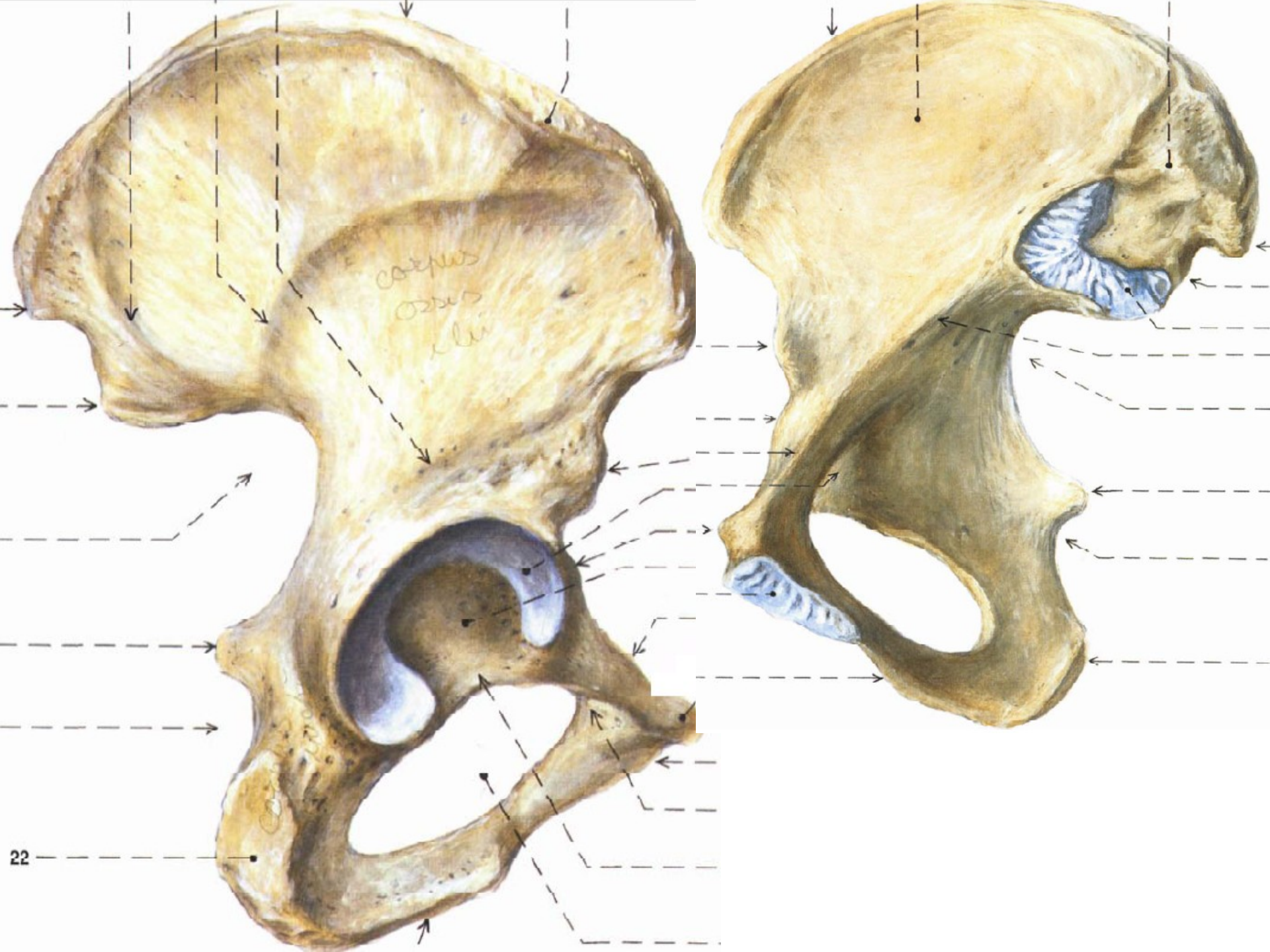


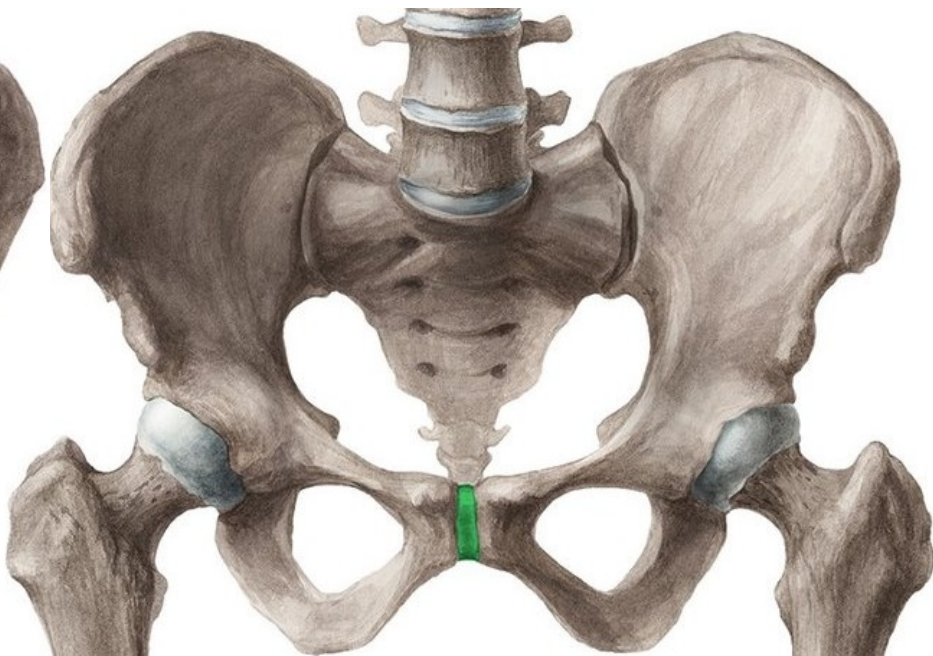
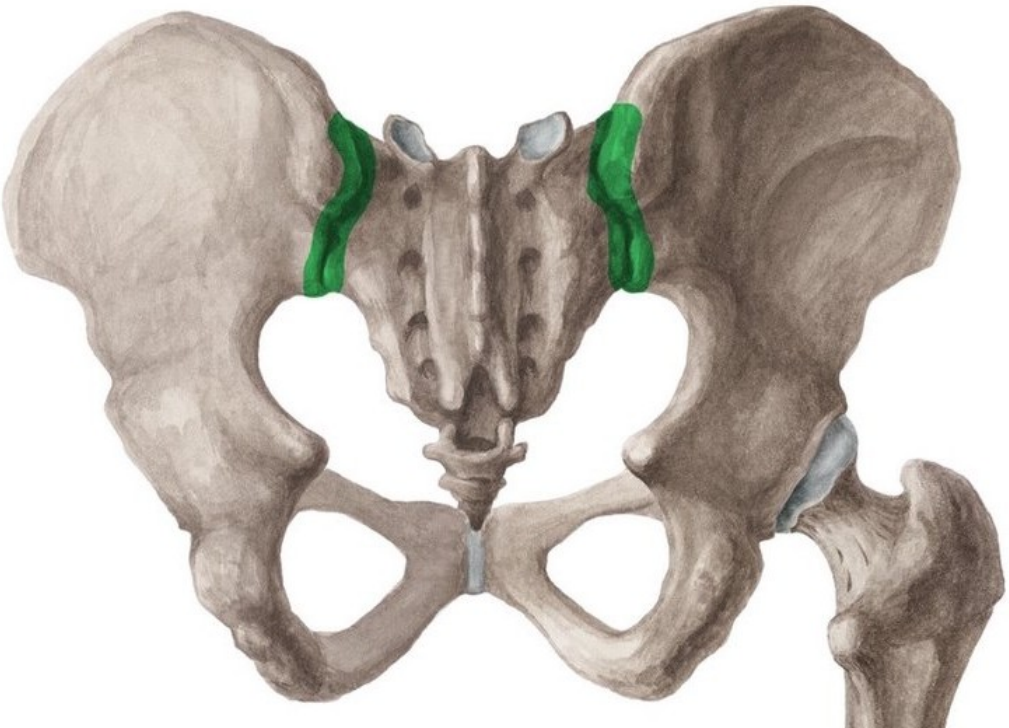
(Normální CT obraz dělohy)

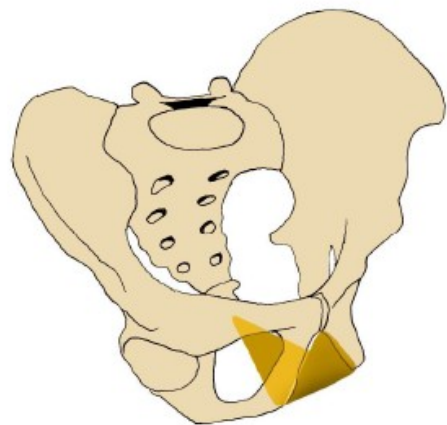
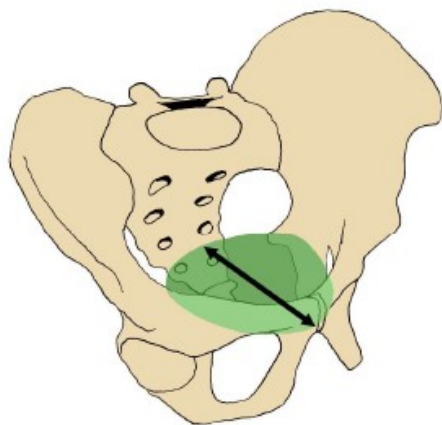
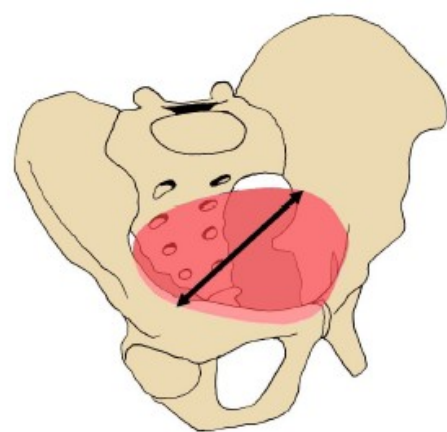
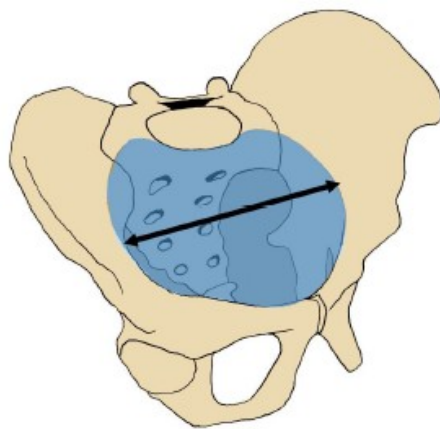
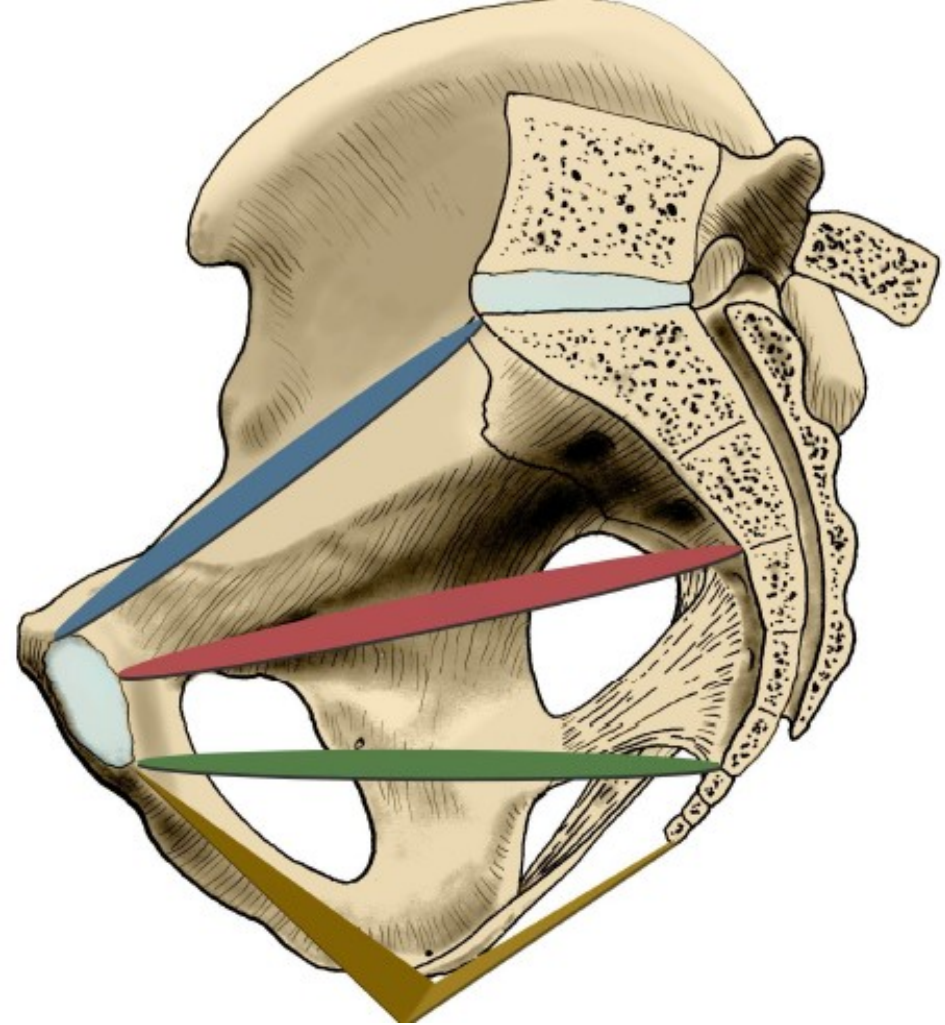


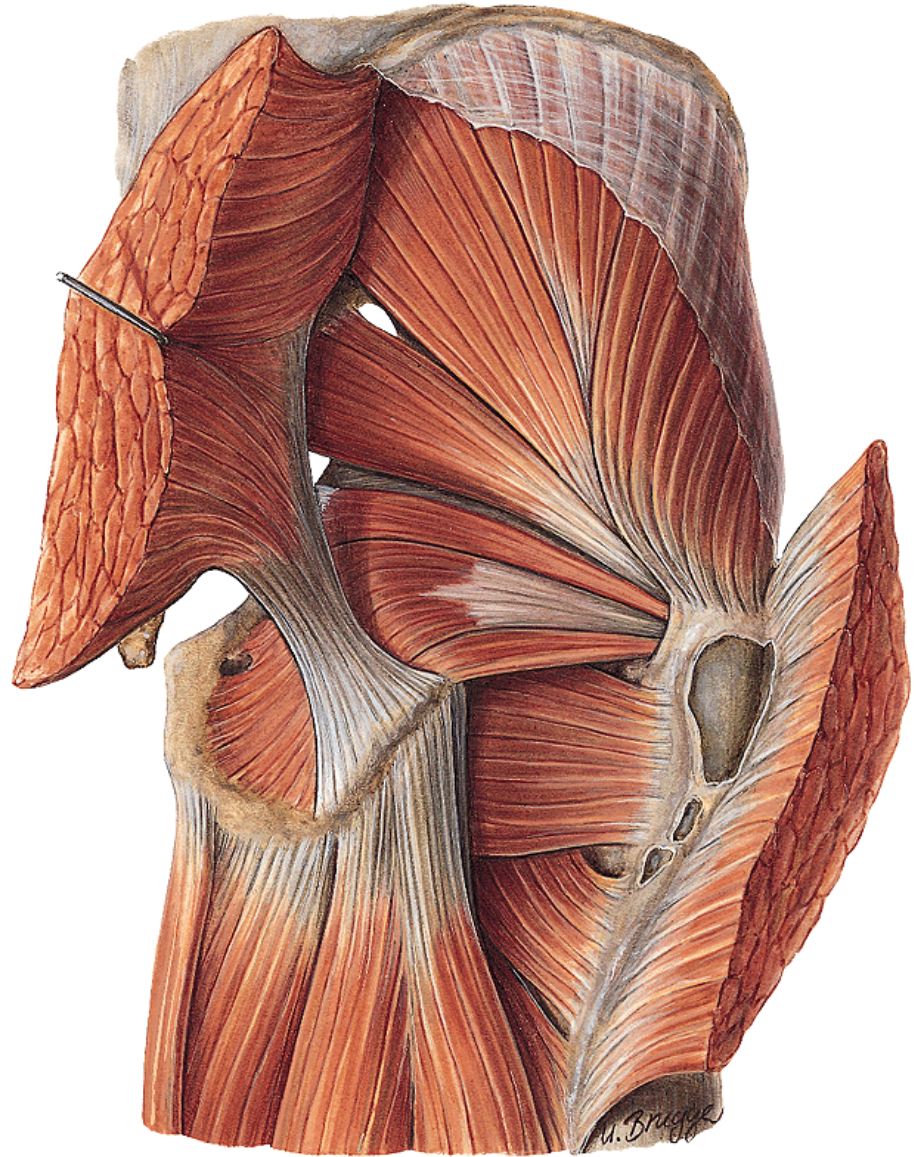
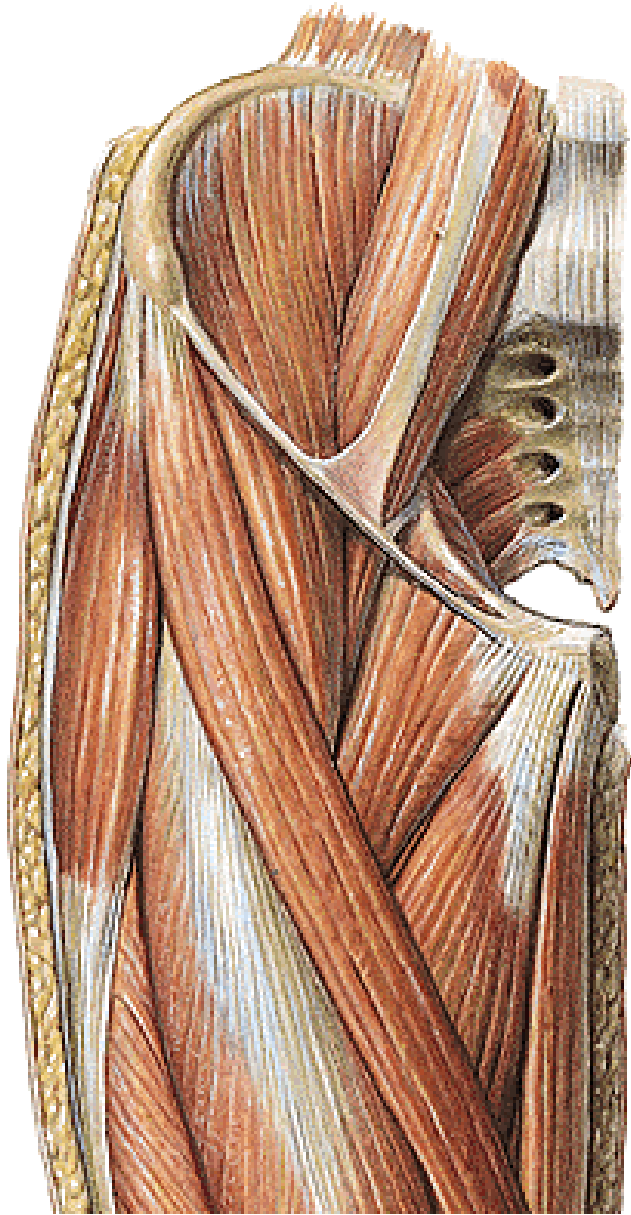
15 CM XV
PAC 11-1-8 PEE
PST 3



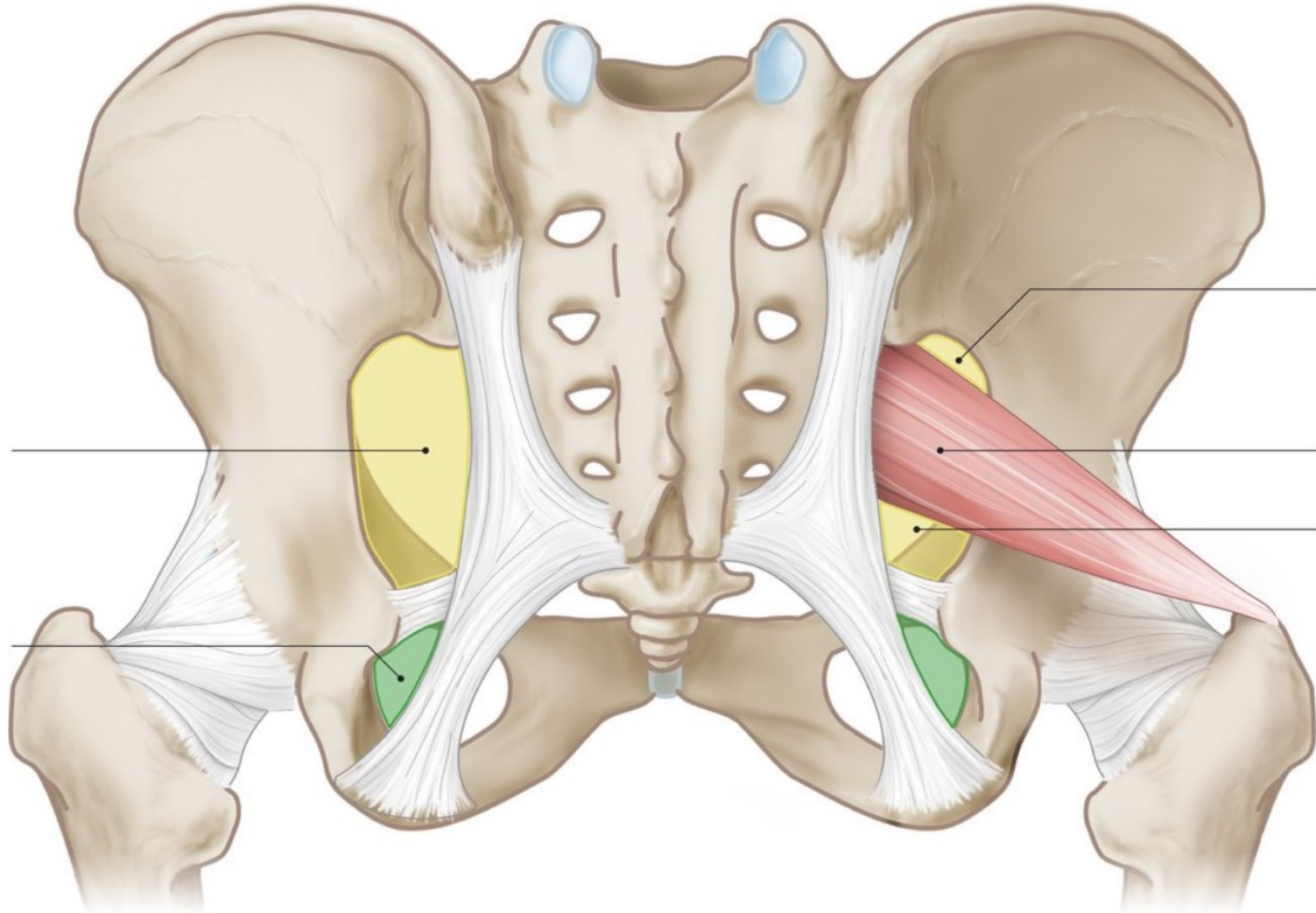








Foramen ischiadicum majus et minus:



Lacuna musculorum et vasorum:

Canalis inguinalis:

Peritoneal folds (anterior abdominal wall):