

POJIVOVÉ TKÁNĚ I – vazivo:

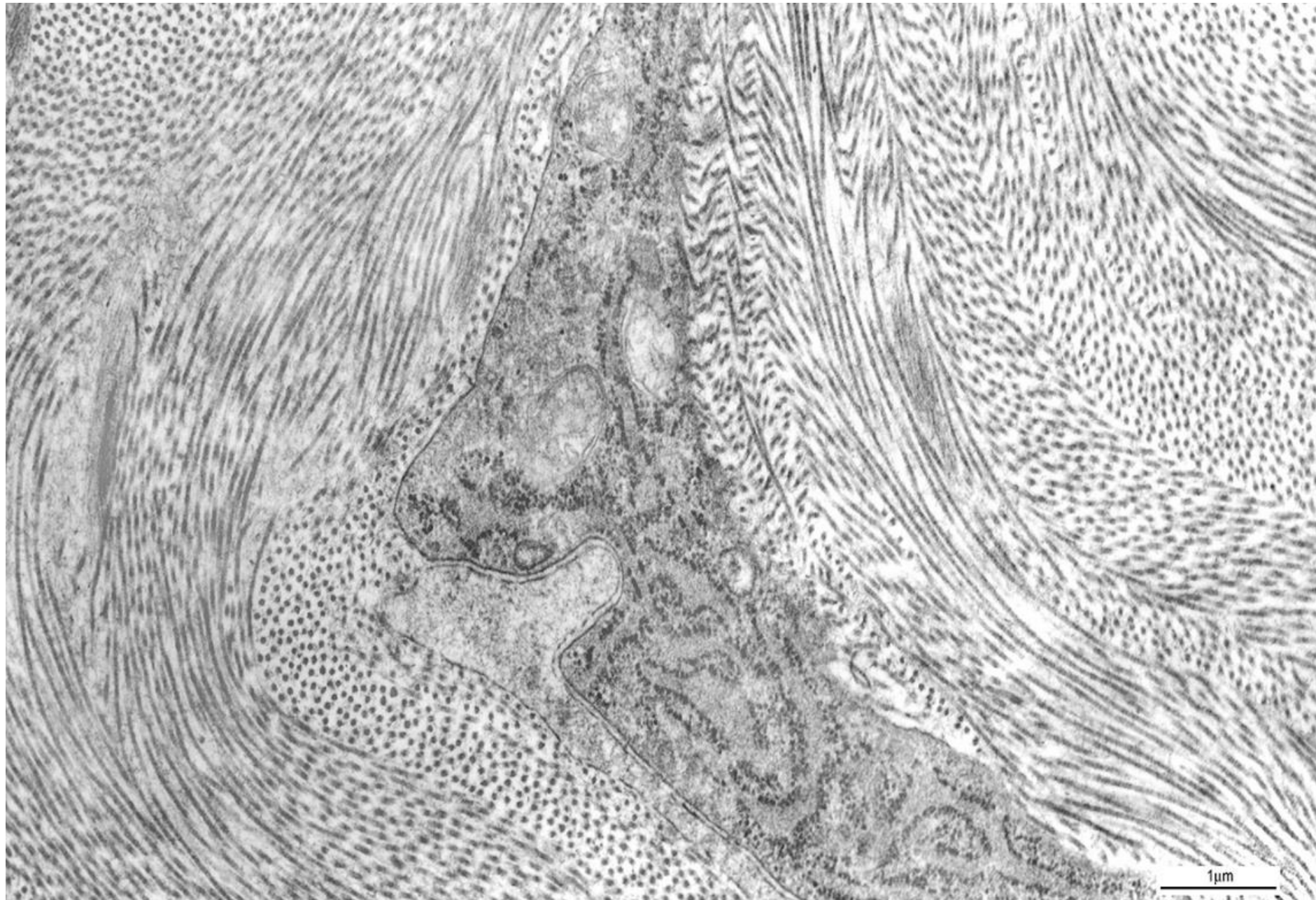
Buňky vaziva

Mezibuněčná hmota - vláknitá složka

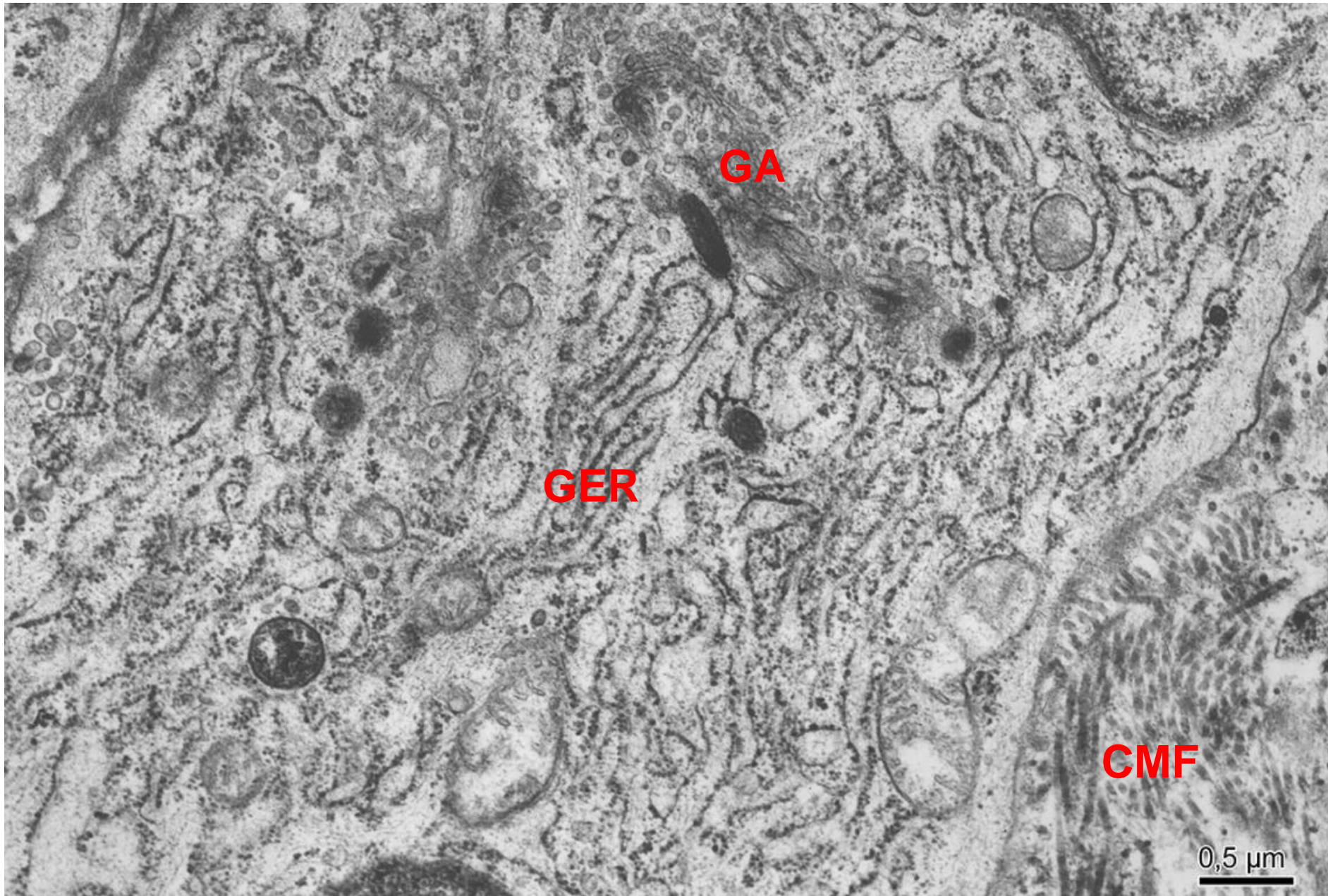
- základní hmota amorfní

Rozdělení vaziva

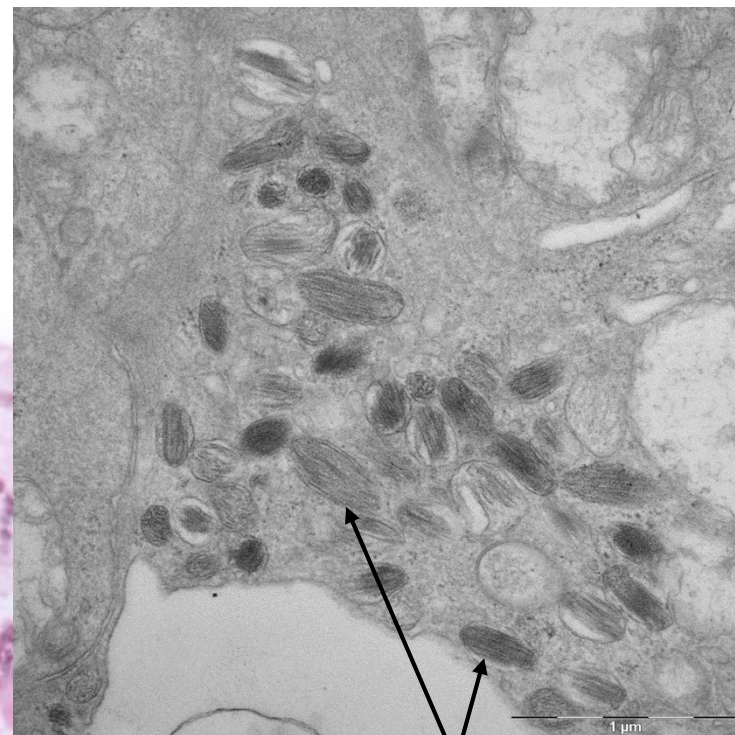
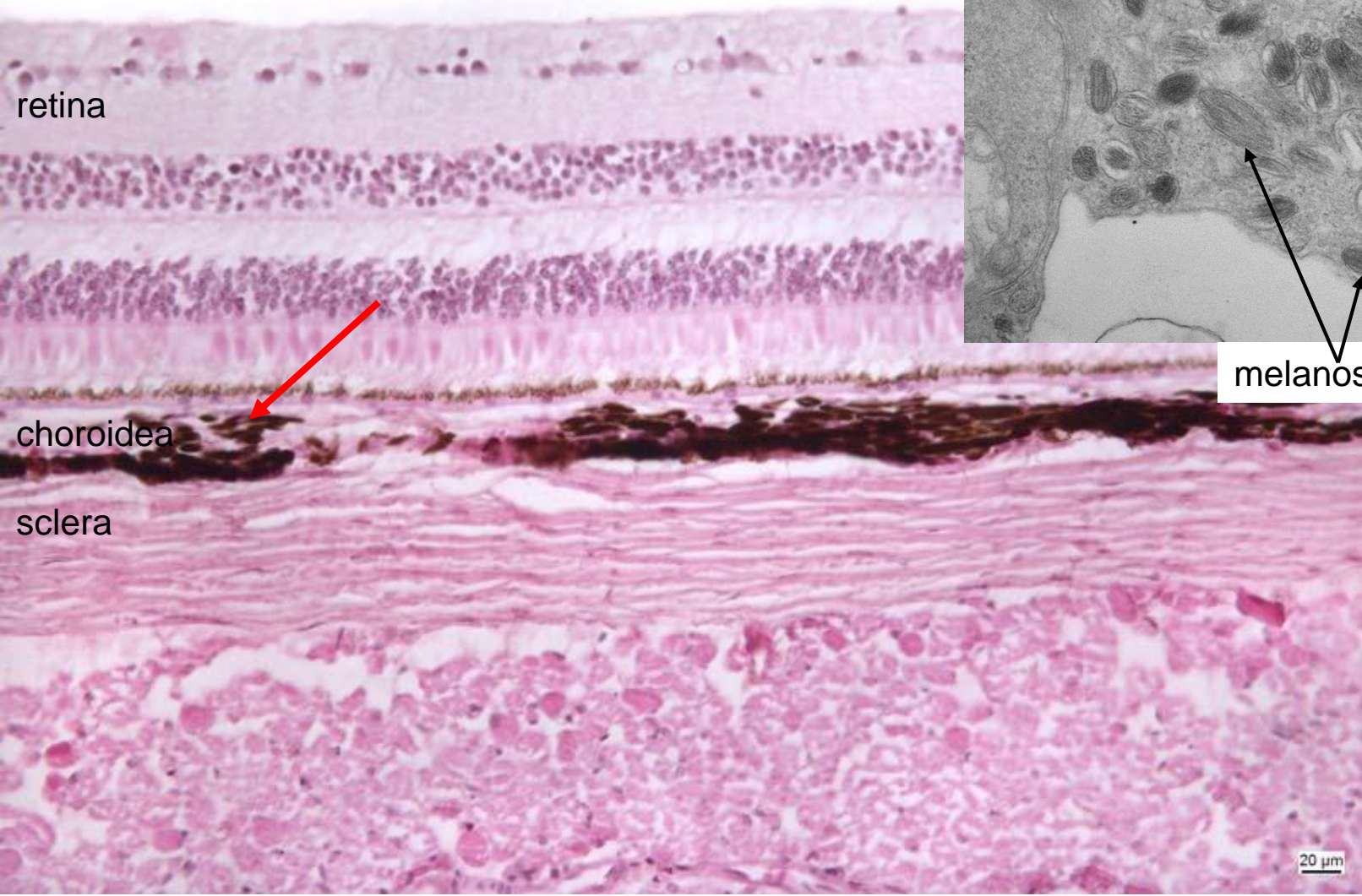
Fibroblast + kolagenní vlákna



Fibroblast – aktivní buňka

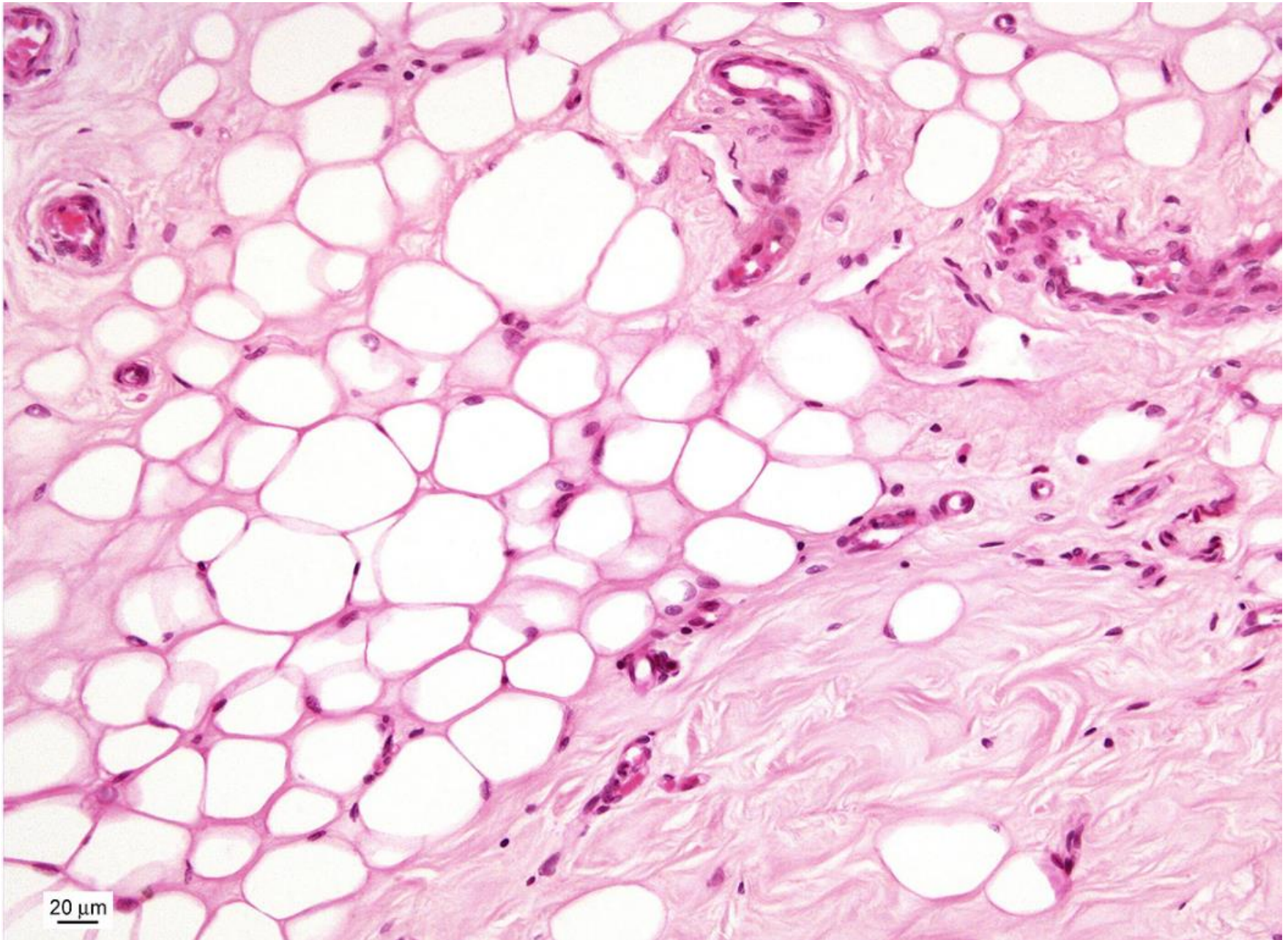


Pigmentové buňky



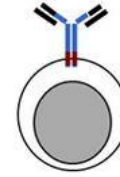
melanosomy

Adipocyt

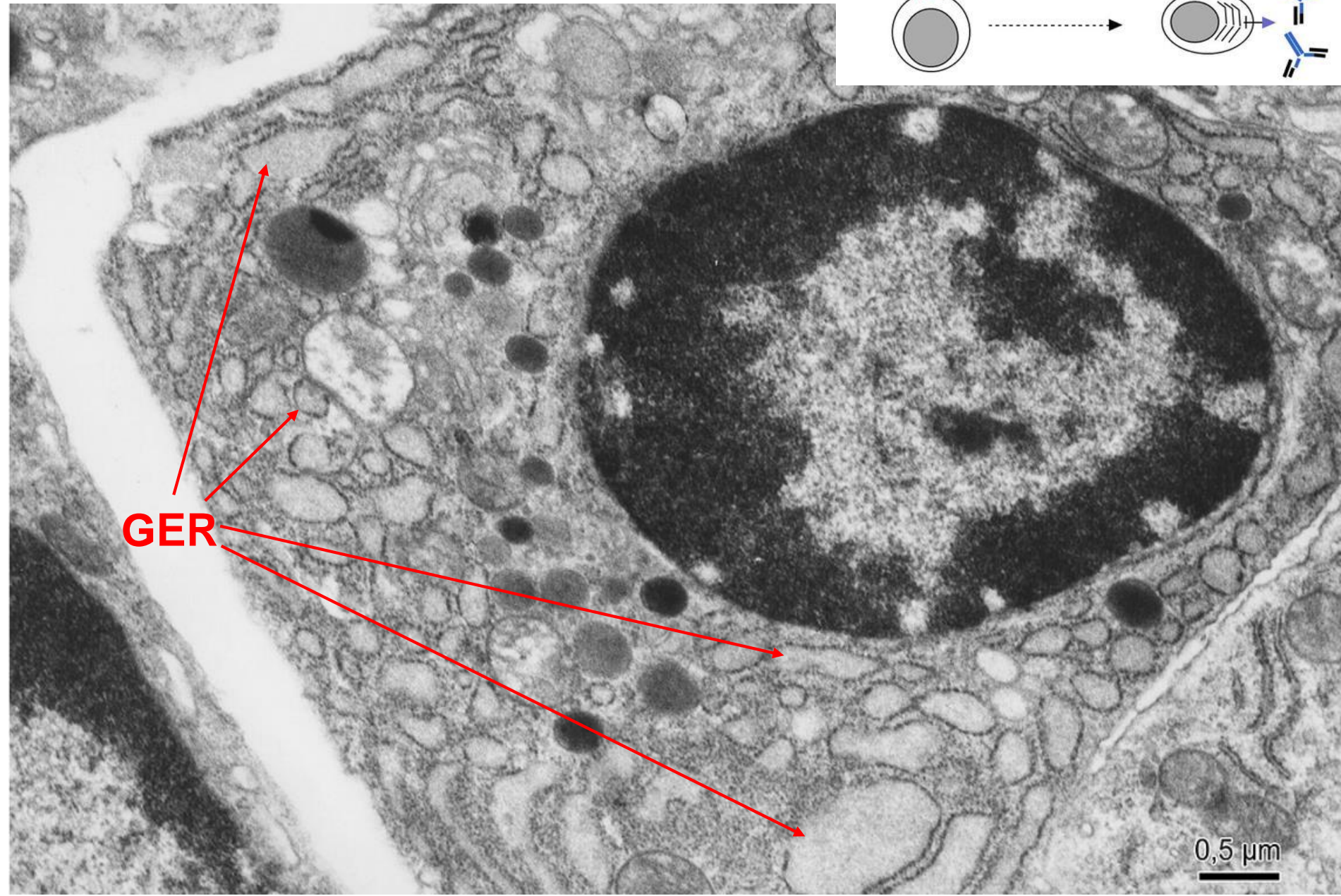
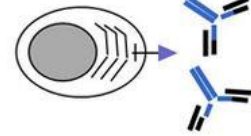


Plazmatická buňka

B cell
membrane Ig (BCR)



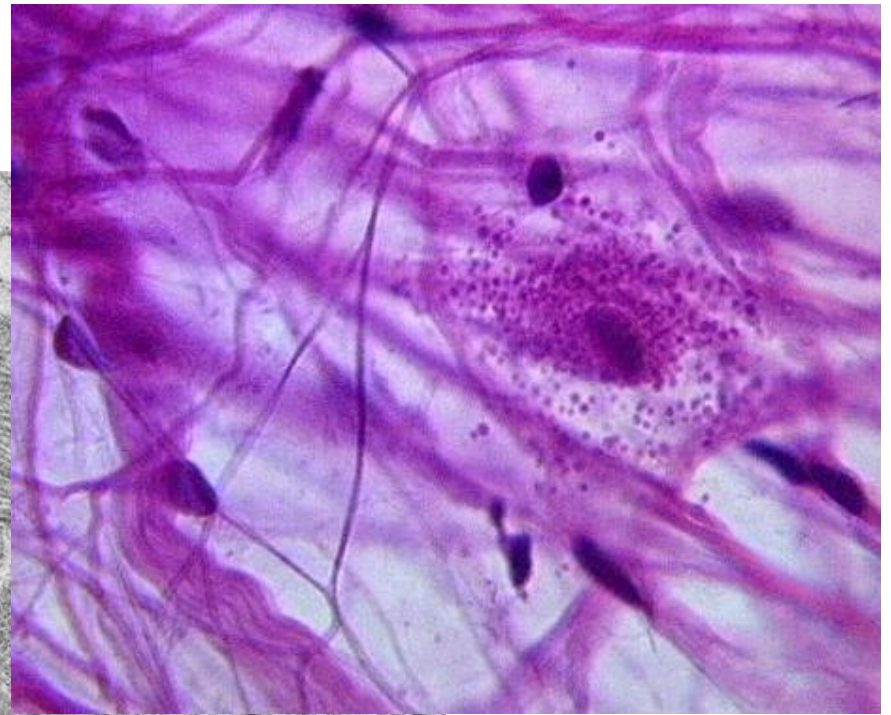
Plasma Cell
secretory Ig (Ab)



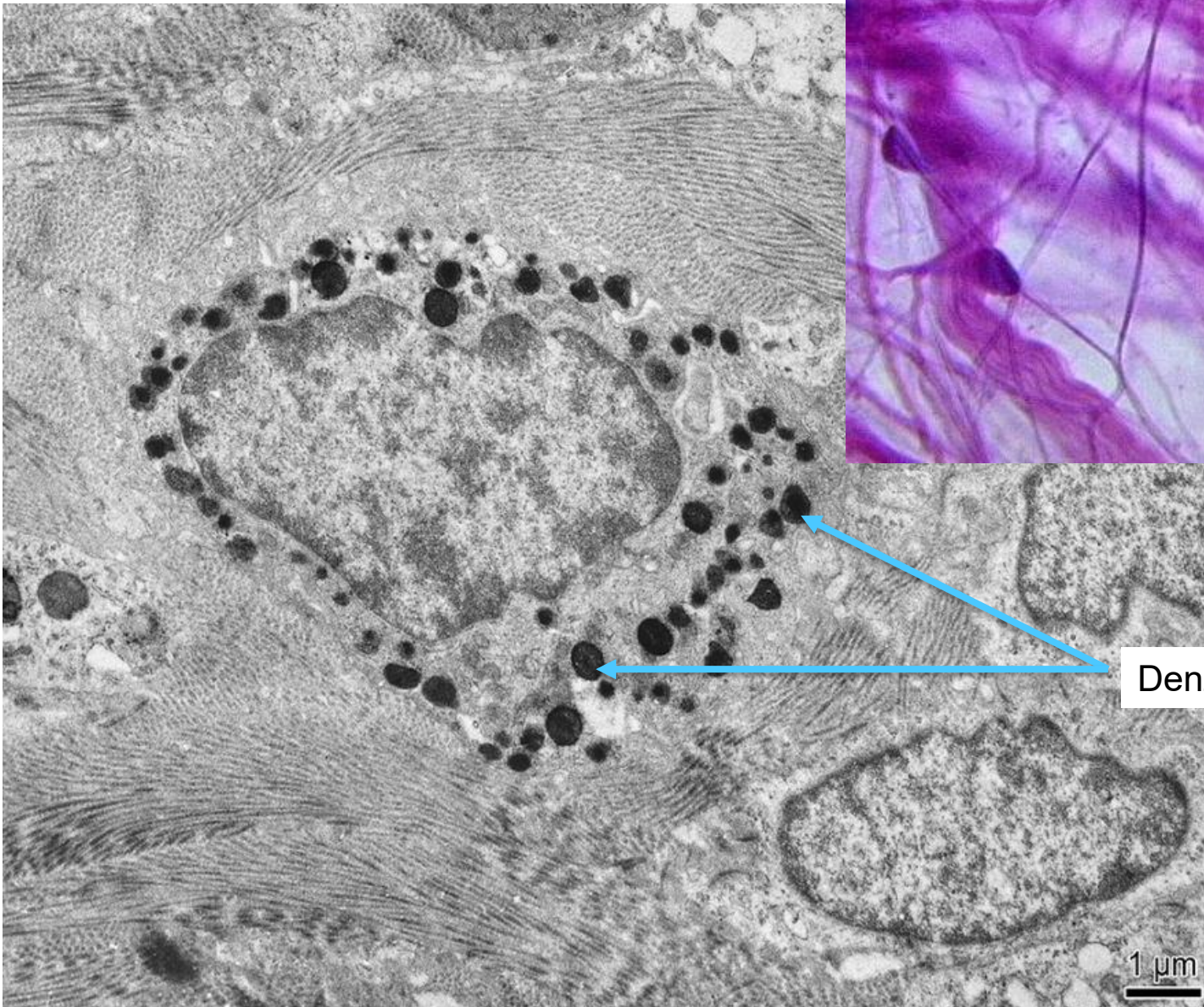
GER

0,5 μm

Žírná buňka



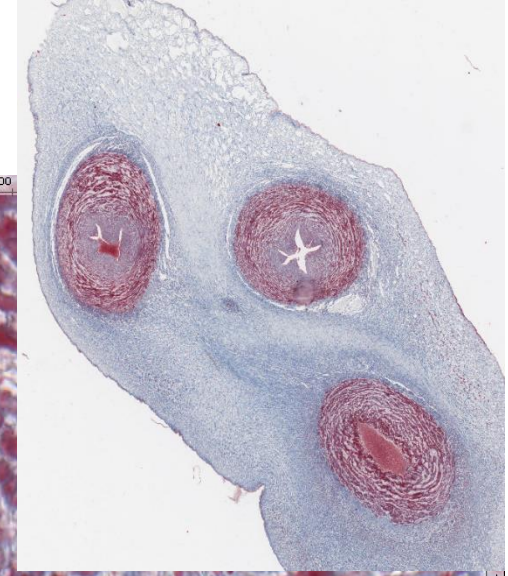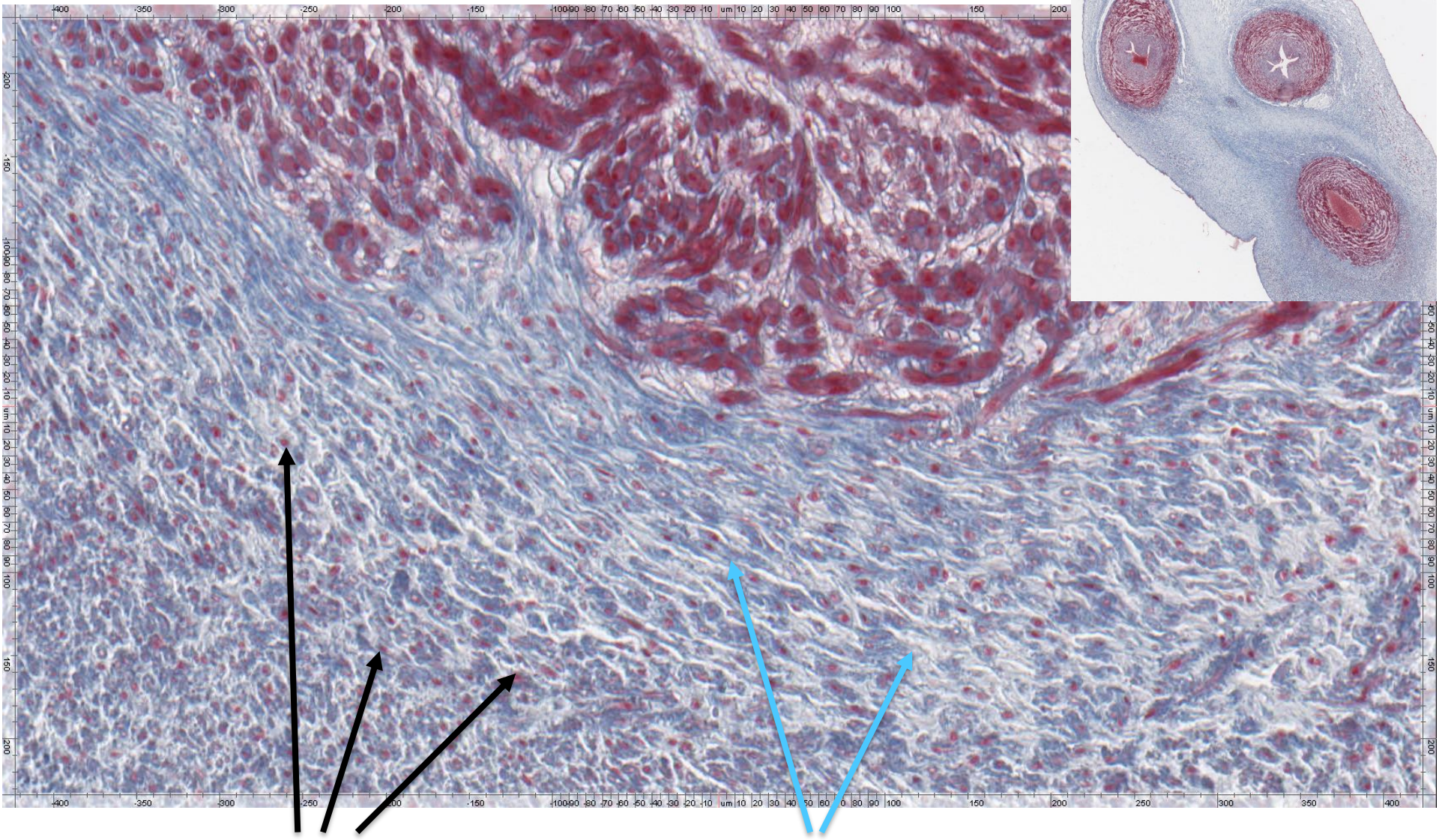
<http://www.gwc.maricopa.edu>



Denzní sekreční granula

1 μm

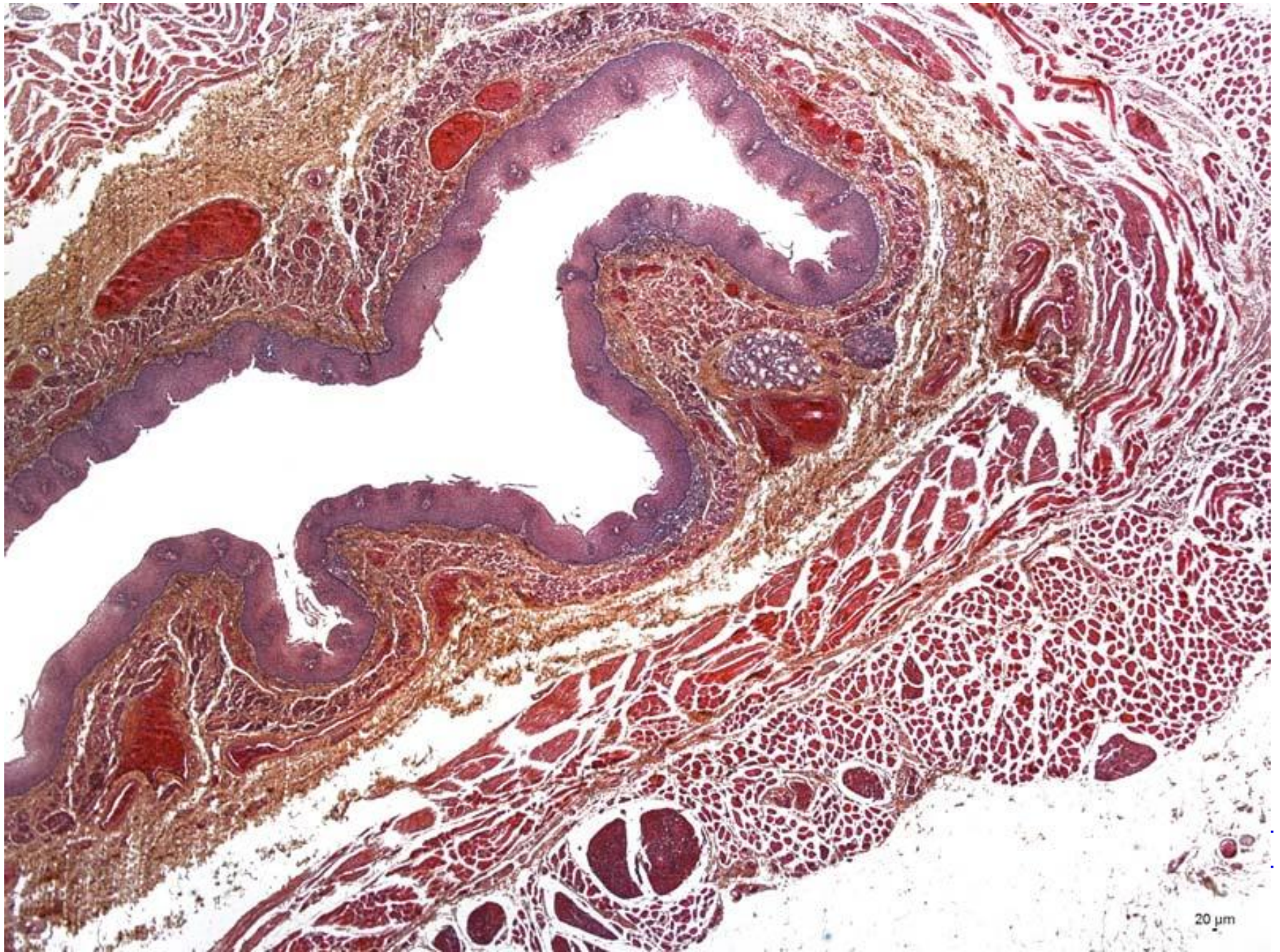
Rosolovit  vazivo – funiculus umbilicalis



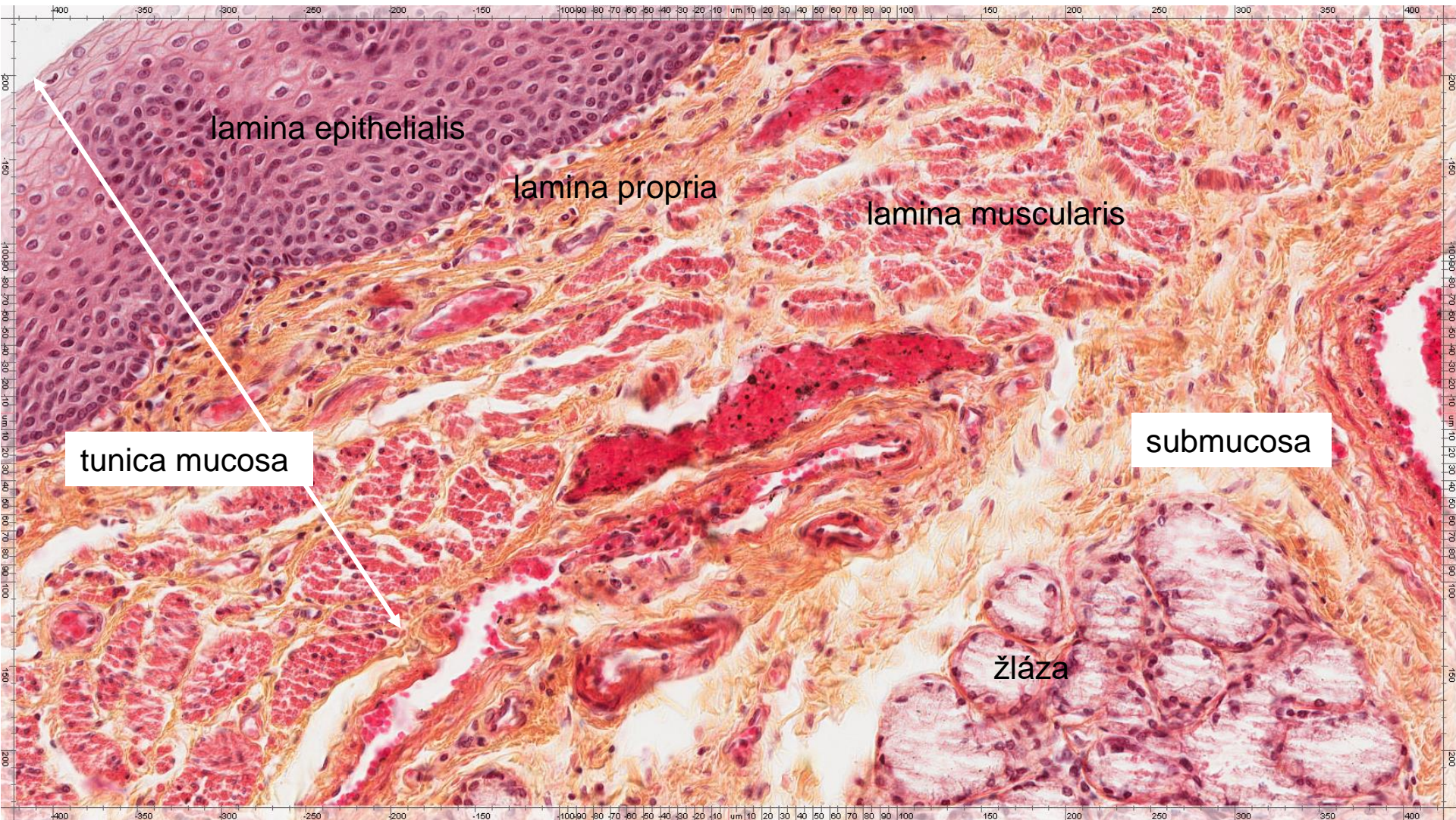
j dra fibrocyt  - **fialov **

kolagenn  vl kna - **modr **

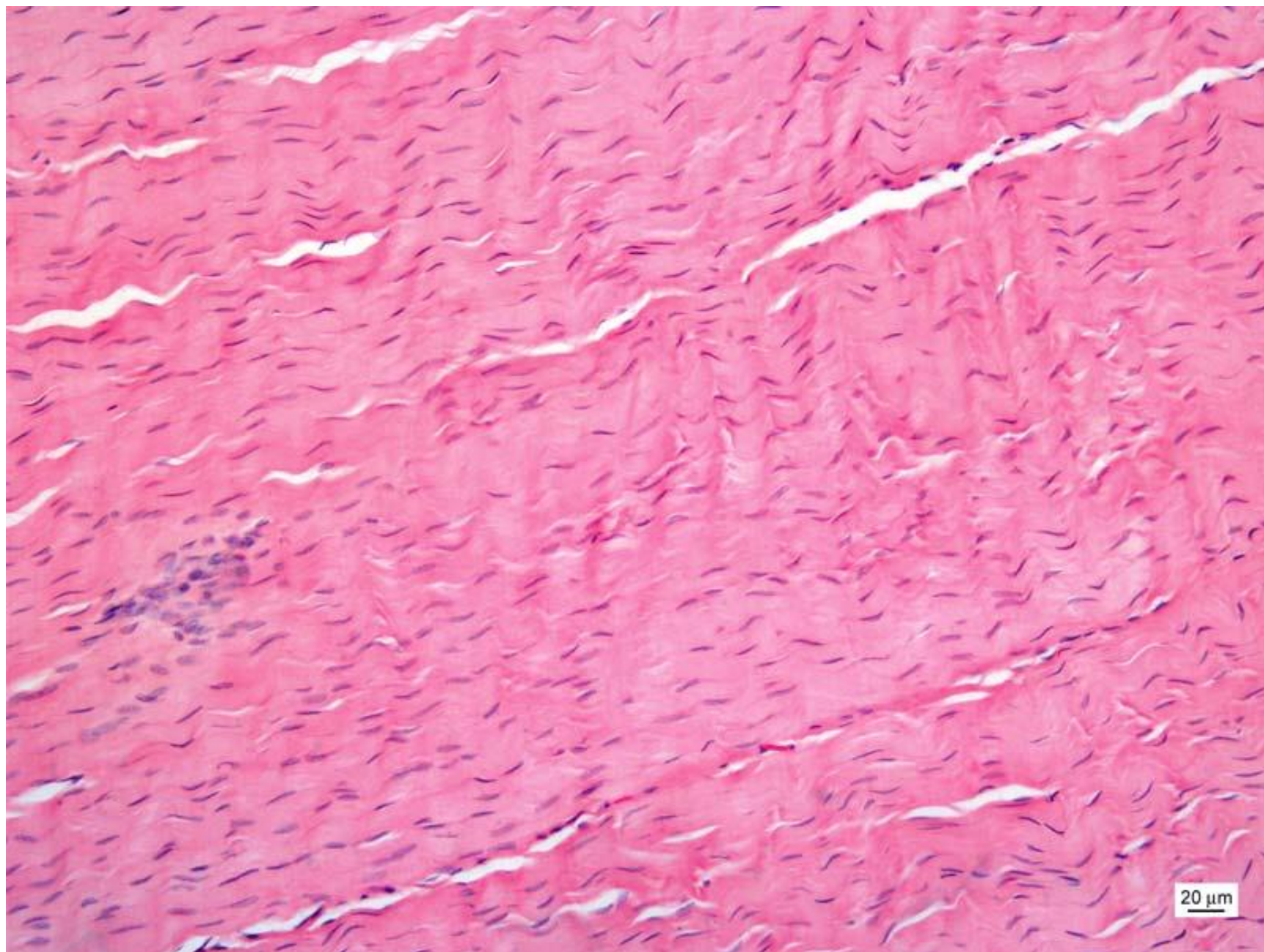
Řídké kolagenní vazivo - jícen



Řídké kolagenní vazivo – tunica mucosa, tela submucosa



Husté kolagenní vazivo uspořádané - šlacha

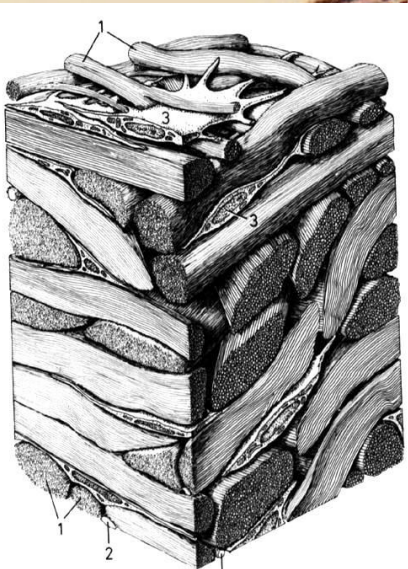


Husté kolagenní vazivo neuspořádané - bělima

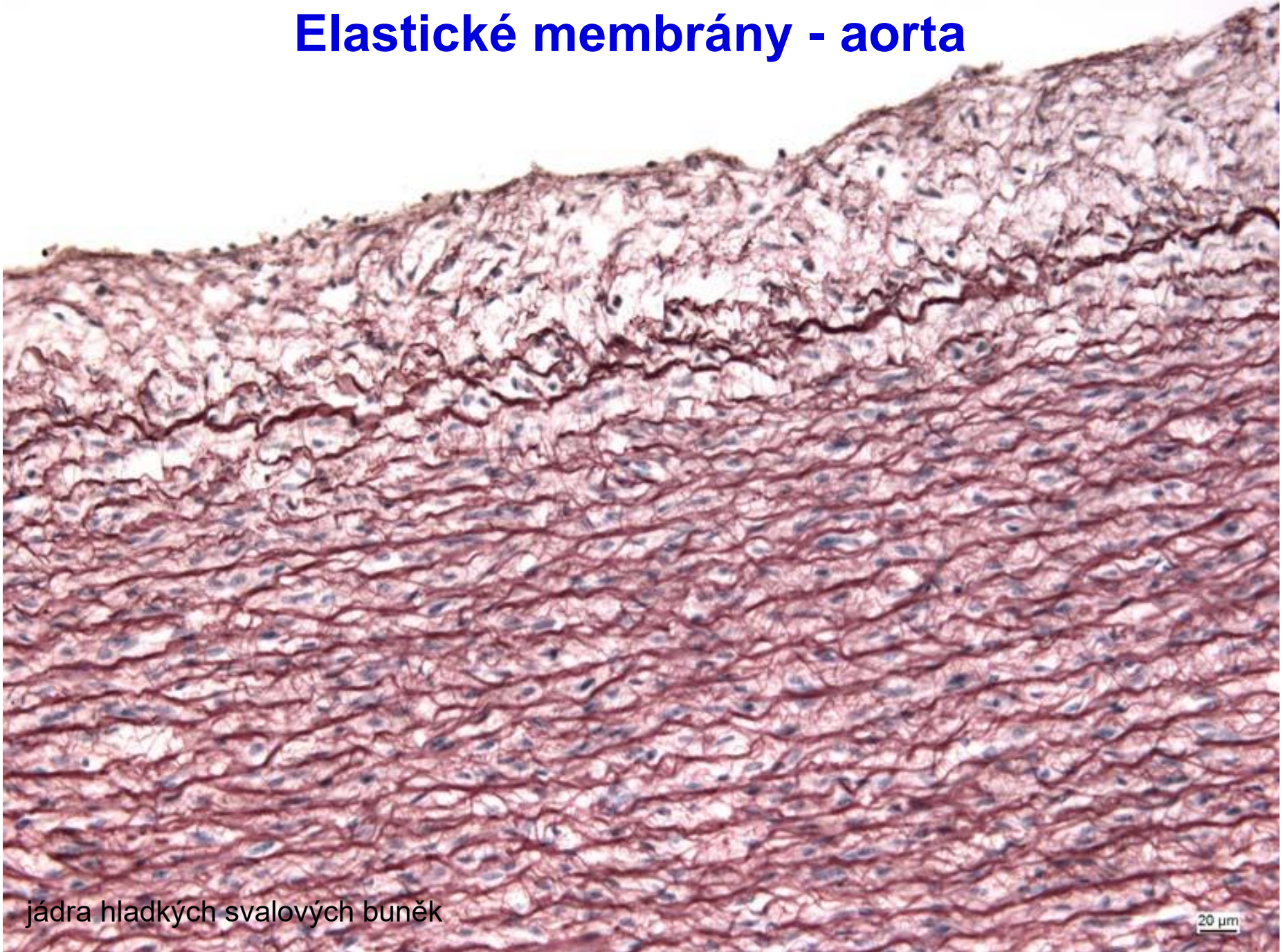retina

cévnatka (choroidea)

bělima (sclera)



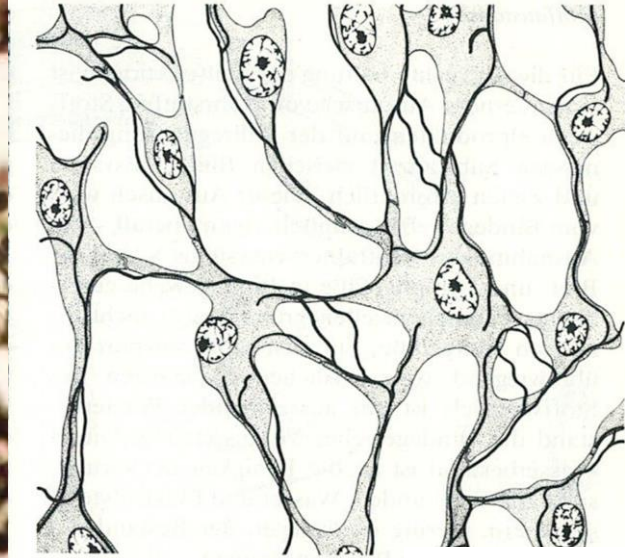
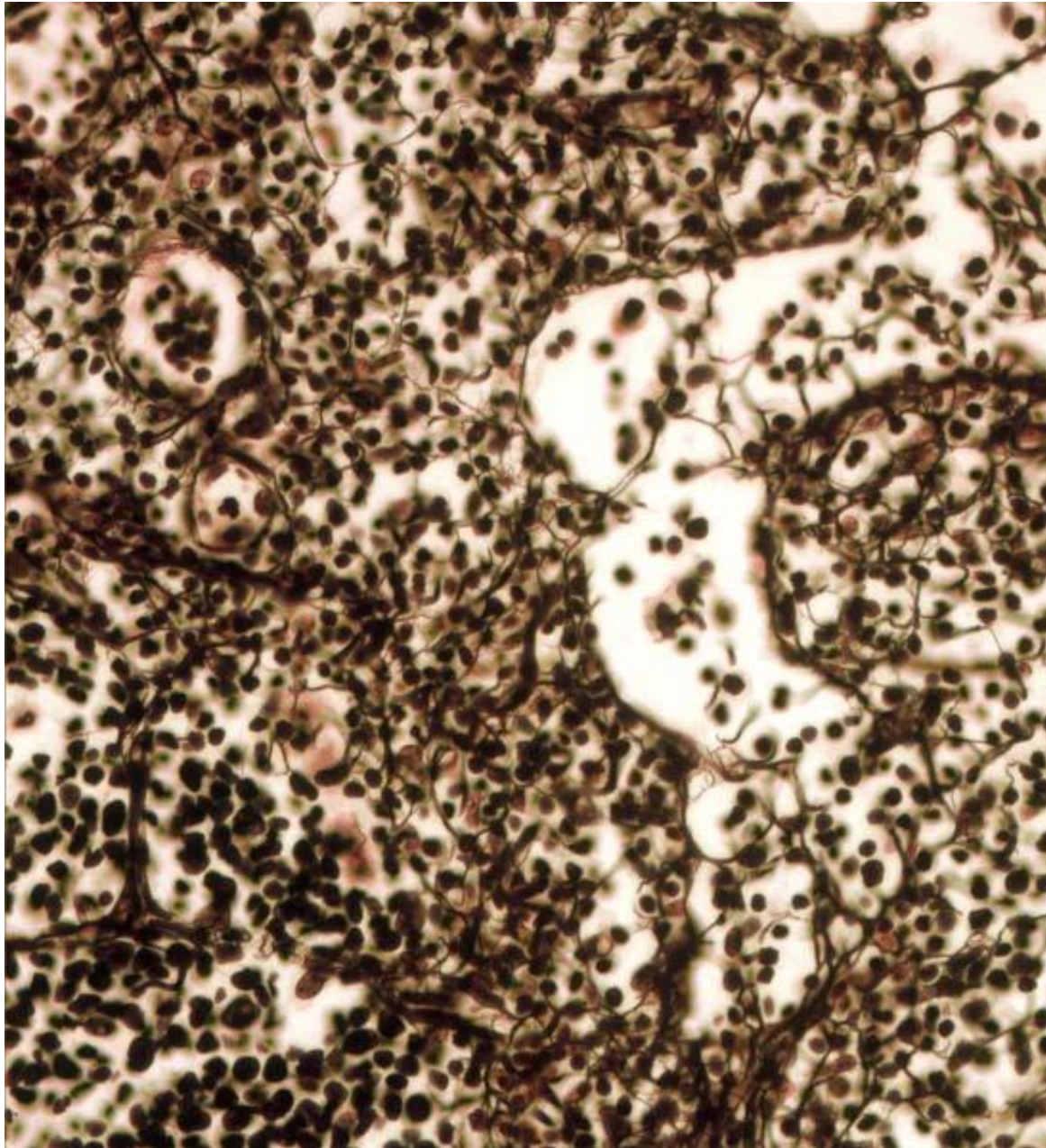
Elastické membrány - aorta



jádra hladkých svalových buněk

20 μ m

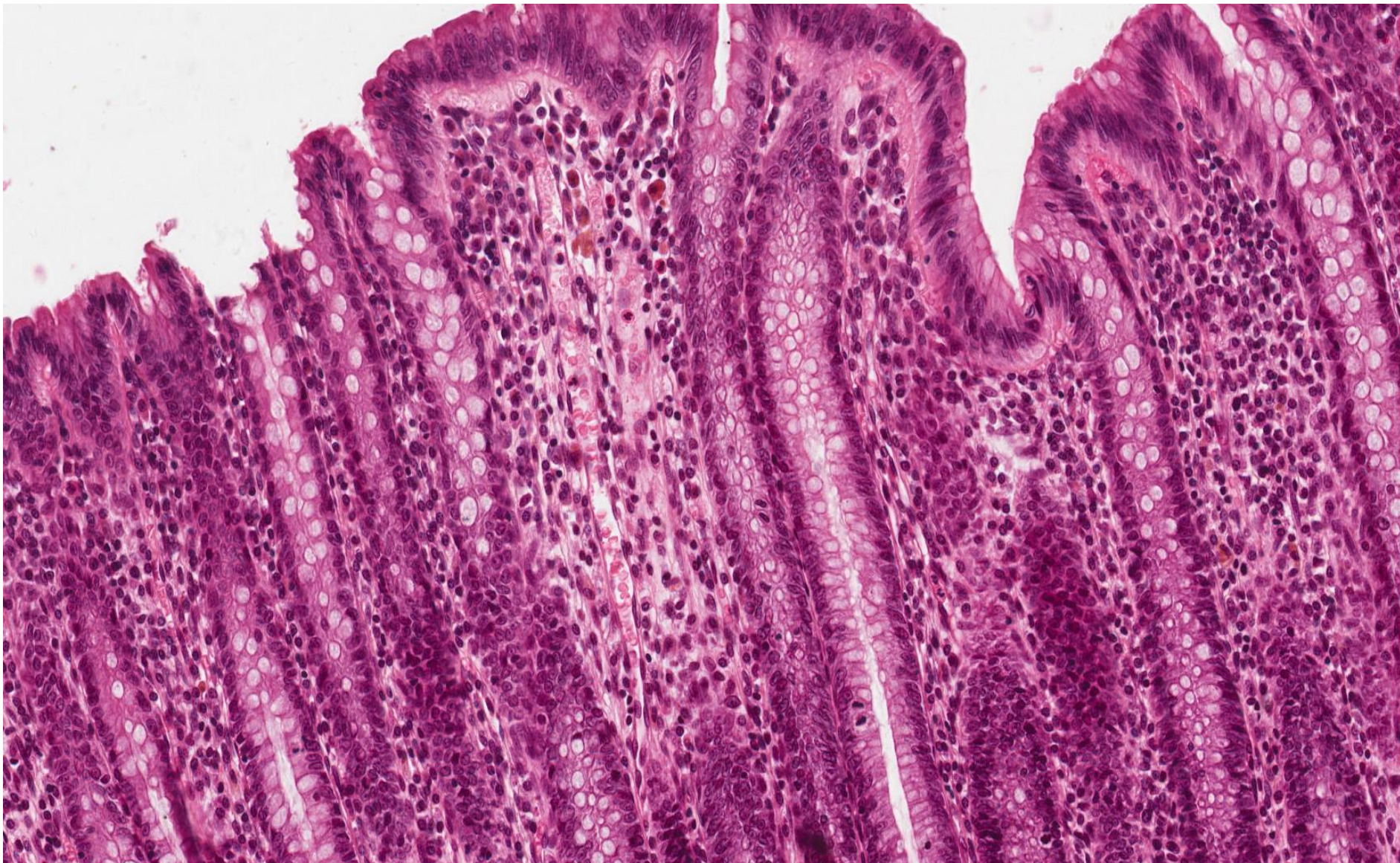Retikulární vazivo – slezina (impregnace)



<http://quizlet.com>

20 μ m

Retikulární vazivo - intestinum crassum (HE)



POJIVOVÉ TKÁŇĚ I – vazivo:

Preparáty:

Rosolovité vazivo (99. Funiculus umbilicalis)

Řídké kolagenní vazivo (11. Esophagus)

Husté kolagenní vazivo (89. Zadní segment oka)

Retikulární vazivo (68. Lien – impregnace)

Elastické membrány (62. Aorta)

Atlas EM:

Strany 33 - 37