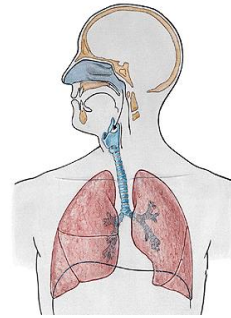


## Respiratory system

MUDr. Marek Joukal, Ph.D.

Department of Anatomy



### Upper respiratory tract

Cavum nasi

Pharynx

### Lower respiratory tract

Larynx

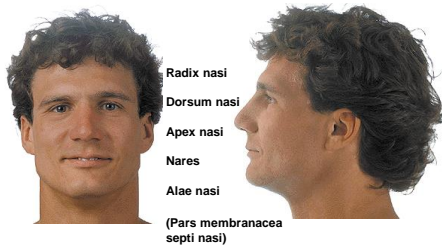Trachea

Bronchi

### Respiratory organ

Lungs

### External nose



Radix nasi

Dorsum nasi

Apex nasi

Nares

Alae nasi

(Pars membranacea  
septi nasi)

### Nasal cartilages

Cartilago septi nasi

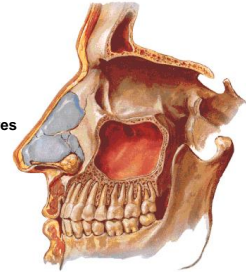
Cartilago nasi lateralis

Cartilago alaris major

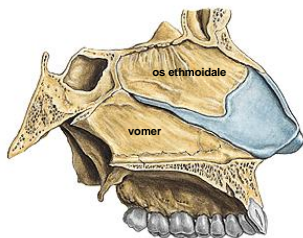
Cartilagine alares minores

Cartilagine nasales  
accessoriae

Cartilago vomeronasalis



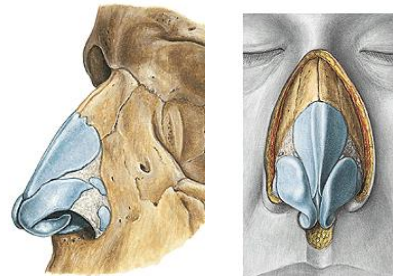
### Septal cartilage



os ethmoidale

vomer

### Lateral nasal cartilage

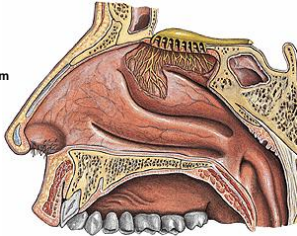


**Nasal cavity**

1. Vestibulum nasi

Skin with hairs - vibrissae

2. Cavum nasi proprium



**Proper nasal cavity**

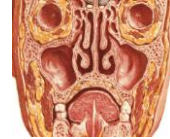
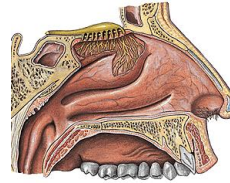
meatus nasi superior

meatus nasi medius

meatus nasi inferior

meatus nasi communis

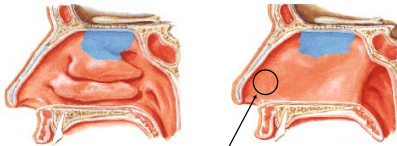
meatus nasopharyngeus



**Mucous membrane of nasal cavity**

Regio olfactoria (2,5 cm<sup>2</sup>)

Regio respiratoria - plexus cavernosi concharum



locus haemorrhagicus Kiesselbachi

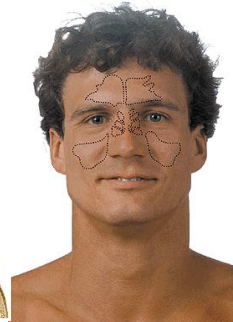
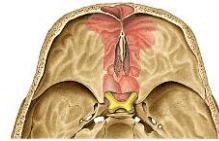**Paranasal sinuses**

Sinus maxillaris

Sinus frontalis

Sinus ethmoidalis (cellulae ethmoidales)

Sinus sphenoidalis

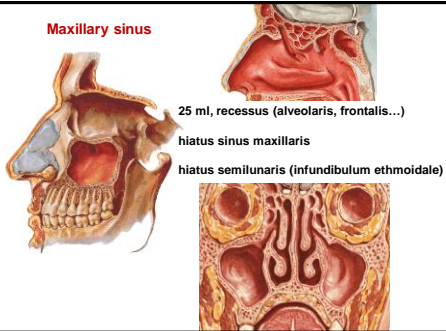


**Maxillary sinus**

25 ml, recessus (alveolaris, frontalis...)

hiatus sinus maxillaris

hiatus semilunaris (infundibulum ethmoidale)

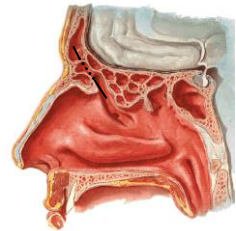
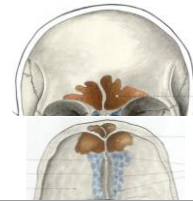


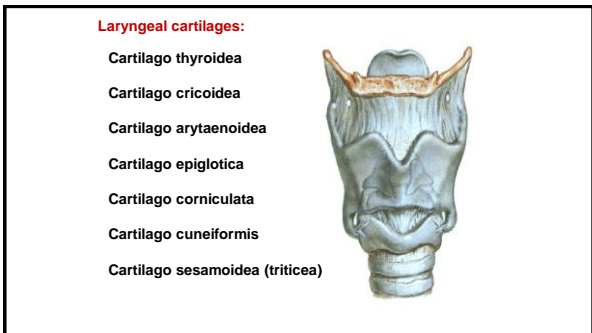
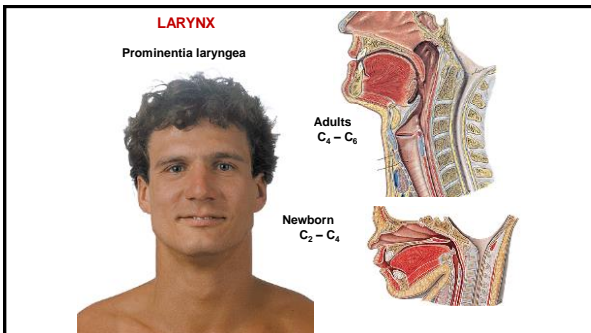
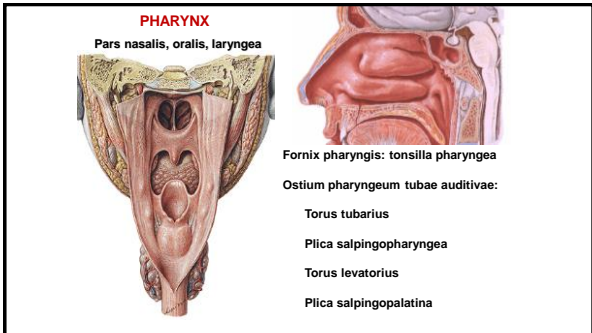
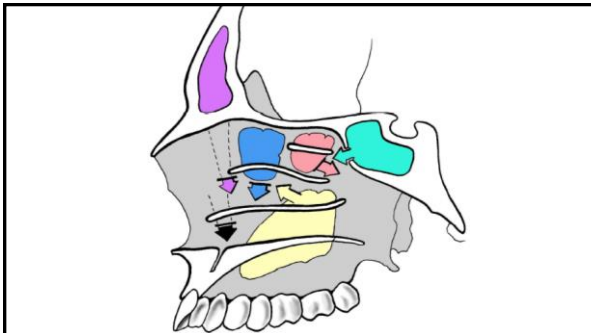
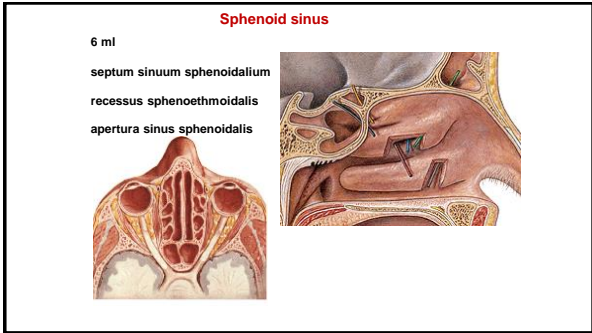
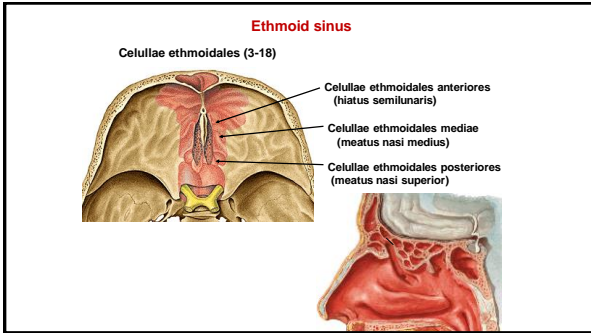
**Frontal sinus**

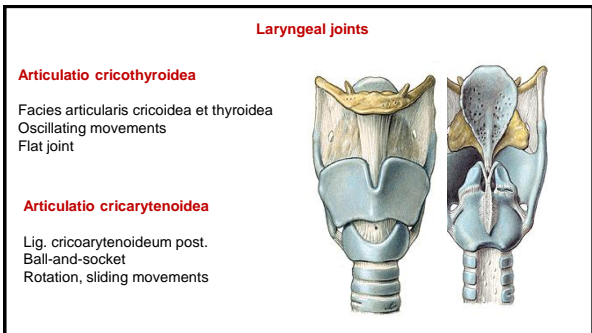
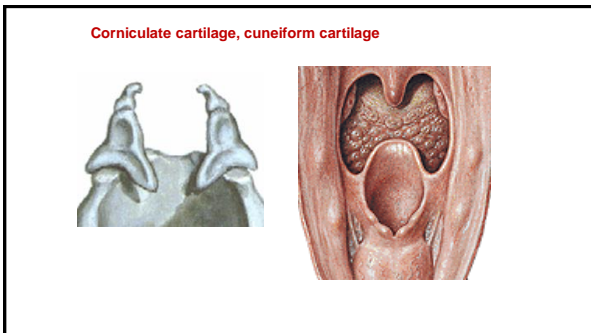
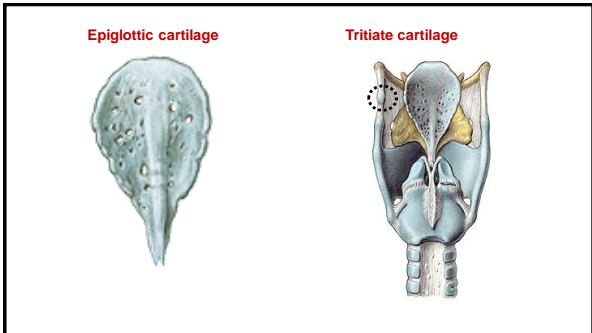
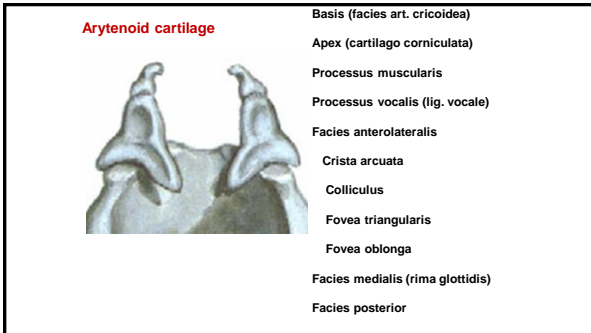
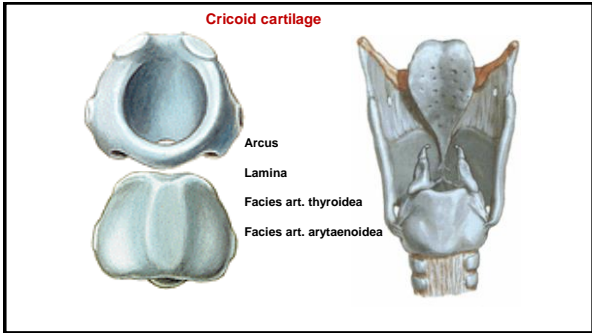
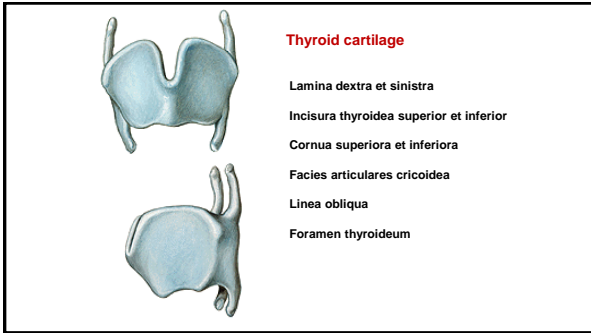
15 ml

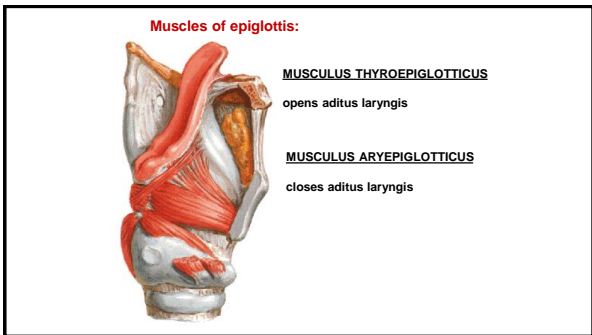
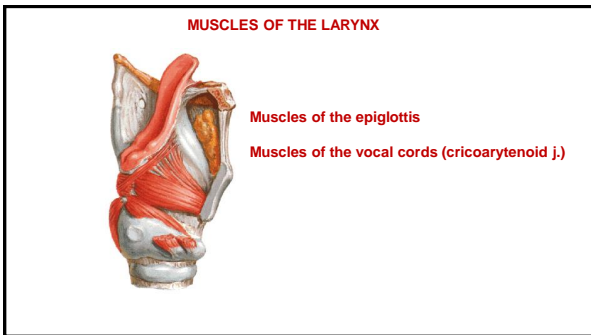
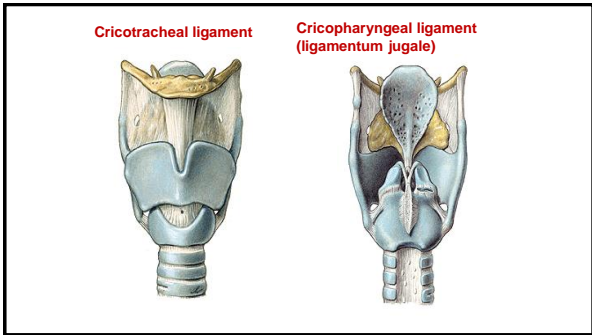
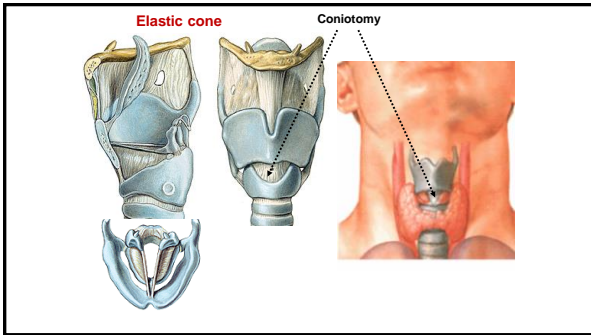
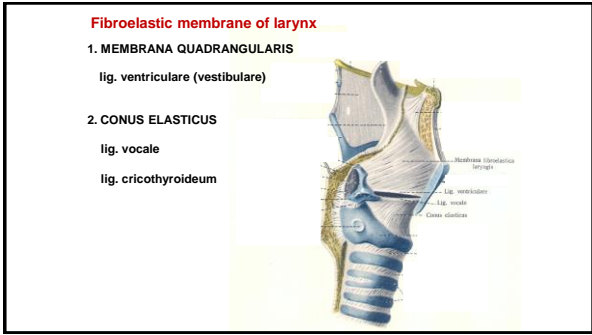
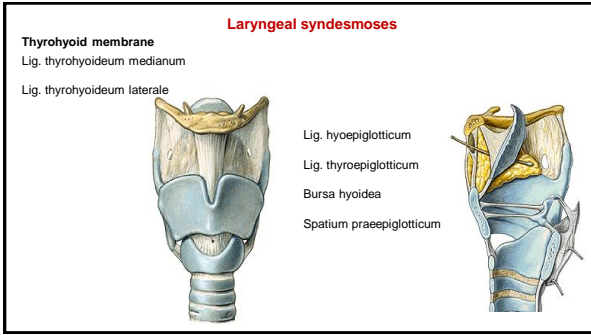
septum sinuum frontaliun

infundibulum ethmoidale (hiatus semilunaris)



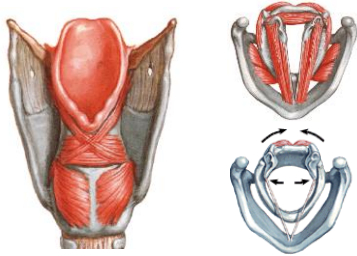






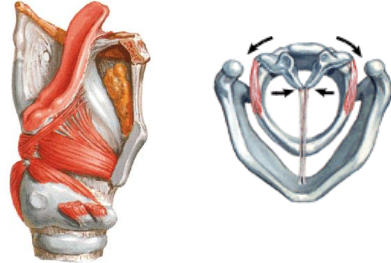
**Abductors of rima glottidis - respiratory position**

**MUSCULUS CRICOARYTENOIDEUS POSTERIOR (POSTICUS)**

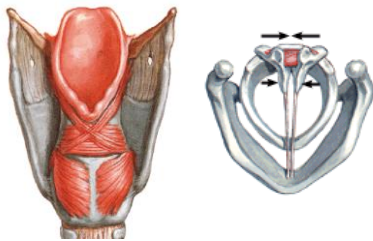


**Adductors of rima glottidis – phonatory position**

**MUSCULUS CRICOARYTENOIDEUS LATERALIS**

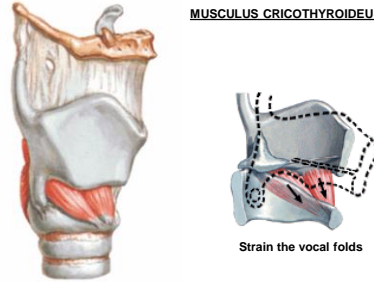


**MUSCULUS ARYTAENOIDEUS (TRANSVERSUS, OBLIQUUS)**



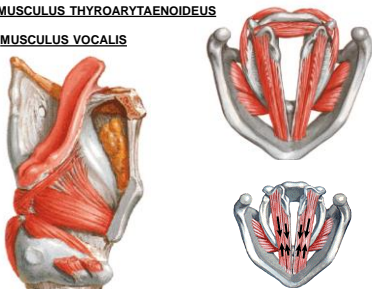
**Tensors of vocal folds**

**MUSCULUS CRICOTHYROIDEUS**

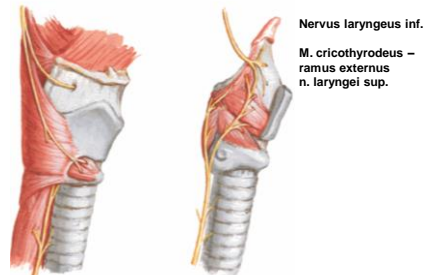


**MUSCULUS THYROARYTENOIDEUS**

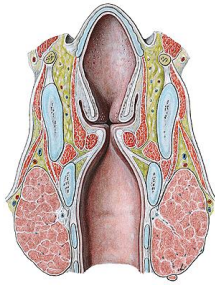
**MUSCULUS VOCALIS**



**Innervation of laryngeal muscles**

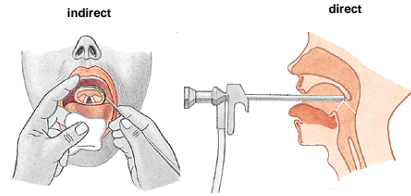


**Laryngeal cavity**

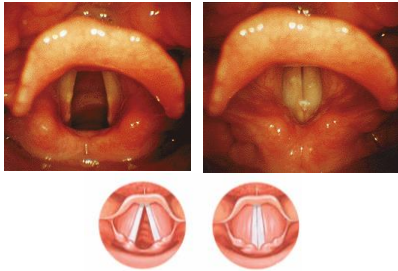


- VESTIBULUM LARYNGIS**  
(aditus laryngis – rima vestibuli)
- GLOTTIS**  
(rima vestibuli – rima glottidis)
- CAVUM INFRAGLOTTICUM**  
(rima glottidis - trachea)

**Laryngoscopy**



**Laryngoscopic view**

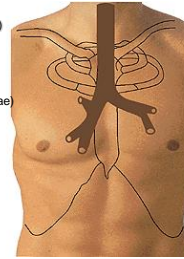


**TRACHEA**

(10 – 12 cm)

C<sub>6</sub> (cartilago cricoidea)

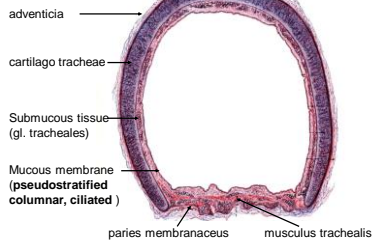
Th<sub>4-5</sub> (bifurcatio tracheae)



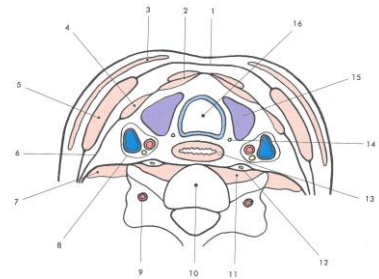
Pars cervicalis

Pars thoracica

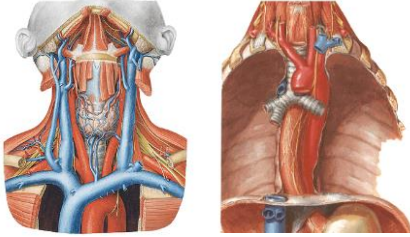
**Tracheal wall**



**PARS CERVICALIS TRACHEAE**

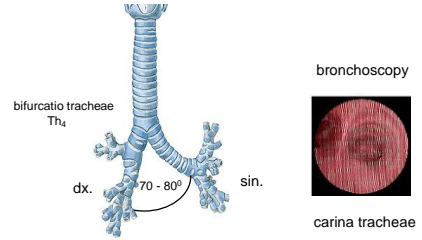


**PARS THORACICA TRACHEAE**



thymus, veins, arteries, tr. sympathicus, n. vagus –  
n. laryngeus recurrens !!!, oesophagus, lymphatic nodes

**BRONCHUS PRINCIPALIS DEXTER ET SINISTER**

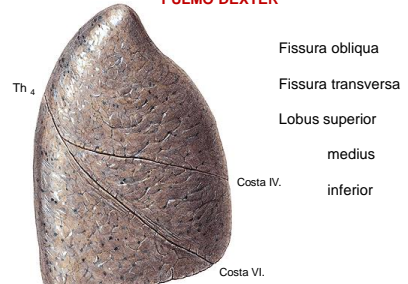


**Lungs**

apex pulmonis  
basis pulmonis  
facies costalis  
diaphragmatica  
medialis  
margo anterior  
inferior  
posterior  
fissurae interlobares



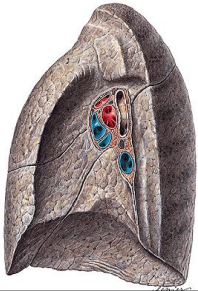
**PULMO DEXTER**



**PULMO DEXTER**

**HILUS PULMONIS**

Bronchus principalis dx.  
Arteria pulmonalis dx.  
Venae pulmonales dx.  
Impressions:  
Apex – sulcus a. subclaviae dx.  
sulcus costae primae  
Impressio cardiaca  
Sulcus venae cavae superioris  
Sulcus venae azygos  
Sulcus oesophageus



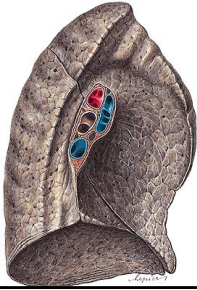
**PULMO SINISTER**

Fissura obliqua  
Lobus superior  
inferior  
Incisura cardiaca  
Lingula pulmonis





**PULMO SINISTER**



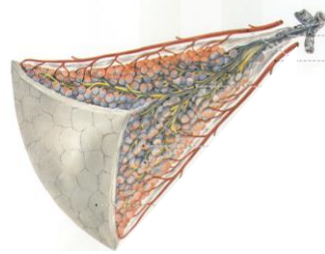
**HILUS PULMONIS**

Arteria pulmonalis sin.  
Bronchus principalis sin.  
Venae pulmonales sin.

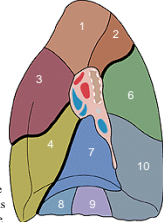
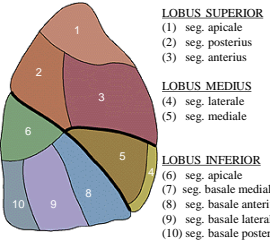
**Impressions:**

Apex – sulcus a. subclaviae sin.  
sulcus v. brachiocephalicae  
sulcus costae primae  
Impressio cardiaca  
Sulcus aorticus  
Impressio oesophagea

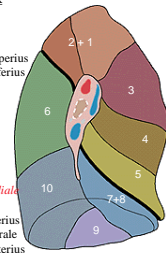
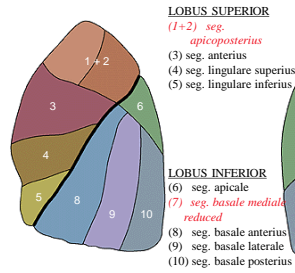
**SEGMENTA BRONCHOPULMONALIA**



**SEGMENTA BRONCHOPULMONALIA DEXTRA**

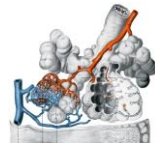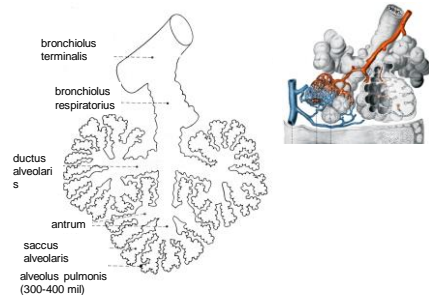
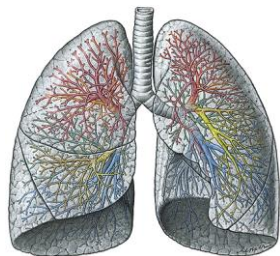


**SEGMENTA BRONCHOPULMONALIA SINISTRA**



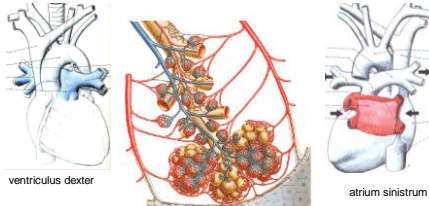
**ARBOR BRONCHIALIS**

Bronchus principalis dx., sin.  
Bronchi lobares (dx. 3, sin. 2)  
Bronchi segmentales (dx. 10, sin. 8)  
*6-18 x ramified*  
Rami bronchiales segmentorum  
Bronchioli terminales  
*(until 1 mm diameter – cartilages)*



**Functional blood circulation (pulmonary circulation)**

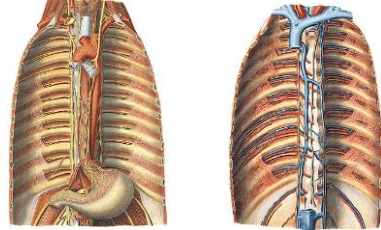
truncus pulmonalis (a. pulmonalis dx. et sin.)  $\xrightarrow{-O_2}$  LUNGS  $\xrightarrow{+O_2}$  Venae pulmonales



**NUTRITIVE BLOOD CIRCULATION**

Aorta thoracica  $\rightarrow$  r. bronchiales

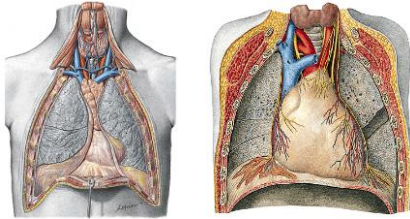
Vv. bronchiales  $\rightarrow$  v. azygos, v. hemiazygos accessoria



**PLEURA**

pleura parietalis  
pleura visceralis  
(fig. pulmonale)

cavum pleurae dextrum  
cavum pleurae sinistrum  
mediastinum

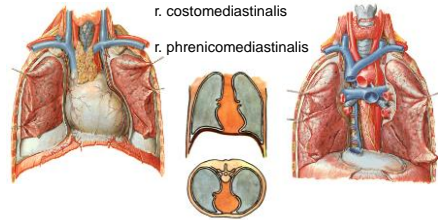


**RECESSUS PLEURAE**

r. costodiaphragmaticus

r. costomediastinalis

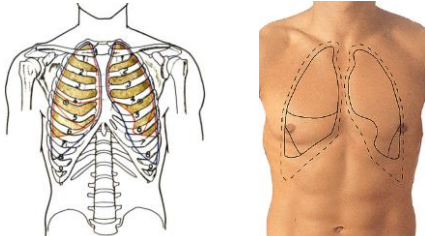
r. phrenicomediastinalis



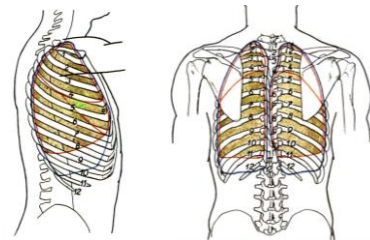
**Projection of pleura**

area interpleuralis superior (thymica)

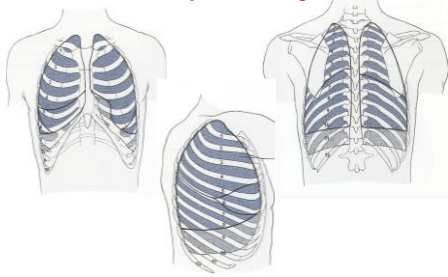
area interpleuralis inferior (pericardiaca)



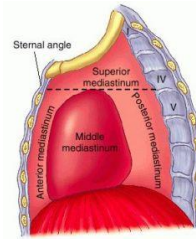
**Recessus retroesophageus Th<sub>4</sub> – Th<sub>12</sub>**



**Projection of lungs**

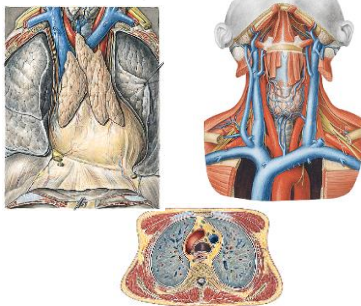


**MEDIASTINUM**

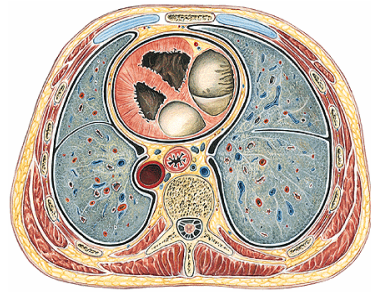


Mediastinum superius  
 Mediastinum inferius:  
     anterior  
     medium  
     posterior

**Mediastinum superius**

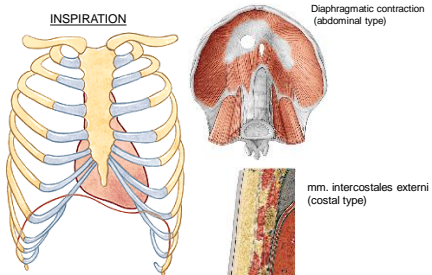


**Mediastinum inferius**



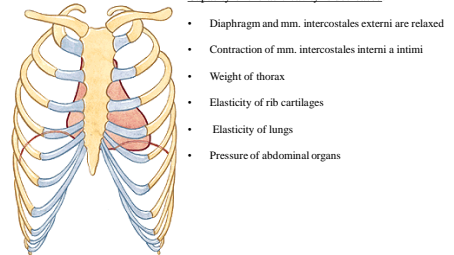
**MECHANISM OF BREATHING** Capacity of thoracic cavity is increased:

**INSPIRATION**



**EXPIRATION**

Capacity of thoracic cavity is decreased:



### References:

Putz, R. (2008):  
Atlas of Human Anatomy Sobotta. Elsevier Books.

Keith L. Moore, Arthur F. Dalley (2005):  
Clinically Oriented Anatomy. Williams and Wilkins.

Platzer, W., Kahle, W., Leonhardt H. (1992):  
Locomotor system. Georg Thieme Verlag, Stuttgart,  
New York, 4th edition.

Čihák, R. (1987):  
Anatomie 1. Avicenum, Zdravotnické nakladatelství.

Netter, F. H. (1997):  
Interactive Atlas of Clinical Anatomy. Novartis, USA.