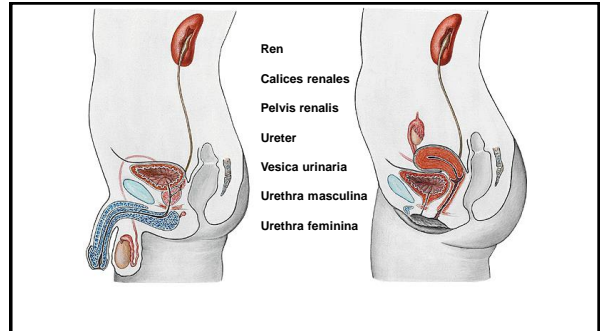


Urinary system

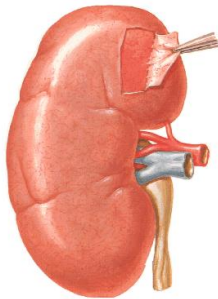
MUDr. Marek Joukal, Ph.D.

Department of Anatomy



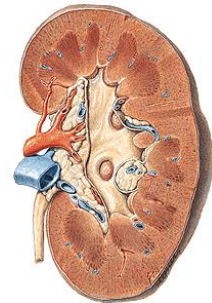
Kidney

- Extremitas superior
- Extremitas inferior
- Facies anterior
- Facies posterior
- Margo lateralis
- Margo medialis
- Capsula fibrosa
- Hilus (hilum) renalis

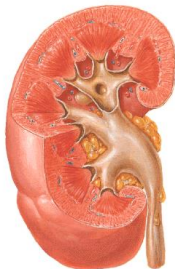

SINUS RENALIS:

- Calices renales
- Pelvis renalis
- Arteria renalis
- Vena renalis

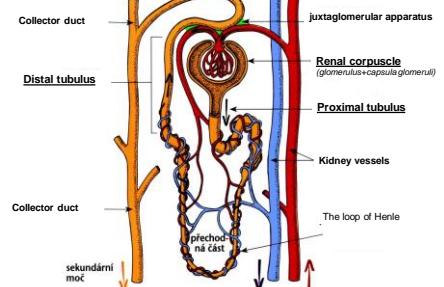


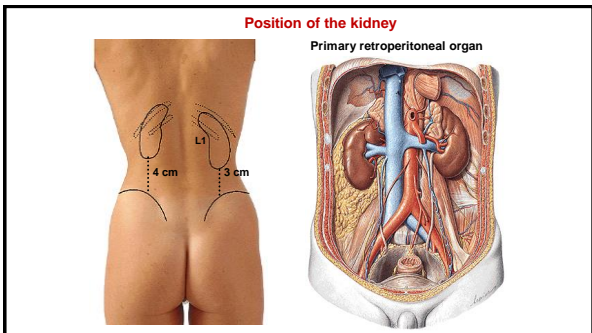
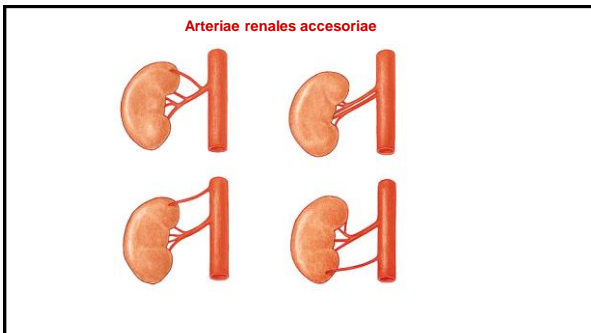
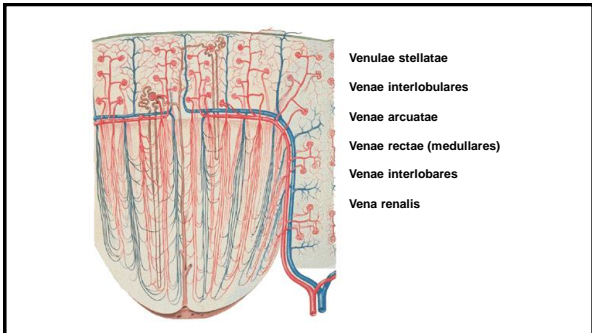
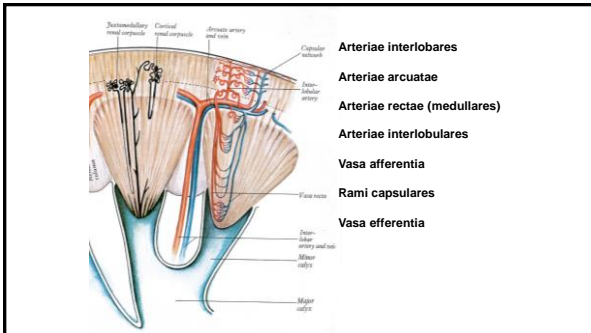
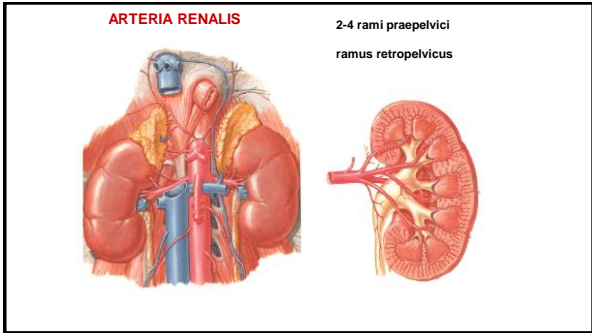
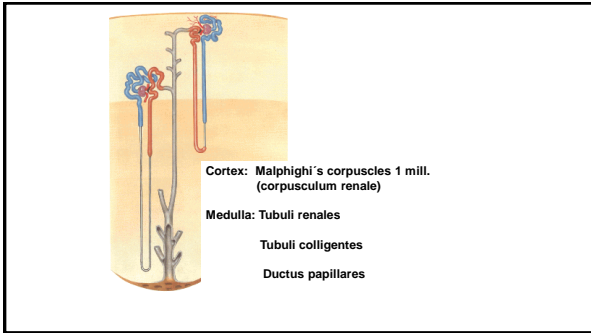
Morphology of the kidney

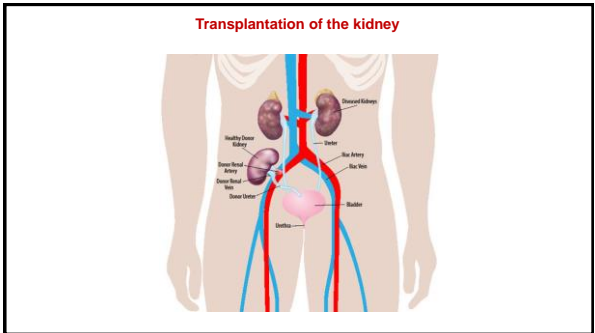
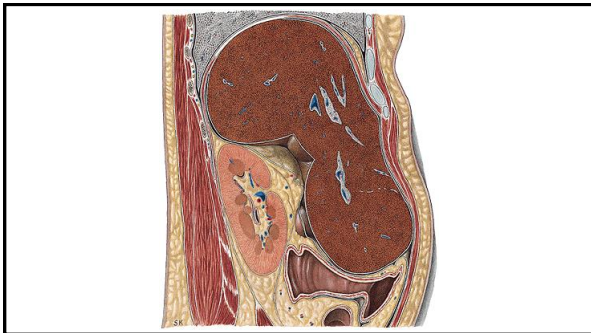
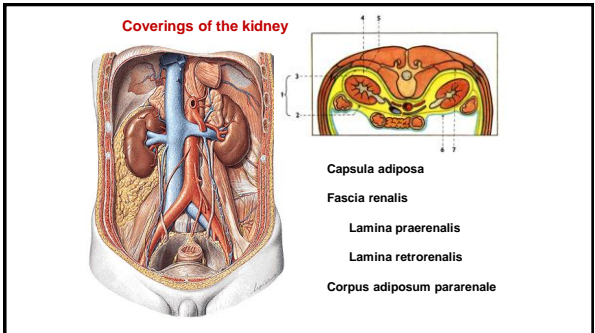
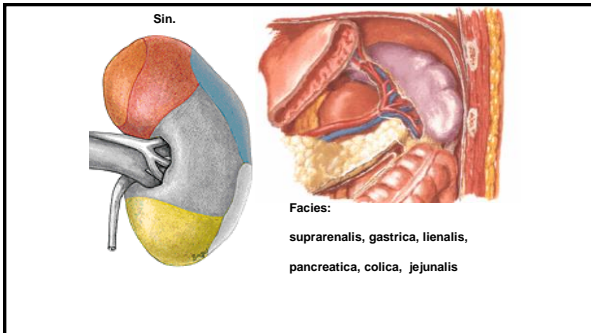
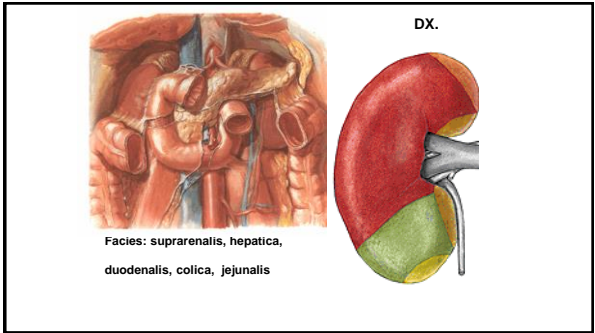
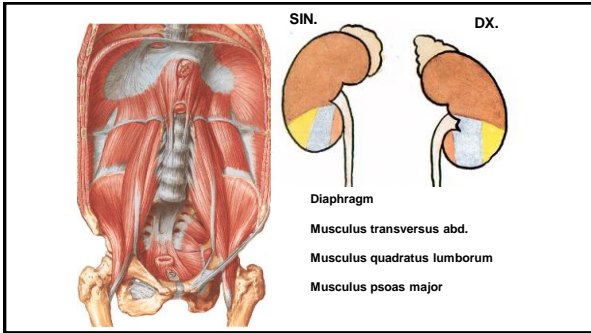


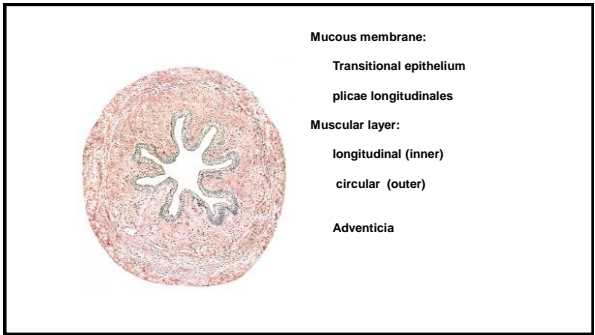
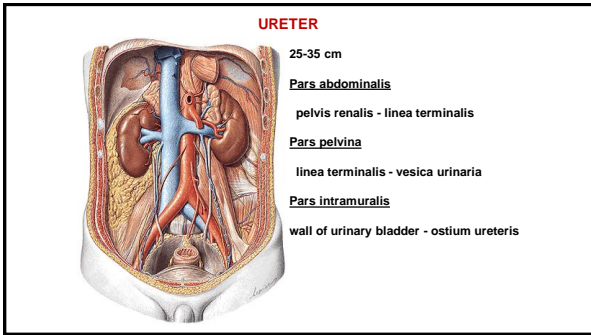
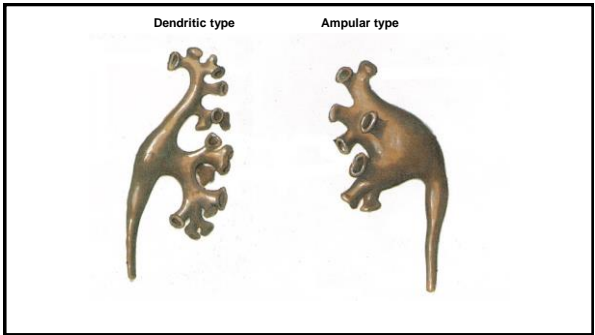
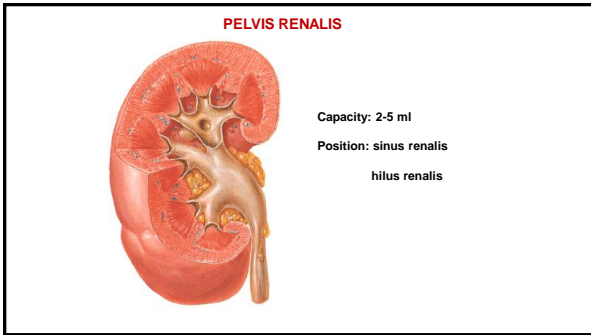
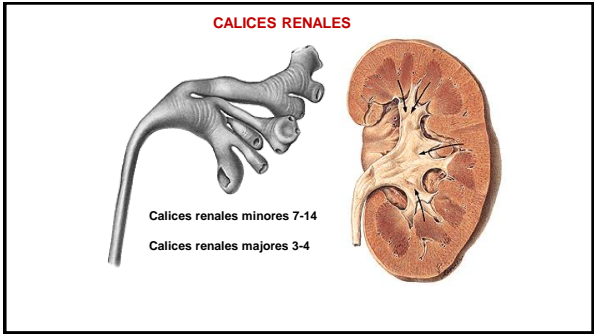
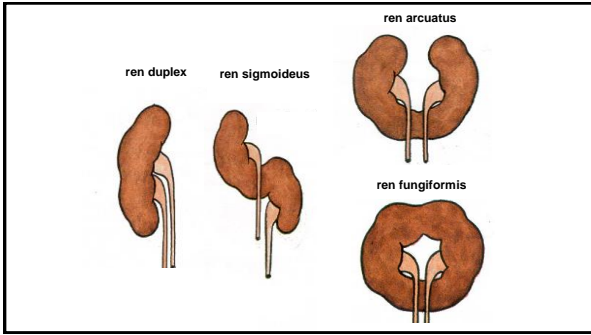
- Capsula fibrosa
- Cortex renalis
- Medulla renalis
- Columnae renales
- Pars radiata corticis
- Pyramides renales
- Papilla renalis
- Foramina papillaria (ductus papillares)
- Area cribrosa
- Lobulus renalis (renculus)

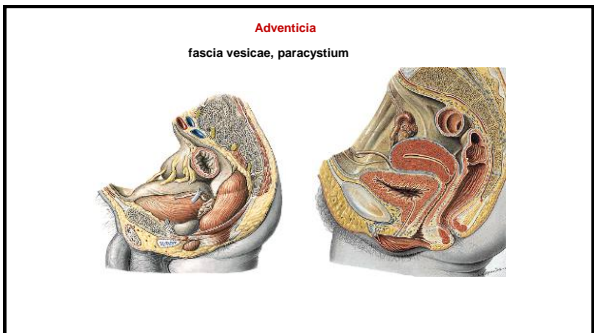
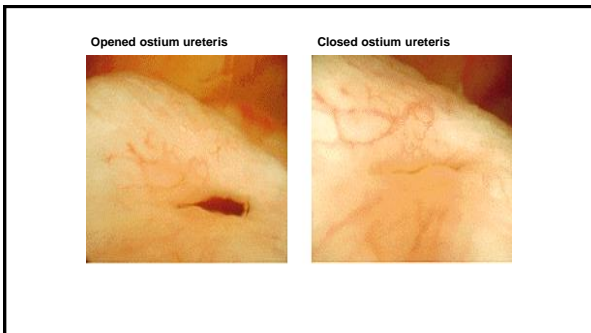
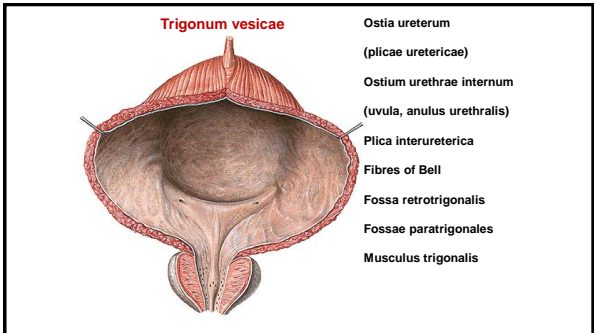
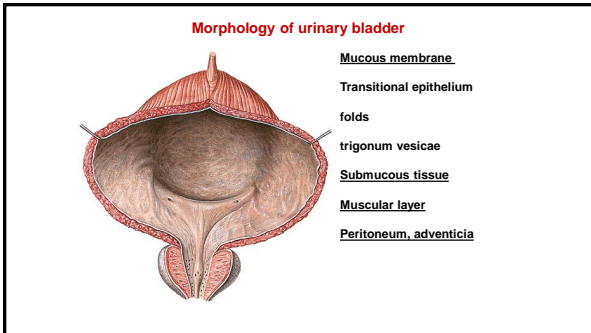
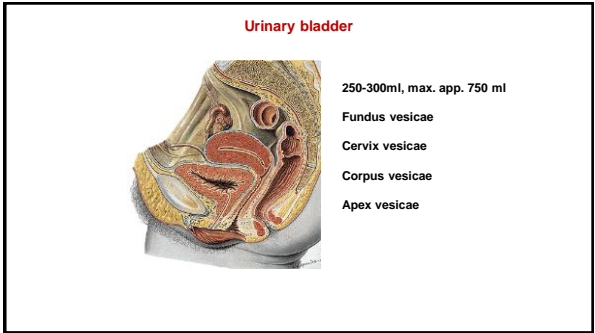
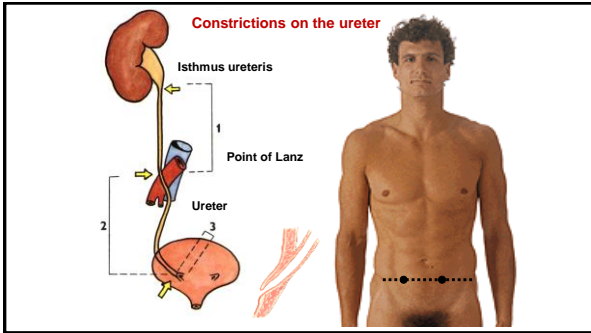
NEFRON

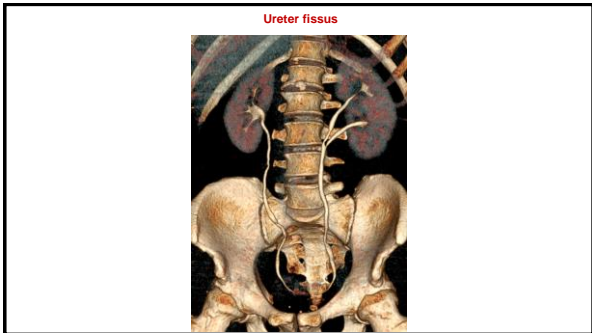
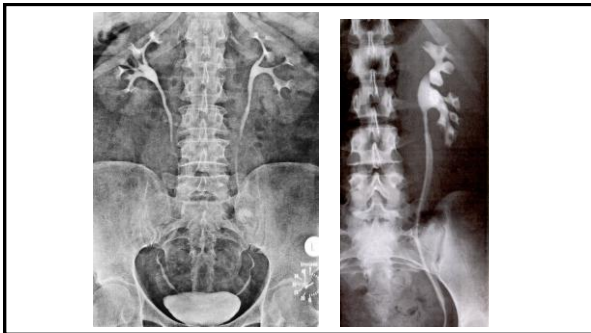
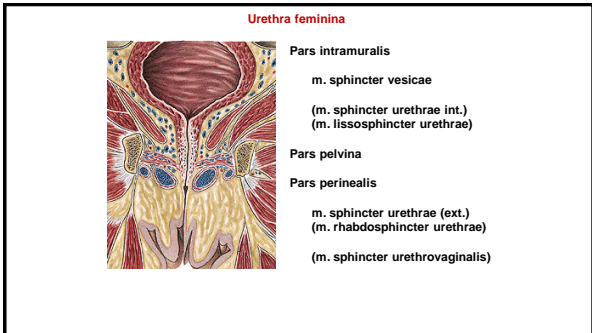
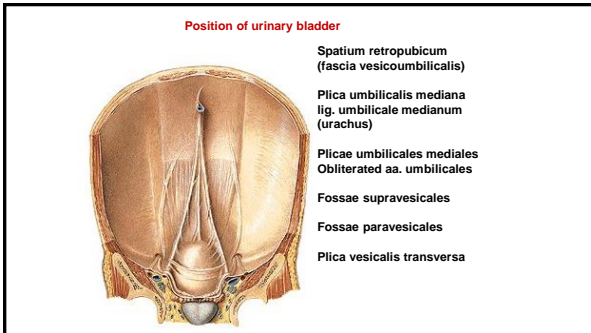
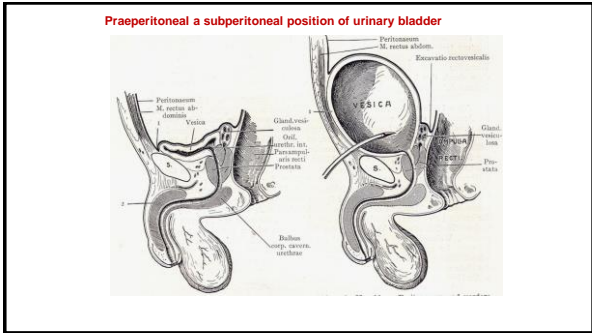
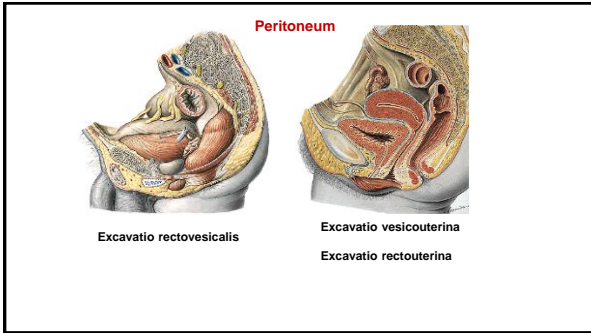


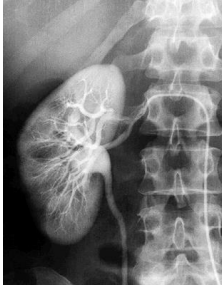












References:

Putz, R. (2008):
Atlas of Human Anatomy Sobotta. Elsevier Books.

Keith L. Moore, Arthur F. Dalley (2005):
Clinically Oriented Anatomy. Williams and Wilkins.

Platzer, W., Kahle, W., Leonhardt H. (1992):
Locomotor system. Georg Thieme Verlag, Stuttgart, New York, 4th edition.

Čihák, R. (1987):
Anatomie 1. Avicenum, Zdravotnické nakladatelství.

Netter, F. H. (1997):
Interactive Atlas of Clinical Anatomy. Novartis, USA.