

A 3D illustration of a blood vessel cross-section. The vessel is shown in a reddish-brown color, with a thick wall. Inside the vessel, there is a dense population of blood cells. The most prominent are red blood cells, depicted as biconcave discs in various shades of red. Interspersed among them are several white blood cells, shown as larger, spherical cells with a pale yellow or white center and a darker outer ring. The cells are arranged in a way that suggests they are flowing through the vessel. The overall lighting is warm and focused on the cellular details.

BLOOD AND HEMATOPOIESIS

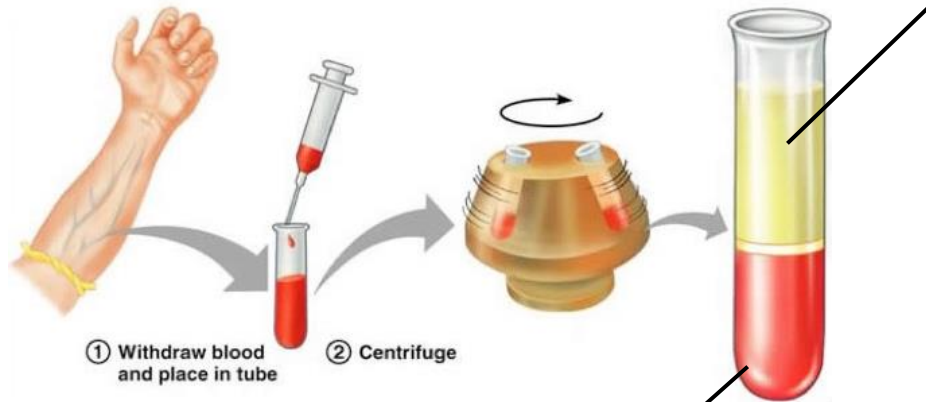
Petr Vaňhara

Department of Histology and Embryology
LF MU

BLOOD

Blood is body fluid

- transport medium (O₂, CO₂, metabolites, hormones, nutrients...)
- homeostasis of inner body environment (thermoregulation, acidobasic equilibrium, oncotic pressure)
- integrity of cardiovascular system (clotting cascade)
- immune reactions



plasma

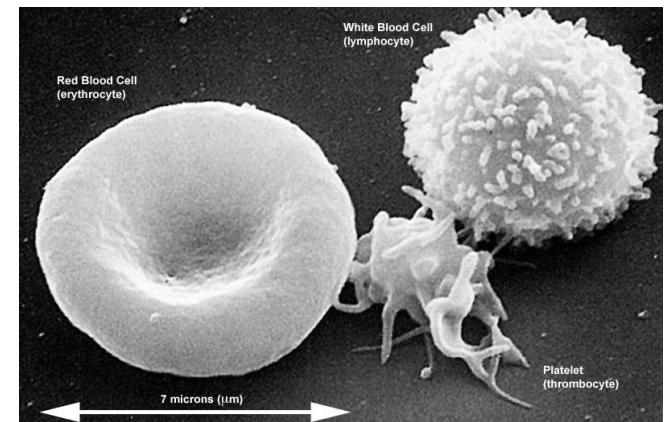
- ions, proteins, low mass organic compounds
- fluid ECM



Blood can be considered as a specialized connective tissue

formed blood elements

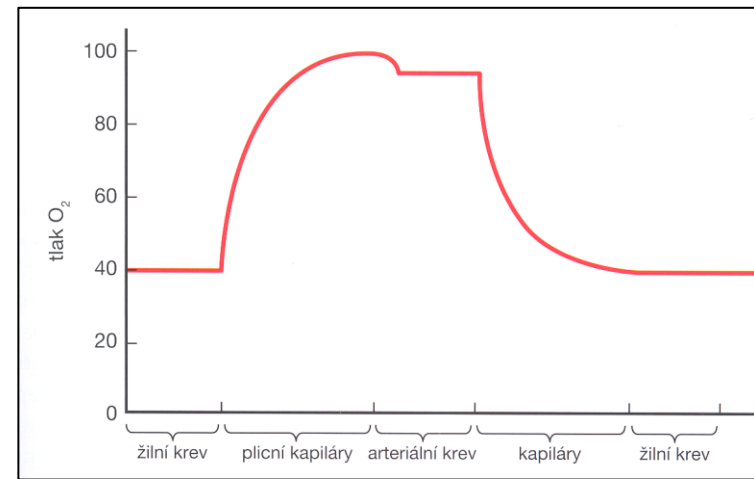
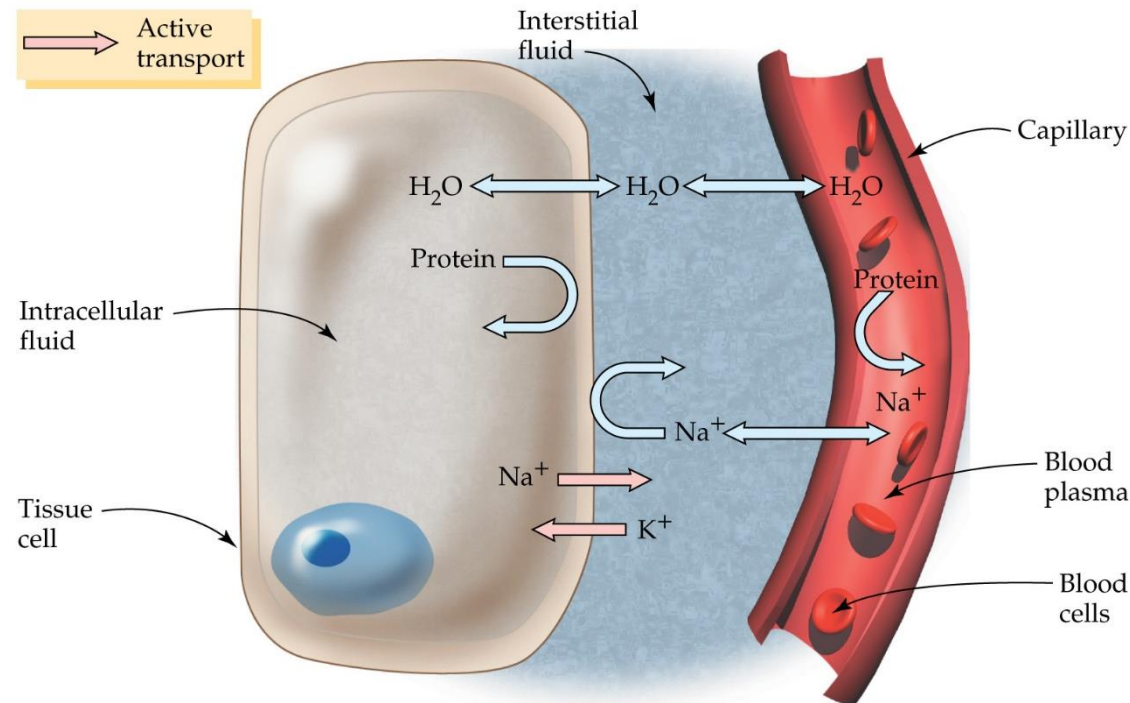
- erythrocytes
- leukocytes
- thrombocytes



BLOOD PLASMA AND TISSUE FLUID

plasma

- 2,8-3,5 l
- pH 7.4 (± 0.05)
- ~ 92% **water**
- ~ 1% **ions** (Na^+ , K^+ , Ca^{2+} , Mg^{2+} , Cl^- , HCO_3^-), **low mass organic compounds** (glucose, aminoacids, cholesterol, lipids, waste products of metabolism), **respiration gases**
- ~ 7% **proteins** (albumins, globulins, fibrinogen)



Venous blood

Lung capillaries

Arterial blood

Capillaries

Venous blood

IONS AND LOW MASS MOLECULES OF BLOOD PLASMA (~1%)

- ~ 1% **ions** (Na^+ , K^+ , Ca^{2+} , Mg^{2+} , Cl^- , HCO_3^-), **low mass organic compounds** (glucose, aminoacids, cholesterol, lipids, waste products of metabolism), **respiration gases**

	Sodium	136–148 mmol/l	Osmotic pressure, volume, pH
	Potassium	3,7–5,0 mmol/l	Membrane potential of cells (nerve, muscle)
Cations	Calcium	2,15–2,61 mmol/l	Permeability of membranes, blood clotting, neuromuscular junctions
	Magnesium	0,66–0,94 mmol/l	Cofactor of enzymes, neuronal conduction
	Iron ♂	12–27 $\mu\text{mol/l}$	Cofactor of enzymes, in hem of hemoglobin
	Iron ♀	10–24 $\mu\text{mol/l}$	
	Copper	12–22 $\mu\text{mol/l}$	Cofactor of enzymes
	Chlorides	95–110 mmol/l	Osmotic pressure, volume, pH
Anions	Bicarbonates [HCO_3^-]	22–26 mmol/l	Transport of CO_2 , buffer - pH
	P_i	0,6–1,4 mmol/l	Buffer - pH
	Iodide	276–630 $\mu\text{mol/l}$	Hormones of thyroid gland

Memorizing of this table is not necessary for completing our course 😊

IONS AND LOW MASS MOLECULES OF BLOOD PLASMA (~1%)

- ~ 1% **ions** (Na^+ , K^+ , Ca^+ , Mg^+ , Cl^- , HCO_3^-), **low mass organic compounds** (glucose, aminoacids, cholesterol, lipids, waste products of metabolism), **respiration gases**

Glucose	3,3–6,1 mmol/l
Aminoacids	2,3–3,9 mmol/l
Urea	3,0–7,6 mmol/l
Lipids	4–9 g/l
Triacylglycerols	0,5–1,8 mmol/l
Phospholipids	1,8–2,5 g/l
Creatinine	55–110 $\mu\text{mol/l}$
Cholesterol (total)	3,5–5,2 mmol/l
Bilirubin	3,3–18,0 $\mu\text{mol/l}$
Lactate	0,55–2,22 mmol/l

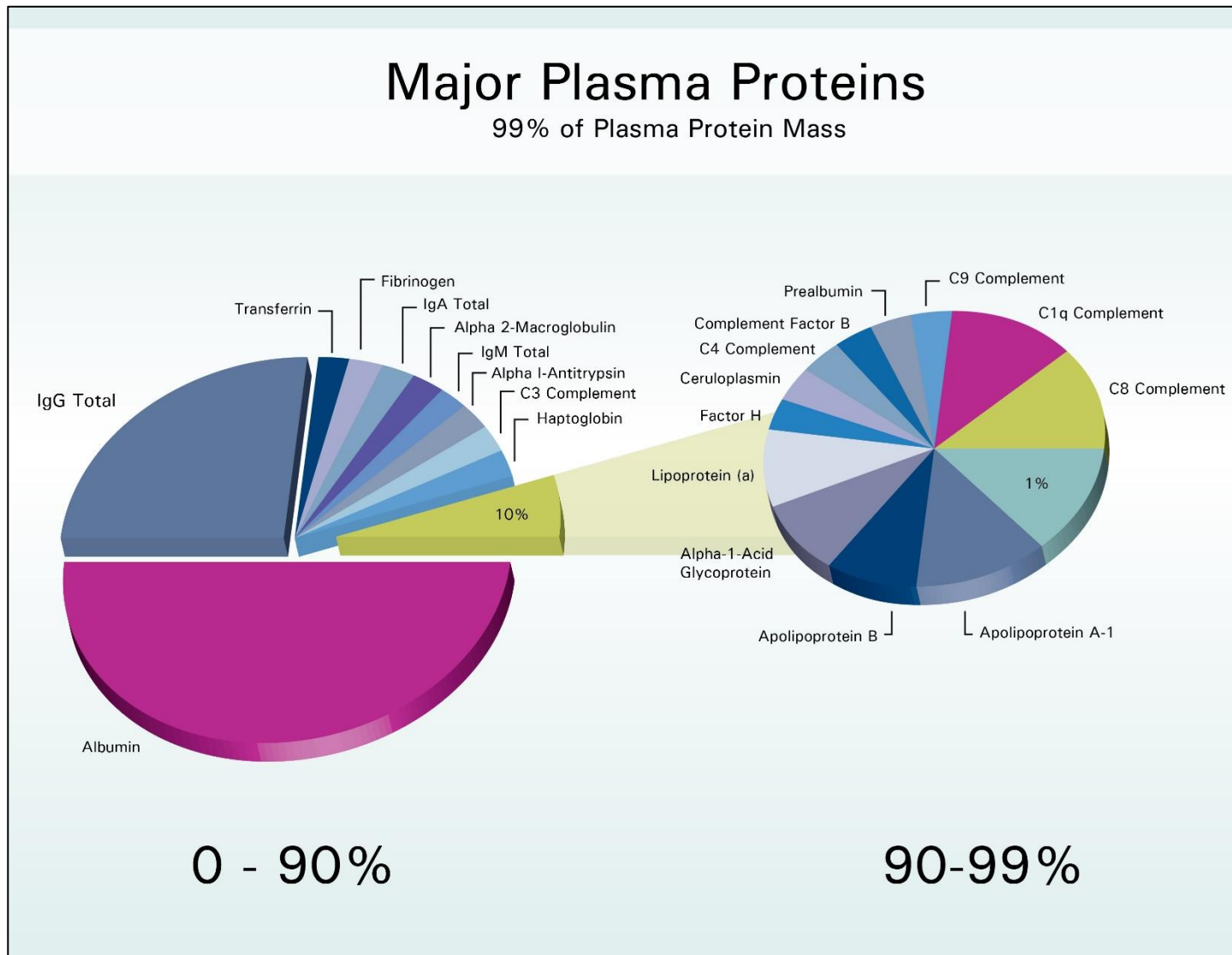
But what is important to know is that:



COMPOSITION OF BLOOD PLASMA IS CONSTANT
and regulated in narrow range → essential for **clinical medicine**

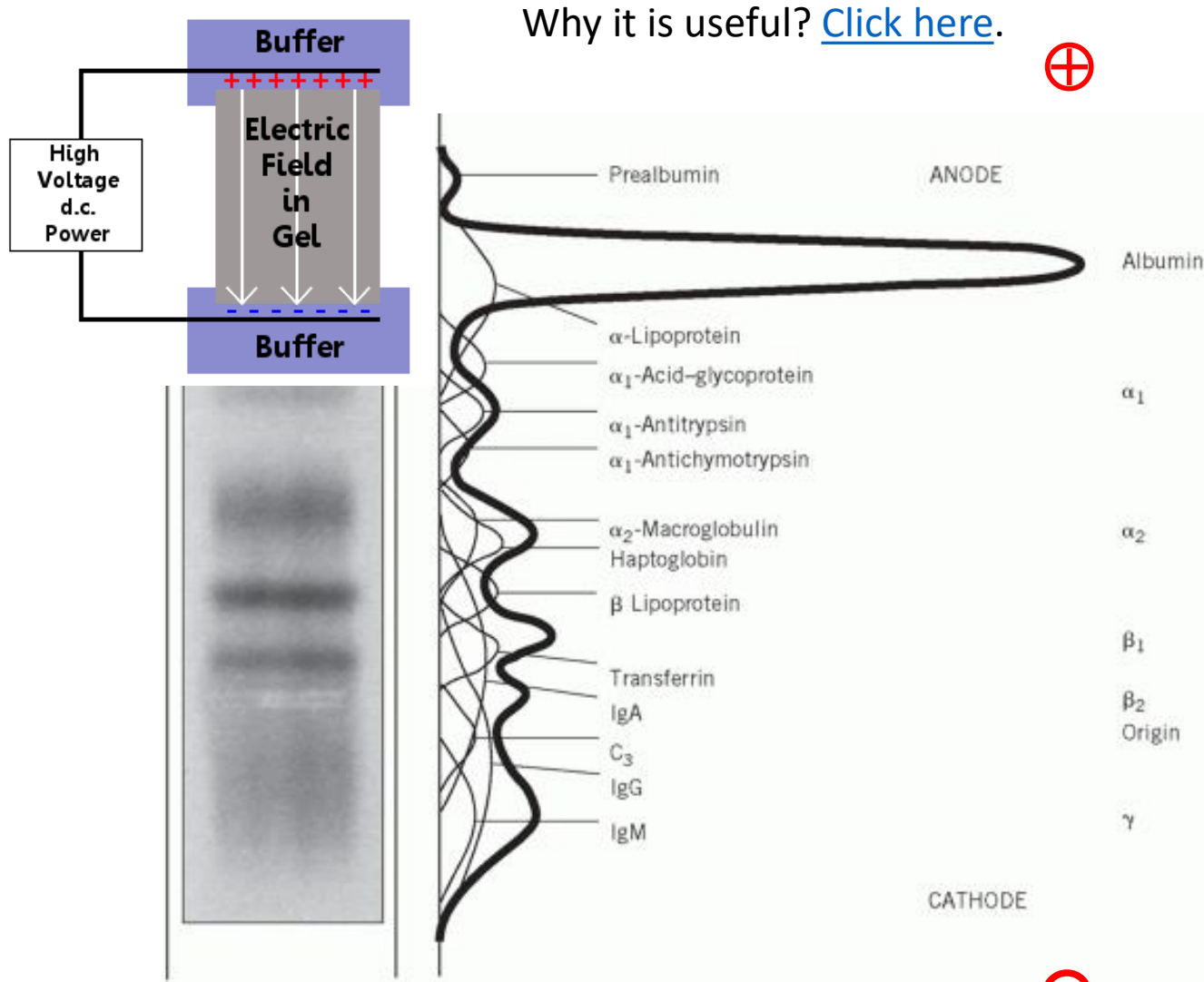
PROTEINS OF BLOOD PLASMA (7%)

- oncotic blood pressure
- transport
- coagulation
- immune response
- regulatory proteins



PROTEINS OF BLOOD PLASMA (7%)

- **prealbumin**
- transport
- **albumin**
- 68kDa
- transport
- osmotic pressure
- **α_1 region**
- α_1 lipoprotein (HDL)
- α_1 acid glycoprotein
- α_1 antitrypsin
- (α_1 fetoprotein)
- **α_2 region**
- α_2 macroglobulin
- haptoglobin
- **β_1 region**
- transferrin
- hemopexin
- β lipoprotein (LDL)
- C4 (complement)
- **β_2 region**
- CRP
- fibrinogen
- β_2 microglobulin
- C3 (complement)
- **γ region**
- IgA, IgG, IgM

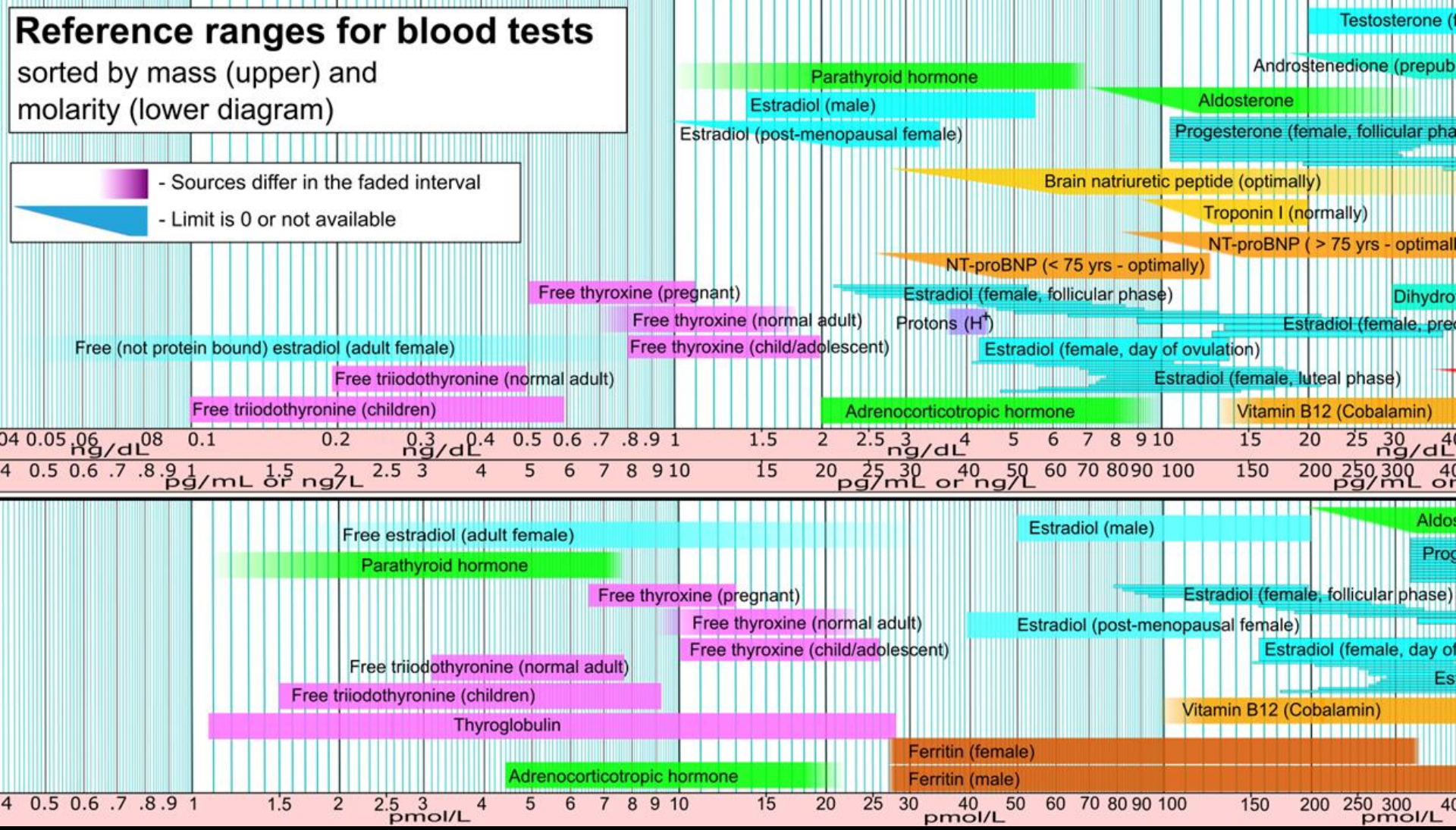


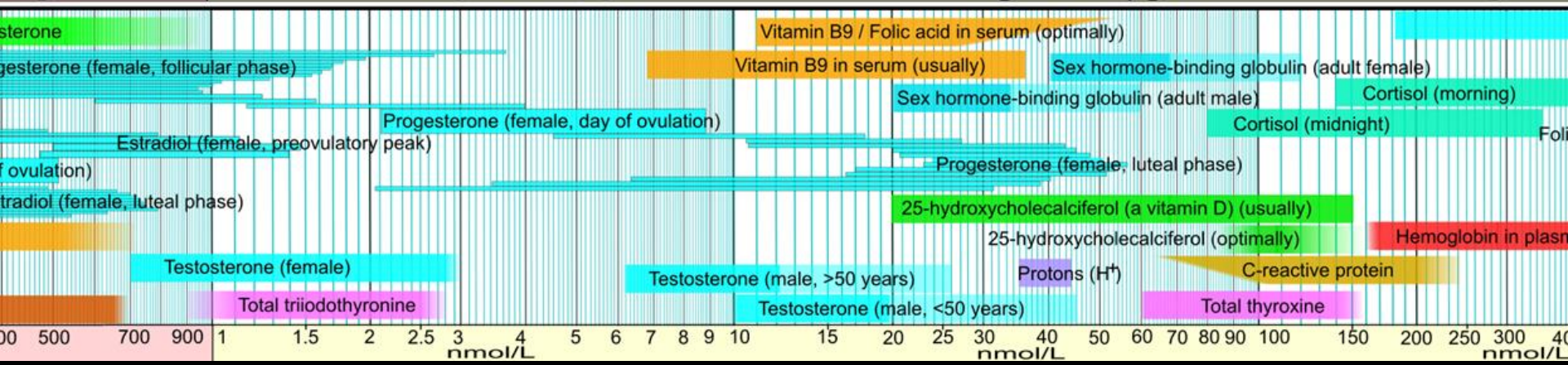
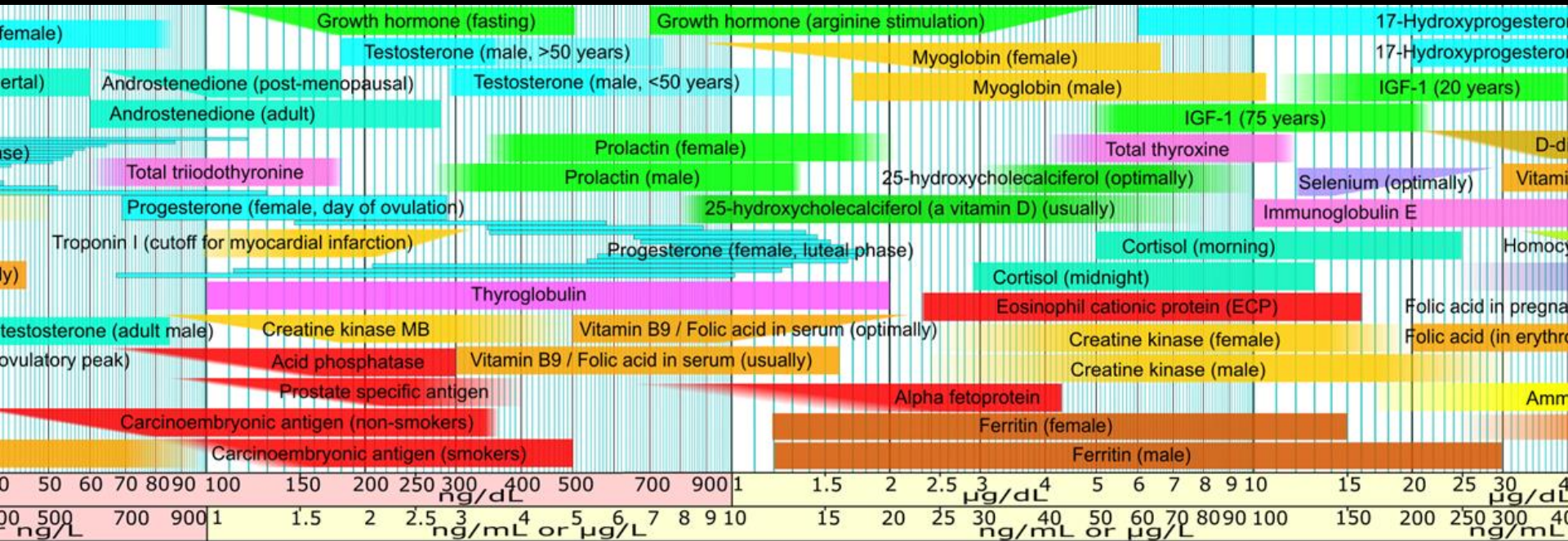
. Electrophoretic separation of serum proteins
A. Electrophoretogram of normal serum on cellulose acetate strip
B. Densitometric scanning from cellulose acetate strip converts bands to characteristic peaks of albumin, α_1 -globulin, α_2 -globulin, β -globulin and γ -globulin

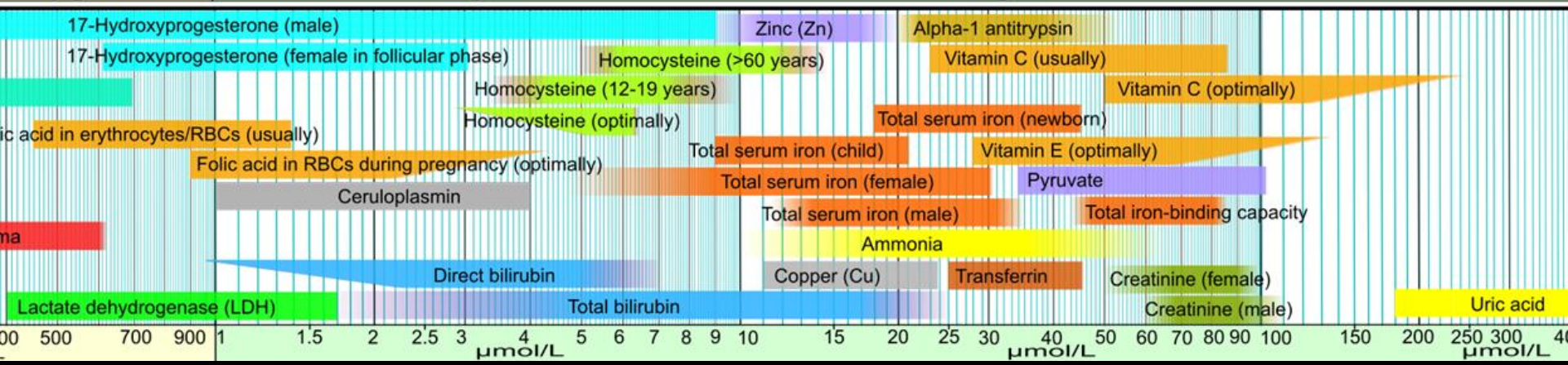
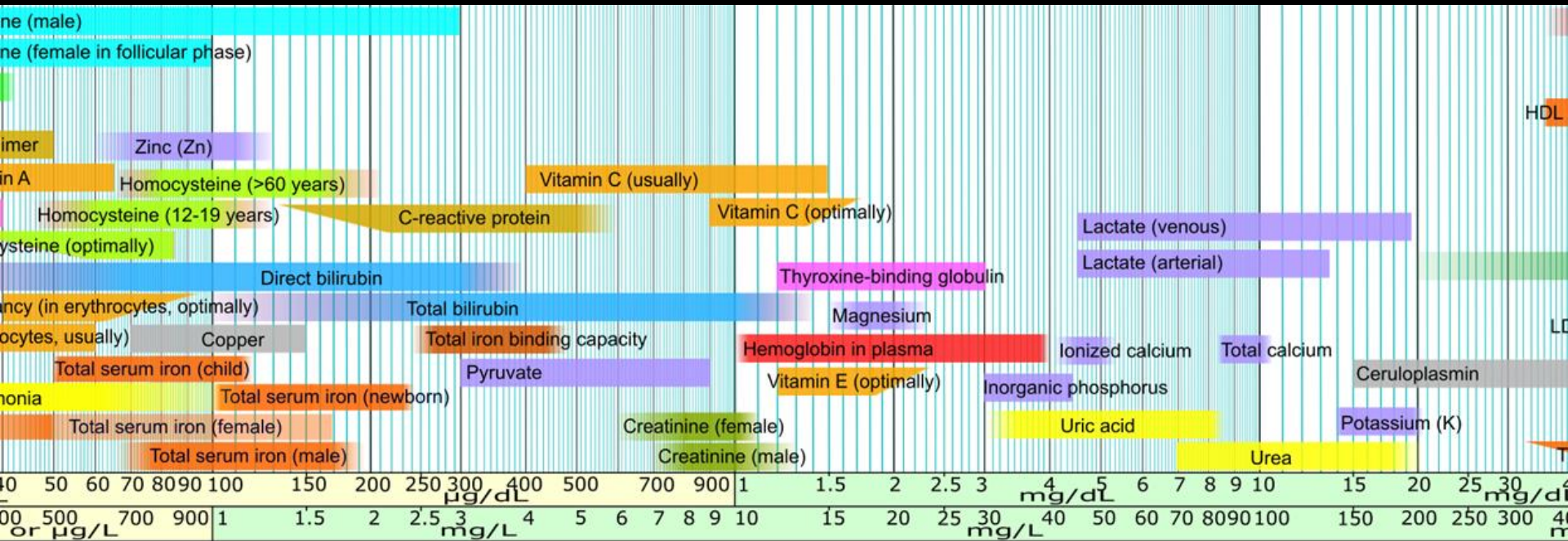
Reference ranges for blood tests

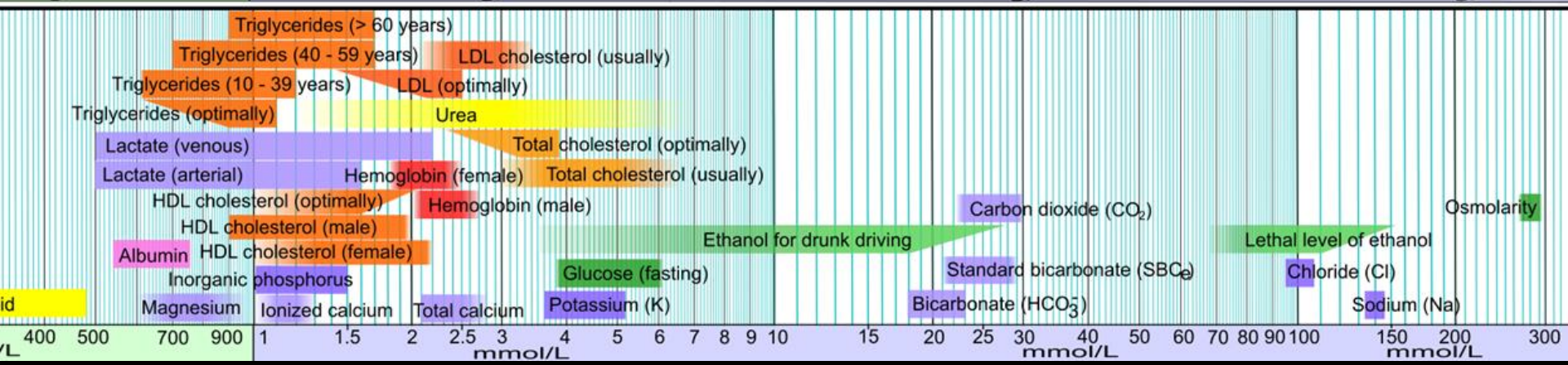
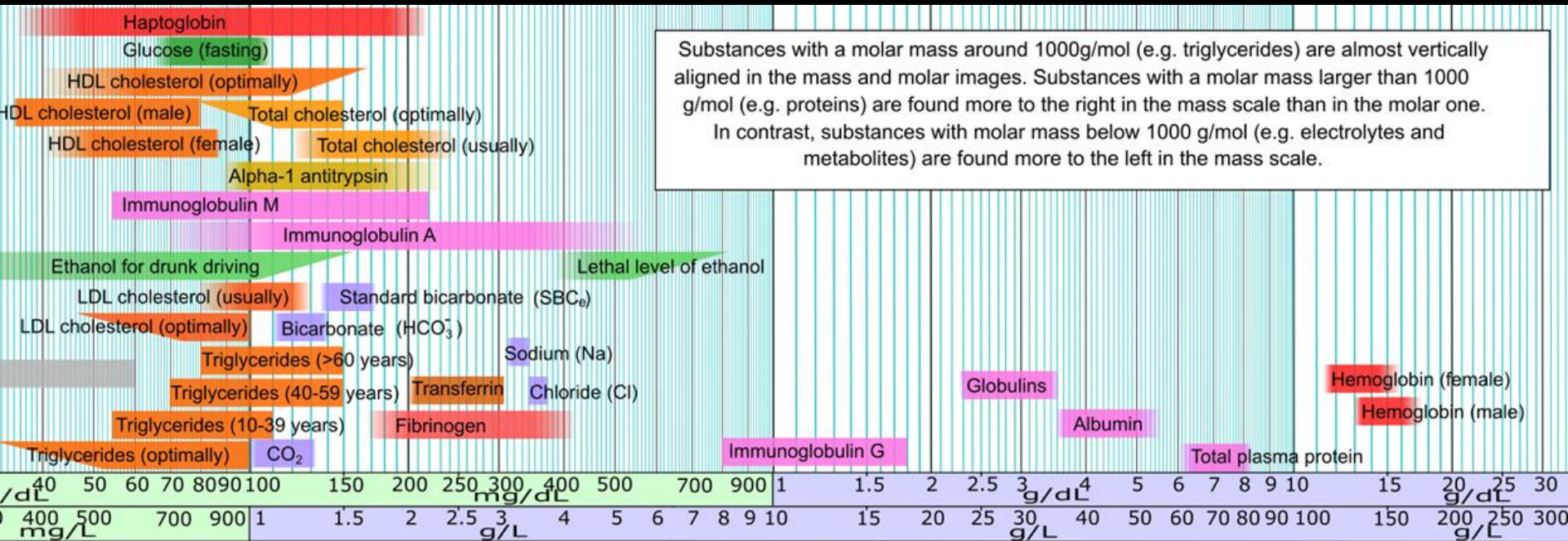
sorted by mass (upper) and molarity (lower diagram)

- Sources differ in the faded interval
- Limit is 0 or not available



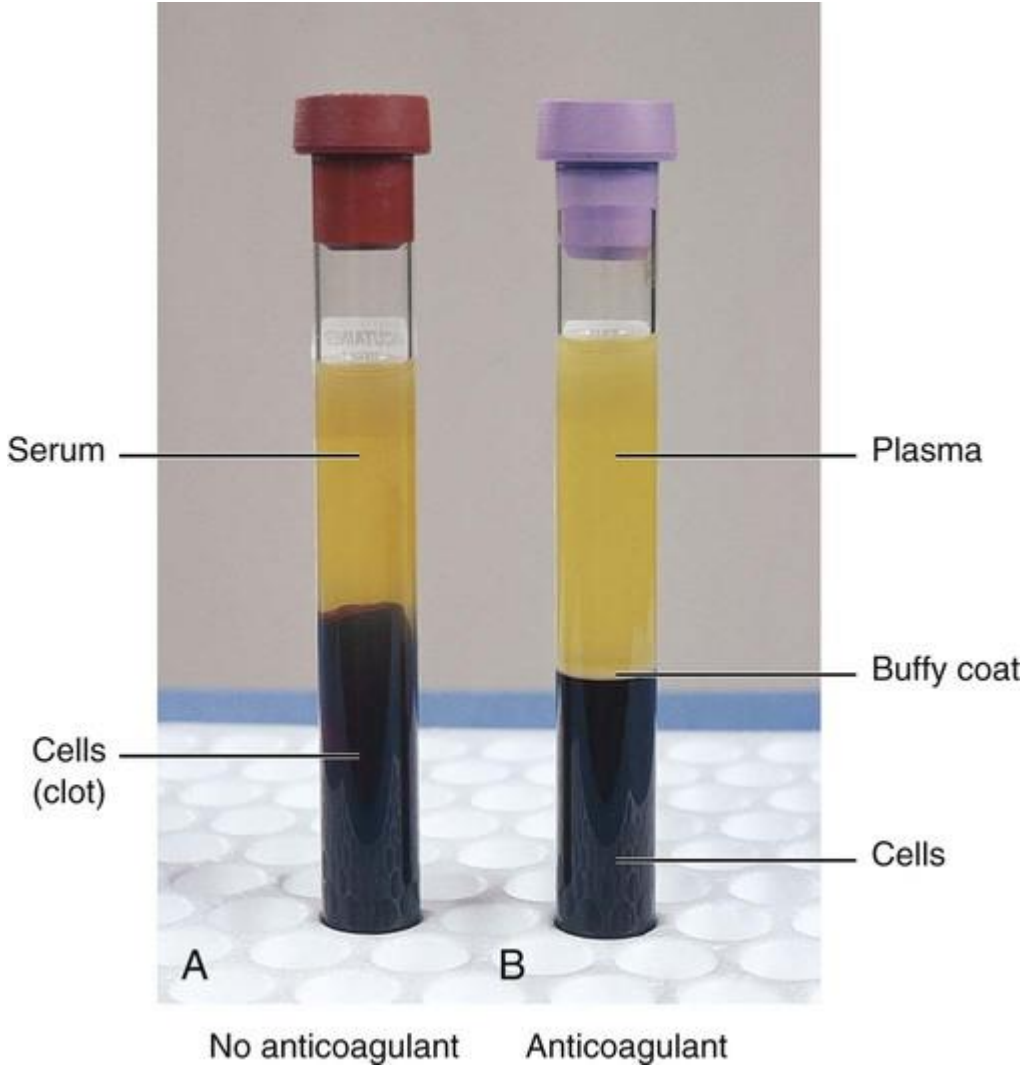




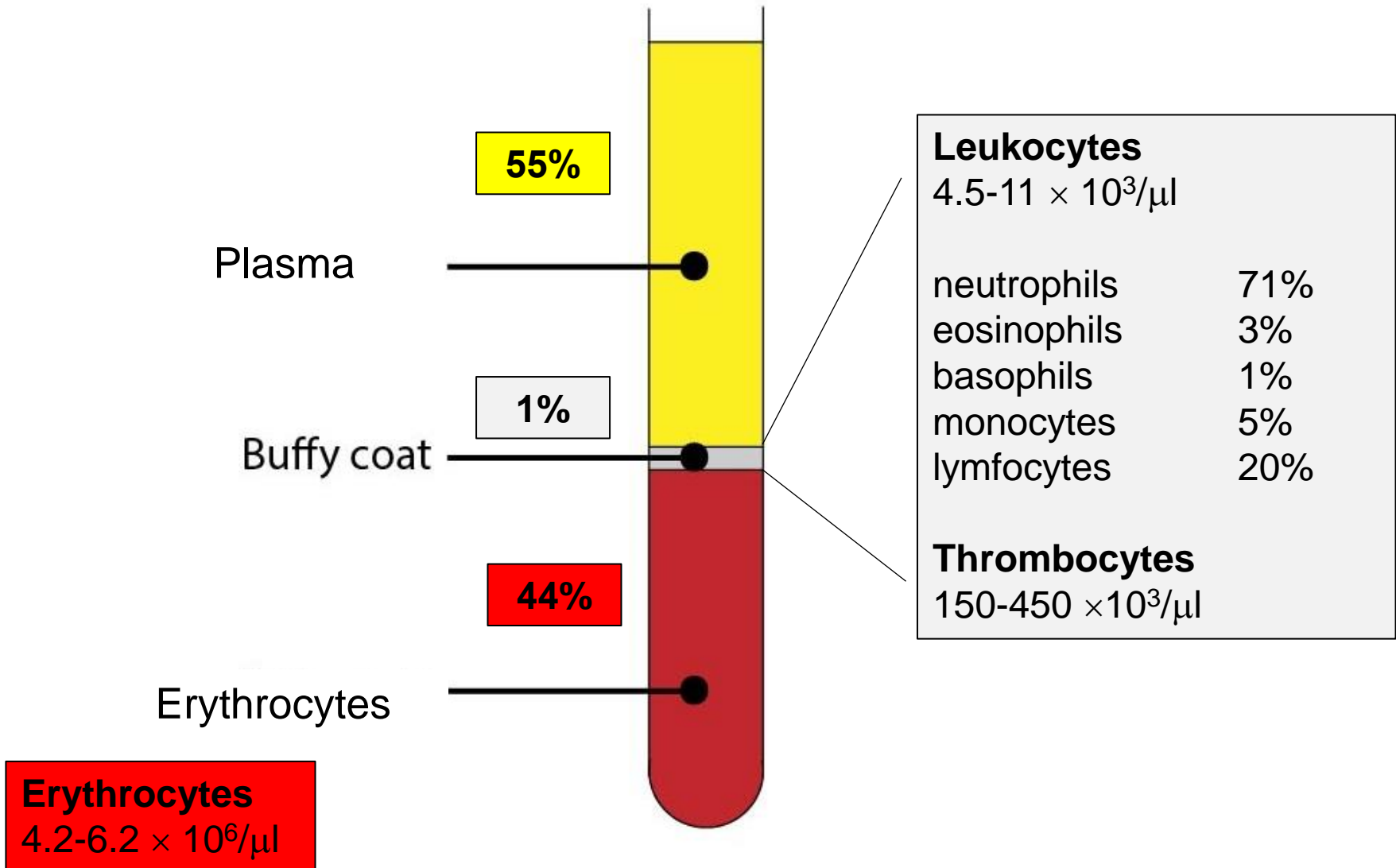


BLOOD PLASMA AND SERUM

- serum ≠ plasma



FORMED BLOOD ELEMENTS



HEMATOCRIT

Ratio of erythrocyte mass volume to volume of full blood

Erythrocytes
 $4.2-6.2 \times 10^6/\mu\text{l}$

HEMATOCRIT



47±5%

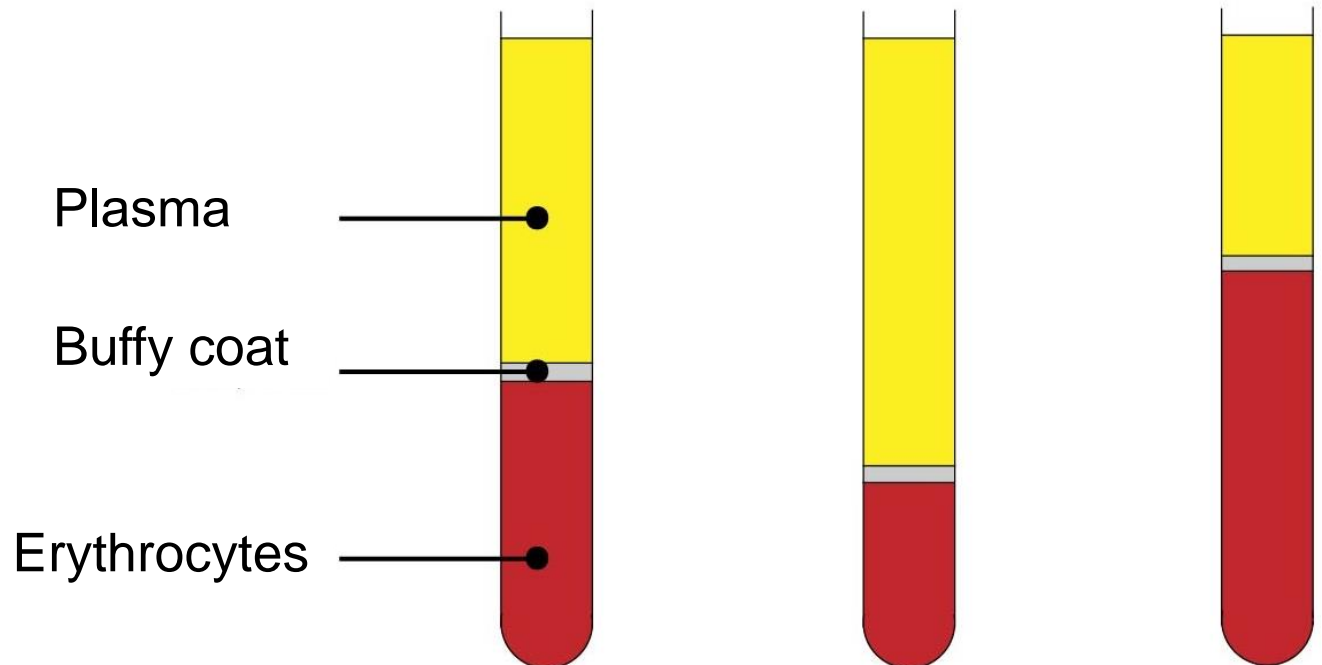


42±4%

Norm

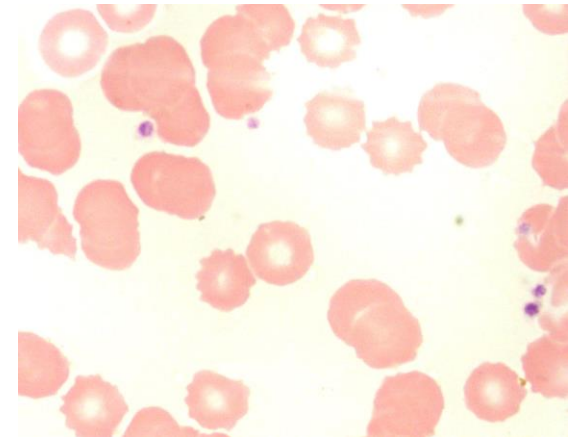
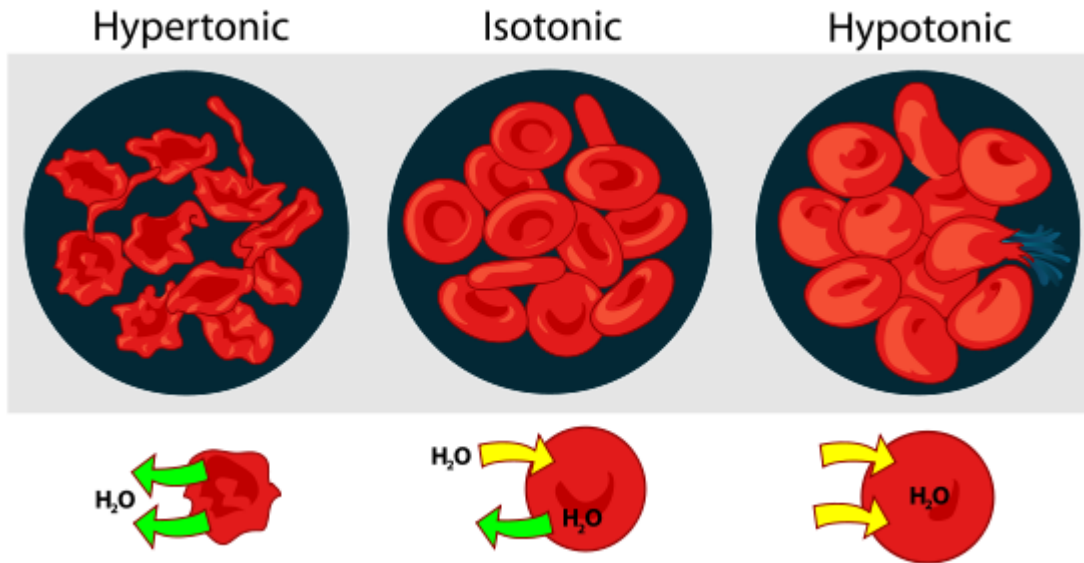
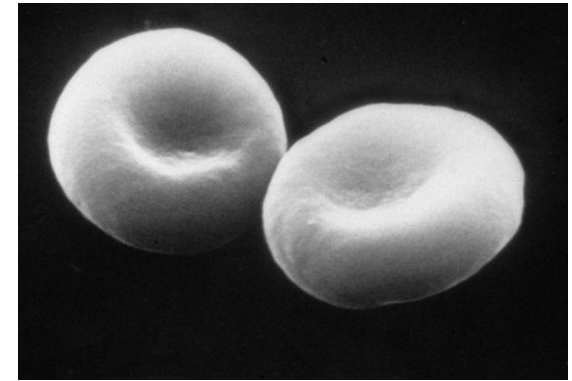

Anemia

Polycythemia



ERYTHROCYTES

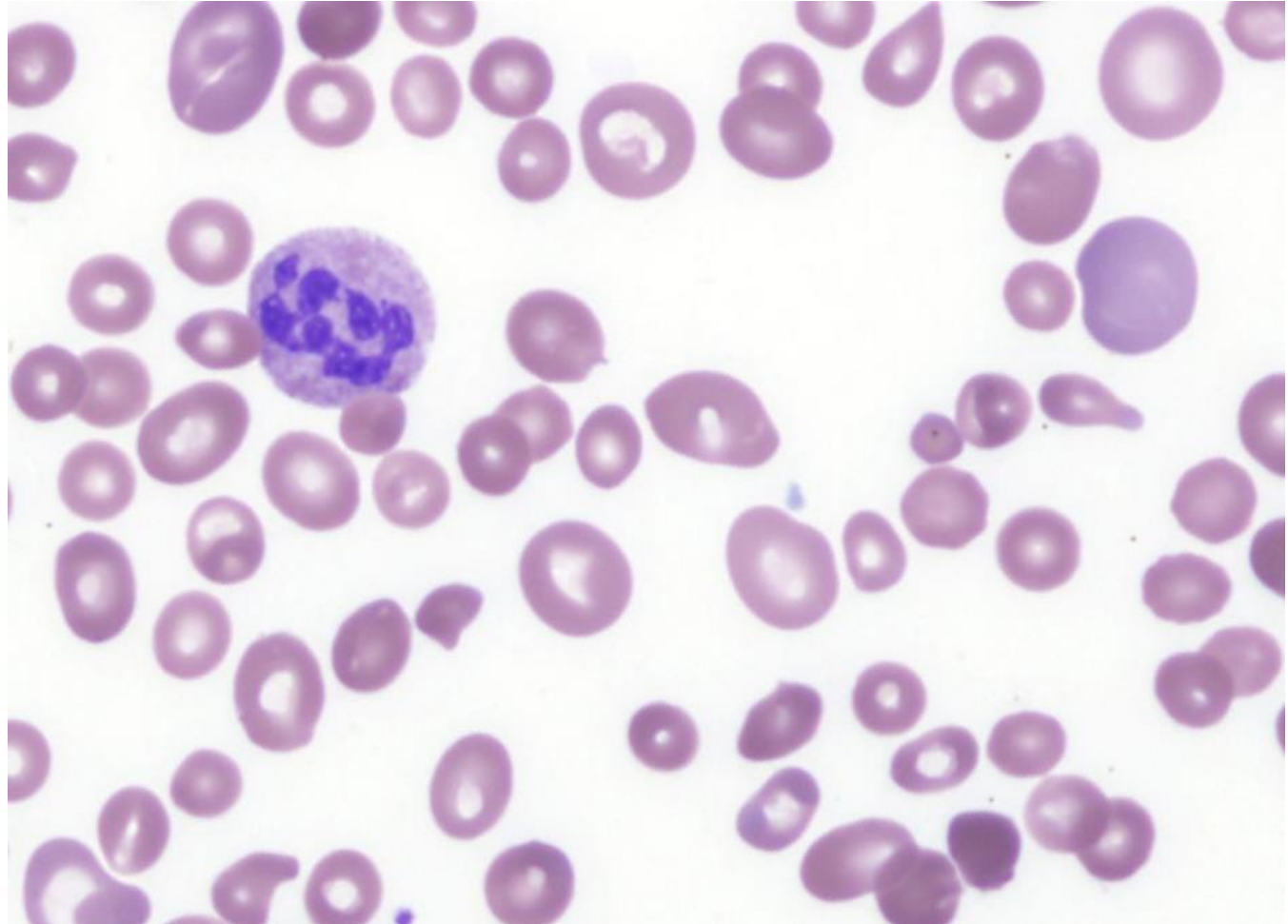
Size depends on osmotic pressure of environment



ERYTHROCYTES

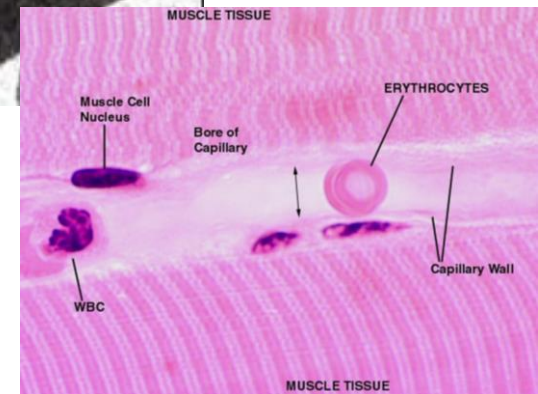

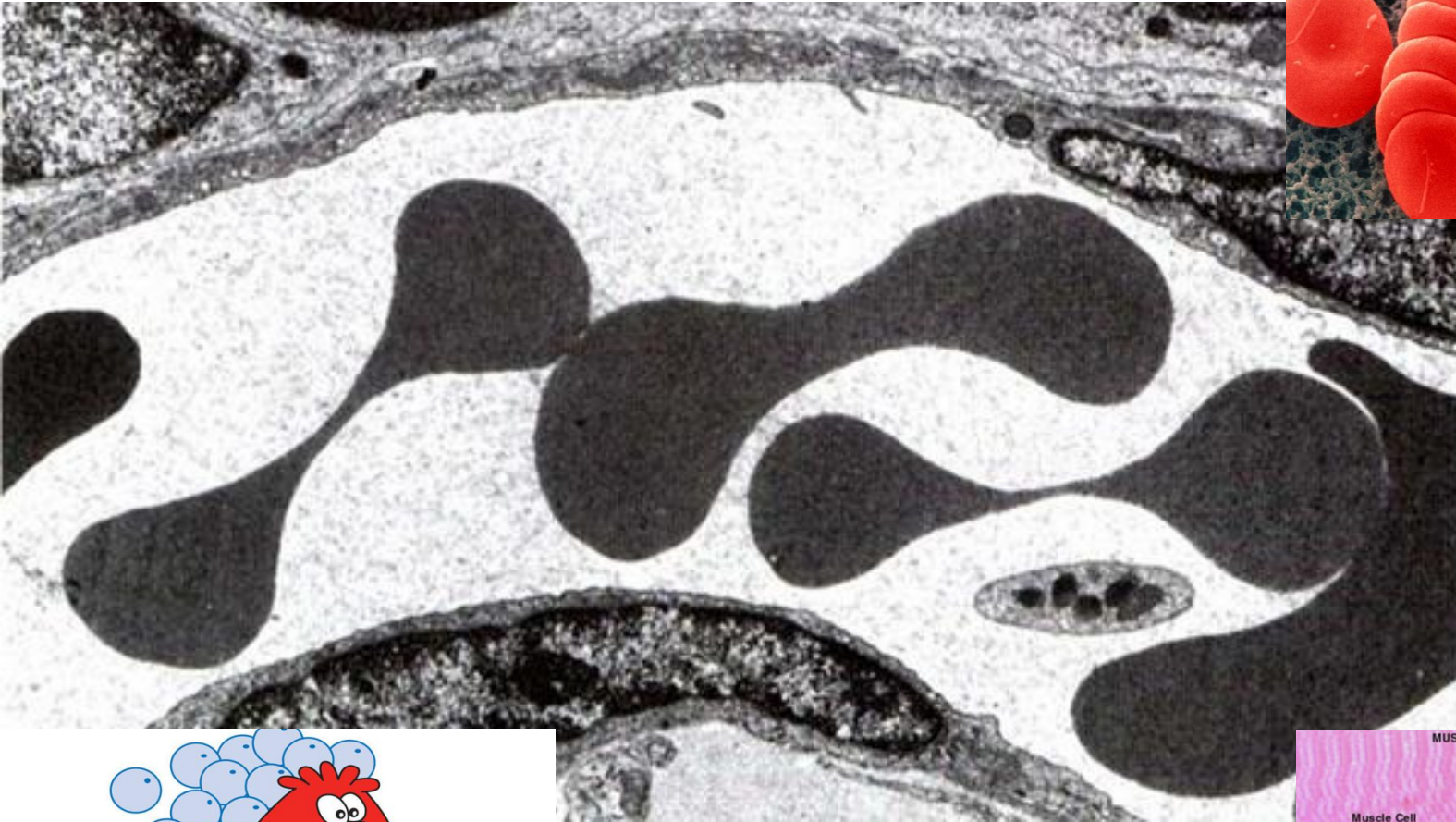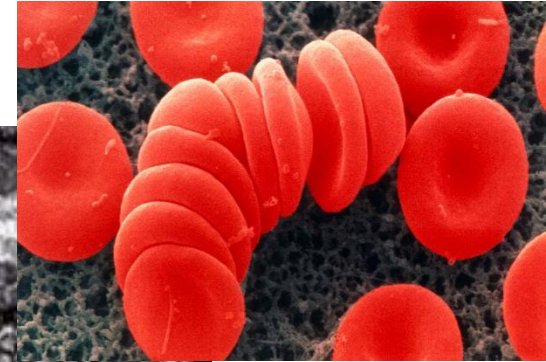
Deviations from normal size

- **anisocytosis**
 - macrocytes ($>9\ \mu\text{m}$)
 - microcytes ($<6\ \mu\text{m}$)



ERYTHROCYTES

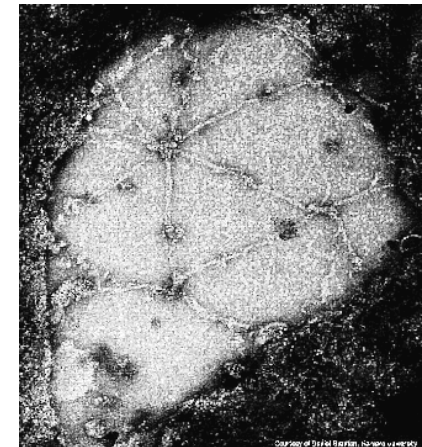
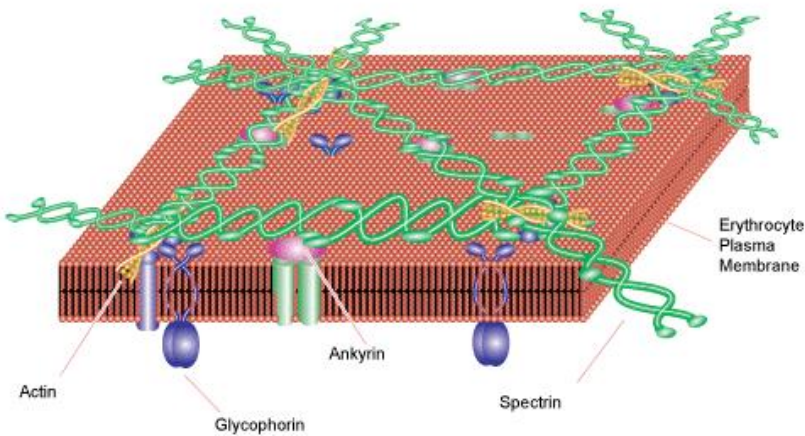
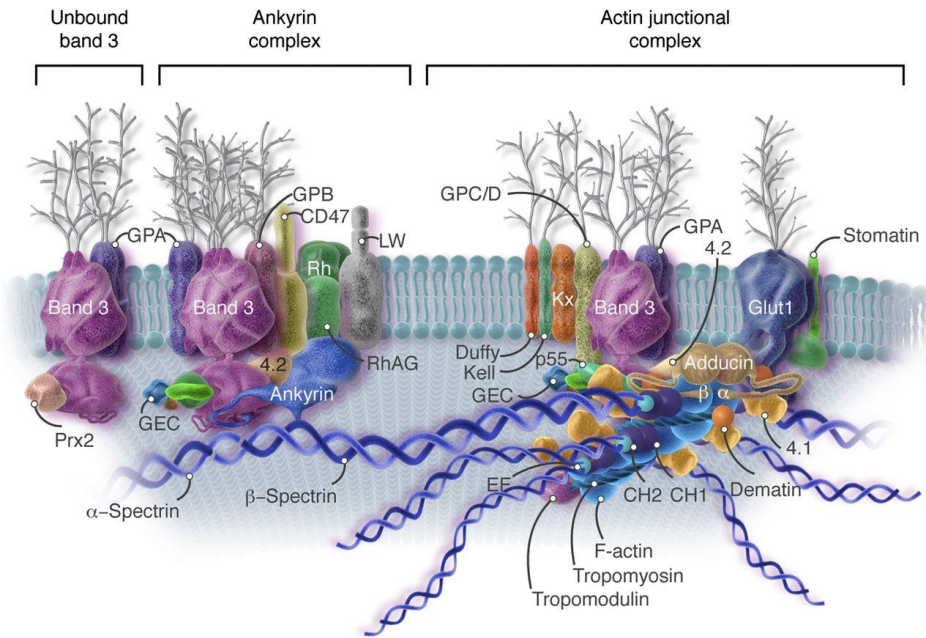
Erythrocyte is amazingly flexible cell



ERYTHROCYTES

Shape of erythrocytes

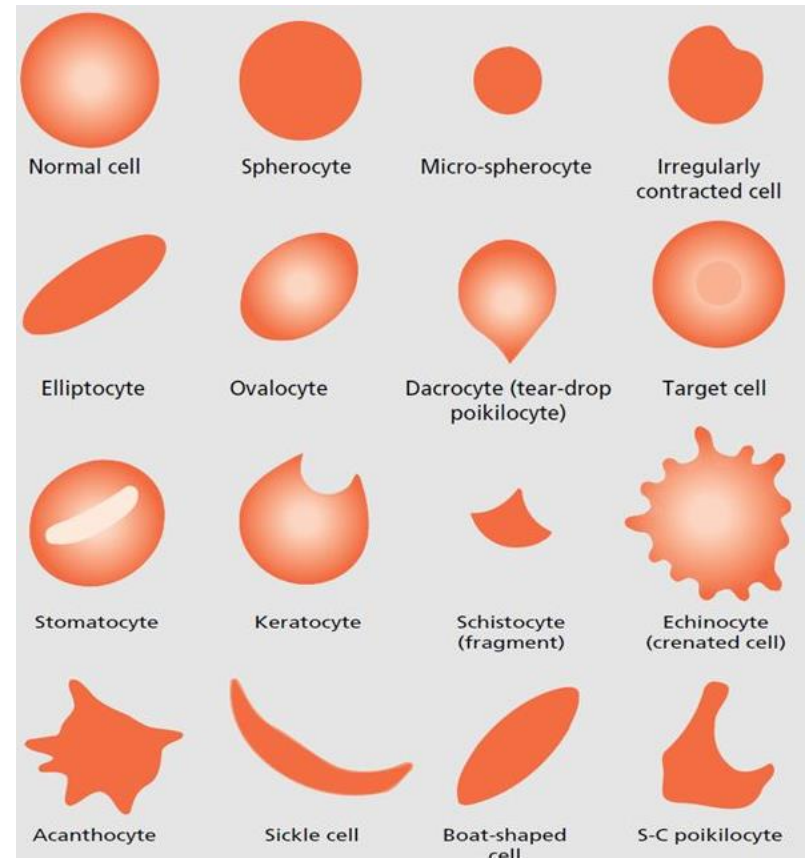
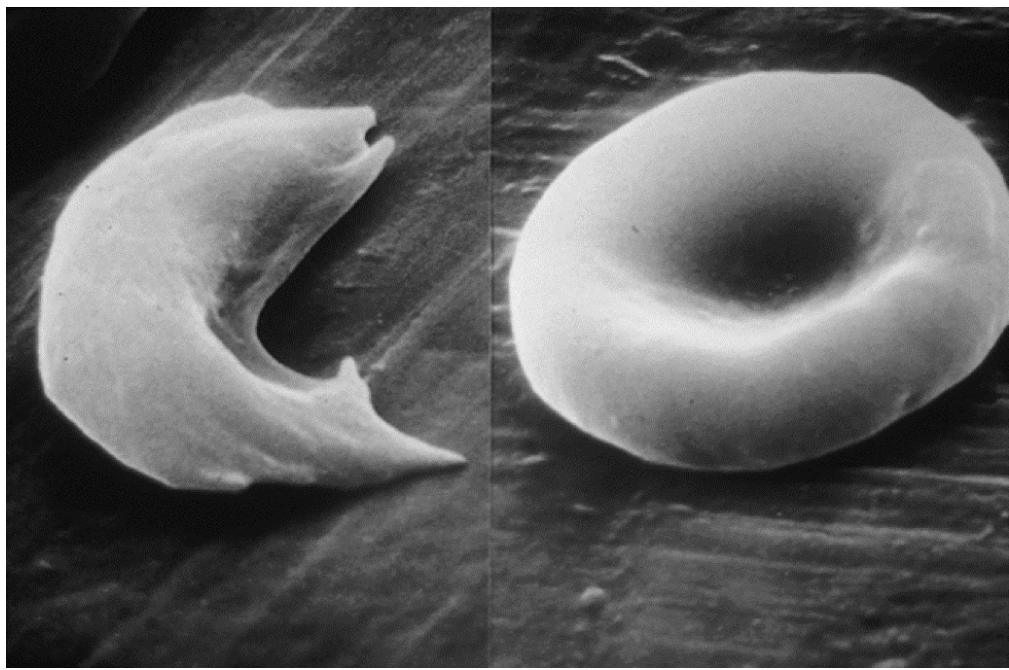
- **integral proteins**
 - band 3, glycoprotein A (ion transporters)
- **spectrin**
- **ankyrin**
- **actin and actin-associated proteins**
 - tropomodulin, tropomyosin
- **hemoglobin**



ERYTHROCYTES

Deviations from biconcave shape

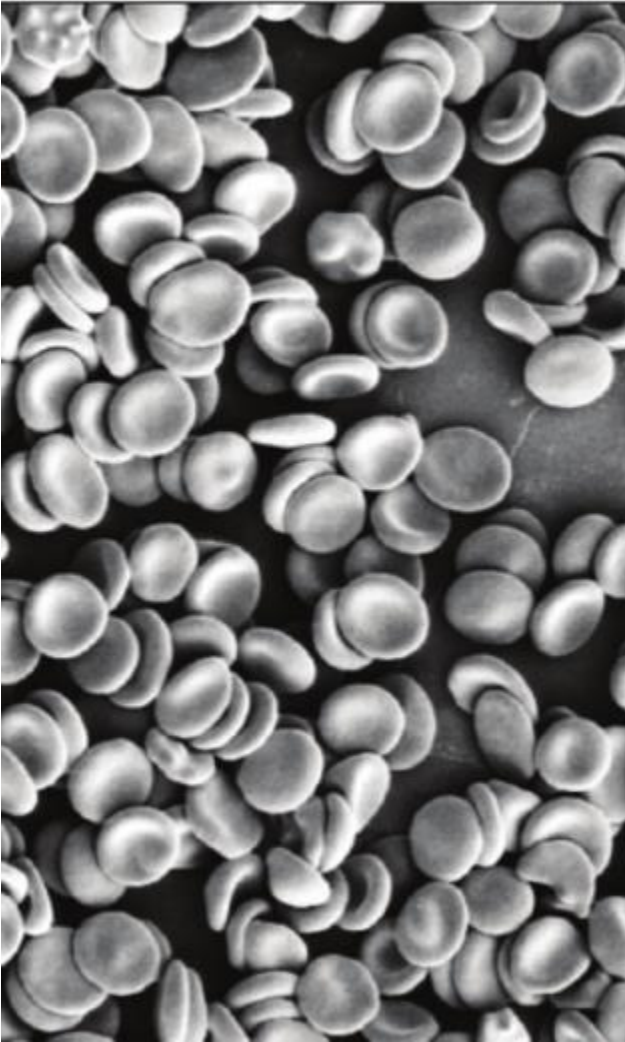
- **poikilocytosis**
 - **acanthocytes** (irregular spikes)
 - **codocytes** („tyre “)
 - **echinocytes** (spiked membrane)
 - **eliptocytes** (elliptic)
 - **spherocytes** (spheroidal)
 - **stomatocytes** (some parts missing or other irregularities)
 - **drepanocytes** (sickle)
 - **dacrocytes** (tear drop)



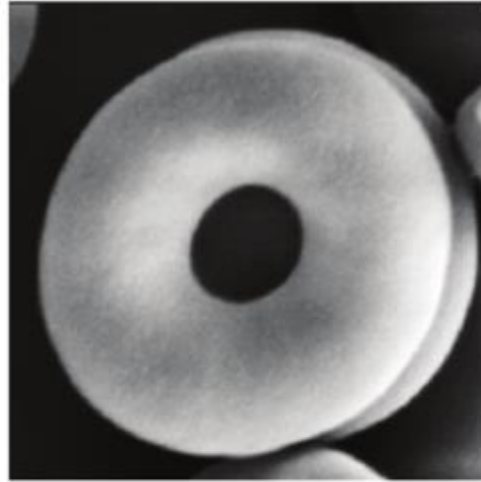
ERYTHROCYTES

Deviations from biconcave shape

Normal

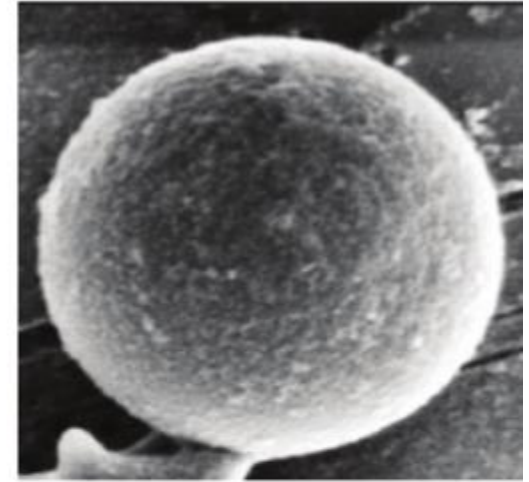


Codocyte

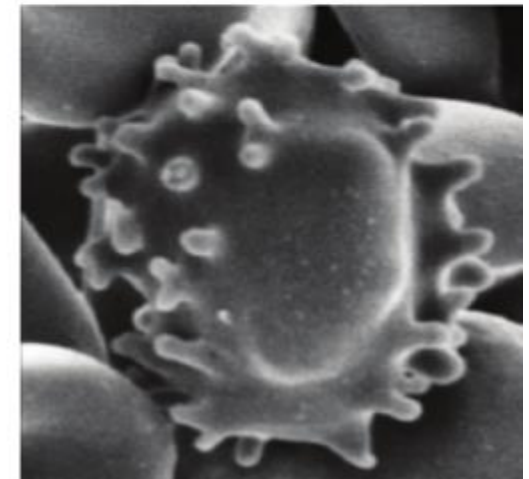
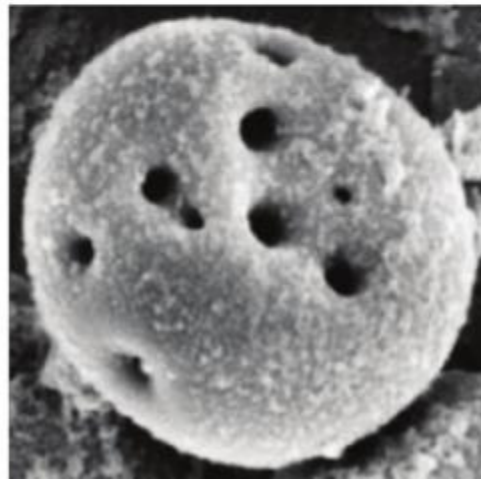


(b)

Spherocyte



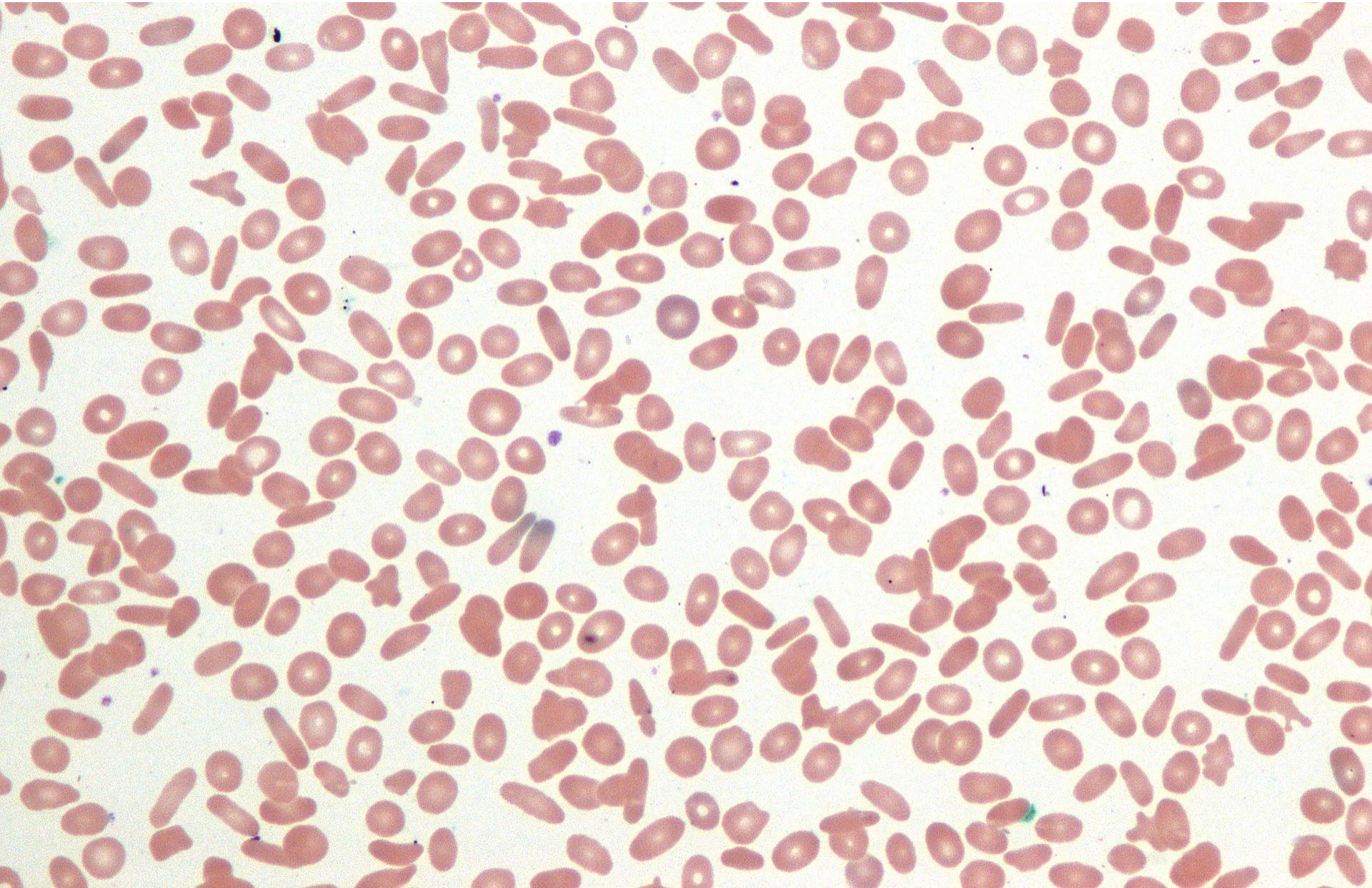
(d)



Echinocyte

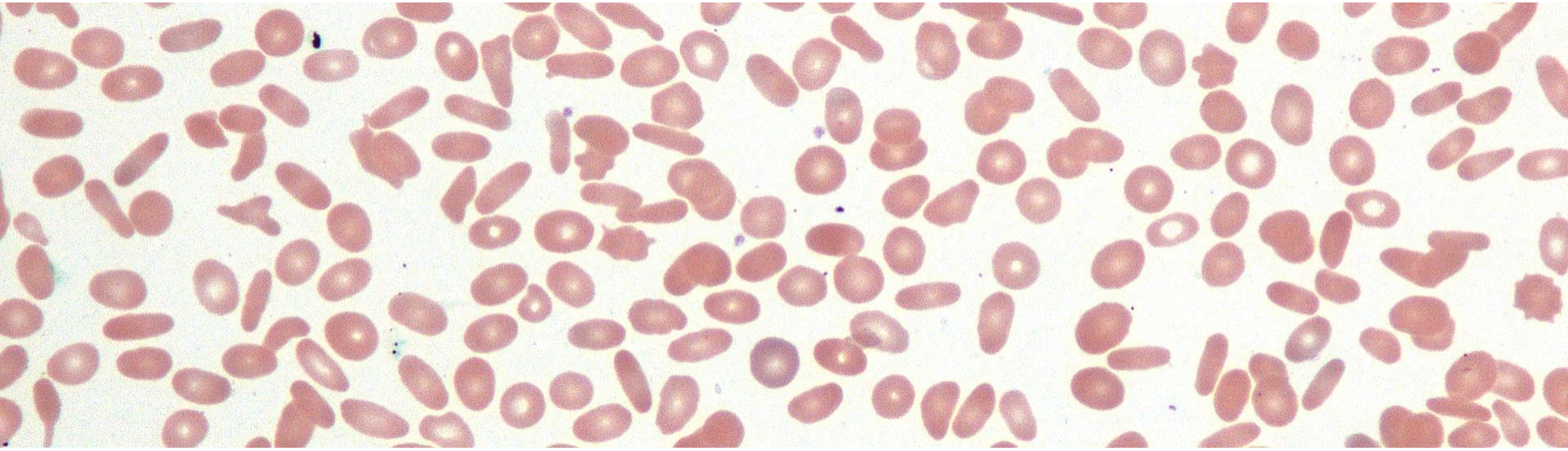
ERYTHROCYTES

Hereditary elliptocytosis

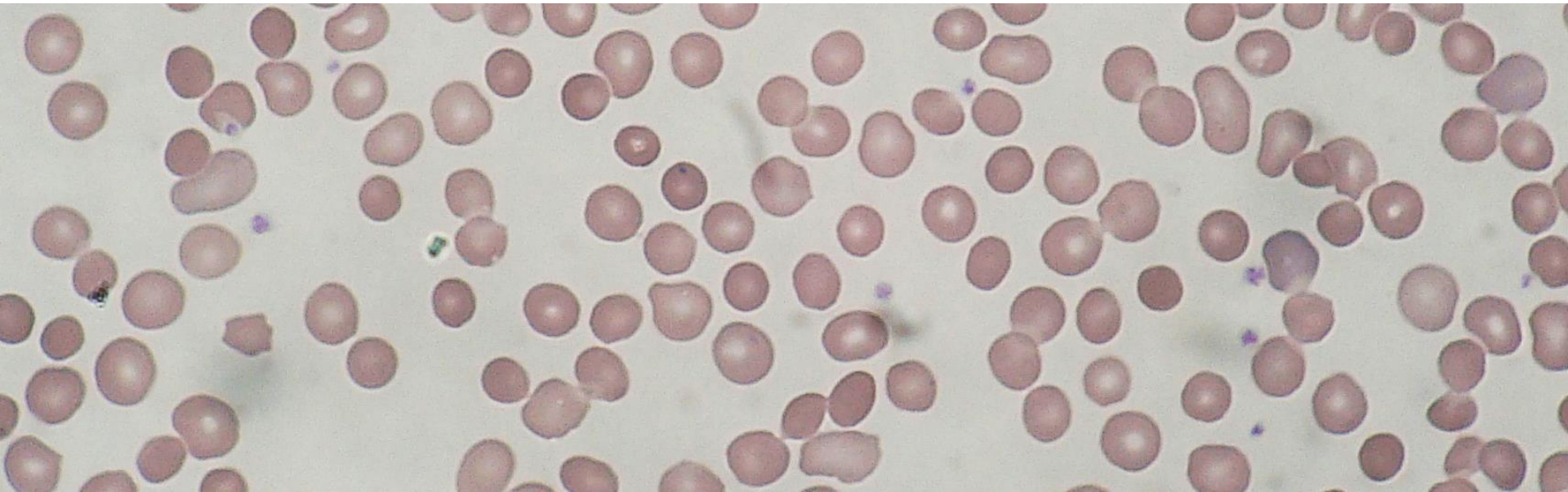


ERYTHROCYTES

Hereditary elliptocytosis



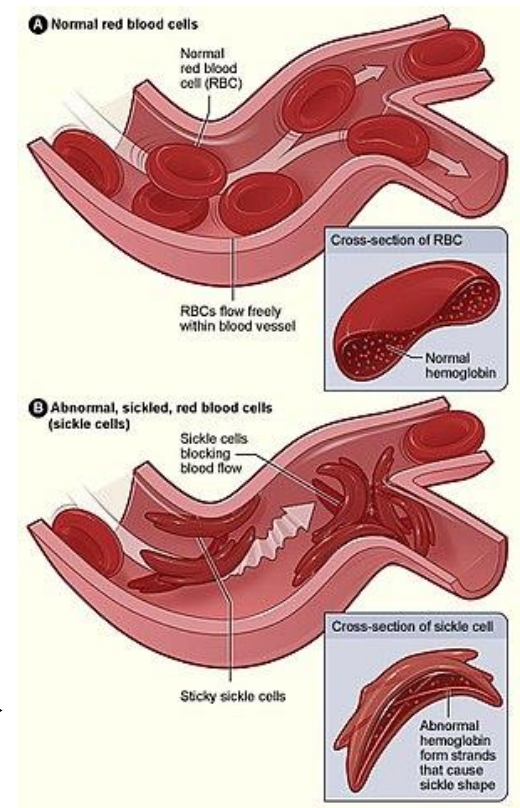
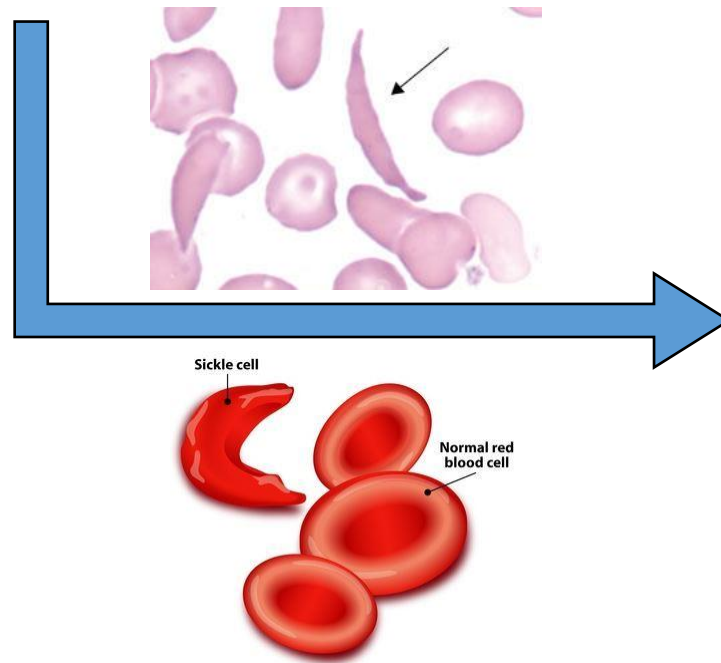
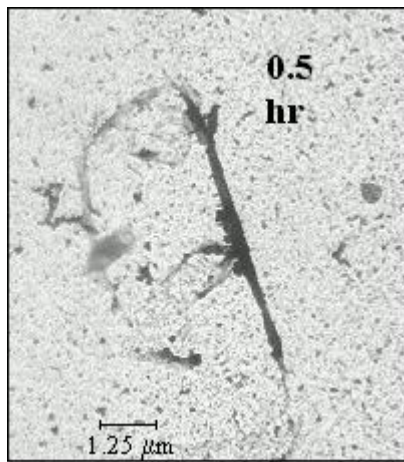
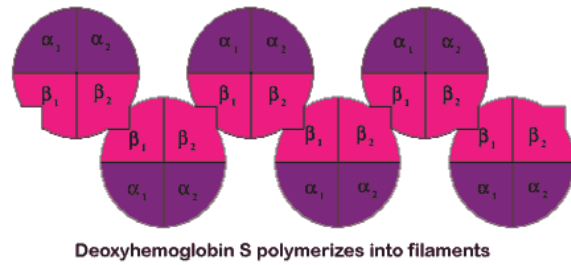
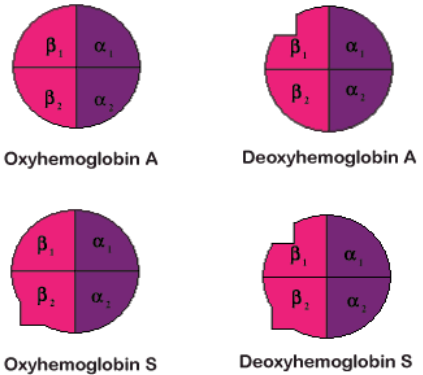
Hereditary spherocytosis



ERYTHROCYTES

Sickle cell anemia

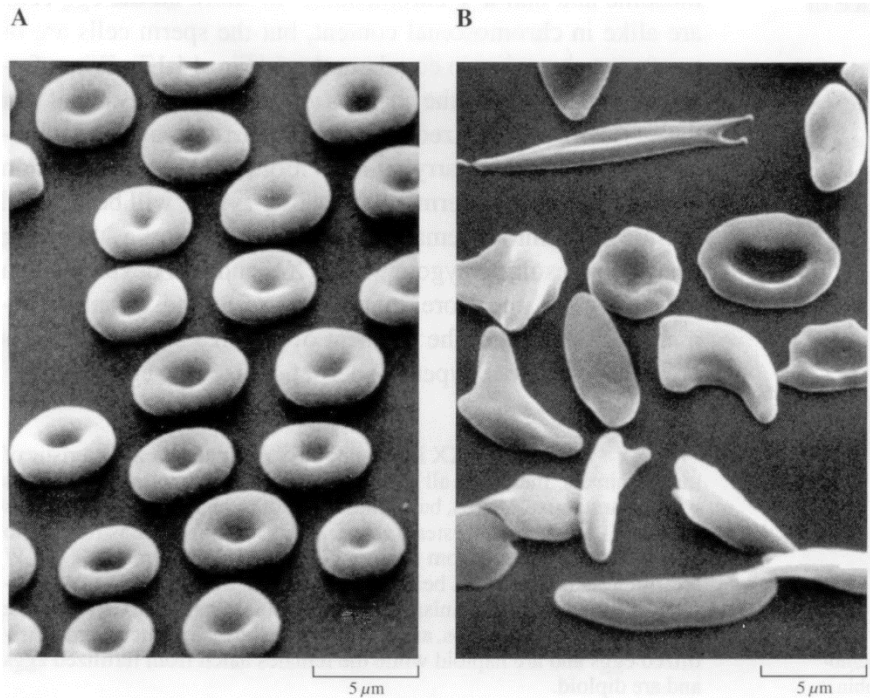
- Abnormal hemoglobin (hemoglobin S)



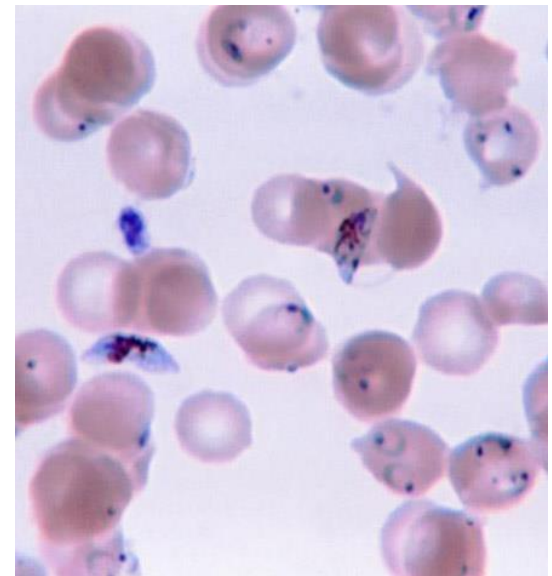
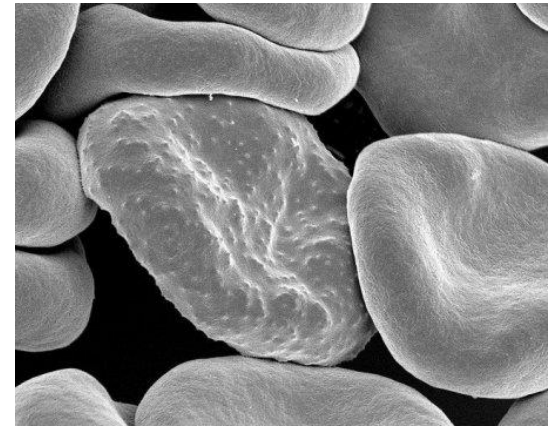
ERYTHROCYTES

Sickle cell anemia

- pathological genotype (heterozygote HbS/HbA) is beneficial

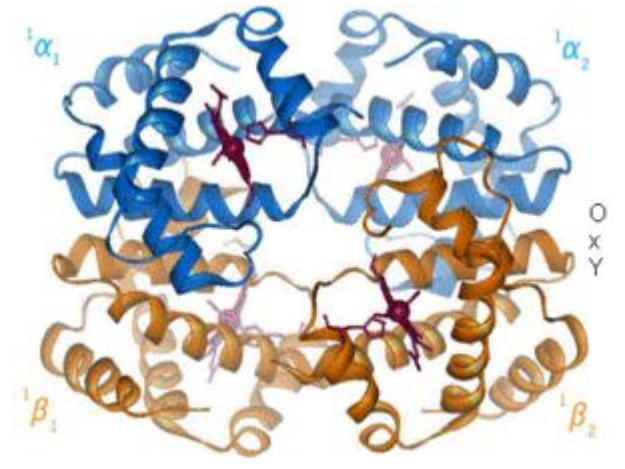
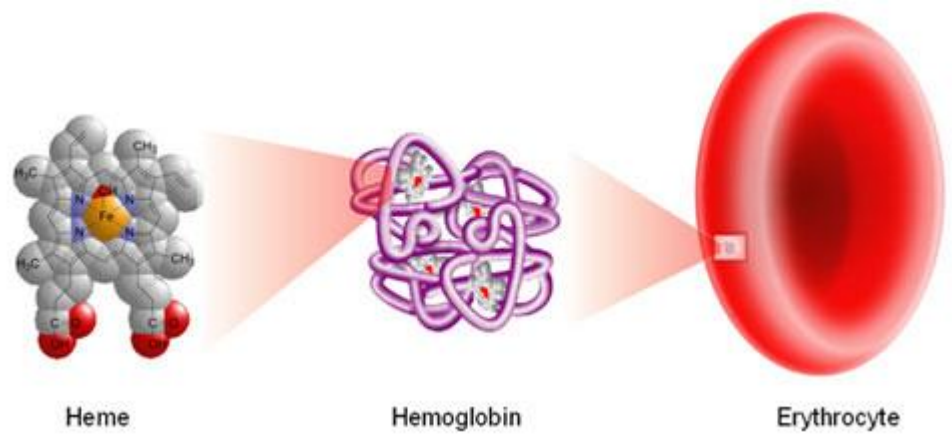
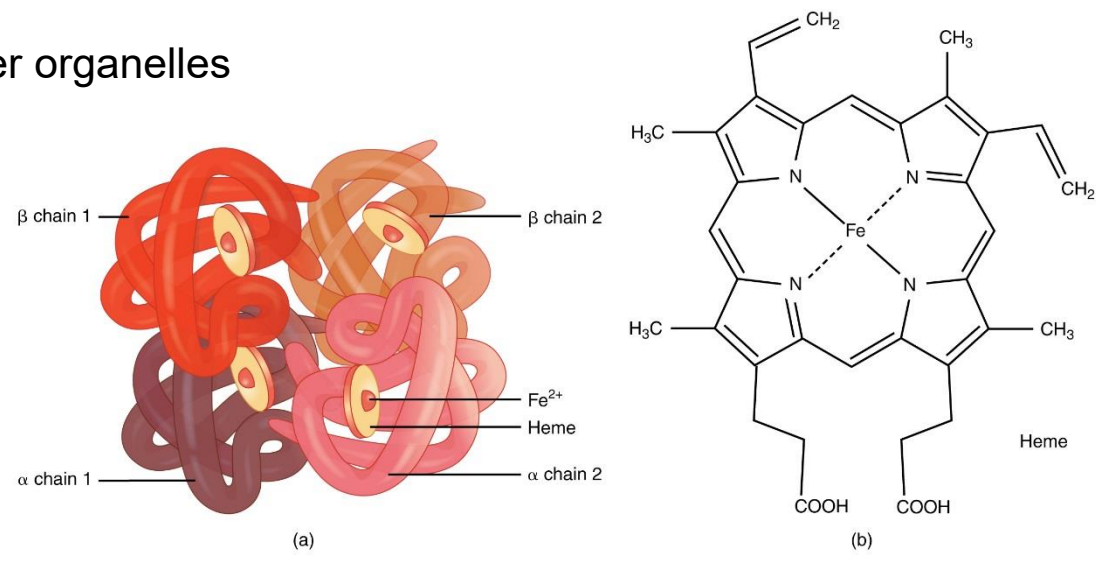


Malaria

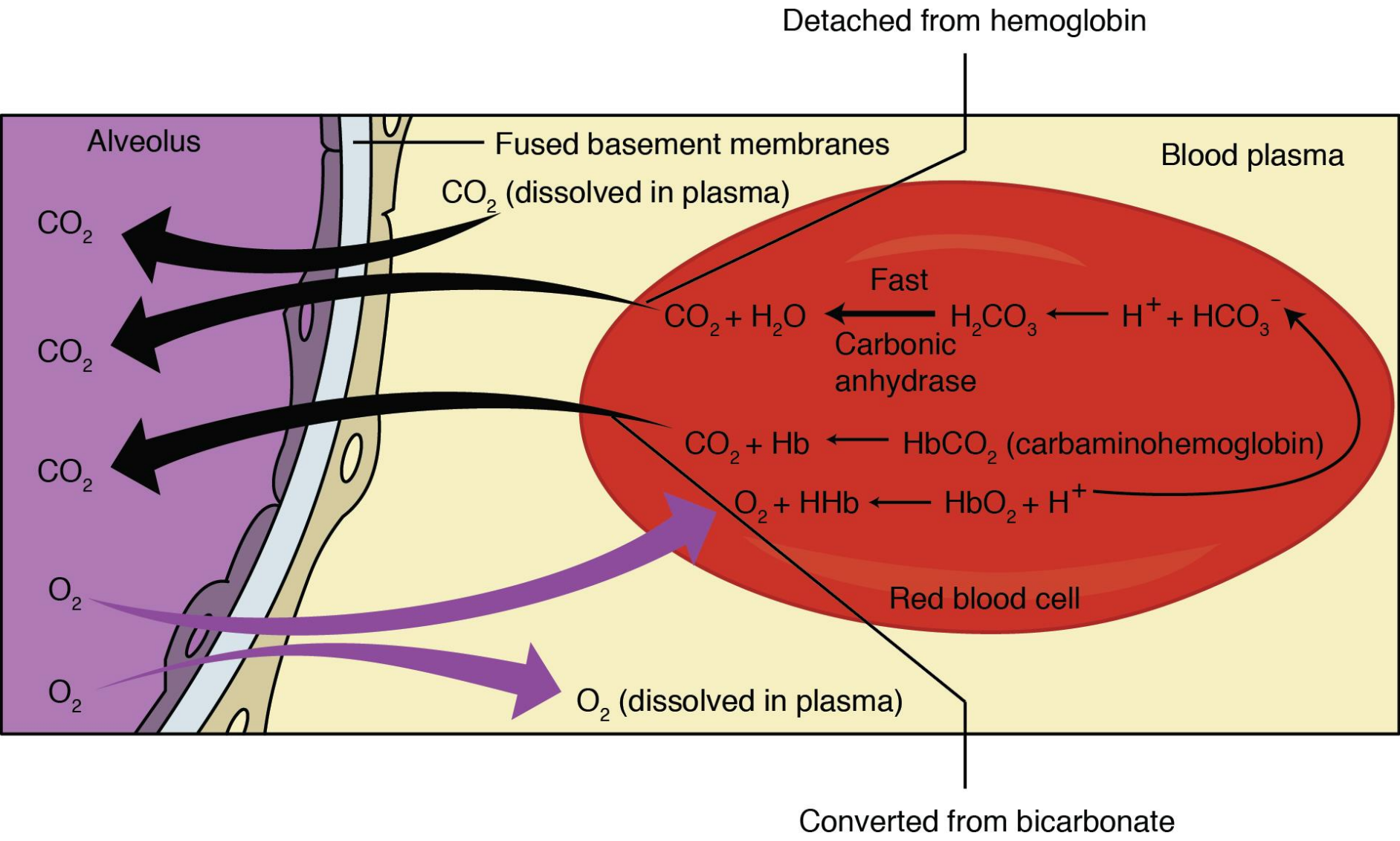


ERYTHROCYTES

- Erythrocytes lack nucleus and other organelles
- Anaerobic glycolysis
- Hemoglobin

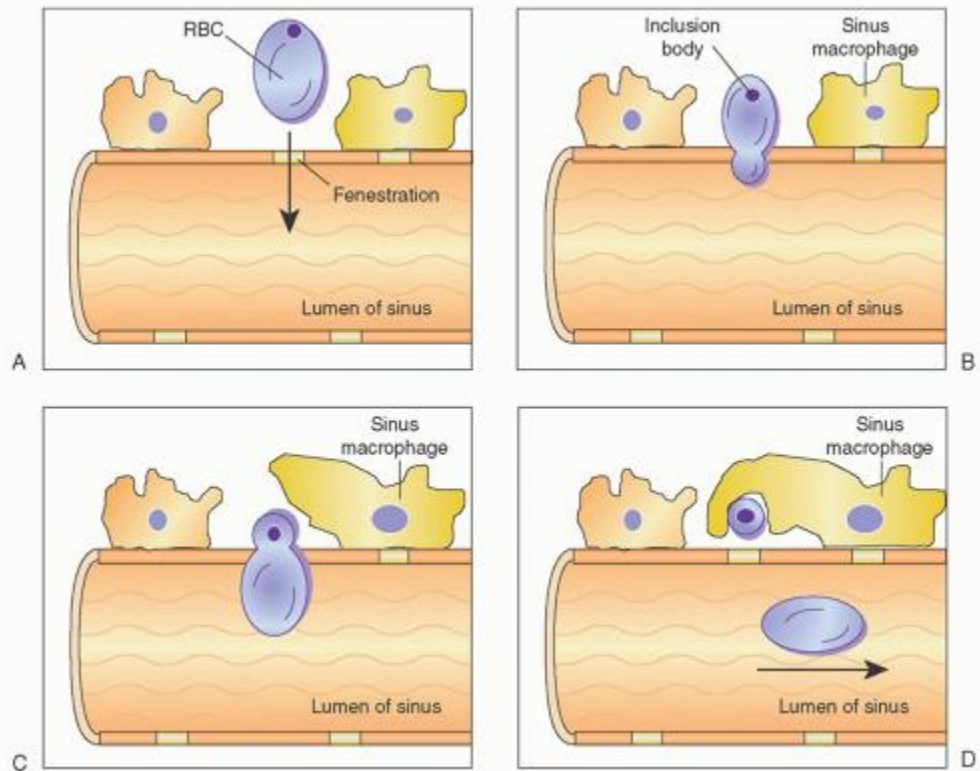
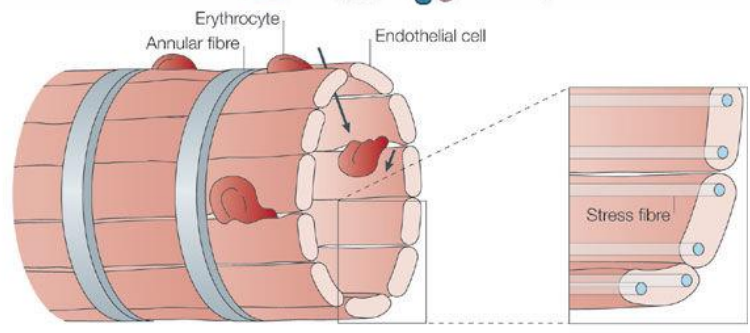
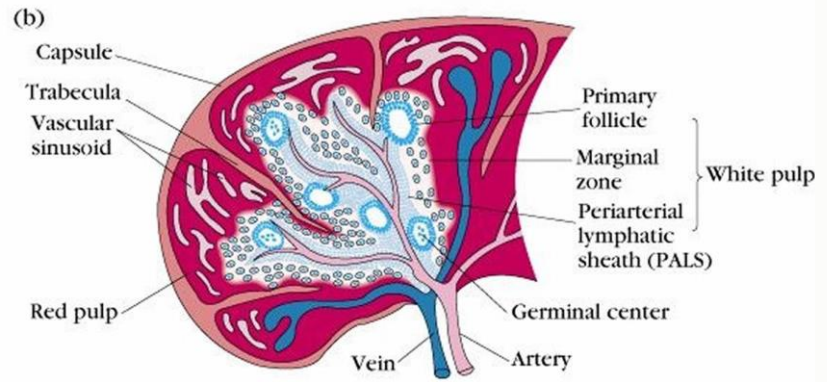
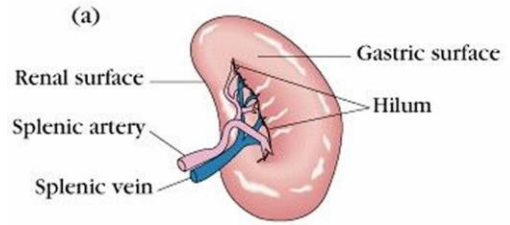
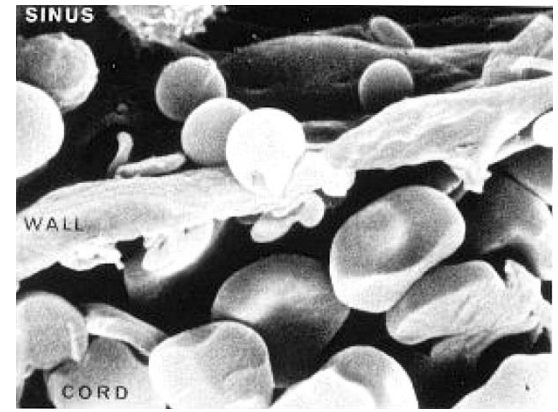


ERYTHROCYTES



ERYTHROCYTES

- Life span 120 days
- Constant abrasion
- No regeneration
- Removal of aged or damaged erythrocytes in spleen



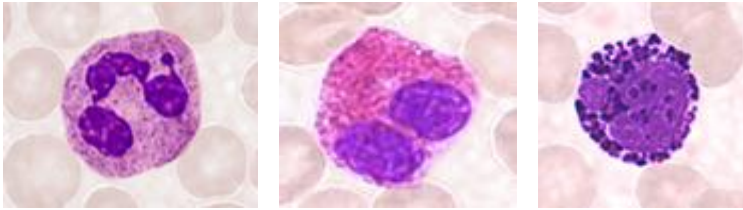
LEUKOCYTES

- immune response
- morphological classification – **cytoplasmic granules**
(does not follow hematopoiesis)

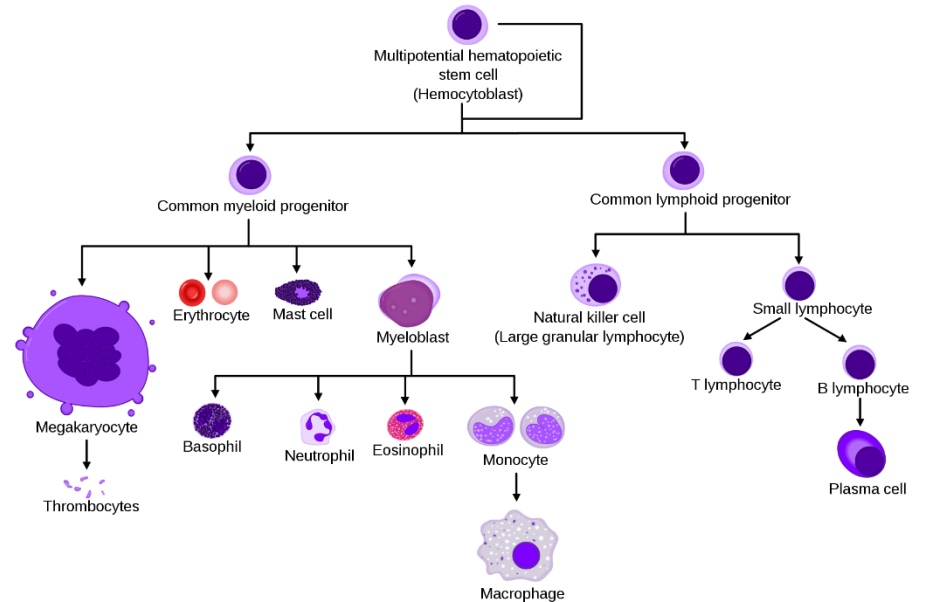
Granulocytes

Agranulocytes

Neutrophils Eosinophils Basophils

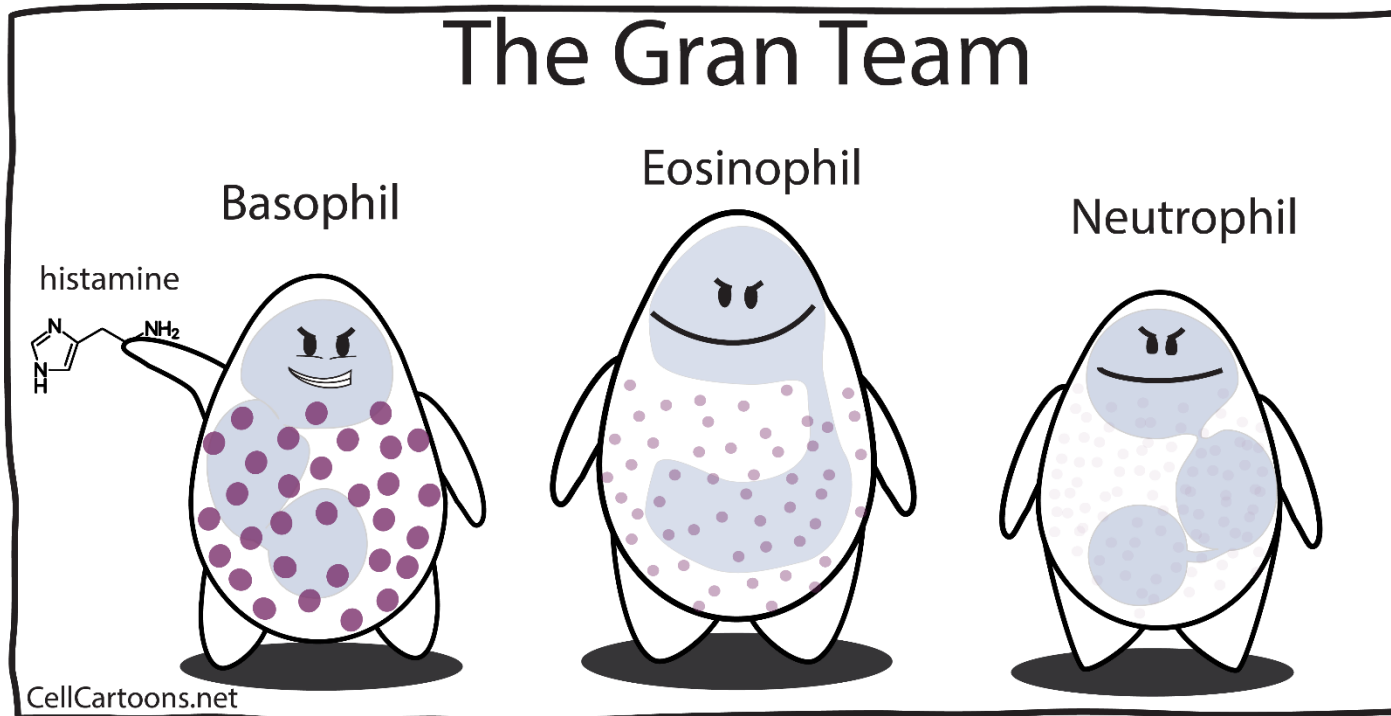


Monocytes Lymphocytes



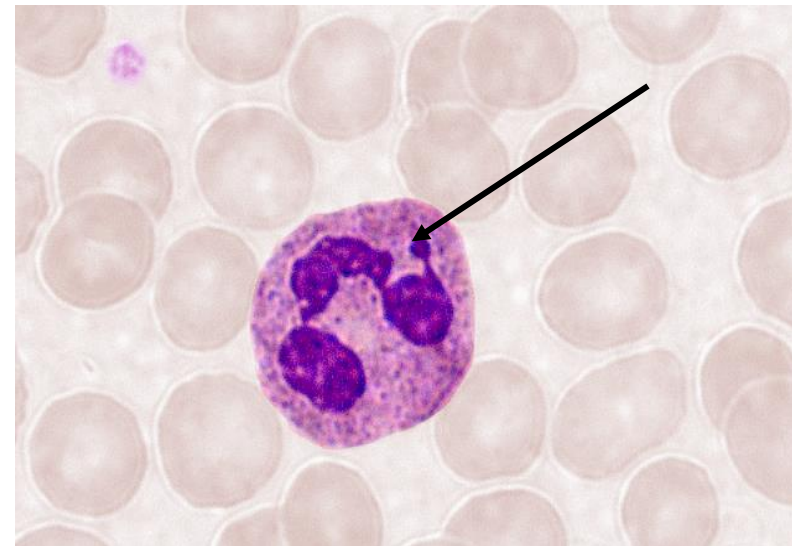
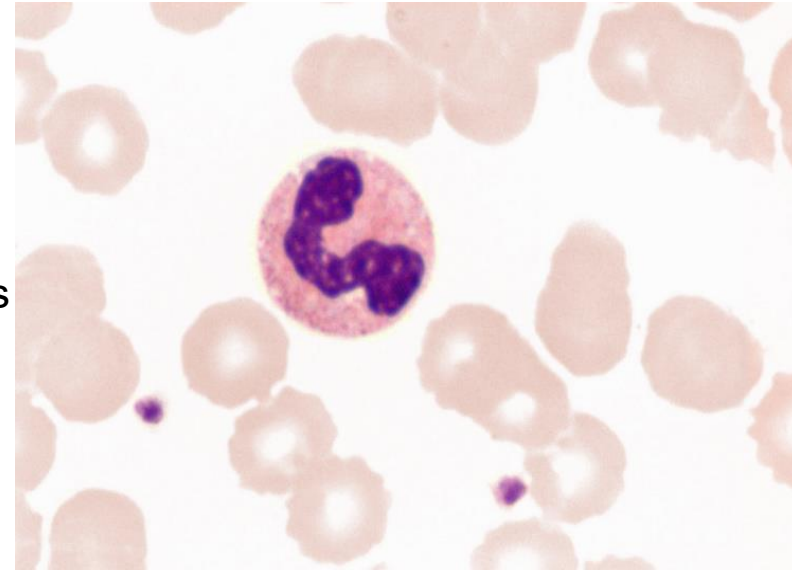
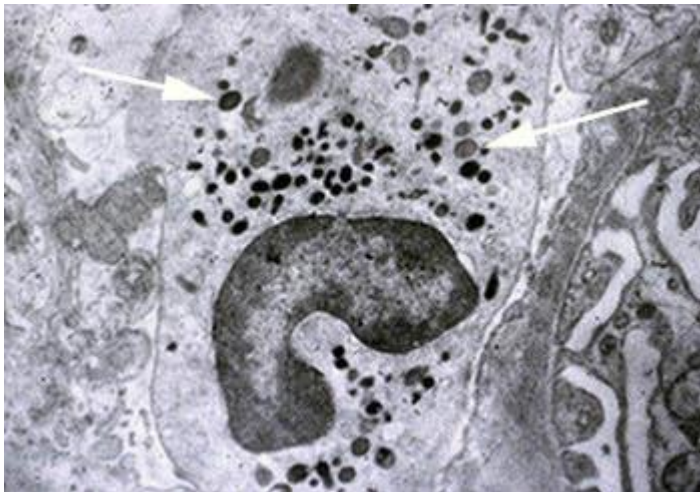
GRANULOCYTES

- Lysosomes (primary, azurophilic, nonspecific granules)
- Specific (secondary) granules
- Polymorphic nucleus
- Terminally differentiated
- Short lifespan (hours)
- Reduced ER, GA, mitochondria (anaerobic glycolysis)
- Apoptosis

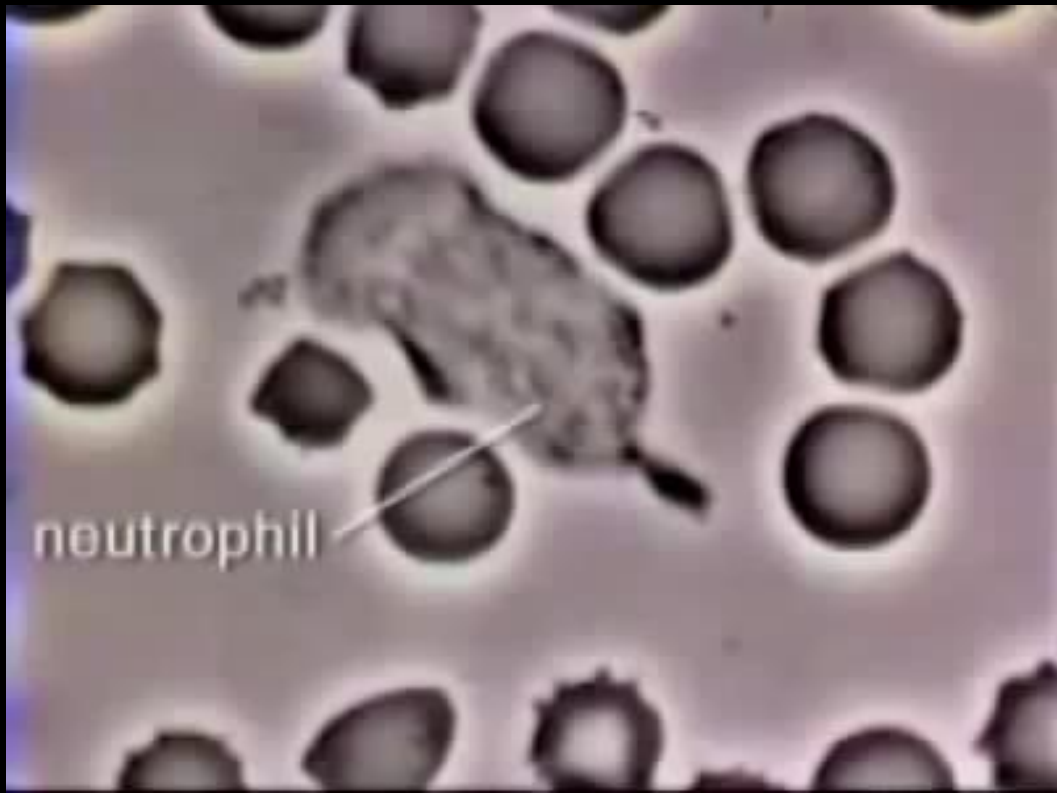




NEUTROPHILIC GRANULOCYTES

- **Neutrophils**
 - 50-70% of leukocytes in circulation
 - $\varnothing > 12 \mu\text{m}$
 - Segmented nucleus
 - Barr's body in females
 - **Azurophilic (primary) granules**
 - myeloperoxidase, lysozyme, proteases, defensins
 - **Neutrophilic (secondary) granules**
 - collagenase, bactericidal enzymes
 - Chemotaxis of other leukocytes
 - Microphages
- **Neutrophilic band**
- **Neutrophilic segment**

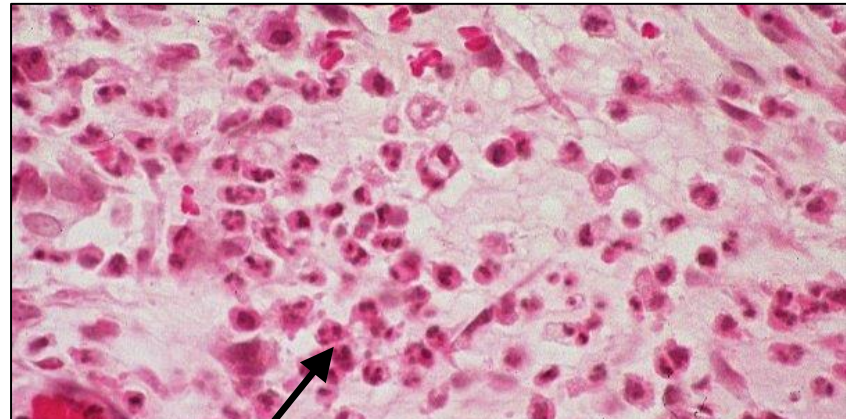
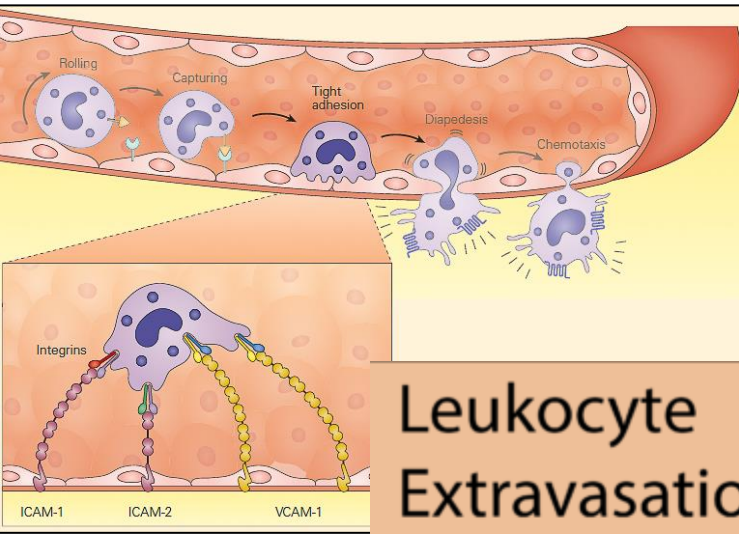


NEUTROPHILIC GRANULOCYTES



NEUTROPHILIC GRANULOCYTES

- Extravasation (diapedesis)

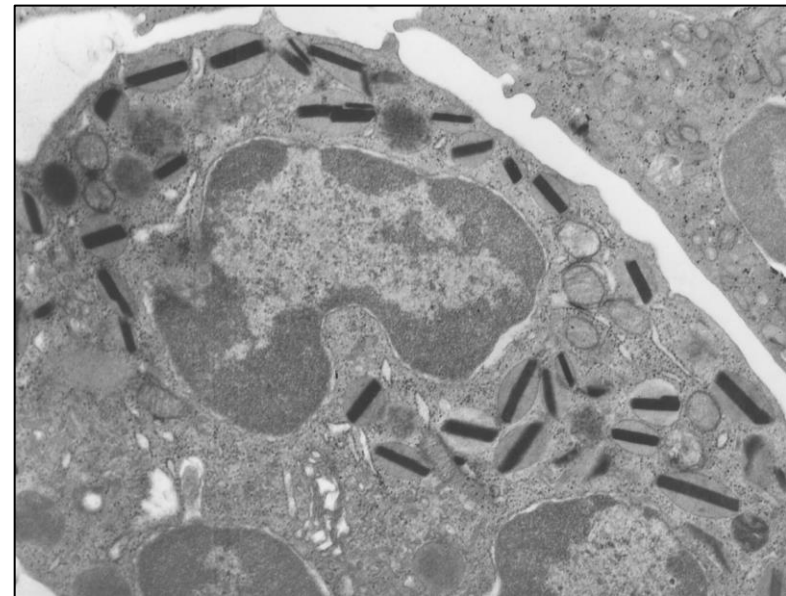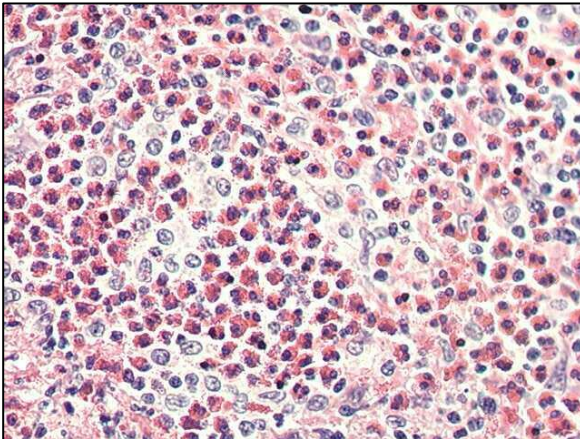
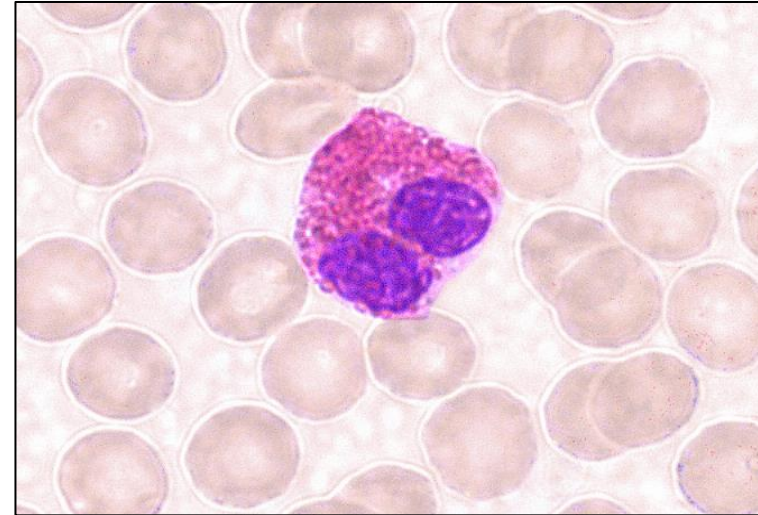


Leukocyte Extravasation

A cartoon illustration depicting leukocyte extravasation. A white leukocyte is shown crawling over a row of white rectangular cells labeled 'Endothelial Cells'. A speech bubble from the leukocyte says 'JUST FOLLOW THE CHEMOKINES'. Another leukocyte is shown crawling underneath the endothelial cells. A speech bubble from this leukocyte says 'HOW DID YOU DO THAT???' with a question mark above its head. The background is a light blue gradient with small white circles.

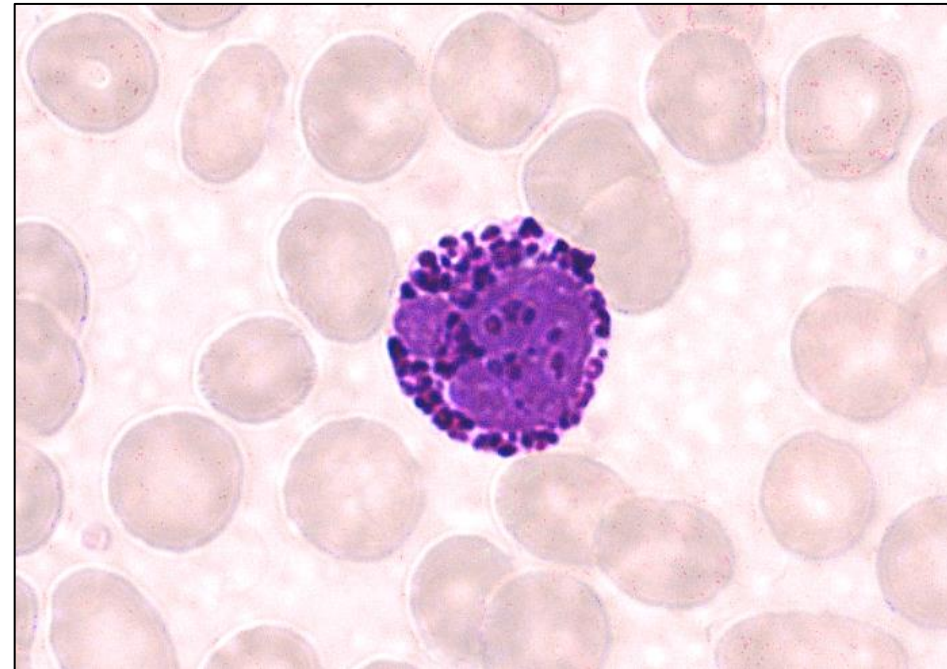
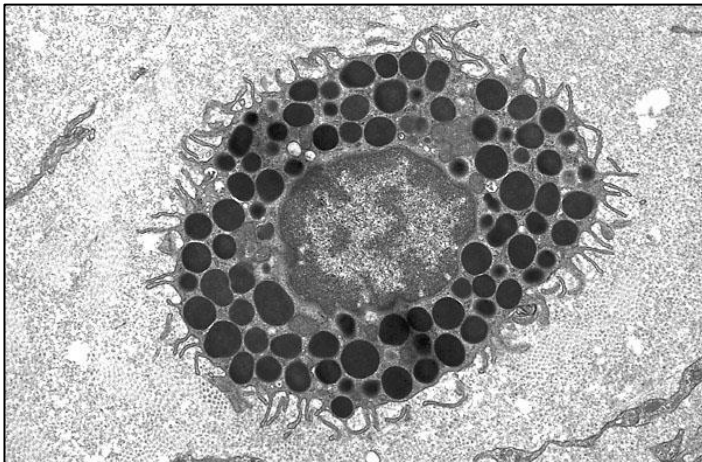
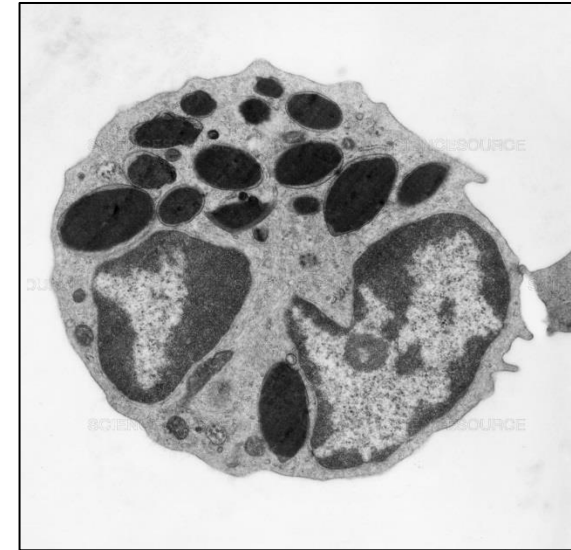
EOSINOPHILIC GRANULOCYTES

- **Eosinophils**
 - 1-4% of leukocytes in circulation
 - \varnothing 12-15 μm
 - Irregular, characteristic bi-segmented nucleus
 - **Azurophilic (primary) granules**
 - myeloperoxidase, lysozyme, proteases, defensins
 - **Eosinophilic (secondary) granules**
 - bright red (eosinophilic)
 - major acidic protein
 - peroxidase
 - cytokines, chemokines
- Chemotaxis of other leukocytes
- Phagocytosis of antibody-antigen complexes
- Parasitic infections, allergic reaction
- Chronic inflammation



BASOPHILIC GRANULOCYTES

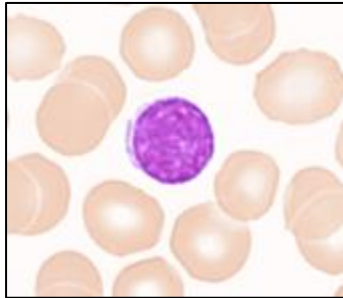
- **Basophils**
 - <1% of leukocytes in circulation
 - \varnothing 12 μm
 - Irregular, bisegmented nucleus, masked by granules
- **Azurophilic (primary) granules**
 - myeloperoxidase, lysozyme, proteases, defensins
- **Basophilic (secondary) granules**
 - 0.5 μm
 - large, dark (basophilic)
 - heparin, histamin - vasodilatation
 - phospholipase A
- Analogs of mast cells
- Receptors for IgE
- Allergy, anaphylaxis, inflammation



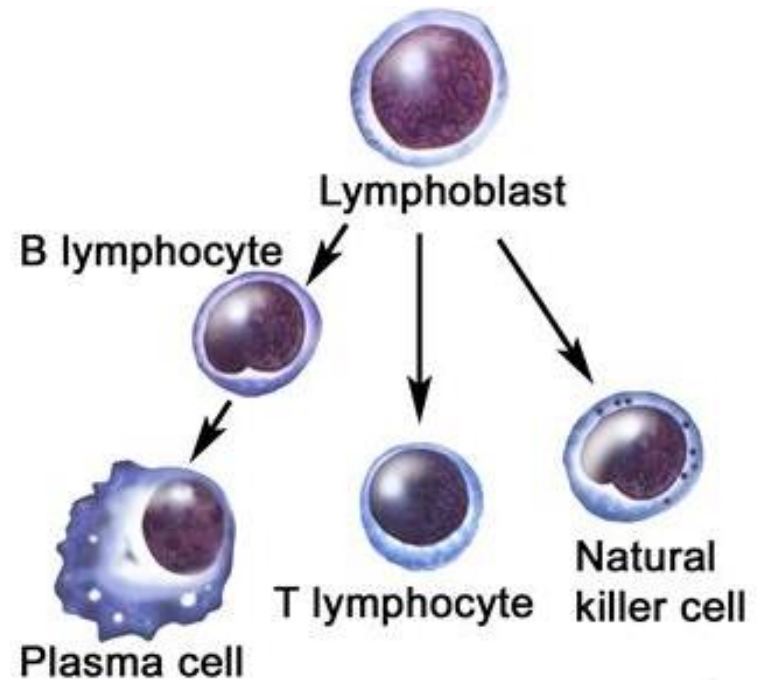
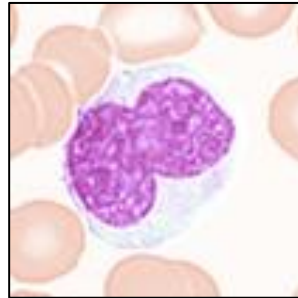
AGRANULOCYTES

- Lysosomes only (azurophilic, nonspecific granules)
- Specific granules absent
- Non-segmented nucleus

Lymphocytes



Monocytes




Lymphocytes


CD8 T Cell



B Cell



Regulatory
T Cell

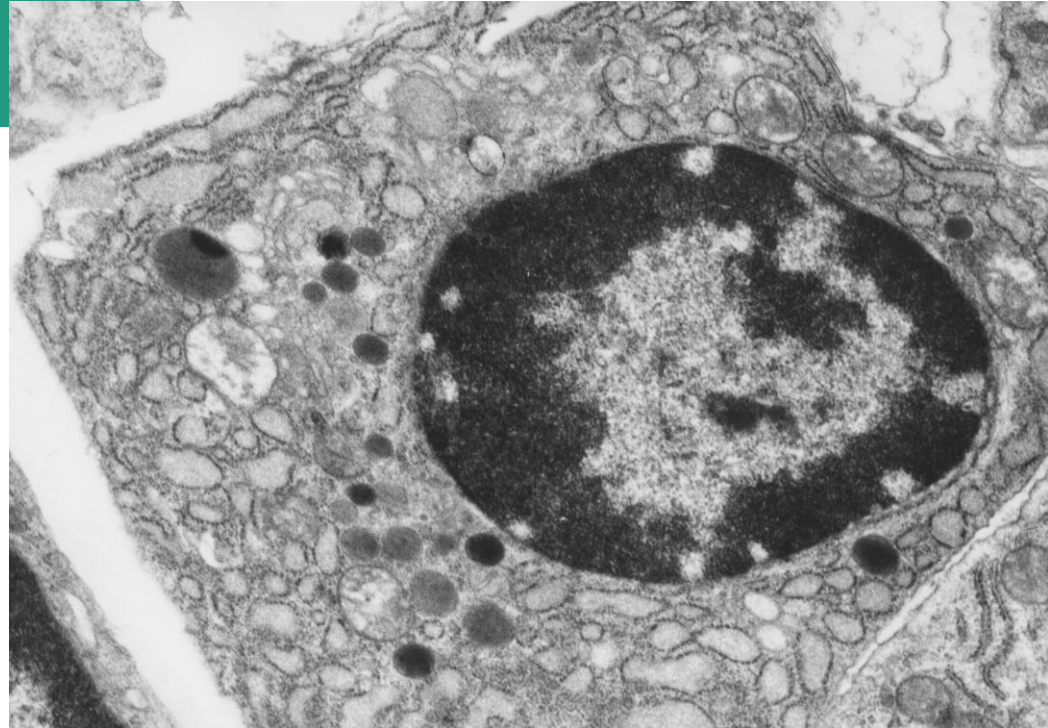
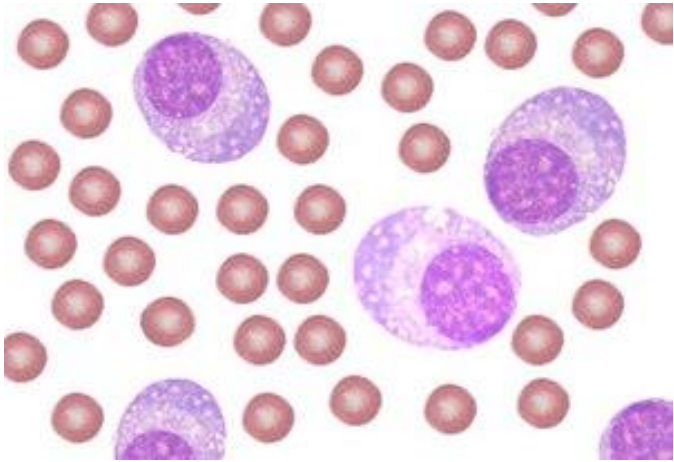
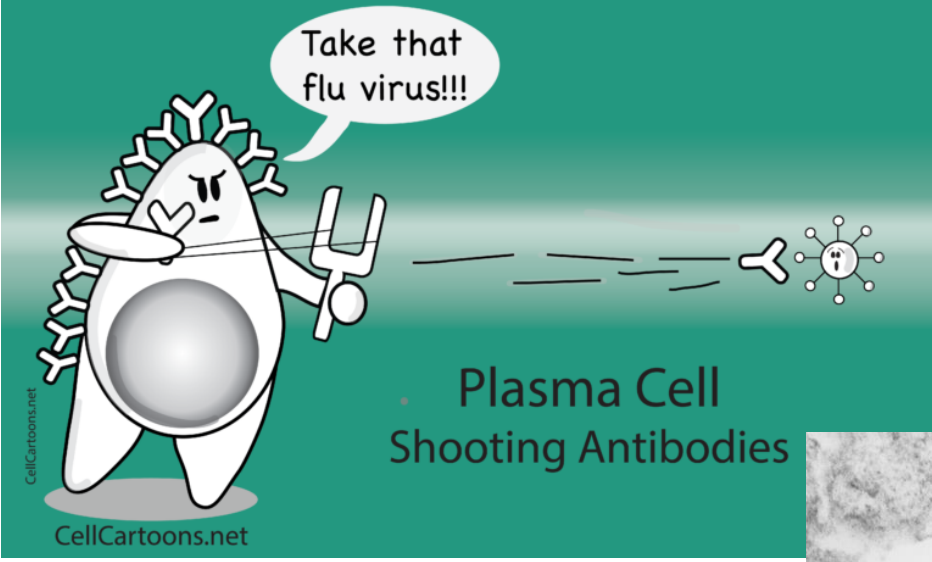


CD4 T Cell



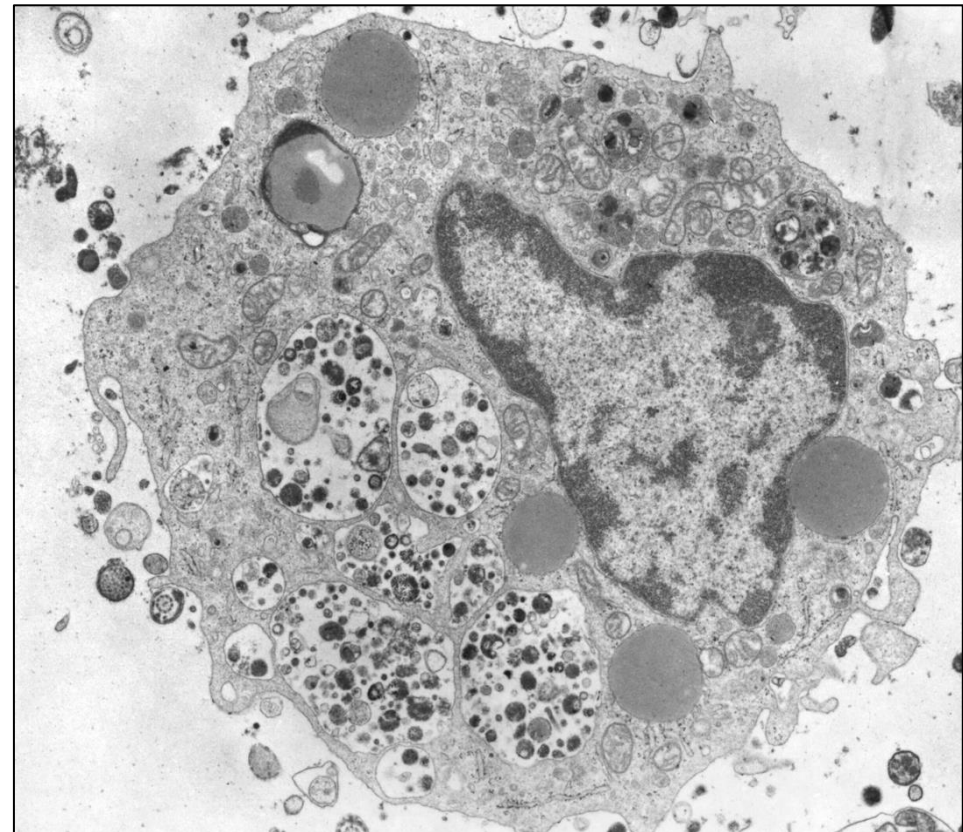
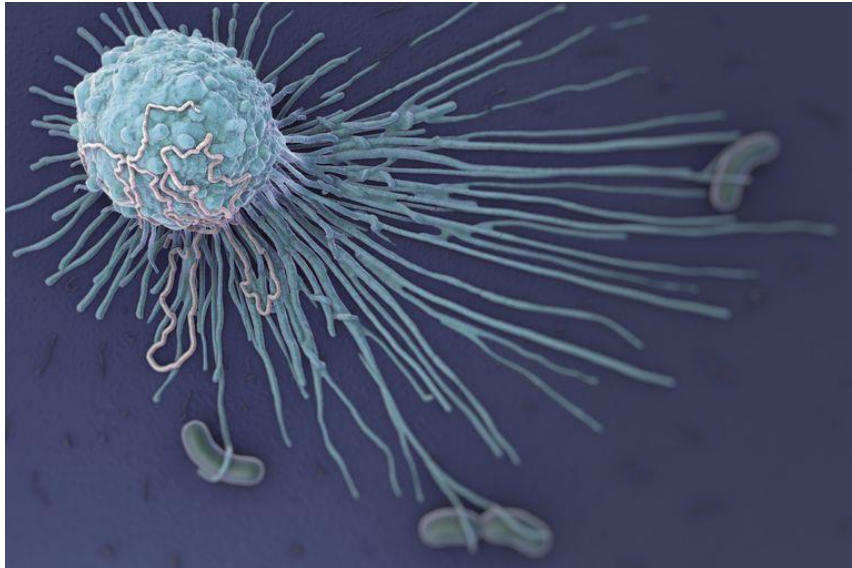
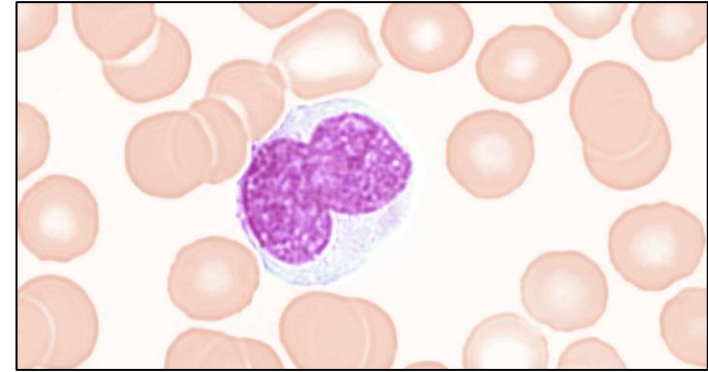
LYMPHOCYTES

- Plasma cells



MONOCYTES

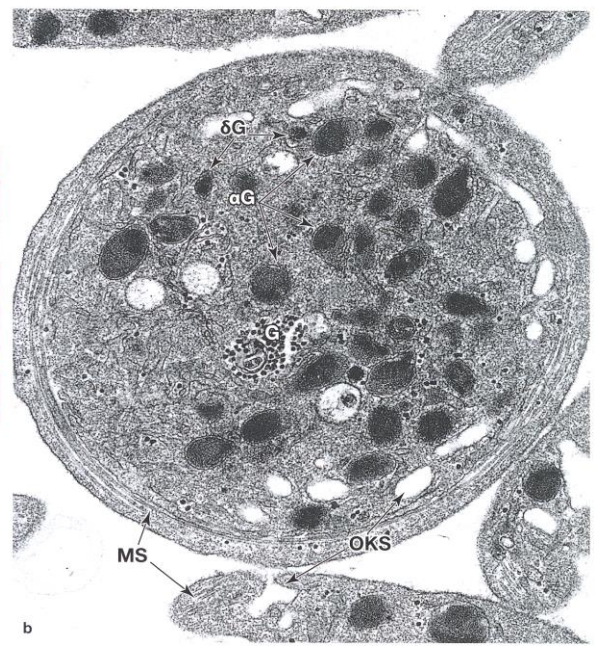
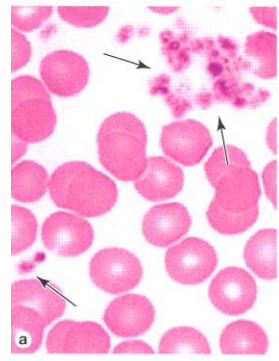
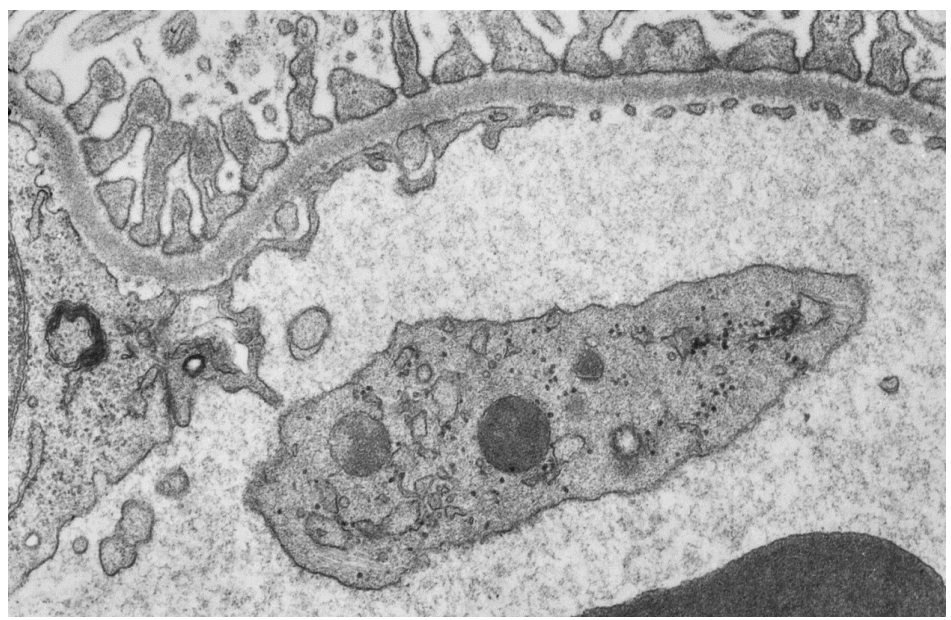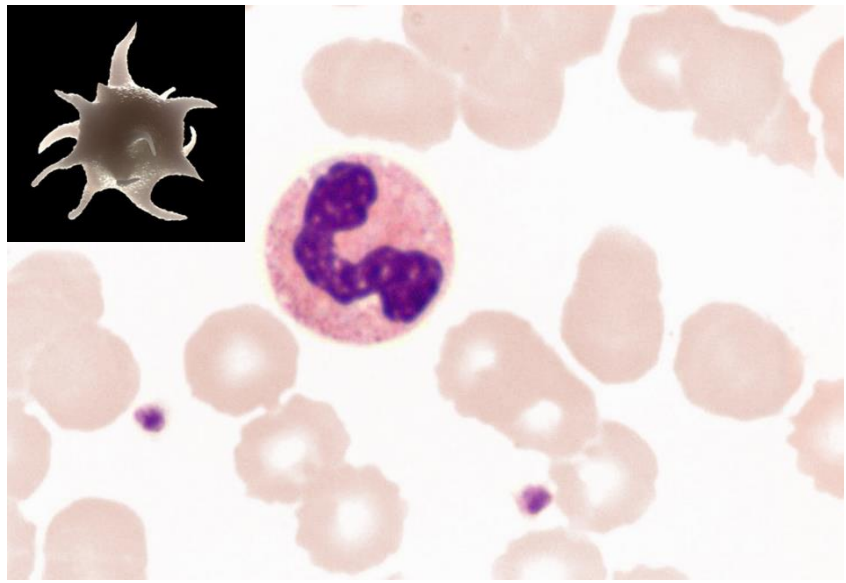
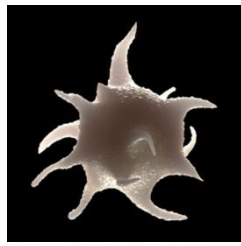
- \varnothing 12-15 μm
- Circulating precursors of macrophages, osteoclasts, microglia, Kupfer cells and dendritic cells
- Mononuclear phagocytic system
- Large, oval (bean, kidney) nucleus with less condensed chromatin and 2-3 nucleoli
- Basophilic cytoplasm
- Azurophilic granules



THROMBOCYTES

- Cell fragments without nucleus
- \varnothing 2-3 μm , discoid shape
- hyalomere, granulomere
- $150-400 \times 10^3/\mu\text{l}$
- blood clotting, repair of vessel wall

α-granules 300-500 nm	fibrinogen, PDGF
δ-granules 250-300 nm	serotonin, Ca^{++} pyrophosphate ADP, ATP
λ-granules 175-200 nm	lysosomal enzymes



THROMBOCYTES

1. Primary aggregation of platelets

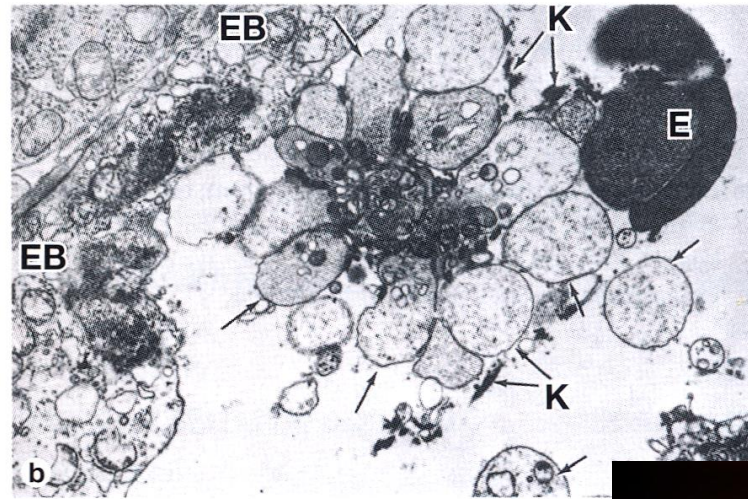
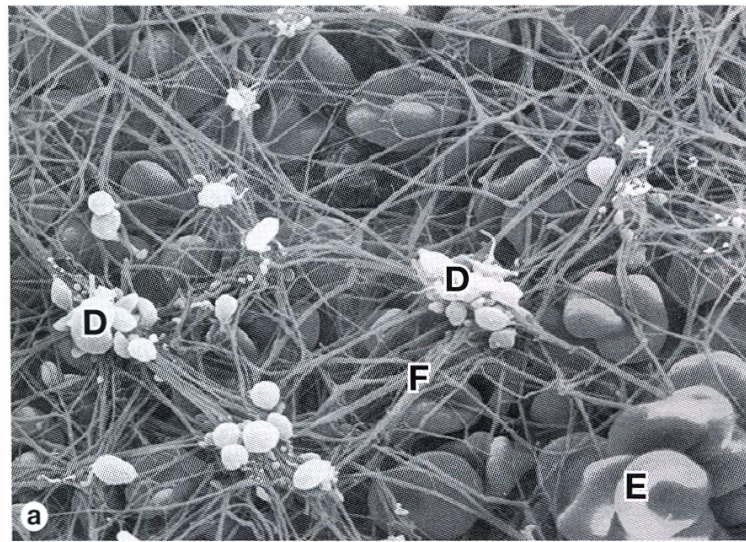
- collagen fibers exposed by endothelial rupture
- platelet clot

2. Secondary aggregation of platelets

- clotting factors, ADP from thrombocytes attracts other platelets – *white thrombus*

3. Coagulation – blood clotting

- fibrin mesh capturing erythrocytes – *red thrombus*

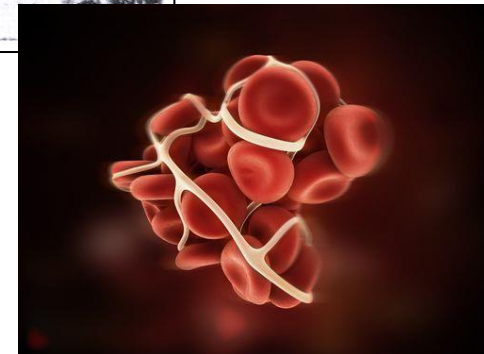

4. Thrombus retraction

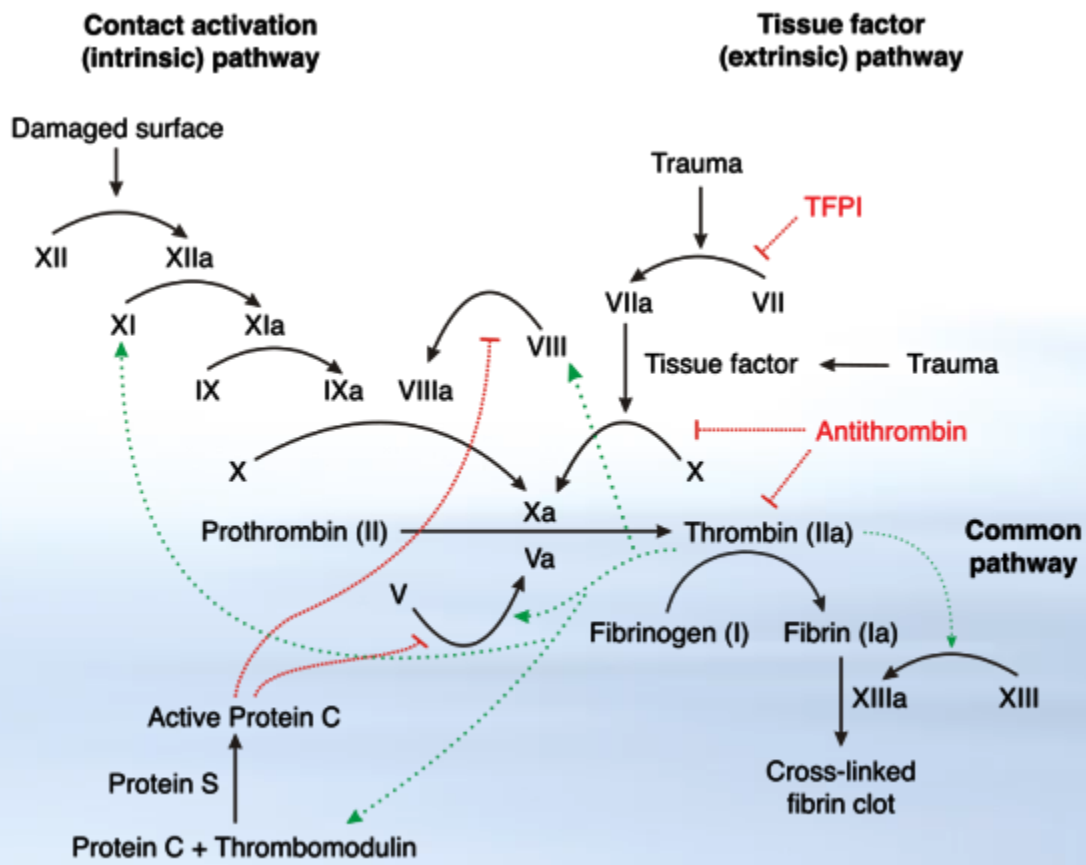
- contraction of thrombus (platelet actin and myosin)

5. Thrombolysis

- dissolving of thrombus (plasmin) and tissue regeneration



THROMBOCYTES



You needn't to know the clotting cascade in full details for our course, leave it for biochemistry



DIFFERENTIAL WHITE BLOOD CELL COUNT

THIS SLIDE IS REALLY IMPORTANT

Neutrophil band 4 %

segment 67 %

1:17

shift to the left

shift to the right

more bands

more segments

Eosinophils 3 %

Basophils 1 %

Lymphocytes 20 %

Monocytes 5 %

$\Sigma = 100 \%$

Norm

DIFFERENTIAL WHITE BLOOD CELL COUNT

Deviations from norm

	↑ Increased	↓ Decreased
Neutrophils	neutrophil granulocytosis	neutrophil granulocytopenia
Eosinophils	eosinophil granulocytosis	eosinophil granulocytopenia
Basophils	basophil granulocytosis	basophil granulocytopenia
Lymphocytes	lymphocytosis	lymphocytopenia
Monocytes	monocytosis	monocytopenia

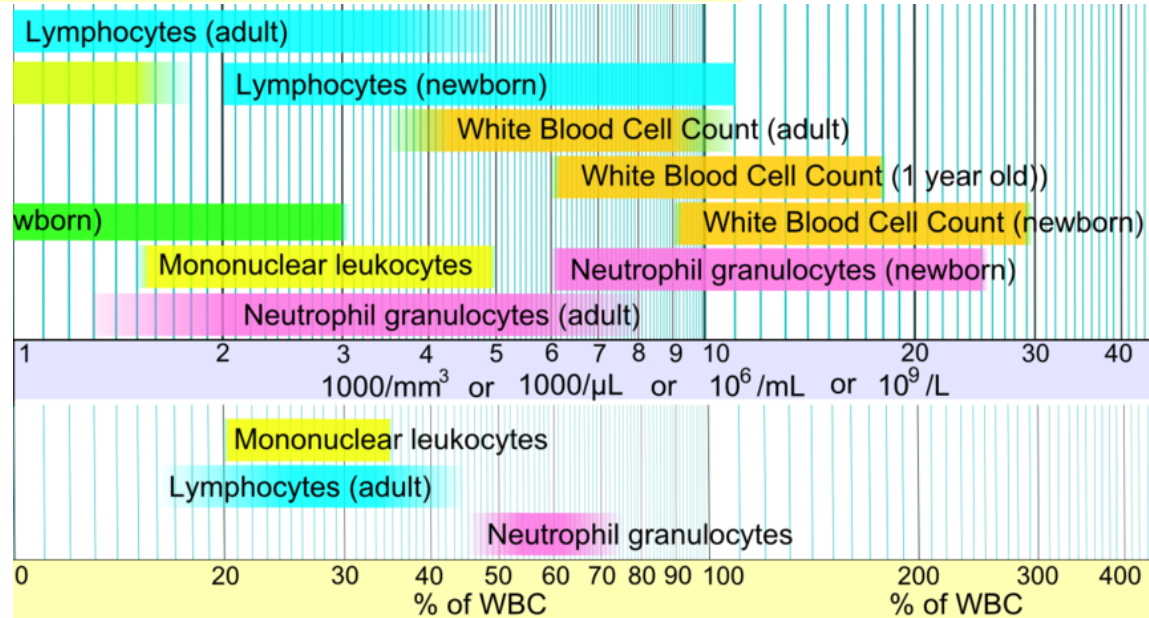
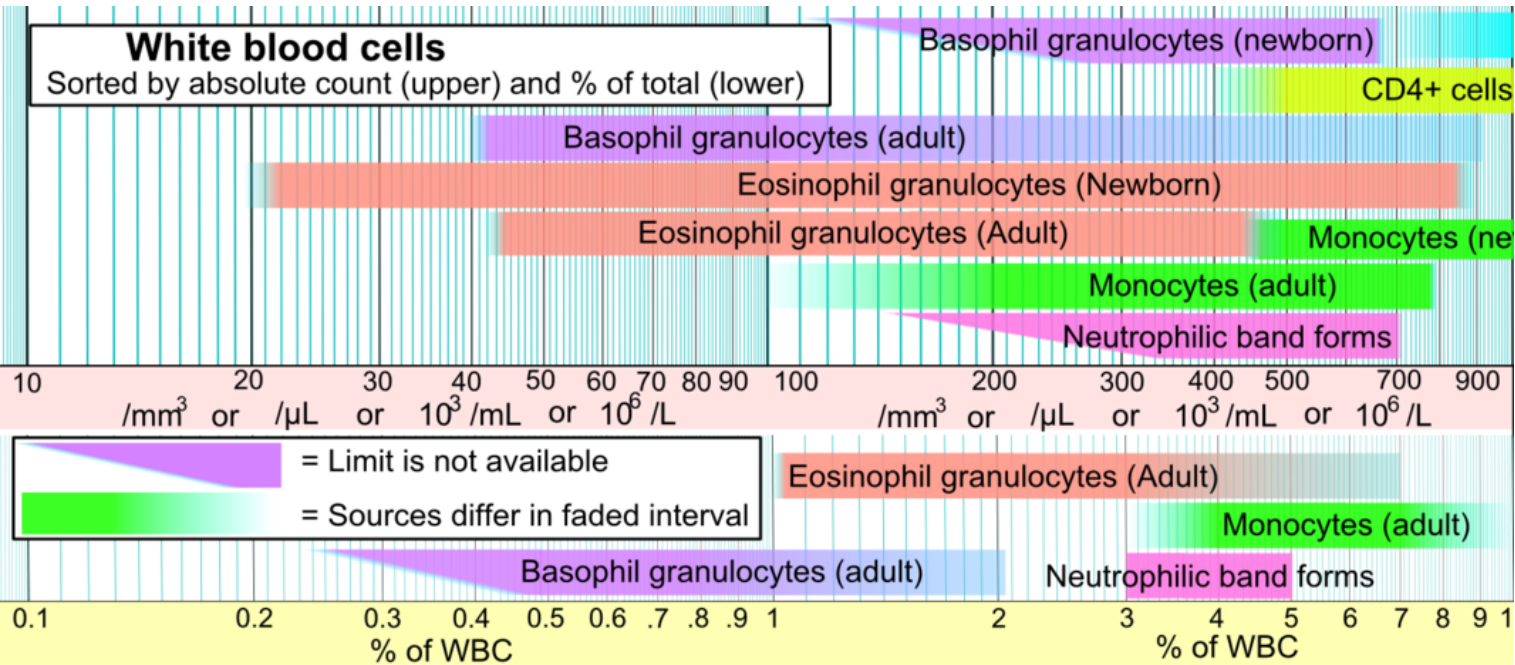
DIFFERENTIAL WHITE BLOOD CELL COUNT

Example of population variability

Neutrophils	bands	0-5 %
	segments	35-85 %
Eosinopils		0-4 %
Basophils		0-1 %
Lymphocytes		20-50 %
Monocytes		2-6 %

According to: Haferlach et al. Kapesní atlas hematologie. Grada 2014

DIFFERENTIAL WHITE BLOOD CELL COUNT



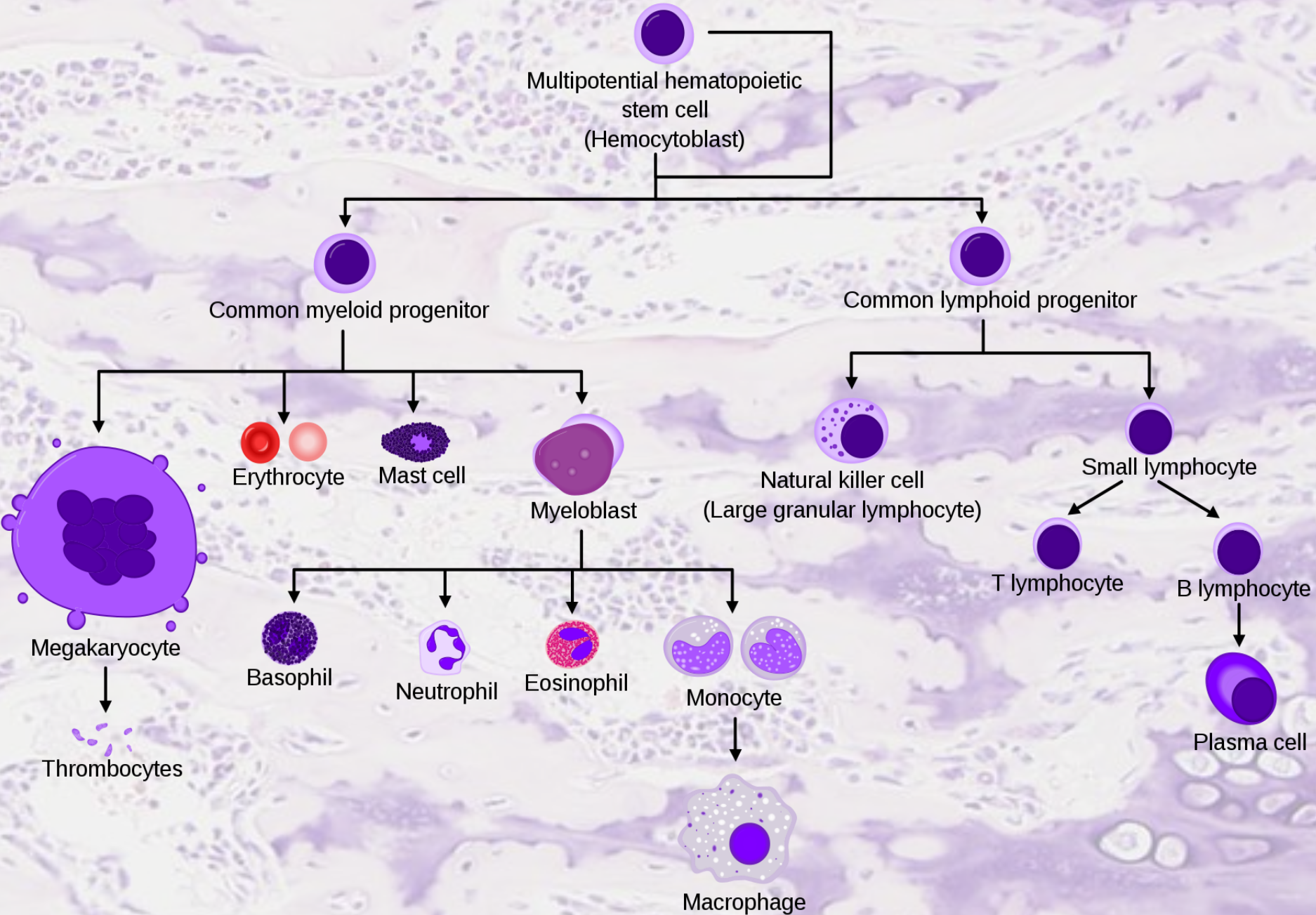
DIFFERENTIAL WHITE BLOOD CELL COUNT

Age dependence

Age	Leukocytes ($\times 10^3$)	Neutrophils (%)	Lymphocytes (%)	Monocytes (%)	Eosinophils (%)
Birth	18	61	31	6	2
1 week	12.2	45	41	9	4
1 mo	10.8	35	56	7	3
6 mo	11.9	32	61	5	3
1 yr	11.4	31	61	5	3
4 yr	9.1	42	50	5	3
10 yr	8.1	54	38	4	2
16 yr	7.8	57	35	4	3

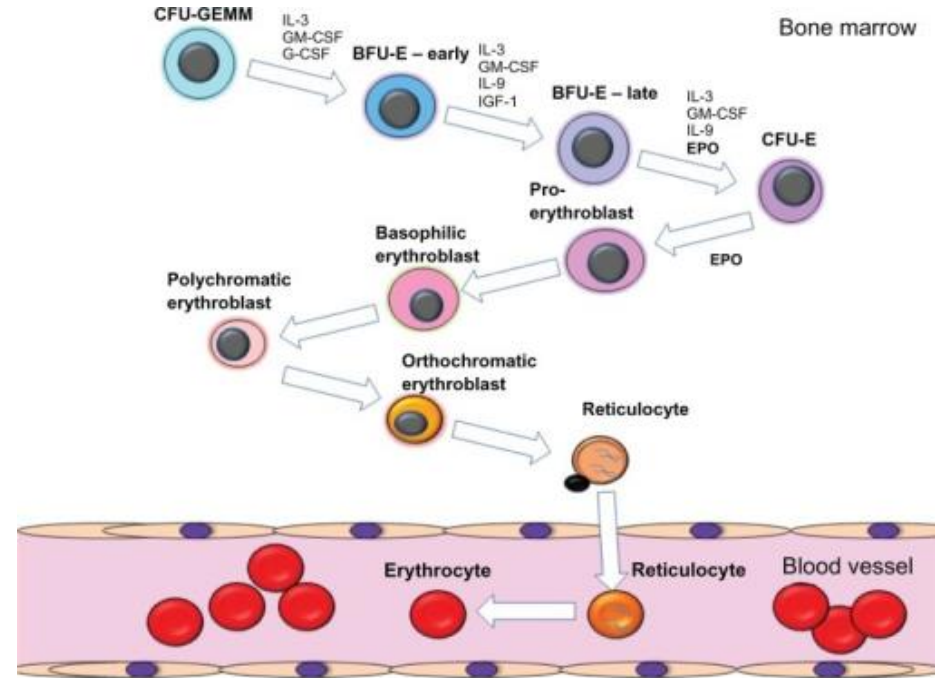
WBC, White blood cell.

HEMATOPOIESIS

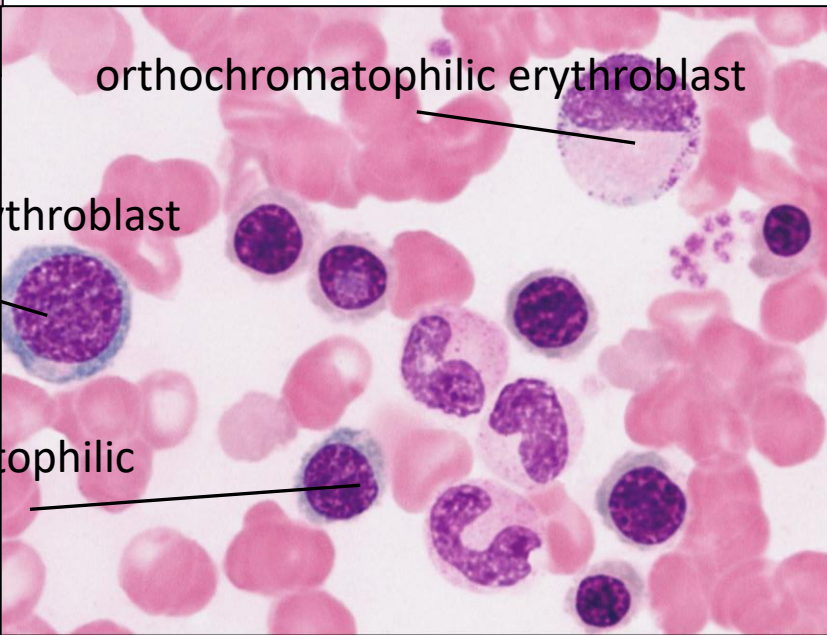
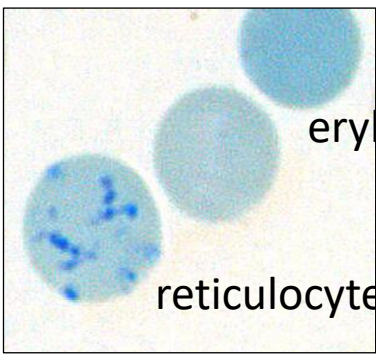
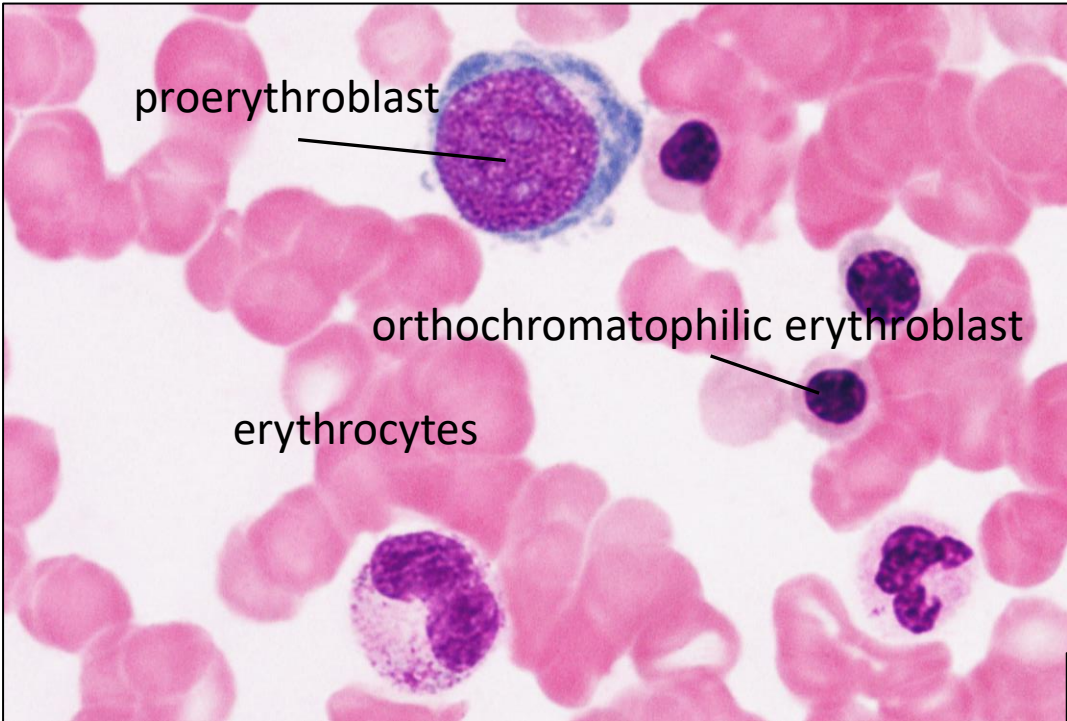


ERYTHROPOIESIS

- 2×10^{11} of new erythrocytes daily
- **proerythroblast** (~14-19 μm)
 - mitotically active
 - dominant, round nucleus with 1-2 nucleoli
 - mildly basophilic cytoplasm
- **basophilic erythroblast** (~13-16 μm)
 - mitotically active
 - heterochromatic nucleus with inconspicuous nucleoli
 - basophilic cytoplasm (sometimes more than in proerythroblast)
- **polychromatophilic erythroblast** (~13-16 μm)
 - mitotically active
 - **production of hemoglobin**
 - blue-gray cytoplasm due to combined basophilic (polyribosomes) and acidophilic aspects (hemoglobin)
 - heterochromatic nucleus (checkerboard appearance)
- **orthochromatophilic erythroblast** (~8-10 μm)
 - mitotically inactive
 - small, compact, eccentric, pyknotic nucleus \rightarrow **extrusion**
 - mildly acidophilic cytoplasm with basophilic residues
- **reticulocyte** (polychromatophilic erythrocyte, ~ 7-8 μm)
 - **lacks nucleus, still spheroid shape**
 - acidophilic cytoplasm
 - *substantia reticulofilamentosa* visible by supravital staining (brilliant cresyl blue)
- **erythrocyte** (~7-8 μm)
 - anucleate, biconcave disc
 - acidophilic cytoplasm

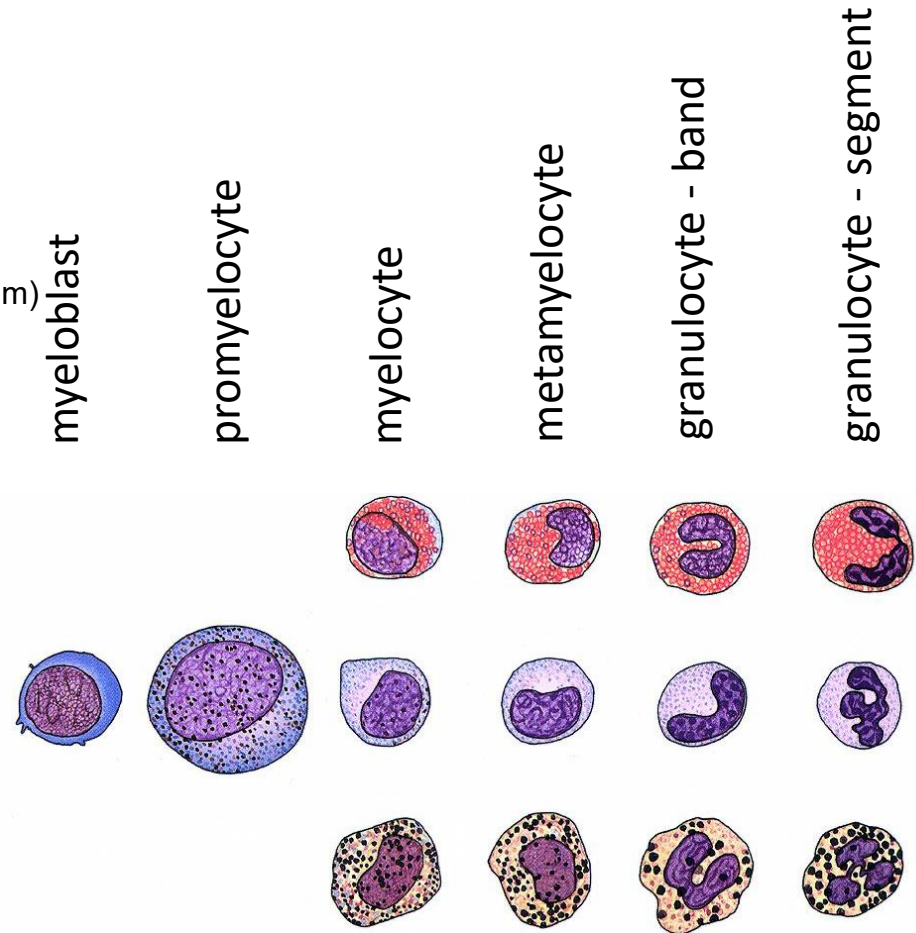


ERYTHROPOIESIS



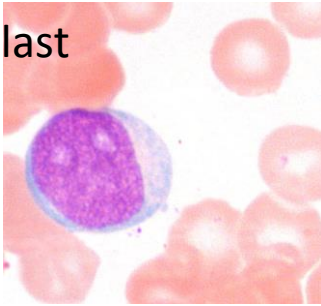
GRANULOPOIESIS

- **myeloblast** (~15 μm)
 - mitotically active
 - round-oval, euchromatic nucleus
 - 2-6 apparent nucleoli
 - weakly basophilic cytoplasm without granules
- **promyelocyte** (~15-24 μm)
 - mitotically active
 - round-oval nucleus with partly condensed chromatin
 - basophilic cytoplasm with azurophilic granules
- neutrophilic, eosinophilic or basophilic **myelocyte** (~10-16 μm)
 - mitotically active
 - oval or bean-shaped nucleus with condensed chromatin
 - increasing number of specific granules in cytoplasm
- neutrophilic, eosinophilic or basophilic **metamyelocyte** (~10-12 μm)
 - mitotically inactive
 - horseshoe-like nucleus with condensed chromatin
- neutrophilic, eosinophilic or basophilic **granulocyte** (~10-12 μm)
 - segmentation of nucleus
 - cytoplasm rich in specific and azurophilic granules

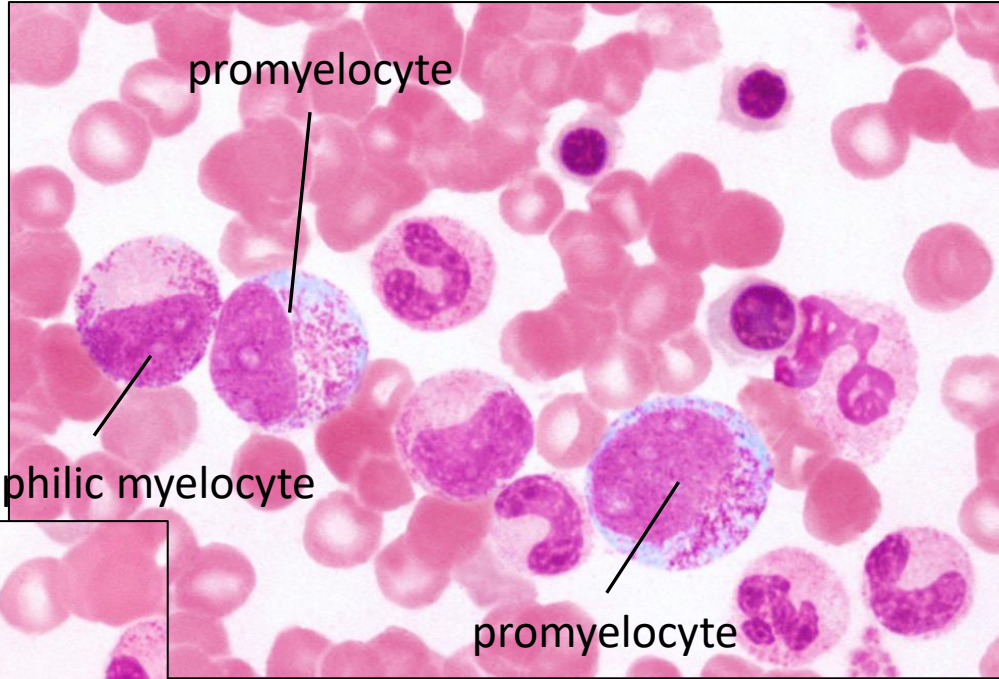


GRANULOPOIESIS

myeloblast



promyelocyte



neutrophilic myelocyte

promyelocyte

polychromatophilic erythroblast

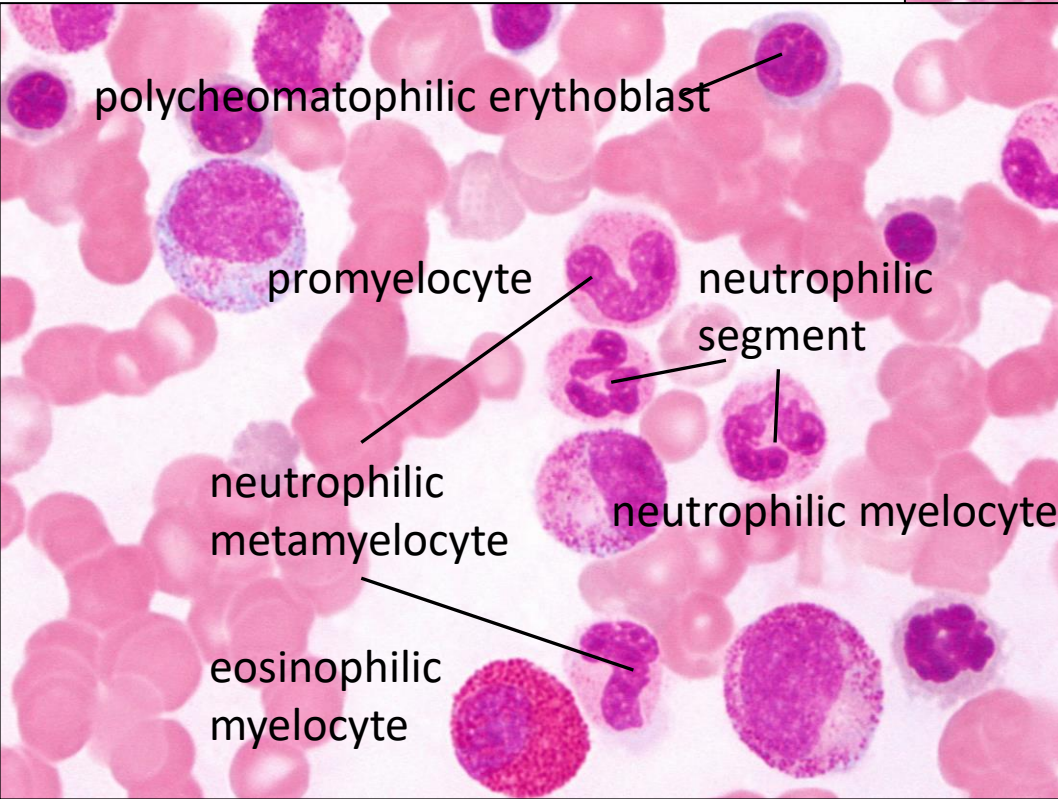
promyelocyte

neutrophilic segment

neutrophilic metamyelocyte

neutrophilic myelocyte

eosinophilic myelocyte

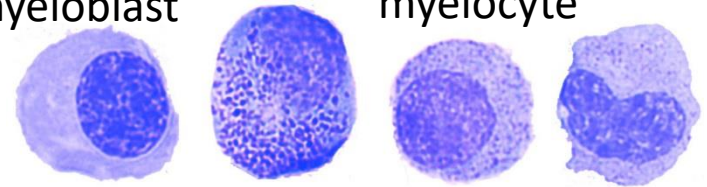


promyelocyte

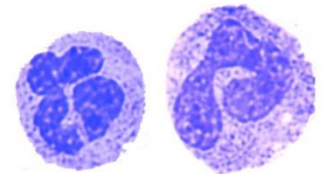
metamyelocyte

myeloblast

myelocyte

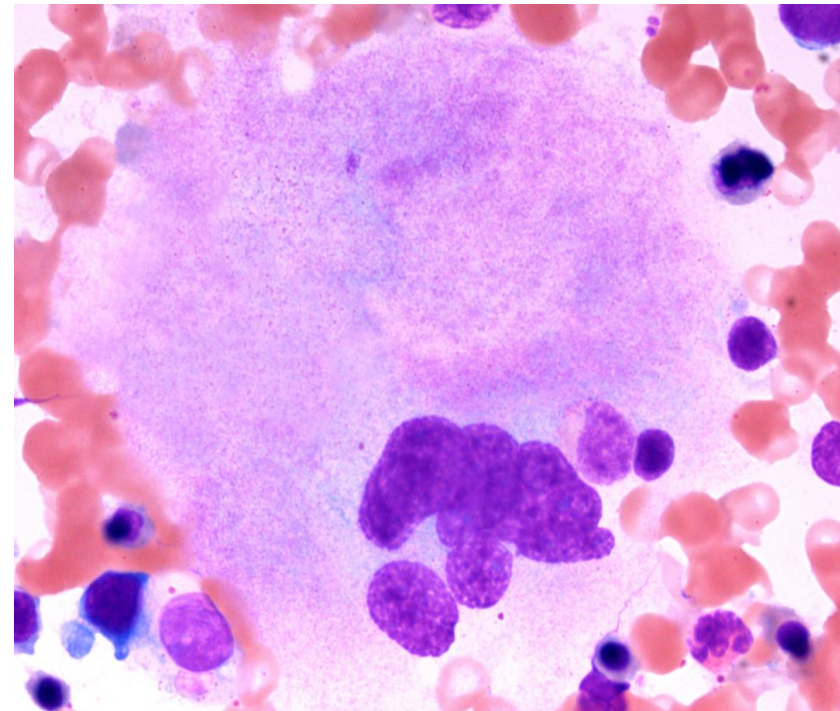
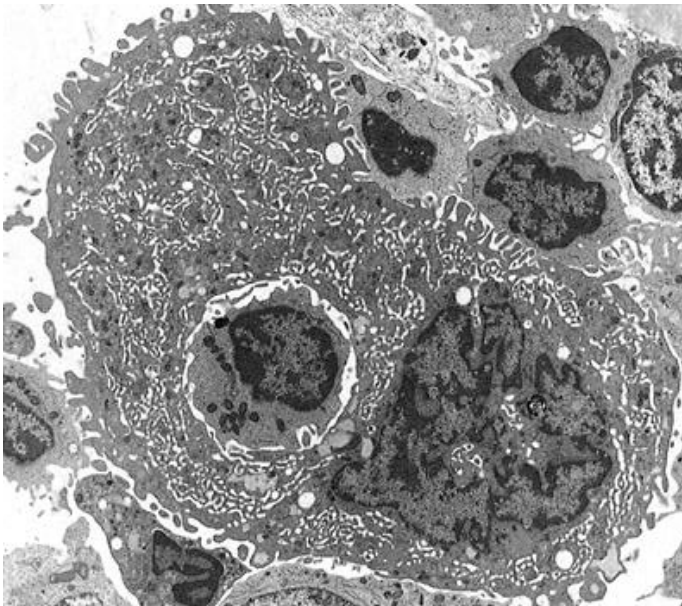
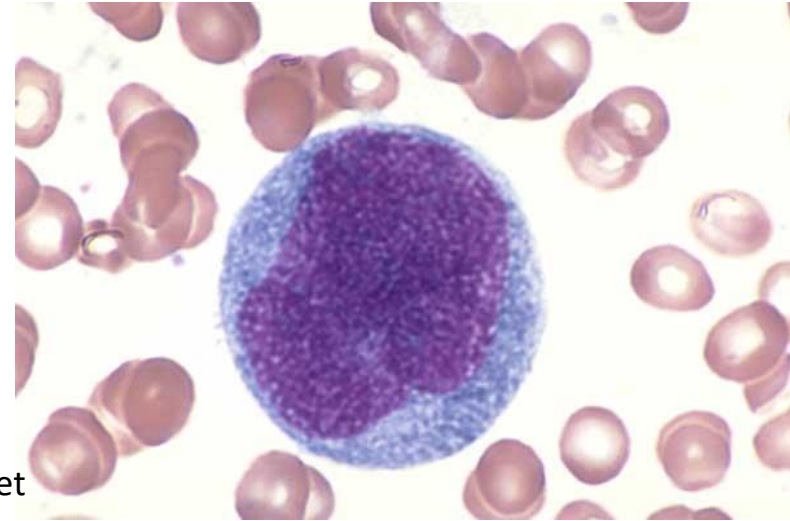


granulocyte



THROMBOPOIESIS

- **megakaryoblast** (up to 30 μm)
 - large oval, nonlobed nucleus with prominent nucleoli
 - basophilic cytoplasm
 - successive endomitoses without karyokinesis and cytokinesis
- **promegakaryocyte** (up to 100 μm)
 - large cell with polyploid nucleus (8n-64n)
- **megakaryocyte** (80-150 μm)
 - polyploid, multilobed nucleus (8n-64n)
 - azurophilic and platelet granules
 - multiple centrioles, ER and Golgi apparatus
 - numerous peripheral invaginations of plasma membrane— platelet demarcation channels defining individual thrombocytes
 - release of **thrombocytes** into bone marrow sinusoids



MONOCYTOPOIESIS AND LYMPHOPOIESIS

MONOCYTOPOIESIS

- **monoblast** (~16 μm)
 - round, bean shaped nucleus with 2-6 nucleoli
 - mildly basophilic cytoplasm
- **promonocyte** (~16-20 μm)
 - mitotically active (1-2 divisions)
 - large nucleus with mild indentation, unapparent nucleoli
 - basophilic cytoplasm
 - azurophilic granules
- **monocyte**
 - short-time in circulation, then extravasation and differentiation to tissue macrophages

LYMPHOPOIESIS

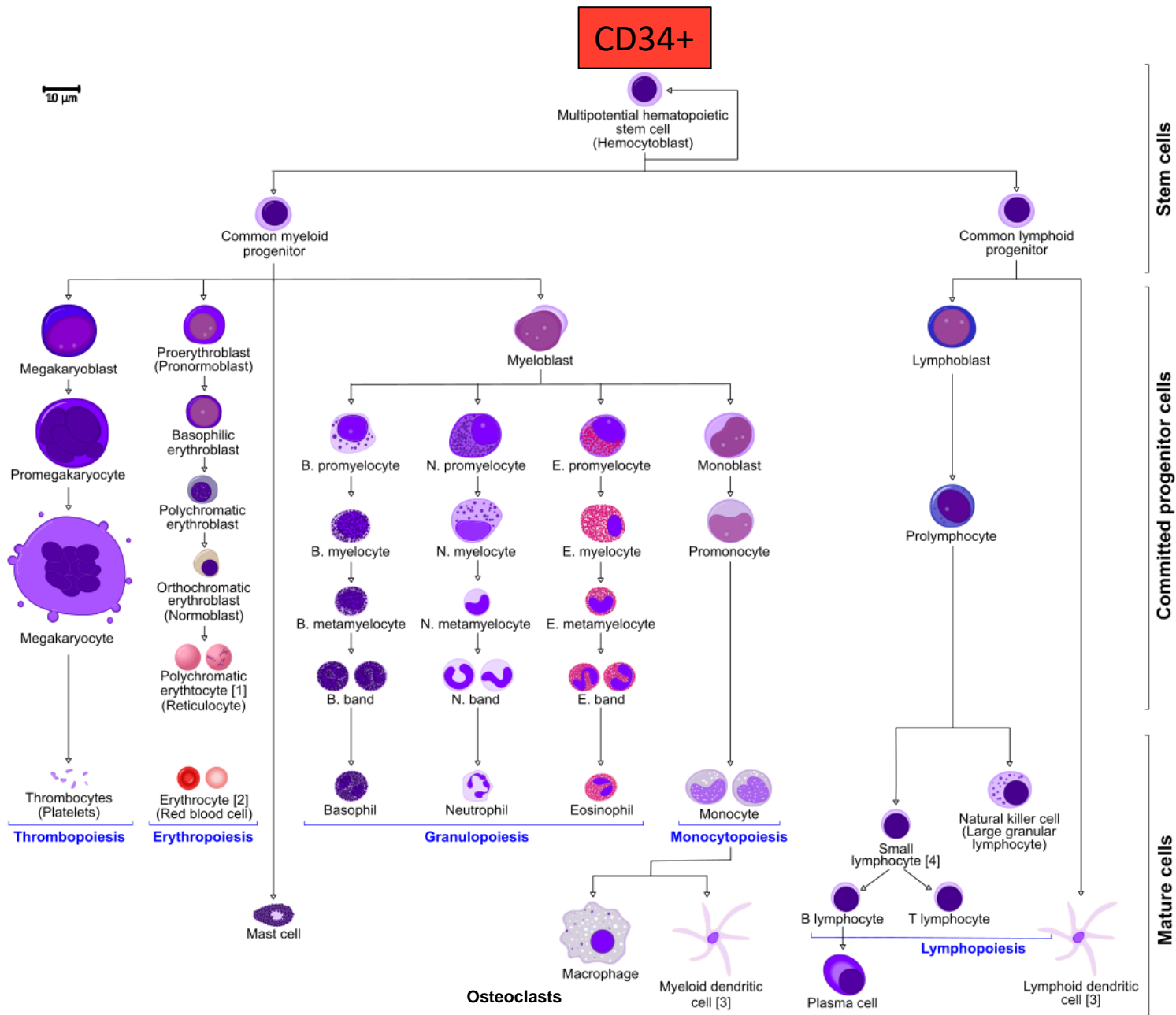
- **lymphoblast** (~18-20 μm)
 - round-oval nucleus with several nucleoli
 - mildly-basophilic cytoplasm without azurophilic granules
- **prolymphocyte** (~12-15 μm)
 - morphological transition and maturation to lymphocytes
- **lymphocyte**
 - further maturation and differentiation outside bone marrow

OVERVIEW OF ADULT HEMATOPOIESIS

Bone marrow

Blood

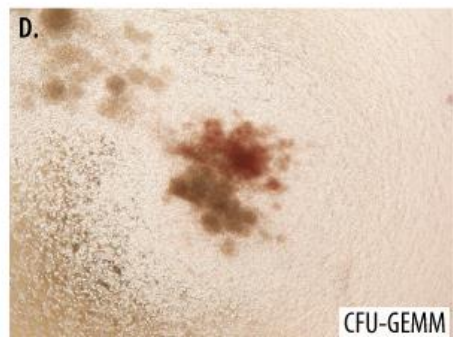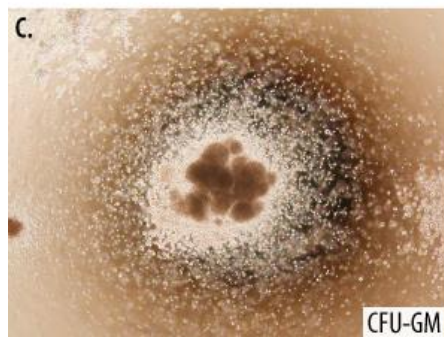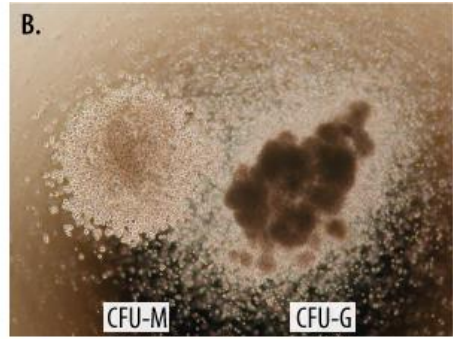
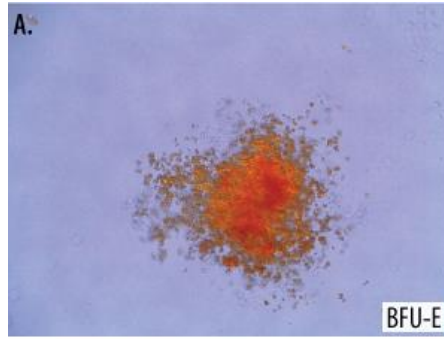
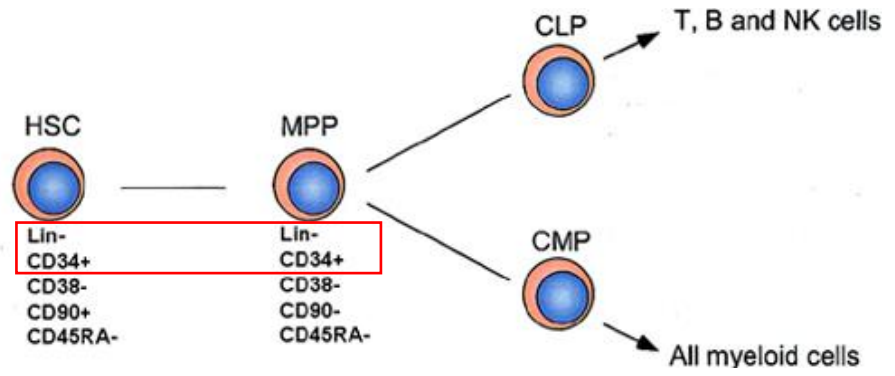
Tissue



HEMATOPOIETIC STEM CELLS AND PROGENITORS

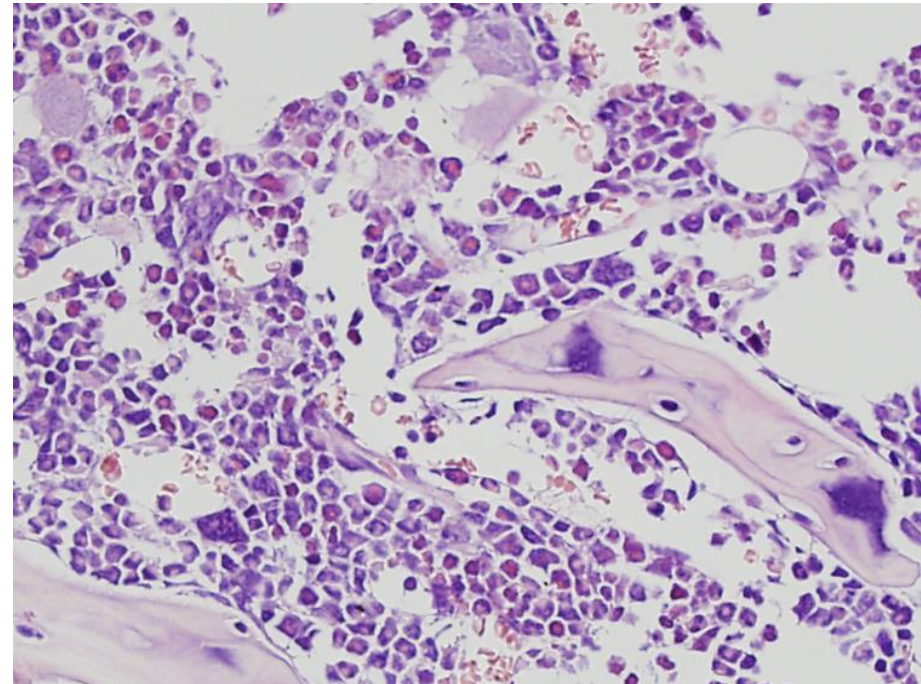
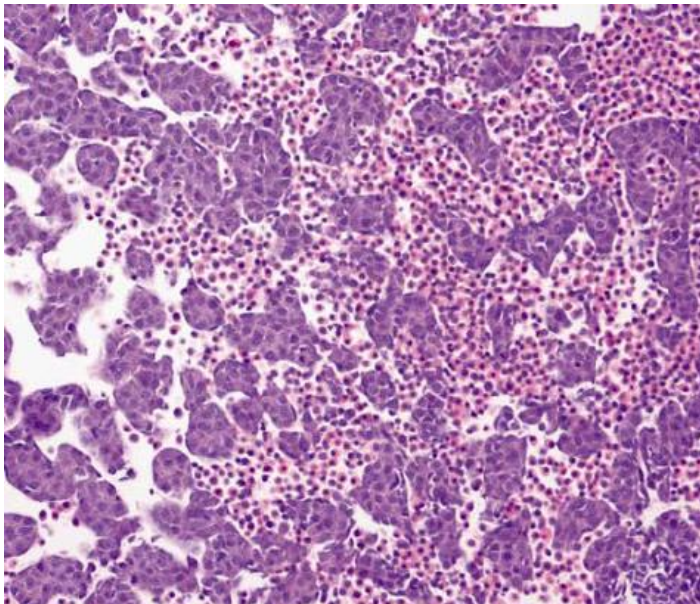
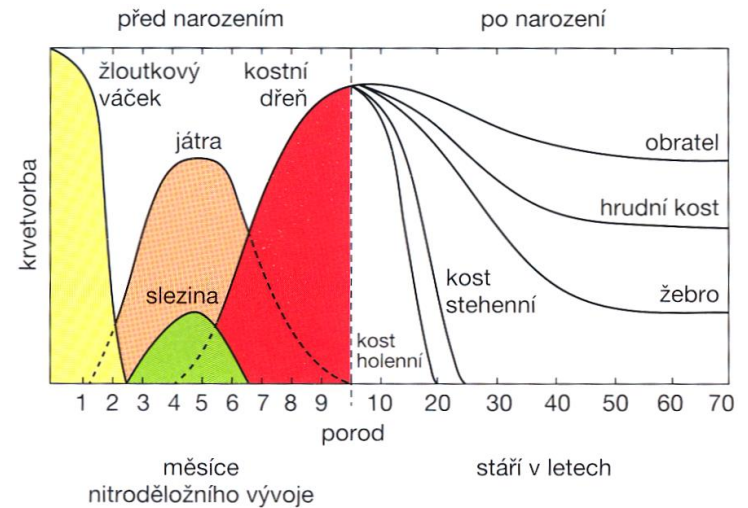
- **Hematopoietic stem cell**
 - Quiescent, slow cell cycle
 - Transmembrane phosphoglycoprotein CD34⁺ - adhesion within niche
 - No expression of lineage surface markers (Lineage negative or Lin⁻)
 - Transplantations

- **Colony/Burst – Forming Unit – CFU/BFU**
 - Progenitors of individual lines
 - Colonies in vitro



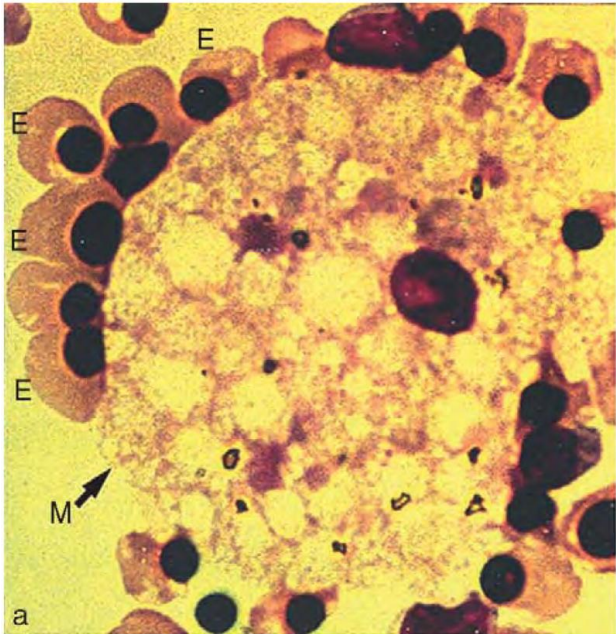
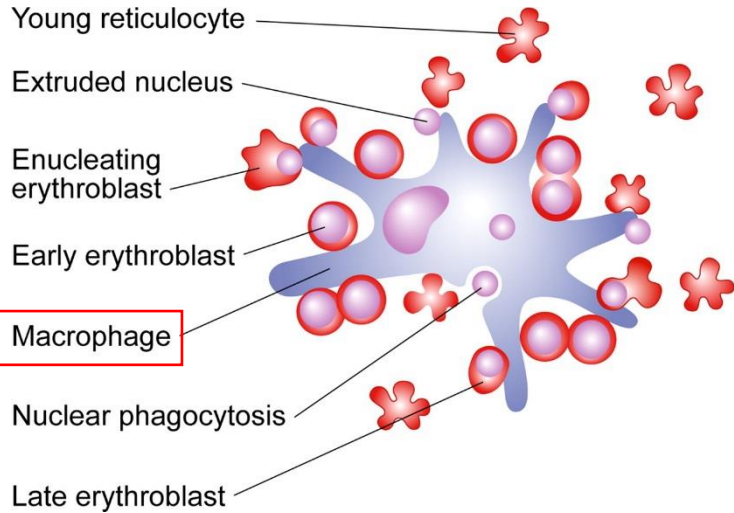
EMBRYONIC HEMATOPOIESIS

- **Extraembryonic mesoblastic period (day 16-20 – week 8)**
 - yolk sac
 - classical model – hemangioblasts (bipotent cells)
 - large, nucleated erythroid cells
- **aorta-gonad-mesonephros (day 28 – week 4)**
- **hepatolienal period (month 1 – birth)**
 - colonization of fetal liver and spleen
- **medullary period (month 4-6. – rest of life)**
 - bone marrow

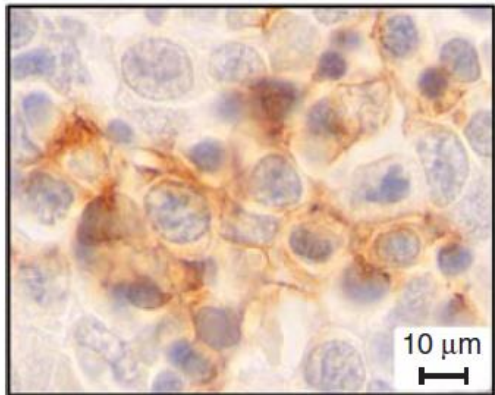


HEMATOPOIETIC ISLANDS

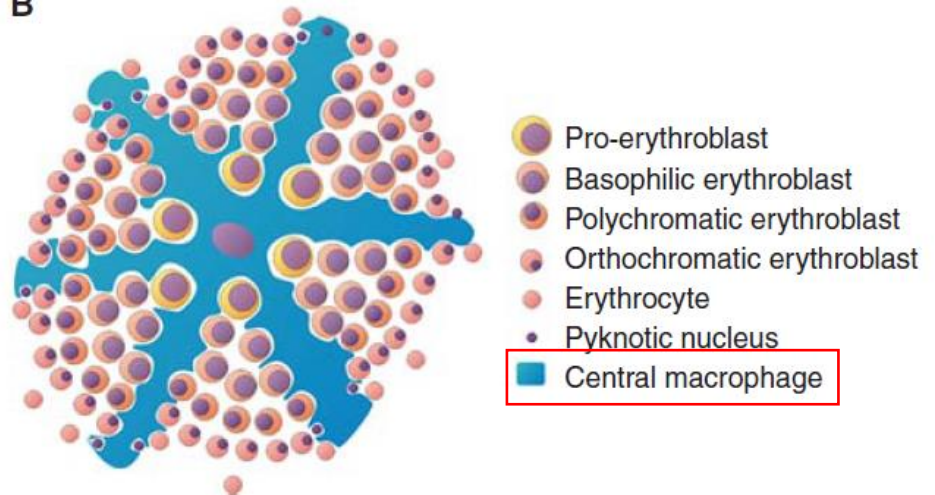
- hepatolienal and bone marrow hematopoiesis
- erythroblast islands



A

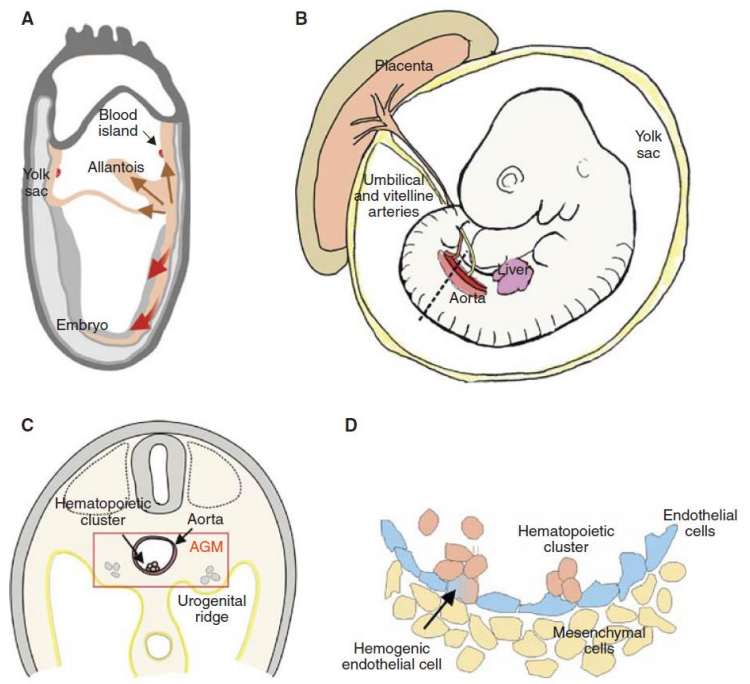
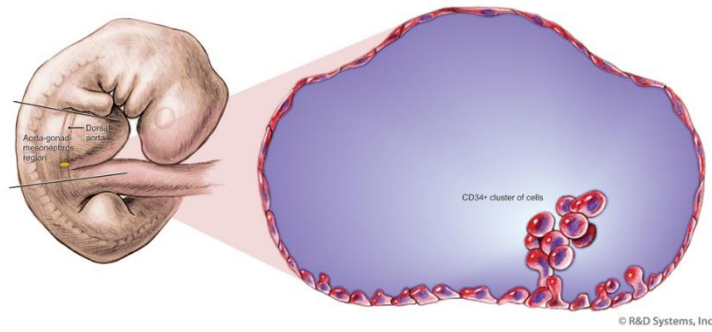


B

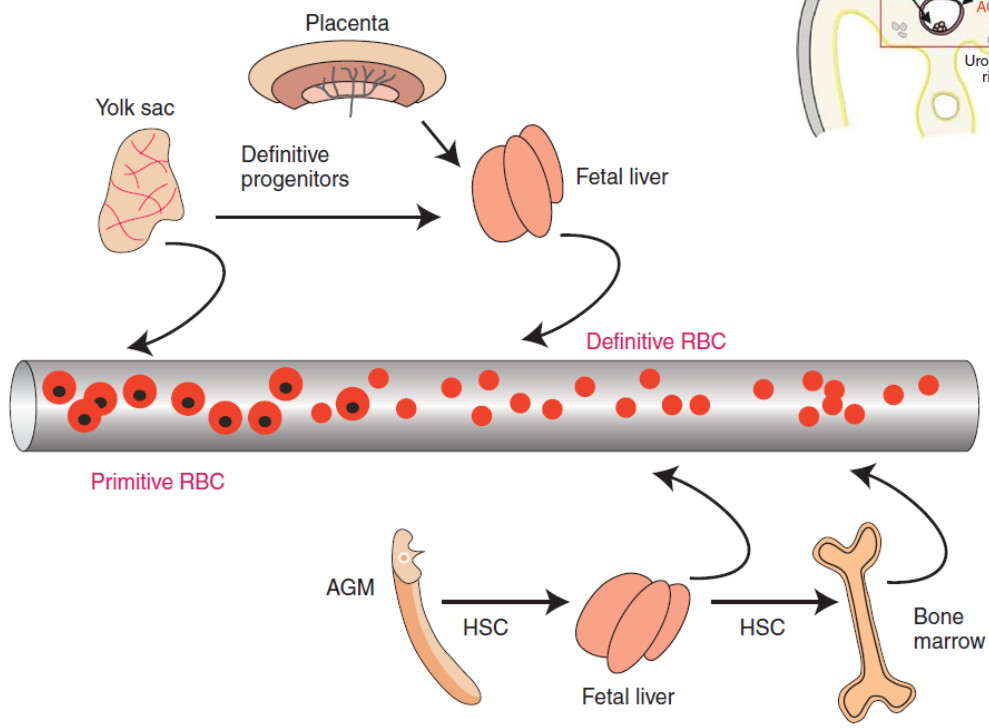


INTRAEMBRYONIC HEMATOPOIESIS

- **Aorta-gonad-mesonephros (day 28 – week 4)**
- para-aortic clusters in mesoderm of splanchnopleura
- source of embryonic HSCs



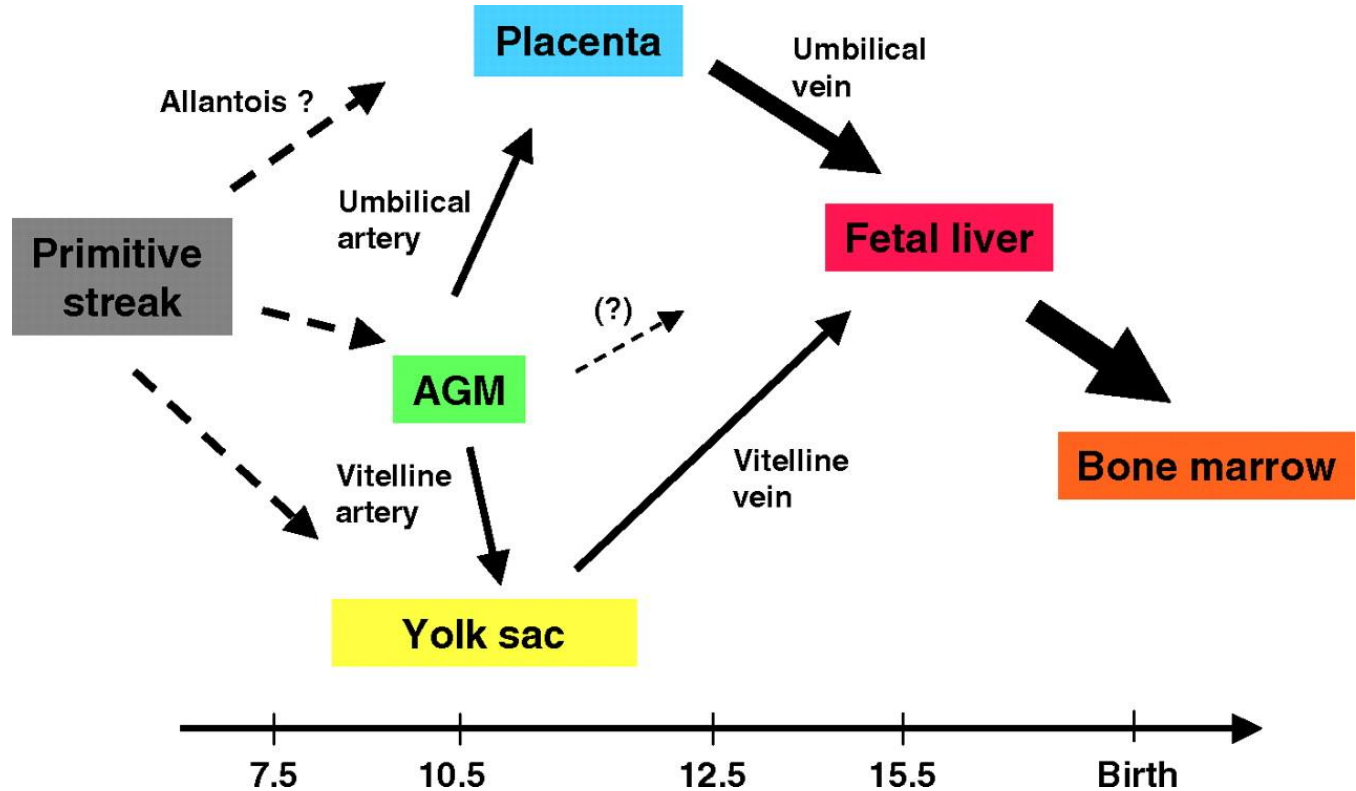
- **Placenta**



SUMMARY OF HEMATOPOIESIS

Embryonic

- yolk sac
- AGM
- liver and spleen
- bone marrow



Adult

- bone marrow (yellow, red)
- extramedullar hematopoiesis rare (pathology)

Thank you for attention



pvanhara@med.muni.cz
www.histology.med.muni.cz