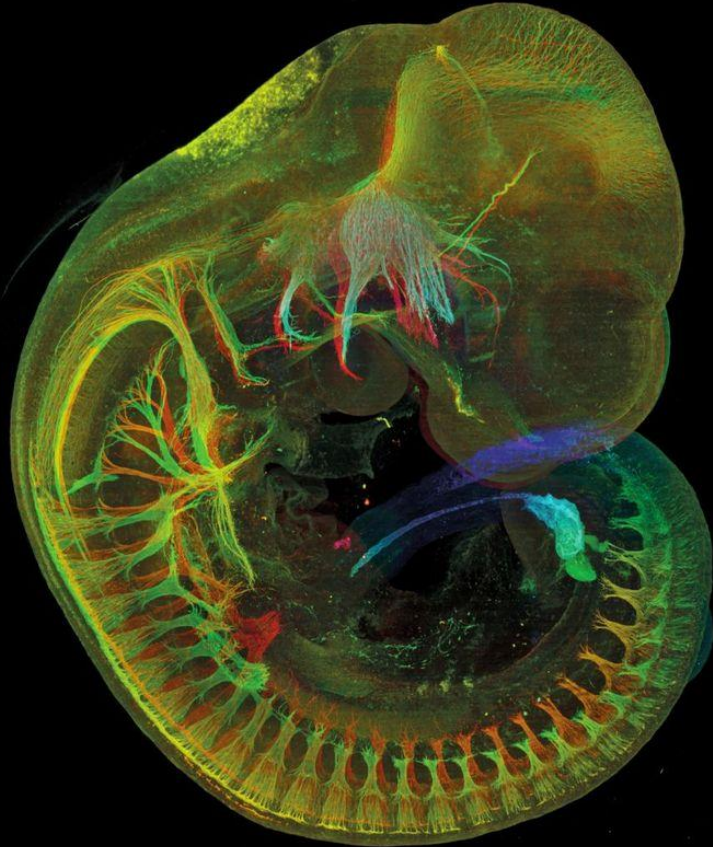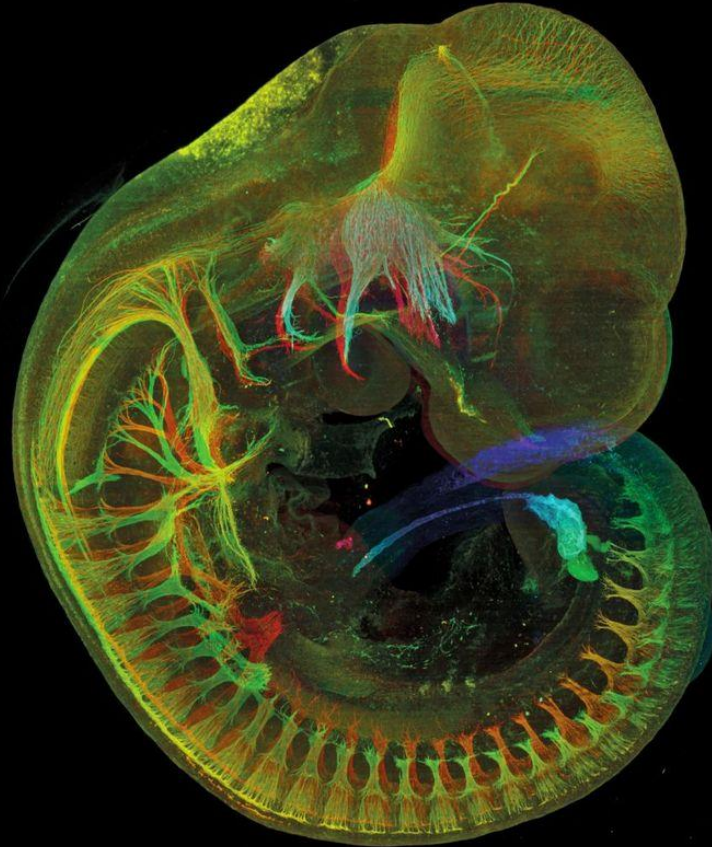


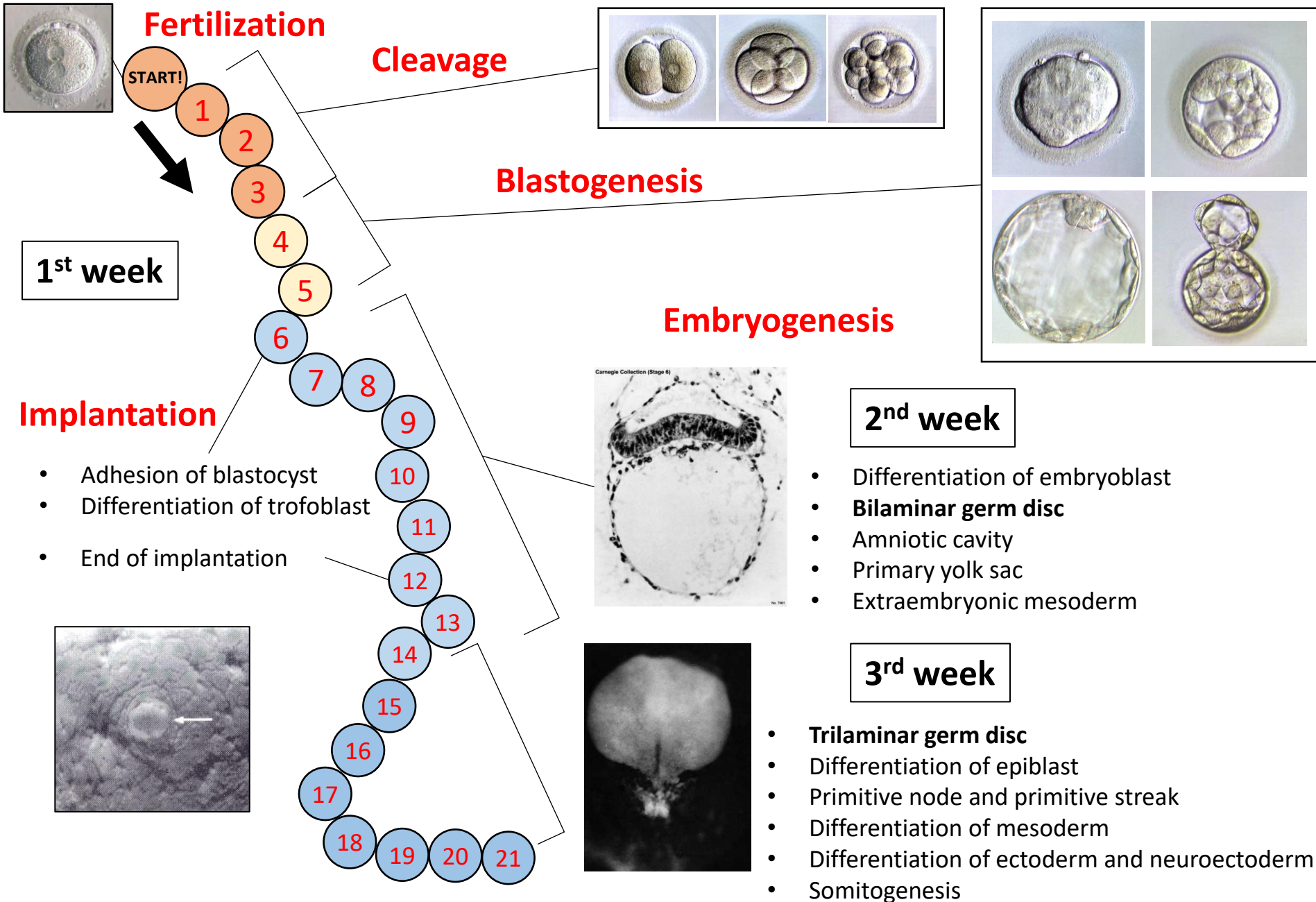
Introduction to embryology III

Petr Vaňhara



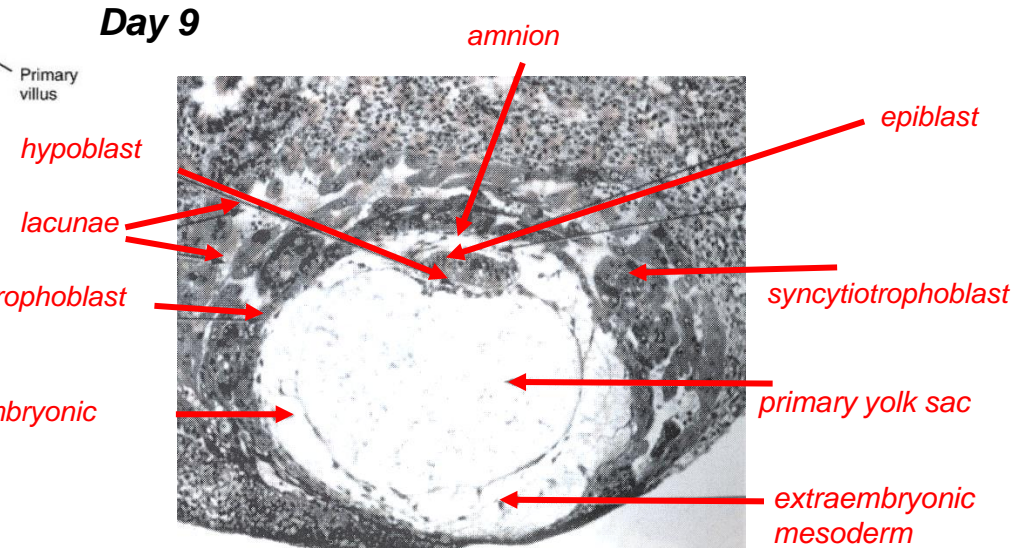
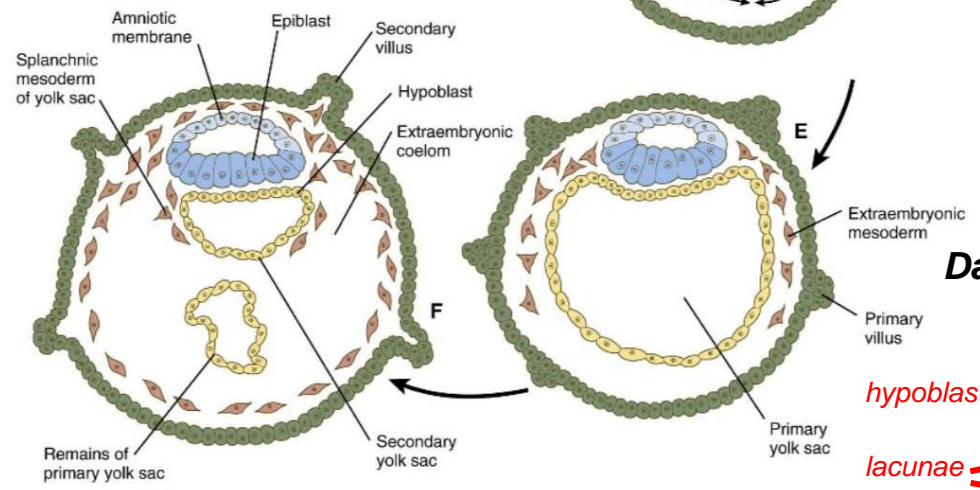
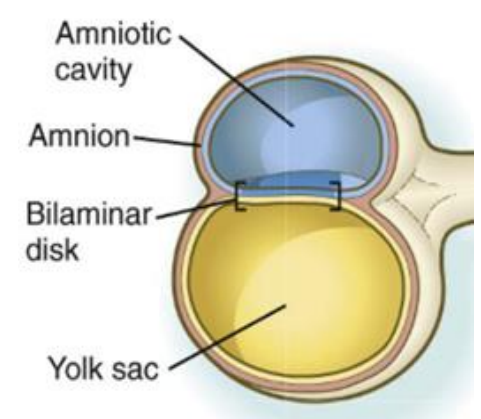
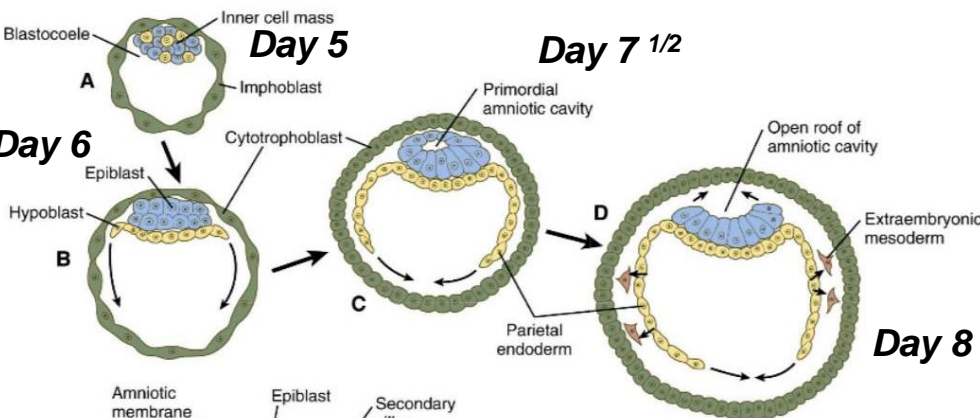
1. Revision of early embryogenesis
2. Trilaminar germ disc embryo
3. Folding of embryo
4. Pregnancy and fetal development
5. Prenatal diagnostics

FIRST EVENTS IN HUMAN LIFE


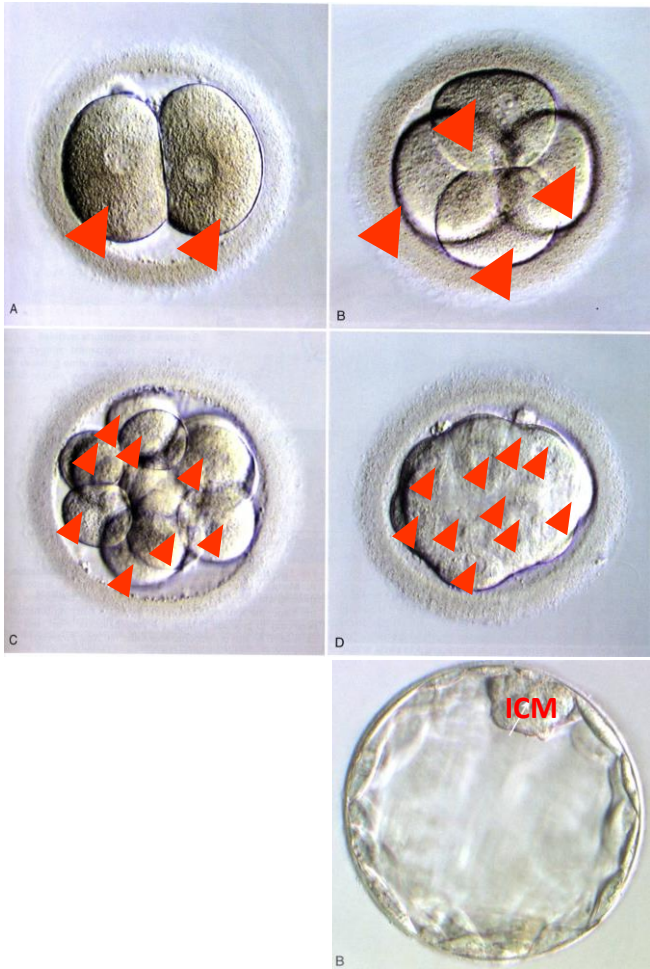


1st-2nd week

BILAMINAR GERM DISC

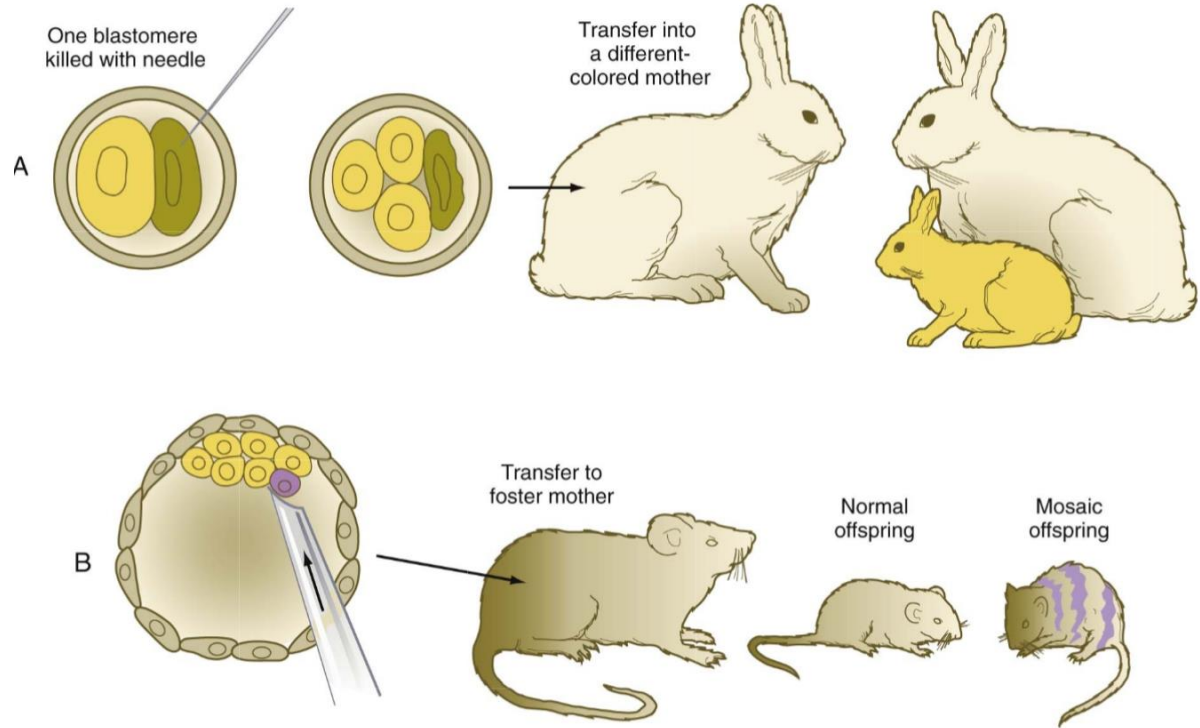
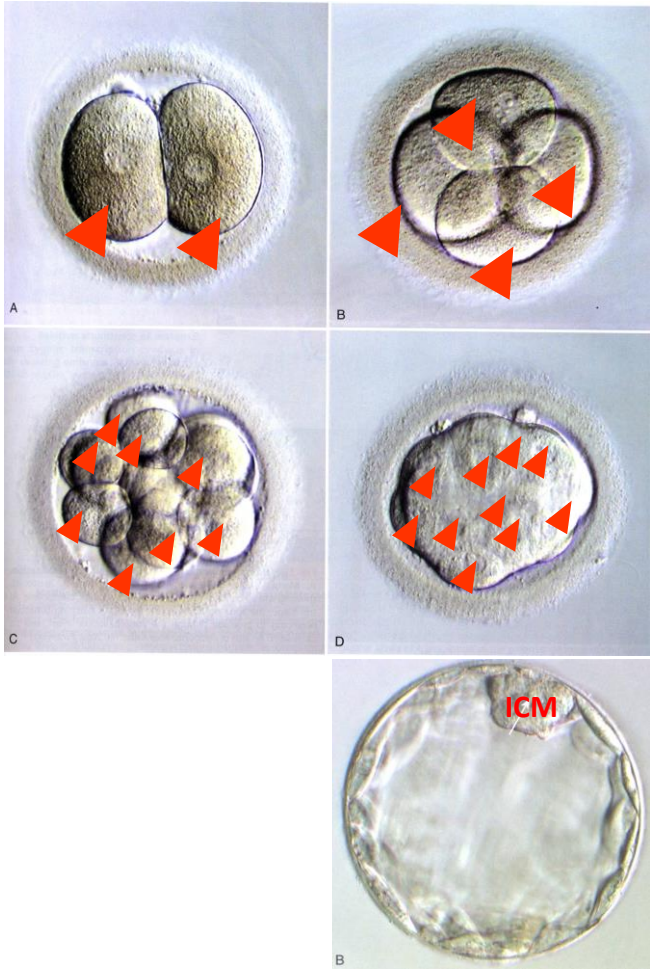


1st week



FIRST EMBRYONIC CELLS - BLASTOMERES

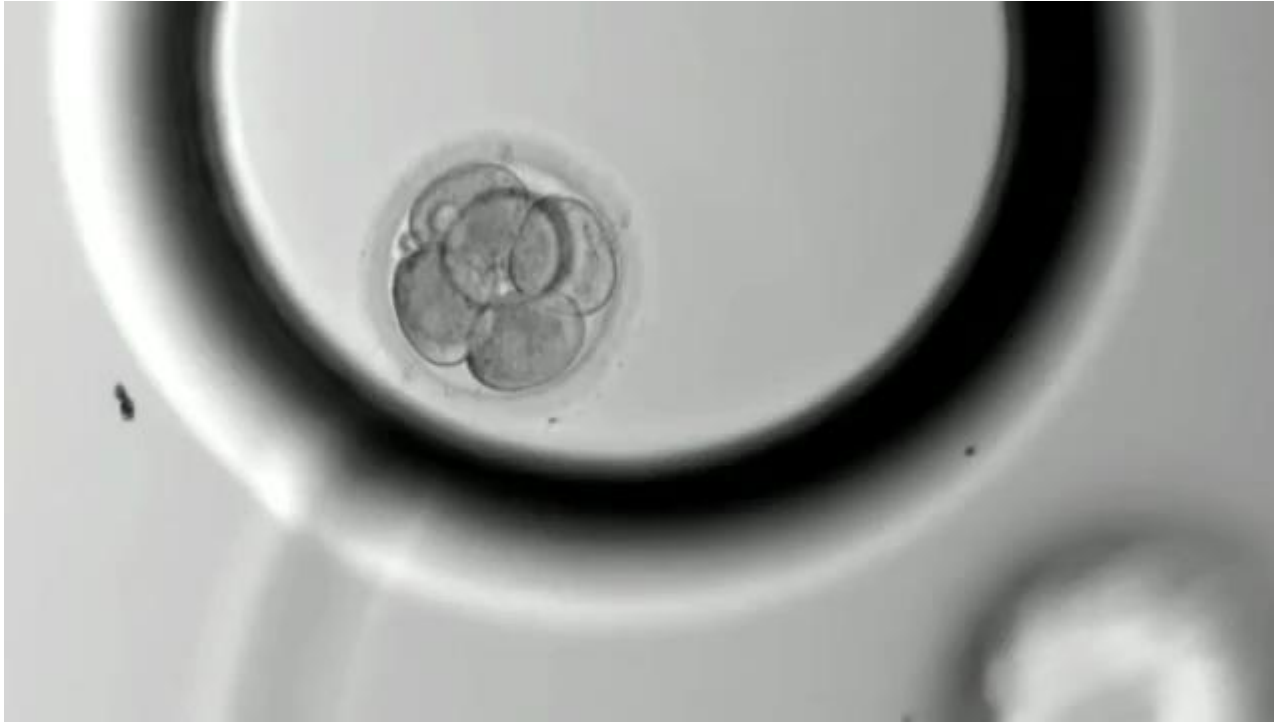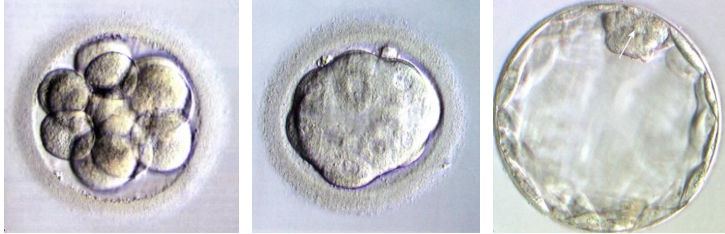1st week



Blastomeres are totipotent

FIRST EMBRYONIC CELLS - BLASTOMERES

COMPACTATION IS CRUCIAL

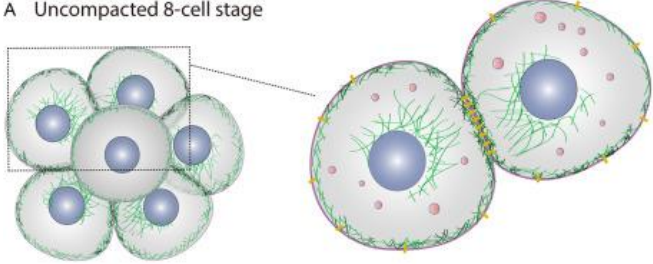


DETERMINATION OF EMBRYONIC CELLS – RESTRICTION OF DEVELOPMENTAL FATE

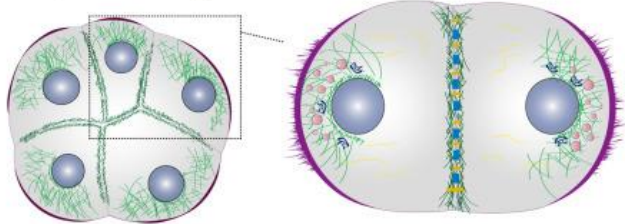
FIRST EMBRYONIC CELLS - BLASTOMERES

POLARITY AND DIFFERENTIATION

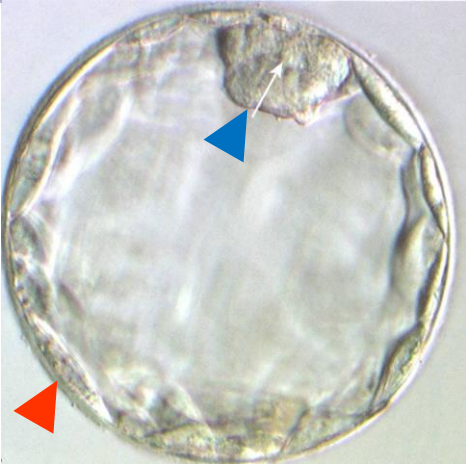
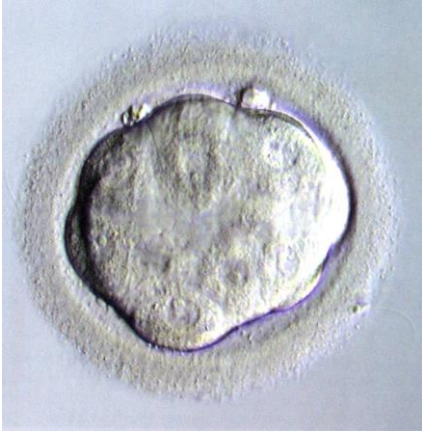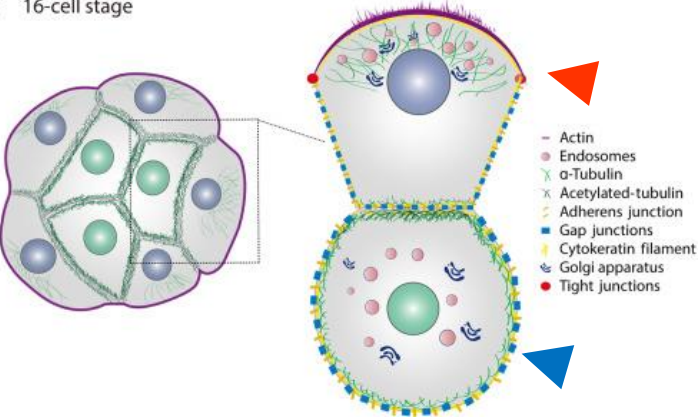
A Uncompacted 8-cell stage



B Compacted 8-cell stage





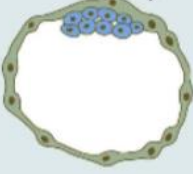
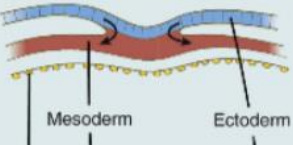
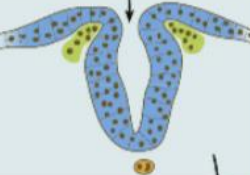

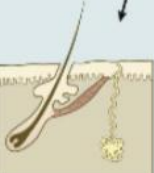
C 16-cell stage



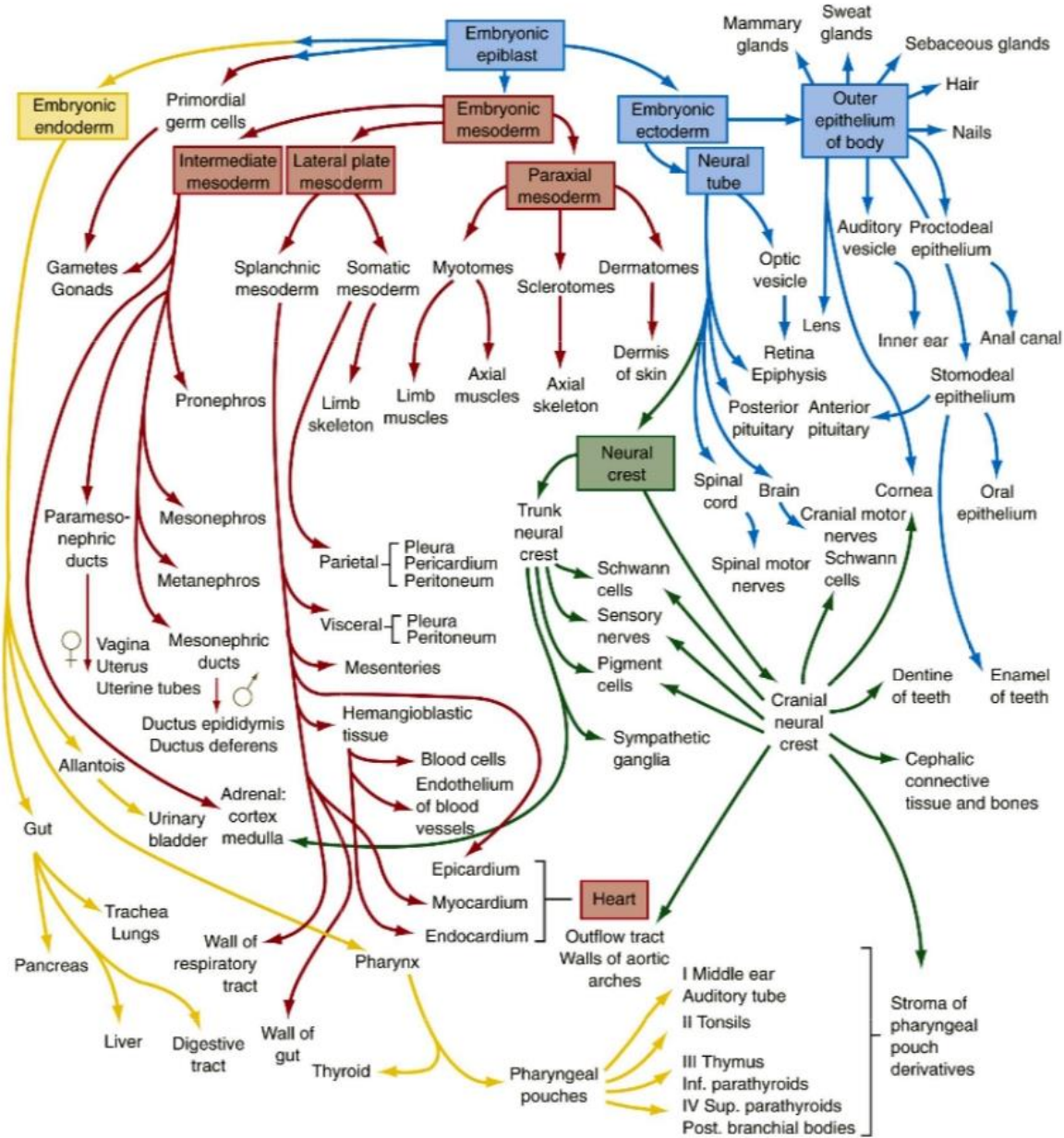
<https://doi.org/10.1016/bs.ctdb.2016.04.008>

DETERMINED BLASTOMERES DIFFERENTIATE TO TROPHOBLAST AND EMBRYOBLAST

EMBRYONIC INDUCTION AND DETERMINATION

Zygote		Cells totipotent
Cleavage		
Inside-outside determination		Only inner cell mass can form embryo proper
Gastrulation Germ layer formation Ectoderm Mesoderm Endoderm		Ectodermal derivatives Brain Spinal cord Peripheral nerves Pigment cells Inner ear Retina Iris Lens Cornea Skin glands Hair Epidermis
Neurulation (neural induction) Central nervous system Neural crest		Remaining ectodermal potency Inner ear Lens Cornea Skin glands Hair Epidermis
Secondary inductions Inner ear Lens		Remaining ectodermal potency Cornea Skin glands Hair Epidermis
Further inductions Cornea Skin glands Hair		Remaining ectodermal potency Epidermis

EMBRYONIC INDUCTION AND DETERMINATION DRIVE DEVELOPMENT OF TISSUES AND ORGANS



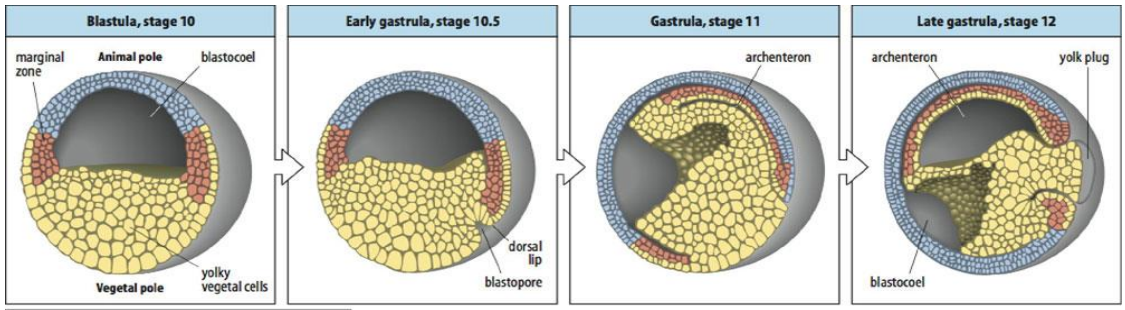
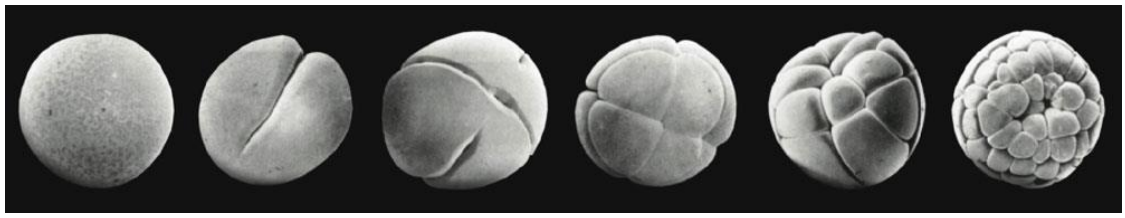
BREAKTHROUGH EXPERIMENT OF HANS SPEMANN AND HILDE MANGOLD 1923

1923

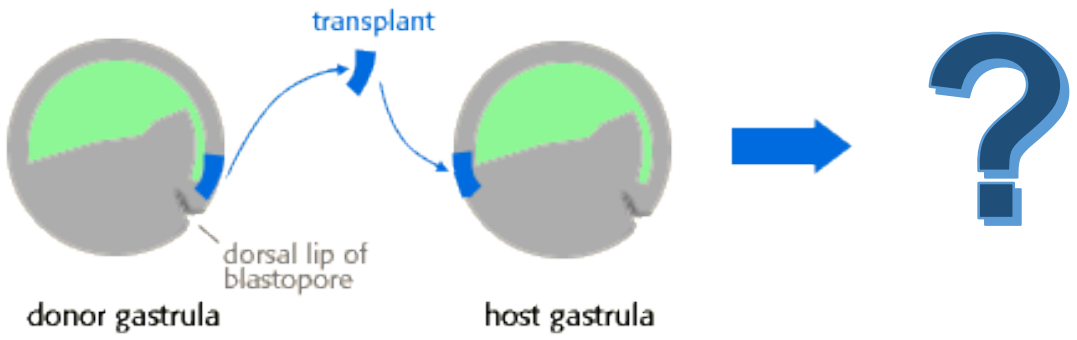
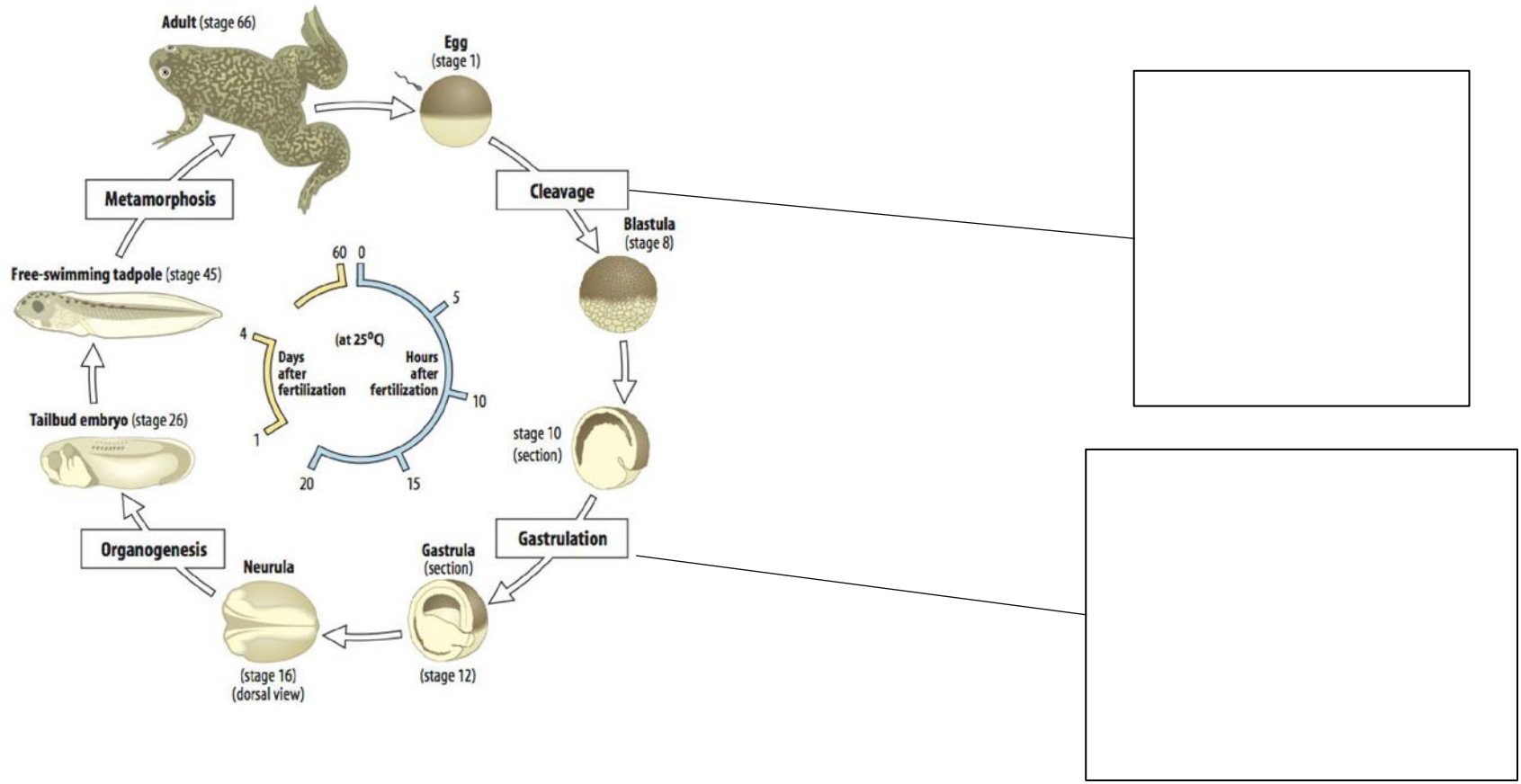


1931

H. Spemann



BREAKTHROUGH EXPERIMENT OF HANS SPEMANN AND HILDE MANGOLD



What did they get?

Two-headed monster!



BREAKTHROUGH EXPERIMENT OF HANS SPEMANN AND HILDE MANGOLD

Induction of Embryonic Primordia by Implantation of Organizers from a Different Species

by

HANS SPEMANN and HILDE MANGOLD (*Née Pröscholdt*)

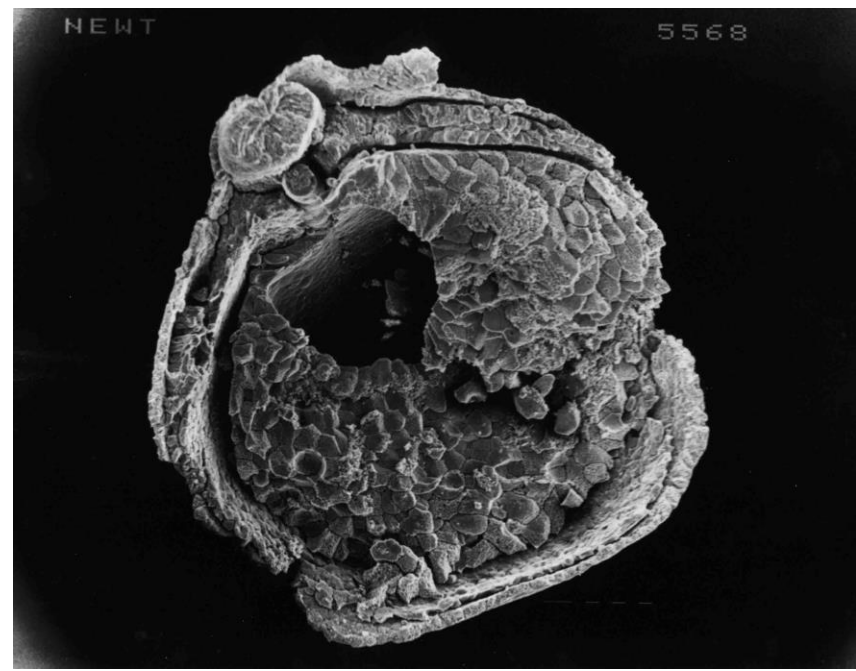
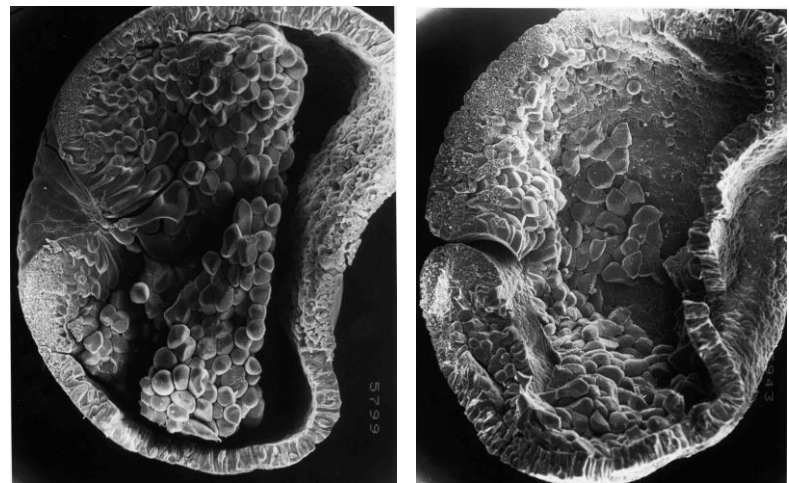
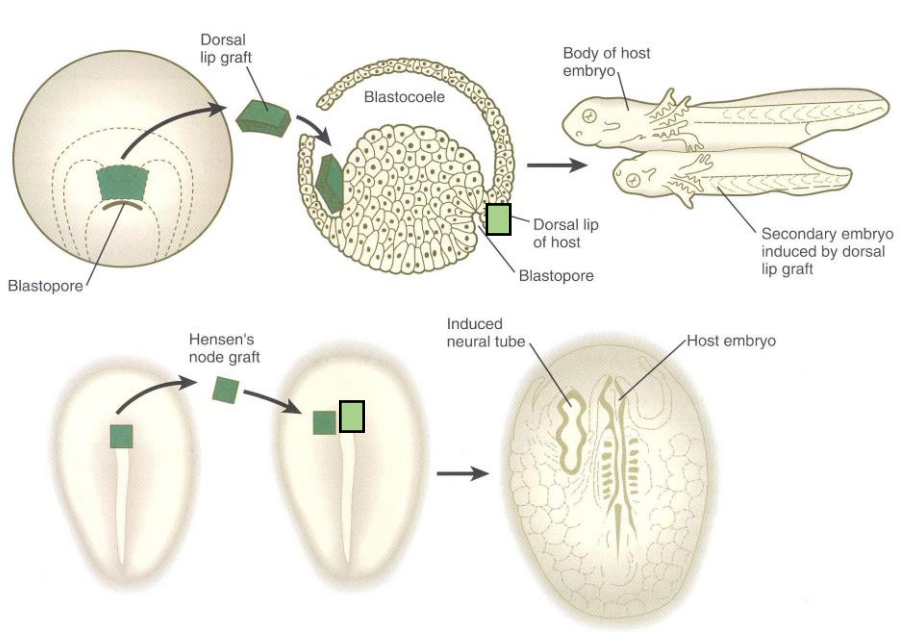
Freiburg i.B.
With 25 illustrations
(Submitted 1 June 1923)

„A piece of upper blastopore lip of an amphibian embryo undergoing gastrulation exerts an organizing effect on its environment in such a way that, if transplanted to an indifferent region of another embryo, it causes there the formation of a secondary embryonic anlage. Such a piece can therefore be designated as an **Organizer**.“



SPEMANN'S ORGANIZER

PRINCIPLE OF EMBRYONIC INDUCTION

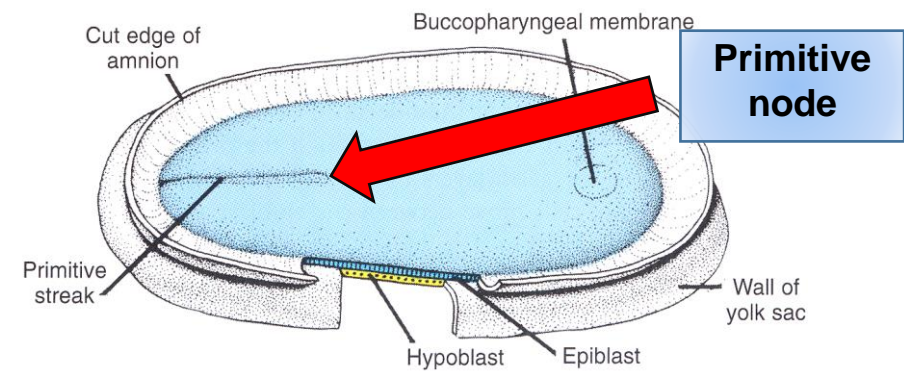
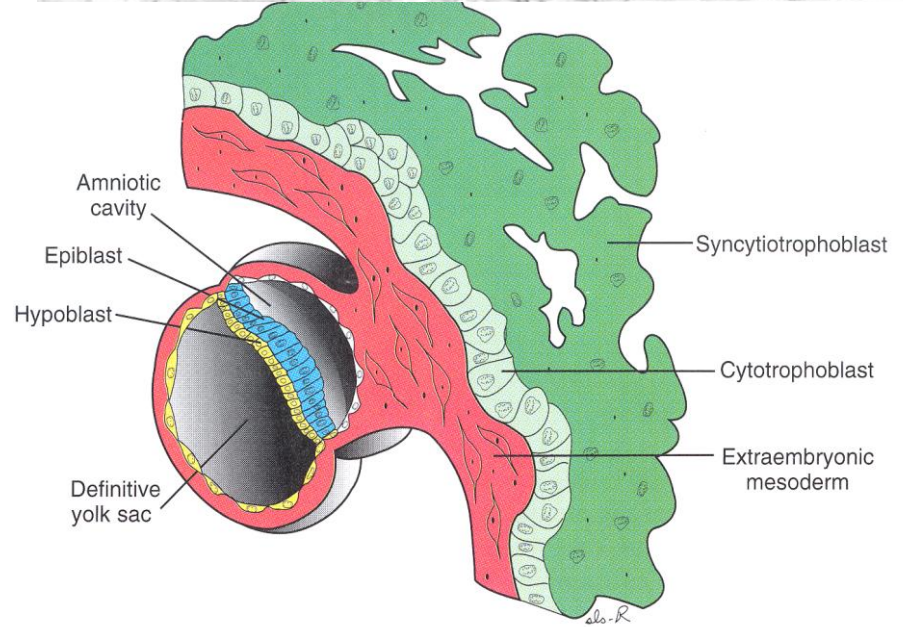
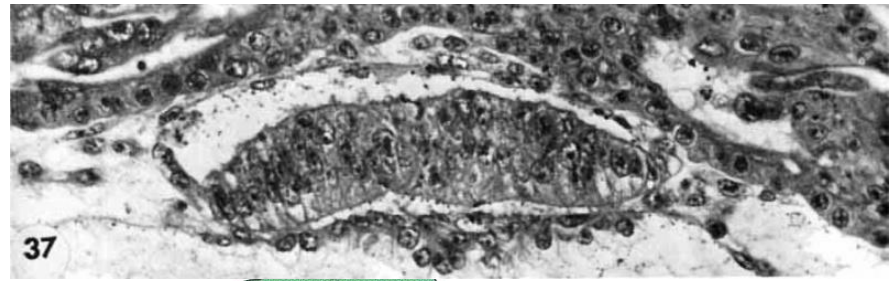
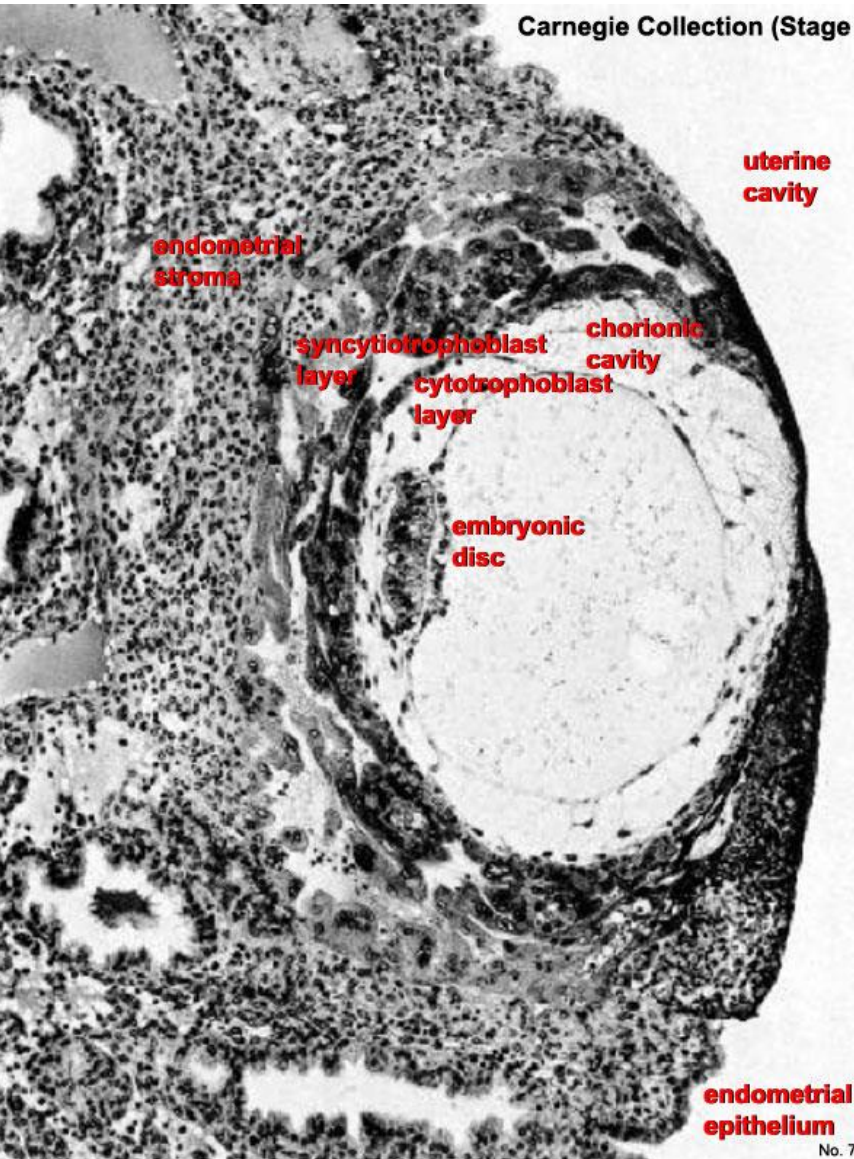


The embryonic „organizer“ stimulates other cells to proliferate, differentiate and make new structures.

ORGANIZER EXISTS IN MAMMALS

BILAMINAR GERM DISC

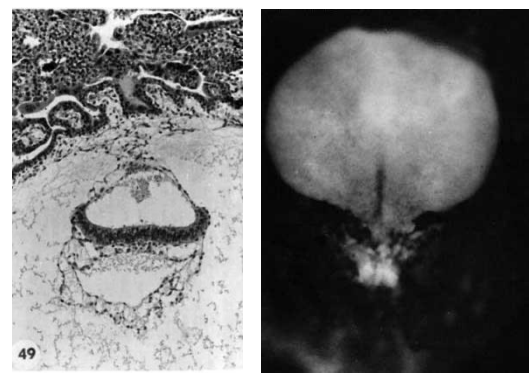
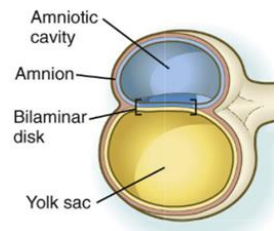
2nd week



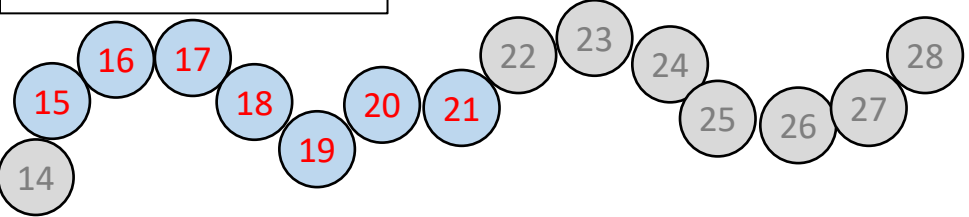
TRILAMINAR GERM DISC

PRIMITIVE STREAK AND PRIMITIVE NODE

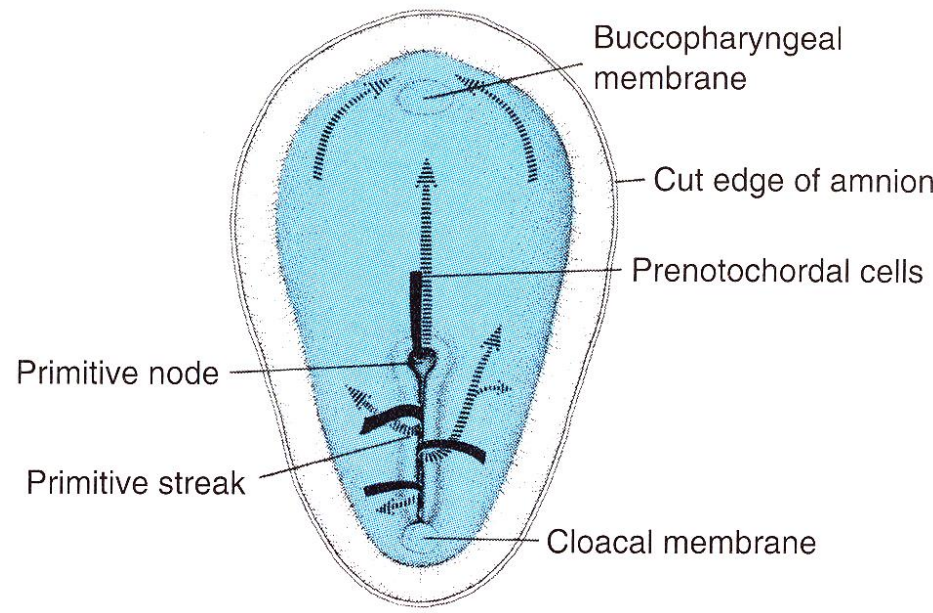
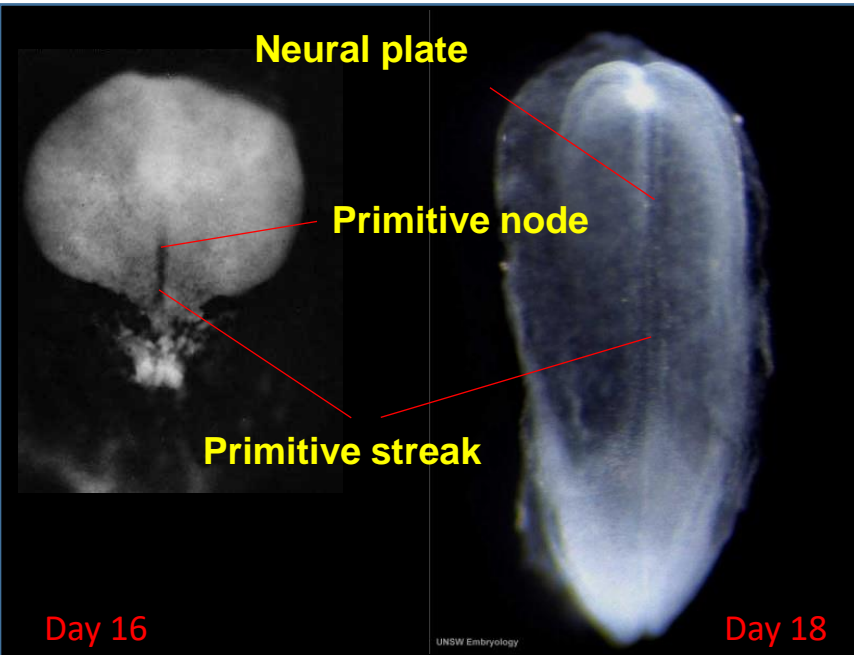
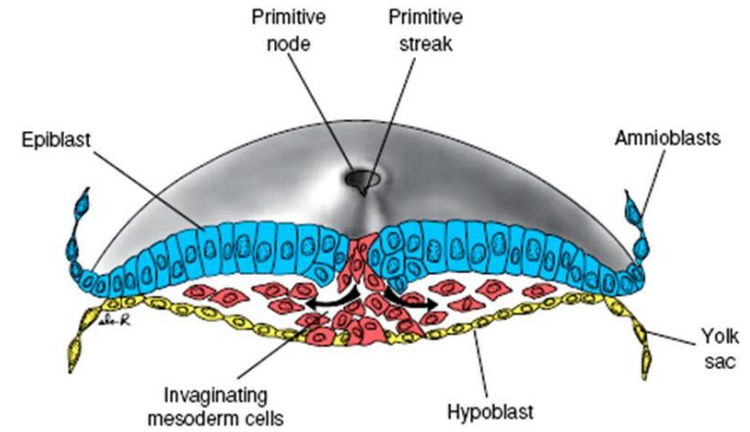
2nd week ends



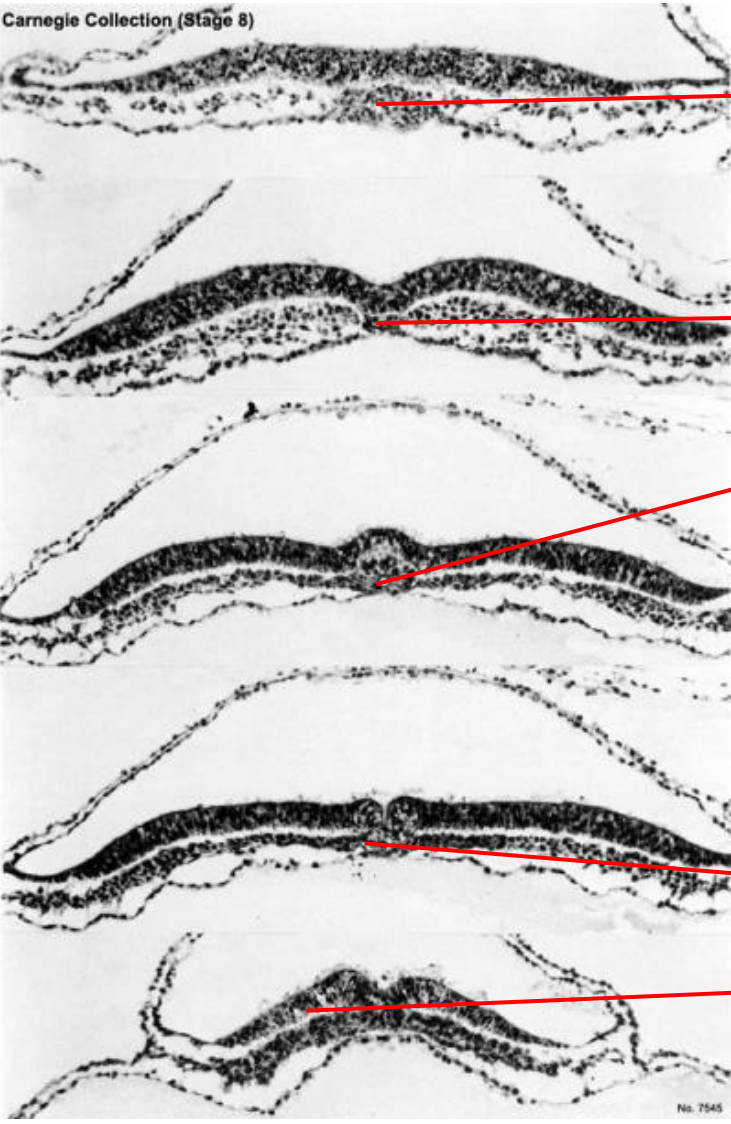
3rd week begins



NEW STRUCTURES



3rd week



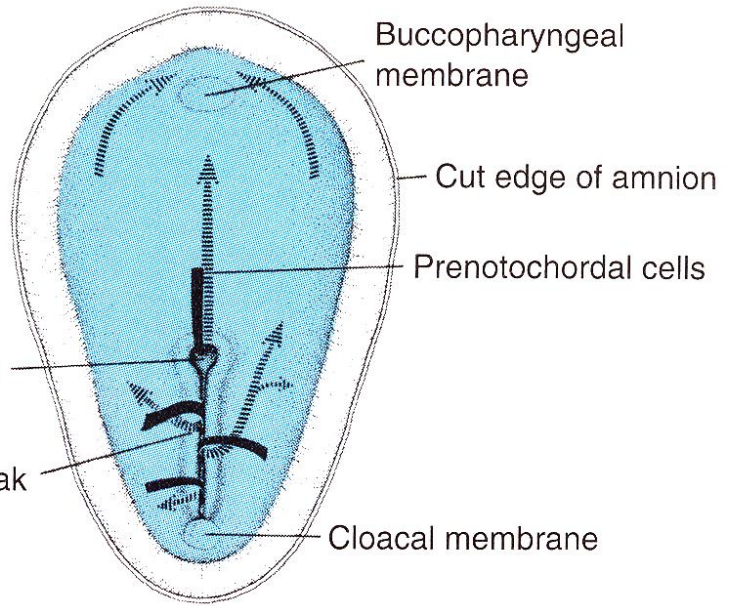
Prechordal plate

Neural plate

Notochordal process

Primitive node

Primitive streak



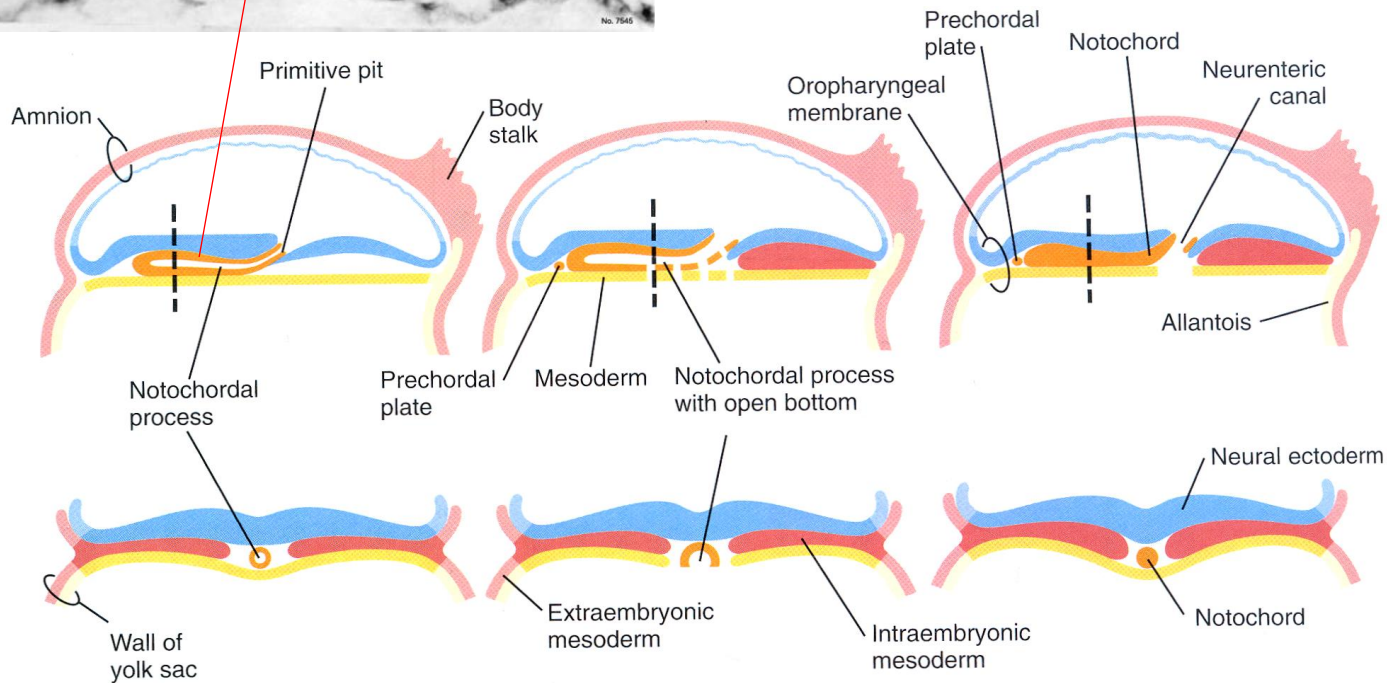
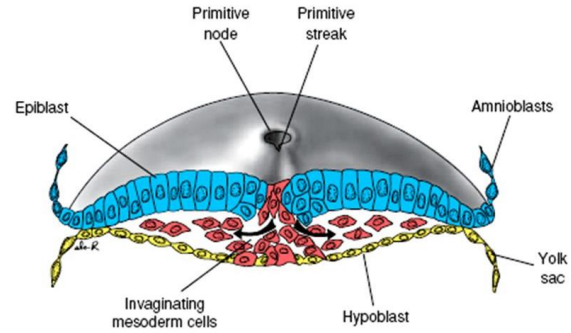
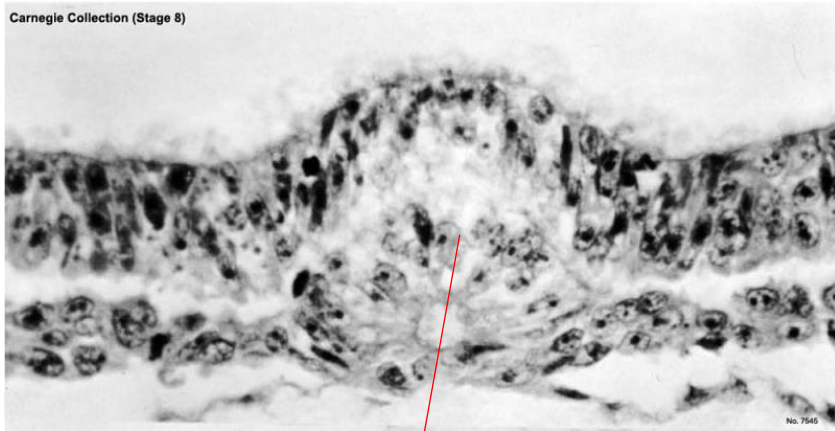
Buccopharyngeal membrane

Cut edge of amnion

Prenotochordal cells

Cloacal membrane

3rd week



Day 17

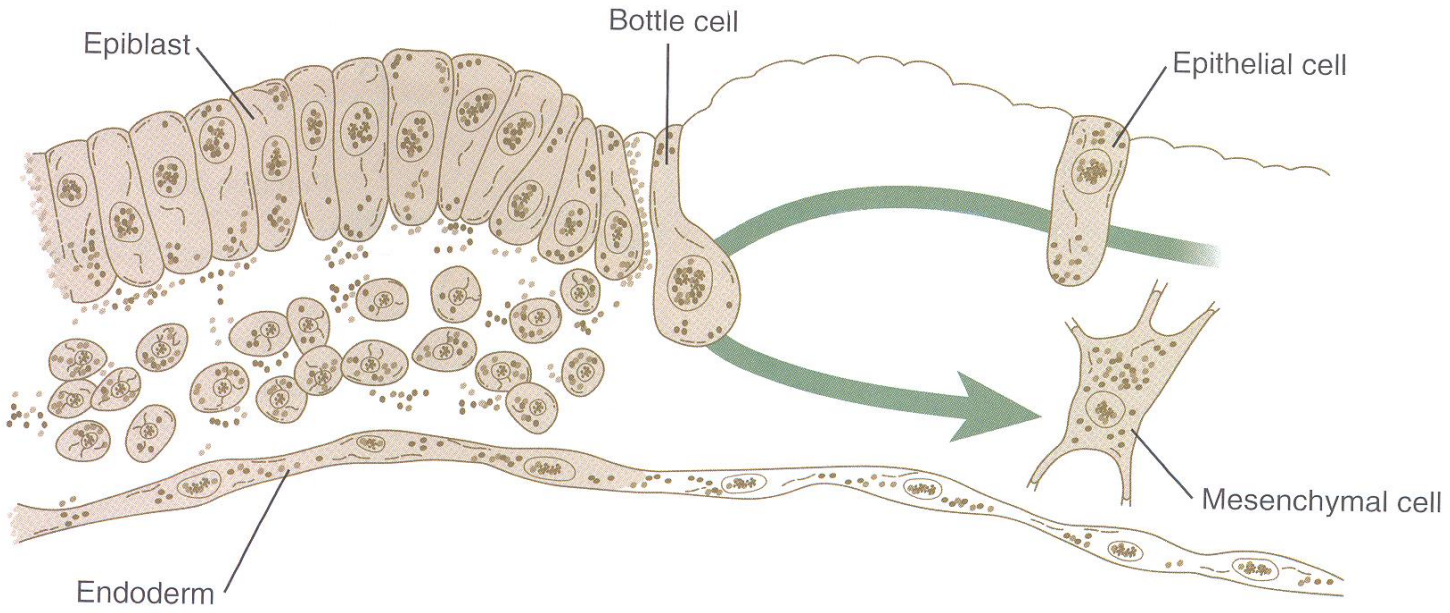
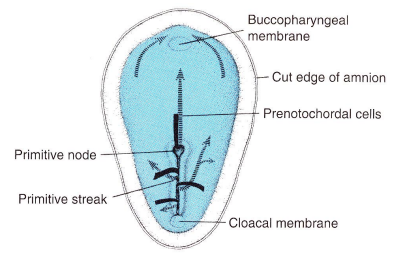
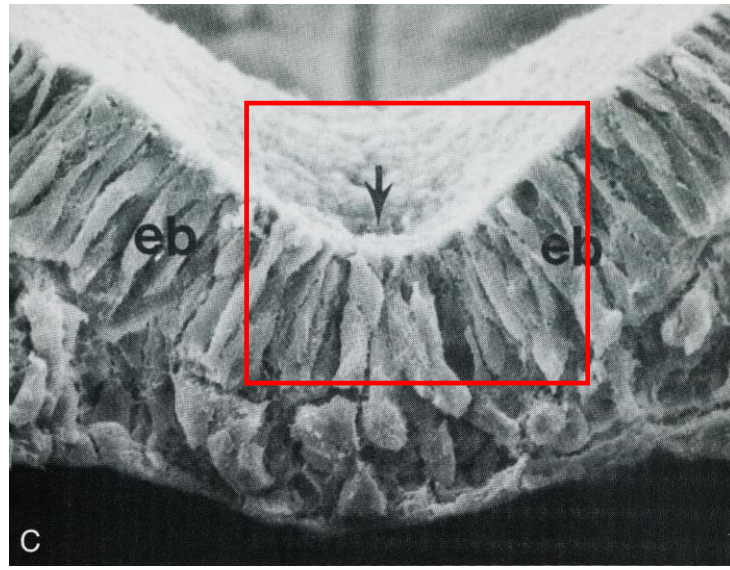
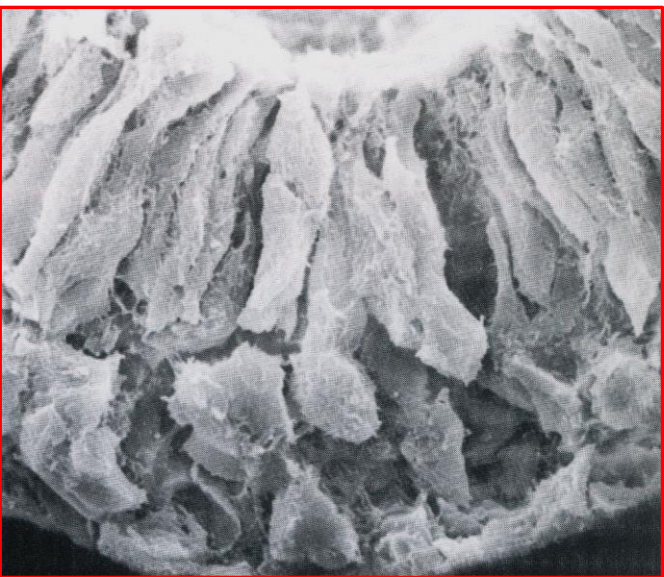
Day 18

Day 19

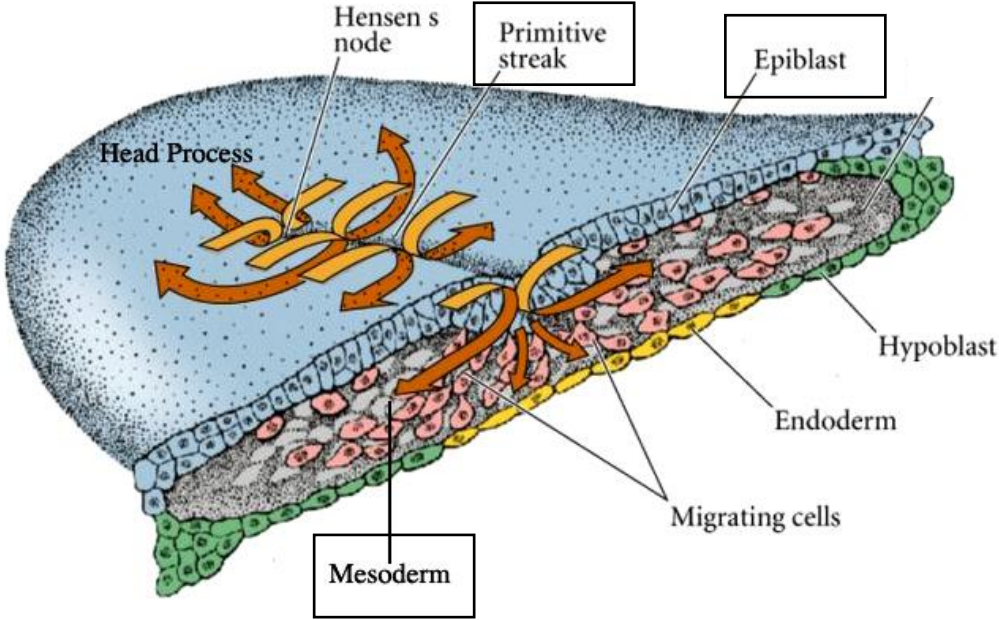
TRILAMINAR GERM DISC

PRIMITIVE STREAK AND PRIMITIVE NODE

3rd week



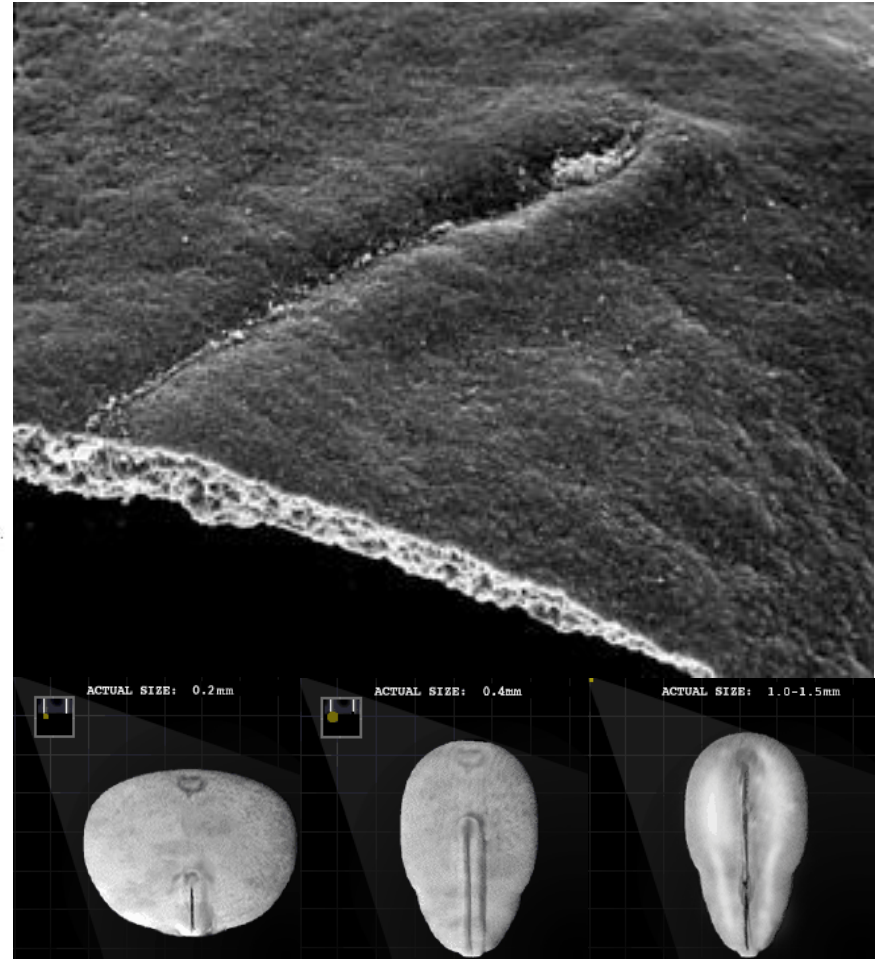
3rd week

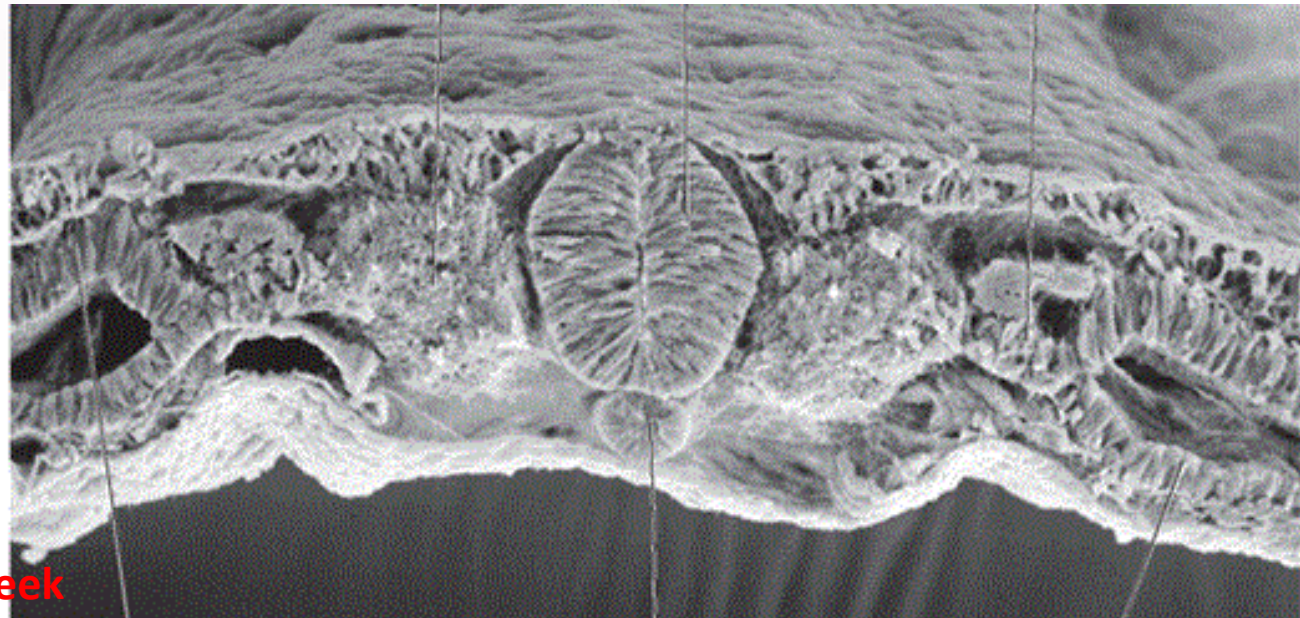
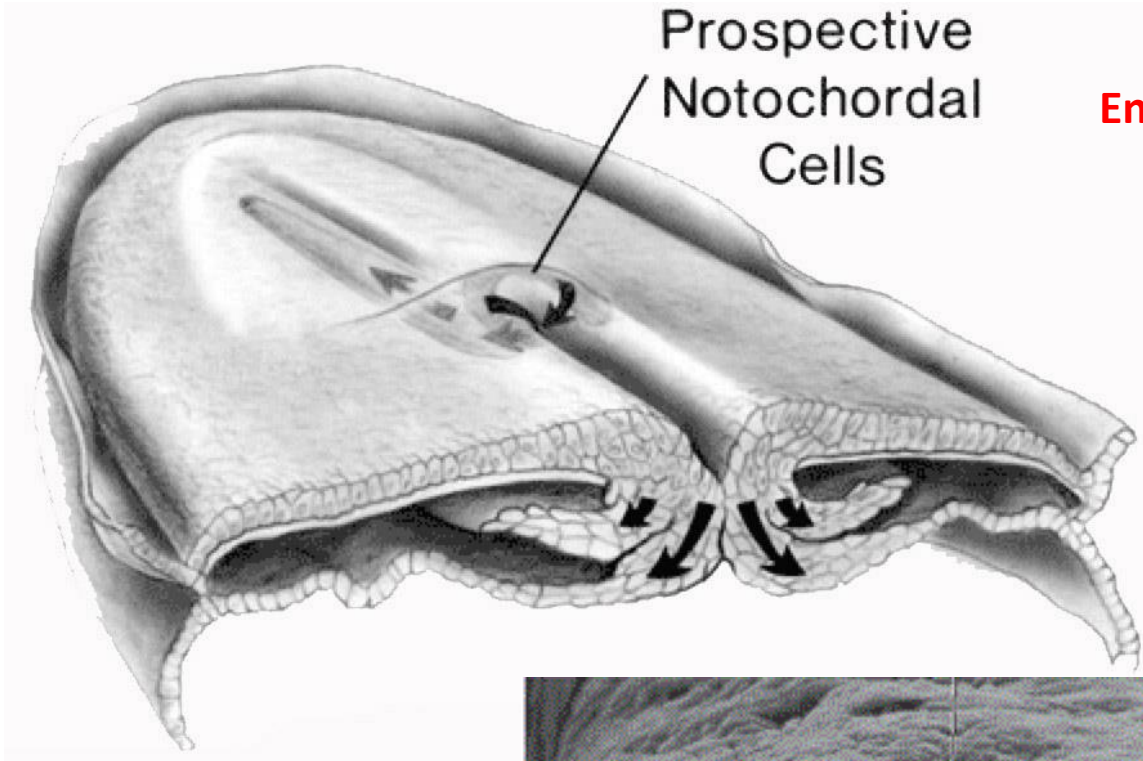


© 2000 Saunders Associates, Inc.

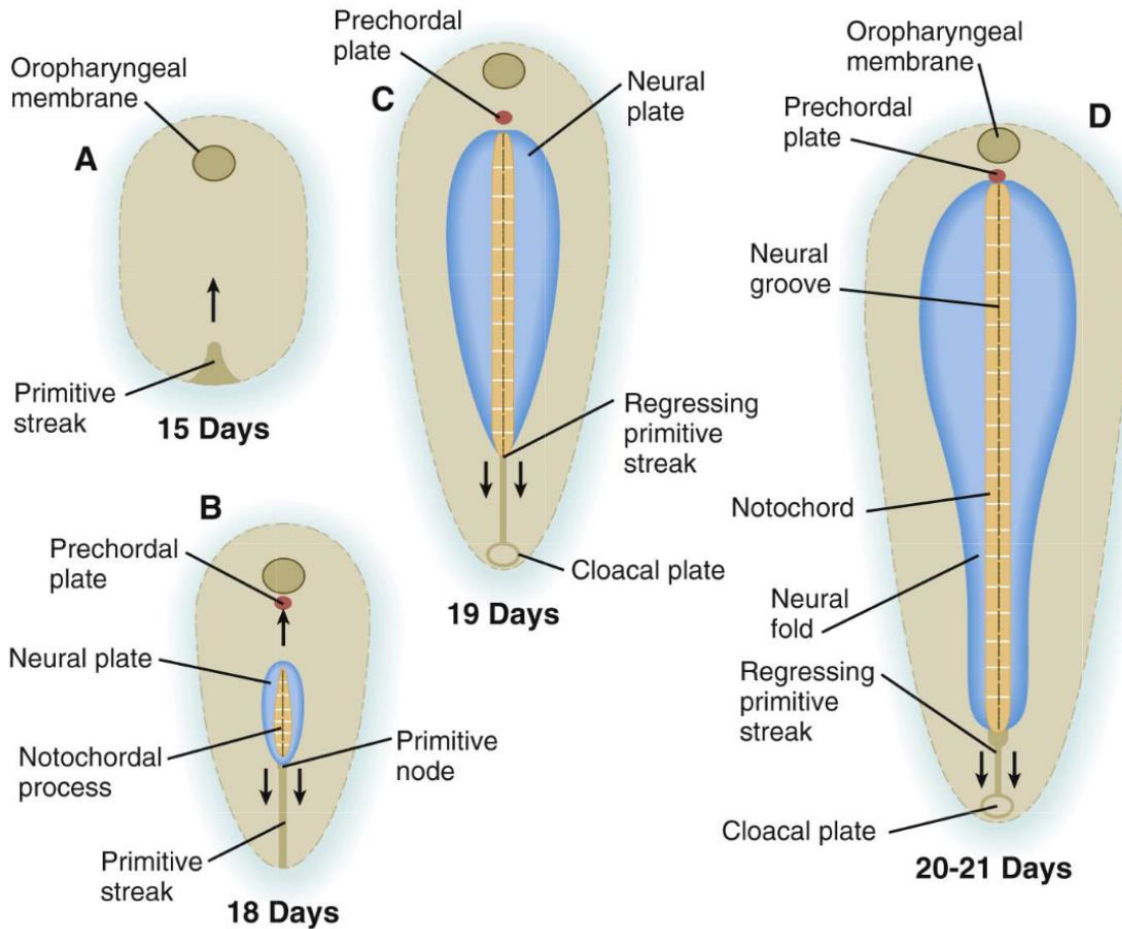
In the 3rd week, cells of epiblast migrate through the primitive streak and establish new cell population within the embryo by the process of gastrulation:

EMBRYONIC MESODERM





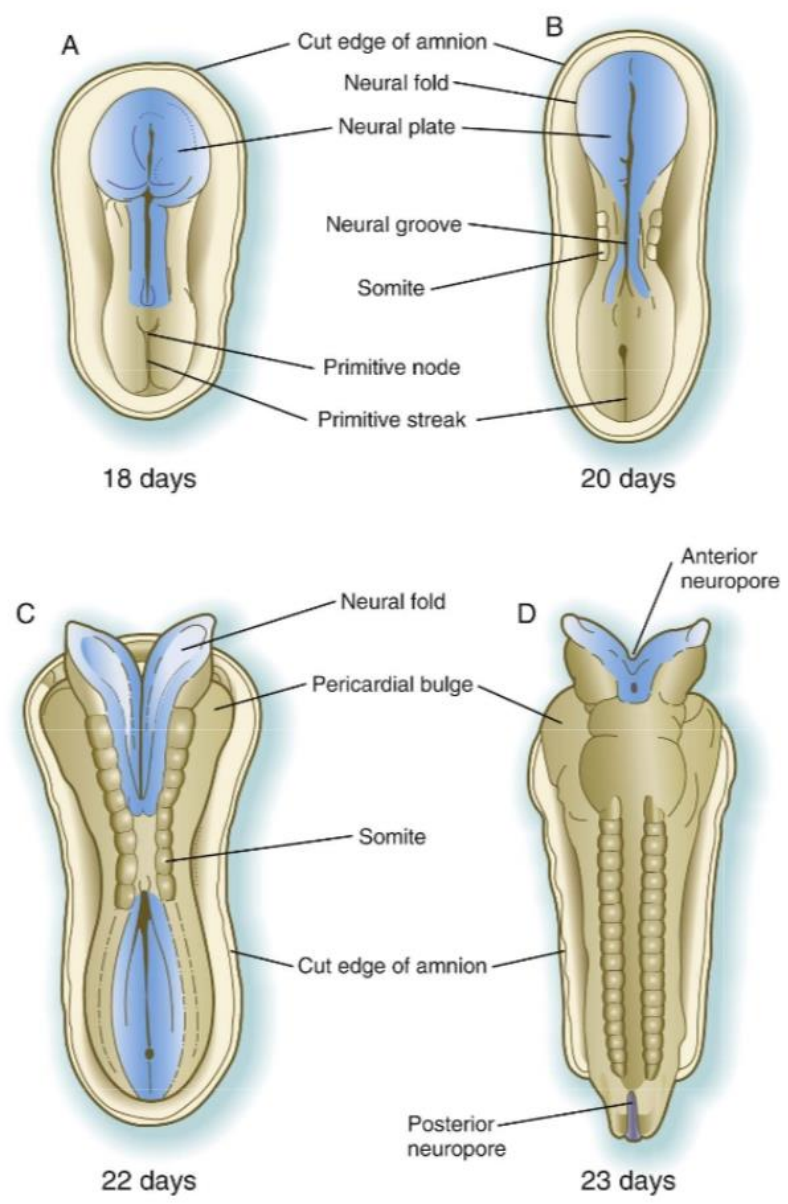
3rd week



Notochord induces differentiation of ectoderm – cellular basis of nerve system is established – **NEUROECTODERM**

NEURULATION

3rd week

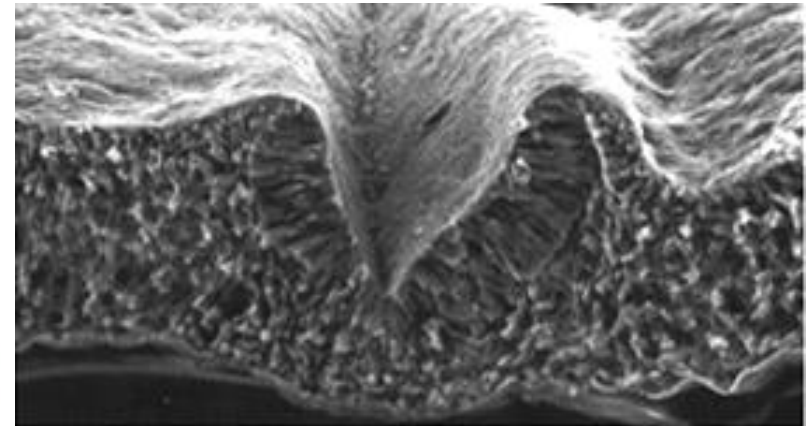
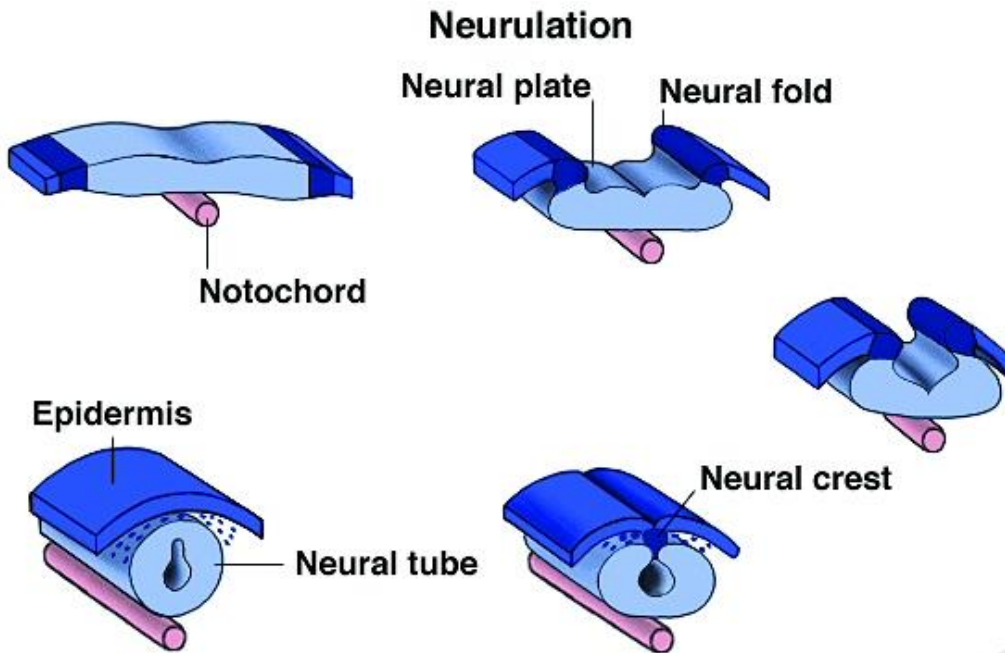


- Neural plate
- Neural folds
- Neural tube

- Neural crest

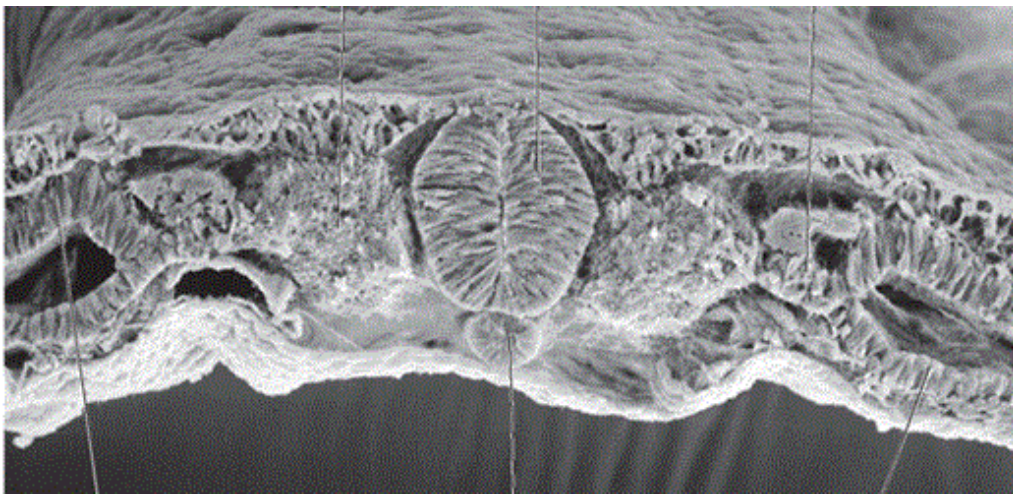
NEURULATION

3rd week



*Endoderm and mesoderm produce BMP4 growth factors, that induce development of **epidermis***

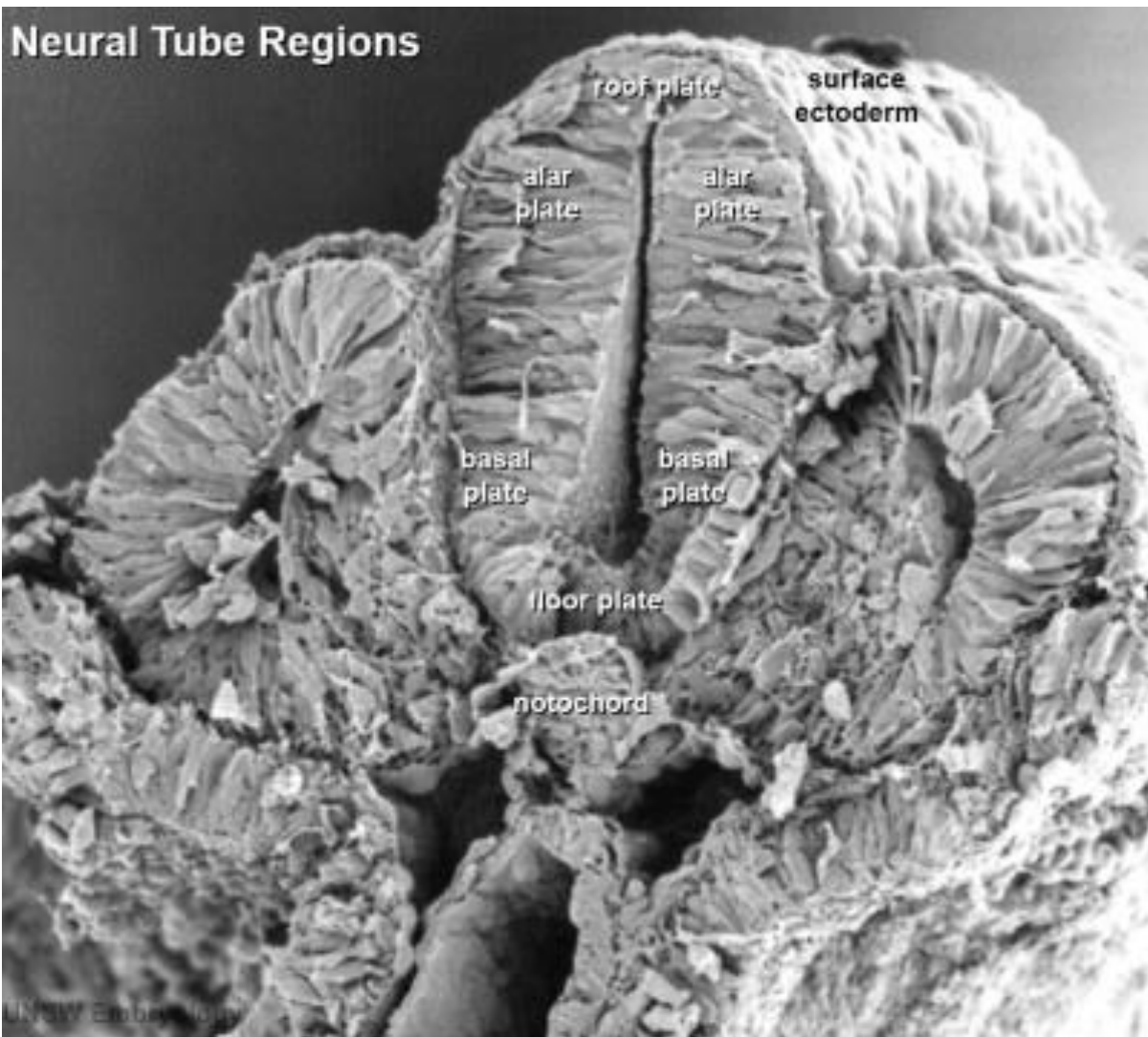
*Notochord produces inhibitors of BMP4 - **noggin**, **chordin** and **follistatin** (cranially) a **wnt3a** and **FGF** (caudally) - ectoderm differentiates into **neuroectoderm**.*



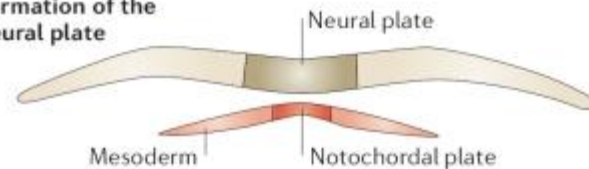
NEURULATION

3rd – 4th week

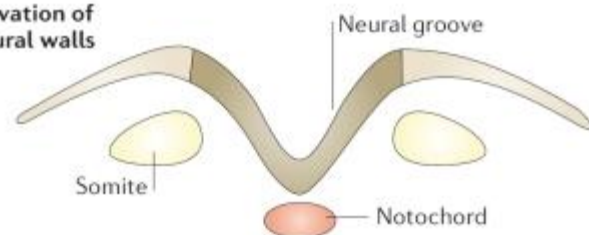
Neural Tube Regions



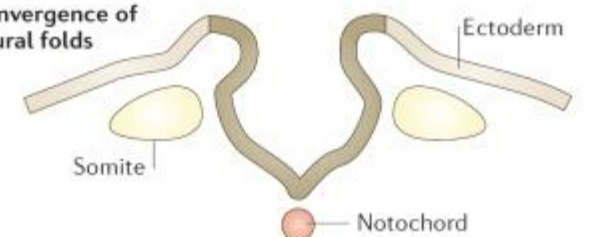
B Formation of the neural plate



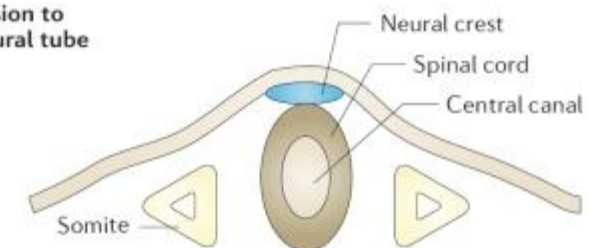
Elevation of neural walls



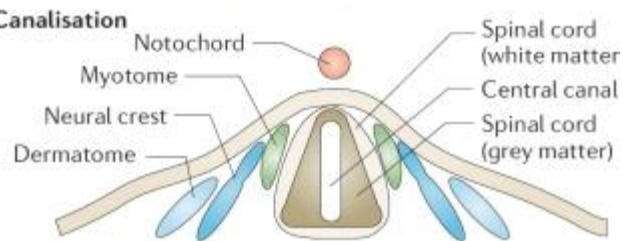
Convergence of neural folds

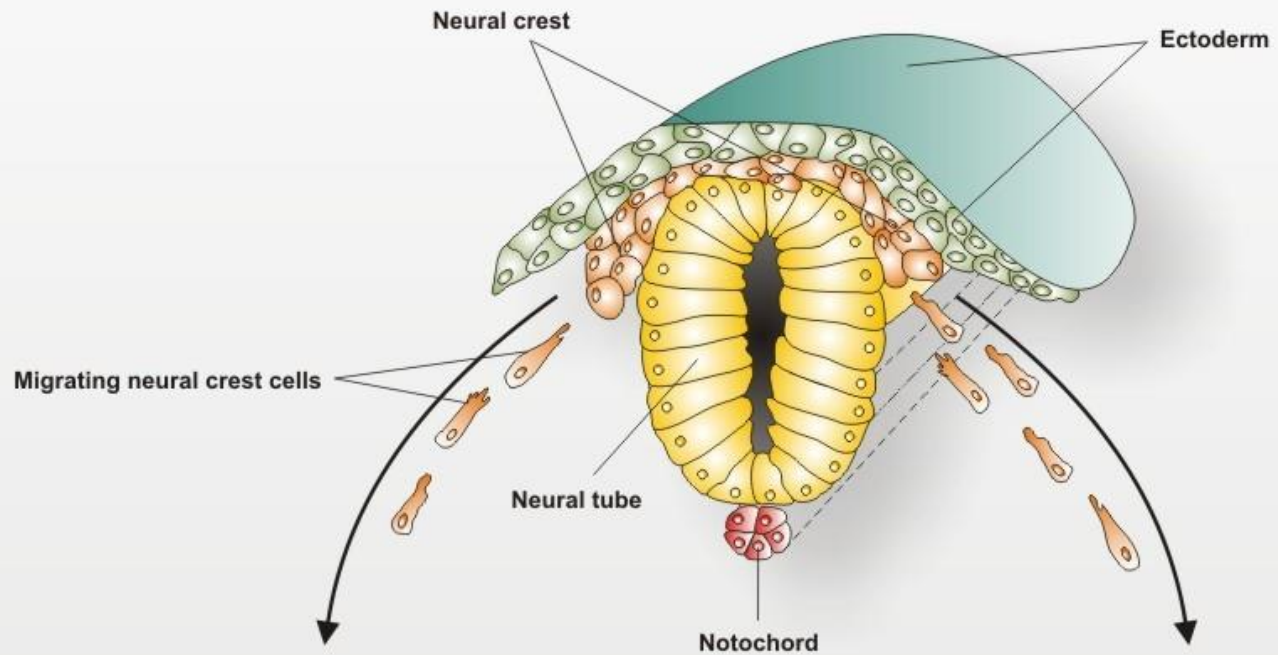


Fusion to neural tube



Canalisation





Mesoderm

Ectoderm



Smooth muscle cells



Osteoblasts
Osteoclasts



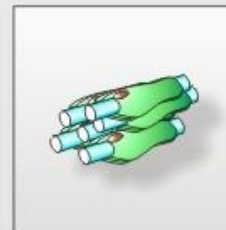Adipocytes



Chondrocytes



Melanocytes

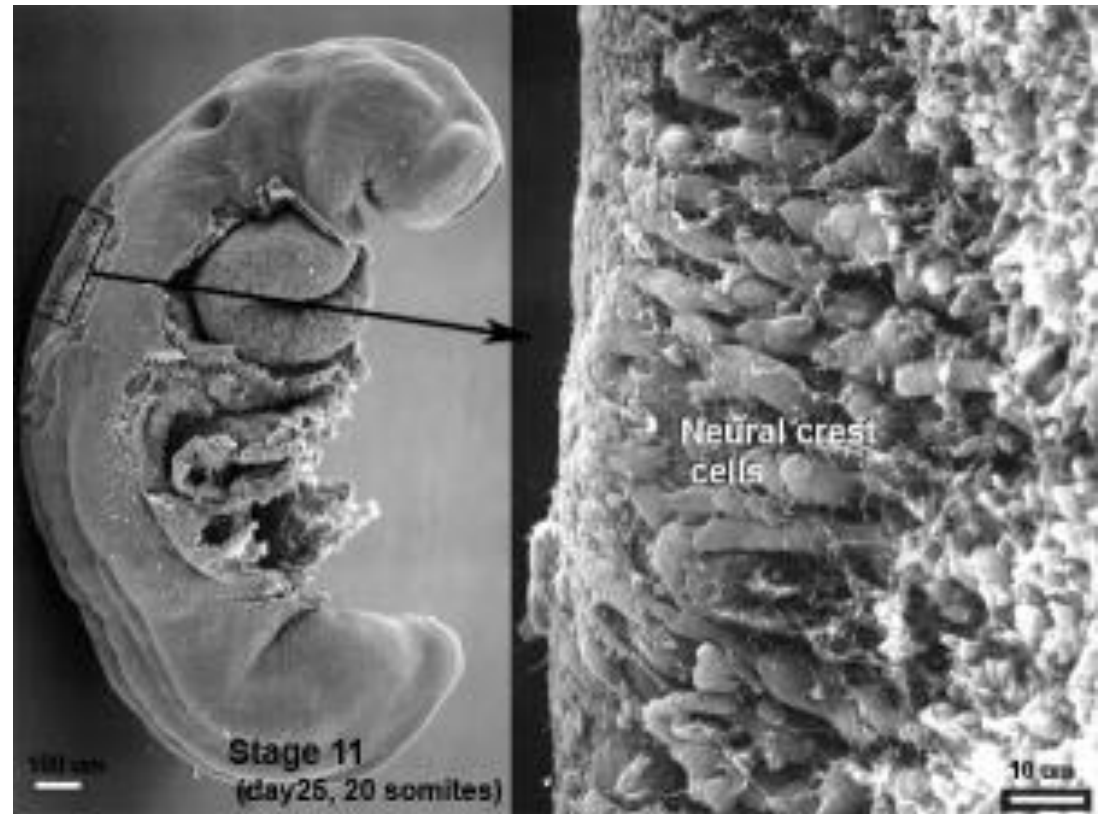
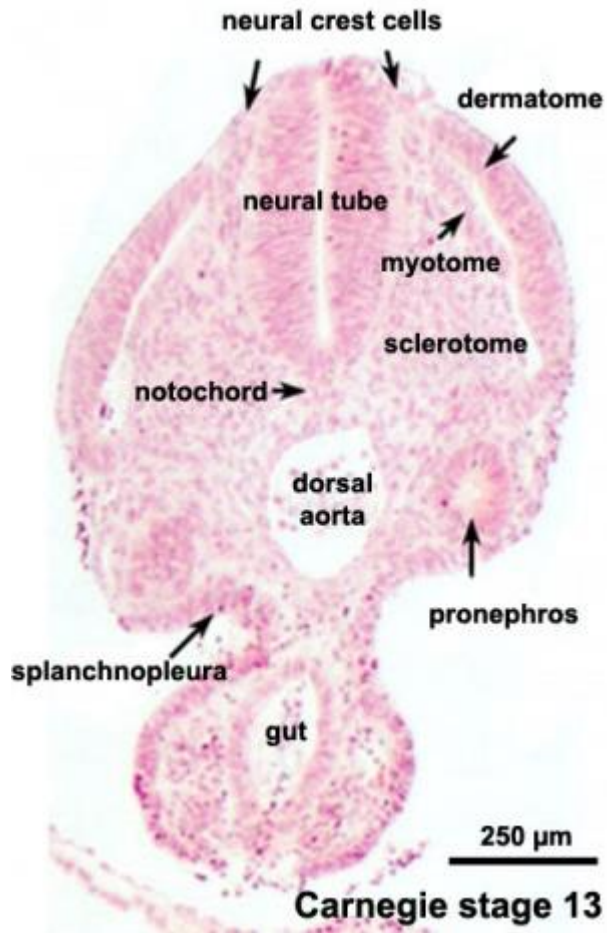


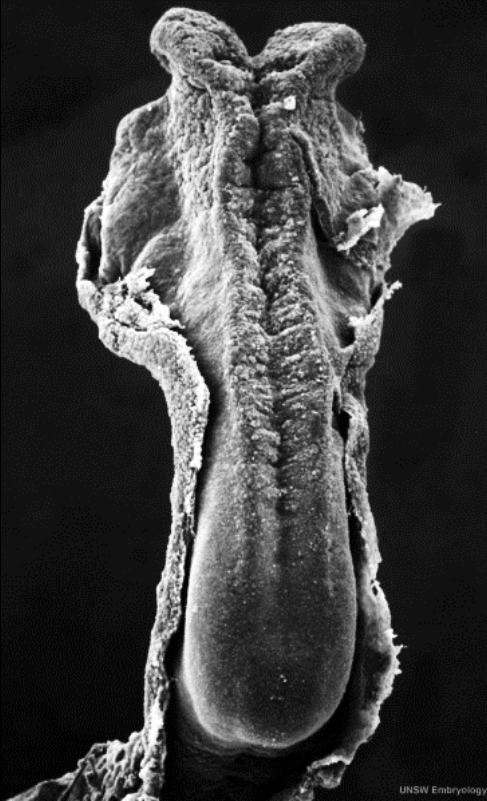Schwann cells



Neurons

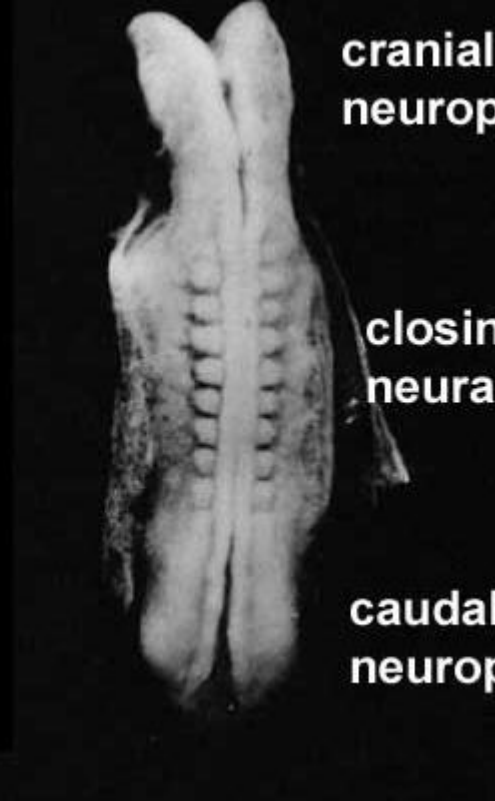
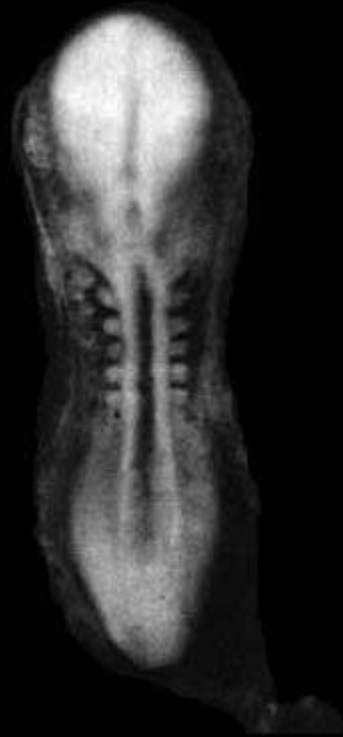NEURULATION





**brain
fold**

**neural
groove**

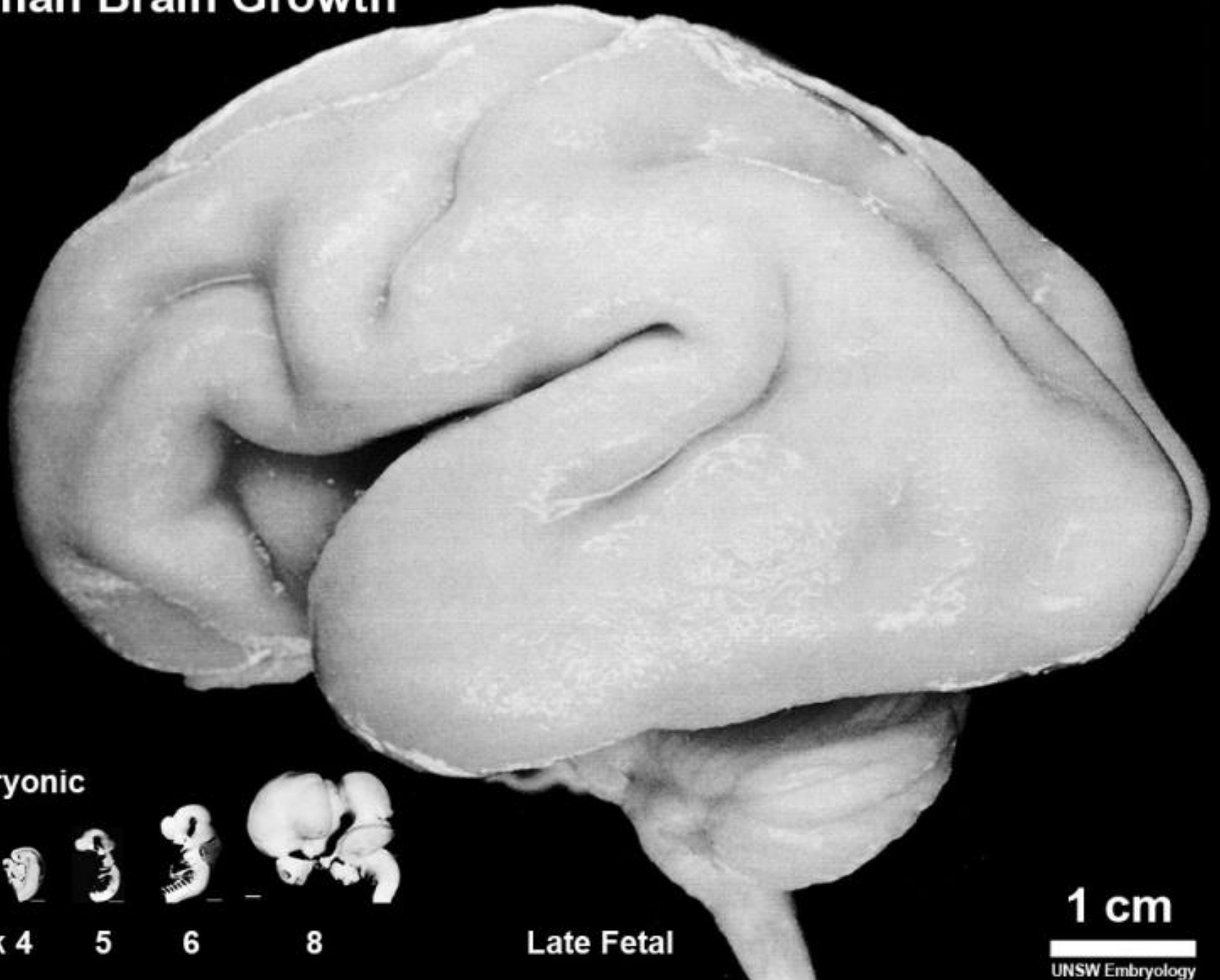


**cranial
neuropore**

**closing
neural tube**

**caudal
neuropore**

Human Brain Growth



Embryonic



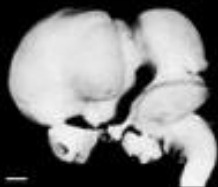Week 4



5



6

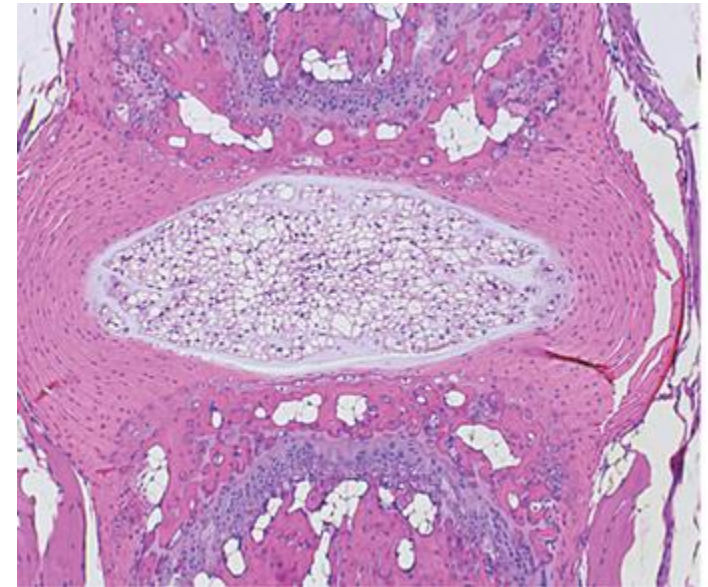
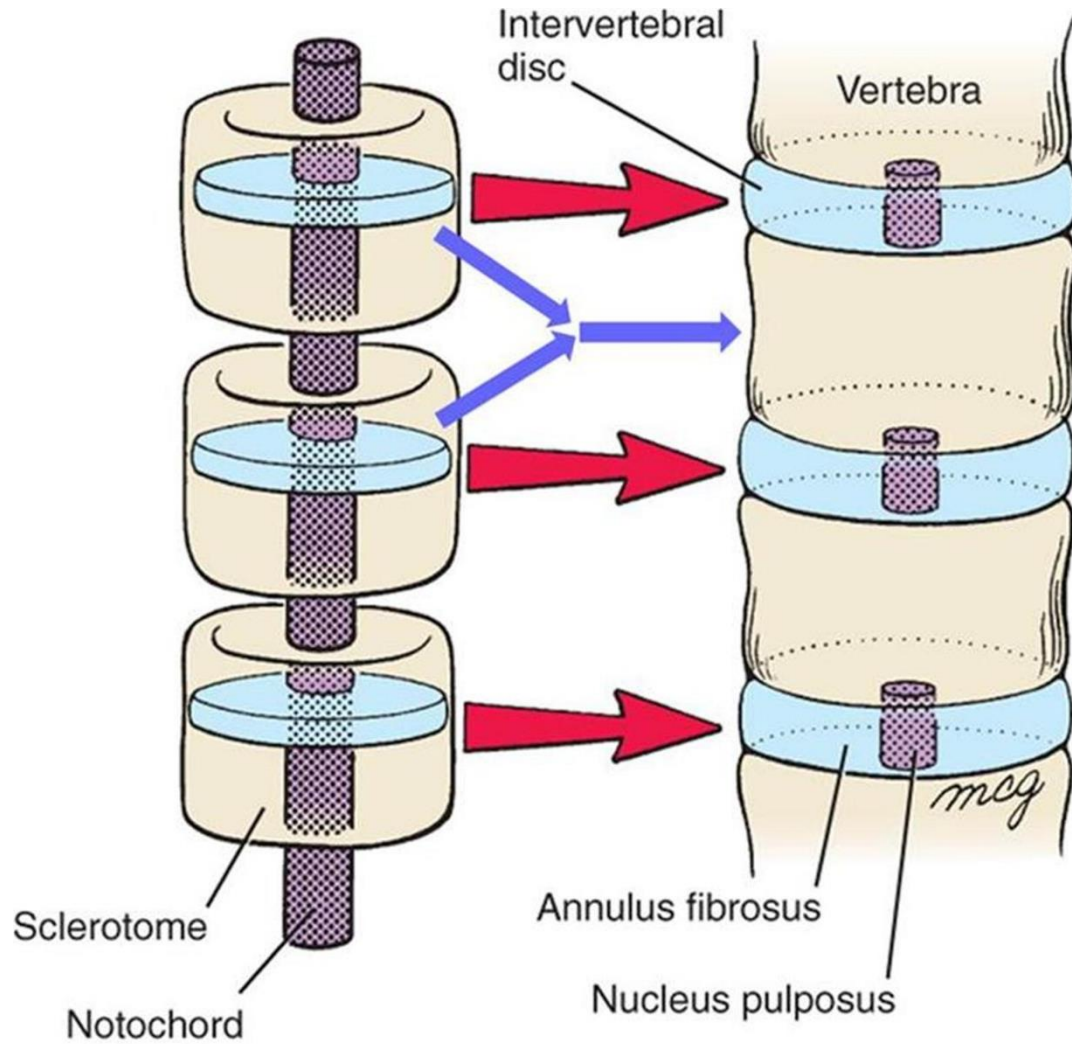


8

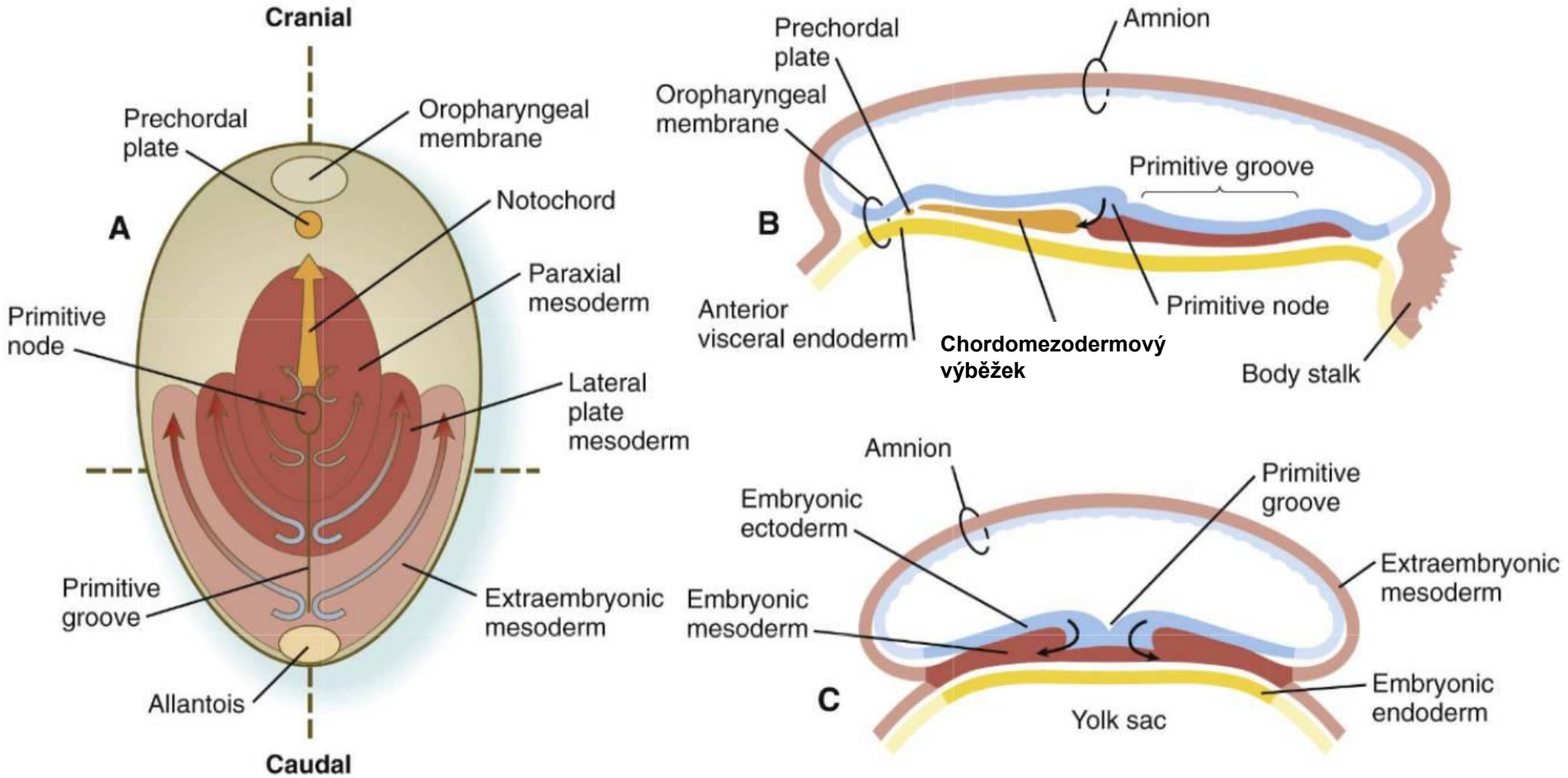
Late Fetal

1 cm

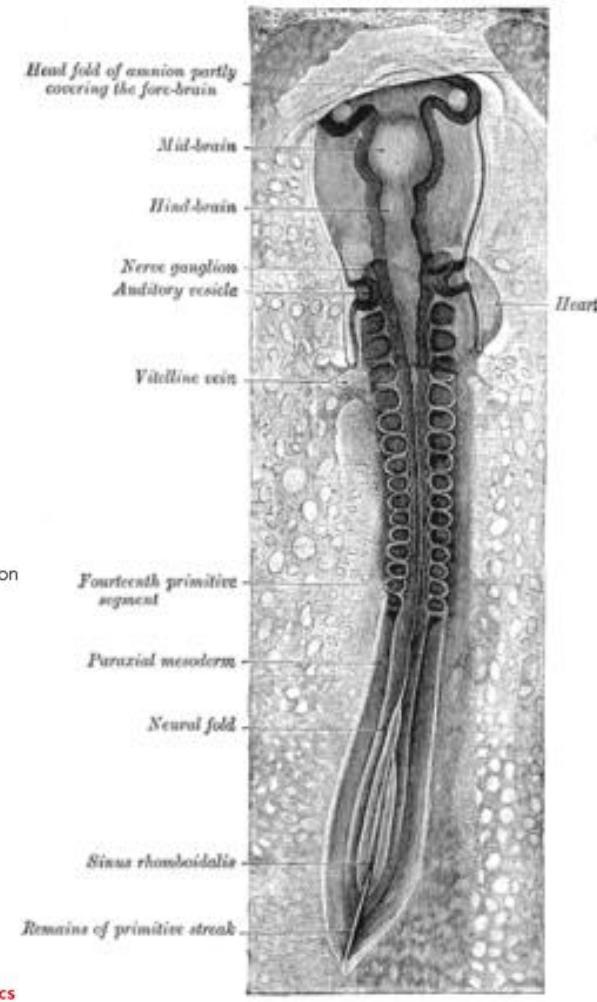
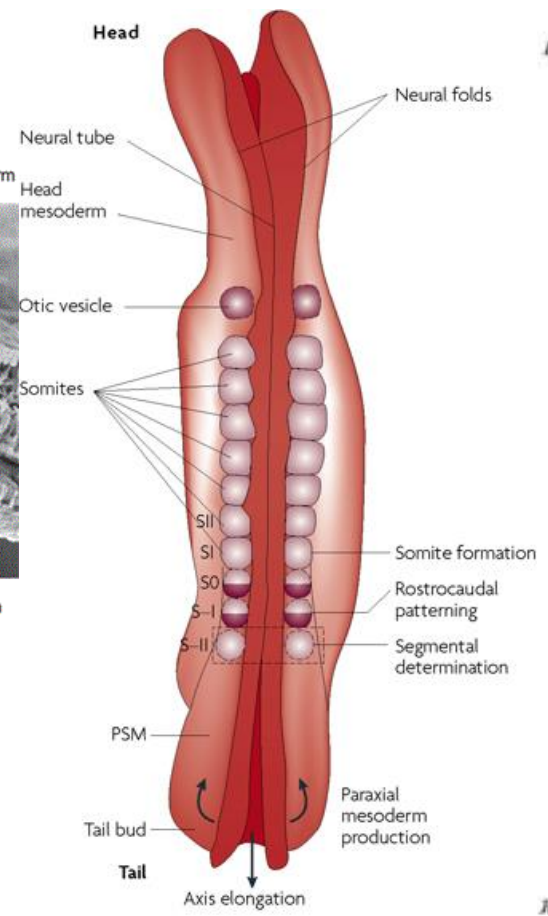
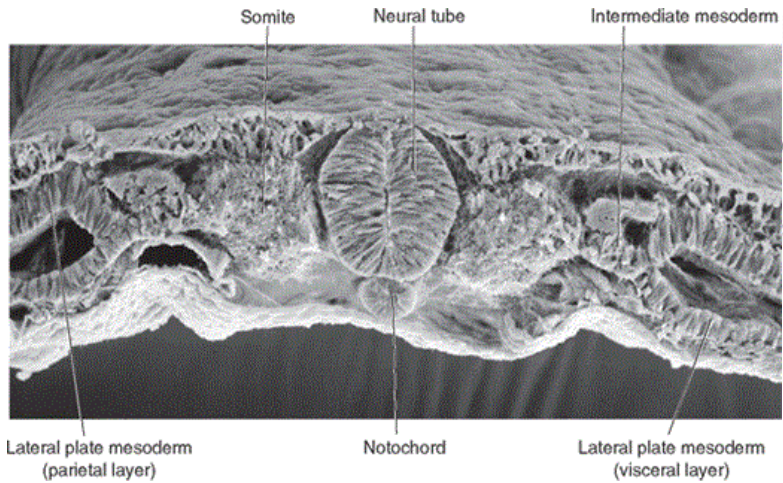
UNSW Embryology

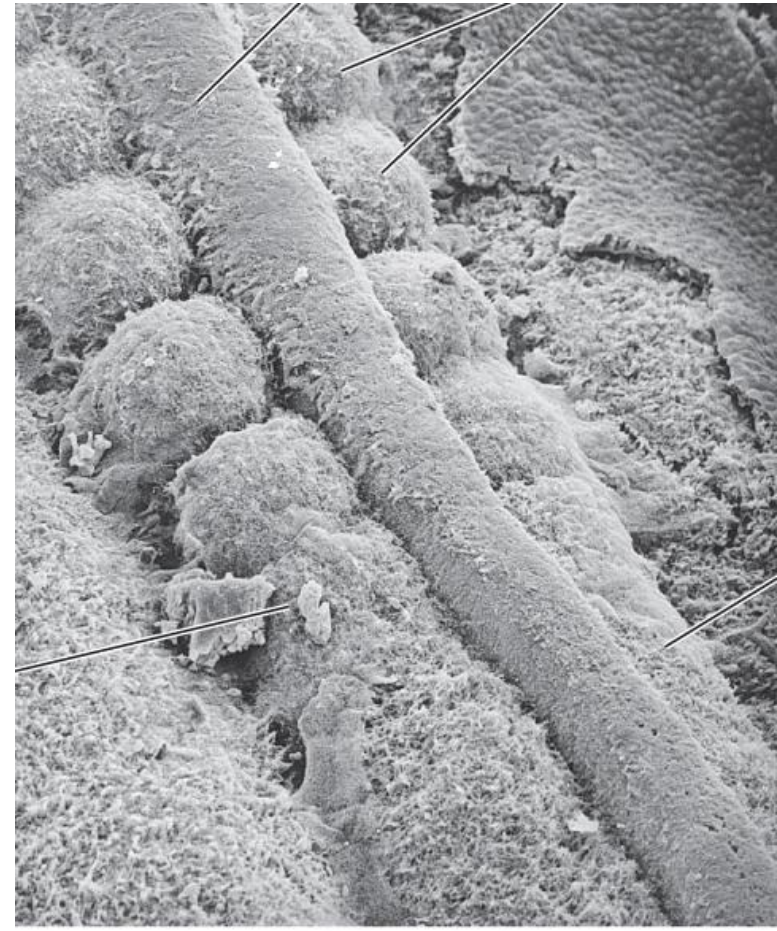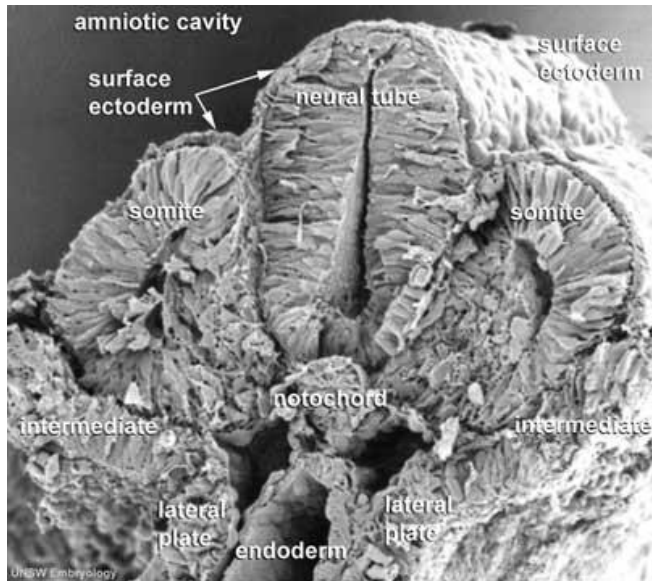
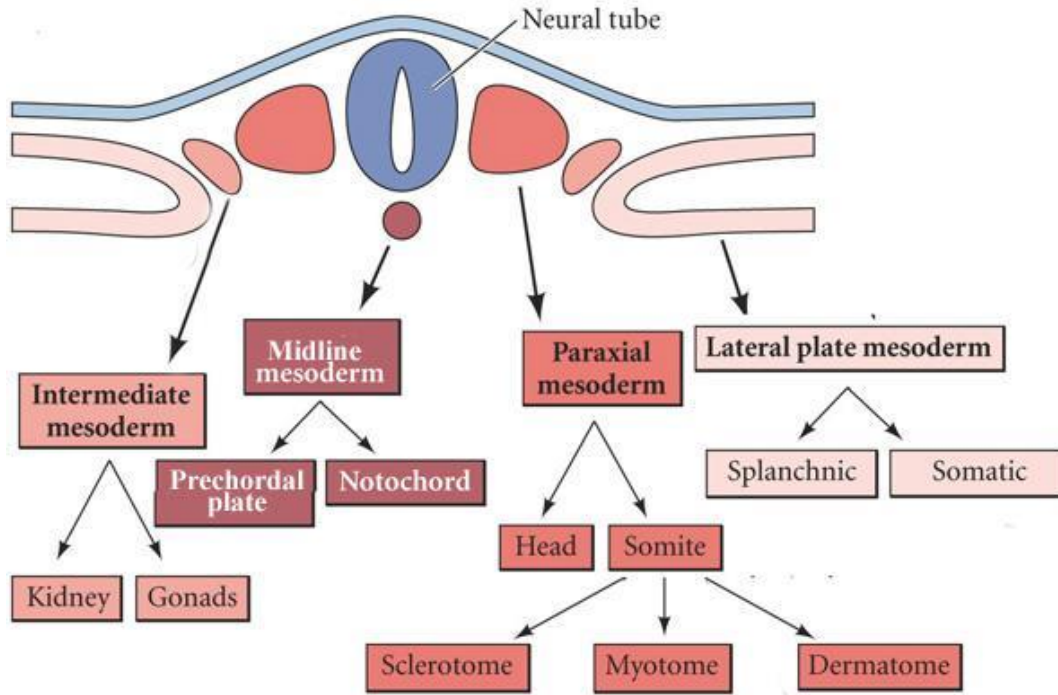


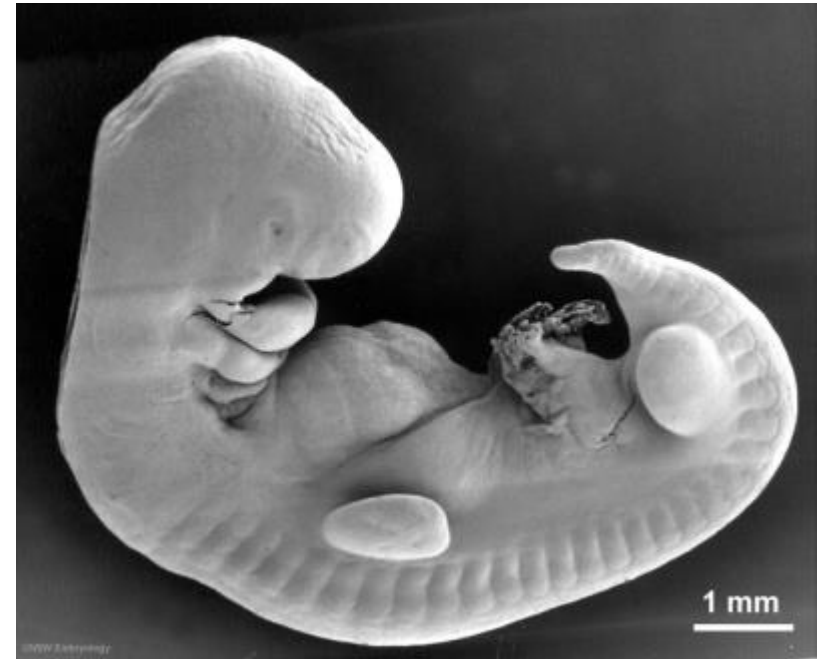
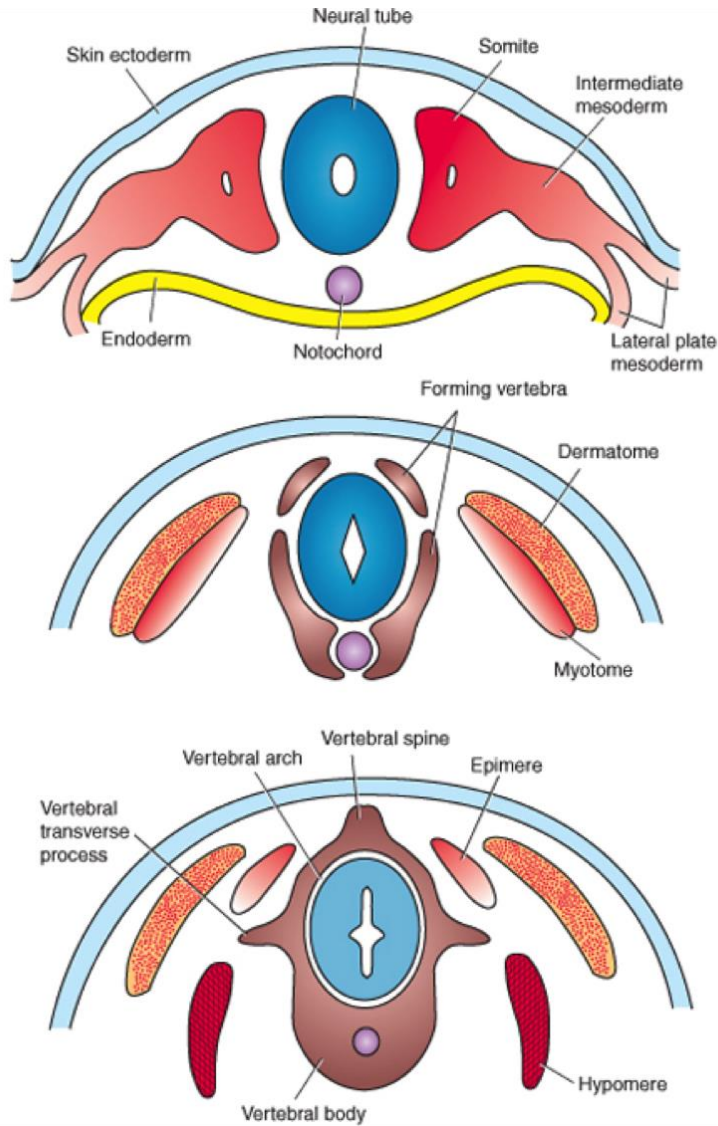
3rd week



3rd – 4th week

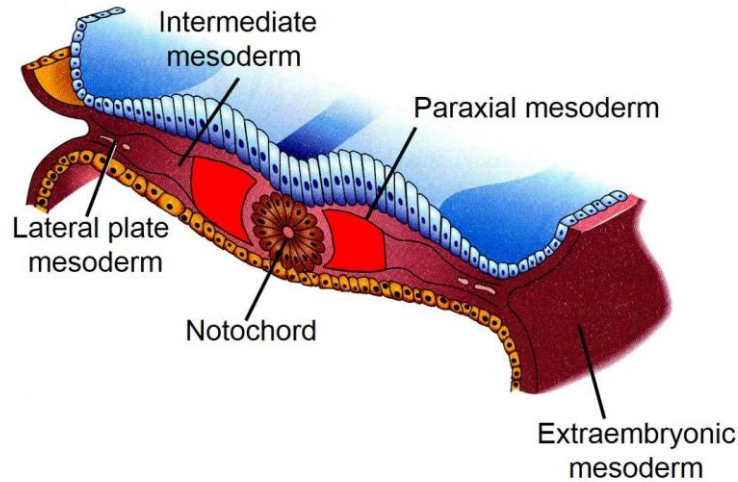




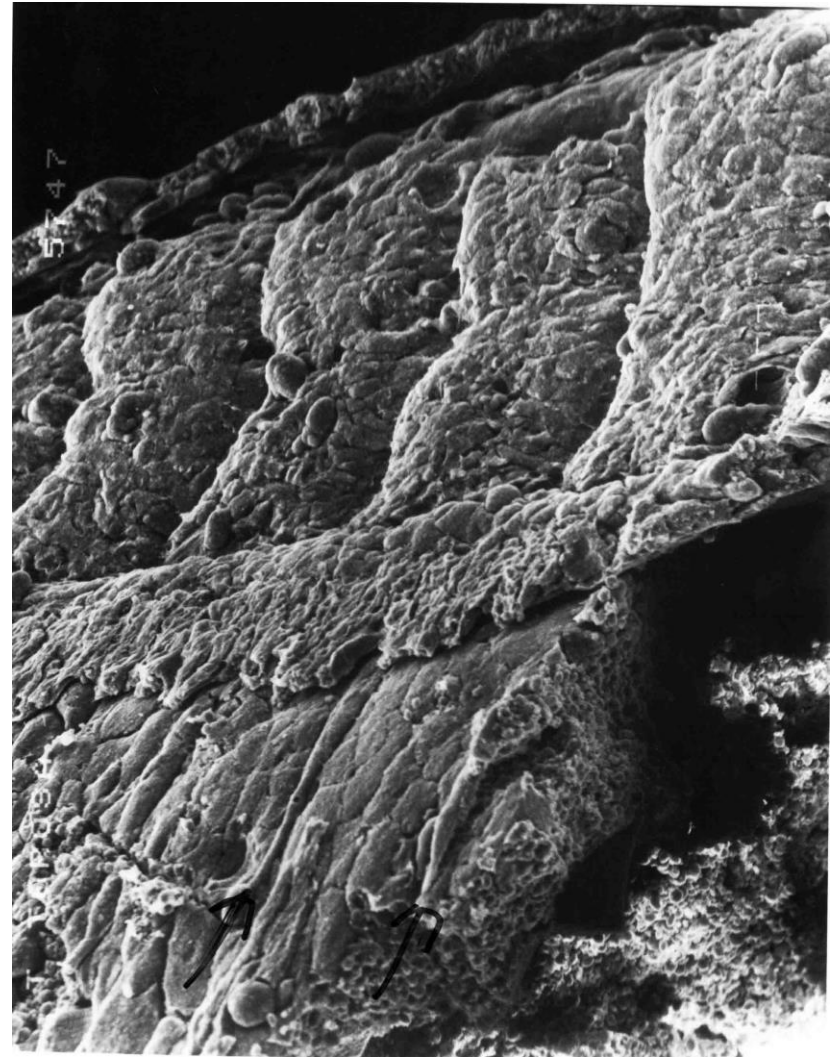


OTHER DERIVATIVES OF MESODERM

3rd – 4th week

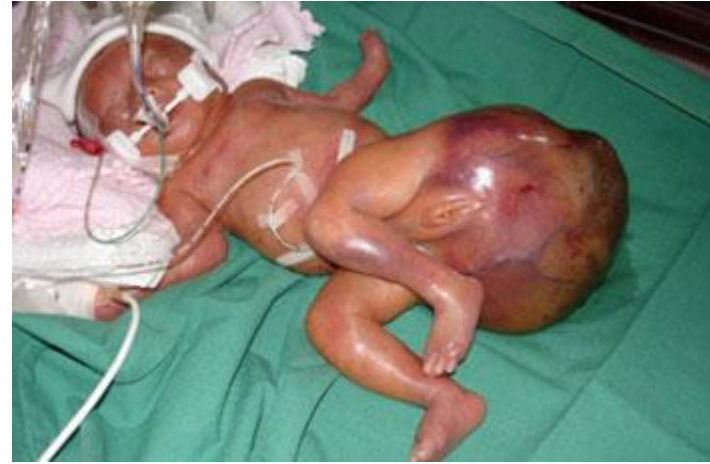
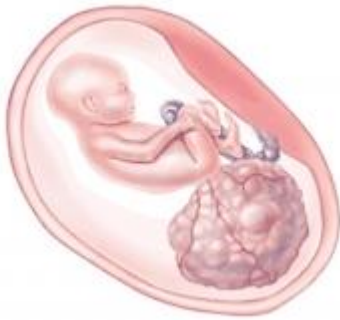
- heart, cardiovascular system
- urogenital system
- muscle and skeletal system
- hematopoietic and lymphatic systems
- connective tissue, dermis
- mesothelium



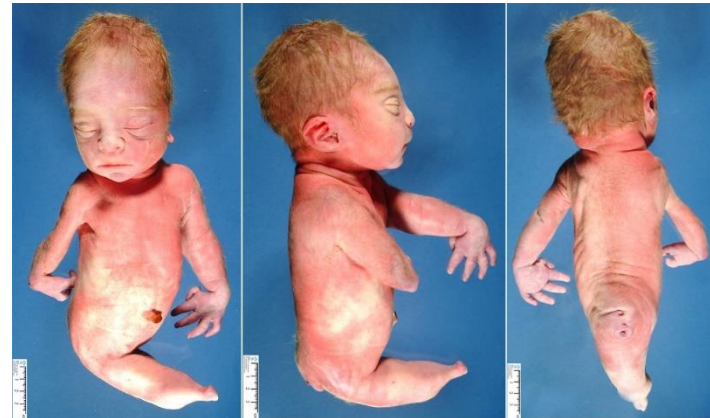DEVELOPMENTAL DISORDERS DURING GASTRULATION

- Primitive streak is a temporary embryonic structure. Persistent primitive streak causes **sacroccocgyeal teratoma**.



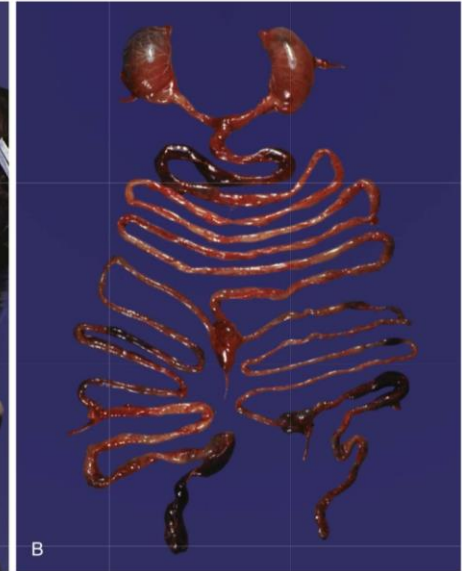
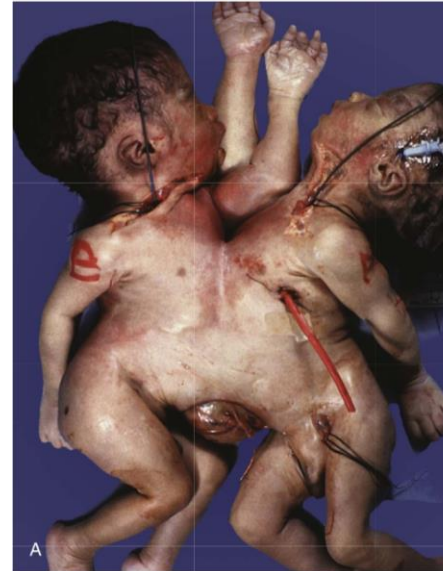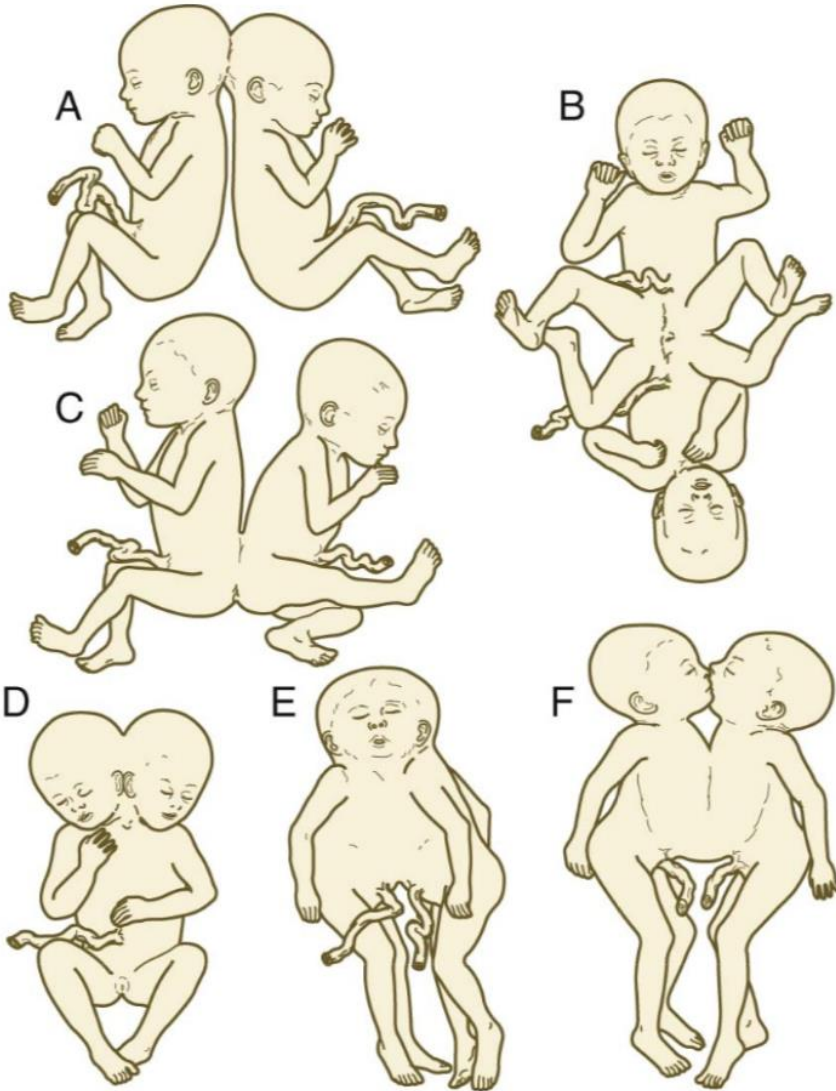
- Failure of primitive streak leads to absence of mesoderm in affected region - **sirenomelia**

- limbs
- urogenital system
- GIT



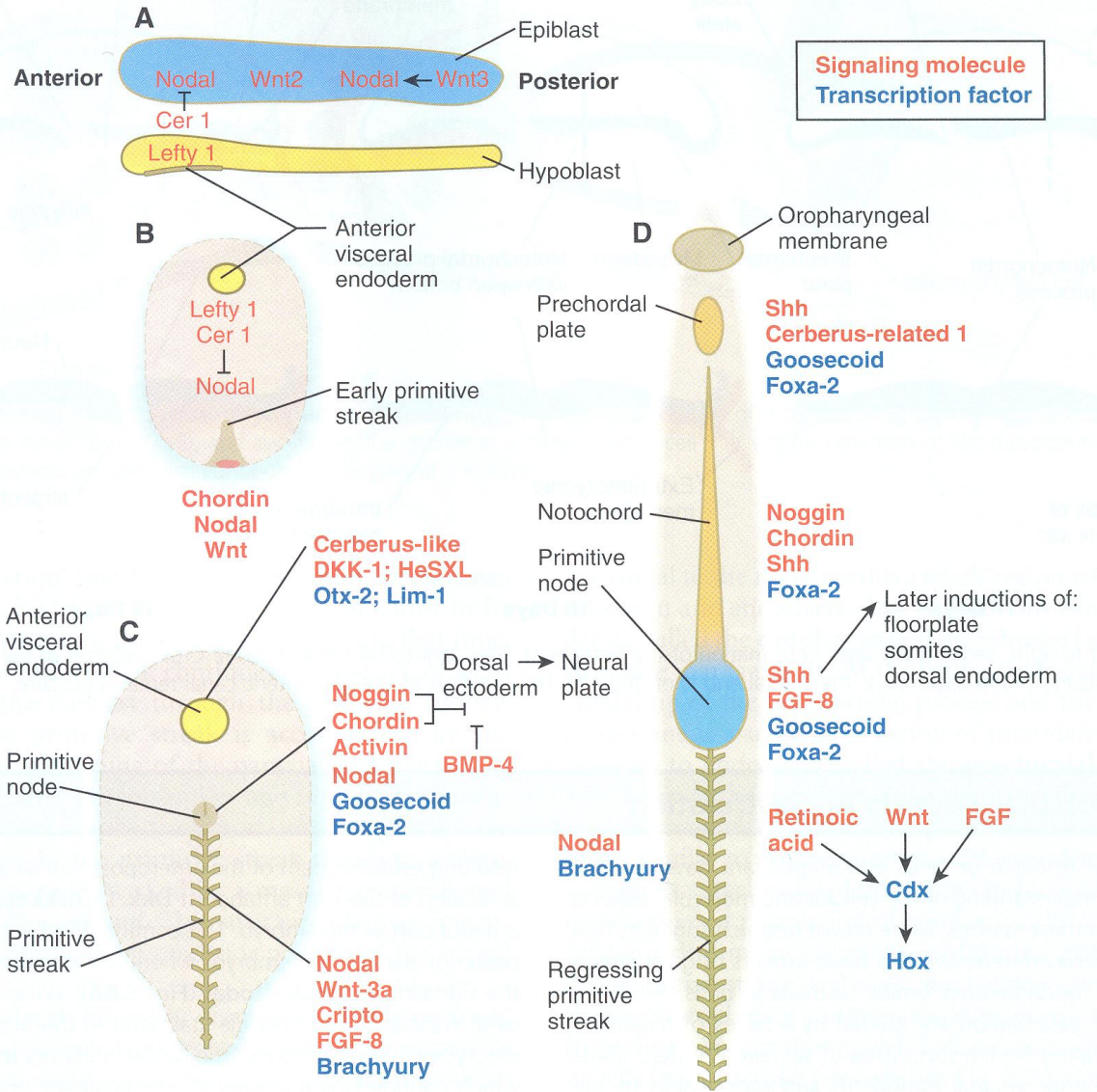
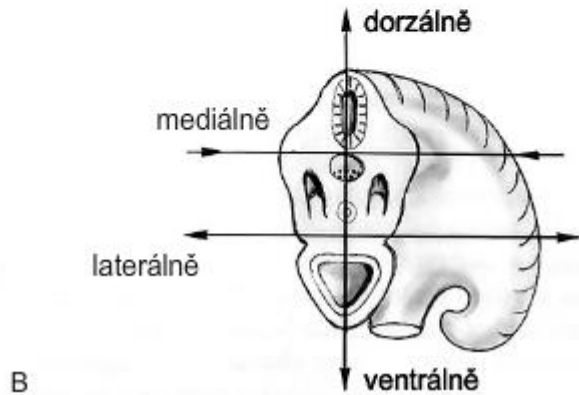
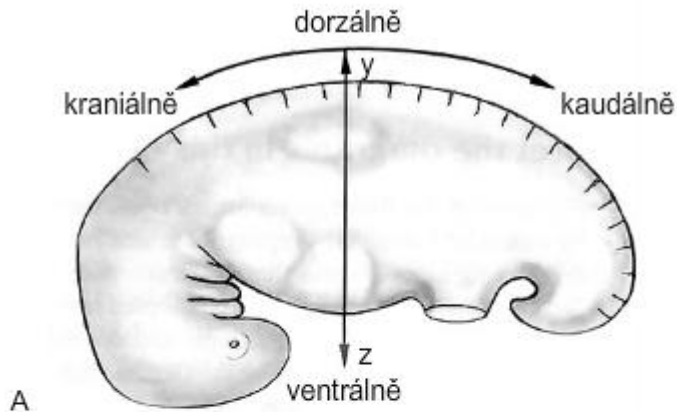
DEVELOPMENTAL DISORDERS DURING GASTRULATION

- If two primitive streaks form, conjoined twins may develop



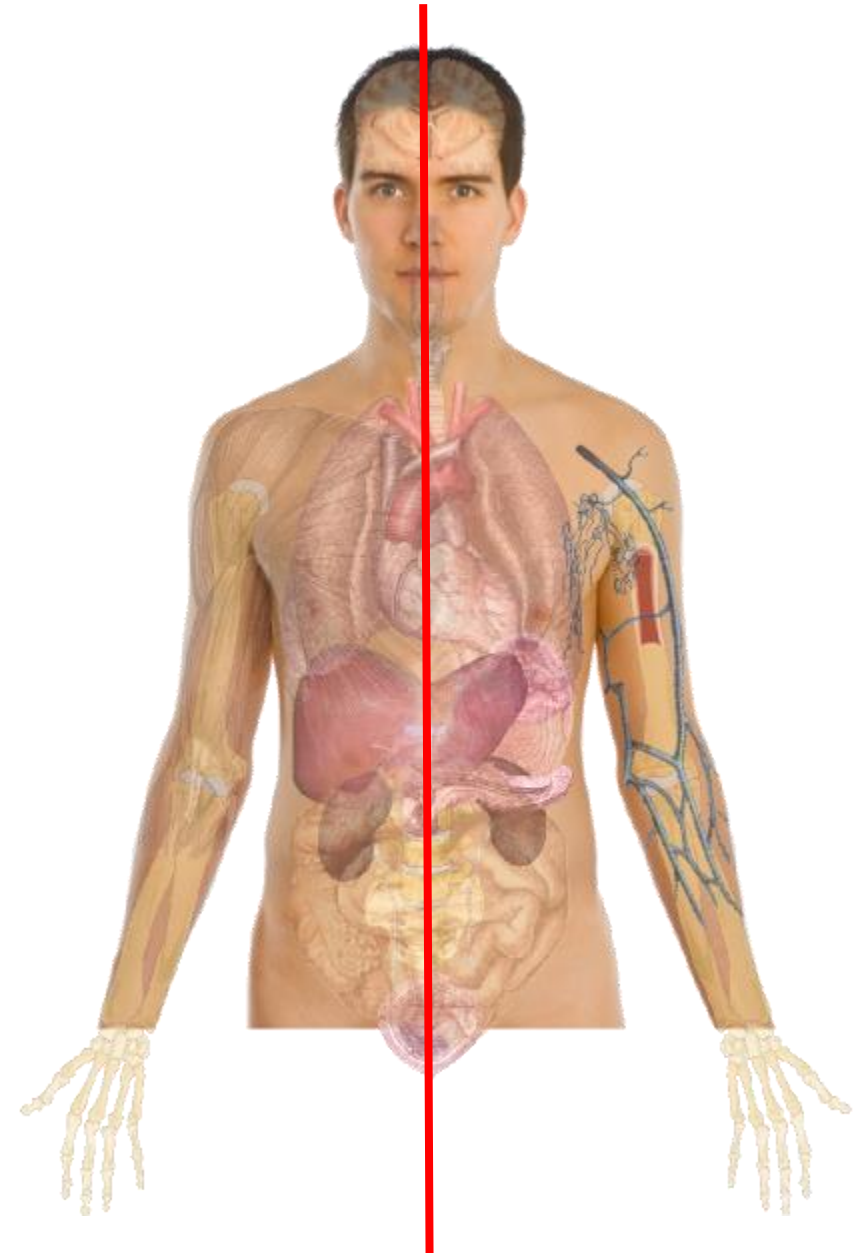
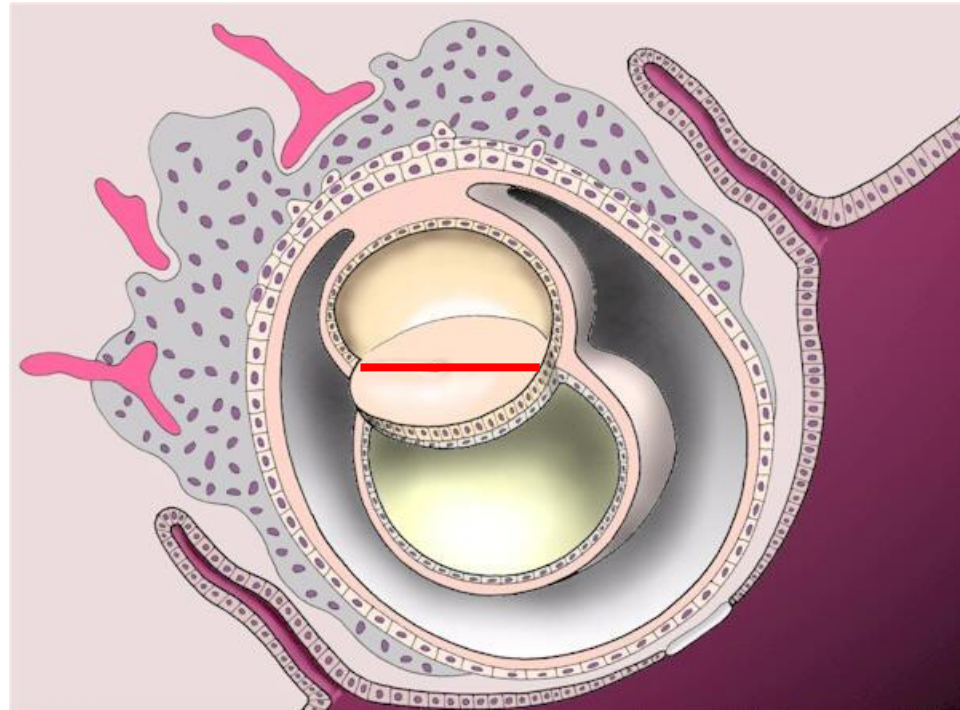
WHAT DETERMINES EMBRYONIC AXES?

3rd week

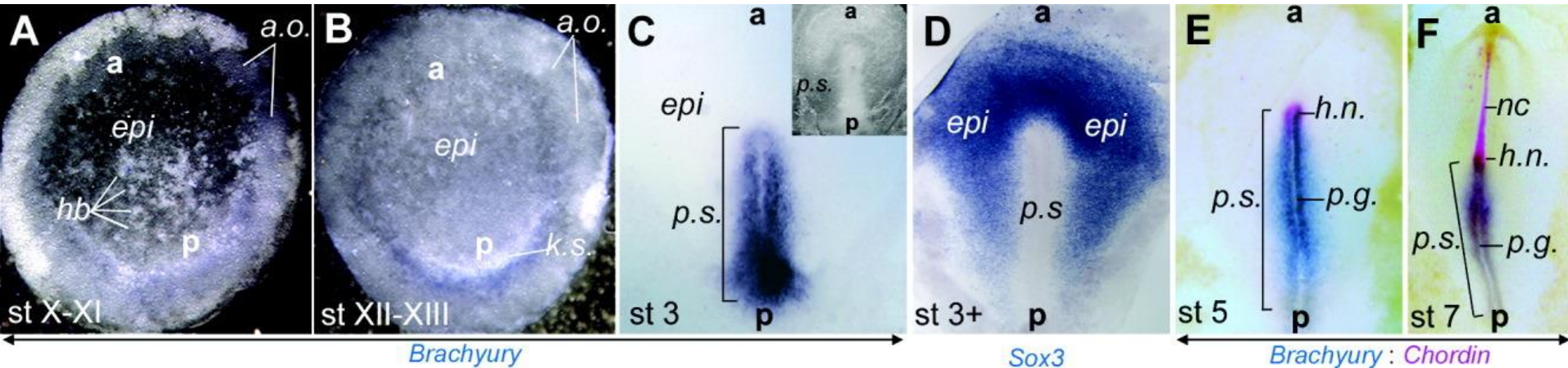


DEVELOPMENT OF LEFT-RIGHT ASSYMETRY

3rd week



CHICK EMBRYO



DEVELOPMENTAL DYNAMICS 229:422-432, 2004

REVIEWS—A PEER REVIEWED FORUM

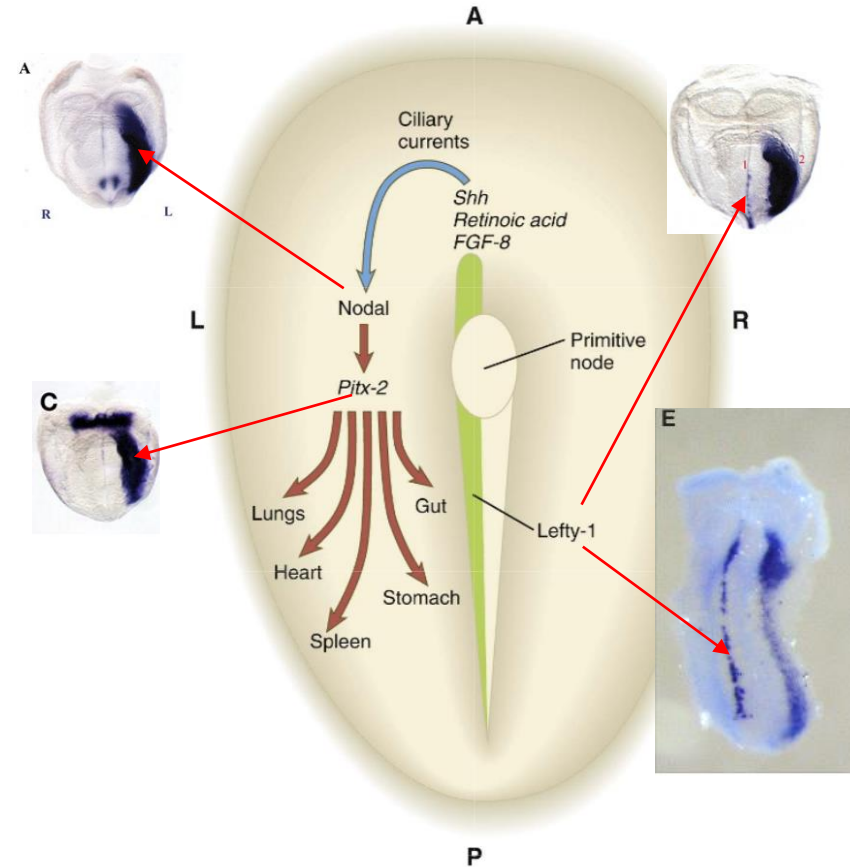
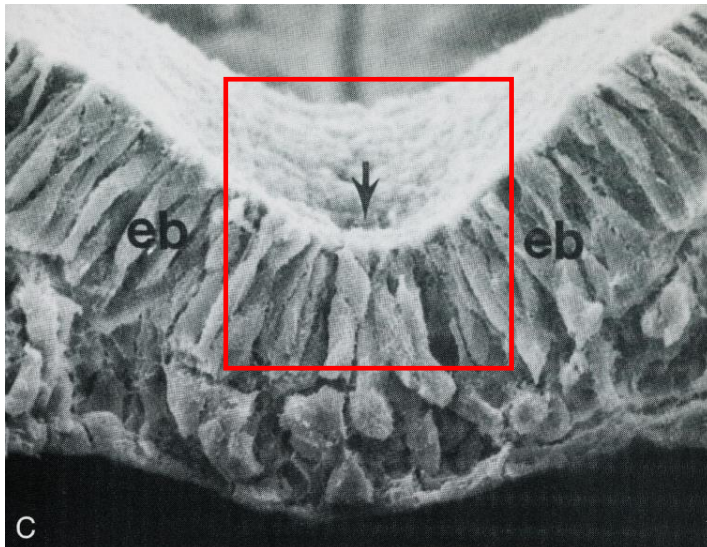
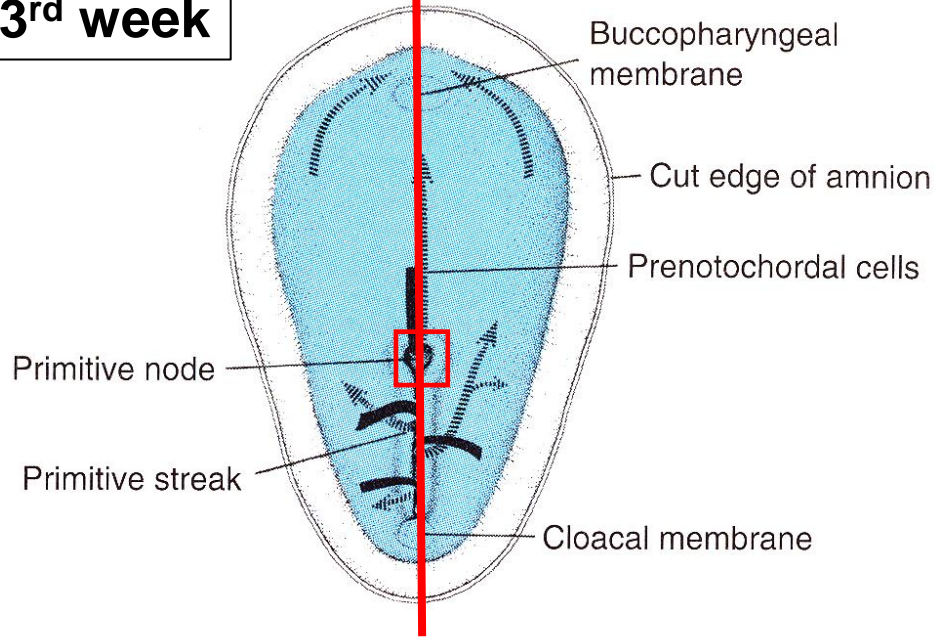
Further reading

Induction and Patterning of the Primitive Streak, an Organizing Center of Gastrulation in the Amniote

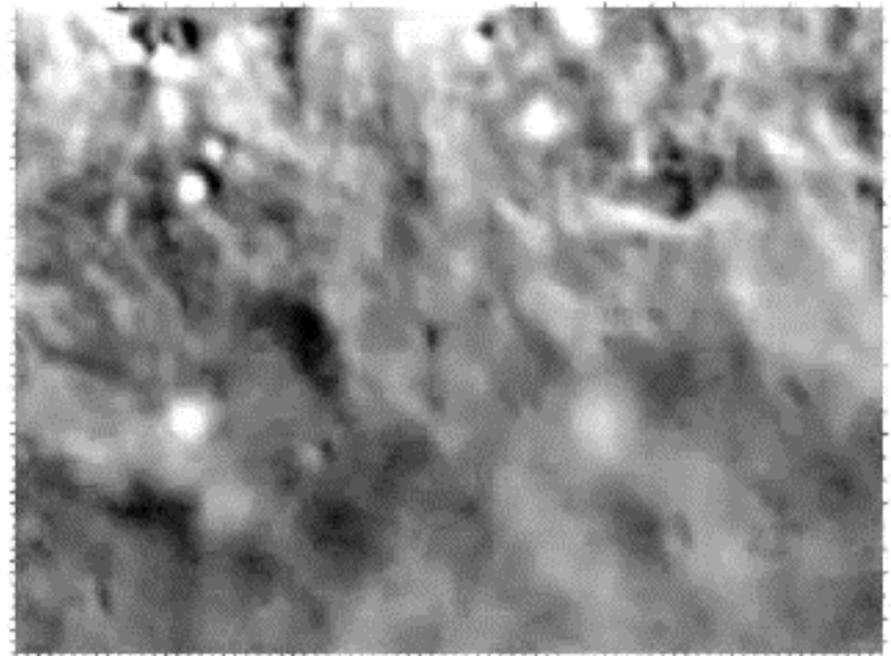

Takashi Mikawa,* Alisa M. Poh, Kristine A. Kelly, Yasuo Ishii, and David E. Reese

DEVELOPMENT OF LEFT-RIGHT ASSYMETRY

3rd week

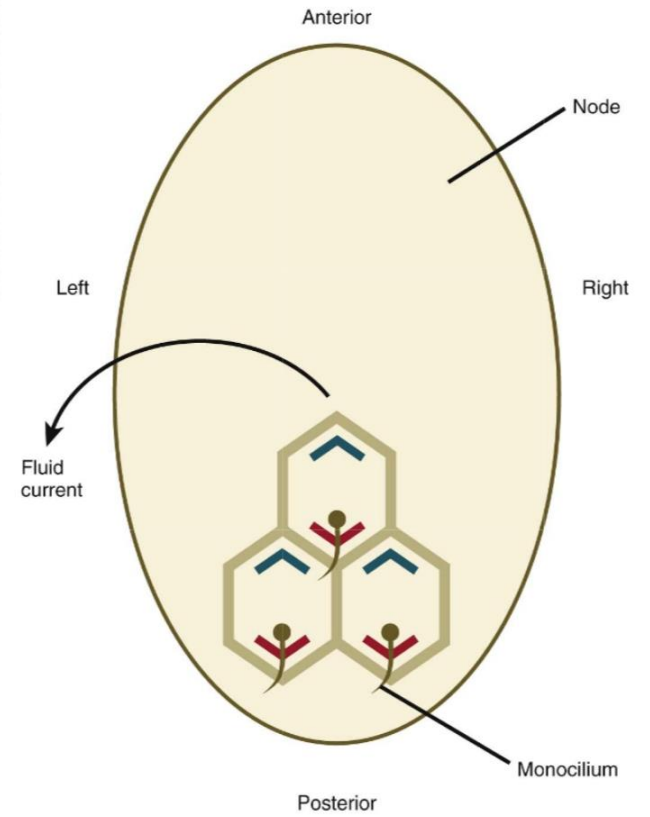
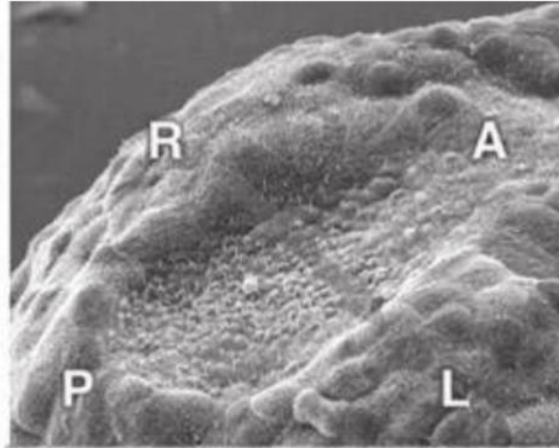
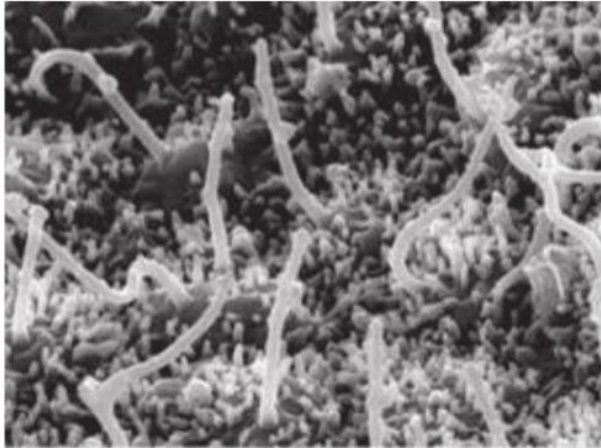

3rd week



DEVELOPMENT OF LEFT-RIGHT ASSYMETRY

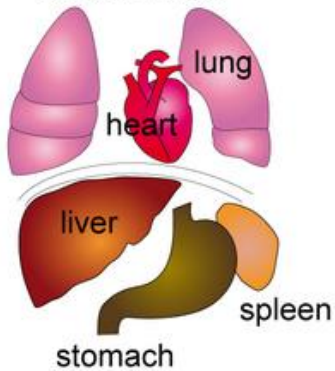
3rd week



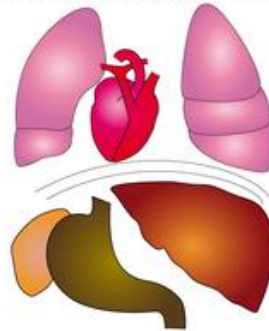
DISORDERS IN AXIS SPECIFICATION LEAD TO MALFORMATIONS

- situs inversus (1:10 000) × situs solitus
- heterotaxia (situs ambiguus)
- dextrocardia
- isomerism

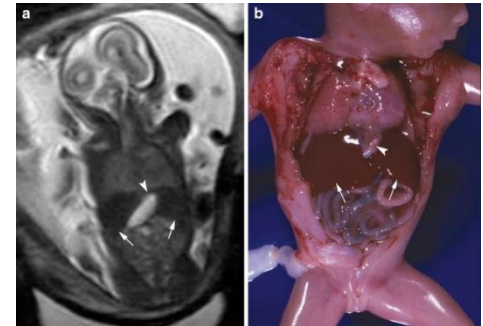
situs solitus



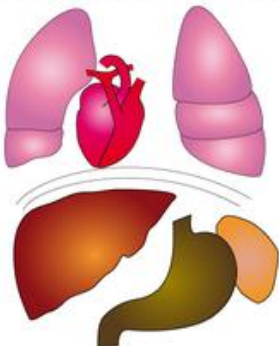
situs inversus totalis



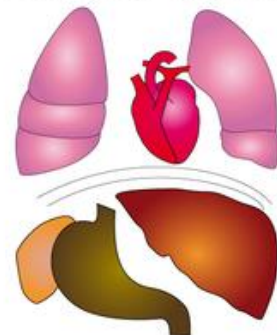
left isomerism (polysplenia)



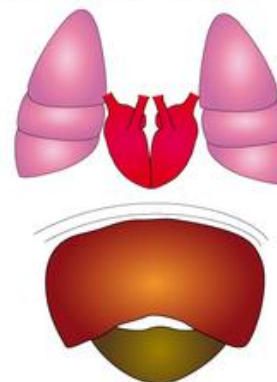
situs inversus thoracalis



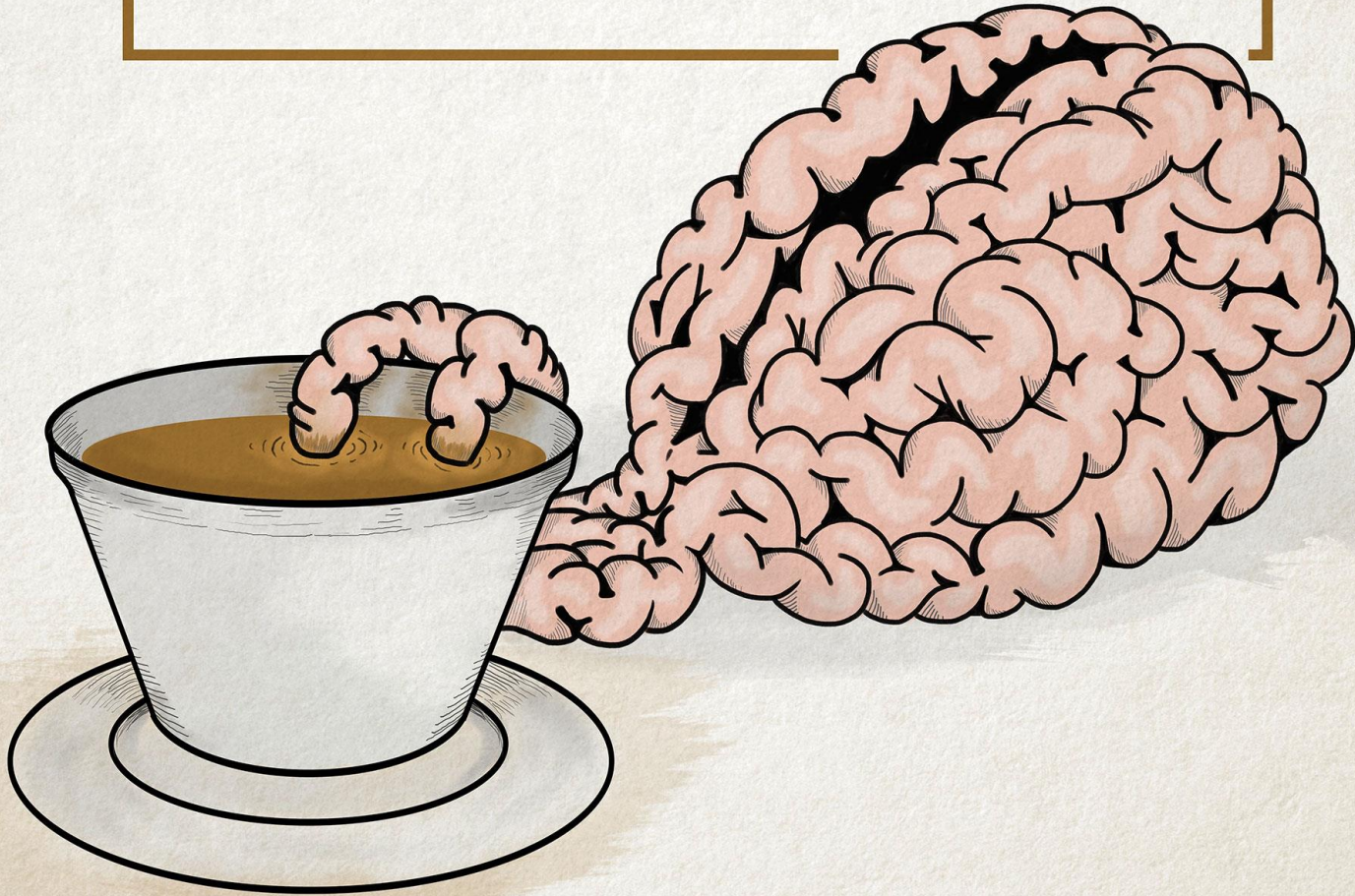
situs inversus abdominalis



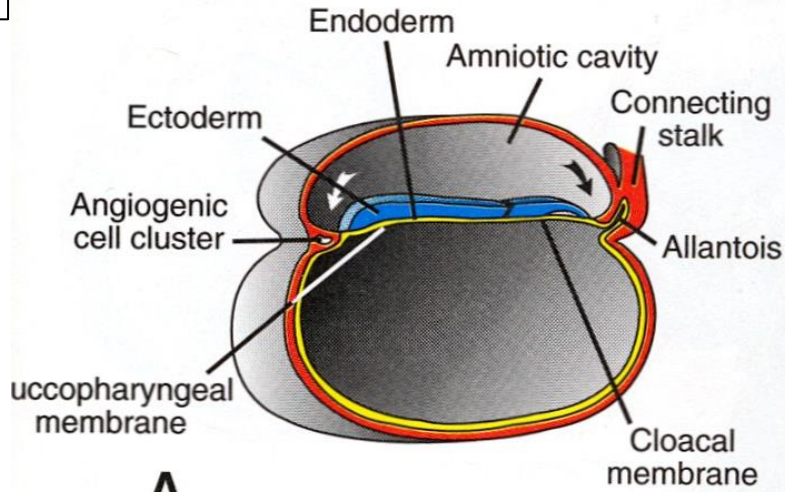
right isomerism (asplenia)



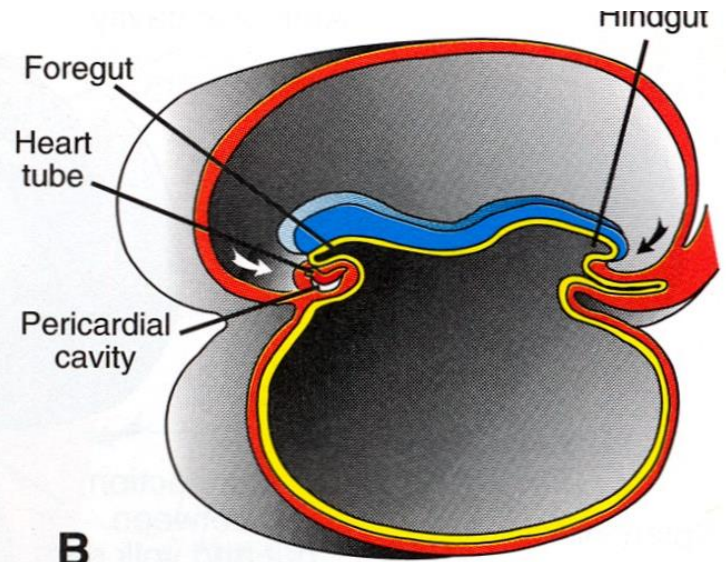
COFFEEBREAK



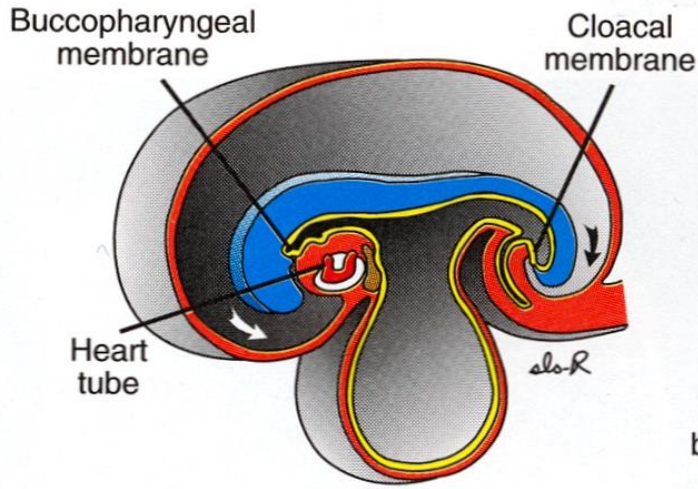
4th week



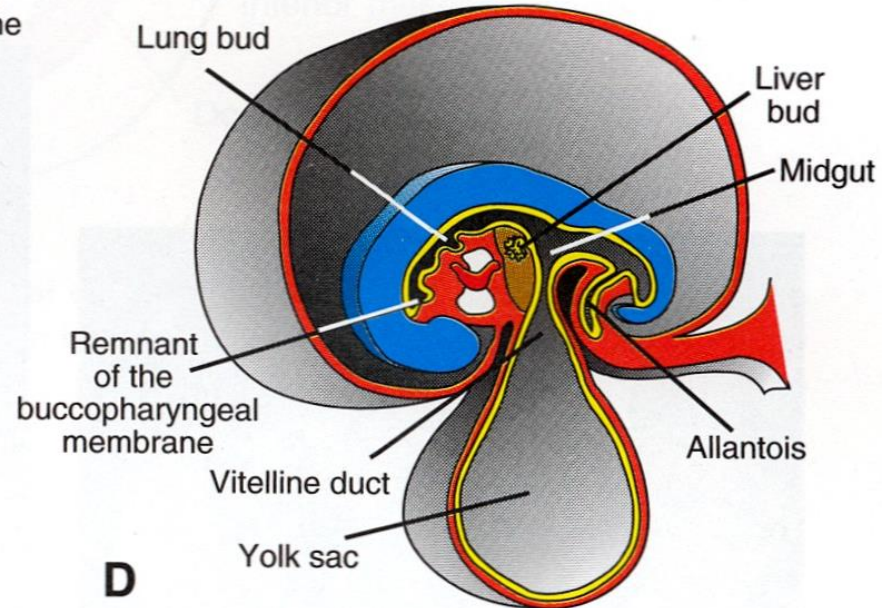
A



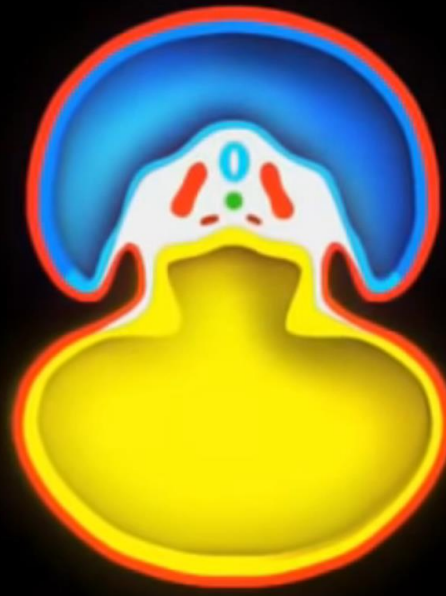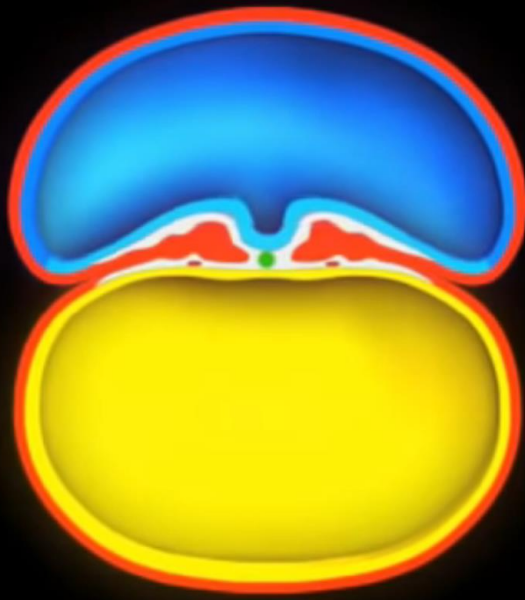
B

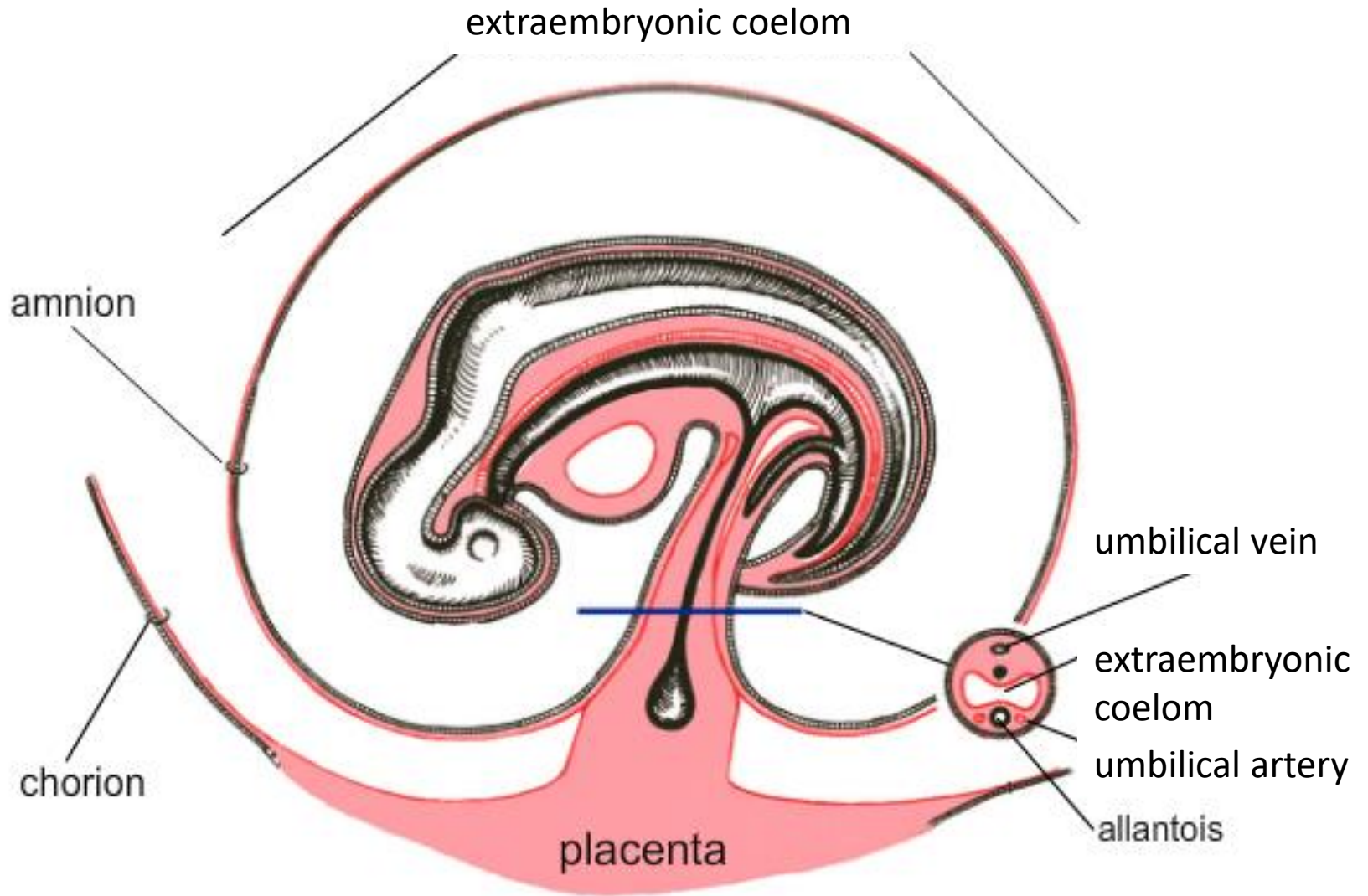


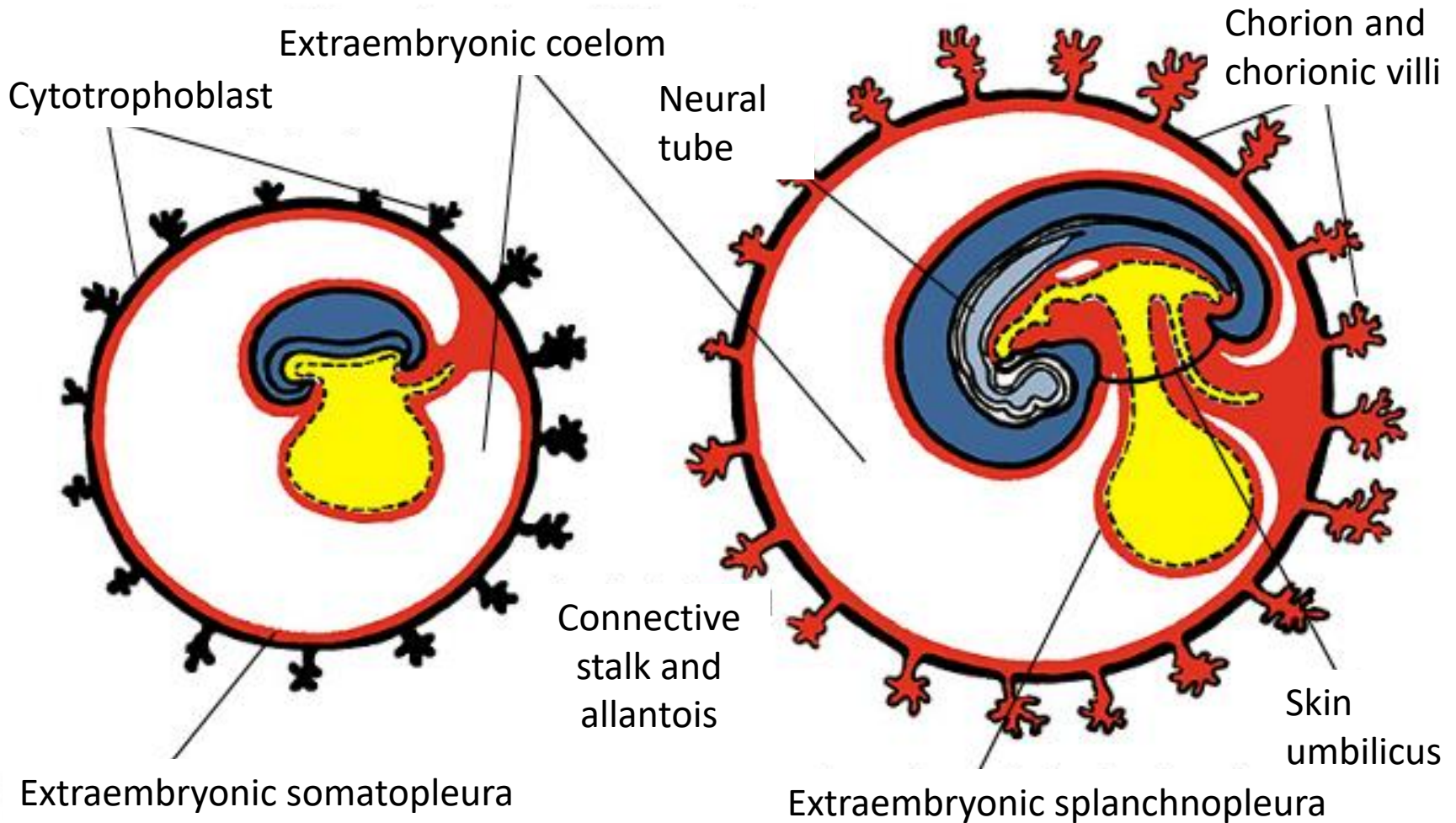
C



D

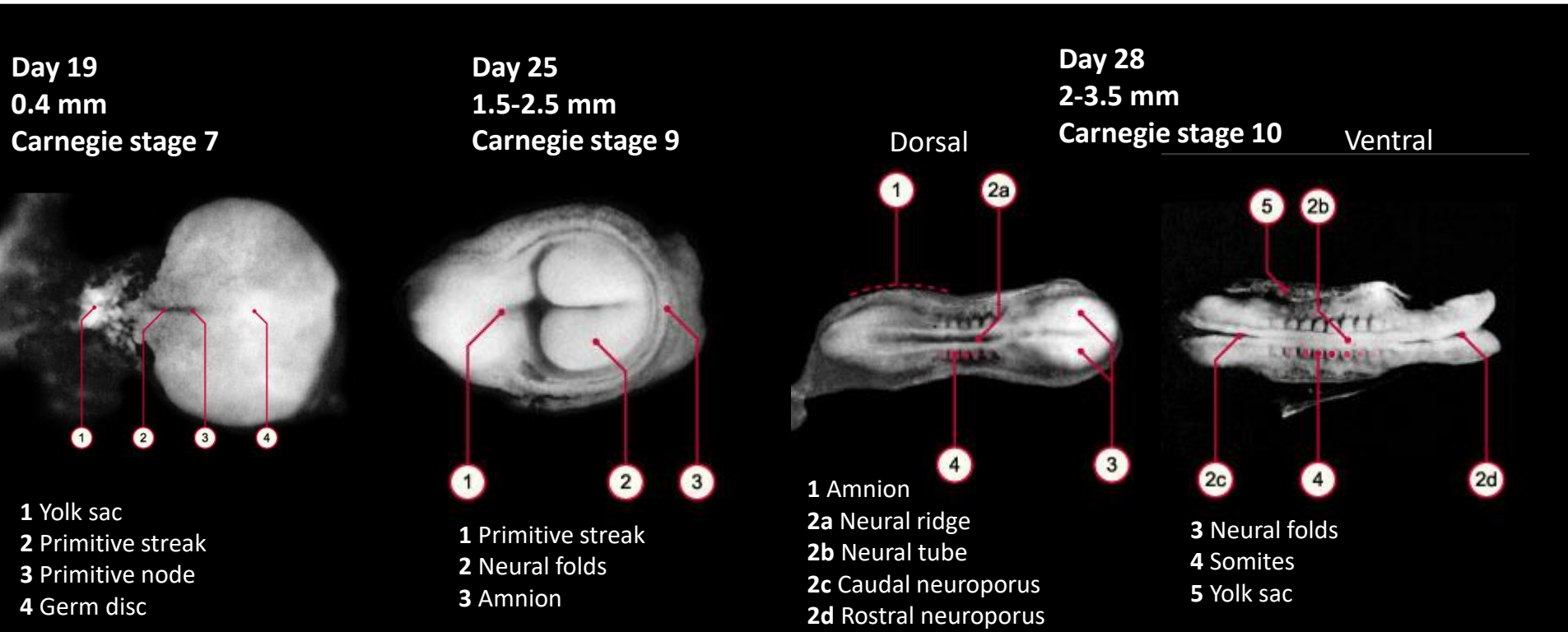


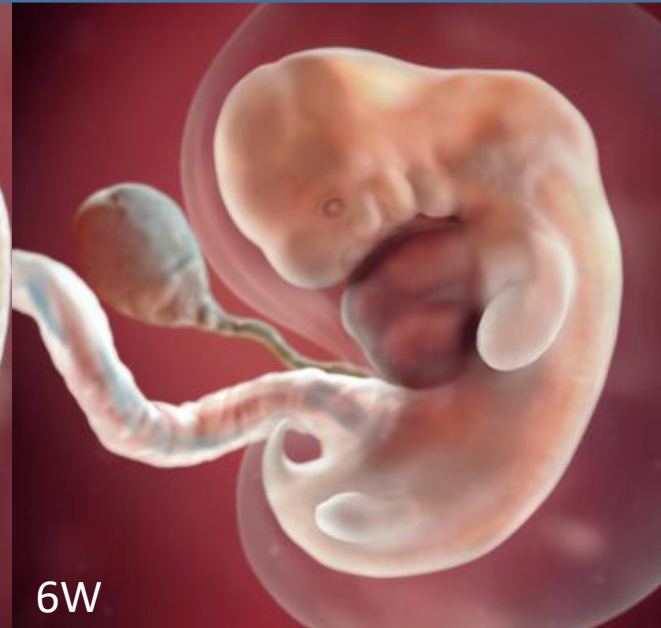
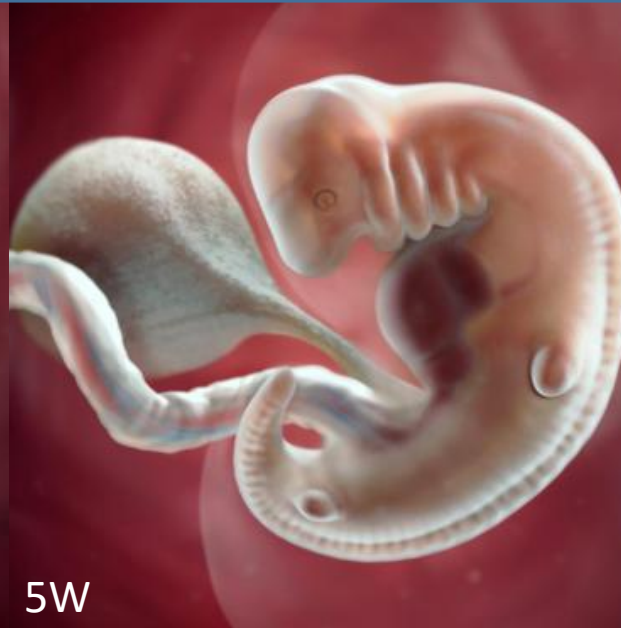
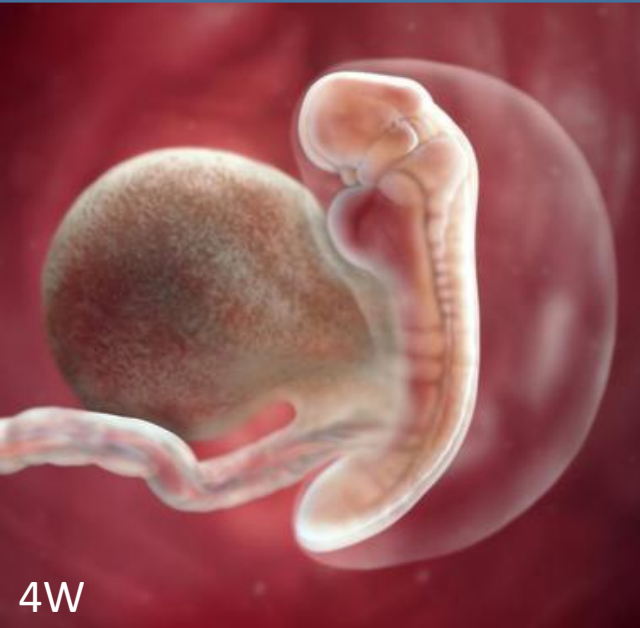

- bilaminar → trilaminar germ disc
- cephalocaudal and lateral flexion of embryo

<http://www.embryology.ch/anglais/iperiodeembryo/carnegie03.html#st710>





4W

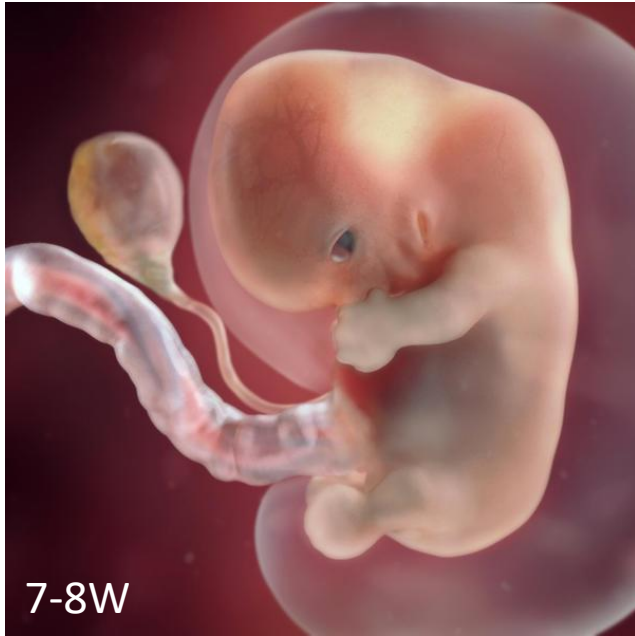5W

6W

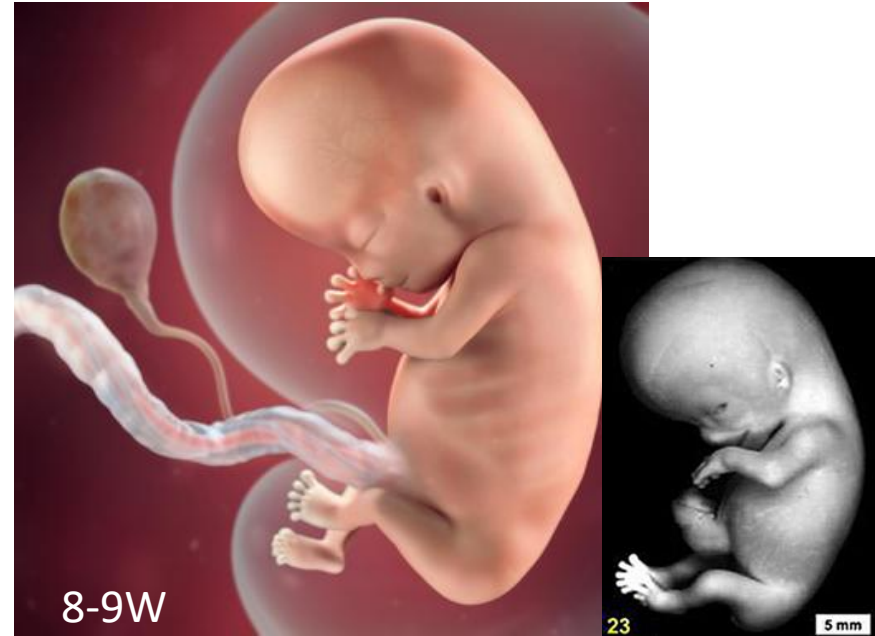- Mesoderm segmentation
- Primitive gut
- Esophagotracheal diverticulum
- Heart (starts beating day 22-23)
- Limb buds
- Primary brain vesicles, closing of neuropores
- Differentiation of neural crest
- Origin of thyroid and anterior pituitary
- Ectodermal placodes, optic vesicle
- Liver diverticulum
- Septum transversum

- Segmentation of mesoderm continues
- Posterior pituitary
- Heart septation begins
- Lung buds branch - pseudoglandular stage of lung development
- Cochlea grows
- Lens vesicle, nasal placodes
- Fourth brain ventricle forms
- Pharyngeal arches, ridges and pouches
- Limb buds grow
- Hematopoiesis in liver
- Retinal pigment

- Derivatives of endodermal pharyngeal pouches (parathyroid, thymus)
- Adrenal gland
- Heart and lungs descended to thorax
- Innervation of limbs, differentiation of myoblasts
- Face development – maxillary and mandibular processes, palatine, choans
- Telencephalon stratifies – archicortex, paleocortex and neocortex. Choroid plexus
- Rotation of stomach
- Pancreatic diverticula fuse

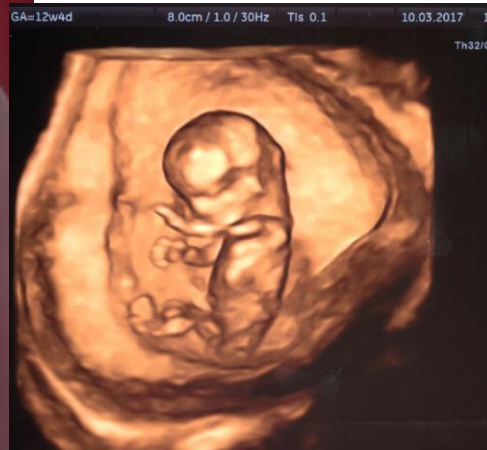
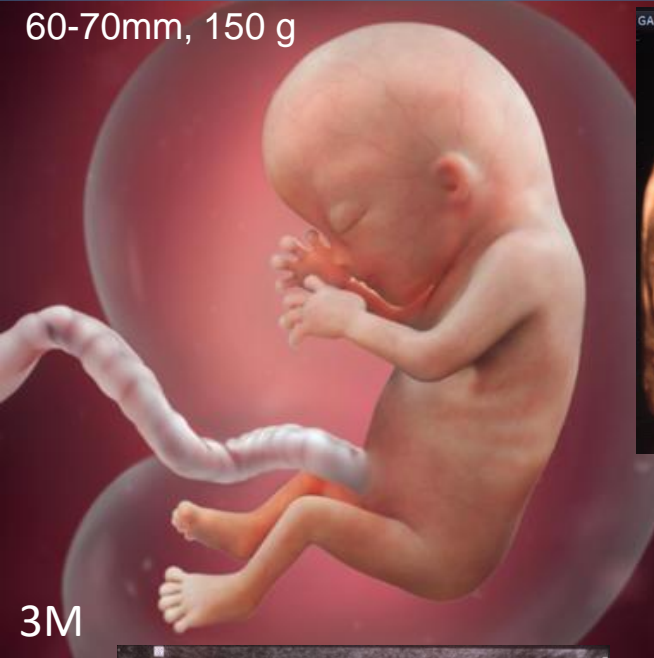
- Secretion from endocrine pancreas
- Growth of liver, growth and luminization of bile ducts
- Ossification of limbs begin
- Development of brain nuclei

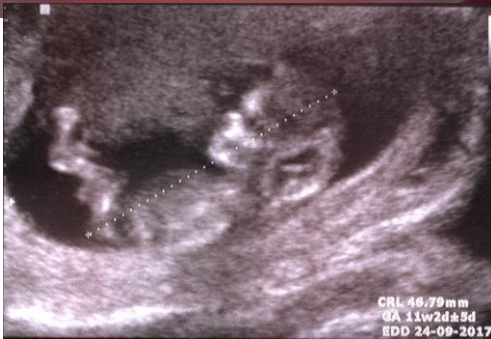

- Joints of upper and later lower limbs allow rotation
- Fingers grow
- Stratification of cerebellar cortex
- Perforation of anal membrane
- Herniation of intestinal loops
- Testes produce testosterone
- Nose, meatus, eyelids, developer, external ears start to grow
- Backbone - 33-34 cartilaginous vertebrae
- Embryonic tail diminished

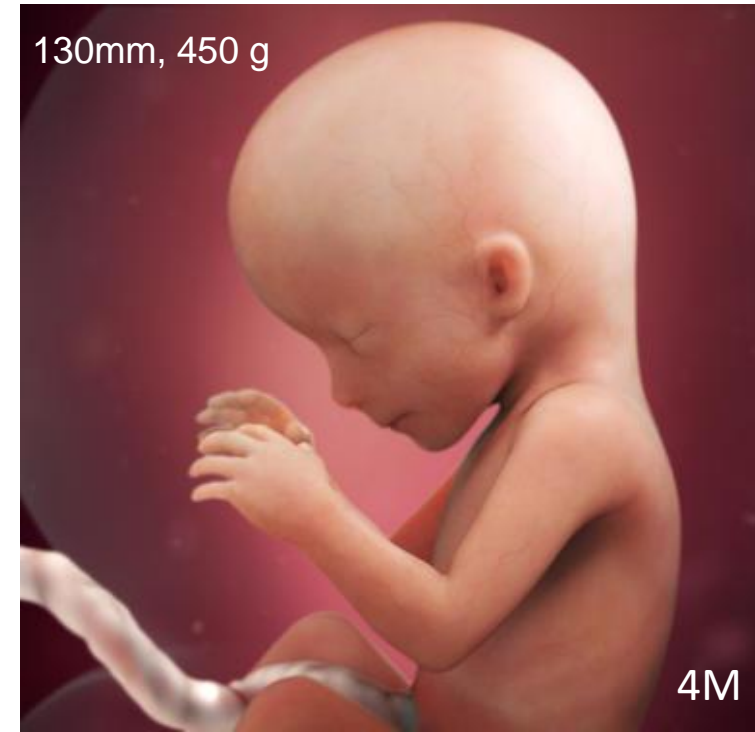
60-70mm, 150 g



3M



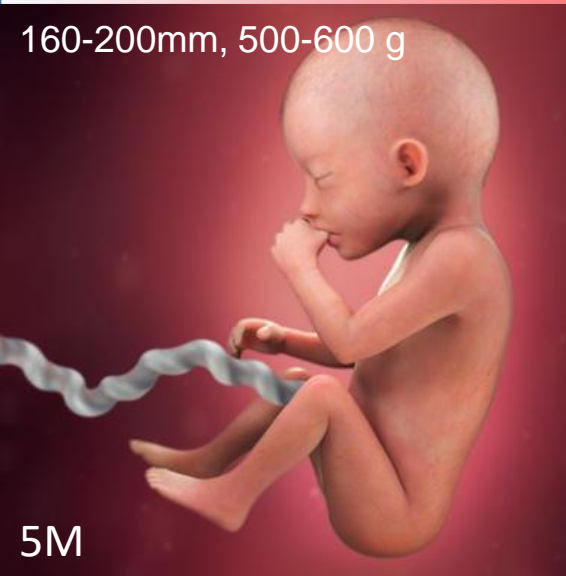130mm, 450 g



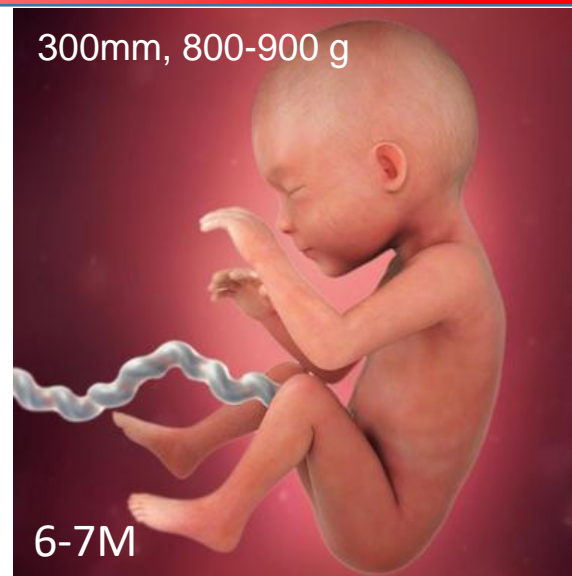
4M

- Fetus swallows amniotic fluid – necessary for GIT development
- Rapid growth of head (non-proportional to rest of body)
- Eyelids fuse
- Ossification centers visible by ultrasound examination
- Development of external genitalia
- Kidneys produce urine, other organs start to work
- Skeletal muscles innervated
- Physiological umbilical hernia, in 12th weeks reposition of intestinal loops

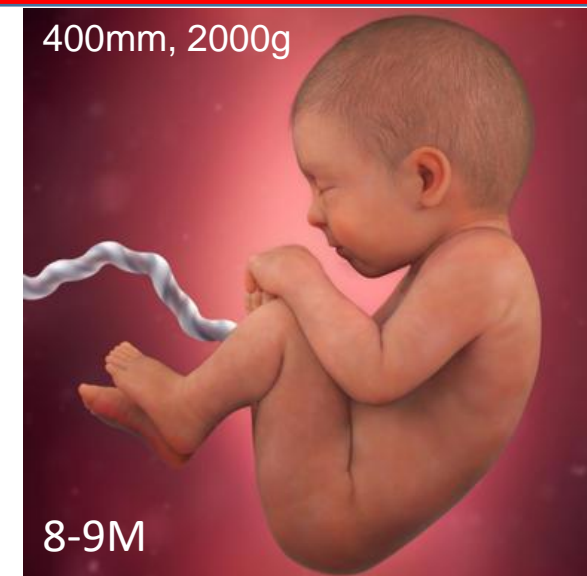
- Rapid growth of fetus
- Ossification of skeleton
- Face growths, mandible visible
- Apparent external genitalia



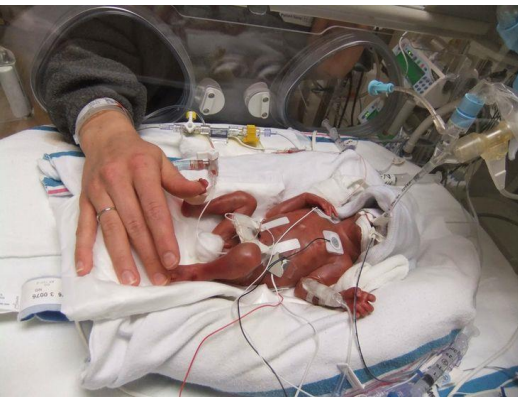- Limbs growth
- Mother feels fetal movements
- Vernix caseosa, lanugo
- Short hairs and eyelashes
- Fetus reacts to sound and later to light
- Lungs start to produce surfactant
- Limit of viability



- Eyelids open
- Wrinkled skin with visible capillaries
- Subcutaneous fat
- Hairs grow
- Maturing of organ systems



- Subcutaneous fat accumulates in limbs
- Smooth, red skin
- Hallmarks of full term fetus

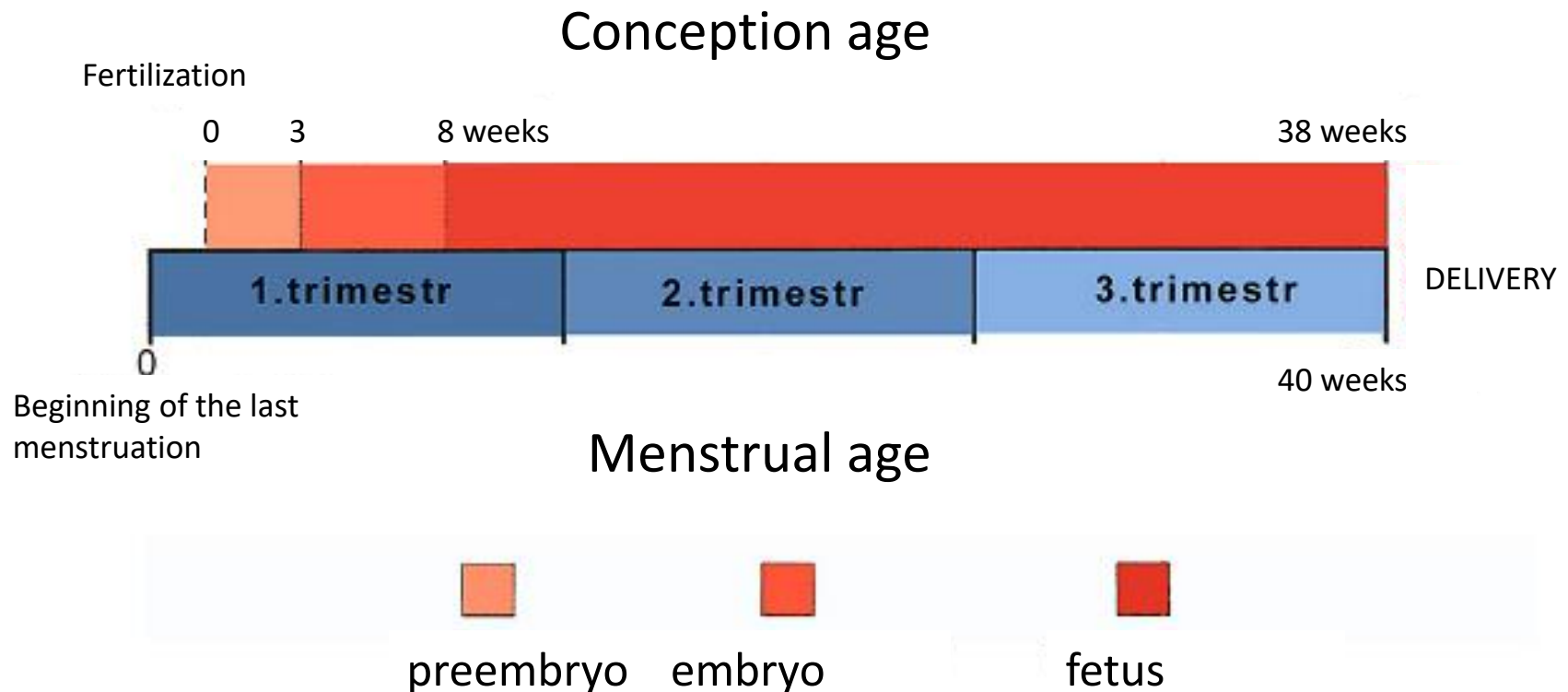


LENGTH OF PREGNANCY

280 days (= 40 weeks = 10 lunar months) from the first day of the last **menstruation**

266 days (= 38 weeks) **from ovulation** (gestation age)

Calculation of term: First day of the last **menstruation + 1 year– 3 months + 7 days**



Full term – related to length of pregnancy (menstrual age)

- preterm (<37 weeks)
- full term (38 – 40 weeks)
- after term (>42 weeks) (meconium in amniotic fluid)

Fetal maturity – development of fetus: **mature X immature**

HALLMARKS OF FETAL MATURITY

Major:

- **length (50 – 51 cm),**
- **weight** (around **3500 g**, physiological range 2500 - 4000g),
- head sizes
- boys - testes in scrotum, girls - labia majora over labia minora

Minor:

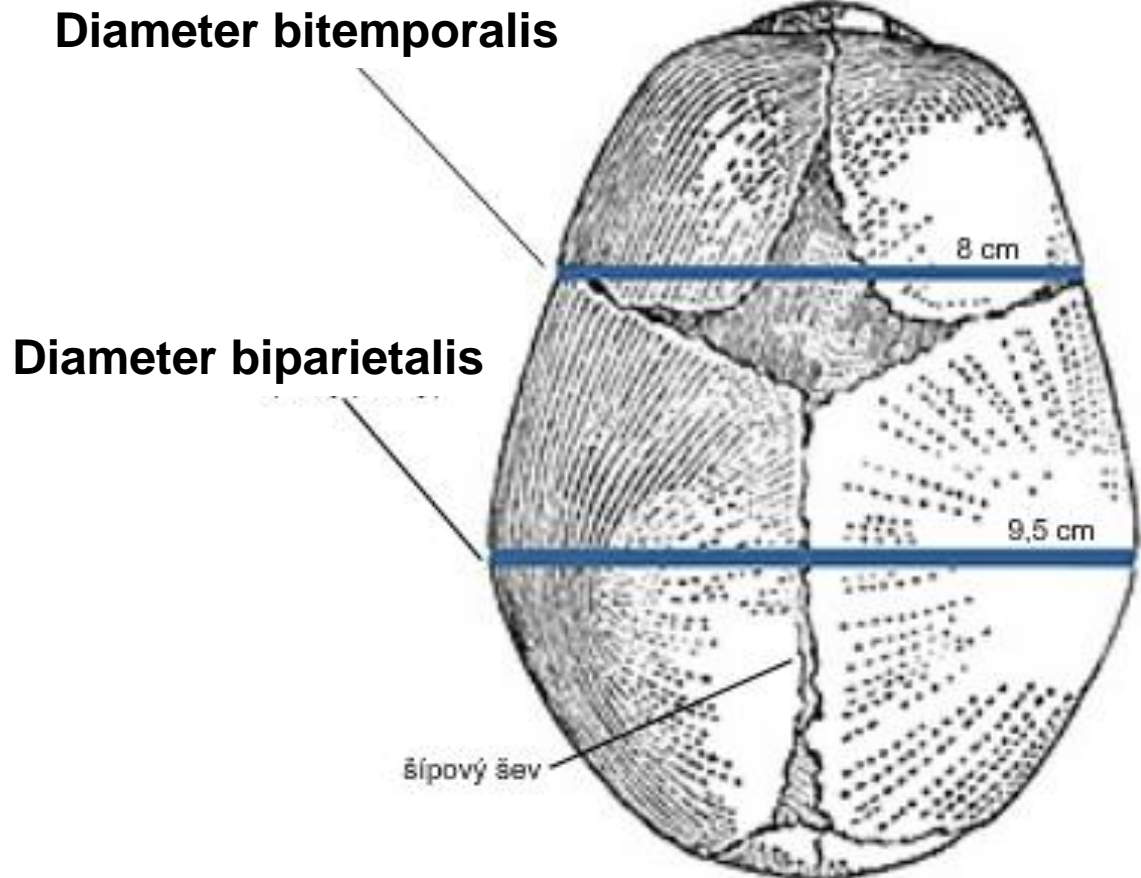
- eutrophic fetus, subcutaneous fat
- skin is not blue (no cyanosis), lanugo remains on shoulders and back,
- eyelashes, hairs several cm long, nails over fingertips
- cranial bones hard, anterior and posterior fontanelle are palpable, and separated
- newborn cries and moves (Apgar score)

Diameter bitemporalis – 8,00 cm

(join of the most distant points on sutura coronaria)

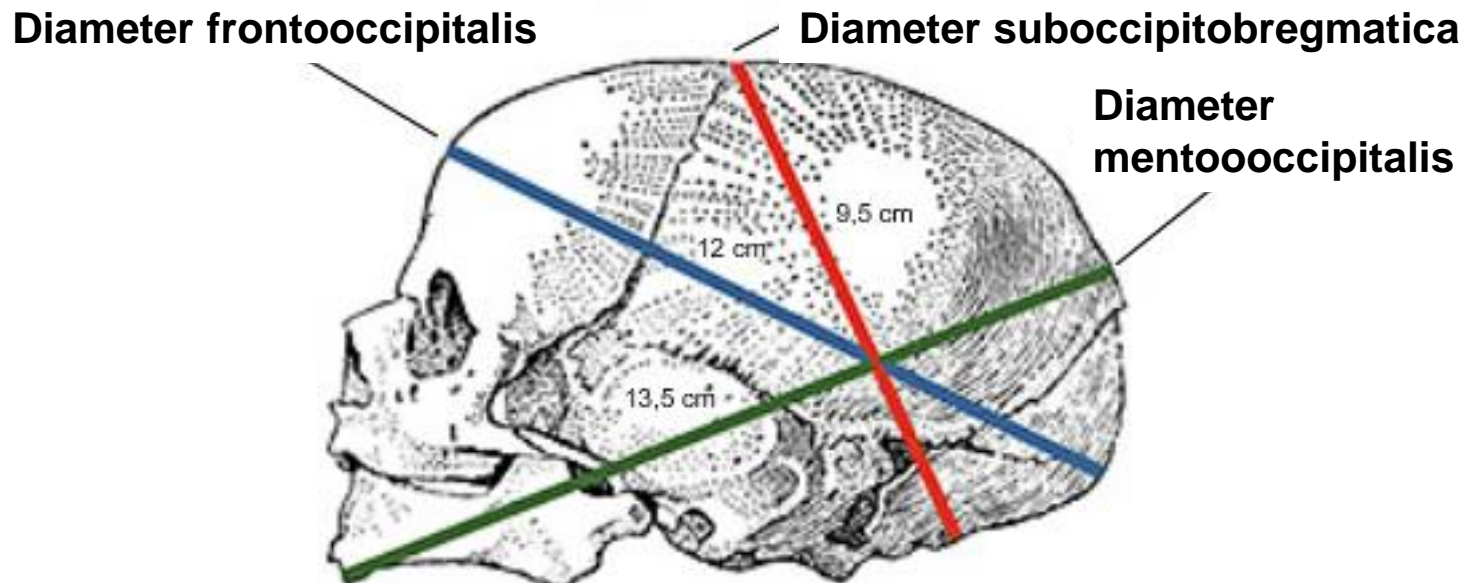
Diameter biparietalis – 9,5 cm

(join of midpoints of tubera parietalia)



Oblique sizes:

- **Diameter frontooccipitalis – 12.0 cm** (join of forehead midpoint and most distant point of occiput)
- **Circumferentia frontooccipitalis – 34.0 cm**
- **Diameter suboccipitobregmatica – 9.5 cm** (join of protuberantia occipitalis externa and midpoint of large fontanelle)
- **Circumferentia suboccipitobregmatica – 32.0 cm**
- **Diameter mentooccipitalis – 13.5 cm** (join of chin midpoint and most distant point of occiput)
- **circumferentia mentooccipitalis – 35 - 36 cm**
- **Diameter biacromialis – 12.0 cm, circumferentia biacromialis – 35 cm**
(join of acromion – acromion)



RULE OF HAASE

- forensic medicine

3. – 5. lunar month: length in cm = square of month

6. – 10. lunar month: length in cm = months multiplied by 5

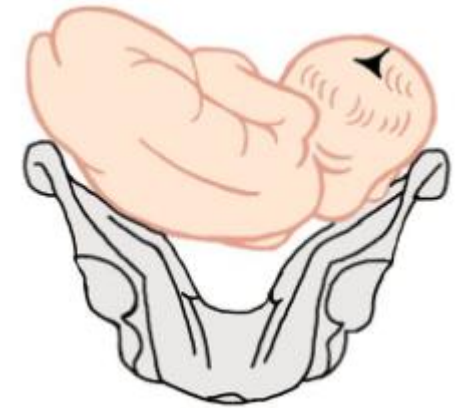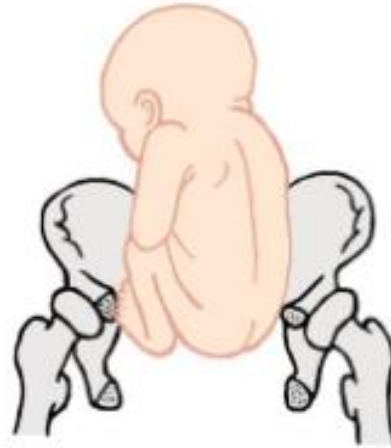
Lunar month	Length of fetus[cm]
3	9
4	16
5	25
6	30
7	35
8	40
9	45
10	50

FETUS IN UTERUS

1. **LIE (*SITUS*)** = relationship of the long axis of the fetus to that of the mother
 - longitudinal: (99 %)
 - transverse: (1 %) perpendicular axes
 - oblique: unstable → longitudinal or transverse position
2. **POSITION (*POSITIO*)** = fetal backbone relative to uterus margin
 - first= left (back to the left)
 - second= right (back to the right)
 - first/second common/less common
3. **FETAL HABITUS (*HABITUS*)** = relationship of one fetal part to another
 - regular = head and limbs in flexion
 - irregular = everything else
4. **PRESENTATION (*PRAESENTATIO*)** = that part of the fetus lying over the pelvic inlet; the presenting body part of the fetus.
 - occiput (most common)
 - vertex, forehead, face (1%)
 - breech
 - trunk, shoulder

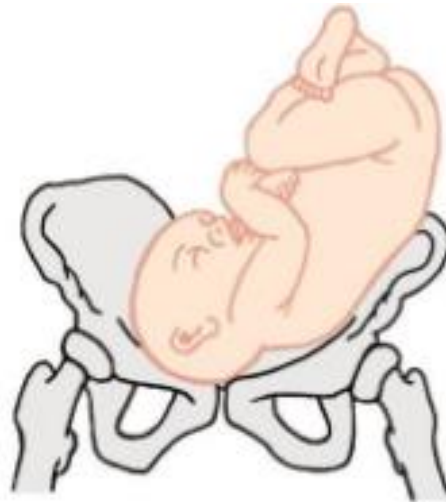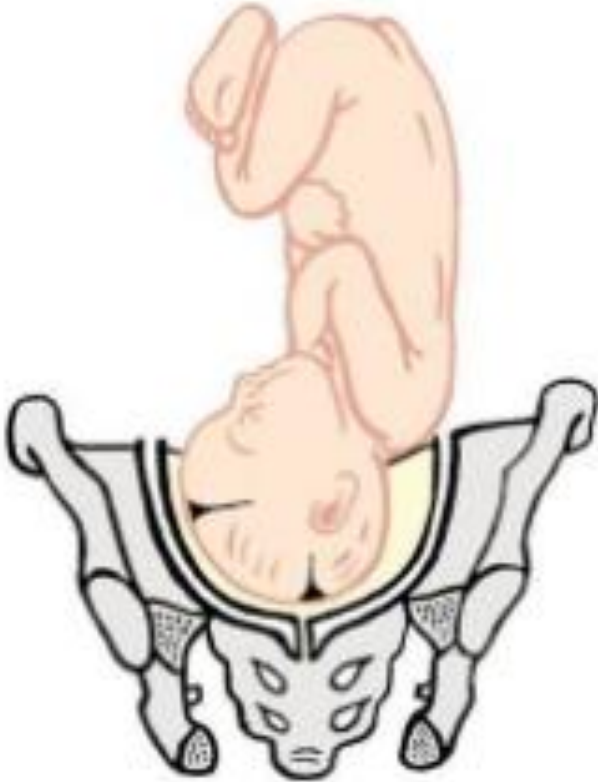FETUS IN UTERUS

longitudinal - occiput



longitudinal - breech

transverse



oblique

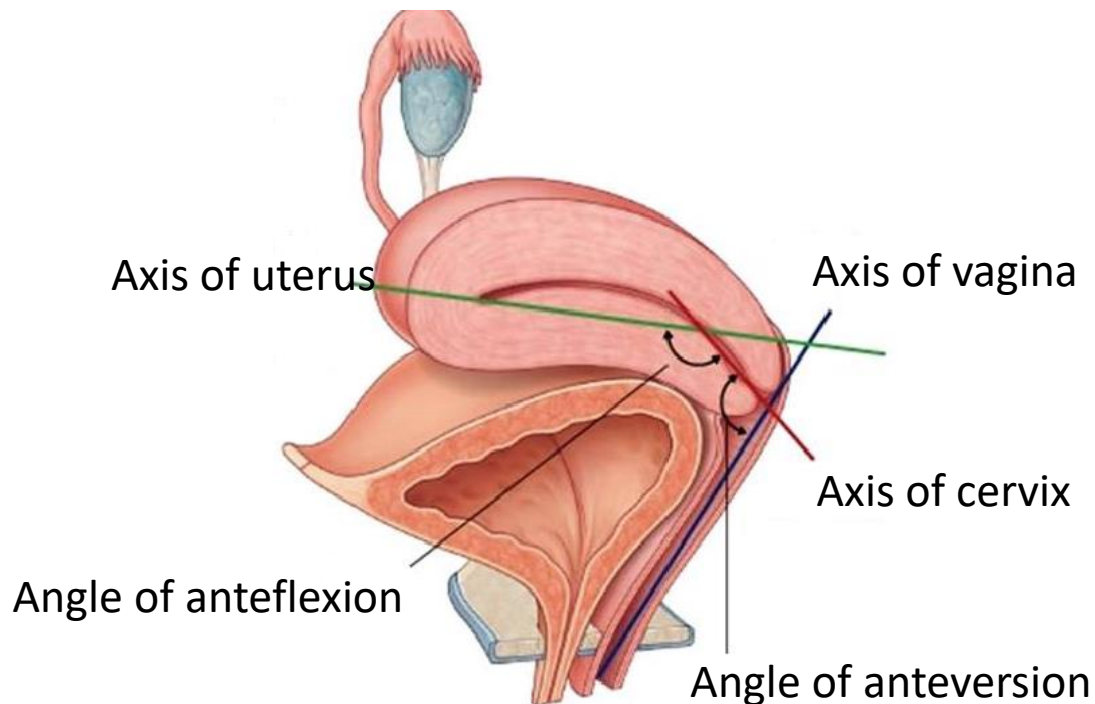
POSITION OF FETUS

Relationship of fetus backbone to uterine margins (margo uteri sin., dx.) and pelvis

Normal position

anteversion (angle of vagina and uterus – facing forward – 70-100°)

anteflexion (angle of uterine isthmus and body – tilting forward – 160-170°)



Rotation and tilting of the uterus to the right
or to the left in late pregnancy



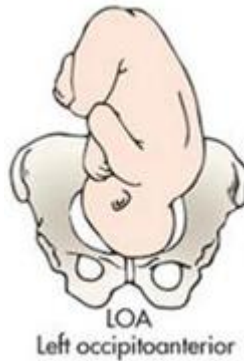Dextroversion, dextrotorsion
Sinistroversion, sinistrotorsion

POSITION OF FETUS

1. COMMON

(left occipitoanterior)

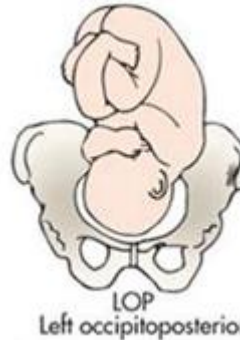Uterus in dextrotorsion
Backbone left and forwards



1. LESS COMMON

(left occipitoposterior)

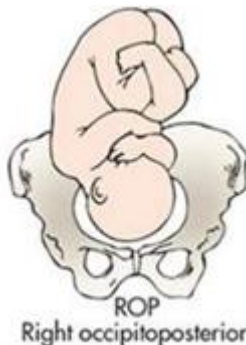Uterus in sinistrotorsion
Backbone left and backwards



2. COMMON

(right occipitoposterior)

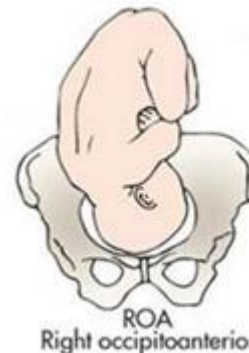
Uterus in dextrotorsion
Backbone right and backwards



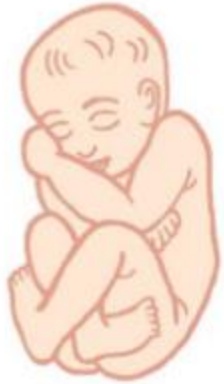2. LESS COMMON

(right occipitoanterior)

Uterus in sinistrotorsion
Backbone right and forwards



HABITUS AND PRESENTATION



HABITUS

irregular (any other)

regular

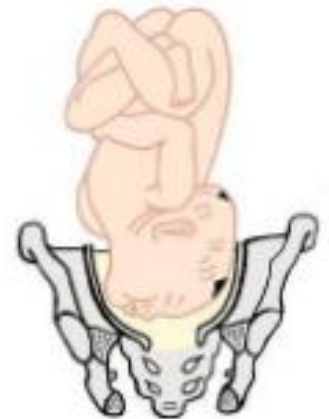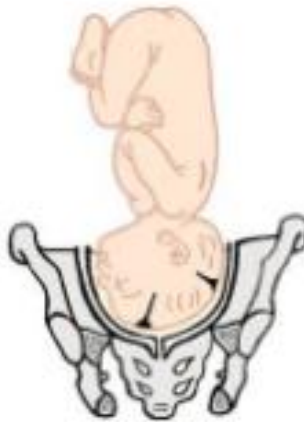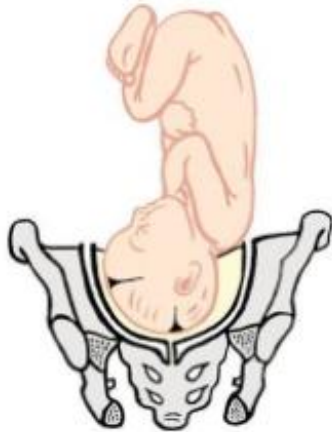PRESENTATION

occiput

vertex

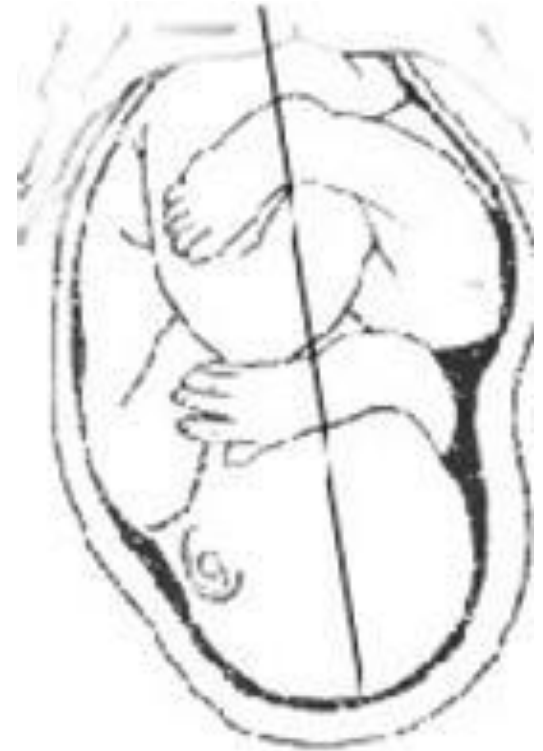forehead

face



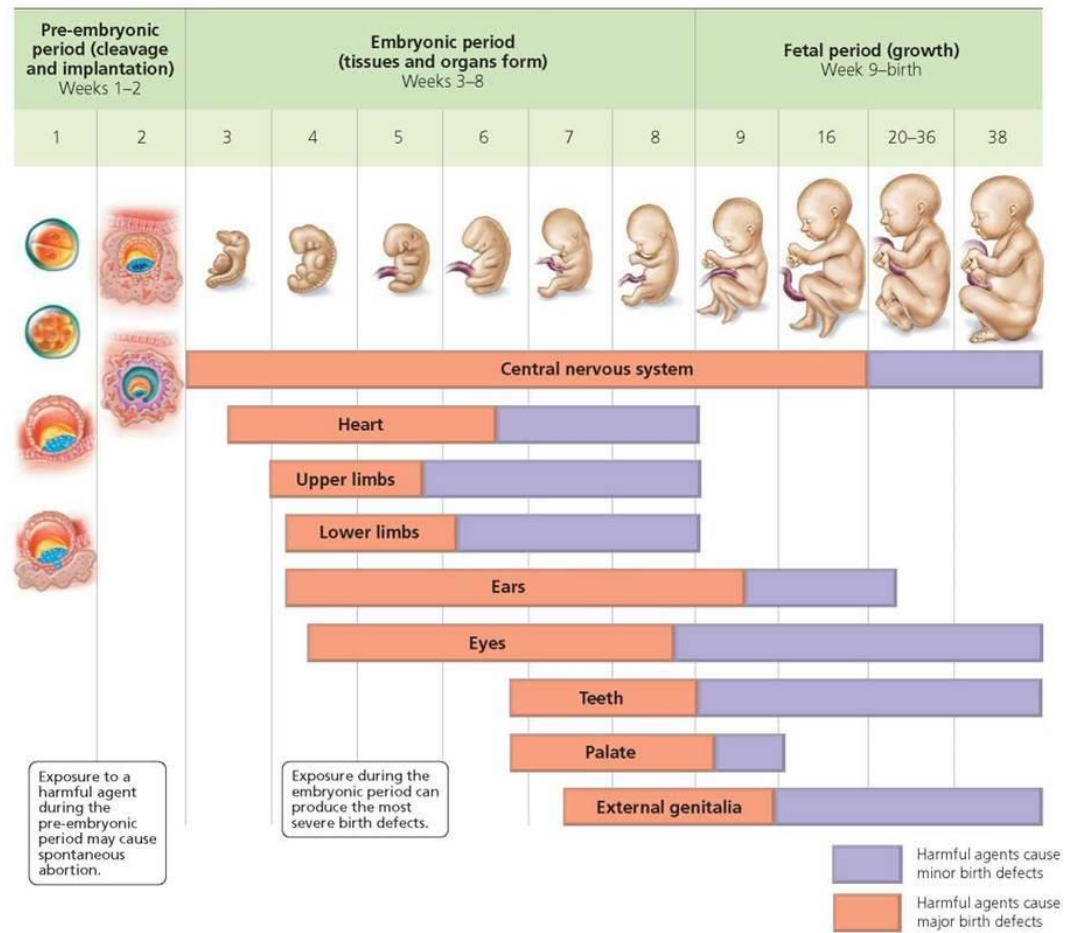
PHYSIOLOGICAL POSITION OF FETUS IN UTERO

- LIE LONGITUDINAL - HEAD FIRST
- POSITION FIRST COMMON
- HABITUS REGULAR
- PRESENTATION - OCCIPUT



INTRODUCTION TO TERATOLOGY

- Congenital disorders – due to abnormal developmental events
- Genetic (inherited) or nongenetic (external) causes
- Teratogens
- Critical developmental periods
- Life style (alcohol, smoking, drugs)
- Infections (rubeola, HIV, toxoplasmosis)
- Lack or abundance of key substances (folic acid × retinoids)
- Chronic diseases (medical treatment)

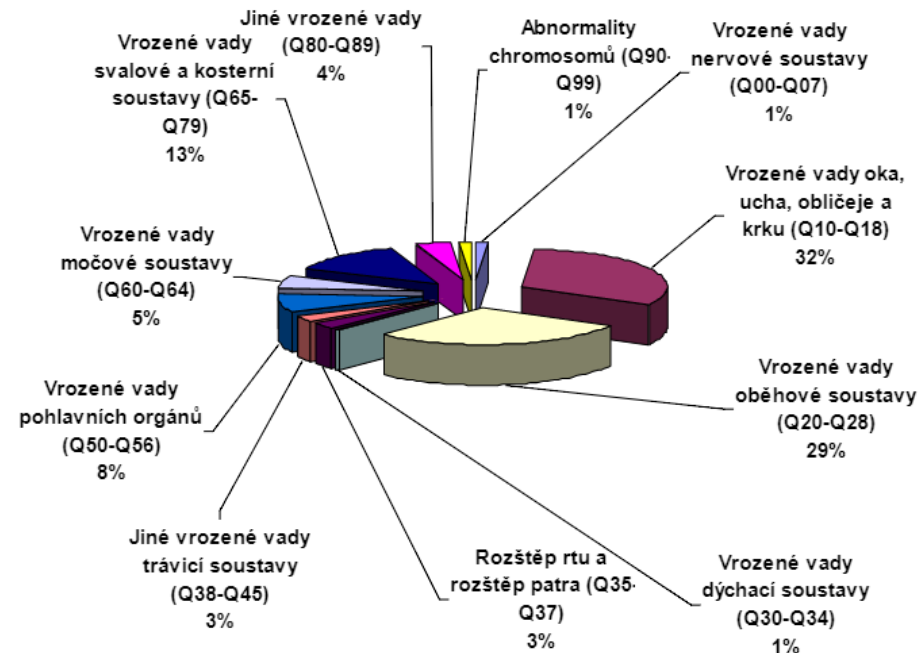


INTRODUCTION TO PRENATAL DIAGNOSTICS

- Interdisciplinary care – biochemistry, genetics, gynecology and obstetrics, neonatology – parts of fetal medicine
- Revealing high risk pregnancies, access to preventive and therapeutic care
- Preventing delivery of fetuses with severe congenital malformations
- Support of delivery of genetically high-risk babies
- Planning and providing clinical care

- Genetic counselling
- Biochemical and ultrasound screening
- Karyotyping and DNA diagnostics
- Clinical diagnostics

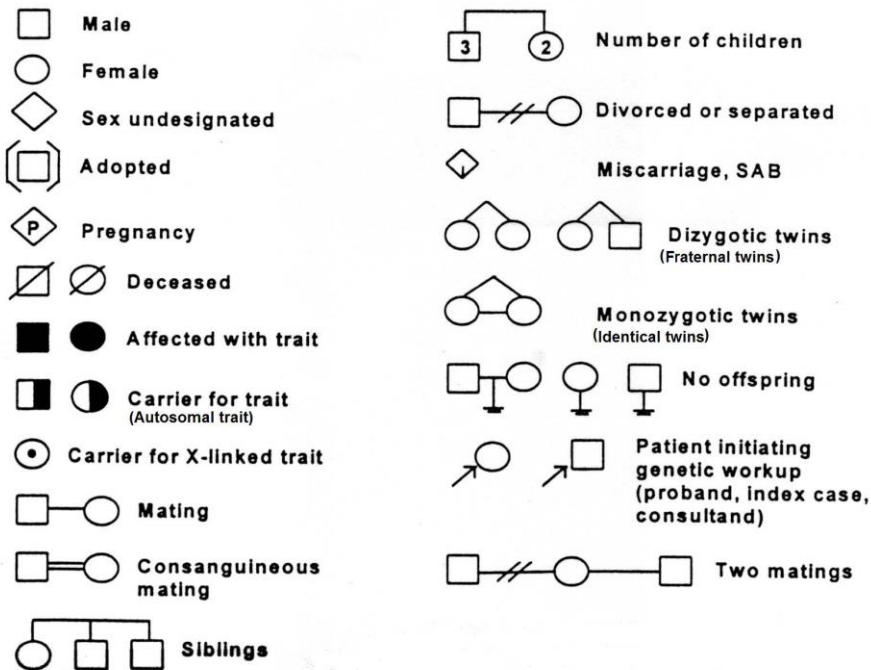
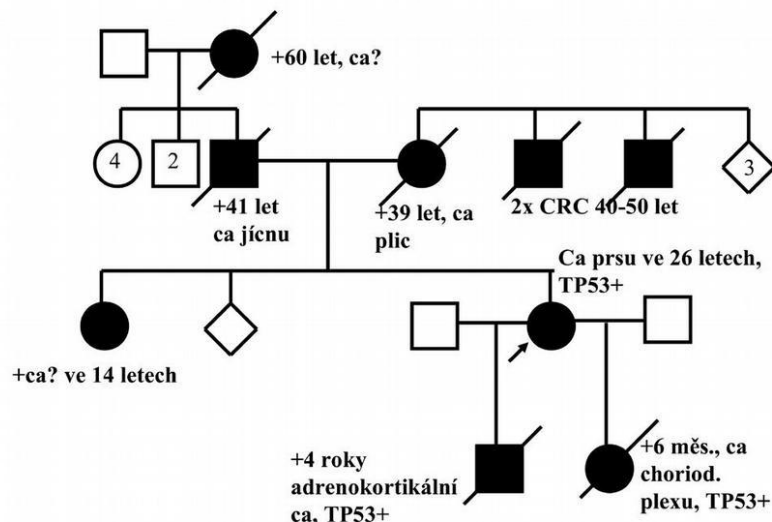
- Indication:
 - congenital disorders in family
 - positive screening in 1st or 2nd trimester
 - abnormal finding by ultrasound
 - maternal age (over 35 years)



ČR 1994-2008

GENETIC COUNSELING

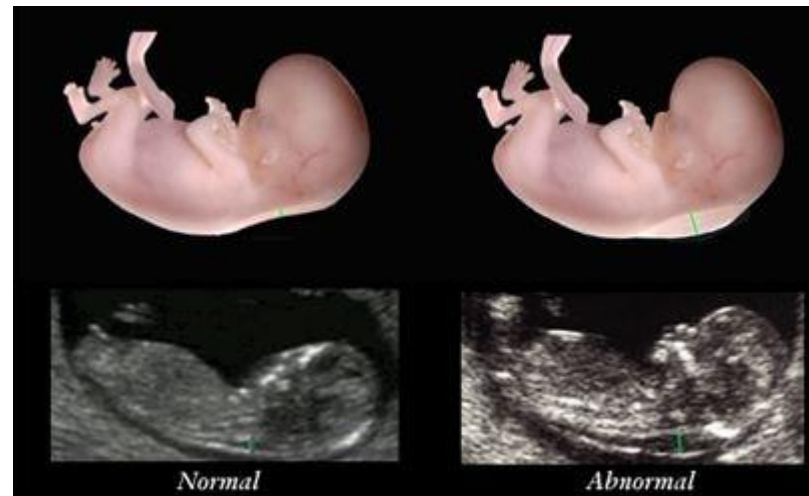
- Anamnesis (case history)
- Preconception counselling
- Explaining of examination results, causes, clinical symptoms, therapeutic options
- Minimization of risk of repeated disease
- Providing diagnosis and information for free choice
- Providing precise diagnosis and risk estimation
- Providing care during pregnancy and later



NONDIRECTIVE
 ALL EXAMINATIONS AND
 PROCEDURES ARE VOLUNTARY

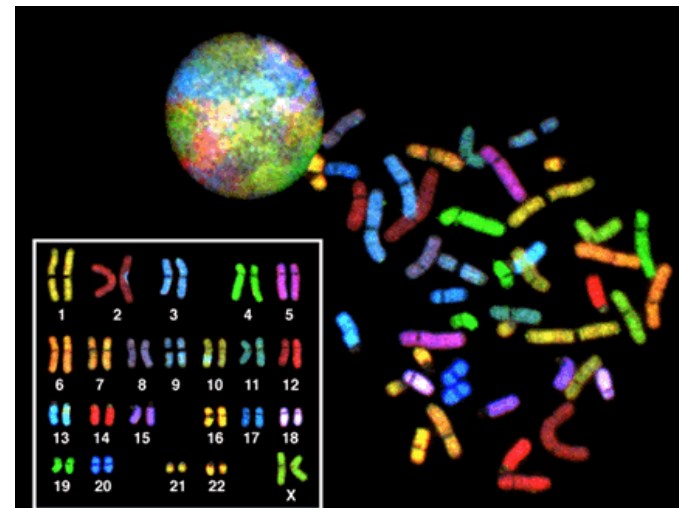
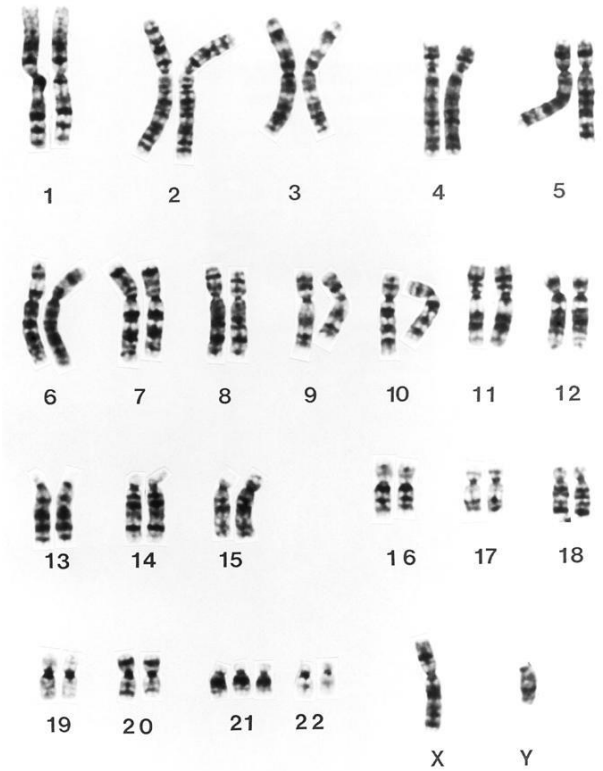
BIOCHEMICAL SCREENING

- Non invasive
 - Revealing high risk pregnancies – chromosomal aberrations and clefts
 - **Screening is not a diagnostics** → further examinations (amniocentesis, karyotype, US)
- Tests between weeks 14-16 („TRIPLE test“)
 - low sensitivity and specificity (50-60%), high false positivity (70%)
 - AFP, E3, hCG
 - chromosomal aberrations, abnormal closing of neural tube, defects of body walls
- Combined screening in week 11-13
 - chromosomal aberrations – Down: 47,XY,+21, Edwards: 47,XY,+18, Patau 47,XY,+18
 - US –nuchal translucence, NT
 - PAPP-A, hCG (multiplies of median, MoM)
 - age included in algorithm
 - output: screening positive vs. negative (limit 1:100)



INVASIVE DIAGNOSTICS

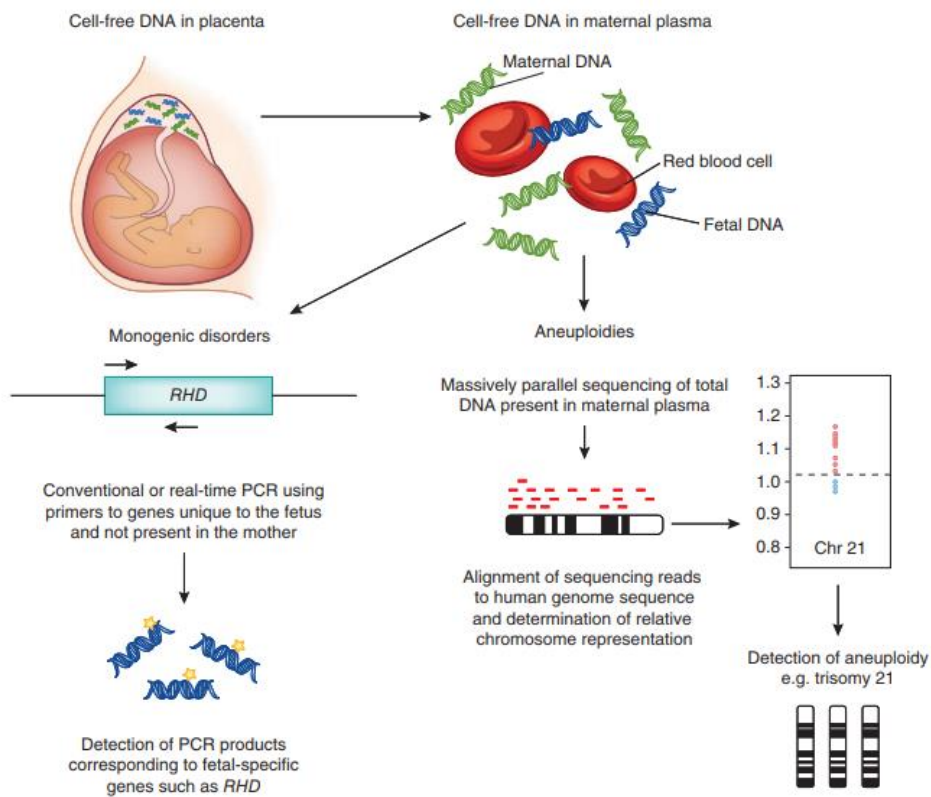
- Amniocentesis
 - 16th-20th week
 - US controlled amniotic fluid aspiration
 - Cell culture, karyotype
 - Risk of miscarriage 0.5-1%
- Chorion villus biopsy
 - 10th-13th week
 - Karyotype, molecular genetic examination
 - Risk 0.5-1%
- Cordocentesis
 - 22nd week
 - Sampling of venous umbilical blood
 - Now diagnostics and therapy of blood diseases (anemia, infections), or diagnostics in multiple pregnancies
 - Risk 1%
- Fetoscopy
 - Transabdominally (earlier transcervically)
 - Visualization and fetal biopsy
 - Risk 3-10%, done rarely



ULTRASOUND DIAGNOSTICS

- 6-8th week
 - confirmation of pregnancy, heart action
 - number of fetuses
- 13-14th week
 - nuchal translucence (risk > 3 mm)
 - nasal bone (present × absent), **minor markers** (omphalocele, tricuspidal regurgitation, abnormality in ductus venosus flow, enlargement of urinary bladder-megavesica)
 - fetal size
- 20-22nd week
 - detailed screening
 - fetal biometry (biparietal diameter, head circumference, length of femur)
 - head and CNS (shape, cavity in septum pellucidum, ventricles, cerebellum, cisterna magna), face (lip, jaws, nose, orbits, profile), heart (action, size, axis, 4-chamber projection, outflow tracts, ...), thorax (pathological structures), abdominal cavity (stomach, intestine, kidneys, urinary bladder, umbilicus and umbilical vessels), backbone, limbs, palms, feet
 - placenta, volume of amniotic fluid
- 30th week
 - fetal size
 - volume of amniotic fluid
 - placenta (exclusion of *placenta praevia*)

ADVANCEMENTS IN MOLECULAR GENETICS



Analysis of cell-free fetal DNA in maternal blood
 Since 12th week
 Massive parallel sequencing (Next-Gen Sequencing)
 Common aneuploidies (trisomy 21,13,18)
 Monogeneous disorders

SOP-M8 NEINVAZIVNÍ DETEKCE ANEUPLOIDIÍ CHROMOZOMŮ 13, 18 A 21 POMOCÍ MULTIPLEX PCR A MASIVNÍHO PARALELNÍHO SEKVENOVÁNÍ (MPS)

Test Clarigo se značkou „CE“, která je nezbytná pro provedení tohoto vyšetření v zemích EU, splňuje základní požadavky Směrnice Rady IVD 98/79/EC pro *in vitro* diagnostiku.

VÝSLEDEK VYŠETŘENÍ:

Chromozom	Stav	Fetální frakce	Předpokládané pohlaví plodu
13	normální	7,1 %	ženské
18	normální		
21	normální		

ZÁVĚR:

Analýzou volné fetální DNA cirkulující v krvi těhotné nebylo zjištěno zvýšené riziko aneuploidie chromozomů 13, 18 a 21.

Komentář: doporučujeme genetickou konzultaci.

Pozn: Při patologickém nálezů je výsledek nutné ověřit některým z invazivních postupů (např. odběr plodové vody, choriových klků, kordocentéza s následnou QF-PCR analýzou nebo stanovením klasického karyotypu apod.).

SUMMARY

- Early embryogenesis
 - From fertilization to a blastocyst
 - Bilaminar and trilaminar germ disc
 - Axial structures of the embryo
 - Notochord and neurulation
 - Definition of germ layers and mesoderm specification
 - Folding of the embryo and beginning of organogenesis
- Development and maturation of fetus
 - Time periods in fetal development
 - Length of pregnancy and hallmarks of full-term/mature fetus
 - Position of fetus in utero
 - Introduction to prenatal screening and diagnostics
 - Introduction to teratology

THANK YOU FOR ATTENTION

QUESTIONS & COMMENTS

pvanhara@med.muni.cz
<http://www.histology.med.muni.cz>